

ESSAYS
IN
SURGICAL ANATOMY AND SURGERY.

AN ESSAY UPON THE SURGICAL ANATOMY AND HISTORY
OF THE COMMON, EXTERNAL, AND INTERNAL
CAROTID ARTERIES.

AWARDED THE FIRST PRIZE OF THE AMERICAN MEDICAL ASSOCIATION,
JUNE, 1878.

AN ESSAY UPON THE SURGICAL ANATOMY AND HISTORY
OF THE INNOMINATE AND SUBCLAVIAN
ARTERIES.

AWARDED THE SECOND PRIZE OF THE AMERICAN MEDICAL ASSOCIATION,
JUNE, 1878.

AN ESSAY UPON THE SURGICAL ANATOMY OF THE
TIBIO-TARSAL REGION.

AWARDED THE (JAMES R. WOOD) ANNUAL PRIZE OF THE ALUMNI ASSOCIATION
OF THE BELLEVUE HOSPITAL MEDICAL COLLEGE, 1876.

AN ESSAY UPON THE SURGICAL ANATOMY OF THE
OBTURATOR ARTERY, AND NOTES UPON
THE SURGICAL ANATOMY OF
THE HIP-JOINT.

BY

JOHN A. WYETH, M.D.,
(UNIVERSITY OF LOUISVILLE,)

Member of the New York County Medical Society, the New York Pathological Society;
Honorary Member of the College of Physicians and Surgeons
of Little Rock, Arkansas.

NEW YORK:
WILLIAM WOOD & CO., PUBLISHERS,
27 GREAT JONES STREET.

1879.

PHILADELPHIA :
COLLINS, PRINTER,
705 Jayne Street.



RD 14
W 97
1879

REPORT OF THE COMMITTEE ON PRIZE ESSAYS.

YOUR Committee to determine the merits of prize essays would respectfully report: That they have had three separate papers submitted to their inspection. Two of these papers present subjects of very great interest and show original researches, but are too imperfect in the estimation of the Committee to command a prize. The remaining paper, in the judgment of your Committee, is fully up to the requirements. Indeed, the paper is so elaborate as to fill a large space in the volume of the Transactions of the Association. The paper should be considered as *two*, and not as *one*. The analysis of 789 cases of operation on the carotid artery, and the careful and minute measurements of the artery and its branches in 121 subjects, showing the range of variation and the percentage of the same, followed by inferences, bold and original, naturally constitutes a paper complete in itself. Another one on the same plan with reference to the innominate and subclavian, being an analysis of 300 cases, and the observation of 52 subjects, is presented to us in such a manner that we may consider the whole as one prize, or they may compete for both.

Your Committee believe that both prizes should be awarded to the two essays by one person. The motto is "*Tempora mutantur et nos mutamur in illis.*"

E. M. MOORE, *Chairman.*
THOS. LOTHROP,
H. R. HOPKINS,
W. W. MINER.

BUFFALO, N. Y., June 6, 1878.

TO

HIS FRIEND,

S. S. LAWS, A.M., D.D., LL.D., M.D.,
PRESIDENT OF THE MISSOURI STATE UNIVERSITY,

THE AUTHOR

BEGS LEAVE TO INSCRIBE

These Essays.

P R E F A C E.

I HAVE been encouraged to offer to the profession, in a complete volume, these "Essays on Surgical Anatomy and Surgery," since separately they have been received with such marked favor by gentlemen eminently qualified to judge of their respective merits. It is gratifying to know that they have already been accepted as standard contributions to surgical and anatomical literature, and that the conclusions arrived at are taught in the lecture-rooms of some of our leading medical colleges. Three of these essays (and only three) were offered in competition for prizes given by liberal associations, and in each instance with gratifying success. I am under lasting obligations to the Committee on Publication of the American Medical Association, and to the Alumni Association Prize Committee for the privilege of publishing these Essays in other than their original form.

The dissections embodied in these Essays were made in every instance by myself, and the measurements were noted at the time. The deductions are positive. No less positive the conviction, that "Surgical Anatomy" has not heretofore, nor does it now receive that careful consideration its vast importance demands. How few graduates of American colleges, who either practice surgery or put themselves in a position where an emergency may require them to undertake a dangerous surgical procedure, are equal to the occasion! While it is true that for the majority of operations the practitioner has time and may make the opportunity to prepare himself for any given case, by special dissections, yet the time does come to all when instant and decisive action is required; when the patient's life, dependent upon his skill and that self-possession which comes from a consciousness of careful preparation, hangs by such a slender thread that one mistake alone is fatal. Is it not close to the border-land of criminality to place one's self in this position?

And yet I have heard teachers in great American colleges say that "too much anatomy was dangerous," and have heard it instilled into the minds of students that it was a good maxim, "to cut when it

was necessary, and tie what was cut." From such teachings has sprung the lack of preparation, and from both, the reckless practice which is called Surgery; a practice which would ligature a large artery for a lesion involving an insignificant branch, the former easily performed and dangerous in its results, the latter more difficult but trifling in its consequences.

In the winter of 1876, in some statements made before the New York County Medical Society, upon the subject of one of these Essays upon which I was then engaged, I earnestly censured the practice of tying the *common carotid* for any lesion of the *external carotid* or its branches, when there was one-half an inch between the lesion and the bifurcation of the *primitive trunk*. My conclusions met with the approval of two eminent surgeons, themselves Professors of Surgical Anatomy in the College of Physicians and Surgeons and the Bellevue Hospital College, and within the last year several younger American surgeons have with creditable skill ligatured the branches of the *external carotid*, rather than tie the *common trunk*.¹ These few instances, with those gathered in these pages, will, I hope, inaugurate a new era in the operative surgery of the neck, and will furthermore encourage younger men not to accept any procedure, no matter how high the authority which endorses it, unless it stands the test of a critical analysis.

In gleaning from the almost boundless field of professional literature the "Surgical Histories of the Great Vessels of the Neck," it has been my aim to arrive at the truth, positive and indisputable. I have accepted nothing that was not satisfactorily stated, not wishing to swell the manuscript with irrelevant matter. To this end I have omitted several hundred cases of deligation of these vessels, heretofore published; those of the *subclavian*² artery when from the description of the operation I was satisfied that the *axillary* was the vessel tied; those of the other vessels when the results were not given, or the operation couched in uncertain terms.

Besides the published cases I have been fortunate in obtaining many operations from private sources in answer to a circular letter of inquiry sent to every quarter of the civilized world. To each of these gentlemen who so courteously responded I beg to express my

¹ Prof. Jos. W. Howe has recently tied both lingual arteries below the posterior belly of the digastric. Dr. George F. Shrady performed the same operation upon the lingual of one side. Prof. L. A. Stimson tied both linguals above the hyoid bone behind the hyo-glossus.

² The subclavian is considered as terminating at the lower border of the first rib.

obligations for the generous contributions to the success of my undertaking. My thanks are especially due to my friend, the late Professor Alpheus B. Crosby, and to Professor Edward G. Janeway, for the use of dissecting material under their control, which would with difficulty have been obtained elsewhere, and without which my investigations could not have been so fully completed. I beg to acknowledge my obligations to the Society of the New York Hospital for the use of their magnificent library, and to the many courtesies extended to me by Dr. Vandervoort and son, the librarians; to the New York Medical Journal Association, and to Professor A. B. Mott for the use of the private notes of operations by his distinguished father.

I have received valuable assistance from the following works: "Contributions to Practical Surgery,"¹ by Dr. George W. Norris, of Philadelphia; an admirable article by Dr. Ch. Piltz, "Zur Ligatur der Arteria Carotis Communis;"² "Ligature of the Common Carotid," by Prof. Jas. R. Wood;³ "Des Effets Produits sur l'Encéphale," etc., by Dr. J. Ehrmann;⁴ a "Prize Thesis on Ligature of the External Carotid Artery,"⁵ by Dr. Landon R. Longworth; "Zur Ligatur der Arteria Carotis Externa,"⁶ by Dr. Madelung; "Medical and Surgical History of the War," by Dr. Geo. A. Otis, U.S.A.; "Ligature of the Subclavian Artery,"⁷ by Prof. Willard Parker; "Ueber Unterbindungen und Aneurysmen der Arteria Subclavia,"⁸ by Wilhelm Koch; and to a magnificent paper on "Subclavian Aneurism,"⁹ by the lamented Alfred Poland.

These various publications I have used for reference to the original article, which I have consulted when it was available; when not available I copied directly from the article accredited. I am indebted to my pupils, Drs. W. L. Wardwell and M. C. Wyeth, for much valuable assistance in reviewing the voluminous manuscript.

It is impossible not to be attracted by the startling mortality following these capital operations upon the *common carotid*, *innominate* and *subclavian* arteries; operations which have been and are now taught and practised as justifiable procedures by many eminent men. And are we not justified in believing that this death-rate

¹ Lindsay & Blakiston, Philadelphia, 1873.

² Archiv für Klinische Chirurgie, 1868.

³ New York Medical Journal, 1856.

⁵ G. P. Putnam's Sons, New York, 1873.

⁷ New York Medical Record.

⁹ Guy's Hospital Reports, London.

⁴ J. B. Baillièrè, Paris, 1860.

⁶ Archiv für Klinische Chirurgie.

⁸ Archiv für Klinische Chirurgie, 1869.

would be shown to be still greater if all of the unsuccessful cases were made public; if every surgeon was honest enough to acknowledge publicly his failures as we are all willing to herald our successes?

In the Essay upon the Surgical Anatomy and History of the Carotid Arteries, I claim to prove that ligature of the *common carotid* for a lesion of the *external carotid* or its branches, when there is half an inch between the seat of lesion and the origin of the *external carotid*, is *wrong in principle, unsafe in practice, and should cease to be a surgical procedure*. The deligation of the *common carotid* is and has been the almost universal teaching and practice, the objections to tying the *external* being that the origins of the branches of this artery were usually so close together and so irregular in their relations (the *anatomical* objection), while the danger of hemorrhage was the *clinical* objection.

I have proven, in the analysis of one hundred and twenty-one consecutive and carefully measured dissections of the three *carotids*, that the anatomical objection has been greatly exaggerated and does not contra-indicate the ligature of the *external carotid*, while the analysis of the Surgical Histories of these vessels, containing 898 carefully collected cases, shows the death-rate after ligature of the *common carotid* to be 41 per cent.; that of the *external carotid* to be only $4\frac{1}{2}$ per cent.!

Surgery as a Progressive Science must abandon any practice which endangers human life, when a safer method is demonstrated.

I hold it to be bad surgery which places a ligature upon the *common carotid* for a wound of the *internal carotid* artery.

The proper procedure is given in the text. I believe it to be bad surgery which places a ligature upon the *common carotid* for a lesion of the *vertebral* artery. The method of differentiation is demonstrated in the text.

In the Essay upon the "Innominate and Subclavian Arteries," I claim to prove that ligature of the *arteria innominata* on account of aneurism is not a justifiable operation, and that ligature of the *subclavian* arteries (more especially the right) in their first surgical divisions on account of aneurism is alike unjustifiable. Nature left to her own resources is more successful than the surgery which ties these vessels; while the methods which belong to Conservative Surgery are given, which are still more successful in the alleviation of suffering and the preservation of life.

The very exceptional conditions in which these vessels may require the ligature are mentioned hereafter.


I believe that the mortality of 65 per cent. following ligature of the *subclavian* arteries in their 3d surgical divisions on account of hemorrhage; and the mortality of 43 per cent. after ligature of these vessels in their 3d divisions on account of aneurism, are unnecessarily great, and that the methods of decreasing this mortality are demonstrated.

The article on the Obturator Artery was originally published in the *New York Medical Record*, and those on the Hip Joint in Professor Sayres' popular work on "Orthopedic Surgery and Diseases of the Joints."

The "Essay on the Surgical Anatomy of the Tibio-Tarsal Region" was published in the *American Journal of the Medical Sciences* in 1876. I discovered that the arterial distribution in this region was not correctly described by the popular text books on anatomy, and I believed that the frequent surgical operations at the ankle-joint based upon a wrong idea of the anatomy were not so safe as those founded upon a close and minute understanding of the relations of the vessels at this point. Subsequent reflection has not changed my convictions upon this subject.

In conclusion, conscious that I have labored earnestly to arrive at the truth; alike conscious that no human undertaking can be utterly free from error, I offer these essays to the medical profession without an apology, feeling assured that what is worth enduring in them will endure.

JNO. A. WYETH.



THE SURGICAL ANATOMY
OF THE
COMMON, INTERNAL, AND EXTERNAL CAROTID
ARTERIES.

FROM their exposed position in the neck, that portion of the human body least protected from violence, the Carotid Arteries and their branches are more often the seat of lesions requiring surgical interference than any other vessels.

This clinical fact, which (in connection with their distribution to the great nervous centre), makes them of most vital interest to the surgeon, together with the varying descriptions of these vessels by different anatomists, and the frightful mortality following the deligation of the *common* trunk to which my attention was called when a student;—are among the reasons which led me to undertake the labor embodied in this essay.

THE COMMON CAROTIDS.

Anatomists agree, without exception, that the *common carotid* arteries bifurcate into the *external* and *internal* carotids, almost invariably on a level with the notch between the two *alæ* of the *thyroid cartilage*; this varying slightly as the head is moved forward or backward. In what is known as the “surgical position” of the neck, that is with the shoulders slightly elevated and the head thrown back and a little below the axis of the body in the recumbent position, there will be found nothing so constant in the anatomy of the arteries as the relation of the termination of the *common carotid* to the upper border of the *thyroid cartilage*.

In 121 instances, 116 bifurcated at this point. In four cases the bifurcation was respectively one-fourth, one-half, three-fourths, and one inch above this line. In the fifth case the *internal carotid* was

wanting, but the small *common* trunk took the usual distribution and relations of the *external carotid*.¹

Prof. Hyrtl states, that any variation in the bifurcation of the *common carotid* from the point above given, will be *below* this line. I cannot agree with him, since in my cases *all* the exceptions were *above* this point.

The anatomy of the *common carotids* is so simple, and so much has been written concerning them, that I can add nothing of importance to the researches of others. What there may be of originality in these investigations will be found in the *two* upper anterior triangles; namely, the *trigonum colli superius* and *trigonum submaxillare*. Taken together they form an irregular quadrilateral, the anterior limit of which will be the median line of the neck, from the *symphysis menti* to the centre of the body of the *os hyoides*; the superior limit corresponds to the lower margin of the *inferior maxilla*, along the *body* and *ramus* to the *condyle*, then backward and downward to the middle of the origin of the *sterno-mastoideus* from the *mastoid process* of the *temporal bone*.

The posterior boundary will be the median line of the *sterno-mastoideus* muscle down to the point of crossing the anterior belly of the *omo-hyoid*; which muscle, passing upward, inward, and forward, forms the inferior border of this space. In this *quadrilateral*, *nine-tenths* of the surgical operations, in which the *carotid arteries* are involved, are performed. The *omo-hyoides* will be found to cross the *common carotid*, in the vast majority of cases, between one-and-a-half and two-and-a-quarter inches below the bifurcation. In a few instances it will be lower or higher than this limit, owing to the development of the muscle or the length of the loop of deep cervical fascia, which passes from its central tendon to the sternal extremity of the first rib.

This irregular *surgical quadrilateral* is divided into the two triangles above mentioned by a pair of muscles intimately associated

¹ In the *New York Medical Record*, vol. xi. 1876, Dr. Eugene Penquet, of Fordham Heights, gives a case very analogous to the above. See also the same case in the *History of the External Carotid*. Koberwein states, he had seen a skull with only one *carotid canal*.

In the case of Dr. Ray (see statistics of *common carotid artery*), is a notice of anomalous absence of the *arteria innominata*; the *right carotid* and *subclavian* coming directly from the arch of the *aorta*.

I have seen reports of one or two cases in which the *external* and *internal carotids* on the right side were derived from the *innominate* at the usual point of origin of the common trunk.—(*Wien Med. Woch.* No. 96, p. 1573, *cit.*)

with each other, viz., the *digastricus* (its posterior belly), and the *stylo-hyoideus*. The first of these two, coming from the digastric fossa on the under surface of the mastoid process, passes downward and forward to be attached by a loop of fascia to the upper surface of the hyoid bone, the anterior belly being reflected upward and forward to the under surface of the *inferior maxilla* just outside the *symphysis*. The *stylo-hyoideus*, more deeply situated than the preceding, is inserted into the *os hyoides* by two tendons which pass on each side of the central tendon of the *digastricus*.

These two muscles vary considerably in their relation to the origin of the *external* and *internal carotids*, owing to the varying distance in different individuals between the chin and the hyoid bone. In the majority of my dissections it crossed between one and one-and-a-half inches above the bifurcation of the *common carotid*. In rare instances higher than this, and in one instance of a high bifurcation, these muscles crossed at that point. The *stylo-hyoideus* was wanting in one case.

The *sterno-mastoideus*, passing obliquely downward and inward, approaches the *internal carotid*, occasionally overlapping its outer portion, just above its origin from the common trunk; the anterior edge of the muscle descending along the *common carotid* obliquely crosses to its inner side completely overlapping it, about one inch and a half below the upper edge of the *thyroid cartilage*.

It will be noticed that the *common carotid* in the last inch and a half of its course, and both the *internal* and *external carotids* in their entire length, are uncovered by muscles, except the delicate *platysma myoides*, and the conjoined bellies of the stylo-hyoid and digastric muscles (about one-half an inch wide), which cross these last two vessels from one to one inch and a half above their origins from the common trunk. A further examination of the surgical anatomy of these vessels will show that in this single triangle, the *trigonum colli superius*, the ligature is applied to the *common carotid* in its upper portion, and to the *external* and *internal carotids* for all lesions of these vessels not requiring a double ligature at the seat of injury.

THE INTERNAL CAROTID.

From its direction this vessel seems to be the direct continuation of the main trunk. Passing upward almost directly in its first portion, it becomes slightly tortuous as it approaches the opening of the carotid canal. As it leaves the *common* trunk, it is usually

trumpet-shaped; this dilatation being due, as I think, to this fact; the blood flowing forcibly along the main artery strikes the septum of bifurcation and is deflected with a certain degree of violence into the two smaller carotids. The pressure upon the *external* is instantly relieved by its numerous branches of distribution derived near its origin; while the *internal* is distended by the constant pressure, which finds no relief until the blood can travel through the tortuous track of the vessel to be distributed to the brain.

Anatomists, as will be seen from the extracts from various standard works given below, usually describe this artery as giving off no branches. Sappey says: "In the course of this vessel from its origin to the base of the cranium it gives off no branches. Haller has, however, seen it give off once the *ascending pharyngeal* and another time the *occipital*."¹ Gray says, "the cervical portion of the *internal carotid* gives off no branches."² "The occipital has in some cases originated from the *internal carotid*." (Quain.³) Wilson says, "the cervical portion of the *internal carotid* gives off no branches."⁴ "In the neck the *internal carotid* gives off no branches." (Leidy.⁵) And Hyrtl, more positive still, gives this artery as "invariably without branches."⁶

In 120 dissections in which the *internal carotid* was present, the *ascending pharyngeal* was derived from it in seven. In three of these pharyngeal arteries came from both *internal* and *external carotid*; in one case there were two branches from the same *internal carotid*. I have never seen the occipital from this vessel. All of these branches were derived within one inch and a half of the *common carotid*.

It may be safely asserted that in *five per cent.*, the *internal carotid* will give off branches in the first half of its cervical portion. At the same time, the presence of these vessels offers no contra-indication to the application of the ligature in this region, since they are so small that they will be occluded by the inflammatory adhesions occurring at and near the ligature. In the cases of hemorrhage after excision of the tonsils, given in the accompanying Surgical History of the Common Carotid, in which this last vessel was tied to arrest

¹ *Traité d'Anatomie Descriptive*, Paris, 1869.

² *Anatomy, Descriptive and Surgical*, London, 1870.

³ *Anatomy of the Human Body*, London, 1845.

⁴ *Human Anatomy*, London, 1858.

⁵ *Human Anatomy*, Philadelphia, 1861.

⁶ *Handbuch der Topographischen Anatomie*, etc., Wien, 1871. "Die carotis interna ist vollkommen astlos."

the flow of blood, the lesion was in the *tonsillar* branches of the *ascending pharyngeal*. If (as is advised in the "conclusions" to this essay), the *external carotid* had been secured instead of the *common*, the hemorrhage would not have ceased, and the *common* or *internal* trunk would have been necessarily ligatured. Notwithstanding this rare anomalous derivation of these vessels, so great is the difference in the death-rate between the ligature of the *external* and *internal*, or *common carotid* arteries, that the former should be tied in all cases without hesitation. If the hemorrhage is not arrested the *common carotid* may then be tied at the point of election.

THE EXTERNAL CAROTID ARTERY.

From the extensive distribution of its branches to the exposed portions of the neck and face, the *external carotid* artery demands a more careful consideration than any single vessel of the human body.

Leaving the *common* trunk at the upper border of the *thyroid cartilage*, well forward of the anterior border of the *sterno-mastoid* muscle, this vessel arches forwards and upwards (its concavity looking toward the lobule of the ear) until, on an average of .92 inch above the bifurcation, after giving off the *facial* branch, it turns obliquely upwards and backwards to a point opposite the insertion of the *external pterygoid* muscle into the neck of the condyle of the lower jaw, where it terminates by dividing into the *temporal* and *internal maxillary* arteries.

Eight regular branches belong to this vessel (though some anatomists, among whom are Hyrtl, Wilson, and Richardson, describe nine).¹ On its anterior aspect arise from below, upward, the *thyroidea superior*, *lingualis*, *maxillaris externa*, and *maxillaris interna*. On its posterior and internal aspect the *pharyngea ascendens*, and posteriorly the *occipitalis*, *auricularis*, and *temporalis*.

THE ARTERIA THYROIDEA SUPERIOR.

"This vessel originates from the front of the *external carotid*, just above its commencement." (Leidy.²) "Close to the *external carotid*,

¹ These writers give the mastoid branch of the occipital as a branch of the carotid. It will be seen further on that this occurred in only 15 of 120 examinations.

² These extracts from celebrated anatomists are given in no spirit of criticism that would reflect unkindly or unjustly upon the reputation of these great men, but to

immediately below the cornu of the *os hyoides*." (Quain.) "From the *external carotid* just below the great cornu of the hyoid bone." (Gray.) "Its origin is so close to the termination of the *primitive carotid* that this last seems often to terminate by a trifurcation. It is not rare to see it originate by a trunk *common* to it and the lingual." (Sappey.)

Wilson gives the origin identical with Quain and Gray, while Hyrtl gives nothing more definite than that it originates from the commencement of the *external carotid*. The average distance of origin of the *thyroidea superior* from above the *centre of bifurcation* of the *common carotid* (this being the centre (a Figs. 1 and 2) of a triangle, the three sides of which are drawn, two from the septum of bifurcation of the two vessels downward to the first swelling that indicates the origins of the *external* and *internal* carotids from the primitive trunk; the third line or base connecting these two), in 121 cases (in all of which it was present) was .11 inch, which point is almost exactly opposite the septum between the two vessels. (See Fig. 1.) By referring to the lines radiating from T (see Fig. 2) we will have the exact range or variation of origin of this vessel, in 121 cases, as deduced from the table of measurements. Between a point one-eighth of an inch above, and one-sixteenth of an inch below this *centre* already indicated, this vessel takes its origin in 68 per cent. The remaining 31 per cent. ranged between one-eighth and one-half inch above this, while 1 per cent. was below the centre of bifurcation one-half inch. (That is in only one single instance.) If to this 68 per cent. we add six cases in which this branch was derived one-half inch above, one case given off one-half inch below the bifurcation, we have over 73 per cent. of cases in which, the necessity existing, a ligature could be applied to the *external carotid* within one-quarter of an inch of its origin without interference with the *thyroidea superior*, while a precautionary ligature applied to this last vessel would render the operation free from the danger of secondary hemorrhage, as far as this branch is concerned.

In four of 121 cases it was from a common trunk with other branches, viz., twice in common with the *lingualis*, and twice with

show that the surgical anatomy of this vessel (the *external carotid*) has not heretofore received that careful and exact study which its importance demands. In the prominence it will take in future (and to which it is hoped these labors may contribute to some extent), in the department of operative surgery, it is believed that a more minute analysis of its relations will be acceptable to the profession of surgery.

the *lingualis* and *maxillaris externa* (as shown in Figs. 5 and 6). In one case it was from the *common carotid* one-half inch below the bifurcation.

Such is the peculiar position of this artery, that should it be wounded too close to the main trunk to allow of its being tied, the *common*, *external*, and *internal carotids* would require the ligature, while on account of the free anastomosis with its fellow of the opposite side, the peripheral end would require torsion. It ranks fourth in size of the branches of the *external carotid*, being largest in two of 77 cases examined as to this feature. One of the most frequent anomalies of the *external carotid* is the origin of the hyoid branches of the *superior thyroid* and *lingual* from the main trunk between these two vessels.

Of its four branches (three of which are quite constant), there are: (1) The *superior laryngeal* perforating the thyro-hyoid membrane, and distributing blood to the muscles and mucous membrane of the larynx. Hemorrhage from this artery has proved fatal in several instances; once in an attempt to dislodge a fragment of oyster-shell lodged beneath the epiglottis, and again in attempts to relieve *œdema glottidis*, the hemorrhage causing death by asphyxia and not by exhaustion proper. (2) The *crico-thyroid*, wounded necessarily in the operation of laryngotomy; and (3) the *cervicalis descendens*, which, crossing the sheath of the *common carotid*, superficially from above, downwards and outwards, is divided in the operation of ligature of the *primitive carotid* above the *omo-hyoideus*. These three are, properly speaking, the *surgical branches*, the hyoid and terminal thyroid distribution possessing no special surgical interest. In two instances I have observed the *thyroidea superior* turn abruptly down along the sheath of the *common carotid* for some distance, and then turn sharply forwards to be distributed to the thyroid body. Under such rare conditions it would probably be divided in the incision for ligature of the *primitive carotid* in the *trigonum colli superius*. In one case of goitre this artery was as large as the *external trunk* (see Fig. 8), seeming to be on the order of the "trifurcation" spoken of by Sappey.

Operation for Ligature.—With the head in the *surgical position*, draw a line from the base of the tragus of the ear to the sterno-clavicular articulation. Parallel with this line make an incision an inch or an inch and a half in length, the centre of which shall be opposite the upper border of the *thyroid cartilage*. A short incision

at right angles to this, in the direction of and along the upper edge of the *thyroid cartilage*, will facilitate the operation. Immediately beneath the skin and *platysma myoides* will be seen the *thyroid, lingual, hyoid* and other veins, which may assume either of the forms or relations shown in Fig. 9, A and B, being most common.

These being tied and divided, or twisted, the artery will be found opposite the point, above so often indicated. In any case it will be found within half an inch above or below this bifurcation of the *common carotid* (see Fig. 2, T).

LINGUALIS.

Gray, Quain, Leidy, and Hyrtl agree in saying that this artery is derived opposite to and runs parallel with the greater cornu of the *os hyoides*. Sappey gives it as coming between the *superior thyroid* and *facial* sometimes in common with one or the other. Wilson gives it as "ascending obliquely from its origin, and then running parallel with the cornu of the *os hyoides*."

In the 121 dissections tabulated in another portion of this article, the average distance of origin of the *lingualis* from the centre of bifurcation (before given) was .68 inch, from the average of the *thyroidea superior* .57 inch (see Fig. 1).

In Fig. 2, the lines radiating from L will give the range of origin of this artery from the *external carotid*. In 82 per cent. of cases this vessel was derived from that portion of the *carotid* between half and one inch above the centre of bifurcation; in 6 per cent. between one and one and three-eighth inches; in 12 per cent. between half and one-eighth above. This leaves 88 per cent. of cases in which the *lingualis* is derived at a sufficient distance above the origin of the *external carotid* to allow the ligature in its first surgical division, *i. e.*, the portion below the *facial, lingual, and occipital*.

While the eminent authorities above quoted generally agree in regard to the intimate relation of this vessel to the *os hyoides* (a relation which my dissections also show) they do not state anything definite as to the distance between it and the *thyroidea superior*; a point of no little interest, since the ligature of the *external carotid* in this, its most important division, depends a good deal upon the average relation of these two branches. In 2 of 121 cases it was from a trunk *common* to it and the *thyroidea superior*; in 2 other cases with this vessel and the *maxillaris externa* (see Fig. 6); in 31 of 121 cases it was common with the *facial*; making this artery

abnormally associated in 35 of 121, or 1 in every $3\frac{1}{2}$. In 5 of 77 cases, noted as to comparative size, this vessel was largest, making it third in size. Extra *hyoid* branches came from the *external carotid* between the *lingualis* and *thyroidea superior* in 15 of 121 cases. Of its 4 usual branches the *hyoid*, *sublingual*, *dorsalis linguæ*, and *ranine*, this last is properly the *surgical branch*. Its intimate relation to the *frænum linguæ* often brings it to the notice of the surgeon.

Operation for Ligature.—From its origin opposite the hyoid bone it ascends obliquely upwards and inwards, and is superficial until it passes underneath the *stylo-hyoides* and *digastricus* (posterior belly), and then more deeply behind the *hyo-glossus* when it disappears.

The incisions should be made as in the case of the *superior thyroid*, except that the *centre* of the perpendicular incision should be *opposite the os hyoides* along which the *transverse* incision should be carried. The relations of the veins will be as in Fig. 9, and the artery will be found in the *lingual triangle*, bounded posteriorly by the *external carotid*, above by the *digastric* muscle, below by the *os hyoides*. In 82 per cent. the artery will be found in the immediate vicinity of the hyoid bone. The *middle constrictor* muscle is behind it; the *platysma myoides* in front, and under this the veins above noted. The hypoglossal nerve is usually *just above* it as it crosses the *carotid*, while the *thyro-hyoid* branch of this nerve crosses the artery on its way to the muscle it supplies. In the accompanying history of the *common carotid* this last vessel was frequently tied for wounds of the branches of the *lingual* in the tongue; a proceeding I cannot endorse, for urgent reasons given in the *resumé* of the Surgical History.

MAXILLARIS EXTERNA (FACIAL).

Quain, Gray, and Leidy give the origin of this vessel as "just above the lingual." Wilson, as above the hyoid bone a little. Sappey says "its origin superior to that of the lingual, is very near it; often in common with it." Hyrtl gives no definite origin, but says, it, with the *lingualis*, is covered at its origin by the posterior belly of the *digastric*.

In my dissections it was not the rule for this muscle to cover the *lingual* at its origin. In a total of 121 dissections of the *external carotid*, the *maxillaris externa* was present in 120. In the instance

in which it was missing, its place was taken in its facial distribution by the *transverse facia* from the *temporal*; in the neck, branches from the *lingual* and extra branches from the carotid to its cervical distribution. The average distance of this artery from the bifurcation was .92 inch, being .24 inch removed from the *lingualis*. (See Fig. 1.)

The range of its origin is seen in Fig. 3, where in 65 per cent. the vessel was between $\frac{1}{2}$ and 1 inch, 31 per cent. between 1 and $1\frac{1}{2}$, and only 4 per cent. between $\frac{1}{2}$ and $\frac{1}{3}$ inch above the bifurcation. Taking the single case in which this artery was wanting, and the cases derived half inch and above this point, we have 96 per cent. in which ligature can be applied to the first *surgical division* of the *external carotid* without danger from the *facial* artery. In 77 cases examined as to comparative size this branch was largest in 45, making it the *largest branch of the external carotid* artery. As shown in Fig. 5, it was common with the *lingual* in its origin in 31 of 120 cases; with the *thyroidea* and *lingualis* in 2 cases; and with the *pharyngea ascendens* in 1 of this number. In 17 of 120 examinations, *extra tonsillar* and *pharyngeal* branches originated from the *carotid* in connection with the *facial*.

Operation for Ligature.—In its cervical distribution this vessel will require to be tied at or near its origin from the *carotid*. The incision along the axis of the *carotid*, as given before, with its centre a quarter of an inch above the hyoid bone, will lead to the *facial*. The relations of the veins are shown in Fig. 9. The posterior belly of the *digastricus* will be found with its centre usually above the origin, but soon crossing the artery. The 9th nerve is just below. For lesion of this vessel in the face it can be readily secured as it crosses the *inferior maxilla* in the depression at the anterior border of the *masseter*. The skin should be well pulled up from the neck before making the incision, so that after healing the cicatrix will fall below the jaw.

PHARYNGEA ASCENDENS.

As to the origin of this branch of the *carotid*, the anatomists heretofore quoted give the *ascending pharyngeal* (Gray and Wilson), "from the commencement of the *external carotid*." Quain and Leidy, "about on a level with the *lingual*." Sappey, as "at first situated

between the *external* and internal carotids;" and Hyrtl "from the inner aspect of the *external carotid*." In their diagrams of the vessel both Wilson and Gray give the origin from the bifurcation of the *common carotid*.

I found it derived from this last point in only 12 instances; while in 111 cases in which it was present, and from the *external carotid* in 121 examinations, its average distance of origin from the bifurcation was .60 inch, a point almost opposite the *lingual*, as given by Leidy and Quain. In Fig. 2, the lines radiating from *P* give the wide range of this vessel. Between the centre of bifurcation and one-half inch above, 26 per cent. were found; between one-half and one inch above, 69 per cent.; and from one to one-and-a-half inches 6 per cent. It was absent from the *external carotid* in ten of 121 examinations; in four of these ten it was from the *internal carotid*, and in three cases *both* of the terminal divisions of the *common carotid* gave off an *ascending pharyngeal*. Taking the 12 cases derived from the bifurcation, and 82 from one-half inch and upwards from this point, we have 85 per cent. of cases, in which this vessel is removed from the first *surgical division* of the *carotid*. Owing to its constant small size (being the smallest of the eight regular branches), its presence will not under any circumstances contraindicate the application of the ligature, because, if it is not itself included in the ligature, the inflammatory process following the operation would occlude so small a vessel. Extra branches in connection with its origin were noticed in two instances of 111. It was from a common origin with the *occipitalis* in fifteen instances.

The *pharyngea ascendens* is not infrequently wounded in operations about the tonsils and posterior pharynx. In the history of the carotids there is one death from hemorrhage from this small vessel.

Operation for Ligature.—First incision same as for *lingualis*, the transverse being parallel with and one-eighth of an inch below the lower border of the *os hyoides*. The vessel will, in the majority of cases, be found between the two carotids and about one-eighth of an inch below the *hyoid* bone. In the event that hemorrhage was not arrested by the ligature of the *external carotid* low down, ligature of the *common* and *internal carotids* would be justifiable, since in twelve of 121 it was derived from the *septum* of bifurcation and in six instances from the *internal carotid*.

OCCIPITALIS.

“From the back part of the *external carotid* about as high as the *facial*.” (Leidy.) Hyrtl nor Wilson gives the origin of this vessel. While Gray says “opposite the *facial*.” Sappey and Quain “opposite the *lingual* or *facial*.”

The *occipitalis* was present in 120 of 121 cases, and the average distance of its origin from the bifurcation was .96 inch (see Fig. 1), which is nearly opposite the *facial*, as given by Gray and Leidy. In Fig. 3 the lines radiating from *O* indicate the wide range of origin of this branch of the *carotid*. 7 per cent. are below one-half inch; 61 from one-half to one inch; 32 per cent. above this point, leaving a total of 93 per cent. in which this vessel is so situated as not to interfere with the application of the ligature in the first half inch of the *external carotid*.

It was absent in one of 121 cases, a branch from the *inferior thyroid* (not the *cervicalis ascendens*) taking its place and distribution.

The hypoglossal nerve wound underneath this vessel (at or very near the origin of the *sterno-mastoid* branch of the *occipital*) and turned forward to its distribution in the tongue invariably. No feature of the anatomy is so constant as the relation between this nerve and artery.

I would offer this explanation; the nerve is distributed well forward in the tongue, which (as is well known) is the most movable organ in the economy. If the nerve, coming out of the condyloid foramen, went directly to its distribution, the sudden and forcible protrusion of the tongue would rupture or interfere with the function of the nerve. To avoid this accident it at first descends, and is looped underneath an elastic, yielding artery, which prevents its being violently stretched and serves to pull it back after the organ is drawn within the mouth.

In 15 of 120 cases, this vessel was common in its origin with the *ascending pharyngeal*; in eleven other instances with the *auricularis posterior*, being abnormally associated in 26 of 120 cases. The *mastoid* branch of the *occipitalis*, which is given by Wilson, Hyrtl, and Richardson as one of the branches of the *external carotid*, was only derived from the *carotid* in 15 of 120 dissections.

The *common carotid* was tied in several instances (see History) for injury to this branch.

Of its branches the *arteria princeps cervicis* may be considered the

most important in a surgical sense, though not so important a factor in carrying on the collateral circulation as is usually thought. It and the *profunda cervicis* from the *superior intercostal* (or subclavian) are both quite small, and the anastomosis in many instances cannot be demonstrated.

The *occipital* artery is sixth in size of the branches of the *carotid*.

Operation for ligature.—Near its origin same as for ligature of *facial*, only the transverse incision should extend posteriorly. Should the emergency demand it may also be secured just underneath the origin of the *digastricus*, though quite deeply situated here. After it reaches the scalp it is more accessible, and does not demand description.

AURICULARIS POSTERIOR.

In 117 cases in which it was present in 121 the average origin was 1.89 inches above the centre of bifurcation (see Fig. 1). Its variations are shown in Fig. 4. 2 per cent. between three-eighths and one inch; 67 per cent. between one and two inches; 30 per cent. above this. As far as ligature of the *external carotid* is concerned, this branch does not demand consideration. It is noticeable that the posterior branches of the *external carotid* (the *pharyngeal*, *occipital*, and *auricular*) are much more uncertain and irregular in their origins than the anterior; the *thyroid* being of all most constant. The *auricularis* was absent in 4 of 121 cases, the *occipital* taking its distribution. In 11 of the 117 instances in which it was present it was in common with the *occipitalis*. It has been ligatured in several instances, once by the elder Pancoast, of Philadelphia.

On account of its intimate relations with the *facial* nerve in front of and the *spinal accessory* underneath it, as it winds below the cartilage of the ear, I do not deem it advisable to attempt to tie it in this position.

It will usually be found on a line with the upper margin of the posterior belly of the *digastric*.

It is seventh in size of the eight branches of the *carotid*.

RAMI PAROTIDEI.

Above the origin of the *auricularis posterior*, and within the substance of the parotid gland, a number of small branches are distributed to the structure of the parotid.

The *external carotid* a little beyond these branches, and when opposite the neck of the condyle of the *inferior maxilla* terminates by dividing into the *maxillaris interna* and *temporalis*.

MAXILLARIS INTERNA AND TEMPORALIS.

This division of the *carotid* averaged a distance of 2.93 inches from the centre of bifurcation (see Fig. 1). The variation in the length of the *external carotid* will be seen in Fig. 4. In rare instances (2) it was only two-and-a-quarter inches long, and in one case it reached the length of four inches. In 95 per cent. it was found to be from two-and-a-half to three-and-a-half inches long. The *maxillaris interna* was largest in 24 of 77 cases, being second in size of the eight branches.

The *temporalis* was fifth in size.

In lesions of the temporal on the scalp this vessel may be readily secured in front of the ear when it passes over the zygoma. If wounded near its origin the *external carotid* may require the ligature above or at the *digastric*. The *transverse facial* branch runs parallel with and is in relation to the zygoma above and the parotid (Steno's) duct below.

Lesions of the *maxillaris interna* require ligature of the *external carotid* below the *maxillaris externa*, with which it anastomoses freely on and in the face. A not infrequent cause of this operation is hemorrhage or lesion of the meningeal arteries. It will be seen that this vessel (like the facial) is widely distributed.

SOME POINTS RELATING TO THE EXTERNAL CAROTID IN GENERAL.

It is not safe to rely upon a symmetrical arrangement of the *external carotids* and their branches upon the two sides. In 15 cases examined upon both sides of the same cadaver, in 7 there was something of symmetry (though not very marked). In 8 there was no attempt at a symmetrical arrangement.

In 121 dissections there were found of the eight regular branches of the *carotid*, coming directly from the main trunk, 888 out of a possible sum of 968. This deficit is explained thus: in 16 cases a single branch was wanting; in 60 instances two had a common origin; and in two other instances three branches came off from a single trunk.

Excluding the branches above the *posterior auricular* going to the parotid gland, there were 48 cases in which extra or abnormal branches came from the *external carotid*, the number of these being 62, distributed to the hyoid region, tonsils, constrictor, and mastoid muscles. They were all too small to contra-indicate the application of the ligature to the parent trunk.

THE OPERATIVE SURGERY OF THE TRIGONUM COLLI SUPERIUS AND TRIGONUM SUBMAXILLARE.

Ligature of the Common Carotid Artery and Internal Jugular Vein.—A line extending from the tragus of the ear to the sterno-clavicular articulation will cover, and be parallel with, the *internal* and *common carotid* arteries in their surgical length. This line will strike the centre of bifurcation of the primitive carotid almost invariably on a level with the upper border of the thyroid cartilage, and will strike the anterior edge of the *sterno-mastoideus* from one inch and a quarter to one-and-a-half below this level.

The incision, being made with its direction, as above given, its centre, about one inch below the bifurcation, extending from one-and-a-half to two inches above and below this point, will divide first the integument, and with this the thin *platysma myoides*, some filaments of the *superficialis colli* nerve, of no importance, and some small veins passing from the *anterior*, either to the internal or *external jugular veins*. About the centre of the wound the edge of the *mastoideus* will be seen, and below this (usually) the anterior belly of the *omo-hyoideus*. The sheath of the *carotid* and *jugular vein* is now exposed, often crossed by the *thyroid veins*, and the *cervicalis descendens* artery; the *descendens noni* nerve almost invariably lying upon the centre of the sheath, it being parallel with the axis of the *common* and *internal carotids*. In two instances I have seen the *superior thyroid* artery turn directly down, in front of the *common* trunk, for an inch or more, and then turn abruptly inwards to be distributed to the thyroid body. Under such abnormal conditions this vessel would probably be divided. The *communicans noni* is occasionally found crossing the sheath from without, inwards, to anastomose with the *descendens*. These nerves will be drawn to the outer or inner side of the wound, as is most convenient. The sheath should be opened on its *tracheal* side as far as possible from the *jugular vein*, and the needle passed from without, inwards, being kept close to the artery in order to avoid wounding the *vein* or in-

cluding the *pneumogastric* or *sympathetic nerves*. I am of the opinion that the sheath should be well opened, and the artery clearly exposed, so that the needle may be manipulated with more of certainty and less danger from these too common and unfortunate accidents. In several instances the artery has been transfixed; the *jugular* has been wounded; the *pneumogastric* or *sympathetic* nerves included in the ligature, for want of precision in separating the artery from the vein. Certainly the danger of slough in the artery is not so great as the dangers above enumerated. Just as the needle is being introduced, pressure above upon the vein would empty it of blood, and of course diminish the danger of wounding it. This pressure should not be long continued, since interference with the return of blood from the brain is never without danger during the administration of an anæsthetic.

The *internal jugular* vein can be secured by this same operation, it being on the outer side of the artery, and concealed by the sternomastoid muscle. The needle should be passed from within outwards, to avoid the nerves.

Ligature of the Internal Carotid.—The incision should be made in the same direction as given for the *common* trunk, with its centre from one-half to three-quarters of an inch above the upper border of the *thyroid cartilage*. The same structures will be divided superficially, and the veins will be seen superficial to the artery. As shown in *C*, Fig. 9, they may cross the internal carotid almost at right angles, or (as in *A* or *B*) they may empty into a single trunk, and run parallel with the *external carotid*. This last is the most usual way, but it will be scarcely possible to ligate the *internal carotid* without division and ligature of these veins. The *descendens noni* nerve will be seen running along the artery, the *hypoglossal* crossing it about one inch from the bifurcation. The vessel being exposed the needle is introduced on the outer side, avoiding the *jugular* vein and *pneumogastric* nerve externally, the *external carotid* internally, and the *hypoglossal* nerve superficially. The *pharyngea ascendens* is in intimate relation to the *internal carotid* running parallel with it on its inner aspect. Occasionally the first cervical ganglion of the sympathetic extends as low as this point. It will be avoided by keeping the needle close to the artery.

The complicated and deep relations of this vessel above the angle of the jaw render it difficult to be reached, yet in hemorrhage from lesion of the artery here the vessel *should be exposed and secured above and below the lesion*.

Ligature of the External Carotid.—This vessel, heretofore so rarely ligatured, may be tied in the majority of cases at two points, viz., between the origins of the *thyroidea superior* and *lingualis*, about one-quarter of an inch above the septum of bifurcation (see Fig 1), or between the origins of the *maxillaris externa* and *auricularis*, about one and one-half inches above the *thyroid cartilage*. At the lower point of election the operation is the same as for ligature of the *internal carotid* on the same plane, except that the *external carotid* is usually from one-quarter to one-half inch nearer the median line than the *internal*.

Notwithstanding that the analysis of these 121 consecutive dissections has convinced me of the propriety of ligaturing this vessel, and that the history of the cases in which it has been tied shows a rate of mortality far below that of ligature of the *common carotid*, yet the proximity of large and important branches to each other, or to the bifurcation of the *common carotid* in many instances, as shown in the following table of measurements, makes it of the utmost importance that the surgeon should proceed with great care and discretion. The wound should be thoroughly cleaned, and the vessel examined with scrupulous care above and below the ligature, and any collateral branch or branches within less than one-quarter of an inch should be also secured.

In many of the cases given in the history of the *external carotid* this precaution was not taken. If the result heretofore has only been a mortality of $6\frac{1}{2}$ per cent., with a closer study of this important vessel, and the adoption of conservative measures which comes of a thorough understanding of the surgical anatomy, can we not hope that even this death-rate may in future be decreased?

Should the artery be found to be normal (as in Fig. 1), I would place the ligature nearer the *lingualis* than the bifurcation, and tie the *lingual* separately. If (as in Fig. 7) a rare form should exist, I would ligature close to these branches, and tie each of them in its turn. This same conservative rule must apply to every case.

The operation at or above the posterior belly of the digastric is comparatively safer, and is applicable to all lesions above this point. The incision is the same as the preceding, except that its centre must be about one-and-one-half inches above the *thyroid cartilage*.

Above this level, that is, after the artery enters the parotid gland, it is so situated that it should not be cut down upon. The incision would involve the *facial nerve*, causing paralysis of the muscles of expression. In malignant disease of the parotid, where this gland

is removed the vessel may as well be secured here as not, since the operation itself usually destroys the *facial nerve*.

It is a remarkable fact, that notwithstanding the close proximity of the branches of the *carotid*, in a number of instances in which it has been ligatured without the precaution of securing immediate collateral branches, there has not followed secondary hemorrhage. No explanation of this fact has appeared so definite as the one given by Prof. H. B. Sands,¹ "which takes into account the remarkable reparative power of the tissues surrounding this vessel. Suppuration is extremely rare; and the wounded tissues soon become consolidated by plastic material, and secondary hemorrhage is prevented by changes occurring *outside of*, as much as by changes taking place *within the vessel ligatured*."

CONCLUSION.

I cannot conclude the surgical anatomy of these arteries without protesting, with all the earnestness I may possess, against the operation of tying the *common carotid* for lesions of the *external carotid* or its branches when this last vessel may be ligatured. The death-rate after the ligature of the *common carotid*, as seen in the conclusions to the history of this vessel, is (forty-one) 41 per cent. That of the *external carotid* is (four and one-half) $4\frac{1}{2}$ per cent.

Before such startling facts, the *theories* of eminent men, and the teachings of surgery to within the present generation, cannot endure.

¹ Prof. of Surgical Anatomy in the Collège of Physicians and Surgeons, New York.

T A B L E

SHOWING THE DISTANCE OF ORIGIN OF THE EIGHT REGULAR BRANCHES OF THE EXTERNAL CAROTID ARTERY FROM THE CENTRE OF BIFURCATION OF THE COMMON CAROTID AND FROM EACH OTHER.

EXPLANATIONS.—The letters R. and L. in the first column indicate that the artery was from the Right or Left side, and when connected by the brace () they were from the same subject. The () extending from one column to another indicates that the two arteries it connects were from a common trunk. The measurements were made from the centre of the Bifurcation of the Common Carotid Artery, as shown in the diagram. The origin of the Superior Thyroid, when not otherwise noted, is *above* the centre of bifurcation, that part of an inch represented by the figures in its columns.

| External Carotid. | Superior Thyroid. | Lingual. | Facial. | Ascending Pharyngeal. | Occipital. | Posterior Auricular. | Temporal. | Internal Maxillary. | |
|------------------------------------------|-----------------------|-----------------------------------------------|-------------------------------|-----------------------|---------------------------------|---------------------------------|----------------|---------------------|----------------|
| No. | | | | | | | | | |
| 1. R. } 2. L. } 3. R. } 4. L. } | Opposite Bifurcation. | $\frac{1}{2}$ } $\frac{1}{2}$ } $\frac{1}{2}$ | $\frac{1}{2}$ } $\frac{1}{2}$ | $\frac{5}{8}$ | $1\frac{3}{4}$ | $2\frac{1}{4}$ | $3\frac{1}{2}$ | $3\frac{1}{2}$ | |
| | | $\frac{7}{8}$ } $\frac{7}{8}$ | $\frac{7}{8}$ | 1 | $\frac{5}{8}$ | $\frac{3}{4}$ | $1\frac{3}{8}$ | $2\frac{7}{8}$ | $2\frac{7}{8}$ |
| | | $\frac{3}{4}$ } $\frac{3}{4}$ | $\frac{3}{4}$ | 1 | $\frac{5}{8}$ | $\frac{7}{8}$ | $1\frac{3}{4}$ | $2\frac{3}{4}$ | $2\frac{3}{4}$ |
| | | $\frac{1}{2}$ | 1 | $1\frac{1}{8}$ | $\frac{7}{8}$ | $2\frac{1}{8}$ } $2\frac{3}{8}$ | $2\frac{3}{8}$ | $3\frac{1}{8}$ | $3\frac{1}{8}$ |
| 6. R. } 7. L. } | Opposite. | $\frac{1}{2}$ } $\frac{1}{2}$ | $\frac{1}{2}$ | $\frac{1}{4}$ | $\frac{1}{2}$ } $1\frac{3}{8}$ | $1\frac{3}{8}$ | $2\frac{3}{8}$ | $2\frac{3}{8}$ | |
| | | $\frac{1}{2}$ } $\frac{3}{4}$ | $\frac{3}{4}$ | $\frac{1}{2}$ | $\frac{3}{8}$ } $\frac{3}{8}$ | $\frac{3}{8}$ | $2\frac{5}{8}$ | $2\frac{5}{8}$ | |
| 8. L. } 9. R. } | Opposite. | $\frac{3}{8}$ } 1 | $1\frac{1}{4}$ | $\frac{3}{8}$ | $2\frac{1}{8}$ } $2\frac{1}{8}$ | $2\frac{1}{8}$ | $3\frac{1}{8}$ | $3\frac{1}{8}$ | |
| | | $\frac{5}{8}$ } 1 | 1 | $1\frac{1}{4}$ | $\frac{3}{8}$ | $\frac{3}{4}$ } $1\frac{3}{4}$ | $1\frac{3}{4}$ | $2\frac{3}{4}$ | $2\frac{3}{4}$ |
| 10. L. } 11. R. } | " | $\frac{7}{8}$ } $1\frac{1}{8}$ | $1\frac{1}{8}$ | $\frac{3}{4}$ | $\frac{3}{4}$ | 1 | 2 | 3 | |
| | | $\frac{1}{2}$ } $\frac{1}{2}$ | $\frac{1}{2}$ | $\frac{1}{2}$ | $\frac{1}{8}$ | $\frac{1}{4}$ | $1\frac{1}{2}$ | $2\frac{1}{2}$ | $2\frac{1}{2}$ |
| 12. L. } 13. R. } | " | $\frac{3}{4}$ } $\frac{3}{4}$ | $\frac{3}{4}$ | $\frac{5}{8}$ | $1\frac{1}{4}$ | $2\frac{1}{2}$ | 3 | 3 | |
| | | $\frac{1}{2}$ } 1 | 1 | 1 | $\frac{1}{2}$ | $\frac{1}{2}$ | $1\frac{3}{4}$ | 3 | 3 |
| 14. L. } 15. L. } | " | $\frac{1}{2}$ } 1 | 1 | 0 | $\frac{3}{4}$ | 2 | 3 | 3 | |
| | | $\frac{1}{16}$ | $\frac{5}{8}$ } $\frac{5}{8}$ | $\frac{5}{8}$ | From Internal Carotid. 0 | 1 | $1\frac{3}{4}$ | $2\frac{3}{4}$ | $2\frac{3}{4}$ |
| 16. R. } 17. L. } | Opposite. | $\frac{7}{8}$ } $\frac{7}{8}$ | $\frac{7}{8}$ | $\frac{3}{4}$ | $\frac{3}{4}$ | $\frac{5}{8}$ | 2 | $2\frac{7}{8}$ | $2\frac{7}{8}$ |
| | | $\frac{5}{8}$ } $\frac{7}{8}$ | $\frac{7}{8}$ | $\frac{7}{8}$ | $\frac{3}{4}$ | $1\frac{3}{8}$ | $1\frac{3}{4}$ | $2\frac{3}{4}$ | $2\frac{3}{4}$ |

| No. | External Carotid. | Superior Thyroid. | Lingual. | Facial. | Ascending Pharyngeal. | Occipital. | Posterior Auricular. | Temporal. | Internal Maxillary. |
|--------|-------------------|-------------------|----------|---------|-----------------------|------------|----------------------|-----------|---------------------|
| 18. R. | | 3 | 7 | 1 | 5 | 7 | 15 | 25 | 25 |
| 19. R. | | Opposite. | 3 | 7 | 1 | 1 | 2 | 2½ | 2½ |
| 20. L. | | " | 3 | 5 | 5 | 5 | 1½ | 2½ | 2½ |
| 21. L. | | " | 5 | 1 | 3 | 7 | 17 | 3½ | 3½ |
| 22. L. | | " | 3 | ½ | 0 | 3 | 15 | 2¾ | 2¾ |
| 23. L. | | " | 3 | 7 | ½ | 3 | 0 | 25 | 25 |
| 24. L. | | " | 1 | ½ | 5 | 5 | 13 | 2½ | 2½ |
| 25. L. | | 3 | 1½ | 1½ | 1½ | 2½ | 25 | 4 | 4 |
| 26. L. | | Opposite. | 5 | 3 | ½ | ½ | 1¾ | 3 | 3 |
| 27. L. | | " | 7 | 13 | ½ | ½ | 2¼ | 3¼ | 3¼ |
| 28. R. | | 3 | 3 | 13 | 1 | 1 | 2¼ | 3¼ | 3¼ |
| 29. L. | | Opposite. | 5 | 5 | 5 | 5 | 2 | 3½ | 3½ |
| 30. R. | | 1 | 7 | 7 | 7 | 7 | 2 | 3¼ | 3¼ |
| 31. L. | | Opposite. | 1 | ½ | ½ | 13 | 1½ | 27 | 27 |
| 32. R. | | " | 1 | 1 | From Bifurcation. | 1¼ | 1½ | 27 | 27 |
| 33. L. | | " | 5 | 3 | 5 | 5 | 1¾ | 25 | 25 |
| 34. R. | | 1 | 5 | 7 | 3 | 3 | 1¾ | 3 | 3 |
| 35. L. | | Opposite. | 5 | 13 | 7 | 7 | 2½ | 3 | 3 |
| 36. R. | | " | 5 | 3 | 3 | 3 | 1½ | 27 | 27 |
| 37. R. | | 1 | 3 | 7 | 3 | 7 | 2 | 3 | 3 |
| 38. L. | | Opposite. | 3 | 1 | 1 | 3 | 2¼ | 2¾ | 2¾ |
| 39. R. | | " | 3 | 1½ | 0 | 2 | 2¼ | 3½ | 3½ |
| 40. R. | | " | 1 | 1 | ½ | 5 | 1½ | 2¾ | 2¾ |
| 41. L. | | " | 3 | 3 | 3 | 13 | 13 | 2½ | 2½ |
| 42. R. | | " | 1 | 7 | 1 | 5 | 1¾ | 2¾ | 2¾ |
| 43. L. | | " | 5 | 7 | 3 | 3 | 2 | 3 | 3 |
| 44. R. | | 3 | 3 | 7 | 1 | 1 | 2¼ | 3 | 3 |
| 45. R. | | Opposite. | 1 | 7 | 3 | 5 | 1¾ | 2¾ | 2¾ |
| 46. L. | | " | 3 | 1½ | 3 | 7 | 25 | 3¼ | 3¼ |
| 47. R. | | " | 5 | 7 | 0 | 7 | 0 | 2¾ | 2¾ |
| 48. L. | | " | 7 | 1 | 1 | 13 | 2 | 3 | 3 |
| 49. R. | | " | 3 | 1½ | 7 | 15 | 2½ | 3 | 3 |

| No. | External Carotid. | Superior Thyroid. | Lingual. | Facial. | Ascending Pharyngeal. | Occipital. | Posterior Auricular. | Temporal. | Internal Maxillary. |
|--------|----------------------|-------------------|----------------|----------------|-----------------------|----------------|----------------------|----------------|---------------------|
| 50. L. | Opposite. | | $\frac{1}{2}$ | 0 | $\frac{1}{4}$ | $\frac{3}{8}$ | $1\frac{3}{4}$ | $2\frac{7}{8}$ | $2\frac{7}{8}$ |
| 51. R. | " | | $\frac{1}{2}$ | $\frac{7}{8}$ | $\frac{1}{2}$ | $\frac{3}{8}$ | $2\frac{1}{4}$ | $3\frac{1}{4}$ | $3\frac{1}{4}$ |
| 52. L. | " | | $\frac{5}{8}$ | $\frac{5}{8}$ | $1\frac{5}{8}$ | 1 | 1 | $3\frac{1}{4}$ | $3\frac{1}{4}$ |
| 53. L. | " | | $\frac{1}{2}$ | $\frac{1}{2}$ | $\frac{5}{8}$ | $\frac{3}{4}$ | 2 | $2\frac{1}{2}$ | $2\frac{1}{2}$ |
| 54. L. | $\frac{1}{8}$ below. | | $\frac{5}{8}$ | $\frac{5}{8}$ | $\frac{5}{8}$ | $\frac{3}{8}$ | $1\frac{1}{2}$ | $2\frac{1}{4}$ | $2\frac{1}{4}$ |
| 55. R. | Opposite. | | $\frac{7}{8}$ | $\frac{3}{4}$ | $\frac{1}{4}$ | $\frac{3}{8}$ | $1\frac{5}{8}$ | $2\frac{1}{2}$ | $2\frac{1}{2}$ |
| 56. L. | " | | $\frac{1}{2}$ | $\frac{3}{4}$ | $\frac{1}{2}$ | $\frac{3}{4}$ | $1\frac{3}{4}$ | $2\frac{7}{8}$ | $2\frac{7}{8}$ |
| 57. R. | " | | $\frac{1}{4}$ | $\frac{5}{8}$ | $\frac{3}{8}$ | 1 | $1\frac{7}{8}$ | $2\frac{1}{2}$ | $2\frac{1}{2}$ |
| 58. R. | $\frac{1}{4}$ | | $\frac{1}{2}$ | $\frac{7}{8}$ | $\frac{5}{8}$ | $\frac{3}{4}$ | 2 | 3 | 3 |
| 59. L. | Opposite. | | $\frac{5}{8}$ | 1 | op. | $\frac{1}{2}$ | $1\frac{3}{4}$ | $2\frac{3}{4}$ | $2\frac{3}{4}$ |
| 60. L. | $\frac{1}{8}$ | | 1 | 1 | 1 | 1 | 2 | 3 | 3 |
| 61. R. | $\frac{1}{8}$ | | $\frac{3}{8}$ | $\frac{3}{4}$ | $\frac{1}{2}$ | $1\frac{1}{2}$ | 2 | $2\frac{1}{2}$ | $2\frac{1}{2}$ |
| 62. L. | Opposite. | | $\frac{1}{2}$ | $\frac{1}{2}$ | $\frac{1}{2}$ | 1 | 1 | $2\frac{3}{4}$ | $2\frac{3}{4}$ |
| 63. R. | $\frac{1}{4}$ | | $\frac{3}{4}$ | $1\frac{1}{4}$ | $\frac{5}{8}$ | $1\frac{1}{8}$ | 2 | $2\frac{3}{4}$ | $2\frac{3}{4}$ |
| 64. R. | $\frac{1}{4}$ | | 1 | $1\frac{1}{4}$ | $\frac{7}{8}$ | $\frac{7}{8}$ | $2\frac{1}{8}$ | $3\frac{1}{8}$ | $3\frac{1}{8}$ |
| 65. L. | Opposite. | | $1\frac{1}{4}$ | $1\frac{1}{4}$ | op. | $1\frac{3}{4}$ | $2\frac{1}{2}$ | $3\frac{1}{2}$ | $3\frac{1}{2}$ |
| 66. R. | $\frac{3}{8}$ | | $\frac{1}{2}$ | $\frac{5}{8}$ | $\frac{3}{8}$ | $1\frac{1}{2}$ | $1\frac{1}{2}$ | $2\frac{3}{4}$ | $2\frac{3}{4}$ |
| 67. R. | $\frac{1}{4}$ | | $1\frac{1}{8}$ | $1\frac{3}{8}$ | 1 | $1\frac{1}{4}$ | $2\frac{1}{4}$ | $3\frac{1}{4}$ | $3\frac{1}{4}$ |
| 68. L. | Opposite. | | $\frac{5}{8}$ | $\frac{5}{8}$ | $\frac{5}{8}$ | 1 | $2\frac{1}{8}$ | 3 | 3 |
| 69. L. | " | | $\frac{3}{8}$ | $1\frac{1}{4}$ | op. | $\frac{3}{4}$ | 2 | 3 | 3 |
| 70. L. | $\frac{1}{8}$ | | $\frac{5}{8}$ | $\frac{7}{8}$ | $\frac{1}{2}$ | $\frac{5}{8}$ | $1\frac{3}{4}$ | $2\frac{1}{2}$ | $2\frac{1}{2}$ |
| 71. R. | $\frac{1}{2}$ | | $1\frac{1}{8}$ | $1\frac{1}{8}$ | $1\frac{1}{4}$ | $1\frac{1}{4}$ | $2\frac{1}{8}$ | $3\frac{1}{4}$ | $3\frac{1}{4}$ |
| 72. L. | Opposite. | | $\frac{3}{4}$ | $1\frac{1}{2}$ | $\frac{1}{2}$ | $\frac{7}{8}$ | 2 | 3 | 3 |
| 73. L. | " | | $\frac{3}{4}$ | $\frac{7}{8}$ | $\frac{7}{8}$ | $\frac{7}{8}$ | $1\frac{7}{8}$ | $2\frac{3}{4}$ | $2\frac{3}{4}$ |
| 74. R. | $\frac{1}{4}$ | | 1 | 1 | $\frac{7}{8}$ | 0 | 2 | $2\frac{3}{4}$ | $2\frac{3}{4}$ |
| 75. L. | Opposite. | | $\frac{1}{4}$ | $\frac{1}{4}$ | 0 | $\frac{3}{8}$ | $1\frac{1}{2}$ | $2\frac{1}{2}$ | $2\frac{1}{2}$ |
| 76. R. | " | | $\frac{3}{8}$ | $\frac{1}{2}$ | op. | $\frac{5}{8}$ | $1\frac{1}{2}$ | $2\frac{1}{2}$ | $2\frac{1}{2}$ |
| 77. L. | " | | $\frac{7}{8}$ | $1\frac{3}{8}$ | $1\frac{1}{4}$ | $1\frac{1}{4}$ | $2\frac{3}{8}$ | $3\frac{1}{4}$ | $3\frac{1}{4}$ |
| 78. L. | " | | 1 | 1 | op. | $\frac{5}{8}$ | $2\frac{1}{2}$ | $3\frac{1}{4}$ | $3\frac{1}{4}$ |
| 79. R. | $\frac{1}{4}$ | | $\frac{3}{4}$ | $1\frac{3}{4}$ | $\frac{5}{8}$ | 1 | $2\frac{1}{4}$ | 3 | 3 |
| 80. R. | $\frac{3}{8}$ | | $\frac{5}{8}$ | $\frac{7}{8}$ | $\frac{5}{8}$ | $\frac{1}{2}$ | $1\frac{7}{8}$ | 3 | 3 |
| 81. L. | $\frac{1}{4}$ | | $\frac{5}{8}$ | 1 | $\frac{7}{8}$ | $\frac{7}{8}$ | $1\frac{5}{8}$ | $2\frac{5}{8}$ | $2\frac{5}{8}$ |

| No. | External Carotid. | Superior Thyroid. | Lingual. | Facial. | Ascending Pharyngeal. | Occipital. | Posterior Auricular. | Temporal. | Internal Maxillary. |
|----------|------------------------|-------------------|----------------|----------------|-----------------------|----------------|----------------------|----------------|---------------------|
| 82. L. | | $\frac{1}{4}$ | $\frac{7}{8}$ | $\frac{7}{8}$ | 1 | 1 | 2 | $3\frac{1}{4}$ | $3\frac{1}{4}$ |
| 83. R. | | $\frac{1}{8}$ | 1 | $1\frac{1}{4}$ | $1\frac{1}{8}$ | $1\frac{1}{8}$ | 2 | $2\frac{7}{8}$ | $2\frac{7}{8}$ |
| 84. L. | | $\frac{3}{8}$ | $1\frac{3}{8}$ | $1\frac{5}{8}$ | $1\frac{1}{4}$ | $1\frac{1}{4}$ | $2\frac{1}{2}$ | $3\frac{1}{4}$ | $3\frac{1}{4}$ |
| 85. L. | | $\frac{1}{4}$ | $1\frac{1}{4}$ | $1\frac{1}{4}$ | 1 | 1 | 0 | $3\frac{1}{2}$ | $3\frac{1}{2}$ |
| 86. L. | | $\frac{1}{4}$ | $\frac{7}{8}$ | $1\frac{3}{8}$ | $\frac{1}{4}$ | $1\frac{1}{4}$ | $2\frac{1}{4}$ | $3\frac{1}{2}$ | $3\frac{1}{2}$ |
| 87. R. | | $\frac{3}{8}$ | $\frac{5}{8}$ | $1\frac{3}{8}$ | 0 | $1\frac{1}{8}$ | 2 | $3\frac{1}{8}$ | $3\frac{1}{8}$ |
| 88. R. | | $\frac{1}{8}$ | $\frac{1}{2}$ | $1\frac{1}{8}$ | 0 | $\frac{3}{4}$ | $2\frac{1}{4}$ | 3 | 3 |
| 89. L. | | $\frac{1}{4}$ | $\frac{7}{8}$ | $\frac{7}{8}$ | $\frac{1}{2}$ | $\frac{7}{8}$ | $2\frac{1}{8}$ | $3\frac{1}{4}$ | $3\frac{1}{4}$ |
| 90. L. | | $\frac{1}{4}$ | $\frac{1}{2}$ | $\frac{3}{4}$ | $\frac{1}{2}$ | $1\frac{1}{4}$ | $1\frac{3}{4}$ | $2\frac{3}{4}$ | $2\frac{3}{4}$ |
| 91. L. | Opposite. | | $\frac{3}{4}$ | $1\frac{1}{4}$ | $\frac{3}{4}$ | 1 | 2 | 3 | 3 |
| 92. L. | " | | 1 | $1\frac{1}{8}$ | $\frac{5}{8}$ | $1\frac{3}{4}$ | $2\frac{1}{2}$ | $3\frac{1}{2}$ | $3\frac{1}{2}$ |
| 93. L. | | $\frac{1}{8}$ | $\frac{1}{8}$ | $\frac{1}{4}$ | $\frac{1}{4}$ | $\frac{1}{2}$ | $1\frac{1}{2}$ | $2\frac{1}{4}$ | $2\frac{1}{4}$ |
| 94. R. | Opposite. | $\frac{1}{8}$ | $\frac{7}{8}$ | $1\frac{1}{8}$ | $\frac{3}{4}$ | $\frac{3}{4}$ | 2 | 3 | 3 |
| 95. L. | | | $\frac{5}{8}$ | $\frac{7}{8}$ | op. | $\frac{5}{8}$ | $1\frac{5}{8}$ | $2\frac{5}{8}$ | $2\frac{5}{8}$ |
| 96. R.* | " | | $\frac{1}{8}$ | $\frac{1}{8}$ | $\frac{1}{8}$ | $\frac{3}{8}$ | 0 | $2\frac{1}{2}$ | $2\frac{1}{2}$ |
| 97. R. | | $\frac{1}{4}$ | $1\frac{3}{8}$ | $1\frac{5}{8}$ | 0 | $1\frac{3}{4}$ | $2\frac{3}{4}$ | $3\frac{1}{2}$ | $3\frac{1}{2}$ |
| 98. R. | | $\frac{1}{8}$ | $\frac{3}{4}$ | 1 | $\frac{7}{8}$ | $1\frac{7}{8}$ | $2\frac{1}{8}$ | $3\frac{1}{2}$ | $3\frac{1}{2}$ |
| 99. R.† | | $\frac{1}{4}$ | $\frac{1}{2}$ | $\frac{1}{2}$ | $\frac{1}{2}$ | $\frac{5}{8}$ | $\frac{5}{8}$ | $2\frac{1}{4}$ | $2\frac{1}{4}$ |
| 100. L.‡ | | $\frac{1}{4}$ | $\frac{1}{4}$ | $\frac{1}{4}$ | $\frac{1}{4}$ | $1\frac{3}{8}$ | $1\frac{3}{4}$ | $3\frac{1}{4}$ | $3\frac{1}{4}$ |
| 101. R. | Opposite. | | $\frac{1}{2}$ | $1\frac{1}{8}$ | $\frac{1}{2}$ | $\frac{3}{4}$ | $1\frac{3}{4}$ | $2\frac{3}{4}$ | $2\frac{3}{4}$ |
| 102. L. | " | | $\frac{3}{4}$ | 1 | $\frac{3}{4}$ | $\frac{3}{4}$ | $1\frac{7}{8}$ | 3 | 3 |
| 103. L. | " | | $\frac{5}{8}$ | $\frac{7}{8}$ | $\frac{3}{4}$ | $1\frac{3}{4}$ | $1\frac{3}{4}$ | 3 | 3 |
| 104. L. | " | | 1 | 1 | 1 | $1\frac{1}{4}$ | 2 | $2\frac{7}{8}$ | $2\frac{7}{8}$ |
| 105. R. | " | | $\frac{1}{2}$ | $\frac{3}{4}$ | $\frac{1}{2}$ | $\frac{1}{2}$ | $1\frac{1}{2}$ | 3 | 3 |
| 106. L. | " | | $\frac{1}{2}$ | $\frac{3}{4}$ | $\frac{7}{8}$ | $\frac{7}{8}$ | $1\frac{3}{4}$ | 3 | 3 |
| 107. L. | " | | $\frac{1}{2}$ | $1\frac{1}{8}$ | op. | $1\frac{1}{8}$ | $1\frac{1}{2}$ | $2\frac{3}{4}$ | $2\frac{3}{4}$ |
| 108. L. | " | | $\frac{1}{2}$ | 1 | $\frac{1}{2}$ | $\frac{1}{2}$ | 2 | $2\frac{7}{8}$ | $2\frac{7}{8}$ |
| 109. L. | $\frac{1}{4}$ above. | | 1 | $1\frac{1}{8}$ | 1 | $1\frac{1}{8}$ | $1\frac{7}{8}$ | 3 | 3 |
| 110. L. | $\frac{1}{4}$ " | | $\frac{5}{8}$ | $\frac{3}{8}$ | 1 | $1\frac{1}{8}$ | $1\frac{3}{8}$ | $3\frac{1}{2}$ | $3\frac{1}{2}$ |
| 111. R. | Opposite. | | $\frac{3}{4}$ | $\frac{7}{8}$ | $\frac{3}{4}$ | 1 | $1\frac{3}{4}$ | $2\frac{3}{4}$ | $2\frac{3}{4}$ |
| 112. L. | § $\frac{1}{2}$ below. | | $\frac{1}{2}$ | $\frac{3}{4}$ | op. | op. | $1\frac{1}{4}$ | $2\frac{1}{4}$ | $2\frac{1}{4}$ |
| 113. L. | Opposite. | | $\frac{3}{4}$ | 1 | $\frac{3}{4}$ | $\frac{7}{8}$ | 2 | 3 | 3 |

| No. | External Carotid. | Superior Thyroid. | Lingual. | Facial. | Ascending Pharyngeal. | Occipital. | Posterior Auricular. | Temporal. | Internal Maxillary. |
|-------------------------------------------------------------------------------|-----------------------------------------|-------------------|---------------|----------------|-----------------------|----------------|----------------------|----------------|---------------------|
| 114. L. | Opposite. | | $\frac{3}{4}$ | 1 | op. | $\frac{3}{4}$ | $2\frac{1}{2}$ | 3 | 3 |
| 115. R. } 116. L. } | $\frac{1}{4}$ above. $\frac{1}{4}$ " | | 1 | $1\frac{1}{4}$ | 1 | $1\frac{1}{2}$ | $2\frac{1}{4}$ | $3\frac{1}{4}$ | $3\frac{1}{4}$ |
| | | | 1 | 1 | op. | 1 | 2 | 3 | 3 |
| 117. L. | Opposite. | | $\frac{3}{4}$ | $1\frac{1}{8}$ | $\frac{3}{4}$ | $2\frac{1}{4}$ | $2\frac{1}{4}$ | $3\frac{1}{8}$ | $3\frac{1}{8}$ |
| 118. R. } 119. L. } | $\frac{1}{4}$ above. Opposite. | | $\frac{3}{4}$ | $\frac{3}{4}$ | 0 | 1 | $1\frac{1}{4}$ | 3 | 3 |
| | | | $\frac{3}{4}$ | $1\frac{1}{8}$ | 1 | $1\frac{1}{2}$ | $2\frac{1}{2}$ | $2\frac{3}{4}$ | $2\frac{3}{4}$ |
| 120. R. | $\frac{1}{2}$ above. | | $\frac{7}{8}$ | $1\frac{1}{8}$ | $\frac{7}{8}$ | $1\frac{7}{8}$ | $2\frac{1}{8}$ | $3\frac{1}{8}$ | $3\frac{1}{8}$ |
| 121. L. | $\frac{1}{2}$ " | | 1 | $1\frac{1}{4}$ | $1\frac{1}{4}$ | $1\frac{1}{4}$ | $2\frac{1}{4}$ | $3\frac{1}{4}$ | $3\frac{1}{4}$ |
| Total distance | | | | | | | | | |
| above bifur- | | | | | | | | | |
| cation 12.81 82.56 110.99 67.31 115.80 221.87 355.12 inches | | | | | | | | | |
| Average dis- | | | | | | | | | |
| tance11- .68+ .92+ .60+ .96+ 1.89+ 2.93+ " | | | | | | | | | |

* This case bifurcated $\frac{1}{4}$ inch above the upper border of the thyroid cartilage.

- † " " $\frac{1}{2}$ " " " " "
- ‡ " " 1 " " " " "
- § " " $\frac{3}{4}$ " " " " "

All the remaining cases were opposite this point.

Total 121. On right side, 50 dissections; on the left, 71.

[NOTE.—Each measurement in these tables was made with compass and rule, and noted at the time the dissection was being made. It was thought unnecessary to measure below the $\frac{1}{2}$ of an inch in general.]

SURGICAL HISTORY
OF THE
COMMON CAROTID ARTERY.

Surgical History of the

| No. | Name of operator. | Source of information. | PATIENT. | | | Cause of operation. | Duration of cause. | Point of deligation. | Date of injury. | Date of hemorrh'ge. |
|-----|--------------------------------|-------------------------------------------------------------------------------------------------------|----------|----------|-------|-------------------------------------------------------------------------|--------------------|----------------------|-----------------|---------------------|
| | | | Sex. | Age. | Side. | | | | | |
| 1 | Abernethy, 1803. | Norris Contributions, Phila., 1873; Dr. C. Pilz, in Langenbeck's Archiv für Klinische Chirurg., 1868. | M. | | L. | Hemor'ge; wound throat; gored by cow. | Few hours. | Below omo-hyoid. | | |
| 2 | Adelmann, 1841. | Arch. Klin. Chir. (ct.) | M. | 30 | R. | Hem. of tongue. | 5 days. | | Nov. 5. | |
| 3 | Adelmann, 1853. | do. | M. | 56 | | Removed cancer; tongue. | | | | |
| 4 | Adelmann, ? | do. | M. | 12 | R. | Removed superior maxilla. | | | | |
| 5 | Adolphus, P., 1862. | Med. Surg. Hist. Rebellion—Dr. Otis. | M. | Mid age. | R. | Shot wound inf. maxilla. | | | Aug. 30. | Sept. 6. |
| 6 | Alexander, C. T., 1862. | do. | M. | 19 | L. | Fragment of shell, temporal region. | | | Dec. 28, 1861. | Jan. 18, 1862. |
| 7 | Andrews, E., Chicago. | Letter to author. | M. | 25 | L. | Stab wound internal carotid, high up. | | | | |
| 8 | Anandale, T., 1875. | Brit. Med. Jr., Oct. 1875. | M. | 62 | R. | Aneurism; arch of aorta. | | | | |
| 9 | Angell. | Arch. Klin. Chir. | | | L. | Epilepsy. | | | | |
| 10 | do. | do. | | | | do. | | | | |
| 11 | Ansiaux. | do. | | | | Removed parotid. | | | | |
| 12 | Arendt, 1821. | do. | M. | 35 | R. | Aneurism anast. of face. | | | | |
| 13 | Arnold, G. C., New York, 1874. | Letter to author. | M. | 30 | R. | Hemorrhage after removal, recurrent tumor, angle of right inf. maxil'a. | 12 days. | At omo-hyoid. | | Feb. 15. |
| 14 | Arnott. | Lancet, 1846, p. 135. | M. | | R. | Hemor'ge, mouth; fall on pipe-stem. | | | | |
| 15 | Auchincloss, 1839. | Norris Contrib. Arch. Klin. Chir. | | 23 | L. | Aneurism anast. of head. | 23 years. | | | |
| 16 | Anbert, Moscow. | Arch. Klin. Chir. | F. | y'g. | R. | Aneurism anast. of ear. | | | | |
| 17 | Awl, Wm. L., 1827. | Ext. Lancaster, Ohio, Gazette, March 20, 1827, kindness Prof. J. H. Pooley. | F. | 12 | R. | Removed immense tumor of right cheek. | Some time. | | | |
| 18 | Baizeau, 1847. | Arch. Klin. Chir. 1868. | M. | 23 | L. | Hemorrhage; fistulous opening near ear. | 17 days. | | | |
| 19 | Baker, J. W., 1870. | Lancet, June, 1870. | F. | 32 | L. | Hem.; removed parotid gland. | | | | |
| 20 | Baker, W. M., 1875. | Am. Jr. Med. Sci., July, 1877, p. 176. | M. | 23 | L. | Hemorrhage; ascend. pharyngeal; fall on pipe-stem. | | Above omo-hyoid. | | 1, 2, 3 days. |
| 21 | Von Balassa, 1854. | Arch. Klin. Chir. | M. | 28 | L. | Prep. resection of inf. maxilla. | 15 years. | do. | | |
| 22 | Von Balassa, 1844. | do. | F. | 18 | L. | Aneurism of common carotid. | 3 years. | | | |
| 23 | Ballingal, 1854, East India. | do. | M. | 30 | L. | do. | 18 months. | | | |

Common Carotid Artery.

| No. | Date of operation. | Hemorrhage occurred, after op. | Lig. came away No. days aft. op. | RESULT. | | | REMARKS. |
|-----|--------------------|--------------------------------|----------------------------------|------------|-----------------------------------|-----------------------------------------|-----------------------------------------------------------------------------------------------------------------------------------------------------------------------------------------------------------------------------------------------------------------------------------------------------------------------------|
| | | | | Recovery. | Condition. | Cause of death, date after op. | |
| 1 | 1803. | | | | | 30 hours. ? | Paralysis of right side after operation; lingual, facial, superior thyroid, and internal carotid arteries were wounded. |
| 2 | Nov. 10, 1841. | 11 and 17 days. | 7 | Recovered. | Cured. | | |
| 3 | Oct. 14, 1853. | | 23 | Recovered. | | | Died 3 months later from cancer. |
| 4 | | | | | | 3d day. ? | Two ligatures applied a short distance apart. |
| 5 | Sept. 6, 1862. | | | Recovered. | | | |
| 6 | Jan. 18, 1862. | Once, middle mening. | | Recovered. | "Total and temporarily disabled." | | |
| 7 | | | | Recovered. | Cured. | | |
| 8 | March 2, 1875. | | | Recovered. | Improved. | | "Seven months after operation tumor very much reduced in size; bruit not so loud; carbolicized catgut." <i>Wardrop.</i> |
| 9 | | | | Recovered. | Cured. | | |
| 10 | | | | | | Died. | |
| 11 | | | | Recovered. | | | Ligature several days before operation for removal. |
| 12 | Nov. 18, 1821. | 6 w'ks. | 17 | Recovered. | Cured. | | The secondary hemorrhage lasted for several days, but was slight; 12 ligatures were applied during the operation. |
| 13 | Feb. 19, 1874. | Immediately. | 11 | Recovered. | Partial and permanent paralysis. | | No anæsthetic; tumor removed on 7th; hemorrhage 9th, and at intervals to 19th; after operation of ligature hemorrhage controlled by compress; stupor; 5 days after operation partial paralysis <i>right</i> face, complete of <i>left</i> arm and leg; 27 months after operation partial paralysis of leg, complete of arm. |
| 14 | | do. | | | | Cerebral anæmia? | It is stated that the patient did not die from hemorrhage. |
| 15 | 1839. | | 20 | Recovered. | Cured. | | Pulsation in tumor ceased immediately; cure rapid. |
| 16 | | Some days. | | | | Inflammation brain. | Tumor began to decline; pain in head; hemiplegia; death. |
| 17 | 1827. | | | Recovered. | Cured. | | This ancient Gazette boasts that this is "the first operation of this magnitude west of the Alleghanies." (The claim is well founded.) |
| 18 | May 27, 1847. | 1, 2, 3 days. | | | | 3d day; exhaustion and cerebral anæmia. | After operation, ringing in ears, difficult deglutition, somnolence. Autopsy: Softening left hemisphere, middle lobe; tubercle in lungs and peritonæum. |
| 19 | | | 21 | Recovered. | Cured. | | "After operation pain, right side, head." |
| 20 | Sep. 23, 1875. | | | | | Few hours after operation. | |
| 21 | Jan. 18, 1854. | 25 days. | 14 | | | 62d day. Cerebral softening. | No anæsthetic; 8th day erysipelas; rigors on 62d. Autopsy: Left hemisphere softened. |
| 22 | Feb. 22, 1814. | | 18 | Recovered. | Cured. | | Partial paralysis right side after operation disappeared; cough; dyspnoea, etc.; no anæsthetic; end 2d month cure complete. |
| 23 | Aug. 17, 1854. | 6 w'ks. | 13 | Recovered. | Cured. | | Peculiar sensation in right arm and leg after operation; tumor suppurated and was punctured. |

Surgical History of the

| No. | Name of operator. | Source of information. | PATIENT. | | | Cause of operation. | Duration of cause. | Point of deligation. | Date of injury. | Date of hemorrhage. |
|-----|------------------------------|------------------------------------------------------------------|----------|---------|-------|---------------------------------------------------|--------------------|----------------------|-----------------|---------------------|
| | | | Sex. | Age. | Side. | | | | | |
| 24 | Bardleben, 1849. | Arch. Klin. Chir. | F. | 25 | L. | Caries of parietal bone and hemorrhage. | | | | |
| 25 | Bardleben, 1854. | do. | M. | 40 | R. | Removed tumor, parotid (cancer). | | | | |
| 26 | Bardleben, 1866. | do. | M. | 41 | R. | Removed tumor of neck. | | | | |
| 27 | Bardleben, 1874-5. | Wien. Mediz. Wochen. 1875, p. 33. | F. | 61 | R. | Traumatic aneurism of middle meningeal. | 2 years. | | | |
| 28 | Barovero, 1825. | Arch. Klin. Chir. | M. | 49 | R. | Fung. tumor of palate. | | | | |
| 29 | Barrier, 1847. | Gaz. Med., 1848, p. 774; Arch. Klin. Chir. | F. | 30 | L. | Traumatic aneurism of temporal artery. | | | | |
| 30 | Batchelder, 1825. | Prof. Jas. R. Wood, in N. Y. Med. Jr., July, 1857. | | | | Osteo-sarcoma of inf. maxilla; removal. | | | | |
| 31 | Bandens, 1855 (Crimean war). | Arch. Klin. Chir. | M. | | | Hem'ge; wounded soldier. | | | | |
| 32 | do. | do. | M. | | | do. | | | | |
| 33 | do. | do. | M. | | | do. | | | | |
| 34 | Bauer, 1856. | Ehrmann, des effets sur l'encepu. etc., Arch. Klin. Chir., 1868. | M. | 30 | | Removed tumor of neck. | | | | |
| 35 | Becton, 1827. | Norris Contrib. cit. | M. | 22 | L. | Epilepsy. | 9 years. | | | |
| 36 | Bedor, 1835. | do. | M. | 20 | L. | Hemorr'ge; puncture in neck with awl. | | | | |
| 37 | Beeby, 1864. | Med. Times & Gaz., Nov. 19, 1864, p. 541. | M. | 64 | R. | Hemorr'ge; cancer of glands of neck. | | | | |
| 38 | Begin. | Arch. Klin. Chir. cit. | M. | | | Hemorrhage. | | | | |
| 39 | Beck. | Schmidt Jahrbuch, No. 150, p. 307. | F. | | L. | Removed tumor of neck (cancer). | | | | |
| 40 | Bell, Jos. (Edinburgh). | Schmidt Jahrbuch, No. 135, p. 293. | M. | 42 | L. | Traum. aneur. of left orbit. | 13 mos. | | | |
| 41 | Bell (England), 1867. | New York Med. Jr., 1869. | | | | Traum. aneur. of orbit. | | | | |
| 42 | Bentley, E. | Med. Surg. Hist. Reb. | M. | | | Wound of middle meningeal. | | | | |
| 43 | Bentley, E., 1864. | do. | M. | Mid age | L. | Shot wound of int. jugular vein and com. carotid. | 5 days. | | May 10. | May 15. |
| 44 | do. | do. | M. | 30 | R. | Shot w'd of head. | | | | |
| 45 | Benedict, 1833. | Arch. Klin. Chir. | F. | 33 | R. | Aneur. carotid. | 18 mos. | | | |
| 46 | Benoit, 1852. | do. | M. | 54 | R. | Aneur. of facial artery. | | | | |
| 47 | Bernard. | Schmidt Jahrb., B. 156, S. 200. | M. | 51 | | Hem.; phagedenic ulceration. | | | | |
| 48 | Bernard, 1833. | Gaz. Med., 1833; Arch. Klin. Chir. | F. | 39 | R. | Aneur. anast. near ear. | 8 years. | | | |
| 49 | Bertherand, 1851. | Ehrmann, des effets. | M. | 30 | L. | Shot wound facial artery. | | | | |
| 50 | Bertherand, 1890. | do. | F. | 4½ mos | L. | Erect. tum., temp. region. | 4½ mos. | | | |
| 51 | Beyer, 1846. | Arch. Klin. Chir. | M. | 24 | R. | W'd of neck, high up. | 11 days. | | | 4, 7, 10 days. |

Common Carotid Artery—continued.

| No. | Date of operation. | Hemorrhage occurred, after op. | Lig came away No. days aft. op. | RESULT. | | | REMARKS. |
|-----|--------------------|--------------------------------|---------------------------------|------------|-------------|-----------------------------------------------|----------------------------------------------------------------------------------------------------------------------------------------------------------|
| | | | | Recovery. | Condition. | Cause of death, date after op. | |
| 24 | Sept. 15, 1849. | | 22 | Recovered. | Cured. | | Symptoms of paralysis followed operation, but disappeared in a few days. |
| 25 | April 6, 1854. | | | | | 9th day; pyæmia; pneumonia; abscess of brain. | On account of hemorrhage during removal, carotid tied; hemiplegia 5th day. |
| 26 | May 27, 1866. | | | Recovered. | Cured. | | Headache, dyspnoea; hemiplegia 3d to 7th day. |
| 27 | 1874-5 ? | | | Recovered. | Cured. | | Carbolized catgut; pulsation tumor ceased after operation; hole through parietal bone eroded by tumor, covered with plate. |
| 28 | Sept. 17, 1825. | | | | | 2 months; encephalitis; gastric fever. | Symptoms of paralysis after operation. Autopsy: Inflammation of brain, pus in right hemisphere; inferior jugular vein tied in same ligature with artery. |
| 29 | Nov. 3, 1847. | | 13 | Recovered. | Cured. | | |
| 30 | June 26, 1825. | | 17 | Recovered. | | | |
| 31 | 1855. | | | | | | Died. Cause of death not stated. |
| 32 | do. | | | | | | Died. Cause of death not stated. |
| 33 | do. | | | | | | Died. Cause of death not stated. |
| 34 | | | | Recovered. | | | No cerebral symptoms. |
| 35 | March 21, 1827. | | | Recovered. | (Doubtful.) | | "Condition unchanged." |
| 36 | April 24, 1835. | | 14 | Recovered. | Cured. | | Cerebral symptoms followed for a few days after operation. |
| 37 | July 9, 1864. | | | | | 12th day; cerebral softening. | "Left hemiplegia on 10th day. Autopsy - <i>Hyperæmia of brain same side of ligature.</i> " |
| 38 | | | | Recovered. | Cured. | | Difficult deglutition and restlessness after operation. |
| 39 | | | 16 | | | Few weeks; cancer. | |
| 40 | | | 19 | Recovered. | Cured. | | |
| 41 | 1867. | | | Recovered. | Cured. | | |
| 42 | | | | | | 15th day; pyæmia. | |
| 43 | May 15, 1864. | 6th day. | | | | 6th day; hem. | |
| 44 | June 8, 1864. | 5th day. | | | | 6th day; hem. and shock. | Ball entered near occipital protuberance, out right auditory meatus. |
| 45 | June 24, 1833. | | 14 | Recovered. | Cured. | | Pulsation returned in tumor. Headache after operation. |
| 46 | | | | Recovered. | Cured. | | Electro-puncture had been tried. |
| 47 | | | | Recovered. | Cured. | | |
| 48 | March 26, 1833. | | | Recovered. | Cured. | | No cerebral symptoms. |
| 49 | June 28, 1854. | | | Recovered. | Cured. | | Cerebral trouble followed. |
| 50 | | | | Recovered. | Cured. | | Ext. carotid tied first; as tumor was not affected, the carotid (common) was tied and the first ligature removed. No cerebral symptoms followed. |
| 51 | 1846. | | 13 | Recovered. | Cured. | | |

Surgical History of the

| No. | Name of operator. | Source of information. | PATIENT. | | | Cause of operation. | Duration of cause. | Point of deligation. | Date of injury | Date of hemorrh'ge. | |
|-----|---------------------|-----------------------------------------|--------------|---------|-------|------------------------------------------------------------------|--------------------|----------------------------------------|----------------|---------------------|--------------|
| | | | Sex. | Age. | Side. | | | | | | |
| 52 | Bickersteth. | Schmidt Jahrb., B. 144, S. 87. | | | | Aneur. com. carotid, high up. | 1 year. | | | | |
| 53 | Billroth, 1864. | Dr. Ch. Pliz, in Langenbeck's Archives. | M. | 27 | R. | Hem. of int. carotid. | | | | | |
| 54 | | | do. | do. | M. | 27 | L. | do. | | | |
| 55 | | | Boeck, 1855. | do. | M. | 68 | R. | Hemorrh'ge; stab mouth, piece of wood. | 7 days. | | 3 or 4 days. |
| 56 | Boeckel, 1861. | do. | F. | 50 | R. | Hemorrhage. | | | | | |
| 57 | do. | Schmidt, B. 169, S. 161. | M. | 28 | R. | Wound of throat, piece of glass (ext. carotid and sup. thyroid). | | | | | |
| 58 | Boileau, 1822. | Ehrmann, des effets; Arch. Klin. Chir. | M. | 36 | R. | Knife wound of neck. | | | | | |
| 59 | Boekenheimer, 1855. | Arch. Klin. Chir. | F. | 44 | L. | Hem.; cancer. | | | | | |
| 60 | Bonet, 1823. | do. | M. | 31 | L. | Hem.; abscess in neck. | | | | | |
| 61 | Bojanus. | do. | | | L. | Nasal polypus. | | | | | |
| 62 | Bontecou, 1862. | Med. Surg. Hist. Reb. | M. | Mid age | L. | Shot w'd of face. | | | May 5. | May 16. | |
| 63 | Bouyer, 1869. | Arch. Klin. Chir. | | | | Removed tumor; parotid. | | | | | |
| 64 | Bowker, 1872. | Lancet, Oct. 11, 1873. | M. | 23 | L. | Hem.; aneur.; ext. carotid. | 2 mos. | Above omo-hyoid. | | | |
| 65 | Bowman, 1859. | Med. Times & Gaz., 1860. | F. | 41 | R. | Traum. aneur. of orbit. | 5 mos. | | | | |
| 66 | Bowman, 1860. | Arch. Klin. Chir. | F. | 40 | L. | Spont. aneur.; orbit. | | | | | |
| 67 | Bos. | Norris Contrib. | F. | 17 | R. | Tumor of Diploë. | 20 mos. | | | | |
| 68 | Buck, Gurdon, 1839. | N. Y. Med. Jr., July, 1837. | M. | 19 | R. | Enceph. tumor; parietal bone. | | | | | |
| 69 | Buck, Gurdon, 1842. | do. | M. | 39 | R. | Suicidal cut-thr't. | 11 days. | | June 28. | Often. | |
| 70 | Buck, Gurdon, 1848. | do. | M. | 30 | R. | Lacerated (glass) wound of angle of jaw. | 5 days. | | July 4. | | |
| 71 | Buck, Gurdon, 1852. | do. | M. | 22 | R. | W'd of ext. carotid or branches. | | | | | |
| 72 | Buck, Gurdon, 1857. | N. Y. Med. Jr., March, 1869. | M. | 22 | R. | Traum. aneur. of right orbit. | | | | | |
| 73 | | | do. | M. | 24 | L. | | | | | |
| 74 | Bunger, 1824. | Arch. Klin. Chir. | M. | 39 | R. | Suicidal wound of neck. | | | | | |
| 75 | Busch, 1865. | do. | M. | 27 | R. | Hem.; mouth; in typhus fever. | 14 days. | | | | |
| 76 | Busch, 1819. | do. | M. | 34 | L. | Aneur. anast. of head and face. | | | | | |
| 77 | Bush, 1827. | Norris Contrib. | F. | 36 | R. | Aneur.; com. carotid, low down. | | | | | |
| 78 | Bushe, 1830. | do. | M. | 19 | L. | Erect. tumor of cheek. | 19 y'rs. | | | | |

Common Carotid Artery—continued.

| No. | Date of operation. | Hemorrhage occurred, after op. | Lig. came away No. days aft. op. | RESULT. | | | REMARKS. |
|-----|--------------------|--------------------------------|----------------------------------|------------|--------------------------|-----------------------------------------------------|-------------------------------------------------------------------------------------------------------------------------------------------------------------------------------------------------------------------------------------|
| | | | | Recovered. | Condition. | Cause of death, date after op. | |
| 52 | | | | Recovered. | Cured. | | Carbolized catgut. |
| 53 | Dec. 13, 1864. | Often. | | | | 3 days after last op. hem. and cerebral exhaustion. | Had had syphilis. Hemorrhage and suppuration from ears repeated. No cerebral symptoms followed first op., loss of consciousness after second. |
| 54 | Dec. 26, 1864. | 3d day. | | | | | |
| 55 | Dec. 1855. | | | | | 2d day, exhaustion. | No anæsthesia. |
| 56 | Nov. 14, 1861. | | | | | 3d day, coma. | Ext. carotid had been previously tied. Autopsy: Inflammation of dura mater. Internal carotid also tied, paralysis. |
| 57 | | | | Recovered. | Cured. | | |
| 58 | | | | Recovered. | Cured. | | |
| 59 | Dec. 14, 1865. | | 17 | | | 44 days; cerebral complications. | |
| 60 | Sept. 24, 1823. | | | Recovered. | Cured. | | Slight brain trouble. |
| 61 | | | 13 | | | 13th day, pyæmia. | |
| 62 | May 16, 1866. | 7th day. | | | | 7th day, hem. | Ball entered left side of chin, broke jaw, carried several teeth away, part of tongue and pharynx; fractured transverse process 3d cervical, against which <i>vertebral artery</i> had cut itself through causing fatal hemorrhage. |
| 63 | June 13, 1860. | | | | | Several days coma. | |
| 64 | | | 18 | Recovered. | Cured. | | |
| 65 | Feb. 28, 1859. | 10, 11, 12 day. | | | | 17th day, hem. | |
| 66 | June 18, 1860. | | 17 | Recovered. | | | Permanent paralysis of sixth nerve. |
| 67 | | After. | | | | | ? Diarrhœa and hem. |
| 68 | Dec. 21, 1839. | 63 day. | | Recovered. | Not cured. | | Died 11 months of hemorrhage and disease. |
| 69 | July 9, 1842. | 2 hours. | 17 | Recovered. | Cured. | | |
| 70 | July 9, 1848. | 71 day. | 12 | Recovered. | Cured. | | Hem. on 71st day, ceased spontaneously. Int. carotid tied. Facial paralysis persistent and complete. (Due to injury.) Int. carotid also tied. |
| 71 | May 10, 1852. | | | | | 11th day, pyæmia. | |
| 72 | Dec. 22, 1857. | | | Recovered. | Not cured. | | Fell from mast striking on feet. 5 mos. after first operation no improvement. 8 mos. later left carotid tied. |
| 73 | Feb. 23, 1859 | | | Recovered. | Cured, with loss of eye. | | |
| 74 | Feb. 19, 1824. | | | Recovered. | Cured. | | |
| 75 | Nov. 23, 1865. | | | | | 2d day; cerebral symptoms and exhaustion. | |
| 76 | May 10, 1819. | | 12 | Recovered. | Improved. | | |
| 77 | Sept. 11, 1827. | | | Recovered. | Cured? | | Tumor was large and suffocation imminent. 27th day tumor diminished one half. 3 years later well. <i>Bradford</i> . |
| | Jan. 15, 1830. | | 29 | Recovered. | Cured. | | |

Surgical History of the

| No. | Name of operator. | Source of information. | PATIENT. | | | Cause of operation. | Duration of cause. | Point of deligation. | Date of injury. | Date of hemorrh'ge. |
|-----|-------------------------------|-----------------------------------------------------------------|----------|-------------|-------|-------------------------------------------------------|--------------------|-------------------------|-------------------|---------------------|
| | | | Sex. | Age. | Side. | | | | | |
| 79 | Busk, 1836. | Med. Chir. Trans., vol. xxii. p. 124. | M. | 20 | R. | Aneur. of orbit. | 6 mos. | | | |
| 80 | Butcher, 1863. | Arch. Klin. Chir. | M. | 42 | R. | Aneur. innom. | | | | |
| 81 | Byrd, W. A., 1876. | N. Y. Med. Jr., Aug. 1876. | M. | Mid age. | L. | Shot w'd of ext. and int. carotid angle of jaw. | 7 hours. | | | |
| 82 | Bjerken, 1807 (Sweden). | Arch. Klin. Chir. | F. | 32 | R. | Aneur. branch of ext. carotid be- hind ear. | 8 years | | | |
| 83 | Blackman, 1843. | Norris Contrib. | M. | 30 | R. | Fung. tumor of neck. | 2 years. | | | |
| 84 | Blackman, 1848. | Am. Jr. Med. Sci., April, 1848, p. 357. | M. | 15 | R. | Fungus hematod. | do. | | | |
| 85 | do. | Arch. Klin. Chir. | M. | 15 | L. | do. | do. | | | |
| 86 | Blasius, 1831. | do. | M. | 30 | L. | Cancer parotid. | | | | |
| 87 | Bliss, D. W., 1864. | Med. Surg. Hist. Reb. | M. | Mid age. | R. | Shot wound inf. maxilla. | 44 days. | | May 12. | |
| 88 | Bliss, Z. E., 1862. | do. | M. | Mid age. | R. | Shot wound of lingual artery. | | | May 3. | May 31. |
| 89 | Brainard, D., 1852. | Arch. Klin. Chir. | M. | 34 | L. | Aneur. anast. or- bit. | 4 mos. | | | |
| 90 | Brce, 1841. | do. | | | | Shot wound. | | | | |
| 91 | Brett. | Norris Contrib. | F. | 17 | | Tumor of parotid. | 5 years. | | | |
| 92 | Breed, B. B., 1864. | Med. Surg. Hist. Reb. | M. | Mid age. | R. | Shot wound right malar and inf. max. | | Below omo- hyoid. | Aug. 1. | Aug. 29, 30. |
| 93 | Brewer, G. G., 1864. | do. | M. | Mid age. | L. | Shot wound neck and cheek. | | | | Oct. 19, 1864. |
| 94 | Bramblett, 1864 | New York Med. Rec., June, 1869. | M. | 47 | L. | Shot wound of cheek. | | | | 10th day. |
| 95 | Briddon, C. K., 1858. | Letter to author. | F. | 40 | L. | Malg. tum. orbit. | Some time. | | | |
| 96 | Briggs, W. T., 1871. | Nash. Jr. Med. Surg., Feb. 1874; Dr. Bowl- ing to author. | M. | 23 | L. | Stab wound int. carotid; aneur- ism. | Several weeks. | Above omo- hyoid. | Jan. 25, 1871. | Often. |
| 97 | Brown, B., 1848. | Am. Jr. Med. Sci., Oct. 1854, p. 415. | F. | 22 | R. | Epilepsy. | 5 years. | | | |
| 98 | Brown, J., 1817. | Norris Contrib. | M. | 35 | R. | Hem.; cut-throat. | 7 days. | | | |
| 99 | Brodie, 1816 (Blagden). | Med. Chir. Trans., vol. viii. p. 224. | M. | 26 | L. | Hem.; extract. of 2d molar of left upper jaw. | 5 days. | | June 30. | Often. |
| 100 | Broca, 1866. | Arch. Klin. Chir. | M. | 47 | R. | Hem. of carotid. | 39 days. | | Feb. 15. | Often. |
| 101 | Von Bruns, 1859. | do. | F. | | R. | Hem. after remov- ing thyroid body. | | | | |
| 102 | Von Bruns, 1866. | do. | M. | Mid age. | L. | Second. hem. int. maxillary. | | | | |
| 103 | Von Bruns, 1844. | do. | M. | 5 m's. | R. | Buccal tumor. | 5 mos. | | | |
| 104 | Bryant, Prof. Thos., 1876. | Am. Jr. Med. Sci., April, 1877. | M. | 56 | R. | Aortic aneur. | Some time. | | | |
| 105 | Caldwell, 1840. | Norris Contrib. | F. | 60 | R. | Erect. tum. orbit. | 1 year. | | | |

Common Carotid Artery—continued.

| No. | Date of operation. | Hemorrhage occurred, after op. | Lig. came away No days aft. op. | RESULT. | | | REMARKS. |
|-----|------------------------------|--------------------------------|---------------------------------|------------|-------------|--------------------------------------------------|---------------------------------------------------------------------------------------------------------------------------------------------------------------------------------------------------------------------------------------------------------|
| | | | | Recovery. | Condition. | Cause of death, date after op. | |
| 79 | Feb. 2, 1836. | 1 day, 16 oz. | 13 | Recovered. | Cured. | | July 13, 1835, struck on head by gaff. Hem. immediate, right ear. July 28, pain in left eye. Sept. 3, ulceration cornea. Feb. 1, aneurism evident. Pressure on left carotid arrested pulsation. Loss of vision left eye after recovery. <i>Brasdor.</i> |
| 80 | May 6, 1863. | | | | | 88 hours. | |
| 81 | May, 1876. | | | | | 20 minutes; previous hemorrhage. | |
| 82 | Oct. 9, 1807. | | | Recovered. | Improved. | | 16 years after tumor began to grow again. |
| 83 | Jan. 21, 1843. | | | | | 8 day (exhaustion.) | |
| 84 | 1848. | | 13 | Recovered. | | | |
| 85 | } 3 weeks later 2d operat'n. | | | | | | |
| 86 | | 1831. | | 14 | Recovered. | (Uncertain.) | 6th day, pyæmia. |
| 87 | June 25, 1864. | | | Recovered. | Cured. | | |
| 88 | Sept. 4, 1862. | | | Recovered. | "Disabled." | | 1870 reported "disability $\frac{2}{3}$ and permanent." |
| 89 | 1852. | | 14 | Recovered. | | | |
| 90 | | | | Recovered. | Cured. | | |
| 91 | | | | Recovered. | Cured. | | |
| 92 | Aug. 30, 1864. | | | | | Same day; exhaustion. | |
| 93 | Nov. 9, 1864. | | | | | Same day; exhaustion. | Ball entered back of neck (left side) and passed out through cheek. |
| 94 | Dec. 1864. | | 18 | Recovered. | Cured. | | 10th day after wound., internal carotid tied. Hem. followed, and common and external carotid secured. Hem. still, arrested by styptic. |
| 95 | July 7, 1858. | | | | | 12th day; cerebral symptoms. | |
| 96 | Feb. 23, 1871. | | | Recovered. | Cured. | | Com. carotid tied first; hem. did not cease; sac opened and both ends of internal carotid tied. No cerebral symptoms followed. |
| 97 | | | 20 | Recovered. | Cured. | | Well in 1853. |
| 98 | June 14, 1817. | | 12 | Recovered. | Cured. | | |
| 99 | July 5, 1816. | 5 minutes. | | | | 2 days; hem. and exhaustion. | Hemorrhage after op. from tooth and wound of op. <i>Hemorrhagic diathesis.</i> |
| 100 | March 26, 1866. | 13 days. | | | | 27 days. | Cavern in right lung. Hem. (General bad condition may account for death.) |
| 101 | July 11, 1859. | Often. | | | | 9 days; abscess of right hem.; coma; hemorrhage. | Autopsy. (See cause of death.) |
| 102 | | | | Recovered. | Cured. | | |
| 103 | | | 19 | Recovered. | Cured. | | |
| 104 | 1876. | | | | | 10th day. | Autopsy: Ascending and transverse arch of aorta enormously enlarged. Right jugular vein, right carotid, and subclavian artery occluded. <i>Distal; Wardrop.</i> |
| 105 | Sept. 16, 1840. | | 39 | Recovered. | Cured. | | |

Surgical History of the

| No. | Name of operator. | Source of information. | PATIENT. | | | Cause of operation. | Duration of cause. | Point of deligation. | Date of injury. | Date of hemorrhage. |
|------|------------------------|------------------------------------------------------------|----------|----------|-------|---------------------------------------|--------------------|----------------------|-----------------|---------------------|
| | | | Sex. | Age. | Side. | | | | | |
| 106 | Campbell, 1845. | Arch. Klin. Chir. | M. | 48 | R. | Supposed aneur. of innominate. | | | | |
| 107 | Cantrell, J. Y., 1862. | Med. Surg. Hist. Reb. | M. | Mid age. | | Shot wound neck, near larynx. | | | May 8. | May 15. |
| 108 | Carnochan, New York. | Am. Jr. Med. Sci., July, 1867. | F. | 34 | R. | Elephantiasis Græcorum. | | | | |
| 109 | do. | do. | F. | 34 | L. | do. | | | | |
| 110 | Carpul. | Arch. Klin. Chir., B. ix. | | | | Hemorrhage. | | | | |
| 111 | De Castro, 1864. | Arch. Klin. Chir., B. xvii. | M. | 31 | R. | Aneur. of extrnal carotid. | 15 mos. | | | |
| 112 | Catollica, Catollica ? | Arch. Klin. Chir., B. ix. | M. | | L. | Traum. aneur. of vertebral. | | | | |
| 113 | Cockle, John, 1872 ? | Am. Jr. Med. Sci., April, 1873. | M. | 48 | L. | Aneur. ascend. aorta. | | | | |
| 114 | Coe, 1851. | Letter from Prof. Paul F. Eve to author; Arch. Klin. Chir. | F. | 55 | L. | Traum. aneur. of carotid. | 5 mos. | | | |
| 115 | Coates, 1816. | Norris Contrib.; Arch. | M. | 41 | L. | Aneur. of com. carotid. | 6 mos. | | | |
| 116 | Cogswell, 1803. | Norris Contrib. | F. | 37 | L. | Tum. of parotid. | do. | | | |
| 117 | Cole, 1815. | Arch. Klin. Chir. | M. | | L. | Shot wound. | 11 days. | | | |
| 118 | Collier, 1815. | Norris Contrib. | M. | 27 | L. | Hem. of wound of angle of jaw. | 5 days. | | | |
| 119 | Colson, 1839. | Norris Contrib.; Arch. Klin. Chir. | F. | 63 | L. | Aneur. of carotid. | | | | |
| 120 | Cooper, A., 1805. | Med. Chir. Trans., vol. i. | F. | 44 | R. | do. | 5 mos. | | | |
| 121 | do. 1808. | Med. Chir. Trans., vol. i. p. 224. | M. | 50 | L. | Aneur. int. carotid. | 6 mos. | | | |
| 122 | Cooper, B., 1840. | Norris Contrib. | M. | 34 | R. | Aneur. com. carotid. | 1 year. | | | |
| 777) | do. | Lancet, 1846, vol. i. p. 134. | M. | | | Hem.; suicidal cut-throat. | | | | |
| 123 | Coote, H., 1858. | London Med. Times & Gaz., vol. i. 1858. | M. | 64 | R. | Fung. growth of right sup. max. | | | | |
| 124 | do. 1863. | Arch. Klin. Chir. | M. | 46 | L. | Hem.; removed sup. maxilla. | | | | Aug. 18. |
| 125 | Curling, T. B., 1854. | Med. Chir. Trans., vol. xxxvii. p. 221. | M. | 49 | R. | Aneur. of orbit; traum. | | | | |
| 126 | Curtis, 1857. | Am. Jr. Med. Sci., 1861. | M. | | R. | Shot wound of month. | 2 w'ks. | | | |
| 127 | Cusack, 1820. | Norris Contrib.; Arch. Klin. Chir. | M. | 36 | L. | Hem.; wound of throat. | | | | |
| 128 | do. 1836. | Dub. Med. Jr., Feb. 1847, p. 262. | M. | 20 | L. | Aneur. of carotid; traum. | 8 years. | | | |
| 129 | Cuveiller, 1860. | Poland in Guy's Hosp. Rep., vol. xv. 1870. | M. | 24 | R. | Aneur. subclav.; bayonet wound. | 2 mos. | Below omo-hyoid. | | |
| 130 | Chadwick. | Lancet, 1851, vol. i. p. 177. | M. | 13 | R. | Lacerated scalp by circular saw; hem. | 12 days. | | | |
| 131 | Chapel. | Arch. Klin. Chir. | | | | Aneur. carotid. | | | | |

Common Carotid Artery—continued.

| No. | Date of operation. | Hemorrhage occurred, after op. | Lig. came away No. days aft. op. | RESULT. | | | REMARKS. |
|------|---------------------------|--------------------------------|----------------------------------|------------|-------------|------------------------------------|----------------------------------------------------------------------------------------------------------------------------------------|
| | | | | Recovery | Condition. | Cause of death, date after op. | |
| 106 | March 8, 1845. | | | | | 19th day, fever, delirium. | Autopsy: Inflammation lungs. Aneurism of arch of aorta. Carotid occluded. <i>Distal</i> ; <i>Wardrop</i> . |
| 107 | May 24, 1862. | | | | | D. 6 weeks. | |
| 108 | 6 m'nths between both op. | | | Recovered. | | | "6 months after 1st op. improvement marked. 8 years later patient was quite presentable; could see, hear, smell, and taste well!" |
| 109 | | | | Recovered. | Improved. | | |
| 110 | | | | Recovered. | Cured. | | |
| 111 | 1864. | 3 days. | 26 | | | 43d day, hem. and prostration. | 3d day sac opened and external carotid was tied. Aneurism located on vertebral artery. <i>Distal</i> . |
| 112 | | Often. | | | | Hem.; sac burst. | |
| 113 | | | | Recovered. | Improved. | | 12 months after op. patient was working as farm laborer. (Am unable to say whether this case is identical with Mr. Heath's or not.) |
| 114 | | | 33 | Recovered. | Cured. | | |
| 115 | Jan. 3, 1816. | | | | | 71st day, hem. | |
| 116 | Nov. 14, 1803. | 45-46, 49-57 days. | | | | 20th day, hem. | |
| 117 | June 28, 1815. | Often. | 14 | | | 4th day, asphyxia. | 2 ligatures, vessel cut between. Hyoid bone broken. Severe laceration. (Ligature probably slipped over end of artery.) Pus in bronchi. |
| 118 | June 22, 1815. | | 13 | Recovered. | Cured. | | |
| 119 | 1839. | 21 days. | 28 | Recovered. | (Improv'd.) | | |
| 120 | Nov. 1, 1805. | | 11 | | | 20th day, inflam. of sac. | Partial paralysis of left side. 2 ligatures; vessel not divided. Inflam. of sac and pressure on larynx caused difficult respiration. |
| 121 | June 22, 1808. | | 22 and 23 | Recovered. | Cured. | | |
| 122 | April 7, 1840. | | 33 | Recovered. | Cured. | | |
| 777) | | Often. | | | | 21st day. | "Died from mental disturbance and irritation of wound." This case not numbered by mistake—numbered at the last. |
| 123 | | | | | | 3d day, hem.; cerebral exhaustion. | |
| 124 | Aug. 22, 1866. | | | | | 2 hours, exhaustion. | Paralysis resulted. Autopsy: Right hemisphere softened. |
| 125 | June 2, 1834. | | 23 | Recovered. | Cured. | | |
| 126 | April 19, 1857. | | 14 | Recovered. | Cured. | | Cerebral symptoms followed, but gradually disappeared. |
| 127 | Aug. 16, 1820. | 32d day. | 21 | | | 60th day, hem. | No cerebral symptoms followed. |
| 128 | Nov. 22, 1836. | | 22 | Recovered. | Cured. | | Sup. thyroid tied; 32d day after hem. and common carotid tied a second time. Hemorrhage persisted. |
| 129 | 1860. | 7th day. | | | | 10th day, hem. | |
| 130 | | | 24 | Recovered. | Cured. | | Right subclavian tied same time. <i>Distal</i> . |
| 131 | | | | | | 4th day, cerebral softening. | Bones of skull were deeply indented by saw-teeth. |
| | | | | | | | Autopsy: Breaking down of brain substance. |

Surgical History of the

| No. | Name of operator. | Source of information. | PATIENT. | | | Cause of operation. | Duration of cause. | Point of deligation. | Date of injury. | Date of hemorrh'ge. |
|-----|-----------------------|--------------------------------------------------|----------|----------|-------|---------------------------------------------------------------------------|--------------------|----------------------|-----------------|---------------------|
| | | | Sex. | Age. | Side. | | | | | |
| 132 | Cheever, 1862. | Med. Surg. Hist. Reb. | M. | Mid age. | L. | Shot wound of left side of face. | | Above omo-hyoid. | May 31. | June 13-14. |
| 133 | Chelius, 1836. | Norris Contrib. | M. | 19 | R. | Aneur. varix. of temp. region. | 1 year. | | | |
| 134 | Chaumet. | Arch. Klin. Chir. | M. | 55 | ... | Removed cancer of parotid. | | | | |
| 135 | Chassaignac, 1859. | Traité des opérations, p. 326. | M. | 26 | L. | Hem. after puncture of retro-pharyngeal abscess; w'd of internal carotid. | Short time. | | | |
| 136 | Cherry, 1858. | Ehrmann des effets. | F. | 12 | ... | Erect. tumor (fungus). | | | | |
| 137 | Chesley, 1864. | Med. Surg. Hist. Reb. | M. | | | Shot wound sup. max. | | | Sept. 30. | Oct. 7. |
| 138 | Chiari, 1829. | Norris Contrib. | M. | 28 | L. | Traum. aneur. of vertebral artery. | | | | |
| 139 | Clark, Le Gros, 1846. | do. | M. | 29 | L. | Wound of external carotid. | | | | |
| 140 | Clark, Le Gros, 1860 | Med. Times & Gaz., 1860, vol. i. p. 190. | M. | 27 | L. | Stab w'd of neck (carving-knife). | 1½ hrs. | | | |
| 141 | Clarke, W. S., 1855. | Lancet, 1855, vol. ii. p. 165; Arch. Klin. Chir. | M. | 35 | R. | Aneur. of carotid (angle of jaw). | 6 mos. | | | |
| 142 | Claus, 1846. | Arch. Klin. Chir. | | 61 | R. | Suicidal cut-thr't. | | | | |
| 143 | Cleary, 1864. | Arch. Klin. Chir., vol. xvii. p. 626. | M. | | R. | Shot w'd of face. | 33 | | | |
| 144 | Cline, 1808. | Norris Contrib. | M. | | | Aneurism. | | | | |
| 145 | Critchett, 1854. | Arch. Klin. Chir., 1868. | M. | 28 | R. | Hem.; abscess. | | | | |
| 146 | do. 1855. | Med. Times & Gaz., 1855. p. 437. | M. | 25 | ... | Hem.; aneur. of orbit. | | | | |
| 147 | Crosby, T. R., 1864. | Med. Surg. Hist. Reb. | M. | 17 | L. | Shot w'd through left temporal bone. | | | May 6. | June 2 and 20. |
| 148 | do. | | M. | 17 | L. | Same vessel tied again. | | | | |
| 149 | De Cruz, 1825. | Norris Contrib. | M. | 44 | L. | Wound of throat. | | | | |
| 150 | Dalrymple, 1813. | Med. Chir. Trans., vol. vi. p. 111. | F. | 44 | L. | Erect. tumor of orbit. | 9 mos. | | | |
| 151 | Davidge, 1823. | Norris Contrib. | M. | | L. | Fung. of antrum. | | | | |
| 152 | Davis, R., 1860. | Ed. Med. Jr., Jan. 1862, p. 685. | M. | | L. | Suicidal cut-thr't; angle of jaw. | | | | |
| 153 | Debrou, 1837. | Schmidt, B. 138, S. 53. | M. | 31 | R. | Stab in neck (knife). | Few hours. | | | |
| 154 | Décès, 1839. | Ehrmann des effets; Arch. Klin. Chir. | F. | 44 | R. | Aneur. of carotid (traumatic). | 1 year. | | | |
| 155 | do. 1850. | do. | F. | 54 | R. | do. | 10½ yrs. | | | |
| 156 | Dehane, 1832. | Am. Jr. Med. Sci., vol. x. p. 496. | F. | 10 | R. | Aneur., traum. | | | | |
| 157 | Delpesch, 1831. | Arch. Klin. Chir. | M. | 31 | L. | Hem. of nose. | 54 days. | | | |
| 158 | Demme, 1859. | Arch. Klin. Chir., vol. ix. and xvii. | M. | | R. | Shot wound of temp. artery. | 35 days. | | | |
| 159 | do. | do. | M. | | L. | Shot wound inf. max. (fracture). | 25 days. | | | |
| 160 | Demme, 1840. | do. | M. | 38 | R. | Aneur. of carotid. | | | | |
| 161 | do. | do. | | | | | | | | |
| 162 | Deguisé, 1827. | Ehrmann des effets. | F. | | | Erect. tumor. | | | | |
| 163 | Delore, 1860. | Gaz. des Hôp., 1860. | M. | 63 | | Aneur. of carotid. | 6 mos. | | | |
| 164 | Désprés (Sedan). | Gaz. des Hôp., 1871, p. 362. | M. | 23 | R. | Shot wound of face and neck. | | Above omo-hyoid. | Sept. 1. | Sept. 9. |

Common Carotid Artery—continued.

| No. | Date of operation. | Hemorrh ^{ge} occurred, after op. | Lig. came away No. days aft. op. | RESULT. | | | REMARKS. |
|-----|--------------------|-------------------------------------------|----------------------------------|------------|---------------------|--------------------------------|---------------------------------------------------------------------------------------------------------------------------------------------------------------------------------------------------------------------------|
| | | | | Recovery. | Condition. | Cause of death, date after op. | |
| 132 | June 14, 1862. | | | | | 10th day. | |
| 133 | Jan. 18, 1836. | | 21 | Recovered. | Cured. | | |
| 134 | | | | | | 8th day. | Artery tied 3 times in succession before hemorrh'ge was arrested. Cerebral symptoms on 2d day. |
| 135 | Aug. 1859. | | | Recovered. | Cured. | | Hem. profuse before op.; after op. aphonia and headache for 24 hours. |
| 136 | | | | Recovered. | Cured. | | |
| 137 | Oct. 7, 1864. | | | | | 5th day. | |
| 138 | July 18, 1829. | | | | | 9th day. | Autopsy: Aneurismal of vertebral artery between 1st and 2d cervical. <i>Wardrop.</i> |
| 139 | Oct. 14, 1846. | | 16 | Recovered. | Cured. | | |
| 140 | Jan. 23, 1860. | | 16 | Recovered. | Cured. | | |
| 141 | July 25, 1855. | | | Recovered. | Cured. (?) | | |
| 142 | Dec. 31, '46. | | | | | 3d day. Glossitis. | Autopsy: Thrombus in carotid. |
| 143 | Oct. 4, 1864. | | | | | 2d day. | Ext. carotid tied 14 days after injury. Common carotid 33. |
| 144 | Dec. 16, 1808. | After. | | | | 4th day. Hem. | |
| 145 | | do. | | | | 3d day. Exhaustion | |
| 146 | | | | | | 4 or 5 months. Hem. | No cerebral symptoms. |
| 147 | June 20, 1864. | 45th day. | 10 | Recovered. | | | Ball entered over left ear; opening large as two fingers; out 3 inches anterior; dura mater not opened. May 17, headache; 20th, comatose; June 2, hem.; June 20, ligature; 45 days later hem.; common carotid tied again. |
| 148 | 45 days later. | | | Recovered. | Cured. | | |
| 149 | Feb. 27, 1825. | | | Recovered. | Cured. | | |
| 150 | April 7, 1813. | 85th day. | 11-27 | Recovered. | Cured; loss of eye. | | 2 ligatures, artery divided between. |
| 151 | April, 1823. | None. | 21 | Recovered. | Cured. | 6 weeks. Tetanus. | Carotid tied between two tendons of origin of sterno-mastoid. |
| 152 | 1860. | | | Recovered. | Cured. | | Headache as a sequel. |
| 153 | 1867. | | 12 | Recovered. | Cured. | | |
| 154 | Feb. 25, 1839. | | 15 | Recovered. | Improved. | | |
| 155 | Sep. 2, 1850. | | 18 | Recovered. | Cured. | | |
| 156 | Jan. 20, 1832. | | 11 | Recovered. | Cured. (?) | | "Very much improved." |
| 157 | 1831. | | | | | 10th day. | Autopsy: Pus at base of brain; inflam. internal jugular vein. |
| 158 | 1859. | | | Recovered. | Cured. | | |
| 159 | | | | Recovered. | Cured. | | |
| 160 | Sept. 24, 1840. | 9, 11, 17 days. | | | | 49th day. Pyæm. Exhaustion. | Cerebral symptoms 5 days after op.; relieved by venesection. Autopsy: Pus in sac and in tissues near wound. |
| 161 | | | | Recovered. | Cured. | | |
| 162 | | | | | | Died. (?) | |
| 163 | | After. | 30 | | | 49th day. Hem. | |
| 164 | Sept. 9. | | | | | 5th day. Coma. | Facial paralysis 2d day after op. (left); 3d day paralysis body on left side. |

Surgical History of the

| No. | Name of operator. | Source of information. | PATIENT. | | | Cause of operation. | Duration of cause. | Point of deligation. | Date of injury. | Date of hemorrhage |
|-----|---------------------------|--------------------------------------------------|----------|-------|-------|---------------------------------------------------------------|--------------------|----------------------|-----------------|--------------------|
| | | | Sex. | Age. | Side. | | | | | |
| 165 | Désprés (Sedan). | Gaz. des Hôp., 1871, p. 362. | M. | | | Shot w'd of ext. and int. carotid. | | | | |
| 166 | do. | do. | M. | | | do. | | | | |
| 167 | Dewar, 1860. | Med. Times & Gaz., 1860, vol. i. p. 90. | F. | 27 | R. | Hem.; pulsating tumor of tonsil. | | | | |
| 168 | Detmold, Prof. Wm., 1840. | Personally to author. | F. | 23 | R. | Vasc. tumor of right side head. | | | | |
| 169 | Detmold, Prof. Wm., 1842. | do. | M. | | L. | Vasc tumor chin. | | | | |
| 170 | Detmold, Prof. Wm., 1845. | do. | | 8 mos | L. | Aneur; anast. of left ear | | | | |
| 171 | Detmold, Prof. Wm., 1847. | do. | F. | 40 | R. | Malg. tumor (to arrest growth). | | | | |
| 172 | Detmold, Prof. Wm., ? | do. | M. | | | Removed sup. max.; malig. dis. | | | | |
| 173 | Dieffenbach, 28. | Arch. Klin. Chir. | M. | 3 | | Fung. of parotid. | | | | |
| 174 | Dietrichson. | do. | F. | 20 | R. | Hem. of tumor. | | | | |
| 175 | Dohlhoff, 1837. | Rust. Mag., 1838; Ehrmann des effets. | M. | 49 | R. | Fung. of medul. palate. | | | | |
| 176 | do. | do. | F. | 51 | R. | Aneur., innom. | | | | |
| 177 | Donaghe, 1856. | Prof. Jas. R. Wood in N. Y. Med. Jr., 1857. | F. | 15 | R. | Cancerous tumor of mouth. | | | | |
| 178 | Dudley, 1841. | Norris Contrib. | M. | | R. | Erect. tumor of orbit. | Several years. | | | |
| 179 | Duffin, 1823. ? | Lancet, 1823, vol. ii. p. 200. | F. | 4 | R. | Hem of facial artery. | | | | |
| 180 | Duke, 1847. | Lancet, 1848, vol. i. p. 233. | M. | 32 | R. | Traum. aneur. of carotid; pharynx (supposed abs.) | 1 year. | | | |
| 181 | Duncan, 1836. | Norris Contrib.; Arch. Klin. Chir. | M. | 60 | L. | Hem.; ulcer of throat. | | | | |
| 182 | do. 1843. | Edin. Med. & Surg. Jr., 1844, vol. lxii. p. 117. | F. | 30 | R. | Aneur. of carotid at bifurcation. | | | | |
| 183 | Dupont, 1814. | Norris Contrib. | M. | 27 | L. | Aneur. of carotid. | 6 mos. | | | |
| 184 | Dupuytren, 1814. | Norris Contrib.; Arch. Klin. Chir. | M. | 42 | R. | Shot w'd of ext. carotid and facial | 22 days. | | | |
| 185 | Dupuytren, 1818. | Ehrmann des effets; Arch. Klin. Chir. | F. | 76 | L. | Aneur. of internal carotid. | 8 years. | | | |
| 186 | do. | Norris Contrib. | M. | 20 | R. | Erect. tumor of ear and temple. | | | | |
| 187 | Dupuytren, 1835. | Arch. Klin. Chir. | M. | 18 | L. | Enceph. tumor of temp. region. | 15 mos. | | | |
| 188 | Dropsy, 1855 (Burnoth). ? | Arch. Klin. Chir. | F. | 25 | L. | Aneur. of carotid. traum. | 1 year. | | | |
| 189 | Dzondi, 1824. | Arch. Klin. Chir. | M. | 60 | R. | Hem.; cancer of tongue. | | | | |
| 190 | do. 1825. | do. | F. | 25 | L. | Removed inferior maxilla. | | | | |
| 191 | Doughty, F. E., 1875. | Prof. Alex. B. Mott to author. | M. | 45 ? | R. | Aneur.; root of neck (probably at bifurcation of innominate). | | | | |

Common Carotid Artery—continued.

| No. | Date of operation. | Hemorrh'ge occurred, after op. | Lig. came away No. days aft. op. | RESULT | | | REMARKS. |
|-----|--------------------|--------------------------------|----------------------------------|------------|-----------------------|--------------------------------------|------------------------------------------------------------------------------------------------------------------------------------------------------------------------------------------------------------------------------------------------------------------------------------------------------------------------------------------------------------------------------------------------------------------------------------------------------------------------------------------------------------------------------|
| | | | | Recovery. | Condition. | Cause of death, date after op. | |
| 165 | | After. | | | | Few minutes. Hem. | Fatal hemorrhage from distal end. |
| 166 | | do. | | | | do. do. | "L'hémorrhagie était tellement foudroyante que j'ai en a peine le temps de découvrir l'artère." |
| 167 | June 2, 1859. | | 14 | Recovered. | Cured. | | Syphilitic diathesis. |
| 168 | 1840. | | 16 | Recovered. | No improvement. | | "Op. made no impression on tumor; died 18 months later of phthisis." |
| 169 | 1842. | | 10 | Recovered. | Cured. | | "After ligature tumor laid open and hot iron applied." |
| 170 | 1845. | | 10 | Recovered. | Cured. | | |
| 171 | 1847. | | | Recovered. | (Growth checked.) | | Died 6 months later from disease. |
| 172 | | | | | | 4th day. | |
| 173 | 1828. | | | | | 14th day, of dis. (?) | |
| 174 | | 7th day. | | Recovered | Cured. | | |
| 175 | May 5, 1837. | | | | | 26th day. Cerebral softening. | 8th day after op. left paralysis. Autopsy: Brain softened. |
| 176 | 1837. | | | | | 5th day. Cerebral complications. | 3d day left paralysis. Autopsy: Caries of clavicle; hyperæmia of brain. |
| 177 | 1856. | | 15 | Recovered. | Arrested temporarily. | | "Died 4 months later exhausted by disease." |
| 178 | Jan. 1841. | | | Recovered. | Cured. | | |
| 179 | 1823 ? | None. | | | | Few hours. | "Hem. ceased after op. Autopsy: Ulceration of submaxillary gland." |
| 180 | June 10, 1847. | After. | 17 | | | 5 weeks. Hem. | Paralysis after op. slight. (Dr. Duke did not puncture the aneurism by mistake, but was called in to tie the carotid.— <i>Author.</i>) |
| 181 | March 29, 1836. | 4, 10, 11 days. | | | | 13th day. Bronchitis and hemorrhage. | Hem. central end of artery; peripheral end was occluded. |
| 182 | Dec. 25, 1843. | 15th day. | 25 | | | 17th day. Hem. and spasm of glottis. | Tracheotomy was performed before operation. Autopsy: Sac had burst into trachea. |
| 183 | 1814. | | | Recovered. | Cured. | | |
| 184 | Feb. 24, 1814. | | | | | 6th day. | |
| 185 | 1818. | | | | | 8th day. Cerebral complications. | After op. cough, difficult deglutition, and general insensibility. Autopsy: No appreciable change in cerebrum. |
| 186 | April 8, 1818. | | 12 | Recovered. | | | |
| 187 | Jan. 1835. | | | | | 15th day. Original disease. | |
| 188 | June, 1855 ? | | 18 | Recovered. | Cured. | | |
| 189 | 1824. | None. | | | | 5th day. Cerebral comp. and disease. | 3d day paralysis of left side. |
| 190 | July 8, 1825. | | | | | 18th day. Brain symptoms. | Autopsy: Softening of cerebrum. |
| 191 | Nov. 1, 1875. | | | Recovered. | Improved. | | This patient was operated upon by Prof. A. B. Mott one year after the above date, and the subclavian was tied in its 3d division. The author saw this man, by invitation of Prof. Mott, one year after the latter had tied the subclavian, when he was almost entirely recovered. A small tumor about the size of an almond, and quite hard, could be felt just behind the sterno-clavicular articulation. Patient told me he was quite weak in his <i>left</i> arm for some time after the carotid was tied. <i>Distal.</i> |

Surgical History of the

| No. | Name of operator. | Source of information. | PATIENT. | | | Cause of operation. | Duration of cause. | Point of deligation. | Date of injury. | Date of hemorrh'ge. |
|------|------------------------------------------|-----------------------------------------------------------------|----------|----------|------|--------------------------------------------|--------------------|----------------------|-----------------|----------------------------------|
| | | | Sex. | Age. | Side | | | | | |
| 192 | Earle, 1832. | Lond. Med. Gaz., 1832, vol. ix. p. 374. | F. | 45 | R. | Removed sup. maxilla. | 2 years. | | | |
| 193 | Eastman, 1873, Buffalo. | Letter from Prof. J. F. Miner to author. | M. | 35 | R. | Aneurism. | | | | |
| 194 | Eccles, 1843. | Norris Contrib. | M. | 46 | R. | Tumor (sup. aneurism). | | | | |
| 195 | Ehrmann, A., 1858. | J. Ehrmann des effets, etc. | M. | 20 | L. | Aneur. of ext. carotid (traum.). | | | | |
| 196 | Eliot, J., 1876. | Am. Jr. Med. Sci., April, 1877. | M. | 41 | R. | Aneur. of innom. | 3 years. | | | |
| 197 | Ellis, 1844. | Ehrmann des effets; Arch. Klin. Chir. do. | M. | 21 | L. | Shot w'd tongue. | 7 days. | | | |
| 198 | | | M. | 21 | R. | do. | 11 days. | | | |
| 199 | Ellis, 1835. | Norris Contrib. | M. | 28 | | Wound of throat. | 8 days. | | | |
| 200 | Ensor, 1874, Africa. | Lancet, 1875; Am Jr. Med. Sci., 1875. | M. | 50 | R. | Aneur. of aorta and innom. | | Below omo-hyoid. | | |
| 201 | Esmarch, 1857. | Arch. Klin. Chir. | M. | 21 | L. | Removed tumor of throat. | | | | |
| 202 | Evan, Thomas? | Lancet, 1853, vol. ii. p. 225. | | | R. | Hem.; opening abscess of scalp. | | | | |
| 203 | Evans, 1828. | Ehrmann des effets; Norris Contrib. | M. | 30 | R. | Aneur. of innom. and carotid. | About 1 year. | | | |
| 204 | Eves, A., 1847. | Lancet, 1849, vol. i. p. 556. | M. | 45 | L. | Suicidal cut-thr't; angle of jaw. | Short time. | Below omo-hyoid. | | |
| 204½ | Eve, Prof. Paul F., see Z at end. Ewing. | Norris Contrib. | M. | 52 | R. | Removed tumor of neck. | 30 y'rs. | | | |
| 205 | | | F. | | L. | Aneurism. | | | | |
| 206 | Fairfax, 1842. | do. | F. | | L. | Aneurism. | | | | |
| 207 | Fearn, S. W., 1847. | Ehrmann des effets; Arch. Klin. Chir. | F. | 68 | L. | Stab; int. carotid. | 2 hours. | | | |
| 208 | Fearn, S. W., 1835. | Ehrmann des effets; Arch. Klin. Chir.; Norris Contrib. | F. | 28 | R. | Aneur., innom. | | At omo-hyoid. | | |
| 209 | Fenin, 1841. | Arch. Klin. Chir. | M. | 27 | R. | Shot wound facial artery. | | | | |
| 210 | Fergusson, 1841. | Arch. Klin. Chir.; Norris Contrib. | M. | 56 | R. | Aneur., innom. and subclavian. | 2 years. | Above omo-hyoid. | | |
| 211 | Field, 1858. | Med. Times & Gaz., 1858, vol. ii. p. 217. | M. | | R. | Hem.; removed sup. maxilla. | 2 days. | | June 15, 1858. | |
| 212 | Von Fillenbaum, 1872. | Schmidt Jahr., B. 156, S. 199. | M. | Mid age. | L. | Shot w'd of neck and face. | 12 days. | | | |
| 213 | do. | Schmidt Jahr., B. 156, S. 199; Wien. Mediz. Woch., 1872, p. 29. | M. | do. | L. | Pistol w'd of face; wound inter. max. art. | Few hours. | | Aug. 10. | Immediate, and 6th and 7th days. |

Common Carotid Artery—continued.

| No. | Date of operation. | Hemorrhage occurred, after op. | Lig. came away. No. daysaft. op. | RESULT. | | | REMARKS. |
|------|--------------------|--------------------------------|----------------------------------|------------|------------|--------------------------------|-------------------------------------------------------------------------------------------------------------------------------------------------------------------------------------------------------------------------------------------------------------------------------------------------------------------------------------------------------------------------------------------------------------------------------------------------------------------------------------------------------------------------------------------------------------------------------------------------------------------------|
| | | | | Recovery. | Condition. | Cause of death, date after op. | |
| 192 | | | | Recovered. | | | Patient was doing well 6 days after operation. |
| 193 | About 1873. | | | (?) | | | |
| 194 | Sept. 23, 1843. | | | Recovered. | | | Pyæmia. |
| 195 | | | | | | | Died of bronchitis in 4 months. Autopsy showed disease to be <i>enlarged</i> gland. |
| 196 | Oct. 15, 1876. | 16th day. | | | | | 4th day. Cerebral complications. Few hours after op. right hemiplegia, hyperæsthesia left face; exter. strabismus left eye. <i>Patient never spoke after operat'n.</i> Subclavian tied same time. (See.) Oct. 31, or 16th day, hem. from sac 16 ounces. Died 25th day, loss of blood in <i>forming</i> clot in sac, and by external hem.; total, 8 lbs. 3 ounces! Body weighed 130 lbs. Autop-y: Ligature loose in wound; floor of arch atheromatous; opening of innominate 2 inches in diameter; sac $3\frac{1}{2}$ inches vertically, transversely 4 inches, antero-posteriorly $3\frac{1}{4}$ inches. <i>Distal.</i> |
| 197 | 1844. | | 17 | Recovered. | Cured. | | No cerebral symptoms except dyspnoea. |
| 198 | 4 days later. | | 14 | Recovered. | Cured. | | No cerebral symptoms noted. |
| 199 | Jan. 26, '35. | | 9 | Recovered. | Cured. | | Patient was a Hottentot. Subclavian tied same time. (See.) Autop-y: Sac ruptured just below ligature. |
| 200 | Sep. 8, 1874. | After. | 28 | | | | 65th day. Pleuritis and hemorrhage. |
| 201 | Aug. 9, 1857. | Once. | | Recovered. | Not cured. | | Persistent hemiplegia (right) after op. Patient died some months later; cause not given. |
| 202 | | | | Recovered. | Cured. | | Pleuro-pneumonia (slight) followed operation. |
| 203 | July 22, 1828. | | | Recovered. | Cured. | | "Paralysis of RIGHT (?) side followed." (Norris.) <i>Distal.</i> |
| 204 | April 2, 1847. | Slight. | 25 | Recovered. | Cured. | | Died 14 months later of gastric trouble. |
| 204½ | | | | | | | |
| 205 | Feb. 11, 1832. | | | | | | 4th day. Exhaust'n. |
| 206 | July 18, 1842. | | | | | | 5th day. Exhaust'n. |
| 207 | Feb. 2, 1847. | | 20 | | | | 79th day. Dyspnoea followed op.; mucopurulent fluid in bronchial tubes; thrombus in carotid. |
| 208 | Aug. 30, 1836. | | | Recovered. | | | Slight cerebral symptoms resulted Subclavian tied 2 years later. <i>Distal.</i> |
| 209 | 1841. | | | Recovered. | Cured. | | |
| 210 | June 22, 1841. | | | | | | 7th day. Pleuro-pneumonia. |
| 211 | June 17, 1858. | | 10 | Recovered. | Cured. | | |
| 212 | 1872. | | | | | | 8th day. Autopsy: Fract. 2d and 3d cervical vertebra; abscess; meningitis, etc. Solid thrombus on both sides of ligature. |
| 213 | Aug. 17, 1872. | Next day. | 23-25 | | | | 38th day. Cerebral complications. Ball entered point of nose, ranged toward left ear, and lodged; hem. left ear; 30 days after operation patient left his bed; on 37th day pain in head; died next day. Autopsy: Pus at base of brain, inflammation of meninges, softening of left hemisphere. Wound. of internal maxillary. |

Surgical History of the

| No. | Name of operator. | Source of information. | PATIENT. | | | Cause of operation. | Duration of cause. | Point of deligation. | Date of injury. | Date of hemorrhage. |
|-----|----------------------------------|---------------------------------------------------|----------|-----------|-------|----------------------------------------------|--------------------|----------------------|-----------------|---------------------|
| | | | Sex. | Age. | Side. | | | | | |
| 214 | Fischer, 1864. | Arch. Klin. Chir. | M. | Mid age. | | Shot wound. | | | | |
| 215 | do. | do. | M. | do. | R. | do. | | | | |
| 216 | do. | | M. | 4 | L. | Hem.; removed thyroid body (sup. thyroid). | 3 days. | | | |
| 217 | Fisher, H. N., 1862. | Med. Surg. Hist. Reb. | M. | Mid age. | L. | Shot w'd inferior maxilla. | | | Dec. 13. | 25, 26, 27 Dec. |
| 218 | Finley, 1824. | Norris Contrib. | M. | | R. | Fungus antri. | Some months. | | | |
| 219 | Foote, 1867, Cincinnati. | N. Y. Med. Jr., March, 1869. | M. | 20 | L. | Traum. pulsating tumor left orbit. | | | | |
| 220 | do. | do. | M. | 20 | R. | do. | | | | |
| 221 | Follin. | Arch. Klin. Chir. | | | | Removed carcinoma of tonsil. | | | | |
| 222 | Forster, 1852. | do. | M. | | L. | Punct. w'd mouth (fall on umbr'la) | Short while. | | | |
| 223 | Fouilloi, 1828. | Arch. Klin. Chir.; Norris Contrib. | M. | 52 ? 33 ? | L. | Removed tumor of parotid. | | | | |
| 224 | Fox, 1848. | Am. Jr. Med. Sci., Oct. 1849, p. 337. | M. | 41 | R. | Aneur. of external carotid. | | Below omo-hyoid. | | |
| 225 | Fleming, 1803 (British Navy). | Norris Contrib.; Arch. Klin. Chir. | M. | y'g. | | Suicidal cut-thr't. | 8 days. | | | |
| 226 | Freye and Botana. | Arch. Klin. Chir. | | | | Aneurism of both carotids. | | | | |
| 227 | Fricke, 1826. | Arch. Klin. Chir.; Norris Contrib. | M. | y'g. | | Cancer of parotid. | | | | |
| 228 | Frothingham, G. E., Mich., 1875. | Am. Jr. Med. Sci., Oct. 1876. | M. | 23 | R. | Traum. aneurism common carotid. | | Below omo-hyoid. | Aug. 16, 1875. | |
| 229 | Frothingham, G. E., Mich., 1872. | Am. Jr. Med. Sci., Jan. 1877. | F. | 35 | L. | Pulsating tumor of orbit. | | | | |
| 230 | Gamgee, S., 1871. | Lancet, June 3, 1871. | M. | 55 | L. | An. of com. carot., high up (spout.). | 2 mos. | Below omo hy. | | |
| 231 | Gannit, 1827. | Arch. Klin. Chir. | | | L. | Carotid aneur. | | | | |
| 232 | Gensoul, 1826. | do. | M. | 50 | R. | Rem. inf. max. | | | | |
| 233 | Gibb, G., 1857. | Lancet, 1857, vol. ii. p. 495. | F. | 45 | R. | Hem. (fall on dish, and carotid divided). | Few hours. | | | |
| 234 | Gibbs, R. W., 1872. | Charles. Med. Jr., 1874; Am. Jr. Med. Sci., 1874. | M. | 40 | L. | Shot wound; aneurism of left submax. region. | | | | |
| 235 | Gibson, 1832. | Norris Contrib. | M. | 17 | L. | Medul. tumor of neck. | 5 years. | | | |
| 236 | Gibson, C. B. | do. | F. | 35 | R. | Osteo-sarcoma of jaw. | 6 years. | | | |
| 237 | Goodlad. | Med. Chir. Trans., vol. vii. p. 112. | F. | Mid age. | L. | Immense tumor of parotid. | | | | |
| 238 | Güntner, 1872. | Schmidt Jahrb., B. 158, p. 35. | M. | 31 | R. | Removed tonsil. | 6 days. | At omo-hyoid. | | |
| 239 | Günther. | Arch. Klin. Chir. | M. | | R. | Stab of int. max. artery. | | | | |

Common Carotid Artery—continued.

| No. | Date of operation. | Hemorrhage occurred, after op. | Lig. came away No. days aft. op. | RESULT. | | | REMARKS. |
|-----|--------------------|--------------------------------|----------------------------------|------------|--------------|--------------------------------|--------------------------------------------------------------------------------------------------------------------------------------------------------------------------------------------------------------------------------------------------------------------------------------------------------------|
| | | | | Condition. | Recovery. | Cause of death, days after op. | |
| 214 | April 18, 1864. | Once. | | | | 2d day; hem.; coma. | Lung injured also. |
| 215 | do. | | 11 | Recovered. | Cured. | | |
| 216 | June 12, 1854. | 2d day. | 9 | | | Several days. | Convulsions on tightening ligature. Autopsy: No thrombus at lig. |
| 217 | Dec. 27, 1862. | | | | | 10th day. | |
| 218 | July 27, 1824. | | | Recovered. | | | |
| 219 | June 22, 1867. | | | Recovered. | Not cured. | | After 1st operation bruit ceased, but returned in 2 hours. After 30 days, symptoms being unfavorable, the right carotid was secured; the bruit ceased, but again returned; ultimately cured. Discharged patient in 3 weeks after last operation. |
| 220 | [1867. July 20, | | | Recovered. | Cured. | | |
| 221 | | | | Recovered. | | | No symptoms of interest followed. |
| 222 | 1852. | | | Recovered. | Cured. | | Paralysis of right side for 9 months. |
| 223 | 1828. | | 15 | Recovered. | Cured. | | |
| 224 | Oct. 21, 1848. | | 20 | Recovered. | Cured. | | Slight cerebral disturbance followed, which gradually disappeared. |
| 225 | Oct. 17, 1803. | | 7 | Recovered. | Cured. | | The carotid was tied in the original wound. Abernethy, Fleming, and Cogeswell tied the carotid in 1803. |
| 226 | | | | Recovered. | Cure of one. | | |
| 227 | | | | | | 18th day. Cancer. | |
| 228 | Sept. 7, 1875. | | 12 | Recovered. | Cured. | | Internal jugular vein also tied; no cerebral symptoms noted; 2 ligatures to artery; voice permanently impaired. |
| 229 | March 29, 1872. | | 18 | Recovered. | Cured. | | Cerebral symptoms for several weeks; pulsation returned; growth of tumor retarded for 3 years, then began again; extirpated with eye; hem. followed, and orbit was tamponed with lint in Monsell's solution. |
| 230 | 1871. | | | | | 6th day. (Cancer of rectum?) | No cerebral symptoms followed. |
| 231 | 1827. | | | Recovered. | Cured. | | |
| 232 | 1826. | | | | | 15th day. | |
| 233 | Aug. 30, 1857. | 6th day, slight. | sup. 35 inf. 48 | Recovered. | Cured. | | Difficult deglutition for several days; both ends of artery tied. |
| 234 | 1872. | | | Recovered. | Cured. | | Paralysis right side after operation, which was much diminished after lapse of 1 year. |
| 235 | Nov. 20, 1832. | | 36 | Recovered. | Cured. | | |
| 236 | June 12, 1844. | | 22 | Recovered. | Cured. | | |
| 237 | Sept. 5, 1815. | | 11 | Recovered. | Cured. | | Tumor extended to clavicle and measured 20 inches; removed after ligature was applied. |
| 238 | June 27, 1872. | | | Recovered. | Cured. | | |
| 239 | | | | Recovered. | Cured. | | After ligature of the common trunk the hemorrhage persisted and the internal maxillary was tied, which arrested hem. The ligature to the common trunk was then removed. (It is likely that the tightening of the ligature by dividing the internal coat of the vessel obliterated its trunk as in ligation.) |

Surgical History of the

| No. | Name of operator. | Source of information. | PATIENT. | | | Cause of operation. | Duration of cause. | Point of deligation. | Date of injury. | Date of hemorrhage. |
|-----|--------------------------------------------------|---------------------------------------------------------------------|----------|---------|-------|---------------------------------------------------|--------------------|----------------------|-----------------|------------------------|
| | | | Sex. | Age. | Side. | | | | | |
| 240 | Gunderlach, 1831. (Möller), 1832. Guthrie. | Arch. Klin. Chir. | | 5½ | R. | Aneur. anast. of frontal and nasal regions. | 5½ y'rs. | | | |
| 241 | | do. | | | L. | do. | 5½ y'rs. | | | |
| 242 | | Lancet, 1850, vol. ii. p. 143. | M. | | | Suicidal cut-thr't common carotid at bifurcation. | 8th day. | | | |
| 243 | Gurlt. | Arch. Klin. Chir. | M. | 26 | R. | Hem.; shot w'd. | | | | |
| 244 | do. | do. | M. | | | Hem. of external carotid. | | | | |
| 245 | Von Graefe, 1829. | do. | | | L. | Wound of neck. | | | | |
| 246 | Von Graefe, 1821. | do. | F. | 30 | L. | Removed lower jaw. | | | | |
| 247 | Green, 1831. | Norris Contrib. | M. | 65 | R. | Aneurism. | 5 mos. | | | |
| 248 | Green, Isaac. | New York Med. Jr., July, 1857. | M. | Mid age | L. | Suicidal cut-thr't; w'd of superior thyroid. | | | | |
| 249 | Greene, F. C., 1863. | Med. Surg. Hist. Reb. | M. | | | Shot w'd of face. | | | May 27. | June 16. |
| 250 | Grandchamp (Pinel), 1839. | Arch. Klin. Chir. | F. | 50 | R. | Pulsating tumor of face. | 2 years. | | | |
| 251 | Greig, 1862. | Edin. Med. Jr., 1862, p. 446. | F. | 47 | L. | Aneurism of orbit (fall on head). | 14 days. | | | |
| 252 | Griffith. | Med. Surg. Hist. Reb. | M. | | | Shot wound of superior maxilla. | | | June 15. | |
| 253 | Gruening, E., N. Y., 1875. | Archives Otolology and Ophth., vol. v. No. 1, 1876; note to author. | F. | 59 | L. | Vascular protrusion of both eyes (fall). | 3 mos. | | | |
| 254 | Hall, J. Z., 1864. | Med. Surg. Hist. Reb. | M. | Mid age | L. | Shot w'd of face. | | Above omo-hyoid. | Aug. 21. | Sept. 4. |
| 255 | Halsted, 1857. | New York Med. Jr., March, 1869. | M. | 37 | L. | Aneur. of orbit, traumatic. | | | | |
| 256 | do. 1858. | do. | F. | 13 | L. | Enceph. tumor of outer canthus of left eye. | 3½ y'rs. | | | |
| 257 | do. 1839, or Halstead. | New York Hosp. Notes, vol. iv. C. 496. | M. | 19 | R. | Enceph. tumor of diploë. | 6 mos. | Above omo-hyoid. | | |
| 258 | Hamilton, 1838 (of Ohio?). | Arch. Klin. Chir. | M. | 18 | R. | Epilepsy. | From childhood. | | | |
| 259 | | do. 1839. | do. | M. | 18½ | L. | do. | do. | | |
| 260 | Hamilton, Prof. Frank H., 1853. | Notes of cases from Prof. Hamilton. | M. | 18 | R. | Sarcom. antrum of Highmore. | Over 7 months. | Above omo-hyoid. | | Often for 2 or 3 w'ks. |

Common Carotid Artery—continued.

| No. | Date of operation. | Hemorrhage occurred, after op. | Lig. came away No. days aft. op. | RESULT. | | | REMARKS. |
|-----|--------------------|--------------------------------|----------------------------------|------------|----------------------|--------------------------------|-------------------------------------------------------------------------------------------------------------------------------------------------------------------------------------------------------------------------------------------------------------------------------------------------------------------------------------------------------------------------------------|
| | | | | Condition. | Recovery. | Cause of death, days after op. | |
| 240 | Sept. 13, 1831. | | 13 | Recovered. | Not cured. | | |
| 241 | Jan. 18, 1832. | | 28 | Recovered. | ? | | Patient died later of variola. |
| 242 | | | | | | Next day. | Ligature to common trunk did not arrest hem.; internal carotid tied, and still hemorrhage resulted, which ceased with the ligature of the external carotid. Internal jugular vein tied with lateral ligature. For other cases of Guthrie see last page. |
| 243 | Aug. 23, 1866. | | 13 | Recovered. | Cured. | | |
| 244 | 1866. | | | | | 3 weeks. | |
| 245 | 1829. | | | | | 3d day. Coma. | Autopsy: Brain inflamed. |
| 246 | July 26, 1821. | | | Recovered. | | | 3d day, paralysis of right side. |
| 247 | April 15, 1831. | | 24 | Recovered. | | | |
| 248 | | | | Recovered. | Imbecile. | | "Patient became imbecile and died some months later of cholera." |
| 249 | June 16, 1863. | | | Recovered. | | | |
| 250 | 1839. | | | Recovered. | | | During previous year, the two facials, the transverse facial, infra-orbital, and temporal artery of the affected side were tied, with no effect upon tumor. No cerebral symptoms followed ligature of common trunk. |
| 251 | March 30, 1862. | | 24 | Recovered. | Cured. | | "Fell down stairs." |
| 252 | July 10, 1864. | | | | | 10th day. | |
| 253 | June 8, 1875. | | | Recovered. | Cured. | | "Disease caused by fall. Supposed fracture at base of cranium, with communication between carotid artery and cavernous sinus." |
| 254 | Sept. 6, 1864. | | | | | 2d day. | |
| 255 | 1857. | | | Recovered. | Cured. | | "Sight impaired in affected eye." |
| 256 | 1858. | | | Recovered. | Cured (loss of eye). | | Tumor diminished at first, but began to grow again, and 10 months later it was removed with the eye. |
| 257 | 1839. | | 13 | Recovered. | Not cured. | | "Died several months later from disease and hemorrhage." |
| 258 | Aug. '38. | | | Recovered. | Improved. | | Although attributed to Prof. F. H. Hamilton by many writers, was not performed by him. I have his authority for this correction.— <i>Author.</i> |
| 259 | Mar. '39. | | | Recovered. | Cured. | | |
| 260 | Dec. 24, 1853. | 7th and 14th days, severe. | 14 | Recovered. | Cured. | | Polypus in right antrum causing protrusion of eyeball, depressing roof of mouth, and closing right nostril; patient weak from loss of blood. After operation patient complained of slight pain in right side of head; hem. from wound on 7th day 3 pints; arrested by pressure in wound; on 14th day vomiting caused hem. from nose; tumor stationary for some time; cure complete. |

Surgical History of the

| No. | Name of operator. | Source of information. | PATIENT. | | | Cause of operation. | Duration of cause. | Point of deligation. | Date of injury. | Date of hemorrhage |
|-----|---------------------------------|-------------------------------------|----------|---------|-------|-------------------------------------------------------|--------------------|----------------------|-----------------|--------------------|
| | | | Sex. | Age. | Side. | | | | | |
| 261 | Hamilton, Prof. Frank H., 1854. | Notes of cases from Prof. Hamilton. | M. | 14 | R. | Aneur. facial artery (traum. false; stab pen-knife). | 6 w'ks. | | | At time of injury. |
| 262 | do. 1855. | do. | M. | 32 | R. | Medul. sarcom. of angle of right jaw (tumor removed). | 2 years. | Below omo-hyoid. | | |
| 263 | do. 1857. | do. | M. | 18 | R. | Hem.; polypus of nose and antrum. | 5 years. | Above omo-hyoid. | | Often and profuse. |
| 264 | do. 1859. | do. | M. | 43 | R. | Medullary sarcoma of right antrum. | Several years. | | | Often. |
| 265 | do. 1860. | do. | M. | 2 | R. | Erect. tumor of outer angle of right eye. | 6 w'ks. | Above omo-hyoid. | | |
| 266 | do. 1865. | do. | M. | 24 | L. | Hem. of ranine artery. | 5 days. | do. | July 4. | July 10. |
| 267 | do. 1866. | do. | F. | 31 | L. | Medul. sarcoma of superior maxilla (recurrent). | 12 y'rs. | | | Often, but slight. |
| 268 | do. | do. | M. | 65 | L. | Removed left sup. maxilla for medullary sarcoma. | | Above omo-hyoid. | | |
| 269 | do. 1869. | do. | F. | Mid age | | do. | | do. | | |
| 270 | do. | do. | M. | 50 | | do. | 6 mos. | do. | | |
| 271 | do. 1877. | do. | M. | 35 | R. | do. | | | | |

Common Carotid Artery—continued.

| No. | Date of operation. | Hemorrhage occurred, after op. | Lig. came away No. days aft. op. | RESULT. | | | REMARKS. |
|-----|--------------------|--------------------------------|--------------------------------------|------------|--------------------------|--------------------------------|-------------------------------------------------------------------------------------------------------------------------------------------------------------------------------------------------------------------------------------------------------------------------------------------------------------------------------------------------------------------------------------------------------------------------------------------------------------------------------------------------------------------------------------------------------------------------------------------------------------------------------------------------------------------------------------------|
| | | | | Condition. | Recovery. | Cause of death, days after op. | |
| 261 | Aug. 15, 1854. | None. | | Recovered. | Cured. | | No cerebral symptoms noted; pulsation in tumor ceased immediately. |
| 262 | Nov. 10, 1855. | After. | | | | 10 hours. | Shock, hem., anæsthetic. |
| 263 | Aug. 29, 1857. | do. | 10 | | | 39th day. | Hemor'ge, exhaustion. |
| 264 | Aug. 1859. | | | Recovered. | (Temporary improvement.) | | 7 y'rs previously dentist broke a tooth on right side, followed by intense pain; 3 years before op. hem. 1 y'r before eyeball began to protrude; after op. eye and tumor removed; hem. profuse but easily controlled. Disease ret'd some time later and proved fat'l. |
| 265 | Feb. 12, 1860. | | | Recovered. | No benefit. | | Tumor covered right temple, had pushed eye out and destroyed it; soft, elastic, with distinct bruit; tumor returned later and patient died from it. |
| 266 | Aug. 15, 1863. | None. | | | | 16th day. | Anæmia; exhaustion. |
| 267 | Sept. 5, 1866. | Next day, slight. | | Recovered. | Not cured. | | On July 4th, patient had lower jaw broken on both sides; abscess formed and the attending surgeon (not Dr. H.) accidentally divided the main artery, in open'g the abscess.— <i>Author.</i> "3 months previously tumor had been removed by Prof. Lewis A. Sayre, but returned in a very malignant form. Day after ligature of carotid, paralysis on left side of face and right side of body; comatose and slight hem. from roof of mouth; patient died 2 mos. later. Autopsy: Granular degeneration of kidneys and cancerous deposit in various organs." (The coma and paralysis were doubtless due to ligature of the carotid. Death in great measure due to disease.— <i>Author.</i>) |
| 268 | | | 28 | Recovered. | Not cured. | | Patient died 6 months later of disease. |
| 269 | May 12, 1869. | | 21 | Recovered. | Not cured. | | Patient died several mos. later of disease. |
| 270 | | None. | | Recovered. | | | "Patient of hemorrhagic diathesis. Sharp pain down neck to collar bone some h'rs after op." |
| 271 | Feb. 25, 1877. | | Had not come away 3 mo's after oper. | Recovered. | Not cured. | | Submaxillary gland removed; wound healed nicely; 3 months later disease seemed on the point of returning; patient lost sight of after this. Prof. Hamilton has furnished me notes of one other case which occurred on McClellan's retreat after the "Seven Days' Battle." The common carotid was tied to arrest hem. from gunshot wound of the ext. carotid; the hem. ceased, but the case was lost sight of in the confusion of the retreat. In every instance he has used his own "aneurism needle," which is described in his work upon the "Prin. and Prac. of Surgery."— <i>Author.</i> |

Surgical History of the

| No. | Name of operator. | Source of information. | PATIENT. | | | Cause of operation. | Duration of cause. | Point of deligation. | Date of injury. | Date of hemorrhage. |
|-----|----------------------------|------------------------------------------------------------|----------|------|-------|--------------------------------------------------|--------------------|----------------------|-----------------|---------------------|
| | | | Sex. | Age. | Side. | | | | | |
| 272 | Hargrave, 1849. | Arch. Klin. Chir. | M. | 61 | L. | Hem.; puncture wound. | | | | |
| 273 | Hart, 1861. | Lancet, 1862, vol. i. p. 271. | M. | 11 | L. | Aneur. anast. of upper lid and orbit. | | | | |
| 274 | Heath, Christopher, 1865. | Lancet, Jan. 1867. | F. | 30 | R. | Supposed aneur. of innominate. | 4 mos. | Above omohyoid. | | |
| 275 | do. 1872. | Brit. Med. Jr., Feb. 1877. | M. | | L. | Aortic aneurism. | | | | |
| 276 | Heine, 1869. | Longworth, Prize Thesis. | M. | 21 | | Hem'ge; removed cirroid aneur. of ear and scalp. | 5 days. | | | |
| 277 | do. 1871. | Wien. Mediz. Woch., 1874, p. 661. | M. | 32 | R. | Removed sarcoma of right tonsil (prepart). | Several years. | Above omohyoid. | | |
| 278 | do. 1873. | Wien. Mediz. Woch., 1874, p. 679. | M. | 50 | R. | Recurrent sarcoma of neck. | | Below omohyoid. | | |
| 279 | Hebenstreit. | Arch. Klin. Chir. | M. | | | Removed tumor of parotid (wound of facial). | | | | |
| 280 | Hendricks, 1864. | Med. Surg. Hist. Reb. | M. | 25 | | Shot w'd of face and neck. | | Above omohyoid. | | |
| 281 | Herpin, 1844. | Arch. Klin. Chir. | F. | 59 | L. | Aneurism of orbit. | | | | |
| 282 | Hewson, 1850. | do. | M. | 48 | L. | Aneur. of external carotid. | | | | |
| 283 | do. 1867. | Am. Jr. Med. Sci., July, 1876, p. 20; Dr. Thos. G. Morton. | M. | 51 | R. | Aneur. of innominate. | Some time. | | | |
| 284 | Von Hippel, 1873? | Schmidt Jahrb., B. 163, S. 59. | M. | 21 | R. | Traumatic pulsating tumor orbit. | 10 w'ks. | | | |
| 285 | Hobart, 1857. | Med. Times & Gaz., 1860, vol. i. p. 64. | M. | | L. | Traumatic aneurism of carotid. | 6 mos. | | | |
| 286 | Hodgson, 1850. | Arch. Klin. Chir. | F. | | | do. | 14 days. | | | |
| 287 | Holscher, 1819. | Norris Contrib. | M. | 23 | R. | Aneurism. | | | | |
| 288 | Holmes, T., 1876 (London). | Am. Jr. Med. Sci., April, 1877. | F. | 21 | L. | Aortic aneurism. | | | | |
| 289 | do. 1870-2? | Lancet, 1872. | M. | 50 | R. | Innominate aneurism. | | | | |
| 290 | Holmes, E. L. (Chicago). | Schmidt Jahrb., B. 172, p. 70. | M. | 21 | L. | Intra-cranial aneurism (of pituitary body). | Some time. | | | |
| 291 | Holt, 1860. | Lancet, 1861, vol. i. p. 560. | M. | 30 | R. | Aneurism of carotid (low down). | 2 mos. | Below omohyoid. | | |

Common Carotid Artery—continued.

| No. | Date of operation. | Hemorrhage occurred after op. | Lig. came away No. days aft. op. | RESULT. | | | REMARKS. |
|-----|--------------------|-------------------------------|----------------------------------|------------|------------|---------------------------------------|-----------------------------------------------------------------------------------------------------------------------------------------------------------------------------------------------------------------------------------------------------------------------------------------------------------------------------------------------------------------------------|
| | | | | Recovery. | Condition. | Cause of death, date after op. | |
| 272 | Jan. 25, 1849. | 14th day. | 18 | | | After 14th day, of bronchial catarrh. | |
| 273 | 1861 ? | | 8 | Recovered. | Cured. | | No symptoms of cerebral disturbance. |
| 274 | 1865. | | 18 | Recovered. | | | "Subclavian in 3d div. tied same time; tumor reduced in size and patient much improved, though of dissolute habits." <i>Distal.</i> (In Lancet, July 2, 1870, is notice of death of this patient on Dec. 8, 1869, from rupture of aortic aneurism. The innominate was not involved in the disease.— <i>Author.</i>) Died 4 years later from rupture of sac. <i>Distal.</i> |
| 275 | Feb. 1872. | | | Recovered. | Improved. | | "Ext. carotid tied when tumor was removed; 5 days later hem. and lig. common carotid." (See Surgical History of the Ext. Carotid Artery.— <i>Author.</i>) |
| 276 | 1839. | | | Recovered. | Cured. | | "Operite man so trocken wie an der Leiche." 6th day paralysis left side and delirium; osteo-plastic resection of lower jaw during operation. Autopsy: Thrombus above and below ligature, <i>continuous clot from carotid into vicht subclavian.</i> |
| 277 | 1871. | | | | | 10th day. | "14 ligatures in wound of extirpation." |
| 278 | 1873. | | 23-25 | Recovered. | ? | | |
| 279 | | | | Recovered. | | | |
| 280 | Dec. 18, 1864. | After. | | | | 90th day. Hem. | Hem. resulted from ulceration of wall of internal jugular vein. |
| 281 | July 26, 1844. | | | Recovered. | Improved. | | 10 months later pulsation was noticed in opposite eye; arrested by cold application. |
| 282 | June 19, 1850. | 28, 29 days. | 29 | Recovered. | Cured. | | |
| 283 | 1867. | | | | | 12th day. (Serous effusion in lungs.) | <i>Distal.</i> |
| 284 | 1873. | | | Recovered. | Improved. | | No symptoms of cerebral disturbance noted. |
| 285 | Sept. 3, 1857. | 2 or 3 times. | 13 | Recovered. | Cured. | | After operation tumor increased, was opened, and to arrest hem. a small artery was tied. Oct. 9, another hem., and a second ligature was applied (to carotid), which came away on Nov. 4. Hodges, Hobart, 2d case. See appendix. |
| 286 | 1850. | | 14 | Recovered. | Cured. | | |
| 287 | Sept. 27, '19. | | 15 | Recovered. | Cured. | | |
| 288 | Oct. 21, 1875. | After. | | Recovered. | ? | | Patient was alive after 13 months had elapsed |
| 289 | | do. | | | | 57th day. Hemorrhage. | Right subclavian tied same time and tumor treated by <i>galvano-puncture</i> ; carb'd cauter used; sac sloughed causing death. |
| 290 | | | | Recovered. | | | Died 3½ years later of disease. Autopsy: Tumor of pituitary body large as hen's egg, pressed upon carotid, causing aneurismal dilatation of this vessel and atrophy of both optic nerves. |
| 291 | Nov. 20, 1860. | 18th day. | 16 | Recovered. | Cured (?) | | "After operation pain in head and retention of urine. (Feb. 4, much better and sent to Margate?)" |

Surgical History of the

| No. | Name of operator. | Source of information. | PATIENT. | | | Cause of operation. | Duration of cause. | Point of deligation. | Date of injury. | Date of hemorrhage. |
|-----|------------------------------------|---------------------------------------------------------------------------------|----------|----------|-------|---------------------------------------------------------|--------------------|------------------------------------------|-----------------|---------------------|
| | | | Sex. | Age. | Side. | | | | | |
| 292 | Horner, 1832. | Norris Contrib. | M. | 34 | R. | Wound of throat. | | | | |
| 293 | Hueter, 1864. | Arch. Klin. Chir. | M. | 58 | L. | Hem., secondary. | "Not long." | | | |
| 294 | Hunt, 1862 (Fortress Monroe). | Letter to author from Prof. Alfred C. Post. | M. | Mid age. | R. | Shot w'd of neck (high up). | | | | |
| 295 | Hunt, Wm., 1868. | Am. Jr. Med. Sci., July, 1876; Dr T. G. Morton. | F. | 28 | R. | do. | Few hours. | | | |
| 296 | Hunter, 1843. | Arch. Klin. Chir. | F. | 60 | | Aneur. in mouth. | | | | |
| 297 | do. | do. | M. | 29 | R. | Aneurism of common carotid. | | | | |
| 298 | Hutchinson, 1856. | Med. Times & Gaz., March, 1856, vol. i. p. 209. | M. | 60 | L. | Hem.; cancer of left submaxil'ry gland. | | Below omohyoid. | | |
| 299 | Hutchison, Prof. J. C. (Brooklyn). | Letter to author from Prof. H; Am. Med. Times, April, 1861, p. 20. | M. | 35 | L. | Puncture wound by iron rod (w'd of internal maxillary). | 13 days. | | Sept. 11. | 11 and 24. |
| 300 | do. 1856. | Letter to author; N. Y. Med. Record, Aug. 1867. | M. | 48 | R. | Aneurism of innominate. | | Below omohyoid, 1 inch above innominate. | | |
| 301 | do. 1877. | Operation witnessed by author; notes from Drs. H. W. Rand and J. E. Richardson. | M. | 50 | L. | Neuralgia of 3d division of trifacial nerve. | 7 years. | | | |
| 302 | Hutton, 1842. | Arch. Klin. Chir. | M. | 47 | R. | Innominate aneurism. | 1 year. | | | |
| 303 | Isaacs, C. E., 1855. | N. Y. Med Jr., July, 1857. | | | | Hem.; shot w'd of angle of jaw; suicide (single ball). | | | | |
| 304 | Jaeger, 1836. | Arch. Klin. Chir. | M. | 28 | R. | Hemorrhage after surgical operation. | | | | |
| 305 | Jameson, 1820. | Norris Contrib. cit. | M. | 26 | | Fungous tumor of antrum. | 13 mos. | | | |
| 306 | Jobert, 1836. | Arch. Klin. Chir. | M. | | R. | Erect. tumor in temporal region. | 4 mos. | | | |
| 307 | do. 1839. | Norris Contrib. | M. | 60 | R. | Aneur. of orbit. | 3 years. | | | |
| 308 | Johnson, C. H., 1850. | Lancet, 1850, vol. ii. p. 118. | M. | 7 | L. | Hem. of pharynx; umbrella driven through fauces. | | | | |
| 309 | Johnson, 1842. | Norris Contrib. | M. | 29 | R. | Aneurism. | 5 w'ks. | | | |
| 310 | Jüngken. | Arch. Klin. Chir., 1868. | M. | 19 | R. | Hem.; aneur. anastomosis. | | | | |

Common Carotid Artery—continued.

| No. | Date of operation. | Hemorrhage occurred, after op. | Lig. came away No. days aft. op. | RESULT. | | | REMARKS. |
|-----|--------------------|--------------------------------|----------------------------------|------------|------------|--------------------------------|-------------------------------------------------------------------------------------------------------------------------------------------------------------------------------------------------------------------------------------------------------------------------------------------------------------------------------------------------------------------------------------------------------------------|
| | | | | Recovery. | Condition. | Cause of death, date after op. | |
| 292 | June 18, 1832. | | 24 | Recovered. | Cured. | | |
| 293 | Dec. 23, 1864. | | 16 | Recovered. | Cured. | | "Slight cerebral disturbance." |
| 294 | 1862. | | | | | Next day. Shock ; exhaustion. | Internal carotid tied also. |
| 295 | 1868. | | 28 | Recovered. | Cured. | | |
| 296 | Aug. 3, 1843. | | | | | 4th day. | |
| 297 | | | | Recovered. | Cured. | | |
| 298 | Jan. 1856. | None. | | | | 10th day. | 3 days before death symptoms of paralysis on right side. |
| 299 | Sept. 24, 1860. | | 22 | Recovered. | Cured. | | "14 hours after operation patient seized with epileptic convulsions, which ceased later." |
| 300 | Jan. 16, 1866. | None. | 12 | | | 41st day. Asphyxia. | Subclavian was not tied owing to its displacement and obliteration by tumor. Autopsy: Aneurism of arch of aorta and innominate. <i>Both carotids, right vertebral and subclavian artery occluded, and no symptoms of cerebral anæmia! Distal.</i> |
| 301 | June 30, 1877. | | | Recovered. | Cured. | | Upon two previous occasions, several teeth had been extracted, the alveolar processes removed, and once the dental branch of 3d division of 5th nerve had been excised but without result. Carbolyzed catgut and antiseptic dressings used. Dr. Jno. D. Rushmore writes me, Aug. 18, 1877, "the operation was followed by complete cessation of pain; wound healed by first intention; patient discharged cured." |
| 302 | June 27, 1842. | 22d day. | 30 | | | 76th day. | Tumor diminished almost entirely after operation; epileptic convulsions before death. Autopsy: Right subclavian also occluded although not included in ligature. <i>Distal.</i> |
| 303 | 1855. | None. | | Recovered. | Cured. | | |
| 304 | May, 1836. | After. | 12 | | | 16th day. Hem. | |
| 305 | Nov. 11, 1820. | | | Recovered. | Cured. | | |
| 306 | Aug. 22, 1836. | | | | | 2d day. | No cerebral symptoms. |
| 307 | | | | Recovered. | Cured. | | No cerebral symptoms. |
| 308 | May 12, 1850. | | 9 | Recovered. | Cured. | | Cure complete 27 days after operation. |
| 309 | Jan. 22, 1842. | | 22 | Recovered. | Cured. | | |
| | | | 16 | Recovered. | Not cured. | | In Langenbeck's Archives, Dr. Pilz gives a 3d case by Jüngen, but as the <i>sex, side, cause,</i> and result of the two operations are identical, I suspect this industrious compiler has accidentally repeated this case. It is my purpose to admit nothing in this history that is not clear and positive.— <i>Author.</i> |

Surgical History of the

| No. | Name of operator. | Source of information. | PATIENT. | | | Cause of operation. | Duration of cause. | Point of deligation. | Date of injury | Date of hemorrhage. | |
|-----|-------------------------------|---------------------------------------------------------|-----------|--------------------------|-------|--------------------------------------------|--------------------|-----------------------------------|----------------|---------------------|-------|
| | | | Sex. | Age. | Side. | | | | | | |
| 311 | Jüngken. | Arch. Klin. Chir., 1868. | M. | | L. | Stab wound of external carotid. | Short while. | | | | |
| 312 | Karatscharoff. | Med. Zeit. Russ., 1846, S. 39; Arch. Klin. Chir. cit. | M. | 33 | R. | Carotid aneurism. | | | | | |
| 313 | Keen, W. W., 1863. | Med. Surg. Hist. Reb.; Otis; Am. Jr. Med. Sci., 1864. | M. | 33 | L. | Shot wound of superior max. | | Above omo-hyoid. | July 1. | July 8. | |
| 314 | Kerr, 1840. | Edin. Med. Journ., 1844, vol. i. p. 119. | F. | 67 | R. | Vascular tumor; supposed aneur. | | | | | |
| 315 | Key, Aston, 1830. | Lond. Med. Gaz., 1830, vol. vi. p. 702. | F. | 61 | R. | Aneurism of innominate. | | | | | |
| 316 | Key (?), 1824. | Norris Contrib. | M. | 40 | | Aneurism. | 5 mos. | | | | |
| 317 | Key & Grouse, 1841. | Schmidt Jahrb., B. 41, S. 75. | F. | 55 | R. | Aneurism of carotid. | | | | | |
| 318 | Koch, 1866. | do. | M. | 38 | R. | Hem.; shot w'd. | | | | | |
| 319 | Kuhl, 1843. | Ehrmann, No. 13; Norris Contrib.; Arch. Klin. Chir. do. | M. | 53 | L. | Aneurism anast. occip. traum. | 24 y'rs. | | | | |
| 320 | | | do. | M. | 53 | R. | do. | do. | | | |
| 321 | | | do. 1836. | Arch. Klin. Chir., 1868. | F. | 43 | R. | Vascular tumor of frontal region. | 4 mos. | | |
| 322 | Kluyskens, 1840. | do. | M. | 23 | L. | Aneurism, traum. | 3 mos. | | | | |
| 323 | Knagges, 1863. | Lond. Med. Times & Gaz., 1863, vol. ii. p. 8. | M. | 15 | R. | Aneurism of carotid, traum. | | Below omo-hyoid. | | | |
| 324 | Knapp, H., 1858 (Heidelberg). | Letter to author from Prof. Knapp. | | 9 mos | L. | Intra-cranial tum. | | Above omo-hyoid. | | | |
| 325 | Knowles, 1867. | Lancet, June, 1869. | M. | 40 | R. | Aneurism of carotid (low down). | 4 mos. | | | | |
| 326 | | Arch. Klin. Chir. | M. | 48 | L. | Headache. | | | | | |
| 327 | Labat. | Gunther, 199; Arch. Klin. Chir., 1868. | F. | | ... | Removed tumor of neck. | | | | | |
| 328 | Lambert, 1827. | Norris Contrib., 1868. | F. | 49 | R. | Aneurism of carotid (at root). | | | | | |
| 329 | Von Langenbeck, 1825. | Ehrmann des effets, p. 41. | M. | 29 | R. | Hem.; ligated superior thyroid artery. | | | | | |
| 330 | do. | Arch. Klin. Chir., 1868. | M. | 48 | R. | Hem. carcinoma. | 5 days. | | | | |
| 331 | do. 1845. | do. | M. | 36 | R. | Traumatic aneurism of carotid; shot wound. | 14 days. | | | | |
| 332 | do. 1859. | do. | M. | 58 | R. | Removed epithelial cancer of neck. | 2 years. | | | | |
| 333 | do. | do. | M. | 65 | L. | do. | | | | | |
| 334 | Lane, 1852. | Lancet, 1852, vol. ii. p. 57. | M. | 30 | L. | Aneurism of carotid (low down). | 5 w'ks. | Above omo-hyoid. | | | |

Common Carotid Artery—continued.

| No. | Date of operation. | Hemorrhage occurred, after op. | Lig. came away, No. days aft. op. | RESULT | | | REMARKS. |
|-----|--------------------|--------------------------------|-----------------------------------|------------|------------|----------------------------------|-------------------------------------------------------------------------------------------------------------------------------------------------------------------------------------------------------------------------|
| | | | | Recovery. | Condition. | Cause of death, date after op. | |
| 311 | | | | Recovered | Cured. | | |
| 312 | 1844. | | | Recovered | Cured. | | Suppuration in sac which had to be opened. |
| 313 | July 16, 1853. | | | | | 4th day. Cerebral complications. | Paralysis 35 days after operation. Autopsy: Abscess in brain. |
| 314 | April 30, 1840. | | 26 | Recovered. | | | Patient died 9 months after operation from pneumonia. |
| 315 | July 20, 1830. | | | | | 4 hours. Coma. | Autopsy: Mouth of <i>left carotid</i> was about one-tenth size of rest of vessel; both vertebrals small. <i>Distal</i> . |
| 316 | Jan. 24, 1824. | | 7 | | | 10th day. | |
| 317 | Sept. 9, 1841. | | 31 | Recovered. | Cured. | | No bad symptoms. |
| 318 | July 22, 1866. | 3, 4, slight. | 10 | Recovered. | Cured. | | Ball entered at infra-orbital foramen, spin. process, 2d and 3d cervical vertebrae. |
| 319 | May 24, 1843. | Several times. | 27 | Recovered. | Not cured. | | One year after a fall from a horse on occiput; disease began 72 days after 1st operation. |
| 320 | Aug. 4, 1834. | 3d day. | 27 | Recovered. | Cured. | | The 2d carotid tied; no marked cerebral symptoms followed the 2d operation, although convulsions occurred after the 1st. |
| 321 | Sept. 16, 1836. | | | | | 2d day. | Cerebral symptoms followed; unconscious 4 hours. Autopsy: Tuberculosis of lungs; pneumogastric nerve injured by inflammation of surrounding structures; <i>right subclavian</i> included in <i>ligature</i> by mistake. |
| 322 | Aug. 5, 1840. | | 22 | Recovered. | No better. | | Died 4 years; rupture of sac; supposed aneur. of vertebral. |
| 323 | Jan. 16, 1863. | | 34 | | | 44th day. | Sterno-mastoides divided in operation; was well united. Autopsy: Suppuration of sac. |
| 324 | 1858. | | | | | Next day. Disease. | Autopsy: Vascular tumor in convexity left hemisphere, large as a man's fist, pressing brain to right; parietal bone outward. |
| 325 | 1867. | | 16 | | | 35th day. Coma. | No cerebral symptoms until 34th day, when paralysis of left side complete. |
| 326 | | | | Recovered. | Improved. | | Died 13 months from rupture of aortic aneur. Autopsy showed above and also varicose condition of left choroid plexus. |
| 327 | | | | Recovered | | | |
| 328 | March 1, 1827. | 11, 49, 61st day. | | | | 62d day. Hem.; exhaustion. | (<i>Distal</i>) |
| 329 | 1825. | | | | | 34 hours. Coma. | Autopsy: Left hemisphere congested; right anæmic and serous effusion. |
| 330 | ? | | 14 | Recovered. | (?) | | |
| 331 | 1845. | | | Recovered. | Cured. | | |
| 332 | Jan. 13, 1859. | | | | | 12th day. (?) | No cerebral symptoms. Autopsy: No brain lesion. (<i>Note</i> .—Int. jugular vein also tied.) |
| 333 | May 30, 1859. | | | | | 2d day. | Lost consciousness before death. Autopsy: No brain lesions. (In this case also the int. jugular vein was tied.) |
| 334 | July 7, 1852. | | | | | 68th day. Inflammation lung. | "Progressed favorably up to 6th day." <i>Distal; Brasdor</i> . |

Surgical History of the

| No. | Name of operator. | Source of information. | PATIENT. | | | Cause of operation. | Duration of cause. | Point of deligation. | Date of injury. | Date of hemorrhage. |
|-----|-------------------------------|---------------------------------------------------------------|----------|---------|---------|-----------------------------------------------------------------|--------------------|----------------------|-----------------|---------------------|
| | | | Sex. | Age. | Side. | | | | | |
| 335 | Lane, L. C., 1873. | California State Soc. Trans.; Am. Jr. Med. Sci., Oct. 1874. | | | L. | Neuralgia following removal of parotid. | | Below omohyoid. | | |
| 336 | Lane, Jas., 1871 | Lancet, Jan. 13, 1872. | F. | 40 | R. | Aneurism of carotid, root of neck. | 5 mos. | Above omohyoid. | | |
| 337 | do. | do. Oct. 14, 1871. | M. | 39 | R. | do. | 9 mos. | | | |
| 338 | do. | Wien. Mediz. Woch., 1875, p. 630. | M. | 37 | L. | Traumatic aneurism of occipital artery behind ear. | 6 mos. | | | |
| 339 | Larrey, 1828. | Clinique Chir., vol. ii. p. 130. | M. | Soldier | R. | Hem.; stab w'd with sabre in duel, right side of neck, high up. | | | | |
| 340 | Lavochevie. | Arch. Klin. Chir., 1868. | M. | 55 | | Hem. of carotid. | | | | |
| 341 | Laub, H., 1874. | Schmidt Jahrb., B. 167, S. 266. | F. | 42 | L. | Hem.; removed part of submaxillary gland. | 8 days. | | | |
| 342 | Lauda, 1838. | Schmidt Jahrb., B. 30, S. 371. | M. | 22 | L. | Traumatic aneurism of carotid; stab wound of neck. | | | | |
| 343 | Lauer. | Arch. Klin. Chir. (cit.) | M. | | L. | Hem.; aneurism, traumatic. | | | | |
| 344 | Lawrence, 1867, England. | Schmidt Jahrb., No. 139, p. 221; N. Y. Med. Jr., March, 1839. | M. | 41 | L. | Traumatic aneurism of orbit. | 1 m'nth. | | | |
| 345 | Lawrence, M. | Arch. Klin. Chir., 1868. | M. | 31 | R. | Hemorrhage. | 1½ days. | | | |
| 346 | Lee, H., 1864. | Lancet, Nov. 1864, p. 523. | M. | 30 | L. | Hem.; opening ulcerating tumor of neck. | | | | |
| 347 | do. 1869. | Lancet, January and March, 1869. | M. | 40 | R. | Traumatic aneurism of carotid, low down. | | | | |
| 348 | Legouest. | Arch. Klin. Chir., 1868. | F. | | L. | Traumatic orbit. aneurism. | | | | |
| 349 | Lenoir, 1851. | do. | F. | y'g. | | Erect. tumor of temporal region. | | | | |
| 350 | Lerylier, 1846. | Ehrmann des effets, p. 48; Pilz (cit.). | F. | 64 | L. | Aneurism of carotid. | | | | |
| 351 | Lewis, J. B., U. S. A., 1864. | Med. Surg. Hist. Reb.; | M. | Mid age | L. | Shot wound of left side of face. | | | July 24. | Aug. 9. |
| 352 | | do. | Otis. | M. | Mid age | R. | do. | | | do. |
| 353 | Lick and Hopmann. | Berlin Klin. Wochen., Aug. 1871, p. 419. | M. | 23 | L? | Shot w'd of face. | | | | |
| 354 | Lisfranc, 1827. | Arch. Klin. Chir., 1868; Norris (cit.). | F. | 18 | R. | Fungus hæmatod. (supposed aneurism). | | | | |
| 355 | Liston, 1841. | Norris Contrib. | M. | 9 | R. | Hem.; puncture of supposed abscess. | 1 day. | Near innom. | | |

Common Carotid Artery—continued.

| No. | Date of operation. | Hemorrhage occurred, after op. | Lig. came away No. days aft. op. | RESULT. | | | REMARKS. |
|-----|----------------------------------|--------------------------------|----------------------------------|---------------|------------|----------------------------------------------|---------------------------------------------------------------------------------------------------------------------------------------------------------------------------------------------------------------------------------------------------------------------------------------------------------------------------------------------------|
| | | | | Recovery. | Condition. | Cause of death, date after op. | |
| 335 | 1873 ? | | | Recovered. | Cured. | | Treatment failing, it was accidentally discovered that pressure upon the carotid gave relief. After ligation of the carotid it was cured. |
| 336 | Sept. 20, 1871. | | 14 | Recovered. | Not cured. | | Tumor at first diminished, afterward much enlarged; subclavian tied same time. <i>Distal.</i> |
| 337 | June 28, 1871. | | 23 | Recovered. | Cured. | | No cerebral symptoms; temp. 1° higher in auditory meatus of right (lig.) side than opposite. |
| 338 | | | | Recovered. | Cured. | | Pulsation ceased after op.; returned 3 days; cure in 9 mos. |
| 339 | 1828. | | 11 | Recovered. | Cured. | | Hem. profuse before operation, and was arrested by ligation; Larrey supposed this a case of both external and internal carotids arising by separate trunks from innominate.— <i>Author.</i> |
| 340 | | | | | | Died. | |
| 341 | 1874. | 120th day. | 21 | Recovered. | Cured. | | |
| 342 | 1838. | | | Recovered. | Cured. | | After operation blind and deaf on left side. |
| 343 | | | 12 | Recovered. | Cured. | | |
| 344 | 1867. | | | Recovered. | Cured. | | |
| 345 | | | | | | 3d day. | Autopsy: Wounded vessel not found; brain normal. |
| 346 | | | | | | 2d day. | Above ligation adherent thrombus. |
| 347 | | | | | | 15th day (about). Cerebral complications. | Paralysis of right side face immediately after operation; temperature right side 2° higher, sweating profusely on <i>left</i> side. Dr. Jno. W. Ogle says, "want of equilibrium in muscles of face, result not of paralysis of the right side, but spasm of the muscles of the left," and "that the sympathetic nerve was injured by ulceration." |
| 348 | | | | Recovered. | Cured. | | External carotid tied at same time. No hemorrhage noted. |
| 349 | | | 15 | | | Died. | |
| 350 | 1846. | | | | | 11th-12th day. Coma. | 11th day <i>paralysis</i> of LEFT side. |
| 351 | Aug. 10, 1864. Aug. 14, 1864. | 4 days. | | Recovered (?) | Not cured. | | Ball entered left malar bone, out beneath left mastoid process. |
| 352 | | | | | | 9th day. 1st, 5th, 2d. | |
| 353 | | 2 days. | 21 | Recovered. | Cured. | | 2 mos. after operation aneurism developed at seat of ligation (diffuse), cured by compress after 6 weeks' trial. |
| 354 | | After. | | | | 18th day. Hem. disease. | Fungus of left cerebral fossa; petrous portion temporal bone carious; internal jugular vein obliterated. |
| 355 | Oct. 21, 1841. | 14 days. | | | | 15th day. Hem. | A tumor in neck, thought to be abscess, was opened; hem. followed. Autopsy: Proximal end of artery open; no attempt at thrombus. |

Surgical History of the

| No. | Name of operator. | Source of information. | PATIENT. | | | Cause of operation. | Duration of cause. | Point of deligation. | Date of injury. | Date of hemorrhage. |
|-----|-----------------------------|-----------------------------------------------------------------------------------------|----------|----------|-------|------------------------------------------------------|--------------------|----------------------|-----------------|-----------------------|
| | | | Sex. | Age. | Side. | | | | | |
| 356 | Liston, 1841. | Lancet, 1844, vol. ii. p. 276. | M. | 20 | L. | Vascular tumor of neck. | | | | |
| 357 | do. 1817. | Ed. Med. Surg. Jr., 1820, p. 72. | F. | 24 | L. | "Beating pain on left side of head and face." | | | | |
| 358 | do. 1838. | Poland in Guy's Hosp. Report, vol. xv. 1870. | M. | 31 | R. | Subclavian aneurism. | 6 mos. | | | |
| 359 | Lizars, J., 1827. | Lancet, April 10, 1830. | M. | | | Prep. resection of superior max.; medullary sarcoma. | | | | |
| 360 | Longmore, 1833 | Lancet, January, 1864, p. 90. | M. | | R. | Shot w'd through larynx; epiglottis carried away. | | | May 3, 1833. | |
| 361 | do. | do. | M. | | L. | Hem'ge from lingual artery. | | | | |
| 362 | Love, W. S., 1864, U. S. A. | Med. Surg. Hist. Reb.; Otis. | M. | Mid age. | | Shot w'd of inf. maxilla. | | Above omo-hyoid. | Aug. 13. | Aug. 21. |
| 363 | do. | do | M. | Mid age. | L. | Shot w'd of left side of face. | | | Sept. 19. | |
| 364 | Lücke, 1865. | Gaz. Hebdom., March 29, 1837; Arch. Klin. Chir., 1858. | M. | 25 | L. | Traumatic aneurism of vertebral (supposed carotid). | | | | |
| 365 | do. 1866. | Schmidt Jahrb., B. 141, p. 202. | M. | 66 | L. | Spontaneous pulsating tumor of forehead. | 7 years. | Above omo-hyoid. | | |
| 366 | Luke, 1829. | Norris Contrib. | M. | 45 | L. | Hem.; ulcer thr't. | 4 days. | | Sept. 30. | 1, 3, 4 day. |
| 367 | do. 1848. | Lancet, 1850, vol. ii. p. 109. | M. | 40 | L. | Suicidal wound (knife). | Short time. | At omo-hyoid. | | |
| 368 | Luzenberg, 1834. | Norris Contrib. | M. | 62 | L. | Parotid tumor. | 20 y'rs. | | | |
| 369 | Lyford, 1818. | Norris Contrib.; Arch. Klin. Chir., 1868. | M. | 36 | L. | Aneurism of carotid. common. | 3 w'ks. | | | |
| 370 | Lynn. | Arch. Klin. Chir., 1868. | F. | | | Second. hem. remov. carotid. | | | | |
| 371 | Macaulay, 1812 (Calcutta). | Norris Contrib.; Ehrmann des effets; Arch. Klin. Chir. (cit). | M. | 36 | L. | Aneurism of int. maxill., traum. | 5 days. | | | Day before operation. |
| 372 | Macgill, 1823, Maryland. | do. | F. | | R. | Pulsating vascular tumor of both orbits. | | | | |
| 373 | do. | do. | F. | | L. | do. | | | | |
| 374 | Maclachlan, 1825. | Norris Contrib.; Arch. Klin. Chir. | M. | 30 | L. | Vascular tumor of scalp, following arteriotomy. | | | | |
| 375 | Mac Manus. | Arch. Klin. Chir., 1858. | | | | Cervical tumor; carcinoma; supposed aneurism. | | | | |
| 376 | Magendie, 1827. | Norris Contrib.; Arch. Klin. Chir., 1858. | F. | 25 | L. | Tumor of antrum, high. | | | | |
| 377 | Mahon, A. D., 1838-9. | Schmidt Jahrb., No. 150, p. 307. | M. | Mid age | R. | Stab of carotid at bifurcation. | | | | |
| 378 | Mahon, M., 1864. | Am. Jr., vol. xlviii. p. 276, 1864, Dr. Madelung; Arch. Klin. Chir., vol. xvii. p. 626. | M. | 25 | L. | Hem.; shot w'd of lower jaw. | | | Nov. 25. | Nov. 29. |
| 379 | Malgaigne, 1845. | Arch. Klin. Chir., 1868. | M. | 46 | R. | Aneurism of carotid, innominate, and subclavian. | | | | |

Common Carotid Artery—continued.

| No. | Date of operation. | Hemorrhage occurred after op. | Lig. came away No. days aft. op. | RESULT. | | | REMARKS. |
|-----|--------------------------------------------------|-------------------------------|----------------------------------|------------|------------------------|--------------------------------|------------------------------------------------------------------------------------------------------------------------------------------------------------------------------------------------|
| | | | | Recovery. | Condition. | Cause of death, date after op. | |
| 356 | | After. | | | | 10th day. Hem. | |
| 357 | June 22, 1817. | | 22 | Recovered. | Relief only temporary. | | As pain ceased on pressure applied to left carotid, this vessel was tied. Relief was not of long duration. |
| 358 | 1838. | 11th day. | | | | 13th day. Hem. | Subclavian tied same time. Autopsy: Carotid and innominate obliterated; subclavian open. <i>Distal.</i> |
| 359 | Dec. 1827. | | | Recovered. | | | Died 17 months after of disease. |
| 360 | May 12, 1863. May 18, 1863. Sept. 4, 1864. | | | | | | Both vessels were closed; no brain symptoms noted. |
| 361 | | | | | | 38 hours. | |
| 362 | | | Recovered. | Cured. | | | |
| 363 | Oct. 7, 1864. | | | | | Next day. | |
| 364 | Aug. 4, 1865. | | 11 | | | 25th day. Hemiplegia. Coma. | Hemiplegia supervened on 23d day. Autopsy: Left hemisphere soft; tumor was in vertebral between atlas and occiput. |
| 365 | Aug. 9, 1836. | 14, 16, 17th day. | | | | 19th day. Hem.; delir. | Delirious after operation. Autopsy: Ulcerated hole in carotid at ligature. |
| 366 | Oct. 4, 1829. | 3d day. | 26 - 22 | Recovered. | Cured. | | |
| 367 | Sept. 6, 1818. | 4th and 10th. | | | | 49th day. Coma. | Erysipelas in face; violent delirium after operation. Autopsy: Arachnoid slightly injected; brain normal. |
| 368 | 1834. | | | Recovered. | Cured. | | |
| 369 | Oct. 30, 1818. | | 27 | Recovered. | Cured. | | |
| 370 | | | | | | 14th day. Exhaustion. | |
| 371 | Dec. 16, 1812. | | 18 - 21 | Recovered. | Cured. | | 2 ligs., vessel divided between them; 4th d. right side slightly paralyzed, which disappeared slowly. |
| 372 | 1823. | | | Recovered. | Not cured. | | |
| 373 | 1 month later. July 10, 1825. | | | Recovered. | Improved. | | "Several months after operation she is said to be doing well and tumors subsiding."— <i>Norris.</i> Autopsy: Pus in pleural sac and mediastinum. |
| 374 | | | | | | 4th day. Pleuritis, pyæmia. | |
| 375 | | | | | | 9th day. Diarrhœa. | |
| 376 | March 4, 1827. | | 11 | Recovered. | Worse. | | 5 days paralysis right arm; convulsions; paralysis improved later; mind impaired. |
| 377 | | | 21 | Recovered. | Cured. | | After operation stupor, which passed off in 2 days. |
| 378 | 1864. | Often. | 8 | Recovered. | | | Ball entered angle left inf. max., fracturing it; passed beneath tongue; exit right side of hyoid bone. On account of continued hem. after lig. of common carotid, ext. carotid was ligatured. |
| 379 | April 3, 1845. | | 18 | Recovered. | Slight improvement. | | Ten weeks after this operation subclavian was tied (or was supposed to have been tied). Autopsy showed carotid obliterated, but subclav. pervious. |

Surgical History of the

| No. | Name of operator. | Source of information. | PATIENT. | | | Cause of operation. | Duration of cause. | Point of deligation. | Date of injury. | Date of hemorrhage. |
|-----|-------------------|--------------------------------------------------|----------|---------|-------|------------------------------------------------|--------------------|----------------------|-----------------|---------------------|
| | | | Sex. | Age. | Side. | | | | | |
| 380 | Maisonneuve. | Arch. Klin. Chir., 1868. | F. | 30 | R. | Varicose aneurism of parietal reg., traumatic. | 2 mos. | | | |
| 381 | do. | do. | | | | Remov. of parotid gland, preparatory. | | | | |
| 382 | Mandt. | do. | M. | 40 | L. | Prep. to removal of fungus of parotid. | | | | |
| 383 | Marchal, 1835. | Norris Contrib.; Arch. Klin. Chir., 1868. | M. | 25 | L. | Hem.; puncture aneurism mistaken for abscess. | | | | |
| 384 | Marquardt, 1869. | Allg. Med. Zeit.; Lancet, Jan. 1870. | M. | Y'g m'n | R. | Stab wound of external carotid angle of jaw. | | | | |
| 385 | Marjolin, 1814. | Norris Contrib.; Arch. Klin. Chir., 1868. | M. | 20 | | Hem.; shot w'd. | 6 days. | | | |
| 386 | Maunder, 1861. | Arch. Klin. Chir., 1868. | F. | 24 | R. | Second. hem. after removal of inf. maxilla. | | | | |
| 387 | do. 1857. | Lancet, Sept. 1837. | M. | 37 | R. | Innominate aneurism (supposed). | | | | |
| 388 | Mayer. | Arch. Klin. Chir., 1868. | | | | Prep. to removal of inf. max. | | | | |
| 389 | Maunoir. | do. | M. | 30 | L. | Cirsoid aneurism. | | | | |
| 390 | Mayo, Ch., 1827. | Norris Contrib.; Arch. cit. | M. | 26 | R. | Tumor of neck. | | | | |
| 391 | Mayo, H., 1828. | Norris Contrib.; Arch. cit.; Ehrmann des effets. | M. | 23 | R. | Hem.; ulcer thro't; lingual artery. | | | | |
| 392 | do. 1834. | do. | M. | 30 | R. | Hem.; knife w'd of throat. | 8 days. | | | |
| 393 | do. 1833. | Norris Contrib.; Arch. Klin. Chir. (cit.). | M. | 5 mos | L. | Erectile tumor of face. | 5 mos. | | | |
| 394 | Mayo, R., 1829. | Arch. Klin. Chir., 1868. | M. | | R. | Hem.; abscess of thro't (after puncture). | | | | |
| 395 | McClellan, 1825. | Norris Contrib.; Arch. Klin. Chir., 1838. | M. | 5 | L. | Erectile tumor of orbit. | 4½ y'rs. | | | |
| 396 | do. | do. | F. | 9 | L. | Erectile tumor of cheek. | | | | |
| 397 | do. | do. | M. | 16 | R. | Vascular fungus of dura mater. | | | | |
| 398 | Maurin, 1829. | Norris Contrib., 1838. | M. | 40 | L. | Aneurism of carotid, traumatic. | 1 m'nth. | | | |
| 399 | McCullough. | Am. Jr. Med. Sci., April, 1864, p. 334. | M. | | L. | Shot wound. | 3 days. | | | |
| 400 | McMurdo, 1845. | do. | M. | 27 | | Hem.; abscess. | 1 day. | | | |

Common Carotid Artery—continued.

| No. | Date of operation. | Hemorrh'ge occurred after op. | Lig. came away No. days aft. op. | RESULT. | | | REMARKS. |
|-----|--------------------|-------------------------------|----------------------------------|------------|-----------------|----------------------------------------|------------------------------------------------------------------------------------------------------------------------------------------------------------------------------------------------------------------------------------------------------------------------------------------------------------------------------------------|
| | | | | Recovery. | Condition. | Cause of death, date after op. | |
| 380 | | | | | | 3d day. | External carotid was tied first; this lig. fell 16th day. The sup. thyroid was tied at this time. Hem. again occurring, the int. and common carotids were tied, followed by complete hemiplegia (L). Autopsy: Right hemisphere softened, the <i>sympathetic nerve included in both the internal and common carotid ligatures.</i> —Pitz. |
| 381 | | | | | | Soon. Cereb'l complications. | |
| 382 | | | | | | 8th week. Return of disease. | |
| 383 | June 19, 1835. | After. | | | | 6th day. Hem.; cerebral complications. | |
| 384 | 1839. | | 20 | Recovered. | | | External carotid was first tied, but not arresting hem. common carotid tied; 2d day convulsions. Attempt to tie ext. carotid a failure; no cerebral symptoms followed. |
| 385 | 1814. | Once. | | | | Several days. Hem.; meningitis. | |
| 386 | March 30, 1861. | | | Recovered. | Cured. | | Pain right side of head for several weeks. |
| 387 | 1867. | | | | | 5th day. | Subclavian also tied. Autopsy: Aneurism of aorta—not of innominate. |
| 388 | (?) | | | Recovered. | (?) | | |
| 389 | Before 1821. | | | Recovered. | No improvement. | | |
| 390 | Oct. 19, 1828. | | 17 | Recovered. | No better. | | Died in 7 months, of hem., disease; cerebral complications; epilepsy followed operation. |
| 391 | do. | | 15 | Recovered. | Cured. | | Patient died 5 years later. Autopsy showed lingual artery to have been wounded. |
| 392 | 1834. | | | | | 13th day. Inflan'n of brain. | 6 days after 1st lig. hem. occurred and a deeper lig. was applied; paralysis of left side. Autopsy: Abscess in right hemisphere. |
| 393 | 1833. | | 8 | Recovered. | Improved. | | |
| 394 | 1829. | Twice. | | Recovered. | Cured. | | |
| 395 | Jan. 10, 1825. | | 14 | Recovered. | Cured. | | |
| 396 | 1825. | | 14 | Recovered. | Cured. | | |
| 397 | do. | | 14 | Recovered. | Cured. | | Dr. C. Pitz of Breslau accredits McClellan with a 4th case under the head of "Epilepsy," the patient "M. 16 R., and vascular tumor over right ear," leads me to believe that the case is identical with this case. I have omitted it on this account, with many others I have found about which an uncertainty exists.— <i>Author.</i> |
| 398 | Nov. 20, 1829. | | | Recovered. | Cured. | | Two ligatures, vessel divided between. |
| 399 | | | | Recovered. | Cured. | | |
| 400 | Dec. 1, 1845. | 5, 6 days. | | | | 7th day. Exhaustion. | Autopsy: Varicose aneurism—int. jug. vein and int. carotid artery. |

Surgical History of the

| No. | Name of operator. | Source of information. | PATIENT. | | | Cause of operation. | Duration of cause. | Point of deligation. | Date of injury. | Date of hemorrhage. |
|-----|--------------------------------|--------------------------------------------------------|----------|----------|-------|-------------------------------------------------------------------|--------------------|---------------------------|-----------------|---------------------|
| | | | Sex. | Age | Side. | | | | | |
| 401 | McGraw, T. A., Michigan, 1873. | Letter to author from Prof. McGraw. | F. | 39 | | Prep. to remov. of pulsating malignant tumor of superior maxilla. | Some time. | | | |
| 402 | McKee, J. C., 1864, U. S. A. | Med. Surg. Hist. Reb.; Otis. | M. | 18 | L. | Shot w'd of left mastoid reg. | | Above omo-hy. | Aug. 21. | Aug. 26. |
| 403 | McMahon, A., U. S. A., 1865. | do. | M. | Mid age | R. | Shot w'd of right malar reg. | | do. | April 9. | |
| 404 | ? U. S. A., 1863. | do. | M. | 18 | R. | Shot w'd of cranium through frontal bone. | | do. | Nov. 25. | |
| 405 | Mettauer, 1842. | Ehrmann des effets, Paris, 1860, p. 38. | M. | 25 | R. | Aneurism, traum. | | | | |
| 406 | do. 1829. | Am. Jr. Med. Sci., Oct. 1849, p. 349. | M. | 43 | L. | Aneurism anast.; antrum of nose. | Several years. | | | |
| 407 | Michaux, 1846. | do. | M. | 44 | L. | Prep. to remov. of polyp. throat. | About 1 year. | | | |
| 408 | Michels, 1835. | Norris Contrib.; Am. Jr. Med. Sci., Oct. 1849, p. 349. | F. | 23 | L. | Aneurism anast. of face and occiput. | 2 years. | | | |
| 409 | Miller, 1825. | do. | F. | 25 | | Wound of neck. | 27 days. | | | |
| 410 | do. 1836. | Norris Contrib.; Ehrmann des effets; | F. | 42 | R. | Erectile tumor of orbit. | 18 mos. | | | |
| 411 | Millies. | Arch. Klin. Chir., 1868. | | | | Aneurism, fusiform; superior thyroid. | | | | |
| 412 | Moon, W. P. | See Morton, T. G. (a). | F. | 29 | R. | Aneurism of external carotid. | | | | |
| 413 | Molina, 1828. | Ehrmann (cit.), p. 43; Arch. Klin. Chir. (cit.). | F. | 29 | R. | Aneurism of external carotid. | | | | |
| 414 | Montgomery, 1829. | Laucet, 1833, p. 421; Norris Contrib. | M. | 40 | L. | Aneurism of carotid. | | | | |
| 415 | Moore, J. H., 1862. | Med. Surg. Hist. Reb.; Otis. | M. | Mid age. | L. | Shot w'd of left temporal bone. | | | Feb. 14. | March 2d, Sth. |
| 416 | Moreland, 1861, Lavallée. | Arch. Klin. Chir., 1868. | M. | 36 | L. | Pulsating fungus of dura mater. | 2 mos. | | | |
| 417 | Morrison, 1832. | Am. Jr. Med. Sci., vol. xix. p. 324; Norris Contrib. | M. | 42 | R. | Aneurism of innom. and carotid. | | | | |
| 418 | Morrogh, 1849. | New York Journ. Med. & Coll. Soc., May, 1852, p. 419. | M. | 24 | R. | Epilepsy. | 8-9 y'rs. | | | |
| 419 | Morton, T. G., Phila., 1864. | do. | F. | 36 | R. | Spontaneous aneurism of orbit. | | | | |
| 420 | do. | Am. Jr. Med. Sci., January, 1868. | M. | Mid age. | R. | Hem. 2d day after attempted removal of tumor of neck. | | 1½ inch above innominate. | | |
| 421 | do. 1839. | Am. Jr. Med. Sci., April, 1876. | M. | 27 | L. | Hem.; lacerated wound of face. | Few days. | | | |
| 422 | do. 1874. | do. | F. | 23 | L. | Supposed intracraial aneurism. | do. | | | |
| 423 | do. | do. | M. | 43 | L. | Pulsating tumor of orbit. | | | | Several times. |

Common Carotid Artery—continued.

| No. | Date of operation. | Hemorrh'ge occurred after op. | Lig. came away No. days aft. op. | RESULT. | | | REMARKS. |
|-----|--------------------|-------------------------------|----------------------------------|------------|------------------------|---------------------------------------------|-------------------------------------------------------------------------------------------------------------------------------------------------------------------------------------------------------------|
| | | | | Recovery. | Condition. | Cause of death, date after op. | |
| 401 | May 17, 1873. | | 60 | Recovered. | Cured. | | |
| 402 | Aug. 27, 1864. | | | | | 6 days. | |
| 403 | May 7, 1865. | | | | | 19 days. | |
| 404 | Dec. 17, 1863. | | | | | 2 days. | Ball entered frontal bone 1½ in. above the supra-orbital ridge, through right orbit, out near angle of inf. maxilla. |
| 405 | 1842. | | | | | 12 days. Coma; hemiplegia. | Hemiplegia (left) in eleven h'rs. Autopsy: Right hemisphere softened. |
| 406 | May 12, 1829. | | | | | 12 days. Cerebral complications. | Paralysis (right) 24 hours after operation; 8th day coma; death in convulsions. |
| 407 | Nov. 8, 1846. | | | Recovered. | Cured. | | Died 2 y'rs after from carcinoma. |
| 408 | March 12, 1835. | | 30 | Recovered. | Cured. | | Patient was 3 months pregnant at time of operation; did well. |
| 409 | Oct. 1825. | | | Recovered. | Cured. | | For 3 days after operation patient was unconscious. |
| 410 | 1836. | | | | | 8 days. Cerebral complications. | 2d day; paralysis of left side. |
| 411 | | | | | | 4 days. | Died suddenly; no autopsy. |
| 412 | | | | | | | |
| 413 | | | 21 | Recovered. | Cured. | | Moeller, see Gunderlach. |
| 414 | March 10, 1829. | 12th day. | 18 | | | 125 days. (?) | Tumor disappeared; cause of death not given. (Probably pyæmia.— <i>Author.</i>) (There was suppuration of the tumor, and at autopsy the int. jug. vein was found involved in the disease. <i>Distal?</i>) |
| 415 | March 22, 1862. | | 12 | Recovered. | Cured. | | Six years after operation there was facial paralysis. (In all probability due to direct injury to 7th nerve (portio dura) by missile.— <i>Author.</i>) |
| 416 | Aug. 7, 1861. | Several times. | | | | 11 days. Pyæmia. | Autopsy: Lower thrombus adherent, upper not. |
| 417 | Nov. 8, 1832. | | 32 | Recovered. | Not cured. | | Died suddenly 20 months after; cause not given. <i>Distal.</i> |
| 418 | Feb. 23, 1849. | | 15 | Recovered. | Improvem't only temp'y | | |
| 419 | Dec. 4, 1864. | | 21 | Recovered. | Cured. | | |
| 420 | 1864. | | | | | 10th day. Pyæmia. | Partial paralysis of left side followed operation. |
| 421 | Oct. 15, 1869. | After. | | | | 21st day. Rupture jug. vein; hem. indirect. | Mediate transfusion practised 5 days after operation; patient did well until 19th day, when int. jug. vein ruptured; died 2 days later. |
| 422 | 1874. | | | | | 24 hours. Cerebral complications. | Although the bruit was distinctly heard by Dr. M., no aneurism was discovered at the autopsy. Intense inflammation at apex of orbit and firm clots in the sinuses. |
| 423 | Jan. 8, 1876. | | | | | Few hours. Serous apoplexy. | Autopsy: Arachnoid opaque and cloudy; large amount of serum beneath; patient had been struck in this eye by snowball 29 years previous. |

Surgical History of the

| No. | Name of operator. | Source of information. | PATIENT. | | | Cause of operation. | Duration of cause. | Point of deligation. | Date of injury. | Date of hemorrhage. |
|-----|------------------------------------------|------------------------------------------------------------------------------------|----------|-------------|-------|------------------------------------------------------------------------|--------------------|-----------------------------------|-----------------|---------------------|
| | | | Sex. | Age. | Side. | | | | | |
| 424 | Mosely, N. R., 1864, U. S. A. | Med. Surg. Hist. Reb.; Otis. | M. | 28 | L. | Shot w'd of left inferior maxilla. | | Above omo- hyoid. | Oct. 27. | Nov. 4. |
| 425 | Moses, I., 1863. | do. | M. | Mid age. | R. | Shot w'd of face. | | 1½ inch above innomi- nate. | Sept. 20. | Often. |
| 426 | Murdock, R., 1863, U. S. A. do. | do. | M. | do. | L. | Shot w'd through larynx at upper border of thyroid cartilage. | | | May 3. | May 12. |
| 427 | | do. | M. | do. | R. | | | | | |
| 428 | Mussy, 1827, New Hamp- shire. | Norris Contrib. p. 281; Ehrmann (cit.). | M. | 20 | R. | Erectile tumor of scalp. | | | | |
| 429 | do. | do. | M. | 20 | L. | do. | | | | |
| 430 | Muller, 1831. | Norris Contrib. | C'd. | 4½ | R. | | | | | |
| 431 | do. 1832. | do. | C'd. | 4½ | L. | | | | | |
| 432 | Mott, Prof. Val- entine, New York. | Notes of the late Val- entine Mott, kindly furnished by Prof. A. B. Mott. | | C'd. | | Aneurism anast. of orbit and nose. | | | | |
| 433 | do. | do. | | 3 mos | | Aneurism anast. of neck and jaw. | | | | |
| 434 | do. | do. | M. | 60 | R. | Aneurism, innom. | | | | |
| 435 | do. | do. | M. | 45 | R. | do. | | | | |
| 436 | do. 1823. | do. | M. | Abt 60 | R. | Osteo-sarcoma of right inf. max. | | | | |
| 437 | do. 1831. | do. | F. | | | Vascular sarcoma extending from occiput to clav. | | | | |
| 438 | do. | do. | F. | | | Lymphatic gland; tumor of enor- mous size. | | | | |
| 439 | do. 1850. | do. | M. | 50 | L. | Malignant tumor of mouth. | | | | |
| 440 | do. 1851. | do. | M. | | L. | Malignant fungus of nose. | | | | |
| 441 | do. 1852. | do. | M. | | R. | do. | | | | |
| 442 | do. 1833. | do. | M. | | L. | Cancer of parotid. | | | | |
| 443 | do. | do. | | | R. | do. | | | | |
| 444 | do. 1858. | do. | M. | 21 | R. | Malignant tumor of antrum, nose, and zygomatic fossa. | | | | |
| 445 | do. 1859. | do. | M. | | R. | do. | | | | |
| 446 | do. 1855. | do. | F. | | L. | Malignant disease of left orbit and frontal sinus. | | | | |
| 447 | do. 1818. | do. | M. | 49 | L. | Rem. tumor of neck. | | | | |
| 448 | do. 1821. | do. | F. | 17 | R. | Remov. inf. max- illa for osteo-sar- coma. | 2 years. | | | |

Common Carotid Artery—continued.

| No. | Date of operation. | Hemorrhage occurred after op. | Lig. came away No. days aft. op. | RESULT. | | | REMARKS. |
|-----|--------------------|----------------------------------------|----------------------------------|------------|-------------------------|-----------------------------------------|---------------------------------------------------------------------------------------------------------------------------------------------------------------------------------------------------------------------------------|
| | | | | Recovery. | Condition. | Cause of death, date after op. | |
| 424 | Nov. 4, 1864. | | | | | 12th day. Exhaust. | |
| 425 | Oct. 23, 1863. | | | | | 2d day. | External carotid was tied 19 days before common, but failed to arrest hem. |
| 426 | May 12, 1863. | 3d day. | | | | Op. failed. | |
| 427 | May 15, 1863. | 5th day. | | | | 1st oper. 8th day. 2d oper. 5th day. | |
| 428 | Sept. 20, 1827. | | | Recovered. | Not improved. | | Tumor afterwards removed, patient lost 2 qts. blood, and more than 20 lig.s. were required. |
| 429 | Nov. 2, 1827. | | | Recovered. | Improved. | | |
| 430 | Sept. 13, 1831. | | | Recovered. | Not cured. | | |
| 431 | Jan. 28, 1832. | | | Recovered. | Cured. | | |
| 432 | | | | Recovered. | | | Tumor had crossed bridge of nose and invaded portion of opposite eye. |
| 433 | | | | Recovered. | | | |
| 434 | | With and after separation of ligature. | | | | Hem. in about 20 days. | Hemorrhage was arterial. <i>Distal.</i> |
| 435 | | | 13 | Recovered. | Cured. | | Died one year later from other affections. Autopsy: Aneurismal tumor was firm, small, and solid. <i>Distal.</i> |
| 436 | May 21, 1823. | | 9 | Recovered. | | | Tumor removed day after ligature of carotid. |
| 437 | Nov. 3, 1831. | | | Recovered. | Cured. | | |
| 438 | | | | Recovered. | | | |
| 439 | Oct. 30, 1850. | | 18 | Recovered. | Cured or much improved. | | Tumor of fauces, pharynx, and mouth, immense size; tumor diminished after operation. |
| 440 | Aug. 9, 1831. | None. | | Recovered. | Temporary relief. | | Tumor broke down after 1st operation, but returned in three months. Upon June 6th, 1832, it was deemed expedient to tie the remaining carotid, which was done. (The notes are marked underneath "successful."— <i>Author.</i>) |
| 441 | Jan. 6, 1852. | do. | | Recovered. | Cured. | | |
| 442 | Aug. 3, 1833. | do. | | | | Within 48 hours. No hem. Coma. | Patient became comatose, and died in this condition. |
| 443 | 15 minutes later | do. | | | | | |
| 444 | Oct. 5, 1858. | do. | | Recovered. | Temporary relief. | | |
| 445 | June 5, 1859. | do. | 14 | Recovered | Improved. | | After last operation tumor subsided. |
| 446 | Dec. 1855. | | | Recovered. | | | |
| 447 | Nov. 14, 1818. | | 14 | Recovered. | | | This patient died about 4 months after operation. (I have been unable to find the cause of his death.— <i>Author.</i>) |
| 448 | Nov. 18, 1821. | | 15 | Recovered. | Cured. | | |

Surgical History of the

| No. | Name of operator. | Source of information. | PATIENT. | | | Cause of operation. | Duration of cause. | Point of deligation. | Date of injury. | Date of hemorrhage. |
|-----|----------------------------------------|-------------------------------------------------------------------------|----------|----------|------|--------------------------------------------|--------------------|----------------------|-----------------|---------------------|
| | | | Sex. | Age. | Side | | | | | |
| 449 | Mott, Prof. Valentine, New York, 1822. | Notes of the late Valentine Mott, kindly furnished by Prof. A. B. Mott. | F. | 22 | L. | Remov. inf. maxilla for osteo-sarcoma. | 1 year. | | | |
| 450 | do. 1823. | do. | M. | 18 | R. | Disar. condyle of inf. maxilla. | 6 years. | | | |
| 451 | do. 1830. | do. | | C'd. | | Aneurism anast. of temple. | | | | |
| 452 | do. 1832. | do. | F. | 19 | | Remov. of tumor of neck. | 5 years. | | | |
| 453 | do. | do. | M. | | R. | Idiopathic epilepsy. | | | | |
| 454 | do. | do. | M. | | L. | do. | | | | |
| 455 | do. 1859. | do. | | *. | L. | Fungous tumor of antrum. | | | | |
| 456 | do. 1861. | do. | | | R. | do. | | | | |
| 457 | (Eve, Prof. P. F., 1835.) | do. | M. | 19 | L. | Bleeding polypus of nose. | | | | |
| 458 | Mott, V., 1836. | do. | M. | | R. | | | | | |
| 459 | do. 1854 ? | do. | M. | | R. | Malignant disease of orbit? | | | | |
| 460 | do. | do. | | | L. | do. | | | | |
| 461 | do. 1848. | do. | M. | | R. | Epilepsy. | | | | |
| 462 | do. 1834. | do. | M. | | L. | do. | | | | |
| 463 | do. 1849.* | do. | M. | 22 | R. | do. | | | | |
| 464 | Mott, Prof. A. B., 1854. | Notes kindly furnish'd by Prof. Mott to author. | F. | 6½ mos | L. | Aneurism anast. of left side of face. | | | | |
| 465 | do. | do. | F. | 7 y'rs | R. | Fungus hæmatod. at orbit. | | | | |
| 466 | do. 1855. | do. | F. | 24 | R. | Recurrent malignant tumor at side of neck. | | | | |
| 467 | do. 1856. | do. | F. | 23 | L. | Aneurism anast. | | | | |
| 468 | do. 1858. | do. | M. | 6 | R. | Malignant tumor of parotid. | | | | |
| 469 | do. 1859. | do. | F. | 9 mos | R. | Large aneurism anast. over parotid gland. | | | | |
| 470 | do. | do. | F. | 2½ y'rs | L. | Fungus hæmatod. of left eyeball. | | | | |
| 471 | do. 1864. | do. | M. | Mid age. | R. | Shot w'd of right antrum. | | | | |
| 472 | do. 1867. | do. | | 23 | L. | Remov. of inf. maxilla, malignant disease. | | | | |
| 473 | do. 1868. | do. | M. | | R. | Subclavian aneurism. | | | | |

Common Carotid Artery—continued.

| No. | Date of operation. | Hemorrhage occurred after op. | Lig. same away No. daysaft. op. | RESULT. | | | REMARKS. |
|-----|--------------------|-------------------------------|---------------------------------|------------|-------------------|----------------------------------|----------------------------------------------------------------------------------------------------------------------------------------------------------------------------------------------------------------------------------------------------------------------------------------------------------------------------------------------------------------------------------------------|
| | | | | Condition. | Recovery. | Cause of death, days after op. | |
| 449 | March 30, 1822. | | 14 | Recovered. | Cured. | | |
| 450 | May 15, 1823. | | | | | 4th day. Pleuritis; pneumonitis. | |
| 451 | 1830. | | 15 | Recovered. | Improved. | | |
| 452 | Feb. 1832. | | | Recovered. | Cured. | | |
| 453 | | | | Recovered. | Slight relief. | | |
| 454 | { 6 months later. | | | Recovered. | do. | | Died about 1 year after of tuberculosis of lungs. Tumor decreased notably after operation. Dr. V. Mott notes this as his 50th case of ligature of the common carotid. The case was given him for operation by his son, Dr. A. B. Mott. |
| 455 | { June 1, 1839. | | | Recovered. | Improved. | | |
| 456 | { 1831. | | | Recovered. | Cured. | | |
| 457 | { July 25, 1835. | | 18 | Recovered. | Temporary relief. | | |
| 458 | { Aug. 25, 1836. | | 13 | Recovered. | | | Polypus returned after Dr. Eve's operation, and was removed by him once or twice, but recurring Dr. Mott tied the vessel of the opposite side. |
| 459 | { 1854? | | | Recovered. | ? | | |
| 460 | { 3 months later. | | | | | 4th day. ? | (NOTE.—A mention of this case is made upon a little brown sheet of paper, faded by time, found among Dr. V. Mott's MSS. I am convinced that it has not been heretofore given.— <i>Author</i> .) The attacks were not so violent and at longer intervals. |
| 461 | { Sept. 14, 1848. | | | Recovered. | Improved. | | |
| 462 | { Oct. 1834. | | | Recovered. | do. | | |
| 463 | { Oct. 30, 1849. | | | Recovered. | do. | | |
| 464 | Feb. 1, 1854. | | 17 | Recovered. | Cured. | | * These 31 cases of Dr. Valentine Mott are all the cases in which Dr. Alexander B. Mott (who has carefully looked over the notes left by his distinguished father) can positively state the results of the operations. There are 20 other cases where mention is made of tying the carotid, but no results given, nor indications by which the cases could be followed out.— <i>Author</i> . |
| 465 | April 10, 1854. | | | Recovered. | Cured. | | Eye was extirpated at same time; no return after two years. |
| 466 | Feb. 3, 1855. | | 17 | Recovered. | Cured. | | |
| 467 | Oct. 30, 1856. | | 21 | Recovered. | Cured. | | |
| 468 | Feb. 8, 1858. | | 12 | Recovered. | Cured. | | |
| 469 | Jan. 20, 1859. | | 14 | Recovered. | Cured. | | |
| 470 | March 27, 1859. | | 13 | Recovered. | Cured. | | Disease did not return; eyeball extirpated same time. |
| 471 | Aug. 24, 1864. | | 15 | Recovered. | | | |
| 472 | 1867. | | 15 | Recovered. | | | Lieut. Maley, 5th U. S. Cavalry; wound by explosive missile. |
| 473 | Aug. 13, 1868. | | 14 | | | 23d day. Pulmon. hem. | The innominate artery was tied same day; ligature loose on 20th. |

Surgical History of the

| No. | Name of operator. | Source of information. | PATIENT. | | | Cause of operation. | Duration of cause. | Point of deligation. | Date of injury. | Date of hemorrhage. |
|-----|--------------------------------|------------------------------------------------------------------------------|----------|-------|-------|-------------------------------------------------------|--------------------|----------------------|-----------------|---------------------|
| | | | Sex. | Age. | Side. | | | | | |
| 474 | Mott, Prof. A. B., 1874. | Notes kindly furnish'd by Prof. Mott to auhor. | M. | 67 | R. | Malignant tumor of antrum. | | | | |
| 475 | Niccoli, 1850. | Arch. Klin. Chir., 1868; Pflz. | M. | 24 | R. | Knife wound, suicidal. | | | | |
| 476 | Nieden, 1874. | Schmidt Jahrb., B. 169, p. 52. | M. | 19 | L. | Pulsating tumor of left orbit. | Several weeks. | | | |
| 477 | Nason, J. J., 1867. | Br. Med. Jr., Feb. 1867; Am. Jr. Med. Sci., April, 1867. | M. | Boy | L. | Wound by pitchfork at bifurcation. | | | | |
| 478 | Norris, Geo. W., Phila., 1855. | Pflz; Am. Jr. Med. Sci., April, 1856. | M. | 46 | L. | Aneurism of carotid, traumatic. | 5 days. | | | |
| 479 | Nottingham, 1841. | Arch. Klin. Chir., 1868; Pflz. | F. | 8 | L. | Tumor of mouth. | 8 years. | | | |
| 480 | Nunneley, 1852. | Med. Chir. Trans., vol. xlii. p. 165. | M. | 31 | L. | Aneurism of orbit, traumatic. | | | | |
| 481 | do. 1856. | do. | M. | 38 | L. | do. | 7 mos. | | | |
| 482 | do. 1858. | do. p. 175. | F. | 65 | L. | Aneurism of orbit, spontaneous. | | | | |
| 483 | do. 1859. | do. | F. | 42 | R. | do. | | | | |
| 484 | do. | do. | M. | 40 | L. | Aneurism of orbit, traumatic. | | | | |
| 485 | do. | do. | M. | 43 | R. | Supposed aneurism of orbit; carcinoma. | 4 mos. | | | |
| 486 | Nussbaum, 1860. | Bayr. Aerz. Intellig. Blatt, 1863, No. 33, S. 461; Arch. Klin. Chir. (cit.). | F. | 8 | L. | Hem. of internal maxilla. | | | | |
| 487 | do. 1862. | do. | F. | 22 | L. | Neuralgia. | | | | |
| 488 | do. | do. S. 472. | M. | 40 | R. | Tic douloureux. | | | | |
| 489 | do. | do. S. 470. | F. | 38 | R. | do. | | | | |
| 490 | do. | Arch. Klin. Chir., 1868. | | | R. | Epilepsy. | | | | |
| 491 | do. | do. | | | R. | do. | | | | |
| 492 | do. | do. | | | R. | do. | | | | |
| 493 | Ossieur, 1848, des Roulers. | do. | M. | | L. | Hem.; puncture wound of vertebral (supposed carotid). | | | | |
| 494 | O'Reilly, 1844. | Dublin Med. Press, Oct. 1844; Lancet, 1844, vol. i. p. 470. | M. | 44 | R. | Supposed aneurism (carcinoma). | 2 years. | | | |
| 495 | O'Shaughnessy, about 1843. | Norris Contrib.; Dublin Med. Press, Oct. 1844; Lancet, 1844, vol. i. p. 470. | M. | 42 | R. | Supposed innominate aneurism (of aorta). | | | | |

Common Carotid Artery—continued.

| No. | Date of operation. | Hemorrhage occurred after op. | Lig. came away No. days aft. op. | RESULT. | | | REMARKS. |
|-----|--------------------|-------------------------------|----------------------------------|------------|---------------------------------------------------------------------------------------|-----------------------------------|--------------------------------------------------------------------------------------------------------------------------------------------------------------------------------------------------------------------------------------------------------------------------------------------------------------------------------|
| | | | | Condition. | Recovery. | Cause of death, days after op. | |
| 474 | Oct. 12, 1874. | | 21 | Recovered. | | | Dr. Alexander B. Mott has tied the common carotid in 4 other instances, but the notes of cases giving accurate results could not be obtained in time. Unfortunately, other cases are necessarily omitted. The author is indebted to Valentine Mott, Esq., for valuable aid in collecting his father's and grandfather's cases. |
| 475 | July 2, 1856. | 2d day. | 16 | Recovered. | Cured. | | Carbolized catgut ligature, compression of carotid had been tried for 10 weeks without effect; patient left bed 6 days after op. |
| 476 | 1874. | | | Recovered. | Cured. | | |
| 477 | 1867. | | 12 | Recovered. | Cured. | | Several days after operation convulsions. Autopsy: Varicose aneurism of internal jugular vein and carotid artery; left hemisphere softened. |
| 478 | Nov. 8, 1855. | | | | | 34th day. Cerebral complications. | |
| 479 | Jan. 4, 1841. | | 19 | Recovered. | Improved. | | No brain symptoms. |
| 480 | Nov. 3, 1852. | | 96 | Recovered. | Cured. | | |
| 481 | March 8, 1856. | Several times, profuse. | | Recovered. | Cured. | | Convulsions day after operation. Autopsy: Left hemisphere softened. |
| 482 | April 3, 1858. | | | | | | |
| 483 | Aug. 24, 1859. | | 23 | Recovered. | (?) | | Very much improved on October 10th following. |
| 484 | | | | Recovered. | Cured. | | |
| 485 | | | | Recovered. | Not cured. | | Paralysis of left side followed 5th day. |
| 486 | Nov. 2, 1860. | | | | | 2d day. Exhaust'n. | No brain symptoms. |
| 487 | March 9, 1862. | | | Recovered. | Cured. | | Loss of sensibility in right arm for 14 days. Nerve resected at same time; 12 hours after operation paralysis of left side; recovery complete. No bad symptoms followed op. |
| 488 | Oct. 30, 1862. | | | Recovered. | Cured. | | |
| 489 | Nov. 8, 1862. | | | Recovered. | ? | | Convulsions continued, seeming in some instances to be exaggerated. |
| 490 | | | | Recovered. | No benefit in either of these three cases; probably increased violence of the malady. | | |
| 491 | | | | Recovered. | | | In one case the jugular vein was wounded and was tied or stitched around some way to arrest hemorrhage; pyæmia followed with pleuritis; partly recovered; "die heftige Blutung wurde durch die umschlungene naht gestillt." |
| 492 | | | | Recovered. | | | |
| 493 | 1848. | After. | | | | 3d day. Hem. | Pressure over carotid arrested hemorrhage, hence ligature. (It is probable the vertebral was compressed with carotid.— <i>Author</i> .) Autopsy: Wound of vertebral. |
| 494 | July 20, 1844. | | | | | 9th day. Apoplexy. | Autopsy: Carcinoma; brain not examined. |
| 495 | 1843? | After. | | | | 10th day. Hem. | Autopsy: Rupture of aneurism of aorta; innominate almost obliterated. |

Surgical History of the

| No. | Name of operator. | Source of information. | PATIENT. | | | Cause of operation. | Duration of cause. | Point of deligation. | Date of injury. | Date of hemorrhage. |
|-----|---------------------------------|------------------------------------------------------------------------------------|----------|------------|-------|----------------------------------------------------------|--------------------|-------------------------|------------------|---------------------|
| | | | Sex. | Age. | Side. | | | | | |
| 496 | Packard, J. H., 1864. | Med. Surg. Hist. Reb.; Otis. | M. | Mid age | R. | Shot w'd of right jaw. | | | Sept. 30. | |
| 497 | Pallan, Prof. M. A., 1861. | Verbal com. to author (army of W. Va.). | M. | | R. | Buckshot wound; fracture of ra- mus of inf. max. | | | | |
| 498 | Palm, 1820. | Arch. Klin. Chir., 1868. | | | | Prep. remov. inf. maxilla. | | | | |
| 499 | Palmer, H., 1863. | Med. Surg. Hist. Reb.; Otis. | M. | Mid age | R. | Shot w'd of right side of neck and ear. | | | July 2, 1863. | July 12. |
| 500 | Parsons, 1846. | Am. Jr. Med. Sci., 1848, p. 330. | M. | 19 | | Pain in head. | 2 years. | | | |
| 501 | Partridge, 1864. | Lancet, Dec. 1864, p. 659. | M. | 21 | R. | Stab with knife; wound of left ex- ternal carotid. | 6 days. | | | |
| 502 | Patruban. | Allg. Wien. Med. Zeit., 1876, No. 48, 50; Am. Jr. Med. Sci., April, 1877. | F. | Girl | | Tic douleureux. | | | | |
| 503 | do. | do. | F. | 63 | R. | do. | | | | |
| 504 | do. | do. | M. | 41 | | do. | | | | |
| 505 | do. | do. | F. | 37 | L. | do. | | | | |
| 506 | do. | do. | M. | Y'g m'n | | do. | | | | |
| 507 | do. | do. | M. | | | do. | | | | |
| 508 | do. | do. | M. | | | do. | | | | |
| 509 | do. | do. | F. | | | do. | | | | |
| 510 | Pauli? Butcher? Geigens? | Schmidt Jahrb. No. 134, p. 338. | M. | 23 | ? | Shot wound of oc- cipital artery. | 14 days. | | | |
| 511 | Parker, Prof. Willard, 1848. | From notes of cases kindly furnished author by Prof. Parker. | M. | | L. | Epilepsy. | | Above omo- hyoid. | | |
| 512 | do. 1851. | do. | M. | 17 | R. | Fibroid tumor of nose. | | do. | | |
| 513 | do. 1854. | do. | M. | 15 | R. | Malign. tumor of face. | | do. | | |
| 514 | do. | do. | M. | 45 | L. | Malign. dis. an- trum. | 6 mos. | do. | | |
| 515 | do. | do. | M. | 45 | R. | do. | 7 mos. | do. | | |
| 516 | do. 1855. | do. | M. | 50 | L. | Hem. ext. caro- tid. | | Below omo- hyoid. | | |

Common Carotid Artery—continued.

| No. | Date of operation. | Hemorrhage occurred after op. | Lig. came away No. days aft. op. | RESULT. | | | REMARKS. |
|-----|--------------------|-----------------------------------|----------------------------------|------------|--------------------------|--------------------------------|-------------------------------------------------------------------------------------------------------------------------------------------------------------------------------------------------------------------------------------------------------------------|
| | | | | Condition. | Recovery. | Cause of death, days after op. | |
| 496 | Oct. 21, 1864. | | | | | Next day. (?) | |
| 497 | June, 1861. | | | Recovered. | | | 13 days after operation patient was "sitting up" in the hospital ward, in every way doing well. |
| 498 | 1820. | | | | | 3d day. | |
| 499 | July 13, 1863. | After. | | | | Next day. Hem. | Autopsy: Ball lodged against atlas, which latter was fractured and pressed against vertebral artery; internal carotid cut almost in two at canal; medulla uninjured. |
| 500 | 1846. | | | Recovered. | No better. | | Improved at first; soon as painful as ever; died in few months of malady. |
| 501 | April 8, 1864. | 10th day. | 11 | | | 29th day. Œdema of glottis. | Wound behind angle of jaw; hemorrhage ceased after ligature; April 26th rigors. Autopsy: Œdema glottidis; congestion of lungs; large abscess behind jaw. |
| 502 | | | | Recovered. | Cured. | | No recurrence in 6 years. |
| 503 | | | | Recovered. | (Partial not permanent.) | | Relapse into previous condition after 4 years. |
| 504 | | | | Recovered. | Cure for 8 months. | | Cessation of pain for 8 months, then return of malady. |
| 505 | | | | Recovered. | (?) | | Died two years after last operation from carcinoma; neurectomy had been performed 14 years before, giving relief to near date of ligature. |
| 506 | | | | Recovered. | No benefit. | | Disease relapsed. |
| 507 | | | | Recovered. | Benefit temporary. | | Relapsed in 11 months (this man was playing cards in a café six hours after this ligature was applied). |
| 508 | | | | | | Died. Pyæmia. | |
| 509 | | | | Recovered. | Cured. | | Resection of the nerve had been twice performed with only temporary relief; slight cerebral symptoms for some weeks; passed off. |
| 510 | | | | Recovered. | Cured. | | |
| 511 | Nov. 8, 1848. | 29th day, controlled by pressure. | 13 | Recovered. | Greatly improved. | | Patient had been trephined by Prof. P., and a depressed spiculum of bone removed. Improved after this for a time, when attacks recurring the carotid was tied. Patient removed to a farm, the epilepsy ceased and he died of some other affection 27 years later. |
| 512 | July, 1851. | None. | | Recovered. | Much benefited. | | Patient seen nine years later; was very comfortable. |
| 513 | April 15, 1854. | do. | 13 | Recovered. | Not cured. | | Patient survived op. some time. Removed to country, where he died. (Disease returned.) |
| 514 | May 6, 1854. | do. | 23 | Recovered. | No benefit. | | Patient died about 5 months after op. from hemorrhage and exhaustion, the two vessels ligatured having an interval of 32 days. |
| 515 | Jan. 7, 1854. | 10th day. | 14 | Recovered. | No benefit. | | |
| 516 | Jan. 3, 1855. | None. | 13 | Recovered. | Cured. | | Internal carotid was tied same time, as the hem. was not entirely arrested by the 1st op. The ulceration was due to the corrosive application of a quack. |

Surgical History of the

| No. | Name of operator. | Source of information. | PATIENT. | | | Cause of operation. | Duration of cause. | Point of deligation. | Date of injury. | Date of hemorrhage. |
|-----|----------------------------------------|------------------------------------------------------------------|----------|----------|-------|------------------------------------------------------|---------------------|----------------------|-----------------|---------------------|
| | | | Sex. | Age. | Side. | | | | | |
| 517 | Parker, Prof. Willard, 1856. | From notes of cases kindly furnished by Prof. Parker. | M. | 50 | R. | Traum. aneur. ext. carotid. | | Above omohyoid. | | |
| 518 | do. 1852. | do. | M. | 44 | R. | Malig. dis. ant. | | do. | | |
| 519 | do. 1857. | do. | F. | 4½ | L. | Erect. tum. face | 4½ y'rs. | do. | | |
| 520 | do. 1861. | do. | F. | 10 mos | R. | Extensive vasc. tum. face. | 10 months. | do. | | |
| 521 | do. | do. | F. | 60 | R. | Malig. tum. antrum. | | do. | | |
| 522 | do. 1864. | do. | M. | 33 | L. | Malig. dis. antrum. | 2½ years. | do. | | |
| 523 | do. * | do. | M. | 38 | R. | do. | do. | do. | | |
| 524 | Pearce, H., 1863. | Med. Surg. Hist. Reb.; Otis. | M. | Mid age | R. | Shot wound inf. max. and throat. | | | Nov. 14. | Dec. 3. |
| 525 | Pearse, G. E. L., 1871. | Lancet, March 16, 1872. | M. | 55 | R. | Hem.; carcin. tongue. | Hem.; several days. | omohyoid. | | |
| 526 | Peace, 1844. | Norris Contrib. | M. | 22 | R. | Hem.; ulcer of jaw. | | | | |
| 527 | Peixoto, 1851. | Arch. Klin. Chir., 1868. | M. | 33 | R. | Tum. of ear. | | Low down. | | |
| 528 | Peck, O. W., 1834, U. S. A. | Med. Surg. Hist. Reb.; Otis. | M. | Mid age | L. | Shot wound left side face. | | At omohyoid. | June 19. | |
| 529 | Perry, 1820. | Norris Contrib. | M. | 30 | R. | Aneurism. | 2 years. | | | |
| 530 | Pétréquin, 1845. | do. | M. | 22 | L. | Erect. tum. orbit. | 5 mos. | | | |
| 531 | Peugnet, E., 1861. | N. Y. Med. Record, Jan. 29, 1876, p. 81. | M. | | L. | Shot wound left antrum. | | | July 21, 1861. | July 24, 27. |
| 532 | Piqué-Dupuytren (San Francisco), 1872. | Pacific Med. & Surg. Jr., Aug. 1872; N. Y. Med. Rec., Dec. 1872. | M. | 44 | R. | Aneur. carotid. | | Low down. | | |
| 533 | Pirogoff, 1843. | Arch. Klin. Chir., 1868. | M. | 20 | L. | Hem.; aneurism anast. of occipital and temp. region. | | | | |
| 534 | do. 1844. | do. | M. | 20 | R. | do. | | | | |
| 535 | do. 1837. | Norris Contrib. | | 9 mos | L. | Erect. tum. occiput. | 9 mos. | | | |
| 536 | do. | Arch. Klin. Chir., 1868. | M. | Mid age. | L. | Hem.; aneurism anast. | | | | |
| 537 | do. | do. | M. | | | Shot wound (military). | | | | |
| 538 | do. | do. | M. | | | do. | | | | |
| 539 | do. | do. | M. | | | do. | | | | |
| 540 | do. | do. | | C'd. | L. | Hem.; aneurism anast. | | | | |
| 541 | do. | do. | M. | | R. | Hem. facial artery; remov. encephaloma parot. | | | | |

Common Carotid Artery—continued.

| No. | Date of operation. | Hemorrhage occurred after op. | Lig. came away No. days aft. op. | RESULT. | | | REMARKS. |
|-----|--------------------|-------------------------------|----------------------------------|------------|-----------------------|--------------------------------|------------------------------------------------------------------------------------------------------------------------------------------------------------------------------------------------------------------------------------------------------------------------------------------------------------------------------------------------------------------------------------------------------------------------------------------------------------------|
| | | | | Recovery. | Condition. | Cause of death, date after op. | |
| 517 | May 8, 1856. | None. | | Recovered. | Cured. | | Punctured wound, fragment of iron. |
| 518 | Dec. 13, 1852 | do. | | | | Died. | Exhaustion. |
| 519 | April 6, 1857. | 18th day. | 21 | Recovered. | ? | | Died before separation of lig. Hem. on 18th day controlled by moderate pressure. |
| 520 | April 29, 1861. | None. | 12 | Recovered. | Cured. | | 3 years after op. patient was perfectly well. |
| 521 | May 29, 1861. | ? | | Recovered. | No benefit. | | Hospital patient; disease was not arrested; died some time after op. from return of the malignant affection. |
| 522 | Oct. 12, 1864. | None. | | Recovered. | Disease not arrested. | | Hospital patient; 2d ligature was not tightened until patient was from under the influence of the anæsthetic, and then with caution. Hem. 10-12th day, from blowing his nose; controlled by pressure; 2 weeks after last op. patient left for his home. Since finishing this paper I have another case in which Prof. Parker tied the common carotid and subclavian and vertebral at same time for subclavian aneurism. The patient died of hem. on the 42d day. |
| 523 | Nov. 9, 1864. | 12th day. | | Recovered. | Improved. | | |
| 524 | Dec. 3, 1863. | | | | | 5th day. | |
| 525 | 1871. | | 21 | | | 30th day. | Disease. |
| 526 | Nov. 8, 1844. | After. | 12 | | | 31st day. | Hem. |
| 527 | Nov. 14, 1851. | | | Recovered. | Cured. | | A temporary ligature was placed around the innominate as a precautionary measure, and removed. (This is given by some authors as lig. of innominate.— <i>Author</i> .) |
| 528 | July 6, 1864. | | | | | 6th day. | |
| 529 | Nov. 18, 1820. | 46th day. | 13 | Recovered. | Cured. | | Hem. after operation controlled by pressure. |
| 530 | June 5, 1845. | | | Recovered. | ? | | |
| 531 | July 27, 1861. | | | | | 11th day. | Exhaustion |
| 532 | 1872. | | 17 | Recovered. | Cured. | | |
| 533 | Jan. 16, 1843. | | 5 | Recovered. | Improved. | | At 6 years of age small tumor of scalp. In 1843, attempt to remove it resulted in such alarming hemorrhage, that P. tied carotid. Tumor not entirely disappearing by following year, remaining carotid tied. Tumor was then treated by compress and cured. |
| 534 | Jan. 9, 1844. | | 16 | Recovered. | Cured. (?) | | |
| 535 | Jan. 26, 1837. | (Occurred.) | | | | 117th day. | Hem. |
| 536 | | | | Recovered. | ? | | |
| 537 | | | | | | | Died. |
| 538 | | | | | | | Died. |
| 539 | | | | | | | Died. |
| 540 | | After. | | | | | Hem. |
| 541 | | | | Recovered. | | | Child was doing well; mother removed beyond reach of surgical interference when hem. occurred, causing death. |

Surgical History of the

| No. | Name of operator. | Source of information. | PATIENT. | | | Cause of operation. | Duration of cause. | Point of deligation. | Date of injury. | Date of hemorrhage. |
|-----|---------------------------------|--------------------------------------------------------------------------------------|----------|----------|-------|-----------------------------------------------------------------|--------------------------------------|----------------------|-----------------|---------------------|
| | | | Sex. | Age. | Side. | | | | | |
| 542 | Pirogoff, 1837. | Arch. Klin. Chir., 1868. | M. | Mid age. | R. | Aneur. innominate. | | | | |
| 543 | do. | do. | M. | Mid age. | R. | do. | | | | |
| 544 | do. | do. | M. | Mid age. | R. | do. | | | | |
| 545 | Pitha, 1840. | do. | M. | Old m'n | L. | Hem. mouth. | | | | |
| 546 | do. 1854. | do. | M. | 8 | L. | Prep. remov. sarcom. parotid. | | | | |
| 547 | Pope, Ch., 1860, St. Louis. | St. Louis Med. & Surg. Jr.; Am. Jr. Med. Sci., April, 1864, p. 556. | M. | | L. | Hem.; arrow wound. | 5 w'ks. | | | |
| 548 | Porter, 1829. | Norris Contrib. | F. | 40 | R. | Aneurism. | 15 y'rs. | | | |
| 549 | do. 1838. | do. | M. | 38 | L. | do. | 5 w'ks. | | | |
| 550 | Porta, 1842. | Arch. Klin. Chir., 1868. | F. | 60 | R. | Aneur. carotid; subelav. innom. | | | | |
| 551 | Post, Prof. A. C., N. Y., 1845. | Letter to author. | M. | 27 | R. | Telangiectasis right cheek. | Many years. | | | |
| 552 | do. | do. | F. | 55 | L. | Malig. dis. tonsil. | Some time. | | | |
| 553 | do. 1862. | do. | M. | 35 | R. | Shot wound ext. carotid, high up. | 24 hours. | | | |
| 554 | do. 1873. | do. | F. | 45 | L. | Prep. to remov. sup. max. | | | | |
| 555 | Post, Wright, 1813 or 1816? | V. Mott; N. Y. Med. Jr., July, 1857; Trans. Phys. Med. Soc., vol. 1; Norris Contrib. | M. | 35 | R. | Pulsat. tumor angle of jaw; aneur. | 10 mos. | | | |
| 556 | do.? | V. Mott; N. Y. Med. Jr., July, 1857. | F. | | | Gland. tum. neck; supposed aneurism. | | | | |
| 557 | Prichard, 1862. | Brit. Med. Jr., April 18, 1863. | M. | 39 | L. | Hem.; stab w'd carving-knife, vertebral artery. | 7 days. | | Aug. 23, 1862. | |
| 558 | Preston, 1830, East India. | Norris Contrib. | M. | 50 | R. | Hemiplegia of left side | 1 m'nth. | | | |
| 559 | do. 1831. | Lancet, 1831, vol. ii. p. 648. | M. | 25 | | Epilepsy. | 5 years. | | | |
| 560 | do. | Norris Contributions, etc. | M. | 51 | R. | Epilepsy and hemiplegia. | 6 years. Paralysis for last 20 days. | | | |
| 561 | do. | do. | M. | 51 | L. | do. | | | | |
| 562 | do. | do. | M. | 24 | R. | Paralysis, partial, left arm and leg; loss vision in right eye. | | | | |
| 563 | do. | do. | M. | 24 | L. | | | | | |

Common Carotid Artery—continued.

| No. | Date of operation. | Hemorrhage occurred after op. | Lig. came away, No. days at. op. | RESULT. | | | REMARKS. |
|-----|------------------------|-------------------------------|----------------------------------|------------|-----------------------|-------------------------------------|-------------------------------------------------------------------------------------------------------------------------------------------------------------------------------------------------------------------------------------------------------------------------------------------------------------------------------------------------------------------------------|
| | | | | Recovery. | Condition. | Cause of death, date after op. | |
| 542 | | | | Recovered. | Slight improvement | | |
| 543 | | | | Recovered. | do. | | |
| 544 | | | | | | 3 weeks. Cerebral complications. | Autopsy: One hemisphere softened partially. |
| 546 | 1840. | Once. | 17 | | | 19th day. Hem.; asphyxia. | Autopsy: Polypus in larynx. |
| 546 | | | 9 | Recovered. | ? | | |
| 547 | Sept. 16, 1860. | Occurred. | | Recovered. | Cured. | | The arrow was driven through left sup max. and was extracted with difficulty; 5 weeks later, on account of hem. the carotid was tied; the "unpleasant fulness" remained after recovery until death of the patient (Gen. Bayard) in the battle of Gettysburg, 3 years later. |
| 548 | Aug. 21, 1829. | | 19 | Recovered. | Cured. | | Sac burst about 4 months after ligature. |
| 549 | Sept. 22, 1838. | After. | 15 | | | 6 weeks. Hem. | |
| 550 | 1842. ? | | | | | 40 hours. | |
| 551 | April 1, 1845. | | | | | Died. Phlebitis; pyæmia, delirium. | Autopsy: Two phleboliths were found in tumor. Phlebitis of int. jugular, although vein was not wounded in the operation. Pus in vein. |
| 552 | 1845. | | | | | 3d day. Disease; cerebral complica. | Paralysis ensued. |
| 553 | 1862. | | | | | A few hours. Exhaustion. | Int. carotid also tied at same time; hem. arrested; patient exhausted by previous hem. |
| 554 | 1873. | | | Recovered. | Cured. | | No cerebral symptoms followed. |
| 555 | Jan. 9, 1813, or 1816. | | 16-18 | Recovered. | Cured. | | No cerebral symptoms noted. |
| 556 | | | | Recovered. | Temporary improvement | | Died 2 or 3 years later from irritation of larynx by pressure of tumor. Autopsy: Tumor was an enlarged gland and was resting on the carotid. |
| 557 | Sep. 5, 1862. | 8th, 14th, 15th day. | | | | 20th day. Hem. | Autopsy: Vertebral wound at edge of foramen magnum. |
| 558 | Nov. 22, 1830. | | 18 | Recovered. | | | |
| 559 | Feb. 4, 1831. | | 29 | Recovered. | | | April 13th, no return of attacks; patient much improved in general health. |
| 560 | Aug. 23, 1831. | | | Recovered. | Improved. | | On the 14th of Feb. 1832, he was again admitted in a state of insensibility and had been speechless for 14 days. Jan. 1833, suffering from paralysis agitans. |
| 561 | Nov. 14, 1831. | | | Recovered. | Not cured nor impr'd. | | |
| 562 | Sept. 2, 1831. | | | Recovered. | Improved temporarily | | 25 days after 1st operation, this man walked 5 miles; on account of heat (it is supposed) the disease returned, and the 2d operation was performed. Preston is accredited with one other case of double ligature for epilepsy, but I am of the opinion that it is a repetition of one of the cases here given, at least the comparison is suspicious and details are lacking. |
| 563 | Oct. 10, '31 | | | Recovered. | Improved. | | —Author. |

Surgical History of the

| No. | Name of operator. | Source of information. | PATIENT. | | | Cause of operation. | Duration of cause. | Point of deligation. | Date of injury | Date of hemorrhage. |
|-----|------------------------------------|---------------------------------------------------------------------|----------|----------------|-------|--------------------------------------------|--------------------|----------------------|----------------|------------------------------|
| | | | Sex. | Age. | Side. | | | | | |
| 564 | Randolph, 1833. | Norris Contrib. | M. | 25 | R. | Aneur. varix. | | | | |
| 565 | Ray, E. R., 1854. | Med. Times & Gaz., Feb. 1865, p. 171. | M. | 55 | L. | Hem.; malig. tumor. | 4 days. | | | 11th and 14th month. |
| 566 | Raynaud, 1871. | Gaz. des Hôp., 1871, p. 425. | M. | 25 | | Hem.; shot w'd neck; ext. or int. carotid. | 7 days. | | Nov. 30. | Dec. 6. |
| 567 | Remer (Breslau). | Arch. Klin. Chir., 1868. | F. | 50 or 60 | L. | Hem.; cancer of neck and face. | | | | |
| 568 | Reese D. M., 1823. | N. Y. Med. Jr., 1857; Jas. R. Wood. | | | | Rem. tum. neck. | | | | |
| 569 | Reyburn, Robt., 1866. | Am. Jr. Med. Sci., July, 1868. | M. | 25 | R. | Aneur. (near bifur. com. carotid). | | Below omo-hyoid. | | |
| 570 | Reynold, W. B., U. S. A., 1864. | Med. Surg. Hist. Reb.; Otis. | M. | | | Shot w'd mouth. | | Above omo-hyoid. | | |
| 571 | do. | do. | M. | | L. | Shot w'd neck. | | | Oct. 7. | Before operation, excessive. |
| 572 | Richard. | Arch. Klin. Chir. (cit.) | | | | Hem.; remov. tum. parotid; facial artery. | | | | |
| 573 | Richardson, W. F., 1865. | Med. Surg. Hist. Reb.; Otis. | M. | | L. | Shot w'd neck behind left ear. | | | | |
| 574 | Richet. | Ehrmann, de- effets; Arch. Klin. Chir., 1868. | | | | Shot w'd parotid region. | | | | |
| 575 | Richter. | do. | M. | 24 | L. | Hem. (after arano-plastic op.). | 12 ? | | | |
| 576 | Reed, F., 1854. | do. | M. | 52 | R. | Tumor neck and face. | | | | |
| 577 | Rigén, 1829, Amsterdam. | do. | | | R. | Innom. aneur., supposed. | | | | |
| 578 | Rivington, W., 1875. | Med. Chir. Trans., vol. lviii. | M. | 23 | L. | Intraorbital aneurism, traumatic. | 1 year. | | | |
| 579 | Robert, 1846 | Ehrmann, des effets, etc.; Arch. Klin. Chir (cit.). | F. | 19 | L. | Aneur., cirroid, frontal region. | 19 yrs. | | | |
| 580 | do. 1847. | do. | F. | 19 | R. | do. | 19½ years. | | | |
| 581 | do. 1857. | Arch. Klin. Chir., 1868. | M. | | L. | Aneur., cirroid. | | | | |
| 582 | Robbins, N. A., U. S. A., 1864. | Med. Surg. Hist. Reb.; Otis | M. | Mid age. | L. | Shot w'd near left ear. | | Below omo-hyoid. | Oct. 16. | Oct. 29. |
| 583 | Robertson, 1837. | Norris Contrib. | M. | 52 | R. | Aneurism. | 2 mos. | | | |
| 584 | Robinson. | Arch. Klin. Chir., 1868. | F. | 42 | R. | Hem. from abscess. | | | | |
| 585 | Rodgers, J. R., 1844. | Schmidt Jahrb., B. 98, S. 77; Archiv für Klin. Chir do. | F. | 11 | R. | Aneur. by anast., head. | | | | |
| 586 | (Van Buren, 1850.) | do. | F. | 17 | L. | do. | | | | |
| 587 | Rogers, D. L., 1832. | Norris Contrib. | | 8 mos | R. | Erect. tum face. | 8 mos. | | | |

Common Carotid Artery—continued.

| No. | Date of operation. | Hemorrh'ge occurred after op. | Lig. came away No. days aft. op. | RESULT | | | REMARKS. |
|-----|--------------------|-------------------------------|----------------------------------|------------|---------------------|-----------------------------------|---------------------------------------------------------------------------------------------------------------------------------------------------------------------------------------------------------------------------|
| | | | | Recovery. | Condition. | Cause of death, date after op. | |
| 564 | 1836. | | | | | Next day. Cerebral complications. | Coma soon after operation. |
| 565 | Nov. 14, 1864. | Dec. 2d. | | | | 17th day. Hem.; erysipelas. | Autopsy: No clot in the artery below ligature; no arteria innominate, the carotid and subclavian direct from the aorta. (I have never seen this anomaly.— <i>Author.</i>) |
| 566 | Dec. 6, 1871. | 2d & 3d days. | | | | 4th day. Exhaustion. | No cerebral symptoms; patient was transfused after suffering from severe hemorrhage, Dr. Raynaud, with generous devotion to duty, furnishing the blood from his own arm. |
| 567 | | None. | | | | 24 hours. Exhaustion and disease. | |
| 568 | 1823. | Profuse | | Recovered. | | | Actual cantery had to be used to arrest hem. after operation. |
| 569 | 1866. | | 12 | Recovered. | | | |
| 570 | Sept. 19, 1864. | | | | | 17th day. | |
| 571 | Oct. 9, 1864. | | | | | Next day. | Hemorrhage before operation had been very profuse. |
| 572 | | | | | | Next day. | |
| 573 | Feb. 22, 1865. | After. | | | | Same day. Exhaustion, hem. | Hemorrhage for 4 days before operation. |
| 574 | | | | Recovered. | Cured. | | |
| 575 | Nov. 20, 1865. | | | | | 2d day. Cerebral complications. | Autopsy: No thrombi in artery; brain œsmic. |
| 576 | May 31, 1854. | | | | | 8th day. | 7th day, paralysis of right leg. Autopsy: Extravasation of blood at base of brain. |
| 577 | Feb. 21, 1829. | | | Recovered. | Cured. | | Patient died of another disease 4 months later: tumor was on arch of aorta, was diminished in size, hard, and filled with a firm coagulum. Patient was operated upon for hernia in May, about one month before his death. |
| 578 | 1875. | | | Recovered. | Cured. | | No cerebral symptoms. |
| 579 | June 5, 1846. | | 19 | Recovered. | | | Slight cerebral symptoms followed each operation, but passed away. |
| 580 | Feb. 22, 1847. | | 18 | Recovered. | Marked improvement. | | In May, 1850, there was no pulsation in the tumor. |
| 581 | 1857. | | | | | A few days. | |
| 582 | Oct. 29 1864. | | | | | 4th day. | |
| 583 | March 21, 1837. | | 17 | Recovered. | Cured. | | |
| 584 | | | | | | 4th day. Exhaust'n. | |
| 585 | 1844. | | | Recovered. | Not cured. | | Temporal artery was also tied. |
| 586 | 1850. | | 14 | Recovered. | Not cured. | | See Van Buren. |
| 587 | Dec. 12, 1832. | | | Recovered. | Cured. | | |

Surgical History of the

| No. | Name of operator. | Source of information. | PATIENT. | | | Cause of operation. | Duration of cause. | Point of deligation. | Date of injury. | Date of hemorrh. &c. |
|-----|---------------------------|--------------------------------------------------------|----------|-------|-------|-------------------------------------------------------|--------------------|----------------------|-----------------|----------------------|
| | | | Sex. | Age. | Side. | | | | | |
| 606 | Santesson, 1853. | Arch. Klin. Chir., 1868. | F. | 18 | R. | Rem. parotid tumor. | 12 y'rs. | | | |
| 607 | Savory, 1871. (?) | Lancet, Sept. 30, 1871. | M. | 40 | R. | Hem. (after opening "sanguineous tumor of neck"). | A few minutes. | | | |
| 608 | Sédillot, 1842. | Norris; Ehrmann (cit.). | M. | 19 | R. | Hem. w'nd ext. carotid. | 13 days. | | | |
| 609 | do. 1848. | Ehrmann des effets. | M. | 25 | L. | Rem. parotid. | | | | |
| 610 | Sisco, 1829. | Norris; Ehrmann. | M. | 17 | L. | Aneurism, traum. | 3 w'ks. | | | |
| 611 | Solly, 1862 (& Garroway). | Brit. Med. Jr., 1862, p. 489. | M. | 34 | L. | Wound face and temporal region; thrown from carriage. | | | May 9, 1862. | |
| 612 | do. 1853. | Lancet, 1853, vol. ii. p. 566; 1854, vol. i. p. 91. | M. | 60 | L. | Aneur. carotid (at bifurcation). | 1 m'nth. | | | |
| 613 | South, 1856. | Med. Times & Gaz., August, 1856, vol. ix. p. 441. | F. | 48 | R. | Aneur. ext. carot. | | | | |
| 614 | do. ? | Arch. Klin. Chir. (cit.). | | | | Aneur. vertebral (supposed carotid). | | | | |
| 615 | Southam, 1864. | Med. Chir. Trans., vol. xlviii. p. 65. | F. | 28 | R. | Aneur. by anast. head. | 8 years. | | | |
| 616 | Surrage, James, 1840. | Lond. Med. Gaz., vol. xxviii. p. 392. | M. | 19 | L. | Aneur. int. max.? | | | | |
| 617 | Sykes, 1821. | Norris Contrib.; Lond. Med. Gaz., vol. xxviii. p. 392. | F. | 18 | R. | Aneur. carotid, traum. | 3 years. | | | |
| 618 | Syme, 1832. | do. | M. | 9 | R. | Hem. ear and mouth. | | | | |
| 619 | do. 1835. | Arch. Klin. Chir., 1868. | M. | 43 | R. | Aneur. carotid, traum. | 7 mos. | | | |
| 620 | do. 1842. | Norris; Ehrmann. | F. | 60 | | Aneur. int. carotid. | 5 mos. | | | |
| 621 | do. 1859. | Arch. Klin. Chir., 1868. | | 20 | L. | Aneur. carotid, traum. | 7 w'ks. | | | |
| 622 | do. 1860. | do. | F. | 22 | R. | Aneur. orbit, spont. | | | | |
| 623 | do. | Brit. Med. & Surg. Jr., 1848. | M. | Y'g | R. | Abscess of neck (supposed aneurism). | | | | |
| 624 | Schiess, Gemuseus, 1868. | Schmidt Jahrb., No. 146. | F. | 40 | L. | Orbital aneur., traum. | 1 year. | | | |
| 625 | Schort, 1857. | Arch. Klin. Chir., 1868. | M. | 34 | R. | Aneur. ext. carotid. | 8 years. | | | |
| 626 | Scarpa, 1828. | Norris Contrib. | F. | 29 | R. | Aneur. carotid. | | | | |
| 627 | Schrader, 1820. | Arch. Klin. Chir., 1868. | M. | 22 | L. | do. | 3 years. | | | |

Common Carotid Artery—continued.

| No. | Date of operation. | Hemorrhage occurred after op. | Lig. came away No. days aft. op. | RESULT. | | | REMARKS. |
|-----|--------------------|-------------------------------|----------------------------------|------------|------------|-----------------------------------------|-------------------------------------------------------------------------------------------------------------------------------------------------------------------------------------------------------------------------------------------------------------------------------------------------------------------------|
| | | | | Recovery. | Condition. | Cause of death, date after op. | |
| 606 | Nov. 14, 1853. | None. | 7 | Recovered. | Cured. | | The internal carotid was torn in two; ligature to common carotid increased the hem., and ligature <i>en masse</i> was applied. 1½ year later patient was well, although the tumor was not entirely removed at above operation. Internal and external carotids must have been included in the ligature <i>en masse</i> . |
| 607 | | | | | | Next day. Exhaustion. | Patient had lost 3 pints of blood. |
| 608 | April, 1842. | | | | | 9th or 10th day. | Hemiplegia, 3 hours after operation, of left side of body, right side face. Autopsy: Softening of right anterior lobe. |
| 609 | 1848. | 8th day. | | | | 14th day. Cerebral complications. | 5th day abundant hemorrhage; 12th day right hemiplegia. Autopsy: Left hemisphere softened and purulent; right congested. |
| 610 | | | 14 | Recovered. | Cured. | | Patient lost the use of left eye, and hearing of same side impaired. |
| 611 | May 23, 1862. | 11th day | | | | 11th day. Complications and hem. | Patient shaved himself on 7th day; paralysis of right side before death; unconsciousness. Autopsy: Carotid closed by thrombus. |
| 612 | Oct. 22, 1853. | Once. | | | | 29th day. Hem.; cerebral complications. | 23d day suffocation, sac opened; 26th day hem. and paralysis of left arm. |
| 613 | July 5, 1846. | | | | | 3d day. (?) | After ligature partial paralysis of left side. |
| 614 | | After. | 14 | | | 14th day. Hem.; asphyxia. | After ligature tumor rapidly increased; burst 14th day in trachea. Autopsy: Aneurism was between trans. proc. 4th and 5th cervical vert. |
| 615 | May 20, 1844. | | 14 | Recovered. | Cured. | | No anæsthetic; ulcerated, and hemorrhage before operation. |
| 616 | Oct. 28, 1840. | 3d day. | | Recovered. | Cured. | | Sac suppurated. |
| 617 | June 20, 1821. | | 10 | Recovered. | Cured. | | 2 lig. of catgut; artery divided between them. |
| 618 | Sept. 1832. | 5th day. | | Recovered. | Cured. | | |
| 619 | Feb. 18, 1835. | | 21 | Recovered. | Cured. | | |
| 620 | April, 1842. | | | | | 30 hours. | Syme could give no reason for death. |
| 621 | June 17, 1859. | | 10 | Recovered. | Cured. | | Method of Antyllus. |
| 622 | July 3, 1860. | | 14 | Recovered. | Cured. | | |
| 623 | | Once, fatally. | | | | Died. Hem. | The tumor was found to be a cyst in intimate relation with the sheath of the carotid. Strange to say, it diminished notably in size after operation. |
| 624 | June 15, 1868. | Several times. | 22 | Recovered. | No better. | | Patient was kicked by a horse. Attempt to tie the remaining carotid some months after was abandoned on account of hemorrhage. |
| 625 | Nov. 5, 1857. | | 11 | Recovered. | Cured. | | |
| 626 | May 23, 1828. | | 21 | Recovered. | Cured. | | |
| 627 | Nov. 14, 1820. | | 26 | Recovered. | Not cured. | | |

Surgical History of the

| No. | Name of operator. | Source of information. | PATIENT. | | | Cause of operation. | Duration of cause. | Point of deligation. | Date of injury. | Date of hemorrhage. |
|-----|----------------------------------|-----------------------------------------------------------------|----------|-------|-------|---------------------------------------------|--------------------|----------------------|-----------------|--------------------------------|
| | | | Sex. | Age. | Side. | | | | | |
| 628 | Schuh, 1848. | Arch. Klin. Chir., 1868. | M. | 18 | R. | Shot w'd of facial. | 1 m'nth | | | 5th day before, and day of op. |
| 629 | do. 1856. | do. | F. | 21 | R. | Hem. int. max. | | | | |
| 630 | do. 1864. | do. | M. | 17 | L. | Secondary hem. (internal maxillary). | 1 day. | | | |
| 631 | Schwartz, 1844. | do. | M. | | L. | Shot wound. | | | | |
| 632 | do. 1850. | do. | M. | | R. | do. | | | | |
| 633 | Scott, 1834. | Med. Chir. Trans., vol. xxii. p. 134; rep. by Geo. Busk. | M. | Boy | R. | Hem. from nose; exophthalmos. | | | | |
| 634 | do. 1832. | Norris Contributions; Ehrmann. | M. | 45 | R. | Remov. tumor face. | 4 mos. | | | |
| 635 | Smith, J. A., 1865. | Med. Times & Gaz., April 8, 1835, p. 358. | M. | 18 | R. | Hem. int. carotid. | 5 days. | | | |
| 636 | Smith, Prof. Stephen, 1876. | N. Y. Med. Jr., June, 1876. | M. | | L. | Cancerous tumor inf. max. | | Above omohyoid. | | |
| 637 | do. 1857. | N. Y. Med. Jr., July, 1857. | F. | 53 | L. | To arrest malign. disease left sup. max. | | | | |
| 638 | Smyth, A. W., New Orleans, 1864. | New Orleans Med. Press, May, 1866; Guy's Hosp. Rep., vol. xvii. | M. | 33 | R. | Aneur. subclavian. | | | | |
| 639 | Spence, 1869. | Schmidt Jahrb., No. 144, p. 87. | | | | | | | | |
| 640 | do. 1842. | Norris Contrib. | M. | 38 | L. | Hem. ulcerat. face. | | | | |
| 641 | do. | Arch. Klin. Chir., 1838. | | | | (Suicidal stab w'd carotid at bifurcation.) | | | | |
| 642 | do. 1865. | do. | M. | | R. | Aneur. carotid. | 35 days. | | | |
| 643 | Shipman, 1844. | Am. Jr. Med. Sci., July, 1847, p. 264. | F. | 70 | R. | Prep. remov. parotid. | 4 years. | | | |
| 644 | Stande, 1861. | do. | F. | 50 | R. | Remov. parotid. | 2 years. | | | |
| 645 | Stedman, 1830. | Norris Contrib. | M. | 58 | R. | Parotid tumor. | 12 y'rs. | | | |
| 646 | Stevens, 1826. | New York Med. Phys. Jr., vol. v. p. 311. | M. | 60 | L. | Remov. tumor. | | | | |
| 647 | Stanley, 1859. | Arch. Klin. Chir. (cit.). | M. | 24 | L. | Hem. after puncture of tonsil. | | | | |
| 648 | Stromeyer. | do. | M. | | R. | Stab wound. | | | | |
| 649 | do. | do. | M. | | | Shot wound maxillary interna. | | | | |
| 650 | Szokalsky, 1864. | do. | M. | 50 | L. | Aneur. orbit, traum. | | | | |

Common Carotid Artery—continued.

| No. | Date of operation. | Hemorrhage occurred after op. | Lig. came away No. days aft. op. | RESULT. | | | REMARKS. |
|-----|--------------------|-------------------------------|----------------------------------|------------|------------|-----------------------------------|--------------------------------------------------------------------------------------------------------------------------------------------------------------------------------------------------------------------------------------------------------------------------------------------|
| | | | | Recovery. | Condition. | Cause of death, date after op. | |
| 628 | Nov. 14, 1848. | | | | | 8th day. Cerebral complications. | 3d day after operation, paralysis of left side; 4th, coma. Autopsy: Pleura and lungs congested; right hemisphere softened. |
| 629 | Dec. 5, 1856. | | 35 | Recovered. | | | After lig. of common carotid 1½ inch of the jaw was resected, and the int. maxillary tied. Patient died 3 months later from necrosis of vertebral column and tuberculosis. (The first operation was made to arrest hemorrhage caused by trephining jaw in neurotomy for facial neuralgia.) |
| 630 | July 26, 1864. | | 16 | Recovered. | Cured. | | Paralysis of right side day after operation with aphasia. 1½ yr. after operation all unpleasant symptoms had disappeared except difficulty of motion in right leg. |
| 631 | May 4, 1849. | | 28 | Recovered. | Cured. | | No cerebral symptoms of note. |
| 632 | 1850. | | | Recovered. | Cured. | | No cerebral symptoms of note. |
| 633 | Nov. 10, 1834. | | | Recovered. | Cured. | | Fell through a ship's hold; 38th day after accident hem. from nose and protrusion of eye; hem. was arrested and the existing exophthalmos disappeared; loss of vision. |
| 634 | Feb. 4, 1832. | | | | | 42 hours. Convulsions. | |
| 635 | Feb. 11, 1865. | | | | | In a few hours. ? | |
| 636 | 1876. | | 14 | Recovered. | Not cured. | | Carbolized catgut lig. Tumor continued to grow. |
| 637 | April 24, 1857. | | 20 | Recovered. | Not cured. | | |
| 638 | May 15, 1864. | | 13 | Recovered. | Cured. | | The innominate and carotid were tied at same operation. 54 days later the vertebral was tied. (Died 10 years later of same aneurism.) |
| 639 | 1869. | | | | | 4th day. Coma. | Carbolized catgut lig. 30 hours after operation paralysis ensued. Autopsy: The lig. was found to have slipped, and it was thought the renewed current had washed the plug in the vessel into the cerebral circulation. |
| 640 | May 24, 1842. | | | | | 61st day. Exhaustion. | No cerebral symptoms noted. |
| 641 | | | | | | 10th day. Pyæmia. | The internal jugular vein was ligatured at same time. |
| 642 | July 25, 1865. | 12th after. | | | | 19th day. Hem. | |
| 643 | May, 1844. | | 28 | Recovered. | Not cured. | | Disease returned, and patient died in 2 years. |
| 644 | | | | Recovered. | ? | | |
| 645 | Sept. 7, 1830. | | 26 | Recovered. | Cured. | | |
| 646 | June 3, 1826. | | 14 | Recovered. | Cured. | | Internal jugular vein tied same time. |
| 647 | Oct. 24, 1854. | 27th day hem. | 14 | | | 61 days. Cerebral complications. | Hemiplegia on 31st day; abscess and softening of left hemisphere. |
| 648 | | After. | | | | Died instantly. Hem.; exhaustion. | |
| 649 | | After op. | | | | Died. Hem. | |
| 650 | 1864. | | | Recovered. | Cured. | | No cerebral symptoms. |

Surgical History of the

| No. | Name of operator. | Source of information. | PATIENT. | | | Cause of operation. | Duration of cause. | Point of deligation. | Date of injury. | Date of hemorrhage. |
|------------------|--------------------------------------------|--------------------------------------------------------------|--------------------------|----------|-------|-------------------------------------------|------------------------------------------|----------------------|-----------------|---------------------|
| | | | Sex. | Age | Side. | | | | | |
| 651 | Textor, 1826. | Ehrmann des effets, p. 38; Arch. Klin. Chir., 1868. | M. | 40 | L. | Knife wound ext. carotid. | 12 days. | | | |
| 652 | Tilanus. | Velpeau; Ehrmann des effets, p. 38; Arch. Klin. Chir., 1868. | | | | Aneur. aorta (supposed carotid). | | | | |
| 653 | Tyerman, 1834. | Norris Contrib. | M. | 35 | R. | Wound of throat. | | | | |
| 654 | Todd, G. R. C., 1876 (South Carolina). | Am. Jr. Med. Sci., July, 1877, p. 112. | M. | 25 | L. | Aneur.; pistol shot wound at bifurcation. | Of w'd, 17 days; of aneur., 2-4 4 hours. | Below omohyoid. | | |
| 655 ^a | Von Thaden, 1864. | Arch. Klin. Chir., 1868. | M. | 22 | R. | Stab wound. | | | | |
| 656 | do. 1836. | do. | F. | 66 | R. | Hem. after resect. of nerve (max. int.). | | | | |
| 657 | Thebaud, J. S., 1865. | Letter from Dr. J. B. Reynolds, with Dr. Thebaud's notes. | | 6 mos | | Aneur. anast. face and eye. | | | | |
| 658 | Travers, 1815. | Norris Contrib.; Archives, etc. | M. | | R. | Hem. fung. tumor of cheek. | | | | |
| 659 | do. 1826. | do. | M. | 35 | R. | Knife wound ext. carot. | Short while. | | | |
| 660 | do. 1809. | Med. Chir. Trans., vol. ii. p. 1. | F. | 34 | L. | Erectile tumor orbit. | $\frac{1}{4}$ y'rs. | | | |
| 661 | Trier, 1834. | Arch. Klin. Chir., 1838 (cit.). | M. | | | Knife wound sup. thy. | | | | |
| 662 | Triboli, 1845. | do | M. | 27 | R. | Knife wound. | 10 days. | | | |
| 663 | Tschansoff, 1867. | Arch. Klin. Chir., Bd. xi. p. 203. | F. | 50 | R. | Epithel. tum. of carot. | 5 years. | | | |
| 664 | do. | Arch. Klin. Chir., p. 204. | M. | 60 | | Epithel. cancer lower jaw and mouth. | | | | |
| 665 | do. | do. | | | | | | | | |
| 666 | Twitchell, 1807. | Norris; Arch. Klin. Chir. (cit.). | M. | 20 | R. | Shot wound int. carotid (neck and face). | 10 days. | | | |
| 667 | { Unknown, 1823. Ullman, 1824. | Arch. Klin. Chir. | M. | 19 | L. | Erectile tumor in region of left ear. | | | | |
| 668 | | do. | do. | M. | 20 | R. | do. | | | |
| 669 | { Unknown, do. (Crimea). Unknown, 1864. | Norris Contrib. | F. | | | Aneur.; face w'd. | 6 w'ks. | | | |
| 670 | | do. | Arch. Klin. Chir., 1868. | M. | | | Hem.; shot wound external carotid. | | | |
| 671 | Unknown, 1864. | Med. Surg. Hist. Reb.; Otis. | M. | Mid age. | | Shot wound lower jaw. | | | | |
| 672 | do. | do. | M. | do. | R. | do. | | | | |
| 673 | do. 1863. | do. | M. | do. | R. | do. | | | | |
| 674 | do. 1864. | do. | M. | do. | L. | Shot wound face. | | | | |
| 675 | do. 1862. | do. | M. | do. | | Shot w'd mouth. | | | | |
| 676 | do. 1863. | do. | M. | do. | R. | Shot wound lower jaw. | | | | |
| 677 | do. 1864. | do. | M. | do. | R. | Shot wound face (right). | | (Near bifur.) | June 19. | July 1. |
| 678 | do. | do. | M. | do. | | Shot wound face. | | | | |
| 679 | do. 1863. | do. | M. | do. | L. | Shot wound inf. max. | | Above omohyoid. | | |
| 680 | do. | do. | M. | do. | | Shot wound sup. max. | | | | |
| 681 | do. 1864. | do. | M. | do. | R. | Shot wound face. | | Below omohyoid. | | |
| 682 | do. 1863. | do. | M. | do. | L. | Shot wound left mastoid process. | | Above omohyoid. | | |
| 683 | do. | do. | M. | | | Shot wound inf. max. | | | Dec. 30, 1862. | |

Common Carotid Artery—continued.

| No. | Date of operation. | Hemorrh'ge occurred after op. | Lig. came away No days aft. op. | RESULT. | | | REMARKS. |
|-----|--------------------|-------------------------------|---------------------------------|------------|---------------------------|-----------------------------------|------------------------------------------------------------------------------------------------|
| | | | | Recovery. | Condition. | Cause of death, date after op. | |
| 651 | May, 10, 1826. | 9th day. | 13 | | | 30th day. Cerebral complications. | 23d day, paralysis of right side. Autopsy: abscess in left hemisphere. |
| 652 | | | | Recovered. | | | Patient died suddenly 5 months later. Autopsy: The aneurism of aorta was full of solid fibrin. |
| 653 | Aug. 14, 1834. | | 11 | Recovered. | Cured. | | |
| 654 | | | 45 | Recovered. | Cured. | | "Comparatively good health." Tumor long since disappeared. |
| 655 | Sept. 26, 1864. | | 16 | Recovered. | Cured. | | |
| 656 | Jan. 29, 1866. | | | | | 4½ days. | "Collapse and unconsciousness day after operation. Autopsy: Both hemispheres congested." |
| 657 | | | 10 | Recovered. | Not cured, but benefited. | | |
| 658 | Nov. 13, 1815. | | 15 | | | 16th day. Meningitis. | |
| 659 | Jan. 27, 1826. | 20th day and aft. | 13 | | | 58th day. Hem. | 19th day, patient was wild with delirium. |
| 660 | May 23, 1809. | | 21 & 22 | Recovered. | Cured. | | Two ligatures applied. |
| 661 | 1834. | | | | | 14th day. Tuberculosis. (?) | The trachea was also wounded. |
| 662 | 1845. | | 8 | Recovered. | Cured. | | |
| 663 | Oct. 1867. | | | | | 8th day. | Autopsy: No thrombus in central end, in distal small clot. |
| 664 | | | 14 | | | 20th day. | |
| 665 | | | | Recovered. | ? | | Died 3 mos. later of some other disease. |
| 666 | Oct. 18, 1807. | | 13 | Recovered. | Cured. | | |
| 667 | 1823. | | | Recovered. | Not cured. | | |
| 668 | 1824. | Twice. | | | | 3d day. Exhaust'n. | On account of hem. a second lig. had to be applied lower down. |
| 669 | | | 14 | Recovered. | Cured. | | |
| 670 | | | | | | 4 hours. Exhaustion. | Hem. ceased with application of ligature. |
| 671 | 1864. | | | Recovered. | | | "Disability ¼ and permanent, April, 1867." |
| 672 | July 8, 1864. | | | | | 2 days. | This artery was tied a second time. |
| 673 | June 7, 1863. | | | | | Next day. | |
| 674 | June 19, 1864. | | | | | 3 days. | |
| 675 | 1862. | | | Recovered. | ? | | |
| 676 | April 11, 1865. | | | Recovered. | ? | | |
| 677 | July 4, '64 | | | | | Died. 1st op. 2 days. | The same vessel was religatured on July 6, on account of hem. |
| 678 | " 6, " | | | | | 2d op. same day. | |
| 678 | June 23, 1864. | | | | | 2 days. | |
| 679 | July 18, 1863. | | | | | 8 days. | |
| 680 | June 7, 1863. | | | | | Same day. | |
| 681 | May 16, 1864. | | | | | Same day. | |
| 682 | Oct. 10, 1863. | | | | | 14 days. | |
| 683 | | | | | | Died Jan. 15, 1863. | |

Surgical History of the

| No. | Name of operator. | Source of information. | PATIENT. | | | Cause of operation. | Duration of cause. | Point of deligation. | Date of injury. | Date of hemorrhage |
|-----|-------------------------|-------------------------------------------------|----------|----------|-------|-----------------------------------------------------------------------------|--------------------|----------------------|-----------------|--------------------|
| | | | Sex. | Age. | Side. | | | | | |
| 684 | Unknown, 1864. | Med. Surg. Hist. Reb.; Otis. | M. | 22 | L. | Shot wound lower jaw. | | | May 10, 1864. | June 2. |
| 685 | do. | do. | M. | 21 | L. | Shot wound neck, internal and external carotid. | | | | |
| 686 | do. 1863. | do. | M. | Mid age | | Shot wound neck, high up. | | | | Just before op. |
| 687 | do. 1862. | do. | M. | do. | | Shot w'nd mouth and neck. | | | May 30. | |
| 688 | do. 1863. | do. | M. | do. | R. | Shot wound neck and face (r.) | | | May 3. | |
| 689 | | do. | M. | do. | | Shot wound neck and jaw. | | | April 12 | May 5. |
| 690 | } do. 1862. | do. | M. | do. | R. | Shot wound neck. | | | | |
| 691 | | do. | do. | M. | do. | L. | do. | | | |
| 692 | do. 1864. | do. | M. | | | Shot wound head and neck. | | | May 5. | May 12 to 21. |
| 693 | | do. | M. | | | | | | | |
| 694 | do. 1864. | do. | M. | 23 | R. | Shot wound fracture of right parietal bone cutting middle meningeal artery. | | | | |
| 695 | do. 1855 ? | Arch. Klin. Chir., 1868, 173. | | | | Hem. after remov. glands. | | | | |
| 696 | | do. 174. | M. | 35 | | Hem. of mouth. | | | | |
| 697 | | do. 306. | | | L. | Aneur., vertebral (supposed carotid). | | | | |
| 698 | | do. 442. | | | | Tumor (carcinoma) of temporal muscle; supposed aneurism. | | | | |
| 699 | do. Hôtel Dieu. | Madelung; Arch. Klin. Chir., Bd. xvii. p. 616. | M. | 20 | | Circoid aneurism of scalp. | | | | |
| 700 | Ure, 1859. | Lancet, 1859, vol. i. p. 559. | M. | 35 | L. | Hem. of mouth; fell with pipe-stem in mouth. | 7 hours. | Above omo-hyoid. | | |
| 701 | Valk, N. N., 1864. | Med. Surg. Hist. Reb.; Otis. | M. | 21 | R. | Shot wound; r. mastoid process. | | do. | Aug. 25. | Sept. 7. |
| 702 | Van Buren, W. H., 1849. | N. Y. Med. Jr., July, 1857, Prof. Jas. R. Wood. | F. | 40 | R. | Malignant disease of right nasal fossa. | | | | |
| 703 | do. 1850. | do. | F. | 17 | L. | Circoid aneurism of scalp. | | | | |
| 704 | do. 1854. | N. Y. Hosp. Notes, kindness Prof. H. B. Sands. | M. | 23 | L. | Aneurism of orbit, left traumatic. | | | | |
| 705 | do. 1852. | N. Y. Med. Jr., July, 1857, Prof. Jas. R. Wood. | F. | | | Hem. of external carotid; removal of parotid tumor. | | | | |
| 706 | do. 1857. | do. | M. | 25 | R. | Enceph. tumor of right orbit. | | | | |
| 707 | Vanzetti, 1865. | Arch. Klin. Chir., 1868. | M. | 60 | | Carotid aneurism. | | | | |
| 708 | Vansant, J., 1865. | Med. Surg. Hist. Reb.; Otis. | M. | Mid age. | L. | Shot wound left side of head. | | | Feb. 6. | Feb. 15. |
| 709 | Vargus, 1823. | Arch. Klin. Chir., 1868. | F. | 30 | L. | Aneur. carotid. | | | | |
| 713 | Velpeau, 1835. | Norris; Ehrmann; Arch. Klin. Chir., 1838. | M. | 16 | L. | Erectile tumor of temporal region. | | | | |

Common Carotid Artery—continued.

| No. | Date of operation. | Hemorrhage occurred after op. | Lig. came away No. days aft. op. | RESULT. | | | REMARKS. |
|-----|-------------------------------|-------------------------------|----------------------------------|------------|-----------------------|-----------------------------------|-------------------------------------------------------------------------------------------------------------------------------------------------------|
| | | | | Condition. | Recovery. | Cause of death, days after op. | |
| 684 | June 2, 1864. | | | | | Next day. | Internal jugular vein, being wounded in operation was also tied. The vessel was tied a second time on account of hem. 13 days after 1st operation. |
| 685 | June 19, 1864. July 3, '64 | July 2. | | | | 17 days after 1st op. | |
| 686 | | | | 19 | Recovered. | ? | |
| 687 | June 18, 1862. | | | | | Next day. | Lingual was also tied. |
| 688 | May 16, 1863. | | | | | 4 days. | Ball entered neck, right side, traversed antrum and out at nose. |
| 689 | May 5. (?) | | | | | Died May 15. | |
| 690 | May 17, '62 | | | | | Same day. | Details not given. |
| 691 | | | | | | Same day. | |
| 692 | | May 21, 1864. | | | | | |
| 693 | May 13, 1864. | After. | | Recovered | | | 13 days. Hem. |
| 694 | | | | | | | |
| 695 | | 30 days. | | Recovered. | Cured. | | Details not given. |
| 696 | | | | Recovered. | Cured. | | |
| 697 | | | | | | 20th day. | Paralysis of right arm resulted. Autopsy: Aneurism of vertebral between 2d and 3d cervical vert. |
| 698 | | | | | | | Died. (?) |
| 699 | | | | Recovered. | Improved. | | Temporal, auricular, and occipital tied at same time. |
| 700 | May 21, 1859. | 1st and 2d day, slight. | | Recovered. | Cured. ? | | No cerebral symptoms; symptoms were favorable on 31st ult. |
| 701 | Sept. 9, 1864. | | | | | 11th day. | Hemiplegia in 24 hours. Autopsy: Right hemisphere softened. |
| 702 | 1849. | | | | | 60 hours. Cerebral complications. | |
| 703 | 1850. | | 14 | Recovered. | Not cured. | | Disease latent; right carotid had been tied 6 years previously by Dr. J. K. Rodgers. No cerebral symptoms followed. |
| 704 | June 24, 1854. | | 15 | Recovered. | Not cured, but impr'd | | Bruit ceased but returned 18th day. 18 months later patient improved and condition good. Pressure on right carotid stops pulsation in tumor. |
| 705 | 1852. | | | Recovered. | Cured. | | Superior thyroid also tied |
| 706 | 1857. | | | | | 13th day. Pyæmia. | Pain ceased on tightening lig. Autopsy: Healthy clot in both central and distal ends; orbit and zygomatic fossa filled with cancerous matter. |
| 707 | 1865. | | | | | 8th day. | Hem. recurring same vessel was tied 6 days after 1st operation. |
| 708 | Feb. 15, '65. Relig. 21. | Once. | | | | Died { 10 days. 4 " hem. | |
| 709 | Aug. 18, 1823. | | | Recovered. | Cured. | | Internal carotid was also tied. |
| 710 | 1835. | Often. | | | | 16th day. Hem. | |

Surgical History of the

| No. | Name of operator. | Source of information. | PATIENT. | | | Cause of operation. | Duration of cause. | Point of deligation. | Date of injury. | Date of hemorrhage. |
|-----|-----------------------|------------------------------------------------------------|----------|----------|-------|--------------------------------------------------|--------------------|----------------------|-----------------|-----------------------|
| | | | Sex. | Age. | Side. | | | | | |
| 711 | Velpeau, 1839. | Norris Contrib.; Arch. Klin. Chir., 1868. | M. | 28 | R. | Aneur. orb., traum. (of both sides). | 6 mos. | | | |
| 712 | Verneuil, 1863. | Arch. Klin. Chir., 1868. | | 41 | | Prep. rem. recur. tumor of parotid. | | | | |
| 713 | do. 1871. | Gaz. des Hôp., 1871, p. 442; Lancet, Nov. 4, 1871, p. 644. | M. | 30 | R. | Hem. shot wound of cheek. | 21 days. | | May 23. | June 15-30 and after. |
| 714 | do. 1870. | Gaz. Hebdom., Nov. 10, 1876, p. 709. | M. | 32 | | Hem. following iliz. ext. carotid. | | | | |
| 715 | Vilardebo, 1847. | Arch. Klin. Chir., 1888. | M. | 70 | R. | Aneurism of carotid and innom. | | | | |
| 716 | Vincent, 1845. | Norris Contrib. | M. | 28 | R. | Hem. wound of tongue. | 8 days. | | | |
| 717 | do. 1829. | Norris Contrib.; Ehrmann (cit.). | M. | 48 | R. | Aneurism. | 8 mos. | | | |
| 718 | do. 1818. | Norris Contrib. | M. | 52 | R. | do. | 3 w'ks. | | | |
| 719 | Voisin. | Eve Collect. Remark. Cases; Arch. Klin. Chir. (cit.). | M. | | R. | Stab wound vertebral. | | | | |
| 720 | Wagstaffe, 1872. | Lancet, June, 1872. | | | | | | | | |
| 721 | Walton, 1851. | Med. Times & Gaz., 1854, vol. 1, p. 185. | F. | 5 mos | R. | Aneur. of orbit. | 3 mos. | | | |
| 722 | Walther, C., 1830. | Arch. Klin. Chir. (cit.). | M. | 29 | L. | Carotid aneurism. | | | | |
| 723 | Von Walther, P. | do. | M. | 38 | L. | Aneurism of ext. carotid. | | | | |
| 724 | Watson, J., 1853. (?) | N. Y. Med. Jr., July, 1857. | F. | Y'g | L. | Stab wound vertebral. | | | | |
| 725 | Warren, 1827. | Norris Contrib. (cit.). | M. | 42 | L. | Aneurism. | 4 years. | | | |
| 726 | do. 1830. | do. | F. | 18 | R. | Erect. tum. orbit. | | | | |
| 727 | do. 1845. | Am. Jr. Med Sci., April, 1845. | M. | 23 | L. | Erect. tum. mouth, face, neck. | | | | |
| 728 | do. | do. | M. | 23 | R. | do. | | | | |
| 729 | do. | | | | | | | | | |
| 730 | do. 1837. | Norris Contrib., etc. | M. | 52 | R. | Scirr. tum. neck. | 30 y'rs. | | | |
| 731 | do. 1836. | Arch. Klin. Chir., 1868. | F. | 45 | L. | Remov. tum. thyroid. | 2 years. | | | |
| 732 | do. 1827. | do. | M. | 60 | L. | Prep. removal of glands of neck for malign. dis. | 1 year. | | | |
| 733 | Wardrop, 1818. | Lancet, vol. xii. p. 394. | | 6 wks | L. | Erect. tum. cheek. | 6 w'ks. | | | |
| 734 | do. 1826. | Norris Contrib. | F. | 5 mos | L. | Erect. tum. face. | | | | |
| 735 | do. 1827. | Lancet, vol. xii. p. 762. | M. | 22 | L. | Erectile tum. face and head. | 12 y'rs. | | | |
| 736 | do. 1825. | Norris Contrib. | F. | 75 | R. | Carotid aneurism, low down. | | | | |
| 737 | do. 1826. | do. | | 57 | R. | do. | | | | |
| 738 | Wattman, 1825. | Ehrmann des effets; Arch. Klin. Chir. (cit.). | M. | 55 | R. | Tum. of submax. gland. | | | | |
| 739 | Webster, N., 1864. | Med. Surg. Hist. Reb.; Otis. | M. | Mid age. | | Shot w'nd (flesh) face. | | | May 8. | |
| 740 | Weber, C. O., 1853. | Arch. Klin. Chir., 1868. | M. | 63 | R. | Hem. after operation for extirp. | | | | |

Common Carotid Artery—continued.

| No. | Date of operation. | Hemorrhage occurred after op. | Lig. came away No. days aft. op. | RESULT. | | | REMARKS. |
|-----|--------------------|-------------------------------|----------------------------------|------------|------------|----------------------------------|-------------------------------------------------------------------------------------------------------------------------------------------------------------------------------------------------------------------------------------------------------------------------|
| | | | | Recovery. | Condition. | Cause of death, date after op. | |
| 711 | July, 1839. | | | Recovered. | Improved. | | Pressure of right carotid arrested pulsation in tumor of left orbit completely and lessened pulsation in that of right eye, and <i>vice versa</i> . After operation tumor of left side ceased to pulsate, and sight was diminished. 6 months later improved, not cured. |
| 712 | | | 20 | Recovered. | ? | | |
| 713 | July 2, 1871. | | | | | 42 hours. Coma. | Two ligatures to carotid; hemiplegia immediate. Autopsy: "Right hemisphere profoundly altered." (<i>Note</i> .—Ext. and int. carotid also tied in a single loop of ligature.) |
| 714 | Feb. 5, 1870. | | | | | Next day. | |
| 715 | | | | | | 21st day. | |
| 716 | April 16, 1845. | Once. | | | | 6th day. Hem. | |
| 717 | July 18, 1829. | | | | | 7th day. Cerebral complications. | Autopsy: Softening of right hemisphere. |
| 718 | Dec. 19, 1818. | | 22 | | | 33d day. Inflammation of sac. | |
| 719 | | | | | | Died. | |
| 720 | | | | | | | |
| 721 | June 5, 1851. | | 23 | Recovered. | Cured. | | No cerebral symptoms. |
| 722 | 1830. | | 14 | Recovered. | Cured. | | |
| 723 | | | | Recovered. | Cured. | | |
| 724 | | | | | | 3d day. Cerebral symptoms. | 2 days after operation paralysis (right); internal jugular vein was also tied. Autopsy: Brain softened. |
| 725 | Oct. 26, 1827. | | | Recovered. | Cured. | | |
| 726 | Jan. 2, 1830. | | | Recovered. | Cured. | | |
| 727 | Oct. 5, 1845. | | | Recovered. | No better. | | Tumor diminished about one-half after 1st ligature, but there was no positive improvement. |
| 728 | Nov. 9, 1845. | | | Recovered. | Improved. | | Tumor was afterwards treated by removing a portion and plunging needles into the remaining parts. Cured. |
| 729 | | | | | | | |
| 730 | March 7, 1837. | | | Recovered. | | | 7th day coma; paralysis of left arm, which disappeared. |
| 731 | Sept. 14, 1836. | | | Recovered. | ? | | |
| 732 | 1827. | | | Recovered. | | | Patient died 1 year later from return of disease. |
| 733 | 1818. | | | | | 14th day. Exhaustion. | Tumor ulcerated freely after operation. |
| 734 | March, 1826 | | 11 | Recovered. | Cured. | | |
| 735 | Oct. (?) 1827. | | 25 | Recovered. | Improved. | | Died 103 days after operation; psoas abscess. |
| 736 | June, 1825. | | | Recovered. | Improved. | | (<i>Distal</i> ') |
| 737 | | | | | | 23d day. | (<i>Distal</i> ') |
| 738 | 1825. | | | | | Died. Brain complications. | Day after operation paralysis of left side. |
| 739 | June 22, 1864. | | | | | 8 days. | |
| 740 | Nov. 11, 1833. | Twice. | 14 | | | 62d day. Hem. | |

Surgical History of the

| No. | Name of operator. | Source of information. | PATIENT. | | | Cause of operation. | Duration of cause. | Point of deligation. | Date of injury. | Date of hemorrhage. |
|-----|-----------------------------|-------------------------------------------------------|----------|------------|-------|---------------------------------------------------------------------|--------------------|-------------------------|--------------------|-------------------------|
| | | | Sex. | Age. | Side. | | | | | |
| 741 | Weber, G. C. E., 1857. | Am. Jr. Med. Sci., April, 1860, p. 374. | M. | 20 | L. | Epilepsy. | 5 years. | | | |
| 742 | do. | do. | M. | 20 | R. | do. | | | | |
| 743 | Weeker, 1868. | Schmidt Jahrb., No. 144, p. 200. | F. | 63 | L. | Pulsating tumor of left eye. | Several months. | | | |
| 744 | Weinlechner, 1861. | Arch. Klin. Chir., 1868. | F. | 40 | R. | Secondary hem. (facial). | Short time. | | | |
| 745 | do. 1863. | do. | F. | 4½ | R. | Hemorrhage. | 15 days. | | | |
| 746 | Weir, R. F., 1863. | Med. Surg. Hist. Reb.; Ois. | M. | Mid age | R. | Shot wound right sup. max. | | | Sept. 17 | Sept. 25. |
| 747 | do. 1864. | do. | M. | do. | L. | Shot wound inf. max. (lingual, vertebral, and oesophagus). | | | Aug. 25 | Sept. 3. |
| 748 | do. | do. | M. | do. | R. | Shot wound inf. max. | | Below omo- hyoid. | July 9. | July 19. |
| 749 | do. 1863. | do. | M. | do. | L. | Shot wound left side of neck. | | | Jan. 1. | Jan. 1 and after. |
| 750 | do. 1862. | do. | M. | do. | R. | Shot w'nd spinal cord and neck (aneurism). | | Below omo- hyoid. | About Sept. 24. | |
| 751 | do. 1863. | do. | M. | 25 | | Shot wound face. | | | July 3. | July 9. |
| 752 | do. 1876. | Letter to author. | | | R. | Innom. aneurism. | | | | |
| 753 | Wickham, 1829. | Norris Contrib. | M. | 55 | R. | Aneurism innom. | | | | |
| 754 | Williams, 1825. | Arch. Klin. Chir., 1868. | M. | | | Remov. tum. neck. | | | | |
| 755 | Williamme, 1829. | Norris Contrib.; Arch. Klin. Chir., 1868. | M. | 21 | L. | Fung. tum. temp. | | | | |
| 756 | Wood, Prof. J. R., 1839. | N. Y. Med. Jr., July, 1857, Prof. Jas. R. Wood. | F. | Mid age | L. | Suicide; knife wound of throat. | | | | |
| 757 | do. 1840. | do. | F. | 36 | R. | Aneur. carotid at bifurcation of innominate. | | Above omo- hyoid. | | |
| 758 | do. 1842. | do. | M. | 6 mos | R. | Aneur. anast. of cheek. | 6 mos. | do. | | |
| 759 | do. 1843. | do. | M. | 37 | R. | Epilepsy. | | | | |
| 760 | do. 1855. | do. | M. | 53 | R. | Malg. disease of antrum. | | Above omo-hy. | | |
| 761 | do. | do. | M. | 53 | L. | do. | | do. | | |
| 762 | do. 1847. | do. | M. | 36 | R. | Aneurism of ext. carotid. | | do. | | |
| 763 | do. 1854. | do. | M. | 23 | L. | Malg. disease of antrum. | | do. | | |
| 764 | do. | do. | M. | Mid age | L. | Malignant tumor of left jaw. | | Below omo-hy. | | |
| 765 | Woodward, A. T., 1860. | Letter to author. | F. | do. | L. | Aneur. anast. of left ext. carotid. | Some time. | | | |

Common Carotid Artery—continued.

| No. | Date of operation. | Hemorrh'ge occurred after op. | Lig. came away No. days aft. op. | RESULT. | | | REMARKS. |
|-----|--------------------|-------------------------------|----------------------------------|------------|-----------------------|--------------------------------|-------------------------------------------------------------------------------------------------------------------------------------------------------------------------------------------------------------------------------------------------------------------------------|
| | | | | Recovery. | Condition. | Cause of death, date after op. | |
| 741 | Dec. 2, 1857. | | 12 | Recovered. | | | Interval of 17 days between the 2 operations; 5 weeks after last operation no attack, but mind weaker. |
| 742 | Dec. 19, 1857. | | | Recovered. | Improved. | | |
| 743 | June 20, 1865. | | | | | 52 hours. | Paralysis of right side followed operation. |
| 744 | May 19, 1861. | | | | | 6 days. | |
| 745 | | | 8-9 | Recovered. | Cured. | | No cerebral symptoms. |
| 746 | Nov. 14, 1863. | | | Recovered. | (?) | | |
| 747 | Sept. 3, 1864. | Once. | | | | Next day. Hem. | |
| 748 | July 20, 1864. | 38, 41 days. | | | | 32d day. | On account of hemorrhage the artery was religatured on Aug. 30th. |
| 749 | Feb. 26, 1863. | | | | | 39th day. Hem. | |
| 750 | Sept. 30, 1862. | 2 days. | | | | 3d day. Hem. | |
| 751 | July 10, 1863. | None. | | | | 3d day. | |
| 752 | 1876. | Once. | | | | 11th day. Hem.; asphyxia. | Antiseptic ligature; no cerebral symptoms; subclavian tied at the same time. Autopsy: Sac bursted in trachea. (<i>Distal</i> .) |
| 753 | Sept. 26, 1829. | | | Recovered. | Temporary improvem't. | | Died about 5 months later from rupture of the sac. Subclavian was tied on 3d December. |
| 754 | | | | Recovered. | (?) | | |
| 755 | June 26, 1829. | | 21 | Recovered. | Improved. | | |
| 756 | June 26, 1839. | Several times. | 12 | | | 33d day. Hem. | "Hem. caused by patient tearing wound open with her own hands." |
| 757 | Dec. 13, 1840. | | 12 | Recovered. | Cured. | | Patient complained of queer feeling in head, which passed off in an hour. (<i>Distal</i> .) |
| 758 | March 2, 1842. | | 9 | Recovered. | Not cured. | | 3 years after operation but little change in tumor. |
| 759 | Sept. 2, 1843. | | 15 | Recovered | Marked improvement. | | |
| 760 | July 2, 1856. | | 14 | Recovered. | do. | | |
| 761 | Sept. 26, 1856. | | | | | 38th day. Exhaustion. | No cerebral symptoms. |
| 762 | Dec. 6, 1847. | | 13 | Recovered. | Cured. | | One of the terminal branches of common carotid was also tied. |
| 763 | Dec. 7, 1854. | | 13 | Recovered. | | | Tumor was immense; mass sloughed after operation and brought away by a ligature; 6 months after operation patient fell into hands of a quack and died. |
| 764 | | | | | | 4th day. | Paralysis on opposite side a few hours after operation. |
| 765 | | | | | | 4th day. | Dr. A. T. Woodward kindly sent me another case where he tied the right common carotid for shot wound of face and neck. Patient was living several days after operation, but as the Dr. lost sight of him, and the result is uncertain, I have thought best to omit this case. |

Surgical History of the

| No. | Name of operator. | Source of information. | PATIENT. | | | Cause of operation. | Duration of cause. | Point of deligation. | Date of injury. | Date of hemorrhage. |
|-----|---------------------------|---------------------------------------------------------------------------|----------|------------|-------|---------------------------------------------------|--------------------|----------------------|-----------------|---------------------|
| | | | Sex. | Age. | Side. | | | | | |
| 766 | Woodward. G. F., 1857. | N. Y. Med. Jr., July, 1857, Prof. Jas. R. Wood. | M. | 33 | R. | Cancerous tumor orbit and brain. | | | | |
| 767 | Wynkoop, G.H. | Notes of case, courtesy of Prof. Willard Parker. | M. | 1½ y r. | | Hem. congen. tum. face (ulcerating). | | | | |
| 768 | Wutzer, 1847. | Arch. Klin. Chir., 1868 (cit.). | M. | 25 | | Aneur. anast. ext. carotid. | | | | |
| 769 | White, 1861-5. | Letter, Dr. J. H. Erskine (Med. Direc- tor Army of Tennes- see). | | | R. | Malignant tumor. | | | | |
| 770 | White, 1845. | Lancet, 1846, vol. i. p. 149. | M. | 34 | R. | Aneurism, carotid, near bifurcation. | 3 mos. | | | |
| 771 | Wright, W., 1855. | Lancet, 1856, vol. i. p. 711. | M. | 70 | R. | Aneurism, inno- m. | | | | |
| 772 | Zeiss. | Norris Contrib. | | 15 mos | L. | Erect. tum. face. | 15 mos. | | | |
| 773 | Zörnroth, L.H. | Arch. Klin. Chir., 1868. | | | R. | Aneurism tempo- ral artery (arte- riotomy). | | | | |

Appendix to History of the

| No. | Name of operator. | Source of information. | PATIENT. | | | Cause of operation. | Duration of cause. | Point of deligation. | Date of injury. | Date of hemorrhage. |
|-----|----------------------------------------------|----------------------------------------|----------|-------|-------|------------------------------------------------|--------------------|----------------------|-----------------|---------------------|
| | | | Sex. | Age. | Side. | | | | | |
| 774 | Guthrie. | Nash. Jr. Med. Surg., Feb. 1874. | F. | 53 | R. | Hem. rem. tumor of neck. | | | | |
| 775 | Eve, Prof. Paul F. (Nashville, Tenn.). | Letter to author. | | | | | | | | |
| 776 | do. | do. | | | | | | | | |
| 777 | Cooper, B. (See 122-3). | | | | | | | | | |
| 778 | Hodges, 1868. | Bost. Med. Surg. Jr., Aug. 6, 1868. | M. | 35 | R. | Innominate aneu- rism. | | | | |
| 779 | Hobart, 1839. | Gny's Hosp. Rep., vol. xvii. | F. | 25 | R. | Aortic aneurism (supposed in- nominate). | | | | |

Common Carotid Artery—continued.

| No. | Date of operation. | Hemorrh'ge occurred after op. | Lig. came away No. days aft. op. | RESULT. | | | REMARKS. |
|-----|--------------------|-------------------------------|----------------------------------|------------|------------|------------------------------------------------------|--------------------------------------------------------------------------------------------------------------|
| | | | | Recovery. | Condition. | Cause of death, date after op. | |
| 766 | April 18, 1857. | Repeat- edly. | | | | 50th day. Disease, hem., and cerebral complications. | Paralysis resulted on left side, 42d day. Tumor continued to grow. |
| 767 | Nov. 1, 1868. | | 21 | Recovered. | Cured. | | A silver wire ligature was used, both ends being cut off and left in wound; the loop worked out on 21st day. |
| 768 | | | 18 | Recovered. | Cured. | | On account of numerous branches going into tumor, it was deemed impracticable to tie the ext. carotid. |
| 769 | | | | | | 3 days. ? | |
| 770 | Aug. 28, 1845. | 6, 10, 11 days. | 10 | Recovered. | Cured. | | |
| 771 | Oct. 1, 1856. | | | | | 88th day. | Paralysis (left) followed operation; abscess of brain at autopsy. <i>Distal.</i> |
| 772 | | | 8 | | | 114 days. Cerebral complications. | |
| 773 | | Once. | | Recovered. | Cured. | | |

Common Carotid Artery.

| No. | Date of operation. | Hemorrh'ge occurred after op. | Lig. came away No. days aft. op. | RESULT. | | | REMARKS. |
|-----|--------------------|-------------------------------|----------------------------------|------------|------------|--------------------------------|------------------------------------------------------------------------------------------------------------------------------------------------------------------------------------------------------------------------------------------------------------------------------------------------------------------------------------------------------------------------------------------------------------------------------------------------------------------------|
| | | | | Recovery. | Condition. | Cause of death, date after op. | |
| 774 | | | | Recovered. | Not cured. | | Ext. carotid wounded; common was tied, but did not arrest hem. The <i>external</i> was then secured <i>above</i> the wound, and this did not arrest hem. The <i>internal</i> carotid was next secured, and hemorrhage ceased. The disease returned, and patient died 6 months later. |
| 775 | | | | Recovered. | | | (For Dr. Eve's 3d case, see Mott, V.) |
| 776 | | | | Recovered. | | | |
| 777 | | | | | | | |
| 778 | April 11, 1868. | 8th day. | | | | 11th day. Exhaustion and hem. | <i>Distal.</i> The subclavian was tied in its 3d division at same time. 8th day, internal jugular vein burst and was tied. |
| 779 | 1839. | 16th day. | | | | 18th day. Hem. | <i>Distal.</i> The subclavian was tied in 1st division at same time. Patient did well until 16th day, when in a fit of passion she sprang from her bed and threw a pillow and some books at the attendant. Hem. from <i>carotid</i> ensued, and death. Autopsy: <i>Subclavian closed, carotid open</i> , although the aorta and not the innominate was the seat of the disease, the pulsation in the tumor had ceased before death, and the process of cure had begun. |

Appendix to History of the

| No. | Name of operator. | Source of information. | PATIENT. | | | Cause of operation. | Duration of cause. | Point of deligation. | Date of injury. | Date of hemorrh'ge. |
|------------------|-----------------------------------|--------------------------------------------------------------------|----------|-------|-------|-------------------------------------------------------------------------------------|--------------------|----------------------|-----------------|---------------------|
| | | | Sex. | Age. | Side. | | | | | |
| 780 | Parker, Prof. Willard, 1863. | Notes of case to author from Dr. Parker. | M. | 32 | R. | Subclavian aneurism. | 12 mos. | | | |
| 781 | Durham. | Mr. T. Holmes in Lancet for 1872. | | | R. | Innominate aneurism. | | | | |
| 782 | Bickersteth, 1864. | do. | | | R. | Aneur. aorta and innominate. | | | | |
| 783 | Little, Prof. Jas. L. | Notes from Dr. Little. | M. | | R. | do. | | | | |
| 784 | Speir, S. Fleet, Brooklyn, N. Y. | Notes from Dr. Speir in Birmingham's Archives of Clinical Surgery. | M. | 31 | R. | Aortic aneurism (supposed innominate). | | | | |
| 785 ¹ | Barwell, Richard, 1877. | Lancet, Nov. 17, 1877; Am. Jr. Med. Sci., Jan. 1878, p. 275. | M. | 45 | R. | Aneurism aorta, carotid, subclav., and innominate. | | | | |
| 786 | Paul. John, 1830. | Lond. Med. Gaz., 1838, vol. viii. p. 71. | F. | 28 | R. | Pulsating tumor above ear. | | | | |
| 787 | Stimson, D. L. | Dr. Stimson to author. | M. | | | Aneurism of common carotid. | | | | |
| 788 | Cooper, S. E. | Amer. Med. Times, June 24, 1862. | F. | 14 | ? | Tumor of parotid and submaxillary glands. | | | | |
| 789 | Bradley, E., New York City, 1877. | Notes of case from Dr. Bradley to author. | M. | 20 | L. | Hem. during removal of vascular tumor of parotid and submaxillary region (Angioma). | 19½ years. | Near clavicle | | |

¹ MR. RICHARD BARWELL. Am. Jr. Med. Sci., Oct. 1878, p. 570, and January, 1878, p. 275. M.; 45; R. Aneurism of aorta, innominate, subclavian, and carotid arteries. Carotid tied Aug. 14, 1877, and subclavian a few minutes later in 3d division. Tumor diminished rapidly in size and consolidated. Nov. 14 patient left the hospital. "On the 22d November, he walked two miles through snow and sleet, thinly clad, sat four hours in wet clothes, without a fire, and died Nov. 24, 1877." Autopsy: "Bronchitis, œdema, and hypostatic pneumonia. Muco-pus in large and small bronchi. Arterial blood was dark. The innominate, right carotid, and subclavian were obliterated. No vessel opened out of the aneurism, which was much diminished in size and consolidated."

[It is probable this patient would have lived comfortably for a much longer time if he had acted more prudently. The reader is referred to the *summaries* for results of these *double distal ligatures*.—Author.]

Common Carotid Artery—continued.

| No. | Date of operation. | Hemorrhage occurred after op. | Lig. came away No. days aft. op. | RESULT. | | | REMARKS. |
|-----|--------------------|-------------------------------|----------------------------------|------------|------------------------------|----------------------------------|--------------------------------------------------------------------------------------------------------------------------------------------------------------------------------------------------------------------------------------------------------------------------------------------------------------------------------------------------------------------------------------------------------------------------------------------------------------------------------------------------------------------------------------------------------------------------------|
| | | | | Recovery | Condition. | Cause of death, date after op. | |
| 780 | Sept. 2, 1863 | 10, 21, 35, and 42 days. | | | | 42d day. Hem. | <i>Wardrop.</i> The subclavian in 1st division and vertebral were tied same time. Autopsy showed that fatal hemorrhage was from <i>distal</i> end of subclavian. |
| 781 | | None. | | | | 6th day. Shock. | <i>Distal.</i> Subclavian in 3d division tied same time. |
| 782 | 1864. ? | | | | | 10 weeks. Suffocation. | <i>Wardrop.</i> 7 weeks later subclavian was tied in 3d division, and death resulted in 21 days. |
| 783 | 1876. | | | Recovered. | Marked improvement to date. | | <i>Distal.</i> Subclavian was tied in 3d division same time. This case will most likely result in a cure. |
| 784 | Aug. 6, 1874. | 26, 27, 28, 30, 31, 32 days. | | | | 34th day. Hem.; dyspnoea. | <i>Distal.</i> Carotid obliterated by Dr. Spier's "artery constrictor," and two days after this subclavian was tied in 3d division. (For other interesting facts, see article on the subclavian.— <i>Author.</i>) |
| 785 | Aug. 14, 1877. | | | Recovered. | Much imp'd on Nov. 13, 1877. | | <i>Distal.</i> Subclavian tied same time in 3d division. |
| 786 | July 29, 1830. | | 15 | Recovered. | Cured. | | |
| 787 | 1877. | | | | | Several weeks. Edema of glottis. | |
| 788 | ? | | | Recovered. | Cured. | | Tumor was removed after ligation. |
| 789 | Dec. 6, 1877. | None. | 3d week. | Recovered. | Cured. | | Tumor grew rapidly within the last year. In operation for removal, while dissecting with the handle of the scalpel, the tumor gave way, and a frightful hemorrhage occurred. The common carotid was tied immediately above the clavicle, the incision being made behind the posterior border of the mastoid muscle. Hem. ceased instantly. The recovery was prompt, and the tumor has entirely disappeared. After ligation of the common trunk the tumor was not removed, but the wound was packed with lint soaked in Monsel's solution. No symptoms of cerebral disturbance. |

THE following cases of ligature of the common carotid artery were discovered after this essay was finished. They are not considered in the summary:—

1. Probably by Dr. JAS. R. WOOD. Bellevue Hospital Records. M.; 50 years. Cancer lower jaw. Operation, January, 1878. Died, from exhaustion, March 29, 1878.

2. DR. F. P. PORCHER. Am. Jr. Med. Sci., Oct. 1878, p. 449. M.; 38; L. Aneurism common carotid. Operation, June 27, 1878. Died, hemorrhage, July 4, 1878. Autopsy: Sac had burst, causing death; artery was tied from $\frac{1}{2}$ to $\frac{3}{4}$ inch from arch of aorta; a catgut ligature was used, *which had become loose, and the artery was not occluded!* "No clot in any portion of it."

3. DR. ERSKINE MASON. Personally to author. Boy. Incised wound of throat. Died in a few hours from exhaustion from hemorrhage before operation.

4. SAME. Personally to author. M.; 12; L. Lacerated wound under jaw. Aneurism resulted July 10, 1861. Dr. Jas. R. Wood tied common carotid. Aneurism increased in size, and profuse hemorrhage occurred July 16, when Dr. Mason opened sac and tied the artery above and below it. Patient died in 15 minutes, from hemorrhage during operation.

5. DR. GEO. E. POST, of Beirut, Syria. F.; 7; R. Supposed recurring fibroid tumor of neck. In second operation for removal, portions of the *internal jugular vein, common carotid artery, pneumogastric, descendens noni, recurrent laryngeal, and sympathetic* nerves were excised. The wound healed kindly, and patient was discharged at end of three weeks. The only important symptom after the operation was paralysis of the bladder, which disappeared in a few days. The child died four months later of the disease, which returned, and proved to be encephaloid.

[It is strange no general disturbance followed section of the sympathetic. In one of the fatal cases in the Surgical History of the Common Carotid, this nerve was *included* in the ligature.—*Author.*]

NOTE.—Of these 5 cases, 4 died within a few days, and the other within a few months of the operation. They are not considered in the summaries. Nos. 729, 720, and 605 are (by errors I cannot now correct) incomplete, but in such a large number of cases, these few mistakes will not change the general result.—*Author.*

SURGICAL HISTORY
OF THE
INTERNAL AND EXTERNAL CAROTID ARTERIES.

Ligature of the

| No. | Name of operator. | Source of information. | PATIENT. | | | Cause of operation. | Duration of cause. | Point of deligation. | Date of injury. | Date of hemorrhage |
|-----|----------------------------------|-------------------------------------------------------------------|----------|----------|-------|---------------------------------------------------------------|--------------------|---------------------------------------|-----------------|-----------------------|
| | | | Sex. | Age. | Side. | | | | | |
| 1 | Buck, Gurdon, 1848. | M. Y. Med. Jr., July, 1857, Prof. Jas. R. Wood. | M. | 30 | R. | Lacerated wound angle right inf. max. (glass). | 5 days. | | July 4. | |
| 2 | do. 1852. | do. | M. | 22 | R. | Wound external carotid or its branches. | | | | |
| 3 | Burchard, T. H., New York, 1873. | Letter to author. | M. | 60 | L. | Hem. pistol w'nd neck, high up (suicidal). | | $\frac{1}{2}$ inch above bif. of com. | | |
| 4 | Byrd, W. A. (Ill.), 1876. | N. Y. Med. Jr.; Aug. 1876. | M. | Mid age | L. | Hem. shot wound near angle inf. maxilla. | 7 hours. | | | |
| 5 | Briggs, W. T., Nashville, 1871. | Nash. Jr. Med. Surg., Feb. 1874, Prof. Bowling; Letter to author. | M. | 23 | L. | Aneur. stab w'nd internal carotid. | Several weeks. | High up. | | |
| 6 | Bramblett, W. H., 1864. | N. Y. Med. Record, June, 1869. | M. | 47 | L. | Hem. shot wound cheek. | | | | 10th d'y after wound. |
| 7 | Guthrie. | | M. | | | Knife wound int. carot. (suicidal). | | | | |
| 8 | Hunt, 1862. | Letter from Prof. Alfred C. Post to author. | M. | Mid age. | R. | Shot wound neck, high up. | | | | |
| 9 | Keith. | Nash. Jr. Med. Surg., Feb. 1874, Prof. Bowling. | F. | 25 | L. | Wound. internal carot. in attempt to remove pin from pharynx. | | | | |
| 10 | Guthrie. | do. | F. | 53 | R. | Hem. wound ext. carotid; removal of tumor from neck. | | | | |
| 11 | McClellan. | McClellan, System of Surgery. | | | | | | | | |
| 12 | Parker, Prof. Willard, 1855. | Note of case from Prof. Parker. | M. | 50 | L. | Hem. wound ext. carotid. | | | | |
| 13 | Pancoast, Prof. | Dr. S. W. Gross in Am. Jr. Med. Sci., April, 1867. | | | | | | | | |
| 14 | Sands, Prof. H. B., 1872. | Notes of case from Prof. Sands to author. | M. | 53 | L. | Secondary hem. remov. inf. max. (malign. tumor of). | | | | |
| 15 | Santesson, 1853. | Arch. Klin. Chir., 1868; Dr. C. Piltz. | F. | 18 | R. | Removal parotid tumor. | | | | |
| 16 | Smith, Prof. Stephen, 1864. | N. Y. Jr. Med., Jan. 1874. | | | L. | Hem. cancer. disease of face. | | Just above bifur. | | |
| 17 | Velpeau, 1835. | Norris Contrib. | M. | 16 | L. | Erectile tumor of temporal region. | | | | |
| 18 | Verneuil, 1871. | Lancet, Nov. 4, 1871, p. 644. | M. | 30 | R. | Shot w'nd cheek. | 21 days. | | May 23. | June 15-30, etc. |

Internal Carotid Artery.

| No. | Date of operation. | Hemorrhage occurred after op. | Lig. came away No. daysaft. op. | RESULT. | | | REMARKS. |
|-----|--------------------|-------------------------------|---------------------------------|------------|------------|--------------------------------|------------------------------------------------------------------------------------------------------------------------------------------------------------------------------------------------------------------------------------------------------------------------------------------------------------------------------------|
| | | | | Recovery. | Condition. | Cause of death, date after op. | |
| 1 | July 9, 1848. | | 11 | Recovered. | Cured. | | Hem. occurred 71st day after operation, 2 ounces; stopped spontaneously; common carotid tied same operation. Facial paralysis persistent and complete (caused doubtless by injury to facial nerve by glass). Common carotid was also tied. |
| 2 | May 10, 1852. | | | | | 11th day. | Pyæmia. |
| 3 | Sept. 1873. | | 7 | Recovered. | Cured. | | Ext. carotid tied same time. |
| 4 | May, 1876. | | | | Cured. | 20 minutes. Exhaustion; hem. | Hem. had been immense before Dr. B. could arrive. Ext. and common carotid also tied. |
| 5 | Feb. 23, 1871. | | | Recovered. | Cured. | | Common carotid was first tied; hem. not arrested; Dr. B. cut into sac and tied both ends of wounded internal carotid. |
| 6 | Dec. 1864. | | 14 | Recovered. | Cured. | | Hem. not ceasing with lig. of internal carotid, the common and ext. carotids were also tied. Common carotid first tied but did not arrest hem.; internal next tied, still no arrest of bleeding; external carotid tied, hem. stopped. Int. jug. vein was also tied. |
| 7 | | | | | | 2 days. | |
| 8 | 1862. | | | | | Next day. | Exhaustion; shock. |
| 9 | | None. | | Recovered. | Cured. | | Only one ligature, and that on proximal side of wound. Hem. was controlled by pressure on com. car. until the int. was tied. |
| 10 | | | | Recovered. | Not cured. | | Common carotid tied, no arrest of hem.; external then tied on distal side of wound: hem. still continued, and did not cease until internal carotid was secured. Patient died 6 months later from return of disease. |
| 11 | | | | Recovered. | | | Ext. carotid was tied same time. |
| 12 | Jan. 3, 1855. | None. | 13 | Recovered. | Cured. | | The common carotid was first tied, but hem. was not arrested until ligature of inter'l carotid. |
| 13 | | | | Recovered. | | | The internal jugular vein was tied at the same time. There was no cerebral disturbance. |
| 14 | 1872. | | 8 | Recovered. | Cured. | | In operation for removal of tumor <i>internal jugular</i> vein was wounded and tied with lateral ligature; 10 days later hem. from ulceration of <i>internal carotid</i> , which was tied above and below bleeding point, and <i>common carotid</i> tied just below bifurcation. The external carotid was secured at the first op. |
| 15 | 1863. | | | Recovered. | Cured. | | The <i>internal carotid</i> was torn in two during operation; <i>common carotid</i> tied, increasing hemorrhage; the vessels were ligatured then <i>en masse</i> . |
| 16 | | | | Recovered. | | | External carotid also tied; no cerebral symptoms. Disease returned and patient died some months after. |
| 17 | 1835. | | | | | 16th day. | Hem. |
| 18 | July 2, 1871. | | | | | 42 hours. | Coma. |

Ligature of the

| No. | Name of operator. | Source of information. | PATIENT. | | | Cause of operation. | Duration of cause. | Point of deligation. | Date of injury. | Date of hemorrhage. |
|-----|---------------------------|--------------------------------------------------------------------------------------|----------|----------|-------|--------------------------------------------------------|--------------------|---------------------------|-----------------|------------------------|
| | | | Sex. | Age. | Side. | | | | | |
| 1. | Bertherand, 1860. | Ehrmann des effets, Dr. Madelung; Arch. Klin. Chir., vol. xvii. | F. | 4½ mos | L. | Erectile tumor of temporal region. | | | | |
| 2 | Bœckel, 1861. | Arch. Klin. Chir., 1838; Gaz. Med. de Strasbourg, 1862, No. 6, p. 100. | F. | 50 | R. | Hem. after removal encondroma near angle jaw. | | | | |
| 3 | Burchard, T.H., 1873. | Letter to author. | M. | 60 | L. | Hem. pistol w'nd neck, high up (suicidal). | | ½ inch above bif. of com. | | |
| 4 | } Busch, W., 1872. | Schmidt Jahrb., Bd. 167, p. 66; Dr. Madelung (cit.). | F. | 29 | R. | Pulsating vascular tumor back of head. | 24 y'rs. | | | |
| 5 | | | do. | F. | 29 | L. | | | | |
| 6 | do. 1836. | Longworth Prize Thesis; Dr. Madelung (op. cit.); Schmidt Jahrb., vol. xviii. p. 341. | M. | 34 | L. | Retro-pharyngeal tumor (prepar. to remove). | | Above digastric. | | |
| 7 | Bushe, G., 1827. | Lancet, 1828, vol. ii. p. 413; Longworth Prize Thesis. | F. | 2½ | R. | Hem. after remov. pulsating tumor temporal region. | | do. | | |
| 8 | Byrd, W. A. (Ill.), 1876. | N. Y. Med. Jr., Aug. 1876. | M. | Mid age | L. | Shot wound ext and int. carotid angle of jaw. | 7 hours. | | | |
| 9 | } V. Bruns, 1856. | Arch. Klin. Chir., vol. xvii.; Dr. Madelung. | M. | 25 | R. | Vascular tumor left cheek, lip, and nose. | | | | |
| 10 | | | do. | | | L. | do. | | | |
| 11 | do. 1839. | Arch. Klin. Chir., vol. xvii.; Dr. Madelung. | M. | 56 | R. | Tumor of parotid. | | | | |
| 12 | do. | | M. | 23 | L. | Fibroid tumor of parotid. | | | | |
| 13 | Bramblett, W. H., 1864. | N. Y. Med. Record, June, 1869. | M. | 47 | L. | Shot w'nd cheek. | | | | 10th day after injury. |
| 14 | De Castro, 1864. | Gaz. Med. d'Orient, 1864, p. 166; Dr. Madelung. | M. | 31 | R. | Hem. after lig. of common carotid for aneur. external. | | | | |
| 15 | Corradi, Italy, 1874. | N. Y. Med. Jr., Sept. 1876. | | 58 | L. | Tumor of parotid. | | | | |
| 16 | Cleary, 1864. | Arch. Klin. Chir., vol. xvii. p. 626, Dr. Madelung. | M. | Mid age. | R. | Shot wound face. | | | | |
| 17 | Demarquay, 1857. | Gaz. Hebdom., 1858, p. 688. | M. | 62 | R. | Hypertrophy of parotid. | | Above digastric. | | |

External Carotid Artery.

| No. | Date of operation. | Hemorrhage occurred after op. | Lig. came away No. days aft. op. | RESULT | | | REMARKS. |
|-----|--------------------|-------------------------------|----------------------------------|------------|-------------|-------------------------------------------|----------------------------------------------------------------------------------------------------------------------------------------------------------------------------------------------------------------------------------------------------------------------------------------------------------------------------------------------------------------------------------------------------------------|
| | | | | Recovery. | Condition. | Cause of death, date after op. | |
| 1 | | | | Recovered. | Cured. | | External carotid first tied some hours before common. As the effect on the tumor was not marked, this last vessel was tied and the ligature removed from the external. (As the ligature was tightened and remained several hours <i>in situ</i> , the vessel can properly be considered as obliterated by the operation, the inner coat being cut and turned in as is the rule in such cases.)— <i>Author.</i> |
| 2 | | Once. | | | | About 5 days. Coma; cerebral exhaust. | After ligature of <i>external carotid</i> , hemorrhage which was arrested by ligature of <i>common</i> and <i>internal carotid</i> . Paralysis resulted after these last two vessels were secured. |
| 3 | Sept. 1873. | None. | 7 | Recovered. | Cured. | | No bad symptoms followed. Internal carotid tied same operation. |
| 4 | Aug. 25, 1872. | | 13 | Recovered. | | | Patient writes Dec. 20, 1873, "Am not able to work; appetite good; sleep badly; pulsation in tumor, place is not so well as when I was discharged." Hemorrhage from the sloughing tumor some time after op., only very slight. <i>External carotid</i> as large as <i>common trunk</i> . |
| 5 | | do. | 16 | Recovered. | Not cured. | | |
| 6 | 1856. | None. | | Recovered. | Cured. | | |
| 7 | 1827. | None. | 13-18 | Recovered. | Cured. | | Pressure and hot iron had been tried to arrest hem. before ligature. No hem. after operation. |
| 8 | May, 1876. | | | | | 20 minutes. Exhaustion from previous hem. | Hemorrhage had been immense before Dr. Byrd arrived. Internal and common carotid were also tied. |
| 9 | 1856. | | 20 | Recovered. | | | |
| 10 | | | 10 | Recovered. | No benefit. | | |
| 11 | March 12, 1859. | | 14 | Recovered. | Cured. | | |
| 12 | Aug. 2, 1859. | | 1 | Recovered. | Cured. | | |
| 13 | Dec. 1864. | | 18 | Recovered. | Cured. | | 10 days after wound <i>internal carotid</i> tied; hemorrhage persisting, common and external carotids also tied. Hem. still followed, though not so severe, arrested by pressure of cloth soaked in tinct. ferri chloridi. |
| 14 | 1834. | | | | | Died in few minutes. Hem; exhaustion. | Hem. not ceasing after ligature of common carotid, the sac suppurated and external tied. Died immediately from previous hemorrhage. (No details of this case.) |
| 15 | 1874. | | | Recovered. | Cured. | | |
| 16 | 1864. | (Occurred.) | 12 | | | 35 days. | External carotid tied 14 days after injury; 33 days later, on account of hemorrhage, common carotid was tied. Died 2 days later. |
| 17 | 1857. | | | Recovered. | Cured. | | |

Ligature of the

| No. | Name of operator. | Source of information. | PATIENT. | | | Cause of operation. | Duration of cause. | Point of deligation. | Date of injury. | Date of hemorrhage. |
|-----|------------------------------|-------------------------------------------------------------------------------------------|----------|----------|-------|------------------------------------------|--------------------|----------------------------------|-----------------|---------------------|
| | | | Sex. | Age. | Side. | | | | | |
| 18 | Dolbeau, 1864. | Longworth (op. cit.); Madelung (op. cit.). | F. | 15 | R. | Hem. abscess sub-max. region. | | Below digastric. | | |
| 19 | Duménil, 1872.? | Schmidt Jahrb., Bd. 160, p. 166. | M. | 13 | L. | Hem. polyp. nose. | | | | |
| 20 | Engel, 1842. | Schmidt Jahrb., 39-40, p. 212; Arch. Klin. Chir., vol. xvii. p. 624; Longworth; Madelung. | F. | | | Suicidal wound near angle jaw. | | | | |
| 21 | Ensign, W. A., 1864. | Med. Surg. Hist. Reb.; Dr. G. A. Otis. | M. | 24 | R. | Shot wound orbit and int. max. artery. | | Above digastric. | June 3. | June 14. |
| 22 | Foucher. | Longworth; Madelung; Gaz. des Hôp., 1892, p. 518. | | | R. | Hem. after amputating tongue by éraseur. | 5 days. | Below digastric. | | |
| 23 | Günther, 1845. | Madelung (op. cit.). | F. | 51 | R. | Hem. after remov. of parotid. | | Above digastric. | | |
| 24 | Guthrie. | Nash, Jr. Med. Surg., Feb. 1874. | F. | 53 | R. | Hem. removal of tumor of neck. | | | | |
| 25 | do. | Arch. Klin. Chir., 1868; Pilz. | M. | | L. | Knife wound int. carotid (suicidal). | | | | |
| 26 | Hamilton, Prof. F. H., 1858. | Notes of case from Prof. Hamilton. | M. | Mid age. | L. | Scirrhus tumor of parotid. | Several years. | | | |
| 27 | Heine, C., 1869. | Schmidt Jahrb., 147, p. 69. | M. | 21 | | Hem. cirsoïd tum. scalp and ear. | | Below digastric. | | |
| 28 | Jones, J. C., 1864. | Med. Surg. Hist. Reb.; Otis. | M. | Mid age. | R. | Shot fracture of right inf. max. | | | Dec. 14. | Dec. 14. |
| 29 | Lannélongue, 1873. (?) | Schmidt Jahrb., Bd. 166, p. 149. | M. | | | Sarcoma of tongue and face. | | | | |
| 30 | Legouest. | Arch. Klin. Chir., 1868; Pilz (cit.). | F. | | L. | Traumatic aneur. of orbit. | | | | |
| 31 | Lizars, Juo., 1830. | Longworth Prize Thesis (cit); Madelung (op. cit.). | F. | 55 | R. | Prep. to removal tumor sup. max. | | Below digastric. | | |
| 32 | Mahon, M., 1864. | Am. Jr. Med. Sci., vol. xviii. p. 276; Madelung (cit.); Lancet, 1829-30, vol. ii. p. 54. | M. | 25 | L. | Shot wound inf. max. | | | Nov. 25. | Nov. 29. |
| 33 | Maisonneuve, 1849. | Bull. de la Soc. de Chir., vol. i. p. 400; Longworth (cit.); Madelung. | F. | 30 | R. | Aneurism anast. temporal region. | 2 mos. | $\frac{1}{2}$ inch above origin. | | |
| 34 | do. 1852. | Mem. de la Soc. de Chir., 1864, tome vi. p. 211; Longworth; Madelung (cit.). | M. | 53 | R. | Carcinoma of tongue. | | Below digastric. | | |
| 35 | do. 1855. | do. | M. | | R. | do. | | | | |
| 36 | do. | do. | M. | 42 | L. | Cancer of left inf. max. and tongue. | | | | |
| 37 | do. 1856. | do. | M. | 51 | R. | Cancer of tongue, jaw, and pharynx. | | | | |

External Carotid Artery—continued.

| No. | Date of operation. | Hemorrhage occurred after op. | Lig. came away No. days aft. op. | RESULT. | | | REMARKS. |
|-----|--------------------|----------------------------------------|----------------------------------|------------------------|------------|-------------------------------------------|----------------------------------------------------------------------------------------------------------------------------------------------------------------------------------------------------------|
| | | | | Recovery. | Condition. | Cause of death, date after op. | |
| 18 | 1864. | | 10 | Recovered. | Cured. | | |
| 19 | 1872. | Occur'd from nose; none from ligature. | | Recovered. | | | The ligature did not arrest hem.; there was no hem. from seat of ligature. |
| 20 | | None. | | Recovered. | Cured. | | Wound from angle of jaw to larynx, opening into pharynx, Hem. before operation was immense. |
| 21 | July 16, 1864. | | | | | Died on table. Exhaustion. | (Ligature of the external carotid was performed too late, as patient could not rally from previous and exhausting hem.) |
| 22 | | | | Recovered. | | | |
| 23 | 1846. | Occurred. | | Recovered. | Cured. | | Hem. after ligature stopped by ice and compress. |
| 24 | | | | Recovered. | | | Common carotid first tied; did not arrest hem.; external tied above wound; hem. not arrested until internal carotid was secured. |
| 25 | | | | | | Died. Hem. and exhaustion. | Internal jugular vein tied (lateral lig.) and common carotid same time. 8 days later ext. carotid tied; internal carotid also. |
| 26 | March, 1858. | None. | | Recovered. | Not cured. | | Disease returned and patient died later. |
| 27 | | Severe. | | Recovered. | Cured. | | 5 days after lig. of ext. on account of hemorrhage the common carotid was tied. Hem. from seat of ligature. |
| 28 | Dec. 14, 1864. | | | Recovered. | | | |
| 29 | | | | Recovered. | Not cured. | | Died of disease some time after operation. |
| 30 | | None. | | Recovered. | Cured. | | Common carotid tied same time. |
| 31 | | None. | | Recovered. | | | Several polypi were removed from the <i>ethmoid</i> bone during operation. |
| 32 | Dec. 3, 1864. | | 8 | Recovered. | Cured (?) | | Ball entered angle left inf. max. fracturing it; passed beneath tongue, out right side hyoid bone; common carotid first tied. Hem. not arrested; external was ligatured 4 days after common. |
| 33 | | After. | 16 | | | Died. Coma; not on account lig. ext. car. | 21 days after lig. of external carotid, hem.; 26th and 27th hem., then lig. of common and internal carotid; <i>sympathetic nerve</i> included in last lig. Hemiplegia ensued after lig. of common trunk. |
| 34 | | | | Recovered. | Cured. | | |
| 35 | Jan. 21, 1831. | | | Recovered from oper'n. | | | Patient died 1 month later from violence of disease. |
| 33 | Nov. 23, 1855. | | | Recovered. | | | Died 60 days after operation from violence of disease. |
| 27 | 1856. | | | Recovered. | ? | | Discharged in 1½ month. |

Ligature of the

| No. | Name of operator. | Source of information. | PATIENT. | | | Cause of operation. | Duration of cause. | Point of deligation. | Date of injury. | Date of hemorrhage |
|-----|-------------------------------------|-------------------------------------------------------------------------------------------------------------------|----------|---------|-------|-------------------------------------------------|--------------------|-----------------------------------------|-----------------|--------------------|
| | | | Sex. | Age. | Side. | | | | | |
| 38 | Maisonneuve, 1854. do. do. | Mem. de la Soc. de Chir., 1864, tome vi. p. 211; Longworth. Dr. Madelung in Arch. Klin. Chir., vol. xvii. p. 628. | F. | 32 | L. | Carcinoma pharynx and tongue. | | | | |
| 39 | | | F. | 32 | R. | do. | | | | |
| 40 | | | M. | 26 | R. | Carcinoma of tongue. | | | | |
| 41 | do. do. do. | do. do. do. | M. | 34 | L. | Unknown. | | | | |
| 42 | | | | | R. | do. | | | | |
| 43 | | | M. | 50 | R. | Carcinoma of tongue. | | | | |
| 44 | do. do. 1856. do. do. | do. do. do. do. | M. | | L. | | | | | |
| 45 | | | M. | 44 | R. | Carcin. of tongue. | | | | |
| 46 | | | M. | 44 | L. | do. | | | | |
| 47 | | | | | L. | Unknown. | | | | |
| 48 | Marchal, 1835. | Norris Contrib. (cit.); Madelung. | M. | 25 | L. | Hem. puncture of aneur. (mistaken for abscess). | | | | |
| 49 | Mastermann. | Arch. Klin. Chir., Bd. 17, p. 616; Madelung. | F. | 16 | R. | Aneur. anast. ear. | | About digastric. | | |
| 50 | Moses, J., 1863. | Med. Surg. Hist. Reb.; G. A. Otis. | M. | Mid age | R. | Shot wound face. | | | Sept. 20 | |
| 51 | Mott, V., 1831. | Am. Jr. Med. Sci., vol. x. p. 17; Dr. Madelung (cit.). | M. | 21 | L. | Melanotic tumor of parotid. | | About digastric. | | |
| 52 | McClellan, 1871. | Am. Jr. Med. Sci., Oct. 1872. | F. | 32 | R. | Recurrent tumor of right parotid. | | At digastric. | | |
| 53 | do. 1845. | McClellan, System of Surgery. | | | | | | | | |
| 54 | McGraw, T. A., Michigan. | Letter to author. | | | | Removal of tumor of parotid. | | | | |
| 55 | do. | do. | | | | do. | | | | |
| 56 | Nélaton, 1858. | Arch. Klin. Chir., Bd. 17, p. 620; Madelung. | M. | 67 | R. | Hem. after remov. parotid tumor. | | Near bifurcation. | | |
| 57 | Noir, 1861. | do. p. 624. | M. | 35 | R. | Hem facial art. | | do. | | |
| 58 | Pancoast, G. L., 1864. | Med. Surg. Hist. Reb. | M. | Mid age | | Shot wound inf. max. | | | June 18, 1864. | June 27. |
| 59 | Parker, Prof. Willard, 1838. | Letter to author. | M. | 52 | R. | Enlarged parotid. | 20 y'rs. | $\frac{1}{2}$ inch ab. bif. | | |
| 60 | do. | do. | F. | Y'g | | Disease parotid. | | | | |
| 61 | Peugnet, Eugene (Fordham). | N. Y. Med. Rec., vol. xi. 1876; Letter from Drs. Katzenbach & Peugnet. | F. | 14 | L. | Osteo-aneurism of left inf. max. | 1 year. | $\frac{1}{2}$ inch above bifur. of com. | | |
| 62 | | | do. | | | R. | | | | |
| 63 | Post, Prof. A.C., 1835. | Letter to author. | F. | 40 | R. | Prep. removal of tumor of parotid. | | | | |
| 64 | do. 1876. | do. | F. | 60 | R. | do. | | | | |
| 65 | Richard, 1855. | Arch. Klin. Chir., Bd. 17, p. 624; Madelung; Longworth. | M. | | | Traumatic aneurism near parotid. | | Ab. 4 in. from origin. | | |

External Carotid Artery—continued.

| No. | Date of operation. | Hemorrhage occurred after op. | Lig. came away No. days aft. op. | RESULT. | | | REMARKS. |
|-----|--------------------|-------------------------------|----------------------------------|------------|------------|----------------------------------------|-----------------------------------------------------------------------------------------------------------------------------------------------------------------------------------------------------------------------------------------------------------------------------------------------------------------------------------------------------------------------------------------------------------------------------------------------------------------------------------------------------------------------------------------------------------------------------------------------------------------------------------|
| | | | | Recovery. | Condition. | Cause of death, date after op. | |
| 38 | March 11, 1854. | | 15 | Recovered. | Cured. | | |
| 39 | do. | | 15 | Recovered. | Cured. | | |
| 40 | March 21, 1854. | | 18 | Recovered. | Cured. | | |
| 41 | 1854. | | | Recovered. | Cured. | | |
| 42 | 1854. | | | Recovered. | Cured. | | |
| 43 | March 28, 1854. | | | Recovered. | ? | | (This case is reported as cured, but as the patient was lost sight of 33 days after operation, I think it is not safe to consider it as a cure.— <i>Author.</i>) |
| 44 | do. | | | Recovered. | ? | | |
| 45 | 1856. | | | Recovered. | Not cured. | | |
| 46 | 1856. | | | Recovered. | Not cured. | | |
| 47 | | | 18 | Recovered. | Cured. | | (It is not certain that this case belongs to Maisonneuve.— <i>Author.</i>) |
| 48 | June, 1835. | After. | | | | Died. Hem. and cerebral complications. | <i>Lig. of external carotid did not arrest hem., and common trunk was tied; 2d day after this convulsions, and death in 6 days.</i> |
| 49 | | | 5 | Recovered. | Cured. | | Part of tumor ligatured also, and part cut away and <i>nitrate of silver</i> applied. |
| 50 | Nov. 26, 1863. | After. | | | | 21st day. | <i>Ext. carotid tied, but failed to arrest hemorrhage; 19 days after, common was tied, and death followed in 2 days.</i> |
| 51 | 1831. | | 12 | Recovered. | Not cured. | | Died 1½ year later from disease. |
| 52 | | | 17 | Recovered. | ? | | In removal of tumor the jug. was tied and facial nerve divided. |
| 53 | | | | Recovered. | ? | | Internal carotid was also tied, and it was thought that the spinal accessory and pneumogastric nerves were divided. |
| 54 | | | | Recovered. | Cured. | | |
| 55 | | | | Recovered. | Cured. | | |
| 56 | 1858. | 10, 11, 18, 19 day aft. op. | | Recovered. | Not cured. | | The disease returned; 2 ligatures applied, and vessel divided between them. |
| 57 | | | 21 | Recovered. | | | |
| 58 | June 27, 1864. | | | | | 3d day. | |
| 59 | July 12, 1838. | None. | 16 | Recovered. | Cured. | | |
| 60 | | | | Recovered. | Cured. | | |
| 61 | July 16, 1875. | 5, 6, 7, 8 and 9 days. | | | | | After 1st operation hem. from aneurism on 21st, 22d, and 2d July, and from seat of ligature on 24th, which was controlled by pressure on common carotid of same side. Next day there was hem. again from the aneurism in mouth, and the common carotid of the opposite side was tied; the hem. was not arrested and the patient died. Autopsy showed that the internal carotid on right side was absent, the common taking the distribution of the external, which it in reality was. (There is but one other such anomalous arrangement of the carotid on record. This I found in the dissecting room in 1876.— <i>Author.</i>) |
| 62 | July 28, 1875. | After. | | | | 2 days. Hem. | |
| 63 | 1855. | None. | | Recovered. | Cured. | | |
| 64 | 1876. | None. | | Recovered. | Cured. | | |
| 65 | 1855. | | | Recovered. | Cured. | | |

Ligature of the

| No. | Name of operator. | Source of information. | PATIENT. | | | Cause of operation. | Duration of cause. | Point of deligation. | Date of injury. | Date of hemorrhage. |
|-----|-----------------------------|---------------------------------------------------------------------------------|----------|----------|-------|----------------------------------------------------|--------------------|----------------------------------|-----------------|---------------------|
| | | | Sex | Age. | Side. | | | | | |
| 66 | Richet, 1861. | L'Union Med., xii. p. 45, 1861; Dr. Madelung. | M. | 42 | L. | Parotid tumor. | | | | |
| 67 | Roser, 1856. | Arch. Klin. Chir., Bd. 17; Madelung (cit.). | F. | | R. | Varicose aneur. of left ear. | | | | |
| 68 | do. | do. | | | | Carcinoma of parotid. | | | | |
| 69 | do. | do. | | | | Facial neuralgia. | | | | |
| 70 | do. | do. | | | | do. | | | | |
| 71 | do. | do. | | | | do. | | | | |
| 72 | Sands, Prof. H. B., 1872. | Personally to author. | M. | 53 | L. | Secondary hem. rem. inf. max. | | | | |
| 73 | do. 1874. | do. | M. | 50 | | Secondary hem. removal of diseased parotid. | | Below digastric. | | |
| 74 | Santesson, 1863. | Arch. Klin. Chir., 1868; Dr. C. Pilz. | F. | 18 | R. | Removal of tumor of parotid; hem. | Few minutes | | | |
| 75 | Sédillot. | Longworth Prize Thesis; Madelung (op. cit.). | | | | Vascular growth of head and face. | | | | |
| 76 | Scott, 1830. | Lond. Med. Gaz., vol. vii. p. 286. | M. | 48 | R. | Prep. to removal of sup. max. for osteo-sarcoma. | | At digastric. | | |
| 77 | Smith, Prof. Stephen, 1864. | N. Y. Med. Jr., Jan. 1874. | | | L. | Hem. cancer. disease. | | Just above origin. | | |
| 78 | Unknown, 1863. | Med. Surg. Hist. Reb.; Dr. G. A. Otis. | M. | Mid age. | | Shot wound inf. maxilla. | | | June 25. | |
| 79 | do. 1862. | do. | M. | do. | R. | Shot w'nd malar bone. | | | Sept. 14. | |
| 80 | do. | do. | M. | do. | R. | Shot wound sup. maxilla. | | | Sept. 14. | Sept. 1 |
| 81 | do. 1864. | do. | M. | do. | L. | Shot wound zygomatic region. | | | June 6. | 6th and 7th. |
| 82 | do. by Larry. | Longworth Prize Thesis. | | | | Wound of external carotid. | | | | |
| 83 | do. | Madelung (cit.). | | | | Removal scirrhous of ear. | | | | |
| 84 | Vanzetti, 1846. | Arch. Klin. Chir., Bd. 17, p. 720; Dr. Madelung. | M. | 23 | R. | Enlarged parotid. | | | | |
| 85 | Verneuil. | Lancet, Nov. 4, 1871, p. 644. | M. | | | Shot w'nd cheek. | 21 days. | | | |
| 86 | do. 1870. | Gaz. Heb., Nov. 10, 1876, p. 709. | M. | 32 | | Prep. to removal of osteo-sarcoma of inf. maxilla. | | | | |
| 87 | Wallace, 1833. | Arch. Klin. Chir., Bd. 17; Madelung; Longworth; Lancet, 1833-4, vol. i. p. 849. | F. | 13 | R. | Nævus of right cheek. | | | | |
| 88 | Weber, C. O. | Dr. Madelung. | | | | Parotid tumor (during removal). | | | | |
| 89 | Widmer, 1838. | Dr. Madelung; Longworth (cit.). | | | | do. | | | | |
| 90 | Wutzer, 1841. | do. | M. | 41 | L. | Fung. of palate. | | $\frac{1}{2}$ inch above origin. | | |
| 91 | do. 1847. | do. | M. | 38 | R. | Fung. of neck and fauces. | | Below digastric. | | |

External Carotid Artery—continued.

| No. | Date of operation. | Hemorrhage occurred after op. | Lig. came away No days aft. op. | RESULT. | | | REMARKS. |
|-----|--------------------------------|-------------------------------|---------------------------------|------------|------------|---------------------------------------|--------------------------------------------------------------------------------------------------------------------------------------------------------------------------------------------------------------------------------------------------------------------|
| | | | | Recovery. | Condition. | Cause of death, date after op. | |
| 66 | 1861. | | | Recovered. | Cured. | | |
| 67 | 1856. | | | Recovered. | Cured. | | Several smaller vessels tied same time. |
| 68 | | | | Recovered. | Cured. | | Patient went home 6 days after operation. |
| 69 | | | | Recovered. | No relief. | | |
| 70 | | | | Recovered. | No relief. | | |
| 71 | | | | Recovered. | Cured. | | |
| 72 | Oct. 22, 1872. | None from ext. carotid. | | Recovered. | Cured. | | During removal of lower jaw for malignant disease, the <i>external carotid</i> and <i>internal jugular vein</i> were secured. About 10 days later severe hemorrhages occurred from ulceration of <i>internal carotid</i> , and it, with the common, was ligatured. |
| 73 | Jan. 28, 1874. | None. | | Recovered. | | | The lingual was also tied. |
| 74 | Nov. 14, 1853. | | | Recovered. | Cured. | | Ligature <i>en masse</i> with <i>internal carotid</i> . |
| 75 | | None. | | Recovered. | | | Two ligatures; artery divided between them. |
| 76 | Nov. 17, 1830. | None. | | Recovered. | Cured. | | |
| 77 | 1864. | | | Recovered. | | | Internal carotid tied same time. Patient died of extension of disease. |
| 78 | July 5, 1863. July 8, 1863. | Once; artery retied. | | Recovered. | | | Artery tied on account of hem. Patient was rated as "totally disabled." (In all probability he was disabled from wound, not from the ligature of the external carotid.)— <i>Author</i> . |
| 79 | Sept. 22, 1862. | | | Recovered. | | | |
| 80 | Sept. 15, 1832. | | | Recovered. | | | |
| 81 | June 7, 1864. | | | | | 12 days. ? | |
| 82 | | | | Recovered. | Cured. | | |
| 83 | | | | Recovered. | | | (NOTE.—Dr. Madelung gives one other case by an unknown surgeon, in which the common and external carotids were tied. As Dupuytren thinks this case is uncertain, I have left it out.— <i>Author</i> .) |
| 84 | | | | Recovered. | Cured. | | |
| 85 | | | | | | 42 hours. Coma. | Internal and external in common loop. The common carotid tied same time. |
| 86 | Jan. 19, 1870. | 16, 17 days. | | | | 19th day after ext. 2d day after com. | Hem. 17th day. Common tied; death. |
| 87 | | None. | 15 | Recovered. | Improved. | | |
| 88 | | | | Recovered. | Cured. | | |
| 89 | | | | Recovered. | | | 2 ligatures to artery. |
| 90 | | Once. | (?) 19-22 | Recovered. | | | Hem. after operation from the occipitalis. |
| 91 | | | 16 | Recovered. | | | |



SUMMARY OF THE SURGICAL HISTORY
OF THE
COMMON, EXTERNAL, AND INTERNAL CAROTID
ARTERIES.

SECTION 1.

Sex.—The statistics contain 789 cases of ligature of the Common Carotid. The sex is stated in 712. Males, 538. Females, 174. Three males being exposed to accidents, or suffering from lesions, necessitating this operation, to one of the opposite sex.

Age.—The age is stated in 542 of 789 instances as follows:—

| | |
|------------------------------|-----|
| Under 1 year old | 16 |
| From 1 to 10 years | 22 |
| “ 10 “ 20 “ | 57 |
| “ 20 “ 30 “ | 151 |
| “ 30 “ 40 “ | 106 |
| “ 40 “ 50 “ | 89 |
| “ 50 “ 60 “ | 55 |
| “ 60 “ 70 “ | 40 |
| “ 70 “ 80 “ | 6 |
| | 542 |

The oldest patient was 75 years; the youngest 6 months of age. In the period of life from 20 to 40, about one-half of the operations were performed.

Side.—Of the 651 cases noted as to this feature—

| | | | |
|-----|----------------|-----------|--------|
| 361 | were tied upon | the right | side. |
| 290 | “ | “ | left “ |

The difference in favor of the right side may be explained, inasmuch as the *carotid* of this side is often involved in lesions of the *right subclavian*, which last vessel is often the seat of injuries result-

ing from the use by preference of the right arm, also in aneurism of the innominate.

The *point of deligation* was at the omo-hyoid muscle (its anterior belly) in the vast majority of cases, although not stated. It is given as—

| | |
|----------------------------------|----|
| Above the omo-hyoid in | 56 |
| At “ “ “ | 4 |
| Below “ “ “ | 25 |

The remainder not definitely stated. In one case (No. 789) the left carotid was reached from behind the sterno mastoid.

Hemorrhage is given as occurring after the operation of deligation in 144 instances. Unfortunately meagreness of detail in the published reports renders it impossible for me to specify whether the bleeding was at the seat of ligature or beyond it, in every instance.

In 27 instances it is specified that *no hemorrhage* occurred after the ligature was applied. If there was or was not hemorrhage after deligation, in the 618 remaining cases, it is not specified.

If we admit that in these 618 cases *no bleeding took place*, we would have only 18 per cent. of hemorrhage after ligature of the *common carotid*. But when we are reminded that many cases proved fatal so soon after the operation that secondary hemorrhage had not the time to occur (the dates of death, in which 288 of the 323 fatal cases are given, show that $\frac{1}{2}$ died on the day of operation, $\frac{1}{4}$ within the third day after, and $\frac{1}{2}$ within the first week), and that the hemorrhage did occur in a fair number of cases in which it is not reported, it is evident that this accident after ligature of the *common carotid* will occur in a much larger proportion of cases than 18 per cent.

| | |
|--------------------------------------------------------|----------|
| Hemorrhage was immediate after deligation in | 3 cases. |
| “ occurred in from 1 to 5 days “ | 19 “ |
| “ “ “ 5 “ 10 “ “ | 13 “ |
| “ “ “ 10 “ 20 “ “ | 23 “ |
| “ “ “ 20 “ 40 “ “ | 10 “ |
| “ “ “ 40 “ 80 “ “ | 7 “ |
| “ “ “ 80 “ 100 “ “ | 1 “ |
| “ “ on 120th day | 1 “ |
| “ “ “ 11th, 14th, and 61st day in | 1 “ |
| “ “ with no date given in | 66 “ |
| | 144 |

LIGATURE CAME AWAY.

The date of separation of the ligature is obtained in 287 instances as follows:—

| | | | | | | | | | |
|--------|---------|---|---|----|--------|---------|---|---|---|
| On the | 4th day | . | . | 1 | On the | 23d day | . | . | 9 |
| | 5 " | . | . | 1 | | 24 " | . | . | 4 |
| | 7 " | . | . | 4 | | 25 " | . | . | 5 |
| | 8 " | . | . | 5 | | 26 " | . | . | 3 |
| | 9 " | . | . | 6 | | 27 " | . | . | 5 |
| | 10 " | . | . | 10 | | 28 " | . | . | 7 |
| | 11 " | . | . | 12 | | 29 " | . | . | 3 |
| | 12 " | . | . | 19 | | 30 " | . | . | 3 |
| | 13 " | . | . | 25 | | 31 " | . | . | 1 |
| | 14 " | . | . | 34 | | 33 " | . | . | 2 |
| | 15 " | . | . | 16 | | 34 " | . | . | 1 |
| | 16 " | . | . | 12 | | 35 " | . | . | 2 |
| | 17 " | . | . | 14 | | 36 " | . | . | 1 |
| | 18 " | . | . | 17 | | 39 " | . | . | 1 |
| | 19 " | . | . | 7 | | 45 " | . | . | 1 |
| | 20 " | . | . | 9 | | 48 " | . | . | 1 |
| | 21 " | . | . | 23 | | 60 " | . | . | 1 |
| | 22 " | . | . | 11 | | 96 " | . | . | 1 |

One is given as not having come away at the end of three months.

In some few of the later dated cases the "Lister carbolized catgut" was used as the ligature, and these never came away, being cut off, left in the wound, and absorbed. In two cases the artery was "constricted," once with Dr. Speir's *constrictor* and once with a thread.¹

RESULT.

Of 789 cases in which the common carotid was tied for all causes, 323, or 41 per cent., died.

Condition after Recovery.—466 patients *recovered*, as reported by the operator, and the *condition* is stated in 371 of these, as follows:—

| | | | | | | | | | | |
|--------------------------------------------------------------------------------------------|---|---|---|---|---|---|---|---|---|-----|
| As cured | . | . | . | . | . | . | . | . | . | 253 |
| " improved | . | . | . | . | . | . | . | . | . | 49 |
| " temporarily benefited | . | . | . | . | . | . | . | . | . | 14 |
| " not cured | . | . | . | . | . | . | . | . | . | 33 |
| Cured of original disease, but with paralysis of opposite side as a result of the ligature | . | . | . | . | . | . | . | . | . | 2 |
| As not benefited | . | . | . | . | . | . | . | . | . | 19 |
| " worse than ever | . | . | . | . | . | . | . | . | . | 1 |

Of the reported cases 68 per cent. were *cured*, in the true sense of that term, and it is probable that this percentage will represent the correct proportion of *cures* in the entire number of recoveries.

¹ In Porcher's case (see Appendix to Common Carotid Statistics), catgut ligature was used, which became loose, and the artery was not occluded.

DATE OF DEATH AFTER DELIGATION.

Of 323 fatal cases in the total of 789, death occurred—

| | |
|-----------------------------------------------|--------------|
| Immediately ("upon the table") in | 4 instances. |
| On the same day of the operation in | 18 " |
| From 1 to 3 days after in | 43 " |
| " 3 " 7 " " | 64 " |
| " 7 " 14 " " | 57 " |
| " 14 " 21 " " | 40 " |
| " 21 " 28 " " | 12 " |
| " 28 " 35 " " | 10 " |
| " 35 " 42 " " | 9 " |
| " 42 " 50 " " | 9 " |
| " 50 " 60 " " | 3 " |
| " 60 " 70 " " | 9 " |
| " 70 " 80 " " | 4 " |
| " 80 " 90 " " | 1 " |
| " 100 " 120 " " | 2 " |
| " 120 " 150 " " | 2 " |
| Several weeks after | 1 " |
| No date given | 35 " |
| | <u>323</u> |

Or $7\frac{1}{2}$ per cent. died within 24 hours, 23 per cent. within 3 days, 45 per cent. within 1 week, 64 per cent. within 14 days, and 75 per cent. within 21 days of the date of operation of deligation.

CAUSE OF DEATH.

In only 200 of the 323 fatal cases is the *cause* of death stated.

| | |
|---------------------------------------------------------------------------------|-----------|
| From cerebral complications alone, following the ligature, there died | 54 cases. |
| From cerebral complications, with "exhaustion" | 4 " |
| " " hemorrhage | 6 " |
| " " injury or shock | 1 " |
| " " pyæmia | 1 " |
| " " original disease | 2 " |
| " " gastric fever | 1 " |
| From meningitis | 1 " |
| " " with hemorrhage | 1 " |

Thus of 200 fatal cases, 27 per cent. died from interference with the functions of the cerebrum alone, by cutting off the supply of blood through one or both *common carotids*.

While in 15 additional instances ($7\frac{1}{2}$ per cent.) interference with the cerebral circulation was an important factor of death.

This point demands the most earnest consideration. I do not think it has heretofore been *emphasized* sufficiently. I hold it to be an overwhelming argument against tying the *common carotid*, when the lesion is in the *external carotid* or its branches, at a point sufficiently removed from the bifurcation of the *primitive carotid* to allow the ligature on the cardiac side.

This will be more fully shown in the comparison of the summaries of the external, with that of the common carotid.

HEMORRHAGE AS A CAUSE OF DEATH.

Of 200 cases in which the *cause* of a fatal result is stated—

| | |
|-------------------------------------------------------|----|
| Died from hemorrhage alone from the carotid | 44 |
| “ “ with “exhaustion” | 12 |
| “ “ “ shock | 2 |
| “ “ “ inflammation of thoracic viscera | 2 |
| “ “ “ erysipelas | 1 |
| “ “ “ spasm of the glottis | 1 |
| “ “ “ diarrhœa | 1 |
| “ “ “ asphyxia | 3 |
| | 66 |

This gives a ratio of mortality of 22 per cent. from *hemorrhage alone* after the ligature, while in 33 per cent. (22 additional cases) bleeding was a factor of death, following the deligation.

(Indirect and fatal hemorrhage came from the vertebral in several instances, from the jugular vein in 2, and from the lungs in one instance.)

“EXHAUSTION” AS A CAUSE OF DEATH.

From exhaustion alone there died 23 cases.

This vague term may imply cerebral interference, hemorrhage, suppuration, etc., and is necessarily useless, unless the particular cause of the *exhaustion* is also given. (See Hemorrhage and Cerebral Complications for *other* cases in which “Exhaustion” is noted as a factor of death.)

| | |
|------------------------------------------------------------------------------------------------------------|----------|
| The original disease for the cure of which the operation was performed was the cause of death in | 7 cases. |
| Intercurrent disease was the cause of death in | 3 “ |
| Pyæmia alone “ “ “ | 12 “ |
| “ with pleuritis “ “ | 1 “ |

| | | | |
|---------------------------------------------------------------------------|---|---|-----|
| Inflammation of thoracic viscera alone was the cause of death in 4 cases. | | | |
| Tetanus alone | “ | “ | 1 “ |
| Glossitis alone | “ | “ | 1 “ |
| Edema of the glottis alone | “ | “ | 2 “ |
| Diarrhœa alone | “ | “ | 1 “ |
| Asphyxia alone | “ | “ | 3 “ |
| Inflammation of aneurismal sac | “ | “ | 2 “ |

CASES IN WHICH SYMPTOMS OF CEREBRAL DISTURBANCE WERE NOTED AS A RESULT OF TYING THE COMMON CAROTID ARTERY (FATAL AND NON-FATAL CASES).

| | |
|---------------------------------------------------------------------------------------------------------|-----------|
| Hemiplegia opposite to side of ligature is noted in | 43 cases. |
| “ “ “ “ with aphasia | 1 “ |
| “ on same side as ligature is noted in | 1 “ |
| Paralysis of face on same side, and of body on side opposite to that of ligature, is noted in | 2 “ |
| Paralysis of opposite arm (none of leg) in | 5 “ |
| Imbecility as result of ligature in | 1 “ |

Delirium, convulsions, headache, and other light symptoms of cerebral disturbance (not counting difficult deglutition which was in most cases a mechanical hindrance) occurred in 18 other instances.

If then it is accepted that paralysis followed ligature of the common carotid in only 52 of the 789 given cases, we have not quite 7 per cent. in which we may expect this danger to ensue.

It is very important in this connection to remember that $7\frac{1}{2}$ per cent. of the 323 fatal cases terminated within a few minutes to 24 hours after the deligation; 23 per cent. inside of three days; 45 per cent. within one week; 64 per cent. within 14 days; 75 per cent. within 21 days, and that after either of these dates paralysis might have resulted.

Secondly, remember that paralysis very likely did occur in some of the cases to which no history proper is attached.

Thirdly, that paralytic symptoms would probably not be recognized in patients operated upon in conditions of extreme prostration, when both motion and intelligence were suspended.

Taking these points into consideration, I am of the opinion that a larger percentage than that given in the foregoing summary should be present in the mind of the operator who has the choice between deligation of the common and external carotids.

In exceptional cases paralysis will remain after recovery from the operation as a permanent malady.

In 42 cases of the entire statistics it is noted that there were “no symptoms of cerebral disturbance.”

REPORT OF AUTOPSY.

Post-mortem examinations were reported in only 85 of the 323 fatal instances. In 18 of these the brain was not examined.

The points of interest in connection with this organ are as follows:

| | |
|--------------------------------------|----|
| Brain, softened in | 16 |
| “ inflamed | 8 |
| “ anæmia of | 1 |
| “ extravasation of, blood | 1 |
| “ abscess of | 7 |
| “ “ and softening | 1 |
| | 34 |

Showing that in 67 examinations of the brain 51 per cent. developed important changes to have occurred.

SYNOPSIS OF LIGATURE OF THE COMMON CAROTID WITH ONE OR MORE OF ITS BRANCHES, OR OF THE INTERNAL JUGULAR VEIN.

Common, external, and internal carotids tied in the same patient. Died 2; cured 2 = 4 cases.

Common, external, and internal carotids, and the internal jugular. Died 1; recovered 1 = 2 cases.

Common and internal carotids in same case. Died 4; cured 2 = 6 cases.

Common and external carotids in same case. Died 5; recovered 4; cured 3 = 9 cases.

Common carotid and internal jugular vein. Died 7; recovered 2; cured, 1 = 9 cases.

Common carotid and external and internal carotid and sup. thyroid. Died 1 = 1 case.

Common carotid and sup. thyroid. Died 1; cured 1 = cases 2.

“ “ “ lingual. Died 1 = 1 case.

“ “ temporal, auric., and occipital. Recovered 1 = 1 case.

“ “ and internal maxillary. Recovered 1; cured 1 = 2 cases.

“ “ “ temporal. Recovered 1 = 1 case.

RE-LIGATURE OF THE COMMON CAROTID.

The same vessel was twice tied in 8 instances. Of these 6 died.

The same vessel was tied a third time to arrest hemorrhage. It proved fatal.

SYNOPSIS OF CASES IN WHICH BOTH COMMON CAROTIDS WERE TIED.

| CAUSE. | Age, yrs. | Interval. | Result. | Cause of death. | Operator. |
|-----------------------|-----------|-----------|-------------------|-----------------|-----------------------------|
| Malig. dis. antrum. | 53 | 2½ mos. | Died 38th day. | Exhaustion. | Wood. |
| “ “ | 45 | 1 “ | Rec. (Not imp'd.) | | Parker. |
| “ “ | 38 | 28 days. | “ improved. | | “ |
| “ “ | 21 | 8 mos. | “ “ | | V. Mott. |
| “ nose. | ? | 10 “ | “ cured. | | “ |
| “ orbit. | ? | 5 “ | Died 4th day. | | “ |
| “ parotid. | ? | 15 min. | “ 48 hours. | Coma. | “ |
| Fungus hæmat. | 15 | 3 weeks. | Recovered. | | Blackman. |
| Aneur. anast. | 5½ | 4 mos. | “ | | Gundelach and Moeller. |
| “ occiput. | 53 | 2½ “ | “ cured. | | Kuhl. |
| “ “ | 20 | 1 year. | “ “ | | Pirogoff. |
| Pulsat. tumor, orbit. | 20 | 28 days. | “ “ | | Foote. |
| “ both orbits. | ? | 30 “ | “ better. | | Macgill. |
| Aneur. orbit. | 22 | 14 mos. | “ cured. | | Buck. |
| Erect. tumor, face. | 23 | 30 days. | “ better. | | Warren. |
| “ ear. | 19 | 1 year. | Died 3d day. | Exhaustion. | Ullmann. |
| “ frontal. | 19 | 8 mos. | Recov'd; better. | | Roberts. |
| “ head. | 11 | 6 years. | “ not cured. | | Van Buren. |
| “ scalp. | 20 | 14 mos. | “ better. | | Mussey. |
| Elephantiasis, face. | 34 | 6 “ | “ “ | | Carnochan. |
| Hem. polypus nose. | 19 | 13 “ | “ “ | | Paul F. Eve and V. Mott. |
| “ internal carotid. | 27 | 13 days. | Died 3d day. | Hem.; coma. | Billroth. |
| “ shot wound. | 21 | 4 “ | Recov'd; cured. | | Ellis. |
| “ “ | ? | same d'y | Died same day. | ? | Unknown. |
| “ “ | ? | 3 days. | “ 5th day. | Hemorrhage. | Murdock. |
| “ “ | ? | 6 “ | “ 38 hours. | ? | Longmore. |
| “ “ | ? | 4 “ | “ 5th day. | ? | Lewis. |
| Epilepsy. | 20 | 17 “ | Recov'd; better. | | Weber. |
| “ “ | ? | 6 mos. | “ “ | | V. Mott. |
| “ “ | 18 | 6 “ | “ cured. | | Hamilton. |
| “ and hemipl. | 51 | 2½ “ | “ no better | | Preston. |
| Paralysis. | 24 | 1½ “ | “ better. | | “ |
| Unknown. | 4½ | 4 “ | “ cured. | | Müller. |

Total, 33. Died 9, or 27 per cent. Of the 24 recoveries, 8 are noted as cured, 11 as improved, 2 as no better, and 1 as not cured.

Of the 9 fatal cases, 4 were for gunshot wounds and 1 for hemorrhage.

The intervals in these 9 cases were, respectively, same day, 3, 4, 6, and 13 days, 15 minutes, 2½ months, 5 months, and 1 year.

It is impossible not to be impressed with the comparatively light mortality following so formidable an operation.

Among the most dangerous complications of ligature of the common carotid is the following, which relates to ligature of the right subclavian, the operations being *simultaneous* or with a varying *interval*.

SIMULTANEOUS LIGATURE OF COMMON CAROTID AND SUBCLAVIAN
ON THE RIGHT SIDE. (FIRST DIVISION.)

| | | | | |
|--------------------------------|------|------|------|------------------|
| Liston, subclavian aneurism, | Died | 13th | day. | hemorrhage. |
| Rossi, innominate | " | 6th | " | cerebral anæmia. |
| Parker, subclavian | " | 42d | " | hemorrhage. |
| Hobart, aortic | " | 16th | " | " |
| Cuvellier, bayonet wound | " | 10th | " | " |
| Kuhl, vas. tum. frontal region | " | 2d | " | not known. |

Of the 4 cases in which hemorrhage was the cause of death, the bleeding came from the *subclavian* in 3, from the *carotid* in one case.

SIMULTANEOUS LIGATURE OF COMMON CAROTID AND SUBCLAVIAN
ARTERIES ON THE RIGHT SIDE (THE LATTER IN ITS THIRD DIVISION).

| | | | | |
|----------------------------------------------------------|------|-----------|------|-----------------------------------------|
| Durham, innominate aneurism, | Died | 6th | day, | shock. |
| Eliot, | " | 25th | " | hemorrhage. |
| Ensor, aortic and | " | 65th | " | " |
| Holmes, innominate | " | 57th | " | " |
| Hodges, | " | 11th | " | " |
| Weir, | " | 11th | " | " |
| Maunder | " | few days | | (?) |
| Sands, aortic | " | recorded. | | (Died 13 months later from aneurism.) |
| Heath, innominate | " | " | | (Died 4 years later from the aneurism.) |
| Lane, | " | " | | (No improvement.) |
| Little " or aortic | " | " | | Probable cure, 1 year later doing well. |
| Barwell, ¹ innom. aortic, carot. and subclav. | " | 3 mos. | " | " |

(Hemorrhage occurred from the carotid in *one* of these cases.)

CASES IN WHICH THE CAROTID WAS FIRST TIED AND THE SUBCLAVIAN
IN ITS THIRD DIVISION AT A LATER PERIOD.

| | | | | |
|--------------------------------------------------------|-------------------|-----------|------|-------------------------------------------------|
| Bickersteth, aneurism innom. and aorta. | Died ² | 21st | day; | suffocation. Carotid tied 7 weeks previously. |
| Wickham, aneurism innominate. | Died ² | 3 months. | | Carotid tied 3 mos. before. |
| Speir, aneur. aorta. | Died | 32 days; | hem. | Carotid "constricted" 2 days before. |
| Fearn, aneur. innom. | Recovered; | | | much improved. Carotid tied 2 years before. |
| Doughty, ³ A. B. Mott, aneurism innominate. | Recovered; | | | cured. Carotid tied one year before subclavian. |

¹ Barwell's case died of pneumonia and bronchitis, and other complications, three months and ten days after the operation. (See Carotid History.)

² In these last five cases death is dated from the deligation of the subclavian.

³ Prof. Mott tied the subclavian in 1876.

Of the 23 instances in which the right common carotid and right subclavian arteries have been tied, 16 proved fatal; 7 recovered, in *one* of which "no improvement" was reported, and in 3 of these 7 a cure is probable.¹

I would conclude from the above: 1st. That ligature of the carotid and subclavian (in its first division) should not be performed.

2d. That it will prove safer to tie the carotid first (when it shall be deemed necessary to tie both vessels in the treatment of aneurism), in order to relieve the sac from the danger of rupture to which it would be exposed by the sudden stoppage of the two great vessels connected with it, before the collateral circulation may have been partially established.

3d. That the subclavian should be tied in its third surgical division.

LIGATURE OF THE RIGHT CAROTID AND THE INNOMINATE.

This has been performed twice. Once by Smythe of New Orleans. The patient lived 10 years, and died of the original aneurism, which again formed by the reverse collateral circulation.

A second time by A. B. Mott. The patient died soon after, of hemorrhage into the thorax, the sac bursting. The vertebrals were tied in both cases.

SECTION 2.

A SPECIAL SUMMARY OF THE HISTORY OF THE COMMON CAROTID ARTERY.

Classification of the various Lesions for which the operation was made.

SPECIAL SUBJECT: WOUNDS.

Divided into—

1. Lacerated.
 - a. Gunshot wounds of military practice.
 - b. Gunshot wounds of civil practice.
 - c. Torn wounds other than gunshot.
2. Punctured.
3. Incised.
4. Wounds, the nature of which is not given.

¹ For further remarks on these cases the reader is referred to the *résumé* of the subclavian arteries.

Lacerated Wounds.

The common carotid artery was tied in 134 instances on account of the above lesions. Of these, 87 proved fatal, or 65 per cent.

Gunshot Wounds of Military Practice.

| | | | |
|-----------------------------|----------|--------|-------------|
| Of cranial region | Total 10 | Died 5 | Recovered 5 |
| “ face alone | “ 53 | “ 36 | “ 17 |
| “ face and neck | “ 15 | “ 14 | “ 1 |
| “ neck alone | “ 18 | “ 17 | “ 1 |
| “ region not stated | “ 15 | “ 9 | “ 6 |
| | 111 | 81 | 30 |

Fatal in 73 per cent.

That cranial wounds appear to be not more fatal is probably owing to the fact that when these wounds are serious they are fatal before assistance can be had; when not penetrating, the hemorrhage is not usually dangerous, and the disturbance is not so great as the terrible lacerations of the neck and face. Naturally the result shows that shot wounds of the face alone are less fatal than those of the neck.

Gunshot Wounds of Civil Practice.

| | | | |
|---------------------------|---------|--------|-------------|
| Of the neck alone | Total 5 | Died 1 | Recovered 4 |
| “ “ face “ | “ 7 | “ 1 | “ 6 |
| “ “ neck and face | “ 1 | “ 0 | “ 1 |
| No region given | “ 3 | “ 2 | “ 1 |
| | 16 | 4 | 12 |

Fatal in 25 per cent.

Difference in favor of civil practice 48 per cent.

Reasons. 1. Military projectiles are larger. Have greater velocity. Cause greater destruction of tissues and more shock.

2. The soldier is excited, the circulation at its height; as a consequence his wounds bleed more freely than an *accidental wound*, as are most of those in civil experience. The exigencies of battle prevent him receiving that prompt attention usually bestowed upon the civilian. By the time the surgeon reaches him and ties his “common carotid,” he is already so prostrated by hemorrhage that he either does not rally, or dies from cerebral inanition.

Lacerated Wounds (not Gunshot).

| | | | |
|---------------------------|---------|--------|-------------|
| Of face | Total 1 | Died 1 | Recovered 0 |
| Of face (arrow) | “ 1 | “ 0 | “ 1 |
| Of throat | “ 5 | “ 1 | “ 4 |
| | 7 | 2 | 5 |

Fatal in 28 per cent.

These were all in civil practice. (In Abernethy's (fatal) case the laceration by cow's horn was very violent and extensive.)

Punctured Wounds.

Total number of cases 33: died 15, recovered 18; rate of mortality according to this result, 45 per cent. These wounds were situated mostly in the upper portion of the neck. In 5 of the fatal cases the mistake was made of tying the common carotid *when the lesion was in the vertebral*,¹ the hemorrhage being supposed to be from the branches of the former.

To arrive at a better idea of the rate of mortality following ligation of the *common carotid* for punctured wounds, we must exclude from the calculation 5 of the fatal cases, leaving a death-rate of 36 per cent. I consider even this as a high rate of mortality, since *punctured wounds* as a rule do not cause profuse hemorrhage, extensive destruction of tissue, or great shock. Doubtless, some of these cases would have been successful if both ends of the bleeding vessel had been secured in the original wound.

Incised Wounds.

Under this heading there are 18 cases: died 8, recovered 10; mortality 44 per cent.

Wounds, the Nature of which is not given.

Total of this class 46: died 21, recovered 25; mortality 46 per cent.

The common carotid was tied on account of wounds (other than gunshot and lacerated) in 97 cases, of which 44 died and 53 recovered, the rate of mortality being 45 per cent.

SPECIAL SUBJECT: TUMORS.

Subdivided into ligation on account of—

1. Malignant growths (not in orbit).
2. Non-malignant growths (not in orbit).

¹ The differential diagnosis in these cases is necessarily very difficult when we consider the free anastomosis through the circle of Willis. Pressure below which only occluded the *carotid* would not arrest, but would rather increase the escape of blood from the *vertebral*, while pressure directly backward, below the transverse process of the 6th cervical, would diminish or temporarily arrest the bleeding from the *vertebral*.

3. Hemorrhage from abscess or ulcer.
 4. Removal of superior maxilla.
 5. Removal of inferior maxilla.
1. Ligature of the Common Carotid artery on account of malignant growths of the antrum of Highmore, parotid gland, of face, etc. etc. (not of orbit). Total 87: died 38, recovered 49; death-rate 44 per cent. Of the 49 recoveries, 13 are reported *cured*, 12 as *improved*, 10 as *not cured*, remainder reported as *recovered*.
 2. For (lesions) growths termed non-malignant (other than of orbit) the common carotid was tied in 75 cases. Died 30, recovered 45; death-rate 40 per cent. Of 45 recoveries, 16 are reported *cured*, 2 as *improved*, 4 as *not cured*.

It is a little surprising that the death-rate in *malignant* diseases should be no higher as compared to *non-malignant* affections. It is probable that some of the cases classed as *malignant* would have been placed with the *non-malignant* tumors, had they been investigated in the light of more recent pathology.

3. On account of hemorrhage resulting from ulcerations, abscess, etc., the *primitive carotid* was tied in 13 cases. Recovered 5, died 8; death-rate 61 per cent. All the recoveries are reported *cured*.
 4. Preparatory to or after removal of the superior maxilla. Total 11: recovered 8, died 3; mortality 28 per cent. Of the 8 recoveries, 2 are given as *cured*, 3 as *not cured*.
 5. Removal of inferior maxilla 18 cases. Recovered 12, died 6; mortality 50 per cent. 5 of the recoveries are reported *cured*.
- Summary of the foregoing 5 classes: Total 204: recovered 119, died 85; mortality 41½ per cent. Of 119 *recoveries*, 41 are reported *cured*, 14 as *improved*, 17 as *not cured*, the remainder as *recovered*.

LIGATURE OF THE COMMON CAROTID ARTERY FOR RELIEF OF ERECTILE AND PULSATING TUMORS.

1. Non-malignant.
 2. Malignant.
1. Non-malignant tumors of the orbit. Total 52 cases: recovered 46, died 6; mortality 11½ per cent. Of 46 recoveries, 28 are marked *cured*, 5 as *improved*, 6 as *not improved*.

The above result must be considered as very favorable indeed. The distance of the *diseased structures* from the seat of ligature, where the artery is in a healthy condition, and which allows a firm clot to form before the ligature cuts through, is probably an important factor of such a marked success.

2. Malignant vascular tumors of the orbit. Total 8: died 4; death-rate 50 per cent. One of the 4 recoveries is noted *cured* (the eye being extirpated at the same time), 2 are given as *not cured*.

Ligature on account of aneurism by anastomosis (other than those of the orbit). Total 71: recovered 51, died 20; death-rate 28 per cent. Of the recoveries 20 are noted *cured*, 9 as *improved*, and 16 *not cured*.

LIGATURE OF THE COMMON CAROTID FOR CURE OF ANEURISM (*i. e.* A SACCULATED BLOOD-TUMOR COMMUNICATING WITH AN ARTERY).

Subdivided into—

1. Ligature between the aneurism and the heart.
2. Ligature by mistake (the carotid tied for vertebral aneurism).
3. Ligature on the distal side of the aneurism.

1. *On the Cardiac Side of the Tumor.*

Total 106: recovered 69, died 37; death-rate 35 per cent.

Subdivided into—

- (a) For aneurism of the *external carotid* or its branches. Total 22: died 5; mortality 23 per cent. Of the 17 recoveries, 16 *cured*, 1 *improved*.
- (b) For aneurism of the *internal carotid* or its branches. Total 6: died 4; or 66 per cent. Of the 2 recoveries, 1 is reported as *cured*.
- (c) For aneurism of the common carotid alone. Total 16: died 7; mortality 44 per cent. Of 9 recoveries, 8 are given as *cured*.
- (d) For aneurism (the seat of lesion not given). Total 62: died 21; mortality 34 per cent. Of 41 recoveries, 35 are noted *cured*, 2 *improved*, and 2 as *no better*.

Summary of above. Of 69 recoveries, 60 were *cured*, and 3 are given *improved*. Rest not noted. The lesions of the *external carotid* being least fatal, those of the *internal* (as far as judged by such a small number of cases) most fatal.

2. *Ligature of the Common Carotid, for supposed Carotid, but in reality Vertebral Aneurism.*

Total 5. All fatal.

The difficulty of distinguishing vertebral from carotid aneurism in the neck arises from the fact that direct pressure from before backwards, in the lower portion of the neck, will interfere with or arrest pulsation in aneurisms of *both* vessels.

If, however, the head be flexed upon the chest, and the sternomastoid muscle thus relaxed, the *carotid* can be compressed by grasping the muscle between the thumb and finger, which are pressed deeply behind the outer and inner borders. This will not involve the vertebral.

Again; if the *carotid* be forcibly compressed by the thumb, backward and inward, low against the vertebral column, at any point above the transverse process of the 6th cervical, the *vertebral* will not be included, since it is protected by the processes.

3. *Ligature of the Common Carotid Artery on the Distal Side of the Aneurism.*

Subdivided into—

- (a) For aneurism of the arch of the aorta.
 - (b) For aneurism of the innominate.
 - (c) For aneurism of the subclavian.
 - (d) For aneurism of the carotid.
- (a) 13 cases are reported in which the aneurism was situated upon the arch of the aorta (or was supposed to be).¹ 6 died. Of the 7 *recoveries*, 5 are noted *improved*. In 4 of the 13 instances the subclavian was also tied, 3 of these 4 proving fatal. (These four were thought to be innominate.) [Nos. 8, 104, 106, 113, 274, 275, 288, 387, 495, 577, 652, 779, 784, respectively.]
- (b) Innominate aneurism, in which—
- (1) The carotid alone was tied.
 - (2) The carotid and subclavian were tied.
- (1) Total 17. Died 12, or 71 per cent. Of 5 *recoveries*, 2 are *cured*, and 2 *improved*, and 1 *not cured*. [Nos. 80, 176, 203, 210, 283, 300, 302, 315, 417, 434, 435, 542, 543, 544, 550, 715, 771.]

¹ See notice of death of Barwell's case, which terminated fatally since writing above.

- (2) Total 14. Died 10. Of the 4 *recoveries*, 2 are most probably *cured*; 1 *improved*; and 1 improved temporarily, dying in five months. [Nos. 191, 196, 200, 208, 289, 379, 591, 752, 753, 778, 781, 782, 783, 784.] (The aorta was involved also in some of these.)
- (c) Subclavian aneurism. Total 5. Recovered 1 (No. 638). In 2 cases the innominate was also tied (Nos. 638, 473). In 2 others the subclavian was also tied (Nos. 129, 358). The case (No. 638) died, about ten years later, of the old aneurism, which had disappeared and then reformed from the recurrent collateral circulation.
- (d) Aneurism of the *carotid*. Total 5. Died 2. [Nos. 77, 328, 736, 737, 757.] Cured 2; improved 1.
- (e) In 1 other case the subclavian was also tied. Recovery (No. 336), "*not cured*."

Summary of Cases of Ligature of the Common Carotid.

On account of aneurisms. Total 166 cases. *Died* 76, or 46 per cent. *Cured* 66, of 90 *recoveries*.

On cardiac side of aneurism. Total 106. *Died* 37, or 35 per cent. *Recovered* 69; *cured* 60.

On distal side of aneurism.¹ Total 60. *Died* 39, or 65 per cent. *Recovered* 21; *cured* only 6.

LIGATURE OF THE COMMON CAROTID ARTERY FOR THE RELIEF OF
NERVOUS DISORDERS.

Subdivided into—

1. Epilepsy.
2. Neuralgia.
3. Hemiplegia.
4. Headache.

1. Epilepsy. Total 20. Died 1. Mortality 5 per cent. Of the 19 *recoveries*, 3 are reported *cured*; 10 *improved* (three of these only temporarily); and 3 *not benefited*.

2. Neuralgia (of Head or Face). Total 14. Died 1. Of the 13 *recoveries*, 6 were *cured*, 4 *temporarily improved*, 1 *not benefited*.

¹ I have included here the five cases in which the vertebral was the seat of the aneurism.

3. Hemiplegia. Total 4. All recovered; three of these are *improved*; 1 *not benefited*.

4. Headache 2. Both *recovered*. Improved 1. No benefit 1.

Summary of Ligatures for Nervous Disorders.

Total 40. Died 2. Mortality 5 per cent. Of 38 recoveries, 9 were *cured*; 18 were *benefited*; no benefit in 6; condition not given in rest.

(The fact that so few of these patients died from an operation of such magnitude is probably due in great measure to the healthy condition of the artery at the seat of ligature, and also to the fact that these patients had not been exhausted by hemorrhage.)

SECTION 3.

SUMMARY OF THE SURGICAL HISTORY OF THE INTERNAL AND EXTERNAL CAROTID ARTERIES.

(a) I have found only 18 cases of ligature of the *internal carotid* in which definite results are given.

From these, nothing reliable as to the practicability of this operation can be deduced, since in only *one*¹ instance was this vessel alone the subject of deligation. In this case (No. 9) the operation was successful.

The *common* and *internal carotids* were tied in 6 cases; 3 *recovered* and were *cured*; 3 *died*.

The *external* and *internal carotids* were tied in 3 cases. All *recovered*; 1 was *cured*.

The *common*, *internal* and *external carotids* were tied in 6 cases; 3 *recovered*; 2 of these were *cured*; 3 *died*.

The *internal jugular vein* and the *internal carotid* were tied in 1 case. *Recovered*.

The *common*, *internal* and *external carotids* and the *internal jugular vein* were tied in 1 case. *Recovered*.

Summary. Total 18. Died 6, or 33 per cent. Of the 12 recoveries, 8 were *cured*; 1 *not cured*; rest noted as *recovered*.

The cause of the operation was—

| | | |
|------------------------------------------|---------|-----|
| Hemorrhage in 14 cases, of which 5 died. | | |
| Erectile tumor | 1 case, | 1 “ |
| Aneurism | 1 “ | 0 |
| | 16 | 6 |

Not given in 2.

¹ Since writing this a second case has been reported of ligature of this vessel alone. *Recovered*; *cured*. See foot-note under Statistics of Internal Carotid.

The cause of death as given is—

Pyæmia in 1 case.

Exhaustion and hemorrhage in 1 case.

“ “ shock in 1 case.

Hemorrhage alone in 1 case.

Coma alone in 1 case.

(The operation will be considered in the closing summary.)

(b) Summary of the ligatures of the external carotid. The statistics give 91 instances in which the *external carotid* artery has been ligatured.

Of these 14 died, or 15 per cent.; but in 10 of these fatal cases the *common carotid* was also tied, leaving only 4 deaths out of 81 cases in which the ligature of the *external* was not complicated with that of the *common carotid*.

If however we exclude all complications, and select only those cases in which the *external carotid alone* was tied, we will have a better idea of the result of this operation.

Of these the statistics contain 67 cases,¹ with three deaths. Rate of mortality $4\frac{1}{2}$ per cent.

These three fatal cases were gunshot wounds in military practice, accompanied by prostration and extensive injury. One died on the table from loss of blood before the operation; the cause of death is not given in the other two.

Of 64 recoveries, 31 are reported cured; 12 as not cured; and 1 as improved. Remainder not noted as to condition.

Hemorrhage after ligature in these 67 cases occurred in 5, none of which proved fatal. It was from the seat of lesion beyond the ligature in 4; the location not noted in 1 case.

Of these 67 cases the *sex* is given in 47, of which 34 were males; 13 females.

The *side of body* is given in 49 instances.² Upon the *right side* in 31; the left in 18.

Age—

| | | | | | | | |
|-------------------------------|---|---|---|---|---|---|----------|
| Between 1 and 10 years of age | . | . | . | . | . | . | 1 case. |
| “ 10 “ 20 “ “ “ | . | . | . | . | . | . | 4 cases. |
| “ 20 “ 30 “ “ “ | . | . | . | . | . | . | 5 “ |
| “ 30 “ 40 “ “ “ | . | . | . | . | . | . | 8 “ |
| “ 40 “ 50 “ “ “ | . | . | . | . | . | . | 8 “ |
| “ 50 “ 60 “ “ “ | . | . | . | . | . | . | 7 “ |
| “ 60 “ 70 “ “ “ | . | . | . | . | . | . | 3 “ |

¹ On account of the peculiarly abnormal arrangement of the bloodvessels I have omitted Dr. Peugnet's case from this summary.

² The artery was tied on both sides in the same patient in 6 instances, all of whom recovered.

The *ligatures* came away as follows (being the only cases noted as to this feature in the entire 91 histories).

| | |
|---------------------|----------------------|
| 5th day 1 | 17th day 1 |
| 7 " 1 | 18 " 4 |
| 8 " 4 | 19 " 1 |
| 10 " 2 | 20 " 1 |
| 12 " 2 | 21 " 1 |
| 13 " 1 | 22 " 1 |
| 14 " 1 | |
| 15 " 4 | Total 26 |
| 16 " 4 | |

In the 67 cases of ligature of the *external carotid alone*, the *causes of operation* were, as far as given, as follows:—

On account of tumors of the *parotid gland* (before, during, or after removal of).

Non-malignant 17; all recovered. Cured 15; not cured 1; noted as recovered 1. Malignant 3; all recovered. Not cured 2; cured 1 = 20 cases.

For affections termed *malignant* (other than those of parotid).

Fungus of palate; recovered 1. Fungus of neck and fauces; recovered 1. Sarcoma of tongue and face; recovered, not cured, 1. Carcinoma;¹ recovered, cured, 4; recovered, not cured, 2; noted as recovered 3 = 12 cases.

[If to these 12 cases are added the 3 other "malignant" cases of the *parotid*, we have 15 instances in which this artery was tied to relieve or cure so-called malignant growths, with 5 cures and no deaths.]

Gunshot wounds of lower jaw 3; recovered 2; died 1. Gunshot wounds of malar region and sup. max. 3; recovered 2; died 1. Gunshot wounds of orbit 1; died 1 = 7 cases.

| | |
|--------------------------------------------------------|---------------------|
| For wound of external carotid 2 | Recovered, cured 2. |
| " " facial artery 1 | " |
| Hemorrhage, removal of tongue 1 | " |
| " abscess of submax. region 1 | " " |
| " polypus of nose 1 | " " |
| " remov. pulsating tumor temp. 1 | " " |
| " " tumor pharynx 1 | " " |
| Aneurism in the parotid 1 | " " |
| Varicose aneurism of ear 2 | " " |
| Vascular growth (nævi, etc.) of cheek 1 | improved. |
| " " " head and face 1 | " |
| " growth ² back of head 1 | " not cured. |
| " growth ² cheek, lip, and nose 1 | " no better. |
| Removal of sup. maxilla osteo-sarcoma 1 | " cured. |
| " " " 1 | " |

¹ In three of these both carotids were tied.

² Both carotids tied.

| | | |
|--------------------------------------|---|----------------------------|
| Facial neuralgia | 1 | Recovered, no improvement. |
| “ “ | 1 | “ “ “ |
| “ “ | 1 | “ cured. ¹ |
| Cause unknown ¹ | 1 | “ cured. |
| “ “ | 1 | “ “ |

HEMORRHAGE.

Of the 91 cases given in the table, hemorrhage is stated to have occurred after ligature of the *external carotid* either at the seat of ligature or beyond it in 12 instances, or about 13 per cent.²

In 6 of these 12 it was deemed expedient to tie the *common* or *internal carotids* or both, afterwards. In *one* case the *external carotid* was re-ligatured successfully.

The remaining cases were treated by cold, astringents, or compress.

[On a previous page it is stated that hemorrhage occurred in only 5 out of 67 cases in which the *external carotid* alone was tied.]

COMPARATIVE SUMMARY AND CONCLUSIONS.

The rate of mortality after ligature of the *common carotid* artery, as given heretofore, is 41 per cent.

After ligature of the *external carotid* the death-rate is 4½ per cent.

There can be but one conclusion to this comparison. The *common carotid should never be tied for a lesion of the external carotid, or its branches, when there is room enough between the lesion and the bifurcation of the primitive carotid to permit the ligature of the external.*

I am led to this conclusion not only by the comparison of the analysis of 789 cases of ligature of the *common trunk*, with the 91 instances in which the *external carotid* was tied, but also from the analysis of 121 dissections of these vessels, made to determine the relations of these arteries and their branches to each other.

It would be a waste of time to cite the eminent authorities in surgery who advise the ligature of the *common trunk* instead of the *external*.

The teaching and practice is almost universal. It is as wrong as it is general. It is as false as it is dangerous. It is 41 per centum of deaths in the one, to 4½ per centum in the other.

¹ Double ligature.

² Dr. Feugnet's case is not included on account of the abnormal arrangement of the vessels.

This "History" carries its own proof of the generality of this practice.

I have selected out of the statistics all the instances in which the *common carotid* was tied when the *external* carotid might have been secured between its origin from the *common* trunk and the lesion.

I have omitted all cases in which meagreness of detail leaves the least doubt as to the seat of lesion, and furthermore, all the cases of malignant growths of the *antrum*, where, owing to the exaggerated nutrition of the diseased structures, the anastomosis had probably been very freely established between the *ophthalmic* and the *internal maxillary*, *facial*, and *temporal* arteries, so that ligature of the *common* trunk became the surest method of "starving out" the disease.

With these numerous omissions there were 251 out of a total of 789, and of these 108 died (or 43 per cent.).

[They are Nos. 2, 3, 4, 5, 6, 11, 13, 15, 16, 17, 19, 21, 24, 25, 27, 28, 29, 30, 40, 45, 46, 48, 49, 50, 61, 62, 63, 67, 68, 76, 78, 82, 86, 87, 88, 91, 92, 94, 99, 102, 103, 116, 123, 124, 132, 133, 134, 137, 143, 147, 148, 151, 158, 159, 168, 169, 170, 172, 173, 177, 179, 184, 186, 187, 189, 190, 192, 197, 198, 202, 209, 211, 213, 217, 223, 227, 232, 234, 237, 239, 240, 241, 246, 249, 250, 252, 254, 257, 261, 263, 265, 266, 267, 268, 269, 270, 271, 276, 279, 298, 299, 306, 313, 319, 320, 321, 338, 341, 349, 351, 352, 353, 359, 360, 361, 362, 363, 365, 368, 370, 371, 374, 378, 380, 381, 382, 384, 386, 388, 391, 393, 397, 398, 401, 403, 406, 408, 415, 416, 421, 424, 425, 428, 429, 436, 442, 443, 448, 449, 450, 451, 457, 458, 464, 468, 469, 471, 472, 486, 496, 498, 510, 512, 513, 519, 520, 525, 528, 533, 534, 535, 541, 546, 551, 553, 554, 572, 573, 575, 579, 580, 585, 586, 587, 594, 599, 603, 606, 609, 611, 615, 616, 628, 630, 634, 636, 640, 643, 644, 645, 646, 649, 656, 657, 658, 663, 664, 667, 668, 671, 672, 673, 674, 677, 678, 679, 680, 681, 683, 684, 694, 698, 699, 703, 705, 708, 710, 712, 713, 716, 733, 734, 735, 738, 739, 744, 746, 748, 751, 755, 758, 764, 765, 767, 768, 772, 773, 786, 788, 789, in the statistics.]

CONCLUSIONS.

1. In all *intra-cranial* lesions involving alone the *internal carotid* or its branches, this vessel should be tied. If this procedure is not successful, then the *external carotid* should be secured at the crossing of the digastric. If the *facial* be given off below this point, it should be secured by a separate ligature.

Since one of the dangerous results of ligature of the *common caro-*

tid is cerebral anæmia, it is evident that this danger will be partially avoided by leaving the anastomotic channel, between the *facial*, *internal maxillary*, and *temporal* branches of the *external carotid*, and the branches of the *ophthalmic* from the *internal carotid*, uninterrupted. If this collateral current should, however, prove to be an impediment to a cure, it should be stopped.

For *lesions* of the *internal carotid* in the neck (excepting aneurism) it should be tied *above* and *below* the lesion in all cases. The operation on the cardiac side alone, be the *common* or *internal* trunk the seat of the ligature, is not justifiable, death having occurred in many instances through the descending current from the circle of Willis.

In aneurism of this artery the single ligature on the cardiac side will suffice.

2. When the *lesion* (excepting aneurism) exists within one-half inch of the bifurcation of the *common carotid*, involving this vessel, or the *external* or *internal* or both, the *common* trunk must be tied on the *cardiac* side, and the other two arteries upon the *distal* side of the lesion. The *superior thyroid* and any other branches of the *external carotid*, between the ligature upon this vessel and the bifurcation, should also be secured.

In case of aneurism in either of these points the single ligature on the *cardiac* side will usually suffice.

3. In *erectile* or *pulsating tumors* of the orbit (intra-orbital aneurism) ligature of the common carotid is to be advised. The vessel should be secured at the *omo-hyoid*, a double ligature applied, the artery divided between, and each end twisted ("torsion" of Bryant). If the disease is malignant the entire contents of the orbital cavity should be removed.

Since the anastomoses between the terminal branches of the *external* and *internal* carotids, through the orbit, are more or less exaggerated in intra-orbital aneurism, and since in the 52 recorded instances of this operation (in non-malignant conditions) the death-rate was only 11½ per cent., I am of the opinion that the ligature of the *common carotid* is the surest and safest operation.

If, however, the operation of enucleation be determined upon (the eye being already destroyed), it may not be necessary to tie the *common carotid*. Pressure upon the artery of the affected side will in most cases control the hemorrhage, until the operation is completed, when the compress in the orbit will most probably control the bleeding; the danger of interfering with the intra-cranial circulation being thus avoided, or deferred until the *necessity exists*.

4. Wounds of the *superior thyroid* artery, too near its origin to permit a ligature on the cardiac side of the lesion, require deligation of the *common, external, and internal carotids*, and torsion of the *distal* end of the wounded vessel.

5. In *incised, punctured, lacerated, and gunshot* wounds of the *external carotid*, or its branches, where it is deemed inexpedient to secure the vessel at the seat of injury, the *external carotid of one or both sides should be secured*, below the origin of the *lingual* (the point of election, see Anatomy). If the *lingual* or any other branch is in immediate contact with the ligature, it (or they) should be also secured.

The *common trunk* should never be tied under such circumstances *except as a last resort*.

6. Hemorrhage of the *tonsils and pharynx*, if not arrested by ligature of the *external carotid*, as advised, will require either the separate ligature of the *pharyngea ascendens* or of the *common and internal carotids*.

7. It must be assumed that when ligature of the *external carotid* below the origin of the *lingual* does not arrest hemorrhage from the pharynx, the bleeding is from the *ascending pharyngeal*, and that this branch originates from the bifurcation or the *internal carotid*. (See Surgical Anatomy.) (The history gives one or two deaths from hemorrhage from the tonsils after ligature of the *common trunk alone*.)

8. Aneurism of the *external carotid* or its branches (excepting the *superior thyroid*) demands deligation of the *external carotid alone*, when a sufficient space exists between the tumor and the bifurcation to admit the ligature with safety.

9. Aneurism of the *internal carotid* should be treated by ligature of *this vessel alone*, when there is sound artery enough between the tumor and the bifurcation to admit the ligature with safety.

10. Aneurism of the *common carotid* (if digital compression shall have been abandoned) should be treated by ligature of this vessel as far from the tumor (on its cardiac side) as possible.

11. Ligature of the *common carotid* for aneurism of the *arch of the aorta* is of doubtful propriety. In deference to the opinion of the eminent surgeons who advise it, it may be considered as *sub judice*.

From my own researches I could not conscientiously advise or perform the operation.

12. Ligature of the *common carotid* alone, for the cure of *innominate aneurism*, is an exceedingly dangerous procedure; 12 of 17 cases proved fatal from the operation. Only 2 were *cured*.

I cannot justify the operation.

13. The *common carotid* and the *subclavian* artery were both tied for the relief of *innominate* (combined with aortic aneurism in some instances) *aneurism* in 14 cases. Died 10.

This operation is only justifiable when every more conservative method shall have been exhausted. (See conclusions to History of the Subclavian, where result of different methods is given.)

14. Ligature of the *carotid artery* alone, or with the *innominate*, for aneurism of the *subclavian* artery is not a justifiable procedure. Nature left to her own resources is safer than this. Conservative surgery (see History of Subclavian) is superior to both.

15. In case of aneurism of the *carotid* alone, too near the bifurcation of the *innominate*, or the arch of the aorta, to permit the ligature being placed on the *cardiac* side, the deligation of the *carotid* on the *distal* side would be advisable, provided the conservative method of *direct* (elastic) *pressure upon the tumor*, combined with perfect quiet and careful dietetic treatment, had been previously and persistently tried and had failed.

(An element of danger in interrupted pressure upon an aneurismal tumor of the carotid is, that particles of the newly formed clot may escape into the cranial circulation.)

16. In epilepsy, while the danger of death as a result of the operation is comparatively slight (5 per cent.), the proportion of *cures* or *improved* cases is not great enough to commend this procedure to the profession.

(Since dilatation of the arterials and capillaries of the medulla oblongata is accepted by *Schræder van der Kolk*, *Niemeyer*, and others as the most constant lesion in epilepsy, I would suggest, and would perform if the opportunity presents, *deligation of both vertebral arteries*. This would arrest the direct and probably irritating flow of blood through this ganglion, leaving the recurrent flow from the carotids (through the posterior communicating arteries) to supply the necessary amount of nutrition to this portion of the encephalon.)

17. In persistent and exhaustive *neuralgia* of the fifth nerve, when all other methods have proved ineffectual, ligature of the *common carotid* should be practised.

The *external carotid* of one or both sides should first be tied, below the lingual (the point of election). If this fails the *common* trunk upon the affected side may be secured.

The operation is contra-indicated when pressure upon the *common carotid* of the affected side does not arrest the pain.

18. In *hemiplegia* or *headache* the ligature of the *common carotid* is not justifiable.

19. Ligature of both *common carotids simultaneously* is not justifiable.

Ligature of both vessels, with an interval of from *one week to one year*, is not as dangerous as might be expected, the danger being less as the interval is greater.

When the importance of tying the external carotid for all lesions of the regions to which it is distributed is fully appreciated and practised by surgeons, the double ligature of the primitive carotids will probably not appear in the future records of surgery; while ligature of the common carotid, with its startling mortality of 41 per cent., will be confined to those emergencies in which it alone is involved.


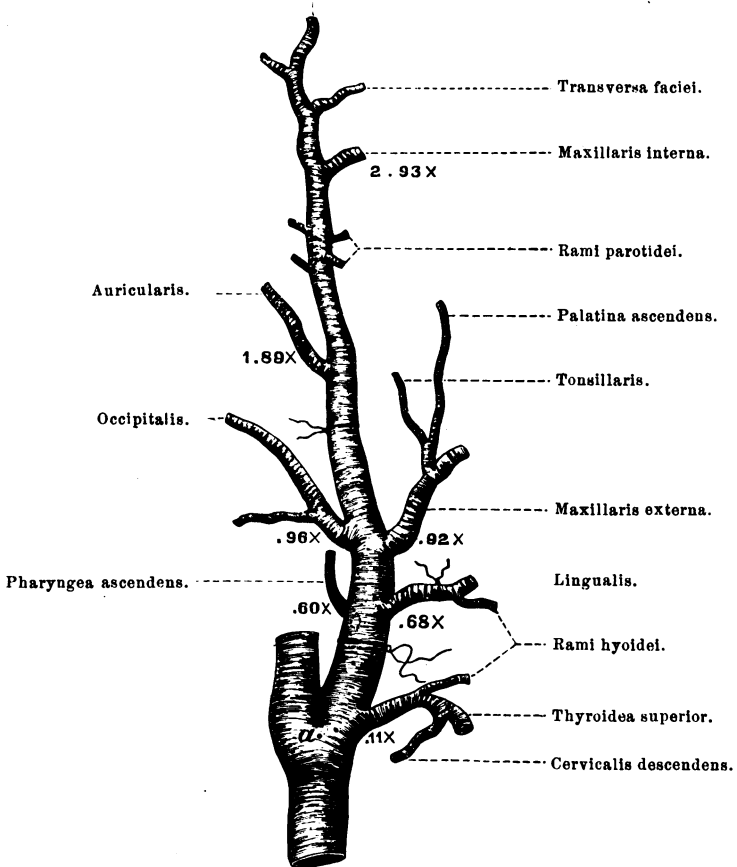



FIG. 1.

Anterior and posterior temporalis.



The relation of the branches of the external carotid to each other (the average of 121 dissections). (Life size.)




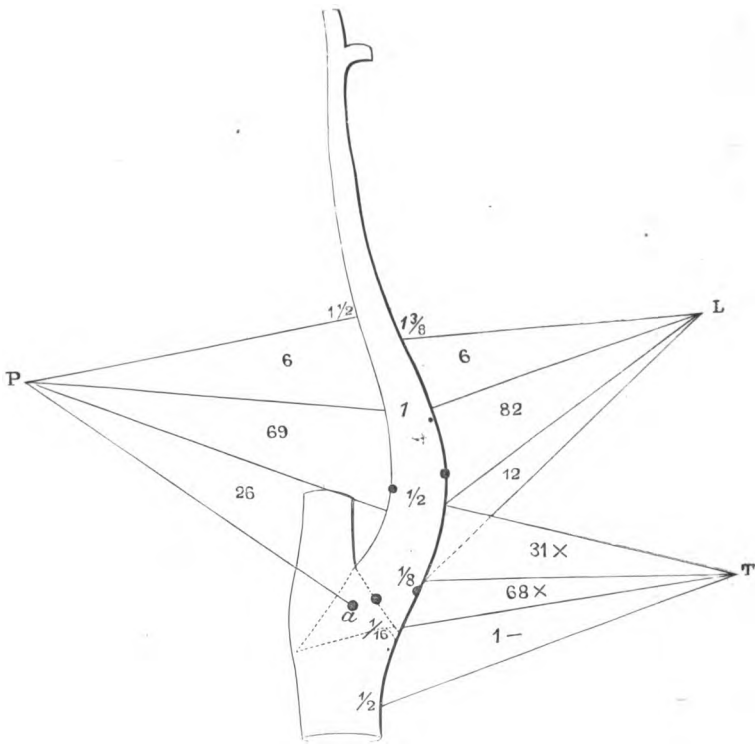


FIG. 2.



Showing range of origin of the thyroidea, lingualis, and pharyngea ascendens.
(Life size.)


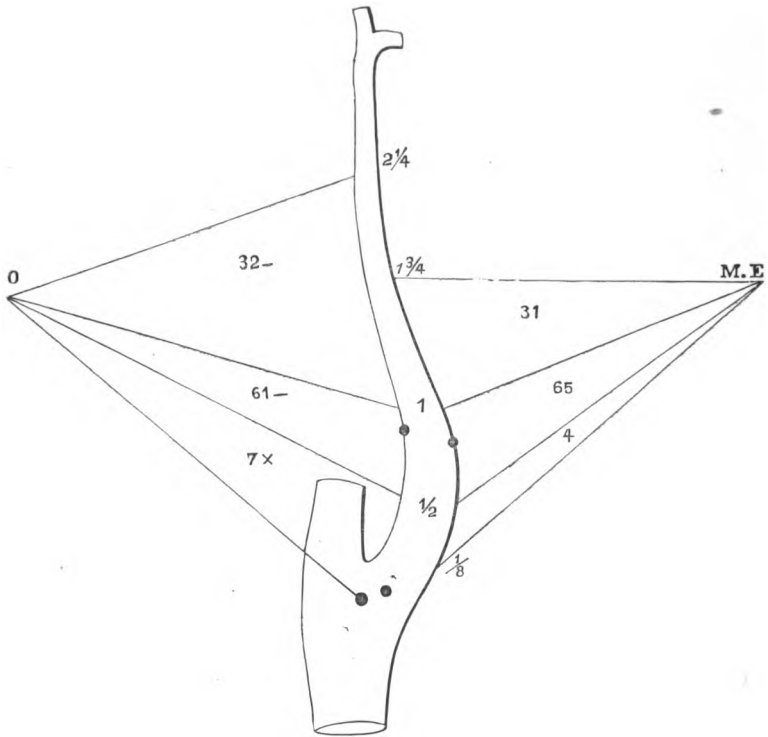
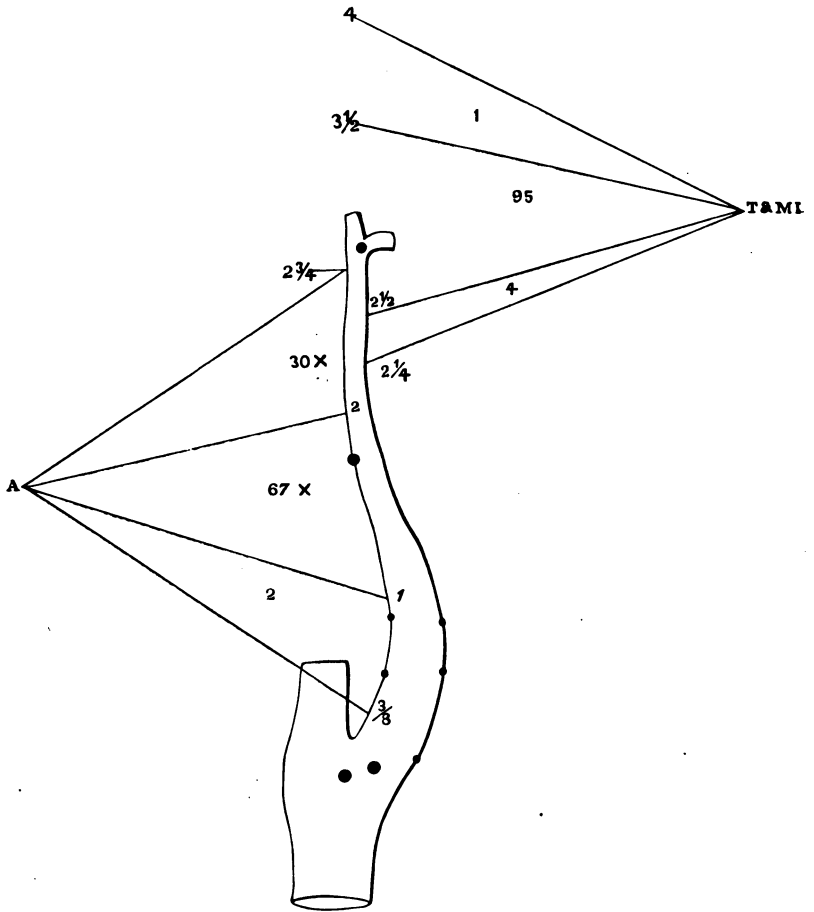


FIG. 3.



Showing range of origin of the occipitalis and maxillaris externa. (Life size.)


FIG. 4.



Showing range of origin of auricularis and range of length of the external carotid.
(Life size.)




FIG. 5.




The lingual and facial,
from a common trunk.
(31 in 121.) (Life size.)

FIG. 6.



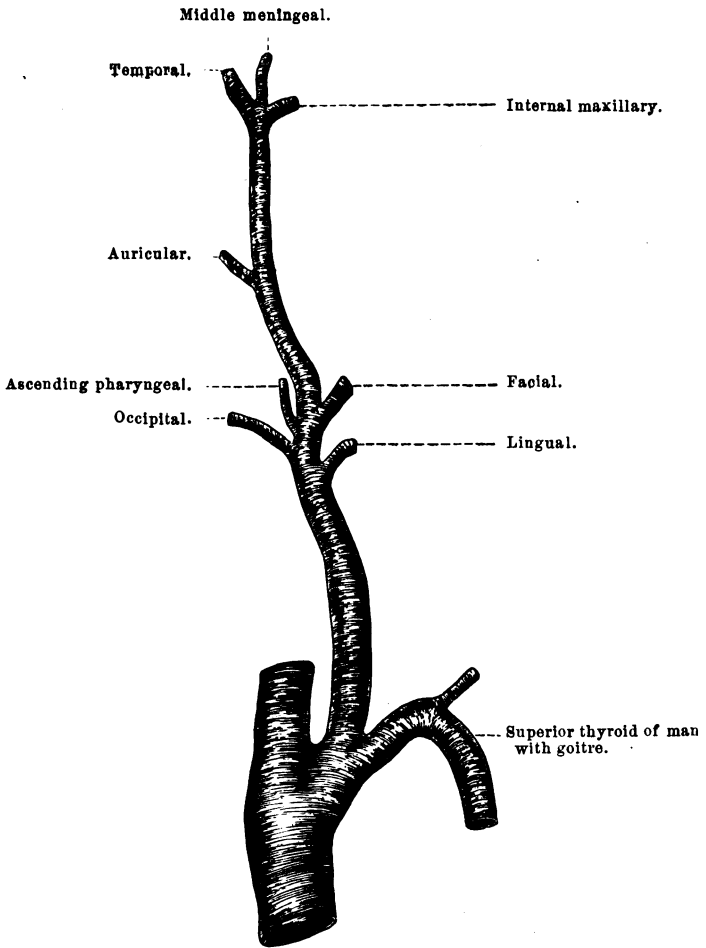
The thyroid, lingual, and
facial, from a common
trunk. (2 in 121.)
(Life size.)

FIG. 7.



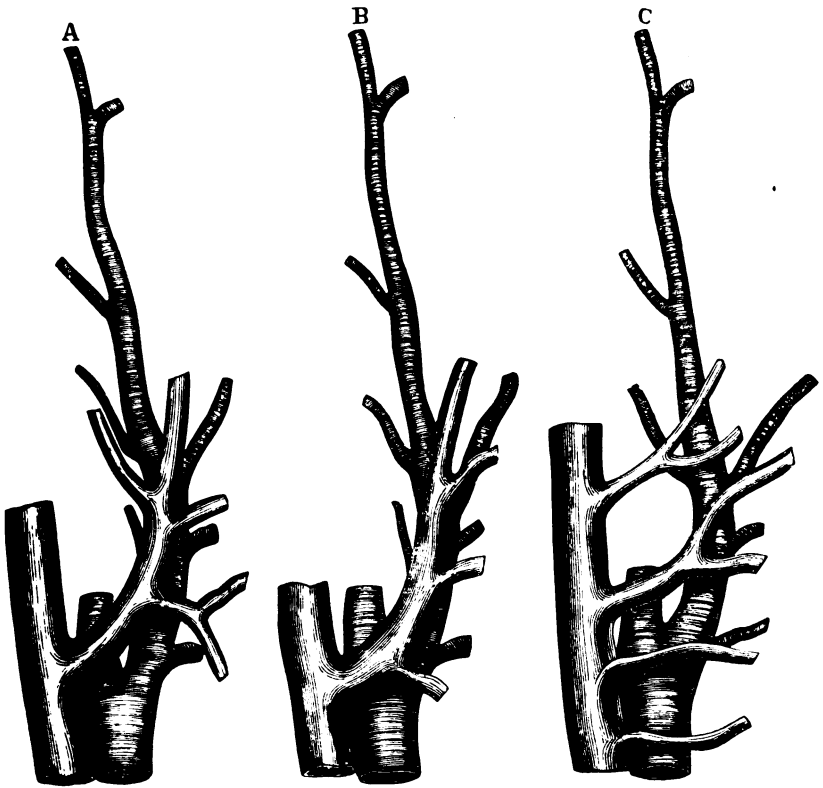
Showing the *dangerous*
relation of the first
five branches of the
external carotid to
each other. (Life size.)

FIG. 8.



An unusual arrangement. (Full size.)

FIG. 9.



Relation of the veins to the carotids. (Life size.)



SURGICAL ANATOMY AND OPERATIVE SURGERY

OF THE

INNOMINATE AND SUBCLAVIAN ARTERIES AND THEIR BRANCHES.

THE ARCH OF THE AORTA, AND ITS RELATIONS TO THE SURGICAL ANATOMY AND OPERATIVE SURGERY OF THE NECK.

WHILE that portion of the *arteria magna* leading directly from the heart is usually described as the *arch* of the aorta, it is not usual for it to form one continuous and unbroken curve, but to consist of three segments of circles joined together, each differing from the other in the length and intensity of its curvature.

THE ASCENDING SEGMENT.

This portion commences at the most inferior surface of the semi-lunar valves; in the great majority of subjects opposite to and behind the left edge of the *sternum*, and about half way between the costo-sternal articulations of the third and fourth ribs, this point (that is the centre of the aortic valves) being usually on a level with the junction of the sixth and seventh dorsal vertebræ (*at the end of expiration*) and about one inch and a half from the internal surface of the *sternum*. From this point the aorta travels obliquely upward and to the right, a distance varying from *two to three inches*, and terminates in the transverse segment near the right border of the *sternum*, and the *costo-sternal* articulation of the right second rib.

If a subject (who has died from other than lesions of the thoracic viscera) be taken, the left ventricle laid open *in situ*, and a straight probe passed into the aorta and pushed directly in the axis of the ventricle, the end of the instrument will be seen to impinge upon the convex surface of the aorta at the point where the *ascending* joins with the *transverse segment*. At this point is situated the bulging known as the *sinus magnus*, and here is the surface upon

which the column of blood, driven by the systole of the ventricle, impinges with the greatest violence, accounting for the clinical fact that atheromatous degenerations and aneurismal dilatations are most frequently seated at the junction of these two segments. It is evident that no exact spot can be selected as in the *actual axis* of the left ventricle, since this axis is *shifting in the rotation of the heart from left to right and from behind forwards with each systole*, yet the weak point is near the place represented by the arrow point (*a*) in Fig. 1. The *semilunar valves*, the *sinuses of Valsalva*, the *coronary arteries*, and the *constriction at the bases of the valves* are the points of interest in connection with the *first portion* of the aortic arch. In a number of measurements of the ascending segment, made after the vessel was fully distended with injection matter, the average circumference around the *sinuses of Valsalva* was four inches; the constriction just above, three and one-fourth to three and one-half inches; while at a point two inches from the ventricle the circumference is greater than that of the *sinuses*.

As to the valves, I found the *anterior* to be largest, the left posterior next, and the right posterior smallest.

It is not usual for any branches other than the coronary arteries to be given off from this portion of the aorta. In twenty-five consecutive examinations as to this feature, there were found *no anomalous* branches, yet, in a capacity where I have examined a great many subjects in connection with demonstrations of the thorax, I have in several instances observed small abnormal branches originating here.

Of the *coronary arteries*, the *right* comes from the sinus of the *anterior* valve, usually within (*i. e.* below) the edge of the semilunar fold, and, when the blood is rushing through the aorta, after the systole, the mouth of the artery is occluded by the valve. The *left* coronary is from the anterior aspect of the *left posterior valve*, and usually within the sinus. It follows, from the unique situation of these two vessels, that they do not pulsate with the heart's systole, and that they are only filled with blood, (1) by *gravity*, when in the upright position; (2) by the *expansion* of the heart muscle in diastole; (3) and principally by the *contraction* of the elastic aorta. The presence of these arteries accounts for the larger development of the two valves with which they are associated. It can be readily imagined that when the heart is contracting, the blood is squeezed out of both veins and arteries in its walls, and that the last few drops *would remain in* the sinuses connected with the two coronary

arteries. This pressure, however little it may be, would serve to precipitate the closure of these *two valves* before the other (the right posterior), hence their development larger than the one having no *coronary pressure* exerted against it.

The *constriction* at the bases of the *semilunar valves* is caused by the aggregation of white fibrous tissue at this point greatly in excess of the elastic fibres found in all other portions of the aorta.

The function of this fibrous band is to prevent dilatation of the aortic orifice and consequent regurgitation of blood after the systole is complete. I have not been able to measure the amount of pressure sufficient to rupture the aorta here, as, in the various experiments made, the valves would either yield or the pressure would be relieved by rupture of the artery beyond this point.

THE SECOND SEGMENT.

This, the *transverse portion* of the aorta, varies in length from three to four inches in different subjects, and extends from near the *costo-sternal* articulation of the right second rib, obliquely to the left and backward, until in the neighborhood of the upper portion of the third dorsal vertebra it turns quite abruptly downward as the *descending portion*. From the convexity of the second segment, a little anterior to its middle line (as looked at from above), arise in quick succession the three great vessels—the *innominate*, *left carotid*, and *subclavian* arteries.

The *arteria innominata*, usually the first branch (larger in itself than the combined calibres of the *left carotid* and *subclavian*), comes off in the majority of subjects immediately in front of the trachea, just behind the middle of the sternum, at a level varying from one-half to one and one-half inch below the upper margin of the *manubrium*. (It is exceedingly rare for the arch of the aorta to be found above or below the points above indicated.)

From this origin the *innominata* travels obliquely upward, backward, and to the right (crossing the trachea from its centre), and bifurcates, near the upper margin of the clavicle, between the *sternal* and *clavicular* origins of the *sterno-mastoideus* into the *carotid* and *subclavian arteries*, the first of these coming from its anterior aspect, the last a direct continuation of the *arch of the innominate*. (The *innominata* in rare instances originates to the left of the trachea, more frequently it is given off before it reaches the windpipe.) The following Table (I) gives a synopsis of 28 consecutive measure-

ments to obtain the average distance of the centre of origin of this artery from the most dependent portion of the semilunar valves (*i. e.* the commencement of the aorta).

TABLE I.

Showing length of *aorta* from most dependent portion of the semilunar valves to centre of origin of the *arteria innominata*. (Measurements made along the centre of the arch.)

| No. | Males. | No. | Females. | No. | Sex not noted. |
|-----|-------------------------|-----|-------------------------|-----|-------------------------|
| 1 | 3 $\frac{1}{2}$ inches. | 1 | 3 $\frac{1}{4}$ inches. | 1 | 3 $\frac{1}{2}$ inches. |
| 2 | 3 $\frac{1}{2}$ " | 2 | 4 " | 2 | 4 " |
| 3 | 3 $\frac{1}{4}$ " | 3 | 3 $\frac{1}{2}$ " | 3 | 3 $\frac{3}{4}$ " |
| 4 | 3 $\frac{1}{2}$ " | 4 | 3 $\frac{1}{4}$ " | 4 | 4 " |
| 5 | 3 $\frac{1}{4}$ " | 5 | 3 " | 5 | 3 $\frac{3}{4}$ " |
| 6 | 3 " | 6 | 3 $\frac{1}{2}$ " | 6 | 3 $\frac{1}{2}$ " |
| 7 | 3 $\frac{1}{2}$ " | 7 | 3 $\frac{1}{4}$ " | | |
| 8 | 3 $\frac{1}{4}$ " | 8 | 3 $\frac{3}{4}$ " | | |
| 9 | 3 $\frac{1}{2}$ " | 9 | 3 $\frac{1}{2}$ " | | |
| 10 | 4 " | 10 | 3 $\frac{1}{4}$ " | | |
| 11 | 3 $\frac{1}{2}$ " | 11 | 3 " | | |

Total number 28. Total of measurements, 97.50 inches.

Average distance of centre of origin of *arteria innominata* from most dependent portion of semilunar valves = 3.48 + inches.

It will be seen, that, while it varies between 3 and 4 inches, the average distance is 3.48 + inches, this origin being in the majority of cases one inch below the upper margin of the *manubrium*.

In table (II.) is given the result of 37 consecutive measurements of the length of the *innominata*. The shortest instance is $\frac{3}{4}$ inch, the longest 2 inches, the average 1.51 + inch.

TABLE II.

Showing the result of 37 measurements of the *arteria innominata*.

| No. | Males. | No. | Females. | No. | Sex not noted. |
|-----|-------------------------|-----|-------------------------|-----|-------------------------|
| 1 | 1 $\frac{3}{4}$ inches. | 1 | 1 $\frac{3}{4}$ inches. | 1 | 1 $\frac{3}{4}$ inches. |
| 2 | 1 $\frac{1}{2}$ " | 2 | 1 $\frac{1}{2}$ " | 2 | 1 $\frac{3}{4}$ " |
| 3 | 1 $\frac{1}{2}$ " | 3 | 2 " | 3 | 1 $\frac{3}{4}$ " |
| 4 | 1 $\frac{1}{4}$ " | 4 | 1 $\frac{3}{4}$ " | 4 | 2 " |
| 5 | 1 $\frac{1}{2}$ " | 5 | 1 $\frac{3}{8}$ " | 5 | 1 $\frac{3}{4}$ " |
| 6 | 1 $\frac{1}{2}$ " | 6 | 1 $\frac{1}{4}$ " | 6 | 1 " |
| 7 | 1 $\frac{1}{2}$ " | 7 | 1 $\frac{1}{4}$ " | 7 | 1 " |
| 8 | 1 $\frac{1}{4}$ " | 8 | 1 $\frac{1}{2}$ " | 8 | 1 $\frac{3}{4}$ " |
| 9 | 1 $\frac{1}{2}$ " | 9 | 1 $\frac{1}{4}$ " | 9 | 1 $\frac{3}{4}$ " |
| 10 | 1 " | 10 | 2 " | 10 | 1 $\frac{1}{2}$ " |
| 11 | 1 $\frac{1}{2}$ " | 11 | 1 $\frac{1}{2}$ " | 11 | 1 $\frac{3}{4}$ " |
| 12 | 2 " | 12 | 1 $\frac{1}{4}$ " | | |
| 13 | 1 $\frac{1}{2}$ " | 13 | 1 $\frac{1}{2}$ " | | |

Total No. = 37. Total length = 56.12 + inches. Average length = 1.51 + inches.

In 5 of 34 cases this vessel gave origin to abnormal branches. In the three cases where the *thyroidea inferior* was derived from the *arteria innominata*, there was no thyroid branch from the axis of this name.

The presence of abnormal branches from the innominate will be again referred to in the "Surgical History" of this vessel.¹

The *left common carotid* originates, on an average, 3.92 inches distant from the commencement of the aorta, and, as shown in the following Table III., its centre of origin is .43+ inch from that of the *innominate*. In 6 of 31 cases I have marked it as *common* with the *innominate*. I do not mean that in 1 of 5 cases it will be found to come off from this last vessel, without being in intimate relation with the arch of the aorta, but that in this proportion of cases they are so intimately associated in their origins that, while their outer walls originate from the *arch*, their inner or adjacent walls are fused together, and this septum does not extend to the level of the aortic curve, being removed upward from $\frac{1}{8}$ to $\frac{1}{2}$ inch.

TABLE III.

Showing the distance between the centres of origin of *arteria innominata* and *carotis sinistra*.

| No. | Males. | No. | Females. | No. | Sex not noted. |
|-----|---------------------|-----|---------------------|-----|---------------------|
| 1 | $\frac{3}{8}$ inch. | 1 | $\frac{3}{8}$ inch. | 1 | $\frac{1}{2}$ inch. |
| 2 | Common. | 2 | Common. | 2 | $\frac{3}{8}$ " |
| 3 | $\frac{1}{2}$ inch. | 3 | " | 3 | Common. |
| 4 | $\frac{3}{4}$ " | 4 | $\frac{1}{2}$ inch. | 4 | $\frac{1}{2}$ inch. |
| 5 | $\frac{1}{2}$ " | 5 | Common. | 5 | $\frac{1}{2}$ " |
| 6 | $\frac{1}{2}$ " | 6 | $\frac{3}{4}$ inch. | | |
| 7 | Common. | 7 | $\frac{1}{2}$ " | | |
| 8 | $\frac{1}{2}$ inch. | 8 | $\frac{1}{2}$ " | | |
| 9 | $\frac{1}{2}$ " | 9 | $\frac{1}{2}$ " | | |
| 10 | $\frac{3}{4}$ " | 10 | $\frac{1}{2}$ " | | |
| 11 | $\frac{1}{2}$ " | 11 | $\frac{1}{2}$ " | | |
| 12 | $\frac{1}{2}$ " | 12 | $\frac{1}{2}$ " | | |
| 13 | $\frac{1}{2}$ " | 13 | $\frac{1}{2}$ " | | |

Total No. = 31. Total length = 13.37 inches. Average = .43+ inch.

The *left subclavian artery*, the second in size of the three great vessels coming from the arch of the aorta, arises to the left of and (as looked at *in situ* from the front) somewhat behind the preceding vessel. Its distance from the commencement of the *arteria magna* and its relation to the *carotid* will be seen in Table IV.

¹ See Surgical Anatomy of the right thyroid axis, and Fig. 3, for arrangement of anomalous branches of the innominate.

TABLE IV.

Showing the distance between the centres of origin of the *carotis* and *subclavia sinistra*, and the distance of the latter from the commencement of the aorta.

| No. | Males. | No. | Females. | No. | Sex not noted. |
|-----|---------------------|-----|----------------------|-----|---------------------|
| 1 | $\frac{1}{2}$ inch. | 1 | $1\frac{1}{4}$ inch. | 1 | $\frac{3}{4}$ inch. |
| 2 | $\frac{3}{4}$ " | 2 | 1 " | 2 | $\frac{3}{4}$ " |
| 3 | $\frac{1}{2}$ " | 3 | $\frac{3}{4}$ " | 3 | $\frac{3}{4}$ " |
| 4 | 1 " | 4 | $\frac{7}{8}$ " | 4 | 1 " |
| 5 | $\frac{3}{4}$ " | 5 | $\frac{3}{4}$ " | 5 | $\frac{3}{4}$ " |
| 6 | $\frac{3}{4}$ " | 6 | $\frac{3}{4}$ " | 6 | $\frac{5}{8}$ " |
| 7 | $\frac{3}{4}$ " | 7 | $\frac{3}{4}$ " | 7 | $\frac{3}{4}$ " |
| 8 | 1 " | 8 | 1 " | 8 | $\frac{5}{8}$ " |
| 9 | $\frac{3}{4}$ " | 9 | 1 " | 9 | $\frac{3}{4}$ " |
| 10 | $\frac{7}{8}$ " | 10 | $\frac{5}{8}$ " | | |
| 11 | $\frac{3}{4}$ " | 11 | 1 " | | |
| 12 | $\frac{7}{8}$ " | 12 | $\frac{3}{4}$ " | | |
| 13 | $\frac{1}{2}$ " | 13 | $\frac{3}{4}$ " | | |

Total No. = 35. Total length = 27.75 inches. Average = .79+, or about four-fifths of one inch.

This gives the distance from the beginning of the *aorta* to the centre of origin of the *subclavia sinistra* as a little less than *four and four-fifths inches*.

The average distance of the centre of origin of the *subclavian* being .79+ inch from the *carotid*, and 4.72 inches from the commencement of the aorta.

The *descending segment*, or the third portion of the arch, begins from $\frac{1}{2}$ to 1 inch beyond the origin of this last artery, when the aorta turns sharply downward near the upper border of the third dorsal vertebra, and is continuous as the *thoracic aorta* beyond the body of the fourth dorsal vertebra.

The Arch of the Aorta as a Whole.

In Fig. 1, I have sketched roughly, yet accurately, the life size and average arrangement of the aortic arch and the great vessels coming from it. It has already been stated in connection with the first portion why the junction of this with the second portion should be the seat of lesions demanding the interference of the surgeon.¹ The situation of the *innominate* just beyond this *weak point*, and in direct range of the blood pressure that is bearing upon the roof of the arch, will also explain why this vessel is involved in lesions, next in frequency to, and almost always in connection with, the lesions of the ascending-transverse junction. The position of the *left carotid* brings it next in order, being often involved with the

¹ See *Résumé of Surgical History*.

innominate; while the *origin and direction* of the *left subclavian* explain why it is rarely the seat of aneurismal disease. In a number of cases in which I measured the angles of incidence and reflection, from the point *a*, Fig. 1, I found that the line of reflection impinged upon the arch of the aorta *beyond* the mouth of the *left subclavian*. While this law of equality of the angles of incidence and reflection is not practicably applicable to the movements of liquids (nor to the aortic arch, which is an elastic and fluctuating cylinder), yet a glance at the direction of the axis of the *left subclavian* (at almost a right angle to the axis of the arch), will explain the immunity of this vessel from lesions resulting from pressure, as compared with the vessels heretofore named, and as compared with the *descending portion* of the arch just beyond, upon which the blood current must impinge with more force. Clinical facts are in accord with this explanation, based upon the anatomical relations. Of less interest to the surgeon, perhaps, is the occasional interference with the circulation in the *coronary arteries* by adhesions of the *semilunar valves* to the sides of the *sinuses of Valsalva* in some instances of aortic regurgitation.

The largest portion of the aorta is at the *sinus magnus* (see Fig. 1), and the diminution in the calibre of the *third segment* is not in proportion to the combined calibres of the three great trunks given off from the second segment.

In 3 of 20 cases examined as to this feature, small abnormal arteries were derived from the anterior aspect of the *transverse segment*.

THE SURGICAL ANATOMY OF THE SUBCLAVIAN ARTERIES.

In order to arrive at results as positive as possible, I selected 13 male and 13 female subjects just as they were brought to the dissecting rooms, and the fifty-two dissections given hereafter are from these subjects.

The *right subclavian*, larger, shorter, and more superficial at its origin than the left, is derived from the *innominate* behind the origin of the carotid, about the level of the upper margin of the clavicle (more frequently above than below this line), behind the interval between the two tendons of the *sterno-mastoideus*. It is the direct continuation backward, upward, and outward of the *arch of the innominate*, and is continuous with the *axillary artery*, at the lower edge of the first rib.

The *left subclavian*, derived 1.23 inch beyond, to the left of, and more deeply situated in the thorax than, the innominate, travels

almost vertically upwards, until it mounts above the upper surface of the first rib, when it curves very abruptly outward and downward, passing behind the scalenus anticus and thence to the lower edge of the first rib. The comparative length of the two subclavians is shown in the—

TABLE

Of measurements of twenty-six subjects, as to the length of the subclavia dextra and sinistra. (The length of the *innominata* appended.)

| FEMALES. | | | | MALES. | | | |
|----------|-------------------------|-------------------|-----------------------|--------|-------------------------|-------------------------|-----------------------|
| No. | Left Sub. | Right Sub. | Innom. | No. | Left Sub. | Right Sub. | Innom. |
| 1 | 4 $\frac{1}{2}$ inches. | 3 inches. | 1 $\frac{1}{2}$ inch. | 14 | 3 $\frac{3}{8}$ inches. | 2 $\frac{7}{8}$ inches. | 1 $\frac{1}{4}$ inch. |
| 2 | 3 $\frac{7}{8}$ " | 2 $\frac{6}{8}$ " | 1 $\frac{3}{4}$ " | 15 | 3 $\frac{6}{8}$ " | 2 $\frac{5}{8}$ " | 1 $\frac{3}{4}$ " |
| 3 | 3 $\frac{6}{8}$ " | 3 $\frac{2}{8}$ " | 2 " | 16 | 3 $\frac{2}{8}$ " | 2 $\frac{2}{8}$ " | 1 $\frac{1}{2}$ " |
| 4 | 3 $\frac{5}{8}$ " | 2 $\frac{6}{8}$ " | 1 $\frac{3}{4}$ " | 17 | 3 $\frac{7}{8}$ " | 2 $\frac{6}{8}$ " | 1 $\frac{1}{2}$ " |
| 5 | 4 $\frac{3}{8}$ " | 3 " | 1 $\frac{5}{8}$ " | 18 | 4 " | 2 $\frac{6}{8}$ " | 1 $\frac{1}{2}$ " |
| 6 | 3 $\frac{5}{8}$ " | 3 " | 1 $\frac{1}{4}$ " | 19 | 4 $\frac{1}{8}$ " | 3 $\frac{5}{8}$ " | 1 $\frac{1}{2}$ " |
| 7 | 3 $\frac{1}{8}$ " | 2 $\frac{5}{8}$ " | 1 $\frac{1}{4}$ " | 20 | 3 $\frac{2}{8}$ " | 2 $\frac{2}{8}$ " | 1 $\frac{1}{2}$ " |
| 8 | 2 $\frac{6}{8}$ " | 2 $\frac{1}{8}$ " | 1 $\frac{1}{2}$ " | 21 | 2 $\frac{4}{8}$ " | 2 $\frac{1}{8}$ " | 1 $\frac{1}{4}$ " |
| 9 | 3 $\frac{2}{8}$ " | 2 $\frac{4}{8}$ " | 1 $\frac{1}{4}$ " | 22 | 3 $\frac{2}{8}$ " | 2 $\frac{2}{8}$ " | 1 $\frac{1}{2}$ " |
| 10 | 4 $\frac{3}{8}$ " | 3 $\frac{4}{8}$ " | 2 " | 23 | 4 $\frac{4}{8}$ " | 2 $\frac{6}{8}$ " | 1 $\frac{1}{2}$ " |
| 11 | 4 $\frac{7}{8}$ " | 4 " | 1 $\frac{1}{2}$ " | 24 | 4 $\frac{3}{8}$ " | 3 $\frac{4}{8}$ " | 1 " |
| 12 | 4 " | 3 $\frac{2}{8}$ " | 1 $\frac{1}{2}$ " | 25 | 4 $\frac{6}{8}$ " | 3 " | 2 " |
| 13 | 3 $\frac{1}{2}$ " | 2 $\frac{6}{8}$ " | 1 $\frac{1}{4}$ " | 26 | 3 $\frac{1}{8}$ " | 2 $\frac{1}{2}$ " | 1 $\frac{1}{2}$ " |

As shown by these figures the average length of the *right subclavian* is 2.83 inches; of the *left* 3.74 inches. The average length of the innominate in these 26 instances is the same as that given in the table of 37 cases on a previous page, *i. e.* 1.51+ inch.¹ The length of the *right subclavian* plus the *innominate* is .60 inch more than the *left*, since this last vessel is given off well to the left of the median line.

Each subclavian may be said to have three *surgical divisions*. The *first division* of the right artery is from its origin from the *innominate* to the inner border of the *scalenus anticus*. That of the left artery, from its origin at the arch of the aorta to the inner border of the *left scalenus anticus*.

The second and third portions of both vessels are identical as regards direction and relation, being different in the origins of their respective branches. The *second surgical division* of each is entirely to the *inner side* of the *inner border* of the first rib. The *third portion*, resting chiefly on the upper surface of the first rib, is in many

¹ The *innominate* is somewhat longer in females than in males.

instances partly within the inner margin of the rib, owing to the obliquity of the scalenus anticus as it passes downward and outward to be attached to the inner margin of this bone. The following tables give the average lengths of the various divisions of these two arteries.

T A B L E.

Subclavia dextra—Length of its three surgical divisions.

| MALES. | | | | FEMALES. | | | |
|--------|------------------|---------------------|----------------------|----------|----------------------|---------------------|-------------------|
| No. | 1st Div. | 2d Div. | 3d Div. | No. | 1st Div. | 2d Div. | 3d Div. |
| 1 | 1 inch. | $\frac{1}{2}$ inch. | $1\frac{1}{2}$ inch. | 1 | $1\frac{1}{4}$ inch. | $\frac{1}{2}$ inch. | 1 inch. |
| 2 | $1\frac{1}{4}$ " | $\frac{3}{4}$ " | $1\frac{1}{2}$ " | 2 | 1 " | $\frac{3}{4}$ " | $1\frac{1}{2}$ " |
| 3 | $1\frac{1}{4}$ " | $\frac{1}{2}$ " | 1 " | 3 | $1\frac{3}{4}$ " | $\frac{3}{4}$ " | $1\frac{1}{2}$ " |
| 4 | $\frac{3}{4}$ " | $\frac{1}{2}$ " | 1 " | 4 | $1\frac{1}{2}$ " | $\frac{1}{2}$ " | $1\frac{1}{2}$ " |
| 5 | 1 " | $\frac{5}{8}$ " | $\frac{1}{2}$ " | 5 | 1 " | $\frac{1}{2}$ " | 1 " |
| 6 | 1 " | $\frac{1}{2}$ " | $\frac{3}{4}$ " | 6 | $\frac{7}{8}$ " | $\frac{1}{2}$ " | $\frac{3}{4}$ " |
| 7 | $1\frac{1}{2}$ " | 1 " | $1\frac{1}{8}$ " | 7 | $1\frac{1}{8}$ " | $\frac{1}{2}$ " | 1 " |
| 8 | $1\frac{1}{4}$ " | $\frac{1}{2}$ " | 1 " | 8 | $1\frac{1}{8}$ " | $\frac{5}{8}$ " | $1\frac{1}{4}$ " |
| 9 | 1 " | $\frac{1}{2}$ " | $1\frac{1}{4}$ " | 9 | $1\frac{1}{4}$ " | $\frac{1}{2}$ " | $1\frac{1}{4}$ " |
| 10 | 1 " | $\frac{1}{2}$ " | $\frac{3}{4}$ " | 10 | $1\frac{1}{16}$ " | $\frac{1}{2}$ " | $1\frac{3}{16}$ " |
| 11 | $1\frac{1}{8}$ " | $\frac{1}{2}$ " | 1 " | 11 | 1 " | 1 " | $1\frac{1}{4}$ " |
| 12 | $1\frac{1}{2}$ " | $\frac{1}{2}$ " | $\frac{7}{8}$ " | 12 | $1\frac{1}{8}$ " | $\frac{1}{2}$ " | $1\frac{1}{8}$ " |
| 13 | 1 " | $\frac{1}{2}$ " | 1 " | 13 | $1\frac{1}{4}$ " | $\frac{1}{2}$ " | $1\frac{1}{4}$ " |
| Total, | 14.6 | 7.37 | 13.25 | Tot'l, | 15.31 | 7.62 | 15.56 |

T A B L E.

Subclavia sinistra—Length of its three surgical divisions.

| MALES. | | | | FEMALES. | | | |
|--------|------------------------|---------------------|----------------------|----------|------------------|---------------------|------------------|
| No. | 1st Div. | 2d Div. | 3d Div. | No. | 1st Div. | 2d Div. | 3d Div. |
| 1 | $2\frac{3}{4}$ inches. | $\frac{1}{2}$ inch. | $1\frac{1}{2}$ inch. | 1 | 2 inches. | $\frac{1}{2}$ inch. | 1 inch. |
| 2 | $2\frac{1}{8}$ " | $\frac{3}{4}$ " | $1\frac{1}{2}$ " | 2 | $1\frac{3}{4}$ " | $\frac{3}{4}$ " | $1\frac{1}{2}$ " |
| 3 | 3 " | $\frac{1}{2}$ " | 1 " | 3 | $2\frac{5}{8}$ " | $\frac{3}{4}$ " | $1\frac{1}{2}$ " |
| 4 | $1\frac{3}{4}$ " | $\frac{1}{2}$ " | 1 " | 4 | $2\frac{3}{8}$ " | $\frac{1}{2}$ " | $1\frac{1}{2}$ " |
| 5 | $1\frac{3}{8}$ " | $\frac{5}{8}$ " | $\frac{1}{2}$ " | 5 | $1\frac{3}{4}$ " | $\frac{1}{2}$ " | 1 " |
| 6 | 2 " | $\frac{1}{2}$ " | $\frac{3}{4}$ " | 6 | $1\frac{1}{2}$ " | $\frac{1}{2}$ " | $\frac{3}{4}$ " |
| 7 | $2\frac{1}{4}$ " | $\frac{3}{4}$ " | $1\frac{1}{8}$ " | 7 | $1\frac{5}{8}$ " | $\frac{3}{4}$ " | $\frac{3}{4}$ " |
| 8 | $2\frac{1}{2}$ " | $\frac{1}{2}$ " | 1 " | 8 | $1\frac{3}{4}$ " | $\frac{5}{8}$ " | $1\frac{1}{4}$ " |
| 9 | $2\frac{1}{8}$ " | $\frac{1}{2}$ " | $1\frac{1}{4}$ " | 9 | $2\frac{1}{4}$ " | $\frac{1}{2}$ " | $1\frac{5}{8}$ " |
| 10 | $1\frac{7}{8}$ " | $\frac{1}{2}$ " | $\frac{7}{8}$ " | 10 | 2 " | $\frac{3}{8}$ " | $1\frac{1}{4}$ " |
| 11 | $2\frac{1}{4}$ " | $\frac{1}{2}$ " | 1 " | 11 | $1\frac{3}{4}$ " | $\frac{3}{4}$ " | $1\frac{1}{4}$ " |
| 12 | 2 " | $\frac{1}{2}$ " | $\frac{7}{8}$ " | 12 | $2\frac{1}{4}$ " | $\frac{1}{2}$ " | $1\frac{1}{8}$ " |
| 13 | $1\frac{1}{2}$ " | $\frac{3}{8}$ " | 1 " | 13 | $2\frac{1}{2}$ " | $\frac{1}{2}$ " | $1\frac{1}{8}$ " |
| Total, | 27.50 | 7.25 | 13.37 | Total, | 26.12 | 7.50 | 15.62 |

While the *first portion* of the *right subclavian* varied in 26 cases from $\frac{3}{4}$ to $1\frac{1}{2}$ inch in length, the average length was 1.15+ inch (being a little greater in females than in males).

The *first portion* of the *left artery* varied from $1\frac{1}{2}$ to 3 inches, the average length being 2.06+ inches (or in males 2.11 inches, in females 2.01).

The *second portion* of the *right subclavian* averaged .58— inch; the same division of the *left subclavian* being .56+ inch in length. (This slight difference may possibly be accounted for in the development of the right muscle more than the left.)

The *third portion* of the *right artery* is a little less; the same division of the *left subclavian* a little more than 1.11 inch in length.

SURGICAL BRANCHES OF THE SUBCLAVIAN ARTERIES.

Nine important arteries arise directly or indirectly from the *subclavian* arteries; the *vertebral*, *internal mammary*, *transversalis colli*, *suprascapular*, *inferior thyroid*, *cervicalis ascendens*, *superior intercostal*, *profunda cervicis*, and *posterior scapular*.

Upon the right side the *vertebral* was derived from the 1st division of the *subclavian* in every one of 26 consecutive cases. It arises from the superior and posterior aspect of the main trunk, and passes upward to the vertebral foramen in the 6th cervical vertebra (often to the 5th, less often to the 4th). As the relation of this vessel to the bifurcation of the *innominate* is considered a point of no little importance in the ligature of the *first division* of the *subclavian*, I have given in Fig. 2 the range of origin of the *vertebral*. Radiating from V, the lines show that, while this branch may range from $\frac{3}{8}$ of an inch to $1\frac{1}{2}$ inch distant from the *innominate*, 4 per cent. will be found between $\frac{1}{2}$ and $\frac{3}{8}$ of an inch, 87 per cent. between $\frac{1}{2}$ and 1 inch, and 8 per cent. between 1 and $1\frac{1}{2}$ inch from the origin of the *subclavian*. I give below the exact parts of an inch in which this vessel was in 20 cases removed from the bifurcation:—

10 males. $\frac{2}{8}$, $\frac{7}{8}$, $\frac{1}{2}$, $\frac{2}{4}$, 1, 1, $\frac{5}{8}$, $\frac{2}{4}$, $\frac{1}{2}$, $\frac{2}{4}$; average .75 inch.

10 females. $\frac{3}{8}$, $\frac{7}{8}$, $\frac{1}{2}$, $\frac{2}{4}$, $\frac{2}{4}$, $\frac{2}{4}$, $\frac{5}{8}$, $1\frac{1}{8}$, $1\frac{1}{2}$, $\frac{7}{8}$; average .81 inch.

Average distance of all cases .78 inch.

Since the average length of the 1st division on this side is 1.15+ inch, the origin of the *vertebral* will be .37 inch (or about $\frac{1}{3}$ of an inch) to the inner side of the inner border of the *scalenus anticus*. It should be looked for and secured without exception in ligature of this division of the main trunk. (See Surgical History.)

The *left vertebral* was derived from the 1st division of the *subclavian* in 24 of the 26 cases, and in 23 of these 24 it was given off (as represented in Fig. 1) just where the *subclavian* bends so abruptly to the left in arching over the first rib. It is thus almost a direct continuation of the axis of the main trunk, a fact which accounts, as I believe, for the larger size of the left vertebral as compared with the right, which is derived from the main trunk at a *right angle* to the blood current, and is thus unfavorably situated. In 22 cases examined the left was larger in 12, they were equal in diameter in 5, the right the larger in 5 instances.¹ (See Fig. 2.) 8 per cent. originate from the aortic arch close to the *subclavian*, 12 per cent. within $1\frac{1}{8}$ inch from the aorta, and 80 per cent. between $1\frac{3}{8}$ and $2\frac{1}{8}$ inches. In 2 of 26 cases it was from the aorta, by the side of the main trunk. Ligature of the vertebral should be practised in ligature of the *subclavian* within the scalenus, though it is a more formidable operation on account of the dangerous proximity of the *thoracic duct*. It can be most safely reached in the 5th intervertebral space.

The *internal mammary* artery is the most regular in its origin of all the branches given off from the *subclavian*. Arising from the anterior and inferior aspect of this vessel just to the inner side of the inner border of the scalenus, it passes downward (a little inward at first) behind the costal cartilages, parallel with the edge of the *sternum* and from $\frac{1}{4}$ to $\frac{3}{4}$ of an inch distant from it. In 47 of 52 cases this branch was from the *first portion* of the main trunk, in 3 of 52 from the *thyroid axis* (twice on the *right* side), and in the remaining 2 of 52 cases it was from the second division of the *subclavian*, just behind the scalenus near its inner border. (This last anomalous origin was on both sides of the same subject.) The phrenic nerve is intimately associated with the origin of the internal mammary. In 21 cases examined as to this feature, the nerve crossed in front of the artery in 17, and behind it in 4 instances. In Fig. 2 the lines radiating from IM indicate the range of origin of this branch, being in 90 per cent. of cases within $\frac{1}{4}$ of an inch of the inner edge of the scalenus on the right side and not varying more than $\frac{1}{2}$ inch to the inner border of this muscle on both sides in 52 cases (a regularity of arrangement exceedingly rare in human anatomy). As shown in Fig. 1, its origin is in the majority of cases intimately associated with that of the *thyroid axis*.

¹ Hyrtl says all of the branches of the right *subclavian* are larger than those of the left. With the above exception this is correct.

The *thyroid axis* is derived from the anterior superior aspect of the subclavian just at the inner margin of the anterior scalenus. In most subjects this *axis* is about $\frac{1}{4}$ inch long, and gives origin to the *inferior thyroid*, *transversalis colli*, and *suprascapular*. This arrangement existed in 34 of 52 cases, the variations from this order being about equal upon the two sides. In 2 of 52 examinations the axis was wanting (both on the right side), the branches being derived from different points.

The *inferior thyroid* artery, the largest branch of the axis, passes upward (inclining at first a little inward), until it arrives at a point between the third and seventh (incomplete) rings of the trachea, where it turns abruptly inward, going behind the *common carotid* and *jugular*, in front of the *vertebral*, and is distributed chiefly to the lower portion of the thyroid body.

In 45 of 52 cases it came directly from the *axis*. Of the 7 anomalies of origin 6 were on the *right side*. It was a branch of the *innominate*, as shown in Fig. 3, in 3 instances, two from its posterior, and one from its anterior aspect. In 4 other cases it came directly from the subclavian. In Fig. 4 is given the range of origin of the *inferior thyroid*. Upon the right side it is within $\frac{1}{2}$ inch of the scalenus in 89 per cent., and from the upper portion of the *innominate* in 11 per cent. of cases. (In ligature of the first portion of the subclavian on the right side, this vessel should be tied, and also on the left side when the ligature is near the scalenus.¹) On the left side the lines radiating from T, Fig. 4, show the marked regularity of origin of this branch.

The *cervicalis ascendens*, a small branch of little surgical importance, is very irregular in its origin, as shown by the following synopsis:—

| | |
|------------------------------------------------------|----------|
| It originated from the inferior thyroid in | 38 |
| “ “ transversalis colli in | 8 |
| “ “ thyroid axis (direct) in | 4 |
| “ “ superior intercostal in | 1 |
| “ “ subclavian (direct) in | 1 |
| Cases | <hr/> 52 |

The most usual origin is therefore from the inferior thyroid, and just where this vessel turns abruptly toward the median line.

The *transversalis colli* passes outward in front of the *scalenus*

¹ It is best to tie the vessel on the left side, well away from the main trunk, on account of the thoracic duct.

muscle and the *phrenic nerve*,¹ underneath the *omo-hyoid*, and between the cords of the brachial plexus, and is distributed to the *trapezius* muscle, sending a branch in the direction of the posterior border of the scapula, which anastomoses with the *posterior scapular* artery; and when this last vessel is not present, this descending branch is continued along the border of the scapula to anastomose with the subscapular branch of the axillary. The *transversalis colli* was missing in 3 of 26 cases on the *right side*, being derived from the *axis* in 22 of 26, and from the *subclavian* in common with the suprascapular in 1 of 26 instances. On the left side it was from the *axis* in 24 of 26, by a common trunk with the suprascapular alone in 1, and was absent in 1 of 26 cases. This branch will be found wanting in the proportion of 4 out of 52 cases, or 1 in 13. The *cervicalis ascendens* was a branch of this artery in 8 of 52 cases. In every one of the 48 instances in which it was present, it was within a radius of $\frac{1}{2}$ inch extending inward from the inner border of the *scalenus anticus* muscle.

The *suprascapular artery*, intimately associated with the preceding, travels suddenly downward and outward from its origin near the inner edge of the *scalenus anticus*, passes between the *subclavian artery* and *vein*, in front of the *phrenic nerve*, crosses in front of the third division of the main trunk, and goes to the suprascapular fossa under the protection of the clavicle, anastomosing with the *dorsalis scapulæ* of the *subscapularis*. It gives off a branch (frequently wounded in operations in this vicinity) which passes behind the *sterno-mastoideus* and along the upper border of the *manubrium*. (It is not usually mentioned.)

| | |
|---------------------------------------------------------------------------------------|-----------|
| The <i>suprascapular</i> was from the <i>axis</i> in | 46 cases. |
| From the <i>subclavian</i> in common with the <i>transversalis colli</i> in | 2 " |
| From the <i>internal mammary</i> in | 1 " |
| And was absent in | 3 " |

of 52. (Twice absent on the right side.)²

The *superior intercostal artery* on the *right side* was present invariably. It was derived from the 1st division in only 6 instances; in 20 of 26 from the 2d division.

On the *left side* it was from the 1st division in 19 of 26 (as against 6 of 26 on the right side) cases, and from the second division in 7 of 26 cases. Its usual origin on both sides is from the *posterior in-*

¹ I have seen the nerve in front of the artery but once.
² Anomalies occur much more frequently in the right subclavian.

ferior aspect of the *subclavian*, and close to the inner edge of the *scalenus anticus*. (The range of origin is shown in Fig. 4.)

The *profunda cervicis* was a branch of the *superior intercostal* in 35 of 52 cases; in 15 it came direct from the *subclavian*, and in 2 of 52 it was a branch of the *thyroid axis*. This vessel is usually very small. I am led to believe that its importance as a collateral channel after ligature of the common carotid or first portion of the *subclavian* has been overrated. On the *right* side, when this branch was not common with the *superior intercostal*, its origin from the main trunk was to the outer side of the *intercostal branch*. (See Fig. 3.)

On the *left* side, under above circumstances, this branch was nearer the inner edge of the *scalenus anticus*.

The *posterior scapular*, one of the most important branches of the *subclavian* in a surgical view, since it must be in dangerous proximity to a ligature applied (as is most often done) in the 3d surgical division (not given in many standard text-books, except as an occasional branch of this artery¹), was present in 36 of 52 dissections, or 69 per cent. It was present in 19 of 26 on the *right* side; and in 17 of 26 on the left. In 23 of the 36 cases in which it was present, it was derived from the 3d division; in the remaining 13, from the 2d division close to its outer limit. In Fig. 4 the range of variation is shown in the lines radiating from P S. On the *right* side 74 per cent. came from the *subclavian* within $\frac{1}{4}$ of an inch to the outer and inner side of the external border of the *scalenus* muscle; 26 per cent. external to this.

On the *left* side 82 per cent. were within $\frac{1}{4}$ of an inch to the outer and inner side of the line dividing the middle and external thirds of the main trunk; 18 per cent. were to the outer side of this. The tendency of this important branch is to originate near the *scalenus*, *i. e.* within one-fourth of an inch of its outer edge. When this vessel is present the *transversalis colli* is small, and when absent the descending branch of the *transversalis* takes its distribution. Passing outward behind the most superficial cords of the brachial plexus, it turns sharply downward, along the posterior border of the scapula, to anastomose with the *subscapular* branch of the *axillary*.

Small *anomalous branches* were observed in only 9 instances—1 from the 2d division of the left side, 4 from the 3d portion, and 2 from the 1st portion.

On the *right* side only 2 small branches were observed, both from

¹ Wilson, Gray, Morton, Monro, Winslow, Cloquet, Paxton, Richardson, Leidy.

the neighborhood of the *internal mammary*. (One of these was the *comes nervi phrenici*, the other a *pericardiac* branch.) None of these had any surgical significance, being so small that they would not, if present, contraindicate the application of the ligature.

OPERATIVE SURGERY.

From the foregoing dissections I would advise the following methods of procedure in ligature of the great vessels at the base of the neck.

Ligation of the Innominate.

From the centre of the interclavicular notch, make an incision about three inches long along the clavicle. A second incision, commencing at the inner border of the sterno-mastoideus about two inches above the clavicle, is made to unite with the first incision at the middle of the interclavicular notch. Dissect the flap upwards, until the sterno-mastoid muscle is exposed, which should be divided over the sternum and clavicle upon a grooved director carefully introduced. Superficial to the muscle some small veins will be found, and underneath its clavicular portion is the junction of the subclavian and jugular, in dangerous proximity. (It is best to leave some of the outer fibres of this muscle attached to prevent its retraction after the operation.) The anterior jugular veins will be seen immediately beneath this muscle, and should be tied and divided. Dissecting carefully, with the handle of the scalpel, the connective and areolar tissue in which these veins are imbedded, the origins of the *sterno-hyoid* and *sterno-thyroid* muscles will be reached, and, when these are divided carefully upon the director, the *arteria innominata* will be seen pulsating just behind the *sterno-clavicular* articulation. Being exposed with the scalpel handle, or any *dissector* not likely to wound the vessel, the aneurism needle should be passed from right to left behind the artery, care being taken to avoid wounding the right *vena innominata* and the *pneumogastric nerve*, or puncturing the *pleura*, which the artery rests upon and is *partly imbedded in*, and (if the ligature is applied low down upon the vessel) the left *innominate vein* which crosses in front. When the aorta is situated low in the *thorax*, it may be necessary to remove the sternal end of the clavicle and a segment of the sternum, as was done by Cooper, of San Francisco, in two instances. (See History.)

From the remarkable results after torsion of large vessels (Bryant's

Surgery), and in consideration of the frightful mortality which has heretofore accompanied this operation, I would advise that the *innominate*, *carotid*, and *subclavian* be *simultaneously* ligatured near the junction of these three trunks, divided between the ligatures, and each well *twisted*. Torsion of the *innominate* would increase the area of resistance to the heart's action, would cause apposition and adhesion of the walls of the artery close to the *aorta*, and avoid the great risk of the *ligature cutting* through, as a result of the constant pulsation and pressure brought against it. Torsion of the *subclavian* would occlude the *vertebral*, *internal mammary*, and the *thyroid axis*, which would obviate the necessity of their being tied (which should *always* be done when torsion is not practised), since a study of the causes of death in the ligature of these large vessels has shown that these branches are among the most important factors of death when left open.¹ Torsion of the *carotid* is not so essential, but should be performed.

Ligature of the Right Subclavian in its 1st Surgical Division, or of the Right Common Carotid at the Root of the Neck. Operation the same as for the Innominate.

The subclavian vein will be found from $\frac{1}{2}$ to $\frac{3}{4}$ of an inch below and in front of the artery. The *internal jugular* vein crosses the artery in front of the *thyroid axis* at the inner border of the *scalenus*. Between this and the common carotid is the *vertebral vein*, and the *pneumogastric* nerve in front, while its *recurrent* branch is looped underneath and passes up behind the vessel. The internal jugular vein should be drawn to the side most convenient, the outer side being safest on account of the right lymphatic duct being at its junction with the subclavian vein. The *phrenic* nerve should not be forgotten, as it crosses the *subclavian* in front of the last portion of the 1st division, being in front of the *scalenus anticus* muscle and behind the *transversalis colli* and *suprascapular* arteries. (In one instance I noticed a communicating filament from the brachial plexus join the phrenic in front of the artery.)

The *vertebral*, *internal mammary*, and *thyroid axis* or *its branches*, may be secured by the same operation as for the ligature of the 1st surgical division on the right side.

The *vertebral* will be found $\frac{1}{3}$ of an inch to the inner side of the inner border of the *scalenus anticus* muscle in the vast majority of

¹ See *Résumé of Surgical History*.

cases. It is the only vessel coming from the posterior inferior aspect of the main trunk in its 1st surgical division (excepting the superior intercostal occasionally seen on the right side, oftener on the left, but in all cases much smaller than the vertebrales).

The *thyroid axis* and its branches are in contact with the inner border of the *salenus anticus*.

The *internal mammary* will be found just beneath and opposite to the *axis*. It can be secured in either of the 5 upper intercostal spaces by making an oblique incision, the centre of which will be between $\frac{1}{4}$ and $\frac{3}{4}$ of an inch distant from the margin of the sternum. Care should be taken not to wound the pleura in passing the aneurism needle around the vessel.

Ligature of the Subclavian Arteries in their 2d and 3d Surgical Divisions.

The *scalenus anticus* muscle on both sides of the neck is the guide in these operations, and it can be found as follows: From the middle of the interclavicular notch, measure along the clavicle to the acromion process. *One-fourth* of this distance from the median line will be opposite the centre of the *scalenus anticus*. Drawing the skin well down upon the clavicle, make an incision through it upon this bone, the incision extending one inch toward the median line, and two inches toward the acromion process, from the middle of the scalenus. Make a second incision at right angles to this, about $1\frac{1}{2}$ inch in length in the axis of the scalenus, terminating in the first incision at the point indicated above as the centre of this muscle. The outer fibres of the clavicular origin of the mastoid muscle are then divided upon a *carefully inserted director* (the large *subclavian vein* is almost in contact with this muscle here). The *internal jugular vein* seen in the anterior portion of the wound will be carefully drawn to the inner side, the operator keeping well above the junction of this with the subclavian and thus avoiding the *lymphatic duct*.

A prominent plexus or group of veins, viz., the *external jugular*, *transversalis colli*, and *suprascapular*, will be seen traversing the wound coming from their respective origins, toward the *subclavian* near the *jugular*. These should be secured and divided. Dissecting carefully, the *suprascapular* and *transversalis colli* arteries will be observed running in general in the direction of the first incision. The posterior belly of the *omo-hyoid* may be found in the upper margin of the wound, crossing the scalenus at about a right angle.

The *transversalis colli* and the *suprascapular* may be secured or held to one side, the finger passed along the *scalenus* until the rib is felt, when the artery will be found just behind the muscle. If it shall have been determined to tie the artery in its second portion, the *scalenus anticus* muscle will be cut upon a director, the operator being careful to avoid the *phrenic nerve* which crosses the muscle in front, coming from above downwards and inwards. (It is between the layers of the sheath of this muscle.) The ligature is next passed around the artery from before backwards, care being taken not to wound the pleura. In all cases of ligature in this division, the *posterior scapular* (if present and within one inch of the ligature), the branches of the *thyroid axis*, the *vertebral*, and the *superior intercostal* should be tied, in order to remove the too constant cause of secondary hemorrhage which the *résumé* of the surgical history of this operation will show to be one of the prime factors of death.

If the third division of the artery is to be secured, the part of the above operation relating to the division of the *scalenus* and ligature of the branches will be omitted. The *posterior scapular* artery alone will require the ligature, with the common trunk. In this last operation the nearest cord of the brachial plexus must be carefully excluded, posteriorly to the artery; the subclavian vein in front and below. Depression of the shoulder and clavicle and extension of the head backward and slightly to the opposite side will facilitate ligature in the first and third divisions and in ligature of the *innominata*.

Ligature of the 2d and 3d divisions of the left subclavian is accomplished by the same procedure as for the opposite side.


The operation for ligature of the 1st portion of the *left subclavian* is more difficult and dangerous, since the vessel is more deeply situated and has the *thoracic duct* in dangerous proximity.

Find the *anterior scalenus* muscle by the rule heretofore given. One inch external to this point, commence an incision (the integument having been pulled down as before) which is carried along the clavicle to the *sterno-clavicular* articulation. Divide the *sterno-mastoid*, and after this the *sterno-hyoid* and *sterno-thyroid* muscles. The *subclavian* artery will be seen ascending almost vertically just behind the *sterno-clavicular* junction. The *internal jugular* vein will be drawn outward, and, passing the finger along the inner border of the *scalenus* muscle, the artery will be felt to pulsate. The *thoracic duct* usually is to the right of and a little behind the artery opposite the upper border of the *sternum*. On a level with the insertion

of the *scalenus* it arches to the left, crosses in front of the *subclavian*, in front of the *scalenus*, behind the *internal jugular*, and curves downward to empty into the *subclavian* at its junction with the *jugular* to form the left *innominate* vein. On account of the intimate relations of the *thoracic duct* to the *left subclavian* artery as this vessel goes behind the *scalenus*, the ligature should not be attempted close to this muscle, nor should the dissection be carried fully to the *scalenus*. The artery should be tied as low down as possible, the *duct* being less likely to be injured here, since in passing behind the aorta it is deeper than the artery. It will be found behind and to the right, the pneumogastric in front and to the right, the left *vena innominata* crossing in front, while the pleura is directly behind. (I consider this operation the most formidable in the domain of operative surgery. It has been undertaken only once (by J. K. Rodgers, of New York¹); the case terminated fatally.)

Ligature of the *thyroid axis* and *internal mammary* artery near their points of origin on the *left side* is not justifiable, on account of the proximity of the *thoracic duct*, which by virtue of its difficult recognition renders operative procedures in this quarter exceedingly dangerous. In very rare instances an anomalous origin of the right subclavian artery, with absence of the innominate, may occur. As seen in Fig. 5, the order of origin is: first, right and left carotid (usually from a common origin), then the left subclavian, and lastly, and from the third portion of the aorta, the right subclavian. From this origin the subclavian passes behind the *œsophagus* and *trachea* to the right, and assumes its normal position behind the *scalenus anticus*. In still rarer instances the aorta is reversed, and with it the order of origin of its branches.

¹ See History of Ligature of Subclavian in 1st Surgical Division.



SURGICAL HISTORY
OF THE
INNOMINATE AND SUBCLAVIAN ARTERIES.

Ligature of the

| No. | Name of operator. | Source of information. | PATIENT. | | | Cause of operation. | Duration of cause. | Point of deligation. | Date of injury. | Date of hemorrhage |
|-----|------------------------------------------------|-----------------------------------------------------------------------------------------------------------------------------------|----------|------|-------|------------------------------------------------|--------------------|---------------------------------------|-----------------|--------------------|
| | | | Sex. | Age. | Side. | | | | | |
| 1 | Mott, Valentine, New York, May 11, 1818. | New York Med. Repository, vol. i. 1818; Norri: Contributions to Practical Surgery; Guy's Hosp. Reports, vol. xvii., Poland. | M. | 57 | | Aneurism of subclavian, from fall on shoulder. | 79 days. | $\frac{1}{2}$ inch below bifurcation. | Feb. 21, 1818. | |

Arteria Innominata.

| No. | Date of operation. | Hemorrhage occurred after op. | Lig. came away No. days aft. op. | RESULT. | | | REMARKS. |
|-----|--------------------|-------------------------------|----------------------------------|-----------|------------|--------------------------------|------------------------------------------------------------------------------------------------------------------------------------------------------------------------------------------------------------------------------------------------------------------------------------------------------------------------------------------------------------------------------------------------------------------------------------------------------------------------------------------------------------------------------------------------------------------------------------------------------------------------------------------------------------------------------------------------------------------------------------------------------------------------------------------------------------------------------------------------------------------------------------------------------------------------------------------------------------------------------------------------------------------------------------------------------------------------------------------------------------------------------------------------------------------------------------------------------------------------------------------------------------------------------------------------------------------------------------------------------------------------------------------------------------------------------------------------------------------------------------------------------------------------------------------------------------------------------------------------------------------------------------------------------------------------------------------------------------------------------------------------------------------------------------------------------------------------------------------------------------------------------------------------------------------------------------------------------------------------------------------------------------------------------------------------------------------------------------------------------------------------------------------------------------------------------------------------------------------------------------------------------------------------------------------------------------------------------------------------------------------------------------------------------------------------------------|
| | | | | Recovery. | Condition. | Cause of death, date after op. | |
| 1 | May 11, 1818. | 23, 24, 25, and 26 days. | 14 | | | 26th day. Hem. | Feb. 21, 1818, patient (a sailor) slipped and fell on deck, striking on right arm, shoulder, and back of head. Not specially inconvenienced by fall. Two days later swelling and intense pain in shoulder. Entered New York Hospital March 1, 1818. Tumor thought to be indolent, and treated by blisters. May 3, felt something give way in tumor, which increased in size and began to pulsate, both above and below the clavicle. Symptoms increasing to May 11th, operation for ligature was made. Tumor had an elevation of 2 inches, and its diameter was from 4 to 5 inches in every direction. It was intended to tie the subclavian in its <i>first portion</i> , but being diseased, the innominate was tied one-half inch below the bifurcation. The ligature was of silk, and the vessel was not entirely occluded by the operator at first until some minutes had elapsed in order to arrest the column of blood gradually. Operation lasted one hour; tumor reduced one-third in size; wound closed by sutures; arm wrapped in cotton; left carotid became very much dilated and patient was bled 16 ounces; 2d day doing well; 3d, ditto; 4th, suppuration began and continued to separation of ligature on 14th day; on 16th and after 23d day, patient was so far improved that he walked alone about the hospital wards; 23d, hemorrhage from wound, and on 24th, 25th, and 26th continued, and he died on 26th day after operation from loss of blood. Autopsy: Innominate not closed on central side of ligature; on distal side the ulcerative process had carried away the remainder of the vessel and portions of the carotid and subclavian, which last two vessels opened into wound; the subclavian was pervious throughout; the carotid was not quite occluded; the clavicle was worn through about its middle; there was no inflammation of the pleura, nor of the serous coat of the aorta. (In the operation a vessel was divided about a half-inch from the innominate on the lower border of the subclavian. It is probable that this was either the <i>comes nervi phrenici</i> (see anatomical notes accompanying this essay), or the sternal branch from the supra-scapular, which traverses this region. An abnormal branch was found to be derived from the <i>arteria innominata</i> near the ligature. I found this anomalous vessel in 5 of 34 consecutive examinations.— <i>Author.</i>) |

Ligature of the

| No. | Name of operator. | Source of information. | PATIENT. | | | Cause of operation. | Duration of cause. | Point of deligation. | Date of injury. | Date of hemorrh'ge. |
|-----|-------------------------------|------------------------------------------------------------------------------------------|----------|-------|-------|------------------------------------------------------|--------------------|---------------------------------------|-----------------|---------------------|
| | | | Sex. | Age. | Side. | | | | | |
| 2 | Graefe, Berlin, 1822. | Graefe & Walthers' Journal, Bd. iv.; Guy's Hosp. Reports (cit.); Norris Contrib. (cit.). | M. | | | Aneurism of sub-clavian. | About 1 year. | 1 inch from aorta. | | |
| 3 | Norman, Bath, 1824. | Fergusson's Surgery, p. 429, Phila., 1845; Norris Contrib.; Guy's Hosp. Reports (cit.). | M. | | | do. | | | | |
| 4 | Arendt, St. Petersburg, 1827. | Chelius, System of Surgery; Norris Contrib.; Guy's Hosp. Reports (cit.). | M. | 36 | | Aneurism of sub-clavian, caused by blow on shoulder. | About 1 year. | $\frac{1}{2}$ inch below bifurcation. | | |
| 5 | Unknown. | Norris Contrib.; Dupuytren, Leçons orales; Guy's Hosp. Reports (cit.). | M. | | | | | | | |
| 6 | Hall, Baltimore, 1830. | Norris (cit.); Baltimore Med. & Surg. Journ., vol i.; Guy's Hosp. Reports (cit.). | M. | 52 | | Spontaneous aneurism of sub-clavian. | About 9 mos. | | | |

Arteria Innominata—continued.

| No. | Date of operation. | Hemorrhage occurred after op. | Lig. came away No. daysaft. op. | RESULT. | | | REMARKS. |
|-----|--------------------|------------------------------------------|---------------------------------|-----------|------------|---------------------------------------------------------------------------------------|----------------------------------------------------------------------------------------------------------------------------------------------------------------------------------------------------------------------------------------------------------------------------------------------------------------------------------------------------------------------------------------------------------------------------------------------------------------------------------------------------------------------------------------------------------------------------------------------------------------------------------------------------------------------------------------------------------------------|
| | | | | Recovery. | Condition. | Cause of death, date after op. | |
| 2 | March 15, 1822. | After few weeks, and on 66 and 67 days. | 14 | | | 67th day. Hem. | On March 15, 1822, the operation was made, intending to tie the subclavian in its <i>first portion</i> , but as in the case of Mott, this vessel was so involved in the disease that the innominate was tied one inch from the aortic arch. The aneurism had existed about one year. Immediately after operation, tumor diminished in size, and patient did well for first few weeks. Hemorrhage occurred later and was repeated until death ensued on the 67th day. Autopsy showed that the <i>central</i> end of the ligatured vessel was closed perfectly. The hemorrhage was from <i>distal</i> side. (Am unable to obtain details of this case.— <i>Author</i> .) |
| 3 | 1824. | 60 h'rs. | | | | 60 hours. Hem. | (Am unable to obtain details of this case.— <i>Author</i> .) |
| 4 | Dec. 24, 1827. | None. | | | | 8th day. Exhaustion. (Pyæmia?) | One year before operation patient had been struck on shoulder, which swelled immediately, but subsided on application of cold. 6 weeks before operation tumor had reappeared and increased rapidly in size. Dec. 24th, 1827, innominate tied. In a few hours difficult breathing, pain, right arm blue; bled patient 20 oz. He continued to grow weaker on 25th, 26th, 27th, and 28th of Dec. 5 days after operation, pus in wound, which increased in quantity. Patient died 8 days after operation, from exhaustion. Autopsy: Cellular tissue in region of wound infiltrated with pus. Innominate closed, ligature not being separated. Circumscribed pneumonia of right lung. (Pyæmia.?) No details of this case. |
| 5 | | Occurred. | | | | Hemorrhage. | No details of this case. |
| 6 | Sept. 7, 1830. | During operation, and immediately after. | | | | 5th day. Exhaustion from hemorrhage, venesection (possibly pyæmia), and pericarditis. | Operation Sept. 7, 1830; innominate diseased and dilated; after ligature hem. from wound controlled by compression with sponges; 1st and 2d day doing well; was bled 15 ounces; 3d day, patient walked a good deal, and went into the yard; 4th day, sudden change for worse, and died 5th day after the operation. Autopsy: Pericarditis; aorta enlarged; innominate, carotid, subclavian, and aorta atheromatous; large clot in sac; aneurism needle had partially transfixed artery, accounting for hemorrhage. |

Ligature of the

| No. | Name of operator. | Source of information. | PATIENT. | | | Cause of operation. | Duration of cause. | Point of deligation. | Date of injury. | Date of hemorrhage. |
|-----|-------------------|-----------------------------------------------------------------------|----------|-----|-------|--------------------------------------------------------------------|--------------------|----------------------|-----------------|---------------------|
| | | | Sex. | Age | Side. | | | | | |
| 7 | Bland, 1832. | Lancet, vol. i. p. 97, et seq.; Guy's Hosp. Reports (cit.). | M. | 31 | | Spontaneous aneurism of subclavian, of about 2 years' duration. | 2 years. | | | |
| 8 | Lizars, 1837. | Norris Contrib.; Lancet, vol. ii. p. 445; Guy's Hosp. Reports (cit.). | M. | 30 | | Subclavian aneurism, fall on right arm; fracture of left clavicle. | Some months. | | | |

Arteria Innominata—continued.

| No. | Date of operation. | Hemorrhage occurred after op. | Lig. came away No. daysaft. op. | RESULT | | | REMARKS. |
|-----|--------------------|-------------------------------|---------------------------------|-----------|------------|----------------------------------|---------------------------------------------------------------------------------------------------------------------------------------------------------------------------------------------------------------------------------------------------------------------------------------------------------------------------------------------------------------------------------------------------------------------------------------------------------------------------------------------------------------------------------------------------------------------------------------------------------------------------------------------------------------------------------------------------------------------------------------------------------------------------------------------------------------------------------------------------------------------------------------------------------------------------------------------------------------------------------------------------------------------------------------------------------------------------------------------------------------------------|
| | | | | Recovery. | Condition. | Cause of death, date after op. | |
| 7 | March 26, 1832. | Occurred. | | | | 18th day. Hem.; exhaustion. | Aneurism had existed for about 2 years. Operation, March 26, 1832. Soon after operation, venesection 18 ounces; 2d day, venesection 10 ounces; 3d day, patient easy, venesection 18 ounces, and purgatives, and on same day, venesection again 11 ounces; 4th day, venesection 3 ounces; 5th day, doing well, venesection 2½ ounces, and again 2 ounces; 6th day, venesection 8 ounces; 7th, 9 ounces; 8th, 12 ounces; 9th and 10th, doing well, and bled 5 ounces; 11th, 12th, and 13th, doing well; 14th, bled 3 ounces; 15th, some fever, and bled 14 ounces, relieved; 16th, not so well; 17th day, hemorrhage from wound about 5 ounces, and in evening of the same day, venesection 6 ounces, and again of 14 ounces; 18th day, hemorrhage repeatedly, and death. Autopsy: No injury to neighboring parts by operation; central end of innominate closed; carotid closed completely; <i>subclavian open</i> . (The patient was bled a total of about 8½ lbs. and lost about 1 lb. by accidental hemorrhage.) |
| 8 | May, 31, 1837. | 20 and 22 days. | 17 | | | 22d day. Hemorrhage; exhaustion. | 4 months before operation, patient fell on left shoulder, breaking clavicle. 15 months before operation he had fallen heavily upon right arm and elbow. Tumor not observed until a few weeks before op., which occurred May 31, 1837. While clearing the innominate, the <i>thyroides ima</i> , or some anomalous branch was found, as in the case of Mott. In Lizar's operation it was divided. Few hours after operation sense of suffocation and pain in chest; 2d day, better and easy; 3d, inability to pass water, catheter; 4th day, pulsation returned in tumor; 5th, 6th, 7th, and 8th, progressed favorably; 9th, 10th, 11th, doing well; 12th, 13th, 14th, not so well, vomited "bilious-looking" fluid; 16th, wound discharging pus; 17th, ligature loose; did well until 20th day, when there was slight hemorrhage from wound; venesection 20 ounces, digitalis, hyoscyamus; 22d day, death from hemorrhage. Autopsy: hemorrhage into pleura; lung softened; central end of innominate not entirely closed; the subclavian was pervious, and the hemorrhage was supposed to be from this and the vertebral. |

Ligature of the

| No. | Name of operator. | Source of information. | PATIENT. | | | Cause of operation. | Duration of cause. | Point of deligation. | Date of injury. | Date of hemorrh'ge. |
|-----|-------------------------------------|---------------------------------------------------------------------|----------|-------|-------|--------------------------------------------------------------------------|--------------------|----------------------|-----------------|---------------------|
| | | | Sex. | Age. | Side. | | | | | |
| 9 | Gore, Bath. | Erichsen; Guy's Hosp. Reports (cit.). | M. | 52 | | Spontaneous subclavian aneurism. | About 2 years. | | | |
| 10 | Cooper, E. S., 1869, San Francisco. | Guy's Hosp. Reports (cit.). | M. | | | Aneurism of carotid, subclavian, and innominate. | | | | |
| 11 | do. 1860. | do. | M. | | | Aneurism of carotid or subclavian, or both. | | | | |
| 12 | Pirogoff. | Allgemein; Krieg's Chir., 1864, p. 459; Guy's Hosp. Reports (cit.). | M. | 46 | | Aneurism of subclavian (traumatic). | Several years. | | | |
| 13 | Huttin (Oran). | Guy's Hosp. Reports (cit.). | M. | 27 | | Punctured wound of branch of axillary, and after ligature of subclavian. | | | | |
| 14 | Smyth, A. W., New Orleans, 1864. | New Orleans Med. Press, May, 1866; Guy's Hosp. Reports. | M. | 32 | | Subclavian aneurism; violent stretching of arm. | About 3 mos. | | | |
| 15 | Mott, A. B., New York, 1868. | Note to author. | M. | | | Subclavian aneurism. | | | | |

Arteria Innominata—continued.

| No. | Date of operation. | Hemorrhage occurred after op. | Lig. came away No. daysaft. op. | RESULT. | | | REMARKS. |
|-----|--------------------|-------------------------------|---------------------------------|------------|-----------|--------------------------------------------------------|----------------------------------------------------------------------------------------------------------------------------------------------------------------------------------------------------------------------------------------------------------------------------------------------------------------------------------------------------------------------------------------------------------------------------------------------------------------------------------------------------------------------------------------------------------------------------------------------------------------------------------------------------------------------------------------------------|
| | | | | Condition. | Recovery. | Cause of death, days after op. | |
| 9 | Sept. 24, 1856. | 17th day. | | | | 17th day. Hemorrhage. | Operation, Sept. 24th, 1856. Did well until 5th day, when erysipelas ensued; 11th day, phlebitis; 17th day, clot of blood escaped from wound during a fit of coughing, and was followed by terrible hemorrhage and death in a few minutes. Autopsy: Cardiac end of artery only partially closed; both subclavians closed; carotid of right side open; purulent infiltration of tissues in neighborhood of wound. |
| 10 | 1859. | None. | | | | 9th day. Exhaustion (probably from uræmia and pyæmia). | Sternal end of clavicle and upper portion of sternum removed to facilitate operation; ligature close to aorta; did well for 5 days, then difficulty of breathing, retention of urine; 9th day, death. Autopsy: Tuberculosis of right lung; pus in right kidney. |
| 11 | 1860. | Occurred. | | | | 34th day? Hemorrhage. | Operation same as above; patient did well for several weeks, when hemorrhage occurred repeatedly; patient becoming discouraged from his hopeless condition, removed the compress, and died on 34th (?) day from hemorrhage. No autopsy. |
| 12 | | | | | | 48 hours. Pyæmia. | After operation, pain in right side, difficulty of breathing; 2d day, paralysis of left side of face; death in 48 hours. Autopsy: Purulent infiltration of pleura and mediastinum, œdema of lungs, and lobular pneumonia. |
| 13 | | Not clearly stated. | | | | 11 hours. Exhaustion from hemorrhage before operation. | Patient received a punctured wound in a duel (thoracic branch of axillary was divided); subclavian was tied; 9 days later, to arrest hemorrhage, the innominate was tied; died in 11 hours. Autopsy: Hem. from thoracic branch of axillary. |
| 14 | 1864. | 14th day, 15, 16, 51. | | Recovered. | Cured. ? | | Aneurism resulted from violent stretching of the arm; 3 months later, innominate and carotid were tied simultaneously; did well until 14th day, when hemorrhage (16 ounces) occurred, which was controlled by compress; 15th and 16th days, continued slight hemorrhage; 17th day, wound <i>was filled with small shot</i> ; 51st day, terrible hemorrhage; 54th day, vertebral tied; 55th day, shot removed from wound; patient continued to do well, and recovered. (NOTE.—After finishing this essay, I learn from the New Orleans Med. and Surg. Journal for July, 1875, p. 27, that this patient <i>died ten years later from hemorrhage from the original sac</i> . Dr. Stone reports case.) |
| 15 | Aug. 13, 1868. | Occurred. | 20 | | | 23d day. Hemorrhage in thorax. | The carotid was tied same time; sac was found to have burst into pleural cavity. |

Ligature of the

| No. | Name of operator. | Source of information. | PATIENT. | | | Cause of operation. | Duration of cause. | Point of deligation. | Date of injury. | Date of hemorrhage. |
|-----|---------------------------|------------------------|----------|------|-------|--------------------------------------------|--------------------|----------------------|-----------------|---------------------|
| | | | Sex. | Age. | Side. | | | | | |
| 16 | Bickersteth, E. B., 1868. | Lancet, Dec. 1872. | M. | 40 | | Subclavian aneurism (traumatic); (strain). | 6 w'ks. | | | |

Ligature of the Subclavian Artery

| No. | Name of operator. | Source of information. | PATIENT. | | | Cause of operation. | Duration of cause. | Point of deligation. | Date of injury. | Date of hemorrhage. |
|-----|----------------------|---------------------------------------------------------------------------------------------------|----------|------|-------|-----------------------------------|--------------------|----------------------|-----------------|---------------------|
| | | | Sex. | Age. | Side. | | | | | |
| 1 | Colles. | Edinburgh Med. & Surg. Journ., vol. xi.; Norris Contrib., Phila., 1873; Arch. Klin. Chir., Bd. x. | M. | 33 | R. | Traumatic aneurism of subclavian. | 2 mos. | st division. | | |
| 2 | Arendt, 1826. | Arch. Klin. Chir., Bd. x. | | | | | | do. | | |
| 3 | Mott, V., 1831. | Am. Jr. Med. Sci., vol. xii.; Norris (cit.). | F. | 21 | R. | Subclavian aneurism. | 1 or 2 years. | do. | | |
| 4 | Bayer, 1829. | Guy's Hosp. Reports, vol. xv. | M. | 21 | R. | Subclav. axillary aneurism. | About 10 w'ks | do. | | |
| 5 | Hayden, G. T., 1835. | Arch. Klin. Chir., Bd. x. | F. | 57 | R. | Subclavian aneurism. | 11 mos. | do. | | |
| 6 | O'Reilly, 1836. | Norris Contrib.; Am. Jr. Med. Sci., 1838. | M. | 39 | | do. | | do. | | |
| 7 | Partridge, 1841. | Norris; Guy's Hosp. Reports, vol xv. | M. | 38 | R. | do. | 5 mos. | do. | | |
| 8 | Liston, 1830. | Arch. Klin. Chir., Bd. x. | M. | 32 | R. | do. | 7 w'ks. | do. | | |
| 9 | Rodgers, 1845. | New York Med. Jr., March, 1846; Guy's Hosp. Reports (cit.). | M. | 42 | L. | do. | 4 w'ks. | do. | | |

Arteria Innominata—continued.

| No. | Date of operation. | Hemorrhage occurred after op. | Lig. came away No. days aft. op. | RESULT. | | | REMARKS. |
|-----|--------------------|-------------------------------|----------------------------------|-----------|------------|--------------------------------|----------------------------------------------------------------------------------------------------------------------------------------------------------------------------------------------------------------------------------------------------------------------------------------------------------------------------------------------------------------------------------------------------------------------------------------------------------------------------------------------------------------------------------------------------------------------------------------------------------------------------------------------------------------------------------------------------------------------------------------------------------------------------------------------------------------------------------------------------------------------------------------|
| | | | | Recovery. | Condition. | Cause of death, date after op. | |
| 16 | May 5, 1868. | 5th, 6th days. | | | | 6th day. Hem. | <p>A lead wire was first applied, but this was removed on 2d day, and two silk ligatures applied above and below the abrasion caused by the lead wire; 5 days after this last operation, hemorrhage, and on 6th day, 3 more hemorrhages occurred; shot were poured into wound; death. Autopsy: Clot firm in innominate on cardiac side; subclavian occluded; carotid open, whence hemorrhage.</p> <p>(Bujalski told Velpeau that he had <i>twice</i> tied the innominate with fatal results. The innominate has been exposed and not tied on account of diseased condition, by A. C. Post, Mr. Key, Porter of Dublin, and Doughty of New York. This last case recovered after ligature of the subclavian, by A. B. Mott, the carotid having been previously tied by Doughty. Peixoto exposed and passed a ligature around this vessel, but did not tie it, and patient recovered.)</p> |

in its First Surgical Division.

| No. | Date of operation. | Hemorrhage occurred after op. | Lig. came away No. days aft. op. | RESULT. | | | REMARKS. |
|-----|--------------------|-------------------------------|----------------------------------|-----------|------------|-------------------------------------------|----------------------------------------------------------------------------------------------------------------------------------------------------------------------------------------------------------------|
| | | | | Recovery. | Condition. | Cause of death, date after op. | |
| 1 | Oct. 10, 1811. | Occurred. | | | | 4th day. Hem. | On account of subclavian being diseased, the ligature was placed in $\frac{1}{2}$ inch of innominate; pleura was wounded; ligature not tightened immediately. Autopsy: Ulceration of subclavian near ligature. |
| 2 | | | | | | 4th day. | |
| 3 | Sept. 22, 1831. | do. | | | | 18th day. Hem. | |
| 4 | Sept. 1829. | do. | | | | 24 hours. Hem. | Sac burst in attempt of patient to raise himself up in bed. Autopsy: Sac full of stinking fluid; 2d and 3d ribs carious; pleuritic adhesions. |
| 5 | Sept. 15, 1835. | do. | | | | 12th day. Hemorrhage; bronchitis. | |
| 6 | April 16, 1836. | do. | | | | 13th day. Hem. | Autopsy: At point of ligature artery had ruptured. |
| 7 | 1841. | None. | | | | 4th day. Pericarditis; pleuritis; pyæmia. | Autopsy: No clot in distal or proximal side of artery. |
| 8 | Sept. 20, 1830. | Occurred. | | | | 36th day. Hem. | Autopsy: Central end of subclavian closed by clot; peripheral end not closed. |
| 9 | 1845. | 13, 15 days. | | | | 15th day. Hem. | Erysipelas on 3d day. Autopsy: Proximal end of artery closed by clot; distal end where vertebral was given off, open; hemorrhage from this point. |

Ligature of the Subclavian Artery

| No. | Name of operator. | Source of information. | PATIENT. | | | Cause of operation. | Duration of cause. | Point of deligation. | Date of injury. | Date of hemorrhage. |
|-----|----------------------|------------------------------------------|----------|------|-------|-----------------------------------------------|--------------------|----------------------|-----------------|---------------------|
| | | | Sex. | Age. | Side. | | | | | |
| 10 | Auvert. | Guy's Hosp. Reports, vol. xv. | M. | 50 | R. | Subclavian aneurism (reduction of shoulder). | 9 mos. | 1st division. | | |
| 11 | do. | do. | M. | 35 | R. | Subclav. axillary aneurism. | | do. | | |
| 12 | Ayres, S. C., 1864. | Med. Surg. Hist. Reb.; Dr. Otis. | M. | | R. | Shot wound fracture of clavicle, external 3d. | | do. | Nov. 15. | Dec. 14. |
| 13 | Bullen, C. H., 1864. | Med. Surg. Hist. Reb.; Dr. A. R. Becker. | M. | 21 | R. | Shot wound near acromion. | | do. | June 9. | June 23-29. |

Ligature of the Subclavian Artery in its First Division,

| | | | | | | | | | | |
|----|----------------------------------|---------------------------------------------------|----|------|----|--------------------------------------------|---------|---------------|-------|-------|
| 14 | Liston, 1838. | Guy's Hosp. Reports, vol. xvii. | M. | 31 | R. | Subclavian aneurism traumatic. | 6 mos. | 1st division. | | |
| 15 | Rossi, 1844. | Gaz. Med., 1844, p. 58; Arch. Klin. Chir., Bd. x. | M. | | R. | Innominate aneurism. | | do. | | |
| 16 | Parker, Willard, New York, 1863. | Note to author. | M. | 32 | R. | Subclavian aneurism. | 12 mos. | do. | | |
| 17 | Hobart, 1839. | Guy's Hosp. Reports, vol. xvii. | F. | 25 | R. | Aortic aneurism (mistaken for innominate). | | | | |

in its First Surgical Division—continued.

| No. | Date of operation. | Hemorrhage occurred after op. | Lig. came away No. days aft. op. | RESULT. | | | REMARKS. |
|-----|--------------------|-------------------------------|----------------------------------|-----------|------------|---------------------------------|--------------------------------------------------------------------------------------------------------------------------------------------------------------------------------------------------------------------------------------------------------------------------------------------------------------------------------------------------------------------------------------------------------------------------------------------------------------------------------------------------------------------------------------------------------------------------------------------------------------------------------|
| | | | | Recovery. | Condition. | Cause of death, date after op. | |
| 10 | | 9, 11. | | | | 11th day. Hem. | Autopsy: Proximal end closed by clot; distal end open, whence hemorrhage; pleura and lung involved in inflammation near wound; pus. Doing well until 8th day; pneumonia; 13th day, hemorrhage, and after do. Autopsy: Proximal end of artery closed, distal open. Ball emerged at back of neck, near 3d cervical vertebra; had fractured clavicle, first rib, and entered thorax; lung hepatized; bloody serum in pleura. Ball fractured acromion, and passed beneath scapula. Autopsy: Subclavian tied $\frac{1}{2}$ from innominate, ligature had cut through; clot on <i>cardiac</i> , none on <i>distal</i> side. |
| 11 | | 13 and after. | | | | 22d day. Hemorrhage; pneumonia. | |
| 12 | Dec. 14, 1864. | None. | | | | Half hour. Exhaustion. | |
| 13 | June 30, 1864. | Occur'd repeatedly. | | | | 8th day. Hem. | |

and the Common Carotid (operations simultaneously).

| | | | | | | | |
|----|----------------|-----------------|-------|-------|-------|---------------------------|--------------------------------------------------------------------------------------------------------------------------------------------------------------------------------------------------------------------------------------------------------------------------------------------------------------------------------------------------------------------------------------------------------------------------------------------------------------------------------------------------------------------------------------------------------------------------------------------------------------------------------------------------------------------------------------------------------------------------------------------------------------------------------------------------------------------------------------------------------------------------------------------------------------------------------------------------------------------------------------------------------------------------------------------------------------------------------------------------------------------------------------------------------------------------------------------------------------------------------------------------------------------------------------------------------------------------------------------------------------------------------------------------------------------------------------------|
| 14 | July 18, 1838. | 11, 13. | | | | 13th day. Hem. | Carotid tied simultaneously; evening of operation, fainting and collapse; 2d, vomiting; 3d day, pain in chest, venesection 12 ounces; 4th day, difficulty of breathing, venesection 8 oz.; 5th day, cerebral symptoms: 12th day, hemorrhage from wound; 13th day, hemorrhage and death. Autopsy: Pus in mediastinum; pericarditis; innominate closed firmly; carotid closed; <i>subclavian open, os also vertebral and other immediate branches</i> ; from distal end of subclavian hem. had come. At autopsy, the left carotid and right vertebral were obliterated. The only vessel going direct to brain was left vertebral. This case is analogous to one by Dr. Hutchison of Brooklyn, in which, after ligature of right carotid, the right vertebral and left carotid were found obliterated (right carotid tied). The common carotid and vertebral tied same time. Autopsy showed that the fatal hemorrhage was from the distal end of subclavian. This patient had progressed without an unfavorable symptom until 16th day, when in a fit of temper she jumped from her bed, and threw a pillow and some books at the nurse; hemorrhage from the carotid ensued and death. Autopsy showed the subclavian closed; the <i>carotid patulous</i> . Although the <i>aorta was the seat of the disease and not the innominate, the pulsation of tumor had disappeared before death, and the process of cure had commenced.</i> |
| 15 | 1844. | | | | | 6th day. Cerebral anæmia. | |
| 16 | Sept. 2, 1863 | 10, 21, 35, 42. | 24 | | | 42d day. Hem. | |
| 17 | 1839. | 16 | 14 | | | 16th day. Hem. | |

Ligature of the Subclavian Artery in its First Division,

| No. | Name of operator. | Source of information. | PATIENT. | | | Cause of operation. | Duration of cause. | Point of deligation. | Date of injury. | Date of hemorrhage. |
|-----|-------------------|------------------------------------------------------------------------------|----------|------|-------|--------------------------------------|--------------------|----------------------|-----------------|---------------------|
| | | | Sex. | Age. | Side. | | | | | |
| 18 | Cuveillier, 1859. | Arch. Klin. Chir., Bd. x.; Guy's Hosp. Reports (cit.). | M. | 20 | R. | Bayonet wound 1st intercostal space. | 2½ mos. | 1st division. | | |
| 19 | Kuhl, 1836. | Dr. C. Piltz; Arch. Klin. Chir., 1868; Surg. Anat. & Hist. Carotid Arteries. | F. | 43 | R. | Vascular tumor of frontal region. | | do. | | |

Ligature of the Subclavian Artery in its Second

| | | | | | | | | | | |
|----|--------------------------------|------------------------------------------------------------------------------------------|----|----------|----|---------------------------------------------------|----------|--------------|----------------|----------|
| 20 | Dupuytren, 1819. | Norris Contrib. (cit.); Arch. Klin. Chir., Bd. x.; Leçons orales, 1834, vol. iv. p. 625. | M. | 37 | L. | Axillary aneurism (traumatic). | 7 years. | 2d division. | | |
| 21 | Liston, 1826. | Guy's Hosp. Reports, vol. xv. | M. | 45 | R. | Subclav. axillary aneurism (traumatic). | 9 mos. | do. | | |
| 22 | Breed, B. B., 1865. | Med. Surg. Hist. Reb. | M. | Mid age. | L. | Shot wound below clavicle. | 3 mos. | do. | Nov. 30, 1864. | Feb. 27. |
| 23 | Da Luz, Lisbon, 1834. | Arch. Klin. Chir., Bd. x. p. 211, 212. | M. | 36 | L. | Medullary fungus axilla (thought to be aneurism). | | do. | | |
| 24 | Grove, J. H., 1864. | Med. Surg. Hist. Reb. | M. | 23 | L. | Shot wound subclav. axillary. | 8 days. | do. | Oct. 5, 1864. | |
| 25 | Nichols, W. P., Norwich, 1832. | Lancet, 1832-3, p. 238. | F. | 21 | L. | Subclav. axillary aneurism (strain in falling). | | do. | | |
| 26 | Anchinloss, Glasgow, 1833. | Edinburgh Med. & Surg. Jr., vol. xlv., 1836, p. 325. | M. | 65 | L. | Subclav. axillary aneurism. | | do. | | |

and the Common Carotid (operations simultaneously)—continued.

| No. | Date of operation. | Hemorrhage occurred after op. | Lig. came away No. days aft. op. | RESULT. | | | REMARKS. |
|-----|--------------------|-------------------------------|----------------------------------|-----------|------------|--------------------------------|------------------------------------------------------------------------------------------------------------------------------------------------------------------------------------------------|
| | | | | Recovery. | Condition. | Cause of death, date after op. | |
| 18 | Aug. 25, 1856. | 7, 8, 9, 10. | | | | 10th day. Hem. | The carotid was closed, as was proximal end of subclavian; distal end of subclavian open, whence hemorrhage. |
| 19 | 1836. | None. | | | | 2d day. (?) | It is stated that Kuhl intended to tie the carotid, and that the subclavian was included by mistake. Autopsy: Pulmonary tuberculosis; cause of death not known; <i>carotid tied same time.</i> |

Surgical Division (behind the Scalenus Anticus).

| | | | | | | | |
|----|-----------------|---------|-------------------|------------|--------|-----------------------------------------|-------------------------------------------------------------------------------------------------------------------------------------------------------------------------------------------------------------------------------------------------------------------------------------------------------------------------------------------------------------------------------------|
| 20 | March 7, 1819. | None. | 15 | Recovered. | Cured. | | 7 years previous patient received punctured wound in left shoulder (from behind); hemorrhage; 2 months later aneurism appeared, which seven years later had reached the size of a child's head; 3 years after ligature the aneurismal tumor was seat of abscess, which was opened, and recovery took place. |
| 21 | Sept. 14, 1826. | 13, 14. | | | | 14th day. Hem. | Artery was first tied in 3d division, but it being involved in disease, a ligature was placed behind scalenus; did well until hemorrhage from wound on 13th day, which occurred again fatally on the 14th. The vessel had given way near the external of the two ligatures, the innermost one having become loosened. <i>Both proximal and distal ends of subclavian were open.</i> |
| 22 | Feb. 27, 1865. | None. | | | | 12th day. Exhaustion; pyæmia; gangrene. | Ball entered thorax and wounded lung; gangrene had resulted before the ligature was applied. Autopsy: Multiple abscesses in both lungs; clot in subclavian. |
| 23 | 1834. | | Be-fore the 15th. | | | 15th day. Exhaustion. | Patient had a fungous growth in left axilla; attempt to remove it; hemorrhage so profuse, it was thought to be an aneurism; ligature behind scalenus; death. |
| 24 | Oct. 13, 1864. | Profuse | | | | 6 hours. Hem. | Ball entered at insertion of deltoid, and lodged between clavicle and first rib; patient did not rally; ball cut out at operation. |
| 25 | April 30, 1832. | | 21 | Recovered. | Cured. | | Aneurism caused by strain of arm in catching from a fall; on account of nearness of tumor, the outer fibres of the anterior scalenus were divided, and the ligature placed in the 2d division. |
| 26 | July 23, 1833. | | | | | 68½ hours. Cerebral symptoms. | On the day of operation, venesection 10 oz.; 2d day, vomited greenish fluid; ordered 2 grs. of calomel every 2 hours; died comatose. Autopsy: Serous effusion beneath arachnoid; brain slightly softened; purulent infiltration in region of wound. |

Ligature of the Subclavian Artery in its Second

| No. | Name of operator. | Source of information. | PATIENT. | | | Cause of operation. | Duration of cause. | Point of deligation. | Date of injury. | Date of hemorrhage. |
|-----|--------------------------------------|------------------------------------------------------------------|----------|----------|-------|---------------------------------------------------------------|--------------------|----------------------|-----------------|---------------------|
| | | | Sex. | Age. | Side. | | | | | |
| 27 | Roux, Paris. | Maladies des Artères Quarantes Années de Prat., vol. ii. p. 391. | M. | Mid age | R. | Hemorrhage from punctured w'nd of axilla and shoulder. | 14 days. | 2d division. | | |
| 28 | Warren, J. C., Boston, 1844. | Lancet, 1845, vol. ii. p. 620 <i>et seq.</i> | M. | 30 | L. | Subclav. axillary aneurism (fall, and reduction of shoulder). | 41 days. | do. | | |
| 29 | V. Pitha, 1856. | Arch. Klin. Chir., Bd. x. (cit.). | M. | 54 | R. | Axillary aneurism. | | do. | | |
| 30 | V. Langenbeck, 1862. | do. | M. | 34 | R. | Diffuse axillary aneurism (stab wound). | 5 mos. | do. | | |
| 31 | Morton, T. G., Phila., 1866. | Am. Jr. Med. Sci., July, 1867, p. 70, and July, 1876. | M. | 51 | L. | Aneurism, axillary. | | do. | | |
| 32 | Gay, 1871 (Great Northern Hospital). | Lancet, 1871, p. 22; do. May, 1871, p. 611. | M. | Mid age. | R. | Subclav. axillary aneurism. | | do. | | |

Ligature of the Subclavian Artery in its Third Surgical Division (between

| | | | | | | | | | | |
|----|------------------------|-----------------------------------------------------------|------|-----|------|-----------------------------------------------|--------|--------------|-------|-------|
| 33 | Ramsden, 1809. | Arch. Klin. Chir., Bd. x. p. 220. | M. | 33 | R. | Axillary aneurism. | 4 mos. | 3d division. | | |
| 34 | Blizard, W., 1811. | Norris Contrib. Pract. Surgery, p. 222. | | Old | | Aneurism. | | do. | | |
| 35 | Colles (1815), 1813. ? | Alfred Poland; Guy's Hospital Reports, vol. xv. p. 68-69. | M. | 48 | R. | Subclav. axillary aneurism (fall from horse). | 6 mos. | do. | | |

Surgical Division (behind the Scalenus Anticus)—continued.

| No. | Date of operation. | Hemorrh'ge occurred after op. | Lig. came away No. days aft. op. | RESULT. | | | REMARKS. |
|-----|--------------------|-------------------------------|----------------------------------|------------|-----------|--------------------------------------------|-----------------------------------------------------------------------------------------------------------------------------------------------------------------------------------------------------------------------------------------------------------------------------------------------------------------------------------------------------------------------------------------------------------------|
| | | | | Condition. | Recovery. | Cause of death, date after op. | |
| 27 | | 4 | | | | 4th (or 5th?) day. Hemorrhage. | A grocer in <i>pursuit</i> of a customer who had passed a counterfeit note in trade with him, was stabbed from <i>behind</i> through right scapula; hemorrhage immediate and frightful; for next few days, do.; on 12th day, Roux tied the axillary; 2 days later, hemorrhage not being controlled, he tied subclavian behind scalenus; hemorrhage again on 4th day; amputation at shoulder; death in 36 hours. |
| 28 | Feb. 8, 1844. | 21 | 13 | Recovered. | Cured. | | Did well until 21st day, when profuse venous hemorrhage occurred to amount of 1 pint; pressure; 22d day, pneumonia supervened; pulse returned in radial artery on 31st day. |
| 29 | | | | | | 6th day. Pneumonia. | Diffuse aneurism resulting from rupture of circumflex artery in attempt at reduction of shoulder; tumor size of man's head; 3d day after operation, partial unconsciousness; 6th, pneumonia and death. |
| 30 | Nov. 5, 1862. | | | | | 9th day. Pyæmia. | 4 days after operation, fever and rigors, and on 9th day, death; thrombus formed on either side of ligature. Autopsy: Adhesions between pleura and lung on right side, bloody serous exudation in left pleural sac. |
| 31 | Nov. 14, 1866. | 44, 46, 47, 68 days. | 19 | Recovered. | Cured. | | 43d day after operation, a bundle of nerves from brachial plexus sloughed away; 44th, frightful hemorrhage; pressure and persalt of iron; 46th and 47th, also hemorrhage; 48th, gangrene of arm evident; 53d day, ligature of subscapularis; 6th day, amputation of arm at upper third; 68th day, hem. again; 90th day, removal of humerus at shoulder-joint. |
| 32 | March 29, 1871. | | | | | 9th day. Bronchitis; pulmonary congestion. | There was no pulsation in the subclavian when reached in the operation. Autopsy: Clavicle partly absorbed; 2d and 3d ribs cut into by absorption from pressure; thrombi on both sides of ligature; lung inflamed. |

the outer edge of the Scalenus Anticus and the lower border of First Rib).

| | | | | | | | |
|----|---------------|-------|-------|-------|-------|---------------------|--------------------------------------------------------------------------------------------------------------------------------------------------------|
| 33 | Nov. 9, 1809. | | | | | 6th day. Exhaust'n. | Autopsy: Firm thrombus on both sides of ligature; 2 lbs. of clotted blood in sac. |
| 34 | 1811. | | | | | 4th day. Exhaust'n? | |
| 35 | 1815 or 1813? | | | | | 6th day. Exhaust'n. | Delirium and rapid gangrene of limb followed operation. Autopsy: No clots had formed which occluded the artery on proximal or distal side of ligature. |

Ligature of the Subclavian Artery in its Third Surgical Division (between

| No. | Name of operator. | Source of information. | PATIENT. | | | Cause of operation. | Duration of cause. | Point of deligation. | Date of injury. | Date of hemorrhage. |
|-----|-----------------------------|-------------------------------------------------------------|----------|----------|-------|----------------------------------------------------------------|--------------------|----------------------|-----------------|------------------------|
| | | | Sex. | Age | Side. | | | | | |
| 36 | Galtié, 1814. | Norris Contrib.; Arch. Klin. Chir., Bd. x. | M. | | | Hemorrhage after disarticulation of humerus for shot fracture. | | 3d division. | | |
| 37 | Blizard, T., 1813. | do. | M. | 47 | L. | Axillary aneurism (traumatic). | 1 m'nth. | do. | | |
| 38 | Warren, J. M., 1847. | Am. Jr. Med. Sci., January, 1849, p. 13. | F. | 30 | L. | Subclav. axillary aneurism (strain while drawing a cork). | 4 mos. | do. | | |
| 39 | Pirie, 1858. | Am. Jr. Med. Sci., July, 1858, p. 229. | M. | 51 | L. | Axillary aneurism (strain). | | do. | | |
| 40 | Skey, F. C., 1840. | Lancet, 1840, p. 376. | M. | | L. | Subclav. axillary aneurism. | 2 mos. | do. | | |
| 41 | Mackenzie, 1846. | Arch. Klin. Chir., Bd. x. p. 228. | M. | 35 | R. | Hem. (thrust of red-hot poker in axilla). | | do. | | |
| 42 | Travers, 1823. | Guy's Hosp. Reports, vol. xv. p. 69. | M. | 73 | R. | Subclav. axillary aneurism. | 3 mos. | do. | | |
| 43 | Bullen, Thos., 1823. | Lond. Med. Repos., 1823, vol. xx. p. 190. | M. | 60 | R. | Subclav. axillary aneurism (tar barrel fell on shoulder). | | do. | | |
| 44 | Todd, 1822. | Norris Contrib., p. 222. | M. | 35 | R. | Axillary aneurism | 1 m'nth. | do. | | |
| 45 | Langenbeck, C. J. M., 1822. | Arch. Klin. Chir., Bd. x. p. 222. | M. | 20? | R. | Punctured w'nd axillary artery. | | do. | | |
| 46 | Sawinkoff, 1823. | Guy's Hosp. Reports (cit.), p. 73. | M. | 30 | L. | Subclav. axillary aneurism. | | do. | | |
| 47 | Detmold, Wm., New York. | Verbally to author. | M. | 40 | L. | Shot wound of axilla. | 5 days. | do. | | |
| 48 | Chamberlaine, R. | Abernethy in Med. Chir. Trans., 1815, p. 128 <i>et seq.</i> | M. | Mid age. | L. | Axillary aneurism (punctured by a cutlass). | | do. | Oct. 5, 1814. | Immediate and profuse. |
| 49 | Post, 1817. | Cooper in Med. Chir. Trans., 1818, p. 185. | M. | 27 | L. | Subclav. axillary aneurism. | 3 w'ks. | do. | | |
| 50 | Wishart, 1823. | Guy's Hosp. Reports, vol. xv. p. 73. | M. | 47 | L. | do. | 6 w'ks. | do. | | |

outer edge of Scalenus Anticus and lower border of First Rib)—continued.

| No. | Date of operation. | Hemorrhage occurred after op. | Lig. came away No. days aft. op. | RESULT. | | | REMARKS. |
|-----|--------------------|-------------------------------|----------------------------------|------------|------------------------------------|-----------------------------------------------|------------------------------------------------------------------------------------------------------------------------------------------------------------------------------------------------------------------------------------------------------------------------------------------------------------------------------------------------------------------------------------------------------------------------------------------------------------------------|
| | | | | Recovery. | Condition. | Cause of death, date after op. | |
| 36 | Aug. 1814. | Occurred. | | | | 3d day. Hem. | After resection, amputation and ligature of axillary; hem. and ligature of subclavian; death 3d day. Autopsy showed ulcerated hole in axillary one inch to central side of first ligature, accounting for hemorrhage. |
| 37 | Jan. 10, 1815. | | | | | 5th day. Cerebral symptoms (probably pyæmia). | 2 days after operation suppuration of sac ensued; 7th day, rupture and discharge of contents of sac. Autopsy: Thrombus on both sides of ligature. |
| 38 | Dec. 24, 1847. | | 96 | Recovered. | Relieved. (Small tumor persisted.) | | Radial pulse returned on 4th day; aneurism very much reduced in size, but a small tumor containing fluid persisted for some time after operation. |
| 39 | 1858. ? | | 17 | Recovered. | Cured. | | |
| 40 | 1840. | | 47 | Recovered. | Cured. | | Phlebitis resulted after operation. |
| 41 | Nov. 19, 1845. | | 20 | Recovered. | Cured. | | |
| 42 | 1823. | Occurred. | | | | 4th day. Exhaust'n. | In passing needle the sac was penetrated; hemorrhage, which did not cease with the ligature, but was controlled by compress. (No anæsthetic.) Radial pulse, which was scarcely perceptible before ligature, was very distinct after; 2d day, venesection 12 oz.; 16th, hem. from wound; 17th, do.; 18th, tumor began to increase in size; 26th, it was punctured; day before patient had coughed up contents of sac; 75th, hem.; numbness of arm during convalescence. |
| 43 | April 23, 1823. | 16, 17, 26, 75. | 21 | Recovered. | Cured. | | (No anæsthetic.) Radial pulse, which was scarcely perceptible before ligature, was very distinct after; 2d day, venesection 12 oz.; 16th, hem. from wound; 17th, do.; 18th, tumor began to increase in size; 26th, it was punctured; day before patient had coughed up contents of sac; 75th, hem.; numbness of arm during convalescence. |
| 44 | Feb. 8, 1822. | | 12 | Recovered. | Cured. | | |
| 45 | 1822. | | 11 | Recovered. | Cured. | | Severe hemorrhage followed wound; ligature of the axillary; new hem. and ligature of subclavian; right arm remained weak after convalescence. |
| 46 | 1823. | | 13 | Recovered. | Cured. | | |
| 47 | | 2, 3. | | Recovered | Cured. | | Load of bird shot entered axilla at close range (2 feet); 5th day after injury, subclavian tied as it crossed 1st rib (incision below clavicle); 2 days after operation, arterial hemorrhage; pressure; 3d, hemorrhage again; recovered; fixation of fingers in flexed position as a result of injury to nerves by shot. Below clavicle, at 1st rib. |
| 48 | Jan. 17, 1815. | None. | 13 | Recovered. | Cured. | | Artery tied behind clavicle; Abernethy gives it as subclavian, as "shoulder was pushed up." No bad symptoms. Below clavicle, at 1st rib. |
| 49 | Sep. 8, 1817. | 5, 6. | 18 | Recovered. | Cured. | | 5th day, hemorrhage (slight) from wound; 6th, do.; 9th, sac bursted, discharging 3 oz. dark coagulated blood; 12th, do. 4 oz.; 13th, 14th, 15th, febrile paroxysms; slight numbness in arm and hand during convalescence. |
| 50 | Aug. 22, 1823. | | 16 | Recovered. | Cured. | | Did well until 10th day, when febrile symptoms ensued; abscess in axilla after convalescence. |

Ligature of the Subclavian Artery in its Third Surgical Division (between

| No. | Name of operator. | Source of information. | PATIENT. | | | Cause of operation. | Duration of cause. | Point of deligation. | Date of injury. | Date of hemorrh'ge. |
|-----|------------------------------------|----------------------------------------------------------------------------------|----------|-------|-------|--------------------------------------------------|--------------------|----------------------|-----------------|---------------------|
| | | | Sex. | Age. | Side. | | | | | |
| 51 | Mayo, 1821. | Stanley in Med. Chir Trans., vol. xii. p. 12. | M. | 38 | L. | Axillary aneurism (rheumatism). | | 3d division. | | |
| 52 | Wells, W., 1828 (Maracaibo). | Norris Contrib., p. 222; Am. Jr. Med. Sci., 1828, p. 28. | M. | 61 | R. | Axillary aneurism. | 7 mos. | do. | | |
| 53 | Liston, Robert, 1820. | Norris Contrib., p. 222; Edin. Med. & Surg. Jr., vol. xvi. | M. | 35 | L. | Subclav. axillary aneurism. | 5 mos. | 2d or 3d. ? | | |
| 54 | Key, Chas. Aston, 1823. | Med. Chir. Trans., vol. xiii. p. 1 <i>et seq.</i> | M. | 36 | R. | Axillary aneurism (muscular exertion). | 3 mos. | | | |
| 55 | do. 1822. | Norris Contrib., p. 222. | | | | Aneurism. | | | | |
| 56 | Gibbs, H. L., 1823. | B. C. Brodie in Med. Chir. Trans., vol. xii. p. 331. | M. | 35 | L. | Subclav. axillary aneurism (struck with rope). | 1m'nth | 3d division. | | |
| 57 | Brodie, 1831. | Guy's Hosp. Reports, vol. xv. p. 69. | M. | 50 | R. | Subclav. axillary aneurism. | 2 mos. | do. | | |
| 58 | Baroni, 1823. | Mem. Med. Soc. de Boulogne; Norris Contrib. | M. | | | Wound of axilla. | A few days. | do. | | |
| 59 | Arendt, 1826. | Arch. für Klin. Chir., Bd. x. p. 222. | M. | 30 | R. | Axillary aneurism. | 1m'nth. | do. | | |
| 60 | Thorpe, Robert, 1827. | Am. Jr. Med. Sci., vol. ii. 1828, p. 136; Med. Chir. Rev., 1828; Norris Contrib. | M. | 36 | R. | do. | 14 mos. | do. | | |
| 61 | Wardrop, 1826. | Lancet, 1826, vol. xii. p. 471; Arch. Klin. Chir., Bd. x. p. 223. | F. | 45 | R. | Innominate aneurism. | 11 mos. | do. | | |
| 62 | Cooper, B., 1827. | Norris Contrib., p. 224; Am. Jr. Med. Sci., 1828. | M. | 38 | R. | Axillary aneurism. | 3 mos. | do. | | |
| 63 | Gibson, W., 1828. | Am. Jr. Med. Sci., vol. ii., 1828, p. 136. | M. | 35 | L. | Wound of axillary (reduction of shoulder-joint). | 2 days. | do. | | |

outer edge of Scalenus Anticus and lower border of First Rib)—continued.

| No. | Date of operation. | Hemorrh'ge occurred after op. | Lig. came away No. days aft. op. | RESULT. | | | REMARKS. |
|-----|--------------------|-------------------------------|----------------------------------|------------|-------------------|--------------------------------------------------------|----------------------------------------------------------------------------------------------------------------------------------------------------------------------------------------------------------------------------------------------------------------------------------------------------------------------------------------------------------------------------------------------------------------------|
| | | | | Recovery. | Condition. | Cause of death, date after op. | |
| 51 | March 19, 1821. | 6, 10, 11, 12. | | | | 12th day. Hem. | Pulse returned in sac 2d day, and venesection to 18 oz.; 3d day, venesection 16 oz. and leeches; 6th, hem. from wound (over a pint); 10th, venesection 16 oz., and calomel, jalap, and salts, also hemorrhage ½ pint; 11th day, hem. from wound; 12th, do. and death. Autopsy: Artery divided by ligature; central end open; distal closed by clot; slight pleuritis and adhesions; first three ribs partly absorbed |
| 52 | April 12, 1828. | | 22 | Recovered. | Cured. | | Patient thought aneurism was caused by severe horseback exercise; arm remained weaker than the other; patient died three years later of ulceration of the bladder. |
| 53 | April 3, 1820. | 5. | 12 | Recovered. | Cured. | | (As the scalenus anticus was partially divided, this might be classed with the 2d division group; practically it is in place here.) Violent hem. from the external jugular occurred on 5th day; controlled by compress. |
| 54 | Sept. 19, 1823. | | 12 | Recovered. | Cured. | | No unfavorable symptoms supervened. |
| 55 | 1822. | | | | | 7th day. Inflammation of sac; pleuritis; pericarditis. | (Details not given further.) |
| 56 | Jan. 5, 1823. | | 12 | Recovered. | Cured. | | Preparatory treatment by venesection and cathartics; no bad symptoms noted. |
| 57 | 1831. | | | | | 7th day. Exhaustion. (Pyæmia?) | Suppuration about wound and high febrile symptoms. Autopsy: Coagula on both proximal and distal side of ligature; purulent infiltration near wound. |
| 58 | Jan. 17, 1823. | | | Recovered. | Cured. | | (In the Gazette Médicale, 1835, is a simple notice of this case as here given; I can find no further account.) |
| 59 | June 6, 1826. | | 16 | Recovered. | Cured. | | |
| 60 | June 21, 1827. | | | Recovered. | Cured. | | Same day of operation, venesection 24 ounces; 2d day, hemorrhage 30 oz.; 17th day, venesection 12 oz.; 4 months after operation, no pulsation in radial. |
| 61 | July, 1823. | | | Recovered. | Temporary relief. | | Symptoms of dyspnoea which had existed previous to operation in a severe form, disappeared after operation; patient died of the aneurism 2 years later; cause of death, bronchitis, anasarca, diarrhœa, and aneurism. Autopsy: Subclavian occluded; aorta and great vessels atheromatous; large aneurism of innominate extending into neck. |
| 62 | Dec. 4, 1827. | Repeat- edly. | | | | 60th day. Exhaustion and hem. from sloughing of sac. | This operation is stated to have lasted only 15 minutes; repeated hemorrhage followed. |
| 63 | March 17, 1828. | | | | | 6th day. Exhaustion; gangrene. (Pyæmia?) | 4th and 5th day arm much swollen; gangrene ensued; delirium. Autopsy: Extensive inflammation of axilla; cardiac end of artery was not filled with clot. |

Ligature of the Subclavian Artery in its Third Surgical Division (between

| No. | Name of operator. | Source of information. | PATIENT. | | | Cause of operation. | Duration of cause. | Point of deligation. | Date of injury. | Date of hemorrhage. |
|-----|--------------------------|-------------------------------------------------------------------------------------|----------|------|-------|-----------------------------------------------------|--------------------|----------------------|-------------------|---------------------|
| | | | Sex. | Age. | Side. | | | | | |
| 64 | Textor, 1828. | Arch. Klin. Chir., Bd. x. p. 223. | M. | 20 ? | R. | Aneurism, axillary (traumatic?). | | 3d division. | | |
| 65 | De Haen, 1828. | do. | M. | | | Aneurism, axillary. | | do. | | |
| 66 | Baker, 1828. | Dr. Jones in Lancet, vol. xvi., 1828-9, p.210. | F. | 18 | R. | Fungus of axilla (supposed aneurism). | | do. | | |
| 67 | Balardini, 1828. | Norris Contrib.; Arch. Klin. Chir., Bd. x. p. 224. | F. | 60 | R. | Aneurism, axillary (result of fracture of humerus). | 3 mos. | do. | | |
| 68 | Porter, 1829. | Dublin Hosp. Reports, vol. v. p. 198; Guy's Hosp. Reports, vol. xv. p. 73. | M. | 40 | L. | Subclav. axillary aneurism (idiopathic). | | do. | | |
| 69 | Crossing, 1830. | Med. Chir. Trans., vol. xvi. p. 344. | M. | 46 | R. | Axillary aneurism (idiopathic). | | do. | | |
| 70 | Bland, 1830. | Norris Contrib., p. 224. | M. | 63 | R. | Aneurism. | | do. | | |
| 71 | Delpech, 1830. | Arch. Klin. Chir., Bd. x. p. 224. | M. | | L. | Axillary aneurism. | | do. | | |
| 72 | Buchanau, M., 1830. ? | Lancet, 1830-1, p. 452. | M. | 55 | | Hemorrhage (after amputation). | | do. | | |
| 73 | Mott, V., 1830. | Notes from Prof. A. B. Mott; Am. Jr. Med. Sci., 1830, p. 309. | M. | 28 | R. | Axillary aneurism (strain). | | do. | | |
| 74 | Roux, Ph. J., 1830. | Arch. Klin. Chir., Bd. x. p. 224. | M. | 22 | L. | Hemorrhage after ligature of axillary. | 9 days. | do. | | |
| 75 | Mayo, 1831. | Norris Contrib., p. 224. | M. | 49 | L. | Aneurism. | 1m'nth. | do. | | |
| 76 | Brodie, 1823. | Arch. Klin. Chir., Bd. x. p. 222. | M. | 56 | L. | Subclavian aneurism. | | do. | | |
| 77 | Fergusson, Wm., 1831. | Ed. Med. & Surg. Jr., vol. xxxvi., 1831, p. 309. | M. | 60 | R. | Axillary aneurism. | 2 years. | do. | | |
| 78 | Porter, 1831. | Norris Contrib., p. 224 | M. | 63 | L. | Aneurism. | 5 w'ks. | do. | | |
| 79 | Blasius. | Arch. Klin. Chir., Bd. x. p. 225. | F. | 33 | R. | Sarcomatous tumor of mamma. | 1 year. | do. | | |
| 80 | Buenger, 1832. | do. | M. | Y'g | | Punctured wound of axilla. | | do. | | |
| 81 | Lallemand, F., 1833. | Arch. Gen., 1835, t. 7, April, p. 477 <i>et seq.</i> | M. | | R. | Sword thrust in axilla. | 24 h'rs. | do. | Feb. 18, 1833. | Imme- diate. |

outer edge of Scalenus Anticus and lower border of First Rib)—continued.

| No. | Date of operation. | Hemorrhage occurred after op. | Lig. came away No. days aft. op. | RESULT. | | | REMARKS. |
|-----|--------------------|-------------------------------|----------------------------------|------------|------------|--------------------------------------------------------------|------------------------------------------------------------------------------------------------------------------------------------------------------------------------------------------------------------------------------------------------------------------------------------------------------------------------------------------------------------------|
| | | | | Recovery. | Condition. | Cause of death, date after op. | |
| 64 | July 28, 1828. | | | | | 4th day. ? | No special cause of death is given. At the autopsy a cord of the brachial plexus was found within the ligature. |
| 65 | Aug. 1828. | | 21 | Recovered. | Cured. | | |
| 66 | 1828. | | | | | Exhaust'n; disease. | Tumor diminished in size immediately after operation, but was not cured. Autopsy: Subclavian obliterated by the ligature. |
| 67 | Nov. 24, 1828. | | 16 | | | 30th day. Suppuration of sac; exhaustion. | Aneurism after fracture of the humerus; venesection and ice did not arrest its development. Autopsy: The central end of the subclavian was found obliterated (condition of the distal end not given). |
| 68 | 1829. | | 17 | Recovered. | Cured. | | Inflammation and suppuration of sac on 25th day; large abscess opened on 45th day. |
| 69 | June 23, 1830. | Occurred. | 85 | Recovered. | Cured. | | 13th day, slight hemorrhage from wound and venesection 16 oz.; 14th day, venesection again 16 oz. |
| 70 | Dec. 17, 1830. | | 43 | Recovered. | Cured. | | |
| 71 | 1830. | | | Recovered? | | | |
| 72 | May 1, 1830. | | | | | 6th day. Prostration. | Patient fell in vat of lye, which necessitated amputation of arm above elbow; hemorrhage ensued; ligature of subclavian; death 6 days later. |
| 73 | Aug. 30, 1830. | | 15 | Recovered. | Cured. | | Discharged cured 27 days after operation. |
| 74 | Aug. 25, 1830. | Occurred. | | | | Few minutes. Exhaustion from hem. before op. above clavicle. | 27 days before operation, disarticulation of humerus for gunshot wound; 19th and 20th days before operation, hemorrhage; subclavian tied below clavicle; hemorrhage again, and subclavian tied near scalenus; on account of hemorrhage, patient was transfused, but died in a few minutes. Autopsy: Pleuropneumonia; thrombi above and below the first ligature. |
| 75 | March 26, 1831. | | | Recovered. | Cured. | | |
| 76 | March 7, 1823. | | | | | 5th day. Exhaustion; gangrene. | Autopsy: Thrombi on both sides of ligature. |
| 77 | May 12, 1831. | 16, 17, | 32 | Recovered. | Cured. | | 6 weeks before operation tumor had grown rapidly; a good sized segment of the artery came away with the ligature; 33d day, slight oozing hem.; 34th, do.; 37th, large abscess in axilla punctured. |
| 78 | Dec. 31, 1831. | | 17 | Recovered. | Cured. | | |
| 79 | 1831. | | | | | 20th day. Septicemia. | Tumor result of blow; 9th day, fever and rigors, and suppuration; difficult breathing, exhaustion, death. Autopsy: Pus infiltration in region of wound; artery still closed by ligature; no clot on cardiac side. |
| 80 | 1832. | | | Recovered. | Cured. | | |
| 81 | Feb. 19, 1833. | | 12 | Recovered. | Cured. | | 5th day, diarrhoea; 12th, do., and on this day the large abscess in axilla was punctured, giving escape to an enormous quantity of bloody pus; radial pulse returned 30th day. |

Ligature of the Subclavian Artery in its Third Surgical Division (between

| No. | Name of operator. | Source of information. | PATIENT. | | | Cause of operation. | Duration of cause. | Point of deligation. | Date of injury. | Date of hemorrhage |
|-----|----------------------------------|------------------------------------------------------------------|----------|----------|-------|-----------------------------------------------------------|--------------------|----------------------|-----------------|--------------------|
| | | | Sex. | Age. | Side. | | | | | |
| 82 | Kuhl, 1834. | Arch. Klin. Chir., Bd. x. p. 225. | M. | 22 | R. | Axillary aneurism, punctured wound. | 15 days. | 3d division. | Feb. 10. | 11-25. |
| 83 | Nicol, Jno. I., 1834. | Ed. Med. & Surg. Jr., vol. xlii., 1834, p. 1. | M. | 68 | L. | Medullary sarcoma of humerus (supposed aneurism). | | do. | | |
| 84 | Seutin, 1834. | Guy's Hosp. Reports, vol. xv. p. 72-3. | M. | 44 | L. | Subclav. axillary aneurism (syphilis). | | do. | | |
| 85 | Lizars, 1834. | Lancet, 1833-4, vol. ii. p. 717. | F. | Mid age. | L. | Axillary aneurism. | 10 y'rs. | do. | | |
| 86 | Earle, 1835. | Norris Contrib., p. 224; Arch. Klin. Chir., Bd. x. p. 224. | M. | 54 | L. | Subclav. axillary aneurism. | 10 mos. | do. | | |
| 87 | Hobart, 1836. | Guy's Hosp. Reports, vol. xv. p. 74-5. | M. | 38 | R. | do. | 4 mos. | do. | | |
| 88 | Montani, 1836. | Arch. Klin. Chir., Bd. x. p. 223. | M. | 21 | R. | Axillary aneurism (punctured wound). | | do. | June 12. | Immediate. |
| 89 | Rigaud, 1836. | Archives Générales, t. xii. 1836. | M. | 31 | R. | Axillary aneurism (punctured, thought to be abscess). | | do. | | |
| 90 | Michaelis, 1836-7. | Arch. Klin. Chir., Bd. x. p. 226. | M. | | | Punctured wound of axillary artery. | | do. | | |
| 91 | Mussey, 1837 (New Hampshire). | Am. Jr. Med. Sci., 1837, p. 390. | M. | 40 | | Removal clavicle and scapula for osteo-sarcoma. | | do. | | |
| 92 | Jobert, 1837. | Guy's Hosp. Reports, vol. xv. p. 73. | M. | 61 | R. | Subclav. axillary aneurism (carrying weight on shoulder). | 4½ mos. | do. | | |
| 93 | White, 1838. | Norris (cit.), p. 226; Arch. Klin. Chir., Bd. x. p. 227. | M. | Y'g. | L. | Aneurism, axillary (punctured wound). | 2 w'ks. | do. | | |

outer edge of Scalenus Anticus and lower border of First Rib)—continued.

| No. | Date of operation. | Hemorrhage occurred after op. | Lig. came away No. days aft. op. | RESULT | | | REMARKS. |
|-----|--------------------|-------------------------------|----------------------------------|------------|------------|---------------------------------------|------------------------------------------------------------------------------------------------------------------------------------------------------------------------------------------------------------------------------------------------------------------------------------------------------------------------------------|
| | | | | Recovery. | Condition. | Cause of death, date after op. | |
| 82 | Feb. 25, 1834. | 6th. | | | | 6th day. Hem. | 15 days before operation, sword thrust in duel; hem. next day, and swelling in axillary region; 25th Feb., ligature; 2d day, abscess opened, and 4 lbs. of blood and pus escaped; 6th day, violent hem. from wound of ligature, and patient died before Dr. K. arrived. Autopsy: Nothing of interest. |
| 83 | Jan. 17, 1834. | 21. | 22 | | | 25th day. Diarrhœa; hem.; exhaustion. | 5th day, patient became lethargic; 10th day, inflammation of wound and suppuration; venesection 8 oz.; after this did well until 21st day, when after forbidden exertion he was "deluged in blood." Autopsy: Cardiac end of artery closed by clot, <i>distal end open</i> . |
| 84 | 1834. | 26 and after, and 35. | 20 | | | 35th day. Hem. | Tumor full of fibrin; 2d rib eroded; purulent infiltration of parts above wound; no clot on cardiac or distal side of ligature. |
| 85 | April 27, 1834. | | | Recovered. | Cured. | | Last six months before operation, tumor had grown rapidly; 8 days before, "felt something give way in the axillary region;" pulse in radial in 60 hours; operator thought the subclavian was in front of scalenus anticus; was not positive; tumor at last account had diminished $\frac{1}{2}$ in size. |
| 86 | April 13, 1835? | | 16 | Recovered. | Cured. | | |
| 87 | 1836. | None. | 23 | Recovered. | Cured. | | |
| 88 | June, 1836. | | 13 | Recovered. | Cured. | | Suppuration of sac after operation. |
| 89 | 1836. | | 13 | | | 46th day. Exhaustion. | Venesection in course of treatment after operation; 18th day, large abscess formed in sac. |
| 90 | 1836-7. | | | Recovered. | Cured. | | |
| 91 | Sept. 26, 1837. | | | Recovered | Cured. | | 19 years previously, metacarpal bone had been removed for disease; 11 years later, arm amputated at shoulder for same affection; 6 years after last operation, subclavian tied in operation for removal of clavicle and scapula; wound united by 1st intention; during the operation, subclavian vein was wounded and air entered. |
| 92 | 1837. | 28-29. | | | | 29th day. Hemorrhage, exhaustion. | 5 days after operation, aneurism developed on cardiac side of ligature; abscess formed on shoulder. Autopsy: Purulent infiltration among tissues; both ends of artery open and in pus; general atheromatous condition of vessels. |
| 93 | Sept. 17, 1838. | | 17 | Recovered. | Cured. | | Following the wound, severe hemorrhage which was arrested by compression; 4 days later, aneurism appeared; after the ligature, the abscess in axilla was punctured with great relief. |

Ligature of the Subclavian Artery in its Third Surgical Division (between

| No. | Name of operator. | Source of information. | PATIENT. | | | Cause of operation. | Duration of cause. | Point of deligation. | Date of injury. | Date of hemorrhage |
|-----|---------------------------------|----------------------------------------------------------|----------|------|------|----------------------------------------------------------|--------------------|----------------------|-----------------|-------------------------|
| | | | Sex. | Age. | Side | | | | | |
| 94 | Nott, Josiah C. (Mobile), 1838. | Am. Jr. Med. Sci., vol. ii. n. s., 1841. | M. | 30 | | Aneurism, shot (small-sized shot) wound axilla. | 2 mos. | 3d division. | | 12th day, 13-16. |
| 95 | Syme, 1838. | Arch. Klin. Chir., Bd. x. p. 227. | M. | 23 | L. | Axillary aneurism (after fall). | 1 m'nth. | do. | Sept. 23. | Extravasat'n immediate. |
| 96 | Hulton, J. P., 1841. | Lancet, 1840-1, vol. ii. p. 377. | M. | 35 | R. | Axillary aneurism (fall, and catching violently by arm). | | do. | | |
| 97 | Pfister, 1840. | Arch. Klin. Chir., Bd. x. p. 227. | M. | 22 | R. | Axillary aneurism (punctured wound). | Some weeks, 3? | do. | Dec. 17, 1840. | Several times. |
| 98 | Gross, Prof. S. D., 1841. | Am. Jr. Med. Sci., vol. x., 1845, p. 19; Norris, p. 226. | M. | 36 | R. | Axillary aneurism. | 18 mos. | do. | | |
| 99 | Hutin, 1841. | Guy's Hosp. Reports, Bd. x. p. 138, vol. xvii. | M. | 27 | R. | Wound of axillary, scissors-blade. | 12 days. | do. | Oct. 28, 1831. | 1, 4, 12. |
| 100 | McDougall, 1842. | Norris Contrib., p. 226. | M. | 24 | L. | Aneurism (shot wound). | 6 w'ks. | do. | | |

outer edge of Scalenus Anticus and lower border of First Rib)—continued.

| No. | Date of operation. | Hemorrhage occurred after op. | Lig. came away No. days aft. op. | RESULT. | | | REMARKS. |
|-----|--------------------|-----------------------------------------------|----------------------------------|------------|---------------------------|---------------------------------------------------|------------------------------------------------------------------------------------------------------------------------------------------------------------------------------------------------------------------------------------------------------------------------------------------------------------------------------------------------------------------------------------------------------------------------------------------------------------------------------------------------------------------------------|
| | | | | Recovery. | Condition. | Cause of death, date after op. | |
| 94 | Nov. 27, 1838. | | 31 | Recovered. | Cured. | | Gun discharged in axilla at close range; hemorrhage on 12th, 13th, and 16th days; compress; in 2 months aneurism appeared; operation successful in all respects; 2 years after operation patient well. |
| 95 | Oct. 28, 1838. | So often that S. had to amputate at shoulder. | | Recovered. | Cured (with loss of arm). | | The frightful hemorrhage occurred through the subscapularis of axillary, which was found to be torn. |
| 96 | Jan. 8, 1841. | | 12 | Recovered. | Cured. | | 3 weeks after fall and strain of arm, aneurism appeared; 50 days after ligature, the sac, which had diminished in size, began to increase rapidly; punctured and discharged pus. (Although the incisions were made, and the artery reached <i>above</i> the clavicle, the operator says the artery was tied 2 inches below this bone! Such a procedure is scarcely possible. — <i>Author.</i>) |
| 97 | Jan. 8, 1841. | 3 times. | | | | 15th day. Hem. | 3 weeks before oper'n, wounded with pointed instrument in axilla (from behind); on account of hemorrhage attempt to tie axillary, which being wounded by the aneurism needle, the subclavian was secured; hemorrhage, rigors, and death. Autopsy showed hemorrhage to have come from cardiac end of subclavian near ligature, which had partially cut through the 5 coats of the artery. |
| 98 | Feb. 18, 1841. | | | | | 30th day. Exhaustion, rupture of sac into pleura. | After ligature the tumor became solidified; 25th day, fever, tumor red with inflammation and painful; 26th, severe pain in chest; 28th day, patient felt as if fluid was passing from pleura into aneurismal sac; died 30th. Autopsy: Between 1st and 2d ribs sac communicated with pleura by free opening; 3 qts. of bloody serum in right pleural cavity. |
| 99 | Nov. 9, 1841. | 6-9. | 9 | | | 10th day. Exhaustion, hem. | "Soldier, fighting duel with scissors blade attached to end of stick," was wounded in axilla; 12 days, ligature of subclavian; 6 days after ligature, patient got out of bed, contrary to orders, went to water closet, and in act of defecation hemorrhage from axilla; compress; 9th day, on account of continued hemorrhage, H. tied the <i>innominate</i> ; died next morning. Autopsy: The only source of hemorrhage was found to be one of the <i>thoracic branches of the axillary</i> ; no other points of interest. |
| 100 | Dec. 12, 1841. | Occurred. | | | | 7th day. Hem | |

Ligature of the Subclavian Artery in its Third Surgical Division (between

| No. | Name of operator. | Source of information. | PATIENT. | | | Cause of operation. | Duration of cause. | Point of deligation. | Date of injury. | Date of hemorrh'ge. |
|-----|-------------------------------------------|-----------------------------------------------------|----------|----------|-------|-----------------------------------------------------|--------------------|----------------------|-----------------|-------------------------|
| | | | Sex. | Age. | Side. | | | | | |
| 101 | Post, A. C., 1843. | N. Y. Jr. Med., vol. iv., March, 1843. | M. | 37 | R. | Hem. (wound of axilla (scythe-blade). | 21 days. | 3d division. | Nov. 15. | Immediate. |
| 102 | Cooper, B. B., 1841-9. ? | Guy's Hosp. Reports, vol. xv. p. 70-1. | M. | 50 | L. | Subclav. axillary aneurism. | 6 w'ks. | do. | | |
| 103 | Wattman, 1843. | Arch. Klin. Chir., Bd. x. p. 228. | | | | Subclav. axillary aneurism (shot wound). | | | | |
| 104 | Mott, V., 1844. | Dr. A. B. Mott to author; N. Y. Jr., Jan. 1845. | M. | 35 | R. | Axillary aneurism (shot w'd). | 22 days. | 3d division. | | |
| 105 | Knorre, 1845. | Arch. Klin. Chir., Bd. x. p. 229. | M. | 22 | R. | Hem (abscess in axilla). | | do. | | |
| 106 | Green, 1844. | Guy's Hosp. Reports, vol. xv. p. 70-1. | M. | 35 | R. | Subclavian aneurism. | | do. | | |
| 107 | Vanzetti, 1846. | Arch. Klin. Chir., Bd. x. p. 229. | M. | 40 | L. | Axillary aneurism. | 17 mos. | do. | | |
| 108 | Syme, 1847. | Ed. Monthly Jr., 1848, p. 217. | M. | 34 | R. | Axillary aneurism. | | do. | | |
| 109 | Manec, 1848. | Arch. Klin. Chir. | M. | 18 | L. | Subclav. axillary aneurism (shot wound). | 7 days. | do. | June 24. | Soon after, and July 2. |
| 110 | Hancock, 1848 | Lancet, 1849, p. 126 <i>et seq.</i> | M. | 34 | | Axillary aneurism (sack of beans fell on shoulder). | 2 years. | do. | | |
| 111 | Linhart, 1848. | Arch. Klin. Chir., Bd. x. p. 229. | M. | Mid age. | R. | Shot wound (shoulder-joint). | A few hours. | do. | | |
| 112 | Crompton, 1849. | do. p. 230. | M. | 49 | R. | Axillary aneurism. | | | | |
| 113 | Syme, 1849. | Ed. Monthly Jr., March, 1850, p. 240. | M. | 50 | R. | Axillary aneurism (thrown from carriage). | | 3d division. | | |
| 114 | Unknown, Schleswig-Holstein War, 1848-50. | Arch. Klin. Chir., Bd. x. p. 230. | M. | | | Shot wounds in neighborhood of axilla. | | do. | | |
| 115 | do. | do. | M. | | | do. | | do. | | |
| 116 | do. | do. | M. | | | do. | | do. | | |
| 117 | Parker, Prof. Willard, 1849. | Notes of cases furnished to author by Prof. Parker. | M. | 31 | R. | Traumatic aneurism and hemorrhage of axilla. | 18 days. | do. | Feb. 5, 1849. | |

outer edge of Scalenus Anticus and lower border of First Rib)—continued.

| No. | Date of operation. | Hemorrh'ge occurred after op. | Lig. came away No. days aft. op. | RESULT. | | | REMARKS. |
|-----|--------------------|-------------------------------|----------------------------------|------------|------------------------------------------------|--------------------------------|-----------------------------------------------------------------------------------------------------------------------------------------------------------------------------------------------------------------------------------------------------------------------------------------------------------------------------------------------------------------------------------------------------------------------------------------------------------------------------------------|
| | | | | Recovery. | Condition. | Cause of death, date after op. | |
| 101 | Dec. 6, 1843. | None. | 27 | Recovered. | Cured (loss of arm). | | Immediately after wound, axillary artery tied by Dr. Cox of Williamsburgh, N. Y.; next day, arm amputated by Dr. Post, 2 inches below head of humerus; in this operation, axillary tied $\frac{3}{4}$ inch above Dr. C.'s ligature; 14 days after amputation, arterial hemorrhage 12 oz.; 21 days after amputation a profuse arterial hemorrhage necessitating ligation of subclavian; external jugular vein divided, and <i>air entered vein</i> ; recovered with no unusual symptoms. |
| 102 | 1841 ? | None. | | | | | 15th day. Pleuritis, pneumonia, empyema. |
| 103 | 1843. | Occurred. | | | | | Hemorrhage ? |
| 104 | April 11, 1844. | | 15 | Recovered. | Cured. | | 11th day after operation, tumor discharging freely; no bad symptoms. |
| 105 | April 6, 1845. | | 13 | Recovered. | Cured. | | Abscess had been opened and hemorrhage resulted for several days; recovery very slow, but without bad symptoms. |
| 106 | 1844. | | | Recovered. | Cured. | | In operation, nerve of brachial plexus was included in ligature; on account of the intense pain, ligature was removed and re-applied; recovered without a bad symptom. |
| 107 | Aug. 17, 1846. | | 23 | Recovered. | Cured. | | |
| 108 | July 29, 1847. | | 15 | Recovered. | Cured. | | 16 years previously, patient fell down stairs and strained his arm; 10 months before operation, tumor increased rapidly; no bad symptoms followed operation. |
| 109 | July 2, 1848. | None. | 26 | Recovered. | Cured. | | During operation, external jugular vein was cut and air entered; recovery slow; ball entered just below clavicle and was cut out of the infra-spinous fossa. |
| 110 | 1848. | 37. | 21 | | | | 37th day. Hem. Was bled on admission; 27th day, sac opened and discharged quite a quantity of offensive blood and pus; 37th day, hem. and death. Autopsy: Artery closed by clot on both sides of ligature; fatal hemorrhage from branches between <i>ligature and sac</i> . |
| 111 | 1848. | | | | | | Next day. Exhaustion, pneumothorax. Resection of humerus immediately after injury. Autopsy: Ball had entered thorax in 3d intercostal space. |
| 112 | March 23, 1849. | | 19 | Recovered. | Cured. | | |
| 113 | Oct. 23, 1849. | | 23 | Recovered. | Cured. | | Erysipelas supervened about 23d day; no other unfavorable symptoms noted. |
| 114 | 1848-50. | | | | | | Pyæmia. |
| 115 | do. | | | | | | do. |
| 116 | do. | | | | | | do. |
| 117 | Feb. 23, 1849. | None. | 18 | Recovered. | Cured (with loss of use hand from ulceration). | | Patient was well and a useful man many years after opera't'n. |

Ligature of the Subclavian Artery in its Third Surgical Division (between

| No. | Name of operator. | Source of information. | PATIENT. | | | Cause of operation. | Duration of cause. | Point of deligation. | Date of injury. | Date of hemorrhage |
|-----|---------------------------------|-----------------------------------------------------|----------|------|-------|---------------------------------------|--------------------|----------------------|-----------------|--------------------|
| | | | Sex. | Age. | Side. | | | | | |
| 118 | Parker, Prof. Willard, 1859. | Notes of cases furnished to author by Prof. Parker. | M. | 32 | R. | Aneurism axilla. | | 3d division. | | |
| 119 | do. 1860. | do. | M. | 39 | R. | do. | | do. | | |
| 120 | do. 1861. | do. | M. | 37 | L. | do. | | do. | | |
| 121 | Goetze, 1850. | Arch. Klin. Chir., Bd. x. p. 230. | M. | 29 | R. | Shot wound under clavicle. | 15 days. | do. | | |
| 122 | Lohmeyer, 1850. | do. | M. | | R. | do. | 23 days. | do. | Oct. 4, 1850. | |
| 123 | Holt, Barnard, 1851. | Lancet, 1852, vol. i. p. 120; 1853, vol. i. p. 133. | M. | 30 | R. | Axillary aneur. | 5 w'ks. | do. | | |
| 124 | Mackenzie, R. J. | Ed. Monthly Jr., Jan. and March, 1852, p. 110. | M. | 29 | R. | do. | 3 w'ks. | do. | | |
| 125 | Gore, 1851. | Guy's Hosp. Reports, vol. xv. p. 72-3. | | | | Subclav. aneur. | | do. | | |
| 126 | Van Buren, Wm. H., 1852. | Contrib. Pract. Surg., V. B., 1865. | M. | 34 | R. | Aneurism, stab wound. | | do. | | |
| 127 | Hamilton, Prof. Frank H., 1852. | Notes of case to author. | M. | 55 | | Removal of large sarcoma from axilla. | | do. | | |
| 128 | Miller, 1853. ? | Arch. Klin. Chir., Bd. x. p. 231. | M. | | | Axillary aneur. | | do. | | |

outer edge of *Scalenus Anticus* and lower border of *First Rib*)—continued.

| No. | Date of operation. | Hemorrh'ge occurred after op. | Lig. came away No. days aft. op. | RESULT. | | | REMARKS. |
|-----|--------------------|-------------------------------|----------------------------------|------------|------------|--------------------------------|--------------------------------------------------------------------------------------------------------------------------------------------------------------------------------------------------------------------------------------------------------------------------------------------------------------------------------------|
| | | | | Recovery. | Condition. | Cause of death, date after op. | |
| 118 | Dec. 13, 1859. | None. | | | | 4th day. Shock. | This man had syphilis, and was of bad and dissipated habits, and could not recover from the shock of so formidable an operation. |
| 119 | Nov. 13, 1860. | None. | 16 | Recovered. | Cured. | | No bad symptoms are noted in the course of recovery. |
| 120 | Oct. 2, 1861. | None. | | Recovered. | Cured. | | The aneurism was caused after lifting a bag of grain. |
| 121 | Nov. 2, 1850. | Occurred. | | | | 5th day. Hem. | Ball entered two fingers' breadth below middle of clavicle, and passed through axilla and out through scapula; hemorrhage on 15th day after injury, which recurred 5 times; 4th day after operation, 2 severe hemorrhages and death. Autopsy: Hemorrhage from distal end of artery, which was found open. |
| 122 | Nov. 3, 1850. | Occurred. | | | | Hemorrhage. | Ball entered below clavicle, passed through axilla, and out through scapula near spina scapulae; wound healed nicely until 23d day; hemorrhage; 4 days later, hemorrhage again; after ligature, hem. ceased until 3d day; on 4th, recurred, and death. Autopsy did not reveal the source of the hem. |
| 123 | June 19, 1851. | | 19 | Recovered. | Cured. | | During the operation a large branch thought to be transversalis colli (more probably the posterior scapular— <i>Author</i>) was mistaken for the subclavian. After the ligature was applied to subclavian, pulsation in sac ceased, but the contents remained fluid for some time. |
| 124 | Nov. 19, 1851. | 18-19-20 | 11 | | | 27th day. Hem. pyæmia. ? | 6th day, rigors, bronchitis; 15th, slight hemorrh'ge from wound; 19th, do. slight; 20th day, do. profuse, arrested by compress; death, 27th. Autopsy: Subclavian vein behind scalenus anticus; large abscess in pleural cavity extending from 4th rib upward; cardiac end of artery open; distal end closed. |
| 125 | 1861. | | | | | Died. | |
| 126 | 1862. | 15 slight. | 15 | Recovered. | Cured. | | Hem. profuse immediately after injury; arrested by pressure; 2d day after ligature, symptoms of gangrene; 4th day, line of demarcation; 7th day, one pound of coagulated blood escaped from sac; 15th, erysipelas and slight hemorrhage; within next month, erysipelas reappeared several times, and patient was at times delirious. |
| 127 | June 23, 1852. | None. | | Recovered. | Cured. | | Dr H. writes: "Whether the tumor returned I do not know, as I lost sight of patient some months after the operation." |
| 128 | 1863. ? | | | Recovered. | Cured. | | |

Ligature of the Subclavian Artery in its Third Surgical Division (between

| No. | Name of operator. | Source of information. | PATIENT. | | | Cause of operation. | Duration of cause. | Point of deligation. | Date of injury. | Date of hemorrhage |
|-----|----------------------------------|--------------------------------------------------|----------|------|-------|------------------------------------------|---------------------------|----------------------|---------------------------|--------------------|
| | | | Sex. | Age. | Side. | | | | | |
| 129 | Caccioppoli, Dom., Naples, 1853. | Gaz. Med. de Paris, 1854, t. ix. p. 62. | M. | 33 | L. | Axillary aneur. (spontaneous). | | 3d division. | | |
| 130 | White, 1853. | Ed. Med. & Surg. Jr., 1854, vol. lxxxii. p. 417. | M. | | L. | Shot wound of axilla; aneurism. | | do. | | |
| 131 | Coppin, 1855. | Arch. Klin. Chir., Bd. x. p. 231. | M. | | R. | Aneurism, axillary (punctured wound). | 3 w'ks. | do. | 3 weeks before operation. | Immediate. |
| 132 | Blaker, 1855. | Guy's Hosp. Reports, vol. xv. p. 70-1. | M. | 59 | R. | Subclav. axillary aneurism (rheumatism). | 2 years. | do. | | |
| 133 | Stanley, 1856. | Arch. Klin. Chir., Bd. x. p. 232. | M. | 40 | R. | Subclav. axillary aneurism. | 6 mos. | do. | | |
| 134 | Gregg, 1857. | Guy's Hosp. Reports, vol. xv. p. 72-3. | M. | 40 | R. | do. | 3 mos. | do. | | |
| 135 | Soule, M. E., 1857. | Arch. Klin. Chir., Bd. x. p. 232. | M. | 22 | R. | Penetured wound of axillary. | | do. | | |
| 136 | Clarke, LeGros. | Lancet, 1859, vol. i. p. 139. | M. | 40 | | Axillary aneur. | | do. | | |
| 137 | do. 1858. | Arch. Klin. Chir., Bd. x. p. 232. | M. | 47 | L. | Subclav. axillary aneurism. | 2 mos. | do. | | |
| 138 | Drayton, H. E., 1859. | Am. Jr. Med. Sci., Oct. 1859, p. 402. | M. | 37 | R. | Subclav. axillary aneurism (fall). | Aneurism existed 15 days. | do. | March 25, 1859. | |
| 139 | Torelli, 1859. | Arch. Klin. Chir., Bd. x. p. 232. | M. | 36 | L. | Axillary aneur. (punctured w'd). | 10 days. | do. | | April 24 |

outer edge of *Scalenus Anticus* and lower border of *First Rib*)—continued.

| No. | Date of operation. | Hemorrhage occurred after op. | Lig. came away No. days aft. op. | RESULT. | | | REMARKS. |
|-----|--------------------|-------------------------------|----------------------------------|------------|------------|---------------------------------------------------------|-------------------------------------------------------------------------------------------------------------------------------------------------------------------------------------------------------------------------------------------------------------------------------------------------------------------------------------------------|
| | | | | Recovery. | Condition. | Cause of death, date after op. | |
| 129 | Feb. 13, 1853. | None. | 19 | Recovered. | Cured. | | Aneurism had been faithfully treated by electro-puncture, but of no avail; after ligature, pulsation in tumor disappeared, but returned in 24 hours; C. then introduced an ivory probe between ligature and loop of ligature, and left it there for some days. No bad symptoms noted. |
| 130 | April 24, 1853. | | 15 | Recovered. | Cured. | | Ball entered left axilla in front, lodged, and was cut out of infra-spinous fossa; hemorrhage immediate and profuse, controlled by pressure. |
| 131 | 1855. | | | Recovered. | Cured. | | A hot iron was thrust into axilla and wounded the artery; hemorrhage immediate and profuse; 3 weeks later, aneurism was discovered; no bad symptoms noted during recovery. |
| 132 | 1855. | 9, 12. | | | | 12th day. Hem. | Patient did well until 9th, when hemorrhage occurred, which proved fatal on 12th. Autopsy: 1st and 2d ribs eroded; large clot in sac; proximal side of artery healthy to near ligature, where it had sloughed and was open; distal side was full of purulent matter and unhealthy. |
| 133 | Aug. 4, 1856. | | | | | 3d day. Pleuritis. | Autopsy: Pint and a half of exudation in <i>left</i> pleural cavity; purulent infiltration of tissues around wound. |
| 134 | 1857. | 8 | | | | 8th day. Pneumonia; pyæmia. Immediate cause hemorrhage. | Pneumonia, abscess, symptoms of pyæmia, and delirium ensued, and on 8th day, during fit of violent and delirious exertion, fatal hemorrhage. Autopsy: Cardiac end of vessel closed; distal end open and a large sized branch opened here (<i>sd. to be internal mammary?</i>) which was cause of hem. |
| 135 | Dec. 13, 1857. | | 20 | Recovered. | Cured. | | |
| 136 | 1858. | 15-16-17 | 14 | | | 15th day. Hem. | Did well to 13th day; patient quarrelled with a fellow patient, and in shaking his fist hemorrhage ensued which was controlled by pressure; on 15th day, repeated hemorrhage, digital pressure; 15th, coughing and hem.; 17th, delirium and hem.; 18th, death. Autopsy: <i>Cardiac end of artery open</i> ; distal end only partially occluded. |
| 137 | Feb. 1858. | | 17 | Recovered. | Cured. | | |
| 138 | April 22, 1859. | | 17 | | | 22d day. Phlebitis; coma. | On 9th day after operation, fever and delirium; jumped from bed and tore wound open; no hemorrhage. Autopsy: Artery closed on both sides of ligatured point. |
| 139 | April 24, 1859. | | 18 | Recovered | Cured. | | 10 days after injury aneurism formed rapidly; hemorrhage on 24th of April, and ligature; 24 days later, thumb and part of index finger amputated on account of gangrene; recovered with partial ankylosis of elbow joint. |

Ligature of the Subclavian Artery in its Third Surgical Division (between

| No. | Name of operator. | Source of information. | PATIENT. | | | Cause of operation. | Duration of cause. | Point of deligation. | Date of injury | Date of hemorrh. ge. |
|-----|-------------------------------------|--------------------------------------------------------------------------|----------|----------|-------|---------------------------------------------------------------------------|--------------------|----------------------|----------------|--------------------------------|
| | | | Sex. | Age. | Side. | | | | | |
| 140 | Paget, 1860. | Guy's Hosp. Reports, vol. xv. p. 70-71. | M. | 54 | R. | Subclav. axillary aneurism (rheumatism). | 4 mos. | 3d division. | | |
| 141 | Busch, W., 1861. | Arch. Klin. Chir., Bd. x. p. 233. | F. | 17 | L. | (Before removal head of humerus and scapula for cancer.) | | do. | | |
| 142 | do. 1862. | do. | F. | 43 | L. | Hem. removal of mammary gland. | | do. | | |
| 143 | do. 1864. | do. p. 234. | F. | 42 | R. | Remov. humerus for carcinoma. | | do. | | |
| 144 | Methner, 1862. | do. | M. | 54 | R. | Hem. (after rem. humerus for carcinoma). | | do. | | |
| 145 | Bennett, H. N. (Conn.), 1862. | Am. Med. Times, Dec. 27, 1862, p. 348. | M. | 20 | L. | Punctured knife-wound axilla. | | do. | | |
| 146 | Furner, 1863. | Dr. Rodgers in Lond. Med. Times & Gaz., vol. ii., 1863, p. 433. | M. | 27 | L. | Axillary aneur., lifting weight. | 10 w'ks. | do. | | |
| 147 | Armsby, Prof., Albany, N. Y., 1863. | Am. Med. Times, 1864, p. 54. | M. | 28 | R. | Aneur., subclav. axillary (after amputation near shoulder). | | do. | | |
| 148 | Knorre, 1864. | Arch. Klin. Chir., Bd. x. p. 234. | M. | 25 | L. | Hem. abscess in axilla. | | do. | | |
| 149 | Vanzetti, 1864. | do. | M. | 40 | L. | Axillary aneur. (punctured w'd). | 2 mos. | do. | | |
| 150 | Venning, Edgecomb. | Lancet, 1865, vol. ii. p. 672. | M. | Mid age. | R. | Aneurism, axillary (fall). | | do. | | |
| 151 | Richet, 1864. | Arch. Klin. Chir., Bd. x. p. 234. | M. | 39 | L. | Hemorrhage (removal of head of humerus). | | do. | | |
| 152 | Browne, R. K. | Am. Jr. Med. Sci. | M. | | | Aneurism axilla (pistol shot wound). | | do. | | |
| 153 | Segond, 1834. | Norris Contrib., p. 224; Arch. Klin. Chir., Bd. x. p. 241. | F. | 40 | | Aneurism axilla (fall, dislocation, and wound of shoulder). | | do. | | |
| 154 | Unknown, C. S. A., 1863. | Dr. H. L. Thomas, C. S. A., in Med. & Surg. Hist. Reb., Part 1., p. 538. | M. | 25 | L. | Shot wound lung, chest, and subclavian artery at lower border of 1st rib. | | do. | July 3, 1863. | Not stated, prob'ly immediate. |

outer edge of Scalenus Anticus and lower border of First Rib)—continued.

| No. | Date of operation. | Hemorrh'ge occurred after op. | Lig. came away No. days aft. op. | RESULT. | | | REMARKS. |
|-----|--------------------|-------------------------------|----------------------------------|------------|---------------------------------|--------------------------------|---------------------------------------------------------------------------------------------------------------------------------------------------------------------------------------------------------------------------------------------------------------------------------------|
| | | | | Condition. | Recovery. | Cause of death, days after op. | |
| 140 | 1860. | 13-23-41-52-65. | 20 | | | 65th day. Hem. | Did well till 13th, hem.; 23d, hem. and pyemic symptoms; hem. on 41st, 52d, and 65th day; death. Autopsy: Sac had suppurated; pus in tissues of shoulder; distal end of ligatured vessel closed; cardiac end closed; (hemorrhage most probably from branches communicating with sac.) |
| 141 | April, 1861. | | | Recovered. | Cured. | | 4 years later patient was perfectly well. |
| 142 | Feb. 8, 1862. | None. | | | | 3d day. Pleuritis. | Breast was extirpated on 28th January, for carcinoma that had returned a third time; Feb. 3d, severe hemorrhage. |
| 143 | July 13, 1864. | None. | | | | 5th day. Septicæmia. | |
| 144 | 1862. | None. | | | | 3d day. Exhaustion. | Patient died, in all probability, from effects of disease with loss of blood before the ligature. |
| 145 | Oct. 12, 1862. | None. | 13 | Recovered. | Cured. | | Hemorrhage after wound immediate and profuse; 2d hemorrhage in a few days, necessitating ligature. |
| 146 | June 18, 1863. | | | Recovered. | Cured. | | A large branch running parallel with subclavian was also tied; a small sized tumor persisted some time after recovery. |
| 147 | Nov. 19, 1863. | | 29 | Recovered. | Cured. | | July 7th, arm shattered by accidental discharge of cannon; amputation near shoulder 3 days later; 5 months, aneurism having appeared, burst and discharged 3 qts. of blood. |
| 148 | May 19, 1864. | | 11 | Recovered. | Cured. | | |
| 149 | July 27, 1864. | | 12 | Recovered. | Cured. (?) | | Digital compression had been tried but failed; after recovery, tumor diminished in size, but was filled with liquid. |
| 150 | Sept. 1864. | Once. | 11 | Recovered. | Cured. (Anchylolysis of elbow.) | | Hemorrhage occurred after operation in October; pyæmia also ensued. |
| 151 | 1864. | | | | | 4th week. Exhaustion. | |
| 152 | ? | | | | | Died. ? | (Author read notice of this case and took notes at time as given, but failed to note date of journal. The case as given is reliable.)— <i>Author.</i> |
| 153 | April 5, 1834. | | 11 | Recovered. | Cured. | | Patient slipped and fell upon an earthen vessel, dislocated arm, and wounded axilla with fragments driven in; humerus reduced by non-professional; 4 or 5 days later, profuse hemorrhage, and one month later, aneurism. |
| 154 | July 3, 1863.? | None noted. | | Recovered. | Paralysis of left arm. | | "One of the nerves of the brachial plexus, probably, having been included in the ligature." ⁵ (Although this accident has happened in several instances, the paralysis in this case could equally have been due to injury from missile.— <i>Author.</i>) |

Ligature of the Subclavian Artery in its Third Surgical Division (between

| No. | Name of operator. | Source of information. | PATIENT. | | | Cause of operation. | Duration of cause. | Point of deligation. | Date of injury. | Date of hemorrhage. |
|-----|---------------------------------------|-----------------------------------------------------------------------------------|----------|-------------|-------|----------------------------------------------|--------------------|----------------------|--------------------|---------------------|
| | | | Sex. | Age. | Side. | | | | | |
| 155 | Azpell, Thos. F., U. S. A., 1862. | Med. Surg. Hist. Reb., Part I., p. 538. | M. | 20 | L. | Aneurism, shot wound left axilla. | 7 days. | 3d division. | April 7, 1862. | April 8. |
| 156 | Unknown, C. S. A., 1863. | Dr. H. L. Thomas, C. S. A., in Med. & Surg. Hist. Reb., Part I., p. 538. | M. | 23 | L. | Shot wound left axilla. | 15 days. | do. | July 2, 1863. | Imme- diate. |
| 157 | Pancoast, G. L., ? U. S. A., 1865. | Med. Surg. Hist. Reb., Part I., p. 539. | M. | 21 | R. | Shot wound right axilla. | 43 days. | do. | M'ch 25, 1865. | M'ch 29. |
| 158 | Gross, F. H., U. S. A., 1864. | do. | M. | 28 | R. | Shot wound right axilla; aneur. | 106 days. | do. | June 5, 1864. | None noted. |
| 159 | Fuller, E. S. E., 1864. | do. p. 539. | M. | 19 | R. | Shot wound axil- lary artery. | 11 days. | do. | Nov. 30, 1864. | Occ- urred. |
| 160 | Shrady, Geo. F., 1864. | do. | M. | 21 | R. | Hem. shot wound axilla. | 12 days. | do. | May 9, 1864. | do. |
| 161 | Curtis, Edward, 1864. | do. | M. | 28 | R. | do. | 28 days. | do. | June 27. | July 14 and 24. |
| 162 | Unknown, Surgeon C. S. A. | Dr. H. L. Thomas in Med. Surg. Hist. Reb., p. 540. | M. | Mid age. | R. | Hem. wound of right shoulder. | 22 days. | do. | Sept. 19, 1863. | Oct. 10. |
| 163 | Mosely, N. R., 1864. | Med. Surg. Hist. Reb., p. 540. | M. | 21 | R. | Hem. shot wound right axilla. | 14 days. | do. | June 3, 1864. | Occ- urred. |
| 164 | Townsend, T. B., ? 1864. | do. | M. | 35 | L. | Shot wound left shoulder and ax- illa. | 29 days. | do. | May 20, 1864. | do. |

outer edge of *Scalenus Anticus* and lower border of *First Rib*)—continued.

| No. | Date of operation. | Hemorrhage occurred after op. | Lig. came away No. days aft. op. | RESULT. | | | REMARKS. |
|-----|--------------------|-------------------------------|----------------------------------|------------|---------------------------------|---------------------------------------|-------------------------------------------------------------------------------------------------------------------------------------------------------------------------------------------------------------------------------------------------------------------------------------------------------------------------------------------------------------------------------------------------|
| | | | | Recovery. | Condition. | Cause of death, date after op. | |
| 155 | April 14, 1862. | | 36 | Recovered. | Partial disability of left arm. | | "Ball entered near collar bone, cut out lower edge of scapula, atrophy of muscles of arm and shoulder. Disability one-half temporary. Still a pensioner in 1872." |
| 156 | July 17, 1863. | Immediate. | 13 | Recovered. | Cured | | Great tumefaction in region of wound; as hemorrhage did not cease with ligature of subclavian, the supra-scapular was also tied; ligature from supra-scapular on 10th day; no bad symptoms followed; ball entered 1½ inch below left scapula, ranged forward, and lodged. |
| 157 | May 7, 1865. | None. | | Recovered. | Total disability of arm. | | Musket ball through the right shoulder and axilla; disability total; still pensioned in 1872. |
| 158 | Sept. 19, 1864. | | | Recovered. | Not cured of aneurism. | | Ball entered one inch below centre of right clavicle, and passed directly through. In 1867, "no use of right arm, total disability from aneurism alone, liable to death, by rupture, upon any exertion." In 1872, still a pensioner. |
| 159 | Dec. 11, 1864. | 5th day. | | | | 5th day. Hem. | Hem. occurred from sloughing of axillary artery. |
| 160 | May 31, 1864. | Three times. | | | | 50 hours. Exhaustion; hemorrhage. | Minnie ball, in through pectoralis major, and out 2 inches above posterior fold of axilla; 2 days after ligature of subclavian, a vein was tied at seat of wound. Autopsy: Slough had destroyed portion of supra-scapular artery and axillary vein. |
| 161 | July 25, 1864. | 2 days. | | | | 16th day. Exhaustion; hemorrhage. | Ball entered right shoulder posteriorly and lodged in axilla, passing through scapula just below spine; 17 days after wound, hemorrhage 3 pints, ligature of axillary; 10 days later, hemorrhage, and on the next day, 28 days after injury, ligature of the subclavian. Autopsy not given; hemorrhage reported as from <i>distal</i> side of ligature and from <i>distal end of axillary</i> . |
| 162 | Oct. 11, 1863. | None. | | | | 10th day. Gangrene; exhaustion. | Ball fractured head of humerus, near coracoid process, and passed out above <i>spina scapulae</i> . Fever and suppuration followed; after ligature of subclavian (9 days) gangrene supervened. |
| 163 | June 17, 1864. | 12th day. | | | | 12th day. Hem. | Patient was of hemorrhagic diathesis and was suffering from a cough; artery gave way 12th day, and death was almost instantly the result. "There were slight fibrinous exudations on either side of where the ligature cut through." (I judge from this that the hemorrhage was at the seat of ligature, and probably from <i>cardiac side</i> .— <i>Author</i> .) |
| 164 | June 18, 1864. | None. | | | | 6th day. Gangrene; exhaust'n; pyæmia. | Ball entered under spine of left scapula and ranged toward chest; gangrene and hemorrhage followed; after ligature of subclavian, no hemorrhage, but rigors and pyæmic symptoms. |

Ligature of the Subclavian Artery in its Third Surgical Division (between

| No. | Name of operator. | Source of information. | PATIENT. | | | Cause of operation. | Duration of cause. | Point of deligation. | Date of injury. | Date of hemorrhage. |
|-----|------------------------------|------------------------------------------------------------|----------|-------------|-------|-----------------------------------------------------------|---------------------|----------------------|-------------------|-----------------------------------|
| | | | Sex. | Age. | Side. | | | | | |
| 165 | Brown, F. H., 1862. | Med. Surg. Hist. Reb., p. 540. | M. | Mid age. | L. | Shot wound arm and axilla. | 23 days. | 3d divi- sion. | May 31, 1862. | June 19. |
| 166 | Hodgen, J. T., 1862. | do. | M. | 19 | L. | Shot wound left axilla. | 19 days. | do. | Oct. 3, 1862. | Oc- curred. |
| 167 | Sheldon, A. V., 1864. | do. | M. | 22 | R. | Shot wound right arm and shoul- der. | 11 days. | do. | May 8, 1864. | May 29. |
| 168 | Allen, Harrison, 1864. | Med. Surg. Hist. Reb., Part. 1., p. 541. | M. | 28 | R. | Shot wound right axilla and shoul- der. | 9 days. | do. | Oct. 27, 1864. | Oc- curred. |
| 169 | Gross, Prof. S. D., 1863. | Dr. Jno. J. Reese in Med. Surg. Hist. Reb., p. 541. | M. | Mid age. | L. | Shot wound left axilla; hemor'ge; diffuse aneurism. | 8 mos., 20 days. | do. | June 25, 1862. | Mar 14. |
| 170 | McClellan, E., ? 1865. | do. | M. | 39 | L. | Shot wound left shoulder; aneu- rism. | 58 days. | do. | April 2, 1865. | Several times. |
| 171 | Baylor, J. C., 1863. | Dr. P. F. Browne in Med. Surg. Hist. Reb., p. 541-2. | M. | Mid age | R. | Shot wound right axilla. | 38 days. | do. | Nov. 8, 1863. | |
| 172 | Selden, Wm., 1864. | Surg. Hist. Reb., p. 542. | M. | 29 | L. | Shot wound left axilla. | 39 days. | do. | June 14, 1864. | Imme- diate and profuse. |

outer edge of *Scalenus Anticus* and lower border of *First Rib*)—continued.

| No. | Date of operation. | Hemorrhage occurred after op. | Lig. came away No. days aft. op. | RESULT. | | | REMARKS. |
|-----|--------------------|-------------------------------|----------------------------------|-----------|------------|---------------------------------------------|--------------------------------------------------------------------------------------------------------------------------------------------------------------------------------------------------------------------------------------------------------------------------------------------------------------------------------------------------------------------------------------------------------------------------------------------------------------------------------------------|
| | | | | Recovery. | Condition. | Cause of death, date after op. | |
| 165 | June 23, 1862. | None. | | | | 4th day. Pyæmia. (?) | Ball entered left arm at deltoid insertion, out at posterior border of axilla; bone not injured; great prostration at time of operation, from previous hemorrhage. |
| 166 | Oct. 22. | 7-9 ? | | | | 9th day. Exhaustion; hemorrhage. | No autopsy. |
| 167 | May 29, 1864. | 17-21. | | | | 21st day. Hem. | 21 days after injury, hem. 40 oz. occurred; hem. when ligature came away; arrested by compression, but recurred fatally. No autopsy. Tied beneath the clavicle. Given as subclavian. |
| 168 | Nov. 5, 1864. | 10, 11 13 days. | 10 | | | 13th day. Hem. | Ball entered near lower edge of clavicle and emerged at upper angle of scapula; extensive slough and suppuration; did well for 10 days after ligature, then on ligature coming away, slight hem.; compression. Autopsy: Nothing of interest. (Tied below clavicle. From direction and location of wound it is evident that the subclavian was tied on first rib, and very likely in the wound of entrance. — <i>Author.</i>) |
| 169 | March 15, 1863. | None. | | | | 2d day. Exhaustion; (shock ?) | Three months after injury, both wounds (of exit and entrance) were healed; Feb. 1st, swelling in axilla began; March 1st, there was perceptible fluctuation, but no thrill; March 14, profuse arterial hemorrhage; after ligature extreme prostration. "Reaction never fairly set in." No autopsy. |
| 170 | May 30, 1865. | 9. | | | | 12th day. Exhaust'n. | Ball entered just below clavicle, emerging at inferior angle of scapula; secondary hemorrhage several times; after ligature, tumor decreased very rapidly; 9th day, hemorrhage. Autopsy: Ligature still on artery, and clot on either side; no clot in sac. (Fatal hemorrhage was very probably from vessels communicating with sac.— <i>Author</i>) |
| 171 | Dec. 16, 1863. | Next day. | | | | 18 hours. Exhaustion; hemorrhage. | About one month after injury, aneurism appeared; after the ligature, the sac was opened and clot turned out, and ineffectual attempts made to secure the bleeding vessels; tampon was used. Autopsy: Ligature was firmly tied around artery; hem. had occurred through collateral circulation through sac.) |
| 172 | July 23, 1864. | None. | | | | 8th day. Hemorrhage; erysipelas; pleuritis. | Although axillary artery was divided, patient rode 8 miles, closely pursued for 3; hem. profuse but ceased spontaneously; did well, suffering only slightly from aneurismal swelling until 2d day, when hem. took place, 1 pint; 3 days after ligature, erysipelas ensued; 6th day, pleuritis; died 8th day. Autopsy: Axillary vein and artery cut in two by ball; no clot on either side of ligature; copious effusion in left pleura; no fibrinous clot in aneurismal sac; pericarditis. |

Ligature of the Subclavian Artery in its Third Surgical Division (between

| No. | Name of operator. | Source of information. | PATIENT. | | | Cause of operation. | Duration of cause. | Point of deligation. | Date of injury. | Date of hemorrh. &c. |
|-----|----------------------------|-----------------------------------------------------------------|----------|---------------------|------|----------------------------------------------------|--------------------|----------------------|--------------------|-----------------------------------------------------------------------------------|
| | | | Sex. | Age | Side | | | | | |
| 173 | Lidell, Jno. A., 1863. | Med. Surg. Hist. Reb., Part I., p. 543-4. | M. | 31 | L. | Aneurism, shot w'nd left axilla. | 23 days. | 3d divi- sion. | June 21, 1863. | June 21. |
| 174 | Coolridge, R. H., 1863. | Isaac Norris, Jr., in Med. Surg. Hist. Reb., p. 545. | M. | 28 | R. | Aneur., axillary, shot wound. | 67 days. | do. | June 9, 1863. | None noted as im- mediate Doubt- less it occu'd 66th day. |
| 175 | Morton, J. C., 1864. | Dr. C. Wagner in Med. Surg. Hist. Reb., Part II., p. 440. | M. | 33 | R. | Shot; flesh w'nd of right arm. | 21 days. | do. | Sept. 30, 1864. | Occu- red. |
| 176 | McLean, C. R., 1863. | Dr. J. Hopkinson in Med. Surg. Hist. Reb., p. 440. | M. | 25 | R. | do. | 51 days. | do. | July 2, 1863. | July 23; Aug. 1-23. |
| 177 | Morton, T. G., 1864. | Dr. W. S. Hendrie in Med. Surg. Hist. Reb., p. 441. | M. | 22 | R. | do. | 27 days. | do. | June 4, 1864. | June 25-30; July 1. |
| 178 | McKee, J. C. | Med. Surg. Hist. Reb., Part II., p. 468. | M. | 34 ? Mid age. | L. | Shot wound and amputation at shoulder-joint. | 3 mos. | do. | May 28. | |
| 179 | Humphrey, O. M. | do. p. 634. | M. | 18 | R. | Solid shot wound shoulder-joint; amputation. | 8 days. | do. | Jan. 30, 1863. | |

outer edge of Scalenus Anticus and lower border of First Rib)—continued.

| No. | Date of operation. | Hemorrh'ge occurred after op. | Lig. came away No. days aft. op. | RESULT. | | | REMARKS. |
|-----|--------------------|--------------------------------------|----------------------------------|-----------|------------|--------------------------------------------|---------------------------------------------------------------------------------------------------------------------------------------------------------------------------------------------------------------------------------------------------------------------------------------------------------------------------------------------------------------------------------------------------------------------------------------------------------------------------------------------------------------------------------------------------------------------------------------------------------------------------------------------------------------------------------------------------------------------------------------------------------|
| | | | | Recovery. | Condition. | Cause of death, date after op. | |
| 173 | July 14, 1863. | 24, 28, 29 | 18 | | | 46th day. Hemorrhage; suppuration. | Ball entered axilla from in front, wounding axillary artery and some of brachial plexus; hem. immediate to syncope; ceased spontaneously; 19th day after wound, aneurism was noticed, no thrill; had felt something "give way" on moving his arm; 21 days after wound, ligature of subclavian; tumor diminished immediately; 5th day, sac burst, and on this and following day discharged several ounces of bloody pus; 18th day, ligature loose; 24th day, profuse hem. from sac; liq. ferri persulph. locally arrested hem.; 28th and 29th, hemorrhage; 40th, 41st, and 42d days, suppuration assumed very offensive character; death, 46th day. Autopsy: Firm clot on both sides of ligature; cicatrices (seemingly tuberculous) on apices of lungs. |
| 174 | Aug. 17, 1863. | None. | | | | 6 hours. Hem. before op'n. Shock? Dyspnea. | Autopsy: Large nerve included in ligature; (Patient had died with symptoms of great dyspnea.) (It is most probable that this nerve was the <i>posterior thoracic</i> , which had been pressed by the aneurism toward the scalenus. Simple ligature of a cord of the brachial plexus going to the arm would not produce such symptoms of dyspnea. This last accident has happened quite frequently.— <i>Author.</i>) |
| 175 | Oct. 21, 1864. | None. | | | | 31st day. Hem. before op'n; exhaustion. | Hemorrhage twelve days after wound; brachial tied; 9 days later, hemorrhage again; subclavian tied; patient improved for a while, but died of exhaustion 31st day. |
| 176 | Aug. 23, 1863. | 9th day. | | | | 9th day. Hem. | July 23d, hem. from brachial, and this vessel tied; Aug. 2, amputation of arm for hem.; Aug. 23, hem. from axillary, and ligature of subclavian; did not do well, and died from hem. Sept. 1. Autopsy: Proximal side of ligature closed by clot; hemorrhage was <i>distal</i> . Below clavicle. |
| 177 | July 1, 1864. | Occurring during, and prob'ly after. | | | | 1 hour. Exhaust'n; hemorrhage. | Hem. from brachial June 25, and axillary tied; June 30th, hem. and compression; July 1, hem. from axillary at ligature; subclavian tied; lost 30 oz. blood in operation, and died in one hour. Dr. W. P. Moon tied the axillary. Autopsy not given. Below clavicle. |
| 178 | Sept. 1, 1864. | Not noted. | | | | 2d day. Cause? | Shot passed through left axilla and aneurism resulted; subclavian tied at amputation. (Cases Nos. 178 to 184, inclusive, were most likely ligatured beneath the clavicle.— <i>Author.</i>) |
| 179 | Feb. 7, 1863. | None. | | | | 20th day. Exhaustion. | Right arm torn off by shot; profuse hem.; immediate amputation by Dr. G. C. Harlan; 7 days later, profuse hem.; Feb. 7, lig. of subclavian, by Dr. Humphrey. |

Ligature of the Subclavian Artery in its Third Surgical Division (between

| No. | Name of operator. | Source of information. | PATIENT. | | | Cause of operation. | Duration of cause. | Point of deligation. | Date of injury. | Date of hemorrhage. |
|-----|------------------------|---------------------------------------------|----------|----------|-------|-------------------------------------------------------------------|--------------------|----------------------|-----------------|---------------------|
| | | | Sex. | Age | Side. | | | | | |
| 180 | Curtis, E. | Med. Surg. Hist. Reb., Part II., p. 635. | M. | 34 | L. | After amputation at shoulder-joint | | 3d division. | June 15, 1864. | July 13; Aug. 5, 6. |
| 181 | Hasson, A. B. | do. p. 643. | M. | 26 | L. | Amputation at shoulder-joint. | | do. | Sept. 17, 1862. | |
| 182 | Morton, J. C. | do. p. 648. | M. | 32 | L. | Hem. axilla; shot wound humerus and scapula. | | do. | Aug. 16, 1864. | |
| 183 | Day, W. E., 1864. | do. Part I., p. 421. | M. | Mid age. | L. | Shot wound root of neck. | | do. | Oct. 6, 1864. | Dec. 14. |
| 184 | Howard, B., 1863. | do. p. ? | M. | 27 | L. | Shot wound of humerus. | | | May 3, 1863. | Occurred. |
| 185 | Levis, R. J. | do. Part II., p. 716. | M. | 21 | L. | Shot wound left arm; amputation. | | | June 18, 1864. | July 25; Aug. 8. |
| 186 | Morton, J. C., 1864. | do. p. 545. | M. | 21 | L. | Secondary hemorrhage after excision of humerus for shot fracture. | 36 days. | 3d division. | Aug. 16, 1864. | Sept. 21. |
| 187 | Wagner, C., 1864. | do. p. 650. | M. | 23 | R. | Hemorrhage from axillary after excision of humerus. | 43 days. | do. | Oct. 8, 1864. | Nov. 21. |
| 188 | Oakes, T. F., 1864. | do. p. 636. | M. | 22 | L. | Excision after shot fracture of humerus. | A few hours. | do. | July 30, 1864. | |
| 189 | Otis, G. A., 1862. | do. p. 760. | M. | 21 | R. | Amputation of upper 3d after shot wound of humerus (hem.?). | 10 days. | do. | March 14, 1862. | |
| 190 | Unknown, 1862. | Med. Surg. Hist. Reb., by Dr. H. L. Thomas. | M. | 19 | L. | Shot wound left shoulder. | 8 days. | do. | May 31, 1862. | June 7. |
| 191 | do. | Med. Surg. Hist. Reb. | M. | Mid age | | Shot wound of humerus. | | do. | | |
| 192 | do. 1863. | do. | M. | 30 | R. | do. | | do. | Jan. 11, 1863. | 12th. |
| 193 | do. 1864. | do. | M. | Mid age. | R. | do. | | do. | July 14, 1864. | Occurred. |
| 194 | Humphrey, O. M., 1864. | Am. Med. Times, vol. vii., p. 161, 1864. | M. | 21 | L. | Crush of arm (railroad accident). | | | | |

outer edge of Scalenus Anticus and lower border of First Rib)—continued.

| No. | Date of operation. | Hemorrhage occurred after op. | Lig. came away No. days aft. op. | RESULT. | | | REMARKS. |
|-----|--------------------|-------------------------------|----------------------------------|------------|----------------------------------|----------------------------------------------------------------------------------------------------------------------------------------------------------------------------------------------------------------------------------------------------------------------------------------------------------------------------------------------------|----------|
| | | | | Recovery. | Condition. | Cause of death, date after op. | |
| 180 | Aug. 6, 1864. | Not given if it occurred. | | | 11th day. Exhaustion. | Amputation at shoulder, June 15, for shell wound; July 13, hem.; axillary artery tied; hem. again, Aug. 5th and 6th; death, Aug. 17th, 1864. | |
| 181 | Sept. 27, 1862. | | | | Few hours. Exhaustion; gangrene. | Fracture of humerus, Sept. 17; ball extracted, Sept. 23; Sept. 26, hemorrhage from sloughing; gangrene; died few hours after last ligature. | |
| 182 | Sept. 26, 1864. | | | Recovered. | Cured, amputation at shoulder. | Dr. J. E. Chesely amputated the arm on same day. | |
| 183 | Dec. 14, 1864. | | | | 4th day. ? | Ball passed through neck at outer edge of left sterno-mastoideus, about 2 inches above clavicle. | |
| 184 | May or June, 1863. | | | | July 18th. Exhaustion. | Humerus was amputated at upper third. | |
| 185 | Aug. 8, 1864. | 7th. | | Recovered. | Cured. | Amputation at upper 3d, on June 18; (?) hemorrhage from and ligature of axillary July 25th, by Dr. G. B. Boyd; Aug. 8th, hemorrhage from ligature, and ligature of subclavian over 1st rib; hem. again on 7th day, controlled by pressure; (Dr. T. H. Squire amputated arm;) after ligature of subclavian, pressure was continued for 6 weeks. | |
| 186 | Sept. 21, 1864. | Not noted. | | | 2d day. Not given. Exhaustion. | Shot fracture head of left humerus, much destruction of tissues. | |
| 187 | Nov. 21, 1864. | | | | 6th day. Exhaust'n. | After excision, arm amputated at shoulder, by Dr. J. C. Morton; 10 days later, hemorrhage and ligature of subclavian. | |
| 188 | July 30, 1864. | | | | 9th day. Exhaust'n. | | |
| 189 | March 24, 1862. | | | | 22d day. Pyæmia. (April 15th.) | | |
| 190 | June 7, 1862. | | | | 11th day. (Exhaustion?) | Ball wounded spinal cord, causing paralysis. | |
| 191 | Aug. 1862. | | | | Died. | | |
| 192 | Jan. 12, 1863. | | | | 29th day. Exhaustion. | Arm amputated at middle third; hemorrhage recurred and ligature of subclavian. | |
| 193 | Soon after. | | | | Died Aug. 30, 1864. | | |
| 194 | | | Before 28. | Recovered. | Cured. | January 17, amputation at upper third humerus; 6 days later, hemorrhage; 7th, do.; 14th, do. profuse; Feb. 1, ligature of subclavian; no unfavorable symptoms except slight surgical fever. I infer that this case will appear in the 3d surgical volume of the Med. and Surg. History, as Dr. Otis has given one case by Dr. H. from same source. | |

Ligature of the Subclavian Artery in its Third Surgical Division (between

| No. | Name of operator. | Source of information. | PATIENT. | | | Cause of operation. | Duration of cause. | Point of deligation. | Date of injury. | Date of hemorrhage. |
|-----|-------------------------|------------------------------------------------------------------|----------|-------|-------|-------------------------------------------------------|--------------------|----------------------|------------------|--------------------------------------------|
| | | | Sex. | Age. | Side. | | | | | |
| 195 | Unknown. | Med. Surg. Hist. Reb. | M. | | | | | | | |
| 196 | do. | do. | M. | | | | | | | |
| 197 | do. | do. | M. | | | | | | | |
| 198 | do. | do. | M. | | | | | | | |
| 199 | do. | do. | M. | | | | | | | |
| 200 | do. | do. | M. | | | | | | | |
| 201 | do. | do. | M. | | | | | | | |
| 202 | Thiersch, 1865. | Arch. Klin. Chir., Bd. x. p. 236. | M. | 28 | R. | Subclav. axillary aneurism (punc- tured wound). | 9 days. | 3d divi- sion. | | Imme- diate, and Jan. 16. |
| 203 | Busch, W. | do. p. 237. | M. | | R. | Hemorrhage after opening abscess of axilla. | | do. | | |
| 204 | do. 1865. | do. p. 236. | M. | | L. | Hemorrh'ge (after punctured w'd). | | do. | | |
| 205 | do. 1866. | do. p. 241. | M. | | L. | Shot wound of axilla. | 23 days. | do. | July 3. | |
| 206 | Church, W. H., 1865. | Dr. H. G. Piffard in Am. Jr. Med. Sci., Oct. 1865, p. 393. | M. | 31 | L. | Suicidal shot w'd of axilla. | | do. | June 3, 1865. | June 3, slight; June 13, profuse. |

outer edge of *Scalenus Anticus* and lower border of *First Rib*)—continued.

| No. | Date of operation | Hemorrhage occurred after op. | Lig. came away No. days aft. op. | RESULT. | | | REMARKS. |
|-----|-------------------|-------------------------------|----------------------------------|------------|------------|------------------------------------|-------------------------------------------------------------------------------------------------------------------------------------------------------------------------------------------------------------------------------------------------------------------------------------------------------------------------------------------------------------------------------------------------------------------------------------------------------------------------------------------------------------------------------------------------------------------------------------------------------------------------------------------------------------------------------------------------------------------------------------------------------------------------------------------------------------------------------------------------------------------------------------|
| | | | | Recovery | Condition. | Cause of death, date after op. | |
| 195 | | | | | | Died. | At the foot of page 547, of 1st surg. volume of his magnificent history, Dr. G. A. Otis says: "I shall enumerate a total of 52 cases of ligature of the subclavian (in a future volume) with 41 deaths." I have been able to find, and have given heretofore (from the 1st and 2d volume), 45 cases, 37 of which were fatal. There is left to be recapitulated in the 3d volume, an additional number of 7 cases, of which 4 (+ 37 = 41) were fatal, and 3 recovered. I have (in order to be as exact as possible) included Dr. O. M. Humphrey's case, as I am sure Dr. Otis will have this case in the 3d volume. I could not obtain from the Surgeon-General's office advance copies of these cases, on account of the labor requisite to hunt them out in advance. I am under many obligations to Dr. Otis for prompt answers to inquiries and other courtesies.— <i>Author.</i> |
| 196 | | | | | | do. | |
| 197 | | | | | | do. | |
| 198 | | | | | | do. | |
| 199 | | | | Recovered. | | | |
| 200 | | | | Recovered. | | | |
| 201 | | | | Recovered. | | | In this category I might include 4 fatal cases of ligature of subclavian for shot wounds, by Hopkinson, Wells, Kennedy, and Anderson, given by Prof. T. G. Morton, in <i>Am. Journal Med. Sci.</i> , July, 1867. These are doubtless included by Dr. Otis in the above 52 cases, and I have so considered them rather than incur the risk of counting them twice. |
| 202 | Jan. 17, 1865. | 17th-29th Jan'y. | 7 | | | 14th day. Pyæmia; hemorrhage. | 4th and 5th days, symptoms of pneumonia; 6th and 7th, rigors and pyæmic symptoms; unfavorable conditions increased, a diarrhœa occurred, and death on 14th day. The ligature of the subclavian did not arrest the hem. completely, and operator could not tie bleeding vessels in wound on that account. |
| 203 | Unknown. | | | | | 6th day. Pyæmia. | Patient was in 6th week of a spell of low fever, and was consequently much exhausted. Abscesses in various parts of body. |
| 204 | Sept. 11, 1865. | Occurred. | | | | 11th day. Pyæmia; hemorrhage. | Gangrene of forearm just before death; numerous abscesses in lungs; <i>artery firmly closed on both sides of ligature</i> ; both axillary artery and vein wounded, the latter most so. |
| 205 | July 26, 1866. | | 14 | Recovered. | Cured. | | Arm slightly paralyzed from injury to nerves by missile. |
| 206 | June 13, 1865. | Occurred. | | | | 3d day. Exhaust'n; hem.; gangrene. | Before operation, hemorrhage 16 oz.; 3d day, do. 6 oz. Autopsy: Axillary wounded in 2d division; diffuse aneurism; gangrene of arm (slight). |

Ligature of the Subclavian Artery in its Third Surgical Division (between

| No. | Name of operator. | Source of information. | PATIENT. | | | Cause of operation. | Duration of cause. | Point of deligation. | Date of injury. | Date of hemorrhage |
|-----|------------------------|--------------------------------------------------------------------------|----------|---------|-------|---------------------------------------------------------------------|--------------------|----------------------|-----------------|--------------------|
| | | | Sex. | Age. | Side. | | | | | |
| 207 | Schauerburg, 1866. | Arch. Klin. Chir., Bd. x. p. 236. | M. | Soldier | R. | Hemorrhage (shot wound shoulder-joint fracture). | | 3d division. | | |
| 208 | Asch, 1866. | do. | M. | Soldier | | Axillary aneur. (shot wound). | | do. | | |
| 209 | Auvert. | Schmidt Jahrbuch., Bd. xvii. p. 341, 1858. | M. | 36 | R. | Subclav. axillary aneurism. | | do. | | |
| 210 | Demme, Sr. | Arch. Klin. Chir. (cit.), p. 237. | M. | | L. | | | do. | | |
| 211 | Forster. | do. | M. | Soldier | L. | Punctured wound of axilla. | | do. | | Profuse. |
| 212 | Chassaignac. | Chassaignac traité Clin. et Pratique, Paris, 1861, t. i. p. 316. do. | M. | | | Hemorrhage after excision of humerus. | | do. | | Occur'd often |
| 213 | | | M. | | | Hemorrh'ge (after division of cicatricial contractions in axilla?). | | do. | | Often. |
| 214 | Lannelongue, Bordeaux. | Schmidt Jahrbuch., Bd. cxv., 1862, p. 376. | | | | Aneurism of axillary (traumatic). | | do. | | |
| 215 | Legouest. | Legouest Chir. d'armée, 1863, p. 421; Arch. Klin. Chir., (cit.), p. 238. | M. | Soldier | | Hemorrhage (resection of humerus). | | | | |
| 216 | Middeldorpf. | Arch. Klin. Chir., (cit.), p. 238. | F. | | L. | ? | | | | |
| 217 | Nélaton. | Schmidt Jahrbuch., 1856, Bd. lxxxix. p. 225. | | | L. | Aneurism (sub-glenoid dislocation). | | | | |
| 218 | Pelican. | Arch. Klin. Chir., Bd. x. p. 239. | M. | | | Hemorrh'ge (after disarticulation of humerus). | | | | |
| 219 | Nussbaum. | Arch. Klin. Chir., Bd. x., 1869, p. 238. | F. | | R. | Hem. during removal of axilla. | | 3d division. | | |
| 220 | do. | do. | | | | Hem. punctured wound axilla. | | | | |
| 221 | do. | do. | | | | Immense tumor of axilla. | | | | |
| 222 | O'Reilly, Dublin. | Cyclop. of Anat. Phys., vol. iv. p. 616-17. | M. | 50 | L. | Diffuse aneurism. | | | | |
| 223 | Pirogoff. | Arch. Klin. Chir. (cit.); Pirogoff's Military Surgery, p. 449. | M. | Soldier | | Hemorrh'ge (after ligature of brachial for traumatic aneurism). | | | | |

outer edge of *Scalenus Anticus* and lower border of *First Rib*)—continued.

| No. | Date of operation. | Hemorrhage occurred after op. | Lig. came away No. days aft. op. | RESULT. | | | REMARKS. |
|-----|--------------------|-------------------------------|----------------------------------|----------------|---------------------------|----------------------------------|------------------------------------------------------------------------------------------------------------------------------------------------------------------------------------------------------------------------------------------------------------------------------------------------------------------------------------------------------------------------------------------------------------------------------------------|
| | | | | Recovery. | Condition. | Cause of death, date after op. | |
| 207 | July, 1866. | | | | | 2d day. Pneumothorax; pneumonia. | Puncture of pleura during passage of needle around artery; violent influx of air to pleural cavity. Autopsy: Right lung completely collapsed and pressed against vertebral column; pleuritis; pneumonia of left lung. |
| 208 | 1866. | Occurred. | | | | Hemorrhage. | |
| 209 | ? | 13, 14 | | | | 22d day. Hemorrhage; pneumonia. | Pneumonia accompanied with cough supervened and hemorrhage occurred 13th and 14th days after operation. Autopsy: Pneumonia; rupture of artery at seat of ligature. |
| 210 | ? | | | Recovered. | Cured. | | |
| 211 | ? | None. | | | | 8th day. Gangrene. | Did well until 4th day, when gangrene ensued, causing death on 8th day. |
| 212 | ? | | | One recovered. | Cured. | | I can find nothing more definite concerning these two cases than this short extract in Chassaig-nac's work cited: "Deux fois j'ai pratiqué la ligature de la sous-clavière; une fois avec succès chez un malade qui avoit subi le disarticulation de l'épaule suivie d'hémorrhagie consecutive. Une autre fois chez un homme qui apres la section d'un bride inondulaire de l'aisselle avoit en des hemor-rhagies recidivées."—(Author.) |
| 213 | ? | | | | | One died. | (I could not obtain the Journal de Bordeaux, where a full account of this case is given. The <i>Jahrbuch</i> only contains announcement.—Author.) |
| 214 | ? | | | | | Died. | |
| 215 | ? | Once. | | Recovered. | Cured. | | |
| 216 | ? | | | | | Pyæmia. | |
| 217 | ? | Once. | | | | Several days. Hem. | Rupture of sac; death. Autop-sy: Arteria dorsalis scapulæ opened into sac. |
| 218 | ? | | | | | Died. | |
| 219 | ? | | | Recovered. | Cured. ? | | |
| 220 | ? | | | Recovered. | Cured. | | |
| 221 | ? | | | | | Died. | (Dr. Wilhelm Koch gives this as a fatal case. Nusbaum says the operation was <i>unsuccessful</i> . As the probability is that Dr. N. told Prof. Gurlt it was fatal (see Archiv), I have so marked it.—Author.) |
| 222 | 1833. | | | Recovered. | Cured (lost two fingers.) | | Thrown by runaway horse dislocation of shoulder; reduction; aneurism appeared (due to injury by fall or reduction?); 4th and 5th fingers were destroyed by gangrene. |
| 223 | ? | | | Recovered. | Cured. | | |

Ligature of the Subclavian Artery in its Third Surgical Division (between

| No. | Name of operator. | Source of information. | PATIENT. | | | Cause of operation. | Duration of cause. | Point of deligation. | Date of injury. | Date of hemorrhage. |
|-----|-------------------------------|--------------------------------------------------------------------|----------|----------|------|--------------------------------------------------------------|--------------------|----------------------|-------------------------|---------------------|
| | | | Sex. | Age. | Side | | | | | |
| 224 | Pirogoff. | Arch. Klin. Chir. (cit.); Pirogoff's Military Surgery, p. 449. | M. | Soldier | | Hemorrhage (after ligature of brachial for traum. aneurism). | | 3d division. | | |
| 225 | do. | Surg. Anat. Arteries. do. | M. | Mid age. | R. | Malignant tumor of axilla. | | | | |
| 226 | do. | Military Surgery. | M. | Soldier | | Hemorrhage shot wound subclav. axillary. | | | | |
| 227 | Broca, 1862. | Lancet, July 2, 1870, p. 11. | | | R. | Innominate aneurism. | | 3d division. | | |
| 228 | Seyppel, 1860. | Arch. Klin. Chir., (cit.), p. 241. | M. | 24 | L. | Axillary aneur. after punctured wound. | 13 days. | do. | | |
| 229 | Langenbeck. | do. | | | | ? | | do. | | |
| 230 | Graf, E., 1866. | do. p. 242. | M. | 32 | R. | Hemorrhage after ulceration arm. | | do. | | |
| 231 | Holthouse, 1864. | do. | M. | 33 | ? | Aneurism (traumatic). | | do. | | |
| 232 | Pereira, 1826. | Arch. Klin. Chir., (cit.); Journ. Med. Soc., Lisbon, 1862, p. 385. | M. | 37 | L. | Axillary aneur. | | do. | | |
| 233 | Vianna, 1845. | do. | M. | 51 | R. | do. | | do. | | |
| 234 | Almeida, 1846. | do. | M. | 41 | R. | do. | | do. | | |
| 235 | Texeira, 1847. | do. | M. | 50 | L. | do. | | do. | | |
| 236 | Barbosa, 1862. | do. | M. | 41 | L. | do. | | do. | | |
| 237 | Bryant, Thos. | System of Surgery, Phila., 1873, p. 204. | M. | 33 | R. | Innominate aneurism. | | do. | | |
| 238 | Burt, W. (Ontario), 1873. | N. Y. Med. Jr., Oct. 1873. | M. | 35 | L. | Hemorrhage after amputation of shoulder. | | do. | | |
| 239 | Bennett, E. P. (Conn.), 1867. | N. Y. Med. Record, Nov. 1867. | M. | 30 | ? | Pulsating tumor of axilla in humeral region. | | do. | | |
| 240 | Butcher. | Schmidt Jahrbuch., Bd. cxxxiv. S. 359. | M. | 42 | | Aneurism. | | do. | | |
| 241 | Busch, F., 1872. | Archiv für Klin. Chir., Bd. xv. p. 475. | M. | 43 | R. | Wound axillary (fracture of humerus). | | do. | Oct. 7. 14, 15, 23, 24. | |
| 242 | Bickersteth, 1864. | T. Holmes in Lancet, 1872, vol. ii. p. 37. | | | | Aneurism of aorta and innominate. | | do. | | |
| 243 | Clédoux, 1875 ? (Navorreux). | Gaz. des Hôp., 1875, p. 237. | M. | 32 | L. | Aneurism, axillary (gored by a cow). | 10 days. | do. | | |

outer edge of *Scalenus Anticus* and lower border of *First Rib*)—continued.

| No. | Date of operation. | Hemorrh'ge occurred after op. | Lig. came away No. days aft. op. | RESULT. | | | REMARKS. |
|-----|--------------------|-------------------------------|----------------------------------|------------|------------------|--------------------------------|--------------------------------------------------------------------------------------------------------------------------------------------------------------------------------------------------------------------------------------|
| | | | | Recovery. | Condition. | Cause of death, date after op. | |
| 224 | ? | Occurred. | | | | Hemorrhage. | |
| 225 | | | | | | 6th day. Phlebitis. | |
| 226 | | Occurred. | | | | Hem.; pyæmia. | |
| 227 | | | | Recovered. | Improved? Cured? | | Patient died a good while after operation, of pulmonary gangrene. The carotid artery, which was not tied because there was no pulsation in it, was found at autopsy to be <i>pervious</i> , though much diminished in calibre. |
| 228 | Sept. 30, 1860. | | 12 | Recovered. | Cured. | | Nov. 17, patient was stabbed in an affray; hem. and marked infiltration of axilla; 24th Nov. puncture of abscess, severe arterial hem. and ligature of subclavian. Recovered slowly. |
| 229 | ? | | | | | Died. | |
| 230 | | | 11 | Recovered. | Cured. | | 6 weeks after fracture of forearm, amputation of upper third humerus; 2 weeks later the stump became greatly infiltrated and swollen, and was punctured; profuse hem. resulted, and ligature of subclavian. Recovered within a year. |
| 231 | 1864. | 3-13. | | | | 13th day. Hem. | Suppuration and rupture of sac just before ligature. |
| 232 | Feb. 10, 1826. | | | Recovered. | Cured. | | This patient recovered in 40 days. |
| 233 | Mar. 1845. | Occurred. | | | | 16th day. Hem. | |
| 234 | Oct. 28, 1846. | | | Recovered. | Cured. | | Recovered in 50 days. |
| 235 | 1847. | | | | | Died. Several days. | |
| 236 | April 2, 1862. | | | Recovered. | Cured. | | |
| 237 | Aug. 1871. | None? | | Recovered. | Improved. | | Patient still living. Rapid convalescence followed, with great diminution and consolidation of the aneurism. |
| 238 | July 1873. | None. | 34 | Recovered. | Cured. | | Drunk; run over by locomotive, crushing both arms. Right, amputated middle 3d forearm; left, at shoulder-joint. Hemorrhage profuse. Ligature of subclavian. |
| 239 | 1867. | None? | 24 | Recovered. | Not cured. | | Tumor ceased to grow, but did not decrease in size as result of operation. Probably connected with exostosis. |
| 240 | ? | | | | | Died. | |
| 241 | Oct. 24, 1872. | | | | | 7th day. Exhaustion (pyæmia?). | Transfusion after ligature immediately. Autopsy: Lungs gelatinous. (Query: Carcinoma or infarction?) Pus in mediastinum. |
| 242 | 1864? | | | | | 21st day. Suffocation. | Carotid had been tied 7 weeks previously. |
| 243 | 1875. | Slight. | 12 | Recovered | Cured. | | Hemorrhage, immediately after accident, was arrested by tampon. Several days after, aneurism appeared. Slight hemorrhage after operation, arrested by compress. |

Ligature of the Subclavian Artery in its Third Surgical Division (between

| No. | Name of operator. | Source of information. | PATIENT. | | | Cause of operation. | Duration of cause. | Point of deligation. | Date of injury. | Date of hemorrhage |
|-----|------------------------|----------------------------------------|----------|-------|-------|------------------------------------------|--------------------|----------------------|-----------------|--------------------|
| | | | Sex. | Age. | Side. | | | | | |
| 244 | Le Dentu, 1876-7. | Am. Jr. Med. Sci., July, 1877, p. 270. | M. | | L. | Wound axillary (dislocation of humerus). | 3 days. | 3d division. | | |
| 245 | Duplay, 1874. | Gaz. Hebdom., Oct. 15, 1875, p. 689. | | C'd. | | Knife wound of axilla. | | do. | | Slight. |
| 246 | Durham. ? | Lancet, 1872, p 37. | | | R. | Aneurism of innominate. | | do. | | |
| 247 | Eliot, Prof. J., 1876. | Am. Jr. Med. Sci., April, 1877. | M. | 41 | R. | do. | 3 years. | do. | | |

outer edge of *Scalenus Anticus* and lower border of *First Rib*)—continued.

| No. | Date of operation. | Hemorrhage occurred after op. | Lig. came away No. days aft. op. | RESULT. | | | REMARKS. |
|-----|--------------------|-------------------------------|----------------------------------|-----------|------------|-----------------------------------|--------------------------------------------------------------------------------------------------------------------------------------------------------------------------------------------------------------------------------------------------------------------------------------------------------------------------------------------------------------------------------------------------------------------------------------------------------------------------------------------------------------------------------------------------------------------------------------------------------------------------------------------------------------------------------------------------------------------------------------------------------------------------------------------------------------------------------------------------------------------------------------------------------------------------------------------------------------------------------------------------------------------------------------------------------------------------------------------------------------------------------------------------------------------------------------------------------------------------------------------------------------------------------------------------------------------------------------------------------------------------------------------------------------------------------------------------------------------------------------------------------------------------------------------------------------------------------------------------|
| | | | | Recovery. | Condition. | Cause of death, date after op. | |
| 244 | 1876-77. | | | | | Next day. Exhaustion. | Amputation at shoulder simultaneously. Autopsy: Aortic valves atheromatous; fatty liver; rupture of axillary at origin of subscapularis. M. Panas remarks: "In all published cases rupture had occurred at this point." Fever supervened. |
| 245 | 1874. | 5 days. | | | | 5th day. Hem. | |
| 246 | ? | None. | | | | 6th day. Shock. | Carotid tied simultaneously. Subclavian tied first, and pulsation (ceased in tumor), or was affected by ligature of this vessel. |
| 247 | Oct. 15, 1876. | 16, 22. | 18 | | | 25th day. Hemorrhage; exhaustion. | Carotid ligatured simultaneously. After operation patient did well with exception of slight cough and difficult deglutition. Digitalis, iodide or bromide of potas., prescribed as indicated by symptoms. 6th day, wounds discharging small quantity pus. 7th and 8th days a little restless. 9th, 10th, 11th, better. 12th, 13th, coughs a great deal, ulceration increasing; potas. iodid. substituted for bromide. 16th day, got up and dressed himself, quite comfortable, went to water-closet, sac ruptured, arterial hemorrhage 16 ounces. Compress of lint saturated with Monsel's solution 5vj.; Monsel's solution injected into sac; same day, 5vijs more injected. 18th day, carried home; ligature came away; no hemorrhage. 20th day, slightly delirious; 5j U. S. sol. morphia every 3 h'rs. 22d day, sac opened and discharged clot of blood size of 3 fingers; later hemorrhage, a pint. 25th day, died. Autopsy: Aorta atheromatous; mouth of innominate 2 inches in diameter; aneurism, anterior aspect of innom.; sac vertically 5½ inches, transversely 4, antero-post 3 and five-sixteenths inches. <i>Coagulum extending into subclavian and carotid.</i> Loss of blood by external hemorrhage, 38 ounces. Clot in sac (equivalent in blood), 5 lbs. 13 ounces. Total loss, 8 lbs. 3 ounces = cause of death. Prof. Antisell estimates blood remaining in body 1 lb. 13 ounces. (The author is indebted to Dr. G. A. Otis for a beautiful photograph of this very interesting case from the Surgeon General's office, and for other kindnesses connected with this essay.) |

Ligature of the Subclavian Artery in its Third Surgical Division (between

| No. | Name of operator. | Source of information. | PATIENT. | | | Cause of operation. | Duration of cause. | Point of deligation. | Date of injury. | Date of hemorrhage. |
|-----|-----------------------------------|-----------------------------------------------------------|----------|------|-------|------------------------------------------|--------------------|------------------------------|-----------------|---------------------|
| | | | Sex. | Age. | Side. | | | | | |
| 248 | Ensor, F., 1874. South Africa. | Lancet, 1875; Am. Jr. Med. Sci., April, 1875. | M. | 50 | R. | Aneurism of aorta and innominate. | | 3d division. | | |
| 249 | Farquharson, R. J., 1876. | Am. Jr. Med. Sci., April, 1877. | M. | 48 | R. | Axillary aneurism. | 1 year. | do. | | |
| 250 | Fergusson, Sir Wm., 1871. | Lancet, March, 1871; Am. Jr., July, 1871. | M. | 53 | R. | do. | | do. | | |
| 251 | do. | Med. Times & Gaz., 1871. | M. | | | Axillary aneurism (thrust of pitchfork). | | do. | | |
| 252 | do. 1872. | Lancet, 1872. | M. | 40 | L. | Subclavian aneurism. | | do. (Close to scale nus.) | | |
| 253 | Farrand, D. O. | Detroit Rev. Med. & Pharm.; N. Y. Med. Record, Oct. 1866. | M. | 36 | R. | Axillary aneurism (rebound of cannon). | | do. | | |

outer edge of *Scalenus Anticus* and lower border of *First Rib*)—continued.

| No. | Date of operation. | Hemorrhage occurred after op. | Lig. came away No. daysaft. op. | RESULT. | | | REMARKS. |
|-----|--------------------|-------------------------------|---------------------------------|-----------|------------|----------------------------------|---------------------------------------------------------------------------------------------------------------------------------------------------------------------------------------------------------------------------------------------------------------------------------------------------------------------------------------------------------------------------------------------------------------------------------------------------------------------------------------------------------------------------------------------------------------------------------------------------------------------------------------------------------------------------------------------------------------------------------------------------------------------------------------------------------------------------------------------------------------------------------------------------------------------------------------------------------------------------------------------------------------------------------------------------------------------------------------------------|
| | | | | Recovery. | Condition. | Cause of death, date after op. | |
| 248 | Sept. 8, 1874. | 46, 53, 54, 58, 63. | 22 | | | 65th day. Pleuritis; hemorrhage. | Patient was a Hottentot. Carotid tied simultaneously. Silk ligature. Pleuritis from reckless exposure on part of patient. Autopsy: Inflammation of pleura; sac ruptured just below seat of carotid ligature. P. S.—Oct. 24th, slight hemorrhage from carotid. Oct. 31, fever, cough, and free hemorrhage from the carotid. Nov. 1st, do. Nov. 5th, do. Nov. 9th, cornea gave way (ulceration), and lens and vitreous humor escaped. <i>Face drawn to left side slightly.</i> Nov. 10th, hemorrhage again. Died Nov. 12, comatose. Subclavian was closed firmly. Pericardium full of fluid. |
| 249 | Sept. 28, 1876. | Occurred. | 43 (removed.) | | | 62d day. Exhaustion; hem. | On 26th day after operation, sac ruptured. 30th, hemorrhage one quart. 46th, ligature removed. 48th, again hemorrhage. 62d day, death. Autopsy: True aneurism of axillary $\frac{1}{4}$ inch in length. Diffuse sac filling entire axilla. Incipient aneurism of innominate at origia. Aortic arch atheromatous. |
| 250 | Feb. 1871. | | | | | 18th day. Pyæmia. | Pressure of aneurisma on brachial plexus has caused "wrist-drop." |
| 251 | April 11, 1871. | | | | | Died. (?) | External jugular vein was tied as precaution against hemorrhage. |
| 252 | 1872. | | | | | Died. | After operation a whitish fluid was seen in bottom of wound; was thought to have been thoracic duct. |
| 253 | | Often. | | | | 42d day. Hem. | Ligature $\frac{1}{4}$ inch outside scalenus. Pulsation in tumor and wrist ceased immediately after operation, but returned in a few minutes, and could be felt $\frac{1}{4}$ inch below ligature. 2d ligature $\frac{1}{4}$ inch lower, and pulsation arrested. <i>Hemorrhage was from distal end.</i> "One thing was found which mystified us not a little; the thyroid axis was absent. That it had been present, was easy of demonstration, as the cicatrix was plain. Vertebral, inf. mam., sup. intercost., were found." (I am of the opinion that this was one of the not infrequent anomalies given in the notes of the 52 dissections accompanying this paper. There was no axis. Inf. thyroid from innominate. Trans. colli and sup. scapular from usual origin of axis. Posterior scapular from 3d division and beyond ligature. The pulsation noticed was felt as soon as the collateral route through anastomosis of suprascapular and trans. colli with the posterior scapular was established, and ceased when the ligature was applied beyond this last vessel.— <i>Author.</i>) |

Ligature of the Subclavian Artery in its Third Surgical Division (between

| No. | Name of operator. | Source of information. | PATIENT. | | | Cause of operation. | Duration of cause. | Point of deligation. | Date of injury. | Date of hemorrhage |
|-----|-------------------------------|------------------------------------------------------|----------|-------|-------|-----------------------------------------------------|--------------------|----------------------|-----------------|--------------------|
| | | | Sex. | Age. | Side. | | | | | |
| 254 | Furner, E. J., 1866. | Lancet, May 2, 1868. | M. | 30 | R. | Axillary aneurism. | | 3d division. | | |
| 255 | Fearn, 1833. | Norris Contributions, Phila., 1873, p. 262. | F. | 30 | R. | Innominate aneurism. | | do. | | |
| 256 | Gärtner, 1869-70 (Stuttgart). | Schmidt Jahrbuch., No. 150, p. 304. | | | | Axillary aneurism (reduction of shoulder). | | do. | | |
| 257 | Holmes, T., 1870. ? | Lancet, 1872. | M. | 50 | R. | Innominate aneurism. | | do. | | |
| 258 | Hughes, A. H., 1872. | Canada Lancet, 1873; Am. Jr. Med. Sci., April, 1873. | M. | 25 | | Axillary aneurism. | | do. | | |
| 259 | Heath, Christopher, 1863. | Lancet, 1868, and July 2, 1870. | F. | 30 | R. | Innominate aneurism (supposed). | 4 mos. | do. | | |
| 250 | Hodges, 1868. | Bost. Med. Surg. Jr., Aug. 6, 1868. | M. | 35 | R. | Innominate aneurism. | | | | |
| 261 | Lane, James, 1871. | Lancet, Jan. 13, 1872. | F. | 40 | R. | do. | 5 mos. | 3d division. | | |
| 262 | Lang, Ed., 1873. | Wien. Mediz. Woch., 1874, p. 770. | M. | 19 | R. | Hem. (fracture of os humeri; hem. after resection). | do. | do. | | |
| 263 | Morton, T. G., 1868. | Am. Jr. Med. Sci., July, 1876. | M. | 37 | R. | Crushed shoulder (railroad accident). | A few hours. | do. | | |

outer edge of *Scalenus Anticus* and lower border of *First Rib*)—continued.

| No. | Date of operation. | Hemorrhage occurred after op. | Lig. came away No. days aft. op. | RESULT. | | | REMARKS. |
|-----|--------------------|-------------------------------|----------------------------------|------------|-------------|--------------------------------|-------------------------------------------------------------------------------------------------------------------------------------------------------------------------------------------------------------------------------------------------------------------------------------------------------------------------------------------------------------------------------------------------------------------------------------------------------------------------------------------------------------------------------------------------------------------------------|
| | | | | Condition. | Recovery. | Cause of death, date after op. | |
| 234 | Oct. 22, 1866. | | 24 | Recovered. | Cured. | | On account of suppuration, the sac was opened and 18 ounces of bloody pus were discharged. This same patient had had his left subclavian tied for aneurism 3 years previous (see No. 146) by Dr. Farner. <i>The transversalis colli on both sides was tied, as it was derived directly from the subclavian.</i> No doubt this vessel was the posterior scapula.— <i>Author.</i>) |
| 235 | Aug. 2, 1838. | | | Recovered. | Improved. | | Aug. 30, 1836, Dr. F. had tied the right carotid in this patient. By Sept. 9, tumor had diminished notably in size, and two years after, although there was no tumor visible, the symptoms pointing to its re-development internally, the subclavian was tied. Recovered; symptoms mitigated, but she died of pleuritis on Nov. 27, 1838, nearly 3 months after the last operation. Autopsy showed innominate alone to be the seat of the disease, and the sac was filled with dense coagulum, except a channel burrowed through its centre about the size of the innominate. |
| 256 | 1869-70. | 13, 33. | | | | 33d day. | Hem. |
| 237 | 1870. ? | Occurred. | | | | 57th day. | Hem. |
| 258 | 1872. | | 12 | Recovered. | Cured. | | Carotid tied simultaneously. Carbolyzed catgut used, and not seen after operation. Tumor treated by galvano-puncture after ligature. Sac suppurated, and death. |
| 259 | 1835. | | 18 | Recovered. | (Improv'd.) | | After ligature, tumor consolidated and pressed upon nerves to such an extent that Dr. H. induced suppuration and rupture of sac, which was successful in every respect. |
| 260 | April 11, 1868. | 8th day. | | | | 11th day. | Right carotid simultaneously. 15 months after ligature, tumor was reduced in size, and patient much improved, notwithstanding she was of dissolute habits, having slept in the streets, drunk, all night, put in jail, etc. etc. In <i>Lancet</i> for July 2, 1870, I see this patient died Dec. 8, 1869, from the "external bursting of an aortic aneurism." Autopsy: Innominate healthy; aneurism of ascending aorta. |
| 261 | Sept. 27, 1871. | | 19 | Recovered. | Worse. | | 6th day, rupture of internal jugular vein, which was tied immediately. No autopsy. Carotid was tied simultaneously. |
| 262 | Feb. 22, 1873. | Next day. | | Recovered. | Cured. | | Tumor at first decreased, but afterward became larger. Carotid was tied simultaneously. |
| 263 | 1868. | | | | | Exhaustion. ? | 12 weeks after fracture, resection. For two months after this last operation, hemorrhage was frequent, and occurred the day after ligature, but was arrested by compress. |
| | | | | | | | Axillary artery tied first, but hemorrhage occurring, the subclavian was secured. |

Ligature of the Subclavian Artery in its Third Surgical Division (between

| No. | Name of operator. | Source of information. | PATIENT. | | | Cause of operation. | Duration of cause. | Point of deligation. | Date of injury. | Date of hemorrhage. |
|-----|----------------------------------|----------------------------------------------------------------|----------|---------|-------|----------------------------------------------------------|--------------------|--------------------------|-----------------|------------------------|
| | | | Sex. | Age. | Side. | | | | | |
| 264 | Marc, Dupuy, 1865. | Gaz. des Hôp., 1870, p. 537. | M. | 20 | R. | Axillary aneurism (stab w'd). | 5 mos. | 3d division. | | Immediate and profuse. |
| 265 | Mott, A. B., 1876. | Orally to author. | M. | 40 | R. | Innominate aneurism. | | do. | | |
| 266 | Mott, Valentine. | Operator's notes, kindness of Dr. A. B. Mott. | M. | 55 | L. | Axillary aneur. (noted "true"). | | do. | | |
| 267 | do. | do. | | | L. | Subclav. axillary aneurism (fall of cask on shoulder). | 3 w'ks. | do. (Close to scalenus.) | | |
| 268 | do. | do. | F. | 14 | L. | Eucephaloid of humerus (amputation at shoulder). | | do. | | |
| 269 | do. | do. | | | L. | Aneurism of subclavian. | | do. | | |
| 270 | Little, Jas. L., New York, 1876. | Orally from Dr. Robert F. Weir. | M. | | R. | Innominate or aortic aneurism. | | do. | | |
| 271 | Panas, 1875. | Gaz. Hebdom., Feb. 11, 1876, p. 91. | M. | 33 | | Hem. (laceration by fall). | 13 days. | 3d division. | | 1, 2, 7, 12, 13 days. |
| 272 | do. | do. | F. | | | W'nd of axillary (reduction of shoulder). | | do. | | |
| 273 | Sosin. | Krieg's Chir. Erfahr.; Med. Surg. Hist. Reb., vol. ii. p. 441. | M. | Soldier | | Hemorrhage, shot wound axilla. | 17 days. | do. | | 15, 16, 17. |
| 274 | do. | do. | M. | do. | | Aneurism, axillary, shot wound. | 4½ mos. | do. | | |
| 275 | Sands, Prof. H. B., 1863. | Notes to author. | M. | 26 | L. | Hem., shot wound left shoulder. | 4 days. | do. | July 14. | 18 |
| 276 | do. 1868. | do. | F. | | R. | Aneurism at sterno-clavic. artic. (supposed innominate). | | do. | | |
| 277 | Stocks, J. W., 1872-3. | Am. Jr. Med. Sci., Oct. 1873. | ? | | | ? | | do. | | |
| 278 | Terrier, F., & Le Fort, 1874. | Gaz. Hebdom., Oct. 15, 1875, p. 668. | M. | 21 | L. | Aneurism (suicidal pistol shot wound). | | do. | Feb. 15, 1874. | Immediate. |
| 279 | Weir, R. F., 1876. | Note to author. | M. | 36 | R. | Innominate aneurism. | 9 mos. | do. | | |

outer edge of Scalenus Anticus and lower border of First Rib)—continued.

| No. | Date of operation. | Hemorrhage occurred after op. | Lig. came away No. daysaft. op. | RESULT. | | | REMARKS. |
|-----|--------------------|-------------------------------|---------------------------------|------------|----------------------|--------------------------------|--------------------------------------------------------------------------------------------------------------------------------------------------------------------------------------------------------------------------------------------------------------------------------------------------------------------------------------------------|
| | | | | Recovery. | Condition. | Cause of death, date after op. | |
| 264 | July 1, 1865. | None. | 10 | Recovered. | Cured. | | |
| 265 | 1876. | None. | | Recovered. | Cured. | | The common carotid was tied one year previous. Patient recovered. (I examined this patient one year after the ligature of the subclavian. A small hard tumor, about the size of a nutmeg, could be felt to rise with the cardiac systole; no thrill. I consider the cure as complete as can be expected. The patient was well in every respect.) |
| 266 | Jan. 9, 1833. | | | Recovered. | Cured. | | |
| 267 | Dec. 2, 1850. | | | Recovered. | Cured. | | Tumor situated below and under (i. e. behind) clavicle. |
| 268 | Sept. 1855. | | | Recovered. | | | |
| 269 | ? | | 18 | Recovered. | | | Pulsation in tumor ceased after ligature to subclav., but recommenced in a few minutes. Another vessel was seen to pulsate alongside of subclavian, which was tied, and then pulsation ceased and did not return. (Note by author.—This last vessel was, no doubt, the posterior scapular, mentioned in the surgical anatomy, which see.) |
| 270 | | | | Recovered. | Marked improvement. | | Carotid was tied simultaneously. This case will very likely result in a cure. |
| 271 | Aug. 13, 1875. | 5th day. | 18 | Recovered. | Cured. | | Wound treated with wash of alcohol and carbolic acid. No pulse was found in radial 3 months after operation. |
| 272 | 1875. | ? | | | | | Died 2 months. ? |
| 273 | Lig. 17th day. | 5th, 9th day. | | | | | 9th day. Hem. |
| 274 | ? | 12, 13, 14 | | | | | 14th day. Hem. |
| 275 | July 18, 1863. | | | | | | 19th day. Exhaustion. |
| 276 | July 16, 1868. | 42-48. | 19 | Recovered. | | | Right carotid tied same time. Died 13 months after operation; aneurism was from aorta and extended in front of the innominate. Hemorrhage was from carotid. |
| 277 | 1872-3. | | | | | | 12th day. Pneumonia. (?) Solidification of one lung. |
| 278 | March 3, 1874. | 6th day. | | Recovered. | Cured (loss of arm). | | Ball lodged in axilla; hemorrhage ceased spontaneously; hem. 6th day after operation; gangrene supervened, and arm was amputated in lower 3d of humerus, on May 29th. |
| 279 | 1876. | 11th day, from sac. | | | | | 11th day. Hem. Carotid was tied simultaneously; rupture of aneurism on 11th day into trachea; upper part of sac was filled with coagulum. |

Ligature of the Subclavian Artery in its Third Surgical Division (between

| No. | Name of operator. | Source of information. | PATIENT. | | | Cause of operation. | Duration of cause. | Point of deligation. | Date of injury. | Date of hemorrhage |
|-----|----------------------------------|---------------------------------------------------------------------------------------|----------|-------|-------|------------------------------------------------------|--------------------|----------------------|-----------------|--------------------|
| | | | Sex. | Age. | Side. | | | | | |
| 280 | Wickham, 1829. | Norris Contrib. | M. | 53 | R. | Innominate aneurism. | | | | |
| 281 | Heath, G. Y., 1876. | Lancet, 1877, p. 384. | M. | 48 | L. | Axillary aneurism (idiopathic). | | 3d division. | | |
| 282 | Speir, S. Fleet, Brooklyn, 1874. | Note from Dr. S. to author; New York Archives of Clinical Surgery, Sept. 1876, p. 96. | M. | 31 | R. | Aortic aneurism (supposed innominate). | | do. | | |
| 283 | Maunder, 1867 (London Hospital). | T. Holmes in Lancet, Sept. 1857, p. 37. | | | R. | Innominate aneurism. | | do. | | |
| 284 | Barwell, Richard. | Lancet, Nov. 17, 1877; Am. Jr. Med. Sci., Jan. 1878, p. 276. | M. | 45 | R. | Aneurism aorta, innominate, carotid, and subclavian. | | | | |
| 285 | Toland, 1874. | Van Buren in Trans. International Med. Congress, 1876, p. 533. | M. | | L. | Subclavian aneurism. | | do. | | |
| 286 | Stimson, D. M., 1872. | Presby. Hosp. Report, N. Y. | M. | 44 | R. | | | do. | | |

outer edge of Scalenus Anticus and lower border of First Rib)—continued.

| No. | Date of operation | Hemorrhage occurred after op. | Lig. came away No. daysaft. op. | RESULT. | | | REMARKS. |
|-----|-------------------|-------------------------------|---------------------------------|------------|----------------|--------------------------------|-------------------------------------------------------------------------------------------------------------------------------------------------------------------------------------------------------------------------------------------------------------------------------------------------------------------------------------------------------------------------------------------------------------------------------------------------------------------------------------------------------------------------------------------------------------------------------------------------------------------------------------------------------------------------------------------------------------------------------------------------------------------------------------------------------------------------------------------------------------------------------------------------------------------------------------------------------------------------------------------------------------------------------------------------------------------------------------------------------------------------------------------------------------------------------------------------------------------------------------------------------------------------------|
| | | | | Recovery | Condition. | Cause of death, date after op. | |
| 280 | Dec. 3, 1829. | | | | | Died about 3 mos. | Carotid was tied Sept. 26, 1829. |
| 281 | Nov. 28, 1876. | None. | | Recovered. | Cured. | | No bad symptoms followed. In March previous patient first felt pain in shoulder; in June, first appearance of tumor; carbolized catgut ligature used. |
| 282 | Aug. 6, 1874. | 26-27-28 30-31-32 | 15 rem'd | | | 32d day. Hemorrhage; dyspnœa. | 2 days before ligature of <i>subclavian</i> , the right <i>carotid</i> had been obliterated by means of Dr. Speir's " <i>constrictor</i> ." The carotid wound healed by first intention; <i>the subclavian went on to suppuration</i> ; 2d day, tumor decreased one-half in size; 4th day, neuralgia; 7th, tumor increasing and looks red; 18th day, inflammation increasing, difficulty of deglutition; 23d, intense pain through aneurism; 25th, swelling spreading to right of sternum, with marked " <i>bruit</i> ;" 26th, hemorrhage from tumor; 27th, do. and pulsation noticed first time in radial; 28th, 30th, 31st, and 32d days, hemorrhage from sac; death. Autopsy: Displacement of right clavicle, erosion of manubrium; liver waxy; left kidney do.; aneurism from transverse portion of arch; neither innominate nor carotid involved; <i>carotid closed by coagula on both sides of constriction; internal coat divided and turned in</i> ; subclavian tied on both sides of the ligature; thrombus in right subclavian vein; <i>sac full of clot.</i> (Note by author.—The " <i>constrictor</i> " of Dr. Speir seems to bid fair to prove a successful innovation in surgery, having been applied to all the large arteries with success, by the inventor.) |
| 283 | 1867. | | | | | Died after 3d day. | Carotid tied simultaneously. |
| 284 | Aug. 14, 1877. | | | Recovered. | Much improved. | | Carotid tied same time; subclavian in 3d division; 3 months after operation, patient was considered out of danger, and aneurism consolidated. Died 3 months after operation. See foot of page 100. |
| 285 | 1874. | | 20 | Recovered. | (?) | | 2 ligatures—Distal. This case is not considered in the summary. |
| 286 | 1872. | | | Recovered. | Cured. | | Removed scapula and part of clavicle for disease after amputation at shoulder. This case is not considered in the summary. |

SUMMARY OF THE SURGICAL HISTORY
OF THE
INNOMINATE AND SUBCLAVIAN ARTERIES.

SUMMARY OF THE CASES OF LIGATURE OF THE ARTERIA INNOMINATA.

I HAVE accepted as reliable 16 cases of ligature of this vessel. The case of Peixoto was not a ligature proper, as the thread was only passed around the artery and was not tightened. I have no reason to doubt the two cases of Bujalski reported verbally to Velpeau, but, as I have been unable to find anything definite concerning them in the literature of this subject, they are noted and not included in the table. Porter's was a case of acupressure of this vessel. Of the 16 cases all were males. All died except one, and he recovered, temporarily cured of the aneurism, which returned and caused death ten years later (see Table). The ages given are 57, 36, 52, 31, 30, 52, 46, 27, 40, and 32.

Of the causes necessitating the operation there were —

| | |
|-----------------------------------------------------------------|----|
| Aneurism of subclavian— | |
| Traumatic | 6 |
| Idiopathic | 3 |
| Character of aneurism not stated | 5 |
| Hemorrhage ¹ of the ligature of subclavian | 1 |
| Cause of operation not given | 1 |
| Total | 16 |

Point of Ligature.—Location indicated in only 3 instances. Once “near the aorta.” Once only $\frac{1}{2}$ inch below the bifurcation of the innominate. Once 1 inch from the aorta.

¹ The case of Hutin.

Hemorrhage after Operation.

| | |
|-----------------------------------------------------------------|------|
| Hemorrhage in 12 cases— | |
| On cardiac side of ligature in | 3 |
| On distal side of ligature in | 5 |
| Source not stated | 3 |
| Into lungs (A. B. Mott), rupture of sac | 1—12 |
| No hemorrhage in 3 cases— | |
| Death 8th day | 1 |
| “ 2d “ | 1 |
| “ (date not given) | 1—3 |
| | 15 |
| Not definitely stated (probably none); death 11 hours | 1 |

Ligatures came away in only 4 cases, respectively on the 20th, 17th, 14th, 14th days.

Recovery, 1 case; *condition* temporarily cured, with slight and probably temporary debility of right upper extremity.

Causes of Death.

| | |
|-------------------------------------------------|----|
| Hemorrhage alone after operation | 10 |
| “ with pericarditis | 1 |
| Exhaustion (with probably pyæmia) | 1 |
| “ (“ “ “ uræmia) | 1 |
| “ from loss of blood before operation | 1 |
| Pyæmia (alone) | 1 |
| | 15 |

Complications with Ligature.

| | | |
|----------------------------------------------------------------------------------------|----|-------------|
| Ligature of innominate and carotid simultaneously | 1 | A. B. Mott. |
| Ligature of innominate and carotid simultaneously, and vertebral on 54th day | 1 | Smyth. |
| Ligature of subclavian (3d division), and innominate 9 days later | 1 | Hutin. |
| Ligature of innominate alone | 13 | |
| Total | 16 | |

In the cases of Lizars and Valentine Mott, an anomalous branch (probably the inferior thyroid) was from the innominate near the ligature. In 5 of 34 consecutive cases examined as to this feature, I found this anomaly; 3 of these 5 were branches to the thyroid body (the thyroid branch from the *axis* being wanting in 2) and two were pericardiac branches.

In the cases of Lizars and Mott, the hemorrhage was from the seat of ligature. (I do not doubt that these abnormal branches were partial causes of the non-closure of the innominate.)

Dates of Death after Operation.

Days. 26, 67, 8, 5, 18, 22, 17, 34, 23, 6, 9, 2, 2½, ½; not given 1.
Total, 15.

Condition of Vessel as shown by Autopsy.

- V. Mott. Innominate not occluded on cardiac side of ligature. Portion beyond ligature had disappeared by sloughing, but the ends of carotid and subclavian were open.
- Graefe. Cardiac end of artery occluded, distal end open.
- Bland. Cardiac end occluded, distal end open. Carotid was closed by clot, but subclavian was open.
- Lizars. Both ends open.
- Gore. Both ends of innominate open. The carotid was open, but subclavian was closed.
- Arendt. Died 8th day. Ligature still *in situ*.
- Hall. Died 5th day. Ligature still *in situ*.
- Bickersteth. Died 6th day. Ligature still *in situ*. Clot in subclavian, none in carotid.
- Mott, A. B. Aneurism burst into thorax. Ligature separated on 20th day. No hemorrhage at seat of ligature.

CONCLUSIONS.

To arrive at a just conclusion as to the propriety of deligating the *innominate* artery, it will be instructive and necessary to compare with this operation other and more conservative methods of treatment.

Of the 16 cases given in the history, 14 were for relief of *subclavian aneurism*. In 1 the cause of the operation is not given. In 1 other (Hutin's) the cause of operation was hemorrhage.

In this last case, a punctured wound of the *thoracic* branch of the *axillary* artery was the cause of ligature of the *subclavian*, and, hemorrhage again occurring, of the *innominate*.

It seems that to have enlarged the original wound and secured the bleeding vessel should have been the first step, instead of ligature of the *subclavian*. And after hemorrhage occurred again (as suggested by Dr. Otis in the *Medical and Surgical History of the Rebellion*), amputation at the shoulder would have been safer than ligature of the *innominate*.

In 14 operations for subclavian aneurism we have 13 *immediately fatal*, and one "temporarily cured," which proved fatal, from the original aneurism, which reformed in the *reversed collateral circulation*, about ten years later.

SYNOPSIS OF 22 CASES OF SUBCLAVIAN ANEURISM IN WHICH "NO TREATMENT" WAS UNDERTAKEN.

18 deaths ; 4 spontaneous cures. (After Poland.)

18 fatal cases. Dates of death after tumor was noticed (and when surgical interference might have been undertaken).

- 1 case. Aneurism had existed for "some time." Died 12 weeks after admission to hospital.
- 1 case. Not known how long aneurism had existed.
- 1 case. Lived "some months." Died of exhaustion and suppuration caused by pressure of sac.
- 1 case. Died of rupture of sac 24 years after recognition of aneurism.
- 1 case. Died from asphyxia caused by pressure of sac, 8 years.
- 1 case. Died from external rupture of sac 2 years and 8 months after recognition of aneurism.
- 1 case. Died from exhaustion from pressure of sac, 2 years after recognition.
- 1 case. Died from dyspnœa from pressure of sac, 2 years after recognition.
- 1 case. Died from dyspnœa and exhaustion from pressure of sac 1½ year after recognition.
- 1 case. Died from rupture of sac into lungs 1½ year after recognition.
- 1 case. Died from rupture of sac into lungs 8½ months after recognition.
- 1 case. Died from rupture of sac into tissues, becoming diffused, and causing death by pressure 5½ months after recognition.
- 1 case. Died from rupture of sac, death by pressure 5 months after recognition.
- 1 case. Died suddenly (probably from cerebral clot) 1½ year after recognition.
- 1 case. Died suddenly, cause not stated, not rupture of sac.
- 2 cases. Died from rupture of popliteal aneurisms.
- 1 case. Died from typhoid pneumonia 3 years after recognition.

Of the 4 cures, 3 remained well; 1 died about 4 years later from rupture of an aortic aneurism. Of these 18 fatal cases in which no treatment was undertaken, 3 died of other disease than the aneurism.

Of the 13 cases in which the duration of life is noted after the recognition of the aneurism, the sum total is 47 years and 9 months.

The sum of life in the 13 cases after deligation of the innominate is about 8 months, a difference in favor of non-interference (in an equal number of cases) of about 47 years of life.

An examination of the cases on the next page will show that judicious treatment without ligature is a more successful method than either this latter or perfect non-interference.

SYNOPSIS OF 14 CASES TREATED BY VALSALVA'S METHOD.

(More or less modified.)

- 1 case. M.; R. Subclavian aneurism. Size, hen's egg. Venesection; cold and lead lotion locally. Recovered. Two and a half years later was working as a carter in the city.
- 1 case. M.; R. Subclavian. Immense size. Venesection. Cold and astringents locally. Tumor reduced in size and firmer; lost sight of while in process of cure.
- 1 case. M.; R. Subclavian (syphilitic). Valsalva's method and antisiphilitics. Cure complete.
- 1 case. M.; R.; age 45. Subclavian (syphilitic). Valsalva's method and antisiphilitics. Cured and seen well 6 years later.
- 1 case. M.; age 42. Subclavian. Venesection. Digitalis. Rest. Marked improvement, so that patient left hospital and was lost sight of.
- 1 case. M.; age 50. Subclavian. Was treated for an intercurrent attack of rheumatism by rest, strict diet, and antiphlogistics. Cured.
- 1 case. M.; age 39. Subclavio-axillary (Pancoast's case). Valsalva's method had been tried and considered a failure. Operation determined on. Carried into operating room. Patient fell into collapse and operation was postponed. Recovered cured. (It is stated that a large dose of aconite had been given by mistake just before the operation was to have taken place.)
- 1 case. M.; age 37. Subclavian. Venesection. Valsalva's method and careful and persistent direct compression for 1½ year. Cured.
- 1 case. M.; age 51. Subclavio-axillary (by Pelletan). Valsalva's method. Cured.
- 5 cases treated by this method (in part) were fatal. Venesection was not practised except in one case. Only local and constitutional treatment. All died within 12 months of the recorded recognition of the disease; 1 from ulceration into trachea, hæmoptysis, and exhaustion; 2 from external bursting of sac; 2 from exhaustion and coma (with pressure on the trachea in one case).

Summary.—14 cases. Cured 7; improved, and in process of cure when lost sight of, 2; died 5. No venesection in 4 of 5 fatal cases. 1 successful case modified by direct pressure.

SYNOPSIS OF 6 CASES TREATED BY DIRECT PRESSURE UPON THE SAC (MODIFICATIONS GIVEN).

(All subclavian aneurism.)

- 1 case. M.; 46 years; R. Leather "cup" moulded over tumor and held in place by figure-of-8 straps around shoulders and axilla. Cured in 14 months. Did light work during treatment, and had no other medication.
- 1 case. M.; 39 years; L. Enormous size. Treated by cold and pressure "in turns." Small cannon-ball suspended so as to press comfortably. Discharged relieved. Some months later violent inflammation (from fall), suppuration, rupture of sac, discharged two quarts of pus and blood. Cured. Debility of arm probably permanent.

- 1 case. M.; 41 years. (13 months' duration.) Kept in bed, on back, ice locally, restricted diet. 3d day air cushion for 12 hours with intermissions amounting to 3 hours. Every half-hour interval of ice. Treatment for 7 days. Tumor began to subside and was cured in 12 months.
- 1 case. (T. Holmes.) (*Lancet*, Feb. 12, 1876, p. 237.) Subclavian. Treated by direct pressure from rubber ball. Cured.
- 1 case. (Dupuytren.) Direct pressure. Resulted fatally.
- 1 case. (Porter.) Exposed axillary and passed needle under it. 35 days later exposed innominate and passed the "acupressure needle" under it. Died from hemorrhage from innominate on 10th day.

(In 1 case given in preceding table, direct pressure was practised with Valsalva's method.)

Summary.—5 cases of "direct pressure" (without operative procedures). Cured 4; died 1.

SYNOPSIS OF CASES OF MASSAGE OR KNEADING IN THE TREATMENT OF SUBCLAVIAN ANEURISM.

Of this method there are 6 cases.

3 cured; viz., by Fergusson, Little, and Porter.

3 died; viz., by Fergusson, Hilton, and Morgan.

(See Guy's Hospital Reports, vol. xvi. p. 42 *et seq.*)

In addition, Mr. Bryant, in his "Practice of Surgery," p. 190, gives a case by Dutoit, of Berne, in which a subclavian aneurism was cured by injection of ergotin around the sac under the skin, and digital compression.

Poland cured one case by digital pressure on cardiac side. A third case was tried for 46 hours and abandoned on account of pain from pressure. The patient died from exhaustion. Paget tried mechanical pressure in a fourth case, but abandoned it as a hopeless undertaking. A fifth case by Verneuil was improved, but lost sight of before a cure was effected.

CONCLUSIONS.

1. That the circumstances justifying ligature of the *arteria innominata*, for the cure of subclavian aneurism, will occur so rarely that practically the operation should be abolished.

2. That nature, unaided, is more successful than surgery which ligatures the innominate.

3. That judicious venesection, persistent and perfect rest in bed, restricted diet, careful medication, combined with a determination,

on the part of both patient and surgeon, to succeed, is safer and more certain of success than either nature or the ligature.

4. That direct pressure by means of any substance that will press equally upon the entire surface of the tumor (Holmes's elastic ball seems best adapted), applied gradually, in order to accustom the patient and the tumor to its presence, in connection with the last method above mentioned, is surest of success as compared with all known methods of treatment.

5. That, should all these means fail after a persistent trial, should the sac by ulceration open and threaten instantaneous death, or should the surgeon from the appearances judge that this accident was on the eve of occurring, then I should deem ligature of the *innominate artery* justifiable and imperative. As insisted upon in the "operative surgery" in connection with this vessel (which see), the artery should be twisted *after being tied*, the carotid treated in the same manner, and the subclavian tied near the innominate. It is most probable that this last vessel will be so involved in the disease that torsion would scarcely be safe. In all cases the *vertebral*, the *thyroid axis* (or its branches), the *internal mammary*, the *intercostal*, and the *posterior scapular* should be tied or twisted.

6. That "kneading, or massage," has an element of danger in the *suddenness* of its action, and is inferior to the above method.

7. That pressure on the *cardiac* side is scarcely practicable; while pressure on the distal side is dangerous and useless as compared with other methods.

8. That the introduction of wire, horsehair, acupuncture, and injections into the cavity of the sac are not to be practised.

9. That in wounds of the innominate it should be tied and twisted (as heretofore given), and the carotid and subclavian treated as before.

[In case the *carotid* were wounded within half an inch of the *innominate*, or the *subclavian* within the same distance, I would consider it safer to practise ligature of both carotid and subclavian, and then torsion of both "stumps" with the innominate—the distal ends of these two vessels to be treated as above. Especially would I insist upon this in wounds of the *subclavian*, since ligature of this artery in its first surgical division has invariably proved fatal. (See 19 cases in history.)]

GENERAL SUMMARY OF CASES OF LIGATURE OF THE SUBCLAVIAN
ARTERY.

This collection of cases includes 288 instances of ligature of the subclavian artery (all in the third surgical division, excepting 32).

The *sex* is given in 262 cases; of this number 240 were males and *only 22 females*; an unmistakable indication that exposure and violence are causes of the lesions requiring so grave an operation.

As to the *side* of body, mention is made in 222 cases; of which 132 are on the *right*, and 90 on the *left* side.

The ages of the patients were as follows (as far as noted):—

| | | | |
|---------------------------|----|---------------------------|----|
| 17 years of age | 1 | 43 years of age | 3 |
| 18 " " " | 3 | 44 " " " | 1 |
| 19 " " " | 4 | 45 " " " | 2 |
| 20 " " " | 6 | 46 " " " | 1 |
| 21 " " " | 13 | 47 " " " | 3 |
| 22 " " " | 8 | 48 " " " | 3 |
| 23 " " " | 4 | 49 " " " | 2 |
| 24 " " " | 2 | 50 " " " | 8 |
| 25 " " " | 5 | 51 " " " | 3 |
| 26 " " " | 2 | 53 " " " | 1 |
| 27 " " " | 4 | 54 " " " | 4 |
| 28 " " " | 7 | 55 " " " | 3 |
| 29 " " " | 3 | 56 " " " | 1 |
| 30 " " " | 11 | 57 " " " | 1 |
| 31 " " " | 5 | 59 " " " | 1 |
| 32 " " " | 6 | 60 " " " | 3 |
| 33 " " " | 8 | 61 " " " | 2 |
| 34 " " " | 5 | 63 " " " | 2 |
| 35 " " " | 11 | 65 " " " | 1 |
| 36 " " " | 9 | 68 " " " | 1 |
| 37 " " " | 6 | 73 " " " | 1 |
| 38 " " " | 4 | Noted as old | 1 |
| 39 " " " | 4 | " " child | 1 |
| 40 " " " | 13 | " " young | 2 |
| 41 " " " | 3 | " " middle-aged | 15 |
| 42 " " " | 3 | | |

A *résumé* by decades shows that accidents leading to ligature of the subclavian are more apt to occur in the "active periods" of life.

| | |
|------------------------------------------|----------|
| Under 20 years there were only | 9 cases. |
| From 20 to 30 years there were | 48 " |
| " 30 " 40 " " " | 69 " |
| " 40 " 50 " " " | 34 " |
| " 50 " 60 " " " | 22 " |
| " 60 " 73 " " " | 10 " |

Hemorrhage.

Of 283 cases, hemorrhage is given as occurring after the operation in 93. There is stated "no hemorrhage" in 37 cases. In the remainder this accident either did not occur, or it is not noted in the account if it did. It is evident that no exact conclusion can be reached as to the proportion of cases in which hemorrhage may occur.

The source of the hemorrhage was as follows in the few cases in which it is specified:—

| | |
|-----------------------------------------------------------------------------|-----------|
| At seat of the ligature (side not stated) | 10 cases. |
| “ “ “ (from distal end of artery) | 13 “ |
| “ “ “ (from central end of artery) | 6 “ |
| “ “ “ (both central and distal end of artery) | 3 “ |
| At seat of lesion beyond ligature | 31 “ |
| From the carotid artery | 2 “ |
| From the internal jugular vein | 1 “ |
| From rupture of sac on cardiac side of ligature (Brasdor-Wardrop) | 5 “ |
| Total | <u>71</u> |

Ligature came away on—

| | | | |
|-------------------|----|-------------------|---|
| 7th day | 1 | 22d day | 3 |
| 9 “ | 1 | 23 “ | 3 |
| 10 “ | 2 | 24 “ | 3 |
| 11 “ | 6 | 26 “ | 1 |
| 12 “ | 10 | 27 “ | 1 |
| 13 “ | 8 | 29 “ | 1 |
| 14 “ | 3 | 31 “ | 1 |
| 15 “ | 7 | 32 “ | 1 |
| 16 “ | 5 | 34 “ | 1 |
| 17 “ | 7 | 36 “ | 1 |
| 18 “ | 8 | 43 “ | 1 |
| 19 “ | 6 | 47 “ | 1 |
| 20 “ | 4 | 85 “ | 1 |
| 21 “ | 4 | 96 “ | 1 |

Result.

Of 283 cases of ligature of the subclavian in its *three* surgical divisions, 162, or 57 per cent., were fatal.

The condition of the 121 recoveries will be found under the *special summaries*.

Death occurred as follows:—

| | | | |
|-----------------------|------------|----------------|----------------|
| In a "few minutes" in | 1 case. | On 18th day in | . . . 3 cases. |
| In a "half-hour" in | . 1 " | " 19 " | . . . 1 " |
| In "6 hours" in | . . 2 " | " 20 " | . . . 2 " |
| In a "few hours" in | . 1 " | " 21 " | . . . 2 " |
| In 18 hours in | . . 1 " | " 22 " | . . . 4 " |
| In 1 day in | . . . 3 " | " 25 " | . . . 2 " |
| On 2d day in | . . . 6 " | " 27 " | . . . 1 " |
| " 3 " | . . . 6 " | " 29 " | . . . 2 " |
| " 4 " | . . . 11 " | " 30 " | . . . 2 " |
| " 5 " | . . . 7 " | " 31 " | . . . 1 " |
| " 6 " | . . . 10 " | " 32 " | . . . 1 " |
| " 7 " | . . . 4 " | " 33 " | . . . 1 " |
| " 8 " | . . . 5 " | " 35 " | . . . 1 " |
| " 9 " | . . . 6 " | " 36 " | . . . 1 " |
| " 10 " | . . . 3 " | " 37 " | . . . 1 " |
| " 11 " | . . . 6 " | " 46 " | . . . 2 " |
| " 12 " | . . . 7 " | " 57 " | . . . 1 " |
| " 13 " | . . . 4 " | " 60 " | . . . 2 " |
| " 14 " | . . . 3 " | " 62 " | . . . 1 " |
| " 15 " | . . . 4 " | " 65 " | . . . 2 " |
| " 16 " | . . . 3 " | " 90 " | . . . 1 " |

Causes of death as given—

| | | | |
|---------------------------|----------|---------------------------------------|----------|
| Hemorrhage alone in | . . . 47 | Pneumonia and pneumothorax | . . . 1 |
| " and pleuritis | . . . 1 | Exhaustion " | . . . 1 |
| " bronchitis | . . . 1 | Cerebral anæmia. | . . . 1 |
| " and pyæmia | . . . 3 | " symptoms | . . . 2 |
| " and pneumonia | . . . 2 | Exhaustion, pyæmia, gangrene | . . . 2 |
| " and exhaustion | . 13 | Pneumonia | . . . 2 |
| " and dyspnœa | . . . 2 | Pyæmia | . . . 9 |
| " erysipelas, & pleuritis | 1 | Bronchitis and pulmonary con- | |
| " exhaustion, and gan- | | gestion | . . . 1 |
| grene | . . . 1 | Inflammation of sac, pleuritis, peri- | |
| " exhaustion, and diar- | | carditis | . . . 1 |
| rhœa | . . . 1 | Exhaustion and pyæmia | . . . 1 |
| Phlebitis | . . . 2 | Gangrene | . . . 1 |
| Suffocation | . . . 1 | " and pyæmia | . . . 1 |
| Shock | . . . 2 | Exhaustion and gangrene | . . . 3 |
| Pleuritis | . . . 2 | Septicæmia | . . . 2 |
| " pneumonia, emphysema. | 1 | Exhaustion | . . . 28 |
| " pericarditis, pyæmia | . 1 | Cause not given in | . . . 18 |

SUMMARY OF LIGATURE OF THE SUBCLAVIAN IN ITS FIRST SURGICAL DIVISION.

I have been able to obtain positive results in 19 cases of the above operation. *Death followed in each case.* 13 were ligatures of the *subclavian* alone; 6 of the *subclavian* and *carotid* of the right side.

LIGATURE OF THE SUBCLAVIAN ALONE.

(All on right side but one.)

The cause of the operation was—

| | |
|------------------------------------------------------|----------|
| Subclavian aneurism in | 8 cases. |
| Subclavio-axillary aneurism in | 2 “ |
| Shot wound of subclavio-axillary region in | 2 “ |
| Cause not given in | 1 “ |
| Total | 13 |

Hemorrhage occurred after the operation in 10 of these 13.

No hemorrhage occurred in 2 cases (one of these dying on the 4th day; the other in half an hour after operation).

In one case no mention is made of hemorrhage. Death on 4th day.

The *autopsies* showed that in the 10 cases in which hemorrhage occurred it was from beyond the ligature in 6, viz.:—

| | |
|-------------------------------------------------|---------|
| From rupture of sac in | 1 case. |
| “ distal end of artery at ligature in | 5 “ |

(In these 5 cases a *firm clot* was found in *central* end of the vessel.)

| | |
|----------------------------------------------------------|-----|
| From rupture of the artery at seat of ligature | 2 “ |
| No autopsy made of hemorrhage in | 2 “ |
| Total | 10 |

Causes and dates of Death.

| | | |
|-----------------------------------------------|----|---------------|
| Hemorrhage alone | 1 | 4th day |
| “ “ | 1 | 18th “ |
| “ “ | 1 | 24 hours. |
| “ “ | 1 | 13th day. |
| “ “ | 1 | 36th “ |
| “ “ | 1 | 15th “ |
| “ “ | 1 | 11th “ |
| “ “ | 1 | 8th “ |
| “ and pneumonia | 1 | 22d “ |
| “ and bronchitis | 1 | 12th “ |
| Pericarditis, pleuritis, and pyæmia | 1 | 4th “ |
| Exhaustion | 1 | half an hour. |
| Cause not given | 1 | 4th day. |
| Total | 13 | |

Hemorrhage had occurred previous to operation in 2 cases (Ayres and Bullen).

LIGATURE OF SUBCLAVIAN IN ITS FIRST DIVISION AND THE COMMON
CAROTID. (SIMULTANEOUSLY.)

Causes of Operation.

| | |
|-------------------------------------------------------|----------|
| Subclavian aneurism in | 2 |
| Innominate " " | 1 |
| Aortic (supposed innominate aneurism) in | 1 |
| Bayonet wound in first intercostal space in | 1 |
| Vascular tumor of frontal region in | 1 |
| Total | <u>6</u> |

Hemorrhage occurred after ligature in 4 of these 6. Of the 4 cases of hemorrhage 3 were from the *distal* end of the *subclavian*, one from the *carotid*.

Dates and Causes of Death.

| | | |
|----------------------------|----------|-----------|
| Hemorrhage alone | 1 | 13th day. |
| " " | 1 | 42d " |
| " " | 1 | 16th " |
| " " | 1 | 10th " |
| Cerebral anæmia | 1 | 6th " |
| Cause not given | 1 | 2d " |
| Total | <u>6</u> | |

Operators—Liston, Rossi, Parker (vertebral tied same time), Hobart, Cuveillier, Kuhl (*subclavian included by accident?*).

Comment is scarcely necessary upon the operation for ligature of this artery in its first division. 19 operations, 19 deaths.

The ligature of the innominate gives a better result, 16 operations and 1 recovery and temporary cure.

There can be little doubt that the cause of death to such an alarming extent is due to the uninterrupted currents of blood from the smaller vessels coming off from the main trunk in dangerous proximity to the point of ligature. In the majority of cases the vessel was closed by a *safe clot* on the *cardiac* side of the ligature. I am of the opinion that the impaction of the blood current has no little to do in consolidating this *cardiac* clot, while the *current* which is *inverse* in the smaller arteries *beyond* the ligature retards the formation of a coagulum by exerting a suction force in the flow of the blood current toward the periphery.

*Conclusions as to the Propriety of Ligature of the Subclavian Artery
in its 1st Surgical Division.*

1. That for aneurism upon the *cardiac* side of the ligature (Brasdor-Wardrop) this procedure is not justifiable, since death has

occurred in every instance. The vessel should be tied in its 3d division (Wardrop).

2. That for aneurism upon the *distal* side of the ligature, the operation is not safe. The same reasons given for opposing the ligature of the *innominate* are applicable here; as is the treatment for the existing aneurism. (See treatment of subclavian aneurism under summary of the *innominate*.)

3. That for injury to the *subclavian* in its 1st division requiring the ligature, it should be secured on *both sides of the lesion*. Every branch within three-quarters of an inch of each ligature should be also tied. Should the *cardiac* ligature necessarily be placed within *one-half inch or less of the arteria innominata*, then the *carotid* should be tied with a double ligature, divided between the two, the upper portion twisted, while the *innominate* with its two "stumps" should be twisted in the same manner. This may at first seem somewhat too "heroic," but since 19 deaths have occurred in succession, and since the autopsies have shown that hemorrhage is not so much to be dreaded on the *cardiac* as on the *distal* side, I am convinced that all these precautions are essential.

SUMMARY OF LIGATURE OF THE SUBCLAVIAN IN ITS 2D SURGICAL DIVISION.

(8 cases upon the left; 5 upon the right side.)

This vessel has been tied behind the *scalenus* in 13 cases; died 9, or 69 per cent.; recovered and cured 4. The *carotid* was secured in none of these operations.

The causes of the ligature were—

| | |
|---------------------------------------------------|-----------|
| Axillary aneurism in | 4 |
| Subclavio-axillary aneurism in | 5 |
| Shot wound of axilla in | 2 |
| Medullary fungus (supposed aneurism) in | 1 |
| Punctured wound of axilla | 1 |
| Total | <u>13</u> |

Hemorrhage followed the operation in 5 instances; 2 recovered, 3 died.

| | |
|------------------------------------------------------------|---|
| From seat of ligature (both ends of vessel open) | 1 |
| “ wound well beyond ligature | 3 |
| “ a vein | 1 |

Of the 4 recoveries all are reported as cured (one with amputation at shoulder-joint on account of gangrene).

Causes and Dates of Death.

| | | | |
|-------------------------------------|--------------------------------|---|-----------|
| Hemorrhage alone | | 1 | 14th day. |
| “ | “ | 1 | 6 hours. |
| “ | “ | 1 | 4th day. |
| Pneumonia | “ | 1 | 6 “ |
| Exhaustion | “ | 1 | 15 “ |
| “ | pyæmia, and gangrene | 1 | 12 “ |
| Pyæmia alone | | 1 | 9 “ |
| Cerebral complications | | 1 | 2½ “ |
| Bronchitis and pulmonary congestion | | 1 | 9 “ |

(Hemorrhage had occurred previous to the operation in 5 instances.)

In one of the above fatal cases the ball had wounded the lung. In another the axillary had been previously tied, and after ligation of the *subclavian* the arm was amputated at the shoulder. A third fatal case was attempted removal of a malignant fungus.

The ligation of the *left subclavian* in its second division is practically as safe as that of the third division, since the comparative length of the first division has removed it further from the great trunk.

The 4 cases of recovery, of the 13 instances of ligation at this point, were *all on the left side*.

CONCLUSIONS.

1. In the *left subclavian*, the application of the ligation to its second division is subject to the same rules and is as safe as that of ligation in the third surgical division (which see).

2. Since the average length of the first portion of the *right subclavian* is 1.15 inch, it would seem that it should be safer to apply the ligation in the second than in the first part, yet in the five instances in which this operation has been performed it has proved as invariably fatal as that in the first division.

As in the operation within the scalenus, every effort should be made to avoid the application of the ligation; but when the necessity still exists, the scalenus should be completely divided, and all the neighboring branches tied on either side of the two ligatures, between which the main trunk should be divided and each end twisted securely, when it is not involved in the disease to such an extent as to contra-indicate torsion.

SUMMARY OF LIGATURES OF THE SUBCLAVIAN ARTERY IN ITS THIRD SURGICAL DIVISION.

(Between the outer border of the scalenus anticus muscle and the lower border of first rib.)

I have found in the literature of this subject up to date (November, 1877), and have accepted as belonging properly to the third division of the subclavian artery, 251 cases of ligature. I have rejected more than 100 cases which have been considered and reported by some writers as cases of subclavian ligature, because, in a large number of these, the description of the method of operating and the point of ligature indicated clearly that the *axillary* was tied and not the *subclavian*. In other cases no result of the operation was given, which rendered its acceptance useless. Between 13 and 20 of my cases were tied *below the clavicle*, but from a detail of the procedure and the character of the lesion I have taken these to be true cases of *subclavian* ligature.

Of these 251 cases, 134 died, or 53+ *per centum*. Of the 117 recoveries, the great majority were cured. (The condition of recovery will be given under each special summary.)

SPECIAL SUMMARY.

(Hemorrhage.)

Ligature of the Subclavian in its third portion on account of Hemorrhage from Gunshot Wounds.

Under this heading there are 49 cases, of which only 8 recovered, a mortality of 83+ per cent. All were cases in military practice with probably only two exceptions. A synopsis of the date, and cause of death, and complications of the operation is subjoined.

Fatal cases. Ligature after gunshot wounds.

9 cases (uncomplicated). Died of hemorrhage alone on 5th, 4th, 5th, 2d, 12th, 21st, 13th, 9th, 9th days respectively.

4 cases (uncomplicated). Pyæmia alone. (Only one date given) 4th day.

2 cases (uncomplicated). Exhaustion alone. On the 29th and 19th days.

4 cases (uncomplicated). Exhaustion and hemorrhages. 16th, 9th days, 18 hours and 2 hours.

1 case (uncomplicated). Gangrene, 10th day.

1 case (uncomplicated). Gangrene, pyæmia, and exhaustion, 6th day.

1 case (uncomplicated). Pyæmia and hemorrhage, (?)

1 case (uncomplicated). Pleuritis, erysipelas, and hemorrhage, 8th day.

1 case (uncomplicated). Hemorrhage (before operation), exhaustion, 31st day. (?)

1 case (civil, uncomplicated). Hemorrhage, gangrene, exhaustion, 3d day.

1 case (uncomplicated). Pneumothorax, pneumonia, 2d day.

4 cases (uncomplicated). (?) (Only two dates given) 11th and 4th.

- 2 cases (with excision of humerus). Exhaustion, 6th and 9th days.
 1 case (with excision of humerus). (?) 2d day.
 1 case (exsection head of humerus). Hemorrhage, 3d day.
 1 case (exsection head of humerus). Exhaustion, pneumothorax next day.
 2 cases (amputation at shoulder). Exhaustion, 11th and 20th days.
 1 case (amputation at shoulder). Gangrene and exhaustion, few hours.
 1 case (amputation at shoulder). (?) 2d day.
 1 case (amputation upper third humerus). Exhaustion, same day.
 1 case (amputation upper third humerus). Pyæmia, 22d day.

41 Total.

All of these except 1 were gunshot wounds, treated on the field, or in military hospitals. A second case was a civilian wounded by a pistol shot, but treated in an army hospital.

Of the 8 recoveries only 1 was in civil practice.

- 1 case of shot wound of lung and subclavian artery.
 1 case of amputation at shoulder (No. 182).
 1 case of amputation, upper 3d (No. 185).
 1 case of resection of humerus (No. 215).
 1 case (civil) small shot wound, axilla (contraction of flexor muscles with fixation of fingers).
 3 cases. Nothing of interest given.

8 Total.¹

Lacerated Wounds (not gunshot).

- 1 case caused by fractured humerus. Died, pyæmia, 7th day.
 1 case caused by dislocation of humerus (amputation at shoulder). Died of exhaustion next day
 1 case caused by fall. Recovered, cured.
 Total 3 cases: Died 2; recovered, cured, 1.

Wound (character not stated).

Only 1 case. Recovered 1.

Punctured Wounds.

Fatal cases. Cause and date of death:—

- 1 case (scissors blade). (Innominate tied later, No. 99.) Died of hemorrhage 10th day.
 2 cases. Hemorrhage, on 5th and 11th days.
 1 case. Gangrene, on 8th day.

4 Total.

¹ Of 8 recoveries the side is stated in 5. Four of these 5 were on the left side. This would indicate that wounds of the left side are less dangerous, which, from the stand-point of surgical anatomy, I am inclined to believe. The condition of these 5 (given) recoveries is as follows: Paralysis of arm; total disability of arm; partial disability of arm; amputation at shoulder; amputation in upper 3d humerus; in 1 case respectively. All gunshot wounds were in males; 22 on right, 21 on left side, as far as given.

Cases of recovery :—

- 1 case (thrust with red-hot poker).
- 1 case (point of scythe blade). Amputation (No. 101).
- 7 cases (nothing specially interesting in character of injury).

9 Total.

Of punctured wounds there are 13 cases, with 9 cures; 4 deaths.
Ratio of mortality 31 per cent.

Ligature of the Subclavian in its 3d Division on account of Surgical Procedures.

Synopsis of fatal cases. Cause and date of death :—

- 1 case. Wound of axillary in reduction of shoulder. Died of exhaustion and gangrene, 6th day.
- 1 case. After amputation. Prostration, 6th day.
- 1 case. After amputation. Prostration, ?
- 1 case. After ligature of axillary for shot wound, a few minutes.
- 1 case. After reduction of shoulder, 2 months.
- 1 case. After removal of head of humerus. Exhaustion, 25th day.
- 1 case. After excision of head of humerus. ? ?
- 1 case. After opening abscess of axilla. Pyæmia, 6th day.
- 1 case. After dividing cicatricial contractions of axilla. ?
- 1 case. After removal of sarcoma of axilla. Septicæmia, 20th day.
- 1 case. After sarcoma (supposed aneurism). Hemorrhage, 25th day.
- 1 case. After removal of mamma (sarcoma ?). Pleuritis, 3d day.
- 1 case. After removal of humerus. Carcinoma. Septicæmia, 5th day.
- 1 case. After removal of humerus. Carcinoma. Exhaustion, 3d day.
- 1 case. After removal of tumor in axilla. ? ?
- 1 case. After fungus, axilla (supposed aneurism). Exhaustion, ?
- 1 case. After malignant tumor of axilla. Phlebitis, 6th day.

17 Total.

The 15 cases of recovery under the above heading are given below.

Cases of recovery. Cause of operation, etc.:—

- 1 case. Amputation for encephaloid of humerus.
- 1 case. Removal of clavicle and scapula for osteo-sarcoma (No. 91).
- 1 case. Removal of head of humerus and scapula; cancer.
- 1 case. Removal of sarcoma of axilla.
- 1 case. Removal of carcinoma of axilla.
- 1 case. Osteo-sarcoma. Supposed aneurism. Recovered, not cured.
- 2 cases. After ligature of brachial for aneurism.
- 2 cases. After opening abscess in axilla.
- 2 cases. Amputations for railroad crush.
- 1 case. After resection of humerus for fracture.
- 1 case. After excision of humerus for fracture.
- 1 case. Ulceration of amputated stump.

15 Total.

Out of 32 cases coming under the above caption 17 were fatal, or 53 per ct. (It is worthy of note that of the 15 recoveries, 6 were in connection with malignant diseases.)

Résumé of Cases of Ligature of the Subclavian in its 3d Division on account of Hemorrhage.

| | Cases. | Died. | Recovered. |
|--------------------------------------------------------------------------------|--------|-------|------------|
| Gunshot wounds | 49 | 41 | 8 |
| Lacerated wounds | 3 | 2 | 1 |
| Punctured wounds | 13 | 4 | 9 |
| ? wound | 1 | 0 | 1 |
| Hemorrhage after, or on account of, surgical procedures ¹ | 29 | 15 | 14 |
| Total | 95 | 62 | 33 |

Or a death-rate of 65 per cent.

SUMMARY OF CASES OF LIGATURE OF THE SUBCLAVIAN ARTERY FOR ALL LESIONS EXCEPT ANEURISM AND GUNSHOT WOUNDS IN ITS FIRST, SECOND, AND THIRD SURGICAL DIVISIONS.

Under this head there are 52 cases in the table, with 27 recoveries.

The conditions are as follows:—

| | |
|-------------------------------------------------------------------------------------|----|
| Cured with no remaining lesion | 20 |
| Cured with amputation of scapula, clavicle, and humerus for osteo-sarcoma | 1 |
| Cured with amputation at shoulder (punctured wound) | 1 |
| Cured with amputation at upper third (railroad accident) | 1 |
| Cured with amputation at shoulder | 1 |
| Cured with resection of arm | 1 |
| Case not cured (tumor still persisting) | 1 |
| Reported as recovered, no mention made of condition | 1 |
| Total | 27 |

R É S U M É.

Ligature in the third Division on account of Aneurism.

Under this head I have made a summary of the following subdivisions, viz.:—

- 1st. Subclavian aneurism.²
- 2d. Subclavio-axillary.
- 3d. Axillary.

¹ The 3 cases of "supposed aneurism" are omitted in this *résumé*.

² It is very probable that all of these cases were subclavio-axillary, as it would be difficult to tie the artery in its third division for aneurism involving this portion alone.

4th. Aneurism on *distal* side of ligature, situation not given.

5th. Aneurism on *cardiac* side of ligature. (Wardrop as suggested by Brasdor.)

For Subclavian Aneurism.

Total 5 cases; recovered, 2. Of the 3 fatal cases the cause of death in—

- 1 was gangrene and exhaustion, on 5th day.
- 1 (probably injury of thoracic duct) on ?
- 1 cause not given.

Subclavio-Axillary Aneurism.

Total 29 cases. Died 13, or 45 *per centum*. The cause and date of death and cause of aneurism as far as given were in —

- 1 case exhaustion 5th day, fall from horse.
- 1 case exhaustion 4th day. ?
- 1 case exhaustion 7th day. ?
- 1 case hemorrhage 35th day, syphilis.
- 1 case hemorrhage 29th day, carrying weight on shoulder.
- 1 case pleuritis, pneumonia, em-
physema 15th day. ?
- 1 case hemorrhage 12th day, rheumatism.
- 1 case hemorrhage 65th day, rheumatism.
- 1 case hemorrhage ? day, shot wound.
- 1 case hemorrhage and pyæmia . 14th day, punctured wound.
- 1 case pleuritis 3d day. ?
- 1 case phlebitis and coma . . . 22d day, fall.
- 1 case pneumonia 22d day. ?

13 Total.

Of the 16 recoveries, all were cured but one.

- In 8 cases no cause of disease is given.
- In 1 case the cause was "strain while drawing a cork!"
- In 1 case "barrel fell on shoulder."
- In 1 case "struck with rope."
- In 1 case shot wound (military).
- In 1 case (No. 147) after amputation.
- In 1 case "cask fell on shoulder."
- In 1 case shot wound (civil).
- In 1 case idiopathic.

Axillary Aneurism.

The ligature was applied in the third division on account of "axillary aneurism" in 75 cases, with 47 recoveries; the death-rate being 37 per cent. As far as given the following is a synopsis of the causes and dates of death and the cause of the aneurism in the 28 fatal cases.

| | | | |
|---------|----------------------------|--------------|-----------------------------------|
| 1 case. | Exhaustion . . . | 5th day. | ? |
| 1 case. | Cerebral symptoms . . . | 8th day, | traumatic. |
| 1 case. | Hemorrhage . . . | 12th day, | rheumatism. |
| 1 case. | Hemorrhage . . . | 6th day, | punctured wound. |
| 1 case. | Hemorrhage . . . | 15th day, | punctured wound. |
| 1 case. | Hemorrhage . . . | 37th day, | "sack of beans fell on shoulder." |
| 1 case. | Hemorrhage . . . | 27th day. | ? |
| 1 case. | Hemorrhage . . . | 46th day, | shot wound. |
| 1 case. | Hemorrhage . . . | ? | shot wound. |
| 1 case. | Hemorrhage . . . | 16th day. | ? |
| 1 case. | Hemorrhage . . . | 62d day. | ? |
| 1 case. | Hemorrhage . . . | 42d day, | "rebound of cannon." |
| 1 case. | Hemorrhage . . . | 33d day, | reduction of shoulder. |
| 1 case. | Hemorrhage . . . | 14th day, | shot wound. |
| 1 case. | Exhaustion and hemorr. . . | 60th day. | ? |
| 1 case. | Exhaustion . . . | 30th day, | fracture of humerus. |
| 1 case. | Exhaustion . . . | 46th day, | idiopathic (opened for abscess). |
| 1 case. | Exhaustion . . . | 30th day. | |
| 1 case. | Exhaustion . . . | 2d day, | shot wound. |
| 1 case. | Exhaustion . . . | 12th day, | shot wound. |
| 1 case. | Exhaustion and dyspncea | 6 hours, | shot wound. |
| 1 case. | Shock . . . | 4th day. | |
| 1 case. | Cause unknown . . . | 4th day, | traumatic. |
| 1 case. | Cause unknown . . . | ? | pistol wound (civil). |
| 1 case. | Cause unknown . . . | ? | traumatic. |
| 1 case. | Cause unknown . . . | several days | ? |
| 1 case. | Cause unknown . . . | ? | thrust of pitchfork. |
| 1 case. | Pyæmia . . . | 18th day. | ? |

28 Total.

In the 47 recoveries, the causes of the aneurism as given were—

| | |
|----------|-------------------------------------------------|
| 4 cases. | Idiopathic. |
| 7 cases. | Punctured wounds. |
| 4 cases. | Shot wounds (2 civil and 2 military). |
| 2 cases. | "Fall." |
| 2 cases. | "Strain." |
| 1 case. | "Fall, with wound and dislocation of shoulder." |
| 1 case. | "Fall and catching by arm." |
| 1 case. | "Muscular exertion." |
| 1 case. | "Gored by cow." |
| 1 case. | "Lifting weight." |
| 1 case. | "Thrown from carriage." |
| 1 case. | "Traumatic." |

26 Total given.

In addition to the foregoing there were 12 cases of aneurism beyond the seat of ligature, the vessel involved in the lesion not being given. The majority (if not all) of these were no doubt aneurisms of the axillary; 6 died and 6 recovered.

The cause and date of death, and cause of aneurism were—

- 1. Hemorrhage 7th day, shot wound (civil).
- 1. Hemorrhage 13th day, traumatic.
- 1. Hemorrhage Several days, dislocation (subglenoid).
- 1. Exhaustion 4th day. ?
- 1. ? ? ?
- 1. Inflammation of sac, pleuritis,
and pericarditis 7th day. ?

Causes of aneurism in the 6 cases of recovery:—

- 3 cases. Cause not given.
- 1 case. Punctured wound.
- 1 case. Pistol-shot wound (civil).
- 1 case. Dislocation or reduction of shoulder.

SYNOPSIS OF CASES OF LIGATURE OF THE SUBCLAVIAN IN ITS 3D DIVISION, FOR ANEURISM BETWEEN THE LIGATURE AND THE HEART.

(Wardrop's operation, after suggestion of Brasdor.)

- 1. Ligature of subclavian alone.
- 2. Ligature of subclavian and the right common carotid.

Ligature of Subclavian alone.

- 1 case (No. 61. Wardrop). Recovered, temporarily relieved.
- 1 case (No. 227. Broca). " " "
- 1 case (No. 237. Bryant). " permanent relief.

Total 3 cases. (Wardrop's case died of the disease 2 years later. Broca's of "pulmonary gangrene." Bryant's case was alive and doing well at last account.)

The following cases were ligatures of the 3d portion, and of the carotid:—

Operations Simultaneous.

Fatal cases:—

| No. | Operator. | Seat of Aneurism. | Date of Death. | Cause. |
|------|-----------|-----------------------|----------------|-------------|
| 246. | Durham. | Innominate. | 6th day. | Shock. |
| 247. | Eliot. | " | 25 " | Hemorrhage. |
| 248. | Ensor. | Aorta and innominate. | 65 " | " |
| 257. | Holmes. | Innominate. | 57 " | " |
| 260. | Hodges. | " | 11 " | " |
| 279. | Weir. | " | 11 " | " |
| 283. | Maunder. | " | Few days. | ? |

Recoveries:—

- 284. Barwell,¹ aortic, carotid, subclavian and innominate aneurism. Probable cure, 3 months later doing well.
- 276. Sands. aorta. Died 13 months later from the aneurism.

¹ Barwell's case died three months after operation. (See foot of page 100.)

259. Heath, innominate. Died 4 years later from the aneurism.
 261. Lane, innominate. No improvement.
 270. Little, innominate or aorta. Marked improvement, one year after operation doing well.

Cases in which the carotid was tied at a previous operation.

Fatal cases:—

242. Bickersteth, innominate and aorta. 21st day, suffocation. Carotid tied 7 weeks previously.
 280. Wickham, innominate. Died 3 months. (?) Carotid tied about 3 months previously.
 282. Speir, aortic. Died 32d day, hemorrhage. Carotid obliterated by "constriction" 2 days before.

Recoveries:—

255. Fearn, innominate. Much improved. Carotid tied 2 years before.
 265. A. B. Mott, innominate. Cured. Carotid tied by Doughty, of New York, 1 year previously.

Total 17 cases; 10 deaths; 7 recoveries.

[On a previous page I have given 6 other cases of the double operation (see Nos. 14 to 19 inclusive), all of which were fatal, making 22 cases, with a mortality of 16, or 73 per cent. Hemorrhage was the cause of death in 10 of these 16 fatal cases; viz., from the *sac* in 5 instances; from the distal end of the *subclavian* in 3; the *carotid* in 1; and rupture of the *internal jugular* in 1 (Hodges). Hemorrhage occurred in one case which recovered temporarily (Prof. Sands).]

A GENERAL SUMMARY OF CASES IN WHICH THE SUBCLAVIAN ARTERY WAS TIED IN ITS 1ST, 2D, AND 3D DIVISIONS ON ACCOUNT OF ANEURISM.

Of the 283 cases of ligature of the subclavian given in the accompanying "History," 167, or 59 per cent., were for the cure of aneurisms. All of these aneurisms were beyond the ligature excepting 21, which were lesions of the aorta, innominate, or both.

As to Sex.

Of the 167 cases, the sex is stated in 153; of which 140 were males, and *only 13 females!* We may expect (according to this ratio) to meet with 12 males with aneurisms, suggesting ligature of the *subclavian*, to 1 female. It is an interesting fact, that, in 13 females, suffering from aneurisms for which the above operation was performed, 6 (*or one-half*) were for *aortic* or *innominate aneurism*, the ratio in males being only 1 in 13 cases.

Of the 21 cases of the *distal* operation, the *sex* is given in 17, of which 11 are *males* and 6 *females*. All of the females recovered *but one*, while of the 11 males *only three recovered*. It is clear from this that the distal ligature is fuller of promise in females than in the opposite sex. I am of the opinion that this is due to the fact that women are more patient and obedient under treatment, and can be kept quieter than men.

As to Side of Body.

The *side* is designated in 145 instances: on the *right* in 89; on the left in 56. According to this aneurism will exist about $1\frac{1}{2}$ times on the *right*, to 1 on the *left* side.

Of the entire 167 cases of aneurism, 85 recovered, a death-rate of 49 per cent. Of these 85 recoveries the *side* of body is given in 80, 37 on the *right* and 43 on the *left*.

Since the artery was tied on the *right side* in 89 given cases, with only 37 recoveries, *we have a death-ratio of 58.5 per centum on this side*; while on the left side, out of 56 given cases there were 43 recoveries, *or a death-ratio of only 23.2 per cent.*, a difference of about 35 per cent. in favor of the ligature of the left subclavian artery. (This difference is doubtless in great measure due to: 1st, the "Brasdor-Wardrop" operations being on the right side. 2d, the greater length and more favorable position of *the left subclavian*.)

The *condition after recovery* on the *right side* is as follows:—

| | |
|------------------------------------------------------------------------------------------------|----|
| Reported permanently and completely cured | 24 |
| With amputation at the shoulder, cured | 1 |
| With loss of use of hand by ulceration, cured | 1 |
| Aortic or innominate aneurism (distal), "improved" | 2 |
| " " " "improved" (died, 4 years, of aneurism) | 1 |
| Aortic or innominate aneurism, "improved" (died, 13 months, of aneurism) | 1 |
| Aortic or innominate aneurism, "no better" | 1 |
| " " " "improved," died, few months, of pulmonary gangrene | 1 |
| Aortic or innominate aneurism, "improved" (died in 3 months of pleuritis) | 1 |
| Aortic or innominate aneurism, "temporary relief," died in 2 years of aneurism | 1 |
| Contents of sac remained fluid for some time | 1 |
| Aneurism persisted 5 years after operation | 1 |

Of the *conditions* on the *left side*, in 43 cases:—

| | |
|----------------------------------------------------------|----|
| Cured without any injury or lasting deformity | 32 |
| “ with amputation at shoulder (gangrene) | 1 |
| “ “ “ (fall) | 1 |
| “ “ upper 3d (pistol shot) | 1 |
| “ partial ankylosis of elbow (punctured wound) | 1 |
| “ “ “ (fall) | 1 |
| “ “ disability of arm (shot wound) | 1 |
| “ lost two fingers, gangrene (fall) | 1 |
| Small tumor persisted in | 1 |
| Noted as recoveries, cure not reported | 3 |

43

It will be seen that not only are the chances for recovery greater after ligature of the left subclavian for aneurism, but that the recovery is more apt to terminate in a complete cure than upon the right side.

Conclusions as to Ligature of the Subclavian Artery in its third Surgical Division.

1. That in gunshot wounds of the axillary region, the ligature of the *subclavian* is fraught with danger from secondary hemorrhage after the establishment of the collateral circulation. That ligature in the seat of injury, upon both sides of every bleeding vessel (in this as in all other lesions) without regard to the extent of the incisions necessary, should be the practice. That wounds thus made in the track of the original wound should be left freely open for drainage. That in case the tumefaction or any accidental condition of the part injured should render the operation at the seat of lesion impossible, then the subclavian should be tied in its third division, the *posterior scapular* sought for and tied (if present). Two ligatures should be placed upon the *subclavian*, the vessel divided between them, and torsion practised with both ends.

2. That in all lesions causing dangerous hemorrhage, while the danger of death does not exist to such an alarming extent as in gunshot wounds, the same operative procedures should be practised as in the foregoing class of cases, subject to the same exceptions.

3. In aneurisms of the axillary region, the ligature (which is fatal in 40+ per cent.) should not be attempted until a persistent trial is made of the various methods recommended under the head of “Aneurisms of the First Surgical Division.” Digital or mechanical pressure as the vessel crosses the first rib, in connection with Valsalva’s method, rest on the back, gentle pressure directly upon the

tumor, if undertaken with a determination on the part of both surgeon and patient to succeed, will (I believe) fail so rarely that ligature of the subclavian will not be necessary in the great majority of cases. Should however the necessity arise, the same rules are applicable as heretofore given.

4. Simultaneous ligature of the subclavian and carotid arteries for relief of aneurism on *cardiac* side of these ligatures (Brasdor-Wardrop) is of questionable propriety. I would advise that the *conservative methods* given (and illustrated in the successful cases) heretofore be courageously and persistently tried. Should these fail and deligation be determined upon, the carotid should be first tied, and, after an interval of some weeks, the subclavian, in its third division (subject to the rules laid down in the operative surgery, which see).

The subclavian should not be tied first, since the danger of an embolus being carried into the cranial circulation would be thus increased.


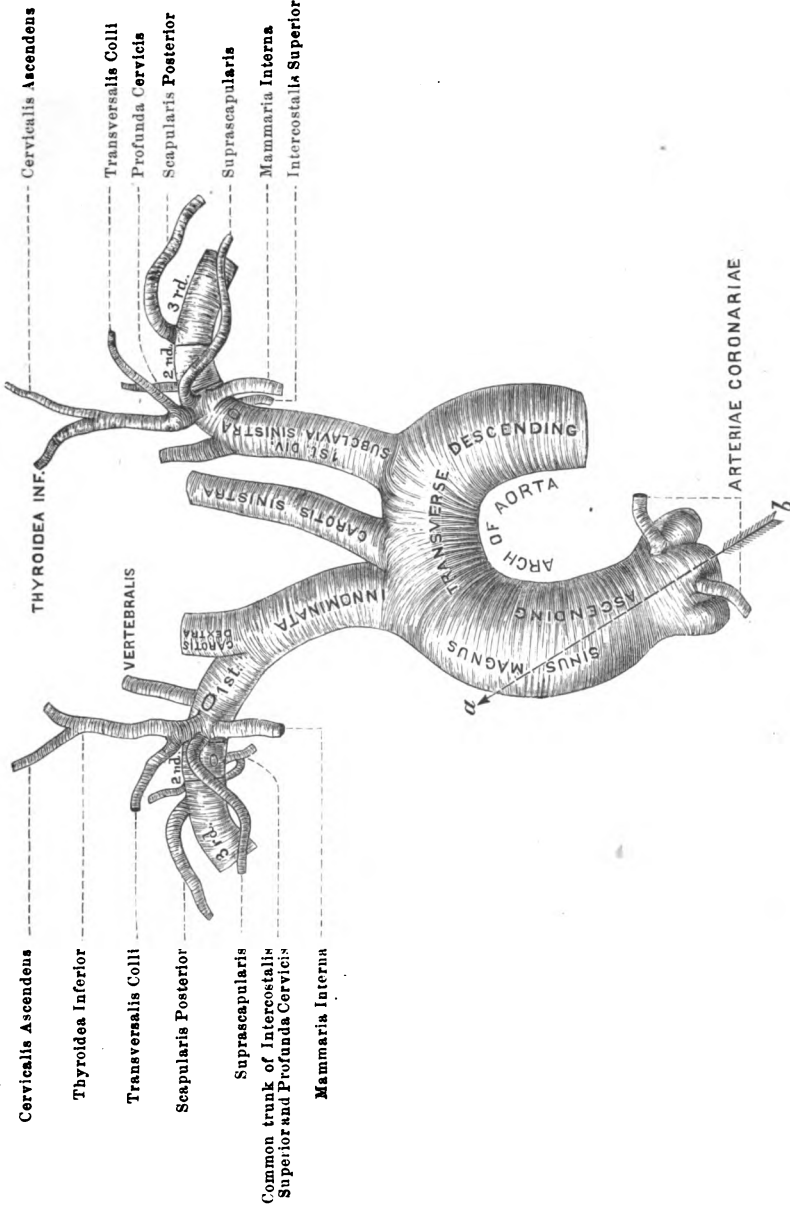
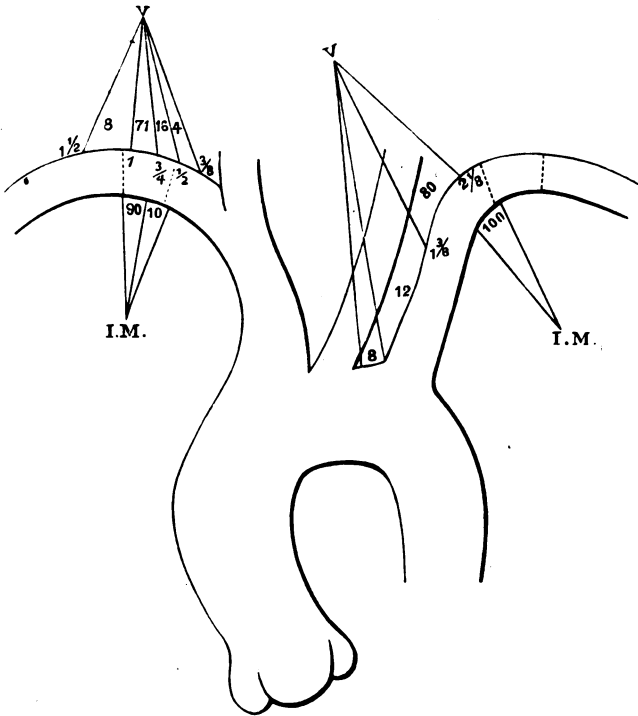


Fig. 1.



The arch of the aorta, the great vessels springing from it, and their relations to each other. The three surgical divisions of the subclavian arteries and their branches. The average arrangement deduced from carefully measured dissections of 26 subjects —one-half of each sex. (Figure reduced from life-size drawing.)

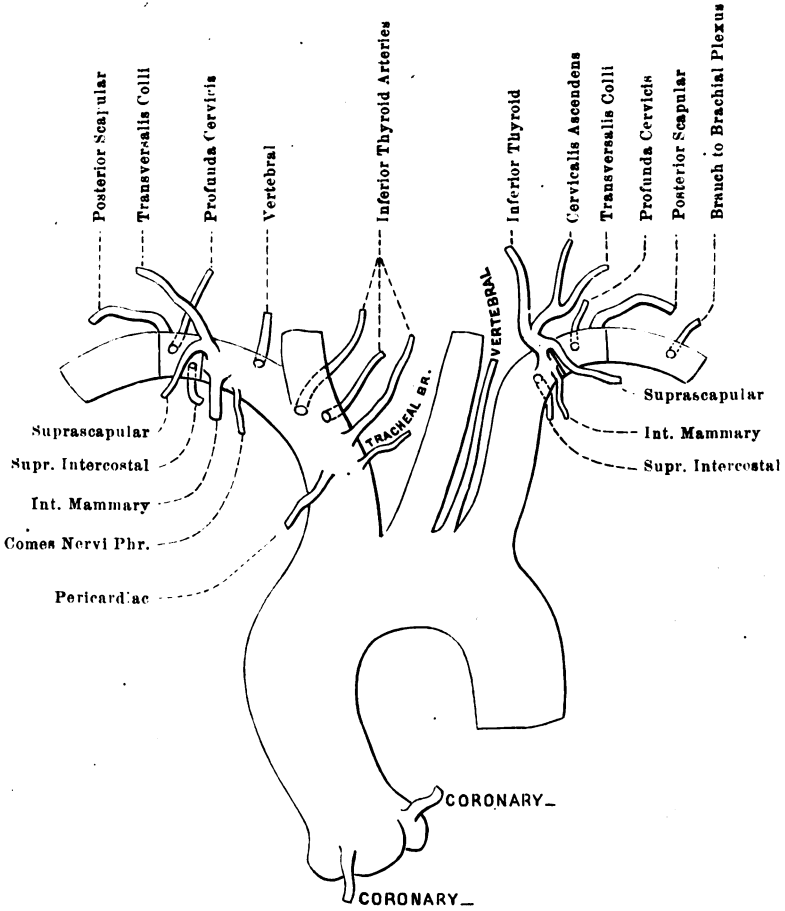
Fig. 2.



Range of origin of the right and left vertebral and internal mammary arteries (deduced from 52 consecutive dissections). (Figure reduced from life-size drawing.)

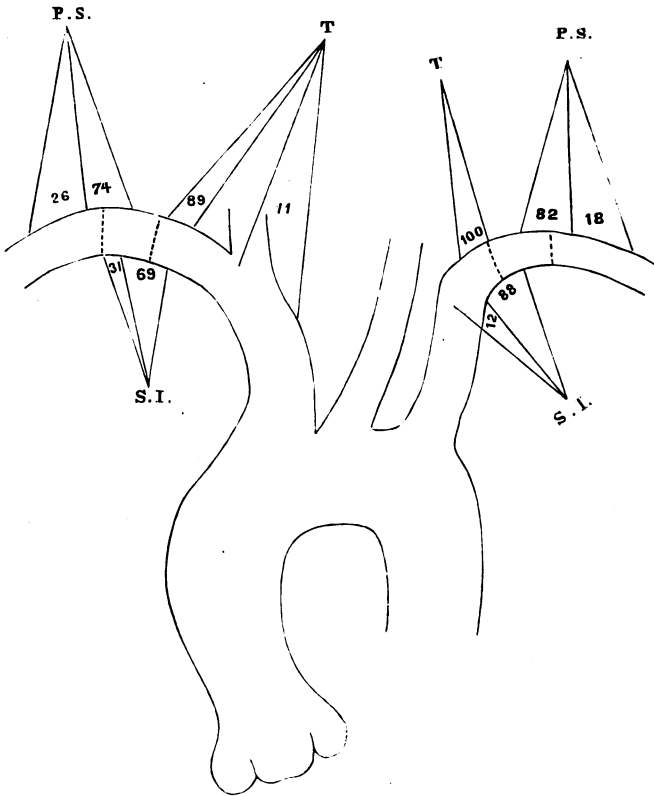


Fig. 3.



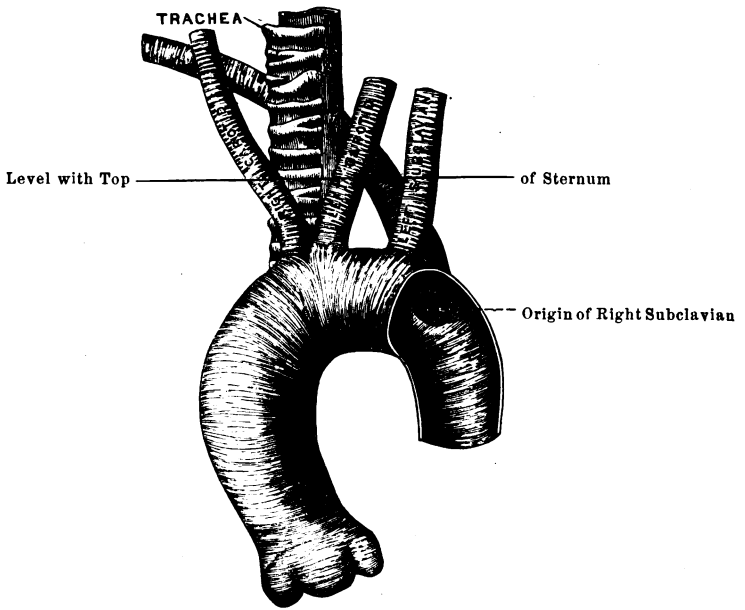
Occasional abnormal positions of the branches of the subclavian arteries.
 (Reduced from life-size drawing.)

Fig. 4.



Range of origin of the inferior thyroid, posterior scapular, and superior intercostal branches of the right and left subclavian arteries. Deduced from 52 consecutive dissections. (Reduced from life-size drawings.)

Fig. 5.



Arch of the Aorta.—Relations of the great vessels when the right subclavian is derived from the descending portion of the arch. (Reduced from a life-size drawing.)



THE SURGICAL ANATOMY

OF THE

TIBIO-TARSAL REGION,¹

WITH SPECIAL REGARD TO AMPUTATIONS AT THE ANKLE-JOINT, AS DEDUCED
FROM EIGHTY-SEVEN CONSECUTIVE DISSECTIONS.

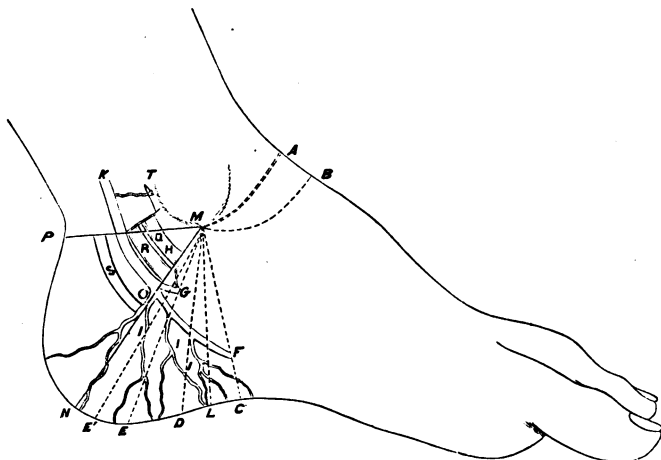


DIAGRAM SHOWING THE ARTERIAL SUPPLY TO THE CALCANEAN REGION, ON THE TIBIAL SIDE OF THE FOOT—DRAWN BY THE AUTHOR, FROM THE AVERAGE OF EIGHTY-SEVEN DISSECTIONS.

- M.—Internal Malleolus.
- PMCN.—Tibio-tarsal Quadrilateral, the Surgical region of this Articulation.
- K.—Posterior Tibial Artery.
- O.—Its point of bifurcation into
- G.—Internal Plantar and
- F.—External Plantar Artery.
- III.—Calcanean Branches of External Plantar.
- T.—Articular Branches from Posterior Tibial.
- H.—Articular Branch from Internal Plantar.
- Q.—Tendon of Tibialis Posterior Muscle.

- R.—Tendon of Flexor Longus Digitorum.
- S.—Tendon of Flexor Longus Pollicis.
- MC.—The line of incision of Gross.
- ML, MD, ME, ME.—Lines of incision showing that the nearer the incision approaches the heel, the more danger is incurred of cutting off the principal blood supply to the Calcanean Flap, in amputation.
- MN.—Line crossing the usual point of bifurcation of the Posterior Tibial.
- MA, MB.—Anterior incision.

¹ Reprinted from American Journal of Medical Sciences, April, 1876.

This Essay was awarded the Annual Prize of One Hundred Dollars, offered by Prof James R. Wood, to the Alumni Association of the Bellevue Hospital Medical College, for "The best Essay on any subject connected with Surgical Pathology or Operative Surgery," February, 1876. The Committee were Professors W. H. VAN BUREN, AUSTIN FLINT, Sr., and ALPHEUS B. CROSBY.

IN both the amputations at the *tibio-tarsal* articulation (Syme's and Pirogoff's), surgeons agree that the perfect success of the operation depends upon the vitality, *i. e.*, the non-interference with the blood supply of the inferior or calcanean flap.

Descriptive and surgical anatomists and operative surgeons agree, with remarkable unanimity, that the integrity of this flap is dependent upon its blood supply, partly from the *anterior and posterior peroneal arteries*, on the outer side, but principally from the *calcanean* branches of the *posterior tibial* on the inner side of the ankle-joint.

In reference to this, Gross says: "Care should be taken not to wound the *posterior tibial* prior to its separation into its *plantar* branches, otherwise sloughing of the soft parts might ensue from deficient nourishment;" while Valentine Mott, in his edition of *Velpeau's Surgery* (quoting from Syme), uses almost the same language: "Both incisions should be continuous, and exactly opposite to each other. Care should be taken not to cut the *posterior tibial* before it divides into the *plantars*, as in two instances when this happened (to Mr. Syme) there was partial sloughing of the flap."

Erichsen says, "unless care be taken to cut the *plantar arteries* long, the flap will be insufficiently supplied with blood, and sloughing, especially of its outer angle, will be likely to occur;" and Hamilton, in the same connection, writes, "the operator must not wound the *posterior tibial* before it has given off the *internal calcanean* branches. *Division of the posterior tibial at a point lower than this does not, as has been affirmed, endanger the vitality of the flap, as it receives no arterial supply from a lower source.*"¹

Holmes is of the opinion that "the integrity of the *posterior tibial*, though desirable, is by no means essential, provided the rest of the subcutaneous tissue has been left uninjured."²

Propos to the generally accepted idea of the origin of this principal blood supply, the following quotations are given:—

"The *internal calcanean* consist of several large branches which arise from the *posterior tibial* just before its division."—*Gray*.

Quain, while mentioning these vessels in his text only in a gene-

¹ The italics are the writer's, not Prof. Hamilton's.

² Laying no claim to personal experience, the author cannot understand how it would be possible to dissect out a bone so full of indentations and rough eminences, so covered with the insertions and origins of ligaments and muscles, and sheaths, through which tendons play, and leave "the subcutaneous tissue uninjured." There are no less than thirteen muscles in relation to this dissection, to say nothing of ligaments.

ral way, gives them specially in his diagrams as branches from the *posterior tibial*, anastomosing with branches of the *posterior peroneal*.

"The *internal calcanean branches*, three or four in number, proceed from the *posterior tibial* artery immediately before its division."—*Wilson*.

"The *calcanean arteries* are two or three branches from the lower part of the *posterior tibial*."—*Leidy*.

"Under the arch of the calcaneum the *posterior tibial* gives origin, 1st, to branches distributed to the periosteum, to the adductor (?) of the great toe, the short flexor of the toes, and to the superficial structures; and, 2d, to other branches of less calibre, which mount the inner border of the foot, to anastomose with descending branches of the *internal malleolar* branch of the *anterior tibial*."¹

Hyrtl mentions the operation of amputation at the ankle-joint, but does not consider the surgical anatomy relating to this procedure.

I assert, without equivocation, that the arterial supply to the calcanean region, as given above, is not correct, in the main; and that the operative surgery at the ankle-joint, based upon the idea that the arterial supply to the calcanean flap is derived from the *posterior tibial*, is unsafe.

Having failed to find this distribution, as given in the text-books some years ago, I determined to investigate this matter thoroughly, and to that end, made 80 consecutive dissections of this region, with all requisite care, the result of which is given in the table and *résumé* appended to this essay.

In 72 of 80 cases the *posterior tibial* bifurcated into its *plantar* branches on a line between the lower border of the inner malleolus and the middle or centre of the heel's convexity. In four of the remaining cases, the separation occurred one-fourth of an inch, and in the other four cases one-half an inch *below* this line M N (*see* diagram). Any variations in the point of division tend, in all cases, toward the line of incision in amputations in this region.

In 38 out of 80 dissections (*almost one-half*), there was not a single *calcanean artery* derived from the *posterior tibial* (K O, *see* diagram).

¹ Sous le vute du calcaneum la tibiale postrieure donne naissance; 1, a des rameaux qui se distribuent au prioste, au muscle adducteur du gros orteil, au court flchisseur commun des orteil, et aux tguments; 2, a d'autres rameaux d'un moindre calibre qui remontent sur le bord interne du pied pour s'anastomoser avec des rameaux descendants de la mallolaire interne, branche de la tibiale antrieure.—*Sappey*.

So it must follow that any line of incision that approximates the terminal bifurcation of this vessel will, in a great many cases, endanger the blood supply, and consequently the success of the operation.

I cannot think that the exceptional cases in which good recoveries have resulted, after division of this vessel, above or at its bifurcation, are arguments of any weight in favor of the incision "well back toward the heel," when compared with the fact that, in such a great proportion of cases, there is no blood supply above this point to the inner side of the flap, and that in some recorded cases where this accident has happened, dangerous sloughing has occurred.

From the standpoint of surgical anatomy, the incision recommended and practised by Prof. Gross, and represented in the annexed diagram by the line M C, is the most rational, since it is farthest removed from the most constant blood supply to this inferior flap, viz., the *calcanean branches of the external plantar artery*.

In 80 cases, 51 calcanean branches were derived above the bifurcation.

In 80 cases, 18 were derived opposite this point.

While out of 80 cases the number of calcanean branches derived from the *external plantar artery*, and distributed to the posterior or calcanean flap, safely within the line of incision of Gross (M C) given above, was 221, or more than three times in number, and carrying, without the least exaggeration, twice the volume of blood of those derived opposite to and above the bifurcation.

Erichsen in his text says: "It is of importance that the incision across the heel should be carried well back over its point. Unless this be done, a large cup-shaped cavity will be left, in which blood and pus will accumulate, and retard the cicatrization of the stump. The principal point to be attended to, however, is that the *plantar arteries* be cut long."

These two propositions I hold as anatomically incompatible. The arteries will be cut short, *dangerously short*, if the incision is carried "well back over the point of the heel," while the great danger of retardation of healing, on account of retained septic matter, might be obviated, by leaving the wound open for drainage at its most dependent part, or cutting a drainage hole in the under surface of this cup-shaped flap, as is recommended by surgeons of experience.

In fact, strict attention to cleanliness should render the collection and absorption of septic matter impossible.

Hamilton, agreeing with Erichsen, perhaps a little more emphatic in his method of expressing it, says: "The lines of this second incision ought not to fall vertically from the malleoli; that is, not at right angles with the sole of the foot, as this would give a redundancy of flap; it would also increase the danger of sloughing, etc. It is better to carry the lines of incision from the two malleoli a little backwards, so that the knife will cross the bottom of the foot about an inch and a half further back; and, in the case of an unusually long heel, it will be proper to carry the incision backwards two inches." And in the same connection as quoted before, he adds: "The operator must not wound the *posterior tibial* artery before it has given off the *internal calcanean* branches, which supply the cellulo-adipose tissue and integument composing the posterior flap. Division of the *posterior tibial* at a point lower than this does not, as has been affirmed, endanger the vitality of the flap, as it receives no arterial supply from a lower source."

The language of this eminent surgeon is decisive and emphatic.

In 38 of 80 dissections, there was not an artery that I could find, by careful dissection, derived from the posterior tibial and distributed to the calcanean region, while in every case of 80 dissections there was one or more branches derived from the external plantar, and distributed directly to this part.

Lister, author of the chapter on amputations in *Holmes's Surgery*, advises that "the calcanean incision be made either vertical to, or sloping towards the heel, commencing at the tip of the external malleolus, and going under the foot to a point considerably below and behind the tip of the inner malleolus. . . . Even the integrity of the *posterior tibial* artery, though desirable, is by no means essential, provided the rest of the subcutaneous tissue has been left uninjured."¹

The great unevenness of the os calcis, its peculiar shape, covered with the attachments of muscles, sheaths, and ligaments, renders it *anatomically* difficult to be dissected out in this operation, without wounding, more or less, the subcutaneous tissue, upon which, Mr. Lister says, the integrity of the flap depends. Moreover, if the "integrity of the *posterior tibial* is not essential," why does this gentleman recommend so positively an incision that must always save this vessel to the operation? Why not cut an "inch and a half, or, in the case of a long heel," two inches back of the vertical line (as

¹ *Holmes's Surgery*, vol. v. pp. 643, 644.

Hamilton does), where he would have plenty of flap and an easier dissection?

The language of these two phases of his operation is irreconcilable, and the assertion that "the integrity of the *posterior tibial* artery, though desirable, is not essential," is not strictly in accordance with the clinical history of this amputation, and is utterly at variance with the anatomy of the blood supply to the calcanean region.

Stephen Smith, in his comprehensive report, says the necessity for re-amputation in this operation is three per cent. *greater* than in any other.

Perhaps the cause of this may arise from the reckless sacrifice of the arterial supply to this region, sanctioned by such eminent surgeons as I have quoted.

The writer of this essay, deeming it unnecessary to introduce any further quotations and comments, since he wishes to be concise, simply begs leave to state that he has entrusted his work to no one; that he measured every dissection with accuracy, and noted it on the spot; and that, in differing so widely in his results and conclusions with gentlemen of such eminence (whom it seems almost sacrilege to contradict), he reiterates his assertion that the *surgical anatomy of this region has, heretofore, not been correctly described.*

TABLE

SHOWING ORIGIN OF THE CALCANEAN BRANCHES OF THE POSTERIOR TIBIAL
AND EXTERNAL PLANTAR ARTERIES, AS DEDUCED FROM NOTES
ON EIGHTY CONSECUTIVE DISSECTIONS.

| Number. | Number of Calcanean Branches derived from the Posterior Tibial Artery. | Number of Calcanean Branches derived opposite the Terminal Bifurcation of the Posterior Tibial. | Number of Calcanean Branches derived from the External Plantar Artery within $\frac{1}{2}$ inches of its origin. |
|-----------------|------------------------------------------------------------------------|-------------------------------------------------------------------------------------------------|------------------------------------------------------------------------------------------------------------------|
| 1 | 0 | 0 | 3 |
| 2 | 1 | 0 | 3 |
| 3 | 0 | 0 | 3 |
| 4 | 0 | 0 | 7 |
| 5 | 0 | 0 | 4 |
| 6 | 2 | 0 | 5 |
| 7 | 0 | 1 | 4 |
| 8 | 1 | 0 | 2 |
| 9 | 0 | 0 | 1 |
| 10 ¹ | 1 | 0 | 3 |
| 11 | 0 | 0 | 1 |
| 12 ² | 1 | 0 | 3 |
| 13 | 1 | 0 | 4 |
| 14 | 0 | 0 | 4 |
| 15 | 1 | 0 | 3 |
| 16 | 1 | 0 | 3 |
| 17 | 0 | 0 | 4 |
| 18 | 1 | 0 | 2 |
| 19 | 0 | 0 | 3 |
| 20 | 1 | 1 | 3 |
| 21 | 1 | 1 | 2 |
| 22 | 1 | 0 | 2 |
| 23 | 0 | 0 | 2 |
| 24 | 0 | 0 | 3 |
| 25 | 0 | 0 | 2 |
| 26 | 0 | 1 | 2 |
| 27 | 1 | 1 | 4 |
| 28 | 1 | 1 | 1 |
| 29 | 1 | 0 | 2 |
| 30 | 1 | 0 | 2 |
| 31 | 0 | 0 | 3 |
| 32 | 1 | 1 | 2 |
| 33 | 1 | 0 | 3 |
| 34 | 2 | 0 | 2 |
| 35 | 1 | 1 | 2 |
| 36 | 0 | 0 | 3 |
| 37 | 0 | 0 | 6 |
| 38 | 1 | 0 | 2 |
| 39 | 1 | 0 | 3 |
| 40 | 0 | 1 | 1 |

¹ This case bifurcated one-half inch lower than usual.

² This case bifurcated one-half inch lower than usual.

| Number. | Number of Calcanean Branches derived from the Posterior Tibial Artery. | Number of Calcanean Branches derived opposite the Terminal Bifurcation of the Posterior Tibial. | Number of Calcanean Branches derived from the External Plantar Artery within $1\frac{1}{4}$ inches of its origin. |
|-----------------|------------------------------------------------------------------------|-------------------------------------------------------------------------------------------------|-------------------------------------------------------------------------------------------------------------------|
| 41 ¹ | 2 | 0 | 2 |
| 42 | 1 | 0 | 3 |
| 43 | 1 | 0 | 2 |
| 44 | 0 | 0 | 3 |
| 45 | 0 | 1 | 2 |
| 46 | 0 | 1 | 4 |
| 47 | 0 | 0 | 2 |
| 48 | 1 | 0 | 3 |
| 49 | 2 | 0 | 2 |
| 50 | 0 | 0 | 3 |
| 51 | 0 | 0 | 3 |
| 52 ² | 1 | 0 | 2 |
| 53 | 2 | 0 | 6 |
| 54 | 1 | 1 | 4 |
| 55 ³ | 0 | 0 | 3 |
| 56 | 2 | 0 | 0 |
| 57 | 1 | 0 | 1 |
| 58 | 0 | 1 | 3 |
| 59 | 0 | 0 | 2 |
| 60 ⁴ | 2 | 0 | 1 |
| 61 | 1 | 0 | 2 |
| 62 ⁵ | 2 | 0 | 2 |
| 63 | 1 | 0 | 3 |
| 64 ⁶ | 0 | 0 | 3 |
| 65 | 1 | 1 | 3 |
| 66 | 0 | 0 | 3 |
| 67 | 0 | 2 | 1 |
| 68 | 0 | 0 | 3 |
| 69 | 1 | 0 | 4 |
| 70 | 0 | 0 | 3 |
| 71 | 1 | 0 | 3 |
| 72 | 1 | 0 | 2 |
| 73 | 2 | 0 | 2 |
| 74 | 0 | 1 | 4 |
| 75 | 0 | 0 | 4 |
| 76 | 0 | 0 | 3 |
| 77 | 1 | 0 | 3 |
| 78 | 0 | 0 | 5 |
| 79 | 0 | 0 | 2 |
| 80 | 0 | 1 | 1 |
| Total . . | 51 | 18 | 221 |

¹ This case bifurcated one-fourth inch lower than usual.

² This case bifurcated one-fourth inch lower than usual.

³ This case bifurcated one-fourth inch lower than usual.

⁴ This case bifurcated one-half inch lower than usual.

⁵ This case bifurcated one-half inch lower than usual.

⁶ This case bifurcated one-fourth inch lower than usual.

SUMMARY ON THE SURGICAL ANATOMY OF THE ARTERIAL SUPPLY TO THE TIBIO-TARSAL REGION, AS DEDUCED FROM 80 DISSECTIONS.

In 72 of 80 cases the posterior tibial artery bifurcated into the external and internal plantar, on a level with a line drawn from the most dependent portion of the internal malleolus, to the middle of the heel's convexity. (See M N, fig. 1.)

In 4 of 80 cases, this bifurcation occurred $\frac{1}{4}$ inch below this point.

In 4 of 80 cases, it was $\frac{1}{2}$ inch below this point; any variation from the usual point of division tending, in my experience, *invariably downward*.

Although anatomists give the arterial supply to the calcanean region (*internal calcanean arteries*) as coming from the *posterior tibial* artery (as shown in extracts given heretofore), the *résumé* of tabulated dissections shows that, out of a total of 80 cases, in 38 *there was not a single calcanean branch derived above the terminal bifurcation of the posterior tibial artery*, while in all of these 80 dissections, one or more good-sized *calcanean arteries* were derived from the *external plantar*, within one and a quarter inches of its origin.

In 80 cases, the number of *calcanean* arteries derived from the *posterior tibial* was 51.

In 80 cases, 18 branches were derived opposite the point of bifurcation, and distributed to this region.

In 80 cases, the number of *calcanean arteries* derived from the *external plantar* was 221, and every one of these was safely inside the line of incision in amputations at the ankle-joint, when that incision is not more than one-half inch posterior to the axis of the leg (see M C, fig. 1), with the foot at right angles to the leg. In all cases, *articular branches* are derived either from the *posterior tibial* or *internal plantar*, or from both. In some exceptional cases, the *internal plantar* gave off small branches to the heel.

The anterior flap is plentifully supplied in all instances by branches from the *anterior tibial*, especially the *malleolar* arteries.

The *anterior* and *posterior peroneal* distribute branches to the outer portion of the calcanean flap, those from the *posterior* anastomosing with the *calcanean* branches of the *external plantar*, and with those of the *posterior tibial*, when they are present. I do not think the branches from the *peroneal arteries* sufficiently large to supply blood enough to maintain the integrity of the calcanean flap, especially when their anastomoses are cut off by section of the *posterior tibial*, or of its *plantar* branches, too near their origin.

The relation of the *posterior tibial* artery is quite constant with the two muscles between which it runs; the flexor longus digitorum in front, and the flexor longus pollicis behind. The most reliable guide to this vessel is its pulsation; but in the event the tourniquet is applied, the thumb should be placed over the middle of a line drawn from the inner malleolus to the centre of the heel's convexity, while the four lesser toes are held still by an assistant, the surgeon moves the great toe, and marks the point at which he feels the tendon gliding under his thumb. The tendon of the longus digitorum is found in the same manner, and half-way between the two a curved incision, with its concavity towards the malleolus, will be over the artery. The relations of the veins on either side, and of the *posterior tibial nerve* behind, are among the least variable features of the anatomy of this region. In two cases I have seen the artery immediately behind the inner malleolus. When the *posterior tibial* is small, the *peroneal* branches undergo compensatory enlargement.

P. S.—Since closing these notes, some weeks ago, the writer has made seven additional dissections of this region, with the following result:—

In 4 out of 7 cases, *calcanean* branches originated from the posterior tibial artery—1, one inch; 1, one-half inch, and 2, one eighth of an inch above the bifurcation.

In 7 cases, 2 *calcanean* branches were derived opposite the bifurcation.

In 7 cases, 19 *calcanean* branches were derived from the external plantar, within one inch of its origin; 3, within one-sixteenth; 2, within one-eighth; 1, within one-fourth; 4, within one-half; 4, within three-fourths, and 5 within one inch of the bifurcation. Articular branches were, as usual, from posterior tibial and internal plantar.

The posterior tibial bifurcated in every case, as usual. (*See diagram.*)

NOTES

UPON THE

SURGICAL ANATOMY OF THE OBTURATOR ARTERY.¹

THE DIFFERENCE OF ITS RELATIONS IN THE MALE AND FEMALE, WITH A CONSIDERATION OF ITS IMPORTANCE IN THE OPERATION FOR RELIEF OF FEMORAL HERNIA—DEDUCED FROM TWENTY-SEVEN CONSECUTIVE DISSECTIONS OF THE ARTERIES IN THE MALE, AND TWENTY-SIX IN THE FEMALE PELVIS.

IN its distribution the *obturator artery* is simple and constant; in its origin and relations there is no artery in the human body which presents so many vagaries. In support of this last statement it will suffice to quote from some of the standard text-books the different opinions of different anatomists upon this artery.

Quain gives its origin as "usually from the *posterior trunk* of the *internal iliac*, not unfrequently from the *epigastric*."

Sappey takes a different view, and says "from the *hypogastric* (*anterior trunk of internal iliac*), sometimes from the *external iliac*, rarely from the *femoral*."

Leidy is of the opinion that it "is a branch of the *posterior trunk*, and often a branch of the *anterior trunk* of the *internal iliac*."

Wilson gives it "from the *anterior trunk*; frequently from the *posterior trunk* of the *internal iliac*."

Gray agrees with Wilson *verbatim*, adding that "in 2 of 3 cases the obturator arises from the *internal iliac*, in 1 of 3½ from the *epigastric*, in 1 of 72 by two roots from both vessels."

Luschka, "from *anterior trunk of internal iliac*; occasionally, from *external iliac*, *epigastric*, or *femoral*."

Velpeau writes: "An examination of several thousand cadavers does not permit me to say that the *obturator artery* comes from the *epigastric* in 1 of 3, nor 5, nor 10, but only 1 in 20." (!)

Tiedemann says, on the other hand, that "you may expect to find

¹ New York Medical Record, October, 1877.

the *obturator* from the epigastric in 1 of 3 cases, this variety being more common in the female than in the male."¹

In the two following tables I have given the analysis of 53 dissections, made in order to contribute something of certainty to the anatomy of this artery. Thirteen subjects of each sex were chosen, and both sides noted as they were dissected.

| FEMALES. | | | | | MALES. | | | | | | |
|----------|---------------|-----------------------------------------------------------|-------------------------------------------------|--------------------------------------|---------------------------------------------------------------------------------------------------------------------------------------------------------------------------------------------------|-----|---------------|-----------------------------------------------------------|-------------------------------------------------|--------------------------------------|----------|
| No. | Side of body. | Originated from anterior trunk of <i>internal iliac</i> . | From posterior trunk of <i>internal iliac</i> . | From the <i>deep epigastric</i> trc. | REMARKS. | No. | Side of body. | Originated from anterior trunk of <i>internal iliac</i> . | From posterior trunk of <i>internal iliac</i> . | From the <i>deep epigastric</i> trc. | REMARKS. |
| 1 | R | ... | ... | 1 | <p>In Nos. 7 and 8 the <i>obturator</i> arched over the crural ring in such a manner, that, had <i>femoral hernia</i> existed, the intestine might have been closely encircled by the artery.</p> | 27 | R | 1 | ... | ... | |
| 2 | L | ... | ... | 1 | | 28 | L | 1 | ... | ... | |
| 3 | R | ... | ... | 1 | | 29 | R | 1 | ... | ... | |
| 4 | L | ... | ... | 1 | | 30 | L | 1 | ... | ... | |
| 5 | R | ... | ... | 1 | | 31 | R | 1 | ... | ... | |
| 6 | L | ... | ... | 1 | | 32 | L | 1 | ... | ... | |
| 7 | R | ... | ... | 1 | | 33 | R | 1 | ... | ... | |
| 8 | L | ... | ... | 1 | | 34 | L | 1 | ... | ... | |
| 9 | R | ... | ... | 1 | | 35 | R | 1 | ... | ... | |
| 10 | L | ... | ... | 1 | | 36 | L | 1 | ... | ... | |
| 11 | R | 1 | ... | ... | | 37 | R | 1 | ... | ... | |
| 12 | L | ... | ... | 1 | | 38 | L | 1 | ... | ... | |
| 13 | R | 1 | ... | ... | | 39 | R | 1 | ... | ... | |
| 14 | L | ... | ... | 1 | | 40 | L | 1 | ... | ... | |
| 15 | R | 1 | ... | ... | | 41 | R | 1 | ... | ... | |
| 16 | L | 1 | ... | ... | | 42 | L | 1 | ... | ... | |
| 17 | R | 1 | ... | ... | | 43 | R | 1 | ... | ... | |
| 18 | L | 1 | ... | ... | | 44 | L | 1 | ... | ... | |
| 19 | R | 1 | ... | ... | | 45 | R | ... | 1 | ... | |
| 20 | L | 1 | ... | ... | | 46 | L | 1 | ... | ... | |
| 21 | R | 1 | ... | ... | | 47 | R | ... | ... | 1 | |
| 22 | L | 1 | ... | ... | | 48 | L | ... | ... | 1 | |
| 23 | R | ... | ... | 1 | | 49 | R | ... | ... | 1 | |
| 24 | L | 1 | ... | ... | | 50 | L | 1 | ... | ... | |
| 25 | R | ... | 1 | ... | | 51 | R | ... | ... | 1 | |
| 26 | L | ... | 1 | 1 | | 52 | L | 1 | ... | ... | |
| | | | | | 53 | L | 1 | ... | ... | | |
| | | 11 | 1½ | 13½ | | | | 22 | 1 | 4 | |

¹ The writer is indebted to Dr. I. Minis Hays for valuable reference in regard to this artery: to "Lawrence on Ruptures," one of the most valuable books on this subject published; and to Dr. W. L. Wardwell for assistance in taking notes of the dissections.

* The { to the left indicates the dissections to have been made upon both sides of the same subject; that to the right, that the origin was the same on both sides of the same subject.

NOTE.—In 8 other dissections in which the sex was not noted, this artery came from the anterior trunk in 5, from the posterior in 1, from the *deep epigastric* in two instances.

It will be seen that in *females*, of 26 cases, the *obturator* was from the *deep epigastric* in $13\frac{1}{2}$ instances; from the posterior trunk of the *internal iliac* in $1\frac{1}{2}$; from the *anterior trunk* in 11 instances.

In *males*, of 27 cases, it was from the *epigastric* in only 5; from the *posterior trunk* in 1; while from the *anterior trunk* of the *internal iliac* it was derived in 22 instances.

In these cases it is seen that, in *females* we may expect to find the *obturator* to be derived from the *deep epigastric* in 1 of 2 cases; in *males*, in 1 of $4\frac{1}{2}$ cases.

And, in a total of 61 cases, regardless of sex, the proportion is 20, or 1 in 3.

Tiedemann is the only one of these anatomists who notices the difference between the origin of this vessel in *males* and *females*.

In 160 cases in which Cloquet noted the *obturator* as coming from the *internal iliac*, 87 were in *males*, 73 in *females*, showing, as in my cases, the greater tendency of this vessel to come from the *internal iliac* in *men*.

In 56 cases this same author noted from the *epigastric*, 21 were in *males*, 35 in *females*; agreeing, also, with the dissections embodied in this article, that the tendency of the *obturator* to come from the *deep epigastric* was much greater in *women* than in *men*.

So great is this difference, that the estimates made from both sexes should not be considered, in view of the probable contact with this vessel in femoral hernia.

An examination of the foregoing tables will show that, in 19 of 26 subjects, this artery was derived from the *same point on the two sides*, showing, in this respect, a symmetry of arrangement I have not noticed in any other artery of the body.

Femoral hernia being comparatively a rare accident in the male, and the *obturator* artery having a dangerous relation to the *femoral ring* in the male sex in only a small proportion of cases, the surgical interest of this vessel belongs to the opposite sex.

When derived from the *epigastric*, it usually comes off from this artery from $\frac{1}{4}$ to $\frac{3}{4}$ of an inch from the origin of the *epigastric* from the *external iliac*. It then turns abruptly down on the outer side of the *femoral ring*, being in intimate relation with the sheath of the *external iliac vein*, and thus makes its way to the *obturator foramen* in such a manner that it would be exceedingly difficult for the intestine, descending to form a *femoral hernia*, to insinuate itself between the *iliac vein* and the *obturator* artery, so as to loop this latter vessel around the hernia. This danger will be greater as the

obturator is distant at its origin from the *external iliac*. However rare this double accident may be (femoral hernia, with the *obturator* artery looped around it), yet, as it can and has occurred in several instances, the surgeon should proceed in every case as if he supposed this accidental arrangement existed.

In the *American Journal of the Medical Sciences*, July, 1878, p. 269, is a notice of a case in which death resulted from division of the obturator artery in an operation for femoral hernia in a *woman*. The vessel was from the epigastric, $\frac{1}{2}$ an inch from its origin. Mr. Barker had collected 12 cases of this accident; in six of these the vessel was secured either by ligature, or with a hook. Of this group 2 died. In 6 nothing was done, and only one died (his own case, which is reported as dying of peritonitis). "At the autopsy, 3 or 4 ounces of *blood were found effused under the peritoneum* in the pelvis." This extravasation may have caused peritonitis and death. It is to be regretted that Mr. Barker does not say what proportion of these twelve cases were *females*. I do not doubt that most of them were of this latter sex.

When the stricture is so situated that Gimbernat's ligament requires division, the point of the probe-pointed bistoury should be kept hard pressed against the surface of the *os pubis* to which this ligament is attached, and as is advised by one of the most eminent American surgeons, "the ligament should be divided without any sawing motion."¹ It is evident that, if the cutting edge of the knife is not pushed beyond the ligament into the pelvis, the artery will not be divided.

I have noticed that the *obturator vein* is in relation to the femoral ring in a much larger proportion of cases than the artery, it being often double, one going to the *internal iliac*, the other to the *external iliac* vein, when the artery was from the *anterior trunk* of the *internal iliac* alone.

Deductions: 1st. That anatomists giving the origin of the *obturator artery* from the *posterior trunk* of the *internal iliac* are *positively wrong*, the vessel not originating from this point in more than 10 per cent.

2d. That in females it will be derived from the *deep epigastric* in one of two or two and one-half cases.

3d. That in males it will be from the *deep epigastric* in one of four or six cases.

¹ Hamilton's System of Surgery, p. 743.

4th. That the *obturator vein* is found to empty into the *external iliac* or *epigastric vein* in a much greater proportion of cases than the artery is found to originate from the *epigastric* or *external iliac*.

5th. That the advice to "feel for the pulsation of this artery before cutting Gimbernat's ligament"¹ (as is frequently given), seems unnecessary, since the insertion of the finger through the constricted canal, completely filled by the intestine, *that has for this reason become strangulated*, is impossible until *after the section is made*.

6th. That, although the conditions in which the *obturator artery* is found to the inner side of a femoral hernia rarely exist, the operation should be made with every regard to this abnormal arrangement.

NOTE.—In one instance I have seen the *obturator* a branch of the *epigastric*, and this latter a branch of the *profunda femoris*. This specimen is the property of the Wood Museum of Bellevue Hospital, and is not included in these notes, on account of its being so unusual.

¹ Holmes's Surgery, vol. iv. p. 779.

NOTES ON THE SURGICAL ANATOMY OF 'THE HIP-JOINT.'

The comparatively trifling amount of blood lost in an operation of such magnitude as the excision of the hip-joint, when there is no means of stopping the supply of blood to the part, has doubtless added very much to the remarkable success which has attended this operation in the hands of its author. The following synopsis of twenty dissections of the hip-joint made with regard to the arterial distribution to this region, may serve to show the extreme nicety of execution requisite, in order to avoid hemorrhage, that would always be annoying, and in some instances dangerous. The arteries found distributing branches to this region were the *gluteal*, *sciatic*, *obturator*, *external* and *internal circumflex*, and the *superior perforating* by anastomoses. None of these approached the line of incision given by Prof. Sayre near enough to be divided, before they broke up into branches of distribution too small to give rise to any noticeable hemorrhage, except one of the terminal branches of the internal circumflex, sometimes mentioned as the *trochanteric* branch, but never described in connection with the surgical anatomy of this operation, to my knowledge. In 20 dissections this artery was present in every case. In 18 of these it came from the *internal circumflex*, passed between the quadratus femoris behind, and the obturator externus in front, and turning toward the digital fossa, broke up into its terminal branches within from one-eighth to one-fourth of an inch of the insertion of the tendon of the obturator externus into that fossa, anastomosing with the *sciatic*, *gluteal*, and *external circumflex* arteries. In 2 cases in which it failed to come from the *internal circumflex*, it was derived from the *sciatic*, and ran in the depression between the quadratus femoris and obturator externus muscles, near the digital fossa.

This vessel varied in size from a crow's-quill, down, oftener small than large, but in all cases of sufficient size, at the distance from the fossa above given, to interfere with the success of the operation, if carelessly divided. As it is only at this point that the knife is used in the deeper structures (in cutting the tendon of the obturator externus out of this fossa), it behooves the surgeon to guard against this danger by keeping the point of the knife "well against the bone," as advised in the operation, and never to attempt to divide this tendon out of the fossa. (The obturator externus muscle was occasionally observed to be inserted into the great trochanter, and not into the digital fossa.)

† From Orthopedic Surgery and Diseases of the Joints. By Prof. LEWIS A. SAYRE.

