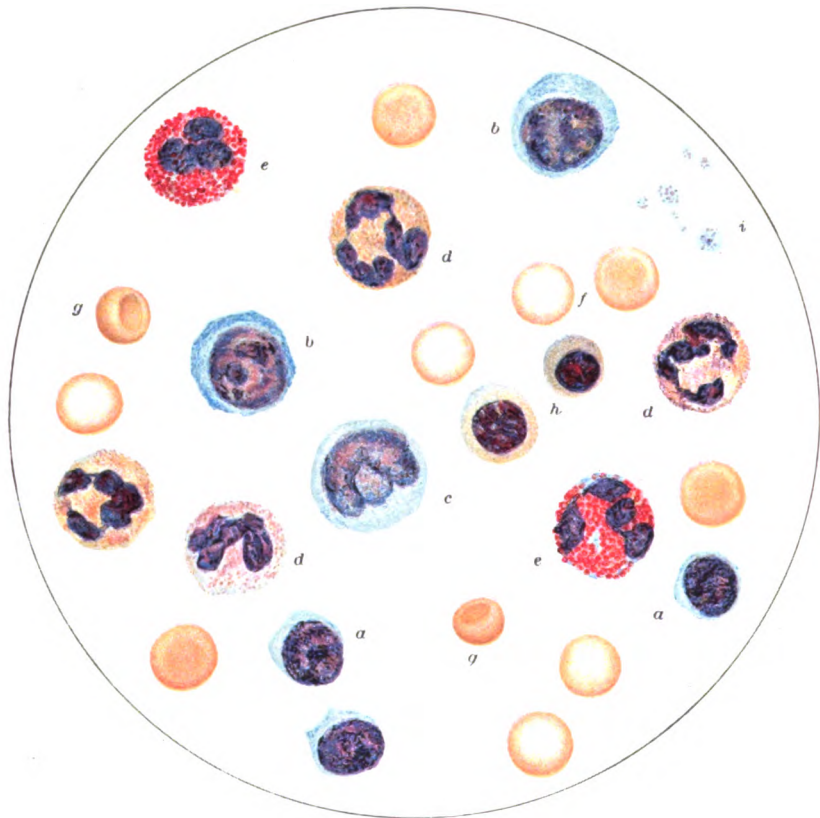

HUMAN BLOOD-CELLS.

*a*, SMALL LYMPHOCYTES  
*b*, LARGE LYMPHOCYTES  
*c*, TRANSITIONAL FORM  
*d*, POLYMORPHONUCLEARS  
*e*, EOSINOPHILES

*f*, ERYTHROCYTES  
*g*, ERYTHROCYTES, CUP-FORM  
*h*, NORMOBLASTS  
*i*, BLOOD-PLATES  
 X 1200

SELECTED CELLS FROM PLATE IN DR. J. C. WILSON'S MEDICAL DIAGNOSIS.

# NORMAL HISTOLOGY

WITH SPECIAL REFERENCE  
TO THE

STRUCTURE OF THE HUMAN BODY

BY  
GEORGE A. PIERSOL, M.D., Sc.D.  
PROFESSOR OF ANATOMY IN THE UNIVERSITY OF PENNSYLVANIA

438 ILLUSTRATIONS, 88 OF WHICH ARE IN COLOR

*ELEVENTH EDITION*



PHILADELPHIA & LONDON  
J. B. LIPPINCOTT COMPANY

COPYRIGHT, 1910  
BY J. B. LIPPINCOTT COMPANY

---

COPYRIGHT, 1912  
BY J. B. LIPPINCOTT COMPANY

---

COPYRIGHT, 1913  
BY J. B. LIPPINCOTT COMPANY

---

COPYRIGHT, 1916  
BY J. B. LIPPINCOTT COMPANY

*Printed by J. B. Lippincott Company  
The Washington Square Press, Philadelphia, U.S.A.*

## PREFACE.


---

THE preparation of the eighth edition was undertaken in response to repeated requests from teachers, and was influenced by the aim stated in the original preface : to present descriptions which should include the salient features of the various structures with sufficient fulness to impress important details without wearying minutiae ; too great conciseness, on the one hand, and too great elaboration of detail, on the other, are alike unsatisfactory.

The fact that histology has its place at the beginning of the medical curriculum, and, indeed, with increasing frequency in the courses preparatory to medicine, often requires the student to study the microscopic details of organs before he has become acquainted with their gross anatomy. In order to minimize this deficiency, the histological descriptions have been prefaced with references to the macroscopic features whenever such explanations seemed desirable. The criticism, for instance, that an outline description of the brain, by pencil as well as by pen, is out of place in a text-book of histology, loses much of its force when the usual ignorance of the student concerning even the chief subdivisions of the central nervous system is recalled. The author believes, therefore, that these additions are justified and will materially facilitate the student's appreciation of the correlation between the structures demonstrated in the dissecting room and the details seen under the microscope.

With the exception of those from other sources, duly acknowledged in the legends, the illustrations have been drawn, with the aid of the camera lucida, by Mr. Louis Schmidt, whose skilful pencil has faithfully represented the preparations. The latter, mostly from the author's cabinet, have been selected to show the usual rather than the unusual histological appearances.

The author gratefully acknowledges the kindness of Prof. William G. Spiller, Prof. G. Carl Huber, Prof. Thomas G. Lee, and Dr. Joseph P. Tunis in placing their preparations at his disposal. To Dr. W. H. F. Addison his thanks are due for repeated courtesies in preparing specimens and for suggestions regarding microscopical technique. The author wishes to express his obligations to the publishers for their hearty coöperation.



# CONTENTS.

THE CELL.		PAGE
General Considerations .....	1	
Structure of the Cell.....	2	
The Cytoplasm .....	2	
The Nucleus .....	3	
The Nucleolus .....	4	
The Centrosome .....	4	
Vital Phenomena .....	5	
Metabolism.....	5	
Growth .....	5	
Reproduction.....	5	
Irritability .....	6	
Cell-Division .....	6	
Mitotic Division.....	7	
Synopsis of Mitosis .....	10	
Amitotic Division .....	10	
Origin and Differentiation of Cells ..	11	
The Germ-Cells.....	11	
The Ovum .....	11	
The Spermatozoon .....	12	
Segmentation.....	12	
Blastodermic Vesicle .....	13	
The Germ-Layers.....	13	
Derivatives of the Germ-Layers.	15	
<b>THE ELEMENTARY TISSUES.</b>		
The Epithelial Tissues.....	16	
Squamous Epithelium.....	16	
Columnar Epithelium .....	18	
Modified Epithelium .....	18	
Endothelium .....	20	
The Connective Tissues.....	21	
Mucous Tissue .....	22	
Reticular Tissue .....	22	
Fibrous Tissue .....	23	
Tendon .....	28	
Adipose Tissue.....	29	
Hyaline Cartilage .....	31	
Elastic Cartilage .....	33	
Fibrous Cartilage .....	33	
Bone .....	34	
Periosteum.....	38	
Bone-Marrow .....	39	
Red Marrow.....	40	
Development of Bone .....	42	
Endochondral Formation ..	43	
Intracartilaginous .....	43	
Subperiosteal .....	47	
Intramembranous Formation	49	
Development of Bone— <i>Continued.</i>		PAGE
Growth of Bones .....		50
Articulations .....		51
Synarthrosis .....		51
Diarthrosis .....		51
Muscular Tissue .....		53
Nonstriated Muscle .....		53
Cardiac Muscle .....		55
Striated Muscle.....		57
Development of Muscle .....		61
Attachment of Muscles .....		62
Aponeuroses .....		63
Fasciæ .....		63
Tendon-Sheaths.....		63
Bursæ.....		64
The Nervous Tissues .....		64
General Considerations .....		64
The Neurones .....		65
Nerve-Fibres .....		68
Medullated Fibres .....		68
Nonmedullated Fibres .....		70
Neuroglia .....		70
Nerve-Trunks .....		71
The Ganglia .....		73
Spinal Ganglia .....		74
Sympathetic Ganglia .....		74
Paraganglia.....		75
Development of Nervous Tissues		76
Nerve-Terminations.....		79
Sensory Nerve-Endings .....		79
Free Sensory Endings.....		79
Encapsulated Sensory Endings .....		80
The Tactile Corpuscles .....		80
The End-Bulbs .....		81
The Genital Corpuscles .....		81
The Cylindrical End-Bulbs.....		82
The Vater-Pacinian Corpuscles.....		82
The Golgi-Mazzoni Corpuscles .....		83
Neuromuscular Endings .....		83
Neurotendinous Endings .....		85
Motor Nerve-Endings .....		85
Endings in Voluntary Muscle .....		85
Endings in Involuntary Muscle .....		86
Endings in Cardiac Muscle..		86

<b>THE BLOOD-VASCULAR SYSTEM.</b>		<b>THE ALIMENTARY CANAL.</b>	
<b>General Structure of Blood-Vessels..</b>	87	<b>The Oral Cavity .....</b>	129
<b>The Arteries .....</b>	89	<b>The Mucous Membrane .....</b>	129
<b>The Veins .....</b>	91	<b>The Teeth.....</b>	131
<b>The Capillaries .....</b>	92	<b>The Enamel .....</b>	131
<b>The Blood .....</b>	94	<b>The Dentine .....</b>	133
<b>The Colored Blood-Cells .....</b>	94	<b>The Cementum .....</b>	135
<b>The Colorless Blood-Cells.....</b>	96	<b>Alveolar Periosteum .....</b>	135
<b>The Blood Plates .....</b>	97	<b>The Pulp.....</b>	136
<b>Blood-Crystals.....</b>	98	<b>Development of the Teeth .....</b>	137
<b>Development of the Blood-Vascular</b>		<b>The Dental Papilla .....</b>	137
<b>Tissues.....</b>	99	<b>Formation of Dentine ..</b>	137
<b>The Blood-Vessels.....</b>	99	<b>The Enamel-Organ .....</b>	139
<b>The Erythrocytes.....</b>	99	<b>Formation of Enamel ..</b>	140
<b>The Colorless Cells .....</b>	100	<b>The Tooth-Sac .....</b>	141
<b>The Heart .....</b>	101	<b>Formation of Cementum</b>	141
<b>The Endocardium .....</b>	101	<b>The Secondary Dentition ..</b>	141
<b>The Myocardium .....</b>	102	<b>The Tongue .....</b>	142
<b>The Epicardium .....</b>	103	<b>The Muscles .....</b>	142
<b>Development of the Heart .....</b>	104	<b>The Mucous Membrane .....</b>	142
<b>THE LYMPHATIC SYSTEM.</b>		<b>Papillary Area .....</b>	143
<b>General Considerations .....</b>	105	<b>Papillæ .....</b>	143
<b>The Lymph-Spaces .....</b>	106	<b>Lymphoid Area .....</b>	145
<b>The Lymph-Vessels .....</b>	107	<b>The Lingual Glands .....</b>	145
<b>Lymphoid Tissue .....</b>	108	<b>The Oral Glands .....</b>	146
<b>The Simple Lymph-Nodules ..</b>	108	<b>The Salivary Glands .....</b>	147
<b>The Lymph-Nodes .....</b>	109	<b>The Parotid Gland .....</b>	148
<b>The Hemolymph Nodes .....</b>	112	<b>The Submaxillary Gland .....</b>	149
<b>Development of the Lymphatic Sys-</b>		<b>The Sublingual Gland .....</b>	149
<b>tem .....</b>	112	<b>The Palate .....</b>	151
<b>The Spleen .....</b>	113	<b>The Pharynx .....</b>	152
<b>Accessory Spleens.....</b>	116	<b>The Mucous Membrane .....</b>	152
<b>Vascular Appendages .....</b>	117	<b>The Lymphoid Tissue .....</b>	153
<b>The Carotid Bodies .....</b>	117	<b>The Faucial Tonsil .....</b>	153
<b>The Coccyeal Body .....</b>	118	<b>The Pharyngeal Tonsil ..</b>	154
<b>MUCOUS MEMBRANES AND GLANDS.</b>		<b>The Oesophagus .....</b>	154
<b>The Mucous Membranes .....</b>	119	<b>The Mucous Membrane .....</b>	154
<b>The Epithelium.....</b>	120	<b>The Submucous Layer .....</b>	155
<b>The Tunica Propria .....</b>	120	<b>The Oesophageal Glands ..</b>	155
<b>The Submucous Layer .....</b>	121	<b>The Muscular Coat .....</b>	156
<b>The Blood-Vessels .....</b>	121	<b>The Stomach .....</b>	157
<b>The Lymphatics .....</b>	121	<b>The Mucous Coat .....</b>	157
<b>The Nerves .....</b>	121	<b>The Gastric Glands .....</b>	158
<b>The Glands .....</b>	122	<b>The Submucous Coat .....</b>	160
<b>General Considerations .....</b>	122	<b>The Muscular Coat .....</b>	161
<b>Simple Tubular Glands .....</b>	124	<b>The Serous Coat .....</b>	161
<b>Compound Tubular Glands .....</b>	124	<b>The Blood-Vessels .....</b>	162
<b>  Tubo-Alveolar Glands .....</b>	124	<b>The Lymphatics .....</b>	162
<b>Serous Glands .....</b>	125	<b>The Nerves .....</b>	163
<b>Mucous Glands .....</b>	126	<b>The Small Intestine .....</b>	163
<b>Simple Alveolar Glands .....</b>	127	<b>The Mucous Membrane .....</b>	163
<b>Compound Alveolar Glands</b>	127	<b>The Villi .....</b>	164
<b>Development of Glands .....</b>	128	<b>The Plicæ Circulares .....</b>	166
		<b>The Glands .....</b>	166
		<b>Brunner's Glands .....</b>	166
		<b>Lieberkühn's Glands .....</b>	168
		<b>The Lymph-Nodules .....</b>	168
		<b>The Solitary Nodules ..</b>	168
		<b>Peyer's Patches .....</b>	169



**The Small Intestine—Continued.**

The Submucous Coat . . . . .	170
The Muscular Coat . . . . .	170
The Serous Coat . . . . .	170
The Blood-Vessels . . . . .	170
Lymphatics . . . . .	171
Nerves . . . . .	171
<b>The Large Intestine . . . . .</b>	<b>171</b>
The Mucous Membrane . . . . .	171
The Submucous Coat . . . . .	172
The Muscular Coat . . . . .	172
The Serous Coat . . . . .	172
The Ileo-Cæcal Valve . . . . .	173
The Vermiform Appendix . . . . .	173
<b>The Peritoneum . . . . .</b>	<b>175</b>
<b>The Liver . . . . .</b>	<b>176</b>
The Lobules . . . . .	177
The Liver-Cells . . . . .	178
The Bile-Capillaries . . . . .	179
The Biliary Passages . . . . .	181
Interlobular Bile-Ducts . . . . .	181
The Hepatic Duct . . . . .	181
The Gall-Bladder . . . . .	182
The Common Bile-Duct . . . . .	183
The Blood-Vessels . . . . .	183
The Lymphatics . . . . .	183
<b>The Nerves . . . . .</b>	<b>183</b>
<b>The Pancreas . . . . .</b>	<b>183</b>
The Pancreatic Duct . . . . .	184
The Gland-Tissue . . . . .	185
The Islands of Langerhans . . . . .	185
The Blood-Vessels . . . . .	186
The Lymphatics . . . . .	186
The Nerves . . . . .	186

**THE ORGANS OF RESPIRATION.**

<b>The Larynx . . . . .</b>	<b>187</b>
The Cartilages . . . . .	187
The Mucous Membrane . . . . .	187
The Vocal Folds . . . . .	189
The Blood-Vessels . . . . .	189
The Lymphatics . . . . .	189
The Nerves . . . . .	190
<b>The Trachea and Bronchi . . . . .</b>	<b>190</b>
The Cartilage . . . . .	190
The Mucous Membrane . . . . .	191
<b>The Lungs . . . . .</b>	<b>191</b>
The Lobule and Lung-Units . . . . .	191
The Bronchioles . . . . .	192
The Air-Spaces . . . . .	194
The Blood-Vessels . . . . .	195
The Lymphatics . . . . .	196
The Nerves . . . . .	196
<b>The Pleuræ . . . . .</b>	<b>196</b>
<b>The Thyroid Body . . . . .</b>	<b>197</b>
<b>The Parathyroid Bodies . . . . .</b>	<b>199</b>
<b>The Thymus Body . . . . .</b>	<b>200</b>

**THE URINARY ORGANS.**

<b>The Kidneys . . . . .</b>	<b>205</b>
The Architecture . . . . .	205
The Kidney-Substance . . . . .	207
The Course of the Tubules . . . . .	207
Details of the Tubules . . . . .	209
The Supporting Tissue . . . . .	213
The Blood-Vessels . . . . .	213
The Lymphatics . . . . .	215
The Nerves . . . . .	215
<b>The Renal Ducts . . . . .</b>	<b>215</b>
The Ureters . . . . .	215
<b>The Bladder . . . . .</b>	<b>217</b>
<b>The Male Urethra . . . . .</b>	<b>219</b>
<b>The Female Urethra . . . . .</b>	<b>221</b>
<b>The Suprarenal Bodies . . . . .</b>	<b>222</b>

**THE MALE REPRODUCTIVE ORGANS.**

<b>The Testicle and Its Architecture . . . . .</b>	<b>227</b>
The Testis—Spermatogenesis . . . . .	229
The Epididymis . . . . .	233
Appendix Testis . . . . .	235
Appendix Epididymidis . . . . .	235
The Paradidymis . . . . .	235
Ductuli Aberrantes . . . . .	235
<b>The Spermatic Ducts . . . . .</b>	<b>235</b>
The Vas Deferens . . . . .	235
The Ampulla . . . . .	236
The Ejaculatory Duct . . . . .	237
The Seminal Vesicle . . . . .	237
<b>The Penis . . . . .</b>	<b>239</b>
Corpora Caverosa . . . . .	239
Corpus Spongiosum . . . . .	239
Blood-Vessels . . . . .	239
Nerves . . . . .	241
<b>The Prostate Gland . . . . .</b>	<b>241</b>
<b>The Bulbo-Urethral Glands . . . . .</b>	<b>244</b>

**THE FEMALE REPRODUCTIVE ORGANS.**

<b>The Ovaries . . . . .</b>	<b>245</b>
The Follicles and Ova . . . . .	245
The Human Ovum . . . . .	248
Corpus Luteum . . . . .	249
<b>Rudimentary Organs . . . . .</b>	<b>252</b>
The Epoöphoron . . . . .	252
Gartner's Duct . . . . .	253
The Paroöphoron . . . . .	253
Vesicular Appendages . . . . .	253
<b>The Oviducts . . . . .</b>	<b>254</b>
<b>The Uterus . . . . .</b>	<b>255</b>
Endometrium . . . . .	256
Uterine Glands . . . . .	256
Myometrium . . . . .	257
<b>The Vagina . . . . .</b>	<b>259</b>

The External Organs.....	260
The Labia.....	260
The Vestibule.....	261
The Paraurethral Ducts.....	261
The Clitoris.....	262
The Bulbus Vestibuli.....	262
The Glands of Bartholin.....	262
The Mammary Glands.....	262
Glandular Tissue.....	262
Excretory Ducts.....	263
The Nipple.....	263
Colostrum.....	264
Milk.....	264

### THE CENTRAL NERVOUS SYSTEM.

The Spinal Cord.....	266
General Considerations.....	267
The Gray Matter.....	268
Anterior Horn Cells.....	269
Posterior Horn Cells.....	270
Neuroglia of Gray Matter.....	272
The Central Canal.....	273
The White Matter.....	273
Neuroglia of White Matter..	274
The Fibre-Tracts.....	274
The Blood-Vessels.....	279
The Brain.....	279
Outline of Gross Anatomy.....	280
The Medulla Oblongata.....	282
The Pons Varolii.....	288
The Mid-Brain.....	291
The Cerebral Peduncles.....	292
The Tegmentum.....	292
The Cerebellum.....	294
The Cortex.....	294
The Internal Nuclei.....	298
The Cerebral Cortex.....	299
The Basal Ganglia.....	304
The Pineal Body.....	308
The Pituitary Body.....	309
The Meninges.....	311
The Pacchonian Bodies.....	314

### THE SENSE ORGANS.

The Skin.....	315
The Hairs.....	323
Development of the Hair...	328
The Nails.....	330
The Sebaceous Glands.....	333
The Sweat-Glands.....	334
The Eye.....	337
General Considerations.....	337
The Fibrous Tunic.....	338
The Sclera.....	338
The Cornea.....	339
The Sclero-Corneal Junction	340

### The Eye—Continued.

The Vascular Tunic.....	341
The Choroid.....	342
The Ciliary Body.....	343
The Iris.....	345
The Nervous Tunic.....	346
The Retina.....	346
The Macula Lutea.....	351
The Ora Serrata.....	352
The Optic Nerves.....	353
The Crystalline Lens.....	354
The Vitreous Body.....	355
The Suspensory Apparatus.....	356
The Eyelids and Conjunctiva.....	357
The Lachrymal Apparatus.....	360
The Lachrymal Gland.....	361
The Lachrymal Canals.....	361
The Lachrymal Sac.....	362
The Naso-Lachrymal Duct.....	362
The Ear.....	362
The External Ear.....	362
The Auricle.....	362
The External Canal.....	363
The Middle Ear.....	365
The Tympanic Membrane..	365
The Mucous Membrane....	366
The Ear Ossicles.....	367
The Eustachian Tube.....	367
The Mastoid Cells.....	369
The Internal Ear.....	369
The Bony Labyrinth.....	369
The Membranous Labyrinth	371
Semicircular Canals....	371
Utricle and Sacculc.....	371
Cochlear Duct.....	373
Organ of Corti.....	376
The Nose.....	380
The Nasal Mucous Membrane..	380
The Olfactory Region.....	381
The Respiratory Region....	382
Jacobson's Organ.....	384
The Accessory Air-Spaces....	384
Organ of Taste.....	385
Taste-Buds.....	385

### APPENDIX—TECHNIQUE.

Fixation and Preservation of Tissues	389
Embedding.....	392
Celloidin Method.....	393
Paraffin Method.....	394
Section-Cutting.....	396
Celloidin Sections.....	396
Paraffin Sections.....	396
Ribbon-Sections.....	397
Staining Methods.....	399
Mounting and Finishing.....	403
Special Methods.....	405
Injecting Blood-vessels.....	408

# NORMAL HISTOLOGY.

## THE CELL.

ALL animals and plants are composed of minute structural elements called "cells." With the exception of the low unicellular forms, in which a single cell constitutes the entire organism, the fully developed animal comprises myriads of cells arranged as the tissues composing the various parts or organs.

Notwithstanding its complexity, the body of even the highest animal, man, may be resolved into four elementary tissues—*epithelial*, *connective*, *muscular* and *nervous*—which serve, primarily, for the purpose of protection, connection and support, motion and control respectively. Every tissue consists of two parts, the cells and the intercellular substance. Upon the first of these, the cells, depend the vitality and growth of the tissue; while the intercellular substance owes its production, directly or indirectly, to the activity of the cells.

Every living organism is derived from a parent cell, the *ovum*. This element, liberated from the ovary of the mother, undergoes certain preparatory changes, known as *maturation*, and then unites with the paternal germ-cell, the *spermatic filament* or *spermatozoon*. The union of these two sex-cells results in fertilization of the ovum. The fertilized ovum immediately divides into the daughter cells, each of which gives rise to two new elements; each of these, in turn, produces two descendants, and so on. As the result of *segmentation*, as this cycle of repeated division is termed, a numerous progeny of new cells arises from the original parent cell. The further division and differentiation of the segmentation cells lead to the formation of the three *germ-layers*—the *ectoderm*, the *mesoderm* and the *entoderm*—from which the definite embryo subsequently is evolved.

Notwithstanding their diversity of form and size, as seen in the adult condition, the cells of the animal body possess certain features in common. So small that they can be seen only when examined with the microscope, they consist of a minute mass of gelatinous substance, the *cell-body*, in which lies embedded a still smaller round or oval body, the *nucleus*. At times within the latter a distinct dot, the *nucleolus*, is seen. The original conception of the cell, as implied by its name, was that of a minute sac, surrounded by a definite membrane or *cell-wall*, filled with fluid and enclosing a second smaller sac, the nucleus, which, in turn, contained a third saccule, the nucleolus. Subsequent study established the gelatinous, not fluid, character of the substance of the cell-body, or *cytoplasm*, and the frequent absence of the cell-wall and the nucleolus. The cell-body and the nucleus are, therefore, the only essential parts of such structural units as are entitled to be regarded as true "cells"—retaining and

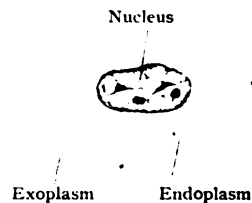


FIG. 1.—Colorless blood-corpuscle, representing type of embryonal cell; cytoplasm exhibits differentiation into endoplasm and exoplasm. X 2500.

using this misleading term in its accepted but not literal sense. The substance of the entire cell, including that of the cell-body and of the nucleus, is the *protoplasm*, the cell being often defined as "a minute nucleated particle of protoplasm."

### THE STRUCTURE OF THE CELL.

**The Cytoplasm.**—The translucent, viscid substance forming the cell-body, the cytoplasm, is complex in both its chemical and structural composition. Chemically, cytoplasm consists of a heterogeneous mixture of water, salts and organic compounds. The latter are grouped under the term *proteids*, which are complex combinations of carbon, hydrogen,

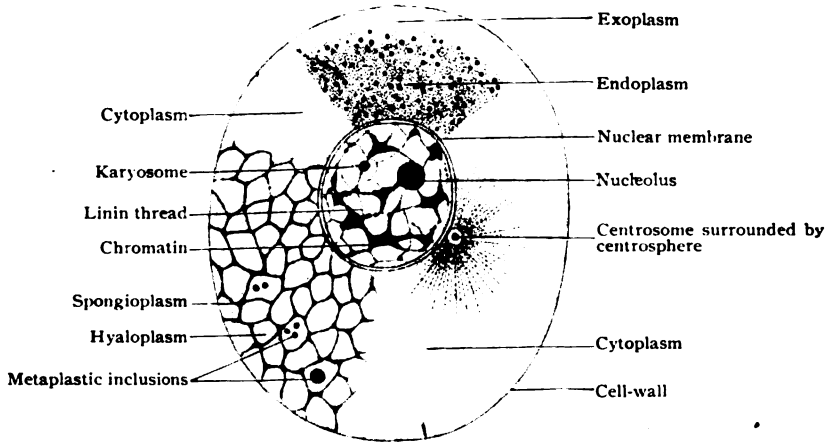


FIG. 2.—Diagram of cell-structure. In the upper part of figure the granular condition of the cytoplasm is represented; in the lower and left part, the reticular condition.

nitrogen and oxygen, with often a small percentage of sulphur. The proteids of the cytoplasm, in contrast to those of the nucleus, contain little or no phosphorus.

The cytoplasm by no means always presents the same structural appearance, since its constituents are subject to changes in their condition and arrangement which produce corresponding morphological variations. Thus, the cytoplasm may be devoid of recognizable definite structure and appear *homogeneous*; at other times it may present aggregations of minute spherical particles and then be described as *granular*, or where the minute spheres are larger and consist of fluid substances embedded within a surrounding denser material, as *alveolar*; or, again, and most frequently, the cytoplasm contains a meshwork of threads or fibrils, more or less conspicuous, which arrangement gives rise to the *reticular* condition. It must be recognized, therefore, that the structure of cytoplasm is not to be regarded as immutable, but on the contrary, as capable of undergoing changes which render it probable that a cell may appear during one stage of its existence as granular and at a later period as reticular.

Whatever be the particular phase of structure exhibited by the cell, histologists are agreed that the cytoplasm consists of two substances—an *active* and a *passive*; while both must be regarded as living, the manifestations of contractility are probably produced by the former.

Within the granular cytoplasm of many young or slightly differentiated cells, as the colorless blood-cells, the active substance is represented by minute spherical particles, or *microsomes*. Often these are not uniformly distributed in the cell-body, a narrow peripheral zone of variable width and firmer consistence being almost free from granules, while the area surrounding the nucleus is densely packed. The terms *exoplasm* and *endoplasm* are sometimes employed to designate the homogeneous peripheral and granular central regions of the cell-body respectively. Although only very exceptionally, as in the case of the ovum, is the animal cell possessed of a definite limiting membrane or *cell-wall*, the peripheral layer of the cytoplasm is usually of greater density. Changes in the surface tension, which is thereby reduced, probably account for the alterations in form—the amoeboid movements—and similar phenomena often regarded as “vital” manifestations.

Since a more or less pronounced reticular arrangement of the active constituent of the cytoplasm is widely encountered in mature cells, this condition may serve as the basis of the description of the morphology of the typical cell. Examination of suitably prepared preparations with adequate lenses shows the cytoplasm of many cells, especially the highly differentiated forms of glandular epithelium, to contain a meshwork composed of delicate threads and plates of the more active substance, the *spongioplasm* (also called *mitome* or the *filar mass*). The spongioplastic threads contain rows of minute granules, the *microsomes*, either scattered or closely placed. Although conspicuous only after appropriate staining, threads of spongioplasm may at times be seen in the unstained and living cell, thereby proving that such structural details are not artefacts due to the action of reagents upon the albuminous substances of the cytoplasm.

The interstices of the meshwork are filled with a clear, more or less homogeneous semifluid substance to which the name of *hyaloplasm* (also *paraplasm*, *paramilome* or *interfilar mass*), has been applied. Embedded within the hyaloplasm, a variable amount of foreign substances is frequently present. These include particles of oil, pigment, secretory products and other extraneous materials, which, while of possible importance in fulfilling the purpose of the cell, are not among its essential morphological constituents. These substances, which are inert and take no part in the vital activity of the cell, are termed collectively *metaplasm*.

**The Nucleus.**—This, the second essential constituent of the cell, usually appears as a sharply defined spherical or ellipsoidal body, which, in stained preparations, is conspicuous on account of its deeper color. Since the nucleus is the nutritive, as well as the reproductive, organ of the cell, the fact that this part of the cell is relatively large in young and actively growing elements is readily explained. While in a general way the nucleus

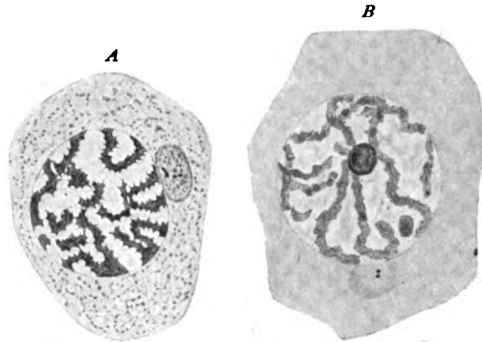


FIG. 3.—Spermatogenic cells, showing variations in the condition and the arrangement of the constituents of the cytoplasm and the nucleus; the centrosomes are seen within the cytoplasm close to the nucleus. *A*, from the guinea-pig,  $\times 1675$  (Meves); *B*, from the cat,  $\times 680$  (von Lenhossek).

corresponds in shape with the form of the cell, being oval or rod-like in elongated columnar or fusiform cells, and compressed or flattened in plate-like elements, its outline is sometimes very irregular, as conspicuously seen in the case of the colorless cells (leucocytes) of the blood. At times the nucleus is capable of changing its form or even position independent of the surrounding cytoplasm. Except during certain phases of division, when the usual demarcation temporarily disappears, the nucleus is sharply defined from the cytoplasm by a distinct envelope, the *nuclear membrane*. The latter encloses the substance of the nucleus, the *karyoplasm*, which structurally resembles the cytoplasm in being composed of two parts—an irregular reticulum of *nuclear fibrils* and an intervening semifluid *nuclear matrix*.

The **nuclear fibrils**, when examined under high magnification after appropriate treatment with suitable stains, such as hematoxylin, safranin and other basic dyes, are shown to consist of minute irregular masses of a deeply colored substance, appropriately called *chromatin*, in recognition of its great affinity for certain stains. The chromatin particles are supported upon or within delicate inconspicuous and almost colorless threads of *linin*. The latter forms the basis of the supporting framework of the nuclear fibrils, in which the chromatin is so conspicuous by reason of its capacity for staining. The individual masses of chromatin vary greatly in form, often being irregular, and at other times thread-like or beaded. Not infrequently the chromatin presents spherical aggregations which appear as deeply stained nodules attached to the nuclear fibrils. These constitute the false nucleoli, or *karyosomes*, as distinguished from the true nucleolus, which is usually present within the karyoplasm. Chemically, chromatin, the most important part of the nucleus, contains *nuclein*, a compound rich in phosphorus.

The **nuclear matrix**, the fluid or semifluid substance which occupies the spaces between the nuclear fibrils, possesses an exceedingly weak affinity for the staining reagents employed to color the chromatin. It usually appears, therefore, clear and untinted, and contains a substance described as *paralinin*.

The **nucleolus**, or *plasmosome*, ordinarily appears as a small spherical body, sometimes multiple, lying among, but unattached to, the nuclear fibres. In stained tissues its color varies, sometimes resembling that of the chromatin, although less intense, but usually presenting a different tint, since it responds readily to dyes which, like eosin or acid fuchsin, particularly affect the linin and cytoplasm. Concerning the nature, purpose and function of the nucleolus much uncertainty exists. According to some

authorities these bodies are to be regarded as storehouses of substances which are used in forming the chromatin segments during cell-division, while other cytologists attribute to the nucleolus a passive rôle, even holding it to be a by-product, which, at least in some cases, is cast out from the nucleus into the cytoplasm, where it may disappear. The nucleolus is credited with containing a peculiar substance known as *pyrenin*.

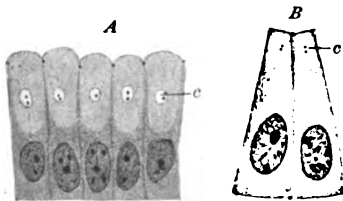


FIG. 4.—Human epithelial cells showing paired centrosomes (c, c); A, from gastric glands; B, from duodenal glands.  $\times 690$ . (K. W. Zimmermann.)

**The Centrosome.**—In addition to the parts already described, many animal cells contain a minute body, the *centrosome*, which probably plays an important rôle during division and, in a lesser degree, during other phases of cellular activity. Ordinarily the centrosome escapes attention because, on account of its minute size and variable staining affinity, it is with difficulty distin-

guished from the surrounding granules. Its usual position is within the cytoplasm, but the exact location seems to depend upon the focus of greatest motor activity; thus, in a dividing element, the centrosome lies immediately related to the actively changing nucleus, while within ciliated epithelium it is found closely associated with the contractile filaments connected with the hair-like appendages. In recognition of the intimate relations between this minute body and the motor changes affecting the cell, the centrosome may be regarded physiologically as its dynamic centre. The centrosome, often represented by a pair of minute granules (*diplosome*), is frequently surrounded by a clear area or halo, the *centrosphere*. As seen in certain invertebrate cells, the centrosome is resolvable into a minute granule, the *centricle*, embedded within a substance known as the *centroplasm*.

### VITAL PHENOMENA.

The vital manifestations of the cell include those complex physico-chemical changes which occur during the life of the cell in the performance of its appointed work. They embrace *metabolism*, *growth*, *reproduction* and *irritability*.

**Metabolism**, the most distinctive characteristic of living matter, is that process whereby protoplasm selects from the heterogeneous materials of food those particular substances which are suitable for its nutrition and converts them into its own substance. Metabolism is of two kinds—constructive and destructive. *Constructive metabolism*, or *anabolism*, is the process by which the cell converts the simpler compounds into organic substances of great chemical complexity. *Destructive metabolism*, or *katabolism*, is the process by which the cell breaks up the complex substances resulting from constructive metabolism into simpler compounds. Vegetal cells possess the power of constructive metabolism in a conspicuous degree and from the simpler substances, such as water, carbon dioxide and inorganic salts, prepare food-material for the nutritive and katabolic processes which especially distinguish animal cells. The latter are dependent, directly or indirectly, upon the vegetal cells for their nutritive materials.

**Growth**, the natural sequel of the nutritive changes effected by metabolism, may be unrestricted and equal in all directions, resulting in uniform expansion of the spherical cell, as illustrated in the growth of the ovum in attaining its mature condition. Such unrestricted growth, however, is exceptional, since cells are usually more or less intimately related to other structural elements by which their increase in size is modified so as to be limited to certain directions. Such limitation and influence result in *unequal growth*, a force of great potency in bringing about the differentiation and specialization of cells, and, secondarily, of organs and entire parts of the body. Familiar examples of the results of unequal growth are seen in the columnar cells of epithelium, the fibres of muscular tissue, and the neurones of the nervous system.

**Reproduction** may be regarded as the culminating vital manifestation in the life-cycle of the cell, since by this process the parent cell surrenders its individuality and continues its life in the existence of its offspring. Cell-reproduction occurs by two methods—the indirect or *mitotic* and the direct or *amitotic*. The first of these, involving the complicated cycle of nuclear changes known as *mitosis* or *karyokinesis*, is the usual method; the second and simpler process of direct division is exceptional and frequently associated with conditions of impaired vital vigor.

**Irritability** is that property of living matter by virtue of which the cell exhibits changes in its form and intimate constitution in response to external impressions. The latter may originate in mechanical, thermal, electrical or chemical stimuli to which the protoplasm of even the lowest organisms responds; or they may be produced in consequence of obscure and subtle changes occurring within the protoplasm of neighboring cells, as illustrated by the reaction of one neurone in response to the stimuli transmitted from other nervous elements.

### CELL DIVISION.

With the exception of the unusual cases in which division takes place by the direct or amitotic method, the production of new generations of cells of all kinds is accomplished by a complicated series of changes, collectively

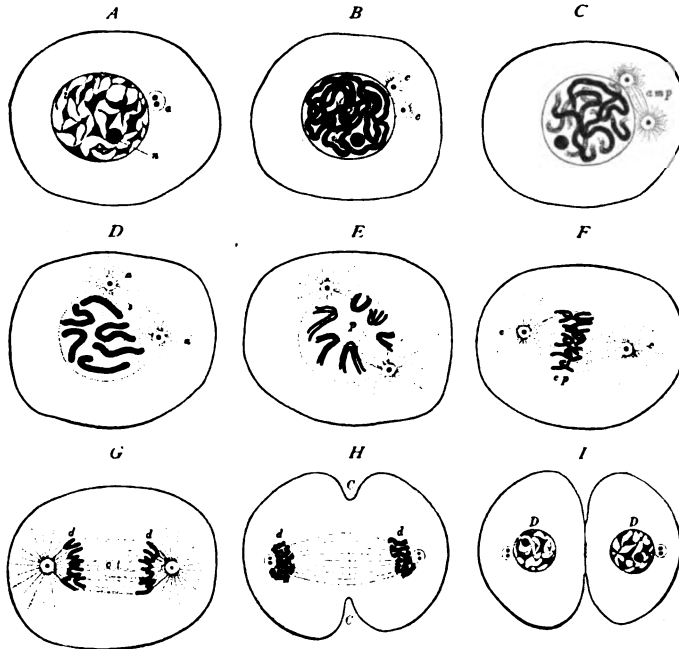


FIG. 5.—Diagram of mitosis. *A*, resting stage, chromatin irregularly distributed in nuclear reticulum; *a*, centrosphere containing double centrosome; *n*, nucleolus. *B*, chromatin arranged as close spirem; *c, c*, centrosomes surrounded by achromatic radial striations. *C*, stage of loose spirem, achromatic figure forming amphiasma (*amp*). *D*, chromatin broken into chromosomes; nucleolus has disappeared, nuclear membrane fading; amphiasma consists of two asters (*a, a*) surrounding the separating centrosomes, connected by the spindle (*s*). *E*, longitudinal cleavage of the chromosomes which are arranged around the polar field (*p*) occupied by the spindle. *F*, migration of chromatic segments towards new nuclei, as established by centrosomes (*c, c*); *e, e*, equatorial plate formed by intermingling segments. *G*, separating groups of daughter chromosomes (*d, d*) united by connecting threads (*ct*). *H*, daughter chromosomes (*d, d*) becoming arranged around daughter centrosomes which have already divided; *C, C*, beginning cleavage of cytoplasm across plane of equatorial spindle. *I*, completed daughter nuclei (*D, D*); cytoplasm almost divided into two new cells. (Modified from Wilson.)

known as *mitosis* or *karyokinesis*, especially affecting the nucleus. In addition to presiding over the nutritive changes within the cell, the nucleus is particularly concerned in the process of reproduction; further, of the various morphological constituents of the nucleus, the chromatin displays the most active change, since this substance is the vehicle by which the characteristics of the parent cell are transmitted to the new elements. So essen-



tial is this substance for the perpetuation of the specific character of the cell, that the entire complex mitotic cycle has for its primary purpose the insurance of the equal division of the chromatin of the mother cell between the two new nuclei. Such impartial distribution of the maternal chromatin takes place irrespective of any, or even very great, dissimilarity in the size of the daughter cells, the smaller receiving one-half, or exactly the same amount of chromatin as the larger.

**Mitotic Division.**—The details of mitosis or karyokinesis include a series of changes involving the nucleus, the centrosome and the cytoplasm. These changes are grouped conveniently into four stages: (1) the *Prophases*, or preparatory changes; (2) the *Metaphase*, during which the mass of maternal chromatin is equally divided; (3) the *Anaphases*, in which the chromatin is distributed to the new nuclei; and (4) the *Telophases*, during

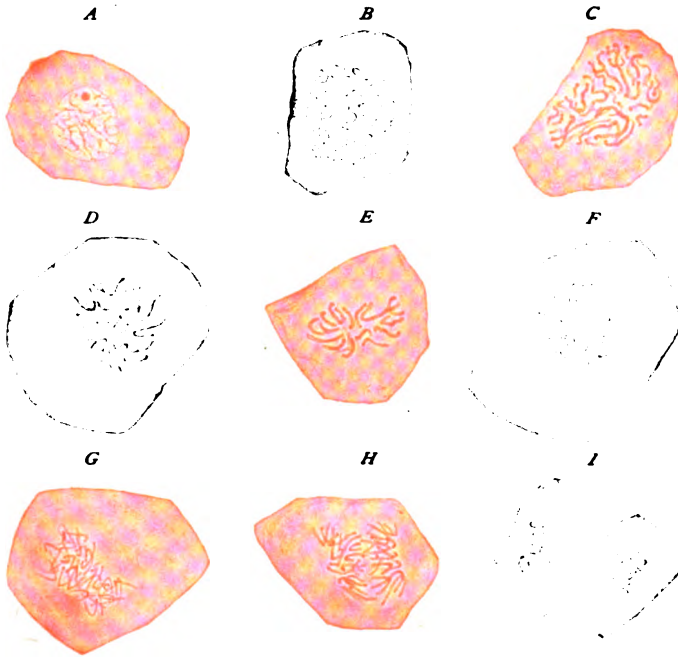


FIG. 6.—Chromatic figures in dividing cells from epidermis of salamander embryo.  $\times 850$ . *A*, resting stage; *B*, close spireme; *C*, loose spireme; *D*, chromosomes ("wreath"), seen from surface; *E*, similar stage, seen in profile; *F*, longitudinal cleavage of chromosomes; *G*, beginning migration of segments towards centrosomes; *H*, separating groups of daughter segments; *I*, daughter groups attracted towards poles of new nuclei, cytoplasm exhibits beginning cleavage.

which the cytoplasm of the mother cell undergoes division and the daughter cells are completed.

Mitosis includes two distinct but closely associated and coincident series of phenomena, the one involving the chromatin and the other the centrosome and the linin. While as a matter of convenience these two sets of changes are described separately, it must be understood that they take place simultaneously and in coördination. The purpose of the changes affecting the chromatin is the accurate and equal division of this substance by the longitudinal cleavage of the chromatin segments. The object of the activity of the centrosomes and the linin is to supply the requisite energy and guid-

ance by which the chromatin segments are directed to the new nuclei in process of formation, each daughter cell being insured in this manner one-half of the maternal chromatin.

The **Prophases**, or preparatory stages, include a series of changes which involve the nuclear substances and the centrosome, and result in the production of the *mitotic figure*. The latter consists of two parts, (1) the deeply staining chromatin filaments and (2) the achromatic figure, which colors only very slightly if at all. The chromatin, which before division begins is disposed along the irregular nuclear fibrils, loses its reticular arrangement and, increasing in amount as well as in its staining affinities, becomes transformed into a closely convoluted thread or threads, constituting the "close skein." The filaments composing the latter soon shorten and thicken to form the "loose skein." The skein, or *spireme*, may consist of a single continuous filament, or it may be formed of a number of separate threads. Sooner or later the skein breaks up transversely into a number of segments or *chromosomes*, which appear as deeply stained curved or straight rods. A very important, as well as remarkable, fact regarding the chromosomes, is their *numerical constancy*, since the cells of every animal and plant always possess a definite number of chromosomes, corresponding to the quota for that particular species; further, in all the higher animals the number is *even*, in man being probably twenty-four. During these changes affecting the chromatin, the *nucleolus*, or plasmosome, disappears and, probably, takes no active part in mitosis. The nuclear membrane likewise fades away during the prophases, the chromatic segments now lying unenclosed within the cell, in which the cytoplasm and nuclear matrix are continuous.

Coincident with the foregoing changes, the *centrosome*, which by this time has become double, is closely associated with the achromatic figure. A delicate radial striation appears around each centrosome, thereby producing an arrangement resembling stars or *asters*. The centrosomes early manifest a disposition to separate towards opposite poles of the cell, this migration resulting in a corresponding migration of the asters. In consequence of these changes, the retreating centrosomes become the foci of two systems of radial striation which meet and together form an achromatic figure known as the *amphiaster*. The latter consists of the two asters and the intervening *spindle*. There seems little doubt that the centrosomes play an important rôle in establishing foci towards which the chromosomes for the new nuclei become attracted. Subsequently the *nuclear spindle*, which originates from the amphiaster, often occupies the periphery of the nucleus, whose limiting membrane by this time has disappeared. The delicate threads of linin composing the nuclear spindle extend within an area, the *polar field*, around which the chromosomes become grouped. The chromosomes, which meanwhile have arisen by transverse division of the chromatin threads composing the loose skein, appear as V-shaped segments, the closed ends of the loops being directed towards the polar field which they encircle.

The **Metaphase** includes the most important detail of mitosis—namely, the *longitudinal cleavage* of the chromosomes, whereby the number of the latter is doubled and the chromatin is equally divided. The cleavage and division are the first steps towards the actual apportionment of the chromatin between the new nuclei, each of which receives not only exactly one-half of the chromatin, but the full quota of chromosomes, and this irrespective of even marked inequality in the size of the new daughter cells.

The notable exception to the constancy of the numerical quota of the chromosomes presented by the germ-cells should be mentioned. Since the chromosomes of the fertilized ovum are derived from the chromatin contributed equally by the paternal and maternal germ-cells—the spermatozoon and the ovum—it is evident that unless the number of chromosomes from each parent be only one-half the usual number for the species, the segmentation nucleus and the succeeding cells would contain twice the normal quota of chromosomes. In order to prevent such redundancy, during the development of the spermatid cells, on the one hand, and the maturation of the ovum on the other, *reduction* of the chromosomes to one-half the usual number actually takes place. The details by which this reduction is accomplished vary in different classes of animals; but, whatever be the method, the result is to reduce the number of chromatin-masses one-half. This may occur before or after the first of the divisions, producing the capable germ-cells. The full quota for the species is restored to the segmentation nucleus and its descendants by the subsequent addition of the reduced contingents of the two germ-cells when fertilization occurs.

Meanwhile the centrosomes have continued to migrate towards the opposite poles of the dividing cell, where each forms the centre of the astral radiation that marks either pole of the amphiaster. The purpose of the achromatic figure is to guide the longitudinally cleft chromosomes towards the new nuclei during the succeeding changes.

The **Anaphases** accomplish the migration of the chromosomes, each pair of sister segments contributing one unit to each of the two groups of chromosomes that are passing towards the poles of the achromatic spindle. In this manner each new nucleus receives not only one-half of the chromatin of the mother nucleus, but also the same number of chromosomes that originally existed within the mother cell, the numerical constancy of the particular species being thus maintained.

In the beginning of their passage towards the poles of the achromatic figure, the migrating chromatic segments, attracted along the linin threads, for a time form a compact group about the equator of the spindle. As the receding segments pass towards their respective poles, the opposed ends of the separating chromosomes are united by intervening achromatic threads, the *connecting fibres*. Sometimes the latter exhibit a linear series of thickenings, known as the *cell-plate* or *mid-body*. The migration of the chromosomes establishes the essential features of the division of the nucleus, since the subsequent changes are only repetitions, in reverse order, of the details of the prophases.

The **Telophases**, in addition to the final stages in the rearrangement of the chromatic segments of the new nuclei, including the appearance of the daughter skeins, of the new nuclear membranes and of the nucleoli, inaugurate the participation of the cytoplasm in the formation of the new cells. During these final stages of mitosis, the cell-body becomes constricted and then divides into two, the plane of division coinciding with the equator of the nuclear spindle. Each of the resulting masses of cytoplasm invests a new nucleus and receives one-half of the achromatic figure, consisting of a half-spindle and one of the asters with a centrosome. The new cell, now possessing all the constituents of the parent element, usually acquires the morphological characteristics of its ancestor and passes into a condition of comparative rest, until called upon, in its turn, to undergo division and enter upon the complicated cycle of mitosis.

## SYNOPSIS OF MITOTIC DIVISION.

## I. Prophases:

*A. Changes within the nucleus: Chromatic figure.*

Chromatin loses reticular arrangement.

Close skein.

Loose skein.

Disappearance of nucleolus.

Division of skein into chromosomes.

Chromosomes grouped around polar field.

Disappearance of nuclear membrane.

*B. Changes within the cytoplasm: Achromatic figure.*

Division of centrosome.

Appearance of asters.

Migration of centrosomes.

Formation of amphiaster.

Appearance of nuclear spindle and polar field.

## II. Metaphase:

Longitudinal cleavage of chromosomes.

## III. Anaphases:

Rearrangement of chromosomes into two groups.

Migration of groups towards poles of amphiaster.

Appearance of connecting fibres between receding groups.

Construction of daughter nuclei.

## IV. Telophases:

Constriction of cell-body at right angles to axis of spindle.

Chromosomes rearranged as daughter skeins.

Appearance of nuclear membranes.

Appearance of nucleoli.

Complete division of cell-body.

Daughter nuclei assume vegetative condition.

Achromatic striation usually disappears.

Centrosomes, single or double, lie beside new nuclei.

**Amitotic Division.**—The occurrence of cell reproduction without the complex cycle of karyokinetic changes, is known as *amitotic* or *direct division*. This process takes place as an exceptional method in the reproduction of the simplest forms of life, and in the multiplication of cells within pathological growths or tissues of a transient nature, as the fetal envelopes.

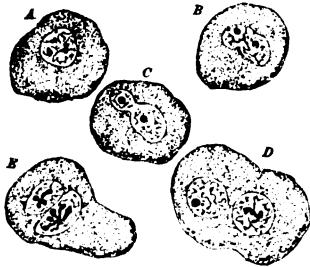


FIG. 7.—Decidual cells exhibiting amitotic division of nucleus (A-D); in E irregular mitosis has occurred.  $\times 350$ .

The essential difference between the amitotic and the usual method of division lies in the fact that, while in the latter the chromatin is equally divided and the number of chromosomes carefully maintained, in the direct method the nucleus remains passive and suffers cleavage of its total mass, but not of its individual components, by constriction or fission.

Neither the chromatic nor the achromatic figure is produced, the activity of the centrosome, when exhibited, being uncertain and perhaps directly expended in effecting division of the cytoplasm and, incidentally, of the nucleus. In many cases amitotic division of

the nucleus is not accompanied by cleavage of the cytoplasm, such processes resulting in the production of multinuclear and aberrant forms of cells. In general, it may be assumed that cells which undergo amitotic division are destined to suffer premature degeneration, since such elements subserve special purposes and are usually incapable of perpetuating their kind by normal reproduction. Flemming has pointed out that leucocytes which arise by direct division, and therefore deviate from the usual mode of origin of these elements, are doomed to early death. Among the higher animals, amitotic division must be regarded, probably, as a secondary process.

### ORIGIN AND DIFFERENTIATION OF THE CELLS.

The body, with all its complex details, is the product of the differentiation and specialization of cells which are the descendants of the fertilized ovum. The latter represents the two parents, since the chromatin of the

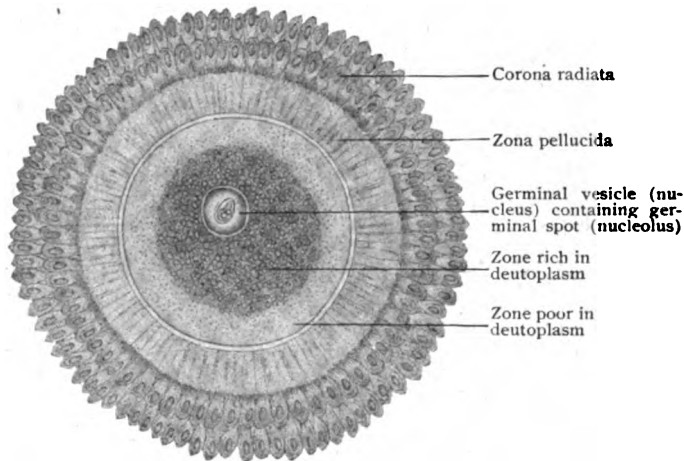


FIG. 8.—Human ovum from ripe Graafian follicle.  $\times 160$ . (Nagel.)

segmentation nucleus is contributed equally by the germ-cells, the spermatozoon and the ovum.

The **ovum** is formed within the female sexual gland, the *ovary*, where it passes through all stages of development, from immaturity to maturation, until finally liberated by rupture of the ovarian tissue. As a cell, the ovum is interesting, since it possesses all parts of the typical cell, including a cell-wall. These parts have long been designated by special names; thus, in the nomenclature of the egg, the cytoplasm is called the *vitellus* or *yolk*, the nucleus the *germinal vesicle*, the nucleolus the *germinal spot*, and the cell-wall the *olemma* or *vitelline membrane*. While the ova of birds and reptiles are often of huge size, the yolk of the hen's egg corresponding to a single cell, the true ovum, the mammalian ova are much smaller and barely visible with the unaided eye. The *human ovum*, when discharged from the ovary, is about .2 millimeter in diameter, spherical in form and composed of cytoplasm containing innumerable yolk-granules. The latter, the representatives of the abundant masses of nutritive material or *deutoplasm* stored as the food-yolk in the bird's egg, are especially numerous in the vicinity of

the nucleus. Towards the periphery of the cell they are nearly wanting, a narrow zone of almost homogeneous cytoplasm lying immediately beneath the delicate vitelline membrane. The liberated ovum is surrounded by a protecting membrane, the *zona pellucida*, which sometimes exhibits a faint radial striation. This envelope must not be confounded with the vitelline membrane, since it is not strictly a part of the ovum, but a product of the surrounding epithelial cells lining the little sac, the *Graafian follicle*, enclosing the egg while within the ovary. The large eccentric spherical nucleus, the germinal vesicle, is about  $37 \mu^1$  in diameter and surrounded by a distinct nuclear membrane. Within the germinal vesicle are found the usual constituents of the nucleus, including the all-important chromatin fibrils, nuclear matrix and nucleolus. The latter, the germinal spot, is distinct and measures about  $5 \mu$  in diameter.

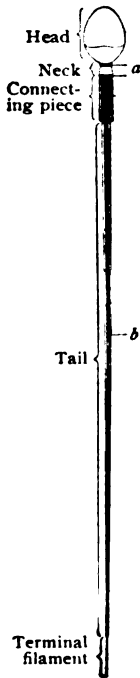


FIG. 9.—Diagram of human spermatozoon; *a*, neck-granules, representing the centrosome; *b*, axial fibre.  $\times 1800$ . (Meves).

The **spermatozoon**, the male germ-cell, is produced by the specialization of epithelial cells lining the seminiferous tubules within the testis. The human spermatozoon consists of three chief parts—the ovoid *head*, *middle-piece*, which includes the slightly constricted *neck* and the *connecting piece*, and the attenuated and greatly extended *tail*. Although the entire length of the spermatogenic element is about  $50 \mu$ , the head measures only about  $5 \mu$ ; the male germ-cell, therefore, is much smaller than the ovum. The head and the neck are the most important parts, since they contain respectively the chromatin and the centrosome of the cells, the *spermatids*, from which the spermatozoa are directly derived.

The centrosome is represented by two minute spherical bodies, the *neck-granules*, which lie in the neck immediately beneath the head and at the anterior extremity of the connecting piece. The *axial fibre* extends throughout the spermatozoon from the neck to the tip of the tail, ending as an attenuated thread, the *terminal filament*. The tail corresponds to a flagellum and serves the purpose of propulsion alone, taking no part in the important changes within the ovum incident to fertilization, during which the head and middle-piece enter the substance of the egg.

Immediately following the construction of a new nucleus from the chromatin contributed by the two parental germ-cells, the fertilized ovum enters upon a cycle of repeated division. As the result of this process, known as *segmentation*, in which the new cells arise by mitotic division, a spherical mass of young cells, the *morula*, is produced. This mass, at first solid, soon acquires a central cavity filled with fluid and is converted into a hollow sphere, known as the *blastodermic vesicle*. The wall of this sac consists of a single layer of cells, except at one place where a small mass of cells is attached to the inner surface. The outer or covering layer of cells is the *trophoblast*; the group of cells attached to the inner surface of the trophoblast is the *inner cell-mass*. Corresponding to the position of the latter,

<sup>1</sup>The sizes of microscopic objects are usually expressed in thousandths of a millimeter, represented by the letter  $\mu$ ;  $1 \mu$  (micron) =  $0.001$  mm.

the surface of the blastodermic vesicle presents an opaque circular field, the *embryonic area*, so called from the fact that within this area the first traces of the future embryo appear.

In consequence of further growth and differentiation of the inner cell-mass, the latter gives rise to two sheets of cells, the *ectoderm* and the *entoderm*. The first of these is continuous with the trophoblast and, in conjunction with the latter, completes the outer layer of the blastodermic vesi-

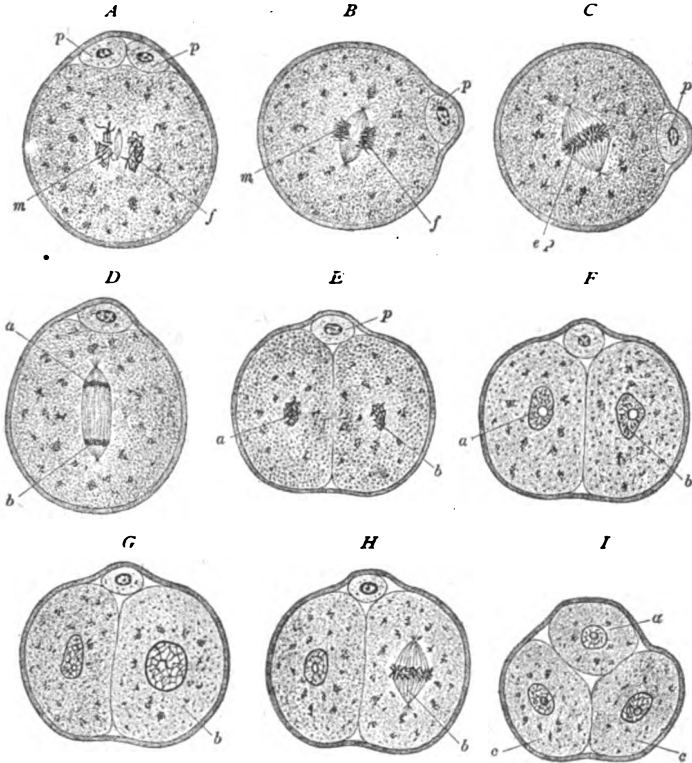


FIG. 10.—Early stages of segmentation as seen in sections of ova of mouse.  $\times 450$ . (Sobotta.) A-D show the rearrangement of the chromosomes contributed by the male (m) and female (f) germ-cells as preparatory to the first cleavage of the fertilized ovum; p, p, polar bodies; e, p, stage of equatorial plate; a, b, daughter groups of chromosomes. E, F, the daughter cells arising from first cleavage. G, one cell (b) is larger and is preparing to divide. H, later stage of this division. I, stage of three segmentation spheres (a and c, c) resulting from this division.

cle. The entoderm gradually expands until it forms a complete second layer within and concentric with the outer stratum of the blastodermic wall. Meanwhile a third layer of cells, the *mesoderm*, makes its appearance between the ectoderm and the entoderm and, in time, converts the wall of the blastodermic vesicle into a trilaminar envelope. The three cell-sheets derived from the inner cell-mass constitute the *blastodermic* or *germ-layers*—structures of great importance, since they supply the cells from which all parts of the embryo are developed. The histological characters of the outer and inner of these primary layers differ, almost from the first, from those of the mesoderm, their component elements being more compact in arrangement and early acquiring the characteristics of covering cells or epithelium.

The mesodermic elements, on the contrary, for the most part assume irregular forms and are loosely held together by intercellular substance, thus

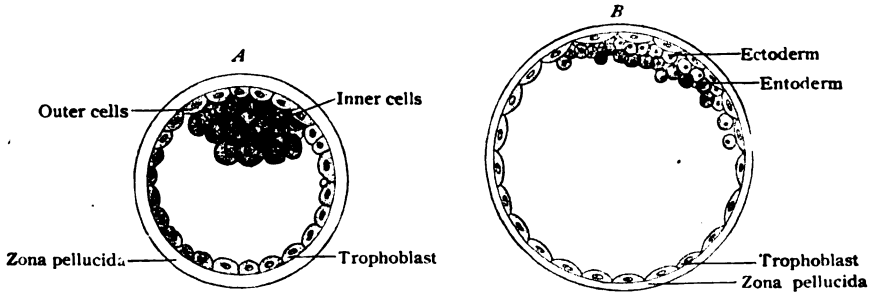


FIG. 11.—Diagrams of very early stages of the mammalian blastodermic vesicle; *A*, the vesicle consists of trophoblast and inner cell-mass; *B*, the inner cell-mass is differentiating into ectoderm and entoderm. (After van Beneden.)

foreshadowing the features which distinguish many of their derivatives as members of the connective tissue group.

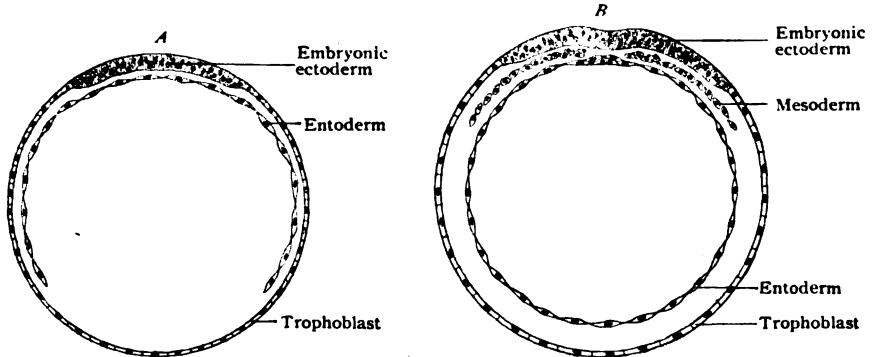


FIG. 12.—Diagrams of later stages of the mammalian blastodermic vesicle; *A*, the thickened embryonic ectoderm corresponds to the area in which the embryo will develop; *B*, the mesoderm is appearing as the third germ-layer between the ectoderm and the entoderm, the latter now forming a complete layer.

The mesoderm undergoes important modifications, splitting into two sheets, a *parietal* and a *visceral layer*, between which is included the primitive

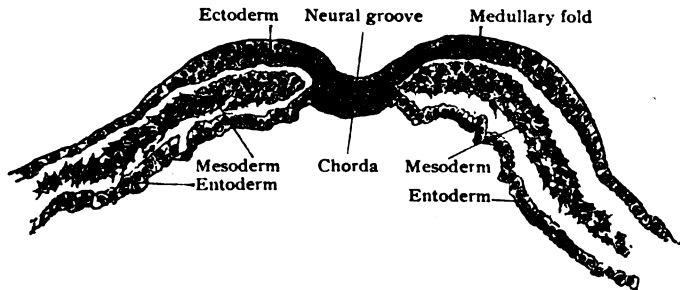


FIG. 13.—Transverse section of rabbit embryo of about eight and one-half days, showing the character of the early germ-layers; the future neural canal is represented by the widely open groove.  $\times 80$ .

body-cavity or *coelom*. Subsequently this space is subdivided into the great serous sacs of the body—the pericardial, the pleural and the peritoneal—



lined with the modified mesodermic elements, known as *mesothelium* (page 21). The cleavage of the middle germ-layer, however, does not involve the mesoderm in the immediate vicinity of the embryonic axis, since on each side of the latter there remains a tract of uncleft *paraxial mesoderm*, in which appears a series of quadrilateral areas, the *mesodermic somites*. These are important since they contribute the material giving rise to the vertebral column and the voluntary muscles.

The parietal layer of the mesoderm adheres to the ectoderm and, in conjunction with the latter, constitutes the *somatopleura*, the ecto-mesodermic sheet that forms the ventro-lateral walls of the body. In like manner, the visceral layer adheres to the entoderm and, with it, constitutes the *splanchnopleura*, whose folding-off establishes the digestive tube.

Since these primary layers give rise to all the tissues of the body, a synopsis of their genetic relations may be given; a word of caution, however, should be added against regarding these groups as too sharply defined, since a certain degree of transition must be recognized.

#### DERIVATIVES OF THE BLASTODERMIC LAYERS.

##### *From the ectoderm are derived:—*

- Epithelium of outer surface of the body, including that of the conjunctiva and anterior surface of the cornea, and of the external auditory canal, together with the epithelial appendages of the skin, as hairs, nails, sebaceous- and sweat-glands (including the involuntary muscle of the latter).
- Epithelium of the nasal fossa, with its glands, as well as the cavities connected therewith.
- Epithelium of the mouth and of the salivary and other glands opening into the oral cavity.
- Enamel of the teeth.
- Tissues of the nervous system.
- The retina; the crystalline lens and perhaps part of the vitreous humor and of the muscle of the iris.
- Epithelium lining the membranous labyrinth.
- Epithelium of the pituitary and pineal bodies.

##### *From the mesoderm are derived:—*

- Connective tissues, including areolar tissue, tendon, cartilage, bone and dentine.
- Muscular tissue, except that of the sweat-glands and the dilator pupillæ.
- Tissues of the vascular and lymphatic systems, including their endothelium and circulating cells.
- All parts of the sexual glands and their excretory passages, as far as the termination of the ejaculatory ducts and of the vagina.
- All parts of the kidney and ureter.

##### *From the entoderm are derived:—*

- Epithelium of the digestive tract, with that of all glandular appendages, except those portions of ectodermic origin at the beginning (oral cavity) and termination of the tube.
- Epithelium of the respiratory tract.
- Epithelium of the urinary bladder and of urethra (except part of male).
- Epithelium of thyroid, parathyroid and thymus bodies.

## THE ELEMENTARY TISSUES.

THE various parts and organs of the complex body may be resolved, in their structure, into four groups of *elementary tissues*—the *epithelial*, the *connective*, the *muscular* and the *nervous*. By the association and modification of two or more of these tissues the organs are made up and acquire the distinctive characteristics demanded by their function. A fifth group—the *vascular tissues*, including the blood-vessels and lymphatics with the contained blood and lymph—is sometimes added in view of the usual occurrence of these tissues as constituents of organs. Since, however, the vascular tissues are genetically related closely with the connective tissues and, where highly specialized, are themselves composite in structure, it seems more appropriate that they be not regarded as an independent group.

## THE EPITHELIAL TISSUES.

The epithelial tissues include, primarily, the sheet of protecting cells (epidermis) covering the exterior of the body and the epithelium lining the digestive tube. Secondarily, they constitute the derivations of the epidermis, as hairs, nails and glands of the skin, and the lining of the ducts and compartments of the glands connected with the digestive canal, as well as the lining of the respiratory tract, which originates as an evagination from the gut-tube. Further, epithelium forms the lining of the genito-urinary tract.

The primary purpose of the epithelium being to protect the delicate vascular and nervous structures lying within the subjacent connective tissue of the skin and of the mucous membranes, the epithelial cells are arranged as a continuous sheet, the individual elements being united by a very small amount of intercellular or cement substance.

Epithelium is devoid of blood-vessels, the necessary nutrition of the tissue being maintained by the absorption of nutritive juices which pass to the cells by way of the minute clefts within the intercellular substance. The distribution of nerve-fibres within epithelium ordinarily is scanty, although in localities possessing a high degree of sensibility, as the tactile surfaces or the cornea, the terminal nerve-filaments may lie between the epithelial elements. Frequently the epithelium is separated from the connective tissue upon which it rests by a delicate *basement membrane* or *membrana propria*. The latter usually appears as a linear subepithelial boundary, being often particularly well marked beneath the epithelium of glands.

Based on the predominating form of the component cells, the epithelial tissues are divided into two chief groups, *squamous* and *columnar*, each of which is subdivided into *simple* and *stratified*, according to the presence of a single or several layers of cells respectively. *Modified epithelium* includes cells which exhibit adaptation and specialization to meet particular uses; such are the ciliated, pigmented and glandular epithelia. Highly differentiated *neuro-epithelium* occurs in the perceptive apparatus concerned in the special senses, the gustatory cells of the taste-buds found on the tongue, the rod- and cone-cells of the retina and the auditory cells of Corti's organ being familiar examples.

**Squamous Epithelium.**—Where this variety of epithelial tissues occurs as a single layer, it consists of flattened polyhedral nucleated plates which, viewed from the surface, form a more or less regular mosaic. Hence

the terms "pavement" or "tessellated" are sometimes applied to this type of epithelium. Such arrangement of the squamous type, however, is unusual in the human body—the alveoli of the lungs, the posterior surface of the anterior capsule of the crystalline lens and the membranous labyrinth being the chief localities in which simple squamous epithelium is found.

The far more usual disposition of the squamous type of epithelium is as a number of superimposed layers, this constituting the important group of *stratified squamous epithelium*. Although the free surface of such struct-




FIG. 14.—Simple squamous epithelium from the anterior capsule of the crystalline lens.  $\times 360$ .

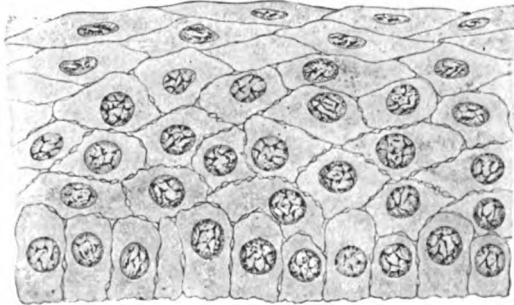


FIG. 15.—Stratified squamous epithelium from anterior surface of the cornea.  $\times 465$ .

ures presents the mosaic formed by the superficial plates, the entire tissue is by no means composed of flattened cells. When seen in section (Fig. 15), the deepest cells are not scaly, but irregularly columnar, resting on the basement membrane by slightly expanded bases. The surface of the underlying connective tissue is beset with minute elevations or papillæ, which serve as advantageous positions for the terminations of blood-vessels or of nerves. Owing to the more favored nutrition of the deepest stratum, the cells next the connective tissue possess the greatest vitality and are the source of the

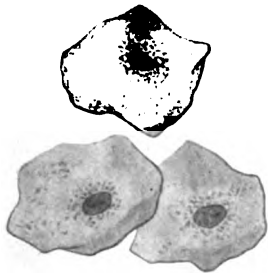


FIG. 16.—Isolated surface cells from epithelium lining the mouth.  $\times 320$ .

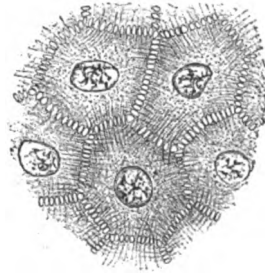


FIG. 17.—Epithelial cells from epidermis, showing intercellular bridges.  $\times 675$ .

new elements necessary to replace the old and effete cells which are continually being removed at the free surface. This loss is due not only to mechanical abrasion, but also to the displacement of the superficial elements by the new cells formed within the deeper layers.

Passing from the basement membrane towards the free surface, the form of the cells undergoes a radical change. The columnar type belongs exclusively to the deepest layer; the superimposed cells assume irregularly polyhedral forms and gradually expand parallel to the free surface, to become, finally, the large thin scales (Fig. 16) so characteristic of the super-

ficial layers of stratified squamous epithelium. The position of the nucleus also varies with the situation of the cells, since within those next the basement membrane the relatively large nucleus lies near the subjacent connective tissue, while within the cells of the middle and superficial strata the nucleus, comparatively small, is placed about the centre of the cell. The irregularly polyhedral cells of the deeper strata frequently are connected by delicate protoplasmic processes which bridge the intervening intercellular clefts (Fig. 17); when such elements are isolated, the delicate connecting

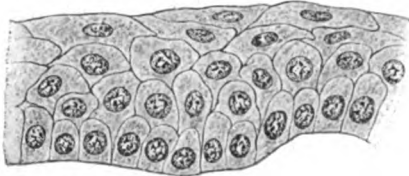


FIG. 18.—Transitional epithelium from the bladder.  $\times 300$ .

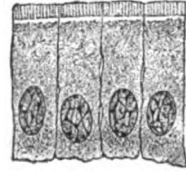

FIG. 19.—Simple columnar epithelium from intestinal mucosa.  $\times 750$ .

threads are broken and appear as minute spines besetting the so-called *prickle cells*. In certain localities, as in the urinary bladder, the columnar cells of the deepest layer rapidly assume the scaly character of the superficial elements. Such epithelium possesses relatively few layers and is often described as *transitional epithelium*, a modification of the stratified squamous variety.

**Columnar Epithelium.**—When consisting of a single layer of prismatic elements, the epithelium constitutes the *simple columnar* variety, which is much more widely distributed than the corresponding squamous group, the lining of the stomach and of the intestinal tube being important examples. When the single layer of cells is replaced by several, as in the *stratified columnar* epithelium, the superficial elements alone are typically columnar. The free ends of the prismatic cells frequently present cytoplasmic specializations in the form of a *cuticular border* or of *cilia*, while their ends which rest upon the basement membrane are pointed, club-shaped, or forked. The intervals formed by such irregular contours are occupied by the smaller cells of the deeper stratum. Each cell is provided with a

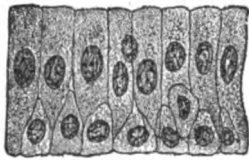


FIG. 20.—Stratified columnar epithelium from vas deferens.  $\times 500$ .

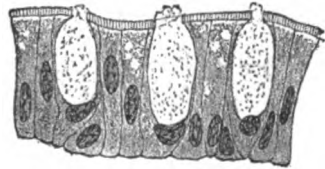


FIG. 21.—Goblet-cells from epithelium lining large intestine.  $\times 500$ .

nucleus, which is situated about the middle within the superficial elements and nearer the base within the deeper ones. The surface cells often contain collections of mucous secretion and, in consequence, become distended into conspicuous chalice forms known as *goblet-cells*. Such modified elements occur in great profusion within the epithelial lining of the large intestine and of the repository tract.

**Modified Epithelium.**—In order to meet particular work, beyond the mere function of protection, epithelial cells may undergo profound modification or high specialization. Thus, in order to produce a current favor-

able for the propulsion of mucus or secretions, the free surface of the epithelium in many localities, as in the trachea and bronchial tubes, the inferior and middle nasal meatuses and the oviducts and uterus, is provided with minute hair-like vibratile processes, or *cilia*. The exact relations of the cilia, specializations of the substance of the cell, to the cytoplasm are still uncertain, although it is probable that the hair-like processes attached to the free surface are connected with delicate intracellular fibrillæ within the superficial and more highly specialized parts of the cells. In man and the higher mammals ciliated epithelium is limited to the columnar variety. The number of cilia attached to each cell varies, but there are usually between one and two dozen such appendages. Their length, likewise, differs, those lining the epididymis being about ten times longer than those attached to the tracheal mucous membrane. Under favorable conditions, including a sufficient supply of moisture, oxygen and heat, ciliary motion may continue for many hours or even days after removal of the tissue.

The cytoplasm of epithelial cells often is invaded by particles of foreign substances; thus, granules of fatty and proteid matters are very common, while the presence of granules of keratohyalin in certain cells of the epidermis

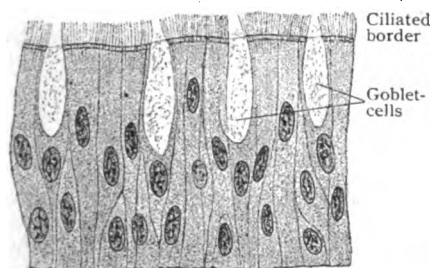


FIG. 22.—Stratified ciliated columnar epithelium from trachea.  $\times 500$ .

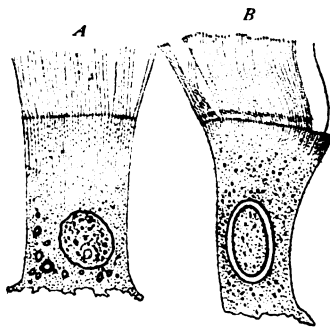


FIG. 23.—Ciliated epithelial cells. *A*, from intestine of a mollusk; *B*, from nasal mucosa of frog.  $\times 675$ . (Engelmann.)

characterizes the stratum granulosum. When the contained particles are colored, as when composed of melanin, the affected cells acquire a dark brown tint and are then known as *pigmented epithelium*. Examples of such cells are seen in the outer layer of the retina and in deep cells of the epidermis in certain races.

On surfaces clothed with columnar epithelium, many cells are distinguished by unusually clear cytoplasm and exceptional form and size. These are the *goblet-cells*, whose peculiar chalice form results from an accumulation of mucoid secretion elaborated within the cytoplasm of the cells. When distention becomes too great, the cell ruptures in the direction of least resistance and the secretion is poured out upon the surface of the mucous membrane as the lubricating mucus. The goblet-cells, therefore, may be regarded as unicellular glands and as representing the simplest phase in the temporary specialization of glandular tissue. When the epithelial elements become permanently modified to engage in the elaboration of secretions, they are recognized as *glandular epithelium*. The cells lining the ducts and the ultimate compartments of the glands are modified extensions of the epithelium covering the adjoining mucous membrane. Their form and condition depend upon the degree of specialization, varying from columnar to

spherical and polyhedral, in the one case, and upon the number and nature of the secretion particles in the other. The cells lining parts of certain glands, as those clothing the ducts of the salivary glands, or the convoluted portion of the uriniferous tubules, exhibit a more or less evident striation. Such cells constitute *rod epithelium*.




FIG. 24.—Pigmented epithelium from the human retina.  $\times 435$ .

The highest and most complex modifications of epithelial tissues are those occurring during the development of the structures designed to receive the stimulus giving rise to the special senses. The epithelium in these localities is differentiated into two groups of elements, the sustentacular and the perceptive; to the latter the name of *neuro-epithelium* is applied. Conspicuous examples of such specialized epithelium are the rod- and cone-cells of the retina and the auditory or hair-cells of Corti's organ in the internal ear.

A more detailed description of glandular epithelium is given in the chapter devoted to Mucous Membranes and Glands (page 119); the details of the neuro-epithelial structures are included under the appropriate Organs of Sense.

#### THE ENDOTHELIA.

This term, as here used, is applied to the modified mesodermic cells that cover serous surfaces and, therefore, includes the lining of the pericardial, pleural and peritoneal subdivisions of the body-cavity, together with the lining of the blood- and lymph-vessels and of the lymphatic spaces throughout the body. In principle, these spaces are intramesodermic clefts and the elements forming their lining are derivatives of the great connective tissue-producing germ-layer. The endothelia, therefore, are closely related to the connective tissues and, in a sense, may be regarded as modified elements of that class. In view of their arrangement as investing cell-sheets and other resemblances, they may be conveniently discussed in connection with the epithelial tissues; indeed by many histologists they are included among the epithelia.

The most striking difference in situation between the endothelia and the epithelia is the fact of the former covering surfaces not communicating with the atmosphere, while the epithelial tissues clothe mucous membranes, all of which are directly or indirectly continuous with the integumentary surface. A further contrast between these tissues is presented in their genetic relations with the germ-layers, since the epithelia, with the exception of those lining certain parts of the genito-urinary tracts which are derived from the mesoderm, are transformations and outgrowths from the ectoderm and ento-




FIG. 25.—Mesothelial cells from surface of omentum; intercellular cement-substance stained by argentic nitrate.  $\times 300$ .

derm, while the endothelia are direct modifications of mesodermic cells. The young mesodermic cells bordering the early body-cavity become differentiated into a delicate lining for this space, and later give rise to the plate-like elements which constitute the lining of the permanent serous sacs. The primary lining is known as the *mesothelium*, which name is often retained to designate the investment of the pericardial, pleural and peritoneal cavities, as distinguished from the endothelium which lines the vascular and other serous spaces.

As seen in typical preparations, obtained from the peritoneum after appropriate treatment with argentic nitrate, the endothelial cells on surface view appear as irregularly polygonal areas mapped out by deeply tinted lines (Fig. 25). The latter represent the silver-stained albuminous intercellular cement-substance, which joins the flattened cells in a manner similar to that seen in simple squamous epithelium. The lines of apposition are sinuous and less regular than those between epithelial cells, in many cases the lines appearing distinctly serrated. The form of the cells and the character of their contours, however, are not constant, since they are greatly influenced by the degree of tension to which the tissue has been subjected. Protoplasmic threads directly connecting the adjoining cells have been described.

After silver staining the intercellular substance frequently shows irregular, deeply colored areas at points where several endothelial cells come together. These figures are described as *stigmata* or *pseudostomata* and by some are interpreted as indications of the existence of minute openings leading from the serous cavity into the subjacent lymphatics. They are, however, largely accidental and due to dense local accumulations of the stained intercellular materials. True orifices, or *stomata*, on the other hand, undoubtedly exist in certain serous membranes, as in the septum between the peritoneal cavity and the abdominal lymph-sac of the frog and, probably, the peritoneal surface of the diaphragm of mammals. The positions of these stomata are marked by a conspicuous modification in the form and arrangement of the surrounding endothelial plates, which are radially disposed about centres occupied by the stomata. The immediate walls of the orifices are formed by smaller and more granular elements, the *guard-cells*, the contraction and expansion of which probably modify the size of the openings.

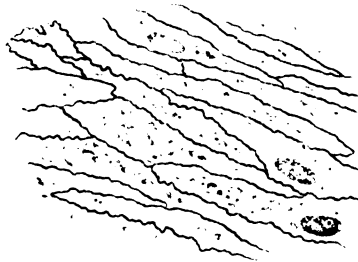


FIG. 26.—Endothelial cells lining artery of dog; stained with silver and hematoxylin.  $\times 450$ .

## THE CONNECTIVE TISSUES.

The important group of connective substances, the most widely distributed of all tissues, is the direct product of the middle germ-layer. Since the latter is also the origin of epithelial, muscular, vascular and lymphoid tissues, that portion of the mesoderm especially concerned in producing the connective tissues has been designated the *mesenchyma*. Their essential rôle, connection and support, being largely passive and mechanical, the physical characteristics of these tissues are of much importance. These depend upon the intercellular substance, which, in marked contrast to the meagre cement-substance of the epithelia, is very large in amount and contributes the chief bulk of the tissue.

During the period of embryonal growth the intercellular substance is semifluid, gelatinous and plastic; a little later, as growing connective tissue, it is still soft, although more definitely formed; while, as the adult areolar tissue, it becomes tough and yielding. Grouped as masses in which fibrous tissue predominates, the intercellular substance acquires the toughness and inextensibility of tendon; where, on the contrary, large quantities of elastic tissue are present, as in certain ligaments, extensibility is conspicuous. Further condensation of the intercellular substance produces the resistance encountered in hyaline cartilage, intermediate degrees of condensation being presented by the fibrous and elastic varieties. In those cases in which the ground-substance becomes impregnated with calcareous salts, the hardness of bone or of dentine results. Notwithstanding these variations in the density and physical properties of the intercellular substance, the cellular

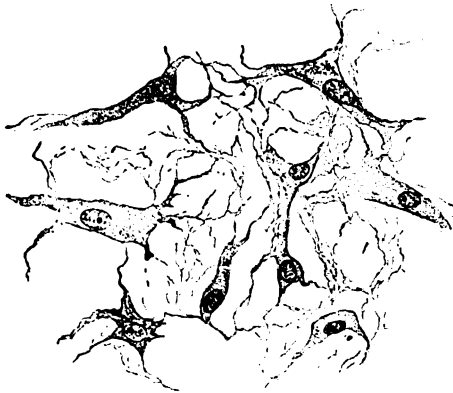

FIG. 27.—Mucous tissue from section of very young umbilical cord.  $\times 350$ .

elements have undergone little radical change, the connective tissue-corpuscle, the tendon-cell, the cartilage-cell and the bone-corpuscle being essentially identical.

The principal forms in which connective tissue occurs are: (1) *Mucous Tissue*, (2) *Reticular Tissue*, (3) *Fibrous Tissue*—loose and dense, (4) *Adipose Tissue*, (5) *Cartilage* and (6) *Bone*.

**Mucous Tissue.**—This form of connective substance is the most immature, being in fact the embryonal type, and closely resembles the parent tissue, the mesenchyma. As seen in sections of the embryo or of the early umbilical cord, it consists of a delicate protoplasmic network containing a semifluid intercellular substance. The network is formed by the union of the processes of irregularly branched stellate or fusiform cells, whose oval nuclei are embedded in plate-like masses of faintly granular cytoplasm. The intercellular ground-substance is semifluid and, depending upon the stage of development, either structureless or traversed by indistinct fibrillæ. The latter owe their origin to the cells and are produced by differentiation of the cytoplasm. Being essentially embryonal tissue, in the higher animals the mucous variety of connective tissue is limited to the earlier stages of development, the so-called *jelly of Wharton* in the young embryo being a striking example. Among the invertebrates, on the other hand, mucous tissue is formed in the adult animal. Certain pathological growths, known as myxoma, exhibit a similar arrangement of cells and yield mucus. The latter substance, produced also by glandular epithelium, contains true mucins—a group of complex proteid substances.

**Reticular Tissue.**—This variety of connective tissue differs from the mucous in retaining only a very meagre amount of intercellular substance and consists, therefore, chiefly—in some instances almost exclusively—of a network of connective tissue cells, the meshes of which are occupied by fluid and the lymphoid elements which the reticulum supports. The cells are flat and stellate and rest upon the surface of the strands of intercellular sub-



stance. Where the latter is best developed, it is composed of delicate fibres which resemble those of fibrous connective tissue. The reticular fibres probably differ somewhat from the white fibres of connective tissue in chemical composition, containing a variety of gelatin known as *reticulin*. Reticular tissue occurs principally as the supporting framework of lymphoid tissue, hence is well seen in suitably prepared sections of the lymph-nodes and of the spleen. It is also found in the mucous membrane of the intestinal tract, while the reticulum of bone-marrow and the interstitial tissue of certain organs, as the kidneys and liver, contain it.

**Fibrous Tissue.**—Under this head are included the more usual forms of connective tissue which have representation in, practically, all parts of the body. They exhibit a wide range of variation in their physical properties which depend upon differences in the intercellular substance, due to modifications in the arrangement and proportions of its constituents. Before considering the several varieties of fibrous connective tissue, loose and dense, the histological components common to all these tissues claim attention. These components are the *cells* and the *fibres*.

**Connective Tissue Cells.**—Although the more active constituent of the connective tissue, it is only in the youngest and immature stages that the cells are conspicuous; later, after the tissue has acquired its definite characteristics, the intercellular substance has usually become so predominant, that the cells are reduced to inconspicuous elements, notwithstanding their important rôle as nutritive and reproductive centres. The irregularly branched or stellate types of the parent mesenchymal cells are retained ordinarily only during the earlier periods of growth, the connective tissue cells decreasing in size and prominence as the intercellular substance increases in amount and differentiates into definite bundles of fibres. In the adult tissues, with few exceptions, the cells appear as small fusiform or flattened elements, in which the deeply staining oval nucleus, surrounded by a small amount of cytoplasm, serves as the chief means of detection. Being thicker than the cell-body, the nucleus projects beyond the general level of the cell and, viewed in profile, appears as a colored linear elevation embedded in a plate of faintly tinged cytoplasm. Since the cells depend for their nutrition on the tissue-juices which occupy the clefts or *lymph-spaces*

between the bundles of fibres, the relation of the connective tissue cells to these bundles is constant and characteristic for, wherever definite bundles are present, the cells are applied to the surface of the fasciculi. Where the latter are closely packed, the juice-channels form a system of intercommunicating spaces or canals, well seen in the cornea after staining with argentic nitrate, when they appear as light, irregularly stellate figures

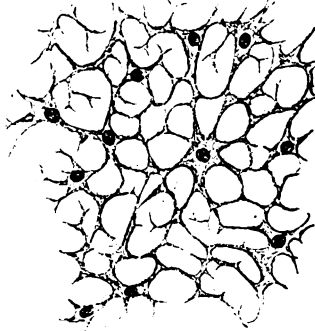


FIG. 28.—Reticular tissue from lymph-node.  $\times 300$ .

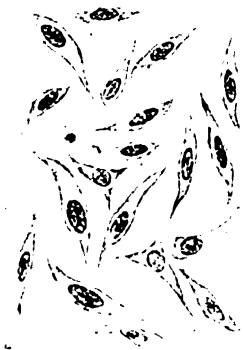

FIG. 29.—Young connective tissue cells from subcutaneous tissue of cat embryo.  $\times 590$ .

(Fig. 30), in which are lodged the connective tissue cells, applied to the wall formed by the dense fibrous tissue. In principle, the same arrangement holds good for cartilage and bone, since in these tissues the cells lie within the lacunæ. The larger branched connective tissue cells sometimes, as when

subjected to thermal, chemical or electrical stimulus, exhibit changes in form, possessing the power of retracting their processes and displaying feeble amœboid movement.

In a few localities in man—the choroid, the iris, the sclera, the dermis and the pia mater—but widely distributed in the lower vertebrates, the branched connective tissue elements often contain dark particles of melanin and, therefore, appear as conspicuous irregular figures shading from brown to black. Such elements are usually spoken of as *pigment-cells*, being, of course, only connective tissue cells modified by the

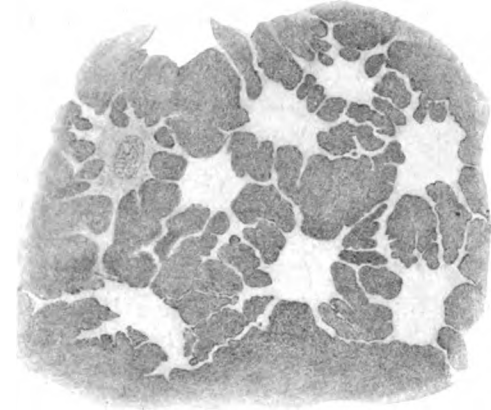


FIG. 30.—Lymph-spaces within dense connective tissue, from cornea of calf; the surrounding ground-substance has been stained with argentic nitrate.  $\times 500$ .

invasion of the colored foreign material. Since this invasion is limited to the cytoplasm, the unaffected nucleus appears as a small light oval area in the midst of the dark figure (Fig. 32). In the amphibians a favorite situation of pigmented cells is the immediate vicinity of blood-vessels, and it is probable that at times the connective tissue cells, as well as leucocytes, may take up colored particles derived from the blood. In addition to the melanin series and the hemoglobin derivatives, a third group of pigments, the *lipochromes*, is derived from fat. A very common modification of the connective tissue element is the appearance of droplets of oil within its cytoplasm. When such invasion becomes extensive, the element becomes a *fat-cell* and a constituent of adipose tissue. Further consideration of the fat-cells will be deferred until adipose tissue is described (page 29).

In addition to the characteristic connective tissue cells and their modifications containing pigment and fat, a variable number of *free cells* are encountered in the less dense forms of fibrous tissue. Much uncertainty exists as to the nature and source of some of these elements, and consequently it is impossible to state definitely their relations. The most constant of these free cells are the *migratory lymphocytes*, which escape from the blood-vessels into the interfascicular clefts. Being unattached to the fibres, they change their position within the tissue and, hence,

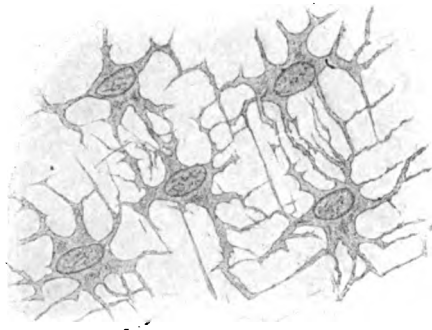


FIG. 31.—Connective tissue cells, from cornea of calf, which occupy spaces similar to those shown in preceding figure.  $\times 575$ .

are often designated "wandering cells" as distinguished from "fixed cells," as the connective tissue elements proper are then termed. The lymphocytes exhibit the usual characteristics of their class (see Blood, page 97) and appear as small irregular cells in which the spherical deeply stained nucleus is surrounded by a narrow zone of cytoplasm. Occasionally larger elements, the *plasma-cells*, are seen, especially in the vicinity of the blood-channels. They are probably derived from the lymphocytes, but differ from these in their much larger size, greater amount of readily staining cytoplasm, and markedly eccentric nucleus. Their cytoplasm stains deeply with basic dyes and contains but few and indistinct granules. Two other forms of free cells, the *mast-cells* and the *eosinophiles*, are conspicuous by reason of the coarse granules with which their cytoplasm is laden. The *mast-cells* are irregularly round or oval in shape and possess an oval nucleus (Fig. 33). The coarse granules are deeply colored by basic dyes but prone to change. The *eosinophiles* are



FIG. 32.—Pigmented connective tissue cells from choroid.  $\times 400$ .



FIG. 33.—Mast-cells from submucous tissue of mouth; *v.*, blood-vessels.  $\times 825$ .

distinguished by large granules which, while staining with acid dyes, possess an especial affinity for eosin, after the action of which they appear copper-red. Under the name, *clasmatocytes*, have been described irregular branched cells with long processes and scattered coarse granules. These elements are, perhaps, modifications of the mast-cells, which they resemble in granulation and staining reactions.

*Connective Tissue Fibres.*—The intercellular substance of fibrous connective tissue includes two varieties of fibrillar constituents, the *white fibres* and the *elastic fibres*. Both of these probably arise by the differentiation of the more peripheral part (exoplasm) of the cell-body of the young connective tissue cells, which in the earliest stages are united in a common cytoplasmic reticulum or *syncytium*. To the agency of the cells, then, must be ascribed the production of the fibrous intercellular substance.

The **white fibres** are grouped in more or less definite bundles, which, as seen in the usual teased preparations of areolar tissue, exhibit a wavy longitudinal striation. This marking is due to the apposition of the individual fibrillæ, which are so thin as to have no appreciable width. In the denser forms of fibrous tissue, as in tendon, the white fibres are assembled in robust fasciculi with great regularity and so closely packed and luted together by cement-substance that all trace of the individual fibrillæ is lost, the bundle appearing homogeneous, unless some means is taken to dissociate its component fibrils. White fibres yield gelatin on boiling with water, and consist chemically of an albuminoid substance termed *collagen*. They are not digested by pancreatin and on the addition of acetic acid become swollen and transparent and, finally, invisible.

The **elastic fibres** usually occur as networks of highly refracting homogeneous fibrils which lie among the bundles of white fibres. The individual fibres are much thicker than the white ones and, although differing in width, maintain a constant diameter until augmented by fusion with other elastic

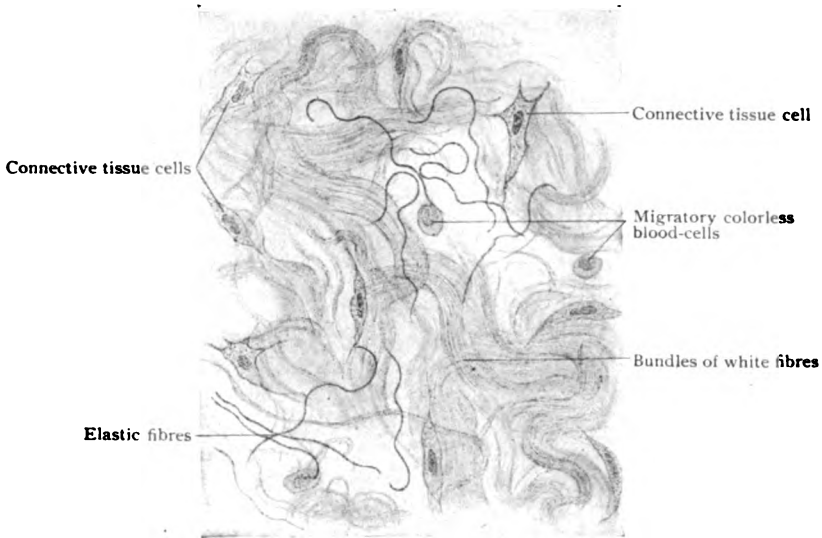

FIG. 34.—Section of subcutaneous tissue, showing constituents of areolar tissue.  $\times 300$ .

fibres. So long as the tissue in which they lie maintains its normal tension, the elastic fibres remain taut and approximately straight, but when dissociated, as in teased preparations, they assume a characteristic form and become wavy, bowed or coiled. The proportion of elastic fibres in fibrous connective tissue is, ordinarily, small, conferring only a moderate degree of elasticity. In certain localities, however, as in the ligamenta flava of man and the nuchal




FIG. 35.—Portions of isolated elastic fibres from ligamentum nuchæ of ox.  $\times 375$ .

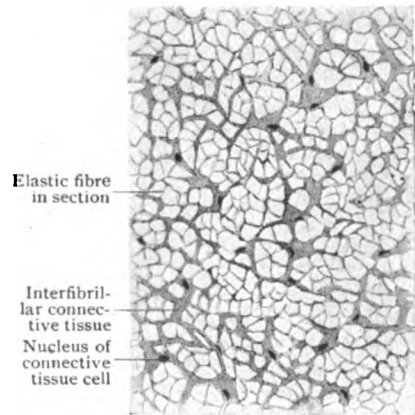


FIG. 36.—Transverse section of ligamentum nuchæ of ox.  $\times 450$ .

ligament of the lower mammals, almost the entire structure is made up of robust elastic fibres, held together by a small amount of intervening white fibres. In transverse sections of such ligaments (Fig. 36), the individual

elastic fibres appear as minute polygonal areas, separated by the white fibres and the associated connective tissue cells. Where, on the other hand, elasticity would be disadvantageous, as in tendons and aponeuroses, very few elastic fibres are present, the dense fibrous structures being composed practically of white fibres alone. Within the walls of the large blood-vessels, the broad ribbon-like elastic fibres are fused into membranous tracts, which contain numerous openings of various size (Fig. 37) and are, therefore, known as *fenestrated membranes*. Elastic fibres withstand dilute acids and alkalis, consequently becoming more evident in tissue treated with acetic acid in which the white fibres disappear. In their chemical composition they differ from the white fibres, yielding *elastin* and not gelatin on boiling and disappearing upon being subjected to pancreatic digestion. Likewise, in their staining reactions elastic fibres differ from the white; by taking advantage of the affinity which the former possess for certain dyes, as orcein, a much wider and more generous distribution of elastic tissue has been established than was formerly appreciated.




FIG. 37.—Fragment of fenestrated membrane from large artery; surface view.  $\times 510$ .

**Loose fibrous or areolar tissue** occurs throughout the body wherever the opposed parts although connected enjoy considerable mobility. Familiar examples are the sheets or tracts of yielding connective tissue, which lie between the skin and underlying fascia or beneath mucous membranes, that unite the muscles and assist in keeping the viscera in place. The variable bundles of white fibres are loosely and irregularly disposed, crossing in all directions and enclosing correspondingly indefinite lymphatic clefts. The elastic fibres form a network of highly refracting threads which, in sections and teased preparations, are more or less wavy and curled. The cellular constituents of the tissue are relatively inconspicuous, but here and there the connective tissue cells are seen as spindle-shaped or irregular plate-like bodies applied to the surface of the fibrous bundles. They are bathed by the tissue-juices that well through the interfascicular spaces within which clefts are also lodged the migratory lymphocytes and other forms of free cells.

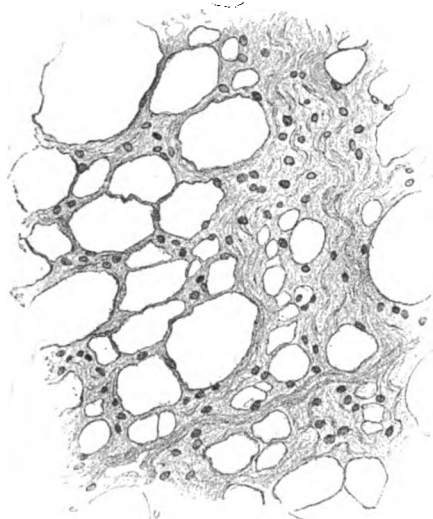


FIG. 38.—Portion of omentum, showing fibro-elastic tissue arranged as a fenestrated membrane; the nuclei belong to the connective tissue and surface endothelial cells.  $\times 120$ .

**Dense fibrous tissue** owes its characteristics to the more compact and orderly arrangement of the bundles of white fibres. Although the individual fibres are no thicker than in the areolar tissue, they are grouped into larger bundles and held more closely together by the inter-fibrillar cement or *ground-substance*. The bundles are disposed with greater regularity, either as closely packed parallel fasciculi, as in ligaments, tendon and aponeuroses, or as intimately felted bands forming fibrous sheets, as in

fasciæ, the cornea and the dura mater. In the dense connective tissue the ground-substance often contains a system of definite interfascicular lymph-spaces, which, in suitably stained preparations, appear as irregularly stellate clefts (Fig. 30) that form, by union of their ramifications, a network of channels for the conveyance of the tissue-juices throughout the dense structure. Where definite, as in the cornea or central tendon of the diaphragm, these spaces are almost, if not completely, filled by the stellate connective tissue cells which they enclose. A somewhat similar, although modified relation, is to be noted in the bursæ, tendon-sheaths and smaller joint-cavities, in which the free inner surface is often clothed by an incomplete covering of branched or plate-like connective tissue cells.

**Tendon**, the densest form of fibrous tissue, consists essentially of parallel bundles of white fibres. The individual fibres, held together by cement substance, are assembled as comparatively large *primary bundles* which, in




FIG. 39.—Longitudinal section of tendon from young subject; the tendon-cells are seen in profile between the bundles of fibrous tissue.  $\times 300$ .

Blood-vessel within septa  
enclosing tertiary bundles

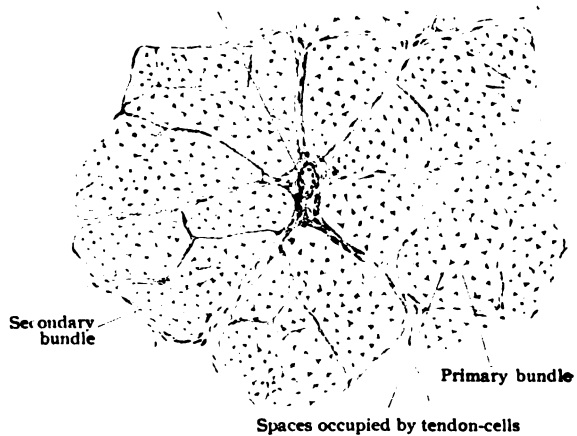


FIG. 40.—Transverse section of a tendon, showing the grouping of the tendon-tissue into primary, secondary and tertiary bundles.  $\times 80$ .

turn, are united by the interfascicular ground-substance and grouped into *secondary bundles*. The latter, invested by a delicate sheath of areolar tissue and partially covered by plate-like connective tissue cells, are held together by partitions or septa of areolar tissue which are extensions of the general connective tissue envelope that surrounds the entire tendon. The larger septa surrounding the *tertiary bundles* support the meagre blood-vessels and nerves and afford a path by which these gain the interior of the tendon. The blood-vessels, however, never penetrate the individual bundles, but are confined to the areolar tissue which invests them. The relations of the nerves to the tendon-tissue are described with the Nerve-Endings (page 85). The primary bundles consist exclusively of white fibres and the cement-substance, which contain collagen and tendo-mucoid respectively. A few delicate elastic fibres are sometimes distinguishable in the vicinity of the tendon-cells. The latter are the equivalents of the usual connective tissue cells, but so modified by the disposition of the bundles to which they conform that they assume distinctive shapes. The *tendon-cells* occur in rows within the clefts between the primary bundles, upon the surface

of which the thin plate-like bodies are applied. Since each cell is in close contact with two or three bundles, the cytoplasm is moulded by the bundles into wing-like expansions. Seen from the surface, the tendon-cells appear as small rectangular elements, whose round nuclei are disposed in pairs, the nucleus of one cell lying close to that of its neighbor. Viewed in longitudinal profile, the tendon-cells appear as nar-

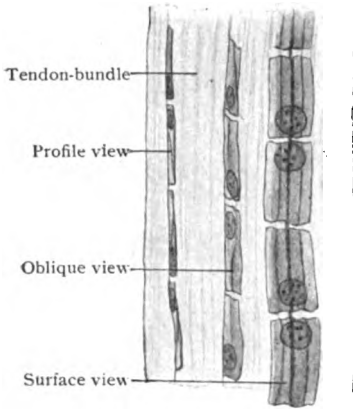


FIG. 41.—Tendon-bundles from tail of mouse, showing different views of the tendon-cells.  $\times 300$ .



FIG. 42.—Transverse section of tendon-bundles (*b*), the interfascicular spaces (*s*) contain the tendon-cells (*a*) applied to the surface of the bundles.  $\times 300$ .

row rods, while when seen in transverse section, they present as stellate figures, the extended limbs of which are the sections of the wing-plates.

## ADIPOSE TISSUE.

The fatty material contained within the body is enclosed, to a large extent, within connective tissue cells in various localities. These modified elements are known as *fat-cells*, which, together with the areolar tissue connecting the cells and supporting the fair supply of blood-vessels, constitute adipose tissue.

The distribution of adipose tissue includes almost all parts of the body. Among the localities in which the accumulations of fat are conspicuous, are the subcutaneous areolar tissue, the orbits, the marrow of bones, the mesentery and the omentum, the subperitoneal tissue and the subpericardial tissue of the heart, the areolar tissue surrounding the kidneys, and the vicinity of the joints. On the other hand, in a few situations, including the subcutaneous areolar tissue of the eyelids, the penis, the clitoris and labia minora, the lungs, except near their roots, and the interior of the cranium, adipose tissue is absent, even when developed to excess in other parts. As ordinarily seen, adipose tissue is of a light straw color and often exhibits a granular texture due to the groups of fat-cells within the supporting areolar tissue.

Examined microscopically in preparations from localities where they are not crowded and retain their individual form, the fat-cells appear as large clear spherical sacs held together by delicate areolar tissue. Unless treated with some stain possessing an especial affinity for fat, as osmic acid or Sudan III, the oily content of the cells appears transparent and uncolored and seemingly occupies the entire cell-body. Critical examination, however, demonstrates the presence of an extremely thin peripheral layer of cytoplasm, which completely surrounds the huge oil-drops and at one place presents a local accumulation enclosing the displaced and compressed

nucleus. In thin sections of adipose tissue, by no means every fat-cell exhibits a nucleus, since, owing to the small size of the latter in comparison with the diameter of the cell, many sections include zones lying beyond the

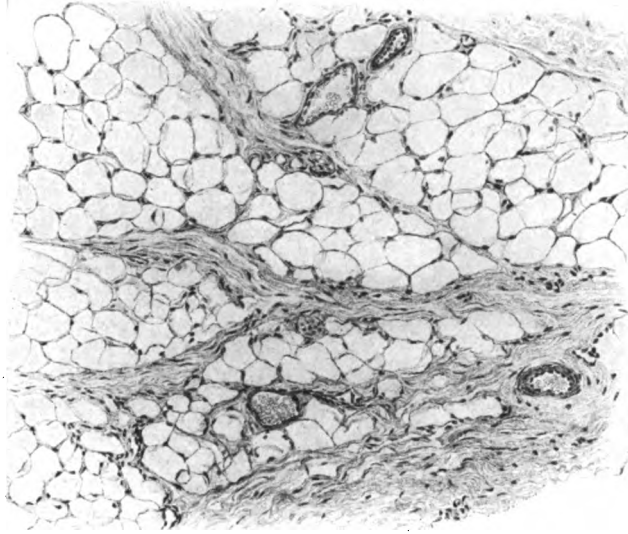


FIG. 43.—Portion of omentum, showing groups of fat-cells between the bundles of connective tissue.  $\times 150$ .

nucleus. During life the fat within the body is fluid. Quite often radiating clusters of slender *fat-crystals* are observed within the adipose cells. These are margaric crystals that formed when the fat solidified after death.

Fat-cells occur usually in groups supported and held together by highly vascular connective tissue. In localities possessing considerable masses of fat, as beneath the scalp and the skin, the cells are grouped into lobules which appear as yellow granules to the unaided eye; in such positions the

individual fat-cells lose their spherical shape and assume a polyhedral form as the result of the mutual pressure of the closely packed vesicles.

In connective tissue elements about to become fat-cells, minute isolated oil-drops first appear within the cytoplasm in the vicinity of the nucleus. These droplets increase in size and number, coalesce and gradually encroach upon the cytoplasm until the latter is reduced to a thin, almost inappreciable envelope, which completely in-

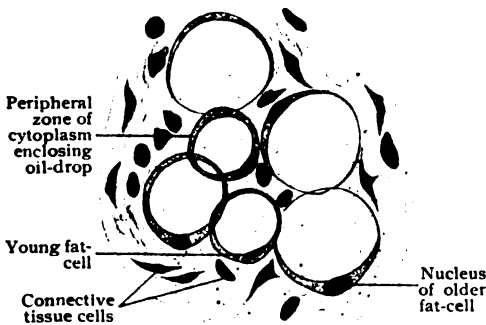


FIG. 44.—Young fat-cells from subcutaneous tissue.  $\times 500$ .

vests the now huge distending oil-drops. The nucleus, likewise, is displaced towards the periphery, where it appears in profile as an inconspicuous crescent embedded within the cytoplasm (Fig. 44). When the invasion of the



cell is extensive, the nucleus may contain minute oil-globules. Although many connective tissue elements become transformed into fat-cells at later periods, the earliest adipose tissue in some localities, as beneath the skin and in the orbit and omentum, is developed from highly vascularized lobular groups of mesenchymal cells (the *fat organs* of Toldt) which seem to be set apart for the production of such tissue. During prolonged fasting and extreme emaciation the fat-cells may lose the greater part, or even their entire quota, of oily contents, which is then often replaced by a thin viscid cytoplasm that distinguishes the so-called *serous fat-cells*. In other cases, after the disappearance of the oil-drops the fat-cells return to a condition closely resembling that of the ordinary connective tissue cell.

## CARTILAGE.

Cartilage includes a group of supporting tissues in which the intercellular substance undergoes increasing condensation until, as the hyaline variety, the intercellular matrix appears homogeneous, the constituent fibres being so compact and closely blended that the fibrous structure is ordinarily no longer appreciable.

Depending upon the differences exhibited by the intercellular matrix, three varieties of cartilage are recognized, *hyaline*, *fibrous* and *elastic*.

**Hyaline cartilage**, or gristle (Fig. 45), is widely distributed, forming the articular surfaces of the bones, the costal cartilages, the larger cartilages of the larynx and the cartilaginous plates of the trachea and bronchi, the larger cartilages of the nose and the middle part of the Eustachian tube. In the embryo the entire skeleton, with the exception of part of the skull, is mapped out by primary hyaline cartilage.

The intercellular *matrix* is apparently homogeneous, but after appropriate treatment it is resolvable into bundles of white fibres; ordinarily, however, these are so closely united and blended by the cementing ground-substance that the presence of the component fibres is not evident. The cartilage-matrix is chemically complex, consisting of a mixture of collagen, chondro-mucoid and albuminoid substances.

The *cartilage-cells*, as the connective tissue elements within the matrix are called, are irregularly oval or spherical nucleated bodies. They are lodged within the interfascicular spaces, or *lacunæ*, which they almost or quite fill. In adult tissue usually two or more cells share the same compart-

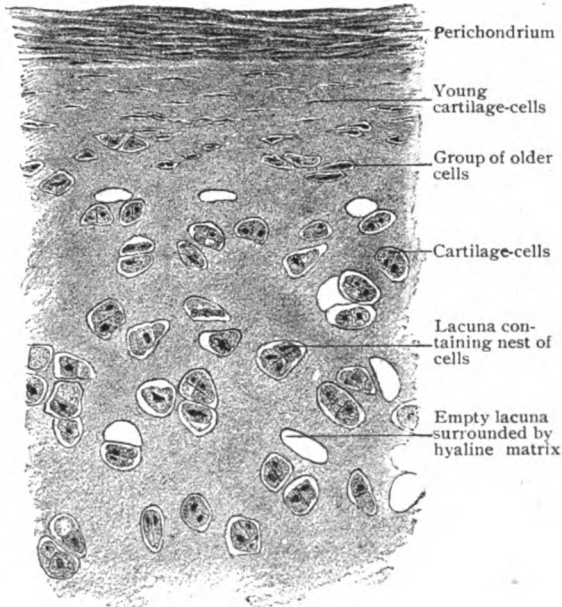


FIG. 45.—Transverse section of peripheral portion of costal cartilage.  $\times 250$ .

ment, the group being the descendants of the original occupant of the space. The matrix immediately surrounding the lacunæ is specialized as a layer of different density, which is described as a *capsule*; a further differentiation of the intercellular substance is often exhibited by the more recently formed matrix, which often stains with intensity and thereby produces the local territories known as the *cell-areas*. The lacunæ of hyaline cartilage are homologous with the lymph-spaces of other dense connective tissues, although channels establishing communication between the adjacent lacunæ are not demonstrable in the higher vertebrates.

The free surface of cartilage is covered by an envelope of dense connective tissue, the *perichondrium*. The latter consists of a compact external *fibrous layer* and a looser inner or *chondrogenetic layer*, containing many connective tissue cells. These elements are disposed in rows parallel to the surface, of the cartilage, and during the peripheral growth of the tissue, gradually assume the characteristics of cartilage cells, being at first spindle-shaped and later ovoid and spherical. The young cartilage cells thus formed become gradually separated by increasing tracts of the newly deposited intercellular matrix. As the groups of cells arising from the division of the transformed elements recede from the perichondrial surface, they lose their parallel disposition and become irregularly arranged and further separated. In addition to the *perichondrial growth* at the surface, cartilage also increases by *interstitial growth* effected by the formation of new cells and the associated matrix in the interior of the cartilage. The interstitial method is identified with the expansion of the primary cartilages, while the perichondrial one is conspicuous in bringing about the additions of new cartilage during the development and growth of the long bones.

In articular cartilage the superficial zone contains sparsely distributed groups of small cells arranged parallel to the free surface. Within the deeper strata, these groups are replaced by elongated rows of larger elements lying perpendicular to the articular surface. This columnar disposition of the cartilage-cells is particularly evident towards the underlying epiphyseal bone.

In parts of the cartilage remote from the perichondrium, the matrix sometimes exhibits a glistening fibrous structure; more often patches of opacity and granularity, due to deposits of lime-salts, affect the hyaline matrix. Such *areas of calcification* are common in the tissues, as the costal cartilages, of aged subjects, although similar changes are almost always present in the laryngeal cartilages, particularly the thyroid and the cricoid, as early as the twentieth year. They may progress until complete calcification of the cartilage occurs. Histologically this alteration consists of a deposit of the inorganic material within the matrix and is not osseous tissue, as implied by the frequently misapplied term, "ossification."

The *blood-vessels* of cartilage are usually limited to the periphery, within the perichondrium or the associated synovial membranes. Nutrition of the cartilage is maintained by imbibition of the tissue-juices through the matrix into the lacunæ. In the thicker masses, as in the cartilages of the ribs, nutrient canals exist in those portions most remote from the perichondrium. Such spaces contain a small amount of areolar tissue supporting the blood-vessels; the latter, however, are limited to the canals and the nutrition of the cartilage-tissue is effected here, as elsewhere, by absorption through the matrix. The *lymphatics* are sparingly present in the perichondrium. *Nerves* never have been demonstrated within the cartilages, which fact is in accord with the insensibility of these tissues and their adaptation to the friction, concussion and compressions incident to their functions.

**Elastic cartilage**, called also *yellow elastic* and *reticular* cartilage (Fig. 46), has a limited distribution, occurring principally in the cartilages of the external ear, lower part of the Eustachian tube, and in parts of the larynx, namely, the epiglottis, the cuneiform and corniculate cartilages and the vocal processes of the arytenoid cartilages. In its physical properties this variety differs from hyaline cartilage, as it is dull yellowish in color and pliable and tough in consistence, in contrast to the bluish opalescent tint and comparative brittleness of hyaline cartilage.

The characteristic histological feature of elastic cartilage is the presence of elastic fibres within the intercellular matrix. The lacunæ containing the cartilage-cells are immediately surrounded by limited areas of hyaline matrix, the so-called "capsules" of some authors.

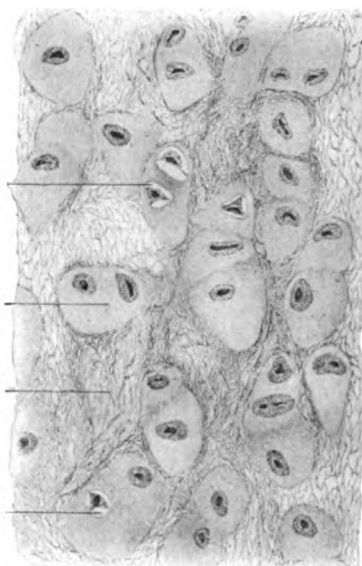


FIG. 46.—Section of elastic cartilage from the epiglottis.  $\times 360$ .

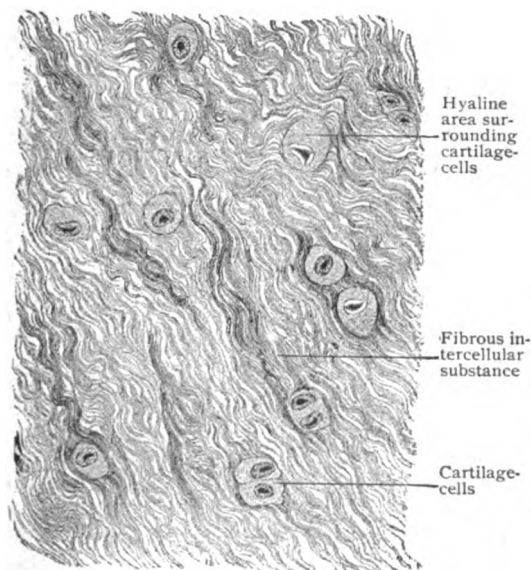


FIG. 47.—Section of fibrous cartilage from intervertebral disk.  $\times 225$ .

The matrix between these homogeneous areas, however, is penetrated by delicate and often intricate networks of elastic fibres. The latter respond, as in other localities, to specific stains. The method by which the elastic fibres develop is uncertain, although their production must be attributed to the influence of the cells. Since the fibres appear relatively late and within the matrix often at some distance from the cartilage-cells, it is probable that they do not arise within the exoplasm of the cells. The elastic cartilages are surrounded by a perichondrium of the usual description.

**Fibrous cartilage**, or *fibrocartilage* (Fig. 47), is found in comparatively few localities, although it occurs in masses of considerable bulk. Its chief situations are the intervertebral disks, the

symphyses, the marginal plates and interarticular disks of certain joints, the sesamoid cartilages and the lining of bony grooves for tendons. In its physical properties, this tissue combines the flexibility and toughness of fibrous tissue with the firmness and elasticity of cartilage. In structure, fibrous cartilage resembles dense fibrous connective tissue, since the principal constituents of its matrix are the wavy bundles of closely packed white fibres. Between these bundles lie small irregularly distributed oval areas of hyaline matrix (the so-called "capsules"), which immediately surround the cartilage-cells, singly or in groups. The number of cells and the proportion of fibrous matrix differ in various localities. A distinct perichondrium is wanting.

### BONE.

Bone or osseous tissue is a dense form of connective tissue, the matrix of which is impregnated with lime-salts; to this modification, shared by the dentine of the teeth, is due the characteristic hardness of the tissue. In

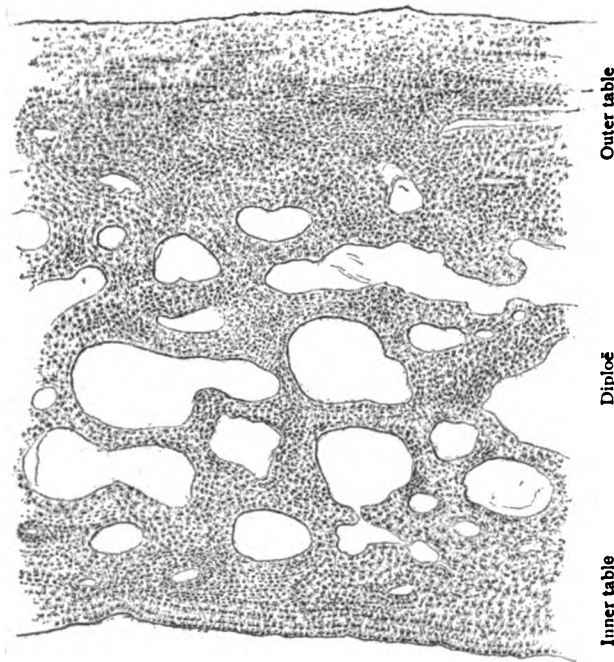


FIG. 48.—Section of frontal bone, showing the spongy bone enclosed within the lamellated compact bone; the latter, however, does not contain Haversian systems.  $\times 18$ .

addition to forming the bones of the principal, and in man the only, framework, or *endoskeleton*, osseous tissue occurs in the lower vertebrates associated with the integument as an *exoskeleton*, represented by the dermal plates of the crocodile or the shell of the turtle. Within various organs, as the sclerotic coat of the eye of birds, the diaphragm of the camel, the tongue of certain birds or the snout of the hog, it constitutes the *splanchnoskeleton*. True osseous tissue does not occur outside the vertebrates, the skeletal frameworks of invertebrate animals consisting of calcareous incrustations or of silicious structures.

Bone consists of two parts, an animal and an earthy portion, the former giving toughness and the latter hardness to the osseous tissue. The animal or organic part of bone may be removed by calcination, the inorganic constituents remaining undisturbed. After such treatment, while retaining its form, the bone is fragile and easily crushed and has suffered a loss of one-third of its weight, due to the destruction and elimination of the animal matters. The inorganic material, on the other hand, may be removed by the action of dilute hydrochloric acid, which dissolves out the earthy matters and leaves the animal part intact. Treated in this manner, the bone, although retaining perfectly its details of form, is tough and flexible, a decalcified rib or fibula being readily tied into a knot. The animal constituents yield *gelatin* after boiling with water, consisting chiefly of *collagen* and *osseo-mucoid*. The inorganic constituents, which form approximately two-thirds of the bone, include a large percentage (83) of calcium phosphate, much less calcium carbonate, with small proportions of calcium fluoride and chloride, and of the salts of magnesium and sodium.

On sawing through a bone from which the marrow and other soft parts have been removed, the osseous tissue is seen to be arranged as a peripheral zone of *compact bone* enclosing a variable amount of *cancellated bone*. In the typical long bones, as the humerus or femur, the compact tissue almost exclusively forms the tubular shaft enclosing the large *marrow-cavity*, while the cancellated tissue constitutes the expanded extremities, with the exception of a narrow superficial stratum of compact bone. The irregular clefts between the lamellæ of the spongy bone are direct extensions of the general medullary cavity and are filled with marrow-tissue. In the flat bones of the skull (Fig. 48), the compact substance is arranged as an outer and an inner plate, or *tables*, of considerable thickness, between which lies the spongy bone, or *diploë*. The short and irregular bones are made up of an inner mass of spongy bone covered everywhere by a shell of compact substance, which often is locally thickened to insure additional strength where needed.

The **cancellated bone** consists of delicate bars and lamellæ united into an intricate osseous reticulum well calculated to yield strength without undue weight. In many positions, conspicuously in the neck of the femur, the more robust lamellæ are disposed according to a definite plan in order to meet the strains of pressure and of tension. Although composed of the same structural elements, compact and spongy bone differ in their histological details in consequence of the secondary modifications which take place during the conversion of the spongy bone, the original form, into the compact. To obtain the classic picture of bone-tissue, in order to study its general arrangement where most typical, it is desirable to examine thin ground sections of the compact substance cut at right angles to the axis of a long bone which has been macerated and dried.

The **compact bone** in such preparations, when examined under low magnification (Fig. 49), is seen to consist of osseous layers arranged as three chief groups: (a) *circumferential lamellæ*, which extend parallel to the external and internal surfaces of the compact bone; (b) *Haversian lamellæ*, which are disposed concentrically and form conspicuous annular groups, the Haversian systems, enclosing the Haversian canals; and (c) *interstitial* or *ground lamellæ*, which include the irregularly arranged tracts filling the intervals between the Haversian systems and the surface lamellæ.

Each *Haversian system* consists of the concentrically disposed lamellæ and the centrally situated channel, the *Haversian canal*, which encloses prolongations of the marrow-tissue and ramifications of the medullary blood-

vessels. Between the annular lamellæ are seen small spindle-shaped or oval spaces, the *lacunæ* (about  $20\ \mu$  long,  $10\ \mu$  wide and  $6\ \mu$  thick), from which minute passages, the *canaliculi*, radiate and join with others to establish communication between the adjacent lacunæ of the same Haversian system. The lacunæ and canaliculi thus form an intercommunicating network of lymph-spaces similar to those in other dense connective tissue. When viewed in profile, as they are in sections cutting the lamellæ at right angles, the lacunæ present their smaller dimensions and appear as minute fusiform

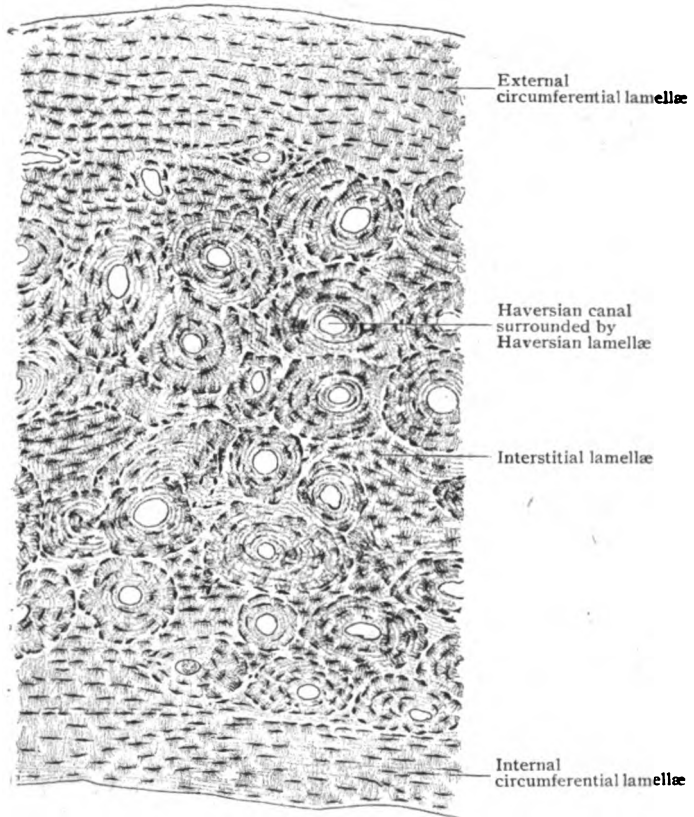


FIG. 49.—Transverse section of compact bone; the section has been ground and dried, hence the lacunæ are filled with air.  $\times 70$ .

spaces; seen in sections which pass parallel to the lamellæ (Fig. 50), the lacunæ are broader and more circular, the spaces with the canaliculi forming the spider-like figures so conspicuous in sections of dried bone.

The characteristic disposition of the lamellæ of the Haversian system is due to the secondary formation of the bone-tissue during the conversion of the spongy bone into the compact, the circumference of each system corresponding to an *Haversian space*, the cavity in which the connective lamellæ were deposited. It follows, from this relation, that the Haversian systems exist only in compact bone, the secondary deposit not occurring during the development of cancellated bone. When deprived of the min-

The **fibrous layer** is composed of bundles of fibrous tissue and supports the larger blood-vessels which, within the deeper parts of the periosteum, break up into twigs that enter the surface of the bone through the Volkmann canals. The fibro-elastic layer includes a feltwork of elastic fibres and delicate strands of fibrous tissue. The inner surface of the periosteum is attached to the underlying bone by processes of connective tissue which accompany the blood-vessels into the superficial canals. This relation

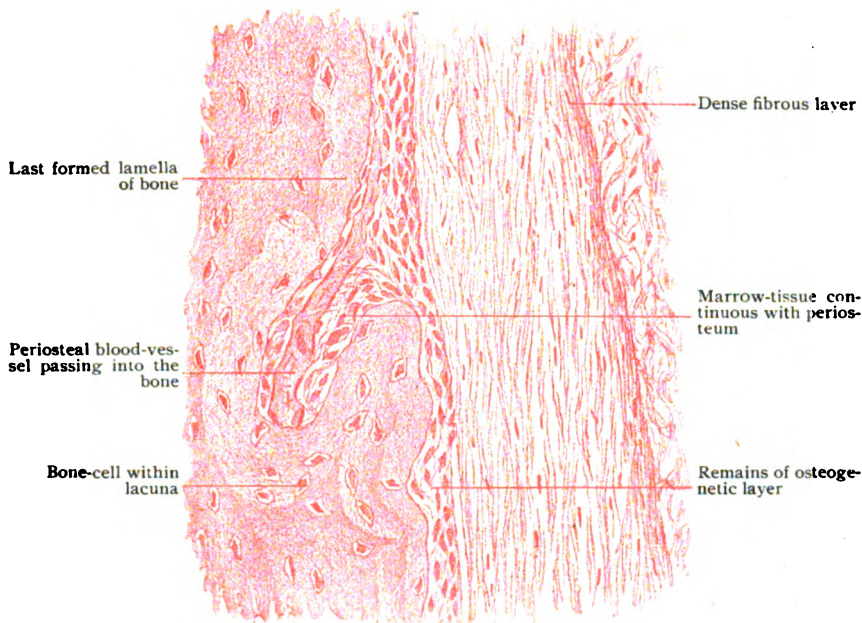


FIG. 54.—Section of young periosteum and subjacent bone.  $\times 275$ .

persists from the continuity of the formative tissue of the young periosteum with the early marrow-tissue.

The **osteogenic layer**, during development and growth of the bone, consists of delicate bundles of fibrous tissue and large numbers of round or fusiform connective tissue cells of an embryonal type. Those next the growing bone are of irregular cuboid form and disposed in a single row upon the surface of the developing osseous tissue. Since these cells are directly concerned in producing the new bone, they are termed *osteoblasts*. Later some of them become imprisoned within the bone-matrix and transformed into bone-cells. After completion of its active rôle, the osteogenic layer becomes greatly reduced and inconspicuous, in the adult periosteum being represented by flattened cells, which no longer form a continuous stratum but occur as scattered groups.

In addition to its important bone-producing function, the periosteum serves as the immediate means by which muscles, tendons, ligaments and fasciæ gain attachment to the skeleton. In every case the union is effected by the fusion and blending of the connective tissue of the attached structure with the outer layer of the periosteum.

**Bone-Marrow.**—The spaces in the interior of bones, whether the large medullary cavities surrounded by the compact substance forming the tubular

shaft of the long bones or the irregular interstices between the trabeculæ of the cancellated tissue, are filled with bone-marrow. The latter also extends into the larger Haversian canals. Apart from its fundamental relations to the development of bone, in addition to supporting the medullary blood-vessels, and therefore assisting in maintaining the nutrition of the bone, the marrow plays a very important rôle in connection with the production of blood-cells. Indeed, with its chief functions in mind, bone-marrow is classed as a *blood-forming organ*, and, as such, finds its systematic consideration with the blood. As a matter of convenience, however, a general description of the marrow-tissue is here given, while the relations of its cellular elements to the circulation are discussed in connection with the Blood (page 100).

Although of a reddish tint within all the bones of the early skeleton, the marrow in the adult includes two kinds—the *red* and the *yellow*. Thus, within the shaft of the long bones it appears as a light yellowish tissue, presenting the characteristics of ordinary adipose tissue; while within the upper ends of the humerus and of the femur, and especially within the bodies of the vertebræ, the ribs, the sternum and the diploë of the cranium, the marrow possesses a dull red color.

*Red Marrow.*—The ingrowth of the periosteal tissue and blood-vessels constitutes the primary marrow of the foetal skeleton; from this tissue the red marrow filling the young bones is directly derived. The red marrow is, therefore, the first formed and typical variety. After early childhood, however, the marrow within the bones of the extremities suffers gradual invasion by fat, until, with the exception of the marrow within the upper ends of the humerus and of the femur, the red tissue gives way to the yellow, the fat-cells replacing most of the marrow-elements.

When examined in section after fixation and appropriate staining, the red marrow exhibits a delicate connective tissue reticulum which supports the blood-vessels and contains within its meshes numerous cells (Fig. 55). Next the bone, the fibrous tissue forms a thin membrane, the *endosteum*, lining the medullary cavity and extending into the larger Haversian canals. The more characteristic cells encountered within the red marrow include:—(1) the *myelocytes*, very numerous and of different ages; (2) the *eosinophiles*; (3) the *megakaryocytes* or giant cells and (4) the *erythroblasts* and other stages of red blood-cells. In addition lymphocytes, connective tissue cells, fat-cells, mast-cells and osteoclasts are usually present in small and varying numbers.

The *myelocytes* include three varieties of cells which, while differing in the granularity of their cytoplasm and the form of their nuclei, are probably directly genetically related. (a) The *myeloblasts* are relatively large ovoid cells, with round nuclei and cytoplasm devoid of granules. They are few in number and regarded as the parent elements (premyelocytes). (b) The *myelocytes*, the most numerous of the marrow-cells, are of uncertain form and possess large round nuclei and cytoplasm containing fine neutrophilic granules. (c) The *polymorphonuclear leucocytes*, the descendants of the preceding elements, are somewhat smaller and more granular than the myelocytes and distinguished by the lobulated nuclei so conspicuous in the most common form of colorless blood-cells. If the genetic relations here outlined be accepted, the typical leucocytes represent later generations of the marrow-cells, which thus become important contributors to the blood. The *eosinophiles*, sparingly represented, are conspicuous by reason of the coarse granules within their cytoplasm which color intensely with acid stains (eosin). The relation of the eosinophiles to the myelocytes shares the



uncertainty of their position as blood-elements. The **megakaryocytes**, the mononuclear giant cells of the marrow, are huge and conspicuous occupants of the reticular meshes. They must not be confused, however, with giant cells of another kind, the **osteoclasts**, which in young marrow are more numerous and equally striking. The distinguishing feature between the two is the nucleus, which in the case of the osteoclast is multiple and in that of the megakaryocyte single. In the last instance, however, the nucleus may assume a very complex contour, sometimes being so lobulated and con-

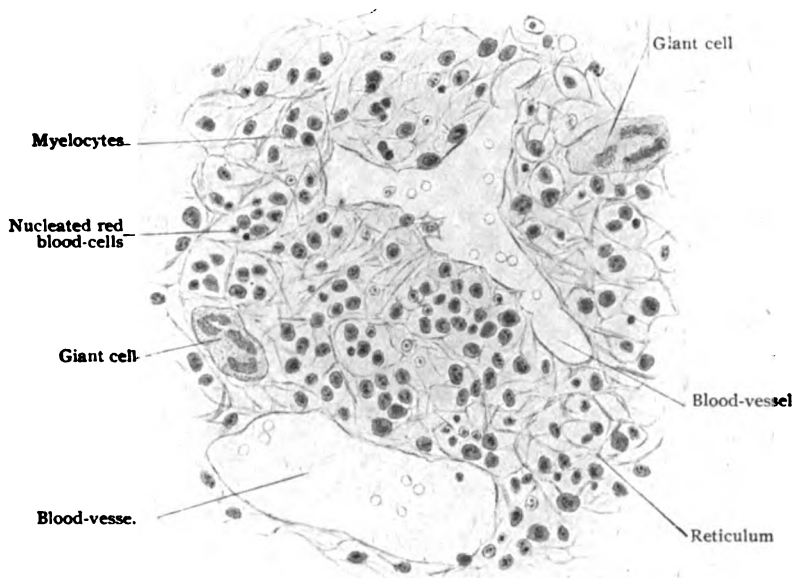


FIG. 55.—Section of red bone-marrow from end of young femur.  $\times 300$ .

torted that what is really one continuous nucleus appears as several. The osteoclasts are multinuclear, two or more ovoid nuclei occupying the huge mass of granular cytoplasm. These cells, moreover, lie close to the trabeculae of young bone, a position in keeping with their particular function as bone-destroyers. The origin and rôle of the megakaryocytes are uncertain, a derivation from the myelocytes and a function as phagocytes or as producers of the blood-plates (Wright) being among the suggested explanations concerning these constituents of the marrow.

The **nucleated red blood-cells** are constant elements of the red marrow and indicate its importance as the chief seat in which the production of the red cells after birth takes place. These blood-cells are represented by three generations: (a) the *erythroblasts*, the descendants of the primary blood-cells, which are transformed into (b) the *normoblasts*. The latter are smaller than the erythroblasts and possess nuclei in which the reticular structure has given place to one of density. By mitotic division the normoblasts give rise to (c) the *nucleated erythrocytes*, which, after losing their nuclei, become the completely developed erythrocytes and pass into the circulation as the ordinary red blood-cells.

*Yellow Marrow.*—After early childhood, the red marrow, which previously fills all the medullary spaces, begins to suffer invasion by fat-cells and conversion into adipose tissue. This change, which results from the substitution of fat-cells for the distinctive marrow components, affects the medullary tissue within the bones of the extremities, except within the upper ends of the humerus and femur. Examined in section, the yellow marrow resembles ordinary adipose tissue, consisting chiefly of the large compressed spherical fat-cells supported by a reticulum of connective tissue. The cells belonging to the latter, occasional plasma cells and myelocytes are the usual elements encountered. In advanced age and during starvation, the customary consistence and yellow color give place to a mucoid condition and reddish tint, the fat-cells of such *gelatinous marrow*, as it is termed, losing much of their oily contents.

**Blood-Vessels of Bones.**—The generous blood-supply of bones is arranged as two sets, the *periosteal* and the *medullary*. The former constitutes a network within the periosteum and supplies twigs, which enter the subjacent compact bone through the Volkmann canals and communicate with the branches from the medullary system. The *medullary artery* is often, as in the case of the long bones, a vessel of considerable size, which, accompanied by the companion veins, traverses the oblique nutrient canal to gain the centre of the marrow. On reaching this position the medullary artery usually divides into ascending and descending branches, from which twigs radiate towards the periphery of the marrow cavity. The twigs terminate in arterial capillaries, which expand rather abruptly into larger venous capillaries, in consequence of this arrangement the rapidity of the blood-stream becoming diminished in its course through the marrow. Within the red marrow, the venous capillaries possess an imperfect endothelial lining, thereby affording an opportunity for the newly formed blood-cells, the erythrocytes and the leucocytes, to gain entrance into the circulation. After thus coming into close relations with the marrow-tissue, the blood is collected by the capillaries which form veins destitute of valves. In addition to the companion veins which accompany the medullary artery through the nutrient canal, in many instances the larger veins pursue an independent course and emerge from the cancellous tissue by means of special canals piercing the compact substance.

Definite **lymphatics** are found only within the outer layer of the periosteum, although the system of intercommunicating spaces within the bone, the lacunæ, and canaliculi, stands in close relation with the larger lymph-channels.

The **nerves** supplying the bones include both medullated and nonmedullated fibres. The latter, distributed partly to the periosteum and partly within the bone, are chiefly sympathetic fibres destined for the control of the involuntary muscle within the walls of the blood-vessels. The medullated sensory fibres are few, some being connected with special endings of the lamellar type within the periosteum.

#### DEVELOPMENT OF BONE.

With the exception of certain parts of the skull—the vault and nearly all of the face—the bones of the human skeleton are preceded by solid masses of embryonal hyaline cartilage. Since the primary development of such bones takes place within the cartilage, they are known as *cartilage bones* and the mode of formation is termed *endochondral development*. The bones not preceded by cartilage are produced within sheets of connective

tissue; such are said, therefore, to be *membrane bones* and their formation is by *intramembranous development*.

**Endochondral Bone-Development.**—The process by which bones preceded by cartilage are formed, known as the endochondral mode, includes two distinct, although closely related, series of changes. The one results in the production of osseous tissue within the mass of cartilage, the *intracartilaginous bone*, the other in the production of bone outside the cartilage and beneath the periosteum, the *subperiosteal bone*. Both take part in the formation of the completed bone, although their contributions to the final result are not only unequal, but vary with different types of bones.

The greater part of the bone formed within the cartilage undergoes absorption, the spongy substance within the ends of the long and the bodies of the irregular bones chiefly representing the persisting contribution of the intracartilaginous bone. Even when the intracartilaginous changes are conspicuous, as in the development of the humerus, femur and other long bones, the important compact substance is the product of the periosteal connective tissue and genetically resembles intramembranous bone. Although the formative processes of both kinds of bone proceed coincidentally and are closely related, as a matter of convenience they will be described separately and as occurring in the development of a typical long bone.

#### *Intracartilaginous Bone.*

—The primary cartilage, formed by the proliferation and condensation of the mesenchymal tissue, gradually assumes the characteristics of embryonal cartilage, which by the end of the second month of foetal life maps out the principal segments of the skeleton. These segments are covered by an immature form of perichondrium, or *primary periosteum*, from which arise the elements actively engaged in the production of the bone-tissue. The primary periosteum consists of a compact outer *fibrous* and a loose inner *osteogenetic layer*, the latter being rich in cells and delicate intercellular fibres.

The initial changes within the cartilage appear at points known as *centres of ossification*, which in the long bones are situated about the middle of the future shaft. These early changes involve both cells and matrix, which exhibit conspicuous increase in size and amount respectively. The cartilage-cells become larger and more vesicular (Fig. 56) and encroach upon

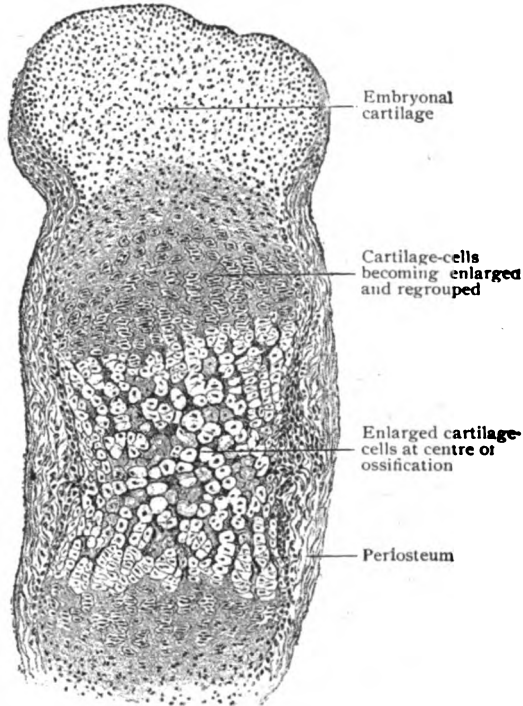


FIG. 56.—Section of tarsal bone of foetal sheep, showing centre of ossification. X 50.

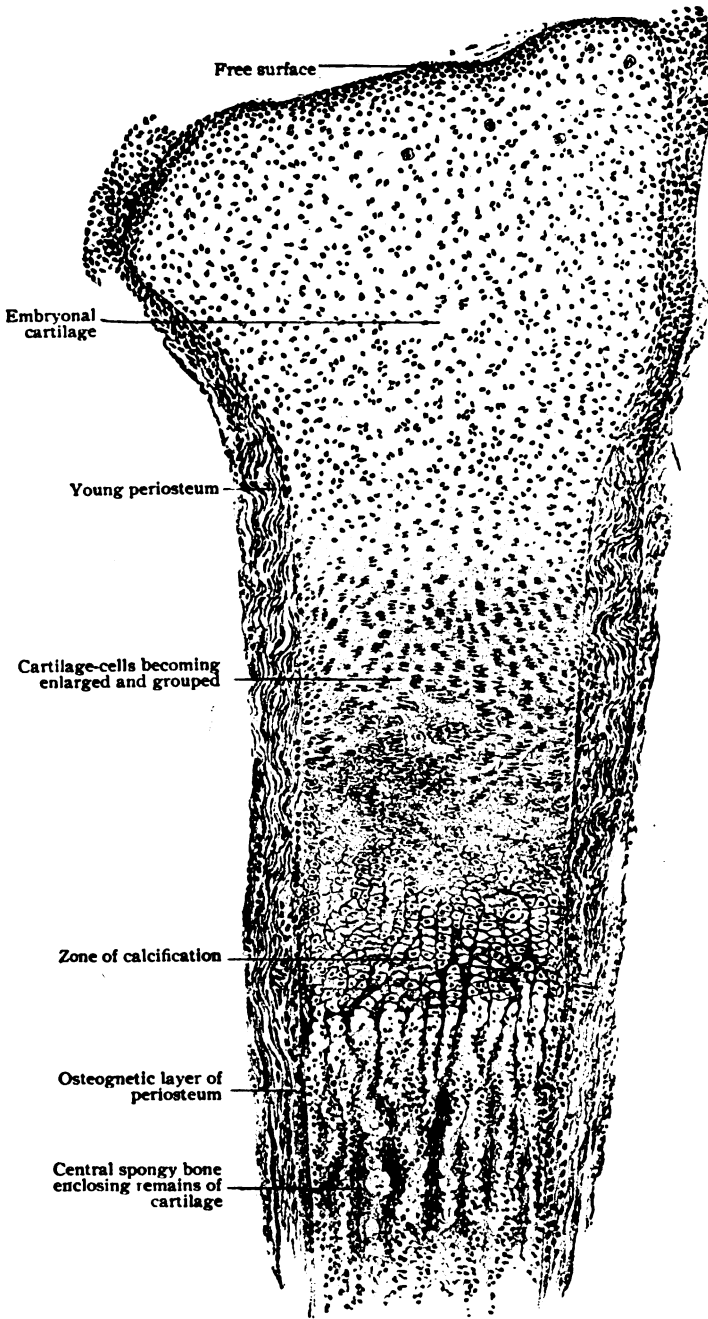


FIG. 57.—Longitudinal section of metatarsal bone of foetal sheep, showing endochondral bone-development.  $\times 40$ .

the intervening matrix, in which a deposit of lime salts now takes place, as shown by opacity and by the grittiness when a knife is carried through such ossific centres. On acquiring their maximum size, the cartilage-cells soon give indications of impaired vitality in their shrinking cytoplasm and degenerating nuclei. The enlarged spaces or lacunæ enclosing these cells are known as the *primary areolæ*.

Coincidentally with, or indeed preceding, these changes within the cartilage, a thin peripheral layer of bone has been formed beneath the young periosteum, thickest around the middle of the shaft and fading away towards the ends. Bud-like processes of the osteogenetic layer grow inward from the periosteum and invade the embryonal cartilage, by absorption of the cartilage-matrix gaining the centre of ossification and there effecting destruction of the less resistant cells and the intervening matrix. In consequence of this invasion by the periosteal tissue, a space, the *primary marrow-cavity*, now occupies the centre of ossification and contains the direct continuation of the osteogenetic layer. This tissue, the *primary marrow*, which has thus gained the interior of the cartilage, contributes the cells upon which a double rôle devolves—to remove the embryonal cartilage and to produce bone.

The cartilage-matrix closing the enlarged cell-spaces on the side towards the primary marrow-cavity progressively suffers absorption, whereby the spaces are opened, converted into *secondary areolæ*, and brought into direct communication with the expanding medullary cavity. The cartilage-cells escape from their former homes into the marrow-cavity and undergo disintegration, taking no part in the direct production of the bone-tissue.

Beyond the immediate limits of the primary marrow-cavity, the cartilage cells in their turn undergo the increase in size and the impairment of vitality described; in addition they often exhibit a conspicuous rearrangement, forming columnar groups separated by intervening tracts of calcified matrix (Fig. 57). This characteristic belt, the *zone of calcification*, surrounds the medullary cavity and marks the area in which the destruction of cartilage is progressing with greatest energy. In consequence of the disposition of the cartilage elements as columnar groups separated by intervening tracts of calcified matrix, a less and a more resistant portion of the cartilage are offered to the attacks of the marrow-tissue by the cell- and the matrix-columns respectively. As the result of this difference, the cells and the immediately surrounding partitions first succumb, while the intercolumnar tracts of calcified matrix remain for a time as irregular indented tapering processes, deeply tinted in sections stained with hematoxylin, which extend beyond the last row of cartilage-cells into the medullary cavity. These trabeculæ of calcified cartilage-matrix serve as supports for the marrow-cells engaged in producing the true bone, these elements, the *osteoblasts*, becoming arranged along the trabeculæ upon which, through the influence of the cells, the immature bone-tissue is deposited.

Simultaneously with the *destructive* phase attending the absorption of the embryonal cartilage by the *chondroclasts*, the *constructive* process of bone-formation is instituted by the osteoblasts. The osteoblasts rest on the irregular trabeculæ of calcified cartilage and bring about the deposit of a layer of bone-matrix upon the surface of the trabeculæ, which thus becomes encased within a shell of immature bone. After the latter has attained a thickness at least equal to that of the osteoblasts, some of the latter are gradually surrounded by the osseous matrix, until, finally, they lie isolated within

the newly formed bone as its cells (Fig. 58). The *bone-cells* are, therefore, imprisoned osteoblasts, which, in turn, are specialized connective tissue elements. The bone-cells occupy minute lenticular or stellate spaces, the

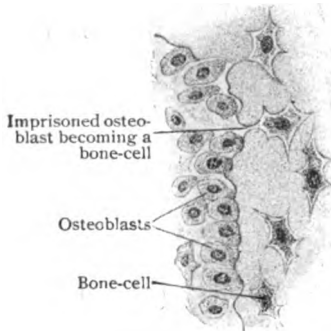


FIG. 58.—Portion of developing osseous trabecula and osteoblasts.  $\times 350$ .

*primary lacunæ*, at this stage the canaliculi being still unformed. The bone-matrix is at first devoid of calcareous material and is, therefore, soft; very soon, however, the deposit of lime-salts begins and the young bone becomes hard. The increase of the new bone is attended by the gradual disappearance of the enclosed calcified cartilage-matrix, the last traces of which, however, persist for some time as irregular deeply stained patches within the osseous trabeculæ, at some distance from the zone of calcification (Fig. 57). Many of the newly formed bony trabeculæ soon undergo absorption, with corresponding enlargement of the intervening marrow-spaces. The remaining trabeculæ increase in thickness by the addition of new lamellæ on the surface covered by the osteoblasts and join to form a trabecular network, the *primary central spongy bone*. In the irregular bones, the primary spongy bone is represented by the cancellated tissue forming the internal framework. In the long bones, the primary spongy bone undergoes further absorption within the middle of the shaft, simultaneously with its continued development within the cartilage at the ends of the shaft, or diaphyses. As the result of this absorption, a large space, the *central marrow-cavity*, is formed, the growth of which keeps pace with the general expansion of the bone. So long as a long bone increases in length, new cartilage is added at the ends of the shaft, to be replaced in its turn by the advancing osseous tissue.

The **absorption** of the newly formed bone is effected through the agency of large polynucleated cells, the *osteoclasts*. These are specialized marrow-elements whose particular rôle is the breaking down and absorption of the bone-matrix. They are very large (50–100  $\mu$ ) and lie, singly or in groups, close to the surface of the bone within depressions, the so-called *Howship's lacunæ*, produced by the erosion of the osseous matrix (Fig. 59). The only part of the central spongy bone which persists after the completed development and growth of the long bones, is that constituting the cancellated tissue within their ends. It will be seen, therefore, that in many cases the product of bone-formation within the cartilage, the primary central spongy bone, is to a

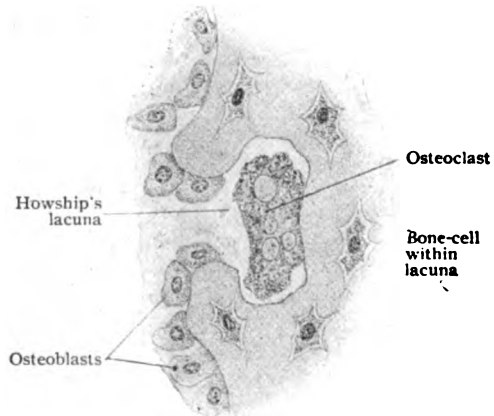


FIG. 59.—Portion of trabecula of spongy bone undergoing absorption by osteoclast.  $\times 450$ .

large extent absorbed and contributes only a small part of the mature skeleton. The early marrow-cavity, including all its ramifications between the trabeculæ, is filled with the young marrow-tissue; the latter gives rise to the red marrow that for a time fills all the bones and later occupies the spongy tissue chiefly within the axial skeleton. It may be emphasized, that the process sometimes spoken of as the "ossification of cartilage" is really a substitution of osseous tissue for cartilage and that, even in the endochondral mode of formation, cartilage is never directly converted into bone.

*Ossification within the epiphyses*, which usually does not begin until some months after birth, repeats in its essential features the details of intracartilaginous bone-formation as seen in the development of the shaft.

After the establishment of the primary marrow-cavity and the surrounding spongy bone, ossification extends in two directions—towards the periphery and towards the adjacent end of the shaft. As this process progresses, the layer of cartilage between the central spongy bone and the free surface, on the one hand, and between the central spongy bone of the epiphysis and that of the shaft, on the other, is gradually reduced until in places it entirely disappears. Over the areas which correspond to the later joint-surfaces, the cartilage persists and becomes the articular cartilage covering the ends of the bone. With the final absorption of the plates separating the epiphyses from the shaft, the osseous tissue composing the segments becomes continuous, "bony union" being then accomplished.

*Subperiosteal Bone.*—It is evident from the foregoing account of the development of bone within cartilage that the true bone-producing elements are contributed by the periosteum when the latter sends its processes into the ossific centre within the cartilage.

The distinction, therefore, between intracartilaginous and subperiosteal bone is one of situation rather than of inherent difference, as in the production of both the osteoblasts are the active agents and the essential features are identical. Since in the development of subperiosteal or perichondral bone the changes within cartilage do not come into account, the details are less complicated and concern primarily only a formative process.

The young periosteum, it will be recalled, consists of an outer compact *fibrous layer* and an inner loose *osteogenetic layer*. The latter is rich in blood-vessels and contains numerous embryonal connective tissue cells and delicate strands of fibres. Some of these cells become the osteoblasts and as such are arranged along the fibrillæ, about which the bone-matrix is deposited through the influence of the cells. The osseous trabeculæ, formed in this manner beneath the periosteum, increase in length by the addition of

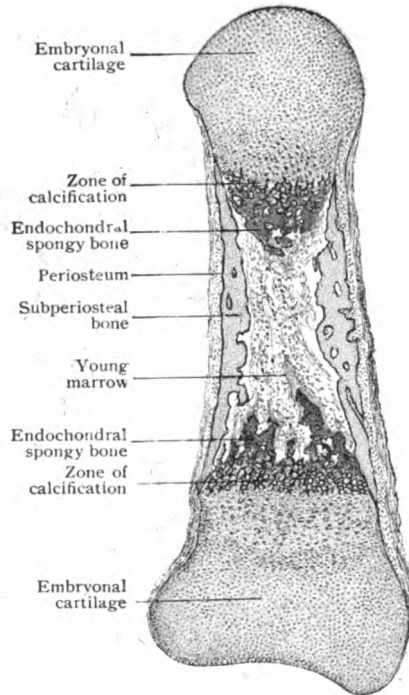


FIG. 60.—Longitudinal section of phalanx of fœtus of five months.  $\times 23$

new matrix at the periosteum, and in thickness by the deposition of new layers of bone-matrix on the surface of the trabeculæ by the osteoblasts, some of these cells being surrounded by the matrix and thus converted into bone-cells. The spaces between the trabeculæ are occupied by the primary marrow, the direct prolongation from the periosteal tissue. During their further growth, the trabeculæ unite to form a subperiosteal bony network, the *peripheral spongy bone*, which surrounds the central spongy bone, or, where that has already disappeared, the central marrow cavity. Towards

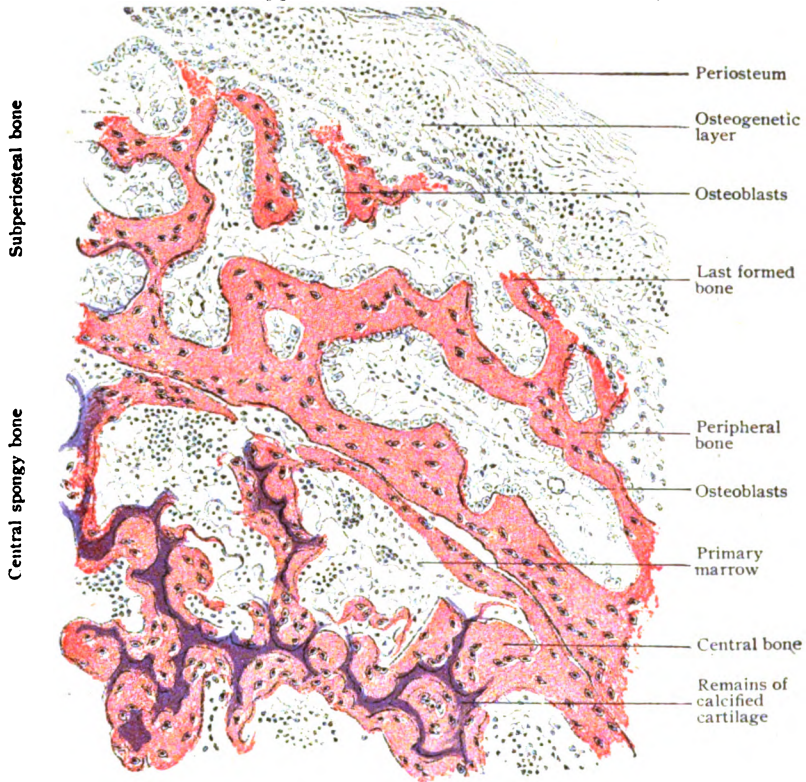


FIG. 61.—Portion of developing humerus of foetal sheep, showing subperiosteal and central spongy bone.  $\times 135$

the ends of the shaft, where the cartilage still intervenes between the central spongy bone and the surface, the subperiosteal bone forms a thin perichondral shell. The two processes, central and peripheral bone-formation, progress simultaneously, so that their products are often seen in the same microscopical field lying side by side, separated, however, by a thin and incomplete layer of calcified cartilage-matrix, known as the *boundary line*. From their relations to cartilage, it is evident that the subperiosteal bone never contains the remains of the calcified cartilage, while such enclosures are very common within the trabeculæ of the central spongy bone (Fig. 61).

The conversion of the peripheral spongy bone into the typical compact bone of the shaft involves the partial absorption of the subperiosteal network and the secondary deposit of new osseous tissue. The initial phase of this



conversion is the partial absorption of the trabeculæ by the osteoclasts within the primary marrow. As the result of this process, the robust and close reticulum of subperiosteal bone is reduced to a delicate osseous framework enclosing enlarged marrow-channels. The latter are now known as the *Haversian spaces* and, in cross-section, are round or oval. After the destructive work of the osteoclasts has progressed to the required extent, the osteoblasts of the marrow-tissue within the Haversian spaces begin the formation of new bone on the walls of the spaces. This process is continued until, layer after layer, almost the entire space is filled with concentric lamellæ. The cavity remaining at the centre of the former space persists as an Haversian canal, while the concentrically disposed layers of secondary bone are the lamellæ of the Haversian system, whose extent corresponds to the form and size of the Haversian space. The interstitial or ground lamellæ of adult bone are the remains of the trabeculæ of the primary subperiosteal spongy bone and are, evidently, genetically older than the Haversian lamellæ. The outer surface of the subperiosteal bone is beset with depressions occupied by the primary marrow-tissue. As these pits deepen in consequence of the increasing thickness of the growing bone, they are converted into the nutrient channels which occupy the circumferential and ground lamellæ. They are, therefore, not surrounded by Haversian layers and correspond to the Volkmann canals, through which so many nutrient vessels enter the bone.

#### Intramembranous Bone-Development.—

The bones not preceded by masses of cartilage, as those constituting the vault of the cranium and the greater part of the face, develop within sheets of connective tissue by a process which, although differing in its earliest details, essentially corresponds to subperiosteal bone-formation. Except where developing muscle occurs, the early roof of the skull consists of the integument, the dura mater and an intervening stratum of young connective tissue. The latter layer contains numerous embryonal cells and delicate bundles of fibres. About the middle of the area corresponding to the later bone, some of these fibrous strands undergo calcification and thereby supply a radiating framework upon the surface of which the osteoclasts, derived from the embryonal connective tissue cells, arrange themselves and bring about the deposit of bone-matrix. Delicate spicules of new bone radiate towards the periphery from the ossification centre thus established. As the trabeculæ increase in size and number, they join to form a bony network, close and robust at the centre and wide meshed and delicate towards the periphery where the osseous reticulum fades into

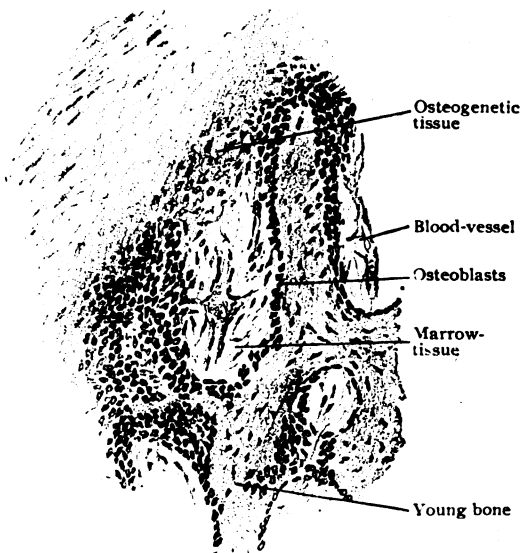


FIG. 62.—Periphery of a developing membrane-bone (parietal), showing trabeculæ covered with osteoblasts.  $\times 95$ .

the connective tissue. The details of this bone-formation by the osteoblasts correspond to those seen in other localities, including the conversion of some of the osteoclasts into bone-cells. With the growth of the bony tissue the network becomes more and more compact until it forms an osseous plate, which gradually expands towards the limits of the future bone. During this growth, the connective tissue covering the outer and inner surfaces of the plate assumes the character and arrangement of a periosteum and from the osteogenetic layer produces the compact surface lamellæ which enclose the intervening spongy tissue. This arrangement is seen in the fully developed bone (Fig. 48), where the so-called outer and inner tables enclose the diploë. The development of the superficial layers of the surface lamellæ is, therefore, identical with that of other subperiosteal surface lamellæ, while the production of the diploë corresponds with that of the peripheral spongy bone in its essentials, even to partial absorption in order to produce enlarged marrow spaces. The secondary deposit of Haversian lamellæ, however, never takes place, the conspicuous systems of concentric layers being absent in the membrane-bones. Increased thickness of the membrane-bones follows the addition of new surface lamellæ; increased area results from the marginal growth of the enclosed network of bony trabeculæ. In the young skull the vault-bones are separated by considerable tracts of connective tissue, conspicuous in the fontanelles and the evident sutures. This isolation continues, in principle at least, even after the bones are in close apposition, and ends only with the complete replacement of the intervening periosteum by bone, such bony union being subject to great individual variations as to time and extent.

**Growth of Bones.**—Since new bone is deposited beneath the periosteum, it is evident that in a long bone such growth results in increased diameter of the shaft, as well as in increased thickness of the bony wall between the central medullary cavity and the surface. In order to maintain the balance between the longitudinal growth of the marrow-cavity (effected by the destruction of the cartilage and the absorption of the intracartilaginous bone) and its lateral expansion, removal of the innermost layers of the subperiosteal bone soon becomes necessary. This is effected by the osteoclasts, absorption of the older internal portion accompanying the deposition of new lamellæ on the surface. By this combination of destructive and formative processes, the thickness of the cylindrical wall of compact substance of the shaft is kept within the proper limits to insure the necessary strength without undue weight. During early growth, increase in the length of the bone is due to the addition at the ends of new cartilage formed by the perichondrium; later, these additions are supplemented by interstitial growth following multiplication of the cartilage-cells. On attaining full growth and completed epiphyseal ossification (page 47), a portion of the cartilage persists as the covering of the articular surfaces. During the development of the short bones, in which the entire bone is made up by a mass of spongy substance enclosed by a shell of compact bone, no definite envelope of subperiosteal bone forms until the cartilage has completely disappeared. The subsequent growth and expansion of such bones is accomplished by the superficial addition and internal absorption of the subperiosteal bone and the accompanying expansion of the central spongy tissue. In the flat bones, as the scapula, the subperiosteal production is well advanced before the intracartilaginous process begins. After the cessation of peripheral growth, the osteogenetic layer of the periosteum becomes denser and much less rich in cells, although it retains an intimate connection with the last formed lamellæ

by means of the processes which continue its tissue into the vascular channels within the bone. In addition to being the most important source of nutrition, on account of its blood-vessels, the periosteum responds to demands for the production of new bone, whether for renewed growth or for repair, and, when occasion requires, again becomes active as the chief bone-forming tissue, its cells reassuming the rôle of osteoblasts.

### THE ARTICULATIONS.

Broadly considered, the individual pieces composing the skeleton are united by articulations of two kinds: (1) the continuous joint (*synarthrosis*), in which the union is effected by uninterrupted masses of tissue and the bones have no, or only very slight, play; and (2) the discontinuous joint (*diarthrosis*), in which the bones are joined by tissue containing definite joint-cavities and, therefore, are free to move on each other.

**Synarthrosis** may be: (*a*) by dense connective tissue (*sutura*), as in the immovable articulations of the skull, where the intervening periosteum is intimately connected with the bones by penetrating processes composed of white and elastic fibres; (*b*) by ligamentous tissue (*syndesmosis*) arranged in dense fibrous bands, which stretch between the adjacent bones and permit of slight movement, as between the lower ends of the tibia and fibula; and (*c*) by cartilaginous tissue (*synchondrosis*), which affords a rigid or flexible joint according to the proportions of the hyaline or fibrous varieties of the tissue. Thus, where the bond of union consists exclusively of hyaline cartilage, as between the component pieces of a young bone, immobility results; where fibrous cartilage predominates, as in the massive intervertebral disks, the union provides great strength and some flexibility. Outside the spongy substance or *nucleus pulposus*, which occupies the centre of the disk and is regarded as the modified remains of the chorda dorsalis of foetal life, the intervertebral disk consists of interwoven bundles of fibrous cartilage. Towards the surface the more typical cartilaginous tissue is replaced by a peripheral layer resembling tendon in structure.

**Diarthrosis** or the true joint includes, as its essential parts, the articular cartilage and the capsule; interarticular and adaptation cartilages and synovial fringes are secondary structures which may or may not be present. The **articular cartilage** covering the surfaces of the bones in apposition is, with few exceptions, of the hyaline variety. Next the joint-cavity, the cartilage-cells are usually flattened and arranged parallel with the free surface; deeper, the cells are more spherical in form and disposed in groups, while in the layers still nearer the underlying bone, the cartilage-cells often show a characteristic columnar arrangement, in which the rows of cells lie in a general way perpendicular to the surface of the bone. The matrix immediately overlying the bone is commonly the seat of more or less marked calcification, a zone of calcified matrix thus forming the union between the cartilage and the bone.

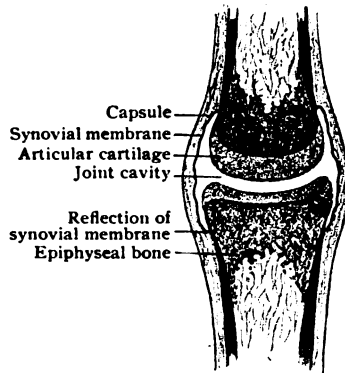


FIG. 63.—Diagram showing essential parts of a typical joint.

Where two joint-cavities exist, separated by an interarticular cartilage, the development of the partition, or *meniscus*, seems to influence the structure of the cartilage capping the articular surfaces of the bones. In such cases, as in the mandibular, costo-sternal, sterno-clavicular, acromio-clavicular and lower radio-ulnar articulations, fibrous cartilage not only forms the interarticular plates, but also contributes the covering of the bones. Such instances, therefore, are exceptions to the usual investment of hyaline cartilage. The adaptation cartilages, or *labra glenoidalia*, as the glenoid and semilunar cartilages in the shoulder and knee joint respectively, that serve to deepen the cups in which the humerus and the femur play, also consist of dense fibrous tissue containing rounded cartilage-cells.

The **capsule** surrounding the joint-cavity includes two layers: the outer fibrous and the inner synovial. The *fibrous layer*, made up of interlacing bundles of dense fibrous tissue, varies much in thickness in different

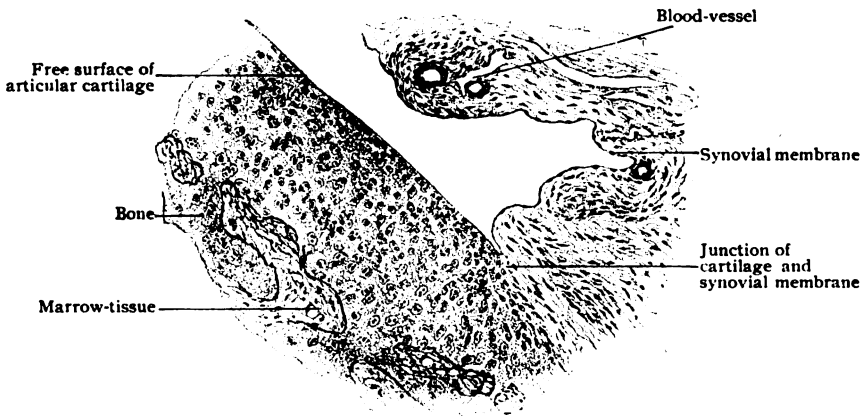


FIG. 64.—Section through margin of joint, showing articular cartilage and synovial membrane.  $\times 100$ .

joints, in the minute articulations between the ear-ossicles being a delicate membrane, while in the capsule of the hip-joint it reaches almost a centimeter.

The *synovial layer*, or synovial membrane, consists of loose connective tissue containing elastic fibres and more or less extensive groups of fat-cells; next the joint-cavity the tissue is condensed into a narrow compact stratum, whose free or joint-surface is clothed with flattened connective tissue cells. The latter are plate-like elements, irregularly oval or stellate in outline, and, where closely placed, form a lining for the capsule that resembles an imperfect endothelium. While the fibrous layer of the capsule is often carried for some distance beyond the margin of the joint to blend with the periosteum, the synovial membrane is reflected from the capsule to the bones and the articular cartilage, extending over the latter for a variable distance, but thinning out and disappearing over the surfaces subject to pressure. The actual articulating surfaces, therefore, are devoid of synovial membrane, the lubricated cartilages coming into contact during the movements of the bones.

Within the larger articulations the synovial membrane is thrown into uncertain folds, which project into the joint, enclose masses of adipose tissue, and are beset with numerous minute elevations. The latter, the *synovial villi*, are found especially around the margin of the articular surfaces and,

in most cases, contain loops of capillary blood-vessels, which, together with the other capillaries within the synovial membrane, are important in producing the fluid within the joint. Although this synovial fluid, or *synovia*, consists almost wholly (94 per cent.) of water, it is slightly viscid and, therefore, well adapted to lubricate the articulating cartilages. In addition to salts, proteid and mucoid substances, the synovia contains oil drops and the remains of cells displaced by abrasion.

*Blood-vessels* and *nerves* are wanting within the articular cartilages, as well as within the interarticular and the adaptation cartilages. The synovial membrane, on the contrary, possesses numerous vessels and nerves. The larger blood-vessels occupy the stratum of loose connective tissue, the capillaries penetrating into the innermost layer and the villi. The nerves include vasomotor and sensory fibres, some of the latter being connected with special endings (Vater-Pacinian bodies and Krause's articular end-bulbs). Definite *lymphatics* are found within the synovial membrane immediately beneath the joint-surface.

## MUSCULAR TISSUE.

Although possessed to some degree by all living protoplasm, contractility is exhibited characteristically by muscular tissue. The latter is made up of greatly elongated elements, which during contraction shorten in the direction corresponding with their long axes and, hence, exert a definite pull that results in motion. In the higher animals muscular tissue occurs in two chief kinds, the *striated* and the *nonstriated*, as distinguished by their histological appearances. The former composes the muscles controlled by the will and therefore is also termed *voluntary muscle*; the latter acts independently of volition and is spoken of as *involuntary muscle*. The association of striated muscle with the will and, conversely, of the nonstriated variety with involuntary action must be made, however, with reservation, since in some animals voluntary muscle is without striations. There is, indeed, reason to believe that the histological differences are not fundamental, but are correlated with function. Thus, the muscles of the œsophagus which in one group of animals are striated, in another group may be represented by nonstriated tissue; further, much of the voluntary muscle of the head may be regarded as the equivalent of the involuntary muscle of the trunk. The nonstriated or involuntary muscle represents a less highly specialized type than the striped, the latter exhibiting to a conspicuous degree histological differentiation. As an intermediate group stands the muscular tissue composing the heart, since the cardiac muscle is beyond the control of the will although it possesses striated fibres. The latter occupy a position, therefore, between the fibre-cells of the involuntary muscle and the elongated striated fibres of the voluntary muscle.

### NONSTRIATED OR INVOLUNTARY MUSCLE.

This variety of muscular tissue occurs in the form of bundles and thin sheets chiefly within the walls of the hollow viscera and of the vessels and, although enjoying a wide distribution in the body, seldom forms considerable masses. Its distribution includes: 1. The *digestive tract*—the muscularis mucosæ from the œsophagus to the anus and delicate bundles within the mucosa; the muscular tunic from the lower half of the œsophagus to the anus; in the large excretory ducts of the liver, pancreas, and some salivary glands, as well as in the wall of the gall-bladder. 2. The *respiratory tract*—in the posterior wall of the trachea and as encircling bundles in the walls of the air-tubes. 3. The *urinary tract*—in the capsule and pelvis of the kidney

and in the walls of the ureter, bladder and urethra. 4. The *male reproductive organs*—in the epididymis, vas deferens, seminal vesicles, prostate and Cowper's glands, and cavernous and spongy bodies of penis. 5. The *female reproductive organs*—in the oviducts, uterus and vagina; in the broad and round ligaments; in the erectile tissue of the external genital organs and in the nipple. 6. The *vascular system*—in the walls of the arteries, veins and larger lymphatics; sometimes in the trabeculæ of the larger lymph-nodes; in the capsule and trabeculæ of the spleen. 7. The *eye*—in the iris and ciliary region; in the eyelids. 8. The *integument*—in the sweat and some sebaceous glands: as the minute erector muscles of the hair-follicles and in the skin covering the scrotum and parts of the external genital organs.

Nonstriated, smooth, pale, unstriped or involutary muscle, as it is variously designated, consists of structural units known as the **fibre-cells**. These are delicate spindle, often prismatic, elements whose tapering ends fit




FIG. 65.—Involuntary muscle from intestine; several isolated fibre-cells are seen above.  $\times 200$ .

between the adjacent fibre-cells. They vary greatly in size, measuring from 50–225  $\mu$  in length and from 3–8  $\mu$  in width. The fibre-cells found in the skin and the blood-vessels are short (15–20  $\mu$ ) and broad; those in the intestinal wall are more elongated (215–220  $\mu$ ) and delicate. The largest elements are encountered in the gravid uterus where they may attain a length of 500  $\mu$  and a width of 30  $\mu$ . Occasionally the cells are bifurcated, especially among the lower vertebrates. Each fibre-cell consists of protoplasm in which are embedded the *nucleus* and the *contractile fibrillæ*. The nucleus, usually described as rod-shaped from its elongated oval or cylindrical form, is placed frequently somewhat eccentrically with regard to the long axis and nearer one pole than the other. It is rich in chromatin which usually presents a reticular arrangement. Influenced by contraction, the nuclei often exhibit deviations from the typical rod-form. Paired centrosomes have been observed within the cytoplasm close to the side of the nucleus. The contractile fibrillæ, convincingly seen only within the large elements of the amphibia, are doubly refracting (anisotropic) threads within the cytoplasm. They lie at the periphery of the fibre-cell, closely related to the denser *boundary zone*, which forms the exterior of the fibre-cell and fulfils the purpose of a limiting membrane, or sarcolemma, although no such definite structure encloses the smooth muscle-cell as in the case of the striated fibre.

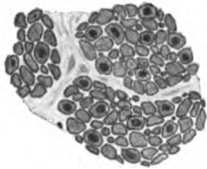


FIG. 66.—Bundles of involuntary muscle in transverse section, showing the fibre-cells cut crosswise.  $\times 400$ .

The individual fibre-cells are held together by an exceedingly delicate investment of connective tissue fibres, both white and elastic, which surround the muscle elements and in cross-sections appear as lines, formerly interpreted as cement-substance, that pass between and around the fibre-cells. Since the latter are fusiform, their transverse areas, irregularly oval or polygonal in outline, vary with the plane of section, being relatively large and nucleated when cut through the middle of the fibre-cell and progressively smaller towards the ends (Fig. 66).

The *blood-vessels* supplying involuntary muscle, meagre in comparison with those of the striped muscle, are guided in their distribution by the septa of connective tissue, in which the larger vessels run. These give off minute branches that terminate in capillary networks which extend between the primary bundles of fibre-cells. Numerous *lymphatics* likewise follow the

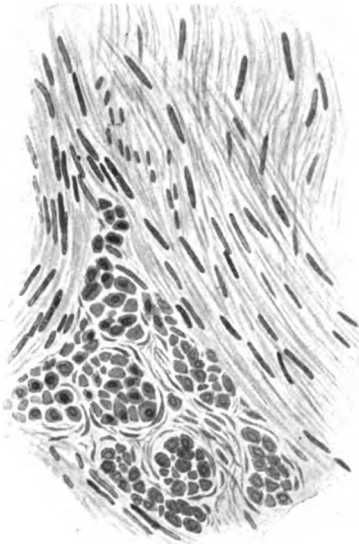


FIG. 67.—Section of uterus, showing bundles of involuntary muscle cut in various directions.  $\times 220$ .

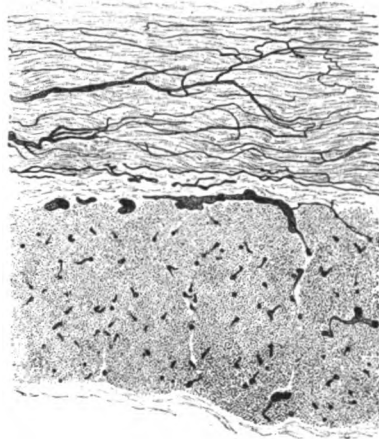


FIG. 68.—Portion of injected intestinal wall, showing arrangement of blood-vessels supplying involuntary muscle; upper layer longitudinally, lower transversely cut.  $\times 50$ .

larger septa of connective tissue. The *nerves* supplying involuntary muscle are sympathetic fibres. The larger trunks form plexuses, closely associated with microscopic ganglia, from which delicate twigs pass between the bundles of fibre-cells. Their ultimate relation with the contractile tissue is described with the Nerve-Endings (page 86).

## CARDIAC MUSCLE.

The contractile tissue constituting the greater bulk of the heart represents a type of muscle which, so far as histological differentiation is concerned, stands between the simpler smooth muscle and the highly complex striated tissue. The striking peculiarity of cardiac muscle, namely its reticular arrangement, is referable to embryonic conditions. The mesenchyma, from which the heart-muscle develops, for a time exists as a protoplasmic reticulum that contains irregularly distributed nuclei but is without cell-boundaries. This tissue corresponds, therefore, to a syncytium. As the syncytial network becomes more compact, owing to the increasing width of its trabeculæ with corresponding diminution of the intervening spaces, delicate contractile threads, the *myo-fibrils*, make their appearance within the reticulum and extend lengthwise through the trabeculæ, without regard to the limits of the future cell-areas. Notwithstanding the differentiation of the greater part of the syncytium into contractile fibrillæ and the conversion of the spongy embryonal tissue into the compact tissue of the heart-wall, evidences of the primary reticular arrangement are seen in the characteristic networks formed by the adult cardiac muscle.

When examined in sections passing parallel to the general course of the fibres (Fig. 69), the heart-muscle exhibits a close irregular reticulum of anastomosing trabeculæ. The latter consist of strands of striated muscle in

which lie oval nuclei, surrounded by pale areas of undifferentiated granular cytoplasm, or *sarcoplasm*, devoid of striations. In cross-sections (Fig. 70), the contractile fibrillæ are seen to be arranged in radiating groups which occupy the periphery of the trabeculæ but do not reach inward as far as the axis. The latter consists of a variable core of sarcoplasm, which surrounds the nucleus and usually contains a small quantity of pigment and fatty particles. In its general histological details, cardiac muscle agrees with typical striated muscle, the alternate light and dark stripes depending upon similar variations




FIG. 69.—Muscle fibres of human heart.  $\times 375$ .

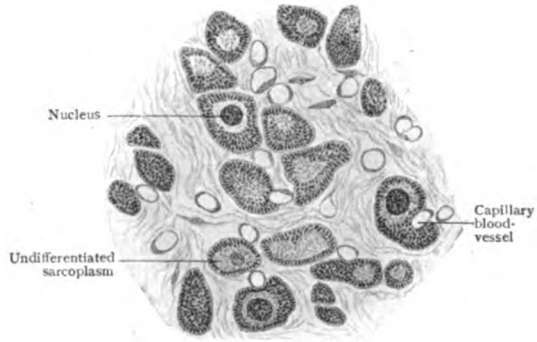


FIG. 70.—Fibres of cardiac muscle in transverse section.  $\times 375$ .

of density along the component fibrillæ. The probable significance of these markings will be considered under Striated Muscle (page 58); suffice it here to indicate the peculiarities in which the muscular tissue of the heart differs from typical striated muscle. Although invested by a delicate sheath, the cardiac fibres do not possess a well defined sarcolemma. Their longitudinal striation, often very distinct, owing to the large amount of sarcoplasm between the groups of fibrillæ, is seemingly interrupted at intervals by dark transverse markings, the *intercalated disks*. Examination of suitably prepared material, under high power, shows, however, that the contractile fibrillæ do not suffer interruption, but are continued without break across the intercalated disks. Further, the disks do not lie on the same plane, but at different levels. After dissociation reagents, such as a solution of caustic potash, heart-muscle breaks up into irregularly branched pieces, the so-called *fibres*. The lines of fracture correspond in position with the intercalated disks and, consequently, the ends of the isolated fibres often are not straight, but exhibit a series of offsets like steps. The incessant contraction of the cardiac muscle, necessitated by its function, is reflected in its structure, the unusually large amount of sarcoplasm which it contains recalling a similar condition observed in the "red" skeletal muscles (page 59), in which a lower degree of differentiation seems associated with the power of enduring frequently repeated contraction.



## STRIATED MUSCLE.

The striped muscular tissue forms the conspicuous masses known as the "muscles" or "flesh" attached to the bony framework of the body. These organs are the active agents in moving the passive levers, the bones, and in producing the movements of the animal. The structural unit of voluntary muscle is the transversely striated *muscle-fibre*, which represents a highly specialized cell. The fibres are the contractile elements by whose shortening the length of the entire muscle is decreased and its force exerted.

The **muscle-fibres** are cylindrical, or prismatic with rounded angles, in form and vary from .01-.1 mm. in diameter. No constant relation exists between the thickness of the fibres and the size of the muscle of which they are components, and, indeed, their diameter varies in the same muscle. The length of the muscle-fibres is likewise subject to great variation. As a rule, the fibres are of limited length, not exceeding from 4-5 cm.; in exceptional cases, as in the sartorius muscle, they may attain a length of over 12 cm. The fibres are usually slightly larger in the middle than at the ends, which are more or less pointed, but sometimes blunted or club-shaped or, rarely, branched. Branched and anastomosing fibres occur in the lingual, facial and ocular muscles.

Each muscle-fibre corresponds to an enormously elongated multinucleated cell and consists of a sheath, or *sarcolemma*, and the contained *sarcous substance*. The sarcolemma forms a complete investment of the fibre and alone comes in contact with the surrounding connective tissue by which the muscle-fibres are attached to one another or to the fibrous structures upon which they directly exert their pull. The **sarcolemma** is a transparent, homogeneous, elastic membrane and envelops the contained sarcous substance so closely that, under ordinary conditions, it is almost or entirely invisible. Being tougher than the muscle-substance, it often withstands teasing with needles while the muscle is broken; where such breaks occur, the muscle-substance sometimes contracts within the sarcolemma, which then becomes visible at the fractures as a delicate tubular sheath (Fig. 71). Sometimes the sarcolemma may be seen projecting beyond the sarcous substance, as a coat sleeve covers the stump of an arm.

The **sarcous substance**, everywhere enclosed within the sarcolemma, also consists of two parts, the less differentiated and passive *sarcoplasm* and the highly specialized *contractile fibrillæ* in which take place the active changes resulting in the contraction of the muscle-fibre. The characteristic cross-striation, resolvable into alternating light and dark bands, that distinguishes the fibres of voluntary muscle depends upon the constitution and arrangement of the contractile fibrillæ. These are threads of great tenuity, which extend the entire length of the muscle-fibre and present series of alternating light and dark segments that probably correspond to differences of density. The dark denser areas are doubly refracting (*anisotropic*); the light less dense ones are singly refracting (*isotropic*). The cross-striation of the muscle-fibre as a whole results from the definite and orderly arrangement of the fibrillæ. Close lateral approximation of the denser and deeply staining

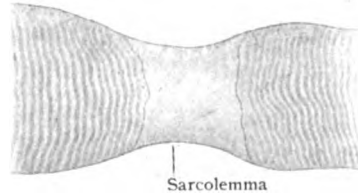


FIG. 71.—Portion of muscle-fibre, showing sarcolemma bridging break in sarcous substance.  $\times 370$ .

segments of the fibrillæ, lying side by side within the sarcolemma, produces the impression of the dark band; the similar relation of the less dense and slightly staining segments produces the light band.




FIG. 72.—Diagrams illustrating structure of striated muscle-fibre. *A*, usual view; *B*, correct view, showing sustentacular septa continued across fibre from sarcolemma. *Z*, intermediate disk (*Zwischenscheibe*); *J*, light band; *Q*, transverse disk (*Querscheibe*); *M*, median disk (*Mittelscheibe*); *S*, sarcolemma. (After *M. Heidenhain*.)

If it were possible to isolate the individual contractile fibrillæ, each would exhibit the details shown in the accompanying diagram (Fig. 72). The dark broad *transverse disk* (*Q*) of anisotropic substance is succeeded at each end by the light band (*JJ*) of isotropic substance. The light band is subdivided by a delicate line, the *intermediate disk* (*Z*), also known as *Krause's membrane*. The sequence which by repetition makes up the contractile fibrilla is, therefore,  $Z + J + Q + J + Z$ . In favorable preparations, the transverse disk appears less dense and lighter midway between its ends where it is traversed by a delicate line (*M*), the *median disk* (Hensen) or *middle membrane* (Heidenhain). The striped muscle of certain insects exhibits an additional band, the *accessory disk*, subdividing the light zone, *J*. The interpretation of these details, shown as ordinarily seen under moderately high magnification in

Fig. 73, has been the subject of vexed discussion. This has been particularly true of the significance of the intermediate disk or membrane of Krause, which is attached to the inner surface of the sarcolemma and extends completely across the muscle-fibre. This arrangement, however, does not imply that the fibre is composed of a series of separate discoidal segments, but rather that the membrane serves to maintain in definite order the contractile fibrillæ, which, while perhaps attached to the membrane, pass uninterruptedly through it.

The distribution of the contractile fibrillæ within the fibre is not uniform, since the fibrillæ are grouped into minute bundles, the *muscle-columns* or *sarcostyles*. This arrangement is shown in transverse

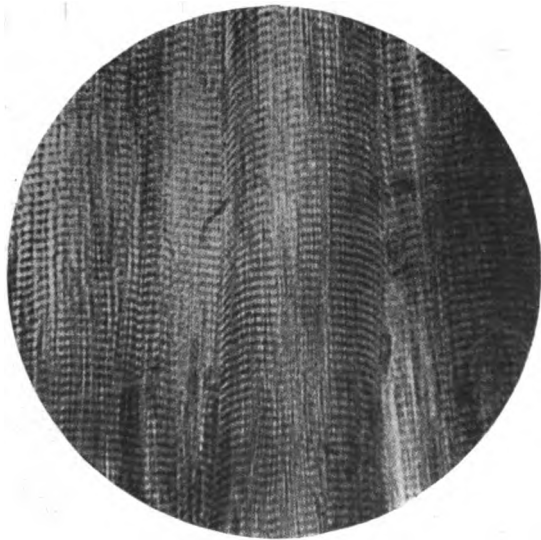


FIG. 73.—Photograph of striated mammalian muscle, showing the usual appearance under moderately high magnification.  $\times 700$ .

sections of muscular tissue (Fig. 74), in which the individual fibres are seen to be made up of stippled areas separated by clear lines. These areas,

known as *Cohnheim's fields*, represent the transversely cut groups of contractile fibrillæ, each dot corresponding to a sarcostyle. The clear lines indicate the distribution of the sarcoplasm; in addition to intervening between the fields of Cohnheim, the sarcoplasm separates the groups of individual fibrillæ, each sarcostyle being entirely surrounded by the less highly differentiated substance.

Each muscle-fibre corresponds to a multinucleated cell. The numerous nuclei result from division of the nucleus of the embryonal cell, the *myoblast*, and remain embedded within the sarcoplasm as the *muscle-nuclei*. Their usual position in mammalian muscle is immediately beneath the sarcolemma; in certain fibres, however, as in the "red" fibres of the ocular and respiratory muscles, the nuclei lie more deeply embedded, therein agreeing in position with the nuclei in the muscles of many lower vertebrates.

The individual muscle-fibres, each invested in its sarcolemma, are grouped into small *primary bundles*, the component fibres of which are held together

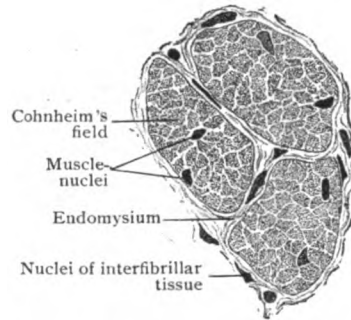


FIG. 74.—Muscle-fibres of lizard in transverse section, showing fields of Cohnheim and muscle-nuclei.  $\times 650$ .

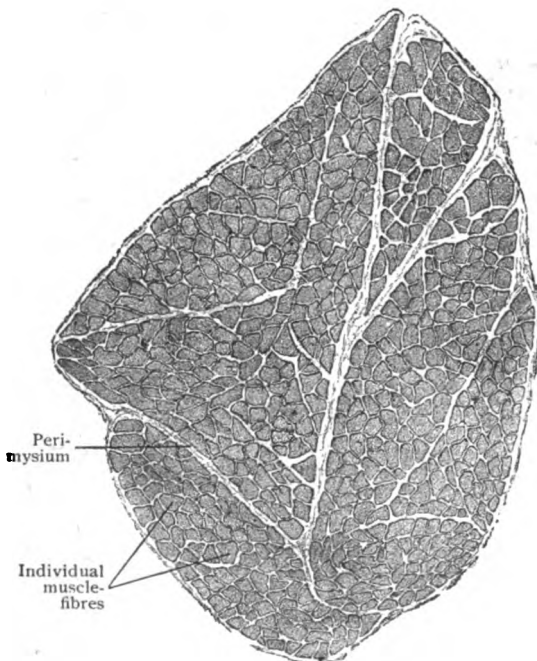


FIG. 75.—Several primary muscle-bundles in transverse section, showing the arrangement of component fibres.  $\times 40$ .

by a small amount of connective tissue, the *endomysium*. The latter is continuous with the envelope of the primary bundles, the *perimysium* (Fig. 75). The primary bundles are associated into uncertain groups, the *secondary bundles*, which are united and surrounded by extensions and subdivisions of the general connective tissue sheath of the muscle, the *epimysium*. In muscles possessing a fine grain, the secondary bundles correspond with the *fasciculi*, but in muscles of coarse texture each fasciculus includes a number of secondary bundles.

Although the skeletal muscles are usually pale in tint and contract energetically when stimulated, particular muscles of certain animals, as the semitendinosus and the soleus of the rabbit, exhibit a deeper color and contract more slowly and prolongedly under stimulation. Such *red muscles*, as they are called, are composed of fibres which are thinner than common and

possess a relatively large amount of sarcoplasm, with nuclei embedded not only beneath the sarcolemma, but also in deeper parts of the fibres (Fig. 76). Although not present in mammals generally in sufficient numbers to affect the appearance of entire muscles, the "red" fibres occur probably in all striated muscular tissue upon which devolves prolonged and frequently repeated effort. Such fibres, therefore, are present in the heart, eye-muscles, and the muscles of respiration and of mastication. Possessing, as they do, a larger proportion of undifferentiated cytoplasm, the sarcoplasm, the red fibres are better able to withstand the fatigue of contraction. The pale

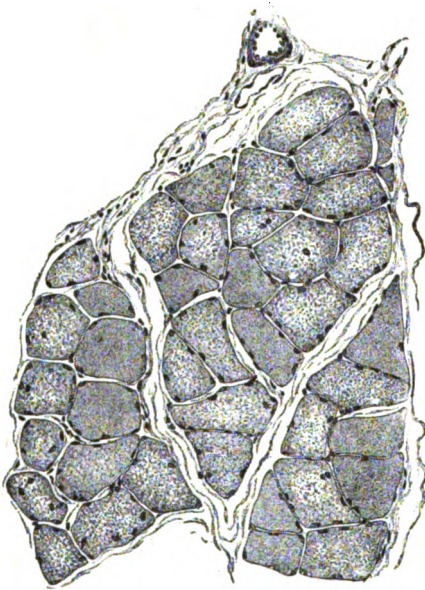


FIG. 76.—Portion of the soleus muscle of the rabbit in transverse section. The more coarsely stippled fibres are of "red" muscle; they also contain nuclei within the sarcous substance.  $\times 160$ .

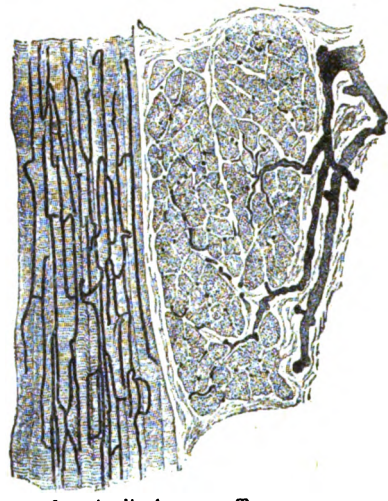


FIG. 77.—Injected voluntary muscle, showing arrangement of inter-fascicular vessels and capillaries.  $\times 50$ .

fibres, on the contrary, gain in rapidity of contraction at the expense of early exhaustion.

The **blood-vessels** supplying striated muscle are very numerous. The larger arteries and accompanying veins enter the muscle along the connective tissue septa and divide into smaller branches which run between the fasciculi. These vessels give off twigs which pass between the finer bundles of fibres and ultimately break up into dense capillary networks that surround the individual fibres with long rectangular meshes. The relation of the blood-vessels to cardiac muscle is exceptionally intimate, the capillaries not only enclosing the trabeculæ with rich networks, but also lying in grooves, or even in channels, surrounded by the muscular tissue. The **lymphatics** are represented by the clefts within the connective tissue around the fibres and by definite lymph-vessels which accompany the blood-vessels in the larger tracts of connective tissue. The **nerves** supplying striated muscle include both motor and sensory fibres. The former terminate in specialized end-arborizations, the *motor nerve-endings*, which lie beneath the sarcolemma and upon the sarcous substance. The sensory fibres are connected with the neuro-muscular end-organs, or *muscle-spindles*. The description of both varieties of terminations will be found under the Nerve-Endings (pages 84, 85).

**Development of Muscular Tissue.**—With the exception of the involuntary muscle connected with the sweat-glands and the dilator fibres of the iris, all of which probably arise from the ectoderm, muscular tissue is a derivative from the middle germ-layer. The voluntary muscles composing the skeletal group, however, arise from the modified mesoderm that forms the periphery of the quadrate areas, or *somites*, of the early embryo, while the tracts of involuntary muscle and the heart-muscle are developed from the mesenchyma. The details of their histogenesis vary in each case. Since *involuntary muscle* is the musculature of the viscera, it generally develops within the walls of tubes. Certain of the mesenchymal cells undergo proliferation and elongation and gradually assume the characteristics of the

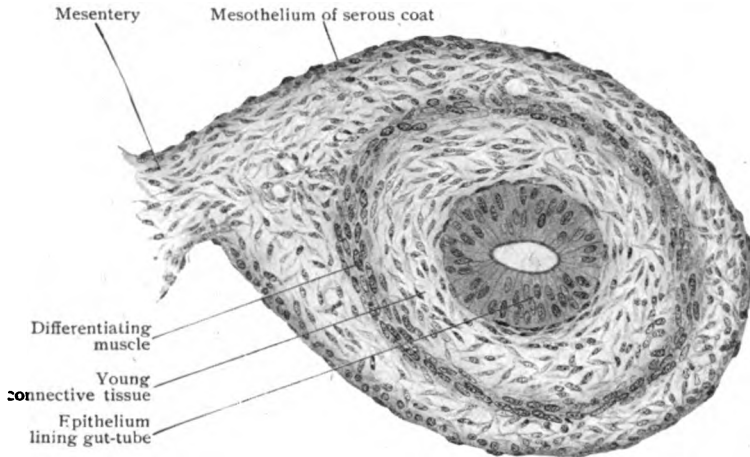


FIG. 78.—Section of developing intestinal wall, showing differentiation of involuntary muscle from splanchnic mesoderm.  $\times 180$ .

fusiform fibre-cell. Their primary loose arrangement gives place to compactness with reduction of the intervening connective tissue.

The *cardiac muscle* originates from the nucleated protoplasmic reticulum, the syncytium, formed by the mesenchyma of the early heart-tube. Contractile threads, the myo-fibriles, make their appearance within the protoplasmic trabeculæ and increase in number by longitudinal splitting. The contractile fibrillæ are for a time homogeneous, but later undergo differentiation in density into light and dark segments, which produce the general transverse striation of light and dark bands. The contractile fibrillæ are not uniformly distributed throughout the substance of the trabeculæ, but appear in groups that condense into narrow wedges, whose bases lie at the periphery of the fibre, with the thin edges towards the centre. The portion of the cytoplasm which is not converted into fibrillæ remains as an undifferentiated sarcoplasm, filling the intervals between the groups of contractile threads. After the appearance of the intercalated disks, the trabeculæ are subdivided into irregular areas, the so-called muscle-fibres, which seem to have only a questionable morphological significance as fundamental units. With the progressive increase in the muscular substance, the intertrabecular spaces and the contained embryonal connective tissue rapidly diminish, the former spongy tissue becoming finally condensed into the definitive heart-muscle.

The *striated muscle* fibres arise from the greatly elongated myoblasts of the mesodermic somites. At first spindle shaped and composed of granular cytoplasm, the embryonal cell increases rapidly in length, while its nucleus

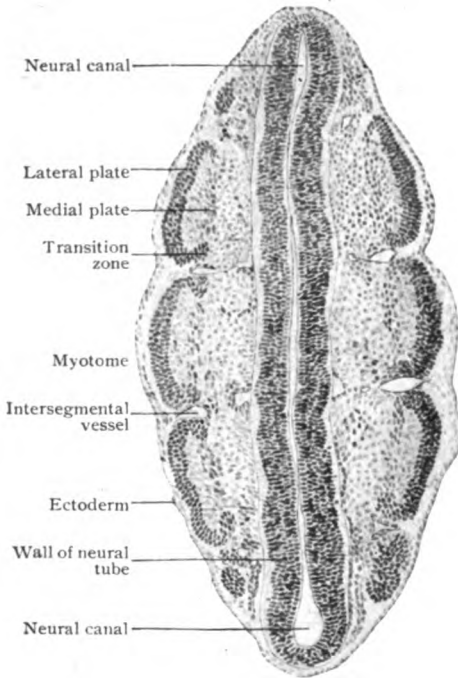


FIG. 79.—Frontal section of rabbit embryo, showing myotomes.  $\times 98$ .

undergoes active proliferation, but for a time is devoid of all fibrillæ. These appear first in the periphery of the young muscle-cell and probably arise by fusion of linear rows of granules. They increase in number by longitudinal cleavage and are disposed in groups separated by the undifferentiated sarcoplasm. During the growth, the nuclei migrate from the interior to the surface of the fibre, where, beneath the sarcolemma already formed, they are found regularly arranged in the completely differentiated fibre, in which relatively little sarcoplasm remains. Coincident with the growth and increased number of the muscle-fibres, the intervening embryonal connective tissue becomes reduced to the meagre endomysium holding the individual fibres together, while that surrounding the primary bundles becomes the perimysium and the general muscle-sheath. During the growth of the young muscle, actual increase in the

number of fibres occurs, but even during childhood, and, still more, subsequent to attaining its full size, enlargement is due chiefly to increased diameter of the existing fibres owing to multiplication of the fibrillæ.

**Attachment.**—The attachment of the muscle fibres, whether to one another or to tendons, aponeuroses, periosteum or fasciæ, is accomplished by the union of the fibrous attachments with the strands of connective tissue between the fibres and never directly with the sarcous substance. On joining a tendon, the pointed or obliquely ending fibres, completely enclosed within the sarcolemma, are received between the tendon-bundles (Fig. 82) which fuse with the endomysium. A similar relation obtains where a muscle is inserted into the periosteum or a fascia; but where the

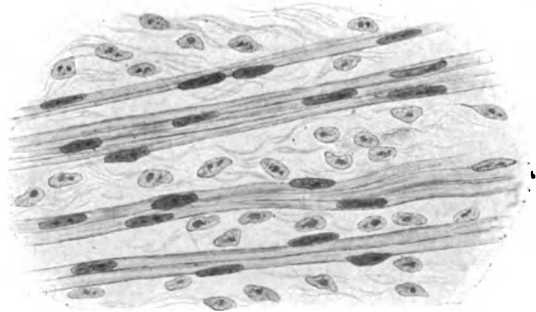


FIG. 80.—Developing voluntary muscle; the fibres are still unstriated.  $\times 525$ .

number of fibres occurs, but even during childhood, and, still more, subsequent to attaining its full size, enlargement is due chiefly to increased diameter of the existing fibres owing to multiplication of the fibrillæ.

muscle is attached to the skin, the radiating muscle-fibres are continued by tendon-bundles of connective tissue rich in elastic fibres, an arrangement well adapted to distribute evenly the pull of the muscle upon the integument.




FIG. 81.—Developing muscle-fibres in which the striation is just appearing.  $\times 375$ .

The **aponeuroses** correspond in structure closely with the tendons, being composed of parallel bundles of dense fibrous tissue which are arranged to form membranous structures.

The **fasciæ** consist of feltworks of bundles of white fibrous tissue with a variable, usually considerable, proportion of elastic fibres. Where very dense, as in the fascia lata, they somewhat resemble tendon-tissue, the component bundles of fibro-elastic tissue being compactly disposed, although interwoven and lacking in uniform placing, and containing little fat. The superficial fasciæ, on the other hand, consist of loosely felted fibro-elastic strands and ordinarily support considerable, at times inordinate, masses of adipose tissue. Where the fascia serves as a muscle-sheath, it contains little fat but an unusual number of elastic fibres, by virtue of which it accommodates itself to the changing form of the enclosed muscular tissue.

**Tendon-sheaths.**—Where tendons play in bony grooves, or where it is necessary to overcome some tendency to displacement, they are bound down and held in place by bands of dense fibrous tissue, which either convert the grooves into canals or form tubular investments that enclose the tendons, although allowing free longitudinal movement. These connective tissue envelopes constitute the *tendon-sheaths* and may surround more than one tendon. Each sheath consists of an outer *fibrous tunic* (*vagina fibrosa*) composed of dense fibro-elastic bundles, continuous with the periosteum at the margins of the groove, and an inner *synovial tunic* (*vagina mucosa*), which lines the deeper surface of the fibrous sheath and at the ends, or next the bone, is reflected, onto the tendon. The latter, therefore, is more or less completely surrounded by a double-walled cylinder, whose cavity is filled with a fluid serving to diminish friction during the play of the tendon. The synovial tunic resembles the lining of joint-cavities, being clothed with an imperfect layer of endothelial plates. In the larger sheaths, minute vascular projections recall the synovial villi.



FIG. 82.—Section of tendon showing the termination of the muscle-fibres.  $\times 200$ .

**Bursæ.**—In situations in which a muscle or tendon moves over a bony prominence, or in which two tendons glide upon each other, the intervening areolar tissue contains a space filled with fluid, termed a *bursa*. Such bursæ, whose evident purpose is to diminish friction, are abundant in connection with the limb-muscles and in the vicinity of the large articulations may communicate with the synovial cavities. Conspicuous examples of such relation are the subscapular bursa, which opens into the shoulder-joint, and the suprapatellar bursa, which communicates with the cavity of the knee-joint. *Subcutaneous bursæ* are also developed in the areolar tissue separating the superficial and deep fasciæ in situations in which the skin glides over a bone and is subject to pressure, as over the tip of the elbow. The immediate lining of the bursal sac consists of an incomplete endothelial investment, while the wall of the sac itself is composed of dense fibro-elastic tissue.

## NERVOUS TISSUE.

The nervous system—the complex apparatus by which the organism is brought into relation with its surroundings and by which its various parts are united into one coördinated whole—consists of structural units, the *neurones*, held together by a special sustaining tissue, the *neuroglia*, assisted by ingrowths of the surrounding connective tissue. The *neurone*, the morphological unit of the nervous system, includes a nucleated protoplasmic accumulation, the *cell-body*, and the *processes*. The former, usually spoken of as the *nerve-cell*, presides over the nutrition of the neurone and, in many cases, is the seat of the subtle changes giving rise to nervous impulse. The processes originate as outgrowths from the cell-body during development and provide the conduction paths along which impulses are conveyed. They are very variable in length, some extending only a fraction of a millimeter

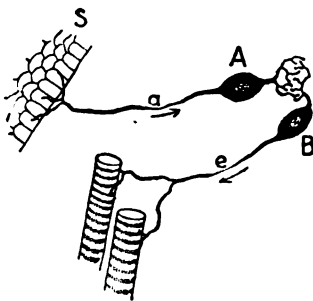


FIG. 83.—Diagram showing fundamental units of nervous system. A, sensory neurone, conducting afferent impulses by its process (a) from periphery (S); B, motor neurone sending efferent impulses by its process (e) to muscle.

beyond the cell-body, while others continue many centimeters to distant parts of the body. The longer processes usually acquire protecting sheaths and are known as *nerve-fibres*. These are associated into bundles and constitute the nerves that pass to the muscles and various other organs.

Reduced to its essential parts, the nervous system consists of two units. The one, the *sensory neurone*, takes up the stimulus received upon the skin or other sensory surface and, by means of its process (nerve-fibre), conveys such impulse from the periphery towards the aggregations of nerve-cells that lie in the vicinity of the body-axis. Functionally, such a path consists of an *afferent fibre*. The impulses thus carried are transferred to the second unit, the *motor neurone*, which, in response, sends out the impulse originating within the cell-body (nerve-cell) along the process known as the *efferent fibre* to the muscle-fibre and causes contraction. The assumed simple relations of the foregoing nervous apparatus are, in fact, superseded by much greater complexity in consequence of the introduction of additional units, by which the sensory impulses are distributed to nerve-cells situated not only in the immediate vicinity of the reception-cell, but at different and often distant levels.



During the evolution of the nervous system from the simpler type, the cell-bodies of the neurones forsake their primary superficial position and recede from the periphery. This recession is expressed in the axial accumulation of the cell-bodies either within the wall, or in the immediate vicinity of the neural tube (brain and spinal cord), to or from which the processes pass. The nervous system is often divided, therefore, into a *central* and a *peripheral* portion. The former, also known as the *cerebro-spinal axis*, includes the brain and spinal cord and contains the chief axial collections of nerve-cells. The *peripheral nervous system*, on the contrary, contains the nerve-cells of the sensory ganglia and is composed principally of the nerve-fibres that pass to and from the end-organs. Intimately associated with and in fact a part of the peripheral nervous system, but at the same time possessing a certain degree of independence, stands the *sympathetic system*, which provides for the innervation of the involuntary muscle and glandular tissue throughout the body and the muscle of the heart.

**The Neurones.**—As before stated, the neurones consist of the cell-body (nerve-cell) and the processes. The latter, as seen in the case of a typical motor neurone extending from the spinal cord to a muscle, are of two kinds: (*a*) the branched protoplasmic extensions, the *dendrites*, which are usually multiple and form elaborate arborescent ramifications that establish relations with other neurones, and (*b*) the single unbranched *axone* (neuraxis, neurite) that ordinarily is prolonged to form the core or axis-cylinder of a nerve-fibre, and, hence, is also often termed the *nerve- or axis-cylinder process*. Although "chained" together as the links that form the various paths along which impulses are conveyed, the neurones are seldom, if ever primarily, actually united to one another, but only intimately related. Their processes, although in close contact, are not directly continuous, contiguous and not continuity being the ordinary relation.

The *dendrites* are usually uneven in contour and robust as they leave the cell-body (nerve-cell), but rapidly become thinner in consequence of their repeated division, until they are reduced to delicate threads that constitute the terminal arborizations, the *telodendria*, formed by the end-branches. The latter are beset with minute enlargements, or varicosities, and finally end in terminal bead-like thickenings. The *axone*, slender and smooth and of uniform thickness, is much less conspicuous than the dendrites. It may be short and extend only to nearby cells, or it may be of great length and connect distant parts that lie either wholly within the cerebro-spinal axis (as from the brain-cortex to the lower part of the spinal cord) or extend beyond (as from the lower end of the spinal cord to the plantar muscles of the foot). On reaching its destination, the axone terminates in an end-arborization or telodendrion, in a manner

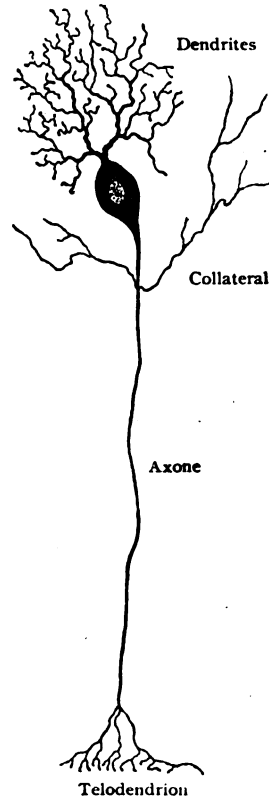


FIG. 84.—Diagram of typical neurone.

similar to the dendrites. Neurones are divided according to the distribution of their axones into two classes. In those of the first class, known as *type I cells*, the axone is continued as a nerve-fibre and is, therefore, relatively long.

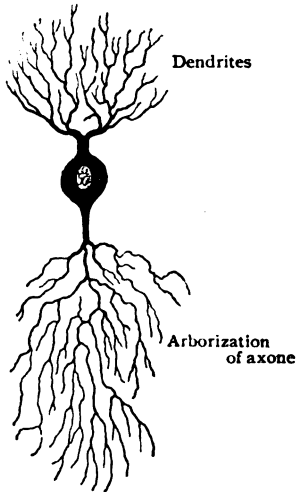


FIG. 85.—Diagram of nerve-cell of type II, in which axone is not prolonged as nerve-fibre.

Soon after leaving the cell-body (nerve-cell), such axones give off delicate lateral processes, the *collaterals*, which, after a longer or shorter course, break up into arborizations that end in relation with other and often remote neurones. The neurones composing the second and much less frequent class, *type II cells*, possess short axones that are not continued as nerve-fibres, but almost immediately break up into complex end-arborizations or *neuropodia*, limited to the gray matter.

The **nerve-cells**, as the cell-bodies of the neurones commonly are called, are in general relatively large elements, those in the anterior horns of the spinal cord measuring from 70–150  $\mu$ . They possess a large spherical nucleus, poor in chromatin but usually provided with a conspicuous nucleolus. Their cytoplasm varies in appearance with the method of fixation and staining to such an extent, that much uncertainty exists as to the relation of many described details to the actual structure of the cells. It is probable,

however, that the cell-body of the neurone consists of a *ground-substance*, homogeneous or finely granular, in which delicate *fibrillæ* and masses of *chromatophilic granules* are embedded; in addition a variable amount of brown or blackish *pigment* is usually present in the vicinity of the nucleus. The fibrillæ, which are continued into all the processes as far as the terminal arborizations, form a dense network surrounding the nucleus that is enclosed by a superficial one. After special staining with methylene blue, the chromatophilic granules appear deeply colored and grouped in variable masses, known as *Nissl bodies*, which occupy the interstices of the fibrillar reticulum. Collectively the granules of "stainable substance" constitute the *tigroid substance* and are most conspicuous in the neighborhood of the nucleus and least so at the periphery of the cell. They are continued into the dendrites as elongated flakes that finally resolve into scattered granules along the processes. The axone, on the contrary, does not contain Nissl bodies, and usually joins the cell-body at an area free from the stainable substance, the process usually arising from a slight elevation known as the *implantation cone*.

Exceptionally, the axone arises from one of the dendrites, either at its base or at some distance from the cell-body. Owing to the size of the cells, little more than the stumps of the processes are ordinarily seen in sections.

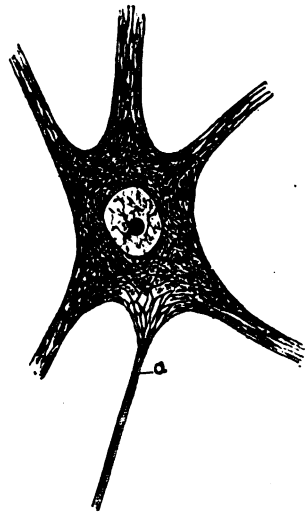


FIG. 86.—Semidiagrammatic representation of structure of neurone; a, axone.

Every neurone possesses at least one process, which is then an axone, although usually provided with both dendrites and axone. Very rarely more than one axone is present. Depending upon the number of their processes, neurones are described as *unipolar*, *bipolar* or *multipolar*. The **unipolar neurones** occur only among the lower vertebrates, the apparent examples seen in the familiar cells composing the spinal and other ganglia connected with sensory nerve-fibres resulting from secondary changes. Primarily, such neurones possess an axone and a dendrite, which pass from the opposite ends of the young oval cell. During development, however, the unilateral growth of the cell-body brings about the gradual approximation of the two processes until they fuse in the single extension into which the flask-shaped cell is prolonged.

Examples of **bipolar neurones**, in which the dendrite and axone pass from opposite sides of the cell-body, are found in the retina and the ganglia connected with the acoustic nerve. An interesting modification of bipolar neurones is presented by the olfactory cells, whose dendrites are

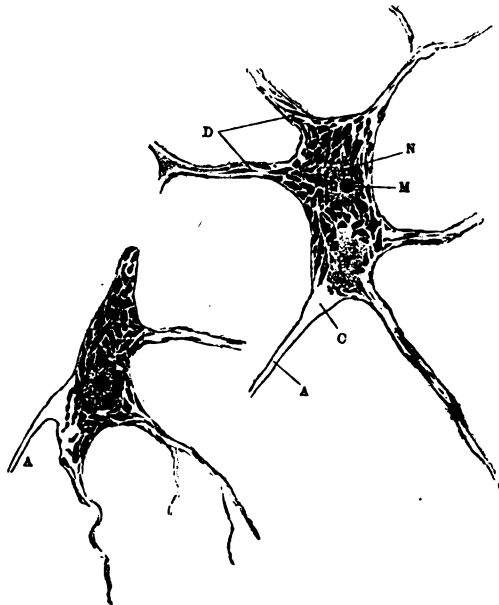


FIG. 87.—Nerve-cells of human spinal cord stained to show Nissl bodies; *D*, dendrites; *A*, axones; *C*, implantation cone; *N*, nucleus; *M*, nucleolus.  $\times 400$ .

represented by the short microscopic processes embedded within the nasal mucous membrane, whilst the axones are prolonged as the fibres of the olfactory nerves.

The cell-bodies of the **multipolar neurones**, which possess one axone and several dendrites, vary in form. Some, as those within the sympathetic ganglia, are approximately spherical and of moderate size, with short delicate dendrites; many are of large size and irregularly stellate form, the dendrites passing out in all directions, as seen in the conspicuous motor neurones within the anterior cornua of the

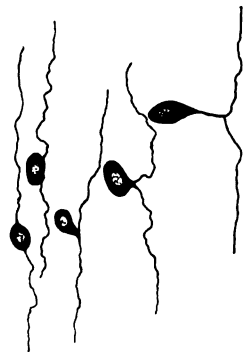


FIG. 88.—Diagram showing transformation of young bipolar sensory neurone into one of unipolar type.

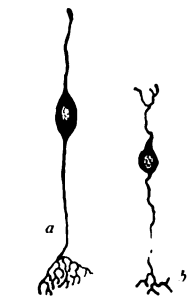


FIG. 89.—Bipolar neurones; *a*, from olfactory mucous membrane—the dendrite is above; *b*, from retina. (Cajal.)

spinal cord; others possess a regular and characteristic outline, as the flask-shaped cells of Purkinje within the cerebellum or the pyramidal cells of the cerebral cortex. Certain multipolar neurones within the cerebral

cortex, and especially those constituting the chief components of the granule layer of the cerebellum, are distinguished by the small size of their cell-bodies and the peculiar ramifications and claw-like telodendria of their dendrites. Within the cerebellar cortex are also found examples of multipolar neurons of type II, whose axones almost immediately undergo branching within the gray matter to which they are connected.

**The Nerve-Fibres.**—From what has been said above, it is evident that nerve-fibres are not independent ele-

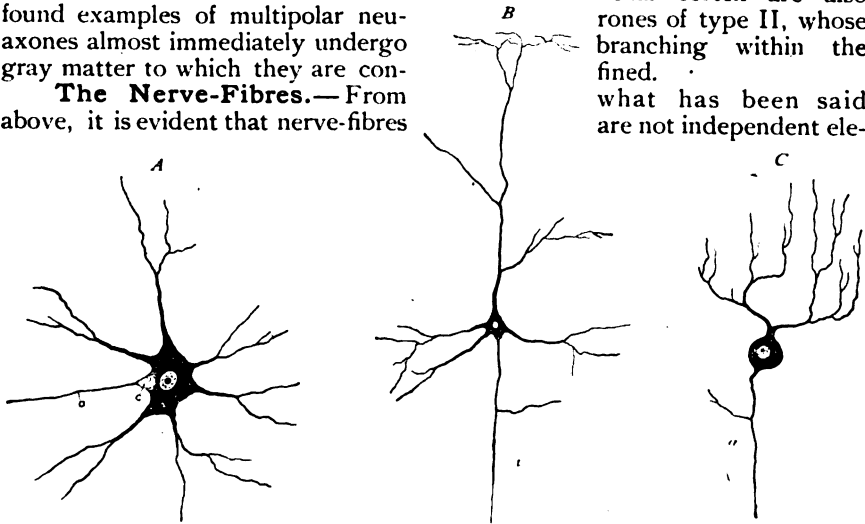


FIG. 90.—Multipolar nerve cells of various forms; A, from spinal cord; B, from cerebral cortex; C, from cerebellar cortex; a, axone; c, implantation cone.

ments, but only the processes of neurones—either the axones that are prolonged as fibres, or the dendrites of neurones situated within the spinal and other sensory ganglia. Although neurones exist which are not continued as nerve-fibres, the converse is not true, since nerve-fibres are always connected with neurones.

The fundamental part of every nerve-fibre is the central cord, known as the **axis-cylinder**, which is composed of delicate threads, the *axis-fibrillæ*, prolonged from the nerve-cell and embedded within a semifluid interfibrillar substance, the *neuroplasm*. In the case of the typical fibres, such as form the chief constituents of the peripheral nerves, the axis-cylinder is surrounded by a relatively thick coat, known as the *medullary sheath*, outside of which lies a thin structureless envelope, the *neurilemma* or *sheath of Schwann*. These coverings, however, do not invest the entire nerve. Thus, for a short distance after leaving the nerve-cell, the axis-cylinder is without covering; soon it becomes surrounded by the medullary sheath, and then, if it be a peripheral nerve, acquires the outer envelope, the neurilemma. In the case of the nerve-fibres that course within the brain and spinal cord, the fibre is devoid of the neurilemma, although it may possess the medullary coat.

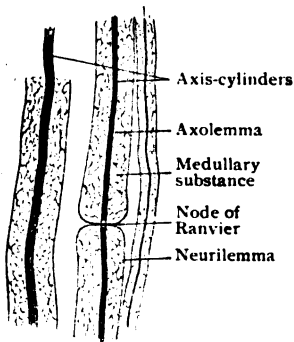


FIG. 91.—Medullated nerve-fibres, as seen in longitudinal section of spinal nerve.  $\times 375$ .

The **medullary sheath** consists of two parts, a delicate reticular *framework* and a fatty substance, the *myelin*, that fills the meshes of the

supporting reticulum. The latter, arranged for the most part as connected membranous lamellæ, resists pancreatic digestion and fat-dissolving reagents and is composed of a substance named *neurokeratin*. The reactions exhibited by myelin indicate its fatty nature, this substance existing during life perhaps in the form of an extremely fine emulsion supported by the framework. When fresh, myelin appears clear and highly refracting and confers upon the nerve-fibres which it covers, "medullated fibres" as they are called, their characteristic whitish color. It is prone to post-mortem changes, so that after death it loses its former uniformity and presents irregular contractions and collections, or extrudes in irregular globules at the ends of the broken fibres. The medullary sheath is not uniformly continuous, but is almost completely interrupted at regular intervals marked by annular constrictions. These constrictions, the *nodes of Ranvier*, correspond to very narrow zones at which the medullary sheath is practically wanting and the neurilemma dips in and comes into close relation with the

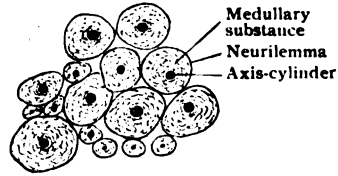


FIG. 92.—Medullated nerve-fibres in transverse section.  $\times 385$ .

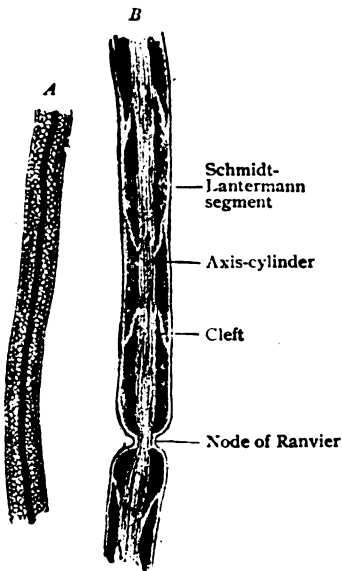


FIG. 93.—Medullated nerve-fibres after treatment with osmic acid; A, fibre showing reticulum within medullary coat; B, one showing same coat divided into segments.  $\times 500$ .

axis-cylinder. The medullary sheath, however, does not suffer complete suppression at the nodes, but is represented by a part of its framework which traverses the constrictions. The latter occur at regular intervals along the fibre which they thus divide into a series of *internodal segments*. In a general way, the segments are longer in large fibres (about 1 mm.), and shorter in those of small diameter, in which they are reduced to .1 mm. or less in length. The axis-cylinder passes uninterruptedly across the nodes and is continuous from its origin in the nerve-cell to its ending in the terminal arborization (telodendrion). The neurilemma also suffers no break at the nodes, but continues from one segment to the other. After treatment with osmic acid, the medullary sheath frequently is broken by clear narrow clefts that extend obliquely from the neurilemma towards the axis-cylinder, and thus subdivide each internodal segment into a number of smaller tracts, known as the *Schmidt-Lantermann segments*. The significance of this subdivision is uncertain, the details being regarded by some as artefacts. Within each internodal segment, beneath the neurilemma, lies a small cell, the *neurilemma cell*, which comprises an elongated oval nucleus surrounded by a meagre amount of cytoplasm. These cells represent the remains of the ectodermic elements (*sheath cells*) that were active during the growth of the nerve-fibre in providing its envelope.

According to the presence or absence of the medullary coat throughout the greater part of their course, nerve-fibres are designated as medullated or

nonmedullated. The *medullated fibres* constitute the majority of those making up the peripheral nerves and the fibre-tracts within the cerebro-spinal axis. The fibres within the latter, however, while medullated are without a neurilemma. The *nonmedullated fibres*, on the other hand, are chiefly prolongations (axones) from the ganglion-cells of the sympathetic system, although in the case of the olfactory nerves the fibres are without a neurilemma. The distinction between these two classes of nerve-fibres, however, is relative rather than absolute, since every medullated



FIG. 94.—Nonmedullated nerve fibres in longitudinal section of splenic nerve.  $\times 310$ .

nerve-fibre becomes nonmedullated not only at its origin from the cell, but also before making its terminal arborization, central or peripheral. Medullated nerve-fibres vary from  $1-20 \mu$  in thickness. According to their diameter, they are grouped as *fine* ( $1-4 \mu$ ), *medium* ( $5-9 \mu$ ) and *coarse* ( $10-20 \mu$ ). In a general way it may be said that the thicker fibres are the longer and are the processes of large nerve-cells; conversely, the finer fibres are shorter and belong to small cells. Although subject to many exceptions, the efferent (motor) fibres are usually the thicker, and the afferent (sensory) the thinner.

Since there are many more peripheral nerve-fibres than nerve-cells, it is evident that the former must undergo division along their course. Such doubling occurs always at a point corresponding to a node of Ranvier, never within an internodal segment, the sheaths being continued on the resulting fibres. On approaching their peripheral termination, the branching becomes more frequent and the medullary sheath thinner until it ceases, after which the axis-cylinder continues covered by only the attenuated neurilemma. The latter, now reduced to an extremely delicate covering beset with occasional nuclei, sooner or later disappears, the naked axis-cylinder alone being thence prolonged to end finally in the varicose threads of the telodendrion. The **nonmedullated nerves proper**, also termed the *pale fibres* or *fibres of Remak*, include those that are devoid of the myelin sheath throughout their course. Such fibres are chiefly the axones of sympathetic neurones. They are often  $2 \mu$  or less in diameter and consist of only the axis-cylinder and the neurilemma, the latter being thin and delicate. The pale fibres, like others, end in terminal arborizations (telodendria) composed of naked axis-cylinders.

**Neuroglia.**—The neurones (nerve-cells and nerve-fibres) within the brain and spinal cord are everywhere held together by a special supporting tissue known as neuroglia. The latter is derived primarily from the invaginated ectoderm which forms the wall of the neural tube, certain elements, the *spongioblasts*, being concerned in the production of the neuroglia, while others, the *neuroblasts*, give rise to the neurones. For a time the supporting tissue is represented by greatly elongated radially disposed fibre-cells that often extend the entire thickness of the wall of the neural tube. Later, the neuroglial elements become differentiated into: (a) those bordering the lumen of the canal, where they are partially retained as the *ependymal cells*; and (b) those which early migrate to more peripheral positions and give rise to stellate *gliogenetic cells* that are converted into spider-like elements (Fig. 95). In chrome-silver preparations these appear as irregular triangular or quadri-

lateral cells from whose angles extend the numerous delicate *fibrillæ* that later become the chief constituents of the neuroglia. So long as neuroglia is being produced, the gliogenetic cells are present and concerned in the production of additional fibrillæ, their cytoplasm becoming progressively reduced until in their final condition of the small *glia cells*, little more than the nucleus remains. During these changes very many fibrillæ lose their connection with the cells and, in conjunction with the glia threads still attached, form an intricate interlacement in which the neuroglia cells, now greatly reduced and for the most part devoid of processes, lie scattered at uncertain intervals.

The mature neuroglia everywhere consists of essentially the same tissues, the differences noted in certain localities depending largely upon variations in its



FIG. 95.—Young neuroglia cells; astrocytes from brain of child.  $\times 300$ .

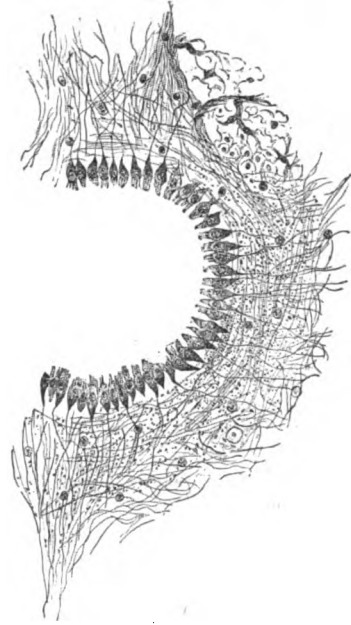


FIG. 96.—Ependymal cells and adjacent neuroglia surrounding central canal of spinal cord of cat.  $\times 75$ . (Rubaschkin.)

compactness. Its chief constituent is the intricate feltwork of *glia-fibres* which are usually free but to some extent connected with the glia-cells. Where, however, the neuroglia borders the brain-ventricles and the central canal of the spinal cord it presents special features. In these situations it forms the *ependyma*, which appears as a single-layered epithelial lining. Within the cord, the cells are pyramidal, their bases looking towards the lumen of the tube and their apices towards the nervous tissue. At least during the earlier years in man, and throughout life in many lower animals, the free surfaces of the cells are beset with hair-like processes resembling the cilia of epithelial cells. The pointed distal ends of the ependymal cells are prolonged into processes continuous with neuroglia fibres that are soon lost in the surrounding glia-complex. Where the ependyma lines the ventricular spaces, the cells are low cuboidal elements that constitute a continuous and single-layered investment, whose primary relation to the surrounding neuroglia is often lost or, at best, obscured.

**The Nerve Trunks.**—The component fibres of the peripheral nervous system are assembled into larger or smaller cords, the “nerves” of gross anatomy, which extend to various parts of the body. Those that supply both muscles and sensory surfaces (integument or mucous membranes), as, for

example, the median or the mandibular nerve, include three sets of nerve fibres: (1) the efferent axones of the motor neurones, whose cell-bodies are situated within the spinal cord or the brain-stem; (2) the afferent dendrites of sensory neurones within the spinal and other sensory ganglia; and (3) the efferent axones of neurones within the sympathetic ganglia that accompany the spinal fibres to the periphery for the innervation of the involuntary muscle of the blood-vessels and of the skin and the glands.

The nerve-fibres, the representatives of the three sets usually more or less intermingled, are grouped into bundles, the **funiculi**, which differ in number and diameter according to the size of the entire trunk that they form. Each funiculus is surrounded by a definite sheath of dense connective tissue,

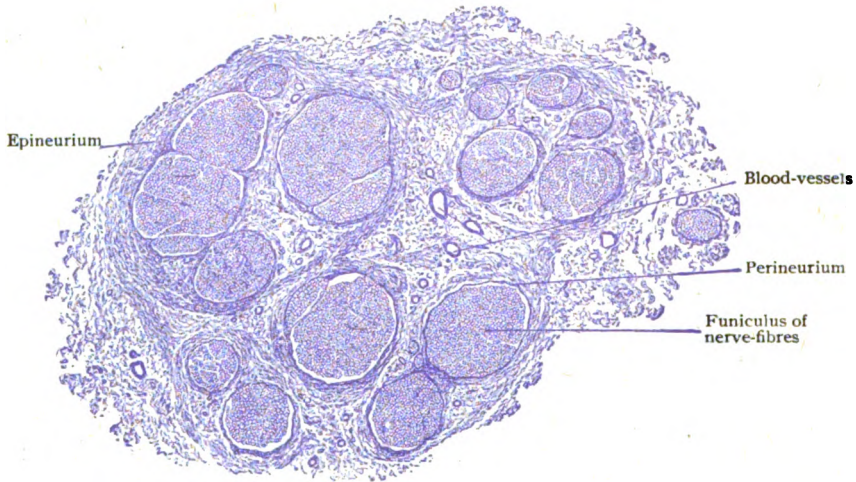


FIG. 97.—Transverse section of small nerve-trunk composed of loosely united funiculi.  $\times 20$ .

the *perineurium*, which is continuous with the delicate fibro-elastic tissue prolonged as the *endoneurium* between the individual nerve-fibres. Where well developed, the sheath of the funiculus consists of concentric fibrous lamellæ, which enclose the *perineural lymph-spaces*. The latter are in relation with the lymph-clefts between the nerve-fibres, on the one hand, and with the lymphatics within the interfunicular tissue on the other. When, as usually is the case, the nerve is made up of several funiculi, these are loosely bound together and the entire nerve-trunk so formed is invested by a general connective tissue envelope, the *epineurium*, in which lie the larger blood-vessels and the lymphatics. These coverings of the nerve-trunk are continued over its branches, even over its smallest subdivisions. The last representative of these envelopes is prolonged over the individual nerve-fibres as the *sheath of Henle*, which lies outside the neurilemma and consists of flattened cells and delicate strands of connective tissue.

In cross-sections of the nerve-trunk (Fig. 98), the transversely cut individual medullated nerve-fibres appear as small circles, sharply defined by a fine outline (the neurilemma), each enclosing a deeply stained dot (the axis-cylinder in section); the interval between the latter and the neurilemma corresponds to the space occupied by the myelin and usually appears clear and unstained, with the exception of delicate and uncertain suggestions of membranous septa. In contrast with the foregoing appearance, is that seen after



the action of osmic acid or special hematoxylin staining (Weigert), the medullary substance then exhibiting a dark color and appearing as a deeply tinted ring which surrounds the axis-cylinder. The neurilemma-nuclei are occasionally seen as deeply stained crescentic figures that partly encircle the

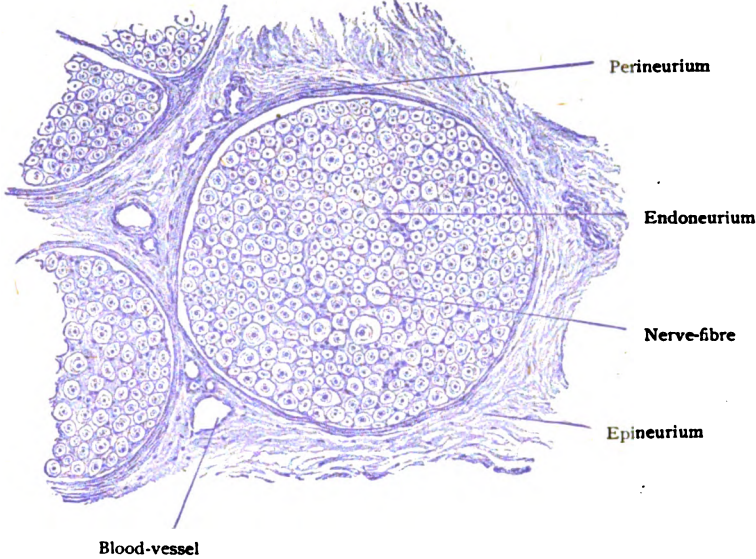


FIG. 98.—Transverse section of funiculus composed of nerve-fibres held together by endoneurium and surrounded by perineurium.  $\times 175$ .

nerve-fibres, lying beneath the neurilemma. Viewed in cross-sections, the non-medullated fibres appear as small irregularly round fields arranged in groups that correspond to bundles. When numerous, the latter are aggregated into secondary bundles between which extend delicate septa of connective tissue, continuous with the general envelope of the nerve-trunk. The fibres being nonmedullated, their diameter is very small, sometimes less than  $1 \mu$ .

**The Ganglia.**—The cell-bodies of the neurones constituting the sensory or afferent paths within the peripheral nerves, as well as those within the sympathetic (visceral) nerves, are collected into aggregations known as ganglia. Familiar examples of the latter are the spinal ganglia on the dorsal roots of the spinal nerves, certain cranial ganglia (as the semilunar [Gasserian] connected with the fifth nerve, the acoustic with the eighth, and those on the trunks of the seventh, ninth, and tenth cranial nerves), and the sympathetic ganglia along the gangliated cords and within the plexuses of the sympathetic.

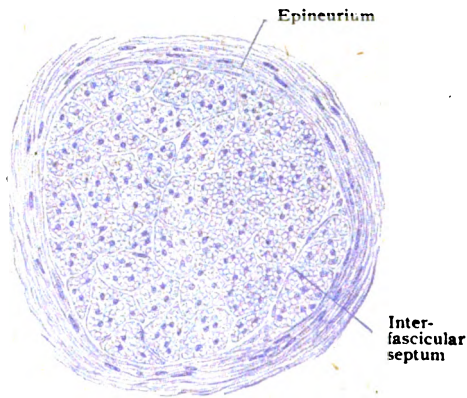


FIG. 99.—Transverse section of small splenic nerve consisting chiefly of nonmedullated fibres.  $\times 180$ .

A longitudinal section of a **spinal ganglion** (Fig. 100), which may be taken as a type of such collections, shows the entire ovoid mass to be surrounded by a *fibrous capsule*, continuous with the epineurium ensheathing the nerves. Immediately beneath the capsule, the ganglion-cells are disposed in a fairly continuous layer of varying thickness, while the more deeply placed cells are broken up into groups by the tracts of nerve-fibres, a small amount of connective tissue prolonged from the endoneurium of the nerve-bundles and accompanying the blood-vessels being also present. The

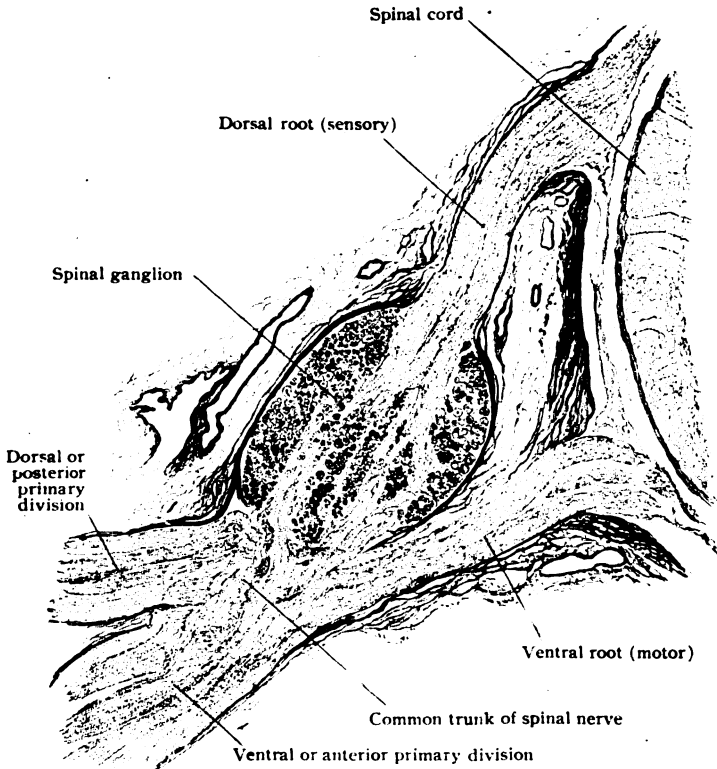


FIG. 100.—Section of spinal nerve, showing its roots, ganglion, common trunk and primary divisions.  $\times 9$ .

majority of the ganglion-cells are from  $60-80 \mu$  in diameter, but some measure as much as  $170 \mu$ , and others as little as  $25 \mu$ . In sections they usually appear round or oval, since only exceptionally are their processes to be seen. Each nerve-cell is surrounded by a *capsule*, lined with flat cells. The nervous elements may be grouped into *large cells*, whose axones give rise to medullated nerve-fibres, and *small cells*, whose axones continue as non-medullated fibres. Depending largely upon the behavior of their axones, Dogiel has described eleven types of nerve-cells of the spinal ganglia. Sympathetic fibres also are present.

The **sympathetic ganglia** correspond in their general structure with those situated on the spinal nerves. They are enclosed by a fibrous capsule, from which prolongations of connective tissue pass into the interior of the ganglion for the support of the nervous elements. The individual ganglion

cells—in mammals always multipolar—are surrounded by nucleated capsules continuous with the neurilemma of the nerve-fibres. Most of the ganglion cells belong to the sympathetic efferent (motor) neurones, whose axones pass as nonmedullated fibres to join the nerve-trunks and finally end in involuntary muscle. Other neurones, whose cell-bodies are more or less triangular, are distinguished by unusually long dendrites that pass, in company with the axone, along the connecting trunk to a neighboring ganglion. Their termination is uncertain, but they probably are sympathetic afferent or sensory neurones. A third and very infrequent variety of neurone possesses richly branched dendrites which form a plexiform arborization in the periphery of the ganglion, while the axone enters a nearby nerve-trunk. Although the axones of the sympathetic neurones for the most part are devoid of medullary sheath, and appear as pale fibres, this condition often applies only to part of their course, since many such processes temporarily acquire a myelin-sheath and run for a variable distance as medullated fibres. The spinal efferents, which join the sympathetic by way of the white rami communicantes, are also

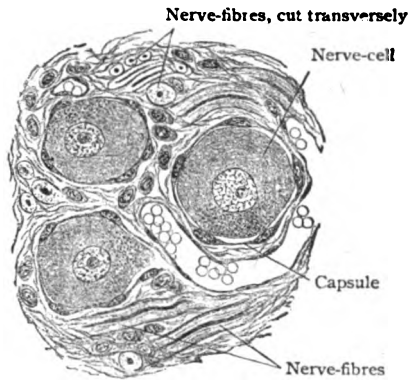


FIG. 101.—Section of spinal ganglion, showing nerve-cells surrounded by nucleated capsules.  $\times 300$ .

medullated fibres. Eventually, they too lose the myelin-sheath and, after a variable but short course as nonmedullated fibres, end in arborizations composed of naked axis-cylinders that surround the sympathetic ganglion cells.

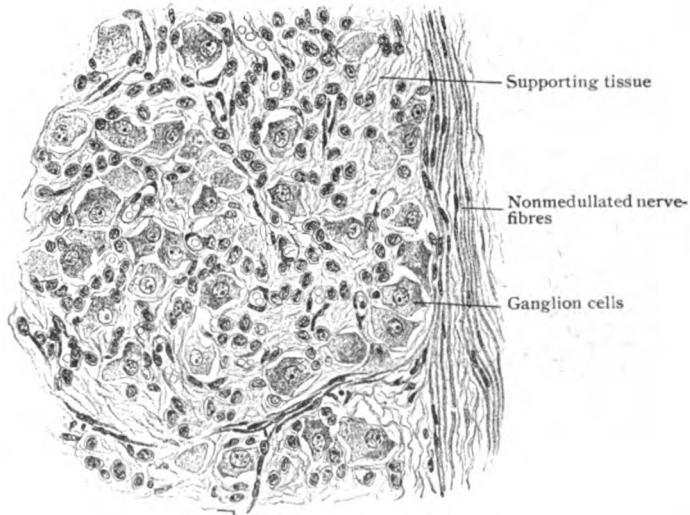


FIG. 102.—Portion of section of sympathetic (semilunar) ganglion from child.  $\times 250$ .

Under the **paraganglia** are included clumps or cord-like collections of cells, which are derived from the formative areas of the sympathetic ganglia and share with cells scattered throughout the sympathetic nerves and ganglia

the peculiarity of being stained yellowish brown by solutions containing chromic acid or chromium salts. In recognition of this affinity, these elements are known as *chromaffine cells* and regarded as related to the sympathetic system. Definite collections of such cells, associated with a complex of blood-vessels along the course of large arteries, occur in the carotid and aortic bodies, as well as within the medulla of the suprarenal body.

#### DEVELOPMENT OF THE NERVOUS TISSUES.

Although the reader must be referred to the larger or special books for a systematic and detailed description of the development of the nervous system, an understanding of the chief features of its histogenesis is so important for an appreciation of

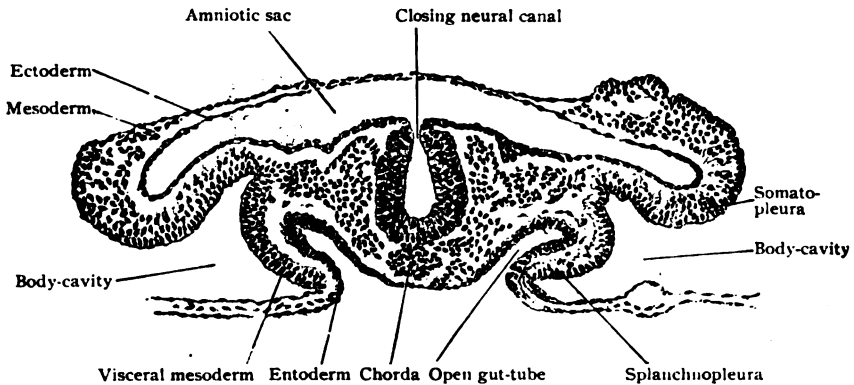


FIG. 103.—Transverse section of rabbit embryo of about nine and one-quarter days.  $\times 80$ . Neural canal is just closing.

the relations of its structural components, that a sketch of these processes finds here an appropriate place.

Among the very earliest phases of the embryo is the formation of a longitudinal furrow, the *neural groove*, bounded by thickened ectoderm and corresponding with the long axis of the embryo. By the approximation and fusion of its dorsal lips, this groove is gradually converted into a closed tube, the *neural canal*.

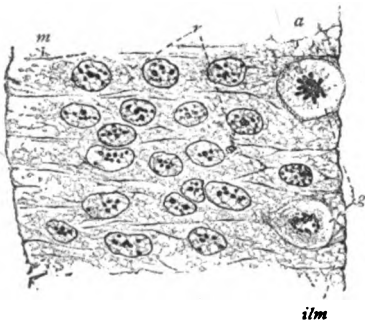


FIG. 104.—Segment from lateral wall of neural tube of pig embryo of 5 mm.; syncytium replacing distinctly outlined cells. *a*, inner zone; *g*, germinal cells; *ilm*, internal limiting membrane; *m*, peripheral zone; *r*, radial strands of cytoplasm.  $\times 690$ . (*Hardensteyn*.)

The walls of this canal, from which all the essential nervous elements are derived, consist at first of only a few layers of the invaginated ectodermic epithelial cells. The latter actively proliferate and become converted into a multinucleated tissue in which the cell-boundaries disappear and the nuclei lie embedded within a general protoplasmic tract or *syncytium*. The larger dividing elements, the *germinal cells*, conspicuous on account of the mitotic figures, lie close to the lumen of the tube. Soon this continuity is interrupted by the appearance of spaces within the syncytium, the cell-substance being resolved into a delicate reticulum, the *myelospangium*. The meshes of the reticulum enlarge, the intervening nucleated tracts elongate, and the increasing nuclei become radially disposed. Following these changes, the elements next the lumen assume a columnar form and radial arrangement and become the *primary ependymal cells*, while the remaining elements, the *indifferent*

cells, increase by the continued division of the germinal cells. The indifferent cells later differentiate into the *spongioblasts*, from which the characteristic constituents of the neuroglia are derived, and the *neuroblasts*, which are directly converted into the neurones.

The *neuroglia* is evolved by the gradual transformation of the spongioblasts and their descendants into fibrillæ and the production of a more definite framework that replaces the primary myelospongium and eventually, in conjunction with the proc-

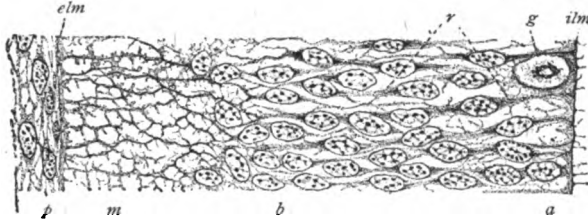


FIG. 105.—Segment of wall of neural tube of pig embryo of 10 mm.; radial strands (*r*) of syncytium and differentiation of ependymal (*a*), nuclear (*b*) and marginal (*m*) layers; *ilm*, *elm*, internal and external limiting membrane; *g*, dividing cell; *p*, pia mater.  $\times 690$ . (*Hardesty*.)

esses derived from the ependymal cells, gives rise to the completed supporting tissue (page 70). The neurones are directly derived from the neuroblasts. The latter are distinguishable from the spongioblasts as soon as they are provided with nerve-processes. These appear as outgrowths from the peripherally directed and pointed ends of the developing nerve-cells. The first, and for a considerable time the only, processes which the motor neurones possess correspond to axones that become the



FIG. 106.—Transverse section of part of developing spinal cord from pig embryo of 30 mm.; *c*, central canal; *ep*, ependymal layer; *n*, nuclear layer; *m*, marginal layer; *r*, radial fibres.  $\times 240$ . (*Hardesty*.)

axis-cylinders of efferent (motor) nerves. Subsequently the dendrites grow out in various directions from the cell-bodies of the young neurones.

The **peripheral nerves**, according to the teachings of His and the views of most anatomists, are essentially outgrowths from the nerve-cells, since the axis-cylinder of the entire nerve-fibre is formed by the peripherally directed growth of the original nerve-process of the neuroblast. The opposed opinion, that the nerve-fibre arises by the fusion of a number of segments, is not in accord with the most recent embryological data. The motor neuroblasts within the spinal cord and the sensory cells within the spinal ganglia send out processes of considerable thickness, which give rise at their extremities to groups of fibrillæ. These increase in thickness and length and, in turn, at their extremities give rise to new groups of fibrils. The latter proceed at first as naked bundles, but soon become surrounded by the *sheath-cells*, which are

of ectodermic origin, and enclose the young developing nerve. After a nerve has become enlarged by the distal ingrowth of fibrils, the sheath-cells wander from the periphery among the fibrillæ, and thus give rise to a network that divides the original fasciculus into a number of secondary bundles. The interfascicular cells increase rapidly, the subdivision continues, and the bundles of fibrillæ become progressively smaller and more compact until, surrounded by membranous septa, they become the *axis-cylinders* of the individual nerve-fibres, enclosed by the *neurilemma* and its cells. The *endoneurium* appears comparatively late and, unlike the neurilemma, is a product of the mesoderm. Later condensations of the mesodermic tissue around the definite bundles of nerve-fibres and around the entire nerve-trunk provide the *perineurium* and the *epineurium* respectively.

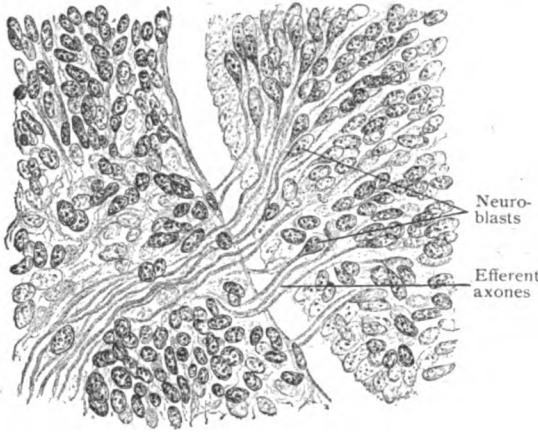


FIG. 107.—Portion of spinal cord of human embryo, showing development of ventral root-axones as outgrowths from ventral neuroblasts.  $\times 300$ . (After His.)

The *medullary sheath* is acquired comparatively late, since it does not appear until about the fourth month of foetal life, some tracts within the central nervous axis, indeed, not obtaining the medullary coat until after birth. It is probable that formation of the medullary substance is in some way influenced by the axis-cylinder, resulting in the deposit of the myelin droplets from the fluid that surrounds the axial thread. Thus, the axis-cylinder is derived from the ectoderm, the neurilemma from the ectoderm, while the medullary sheath is indirectly from the ectoderm.

The *sensory ganglia* develop from groups of ectodermic cells that form a ridge, the *ganglion-crest*, on the margin of either lip of the still open neural tube, just where the general ectoderm passes into that lining the groove. On closure of the latter, the ganglion-crests fuse into a dorsal wedge-shaped mass that becomes a centre of proliferation from which cells migrate outwards over the dorso-lateral wall of the tube. In consequence, a series of segmentally arranged cell-aggregations appears on each side of the neural canal, these collections being the rudiments of the later spinal ganglia. Within them certain cells soon become fusiform and, assuming the rôle of neuroblasts, send out a process from each end. One process, the axone, grows centrally, while the other, the dendrite, extends peripherally and becomes the chief part of a sensory neurone, the afferent nerve-fibre. The subsequent growth of the neurone is not symmetrical, but to one side, so that the two processes approximate and, finally, join the cell-body by a common stalk, the neurone being thus converted into an unipolar ganglion-cell. The centrally directed processes,

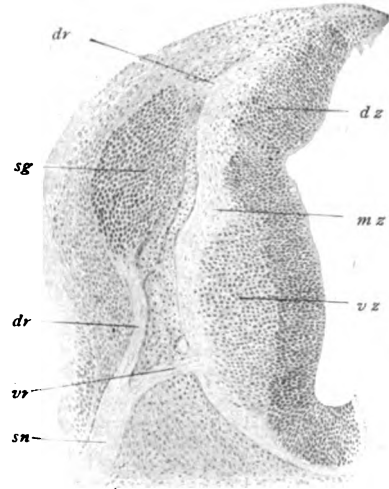


FIG. 108.—Cross-section of part of dorsal region of human embryo, showing development of spinal ganglion; *dz*, *vz*, *mz*, dorsal, ventral and marginal zones of early spinal cord; *dr*, *vr*, dorsal and ventral root-fibres of spinal nerve (*sn*); *sg*, spinal ganglion on dorsal root.  $\times 75$ .

later the dorsal root-fibres of a spinal nerve, grow into the developing cord and enter the immature white matter to end, when development is complete, at various levels in relation with the neurones within the gray matter of the cord. The peripherally directed processes, on the other hand, mingle with the axones from the motor neurones to form the mixed nerves distributed to the various parts of the body. The essential parts of the sensory neurones, the cell-body and the processes, are derivatives of ectodermic elements, while the sheaths, whether of the nerve-cells, of the fibres, or of the entire ganglion, are contributions of the mesoderm.

The **sympathetic ganglia**, which include essentially three sets—those of the gangliated cords, those within the prevertebral plexuses, and those within the organs—are direct descendants of the neurogenetic elements derived from the developing spinal nerves. The earliest suggestions of definite sympathetic ganglia appear about the beginning of the second fetal month as aggregations of neuroblasts at the distal ends of the visceral rami of the developing spinal nerves. From these cells are derived the definite sympathetic neurones of the gangliated cords, as well as those which follow the mesial ingrowth of the spinal fibres for the production of the prevertebral and the terminal ganglia. The ganglia thus established constitute for a time a series of isolated nodes. Subsequently these are connected by the differentiation of sympathetic axones which grow from one young ganglion to the next and, in conjunction with the spinal fibres, form the longitudinal strands of the gangliated cords. Other sympathetic neurones send axones centrally and so assist in producing the efferent splanchnic nerves, whilst still others send axones to accompany the growing efferent somatic spinal trunks.

### NERVE-TERMINATIONS.

The terminations of the fibres composing the peripheral nerves—the axones of certain motor neurones situated within the cerebro-spinal axis and within the sympathetic ganglia and the dendrites of the neurones within the sensory ganglia—supply the apparatus by which the various structures are brought into intimate relation with the central nervous system. Some of these terminations convey impulses that produce various sensations (pain, pressure, muscle-sense, temperature); others transfer impulses resulting in muscular contractions. The nerve-terminations, therefore, may be grouped according to function into *sensory* and *motor endings*.

### SENSORY NERVE-ENDINGS.

Since the sensory endings are the more or less modified terminal arborizations of neurones whose cell-bodies lie within the spinal and other sensory ganglia, such terminations are functionally the beginnings of the paths conducting sensory stimuli to the central nervous system. According to their relations to the surrounding tissue, the sensory endings are broadly grouped into *free* and *encapsulated*.

**Free Sensory Endings.**—These endings include numbers of nerve-terminations found in the skin and the mucous membranes, chiefly within the epithelium but to some extent also within the connective tissue, and between the fibres of voluntary muscle. As a rule, the sensory (afferent) nerve-fibres branch only to a limited degree until near their peripheral destination, where they undergo repeated division, always at a node of Ranvier and in various directions. The medullary coat of the main fibre is retained until close to its termination, although some of its branches may course as nonmedullated fibres for a considerable distance before ending or entering the epithelium.



FIG. 100.—Free sensory endings within epidermis of rabbit; in several places nerve fibrillae terminate in end-knobs. (*Dogiel*.)

In the skin—and the same general plan applies to the mucous membranes—the fibres destined for the epidermis lose their myelin coat beneath the epithelium which they enter as vertically coursing nonmedullated fibrils. Within the epithelium they break up into delicate fibrils which undergo

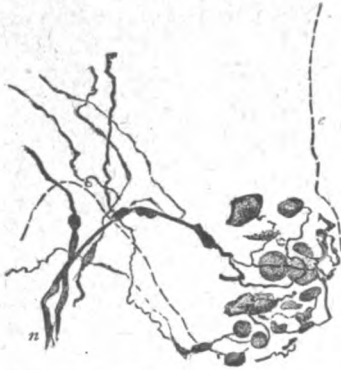

FIG. 110.—Tactile cells of Merkel lying within interpapillary epithelium; broken line indicates junction of epithelium and connective tissue layer; (n) nerve passing into epithelium.  $\times 160$ . (Worthmann.)

further division into still finer varicose threads that ramify between the deeper epithelial cells and terminate in free end-knobs. Similar, but far less numerous free-endings, varicose and club-like in form, occur within the connective tissue layers of the skin and mucous membranes. Conspicuous ramifications of sensory fibres surround the hair-follicles, lying upon the outer surface of the glassy membrane.

The **tactile cells**, found in the deeper layers of the epidermis and sparingly within the subjacent corium, represent a somewhat more differentiated form of intraepithelial terminations and suggest transitions to the more specialized end-organs. In these endings the nerve-fibrils terminate in cup-shaped expansions, the *menisci*, against which rest the tactile (modified epithelial) cells. The

latter may be regarded as imperfectly differentiated *neuroepithelium*, highly differentiated examples of which are seen in the gustatory cells in the taste buds, in the visual cells in the retina and the auditory cells in the organ of Corti.

**Encapsulated Sensory Endings.**—In their most highly developed forms, these endings (*corpuscula nervorum terminalia*) are represented by large special end-organs in which the terminations of the axis-cylinder are enclosed within an elaborate laminated capsule. The latter, however, is more often present as a much simpler and thinner envelope consisting of strands of connective tissue.

Transition forms between the intraepithelial tactile cells above noted and the more specialized end-organs, always within the connective tissue, are seen in the *corpuscles of Grandry* (not found in man but conspicuous in the skin covering the bill of many water-fowl), in which the ramifications of the nerve-fibrillæ end within a disk-like mass, the *tactile disk* enclosed between large modified epithelial elements, the *tactile cells*.

The group of simpler encapsulated end-organs includes three well-known examples: the *tactile corpuscles*, the *end-bulbs*, and the *genital corpuscles*.

**The Tactile Corpuscles.**—These bodies, also called the *corpuscles of Meissner*, are most numerous in the corium of the skin covering the flexor surface of the fingers and toes. They are found also in the integument of other regions possessing sensibility in a high degree, such as the lips, margin of the eyelid, nipple, penis and clitoris, as well as on the dorsum of the hand and foot and the radial surface of the forearm. On the volar surface of the distal segments of the fingers, where they are most numerous, some twenty are found to the square millimeter. The corpuscles occupy the summit of the papillæ

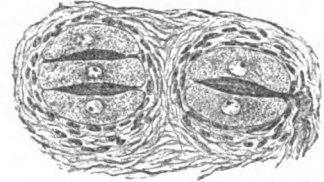


FIG. 111.—Two corpuscles of Grandry from bill of duck; nerve is seen entering corpuscle on right.  $\times 265$ .



and ridges of the connective tissue stratum of the skin and lie close beneath the epidermis, with their long axes perpendicular. They are elongated irregular ellipsoids, often somewhat sinuous in outline, and, in the larger papillæ, two may be joined at the deeper ends to form a compound body. The tactile corpuscles are relatively large, being from 80-150  $\mu$  long and about one-third as broad. Depending upon its size, each corpuscle receives from one to four nerve-fibres, which usually enter in the neighborhood of the deeper pole and, on piercing the capsule and losing the medullary coat, divide into a number of naked axis-cylinders. These pass in parallel or spiral windings, beset with varicose thickenings, between the flattened tactile cells, the entire interlacement being embedded within a semifluid substance and enclosed by a thin nucleated fibrous capsule.

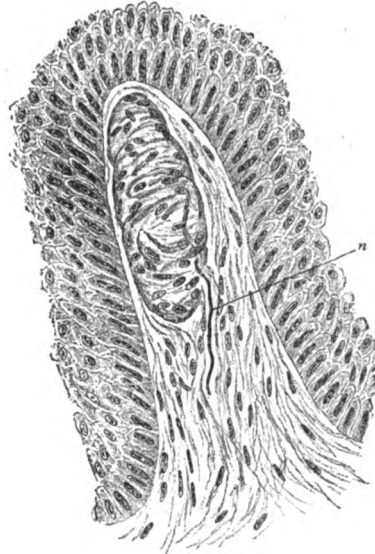


FIG. 112.—Corpuscle of Meissner lying within papilla of corium of skin from finger; only deeper layers of overlying epidermis are shown; n, entering nerve-fibre.  $\times 270$ .

**The End-Bulbs.**—These endings include a variety of irregularly spherical or ellipsoidal bodies found in the edge of the eyelid, the conjunctiva and corneal margin, the lips and oral mucous membrane, the glans penis and clitoridis and probably other parts of the integument highly endowed with sensibility. In the conjunctiva, they lie superficially placed within the connective tissue near the summit of the papillæ and folds, where such elevations exist, but always close beneath the epithelium. They vary considerably in size, often being small but sometimes measuring from 50-100  $\mu$  in diameter. Usually a single nerve-fibre, exceptionally two or even more, enters each bulb, losing its medullary coat as it pierces the thin fibrous capsule. Within the latter the nerve, now represented by the naked axis-cylinder, divides into from two to four branches, which, after describing several annular or spiral turns, give off varicose fibrils that divide into the terminal threads, forming an intricate maze within the semifluid substance (granular in preparations) enclosed by the fibrous capsule.

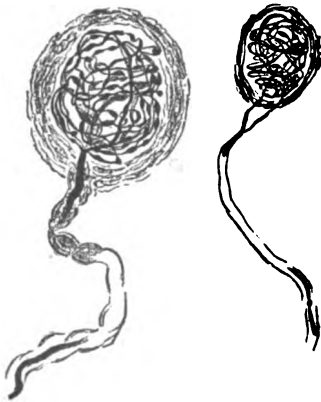


FIG. 113.—Two end-bulbs of Krause from human conjunctiva. (Dogiel.)

.02-.35 mm. in diameter. They present the same general architecture as the end-bulbs, but are larger and possess a somewhat thicker capsule and contain a more intricate interlacement of the terminal nerve-fibrillæ.

**The Genital Corpuscles.**—These endings are most numerous (from one to four to the square millimeter) in the deeper strata of the corium covering the glans penis and clitoridis, but occur also in the skin of the neighboring parts of the genitalia. They are of irregular oval or lobulated outline and from

The latter are derived from the subdivision of two or three fibres that, after losing their medullary coat, enter near the base of the corpuscle. The fibrillæ are beset with varicose enlargements and club-shaped terminal swellings. The fibrous capsule consists of several connective tissue lamellæ, possessing flattened nuclei, and encloses the semi-fluid or granular substance in which the end-arborizations are embedded.

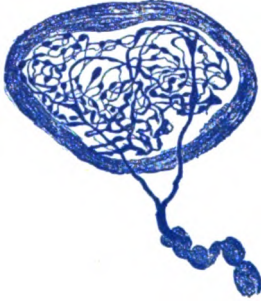


FIG. 114.—Genital corpuscle from integument of penis; nerve divides before piercing capsule and terminates in intricate end-windings. (Dogiel.)

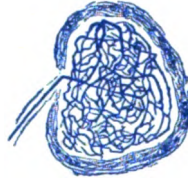


FIG. 115.—Genital corpuscle from integument of human clitoris.  $\times 350$ . (Worthmann.)

In contrast to the foregoing end-organs, in which the axis-cylinder subdivides into numerous terminal threads disposed as more or less elaborate intertwinings, a second group is distinguished by the presence of a *lamellated capsule* that encloses a cylindrical core, the *inner bulb*, containing the slightly branched axis-cylinder. These endings, of which the Pacinian corpuscle is representative, are relatively large and occur chiefly in the skin and the serous membranes.

A transitional form, connecting them with the spherical end-bulbs, is the **cylindrical end-bulbs**. These are found in various parts of the corium, the oral mucous membrane, and between the bundles of striped muscle and of tendon. They are irregularly cylindrical, often somewhat bent, and consist of a thin lamellated capsule that encloses a core of semi-fluid substance in which is the centrally placed axis-cylinder. The latter, after losing the medullary coat on entering the proximal pole of the cor-



FIG. 116.—Cylindrical end-bulbs attached to sensory nerves in parietal peritoneum of man. (Dogiel.)

puscle, traverses the core with little or no branching until near the distal pole, where it ends in a single or slightly subdivided terminal enlargement.

**The Vater-Pacinian Corpuscles.**—These structures, also called the *lamellated corpuscles*, are large ellipsoidal bodies, from .5–1.5 mm. in length and about one-third as much in breadth, situated within the connective tissue in many parts of the body. In man they are found in the deeper layer of the corium, especially in the skin covering the palmar and plantar aspects of the fingers and toes and the nipple, in the connective tissue in the

vicinity of the joints, in tendons, in the muscle-sheaths, in the periosteum, in the tunica propria of the serous membranes (the parietal peritoneum, the mesentery and the pleura), in the neighborhood of the pancreas and of the oviduct. They are particularly large in the mesentery of the cat, where they may be detected readily as oval pearly bodies, sometimes

The most conspicuous part of the Pacinian corpuscle is the robust *capsule* which makes up the entire bulk of the body and consists of from one to three dozen thin concentric lamellæ. The opposed surfaces of the capsule are separated by a single layer of flat tissue cells, whose nuclei appear as small dark openings along the concentric lamellæ. The axis of the Pacinian corpuscle is occupied by a core of semifluid substance, the *inner bulb*, in which the naked axis-cylinder is embedded. On joining the proximal pole of the corpuscle, the fibrous (Henle's) sheath of the nerve-fibre blends with the lamellæ of the capsule, while the medullary coat is retained during the somewhat tortuous path of the fibre through the capsule as far as the core. At this point the

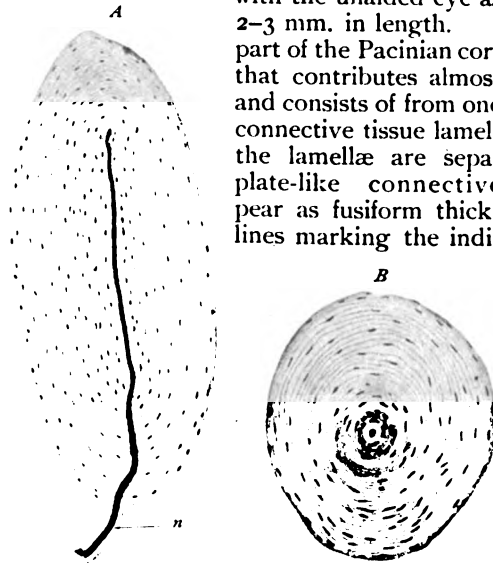


FIG. 117.—Vater-Pacinian corpuscles from skin of finger; *A*, longitudinal, *B*, transverse section; *n*, nerve entering capsule to reach inner bulb.  $\times 145$ .

remaining envelope of the nerve-fibre disappears, the subsequent part of its course, through the inner bulb, being as the naked axis-cylinder. At a variable distance from, but often just before gaining, the distal pole of the core, the axis-cylinder divides into from two to four branches, each of which terminates in a slightly expanded end-knob. Sometimes shortly after penetrating the capsule, the nerve-fibre splits into two or more axis-cylinders, which then share in common the envelope of semifluid axial substance.

The **Golgi-Mazzoni corpuscles**, found in the corium of the skin on the finger-bulbs and on the external genital organs, in the conjunctiva, and in the peritoneum, are modifications of the ordinary Pacinian corpuscles. They differ from the latter in being smaller and in possessing fewer lamellæ, a relatively larger core and a more branched axis-cylinder.

Mention may be made of the *corpuscles of Herbst*, which, on account of their accessibility, are frequent objects of study. They are found in the velvety skin covering the bill and in the tongue of water-fowl and are associated with the Grandry's corpuscles already mentioned. They closely resemble the Pacinian bodies of mammals, but differ in being smaller, relatively broader, and in exhibiting a double row of oval nuclei within the inner bulb and around the axis-cylinder.

**Neuromuscular Endings.**—In addition to sensory nerve-fibres which end between the muscle fibres as free terminal fibrils, voluntary muscle is provided with special sensory end-organs, long known as *muscle-spindles*, probably concerned in transmitting impulses that afford impressions as to tension or "muscle-sense." The neuromuscular endings lie within the con-

nective tissue surrounding bundles of voluntary muscle-fibres and are long spindle-shaped structures, varying in length from 1-5 mm. or more and in width from .1-.3 mm. where broadest. They are widely distributed, being present probably in almost all the skeletal muscles, and are especially numerous in the small muscles of the hand and foot. They have not been found in the muscles of the eye, some of those of the face, those of the pharynx, the intrinsic muscles of the larynx, some of the perineal muscles, and the diaphragm.

Each muscle-spindle consists of a *capsule*, composed of a few concentric layers of fibrous tissue, which encloses a group of from three to ten, but sometimes

as many as twenty, striated muscle-fibres, medullated nerves, blood-vessels and interspersed connective tissue. These *intrafusal fibres*, as the enclosed muscle-fibres are called, differ from those of the adjacent muscle in being much smaller in diameter and length, markedly tapered towards either end, more coarsely but less distinctly striated and in possessing nuclei within the sarcous substance. The intrafusal fibres collectively are surrounded by a thin special fibrous envelope, the *axial sheath*, between which and the capsule lies a periaxial lymph-space. Each spindle receives usually several med-

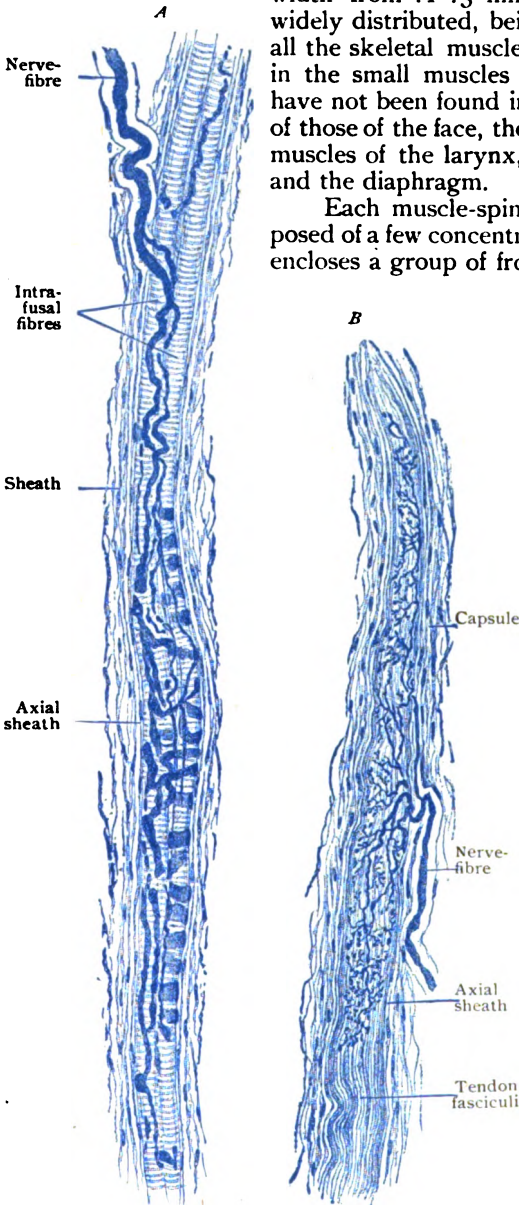


FIG. 118.—*A*, neuromuscular ending; *B*, neurotendinous ending in longitudinal section, methylene-blue staining.  $\times 260$ . (Drawn from preparation made by Professor Huber.)

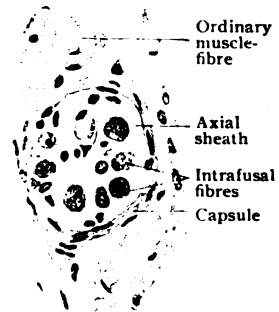


FIG. 119.—Neuromuscular ending in transverse section.  $\times 370$ .

ullated nerve-fibres, which, after incorporation of their fibrous sheaths with the capsule, pierce the latter at various points and proceed to the individual

muscle-fibres. After repeated division during their course through the capsule and periaxial space, the nerve-fibres pierce the axial sheath, lose their medullary coat and terminate either as one or more ribbon-like branches that encircle the muscle-fibres in annular or spiral windings, or, after further subdivision, as branched telodendria in which the fibrils end in irregular spherical or pyriform swellings.

**Neurotendinous Endings.**—In their general architecture, these end-organs resemble the muscle-spindles. They lie within the interfascicular connective tissue, at the junction of the muscle and tendon, and are probably present in all tendons, although in variable numbers. Like the neuromuscular endings, the *tendon-spinales*, as they are often called, are long fusiform structures, from 1.-1.5 mm. in length, surrounded by a fibrous *capsule*. The latter encloses a group of from eight to twenty intrafusal tendon fasciculi, which are smaller and apparently less mature than those composing the surrounding tendon-tissue. The intrafusal fasciculi are invested by a fibrous *axial sheath*, between which and the capsule lies a periaxial lymph-space. On reaching the spindle, after repeated branching, the medullated nerve-fibres penetrate the capsule, with which their fibrous sheaths blend, and undergo further division. The medullary coat is lost after they pierce the axial sheath, the naked axis-cylinders then breaking up into smaller fibrils that extend along the intrafusal fasciculi. The terminal ramifications, applied to the surface of the fasciculi, vary in details. Some arise as short lateral branches that partly encircle the fasciculi and end in irregular plate-like expansions, while others terminate between the smaller fasciculi. The tendon-spindles are probably concerned in appreciating the degree of tension exerted by the pull of muscular contraction.

The **terminal cylinders**, or *Ruffini's endings*, are elongated slightly fusiform end-organs, which supplement the fine sensory nerve-endings in connective tissue. They lie at the junction of the corium and the subcutaneous layer of the fingers and toes. They resemble somewhat the tendon-spindles, being provided with a fibrous sheath which surrounds the elaborate end-arborizations of the entering nerve-fibre. The latter, sometimes single but often double, loses its fibrous sheath on penetrating the capsule, with which the sheath blends, and enters the connective tissue as a naked axis-cylinder. This subdivides into numerous branches, which are beset with irregular varicosities and end in small club-shaped expansions.

#### MOTOR NERVE-ENDINGS.

The motor endings include (*a*) the terminations of the axones of neurones, whose cell-bodies (nerve-cells) are situated within the motor nuclei of the spinal cord and brain-stem, that pass to voluntary muscle; (*b*) the terminations of sympathetic neurones that end in involuntary muscle and (*c*) in cardiac muscle.

**Endings in Voluntary Muscle.**—On approaching their peripheral destination, the medullated efferent nerve-fibres branch repeatedly, each fibre in this way coming into relation with a number of muscle-fibres. When the medullated nerve-fibre reaches the muscle-fibre which it supplies, its medullary coat abruptly ends and the neurilemma becomes fused with the sarcolemma, while the axis-cylinder passes beneath the sarcolemma to terminate in an *end-plate*. The latter appears as an oval field, from 40-60  $\mu$  in its longest diameter, which is applied to the surface of the muscle-substance. In profile it often shows as a slight elevation. Embedded within a nucleated sheet of granular protoplasm, the *sole plate*, lie the terminal arborizations of the

axis-cylinder, formed of irregular varicosities and club-shaped ends. Usually each muscle-fibre is provided with a single motor end-plate, which may lie at an equal or unequal distance from the ends of the fibre. Exceptionally two end-plates are found on one muscle-fibre, in which case the end-organs usually lie near each other.

**Endings in Involuntary Muscle.**—The terminations of

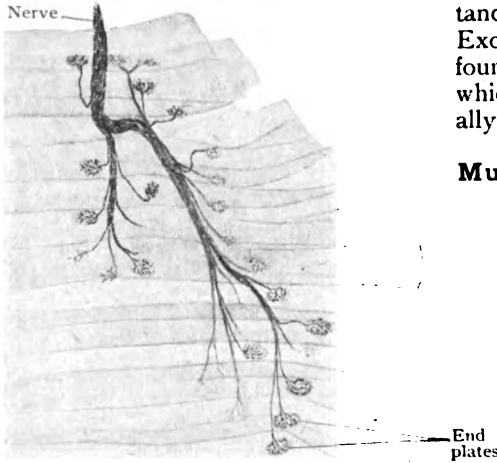


FIG. 120.—Motor nerve-endings in striated muscle; bundle of nerve-fibres separates to supply the individual muscle-fibres.  $\times 135$ .



FIG. 121.—Motor nerve-ending in striated muscle; terminal arborization of axis-cylinder lies beneath sarcolemma embedded in granular sole-plate.  $\times 500$ .

the sympathetic axones supplying the nonstriated muscle are comparatively simple. The cell-bodies of the neurones contributing the immediate fibres of distribution to visceral muscle usually occupy the nodal points (microscopic ganglia) of plexuses within the walls of the organs, from which bundles of non-medullated nerve-fibres extend to and surround the muscle-bundles. Entering the latter, the nerve-fibres divide into delicate varicose threads that pass between the muscle-cells, parallel with their long axes. As they course within the intercellular substance, the varicose fibrils give off short lateral branches that end, as does also the parent fibril, on the surface of the muscle-cells in minute terminal knobs.

**Endings in Cardiac Muscle.**—These, also the terminations of sympathetic neurones, include varicose nerve-fibrils which may be followed between the muscle-fibres. During this course side branches arise which, as well as the main fibril, terminate on the muscle elements in endings of varying complexity. In some cases these are merely minute simple end-knobs, resembling those in involuntary muscle; in other cases they are more elaborate and of a group of secondary fibrillæ bearing nodular endings, the whole recalling somewhat the motor end-plates in striated muscle.



FIG. 122.—Motor nerve-ending in involuntary muscle. (Huber.)

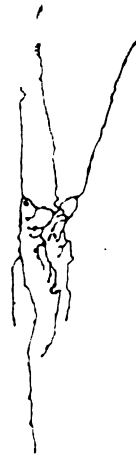


FIG. 123.—Motor nerve-ending in cardiac muscle. (Smirnow.)

## THE VASCULAR SYSTEM.

THE vascular or circulatory system includes the organs immediately concerned in conveying throughout the body the fluids which bring to the tissues the nutritive substances and oxygen necessary for their metabolism and carry away from them to the excretory organs the waste products formed during metabolism.

The system is composed of two parts, the one consisting of organs in which circulates the blood, while the organs of the other contain a colorless or white fluid known as lymph or chyle. The former of these subsystems is the *blood-vascular system* and the latter is the *lymphatic system*. Since, however, the two systems communicate and the lymphatic system develops as an outgrowth from the blood-vascular, it is evident that they are intimately associated both anatomically and embryologically.

### THE BLOOD-VASCULAR SYSTEM.

The blood-vascular system consists of (1) a system of canals known as the *blood-vessels*, traversing practically all parts of the body, and (2) of a contractile organ, the *heart*, by whose contractions the blood is forced through the vessels. The latter, in turn, are divisible into: (a) the *arteries*, which carry the blood from the heart to the tissues; (b) the *capillaries*, exceedingly fine vessels which form a network in the tissues; and (c) the *veins*, which return the blood from the tissues to the heart.

**General Structure of Blood-Vessels.**—Although passing into one another insensibly and without sharp demarcation, typical arteries, capillaries and veins present such characteristic histological pictures that they are readily distinguished. All blood-vessels, including the heart, possess an endothelial lining which may constitute a distinct inner

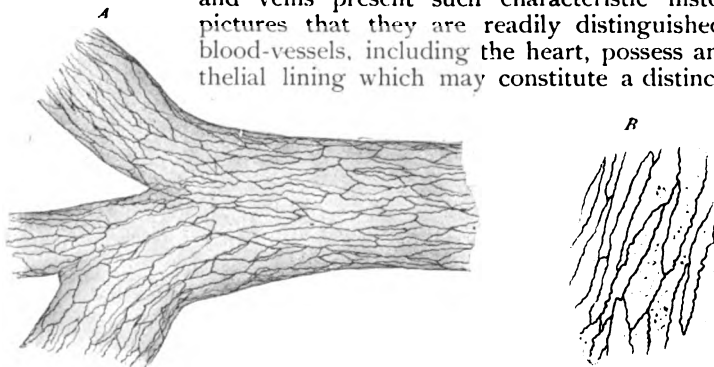


FIG. 124.—A, endothelial lining of small artery after silver-staining.  $\times 200$ . B, endothelial cells more highly magnified.  $\times 300$ .

coat, the *tunica intima*, or, as in the capillaries, even the entire wall of the vessel. Usually, however, the intima consists of the endothelium reinforced by a variable amount of fibro-elastic tissue, in which the elastica predominates. Except within the walls of capillaries, external to the intima lies a thick middle coat, the *tunica media*, composed of intermingled lamellæ of involuntary muscle and elastic tissue and fine fibrous fibrillæ. Outside the media follows the *tunica externa* or *adventitia*, which, although usually thinner than the middle

coat, is of exceptional strength and toughness. It should be noted that the endothelial tube is the fundamental and primary structure in all cases, the other coats being secondary and variable according to the size and character of the vessel. The customary division of the wall into the three coats is more or less artificial and in the larger vessels often uncertain. The recognition of an inner endothelial and an outer musculo-elastic coat frequently more closely corresponds to the actual arrangement than the conventional subdivision into the three tunics.

The **endothelial lining** of the arteries consists of elongated spindle-shaped plates united by sinuous lines of cement substance, which, after silver-staining, map out the contours of the cells with diagrammatic clearness (Fig. 124). Within the veins, the endothelial plates are shorter and broader

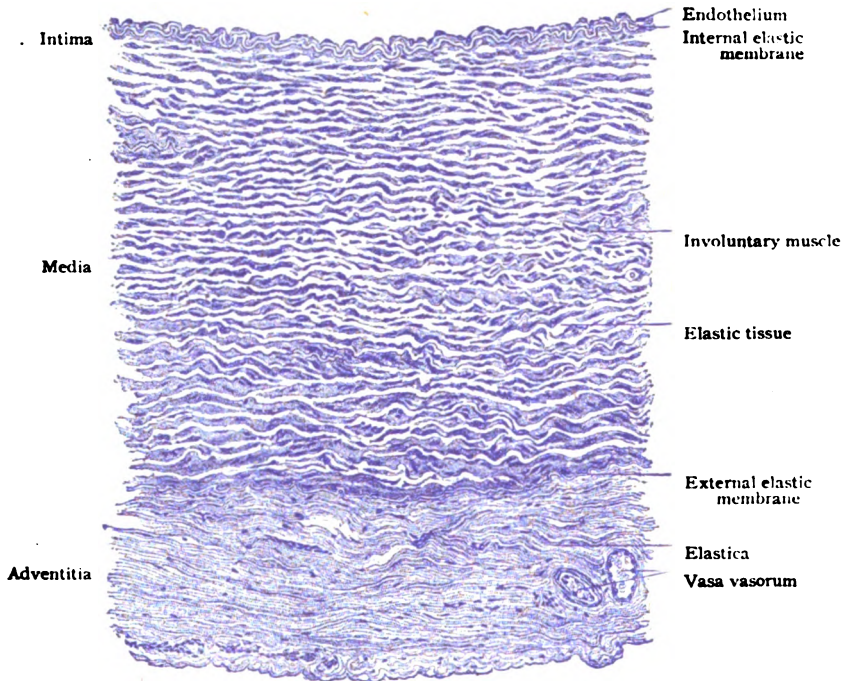


FIG. 125.—Transverse section of artery of medium size.  $\times 150$ .

than in the arteries. The demarcation of the endothelium into distinct cells is less evident in the capillaries than in the larger vessels, in some cases a continuous syncytial sheet replacing definitely outlined plates. The presence of small oval nuclei is readily demonstrated by suitable stains.

The **involuntary muscle** varies in amount from the imperfect single layer of muscle-cells found in the arterioles to the robust muscular coat of many lamellæ in the larger arteries. It is relatively best developed in arteries of medium size, where the muscle occurs in distinct broad or sheet-like bundles between the strands of elastic tissue. The component fibre-cells are short and often branched and, for the most part, circularly disposed. The distribution of the muscular tissue is much less regular and constant in the veins than in the arteries, since in many it is scanty, in some entirely wanting, and in a few excessive, occurring as both circular and longitudinal layers. The



*striated muscle* found in the large vessels communicating with the heart resembles that of the cardiac wall, with which it is continuous.

**Connective tissue** is represented in the arteries and veins by both fibrous and elastic tissue. The former is present usually as bundles of white fibres between the other components of the vessel-wall. The elastic tissue is conspicuous in all arteries, save the smallest, and in many veins. It presents all variations in amount from loose networks of delicate fibres in the smaller vessels to robust plates and membranes in the largest arteries. Within the intima of the latter, the elastic tissue often occurs as sheets broken by pits and perforations, which are, therefore, known as *fenestrated membranes*.

**Nutrient blood-vessels** are present in the walls of all the larger vessels, down to those of 1 mm. in diameter, and provide nourishment for the tissues composing the tubes. These *vasa vasorum*, as they are called, are usually branches from some neighboring artery; their favorite situation is the external coat, within which they break up into capillaries that, in the larger vessels, invade the media, but never the intima. The blood from the vessel-wall is collected by small veins that accompany the nutrient arteries, or, as in the case of the veins, empty directly into the venous trunk in whose walls they course.

The **lymphatics** are represented by networks of surrounding canals within the adventitia. In certain situations, conspicuously in the brain and the retina, the blood-vessels are enclosed by lymph-channels, the *perivascular lymph-sheaths*, that occupy the outer coat.

The **nerves** distributed to the walls of blood-vessels, except those of the nervous substance of the brain and spinal cord in which nerves are wanting, are numerous and include both efferent and afferent fibres. These form a perivascular plexus around the vessel from which motor (sympathetic) fibres pass to the involuntary muscle, while the sensory fibres end within the outer and inner tunics. Special nerve-endings have been described in both the external and internal tunics.

**The Arteries.**—In cross-sections of arteries of medium size, after the usual methods of preservation which cause some contraction of the vessels, the *intima* presents a plicated contour, since it follows the foldings of the *internal elastic membrane*. The latter appears as a conspicuous corrugated light band, marking the outer boundary of the inner tunic. The lining endothelial cells are so thin, that in profile their presence is indicated chiefly by the slightly projecting nuclei. The endothelium and the elastic membrane are separated by a thin layer of fibro-elastic tissue. The *media*, thick and conspicuous, consists of circularly disposed flat bundles of involuntary muscle separated by plates of elastic tissue. After the usual stainings, these plates appear light and almost uncolored, but after selective dyes, as orcein, the elastica is very conspicuous (Fig. 126). Delicate bundles of fibrous tissue lie among the musculo-elastic strands. The outer boundary of the media is marked by a more or less distinct *external elastic membrane*. The *adventitia* varies in thickness, being relatively better developed in the medium sized arteries than in the larger ones. It consists of bundles of fibrous tissue intermingled with elastic fibres of varying thickness. Sometimes scattered bundles of longitudinal muscle are present. The adventitia contains the nutrient blood-vessels and the chief lymph-channels and blends with the surrounding areolar tissue without sharp demarcation.

Followed towards the capillaries, the coats of the artery gradually diminish in thickness. The elastic tissue becomes progressively reduced until it entirely disappears from the middle coat, which then is a purely

muscular tunic. Before the capillary is reached, the muscle is reduced to a single layer of cells, which in turn gives place to groups of muscle-cells that partially wrap around the vessel. After the disappearance of the muscle-cells the blood-vessel has become a true capillary. The adventitia shares in

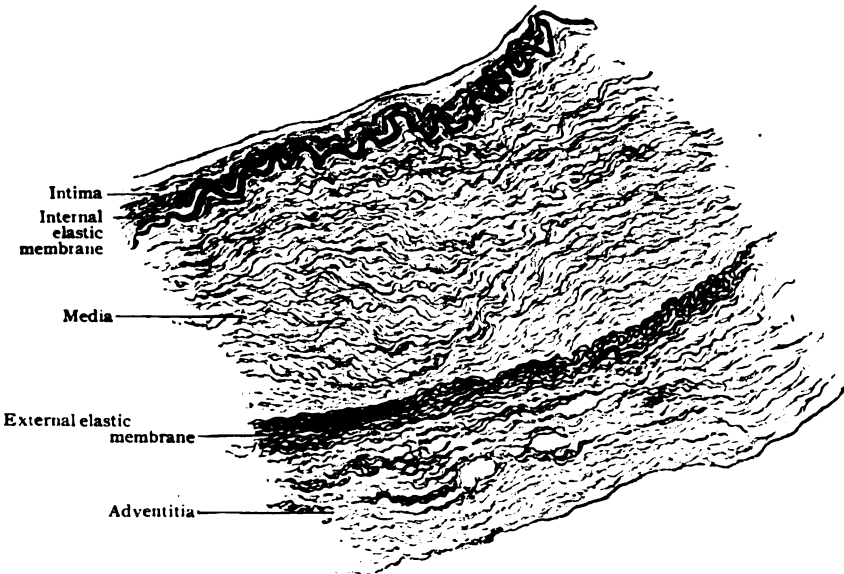


FIG. 126.—Transverse section of artery of medium size, stained to show elastic tissue.  $\times 100$ .

the general reduction, and in the smallest arteries consists of only a few fibro-elastic strands outside the scattered groups of muscle-cells.

In the **large arteries** chiefly the intima and media thicken. Although the inner coat greatly increases and contains a large amount of fibrous tissue

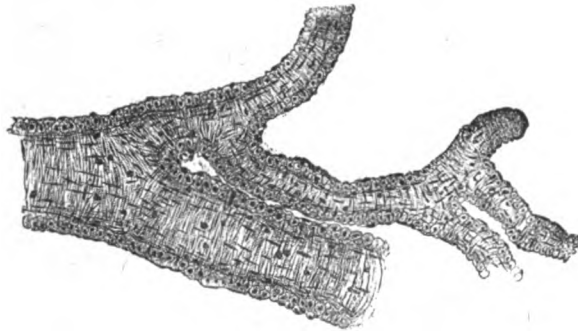


FIG. 127.—Small arteries in which muscular coat is reduced to single layer of cells.  $\times 150$ .

and elastica, a conspicuous internal elastic membrane, as seen in the smallest vessels, is lacking. The character of the thickened media also changes, the muscle being relatively reduced and overshadowed by the excessive amount of fibro-elastic tissue, which confers a more compact and denser character to the wall of the vessel. The adventitia, while proportionately thinner than

in arteries of medium size, is also increased, and consists of robust fibres and plates of elastica, many of which are longitudinal, and strong bundles of fibrous tissue. Exceptionally, among the lower animals if not in man, scattered bundles of involuntary muscle are found within the external tunic. In the roots of the aorta and pulmonary artery, the media consists chiefly of striated

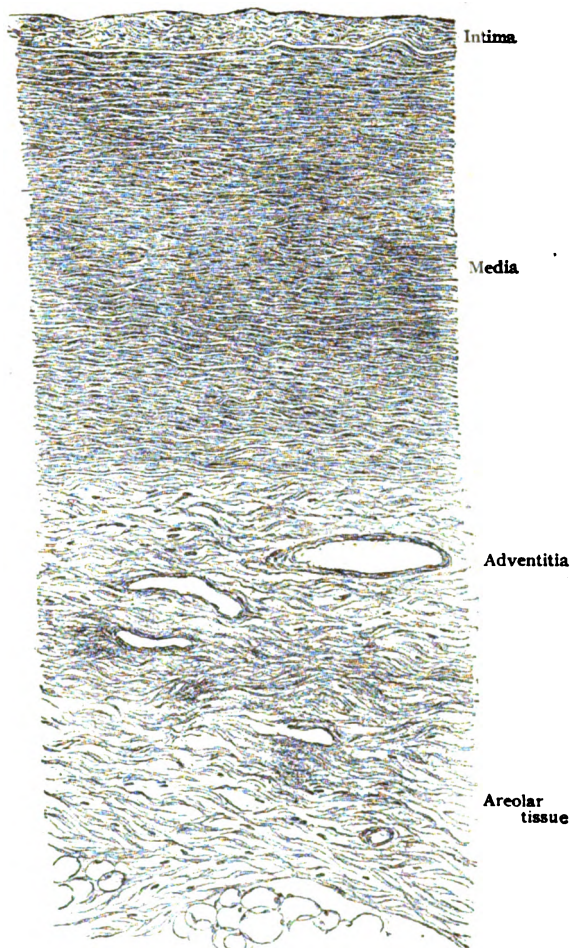


FIG. 128.—Transverse section of abdominal aorta.  $\times 90$ .

muscle resembling the myocardium with which it is continuous, both vessels having been derived from the anterior segment of the primary heart-tube.

**The Veins.**—Although the walls of the veins are thinner than those of the corresponding arteries, their thickness for veins of a given diameter is not constant, owing to the frequent irregularity in the composition of the tunics. In consequence of the smaller amount of muscular and elastic tissue that they contain, veins are generally more flaccid and less contractile than the arteries which they accompany. In veins of medium size, the *intima* consists of the lining endothelium, the cells of which are broad and short, a

thin layer of fibrous tissue and networks of elastic fibres. A distinct internal elastic membrane is seldom present. In some veins, as the cephalic, basilic, mesenteric, iliac, femoral and saphenous, the intima contains bundles of involuntary muscle. The *media*, the most variable coat of the vein-wall, consists of circularly disposed thin sheets of muscular and fibro-elastic tissue, reinforced by longitudinal strands of fibro-elastic tissue and, sometimes, muscle. In certain veins, as the saphenous, deep femoral and popliteal, these longitudinal strands constitute a distinct zone beneath the intima. While in the larger veins the intima is only exceptionally increased, as in the hepatic portion of the inferior vena cava and the portal vein, the *media* is often markedly thickened. This increase is due chiefly to excess of the elastic and fibrous tissue, the muscle remaining proportionately scanty.

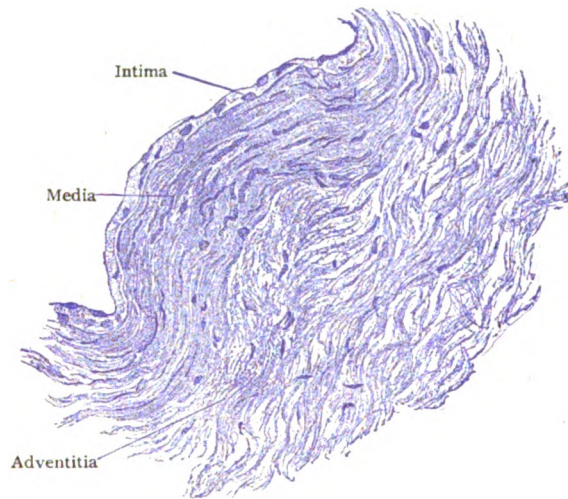


FIG. 129.—Transverse section of vein of medium size.  $\times 250$ .

The splenic and portal veins, however, are particularly rich in muscular tissue. On the other hand, the *media* may be almost wanting, as in the greater part of the inferior vena cava and the larger hepatic veins, or entirely disappear, as in the superior vena cava and in the veins of the pia and dura mater, of the retina and of bone. The **valves**, with which many veins are provided, consist of paired crescentic projections of the intima, covered on both sides with endothelium. The two layers of endothelial plates are separated by a thin stratum of delicate fibrous tissue, which contains a dense network of elastic fibres beneath the inner endothelium.

**The Capillaries.**—The most favorable arrangement for efficient nutrition is, manifestly, one insuring the passage of the blood-stream in intimate relations with the tissue-elements and at a reduced rate of speed. These requirements are met in the capillaries, whose collectively increased calibre and thin walls favor slowing of the blood-current and the passage of the plasma and oxygen into the surrounding tissues. The walls of the capillaries consist of only the lining plates, the entire vessel being in fact a delicate endothelial tube. The cells composing the latter are elongated lanceolate plates, possessing oval nuclei, united by narrow lines of cement substance. Although the transition from the arterioles is usually gradual, the final

disappearance of the arterial muscle-cells marks the beginning of the true capillaries. The passage of the latter into the veins is less definite, since muscular tissue is wanting in both the capillaries and the smaller veins. In the smallest capillaries, two endothelial plates may suffice to encircle the entire lumen; in the larger three or four cells may be required to complete the vessel. Although preformed openings (stomata) in the walls of the capillaries do not exist, the escape of leucocytes and, under certain conditions, also of red blood-cells (diapedesis) and of small particles of foreign substances, takes place between the endothelial plates. In some capillaries, as in those of the choroid, liver or renal glomeruli, the usual demarcation of the wall into distinct cells is wanting, the individual endothelial plates being replaced by a continuous nucleated sheet or syncytium. When capillaries

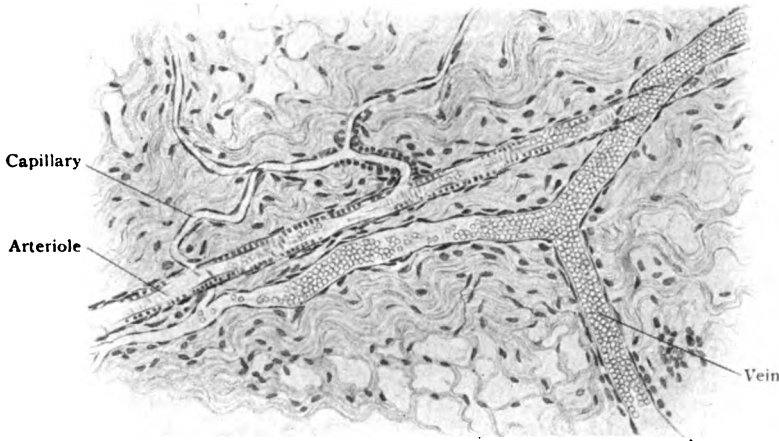


FIG. 130.—Capillaries arising from arteriole and ending in small vein; from the omentum.  $\times 150$ .

course in dense fibrous tissues, not uncommonly the vessel is accompanied by ensheathing delicate strands of connective tissue, the *adventitia capillaris*.

In certain organs, conspicuously in the liver, the ultimate blood-vessels arise by the invasion and subdivision of the large primary blood-channel by the developing tissue-cords. Such blood-vessels are known as **sinusoids** (Minot) and differ from ordinary capillaries in connecting entering (afferent) and emerging (efferent) vessels of the same nature, both being either venous or arterial. Capillaries, on the contrary, establish communication between arteries and veins. In consequence of the invagination and intergrowth which takes place between the original blood-channel and the tissue of the developing organ, the endothelium of the sinusoids has an unusually intimate relation to the cords of tissue-cells, little or no connective tissue intervening.

The capillaries are arranged usually as networks, the component channels of which are of fairly constant diameter within a particular tissue. During life, it is probable that none are too small to permit the passage of the red blood-cells, while many admit two or even three such elements abreast. Their usual diameter varies between 8 and 20  $\mu$ . The capillary networks in various parts of the body differ in the form and closeness of their meshes, since these details are influenced by the arrangement of the elements and by the function of the structures supplied. Thus, in muscles, tendons and nerves the meshes are elongated and narrow; in glands, the lungs and

adipose tissue they are irregularly polygonal; in the liver-lobules they converge; while in the subepithelial papillæ of the skin and mucous membranes the capillaries commonly form loops. In general, the greater the functional activity of an organ, the closer is its capillary network. Organs actively engaged in excretion, as the kidneys, or in the elimination of substances from the blood, as the lungs and liver, as well as organs producing substances directly entering the circulation (organs of internal secretion), as the thyroid gland, are provided with exceptionally rich and close networks.

### THE BLOOD.

The fluid circulating within all parts of the blood-vascular system consists of a clear, almost colorless *plasma* or *liquor sanguinis*, in which are suspended vast numbers of small free corpuscular elements, the *blood-cells*. The latter are of two chief kinds, the colored cells or *erythrocytes*, and the colorless cells or *leucocytes*. The characteristic appearance of the blood is due to the presence of hemoglobin contained within the erythrocytes which, while individually only faintly tinted, collectively impart the familiar hue, as well as a certain degree of opacity. That the characteristic pigment is limited to the cells is shown by the lack of color and transparency of the plasma when examined under the microscope, although to the unaided eye the blood appears uniformly red and somewhat opaque.

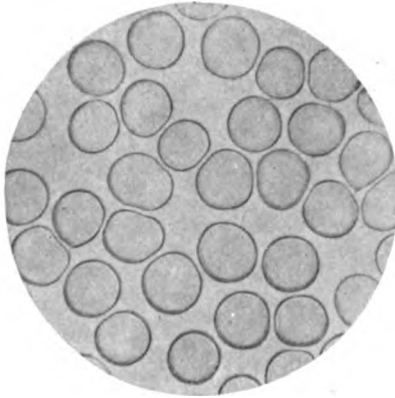


FIG. 131.—Human colored blood-cells, spread into a single layer and dried.  $\times 1000$ .

#### The Colored Blood-Cells.—

As usually seen, the mature colored blood-cells, *erythrocytes* or *red corpuscles*, of man and other mammals (except those of the camel family, which are elliptical in outline) are small biconcave circular nonnucleated disks, with smooth contour and rounded edges. When viewed by transmitted light, the individual "red" cells possess a pale greenish-yellow tint, and only when they are collected in masses or in several layers is the distinctive blood-color evident. The peculiar form of the corpuscle as ordinarily

seen—biconcave in the centre and biconvex at the margin—renders accurate focussing of all parts of its surface at one time impossible, the cell appearing, according to focal adjustment, either as a dark ring enclosing a light centre or *vice versa*. Viewed in profile, the disk presents a figure somewhat resembling a dumb-bell, the thicker margins of the cell being connected by the thinner concave centre. Although the biconcave discoidal form of the mammalian erythrocytes is the one ordinarily exhibited, there is evidence for believing that within the circulation, during life and in carefully fixed preparations, the red blood-cells are cup-shaped, similar to spheres more or less deeply indented.

The structure of the red blood-cell has long been and still is a subject of dispute. According to one view, the cell consists of a soft tenacious envelope enclosing a fluid contents containing the coloring matter, the hemoglobin. The other view regards the corpuscle as composed of an extremely

delicate spongy stroma, containing the hemoglobin, but without a distinct investing membrane. It seems probable that although no definite envelope is present, in the sense of a distinct cell-wall, a peripheral condensation of the semifluid and hemoglobin-containing stroma exists.

The average diameter of the discoidal red blood-cells of man is  $7.8 \mu$ , some corpuscles measuring as little as  $4.5 \mu$  and others as much as  $9.5 \mu$ . Their thickness is about  $1.8 \mu$ . The average diameter of the cup-shaped corpuscles is  $7 \mu$  and their thickness  $4 \mu$  (Lewis). It is probable that the average size is uninfluenced by sex and is constant for all races. The number of red cells contained in one cubic millimeter of normal human blood is approximately 5,000,000 in the male and something less (4,500,000) in the female. The number of corpuscles is practically the same whether the blood be taken from the arteries, capillaries or veins, but is lower in the blood from the lower extremity than from the upper, owing to the larger proportion of plasma in the more dependent parts of the body. In general, the red blood-cells of mammals are small and their size, which greatly varies in different orders, bears no relation to that of the animal. The corpuscles of man are among the largest and exceeded by only those of the elephant ( $9.4 \mu$ ) and of the two-toed sloth. The human cells are approximated in size by those of some small mammals—guinea-pig ( $7.5 \mu$ ), dog ( $7.3 \mu$ ), rabbit ( $6.9 \mu$ ) and cat ( $6.5 \mu$ ). Those of many familiar animals, as the horse, hog, sheep and goat, are distinctly smaller. The smallest corpuscles ( $2.5 \mu$ ) are those of the musk-deer. The positive recognition of human blood, as differentiated from that of some of the domestic animals, by measurement of the red cells, is uncertain and often impossible. The non-nucleated mature red cells are the distinguishing characteristic of mammalian blood, the red cells of the other vertebrates being nucleated and, with few exceptions, large oval elements. The largest red cells are found in the tailed amphibians; those of the amphiuma are the largest known and attain the gigantic length of  $80 \mu$ .

After fresh blood has been distributed as a thin layer and allowed to remain unshaken for some minutes, the red cells exhibit a tendency to become arranged in columns, with their broad surfaces in contact, similar to piles or *rouleaux* of coin. If the stratum of the blood be thin, the red cells usually later separate, but they sometimes retain their columnar grouping. The erythrocytes are very sensitive to reagents and conditions and readily undergo change and distortion. Exposure to even a current of air often produces conspicuous effects. Alterations in form result from the action of solutions of lower or higher density than that of the normal plasma. The latter is conveniently substituted by a "normal" (.85%) solution of sodium chloride. If the proportion of salt be reduced, the corpuscles swell, at first losing their concavity, then assuming the spherical form, parting with their hemoglobin and becoming colorless. When subjected to saline solutions denser than the "normal," the exterior of the corpuscles becomes irregular



FIG. 132.—Human blood corpuscles; two leucocytes are seen among the red cells, most of which are grouped in rouleaux.  $\times 625$ .

and beset with knob-like projections, or *crenated*; increased concentration of the solution leads to marked shrinkage and distortion, until the cells lose all resemblance to their usual form. Certain reagents, as water, aqueous dilutions of acetic acid and ether, promptly decolorize the erythrocytes by extraction of the hemoglobin. Alkaline solutions completely destroy the red cells.

**The Colorless Blood-Cells.**—The colorless cells observed within the blood are probably only incidentally, not genetically, related to the erythrocytes; further, they, in part at least, primarily circulate within the lymph-vascular system, from which they are poured into the blood. They are not confined, however, to the blood- and lymph-vessels, but occur also in bone-marrow, lymphoid tissue and, as the "wandering cells," within the connective and epithelial tissues. Their distribution, therefore, is a very wide one.

When examined in fresh and unstained preparations, the colorless cells or leucocytes appear as pale nucleated elements which, by their pearly tint and refracting property, are readily distinguished from the much more

numerous erythrocytes. Their shape is variable, but when first withdrawn from the body is usually irregularly spherical or oval. When placed on a warmed slide and maintained at the temperature of the body, many of the colorless cells exhibit amœboid motion, whereby not only alterations in their outlines but also changes in their actual position are produced. Although always present, the nucleus may be obscured by the overlying cytoplasm; it is most distinct when the cell is expanded, as when undergoing amœboid changes. A distinct cell-wall is absent, although probably the most superficial zone of cytoplasm possesses slightly greater density.




FIG. 133.—Varieties of colorless blood-cells seen in normal human blood; *a*, small lymphocytes; *b*, large lymphocyte or mononuclear leucocyte; *c*, transitional leucocyte; *d*, polymorphonuclear leucocytes; *e*, eosinophile; *f*, red cells.  $\times 900$ .

The size of the colorless corpuscles varies with the type of the cell, as described below, but in general their diameter is larger than that of the erythrocytes, being commonly from 10–12  $\mu$ . Their number is much less than that of the red cells, the usual ratio being about one colorless to six hundred red cells. Even within physiological limits this ratio varies considerably, from 5000 to 10,000, with an average of 7500, white cells being normally found in one cubic millimeter of human blood.

After fixation and staining (see frontispiece), five varieties of colorless cells may usually be distinguished in normal blood.<sup>1</sup> Two of these are

<sup>1</sup> It should be noted that the differentiation of these cells is founded upon not only their morphological characters, but also the behavior of the granules embedded within their cytoplasm when subjected to certain combination stains. A generation ago Ehrlich divided the aniline dyes into three groups—*acid*, *basic*, and *neutral*. The first includes such dyes as acid fuchsin, orange G or eosin, in which the coloring principle acts or exists as an acid and exhibits an especial affinity for the cytoplasm. The second group, the basic stains, includes dyes, as hematoxylin, methylene-blue, methyl-violet, methyl-green or thionin, in which the coloring principle exists chemically as a base in combination with a colorless acid and particularly affects the chromatin; hence such are nuclear stains. Neutral dyes, produced by mixture of solutions of an acid and a basic stain, have a selective affinity for certain so-called neutrophilic granules.



known as *lymphocytes*, in recognition of their origin from lymphoid tissue, and the others as *leucocytes*. The genetic relations of these groups are still a subject of discussion. According to one view, all forms of colorless cells are derived from similar sources, the recognized varieties being only different stages in the development of the same elements. The other view regards the leucocytes and the lymphocytes as distinct in origin, the latter arising within lymphoid tissue and the former chiefly within the bone-marrow. A discussion of this mooted subject is beyond the purpose of these pages. Suffice it to note, that facts concerning the early development of these cells lend support to the belief that there is a close primary relation between the two groups.

If a thin film of blood be fixed by heat and stained with a "triacid stain" the following varieties of colorless cells are distinguishable:

1. **Small Lymphocytes.**—These are distinguished by a large compact deeply staining nucleus that occupies almost the entire cell. The meagre cytoplasm, reduced to a mere narrow peripheral zone, is devoid of granules. The small lymphocytes measure about  $7.5 \mu$  in diameter and constitute from 20–30 per cent. of all the colorless cells.

2. **Large Lymphocytes.**—These are presumably older forms of the preceding variety, from which they differ in their larger size ( $12-15 \mu$ ) and relatively small oval nucleus. The cytoplasm is nongranular and comparatively plentiful.

3. **Large Mononuclear Leucocytes.**—These elements, from  $10-15 \mu$  in diameter, exhibit clear pale nuclei, which are usually eccentrically placed and oval or slightly indented. The cytoplasm, generous in amount, appears uniform save for fine neutrophilic granules which are often present.

4. **Polymorphonuclear Leucocytes.**—These are by far the most common type of white cells, of which they constitute approximately 70 per cent. Their diameter is about  $10 \mu$ , hence they are somewhat larger than the erythrocytes. The cytoplasm is relatively abundant and contains fine neutrophilic granules. The nuclei are very conspicuous on account of their great diversity of form. At first sight they appear multiple, but on closer examination are seen to consist of irregular nuclear segments connected by delicate processes. Occasionally, however, two or more actually isolated nuclei exist, in such cases the cells being truly polynuclear.

5. **Eosinophiles.**—The blood-cells of this type resemble the polymorphonuclear leucocytes in size ( $10 \mu$ ) and in the lobulated form of their nuclei. Their distinguishing feature is the presence of coarse, highly refracting granules within the cytoplasm that display an especial affinity for eosin and other acid dyes. The eosinophiles are prone to rupture, the pale nucleus then lying in the midst of a swarm of brightly tinged granules.

*Mast-cells*, with coarse basophilic granules, and the finely granular *basophiles* are other granular colorless cells that are occasionally observed, as are also the *myelocytes* derived from the bone-marrow. They are, however, rarely present in normal blood.

**The Blood-Plates.**—In addition to the erythrocytes and colorless cells, the blood of man, and perhaps of other mammals, constantly contains small bodies, the *blood-plates* or *plaques*. They are exceedingly prone to change, or indeed to disappear altogether, when exposed to the air; hence, to insure their presence in an unaltered condition, the blood must be drawn directly into a drop of .8 per cent. salt solution, or, still better, into one of osmic acid solution. After such precautions, the blood-plates appear as round or oval disks, from  $2-4 \mu$  in diameter, commonly somewhat less than

one third the size of the red cells. They possess a minute chromatin mass, the assumed equivalent of a nucleus, and are said to exhibit amoeboid movements. They may be directly observed as free bodies circulating within the blood-vessels. On withdrawal from the latter, without precautions for their preservation, the blood-plates collect in irregular masses and undergo disintegration, their remains often being centres from which radiate the threads of fibrin. The blood-plates are supposed to assist in arresting hemorrhage.



FIG. 134.—Human blood, showing erythrocytes and blood-plates.  $\times 625$ .

They have been variously attributed to disintegration of the leucocytes, to extrusion from the red cells, to destruction of the endothelium of the vessels, and, recently by Wright, to fragmentation of long processes sent out by the giant cells (*megakaryocytes*) of the bone-marrow. In view of their constant presence and large normal quota—an average of 400,000 or more in one cubic millimeter of blood—none of these suggested sources of the blood-plates seems satisfactory.

**Granules.**—In addition to the corpuscles and plates, extremely minute granules occur in varying numbers in normal blood. The nature of these particles differs. Some, but probably not in human blood, are finely divided fat; others, known as *hematoconia*, are of uncertain composition but are not fatty; while still others are probably derived from the disintegration of the endothelial and blood-cells. The destruction of the latter accounts for the constant presence of minute particles of pigment.

**Blood-Crystals.**—The chief constituent of the red cells, the hemoglobin, probably exists within the corpuscles as an amorphous mass in combination with other substances, from which it must be freed by solution before crystallization occurs. After solution, or "laking," as it is termed, the coloring matter of the blood, in the form of oxyhemoglobin, separates into microscopic crystals, usually elongated rhombic or rectangular plates. On mixing dried blood with a few grains of sodium chloride and a small quantity of glacial acetic acid, and heating until bubbles appear, minute brown crystals are formed in large numbers. These are *hemin crystals* and derived from the reduction of hemoglobin. They indicate only the presence of blood and are valueless in differentiating the blood of man from that of other animals. In blood-clots of long standing, minute crystals of hematin often appear as yellowish-red plates. This substance is likewise a reduction-product of hemoglobin.

After death, or upon standing after withdrawal from the body, blood undergoes coagulation, whereby the corpuscles become entangled among the innumerable delicate filaments of **fibrin**. In microscopical preparations of fresh blood, the fibrin appears after a time within the plasma in the form of innumerable delicate threads, which cross and interlace in all directions and radiate from centres marked by groups of blood-plates. The entanglement of the corpuscles in the fibrin-net results in the production of a dark-red, jelly-like mass, the *blood-clot* or *crassamentum*, that separates from the surrounding clear straw-colored fluid, the *serum*. In stained sections, the white cells within the clot are readily identified as deeply tinted bodies, particularly along the free border.

## DEVELOPMENT OF THE BLOOD-VASCULAR TISSUES.

**The Blood-Vessels.**—The earliest blood-vessels within the embryo are networks of delicate channels within the mesoderm. The large vessels of the trunk arise by consolidation and fusion of the axial portions of the network; the extension of the smaller vessels occurs by the growth and conversion of the mesodermic cells with which the primary blood-tubes are intimately connected. The development of new vessels proceeds from the cells constituting the walls of the preëxisting channels. These walls consist of delicate endothelial plates from which pointed sprouts grow into the surrounding tissue. These outgrowths are at first solid, but later become hollowed out by the gradual extension of the lumen of the parent vessel.

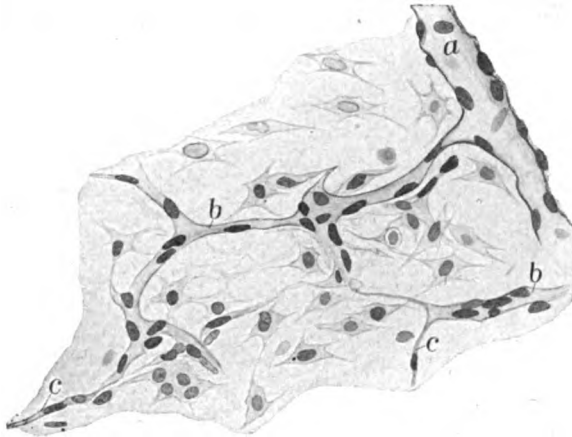


FIG. 135.—Developing blood-vessels in embryonal subcutaneous tissue; *a*, large capillary; *b*, young capillaries; *c*, solid protoplasmic outgrowths forming new vessels.  $\times 300$ .

All vessels consist at first of a single layer of endothelial cells. This simplicity persists in the capillaries, while the walls of the larger vessels become reinforced by additional layers differentiated from the surrounding mesodermic tissue.

**The Erythrocytes.**—The first, and for a time the only, blood-cells within the embryo are the *primary erythroblasts* derived from the mesodermic elements within the angioblastic areas, the *blood-islands*. These cells, separated by the colorless plasma which appears between them and in which they henceforth float, undergo mitotic division and produce nucleated elements, the *primary erythrocytes*, that, in turn, give rise to similar corpuscles. The earliest erythroblasts are relatively large round nucleated cells, whose cytoplasm is faintly granular. Their large nuclei contain networks of chromatin. For a time the cytoplasm is colorless, but soon becomes tinged with hemoglobin. From the primary blood-forming cells, the *hemoblasts*, later arise large erythroblasts, the *megaloblasts*. These are succeeded by smaller nucleated cells, the *secondary erythroblasts* or *normoblasts*, which are formed chiefly within the capillaries (and possibly surrounding tissues) of the liver and, probably, to a limited extent within the spleen. The nuclei of the normoblasts are not only of smaller size than those of the primary blood-cells, but denser and much more compact. By mitotic division, the normoblasts give rise to the young *nucleated erythrocytes*, which lose their nuclei

and become the ordinary erythrocytes or red blood-cells. This loss of the nuclei, effected probably by fragmentation and absorption and not by extrusion, begins in the human embryo about the second month, but is not completed until towards the close of foetal life. Even at, or for a few weeks after birth, occasional nucleated erythrocytes may be encountered in the circulation. During the last months of foetal life, the erythroblasts retire more and more within the red bone-marrow, which, after birth, becomes the chief, if indeed under normal conditions not the exclusive, seat of the production of new red-cells during life. Hence the significance and frequent classification of this tissue (page 40) as a blood-forming organ.

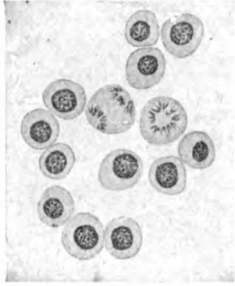


FIG. 136.—Embryonal blood; the dividing erythroblasts are producing nucleated erythrocytes.  $\times 600$ .

**The Colorless Cells.**—Our knowledge concerning the origin of the earliest white blood-cells is incomplete and the views concerning the genetic relations of the lymphocytes and the leucocytes are far from accord. Although the exact location is uncertain, it is generally assumed that these cells arise from mesodermic elements, and to that extent, at least, share

a common origin with the erythrocytes. Further, that the white cells are formed outside the blood-vascular system, which they subsequently enter. The assumption, that the first lymphocytes are formed *in loco* within the early thymus body, by the metamorphosis of the entodermic epithelium, and that the subsequent migration of lymphocytes so derived establishes foci from which are developed the various masses of lymphoid tissue throughout the body, needs confirmation. The progenitors of the leucocyte-group of colorless cells seem to be large elements, the *myeloblasts*, which appear in the developing liver and the early bone-marrow and possess abundant cytoplasm devoid of granules. These primary elements give rise to the *myelocytes*, which exhibit a granular cytoplasm and are found chiefly in the bone-marrow and, to a limited extent, the spleen. From the myelocytes descend the various forms of the leucocytes and, probably, the huge mononuclear marrow-cells, the megakaryocytes. The lymphocytes, on the other hand, are the especial derivatives of the lymphoid tissues, within the so-called germ-centres in which they arise by mitotic division. The lymph-nodes, the spleen and the red bone-marrow are, therefore, the most important seats of the production of the colorless blood-cells. From the standpoint of early development, the sharp distinction between the lymphocytes and the

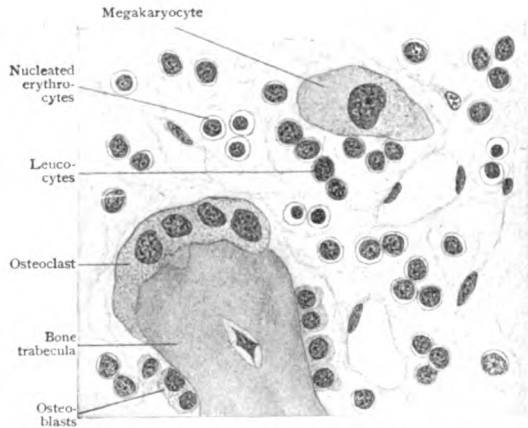


FIG. 137.—Section of embryonal bone-marrow, showing nucleated erythrocytes, leucocytes and megakaryocyte.  $\times 625$ .

leucocytes, as insisted on by Ehrlich and his supporters, based on the assumption that the leucocytes originate exclusively within the bone-marrow, is open to challenge. As shown by Ebner, all the typical forms of white cells, including the polymorphonuclear leucocytes, appear before the differentiation of the earliest bone-marrow. It is not improbable, therefore, that all forms of the white cells are related genetically and traceable to common ancestors.

## THE HEART.

In principle, the heart is a modified blood-vessel, formed by the fusion of two heart-tubes and converted into an efficient organ for propulsion by the unusual development of muscular tissue within its walls. As are the walls of the larger arteries, so also is that of the heart composed of three general layers. The inner of these, the *endocardium*, consists of an endothelial lining and fibro-elastic tissue. The middle layer, the *myocardium*, contributes by far the greatest bulk of heart-tissue and is made up of intricately arranged

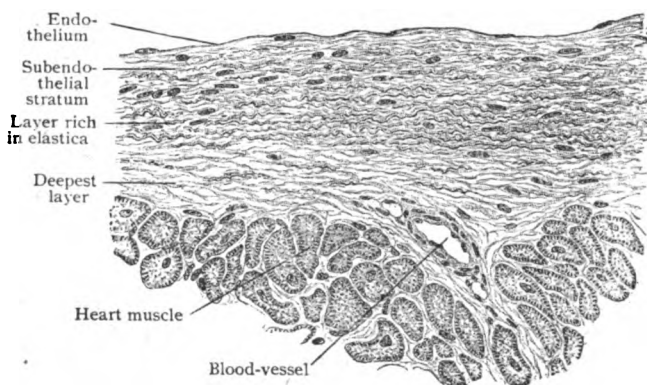


FIG. 138.—Section of endocardium.  $\times 325$ .

sheets of cardiac muscle and fibro-elastic tissue. The outer layer, the *epicardium*, the visceral layer of the pericardium, is a stratum of fibro-elastic tissue, covered externally, except at the base where the great vessels join the heart, with endothelium.

**The Endocardium.**—The endocardium follows all the irregularities of the interior of the heart, lining every recess and covering the free surfaces of the valves, tendinous cords and papillary muscles. It consists of a single layer of endothelial plates and the underlying connective tissue. The latter contains scattered strands of involuntary muscle and is rich in elastic fibres. The elastic tissue occupies particularly the deeper parts of the endocardium, being almost wanting beneath the endothelium, and in the auricles or atria, where it is most abundant, may be condensed into fenestrated membranes. The deepest layer of the endocardium blends with the connective tissue of the subjacent myocardium.

The **valves of the heart** are essentially duplicatures of the endocardium, strengthened in their thicker parts by fibro-elastic tissue. In the case of the *atrio-ventricular valves*, this tissue is continuous with the dense fibrous rings (annuli fibrosi) to which the leaflets are attached. Towards the free margin of the valve, the layers are blended and reduced to a thin fibrous stratum covered on both sides by endothelium. Strands of nonstriated muscle occur

near their attached borders, while the fibro-elastic tissue of the chorda tendineæ is continuous with the middle layer. The *semilunar valves* guarding the aorta and the pulmonary artery correspond in their general structure with the other valves, although muscle in them is wanting. At the periphery and in the central thickenings or *noduli* of the leaflets, the elastic tissue is particularly rich. Within the folds guarding the orifices of the inferior vena cava and of the coronary sinus, the interendothelial connective tissue is an inconsiderable layer, which, in the case of the Eustachian valve, is sometimes further reduced by absorption resulting in a fenestrated condition of the leaflet.

**The Myocardium.**—The middle layer of the heart-wall, the myocardium, is composed of a close elongated network of muscle-fibres, the intermuscular spaces of which are filled with connective tissue. The latter corresponds to an endomysium and, within the ventricles, contains only a small amount of elastic tissue, except around the openings of the valves.

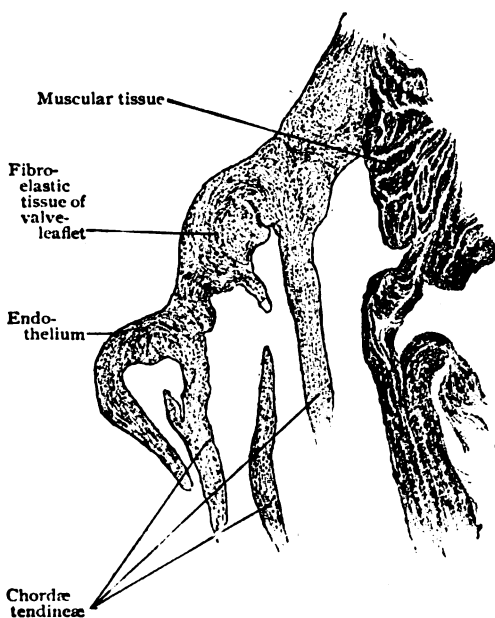


FIG. 139.—Longitudinal section of leaflet of tricuspid valve.  $\times 20$ .

In these locations, dense plates of fibrous tissue (*annuli fibrosi*) encircle the valvular orifices and contain many elastic fibres, as well as give attachment to the strands of cardiac muscle. The histology of cardiac muscle has been described elsewhere (page 55) and need not here be considered. Although as ordinarily seen in microscopical preparations, the fibro-muscular sheets that compose the myocardium seem to follow no particular arrangement, it has been shown that in the architecture of the heart they are disposed according to a definite but complex plan. For a description of this arrangement, however, the reader must be referred to the systematic text-books of anatomy.

In addition to the ordinary fibres of cardiac muscle, the subendocardial layer of the myocardium in many places, especially in the ventricles, contains peculiar fibres, distinguished by their large size, pale color and abundant sarcoplasm, with a corresponding lessening in the number of contractile fibrillæ. These have long been known as *Purkinje fibres* and were regarded as immature and imperfectly differentiated muscle-elements. Their significance, however, has only recently been recognized. They are now regarded as the terminal part of an elaborate system of special muscle-fibres, whose probable function is the coördinative connection of the auricular and ventricular musculature, that otherwise are distinct and unconnected. The most evident part of this system is the definite *atrio-ventricular bundle*, which, beginning in the auricular wall in the vicinity of the coronary sinus, passes from the auricular septum, over the attachment of the posterior leaflet of the tricuspid valve, into the *pars membranacea septi*; here dividing

into a right and left limb, the bundle continues into the interventricular partition. Although distinct and compact during this course, at its two ends the atrio-ventricular bundle breaks up into radiating and interlacing strands, which form an intricate network composed of Purkinje fibres. The latter disappear among the elements of the myocardium by gradual transition into the ordinary fibres of cardiac muscle. The Purkinje fibres ramify not only within the main walls of the heart-chambers, but also invade the trabecula (columnæ carneæ) and papillary muscles of the ventricles. For a time muscular throughout their length, the papillary muscles become transformed into the fibrous chordæ tendineæ in the segments attached to the valves. These fibrous cords often contain considerable elastic tissue which is continuous with the fibro-elastic layer of the valve-leaflets.

**The Epicardium.**—The external layer of the heart-wall, the epicardium, corresponds in its general structure with other parts of the pericardium. It consists, as do other serous membranes, of a single layer of endothelial cells that covers the free surface of the heart and rests upon a stratum of fibro-elastic connective tissue. The elastic fibres are very fine and numerous and form a dense network immediately beneath the endothelium. Those within the auricular epicardium are prolonged into the adventitia of the great veins, while the elastic fibres of the ventricular covering end before reaching the aorta and pulmonary artery. Where not separated from the muscle by subserous fat, which may be abundantly present even in normal hearts, especially in the auriculo-ventricular and the interventricular grooves, the epicardium is intimately attached to the subjacent muscular coat. The numerous branches of the coronary vessels, as well as the nerve-trunks and the microscopic ganglia connected with the coronary plexuses, lie beneath the epicardium or within its deepest layer.

**Blood-Vessels.**—The unusually generous vascular supply of the heart includes the branches derived from the coronary arteries and the capillaries. The former ramify beneath the epicardium and are, to some extent, *end-arteries*, that is, arteries which do not directly anastomose with their neighbors. Although both the epicardium and the deepest layer of the endocardium contain small vessels destined for their tissues, it is to the heart-muscle that the blood is chiefly directed. The larger vessels of the myocardium course within the more robust tracts of connective tissue, giving off the twigs which resolve into the capillary networks. These exhibit elongated meshes, similar to those seen in voluntary muscle, which enclose the muscle-fibres. The relation of the capillaries to the individual fibres is most intimate, since in many places the capillaries are received in grooves, or almost tunnels, in the muscle-substance. The valves are devoid of blood-vessels, with the exception of those accompanying muscular tissue within the bases of the auriculo-ventricular leaflets.

The **lymphatics** of the heart are represented by the numerous lymph-spaces within the connective tissue between the muscle-bundles, and by the more definite lymphatic vessels. The latter form two sets, a network within the deepest layer of the endocardium and a network beneath or within the epicardium. These networks communicate with the larger lymphatic vessels which lie in the auriculo-ventricular groove.

The **nerves** are many and contributed by the vagus and the sympathetic. They include both medullated and nonmedullated fibres which form the coronary and many small subsidiary plexuses. Scattered in these superficial plexuses lie numerous nerve-cells, sometimes singly but often collected into microscopic ganglia. They are especially plentiful around the orifices of the

great veins opening into the auricles, a vicinity corresponding to the upper end of the atrio-ventricular bundles, and over the upper parts of the ventricles. Nerve-fibres and ganglion-cells have been demonstrated within the atrio-ventricular bundle. The distribution-twigs contain both efferent (motor) and afferent (sensory) fibres. The immediate motor fibres supplying the heart-muscle, whose axis-cylinders end on the surface of the muscle-fibres usually in minute swellings (page 86), are probably exclusively the axones of sympathetic neurones, since it is doubtful whether the vagus fibres extend beyond the cell-bodies of such neurones, which they enclose in terminal arborizations. The sensory fibres, at least in part from the vagus, are distributed to the epicardium, endocardium and the connective tissue of the myocardium. Within the epicardium especially and to a limited degree also in the other layers, the afferent fibres are connected with endings which resemble the neurotendinous spindles.

**The Pericardium.**—The parietal pericardium corresponds in its general structure to that of the visceral portion, the epicardium, above described. Its free surface is covered with a single layer of endothelial plates, which rest on the connective tissue layer. The latter consists of fairly dense fibrous tissue, intermingled with fine elastic fibres, which form a close network immediately beneath the endothelium. Where not intimately attached to the pleura, a much looser *subserous layer* of fibro-elastic connective tissue is present. This, as well as the outer part of the pericardium, contains a variable amount of adipose tissue. The *blood-vessels* and *nerves* of the pericardium are comparatively few; some of the nerves, which are chiefly afferent, are connected with Pacinian corpuscles. The *lymphatics* are represented by interfascicular lymph-spaces and more definite channels within the connective tissue. The lymphatics beneath the endothelium possess thin walls and stand in intimate relation to the pericardial sac, particles passing between the endothelial plates into the lymph-channels although no preformed openings or stomata exist.

**Development of the Heart.**—A systematic account of the formation of the heart is beyond the purpose of these pages. Suffice it to note, that, very early in the young embryo, two heart-tubes are folded off in the visceral layer of the mesoderm. These tubes, at first entirely separate, gradually approach the ventral mid-line and eventually fuse, a single heart thereby arising. The wall of the latter, as well as of the primary tubes, consists of two layers, separated by a distinct space. The inner of these layers is composed of a single strand of very delicate mesodermic (mesenchymal) elements, which become the lining of the heart; it is, therefore, known as the *endothelial heart* and lies within the outer *myocardial layer* of the heart-wall as a shrunken cast within a mould. The outer layer is, from the first, thicker and exhibits a tendency to form trabeculæ, the resulting myocardium being for a time loose and spongy. Later, the two layers of the heart-wall come into contact, when the endothelial stratum becomes applied to the irregular surface of the myocardium, every ridge and pocket of which receives an investment of endothelium. The subsequent consolidation which the heart-walls undergo brings about the effacement of the primary spongy texture of the myocardium, except within the innermost zone, where the ridges and bands of the *columnæ carneæ* remain throughout life as the manifestations of the primary condition. During these changes, the mesenchyma of the trabeculæ differentiates into the syncytium, from which arise the myofibrils of the later heart-muscle (page 61), and into the connective tissue filling the interstices between the network of muscle-fibres. The



structural peculiarities of the cardiac fibres, as contrasted with those of ordinary striated muscles, indicate a less complete differentiation in the heart-muscle, this being particularly true of the Purkinje fibres. These characteristics are probably correlated with the exceptional activity that the heart-muscle is called upon to endure, since, as seen in the "red" muscles (page 59), a lower degree of histological differentiation favors prolonged exertion, although at the expense of rapidity of contraction. The valves are formed from cushion-like thickenings of the mesenchyma. Those surrounding the primary efferent vessel, the truncus arteriosus, lead to the subdivision of this tube into the aorta and the pulmonary artery and, likewise, to the formation of the three leaflets of the semilunar valves. In the case of the auriculo-ventricular valves, the septal leaflets are formed from the endocardial cushions, which appear on the surfaces of the partition (septum intermedium) that divides the auricular canal, the channel connecting the primary auricular and ventricular segments of the heart. The other leaflets of these valves are derived from the walls of the auricular canal, a process of undermining partially freeing portions of the innermost layer of the heart-wall. These overhanging plates are connected, however, with the ventricular myocardium by strands of tissue, the later papillary muscles. The latter for a time are entirely muscular, but later the muscle-tissue disappears near the valve-leaflet and the bands are converted into the fibrous strands, the chordæ tendinæ.

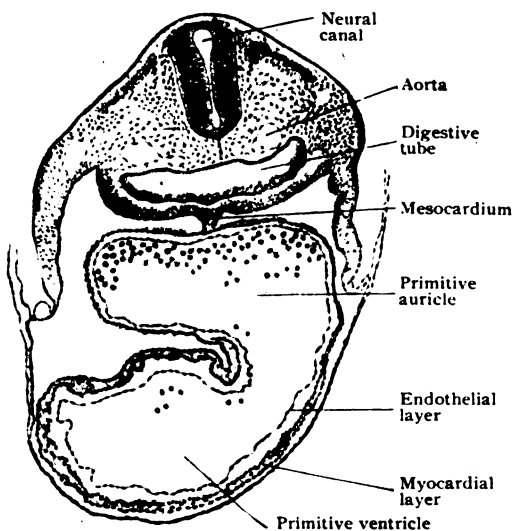


FIG. 140.—Transverse section of early rabbit embryo passing through young heart, showing venous segment behind and arterial in front.  $\times 75$ .

FIG. 140.—Transverse section of early rabbit embryo passing through young heart, showing venous segment behind and arterial in front.  $\times 75$ .

## THE LYMPHATIC SYSTEM.

The lymphatic or lymph-vascular system consists of an almost universally present system of channels, some of which are definite tubes, the *lymphatic vessels*, and others uncertain and often illy defined clefts, the *lymph-spaces*, between the bundles of connective tissue. The vessels contain the *lymph*, a fluid usually colorless and containing numerous corpuscles, the *lymphocytes*. Since the latter are familiar as one of the chief types of colorless blood-cells, they are described in connection with the blood (page 96), in which they circulate. Although the lymph is ordinarily clear, that within the lymphatics leading from the intestines appears, especially during digestion, more or less milky, in consequence of the lymph-cells being loaded with particles of fat which they have taken up from the intestinal contents. For this reason these intestinal lymphatics are often termed *lacteals*. The lymphatics resemble the veins, from which, indeed, they

probably originate, and into which they finally pour their contents. They arise from capillaries, have walls closely resembling in structure those of the

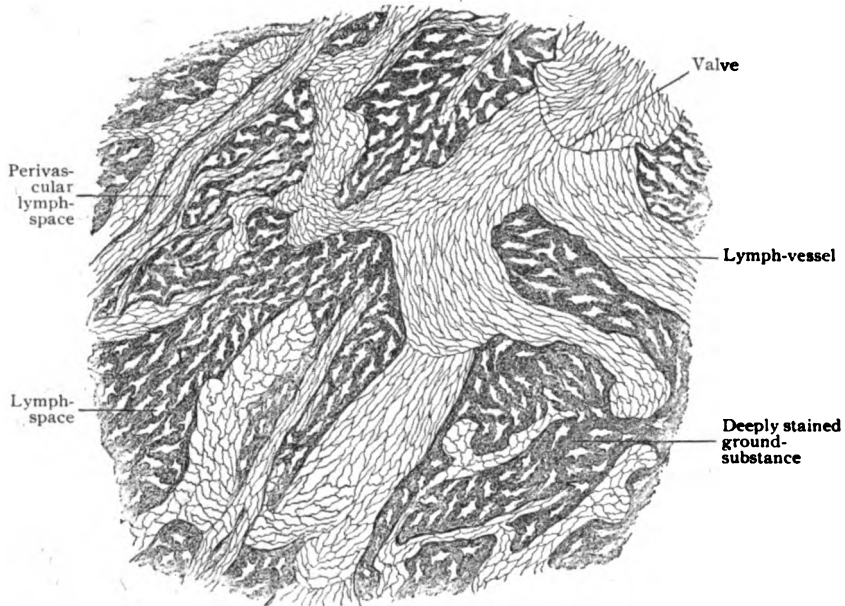


FIG. 141.—Portion of central tendon of rabbit's diaphragm, treated with silver nitrate; lymphatic vessels are shown as light irregular tracts; lymph-spaces are seen within stained ground-substance.  $\times 120$ .

veins, and are provided with many valves. On the other hand, the lymphatics form a system which is closed, except

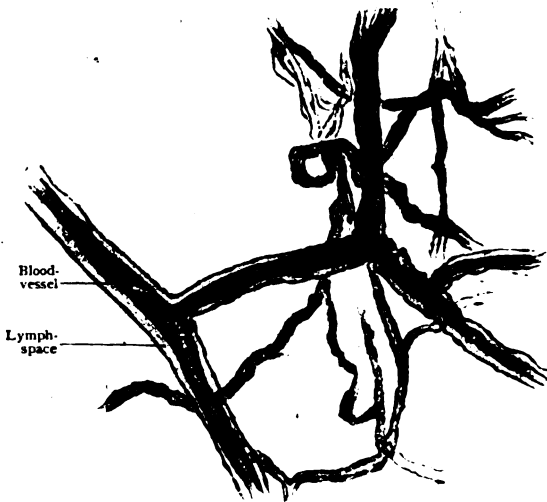


FIG. 142.—Perivascular lymph-spaces surrounding retinal blood-vessels.  $\times 225$ .

where the two chief trunks open into the subclavian veins, the capillaries beginning as blind channels. The most striking feature of the lymph-paths, however, is the presence along the vessels of more or less conspicuous masses of lymphoid tissue, the *lymph-nodes*, often mis-called lymphatic "glands" (*lympho-glandulæ*).

#### Lymph-Spaces. —

These spaces exist practically in all structures of the body, for the most part, however, as the interfascicular clefts within connective tissue. The

lymph-spaces are filled by a clear watery fluid, the tissue-juices, and are imperfectly lined by flattened connective tissue cells. The spaces present

great variations in size. In some localities, as within the nervous tissues, they surround even individual cells; in other places they are represented, in principle at least, by large cavities, since the subdural and subarachnoid spaces, the chambers of the eye, the channels of the internal ear occupied by the perilymph, the synovial sacs of the joints, and, indeed, the great serous cavities—the pericardial, pleural and peritoneal sacs—are all regarded as belonging to the lymph-spaces. Although a conclusion not beyond discussion, the lymph-sacs are now believed to form a closed system of intercommunicating channels, which, while in intimate relation with the lymphatic capillaries, do not actually open into the latter. In many localities, however, the spaces and capillaries are separated by only delicate partitions which allow the passage of fluids, and also of lymphocytes, from the tissue-spaces into the lymph-vessels. Within the adventitious coat of certain blood-vessels, conspicuously those of the retina, the surrounding lymphatic channels constitute *perivascular lymph-spaces*.

**The Lymph-Vessels.**—The definite lymph-paths include the *capillaries* and the *vessels*. The lymphatic capillaries are arranged in networks, varying in closeness and complexity, and resemble in structure the blood-capillaries, consisting of a single layer of endothelial plates. They differ from the blood capillaries in being usually much greater in calibre and less regular in size (30–60  $\mu$ ), larger and smaller capillaries, often beset with irregular constrictions and enlargements, being indefinitely interspersed.

The more formal lymph-channels, the *lymphatics*, as they are commonly called, which arise from the networks of lymph-capillaries and convey the lymph ultimately to the subclavian veins, closely resemble the veins in arrangement and structure. The larger lymph-vessels (from .5 mm. and upwards) possess walls consisting of three coats, which are much like those of the veins. These include: (a)

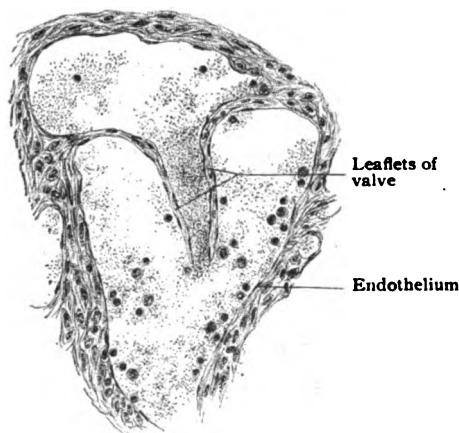


FIG. 144.—Section of lymphatic, showing valve.  $\times 180$ .

the *intima*, composed of the endothelial lining and a thin layer of fibro-elastic tissue; (b) the *media*, made up of circular involuntary muscle interspersed with connective tissue and few elastic fibres; and (c) the *adventitia*, consisting of fibro-elastic tissue and, sometimes, of longitudinal bundles of smooth muscle. The numerous *valves* are essentially folds of the intima.

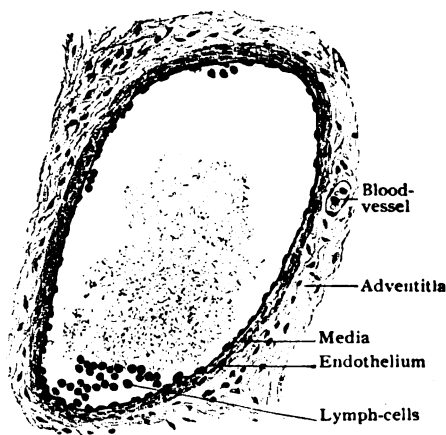


FIG. 143.—Transverse section of small lymph-vessel.  $\times 160$ .

**Lymphoid Tissue.**—Wherever found, whether as diffuse masses, simple nodules, or as the larger and complex lymph-nodes, lymphoid or adenoid tissue is composed of two chief constituents—the supporting connective tissue *reticulum* and the *lymphoid cells* contained within the meshes of the reticulum.

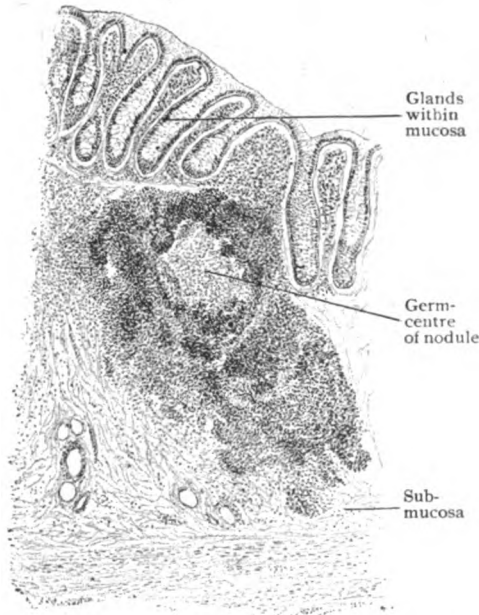


FIG. 145.—Simple lymph-nodule from large intestine.  $\times 120$ .

numerous and closely packed and present the characteristics of the lymphocytes in the blood, this resemblance being explained by the fact that such blood-cells are derived from the lymphoid tissues.

The simple lymph-nodules, varying in size but seldom more than 2 mm. in diameter, are irregularly spherical or ellipsoidal masses of lymphoid tissue, in which a denser peripheral zone encloses and blends with a less compact core. Within the latter, which being of looser texture appears as a lighter central area, usually are seen lymphoid cells in various stages of mitotic division. Such foci are known as *germ-centres* and indicate the birthplaces of many new lymphocytes. Although the limits of the lymph-nodules are commonly imperfectly defined by a condensation of the surrounding connective tissue, a distinct capsule is wanting. Definite lymph-channels are found neither upon the surface nor within the simple nodules; the latter are provided, however, with a generous network of capillary blood-vessels. Intermediate in complexity, between the simple nodules on the one hand

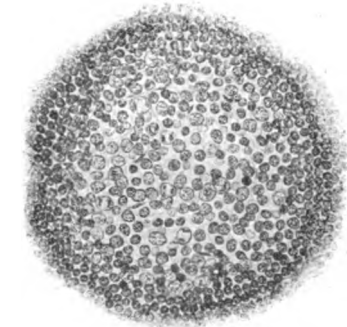


FIG. 146.—Portion of lymph-nodule showing details of germ-centre.  $\times 280$ .

and the typical lymph-nodes on the other, stand such structures as Peyer's patches and the faucial tonsils, in which groups of simple nodules are blended into a single organ, the component nodules only partially retaining their individuality.

The **lymph-nodes** are flattened oval or bean-shaped bodies, from a few millimeters to two centimeters or over in length, that are scattered along the

lymphatic vessels, sometimes singly but often in chains or groups. On nearing a node, the lymph-vessel divides into a number of stems, the *afferent vessels*, which enter the substance of the node and communicate with the capillary network within its interior. From the latter other channels, the *efferent vessels*, arise and emerge from the node at a point usually, but not always, marked by a slight depression, the *hilum*. The lymph-nodes are invested by a distinct fibrous *capsule*,

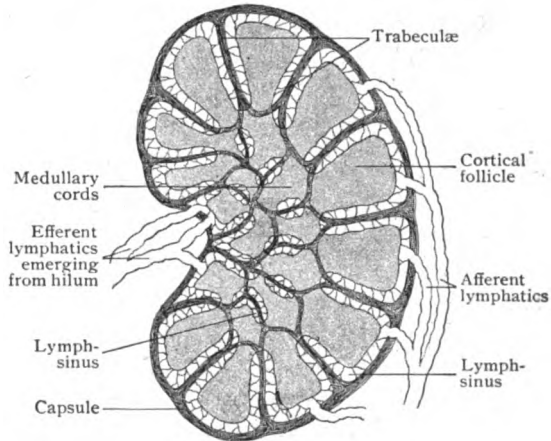


FIG. 147.—Diagram illustrating architecture of lymph-node.

in which elastic fibres and occasional unstripped muscle are present. From the inner surface of this envelope, the fibro-elastic tissue is continued into the substance of the node in the form of numerous radially directed trabeculae,

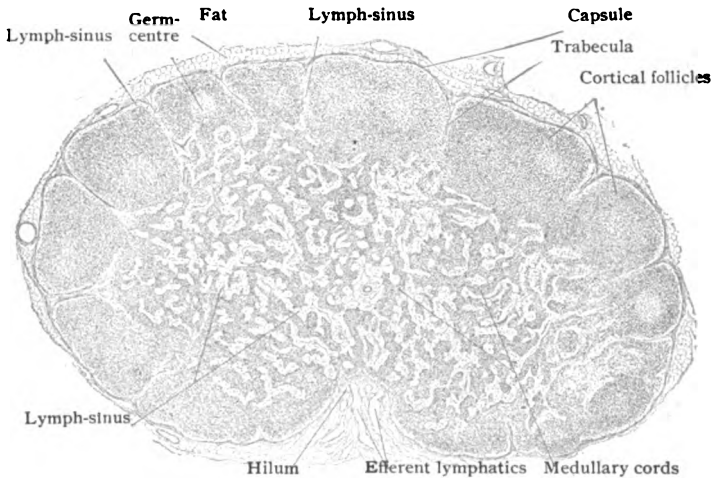


FIG. 148.—Section of small lymph-node through hilum.  $\times 23$ .

which thus subdivide the other zone, or *cortex*, into a series of compartments. On reaching the inner limit of the cortical zone, the trabeculae are less regular and freely anastomose, thereby breaking up the deeper parts of the node, the *medulla*, into uncertain cylindrical compartments. The spaces

thus imperfectly defined by the trabeculae are incompletely filled by masses of compact lymphoid tissue, the general form and arrangement of which correspond to the compartments in which they lie. The masses contained within the peripheral spaces are irregularly spherical or pyramidal and constitute the *cortical nodules*; those within the intercommunicating central compartments form a network of irregular cylinders, the *medullary cords*, which are continuous with one another and with the deeper part of the cortical nodules (Fig. 148).

The intervals between the tracts of lymphoid tissue and the trabecular framework constitute a system of freely communicating channels, the *lymph-*

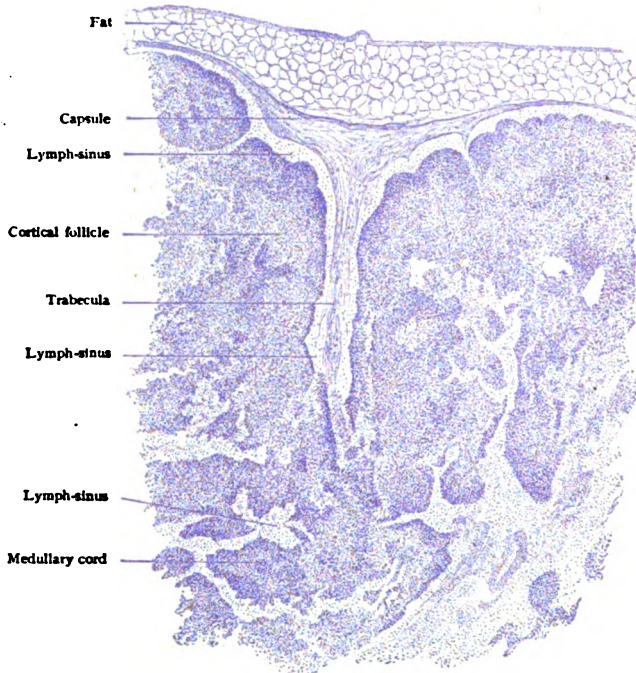


FIG. 149.—Portion of periphery of lymph-node, showing relation between trabecula, sinus, and lymphoid tissue.  $\times 50$ .

*sinuses*, through which slowly passes the lymph brought to the node by the *afferent lymphatic vessels*. The latter pierce the capsule on the convex surface of the node and open into the sinuses that partially surround the cortical nodules. After traversing the peripheral sinuses, the lymph passes into the irregular channels of the medulla and finally escapes from the node through the *efferent lymphatics*, which usually emerge at the hilum, if one be present, on the surface of the node opposite to the entrance of the efferent vessels. The lymph-sinuses, therefore, are bounded on one side by the capsule or trabeculae and on the other by the masses of dense lymphoid-tissue. The lumen of these channels, however, is not free, but occupied by a delicate wide-meshed reticulum consisting of fine strands of connective tissue where most marked, or of the anastomosing processes of stellate cells where very delicate. The sinuses are lined by an imperfect layer of flattened plate-like cells, that represent the endothelium of the adjoining lymphatic

vessels. Although both the afferent and efferent lymphatics are provided with valves close to the node, no such folds occur along the sinuses. The

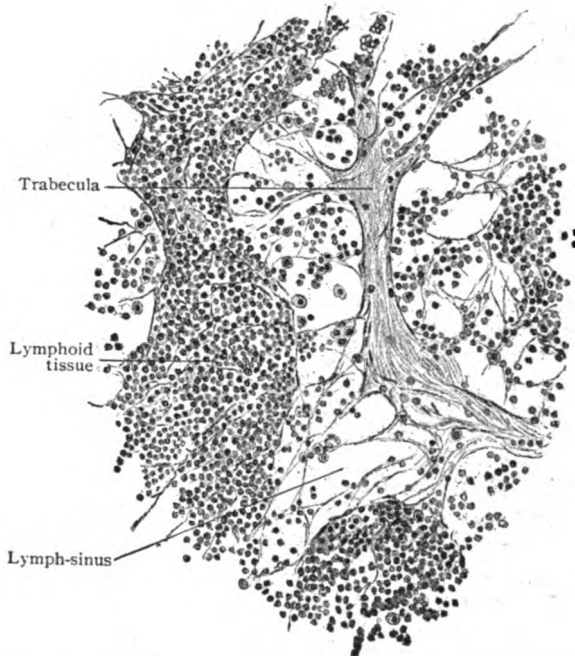


FIG. 150.—Portion of medulla of lymph-node, showing details of lymph-sinus and medullary cords.  $\times 250$ .

passage of the lymph through the node is retarded by the reticulum within the sinuses, thus favoring the entrance of the young lymphocytes from the

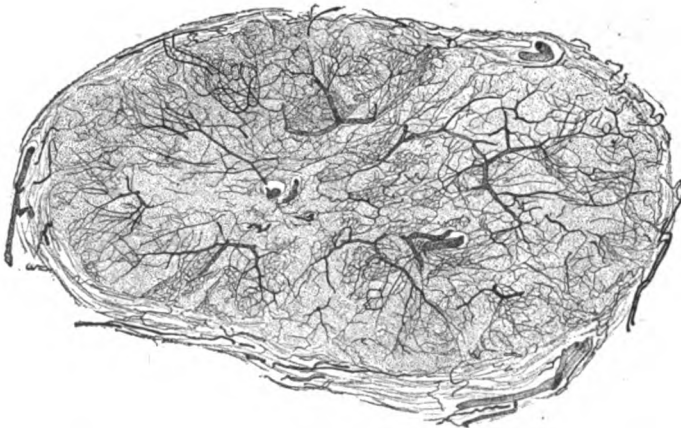


FIG. 151.—Cross-section of small lymph-node, injected to show rich vascular supply.  $\times 10$ .

bordering lymphoid tissue into the sluggishly moving lymph-stream. Germ-centres, the particular foci for the production of lymphocytes, usually are present within the cortical nodules, but are not found in the medullary cords.

The **blood-vessels** for the nutrition of the lymph-nodes are numerous. Some pierce the surface of the node at various points and are distributed to the capsule and the trabeculæ; most, however, enter through the hilum. After following for a short distance the trabeculæ, the arterioles cross the sinuses and enter the cords and nodules of the denser lymphoid tissue, within which they break up into rich capillary networks.

The **nerves** enter the lymph-nodes at the hilum, in company with the blood-vessels. They include both medullated and nonmedullated fibres, but are chiefly sympathetic fibres destined for the involuntary muscle of the vessels and of the capsule.

**Hemolymph Nodes.**—In addition to the ordinary lymph-nodes, there occur in various regions, especially in the prevertebral region of the

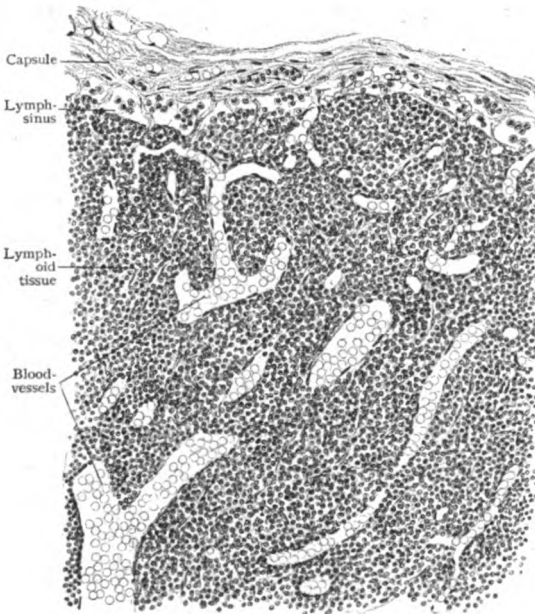


FIG. 152.—Modified lymph-node, containing enlarged blood-vessels and approaching type of hemolymph node.  $\times 120$ .

abdomen, structures which resemble lymph-nodes in form and size, but differ from them in the deep red color which they usually exhibit. These bodies are known as the hemolymph nodes. Their distinguishing feature is the substitution of blood-channels for the usual lymph-sinuses, which, in the typical hemolymph nodes, may be entirely wanting. The path of the blood resembles that within the spleen, since the blood-cells escape from the imperfectly walled vessels into the lymphoid tissue and thence pass into the blood-sinuses and on to the veins. In many cases, however, the substitution of the lymph-sinuses by blood-spaces is not complete, the sinuses occupying the central parts of

the node with the spaces at the periphery. All gradations, in fact, are encountered, from the typical hemolymph node at the one extreme to a lymph-node with enlarged blood-vessels on the other. While these nodes share in the production of lymphocytes, they are probably seats of destruction of the erythrocytes, whose remains are seen in the phagocytes.

**Development of the Lymphatic System.**—The *lymph-vessels* probably arise from the veins by a process of budding, similar to that followed in the extension of the blood-vessels. The first lymphatics appear along the course of the internal jugular vein, as a series of outgrowths from that vessel. These spaces fuse to form a lymph-channel accompanying the vein, other lymphatics arising in a similar manner in connection with the subcardinal, mesenteric and azygos veins. The various channels thus formed unite to form a continuous system, which later acquires new connections with the subclavian veins near their junction with the internal jugulars.



The origin of the first *lymph-cells*, the lymphocytes, is uncertain (page 100), these elements appearing outside the vessels as derivatives of the mesoderm. After the establishment of the lymphoid tissue, new cells are continually being formed within the various lymph-nodes and nodules. The *lymph-nodes* are formed by two fundamental parts, the *lymphoid element*, consisting of lymphocytes in a reticulum surrounding the terminal artery and its capillaries within the cords and germ-centres respectively, and the *sinus-element*, represented by channels resulting from multiplication of the lymph-vessels. The vascular factor is constant and present in the simplest nodule; the sinus-element, on the contrary, varies, sometimes (as in the usual node) being developed from closely packed lymph-ducts, and at other times (as in the hemolymph nodes) being venous channels occupied by blood. By the subsequent intergrowth of the lymphoid element and the greatly multiplied lymph-capillaries, the intervening bridges of connective tissue are reduced until only a reticulum remains, the lymphoid tissue being brought ultimately into intimate relation with the surrounding sinus.

## THE SPLEEN.

The spleen lies far back on the left side in the abdominal cavity, between the stomach and the diaphragm, and measures approximately five inches in length and about three inches in width. Its form is variable and greatly in-

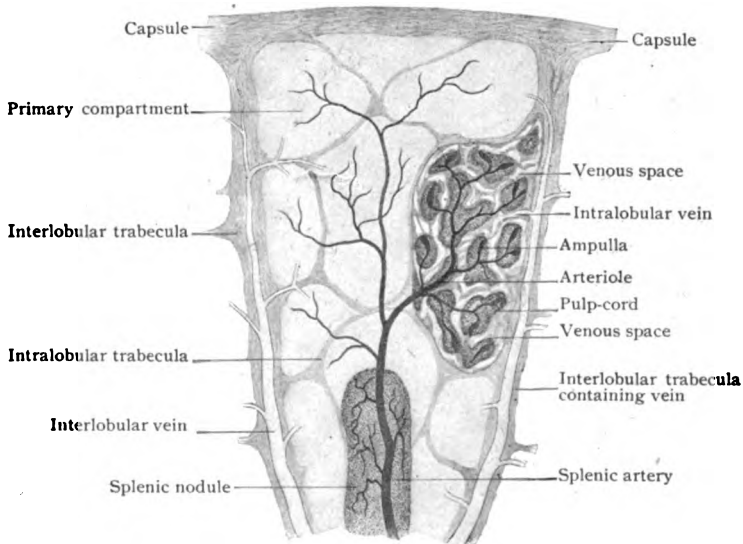


FIG. 153.—Diagram illustrating architecture of a splenic unit; splenic pulp is represented in only one compartment. (After Mall.)

fluenced by the surrounding organs, since its substance is soft and yielding. It contains large quantities of blood and, hence, appears of a dark red or purple color. The spleen may be classed as a huge hemolymph node, possessing the functions of producing lymphocytes and destroying erythrocytes.

The spleen is enclosed by a distinct *capsule*, which consists of bundles of dense fibrous tissue, numerous elastic fibres, and sparsely distributed bundles of unstripped muscle. With the exception of the hilum, the area between

the peritoneal folds at which the splenic vessels and nerves enter or leave the organ, the outer surface of the capsule is united with the serous membrane, the peritoneum, which almost completely invests the spleen. At the hilum the tissue of the capsule is continued into the organ and supports the blood-vessels and nerves. The capsule, furthermore, gives off from its deeper surface numerous processes, the *trabeculae*, which pass into the substance of the organ and break up into innumerable delicate prolongations that unite to form the supporting fibrous *framework*. This framework is arranged with a certain degree of regularity, since the trabeculae subdivide the spleen, at least its peripheral zone, into fairly regular compartments, the *splenic lobules* of Mall, about 1 mm. in diameter. Each of these units is imperfectly defined by three *interlobular trabeculae*, from which secondary *intra*

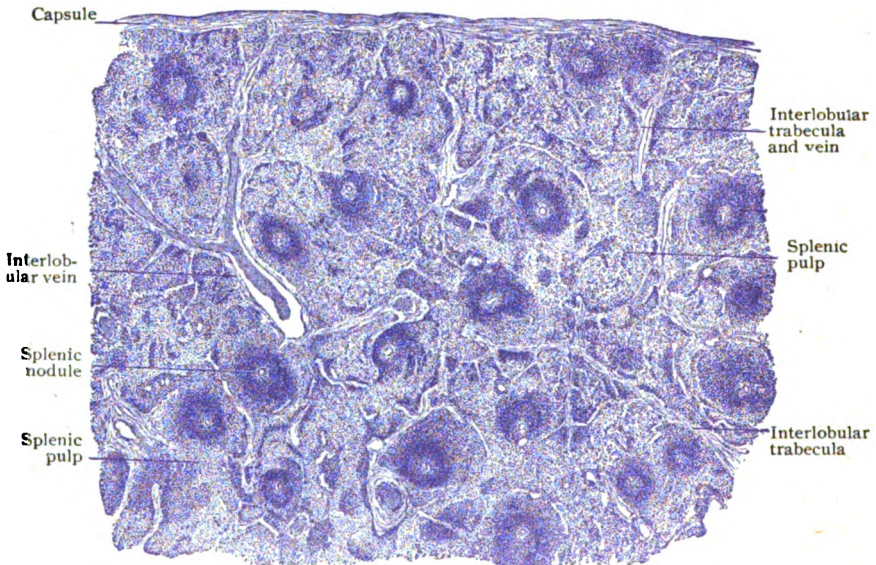


FIG. 154.—Section of spleen under very low magnification, showing general arrangement of splenic tissue.  $\times 10$ .

*processes* penetrate the lobule and subdivide the latter into about ten *primary compartments*. These, as well as the lobules themselves, are not isolated, but freely continuous, since the intervening trabeculae and processes form only incomplete partitions. The spaces within the fibrous framework are filled with the highly vascular lymphoid tissue, known as the *splenic pulp*.

The relation of the blood-vessels to the splenic lobules, although complex, is very definite. The branches of the splenic artery, after entering at the hilum and running some distance within the trabeculae in company with the larger veins; break up into smaller vessels, each of which, parting from the vein, enters the proximal end of a lobule, through the middle of which it courses, giving off twigs, one for each primary compartment of the lobule. On leaving the trabeculae, the arteries carry with them prolongations of connective tissue, which, with the adventitiæ of the vessels, surround the latter with fibro-elastic coats of considerable thickness. Within these envelopes local accumulations of lymphoid cells (lymphocytes) occur and in consequence the arteries are surrounded by spherical or fusiform masses of dense

lymphoid tissue, the *splenic nodules* or *Malpighian bodies*. Depending upon the plane of section, these nodules appear in preparations of the spleen as irregular round or elongated deeply staining tracts, in which the artery usually lies somewhat eccentrically. During its course through the nodule, the artery gives off lateral branches which are resolved into capillaries that pierce as well as supply the ensheathing lymphoid tissue.

The terminal twigs of the artery are the small short vessels, known as the *pulp-arterioles*, which enter the anastomosing strands of lymphoid tissue, the *pulp-cords*, that, together with the blood-spaces, constitute the splenic pulp occupying the intervals of the fibrous framework. After repeated branching, the pulp-arterioles give rise to arterial capillaries possessed of relatively thick walls. The further course of the blood-stream probably varies, since some of the arterial capillaries become directly continuous with enlarged thin-walled channels, the *ampullæ* or *splenic sinuses*, which lie

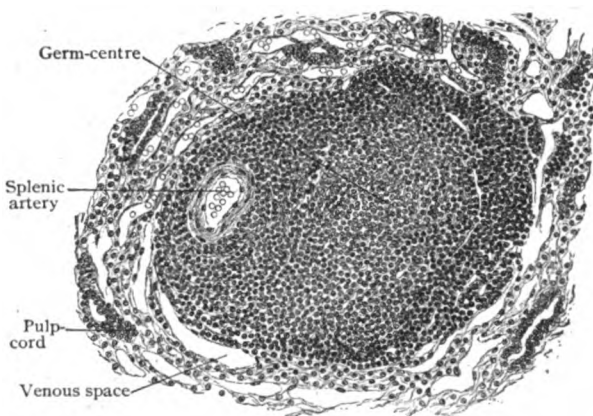


FIG. 155.—Section of splenic nodule, showing its relations to surrounding pulp-tissue.  $\times 120$ .

between the pulp-cords and convey the blood into the wide venous capillaries that constitute the commencement of the more definite intralobular veins. Other of the arterial capillaries and the capillaries coming from the splenic nodules lose their walls, the blood escaping into the splenic pulp, which thus becomes infiltrated with great numbers of erythrocytes and consequently appears of a deep red tint. After slowly welling through the pulp, during which passage the effete erythrocytes are attacked and destroyed by the phagocytic lymphoid cells, the blood passes by narrow channels into the venous spaces and radicles forming the intralobular veins. It is probable, therefore, that while one part of the blood brought to the spleen finds its way actually into the splenic pulp, another part may pass, by a closed path and under usual conditions, from the arteries into the veins, without mingling with the lymphoid elements of the splenic pulp. The *intralobular veins* are tributary to the larger *interlobular veins*, which occupy the interlobular trabeculæ and, finally, emerge at the hilum as the branches of the splenic vein.

The **splenic pulp** consists of an intricate complex made up of a delicate supporting *reticulum*, continuous with the terminal ramifications of the intralobular trabeculæ, and the cells contained within and supported by the meshwork, together with the thin-walled splenic sinuses and venous channels. The *pulp-cells* include a variety of elements, the most constant of which are: (a) lymphocytes; (b) leucocytes of the mononuclear and poly-

morphonuclear types; (*c*) red blood-cells; (*d*) phagocytic cells containing disintegrating red-cells or pigment particles derived from the destruction of the same; and (*e*) large multinucleated cells. A variable amount of free pigment from the disintegrated red cells is also present. During embryonic life, and perhaps later in response to unusual demands for new red blood-cells (as after severe hemorrhage), the spleen is the birth-place of new red cells; these are at first nucleated, but soon lose their nuclei. The elements forming the imperfect endothelial lining of the ampullæ or splenic sinuses are peculiar in being elongated and possessed of nuclei which project into the lumina of the channels. They are sometimes called *splenic fibres* and are said to be contractile. The reticular tissue is disposed around the splenic sinuses and venous radicles in rings which probably support and prevent collapse of the delicate channels. The splenic nodules correspond in structure with the cortical nodules of lymph-nodes and often enclose

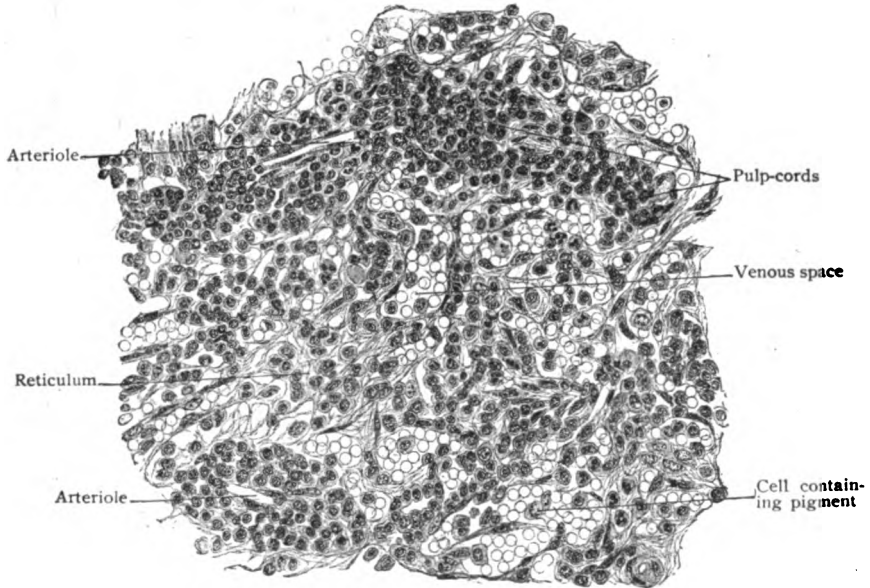


FIG. 156.—Section of spleen, showing details of pulp-tissue.  $\times 300$ .

germ-centres. Since within the spleen the worn-out erythrocytes are destroyed and new lymphocytes are produced, it is evident that the blood carried away from the organ by the splenic vein is poorer in red and richer in white cells than that brought by the splenic artery.

The **lymphatics** are represented by a meagre set of superficial vessels, which lie beneath the serous membrane and converge towards the hilum.

The **nerves**, derived from the sympathetic solar plexus, include many nonmedullated fibres. For the most part they are sympathetic fibres destined for the unstriped muscle within the walls of the blood-vessels and within the trabeculæ. They enter at the hilum and accompany the branches of the splenic artery. Delicate nonmedullated fibres have been described within the splenic pulp, some of which are presumably sensory in function.

**Accessory spleens** are common, but they are not all of the same significance. Some are isolated parts of the spleen, which have become

constricted and eventually separated. Others are seemingly independent masses of splenic tissue. Not a few have no splenic nodules and are intermediate between the spleen and the lymph-nodes, and, probably, are to be classed as hemolymph nodes.

As a matter of convenience, mention may be made at this place of two organs—the *carotid* and the *coccygeal bodies*—concerning whose functions little or nothing is known. The systematic position of these structures is at present uncertain, but, from its histological characteristics, the carotid body is probably to be regarded as closely related to or, in a sense, an appendage of the system of sympathetic nerves, whilst the coccygeal body may be included, with seeming propriety, with the organs of internal secretion. Their grouping and description here, therefore, must be understood to be a matter of convenience and expediency and not an attempt to define their true relations.

### THE CAROTID BODY.

This organ, also known as the *glomus caroticum*, *carotid gland* and *ganglion intercaroticum*, is a small ovoid body measuring usually about 5 mm. in length, from 2.5–4 mm. in width and about 1.5 mm. in thickness.

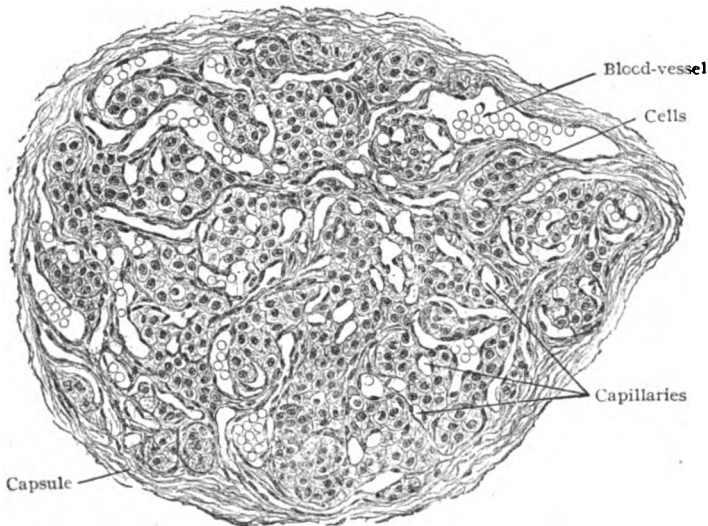


FIG. 157.—Section of carotid body of adult man; one entire lobule is shown.  $\times 170$ .

It may attain a length of 7 mm. and exists on both sides. Its most frequent position is on the median and deep side of the upper end of the common carotid artery in close relation with the point of division of the latter vessel into the external and internal carotids. The body usually lies not within the bifurcation, but rather on the inner side of the common carotid, so that its form and relations are best displayed by dissection from within outwards.

The body is surrounded by a thin fibrous *capsule*, from which delicate septa penetrate inwards and divide the organ into a small and uncertain number (5–15) of spherical masses or *lobules*, from .2–.5 mm. in diameter, which consist of a complex of blood-vessels, nerve-fibres and peculiar cells.

The latter are irregularly disposed as clumps or cell-balls and occupy the interspaces within the close network of large capillaries which ramify among the cells. The characteristic elements of the carotid body are the polygonal cells, about  $10\ \mu$  in diameter, with large round nuclei. Their protoplasm is finely granular and is especially prone to change, being best preserved in solutions of chromic acid salts. When so treated, they take on the peculiar yellow color entitling them to be classed as *chromaffine cells*. The large number of nerve-fibres within the carotid body is remarkable. They are mostly nonmedullated and are derived chiefly from the neighboring sympathetic plexus surrounding the carotid artery. After entering at different places, they ramify within the organ in all directions, the finest filaments being lost among the groups of cells. The penetrating nerve-trunks usually enclose typical ganglion-cells and, in a sense, the chromaffine cells likewise, since the nerve-fibres surround the groups of these elements.

In view of (1) the identity of its elements with other chromaffine cells, which are now recognized as closely associated with the sympathetic system in other localities, as in the medulla of the suprarenal body, (2) its extraordinary richness in nerve-fibres, (3) its general resemblance to a sympathetic ganglion, and (4) its direct development from embryonal sympathetic ganglion-cells, Kohn concludes that, since the carotid body is neither a gland nor a typical ganglion, it must be regarded as accessory to the sympathetic system and, in recognition of this relation, proposes the name *paraganglion caroticum* for the organ. Concerning its function nothing is definitely known.

The blood-vessels supplying the carotid body are branches which pass directly from either the common carotid artery or its terminal branches.

#### THE COCCYGEAL BODY.

This organ, also often called the *glomus coccygeum*, *coccygeal gland*, or *Luschka's gland*, is a small reddish yellow ovoid body which lies embedded in fatty areolar tissue usually immediately in front of the tip of the coccyx, but sometimes just below. The dimensions of the organ are small, its transverse and greatest diameter being from 2.5–3 mm. and its thickness less than 2 mm. It sometimes is divided into two or even more tiny lobes. The body thus described is, however, only the largest of a series of nodules which includes a variable number of structures, for the most part of minute size, irregularly grouped around the chief mass (Walker). The additional nodules are in many cases connected with the principal body by means of delicate pedicles; in others they are entirely free, but in all instances they are grouped around the middle sacral artery or its branches.

The body, as seen in transverse sections (Fig. 158), includes an irregularly oval field of connective tissue, fairly well defined from the surrounding fatty areolar tissue, in which are enclosed numerous aggregations of epithelial cells and, sometimes, a thick-walled artery. The proportion of cell-masses to the connective-tissue stroma varies, in some cases the cellular constituents predominating, but commonly the fibrous stroma being the more bulky. The individual cell-groups are uncertainly circumscribed by a slight condensation of the surrounding fibrous stroma. Each aggregation of cells contains a central blood-space, limited by an endothelial wall similar to that of a capillary. Against this wall the epithelial cells lie without the intervention of connective tissue; likewise the cells themselves are closely packed in direct apposition with one another and in consequence present a polygonal

contour. They are disposed around the central vessel in from two to five layers, the individual cells being indistinctly outlined and composed of clear protoplasm containing a relatively large and deeply-staining nucleus. Concerning the mooted question as to the presence of chromaffine cells within the coccygeal body, the testimony as to their absence seems convincing. The cells at no period exhibit the chrome-reaction, and have no histogenetic

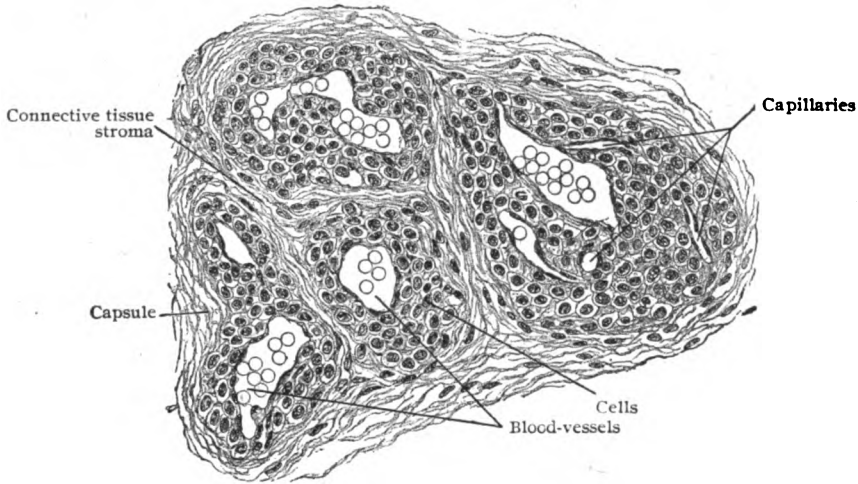


FIG. 158.—Section of coccygeal body of adult man.  $\times 220$ .

relation to the sympathetic system. On the other hand, the epithelial character of the cells, their intimate relation to the blood-vessels, and the absence of excretory ducts, seem to justify the inclusion of the coccygeal body, at least provisionally, among the organs of internal secretion.

## MUCOUS MEMBRANES AND GLANDS.

The apertures of the digestive, respiratory and genito-urinary tracts on the surface of the body mark localities at which the integument becomes continuous with the walls of cavities and passages communicating with the exterior. The linings of such spaces and tubes constitute *mucous membranes*. The latter, however, not only form the free surface of the chief tracts, but are continuous with the ducts and tubes leading into the *glands*, which are secretory appendages developed as outgrowths from the mucous membranes. These membranes line two great tracts, the *gastro-pulmonary* and the *genito-urinary*.

### THE MUCOUS MEMBRANES.

Every mucous membrane comprises two distinct parts: the *epithelium*, which forms the immediate free surface and protects the delicate subjacent structures, and the *tunica propria*, a connective-tissue stroma which gives place and support to the terminal branches of the blood-vessels and nerves and the beginnings of the lymph-channels. A stratum of *submucous tissue*, ordinarily loose and extensible, usually connects the mucous membrane with the surrounding structures.

The **epithelium** may be squamous or columnar, simple or stratified. Its character is determined largely by the conditions to which it is subjected or by its function. Thus, where a mucous membrane is exposed to the mechanical influences of foreign bodies, the epithelium is commonly strati-

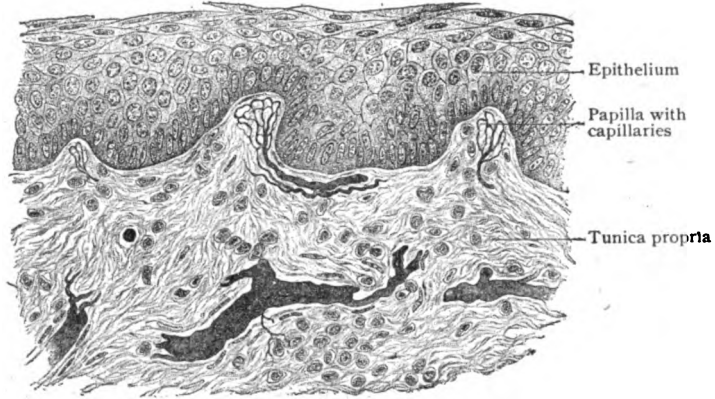


FIG. 159.—Section of oral mucous membrane, showing epithelium and tunica propria.  $\times 300$ .

fied squamous, as in the upper part of the digestive tract. Where concerned in facilitating absorption, as in the intestinal tube, it is simple columnar in type. In localities in which the existence of a current favors the function of an organ, either as a means of freeing the surface from secretion or particles of foreign matter, as in the respiratory tract, or of propulsion through a tube,

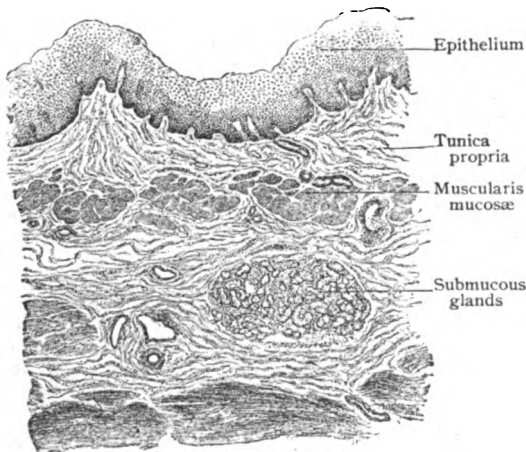


FIG. 160.—Section of mucous membrane of oesophagus.  $\times 55$ .

as in the oviduct, the epithelium is of the ciliated columnar variety. Modifications of the epithelial cells, owing to the presence of pigment or of secretion, distinguish certain mucous membranes, as those of the olfactory region and the large intestine respectively. The **tunica propria** consists of a stroma of interlacing bundles of fibro-elastic connective tissue, supporting spindle-shaped or stellate connective tissue cells. The latter commonly lie against the walls of the interfascicular lymph-spaces that occur between the bundles of stroma-tissue. In many localities the outer surface of the tunica propria is beset with elevations, the *papilla*, over which the epithelium extends. When slight, such irregularities may not modify the free surface of the mucous membrane, since the epithelium completely fills the depressions between the elevations. When more pronounced, the papillae or folds of connective tissue produce conspicuous modelling of the surface,



as seen in the papillæ of the tongue or the rugæ of the vagina. The papillæ contain the terminal loops of the blood-vessels and many of the endings of the sensory nerves. Where increase of surface is desirable, the mucous membrane may be thrown into cylindrical elevations, or *villi*, as conspicuously seen in the small intestine. In many places, particularly in the digestive tract, the mucous membrane contains more or less definite accumulations of lymphoid tissue, of varying size and complexity, as exemplified by the lymph-nodules within the vermiform appendix and the Peyer patches within the ileum. A more or less definite line separates the epithelium from the subjacent tunica propria. This demarcation is the *basement membrane* or *membrana propria*. Often the basement membrane appears as a mere line beneath the epithelium and is then, probably, due to the apposition of the bases of the epithelial cells. Where, as around glandular tissue, it is well developed and appears as a definite homogeneous membrane, it is a product of the tunica propria. Exceptionally a reticular structure is recognizable. Sometimes the deepest stratum of the mucous membrane, next the submucous layer, is occupied by a narrow sheet of involuntary muscle, the *muscularis mucosæ*. While not everywhere present, it is well developed in the intestinal tract and in places consists of two distinct strata, a circular and a longitudinal. The muscularis mucosæ belongs to the mucous membrane and must not be confounded with the muscular coat proper which is often a conspicuous additional tunic.

The **submucous layer**, the stratum of areolar tissue connecting the mucous membrane with the underlying structures, varies in thickness and density. Usually the attachment is a loose one and readily permits changes in position and tension of the mucous membrane; the latter, under such conditions, is often thrown into temporary folds or rugæ, as in the œsophagus and stomach. In other places the folds are permanent and not effaced by distention of the organ, as conspicuously demonstrated by the plications in the duodenum in which the submucous tissue forms the basis of the band-like elevations.

The **blood-vessels** supplying mucous membranes reach the latter by way of the submucous tissue, in which the larger arterial branches divide into twigs that pass into the mucosa. Within the deeper parts of the tunica propria the arterioles break up into capillaries forming subepithelial and papillary networks, the vascular loops being limited to the connective-tissue stroma. The veins usually follow the arteries in their general course. When glands are present, the capillaries surround the tubules or alveoli with rich networks, in close relation with the basement membrane. The **lymphatics** within the mucous membrane are often represented by lymph-spaces between the bundles of stroma-tissue. Towards the deeper parts of the mucosa, however, more definite paths exist as thin-walled channels which converge towards the submucous tissue. Within the latter the lymphatics form networks, provided with valves and beset with the accompanying dilatations.

The **nerves** distributed to mucous membranes include medullated and nonmedullated fibres derived from the cranial or spinal trunks and the sympathetic ganglia. The pale sympathetic fibres are destined for the involuntary muscle of the stroma and of the blood-vessels and for the glands. The immediate supply of the involuntary muscle-cell is always the efferent fibre (axone) from the sympathetic neurone, which is thus the last link in the chain conducting the motor impulse. The position of the sympathetic cells varies, in some cases being remote and in others close to the muscle

supplied. When near the mucous membrane, they occupy the microscopic ganglia within the submucous layer. Surfaces highly endowed with sensibility are generously provided with twigs containing medullated fibres. As the latter approach their destination, they lose their medullated character and, as naked axis-cylinders, form subepithelial plexuses from which fibrils pass into the papillæ, where some terminate in free or special endings. Others enter the epithelium and penetrate between the cells for a variable distance to end free, for the most part, in minute bulbous swellings.

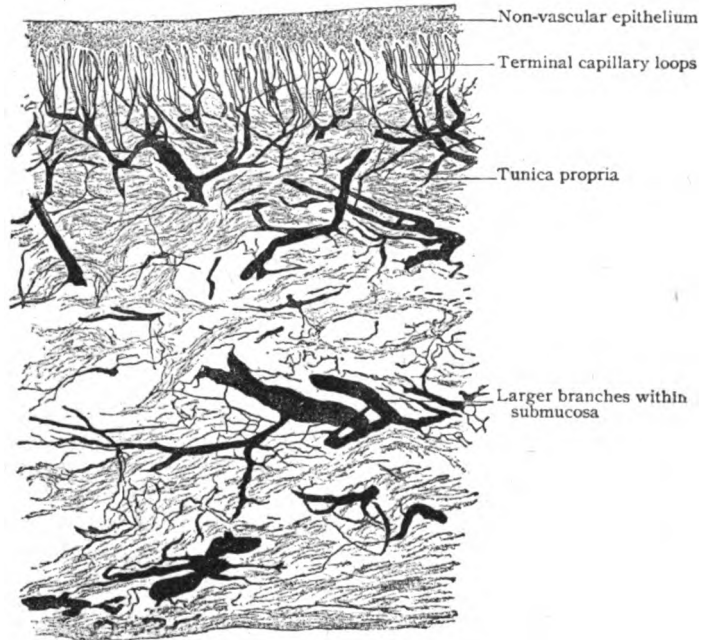


FIG. 161.—Section of injected oral mucous membrane; the terminal capillary loops occupy the papillæ of the tunica propria.  $\times 60$ .

### THE GLANDS.

Glands are essentially outgrowths from the epithelium of mucous membranes, the epithelial elements becoming modified into gland-cells which assume the rôle of secretion-forming organs, whose products are discharged on the free surface and keep the latter moist. This last purpose, however, is incidental in the case of many important glands, as the parotid, pancreas or liver, since these organs supply secretions for particular ends.

The simplest type is the *unicellular gland* found in the lower forms; in principle this is represented in man and the higher animals by the goblet-cells which occur in profusion in mucous membranes covered with columnar epithelium. The viscid secretion, or *mucus*, poured out by the goblet-cells serves to protect and lubricate the surface of the mucous membranes. The term "gland," however, commonly implies a more complex organ, composed of an aggregation of secretion-producing cells enclosed within connec-

tive tissue and provided with ducts and blood-vessels. The application of the term to lymph-nodes is undesirable, since these structures do not secrete. Further, designating such organs as the thyroid, parathyroid and suprarenal bodies as "ductless glands" seems less satisfactory, from the view-point of accurate terminology, than grouping them as "organs of internal secretion." Only those organs which produce secretions that are carried off through definite openings or ducts are entitled to the term gland.

Glands are classified according to their form into two chief groups, the *tubular* and the *alveolar*, each of which occurs as *simple* or *compound*. In many instances, however, no sharp distinction between these conventional

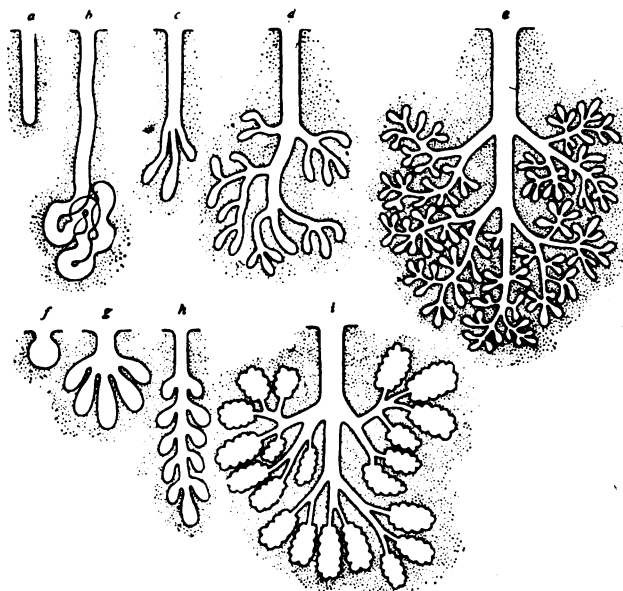


FIG. 162.—Diagram illustrating types of glands. *a-e*, tubular; *f-i*, alveolar or saccular. *a*, simple; *b*, coiled; *c, d*, increasingly complex compound tubular; *e*, tubo-alveolar; *f*, simple; *g, h, i*, progressively complex compound alveolar.

groups exists, some important glands, as the salivary, being in fact a blending of the two types; such glands are, therefore, appropriately called *tubo-alveolar*.

In the least complex type, the simple tubular, the gland consists of a cylindrical depression lined with epithelium continuous with and covering the adjacent surface of the mucous membrane, as an outgrowth of which it is developed. In such simple glands the two fundamental parts, the *fundus* and the *duct*, are seen in their primary type. The fundus includes the deeper portion of the gland, in which the epithelium has assumed the secretory function, the cells becoming larger and more spherical. The distinction between spongioplasm and the intervening substances is usually marked in consequence of the particles of secretion (metaplasm) stored up within the meshes of the spongioplastic reticulum; hence the latter is often strikingly displayed. The duct connects the fundus with the free surface and carries off the secretion produced by the gland-cells. It is lined with cells that take no part in secretion and retain for some distance the character of the adjoin-

ing surface epithelium. Dilation of the fundus of the primitive type produces the simple alveolar or saccular gland; division of the fundus and part of the duct gives rise to the compound tubular variety; repeated subdivision of the duct, with moderate expansion of the associated terminal parts, leads to the production of the tubo-alveolar type.

**Simple tubular glands** may be minute cylindrical depressions of almost uniform diameter, as the crypts of Lieberkühn in the intestine, or they may be somewhat wavy and slightly expanded at the fundus, as seen in the gastric glands towards the cardiac end of the stomach. When torsion becomes very pronounced, as in the sweat-glands, the *coiled gland* results.

**Compound tubular glands** present all degrees of complexity, from a simple bifurcation of the fundus and adjoining part of the duct, as in the pyloric glands, to the elaborate duct-system ending in tubular terminal divisions, conspicuously exemplified in the kidney.

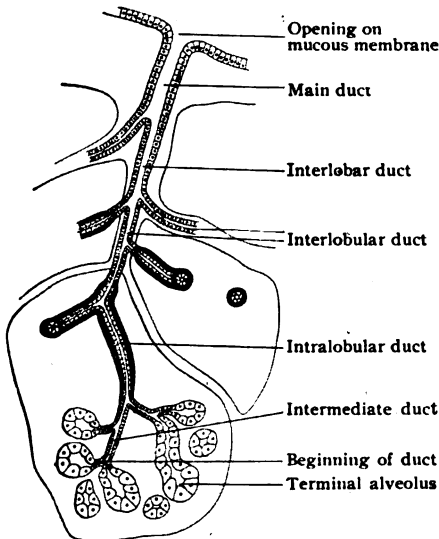


FIG. 163.—Diagram illustrating relations of duct-system in glands of tubo-alveolar type.

delicate connective tissue and constitute a pyramidal mass of glandular tissue, the *primary lobule*. The primary lobules are assembled into larger groups, the *secondary lobules*, which in turn are united by the interlobular connective tissue as the *lobes* of the gland. The lobes are held together more or less firmly by the interlobar areolar tissue continuous with the general fibrous envelope or *capsule*, which invests the entire organ and separates it from the surrounding structures.

The interlobar tissue and its interlobular continuations contain the blood-vessels, lymphatics and nerves supplying the gland and, in addition, the major part of the system of duct-tubes. In the larger glands the ducts constitute an elaborate system of passages arranged after the general plan shown in the accompanying diagram (Fig. 163). Traced from the alveoli, the duct-system begins as a narrow canal, the *intermediate duct*, lined with low cuboidal or flattened cells directly continuous with the glandular epithelium of the alveoli. After a short course the intermediate tube increases in diameter and becomes the *intralobular duct*, which is often conspicuous on

**Tubo-alveolar glands**, modified compound tubular, constitute a very important group comprising many of the chief secretory organs of the body, as the salivary glands. They are made up by the repetition of similar structural units, differences in the size of the organs depending upon the number of associated units.

Each unit corresponds to the groups of terminal compartments, or *alveoli*, connected with a single ultimate division of the duct-system. The alveoli or acini contain the secreting cells and are limited externally by a basement membrane, often well developed, which supports the glandular epithelium and separates the latter from the perialveolar blood-vessels that surround the alveolus. The alveoli belonging to the same terminal duct are held together by

account of its tall and sometimes striated epithelium. The further path of the excretory passages lies within the connective tissue separating the divisions of the glandular substance and embraces the *interlobular* and the *interlobar ducts*. The latter join to form the usually single main *excretory duct* which opens on the free surface of the mucous membrane. The excretory duct is lined for some distance by cells resembling those covering the adjoining mucous membrane; where these are stratified squamous in type, this character is retained for only a short distance within the duct, gradually giving place to the simple, sometimes at first double, layer of columnar epithelium which extends as far as the intralobular ducts. The walls of the larger ducts consist of a fibrous coat, containing much elastic tissue and lined

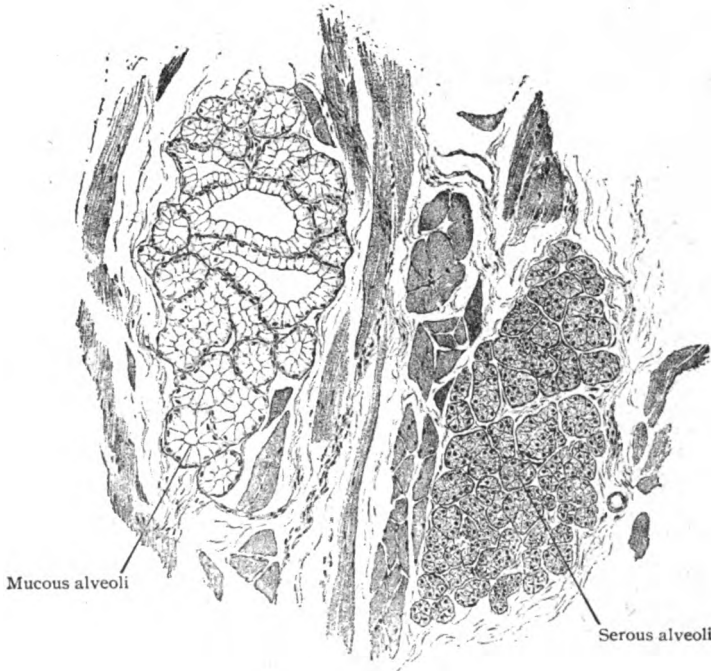


FIG. 164.—Section of tongue, showing alveoli of serous and mucous types of glands.  $\times 60$ .

by epithelium; in the large glands, as in the parotid, liver, pancreas, or testicle, the walls are strengthened externally by a layer of unstriated muscle.

The **glandular epithelium** lining the alveoli rests upon the basement membrane and usually consists of a single layer of spherical or polygonal secreting cells. The latter do not completely fill the alveolus, but leave an intercellular cleft-like lumen into which the product of the cells is poured and from which the secretion passes into the beginning of the duct. Depending upon the peculiarities of the cells and the character of their secretion, glands are divided into *serous* and *mucous*. It should be noted, however, that in many glands both serous and mucous cells occur, either within adjoining primary lobules, or, indeed, within the same alveolus.

The **serous glands** are distinguished by cells which are distinctly granular, somewhat pyramidal, and provided with nuclei situated near the centre. The secretion elaborated by such glands is thin and watery. The

general appearance of the cells depends upon the number and size of the particles or droplets of secretion stored within their cytoplasm and changes markedly with the variations of functional activity of the gland. When a serous gland is at rest, its cells are loaded with secretion and appear, therefore, larger and coarsely granular. After active function, on the other hand, the cells are exhausted and appear smaller and almost free from granules, often exhibiting a differentiation into a clear outer zone, devoid of granules, and a darker inner zone, next the lumen, in which secretion-granules still remain.

The **mucous glands** elaborate a clear viscid homogeneous secretion, which when present in quantity, as during rest, distends the cells, crowding the nuclei against the basement membrane and giving the cells a clear and transparent character.

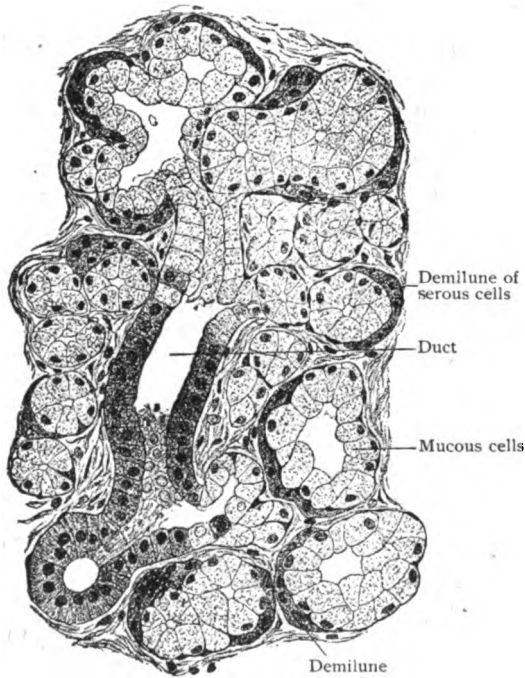


FIG. 165.—Section of sublingual gland, showing serous cells grouped as demilunes.  $\times 245$ .

and transparent character. When loaded and distended with secretion, the transparent cells have well-defined outlines and a narrow peripheral zone containing the displaced nucleus and granular cytoplasm. After prolonged activity, the exhausted cells contain relatively little secretion, hence the threads of spongioplasm are no longer separated but near together. In consequence, the cells lose their transparency and become smaller, darker and more granular than when the gland is resting.

The alveoli of mixed mucous glands often contain crescentic groups of small cells lying between the usual large clear elements and the basement membrane (Fig. 165). These are the *demilunes*. Although opinions differ as to their nature, it is probable that ordinarily they

are aggregations of serous cells. In order to afford means of escape for their secretion, since the serous cells are excluded from the lumen of the alveolus by the mucous elements, minute intercellular channels, the *secretion-canalliculi*, pass from the main lumen to the demilunes (Fig. 166). Such secretion-canalliculi are not limited to mixed mucous glands, but are found in serous alveoli and in other glands containing isolated secreting cells, as in the peptic glands of the stomach (Fig. 198). Probably not all demilunes are composed of serous cells, since small groups of mucous cells, when containing little secretion, become peripherally displaced by the distended cells and then appear as crescents. These, however, are not provided with secretion-canalliculi. Minute secretion-channels have been described within the cytoplasm of glandular epithelium, as the liver cells; it is undecided, however, whether such *intracellular secretion-canalliculi* are preformed or not.

According to the proportions of the two types of alveoli, the tubo-alveolar glands have been arranged in four groups: (a) *pure serous glands*, in which only serous alveoli are present, as the parotid; (b) *mixed serous glands*, in which a few mucous alveoli are intermingled with the serous, as in the submaxillary; (c) *mixed mucous glands*, in which the serous cells occur as demilunes, as in the sublingual and buccal; and (d) *pure mucous glands*, in which only mucous alveoli, without demilunes, are found, as in the palatal.

**Simple alveolar glands** in their typical flask-like form, abundant in the skin of the lower vertebrates, are represented by the simple sebaceous glands. The dilated sac-like fundus is lined with clear and distended cells, which become modified into duct-cells at the exit.

**Compound alveolar glands** consist of a number of saccular alveoli that open into a common duct, as in the case of the large sebaceous glands and the tarsal glands of the eyelid; or they may be much more complex, being made up of a number of alveolar systems, the ducts of which join a large excretory passage. When of such composition they strongly resemble the tubo-alveolar type, the saccular character of the alveoli being the chief distinction. The parotid and the serous part of the submaxillary are regarded by some histologists as examples of compound alveolar glands. The lung affords a conspicuous example of the principle of the compound saccular type in its mode of development and the arrangement of the air-tubes and saccular terminal compartments.

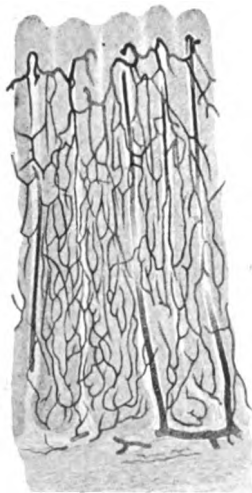


FIG. 167.—Injected gastric mucous membrane, showing capillary network surrounding tubular glands.  $\times 50$ .

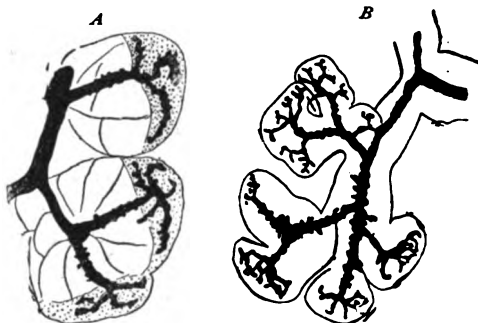


FIG. 166.—Portions of salivary glands, showing terminal ducts and secretion-canaliculi; A, from submaxillary of dog—the canaliculi extend to the demilunes of serous cells; B, from submaxillary of rabbit—the canaliculi pass between the serous cells.  $\times 500$  and  $290$ . (Retzius.)

The **blood-vessels** distributed to glands are always numerous, since an adequate blood-supply is necessary to bring to the gland-cells the materials from which their cytoplasm may select the substances required for their metabolism and secretory activity. In the case of the smaller and simpler glands, the capillaries of the mucous membrane form a meshwork outside the basement membrane enclosing the glandular epithelium. The large compound glands are provided with vessels whose general arrangement corresponds with that of the duct-system, the blood-vessels following the tracts of interlobular connective tissue and its extensions between the alveoli. On reaching the latter the capillaries form networks that overlie the basement membrane and thus bring the blood-current into close, but not direct, relation with the secreting cells. When the relation between the capillaries and the cells is unusually intimate, as it is in the liver or the

cortex of the suprarenal body, a basement membrane is wanting, a delicate reticulum and the wall of the vessel alone intervening between the bloodstream and the protoplasm of the cells. Although subject to local deviations, as in the liver, the veins follow the general course of the arteries, the larger

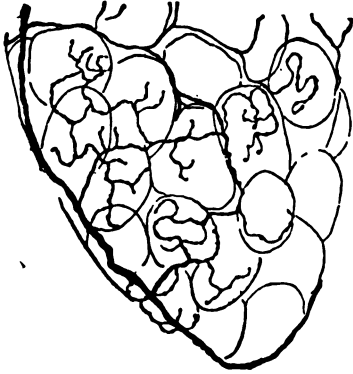

FIG. 168.—Portion of submaxillary gland of rabbit, showing distribution of nerves to the alveoli.  $\times 290$ . (Retzius.)

blood-vessels, together with the duct-tubes, the lymphatics and the nerves, occupying the tracts of connective tissue between the lobes and the lobules. The lymphatics are represented by the trunks which accompany the ducts within the interlobular tissue. Within the lobules the lymph-channels become less definite until, finally, they are recognizable only as the lymph-spaces between the bundles of connective tissue separating the alveoli.

The nerves distributed to the larger glands include both medullated and non-medullated fibres which follow the arteries and ducts, around which they form plexuses. Along these strands sympathetic ganglion-cells occur, sometimes singly but more often grouped as microscopic ganglia, from which sympathetic fibres proceed to the muscle of the blood-vessels and ducts and to the alveoli. Upon reaching the latter, the nonmedullated fibres break up into end-plexuses surrounding the alveoli; the ultimate distribution includes *epilemmar* and *hypolemmar fibrillæ*, the former lying upon and the latter beneath the basement membrane. The hypolemmar fibrillæ, derived from the extra-alveolar plexus, pass through the basement membrane and end in fine varicose threads between the gland-cells.

**Development.**—Since glands are only extensions of the mucous membrane or integument upon which they open, their development begins as an outgrowth or budding from the epithelium covering such surfaces. In the simple tubular glands the minute cylinders are closely placed and composed of densely packed cells. In the case of the larger compound glands, as the salivary or pancreas, the first anlage consists of a solid cylindrical plug which, penetrating into the mesoderm, soon begins to branch. The ends of the terminal divisions enlarge and eventually become the alveoli. Meanwhile the surrounding mesoblast undergoes condensation and forms the interlobular and other septa, as well as the general envelope, or capsule, thereby giving definite form to the glandular aggregation. The vascular and other structures usually found within the interlobular tissue are secondary and later formations. The development of the gland involves a double process of active growth, the extension of the epithelial processes and a coincident subdivision of the latter by the mesoderm to form the units of the organ. The lumen of the gland appears first in the main excretory duct, from which it extends into the secondary tubes and, finally, into the alveoli.

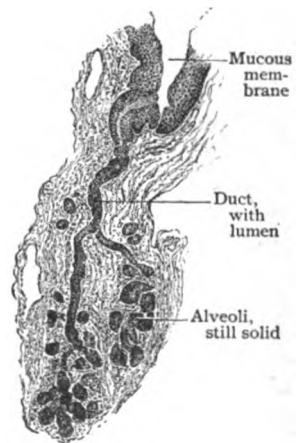


FIG. 169.—Section of fetal oral mucous membrane, showing developing tubo-alveolar gland.  $\times 50$ .



## THE ALIMENTARY CANAL.

THIS long and complicated tube, extending from the mouth to the anus, is developed from the entoderm with a mesodermic envelope, except at the two ends, each of which is at first a pouch lined by ectoderm. It consists of the mouth, pharynx and œsophagus above the diaphragm, and of the stomach and small and large intestine below the diaphragm. There are many accessory organs connected with the alimentary canal whose primary function is to assist in the processes of digestion. The most important of these above the diaphragm are the teeth, the tongue and the salivary glands; those below the diaphragm are glands of various kinds, mostly so small as to be contained within the mucous membrane. Two large organs, however, the liver and the pancreas, belong to this class, both being primarily outgrowths from the early gut-tube. The general structural plan of the alimentary canal, presenting in places, however, great modifications, includes: (1) a lining of *mucous membrane*; (2) a *submucous layer* of connective tissue into which glands may penetrate from the mucosa; (3) a double layer of unstriped *muscle*, arranged, for the most part, as an inner circular and an outer longitudinal stratum; and, below the diaphragm, (4) a *serous covering* from the peritoneum, which, although originally complete, is in the adult wanting in certain parts.

### THE ORAL CAVITY.

**The Mucous Membrane.**—The histological transition from the skin covering the exterior of the lips to the oral mucous membrane takes place gradually, the two being connected by a broad intermediate zone which approximately corresponds to the red area of the lips. The oral mucous membrane is everywhere covered with stratified squamous *epithelium*, from .2-.4 mm. in thickness, which presents the details of the varying strata of cells typical of such structures (page 17). When for any reason the large flat surface cells are not removed, as ordinarily they continually are by abrasion, they form a whitish semiopaque film that masks the rosy tint of the oral mucosa. The *tunica propria* consists of closely felted bundles of fibrous tissue and elastic fibres, and passes into the submucous stratum without sharp demarcation. Towards the surface supporting the epithelium, the bundles become more delicate and closer, so that the stroma acquires a less fibrous and more homogeneous appearance. The subepithelial border of the tunica propria is beset with innumerable minute elevations, the *papillæ*, which are especially well developed on the lips, the anterior part of the hard palate and the gums. The papillæ of the tongue are special structures and are, therefore, here not considered. Within the elevations, which contain the vascular loops and nerves, the stroma is relatively compact and homogeneous. In addition to the ordinary connective tissue cells, leucocytes and mast-cells are frequently encountered within the stroma; the mast-cells, distinguished by their coarse basophilic granules, are particularly abundant in the gum, close to the neck of the tooth. The oral mucous membrane is attached to the surrounding bones and muscles by the *submucous layer*, a stratum of generally loose fibro-elastic tissue containing the larger blood-vessels, lymphatics and nerve-trunks and the small oral glands. According

to the amount and character of this layer the mobility of the oral lining varies. Where plentiful and loose, as over the floor of the mouth, the mucosa is freely movable, while over the hard palate and the alveolar processes of the jaws the submucous tissue is so meagre that the mucous membrane is almost directly blended with the periosteum and correspondingly fixed.

The **blood-vessels** supplying the oral mucous membrane are numerous, the larger stems occupying the submucous layer, within which they form a wide-meshed network. Thence the twigs pass into the tunica

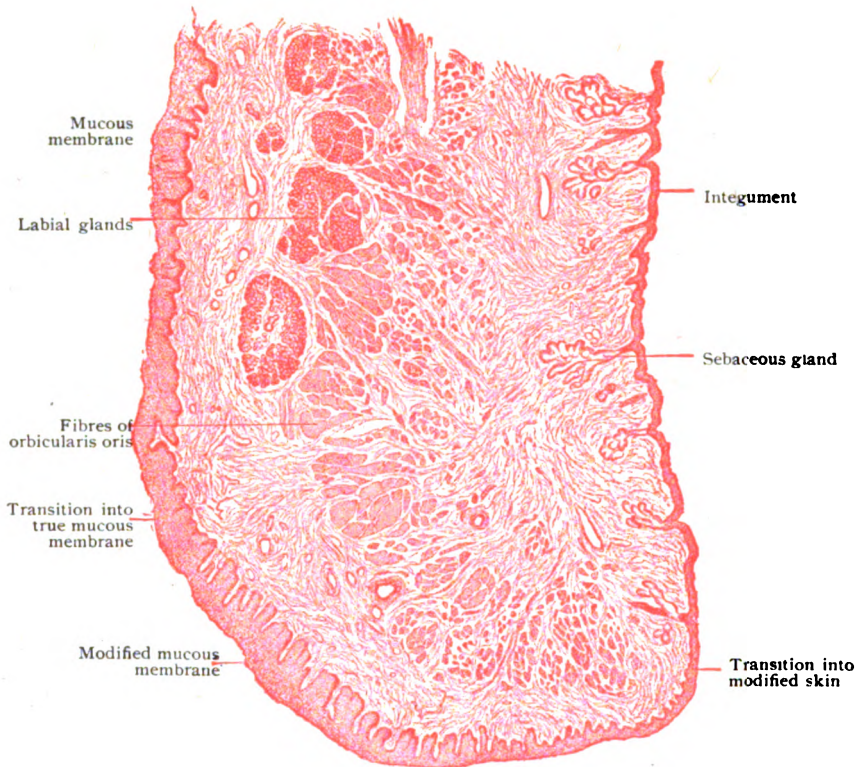


FIG. 170.—Sagittal section of lip of young child, showing transition of skin into oral mucous membrane.  $\times 20$ .

propria, where they form a second and closer network. Their ultimate distribution includes capillary loops that occupy the papillæ, the smaller elevations containing only one or two terminal loops and the large ones a tuft of half a dozen or more. The **lymphatics** are represented by a network of lymph-spaces within the tunica propria which drain into the wide-meshed reticulum of definite lymph-channels within the submucosa. The **nerves** are chiefly medullated fibres that assume a loose plexiform arrangement within the submucosa. From here numerous twigs enter the tunica propria and break up into the component fibres, which mostly terminate in the stroma and papillæ either free or in connection with end-bulbs or tactile corpuscles. A few fibres, after losing the medullary coat, penetrate the epithelium and, after repeated branching, end between the epithelial cells as naked axis-cylinders.

## THE TEETH.

In principle the teeth may be regarded as hardened papillæ of the oral mucous membrane; they consist, therefore, of two fundamental parts, the connective tissue body or core and the epithelial capping. The primary tissues become greatly modified and give rise to the three constituents of the typical mammalian tooth, of which the *enamel* is derived from the ectodermic epithelium, and the *dentine*, with the pulp, and the *cementum* are produced by the mesoderm.

**The Enamel.**—This, the hardest tissue of the body, covers the crown, the part of the tooth projecting beyond the gum, and is thickest on the cutting edge or grinding surface. It gradually thins off towards the neck, around which its terminal border appears as a wavy or serrated line. The remarkable hardness of the enamel is due to the excessive amount (97 per cent.) of earthy material and the small proportion (3 per cent.) of organic matter which it contains. The enamel—the product of epithelial cells, the *ameloblasts*—consists of an aggregation of five- or six-sided columnar elements, the *enamel-prisms*, which measure from 3–5 mm. in length and from 3–5  $\mu$  in width. Their general disposition is at right angles to both the surface of the dentine, upon which they rest, and the exterior surface of the crown. Since the prisms usually extend the entire thickness of the enamel, they are of slightly larger diameter at the surface of the tooth than next the dentine. They run for a short distance almost at right angles to the surface of the dentine, then bend laterally for a considerable part of their course, but reassume a vertical path on approaching the external surface. In addition to these general curves, the ranges of enamel-prisms have a spiral arrangement, in consequence of which the parallelism of the prisms is disturbed and the bundles appear in sections

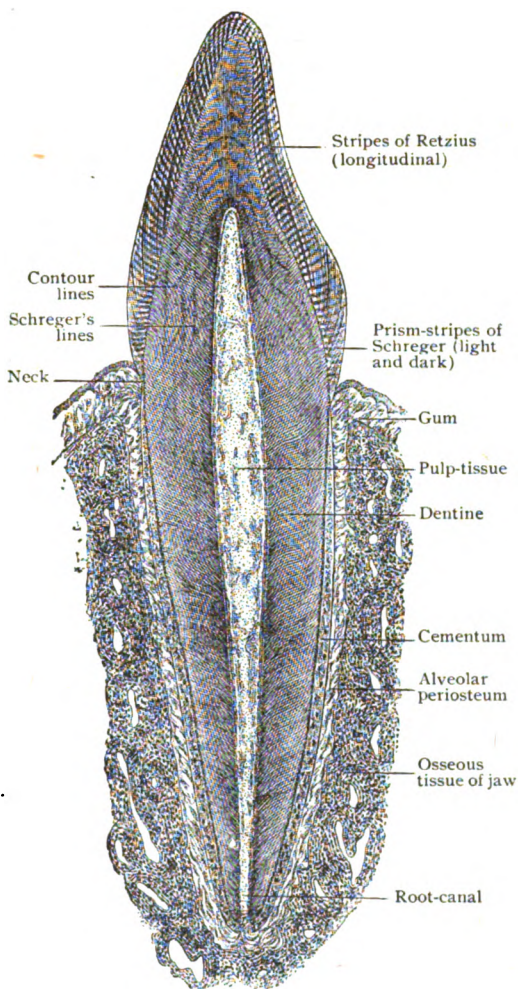


FIG. 171.—Sagittal section of canine tooth *in situ*. Semidiagrammatic.

as interwoven. In thin, accurately transverse sections, enamel presents a mosaic of minute hexagons, which are the ends of the cut individual prisms. Each prism consists of a darker central and a lighter peripheral zone, which depend upon variations of density. The lighter peripheral zone probably represents a film of less completely calcified substance and is often interpreted as cement material holding the prisms together. After decalcification and staining, the true cement substance may be distinguished as delicate lines defining the prisms. Particularly, but not necessarily, after the action of acids, the enamel-prisms in longitudinal sections exhibit alternate light and dark transverse markings with seemingly beaded or varicose outlines. These appearances are probably optical and depend upon the wavy contour of the central denser substance of the prisms. The true outlines of the prisms are straight, the opposed surfaces of the adjoining columns being separated by a uniform thin layer of the cement-substance.

When an axial longitudinal section of a ground tooth is examined by reflected, not transmitted, light, the enamel exhibits a series of alternate dark and light bands, known as the *prism-stripes of Schreger*. These markings (Fig. 171), which are comparatively coarse and generally vertical to the surface of the tooth, depend upon the relation of the ranges of enamel-prisms to the axes of the rays of light. Rotation of the illuminating pencil through  $180^\circ$  changes the dark stripes to light ones and *vice versa*. Each stripe includes from ten to twenty enamel-prisms and is invisible by transmitted light. In addition to the foregoing markings, the enamel often presents, in radial longitudinal sections, brownish parallel lines, the *stripes of Retzius*, which correspond in their general direction with the contour of the tooth, but run at an angle of from  $15^\circ$  to  $30^\circ$  with the free surface. In cross sections, these stripes are represented by a series of concentric lines encircling the crown, parallel to and near the surface; in the middle and deeper parts of the enamel they are much less evident or entirely wanting. The significance of the



FIG. 172.—Ground section of enamel, showing ranges of enamel-prisms.  $\times 500$ .

stripes of Retzius is still disputed, but it is probable, since they surely do not depend upon pigment, that they are due to local imperfections of the calcification of the enamel-prisms during certain periods of the growth of the enamel.

The *enamel-cuticle*, or *membrane of Nasmyth*, is a delicate envelope that completely invests the crown of the newly-erupted tooth. In the course of time it disappears from the areas exposed to wear, but over the protected surfaces it may persist throughout life. The membrane (from  $2-4 \mu$  in thickness) is transparent, structureless and resistant to the action of acids, less so to alkalis, and affords protection to the subjacent enamel. Since the cuticle is not only continuous with the cortical substance of the enamel-prisms, but also agrees with it in optical and chemical properties, the origin of the membrane may be referred to the enamel-producing elements, the epithelial cells forming the inner layer of the enamel-organ (page 140). After the completion of their work in producing the enamel-prisms, they produce a continuous envelope, which never undergoes calcification and remains as the enamel-cuticle.

**The Dentine.**—The dentine or ivory, the substance which contributes the bulk of the tooth, encloses the cavity containing the pulp and is itself surrounded by the enamel and the cementum. In both its genesis and chemical composition, dentine resembles bone, like the latter being a connective tissue modified by impregnation with lime-salts. Dentine exceeds bone in hardness and contains a larger proportion (72 per cent.) of earthy matter and a smaller amount (28 per cent.) of organic substance. After decalcification with acids, the remaining animal material retains the previous form of the dentine and yields gelatin on prolonged boiling in water. Dentine, like bone, is formed through the agency of specialized connective tissue cells, the *odontoblasts*, but differs from it in the small number of these cells which become imprisoned in the intercellular matrix. When this occurs, as it occasionally does, the *dentine-cells* correspond to the bone-cells, both being connective tissue elements within lymph-spaces in the calcified intercellular substance.

Examined in dried sections under low magnification, the dentine exhibits a radial striation, composed of fine dark lines which extend from the pulp-cavity internally to the enamel externally. These dark lines are the *dentinal tubules*, filled with air, which are homologous with the lacunæ and canaliculi of bone and contain the *dentinal fibres*, as the processes of the odontoblasts are called. In the crown, as seen in longitudinal sections, the course of the dentinal tubules is radial to the pulp-cavity; in the body and fang their course is approximately horizontal and almost parallel. The canals, however, are not straight but wavy, the first bend being directed towards the root and the second towards the crown. In addition to these *primary curves*, especially marked in the crown, the tubules exhibit numerous shorter *secondary curves*, the whole arrangement imparting to the individual canals a spiral course. In consequence of the uniformity of these curvatures, the tooth-ivory displays a series of linear markings, *Schreger's lines*, which parallel the outer surface of the dentine. These markings, however, must not be confounded with another set of striæ, the *contour lines of Owen*, or the *incremental lines of Saller*, which, best seen in the crown, run obliquely to the surface of the dentine (Fig. 171) and depend probably upon variations in calcification incident to the growth of the dentine.

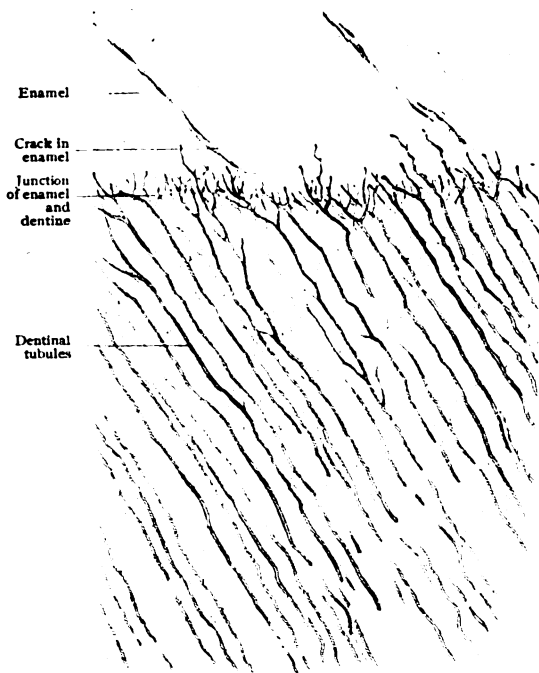


FIG. 173.—Ground section of human tooth including adjoining enamel and dentine.  $\times 280$ .

The **dentinal tubules** are minute canals (from  $1-2 \mu$  in diameter), which begin at the pulp-cavity, where they are largest, and extend to the outer surface of the dentine, to end beneath the enamel or the cementum. Each spirally coursing canal undergoes branching of two kinds, a dichotomous division at an acute angle in the vicinity of the pulp-cavity, resulting in two canaliculi of equal diameter, and a lateral branching during the outer third of their course, whereby numerous tubuli of diminishing size are given off. The dentinal tubules are occupied by the *dentinal fibres*, the processes of the odontoblasts within the pulp, which in the young tooth are proto-

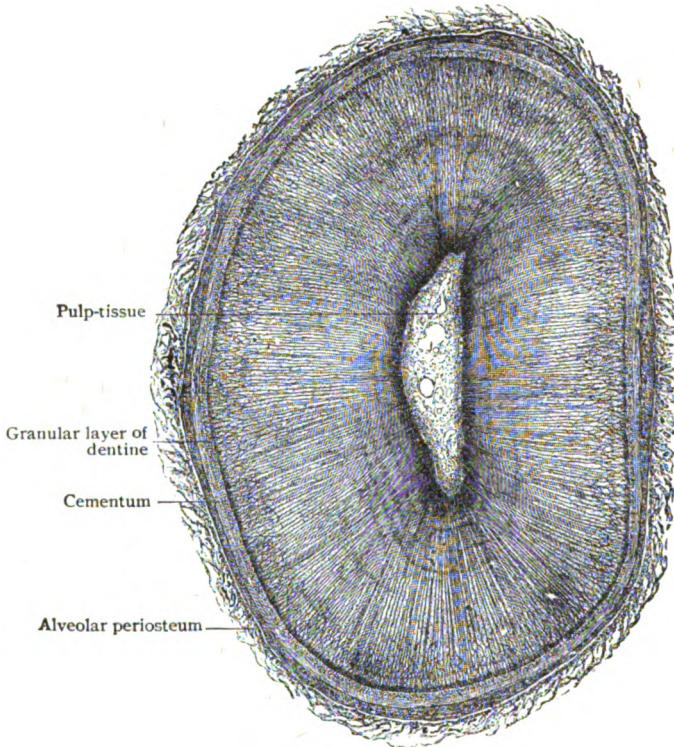


FIG. 174.—Transverse section of root of lower canine tooth.  $\times 30$ .

plasmic threads; later they lose this character and become harder and stiffer. The dentinal tubules differ in their mode of ending in the crown and the root. In the former situation, the outer surface of the dentine is indented with small crescentic depressions, filled with enamel, in which the tubules abruptly end, as if cut off. On the root, where the surface of the dentine is smooth and covered with cementum, the tubules end in curves or loops beneath the cementum, only in exceptional cases communicating with the canaliculi of the cementum. The immediate walls of the dentinal tubules are formed by delicate membranes, the *dentinal sheaths* of Neumann, which are specialized parts of the intertubular matrix of greater density and less complete calcification. After softening the decalcified dentine by alkalis, the sheaths may be isolated, since they resist the action of reagents which attack the surrounding substance.

The intertubular **dentine-matrix** resembles that of bone in being composed of bundles of extremely delicate fibrous fibrillæ that swell on treatment with water containing acids or alkalies and yield gelatin after prolonged boiling in water. The disposition of the bundles of fibrillæ, more regular in dentine than in bone, is chiefly longitudinal and parallel to the primary surfaces of the dentine; additional bundles run obliquely crosswise in the layers of dentine. The bundles of fibrillæ, from 2–3  $\mu$  in diameter, appear in transverse sections as small punctated fields. The fibrillæ are knit together by the calcified ground-substance, in which the lime-salts are deposited in the form of minute spheres, the interstices between the spherules being later filled and calcification thus completed. When, as often happens, the calcification is imperfect, irregular clefts, the *interglobular spaces*, result. These spaces are bounded by the spherules, or *dentine-globules*, of calcareous material and are of irregular form and uncertain extent, being, however, usually largest in the crown. The junction of the dentine and cementum is always marked by a zone of closely placed interglobular spaces of small size; under low magnification in ground sections these spaces appear as dark granules, hence the zone is called the *granule layer* of Tomes.

**The Cementum.**—The cementum, the *crusta petrosa* of the older writers, forms an investment of modified bone that covers the outer surface of the dentine from the neck to the apex of the tooth. Beginning where the enamel ends, or overlapping the latter to a slight extent, the cementum gradually increases in thickness until over the root, especially between the fangs of the molars, it forms a layer several millimeters thick. The matrix of the cementum differs from that of ordinary bone in containing slightly less organic matter and a greater number of fibre-bundles that run vertically to the bone-lamellæ. These bundles correspond to the fibres of Sharpey in other situations. The lacunæ are larger than those of ordinary bone and the canaliculi are unusually long and elaborate. As in bone, so in the cementum these lymph-spaces contain connective tissue elements, the *cementum-cells*. Although connecting with one another by means of the canaliculi, the lacunæ seldom communicate with the dentinal tubules, the latter commonly ending in loops or blind expansions. The outer surface of the cementum is intimately attached to the surrounding alveolar periosteum, the so-called *pericementum*, since from the latter the cementum is derived. Typical Haversian canals are found in cementum only when this layer is hypertrophied.

**The Alveolar Periosteum.**—The periosteum investing the jaws also lines the sockets receiving the roots of the teeth, which are by this means securely held in place. The name, *pericementum* or *peridental membrane*,

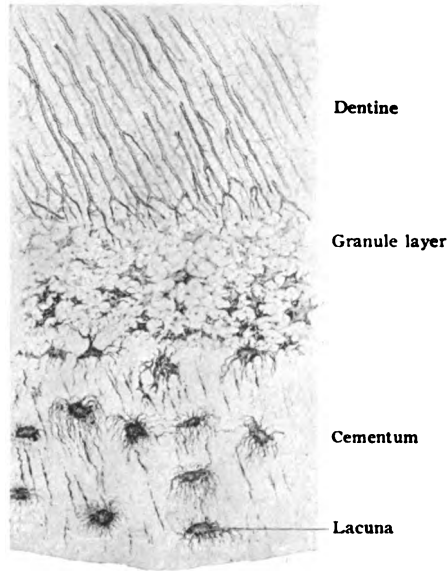


FIG. 175.—Ground section of root of dried tooth including adjoining dentine and cementum.  $\times 300$ .

is often applied to this part of the periosteum, which lines the alveoli, on the one hand, and covers the cementum on the other and thereby fulfils the double rôle of periosteum and root-membrane. The alveolar periosteum is made up of tough bundles of fibrous tissue, elastic fibres being almost wanting, which are prolonged as the penetrating fibres into the cementum, on one side, and as the fibres of Sharpey into the alveolar wall, on the other. In the upper part of the root, the fibrous bundles are almost horizontal, but towards the apex they are more oblique, the periosteum here losing its dense character and becoming a loose connective tissue through which the blood-vessels and nerves pass to the root-canal on their way to the pulp. At the alveolar border the pericementum is directly continuous with the stroma of the gum and immediately beneath the border of the enamel the fibrous bundles are consolidated into a dense band, the *ligamentum, circulare dentis*, which still further aids in maintaining the firm union between the tooth and

the alveolar wall. In addition to blood-vessels and nerves, within the pericementum lie irregular groups of epithelial cells, which appear as cords or networks within the connective tissue stroma. The groups are the remains of the enamel-sheath (page 140), which surrounded the young tooth during its early development, and have been mistaken for glands.

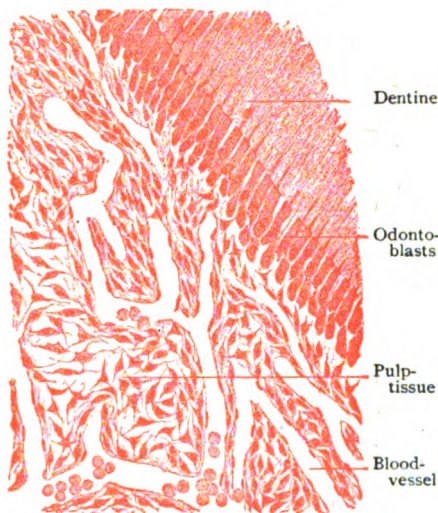


FIG. 176.—Section of periphery of pulp-tissue of young tooth.  $\times 175$ .

**The Pulp.**—The contents of the pulp-cavity is the modified mesodermic tissue of the dental papilla remaining after the formation of the dentine. The adult pulp consists chiefly of soft highly vascular connective tissue, containing few or no elastic fibres but many irregularly distributed cells. The general type of the tissue resembles embryonal, both in its fibrous tissue and in its cells, the latter being round, oval or

stellate with long processes. The peripheral zone of the pulp, next the dentine, is of especial interest, since in this situation lie the direct descendants of the dentine-producing cells, the *odontoblasts*. These are tall columnar cells, arranged vertically to the surface of the pulp, about  $25 \mu$  in length and  $5 \mu$  in breadth, which send out long delicate processes, the *dentinal fibres*, into the dentinal tubules and short ones into the pulp-tissue. The spaces between the bases of the odontoblasts are occupied by smaller cells, less regularly disposed and less cylindrical and more uncertain in form.

The **blood-vessels** supplying the pulp are from three to ten small arteries which break up into capillary networks soon after entering the pulp-cavity. In human teeth the capillaries usually do not invade the layer of odontoblasts. The larger veins, formed by thin-walled radicles, follow the general course of the arteries. **Lymphatics** have been recently demonstrated within the pulp as networks. The **nerves** supplying the pulp-tissue are numerous, each fang receiving a main stem and several additional smaller twigs, which in a general way accompany the blood-vessels. They include



both medullated and nonmedullated fibres, the latter being sympathetic fibres destined for the walls of the blood-vessels. On reaching the crown-pulp, the larger twigs are replaced by finer branches that subdivide into many fibres. These, on reaching the periphery of the pulp, form a plexus beneath the layer of odontoblasts from which nonmedullated axis-cylinders are given off. Some of these end beneath the odontoblasts in minute nodular swellings; others penetrate between the odontoblasts and terminate in pointed or bulbous free endings. Delicate fibres have been traced from the superficial pulp-nerves into the dentinal tubules.

### DEVELOPMENT OF THE TEETH.

About the beginning of the seventh week of foetal life, the ectodermic epithelium thickens along the margins of the oral opening and forms a ridge of proliferated epithelium, the *labio-dental strand*. This grows into the surrounding mesoderm and divides into two plates which, while continuous at the surface, diverge almost at right-angles at the deeper plane. The lateral or outer plate is vertical and corresponds to the plane of separation, effected by the *labial furrow*, that later occurs in differentiating the lips from the tissues forming the jaw. The median or inner plate grows more horizontally into the mesoderm and is the one directly concerned in the tooth-development; for this reason it is termed the *dental ledge*.

The anlages or embryonic rudiments of the milk-teeth are indicated by club-shaped epithelial outgrowths, which grow from the deeper surface of the dental ledge to form the *enamel-organs*, as well as to meet, and later cap, the mesodermic elevations, the *dental papillæ*. The bulbous end of the epithelial outgrowth increases rapidly and differentiates into the typical three-layered enamel-organ. The latter is attached for a time to the dental ledge by a broad strand of cells, which becomes more and more reduced until, finally, it is broken and the enamel-organ is isolated from the oral epithelium.

**The Dental Papilla.**—This structure appears, shortly after the club-shaped enamel-organ begins to expand (Fig. 177, C), as a condensation of the mesoderm beneath the epithelial outgrowth. At first the papilla consists of a close aggregation of small round proliferating cells, but later, coincidentally with the differentiation of the three layers of the enamel-organ, the peripheral cells of the dental papilla become elongated and arranged as a continuous row of cylindrical cells, which cover the apical portion of the papilla and lie beneath the enamel-organ. These cylindrical mesodermic cells are the *odontoblasts*, the active agents in the production of the dentine. Where engaged in this process, particularly over the summit of the papilla, the cells measure from 35–50  $\mu$  in length and from 5–10  $\mu$  in breadth, but over the sides of the papilla they gradually become lower and less characteristic, until, at the base, they resemble the central cells of the papilla. So long as the tooth grows, odontoblasts are differentiated in the vicinity of the last-formed part of the root; after such differentiation and the odontoblasts engage in producing dentine, mitosis is no longer observed in these cells.

The formation of the dentine is accomplished through the agency of the odontoblasts in the same manner as the osteoblasts produce the matrix of bone. The earliest dentine appears as a thin homogeneous stratum, the *predentine*, which overlies the tip of the papilla and underlies the enamel-organ. This layer is resolvable into collagenous fibrillæ similar

to those of bone-lamellæ. The *dentine-matrix*, deposited through the activity of the odontoblasts, is for a time uncalcified. The deposits of lime-salts occurs first over the apex of the papilla and next the enamel, a zone of uncalcified matrix around the pulp-cavity marking the youngest dentine. The calcareous material is deposited in the form of minute spheres, the *dentine-globules*, calcification being completed by the subsequent filling of the interglobular clefts. When for any reason calcification is incomplete, these clefts remain

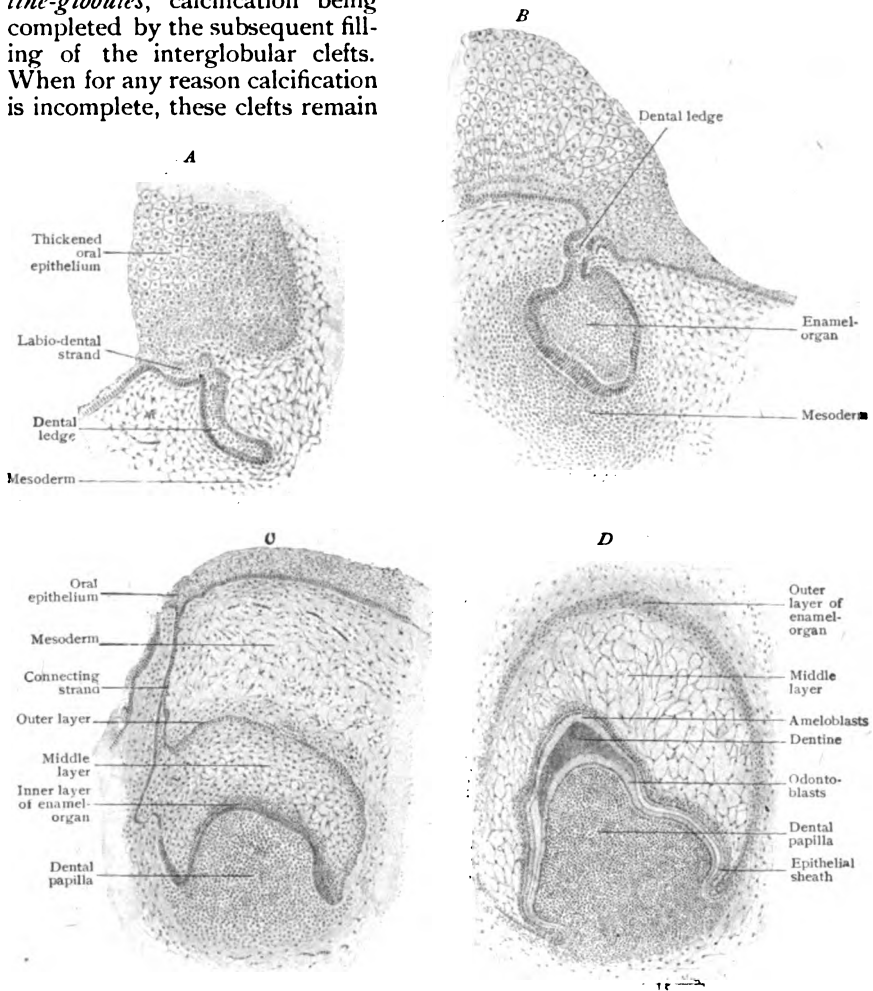


FIG. 177.—Sections showing four early stages of tooth-development. A, B,  $\times 75$ ; C, D,  $\times 50$ .

uninvaded and are recognized as the interglobular spaces. The dentine-matrix differs from that of bone in being produced by a single set of cells, while the bone-matrix is the collective work of relays of osteoblasts which, while contributing their increment, become imprisoned in the lacunæ within the matrix that they have formed. In human dentine, on the contrary, the odontoblasts remain on the surface and only exceptionally become enclosed within the dentine-matrix. With the completion of dentine-production, the odontoblasts become narrower and smaller and later exhibit evidences of

impaired vitality. Their dentinal processes likewise grow thinner and less flexible and gradually assume the characteristics of the dentinal fibres. The portions of the dental papilla remaining after the dentine has been completed persist as the definite pulp-tissue, receiving a generous vascular and nervous supply.

**The Enamel-Organ.**—The end of the ectodermic epithelial outgrowth, which early marks the position of the future tooth, soon broadens and becomes invaginated to form the young enamel-organ that overlies the top of the mesodermic dental papilla (Fig. 177). In contrast to the latter, which as the pulp-tissue partially persists as a permanent structure, the enamel-organ is only transient and ultimately disappears. When fully developed, the enamel-organ consists of three principal parts, the outer, middle and inner layers. Since the organ is converted into a cap by the pushing in or invagination of its broader and deeper surface, it follows that the outer and inner layers are directly continuous at the margin of the invested area. The *outer layer* consists of flattened epithelial cells, which send processes into the surrounding vascular connective tissue that invests the tooth-germ as the



FIG. 178.—Isolated odontoblasts from tooth of newborn child.  $\times 300$ . (Ebner.)

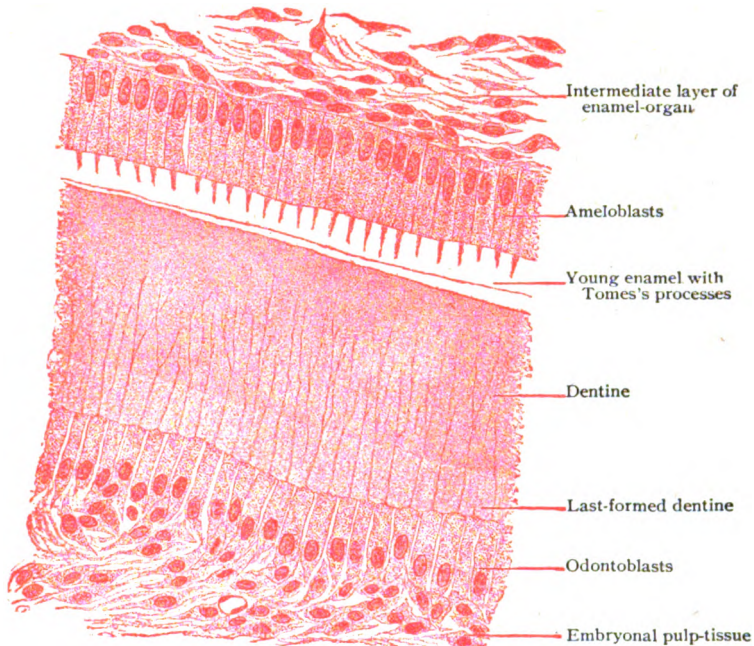


FIG. 179.—Section of developing tooth through junction of enamel and dentine.  $\times 400$ .

*dental sac*. The *middle layer*, conspicuous by reason of its clear loose texture, consists of epithelial elements that have become highly modified in consequence of an enormous distention of the intercellular clefts by fluid, the epithelial plates in this manner being reduced to stellate cells connected by delicate processes. The inner border of this peculiar area constitutes

a transitional zone known as the *intermediate layer*. This is best marked over the upper part of the crown, at the sides thinning out and entirely disappearing at the margin of the enamel-organ. The *inner layer* of the enamel-organ comprises a single row of closely set tall columnar elements, the *enamel-cells*, also called *adamantoblasts* or *ameloblasts*, through whose active agency the enamel is produced. The ameloblasts are best developed over the top of the dental papilla, where they measure from 25–40  $\mu$  in length and from 4–7  $\mu$  in breadth. They possess oval nuclei that usually lie close to the outer ends of the cells. The ameloblasts are united by a small amount of cement-substance and defined from the intermediate layer by a distinct border. Over the sides of the dental papilla, corresponding to the lateral limit of the future crown, the ameloblasts gradually diminish in height until they are replaced by low cuboidal cells which, at the margin of the enamel-organ, are continuous with the epithelium of the outer layer. Preparatory to the formation of the dentine of the root of the tooth, this margin of the enamel-organ grows towards the base of the elongating dental papilla, which is in consequence embraced by the extension of the enamel-organ. This investment is known as the *epithelial sheath* (Fig. 177, D), a structure of importance in determining the form of the tooth, since it serves as a mould in which the dentine is deposited; there is, however, insufficient evidence to regard the epithelial sheath as an active or even necessary factor in the production of the dentine.

The formation of the enamel results from the activity of ectodermic epithelium and may be regarded as a cuticular development carried on by the ameloblasts. The initial phase in the production of the enamel is the appearance of a delicate cuticular zone at the inner end of

each ameloblast; this fuses with the zones capping the adjoining cells to form a continuous homogeneous layer. The latter differentiates into rod-like segments, the *enamel-processes*, or *processes of Tomes*, which are the rudiments of the enamel-prisms and the interprismatic substance. The latter gradually decreases in amount as the formation of the enamel-columns progresses, since the greater part of this intercolumnar substance is transformed into the cortical portion of the enamel-prisms, while the remainder persists as the meagre cement-substance between the mature prisms. The enamel-processes are for a time uncalcified, but later the calcareous material is deposited as

FIG. 180.—Isolated ameloblasts from new-born child. *a*, basal plate; *b*, cuticular border; *c*, processes of Tomes; *d*, homogeneous mass still capping process.  $\times 400$ . (Ebner.)

granules and spherules, which appear first in the axis of the prisms. The developing enamel increases in thickness by the addition of the increments formed at the inner ends of the ameloblasts, the same cells sufficing for the production of the entire tissue. The earliest formed enamel lies in apposition with the oldest dentine, the youngest enamel immediately beneath the ameloblasts. The enamel is deposited, therefore, from within outwards, or in the reverse of the direction followed by the growth of the dentine. The oldest strata of both substances lie in contact; the youngest on the outer and inner surfaces of the tooth. After the requisite amount of enamel has been produced, differentiation into prisms ceases; consequently the last-formed enamel remains as a continuous homogeneous layer which invests the free surface of the crown and constitutes the enamel-cuticle or membrane of Nasmyth.

**The Tooth-Sac.**—Coincidentally with the development of the enamel-organ and the growth of the dental papilla, the surrounding mesoderm differentiates into a connective tissue envelope known as the dental or tooth-sac. The latter not only closely invests the enamel-organ, but is intimately related to the base of the dental papilla. In contrast to the epithelial enamel-organ which is entirely without blood-vessels, the inner part of the tooth-sac is abundantly provided with capillaries and is, therefore, an important source of nutrition for the growing dental-germ. The part of the sac opposite the root of the young tooth at first is prevented from coming into contact with the dentine by the double layer interposed by the epithelial sheath. This relation continues until the cementum begins to develop, when the vascular tissue of the dental sac breaks through the epithelial sheath to reach the outer surface of the dentine, upon which the cementum is deposited. In consequence of this invasion the epithelial sheath is broken up into small groups or nests of cells that persist for a long time as the epithelial islands encountered within the fibrous tissue of the alveolar periosteum, into which the dental sac is converted. As development proceeds, the tissue of the tooth-sac becomes denser, the part opposite the root persisting as the pericementum, while the superficial part blends with the tissue forming the gum.

The formation of the cementum is brought about through the agency of mesodermic tissue in a manner almost identical with the development of mesoperiosteal bone (page 47), the cement-producing cells, the *cementoblasts*, corresponding to osteoblasts, and like them bringing about a deposit of osseous matrix upon the osteogenetic fibres from the alveolar periosteum. The cementum appears first in the vicinity of the neck of the tooth and thence progresses towards the apex of the root, as the dentine of the fang is formed. The layer of cementum is thickest at the apex, which it invests except where the canal or canals remain for the blood-vessels and nerves that pass to the pulp-cavity.

Provision for the development of the permanent teeth is made by the early differentiation of a second set of dental rudiments during the growth of the first. This includes the outgrowth of the enamel-organs of second dentition from the dental ledge and the subsequent appearance of new dental papillæ from the mesoderm. The enamel-organ for the first permanent molar appears about the seventeenth week of foetal life and is soon followed by the corresponding dental papilla. The germs of the permanent incisors and canines, including the papillæ, are formed about the twenty-ninth week and those for the premolars about one month later. The enamel-organ of the second permanent molar appears about four months after birth and the papilla about two months later, while the enamel-sac for the third molar, which forms about the third year, precedes its papilla by almost two years. It is evident, therefore, that the development of these teeth proceeds very slowly, the embryonal structures being present years before the eruption of the permanent teeth. The presence of the milk teeth and of the germs of the permanent ones results in excessive crowding in the jaws during the fifth year. In order to accommodate the representatives of both sets, the crowns of the permanent teeth press between and against the roots of the milk teeth, which then undergo absorption. The latter process is effected by connective tissue cells, the *odontoclasts*, in a manner similar to that by which bone is removed by the osteoclasts. In consequence, before the temporary tooth is displaced it often is reduced to little more than the crown. Not until some time after eruption are the roots of the permanent teeth fully formed.

## THE TONGUE.

The tongue is essentially a complex mass of striped muscle, the free surfaces of which are covered by an extension of the mucous membrane lining the mouth and the pharynx.

The **muscles** of the tongue include two groups, the *extrinsic* and the *intrinsic*. The former (the genio-glossus, the hyo-glossus, the stylo-glossus and the palato-glossus) are all paired and extend from the skull or the hyoid bone to the tongue; the latter comprise the particular muscle, the *lingualis*, forming the chief mass of the organ. The tongue is incompletely divided into symmetrical halves by a vertical partition of dense connective tissue, the *septum linguæ*, which extends from the hyoid bone behind to the tip of the tongue but fades away before reaching the apex. It is much better developed in the middle third of the tongue than at the ends, but even here the septum

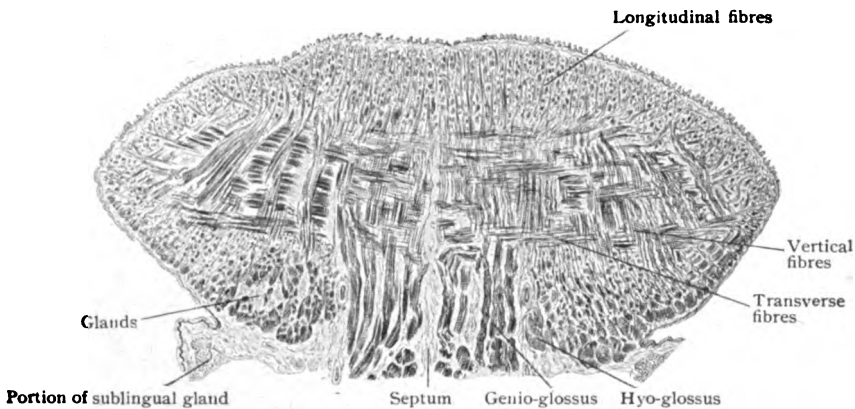


FIG. 181.—Transverse section of child's tongue, through middle third.  $\times 3$ .

falls short of the dorsal mucous membrane by a few millimeters. On viewing with low magnification a cross-section of the tongue at its middle third (Fig. 181), the intricate feltwork of muscle-fibres is seen to comprise fibres running in three general directions—longitudinal, vertical and transverse. The *longitudinal fibres* appear transversely sectioned and form a well-marked superficial or cortical layer, some 5 mm. thick, immediately beneath the scanty submucous tissue covering the dorsum. These fibres include the principal part of the lingualis muscle, supplemented by fibres from the stylo-glossus. The *vertical fibres*, most conspicuous as the deeply placed and obliquely cut masses of the genio-glossus on either side of the septum, radiate towards the dorsal surface, where the lingual bundles end in the submucous layer. The *transverse fibres* are entirely from the lingualis, with the exception of those contributed by the palato-glossus. They arise from the septum and interlace with the vertical and longitudinal bundles; on approaching the mucosa, they break up into strands which find their way between the superficial longitudinal fibres to a submucous insertion. Branching is a peculiarity exhibited by many muscle-fibres that end in the submucosa.

The **mucous membrane** of the tongue corresponds in general structure with that lining the adjacent surfaces of the mouth and pharynx in consisting of the epithelium, the tunica propria and the submucous layer. Over the

sides and under surface of the tongue it is thin and smooth, with small papillæ towards the tip; on the dorsum the mucous membrane is greatly modified and presents characteristic appearances. The dorsal surface, moreover, includes two areas, the *papillary* and the *lymphoid*, which exhibit very different details.

The **papillary area** comprises the anterior two thirds, the lymphoid the posterior third. In the infant's tongue the junction of these areas is marked by a V-shaped groove, the *sulcus terminalis*, but this disappears and later the boundary is indicated by the conspicuous row of circumvallate papillæ. The anterior area is everywhere beset with elevations, the **papillæ**, which are of three varieties—the filiform, the fungiform and the circumvallate. The *filiform* or *conical papillæ*, so abundant as to impart a velvety

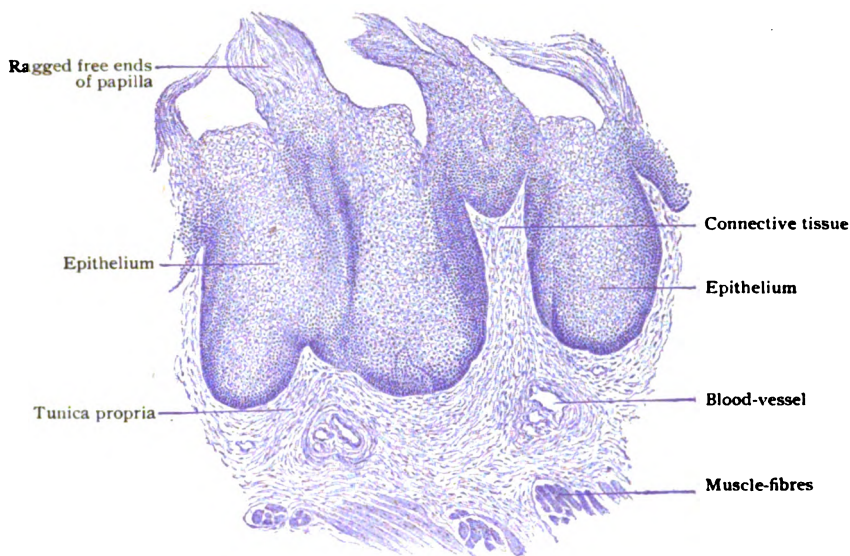


FIG. 182.—Section of lingual mucous membrane showing filiform papillæ.  $\times 75$ .

appearance to the tongue, are conical or cylindrical elevations of the tunica propria, composed of fibrous connective tissue with many elastic fibres and covered by a thick stratum of epithelium. The surface of the connective tissue core bears a number of small secondary papillæ, which, however, do not model the free surface of the mucous membrane. The filiform papillæ vary from .5–2.5 mm. in height and often end in brush-like strands of horny epithelial cells. The *fungiform papillæ* are far less numerous than the filiform and appear during life as red points, chiefly near the margins of the tongue, in consequence of their thinner epithelium. As implied by their name, they are more or less mushroom-like in form and vary from .5–1.5 mm. in height. The connective tissue core is beset with a number of secondary papillæ, over which stretches a smooth layer of epithelium. The latter contains occasional taste-buds. The *circumvallate papillæ*, the most conspicuous of these elevations, usually number nine or ten, from six to sixteen being the extremes. They are disposed as an irregular V, with the apex of the group directed backwards. These elevations, from 1–1.5 mm. high and from 2–3.5 mm. broad, consist essentially of a fungiform papilla sur-

rounded by a shallow groove bounded externally by a low annular wall. Their chief interest is their being the principal seats of the taste-buds (page 385), which are lodged within the epithelium lining the mesial wall

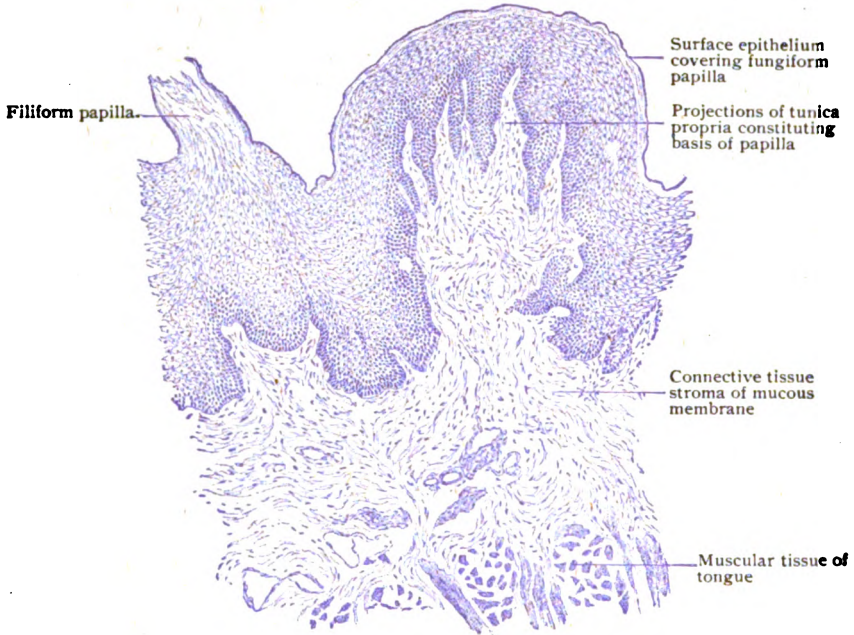


FIG. 183.—Section of lingual mucous membrane, showing fungiform papilla.  $\times 75$ .

of the groove. Into the bottom of this groove open the ducts of the serous lingual glands. At the edges of the tongue, on each side just in front of the

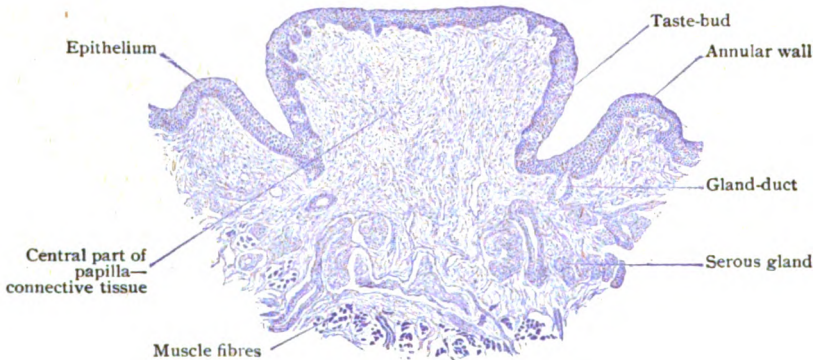


FIG. 184.—Section across circumvallate papilla from child's tongue, showing central part and encircling wall.  $\times 45$ .

anterior palatine pillar, may be seen a series of small transverse parallel ridges, the *papille foliate*. This structure, varyingly pronounced in man but well developed in the rodents, is of interest on account of the many taste-buds which it often contains.



The posterior or **lymphoid area**, the part of the dorsum behind the circumvallate papillæ, presents a striking contrast to the anterior two thirds of the mucous membrane. The surface is thrown into uncertain rounded elevations, which, while smooth and devoid of papillæ, impart to this portion of the tongue an uneven and mammillated appearance that is further accentuated by numerous minute pits. The latter lead into small crypts, each lined by stratified epithelium continued from the surface and surrounded by a zone of lymphoid tissue. The latter contains a number of lymph-nodules, with germ-centres, blended together by the intervening diffuse lymphoid tissue and lodged in the tunica propria. These spherical masses, the *folliculi linguales*, resemble in miniature the lymphoid organs found on the side-walls of the oro-pharynx and, hence, are often termed collectively the *lingual tonsil*.

The **glands of the tongue** include both mucous and serous varieties, which are distributed in three groups: (1) the serous glands, (2) the mucous glands and (3) the anterior sero-mucous glands. The *serous glands* are small and occur in the vicinity of the circumvallate and foliate papillæ,

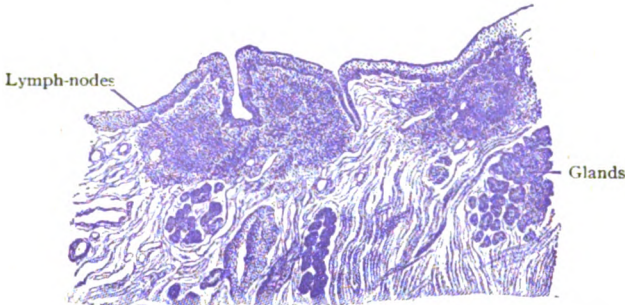


FIG. 185.—Section from posterior third of child's tongue, showing lymphoid tissue constituting a part of the lingual tonsil.  $\times 30$ .

occupying the deeper part of the tunica propria, with some alveoli between the subjacent muscle-bundles. Their ducts lead through the mucosa and open preferably at the bottom of the furrows along which the taste-buds are lodged. They belong to the tubo-alveolar group, with the tubular type of the ultimate compartments pronounced. The gland-cells are somewhat pyramidal, rest upon a basement membrane of great delicacy, and secrete a thin, watery, albuminous fluid. The *mucous glands* are found just in advance of the more median circumvallate papillæ, along the margins of the tongue, and scattered through the lymphoid area, especially towards the root. They are tubo-alveolar in type and among the examples of pure mucous glands. Their viscid, mucin-containing secretion is produced by the cylindrical gland-cells and carried off by ducts, which are lined with columnar epithelium and open on the free surface or, not infrequently, into the lymphoid crypts. The *anterior lingual glands*, or *glands of Nuhn*, form two elongated groups, 15–20 mm. long and 7–9 mm. wide, which lie near the tip of the tongue, on either side of the mid-line. Both serous cells and mucous alveoli occur, hence they belong to the mixed mucous and tubo-alveolar type and possess demilunes. They open on the under surface of the tongue.

The **blood-vessels** of the tongue include, in addition to the branches of the lingual artery that break up into capillary networks supplying the muscles, a vascular meshwork within the mucous membrane from which twigs ascend to the papillæ. Each of the latter contains a tuft of elongated

capillary loops (Fig. 186) which occupies the connective tissue stroma, including that of the secondary papillæ. Other twigs pass to the glands and end in capillary networks that surround the alveoli; still others provide capillaries which ramify within the aggregations of lymphoid tissue. The **lymphatics** of the tongue constitute two groups, a superficial within the mucous and submucous layers and a deep one within the musculature. The submucous vessels arise from the rich network of lymph-channels within the

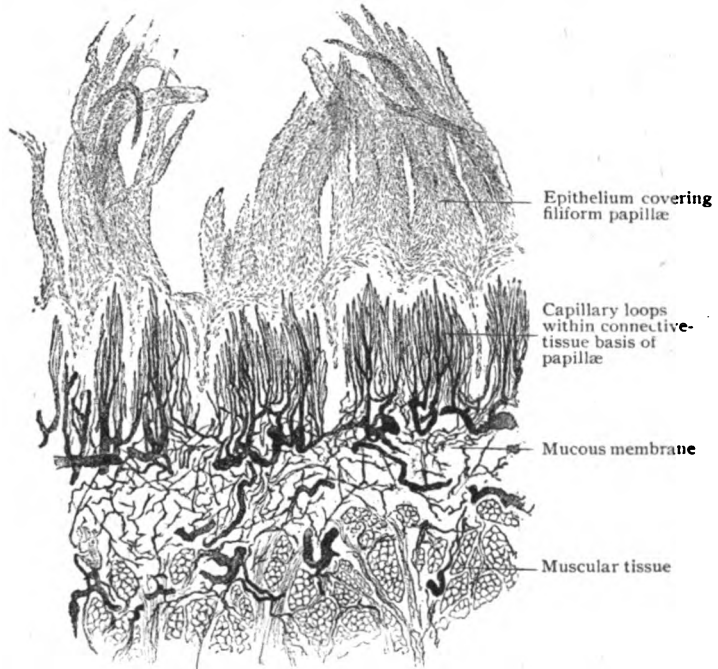


FIG. 186.—Injected mucous membrane from upper surface of tongue.  $\times 60$ .

dorsal mucosa, the apical network being especially close. The lymph-nodules of the posterior area are surrounded by meshes of lymphatics.

The **nerves** of the tongue include three sets of fibres concerned in conveying the impulses for common sensation, taste and motion. Those for common sensation, derived from the trigeminus and glossopharyngeal nerves, end in the lingual mucous membrane in the manner already described for the oral mucosa (page 130), the papillæ receiving fibres that confer great sensibility. The gustatory impulses are collected by the fibres from the chorda tympani and the glossopharyngeal, which are distributed to the anterior two thirds and the posterior third respectively. Such fibres end in close relation with the receptive neuroepithelial cells within the taste-buds (page 385). The motor fibres are from the hypoglossal nerve. As in other localities, so here, nonmedullated sympathetic fibres, destined for the blood-vessels and glands, are included in many nerve-trunks along with medullated fibres.

**The Oral Glands.**—In addition to the large salivary glands which, although pouring their secretion into the oral cavity, are situated outside of the immediate walls of the mouth, certain groups of glands, for the most part insignificant in size, lie within the oral wall and contribute secretions

serving for the lubrication of the oral mucous membrane. Such oral glands include the labial, within the lips, the buccal and the molar, within the cheeks. The *labial glands* are very numerous and constitute an almost unbroken zone, something over a centimeter in width, that surrounds the oral cleft just inside the margin of the red lip-area. They are alveo-tubular in type, lie within the submucous layer, between the mucous membrane and the muscle, and belong to the mixed mucous glands. The gland-cells, although chiefly mucous in character, include limited peripheral groups of serous cells arranged as demilunes beneath the basement membrane. The *buccal glands*, smaller and more scattered, occupy the submucosa beneath the buccinator muscle. They correspond in structure with the labial glands. The same is true of the *molar glands*, several small groups on the outer surface of the buccinator muscle, whose ducts pierce the cheek.

## THE SALIVARY GLANDS.

The salivary glands include the *parotid*, the *submaxillary* and the *sublingual*, all organs of some size, and elaborate secretions poured into the oral cavity to assist in preparing the food for deglutition and further chemi-

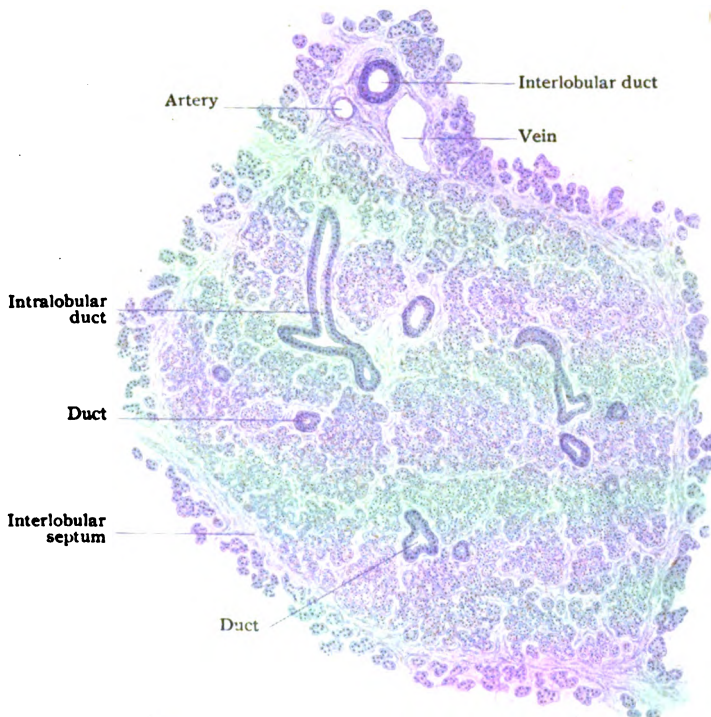


FIG. 187.—Section of small lobule of parotid gland.  $\times 70$

cal change. For the latter purpose, the parotid gland is of most importance and in all animals maintains its character as a true (serous) salivary gland. The others, the submaxillary and sublingual, are variably mixed glands, the former sometimes and the latter never approaching the pure serous type.

**The Parotid Gland.**—This, the largest of the salivary glands, lies between the upper part of the ramus of the lower jaw, which it overlaps both within and without, and the external ear. It is invested by a strong fibrous *sheath*, continuous with the cervical fascia. The gland is subdivided into many lobules by septa of dense fibro-elastic tissue and, hence, possesses considerable toughness. The parotid consists entirely of serous alveoli, although mucus-producing acini may occur in the *accessory lobules* along the main (Stenson's) duct. The *primary lobules* are made up of alveoli, lined with pyramidal glandular epithelium whose appearance changes with functional activity. When at rest, the cells are filled with minute secretion-granules; the latter, however, are sensitive to reagents, often undergoing

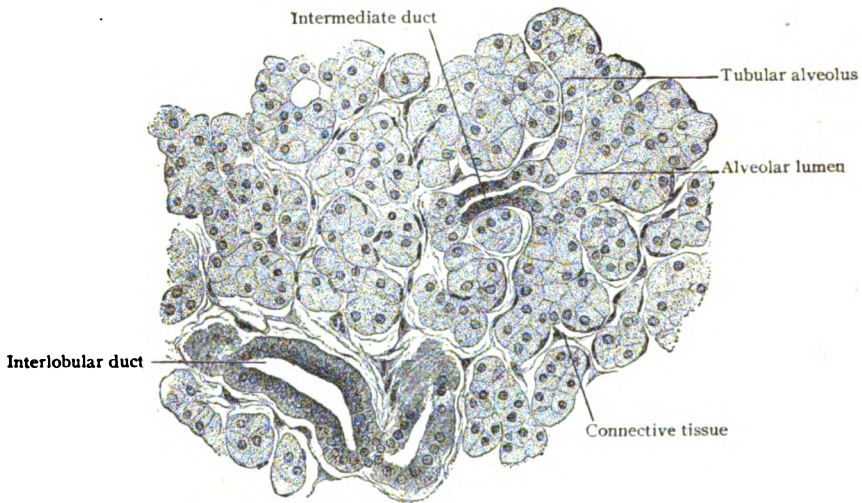


FIG. 188.—Section of parotid gland, showing serous alveoli.  $\times 270$ .

partial or complete solution. Hence, the reticulated appearance of the cytoplasm frequently observed in the gland-cells after fixation. The spherical nuclei occupy the middle of the serous cells.

The *duct-system* begins at the alveoli as the intermediate tubules, which in the parotid are relatively long and narrow and lined with low or flattened cells continuous with the alveolar epithelium. Secretion-canalliculi extend between the gland-cells part way to the basement membrane. The intra-lobular tubules, of larger diameter ( $35 \mu$ ) than either the immediately preceding or succeeding segments of the duct, are lined with a single layer of columnar cells that exhibit differentiation into an inner zone, finely granular and containing the nucleus, and an outer or basal zone, next the basement membrane and displaying a faint longitudinal striation or "rods." The interlobular and interlobar ducts gradually increase in diameter and, for the most part, possess a single layer of columnar cells; in the larger canals, however, this may be reinforced by an additional imperfect row of small cells. The columnar cells extend to near the termination of the main excretory duct, where they give place to the stratified squamous epithelium continued into the canal from the oral mucous membrane. The wall of the *parotid* or *Stenson's duct*, in addition to the epithelium, consists of fibrous tissue, mixed with many elastic fibres and a few bundles of unstriated muscle.

**The Submaxillary Gland.**—This organ, intermediate in size between the parotid and sublingual glands, lies largely under cover of the lower jaw, invested by a fibrous capsule derived from the cervical fascia. It consists of two parts, the superficial, resting on the outer surface of the mylo-hyoid muscle, and the deeper, which winds around the posterior border of the last named muscle and extends forwards as a tongue-like process, between the mylo-hyoid and the hyo-glossus muscles almost as far as the sublingual gland, beneath the mucous membrane of the floor of the mouth.

The submaxillary gland differs in structure from the parotid in possessing both serous and mucous alveoli, the mucous forming approximately one fifth of the entire gland-tissue. The *alveoli* containing serous cells resemble those of the parotid, during rest being filled with cells loaded with minute

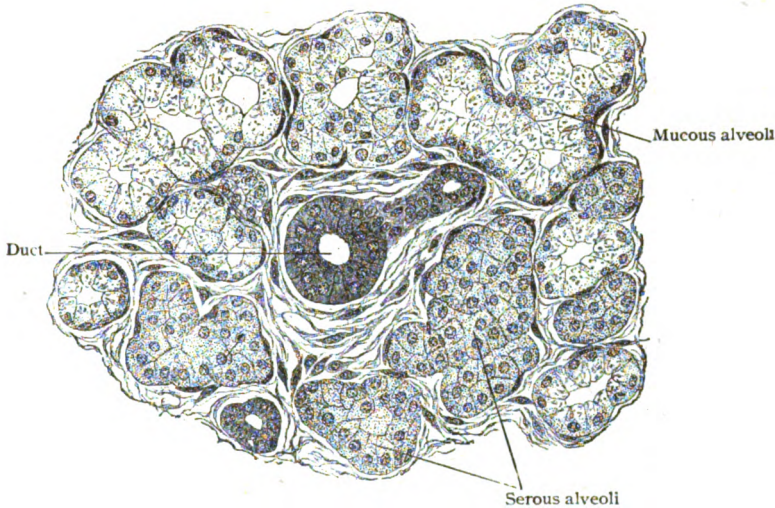


FIG. 189.—Section of submaxillary gland, showing serous and mucous alveoli.  $\times 270$ .

secretion granules. These cells often exhibit a differentiation into an inner granular and an outer almost granule-free zone. The mucous alveoli are somewhat larger than the serous ones and contain chiefly mucus-secreting cells, although limited groups of serous cells are present as demilunes. Intermediate tubules connect alveoli of both kinds with the intralobular ducts, those from the mucous alveoli being shorter and less branched than those from the serous acini. The latter are lined with low cuboidal cells, which pass gradually into the gland-cells of the alveoli, in contrast to the abrupt transition in the tubules leading to the mucous acini. The cells lining the intralobular ducts exhibit the striation seen in the corresponding part of the parotid, this rod-epithelium sometimes containing yellowish pigment. The interlobular and interlobar ducts resemble those of the parotid gland. The main *excretory* or *Wharton's duct* possesses, in addition to its fibrous tissue and a subepithelial layer of elastic fibres, feebly developed bundles of longitudinally disposed unstriated muscle. Goblet-cells appear among the columnar epithelium lining the deeper parts of the duct.

**The Sublingual Gland.**—This, the smallest of the salivary glands, underlies the mucous membrane of the floor of the mouth, through which it shows as an oval elevation at the side of the median fold, the frenulum. The

gland does not possess a distinct capsule and consists of an aggregation of separate glands, each of which has its independent duct, rather than a consolidated single organ.

The sublingual gland belongs to the mixed mucous type and possesses a curtailed *duct-system*, in which distinctive intralobular and intermediate ducts are wanting. The interlobular ducts subdivide into smaller canals that enter the primary lobules and give off wider passages lined with cuboidal epithelium. Towards the distal ends of these terminal canals the mucous gland-cells appear, at first isolated or in groups, until they constitute the entire lining of the passage. The condition of the *alveoli*, as regards the mucus-producing cells, varies even in the same lobule. Sometimes an entire primary lobule is composed of alveoli filled with mucous cells; at other times

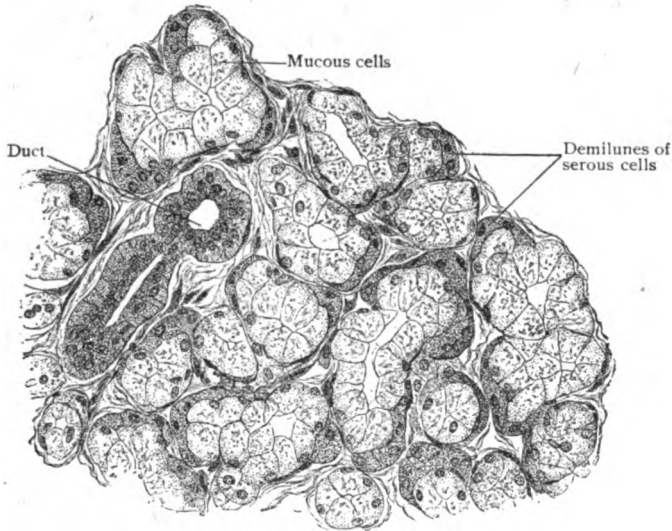


FIG. 190.—Section of sublingual gland, showing serous cells grouped as demilunes.  $\times 270$ .

empty and engorged alveoli alternate, or the depleted acini may predominate. The demilunes of serous cells are also uncertain, since these may be absent or present in considerable numbers and of large size. The relatively wide lumen of the alveoli and the more pronounced reticulated appearance of the gland-cells distinguish the exhausted sublingual gland from the parotid under like conditions.

The normal *secretions* of the salivary and oral glands contain no formed elements, although granules and cellular remains may be present. The spherical so-called *salivary corpuscles*, which occur in varying numbers in the mixed oral secretion, have no relation to the salivary glands, since they are only modified lymphocytes which have escaped from the lymphoid tissue of the faucial and lingual tonsils. On entering the mouth, these cells are affected by the saliva and become greatly swollen, the granular remains of their cytoplasm exhibiting molecular motion to a marked degree.

The **blood-vessels** of the salivary and larger oral glands follow the same general arrangement. The larger arteries accompany the ducts in their course within the interlobular connective tissue, giving off twigs which supply the walls of the excretory passages. From the interlobular vessels,

branches enter the connective tissue between the primary divisions of the glandular tissue and eventually break up into close capillary networks which surround the individual alveoli, the basement membrane and the endothelium alone separating the blood-stream and the gland-cells. The veins maintain the general path of the arteries. The definite **lymphatics** are limited to the interlobular tissue, usually accompanying the ducts. The perialveolar clefts between the bundles of the fibrous framework represent the interlobular lymph-channels, which are tributary to the lymphatic vessels between the lobules. The **nerves** supplying the salivary glands form plexuses within the interlobular tissue and include both medullated and nonmedullated fibres. The latter, destined chiefly for the blood-vessels and gland-tissue, are in part the axones of sympathetic neurones, whose cell-bodies are the ganglion-cells collected in microscopic groups along the walls of the larger ducts. On reaching the alveoli, the nonmedullated fibres form epilemmar plexuses on the outer surface of the basement membrane, from which delicate fibrils pierce the membrane to end as varicose hypolemmar threads between the gland-cells.

### THE PALATE.

The **hard palate** forms the roof of the mouth, and is bounded laterally by the alveolar border of the upper jaw. The mucous membrane is united firmly to the periosteum covering the roof-bones by the dense connective tissue of the submucous layer. Near the front border of the area, the mucous membrane is thrown into a series of irregular ridges, the *palatal rugæ*, over which the secondary papilla of the tunica propria are well marked. On each side of an oval median area, the submucosa is occupied by an almost continuous layer of *palatal glands*, composed of small groups of mucous alveoli, whose ducts open on the surface as minute scattered orifices.

The **soft palate** is essentially a fold of mucous membrane, enclosing muscles, tendinous expansions and glands, continued backwards and downwards from the hard palate to form the mobile arched partition between the nasal and oral subdivisions of the pharynx. The free border is prolonged in a median conical prominence, the *uvula*, which breaks the general curve of the border into a double arch. The soft palate includes four general layers, which, from above downwards, are: (1) The *pharyngeal mucous membrane*, which for some distance above the free edge of the palate corresponds with the oral mucosa in possessing stratified squamous epithelium and a layer of elastic fibres in the deeper margin of the tunica propria. Higher, but at a variable distance from the free border, the mucosa changes and assumes the characteristics of the respiratory mucous membrane. (2) The *fibro-muscular layer*, which comprises the expansions of the tendons of the tensor palati muscles and a complex of striped muscle bundles. (3) The *glandular layer*, which is in places 5-6 mm. thick and continuous with the glands of the hard palate. The glands are examples of the pure mucous variety, and so closely set that they form a layer broken only in the mid-line near the hard palate by a fibro-muscular septum. They mostly end near the free border of the palate in the vicinity of the base of the uvula, but some are continued into this projection, almost to its tip, as a cylindrical tract of glands through and about which run the fibres of the azygos uvulæ muscle. (4) The *oral mucous membrane*, which, although strictly belonging for the most part to the oro-pharynx,

resembles the general lining of the mouth. The submucous tissue of this surface contains a variable amount of fat, which is wanting in the corresponding position on the upper aspect of the palate. Scattered small taste-buds

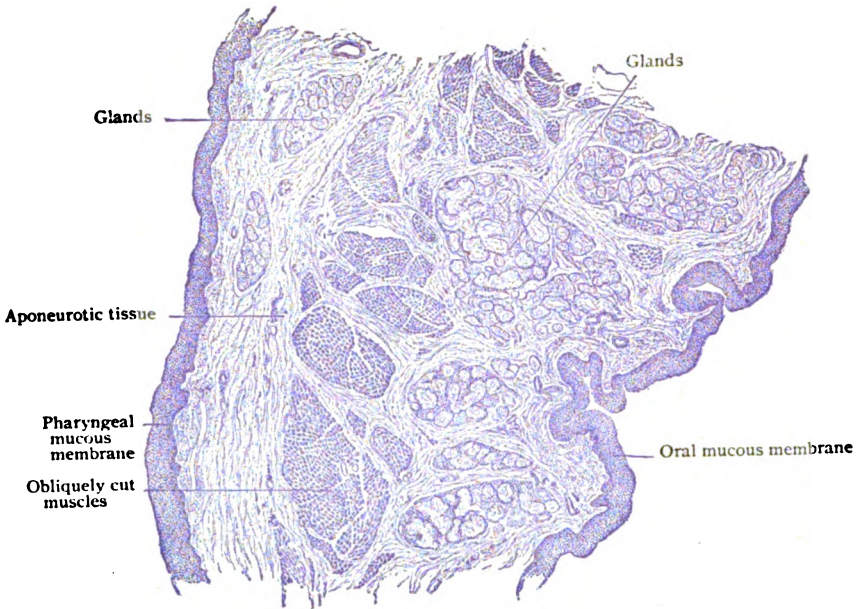


FIG. 191.—Lateral sagittal section of soft palate.  $\times 15$ .

are occasionally encountered within the epithelium of the lower surface. The ultimate distribution of the blood-vessels and nerves of the palatine mucosa follows the general plan of the oral mucous membrane.

## THE PHARYNX.

The pharynx or throat is a musculo-fibrous sac, lined with mucous membrane, that extends from the base of the skull to the level of the upper border of the seventh cervical vertebra. It communicates with the Eustachian tubes, the nasal fossæ, the oral cavity and the larynx, and is continuous below with the œsophagus. The walls of the pharynx comprise three general strata: (1) the *muscular layer*, made up of the striated fibres of the pharyngeal constrictors and the associated muscles; (2) the *fibrous layer*, a membranous framework of dense fibro-elastic tissue, strong above but weaker below and continued into the œsophagus; and (3) the *mucous membrane*, which, with the submucous layer, lines all parts of the pharynx and presents striking local modifications.

Within the naso-pharynx, that division lying above the level of the soft palate, the mucous membrane mostly resembles that of the adjoining respiratory part of the nasal fossæ, being clothed with stratified ciliated epithelium and containing many small mixed (sero-mucous) tubo-alveolar glands. Over portions of the posterior wall of the naso-pharynx, as well as over the uvula and neighboring region of the upper surface of the soft palate, the epithelium is



stratified squamous, the place of transition being subject to great individual variation. Where covered with the squamous cells, the glands are usually mucous in type. The lower divisions of the pharynx, the oro- and the laryngo-pharynx, are invested with stratified squamous epithelium.

**Lymphoid tissue** occurs in great abundance, in certain localities, particularly on the upper posterior pharyngeal wall, causing the mucous membrane to be thrown into elevations. The larger and more constant collections of lymphoid tissue are called "tonsils," of which the *faucial tonsils* in the oro-pharynx, the *pharyngeal tonsil* in the upper part of the naso-pharynx, the *tubal tonsils* at the openings of the Eustachian tubes, and the *lingual tonsil* on the posterior third of the tongue are examples.

The **faucial tonsils**, also called *palatine*, are two almond-shaped masses of lymphoid tissue, one on each lateral wall of the oro-pharynx, between the palatine pillars. Each tonsil, some 20 mm. long, 15 mm. broad and 10 mm. thick, is enclosed by a fibro-elastic *capsule*, which becomes continuous with the submucous layer where the mucous membrane is adherent to the tonsil, as it is on the free surface. The latter is broken by an uncertain number (10-20) of pits of varying size and depth. These depressions, or *crypts*, cut the lymphoid tissue into irregular tracts, which are still further subdivided by connective tissue septa that penetrate from the capsule. The crypts, with their side branches, are completely lined with mucous membrane continued from the adjacent free surface. The tunica propria, however, is thin and so invaded by the lymphocytes that the epithelium is the most conspicuous representative of the mucous membrane. Each crypt with its surrounding tract of lymphoid tissue repeats, in its general makeup, the structure of the lingual lymph-follicles already described. The lymphoid mass contains lymph-nodules, with germ-centres, blended together by the more diffuse lymphoid tissue. The entire tonsil is built up by repetition of such structural units. Numbers of lymphocytes wend their way into the subepithelial tissue, which in consequence becomes infiltrated with the lymph-cells, thence pass into the epithelium and, finally, escape into the pit and onto the free surface of the mucous membrane. These cells become the salivary corpuscles.

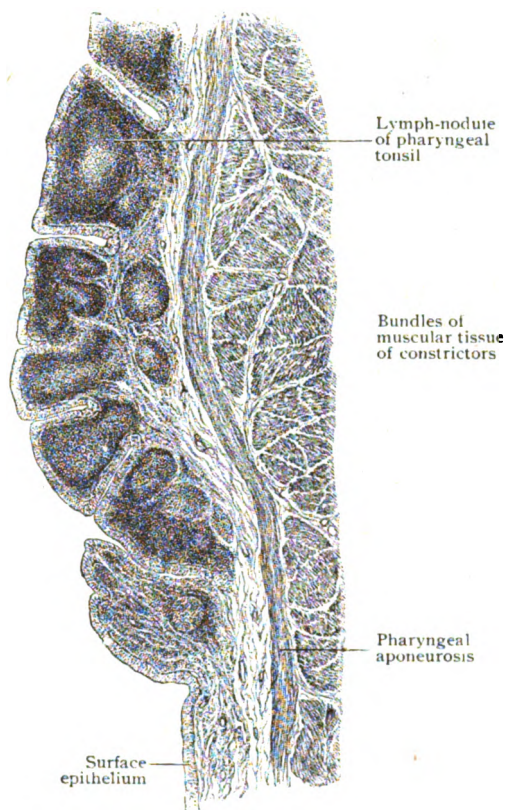


FIG. 192.—Sagittal section of posterior wall of pharynx of child, showing part of pharyngeal tonsil.  $\times 20$ .

The **pharyngeal tonsil** is an unpaired median mass of lymphoid tissue in the postero-superior wall of the naso-pharynx. It, as well as the faucial tonsils, is best developed in early childhood, although often hypertrophied in adolescence. This tonsil

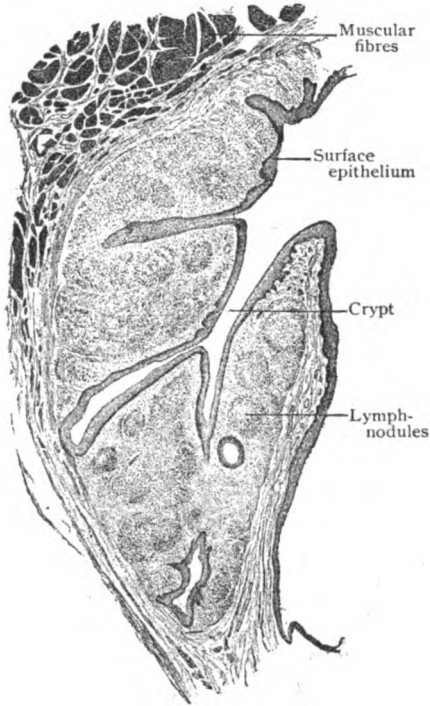


FIG. 193.—Section through faucial tonsil, showing general disposition of lymphoid tissue around the crypts.  $\times 20$ .

consists of a series of lobulated masses of lymphoid tissue arranged around a central depression with lateral recesses. In its general composition, it resembles the faucial tonsil, consisting of lymph-nodules and diffuse lymphoid tissue. The latter is less circumscribed and infiltrates the surrounding mucous membrane, so that the limits of the pharyngeal tonsil are not well defined. The name, **tubal tonsils**, is sometimes applied to the collections of lymphoid tissue that surround the openings of the Eustachian tubes. The lymphoid tract extends for some distance along the tube, as well as towards the pharyngeal tonsil, and contains small lymph-nodules.

The **blood-vessels** and **nerves** of the pharynx, although collectively derived from a varied and somewhat complex source, follow in their detailed distribution the plan common to mucous membranes, and call for no special description.

The **lymphatics** within the pharyngeal mucous membrane are unusually abundant, particularly in

the vicinity of the more definite masses of lymphoid tissue. The latter, especially the faucial tonsils, are of great practical importance. They are very frequently the seat of serious infections, their numerous and often deep crypts affording favorable resting places for bacteria.

## THE ŒSOPHAGUS.

The Œsophagus or gullet is the tube, about 25 cm. in length, that connects the pharynx and the stomach and serves for the passage of food. Its walls, 3-4 mm. thick, consist of four coats (Fig. 194) which, from within outwards, are: (1) the mucous membrane, (2) the submucous layer, (3) the muscular tunic and (4) the fibrous coat.

The **mucous membrane**, usually thrown into longitudinal folds, includes a tunica propria, composed of fibrous connective tissue and delicate elastic fibres, and a thick coating of stratified squamous epithelium. The surface of the stroma-layer beneath the epithelium is modelled by longitudinal ridges and papillæ, between which pass the ducts of the glands in their course to the free surface. The deeper part of the tunica propria is occupied by a thin stratum of involuntary muscle, the *muscularis mucosæ*, which is feeble and indistinct in the upper part of the gullet but robust and conspic-

uous in the lower portion. Collections of lymphoid tissue occur within the mucosa as more or less distinct aggregations. Mostly they are small diffuse areas around the ducts of the mucous glands, but in some places, especially towards the lower end of the œsophagus, they assume the form of distinct lymph-nodules (Fig. 195).

The **submucous layer**, although of considerable thickness, is loose in texture and, therefore, permits free motion of the mucous membrane upon the muscular tunic. Scattered along the length of the gullet are many

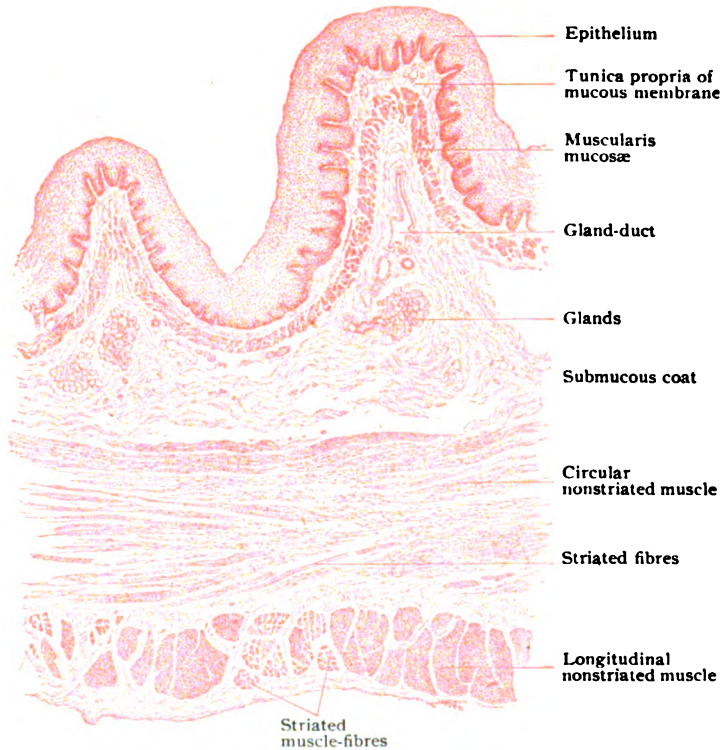


FIG. 194.—Transverse section of œsophagus, through upper third.  $\times 18$ .

**œsophageal glands.** These are of two kinds—the ordinary *mucous glands*, situated within the submucous coat and most abundant in the upper half of the tube, and the special *cardiac glands*, lodged within the tunica propria and limited to the two ends of the œsophagus. The usual glands are tubo-alveolar in form and pure mucous in type, mucus-producing cells alone being present. Their ducts, commonly somewhat tortuous, are often dilated into miniature ampullæ just before penetrating the muscularis mucosæ; they leave the tunica propria and enter the epithelium in the valleys between the papillæ. The smaller ducts are lined with simple columnar epithelium, which in the larger tubes may become stratified and, near the free surface, may be replaced by stratified squamous cells.

The special glands correspond in structure to those found at the cardiac orifice of the stomach (page 160); hence their designation as “cardiac.” They consist of small oval or pyramidal groups of richly branched tubules

and constitute a constant narrow zone surrounding the termination of the œsophagus. Lying entirely within the tunica propria, their bases abutting against the muscularis mucosæ, they open on the free surface by wavy ducts that pierce the summit of the papillæ and traverse the epithelium. Less definite and much less constant groups of similar tubules occur within the mucosa, along the sides, at the upper end of the œsophagus; these have been described as the *superior cardiac glands*.

The **muscular coat** of the œsophagus includes an inner circular and an outer longitudinal layer, although the individual bundles are often irregularly and obliquely disposed, and above somewhat intermingled. The histological character of the muscular tissue varies in different parts of the tube.

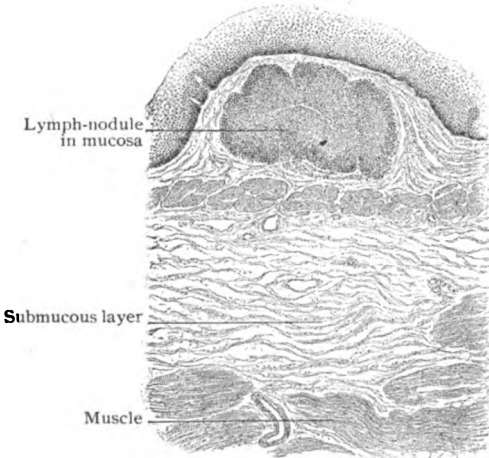


FIG. 195.—Section of mucous membrane of œsophagus, showing lymph-nodule.  $\times 55$ .

Thus in a general way, within approximately the lower half of the œsophagus the muscle is entirely unstriated; within the second quarter both striated and unstriated muscle appear; while within the first quarter striated muscle almost exclusively is present. Although within the longitudinal layer unstriated fibres do not appear within the upper fourth or fifth, the zone of purely striated fibres within the circular layer includes only about the first 2.5 cm., below which level unstriated fibres gradually become more abundant.

The **fibrous coat** is poorly developed above the diaphragm, consisting of areolar tissue that attaches the œsophagus to the surrounding structures, aided in places by strands of unstriated muscle. After piercing the diaphragm, the peritoneum contributes a limited serous coat, which, with its connective tissue stroma and surface mesothelium, constitutes a more definite investment for the alimentary tube from this point on.

The **blood-vessels** of the œsophagus, after sending twigs directly for the supply of the muscular tissue, gain the loose submucous layer, within which lie branches of considerable size. From these, in addition to small vessels for the circular muscle and the glands within the submucosa, twigs are given off that enter the mucous membrane and break up into capillary networks from which terminal loops invade the papillæ. The venous radicles of the mucosa are tributary to the veins within the submucous tissue, from which the larger trunks accompany the arteries.

The **lymphatics** are represented by networks within the submucous and muscular coats. The former take up the fluid collected by the lymph-spaces of the mucous membrane. These networks are connected by independent trunks with neighboring lymph-nodes, those from the lower end of the œsophagus passing to the upper nodes of the cœliac group.

The **nerves** of the œsophagus include both medullated and nonmedullated fibres. The former, largely from the vagi, contribute fibres supplying the striated muscle, in which they end in motor plates. The nonmed-

ullated fibres are chiefly sympathetic and, therefore, are destined especially for the involuntary muscle and glands. Between the longitudinal and circular layers of muscle they form a wide-meshed plexus, containing many microscopic ganglia, that corresponds with the *plexus myentericus* of the stomach and intestine, with which organs it will be described (page 163). The mucous membrane receives nonmedullated fibres, from an indefinite plexus within the submucous layer, which terminate within the tunica propria in free endings, some threads entering the deeper layers of the epithelium.

## THE STOMACH.

Being essentially a greatly dilated and modified segment of the digestive tube, connecting the œsophagus and the small intestine, the walls of the stomach agree in their general makeup with those of the other parts of the

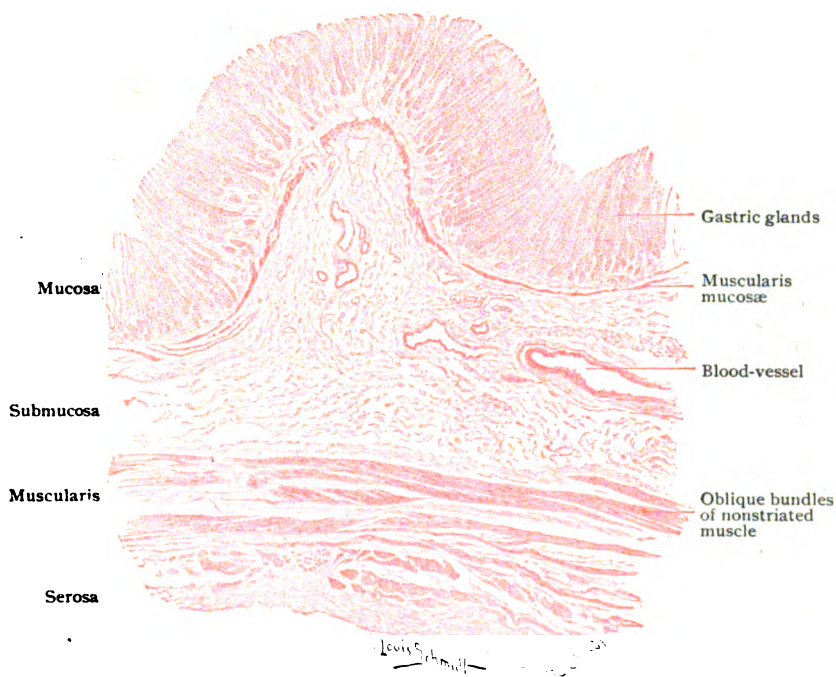


FIG. 196.—Transverse section of human stomach, left third, showing general arrangement of coats.  $\times 18$ .

alimentary canal lying below the diaphragm. They consist, therefore, of four coats—the *mucous*, the *submucous*, the *muscular*, and the *serous*. When moderately distended, the stomach is a somewhat flattened pear-shaped sac, with the large end up and the point bent to the right. The highest part of the stomach is called the *fundus*; the end joining the œsophagus is the *cardia*, and that meeting the intestine the *pylorus*.

The **mucous coat**, or *mucosa*, thickest near the pylorus (1.5–2 mm.) and thinnest at the cardiac end (.35–.55 mm.), is loosely attached to the muscle by the submucous tissue and, possessing little elasticity, is easily thrown into folds or *rugæ* when the other coats contract. During distention these folds are largely effaced, but under the more usual conditions are

conspicuous as longitudinal plications, particularly at the pyloric end and along the greater curvature. The surface of the gastric mucous membrane is divided into small, slightly raised, polygonal areas or *mammillæ*. The latter, from 1-4 mm. in diameter, are stippled with closely placed microscopic pits, the *gastric crypts*, into which open groups of the individual gland-tubes. The crypts are particularly wide (.2 mm.) in the pyloric region, where they reduce the intervening tissue to mere ridges which in section appear as villous projections (*plicæ villosæ*).

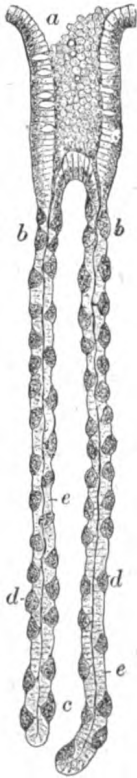

FIG. 197.—Gastric glands from fundus-end of stomach; *a*, opening on surface; *b*, neck; *c*, fundus; *d*, parietal cells; *e*, chief cells.  $\times 105$ .

cells extend between the gastric glands, in places penetrating almost as far as the epithelium.

The **gastric glands** comprise two principal varieties, the *fundus* and the *pyloric glands*. The former occur throughout the greater part of the stomach, including the fundus, the anterior and the posterior walls and the curvatures; the latter are present in the pyloric fifth of the stomach. An additional variety, the *cardiac glands*, is represented by a narrow granular group at the œsophageal orifice.

The **fundus glands**—the gastric glands proper—are closely set tubules, single or slightly branched and usually somewhat wavy, which extend almost

The *epithelium* covering the free surface of the mucosa is a single layer of tall columnar cells (20-30  $\mu$  high), many of which are engaged in secreting mucus and consequently appear as goblet-cells. Where the œsophagus joins the stomach, the opaque stratified squamous epithelium of the gullet abruptly changes into the transparent columnar gastric cells. The line of transition is zigzag and well defined, the pale œsophageal mucous membrane contrasting with the reddish-gray gastric lining. The unusual thickness of the mucosa at the pylorus is in part due to the depth of the depressions, the gastric crypts, into which the glands open.

The *tunica propria* consists of a delicate connective tissue framework, composed of fibrous and reticular tissue and elastic fibres, supporting many lymphocytes and intermingled with strands of involuntary muscle and capillaries. This stroma resembles loose lymphoid tissue and, where the gastric glands are closely placed, is reduced to the septa and envelopes which separate and invest the deeper parts of the gastric glands. The latter, here and there, are so surrounded by aggregations of lymphocytes that the stroma assumes the appearance of lymphoid tissue. In the vicinity of the pylorus and sometimes of the cardia, more definite accumulations of such tissue occur in the form of small *lymph-nodules* (Fig. 200), the so-called "lenticular glands." Occasionally they are of sufficient size to reach almost the free surface, although commonly they are limited to the deeper parts of the mucous membrane. The *muscularis mucosæ*, as in other parts of the intestinal tube, consists of a thin but well-marked layer of involuntary muscle within the tunica propria next the submucous coat. Two strata are usually distinguishable, an inner circular and an outer longitudinal. Delicate strands of muscle-

the entire thickness of the mucosa and abut against the muscularis mucosæ. Each gastric crypt corresponds to an excretory duct and receives several of the tubules, in which the neck, body and fundus of the gland are recognized. The slightly constricted neck marks the transition of the columnar epithelium lining the crypt, prolonged from the free surface, into the gland-cells. The latter are of two kinds, the chief and the parietal. The *chief cells*, called also central or adelmorphous, are clear low cylindrical or cuboidal elements that line the tubule and surround a narrow but distinct lumen. Their spherical nuclei occupy the central part of the clear cytoplasm that sometimes (during rest) is filled with secretion or zymogen granules and at other times, after the granules have disappeared, shows a distinct reticulum. These elements, often imperfectly preserved, are probably concerned in producing pepsin. The *parietal cells*, known also as acid, oxyntic or delomorphous, although relatively few are conspicuous by reason of their size, peripheral position (Fig. 198) and selective affinity for certain stains. They are large, of rounded triangular form, and lie immediately beneath the basement membrane, which often displays in profile an outward bulging as it passes over the cell. The finely granular cytoplasm encloses a distinct spherical nucleus that may be double. Although arranged with little regularity, the parietal cells are most numerous towards the neck of the tubule, where they may form an almost unbroken layer; they decrease in number on approaching the fundus, in which they are few or wanting. While excluded by the chief cells from contact with the lumen of the tubule, the parietal cells are connected with the central cleft by means of lateral channels, the *secretion-canaliculi*, that pass outwards between the chief cells and enclose the parietal cells with networks.

The *pyloric glands* differ from the fundus glands in the excessive width and depth of their crypts, the excretory ducts, into which groups of relatively short tortuous gland-tubules open, and in the character of their lining cells. The latter are almost exclusively columnar or pyramidal elements which resemble the chief cells of the fundus glands. That, however, they are at least functionally different is shown by their behavior with certain stains, as well as by the mucus reaction of their secretion. The spherical nuclei commonly lie near the basement membrane. Occasional parietal cells are also present. Owing to their tortuous course, the deeper parts of the pyloric tubules, when viewed in sections, are cut in various planes. Within the intermediate zone between the pyloric and adjoining portions of the stomach,

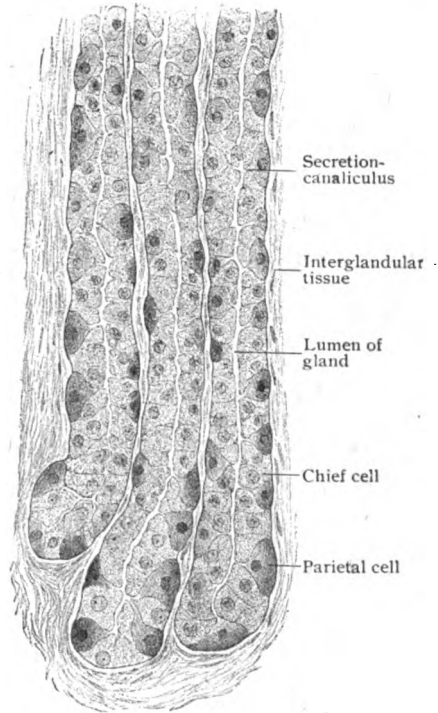


FIG. 198.—Deep portions of gastric glands from fundus, showing the two varieties of lining cells and secretion-canaliculi connecting parietal cells with the gland-lumina.  $\times 315$ .

the pyloric and the fundus glands are intermingled. Passing towards the intestine, the transition of the pyloric glands into those of the duodenum is gradual, the gastric tubules sinking through the muscularis mucosæ until, as the duodenal glands, they occupy the submucosa.

The **cardiac glands** form a narrow annular group, some 5 mm. in width, surrounding the orifice of the œsophagus. According to the character of their cells, which resemble the chief cells of the gastric tubules,

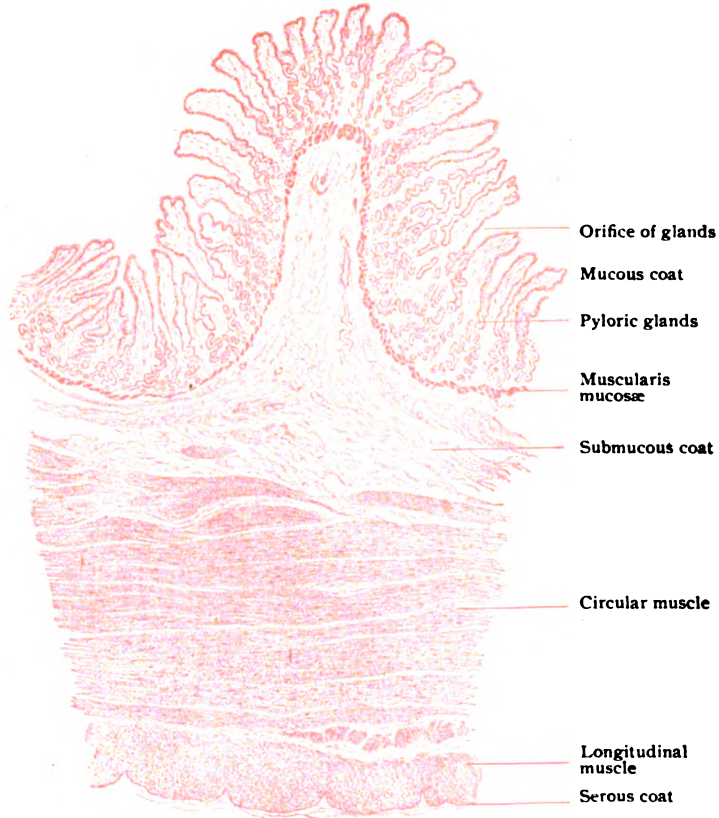


FIG. 199.—Transverse section of human stomach, pyloric end; a ruga is cut across, showing the mucosa supported by core of submucous tissue.  $\times 18$ .

with a few parietal cells, the cardiac glands may be regarded as modified fundus tubules; their mucus reactions and repeatedly branched condition, however, suggest similarity to the pyloric glands. Their excretory crypts often exhibit ampullary enlargements. Among the more distinctive cardiac tubules are usually a few shorter ones which recall the intestinal crypts of Lieberkühn.

The **submucous coat** consists of loose fibro-elastic connective tissue and allows the mucous membrane to move freely on the muscular coat. In the more permanent rugæ, the submucous tissue forms the core of the elevation. The submucosa contains blood-vessels of considerable size, a meshwork of lymphatics and the nerve-plexus of Meissner, as well as occasional groups of fat-cells.



The **muscular coat**, composed entirely of unstriped muscle, comprises three irregular layers—the external of longitudinal, the middle of circular and the inner of oblique fibres. None of these layers is complete in all parts of the stomach, the circular being the least imperfect and usually the most conspicuous. The *external layer* consists of longitudinal fibres, continuous with the corresponding ones of the œsophagus above and with those of the duodenum below. It is best developed along the lesser curvature, over the greater curvature and intervening surfaces being a thin and irregular stratum. Towards the pylorus the longitudinal fibres form a more compact and thicker layer, which passes without interruption over the gastro-intestinal junction into the outer muscle of the duodenum. The *middle layer*, while complete and circularly disposed within the pyloric end, is imperfect and oblique towards the fundus. It is continuous above with the superficial circular fibres of the gullet; these, on reaching the stomach, however, are arranged as loops, which overlie the lesser curvature but do not reach the fundus. As these loops pass downward they increase in length and regularity until, at the middle of the stomach, the circular strands completely girdle the organ. Towards the pylorus the circular bundles thicken and, at the immediate end of the stomach, surround the opening into the intestine with a robust muscular ring, the *pyloric sphincter*, the outer part of which alone continues into the duodenum. The *inner layer*, the least complete and most oblique, begins at the left of the œsophageal orifice as a prolongation of the deeper circular fibres of the gullet. On the stomach the fibres are disposed as loops which cover the fundus with a fairly continuous layer, but become progressively more oblique and incomplete over the surfaces of the middle third, being absent over the lesser curvature and the pyloric fourth of the stomach. It is evident, therefore, that within the narrow tubular part of the organ, the muscle layers have the most definite and orderly disposition; here they show in cross-sections as a well-developed inner circular and a definite external longitudinal stratum (Fig. 199).

The **serous coat** corresponds in structure with other portions of the visceral peritoneum, consisting of the surface mesothelial plates and the subjacent tunica propria of fibro-elastic connective tissue.

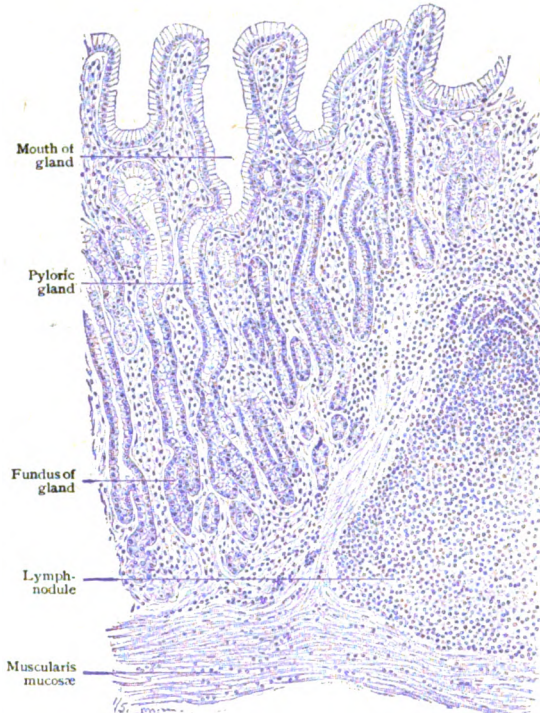


FIG. 200.—Section of pyloric end of stomach, showing glands and part of a lymph-nodule.  $\times 182$ .

The **blood-vessels** of the stomach include arterial branches from the three subdivisions of the cœliac axis. At first the arteries lie just beneath the peritoneum, between the folds of which they gain the stomach and to which they give off branches. They then pierce the muscular tunic, whose outer part is supplied during their passage. On reaching the submucous coat, the arteries, still of considerable size, form a coarse network, from which some small vessels pass into the muscular layer to complete its supply, while many more penetrate the muscularis mucosæ and enter the tunica propria. Here they form a network beneath the glands from which pass slender capillaries to surround the gastric tubules and to encircle the mouths

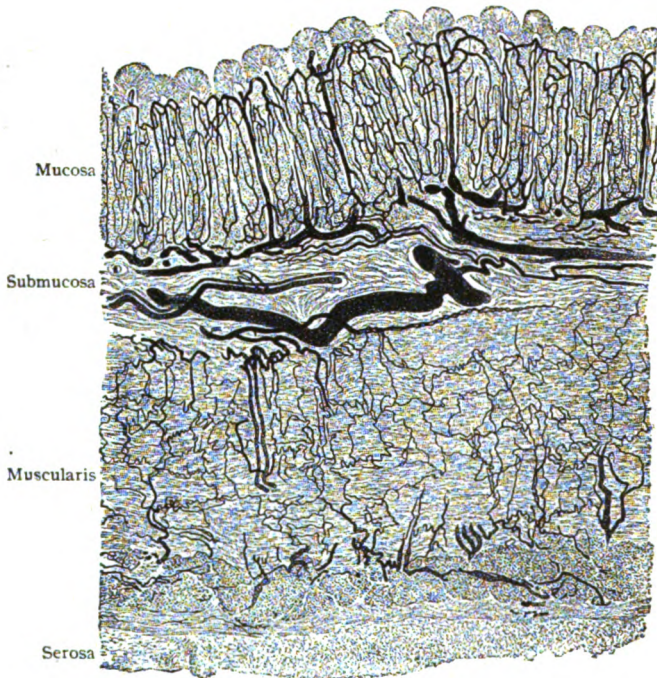


FIG. 201.—Transverse section of injected stomach.  $\times 50$ .

of the glands beneath the epithelium. From these superficial capillaries the blood is returned by relatively straight unbranching veins that pass between the gland-tubules and join the venous plexus in the deepest part of the tunica propria. Thence tributaries join the submucous venous plexus from which the larger trunks accompany the arteries. Although the important tributaries of the portal system are devoid of valves, the veins which immediately drain the stomach are provided with such folds.

The **lymphatics**, or *chyle vessels*, begin within the tunica propria as blind capillaries that course between the gland-tubules as far as the close network in the depth of the stroma. Numerous channels establish communication between the lymph-paths of the mucosa and the wide-meshed plexus of larger vessels within the submucous coat. A second network of lymph-capillaries extends between the layers of muscle and joins the efferent lymph-paths that connect the gastric walls with the neighboring nodes.

The **nerves** of the stomach are from the vagi and the sympathetic and contain both medullated and nonmedullated fibres, the latter predominating. After forming a *subserous plexus* beneath the peritoneum, they pierce the external layer of longitudinal muscle and between the latter and the circular muscle broaden out and unite into the *plexus myentericus* or *plexus of Auerbach*. This is an extended network, with rounded angular meshes, whose points of intersection are occupied by microscopic ganglia composed of small groups of sympathetic cells. From these numerous fibres

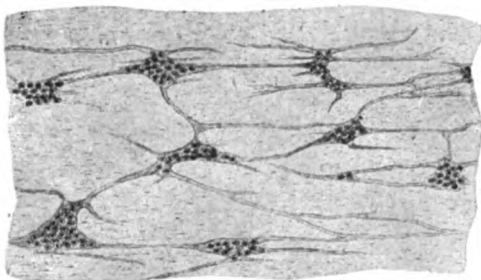


FIG. 202.—Surface view of muscular coat of stomach, showing groups of ganglion-cells and nerve-fibres of plexus of Auerbach.  $\times 50$ .

pass to the adjoining sheets of involuntary muscle to terminate in free endings among the fibre-cells (page 86). Other fibres form the intramuscular plexus and penetrate, as obliquely directed bundles, the intervening muscle to gain the submucous coat. Within the latter they form the *submucous plexus* or *plexus of Meissner*, which, while resembling the intramuscular network in its general features, is less pronounced, finer meshed and beset with smaller ganglia. Numerous nonmedullated fibres leave the submucous plexus to enter the overlying tunica propria, in which some end in delicate plexiform threads around the gastric glands and others in fibrils for the muscularis mucosæ. Medullated fibres, dendrites of sensory neurones, are also present within the mucosa, where they form a subepithelial plexus after losing their medullary coat. They end in minute varicose threads within the tunica propria; whether some fibrils pass between the epithelial cells is uncertain.

## THE SMALL INTESTINE.

The small intestine, about 7 meters or 23 ft. in length, is conventionally divided into three parts—the *duodenum*, the *jejunum* and the *ileum*. Although typical portions of these segments can be readily distinguished from one another, chiefly by the modifications of the mucous coat, the transition between them is so gradual that differentiation is in places impossible. The small intestine, as other parts of the alimentary tube below the diaphragm, consists of four coats—the *mucous*, the *submucous*, the *muscular* and the *serous*.

The **mucous membrane**, or *mucosa*, presents the greatest variations, since its function as an absorbent surface requires an extent of area most economically provided by folds and projections. These elevations of the mucosa, which include plications and villi, are most marked in the upper part of the intestine, where absorption is most active, thence gradually decreasing until in the terminal part, where the small intestine passes into the large, they almost disappear.

The *epithelium*, everywhere covering the free surface, including the villi, consists of a single layer of columnar cells, whose ends next the intestinal lumen are invested by a narrow and often delicately striated cuticular border. The latter, present only in the fully matured cells, lacks stability and is readily resolved into minute vertical rods, probably continuous with the spongio-

plastic threads within the body of the cell. In places, especially over the villi, many of the epithelial elements are engaged in producing mucus and, hence, appear as goblet-cells. Migratory lymphocytes are usually to be seen between the cells, while during digestion the cytoplasm of the latter is often loaded with particles of fat. The oval nuclei occupy the deeper parts of the cells. The *tunica propria* of the intestinal mucosa resembles lymphoid tissue, since it consists of a delicate connective tissue reticulum containing numerous small round cells similar to lymphocytes. This stroma fills the

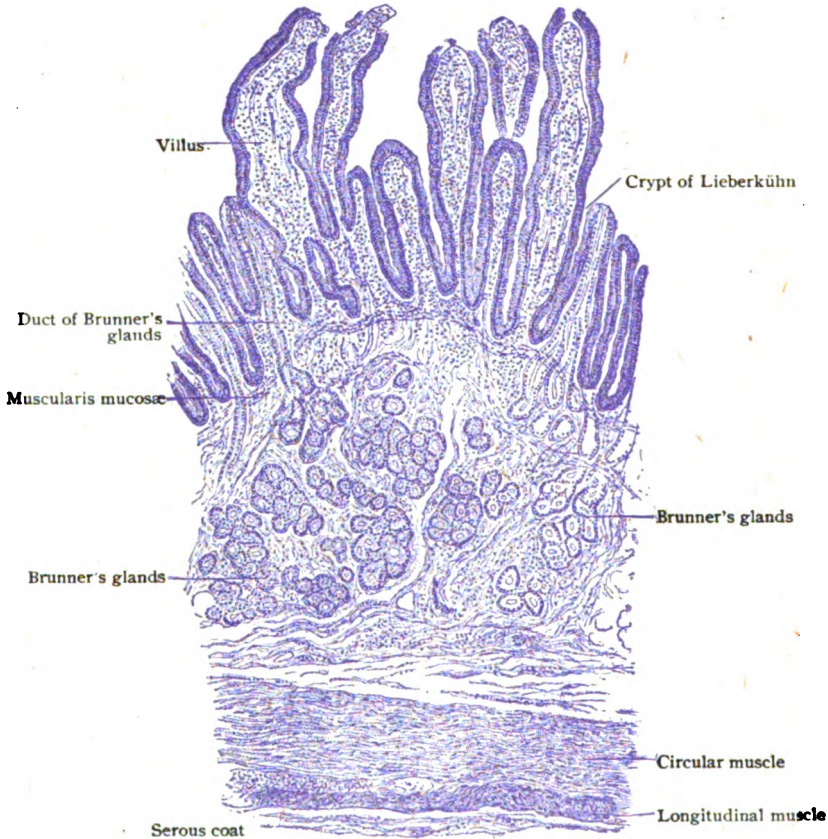


FIG. 203.—Transverse section of small intestine (duodenum), showing general arrangement of coats and the two varieties of glands.  $\times 90$ .

spaces between the glands and forms the core of the villi over which the epithelium stretches. The deeper part of the mucosa is occupied by a well-marked *muscularis mucosae*, composed of an inner circular and an outer longitudinal layer of unstripped muscle.

The villi are minute projections of the mucosa, barely visible to the unaided eye, whose presence imparts the characteristic velvety appearance to the inner surface of the small intestine. Although found throughout the latter (but absent in the large gut), they are most abundant (20-40 to the sq. mm.) in the duodenum and the jejunum and less numerous (15-30 to the sq. mm.) in the ileum. In the duodenum they appear close to the

pylorus, but are better developed in the second part, where they are low and broad and measure .2-.5 mm. in height and .3-1 mm. in width. In the jejunum the villi are conical and somewhat laterally compressed, while in the ileum their shape is cylindrical, filiform or wedge-like and their height from .5-1 mm. The villi are projections of the mucous coat alone (Fig. 204) and consist of a framework of the lymphoid stroma-tissue, covered by columnar epithelium, supporting the absorbent vessel and the blood-vessels

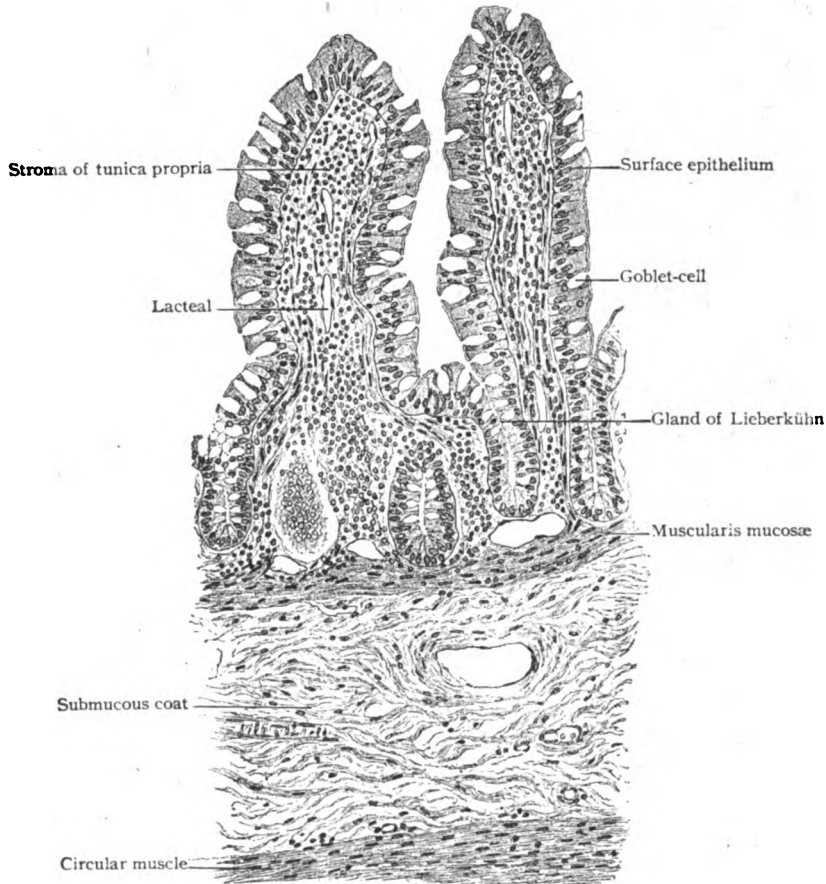


FIG. 204.—Transverse section of small intestine (jejunum), showing the villi cut lengthwise.  $\times 150$ .

and intermingled with a few strands of unstriped muscle. The supporting framework of the villus—a complex of fibrous, reticular and elastic tissue—is condensed beneath the epithelium into a delicate membrane. The *lacteal*, as the absorbent vessel or lymphatic occupying the villus is usually termed, begins as a blind, often slightly club-shaped channel, which runs through the centre of the villus, surrounded by the delicate muscle-bundles and the blood-capillaries. While the slender cylindrical villi possess a single lacteal (25-35  $\mu$  in diameter), those of broader form often contain two, three or even more such vessels, which may communicate by cross-channels. Their walls

consist of a single layer of endothelial plates and are surrounded by the strands of muscle. While the absorbent vessels within the villi are at times conspicuous by reason of the particles of fat which they contain, and hence

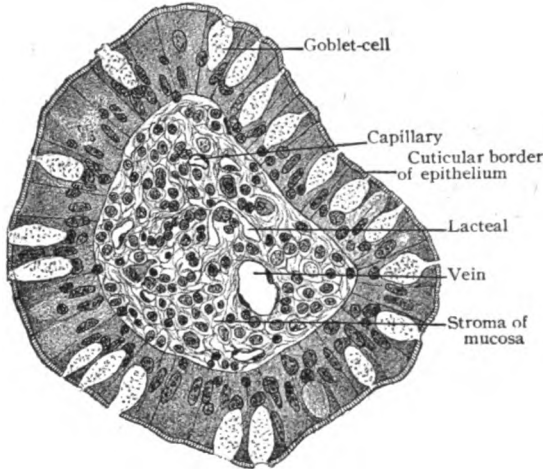


FIG. 205.—Transverse section of a single villus, showing relation of epithelium, stroma and vessels.  $\times 350$ .

are called "lacteals," they are only blind lymph-radicles and actually belong to the system of lymphatics. Their special purpose is to carry the materials taken from the intestinal contents to the great lymph-channel, the thoracic duct.

The *plicæ circulares*, or *valvulae conniventes*, within the duodenum and jejunum, additionally model the mucous membrane and greatly increase its secreting and absorbing surface, as well as retard the passage of the intestinal contents, thereby facilitating the digestive processes. These transverse folds begin in the second part of the duodenum and are duplicatures which involve not only the entire thickness of the mucosa, but contain a central supporting projection of the submucous coat (Fig. 207); hence they can not, as a rule, be effaced by distention. The height of the folds, where well developed, rarely exceeds 6 mm., and towards the lower part of the jejunum is much less; in the terminal portion of the ileum they usually are wanting.

**Glands.**—The structures within the wall of the intestinal tube to which the term "glands" has been applied include two entirely different groups—the true secreting organs, the glands of Brunner and the crypts of Lieberkühn, and the accumulations of lymphoid tissue, the single or aggregated lymph-nodules, which do not secrete.

The **glands of Brunner or duodenal glands** (Fig. 208) are limited to the first division of the small intestine. Beginning at the pylorus, where they are most numerous and extensive, they gradually decrease in number and size, until, at the lower end of the duodenum, they are entirely wanting. In the vicinity of the opening of the bile-duct, however, they are locally augmented. These glands are direct continuations of the pyloric glands of the stomach, with which they agree in all essential structural details. They are not confined to the mucous coat, as are the gastric

are called "lacteals," they are only blind lymph-radicles and actually belong to the system of lymphatics. Their special purpose is to carry the materials taken from the intestinal contents to the great lymph-channel, the thoracic duct.

The *plicæ circulares*, or *valvulae conniventes*, within the duodenum and jejunum, additionally model the mucous membrane and greatly increase its secreting and absorbing surface, as well as retard the passage of the intestinal contents, thereby facilitating the digestive

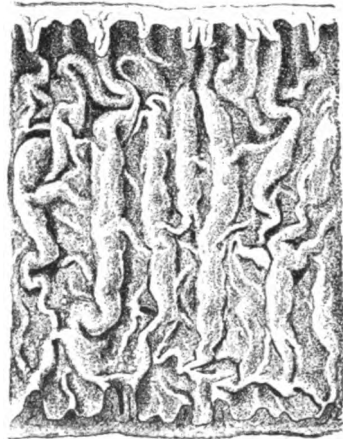


FIG. 206.—Surface view of mucous membrane of jejunum; stippled appearance is due to villi, which cover also the folds. Natural size.

glands, but occupy chiefly the submucosa (Fig. 209). The upper part of the duodenum possesses, therefore, a double layer of true glands—the

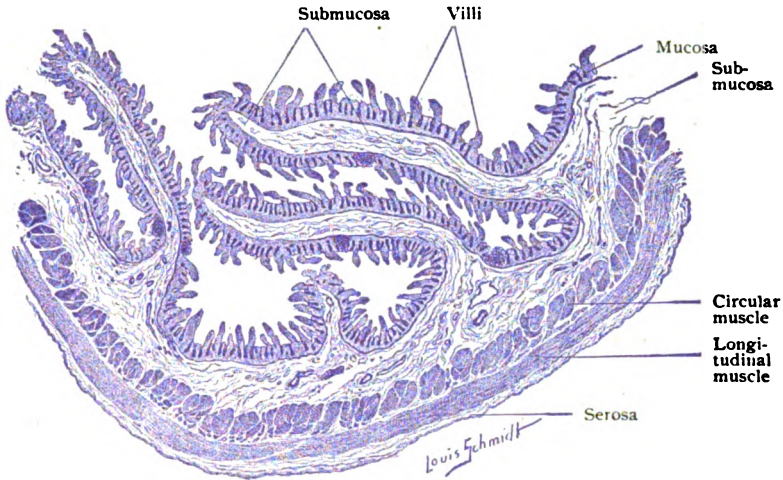


FIG. 207.—Longitudinal section of duodenum; plicae circulares are cut across, showing relation of these folds to the villi.  $\times 11$ .

crypts of Lieberkühn within the mucous coat, beneath which, in the submucosa, lie the glands of Brunner. The individual duodenal glands, tubo-

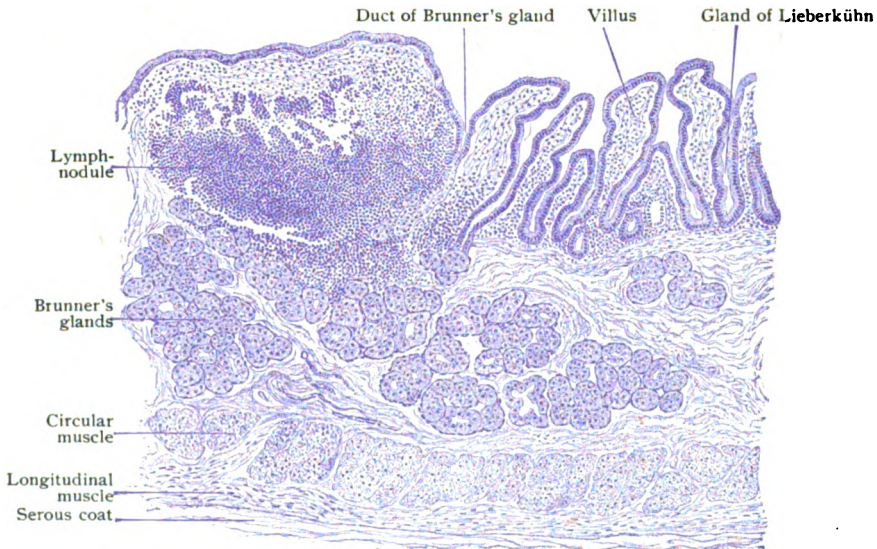


FIG. 208.—Longitudinal section of duodenum, showing Brunner's and Lieberkühn's glands villi and lymph-nodule.  $\times 68$ .

alveolar mucous in type, form somewhat flattened spherical or polygonal masses (.5–2 mm.), consisting of richly branched tubules ending in dilations. Their excretory ducts pierce the muscularis mucosæ and, after

traversing the tunica propria, open either directly on the free surface, or into the crypts of Lieberkühn. The columnar gland-cells lining the duodenal alveoli are probably identical in nature with those of the pyloric glands.

The **crypts** or **glands of Lieberkühn** are simple tubular depressions which are found not only throughout the small intestine, but the large one as well. Under low magnification, the surface of the small intestine exhibits numerous pits, the orifices of these crypts, which almost fill the spaces between the bases of the villi; with the exception of the areas immediately overlying the lymph-nodules, where they are displaced, these glands are present in all parts of the intestinal tube. They are very closely set, narrow and penetrate the tunica propria as far as the muscularis mucosæ. In length they vary from .2-.4 mm., and in diameter from 60-80  $\mu$ . The lining of the crypts rests upon a delicate basement membrane and consists of a single

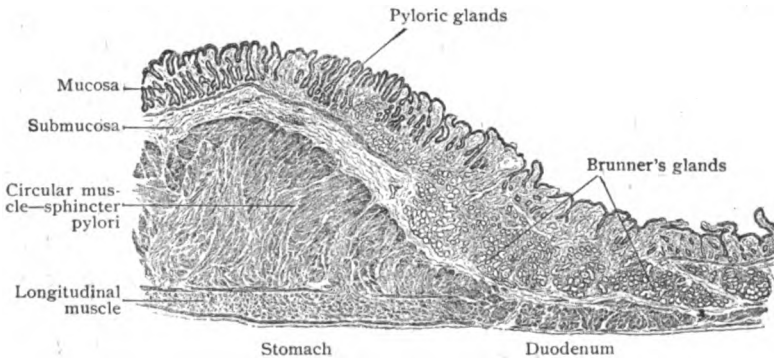


FIG. 209.—Longitudinal section through junction of stomach and duodenum, showing transition of pyloric into duodenal glands; also thickening of circular muscle to form sphincter pylori.  $\times 15$ .

layer of columnar cells, continuous with those covering the villi. They differ from these in being shorter and without the cuticular border seen on the villi. In view of the presence of mitotic figures within the crypt-epithelium of the adult, it is probable that the young cells here produced are gradually pushed upwards and supply the elements required to replace the old worn-out surface cells on the villi. Goblet-cells, as well as migratory colorless blood-corpuscles, occur among the lining of the crypts. Constantly within the human ileum, the deepest parts of the crypts of Lieberkühn contain small groups of granular elements, the *cells of Paneth*, whose significance is undetermined. The duodenum, jejunum and vermiform appendix are uncertain seats of these cells, while within the large intestine they are absent. The fact that such cells are wanting in many orders of animals possessing well developed intestinal crypts, points to some special, rather than a general, purpose.

**Lymph-Nodules.**—The lymphoid tissue within the intestinal tube occurs in the form of circumscribed nodules, which may remain isolated, as the *solitary nodules*, or be collected into considerable masses, as *Peyer's patches*.

The **solitary nodules** vary greatly in number and size, sometimes being abundant in all parts of the small intestine, at other times almost wanting; usually they are few in the upper and numerous in the middle and lower parts of the tube. They appear as small whitish elevations, spherical or pyriform in shape and from .2-2.5 mm. in diameter. Villi and crypts of Lieberkühn are wanting over the prominence of the nodules (Fig. 210).



In structure the solitary nodules correspond to lymph-nodules in other localities, consisting of a capsule of fibrous tissue enclosing the delicate reticulum which supports the lymphocytes within its meshes. Within the larger nodules, spherical or ellipsoidal germ-centres are present; they are, however, not constant, being present, as a rule, in young subjects, but often absent in older ones. Each nodule is surrounded by a rich network of small blood-vessels, from which fine capillaries penetrate the lymphoid mass (Fig. 151). Definite lymph-paths are absent within the nodules, although a plexus of lymphatics surrounds their exterior.

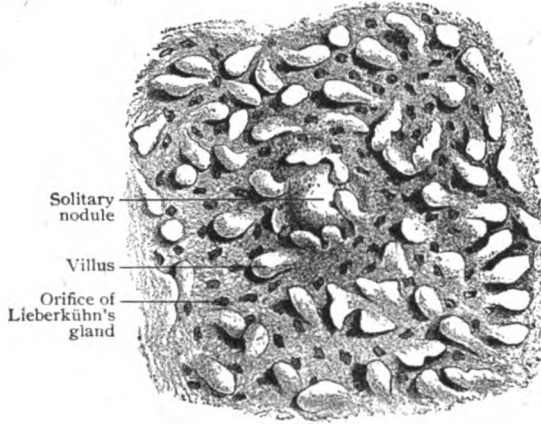


FIG. 210.—Surface view of mucous membrane of small intestine (ileum), showing villi, glands and solitary lymph-nodules.  $\times 10$ .

The **aggregated nodules** or **Peyer's patches**

are collections of simple nodules, the individual nodules being blended by intervening lymphoid tissue (Fig. 211). They are present in the lower half of the small intestine, especially in the ileum, but exceptionally are found as high as the beginning of the jejunum. The patches appear as slightly raised elongated oval areas. They

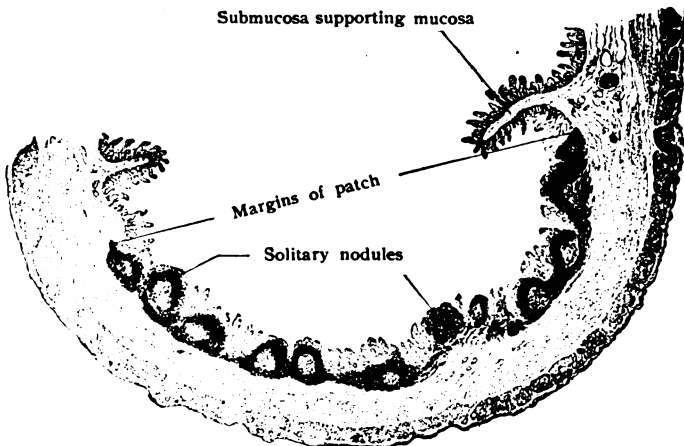


FIG. 211.—Transverse section of ileum, showing a Peyer's patch cut across.  $\times 8$ .

usually number about thirty, although as few as eighteen or as many as eighty have been counted. Their length is ordinarily from 1–4 cm. and their breadth from 6–16 mm. Each patch contains from 20–30 ovoid individual lymph-nodules which, when well developed, occupy both the mucous and submucous coats, their smaller ends almost reaching the epithelium and their bases the muscular tunic. The villi and crypts of Lieberkühn are present over the areas between the nodules, although less developed than beyond the patch.

In structure, the component lymph-nodules correspond to the solitary nodules, the aggregated nodules being blended into a continuous mass by the less dense lymphoid tissue filling the spaces between the individual nodules. The entire patch is defined from the surrounding tissues by an imperfect fibrous capsule.

The **submucous coat** of the small intestine, although lax, does not allow displacement of the plicæ circulares, except in the lower part of the tube. In addition to most of Brunner's glands and the lymph-nodules, the submucosa contains blood-vessels and lymphatics of considerable size and the nerve-plexus of Meissner.

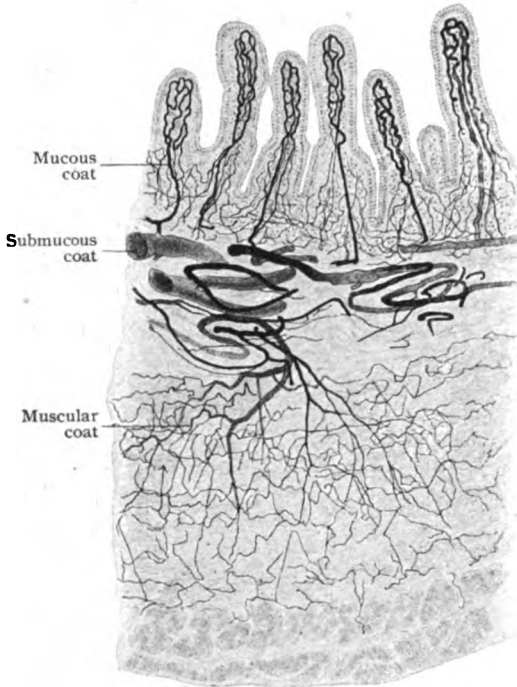


FIG. 212.—Transverse section of injected small intestine, showing general distribution of vessels.  $\times 45$ .

The **muscular coat**, about .4 mm. thick, consists of an inner circular and an outer longitudinal layer of involuntary muscle. The circular stratum is some two or three times as thick as the longitudinal one and is the more regular in arrangement. The thin longitudinal layer is often imperfect, especially along the attachment of the mesentery. The entire muscular coat diminishes in thickness towards the lower end of the small intestine.

The **serous coat**, with the exception of that of the duodenum, completely invests the gut except along the line of attachment of the mesentery, where the two layers of peritoneum diverge, leaving a non-serous area

between them for the passage of blood-vessels, lymphatics and nerves. In structure the serous coat of the intestine corresponds to that of the stomach, and includes essentially the fibro-elastic connective tissue stroma, covered on the free surface with mesothelium.

The **blood-vessels** supplying the small intestine reach the walls of the tube between the peritoneal folds constituting the mesentery. After sending branches to the serous coat, the arteries penetrate the muscular tunic (to the outer part of which twigs are given in passing) to gain the submucosa. Within the latter, additional twigs are given to the muscular coat, while others supply the glands and lymph-nodules lying in this tunic. Larger branches pass from the vessels of the submucosa into the mucous membrane, some to break up into capillaries forming networks around the gland-tubules and others to supply the villi. Each villus receives from one to three arterioles, which resolve into capillaries occupying the peripheral part of the stroma. The blood is returned by a single axial vein which traverses the projection and becomes tributary to the larger venous stems within the submucous coat, as do the other veins of the tunica propria that commence near

the epithelium. The veins within the submucosa accompany the arteries through the muscular coat and unite into the emergent venous channels that course with the arteries between the peritoneal folds.

The **lymphatics** of the small intestine, long known as the *lacteals* on account of their milky appearance when containing finely divided particles of fat, begin as the absorbent vessels of the villi. In addition, lymph-channels form a plexus within the tunica propria in the neighborhood of the muscularis mucosæ, from which tributaries pass to the larger submucous plexus. The latter is characterized by irregular contours, due to the dilations associated with the numerous valves. The emergent lymphatics penetrate the muscular coat and, within the serous tunic, unite into larger trunks that pass to the lymph-nodes between the peritoneal folds; from these smaller nodes lymphatics converge to the larger mesenteric lymph-nodes.

The **nerves** supplying the small intestine are derived from the solar plexus, and include both medullated and nonmedullated fibres, the last being chiefly from the sympathetic. In their distribution, they closely follow the arrangement observed in the stomach (page 163), including the plexus of Auerbach and of Meissner and, additionally, a plexus of nonmedullated fibres within the villi.

### THE LARGE INTESTINE.

The large intestine, subdivided into the cæcum, the colon and the rectum, measures about 1.5 meters or nearly 5 ft. in length. As other parts of the intesti-

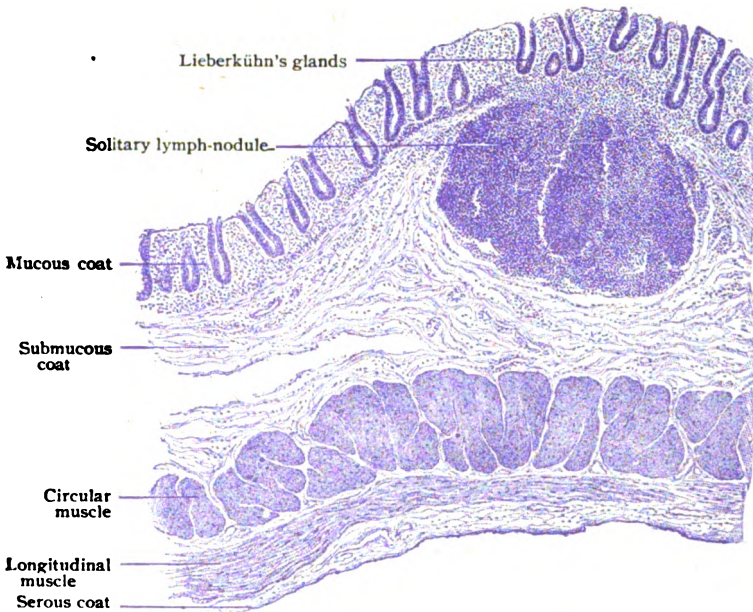


FIG. 213.—Longitudinal section of large intestine (ascending colon), showing the general arrangement of the coats and a solitary lymph-nodule.  $\times 30$ .

nal tube, it consists of four coats—the mucous, submucous, muscular and serous.

The **mucous coat** of the large intestine agrees in its essential structure with that of the small gut, consisting of a *tunica propria*, resembling lymphoid tissue, covered by a single layer of columnar *epithelium* exhibiting a cuticular

border. It differs, however, in having neither villi nor plicæ circulares, and, in consequence, lacks the velvety appearance of the small intestine, the mucous surface being smooth, although thrown into folds and pouches by modifications in other coats. The muscularis mucosæ is less regular in its development, being feebly represented in the colon and exceptionally thick in the rectum.

The *crypts of Lieberkühn* resemble those of the small intestine, but are larger (.4-.5 mm. long) and less interrupted. Within the rectum they may attain a length of .7 mm. The lining of the crypts is conspicuous on account of the abundance of goblet-cells, which in the middle and upper parts of the tubules almost replace the ordinary epithelial elements. As in the small intestine so here, mitotic figures are often seen in the cells lining the crypts, the new elements so arising being eventually pushed to the surface to replace the old ones that are disappearing.

The *lymphoid tissue* occurs as solitary nodules only, Peyer's patches being absent in the large intestine. The lymph-nodules are largest and most plentiful in the cæcum and in the vermiform appendix; in the latter situation

they are so numerous that in places they form an almost continuous mass of lymphoid tissue. In the colon the nodules are less abundant, but in the rectum they are again numerous. They are generally of larger size (1.5-3 mm.) than in the small intestine.

The *submucous coat* closely resembles

the similar fibro-elastic connective tissue tunic of the small intestine, and allows fairly free play of the mucous membrane. In addition to the blood-vessels, lymphatics and nerve-plexus of Meissner, it contains the deeper and more expanded portions of the solitary lymph-nodules.

The *muscular coat* includes a thicker internal layer of circular fibres and an external one of longitudinal fibres; the latter, however, are not uniformly distributed, but, in most places, are collected into three bands, the *tæniæ*, between which the longitudinal muscular coat is extremely thin or imperfect. These bands are shorter than the layers of the intestinal wall internal to them, and are responsible for the characteristic sacculation of the large intestine. The circular muscle increases markedly towards the lower end of the rectum, and in the anal canal becomes augmented into a sheet of involuntary muscle, some 4 mm. thick, known as the *internal sphincter*.

The *serous coat* is incomplete in certain parts of the large intestine owing to secondary changes during development and growth. In structure it corresponds to the peritoneal investment of other parts of the alimentary tract (page 175). The characteristic little fringes or bags, the *appendices epiploicæ*, that are attached, particularly along the median aspects of the ascending and descending colon and on the lower side of the transverse colon, consist of pouches of peritoneum filled with adipose tissue (Fig. 218).

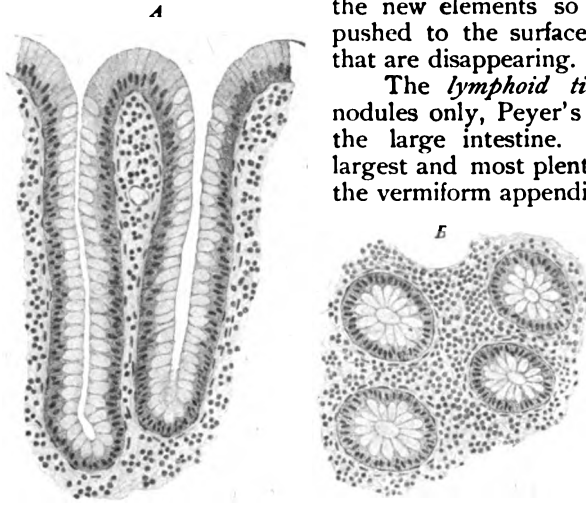


FIG. 214.—Portion of mucosa of large intestine, showing crypts of Lieberkühn cut lengthwise (A) and crosswise (B); epithelial elements contain mucus and are "goblet-cells."  $\times 160$ .

The blood-vessels, lymphatics and nerves of the large intestine follow, in the details of their distribution, the general plan described in connection with the small intestine (page 170).

The **ileo-colic valve**, guarding the entrance of the ileum into the large intestine, results from the thrusting of the small gut into the large, during foetal life, in such a way that originally all layers of the intestinal wall are involved. Where the two serous coats come into contact, the mesothelium disappears and the permanent union is effected by fibro-elastic tissue and secondarily developed longitudinal muscle. Although both layers of the original muscular coat are carried into the folds of the valve, it is the circular muscle that undergoes marked thickening and forms the efficient sphincter guarding the opening. The mucosæ covering the two sides of the crescentic valve-folds differ, that continued from the ileum possessing villi which, as rudimentary elevations, continue almost to the margin of the folds.

The **vermiform appendix**, the slender worm-like appendage attached to the cæcum, about 8.4 cm. ( $3\frac{1}{4}$  in.) long and 6 mm. in diameter, contains all the coats of the large intestine. The mucous coat is thrown into longitudinal folds and encloses a narrow irregular lumen. In its general structure it corresponds to the mucosa of the large intestine, but is infiltrated to an unusual degree with lymphocytes. These are collected into many lymph-nodules, with germ-centres, the lymphoid tissue being so abundant that it often almost encircles the appendix as a continuous mass. The crypts of Lieberkühn contain an unusually large number of goblet-cells; these are, however, few on the free surface. The inner circular muscle is about twice as thick as the external longitudinal layer. The lymphoid tissue of the vermiform appendix is, as elsewhere, most developed in childhood and tends to atrophy in middle life. Along with such atrophy, the walls of the appendix manifest a disposition to adhere, more or less obliterating the lumen of the tube. In consequence of these changes, after the thirty-fifth year the appendix often exhibits variations from the normal condition.

The **rectum**, including the anal canal, presents modifications calling for passing notice. The crypts of Lieberkühn are especially large (.7 mm. in length), although less numerous, and do not entirely disappear until the transition of the columnar to the stratified squamous epithelium has been reached or, sometimes, even slightly passed. This transformation begins at the upper ends of the vertical mucosa-folds, the *rectal columns* or *columns of Morgagni*, that surround the anal canal and contain strands of muscle; at the level of the crescentic folds, the *anal valves*, connecting the bases of the

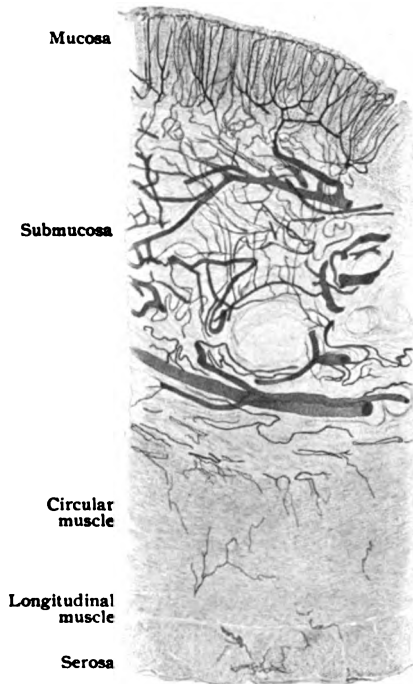


FIG. 215.—Transverse section of injected large intestine, showing distribution of arteries to the coats.  $\times 20$ .

columns, the mucous membrane is replaced by the skin lining the lower segment of the anal canal. The surface of the rectal mucosa is punctated with minute tubular depressions, the *rectal pits* of Cunningham, at the

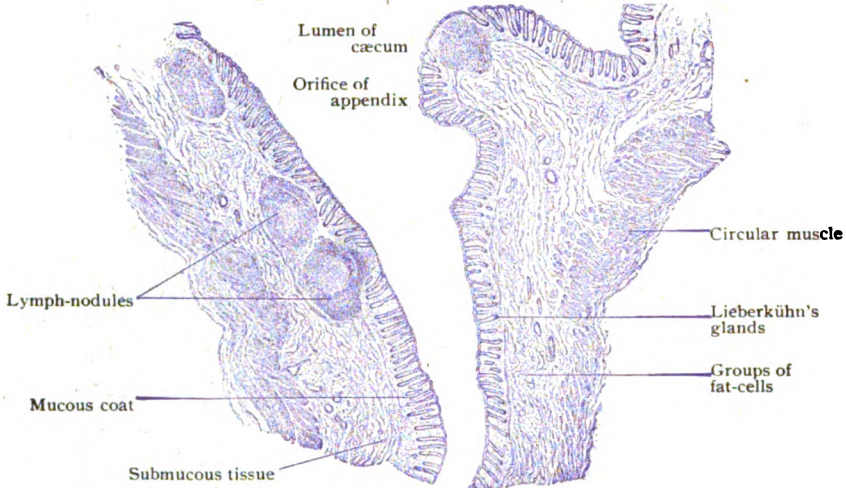


FIG. 216.—Longitudinal section through junction of vermiform appendix and cæcum.  $\times 10$ .

bottom of each of which is an accumulation of lymphoid tissue resembling a lymph-nodule. The submucous coat is lax and contains the extensive hémor-

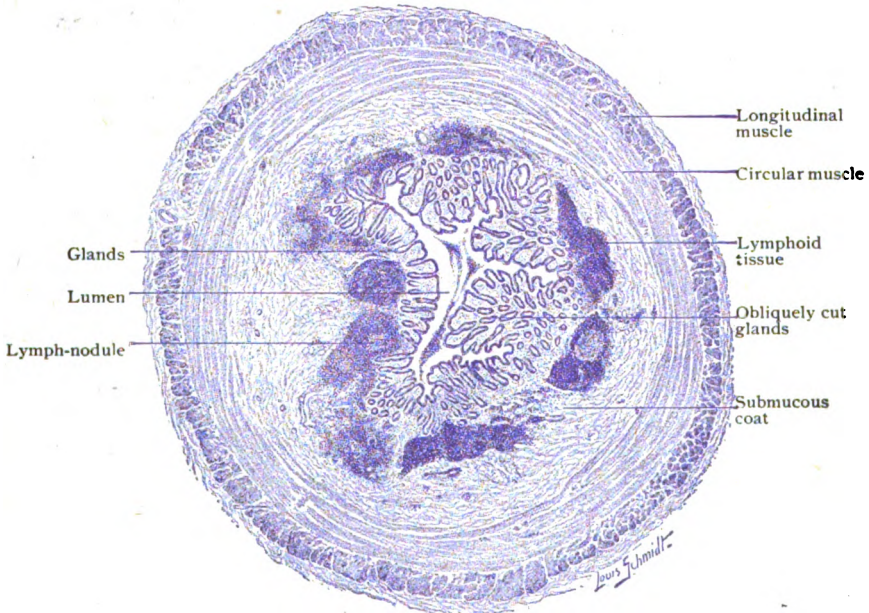


FIG. 217.—Transverse section of vermiform appendix.  $\times 10$ .

rhoidal plexus of veins. In addition to the temporary folds, the rectal mucous membrane presents usually three crescentic shelf-like projections, the *rectal valves*, that are ineffaceable. These plicæ are formed by the

infolding of the mucosa, submucosa and greater part of the muscular tunic, a portion of the longitudinal muscle passing over the creases externally. The shortness of the muscular bands, into which the longitudinal muscle is condensed in front and behind, serves to maintain these transverse folds. Where the peritoneum is wanting, as it is except over part of the anterior aspect of the rectum, the serous coat is replaced by a fibrous one composed of fibro-elastic tissue.

## THE PERITONEUM.

The peritoneum, the serous membrane lining the abdominal cavity and covering more or less completely the therein contained organs, consists of a connective tissue *stroma* and the surface layer of *mesothelium*. The latter is a single layer of plate-like cells (Fig. 25) irregularly polygonal in form and of varying size, whose contours are mapped out, after staining with silver nitrate, by delicate sinuous dark lines that correspond with the particles of reduced silver in the intercellular cement-substance. Each cell encloses an oval flattened nucleus, usually somewhat eccentrically placed, that is almost invisible until tinged with some appropriate dye. The size and form of the mesothelial plates vary much with the tension to which they are subjected; when unduly stretched, they are often imperfect or, indeed, displaced.

The *stroma* consists of a feltwork of connective tissue bundles of variable fineness, those of the parietal being commonly more robust than those of the visceral peritoneum. The deeper part of the stroma contains numerous elastic fibres, which are most abundant and developed in the parietal sheet, where they form a distinct network. Seldom in the mesenteries but constantly in the omenta, the stroma undergoes partial absorption, whereby larger or smaller openings, *fenestra*, result (Fig. 38). In this manner what originally was a continuous sheet becomes a fenestrated membrane, over which the mesothelium stretches as an unbroken covering, investing the trabeculæ as well as the parts still retaining the character of membranes. The nuclei of the connective tissue cells and those of the mesothelial plates are seen intermingled. Although all the important peritoneal folds, as the mesenteries, omenta and many of the so-called ligaments of the viscera, theoretically include two layers of serous membrane and an intervening layer of connective tissue prolonged from the body-wall, in which course the vessels and nerves supplying the organs, such duplicatures consist essentially of a general connective tissue stroma-layer covered on each side by a stratum of mesothelium. Wherever two peritoneal surfaces are brought into permanent contact, the mesothelium disappears and the serous character of the attachment is lost, the union henceforth being one of fibrous tissue. Where readily movable, as over most parts of the abdominal and pelvic walls and many folds, the attachment of the peritoneum to the subjacent parts is effected by a layer of fat-laden **subserous tissue**. This fibro-elastic layer varies in thickness, but in many places, as over the liver, stomach or intestine, where the perito-

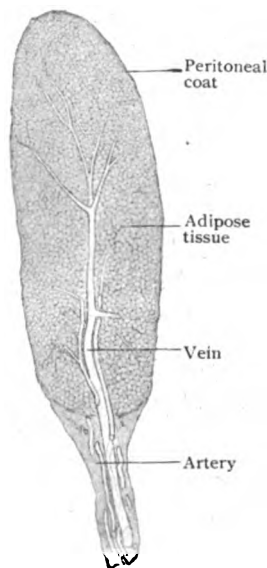


FIG. 218.—Longitudinal section of an epiploic appendage.  $\times 22$ .

neum is intimately attached, the subserous tissue is so reduced as to be practically wanting. In certain localities, conspicuously in the broad ligament of the pelvis, the subserous tissue contains strands of unstriated muscle.

The **blood-vessels** supplying the peritoneum itself are meagre in size and number. The **lymphatics** include a superficial network beneath the mesothelium and a deeper plexus of lymph-channels within the stroma. The **nerves** include both medullated and nonmedullated fibres, the latter being destined for the walls of the blood-vessels. The sensory fibres supplying the parietal peritoneum in many cases are connected with lamellated corpuscles and end-bulbs (Fig. 116).

### THE LIVER.

The liver, the largest gland in the body, consists of very delicate glandular tissue disposed around the ramifications of the portal vein. Developed in the primitive anterior mesentery, its connective tissue (mesodermic) ele-

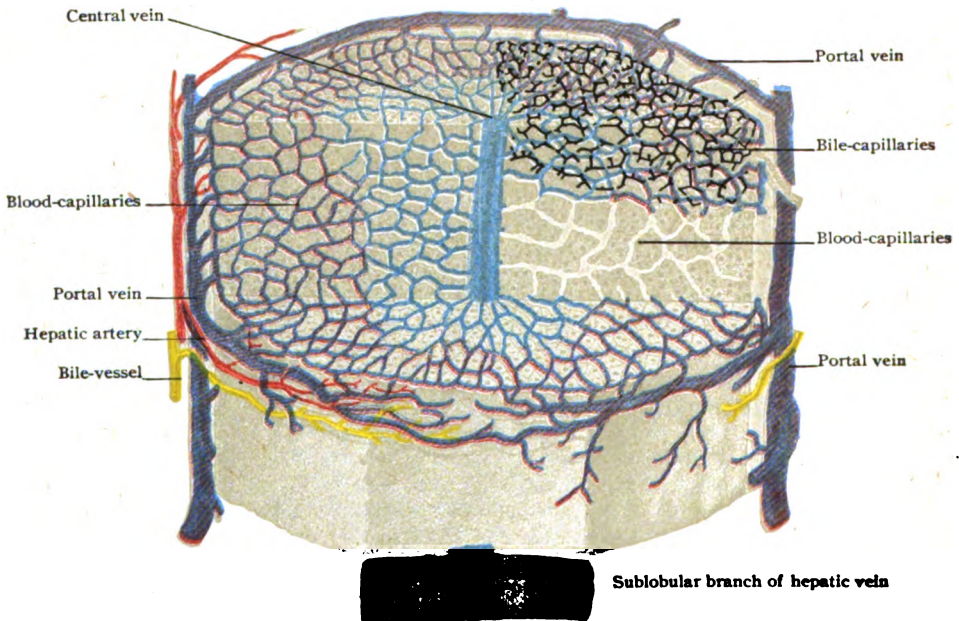


FIG. 219.—Diagram of hepatic lobule; portions of surface and of transverse and longitudinal sections of the lobule are represented. The branches of the portal vein are purple; of the hepatic artery, red; of the hepatic veins, blue; of bile-ducts, yellow; the intralobular bile-canaliculi are black.

ments have a common origin with the diaphragm, while its duct and glandular elements are derived from a sprout from the duodenum. Hence the liver is an outgrowth and appendage of the alimentary tube. Its peculiar shape is due chiefly to the pressure of surrounding organs, since its tissue is so plastic as to be moulded by them. The liver weighs from 1450–1750 gm., approximately 3–3¼ lbs., and in the adult contributes about one fortieth of the entire body weight.

In its fundamental arrangement, the liver corresponds to a highly modified compound tubular gland. Early in foetal life, however, the terminal divisions of the tubules unite to form networks, after which the tubular



character of the liver becomes progressively more masked by the intergrowth of the cell-cords and the large veins. The glandular tissue is subdivided by connective tissue into small cylindrical masses, the *lobules*, which on the surface of the organ are seen as little polygons, 1–2 mm. in diameter. This interlobular tissue is continuous with the fibrous envelope, or *capsule*, that invests the exterior of the liver, at the transverse fissure being prolonged as the *capsule of Glisson* into the organ in company with the interlobular vessels. The distinctness with which the lobules are defined depends upon the amount of the interlobular tissue. This is notably abundant in the hog's liver, in which the lobules appear as sharply marked polygonal areas. In the human liver, on the contrary, the interlobular tissue is very meagre, the lobules, in consequence, being poorly defined and uncertain in outline (Fig. 221).

**The Blood-Vessels of the Lobule.**—The arrangement of the blood-vessels is the salient feature in the architecture of the fully formed hepatic

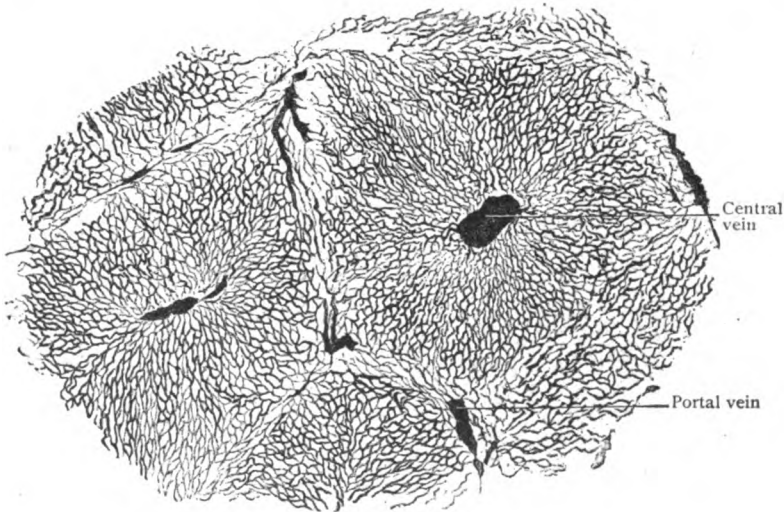


FIG. 220.—Section of liver injected from hepatic vein, showing intralobular capillary network.  $\times 100$ .

lobule. The divisions of the portal vein—the vessel bringing blood to the liver for its function—enter at the transverse fissure and break up into branches which ramify within the interlobular tissue (capsule of Glisson) and encircle the lobules. These *interlobular veins* give off numerous small branches that enter the periphery of the lobules to resolve at once into the *intralobular capillary network*. The general disposition of this network is radial, the capillaries converging towards the middle of the lobule where they join to form and empty into the *central or intralobular vein*. The course of the latter corresponds with the long axis of the lobule, hence, in cross-sections of the lobule, the central vein appears as a transversely cut channel towards which the capillaries converge (Fig. 220). The *capillary network* within the lobule is made up of vessels usually about  $10\ \mu$  in diameter, the widest capillaries ( $20\ \mu$ ) being in the immediate vicinity of the afferent and efferent veins. The meshes of the capillary network vary from  $15\text{--}45\ \mu$  in their greatest dimension, those at the periphery being broader and more rounded, while those near the centre of the lobule are narrower and more elongated.

The central vein traverses the axis of the lobule, enlarging as it proceeds, to the *base*, as the side of the lobule through which the vein escapes is termed. The central vein begins usually about midway between the base and the opposite border of the lobule and is formed by the confluence of the capillary tributaries. Immediately on emerging from the lobule, the central vessel opens into a *sublobular vein*, which runs, in a general way, at right angles to its intralobular tributaries and along and beneath the bases of the lobules.

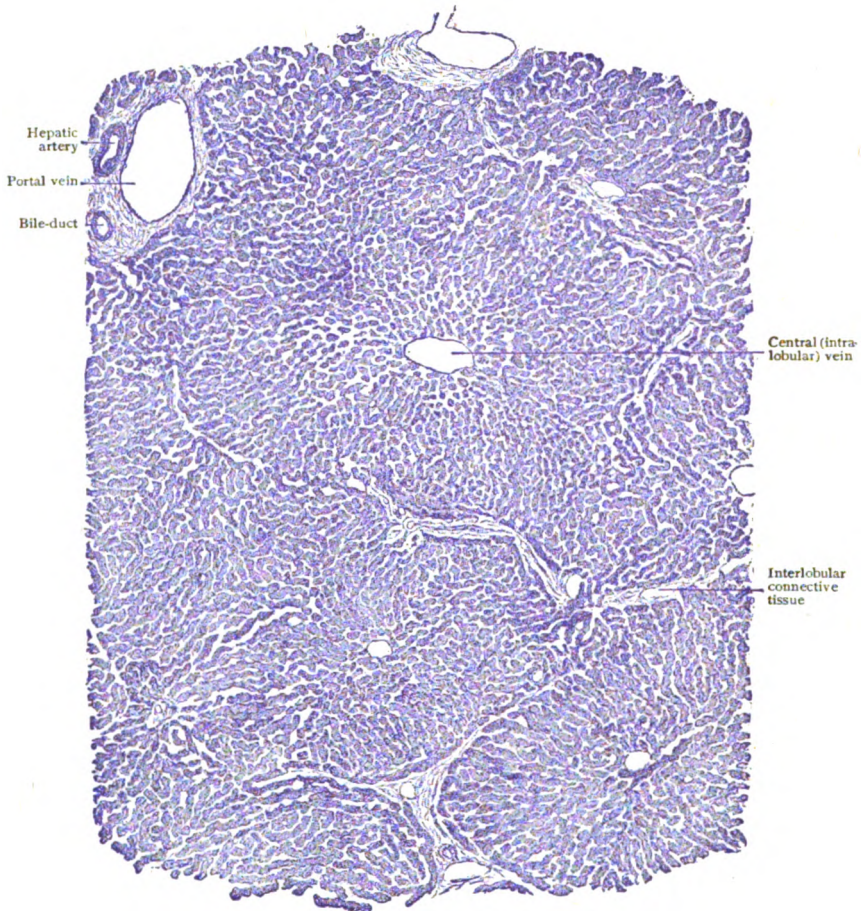

FIG. 221.—Section of un.injected liver, showing the general arrangement of the lobules, interlobular and intralobular vessels.  $\times 120$ .

The sublobular veins are thus surrounded by the bases of the lobules, a single central vein returning the blood from each. The sublobular veins join to form larger trunks, which in turn unite and constitute the branches of the *hepatic veins*, the large venous channels, commonly several, that carry the blood from the liver into the inferior vena cava.

**The Liver-Cells.**—The meshes of the interlobular capillary network are occupied by the hepatic cells, the bile-capillaries and a meagre amount of delicate connective tissue. The liver-cells are arranged as cords or trabec-

ulæ which conform in their general disposition and shape to the intercapillary spaces which they fill. When isolated, the liver-cells present a polygonal outline and measure from 15–25  $\mu$  in their longest dimension. Each cell comes into contact with from six to nine other ones, the surfaces of contact being plane from mutual pressure. Always one side, often more than one, exhibits a shallow concavity that indicates the surface of former contact with a capillary. The cells lie against at least one capillary and sometimes several, this relation depending upon the size of the blood-channel. The liver-cell consists of finely granular protoplasm, which at times exhibits a differentiation into an outer and inner zone. It is without a cell-membrane, although the cytoplasm is condensed at the periphery. The spherical nucleus contains relatively little chromatin and usually a nucleolus. Occasional cells are conspicuous on account of their large size and unusually large nucleus; such elements probably undergo direct division and produce the double nucleated cells constantly encountered in sections of normal liver. Centrosomes have also been observed. Particles of glycogen, minute oil drops, and granules of bile-pigment are fairly constant inclusions. Fat-containing cells are most abundant at the periphery of the lobule, those containing pigment particles near the centre.

**The Bile-Capillaries.**—These minute canals, representing the lumina of ordinary tubular glands, form a network of intercommunicating channels throughout the lobule, closely related to the liver-cells. Instead of the arrangement usual in glands, where several secreting cells border the gland-lumen each with a single surface, in the exceptional case of the liver the excretory channels are bounded by the opposed surfaces of only two cells, the bile-capillary occupying but a small part of these surfaces, which it models with a narrow groove. Moreover, the canaliculi are not limited to a single surface on each cell, for they are found between all surfaces where two liver-cells are directly in contact. Hence, each hepatic cell is in immediate relation with a number of bile-capillaries. The latter, however, never lie on the surfaces of the liver-cells directed towards the blood-channel, the bile-canalculus never separating the blood-capillary and the liver-cell. Whilst the dominating direction of the bile-capillaries is radial and corresponds to the general disposition of the trabeculæ of hepatic cells, this radial arrangement is converted into a network by numerous cross-branches (Fig. 224). The resulting meshes agree in size and form with the individual liver-cells, which often appear surrounded by the bile-capillaries. The latter possess no walls other than the substance of the liver-cells between which they lie. The diameter of the minute biliary canals (1–2  $\mu$ ) remains con-

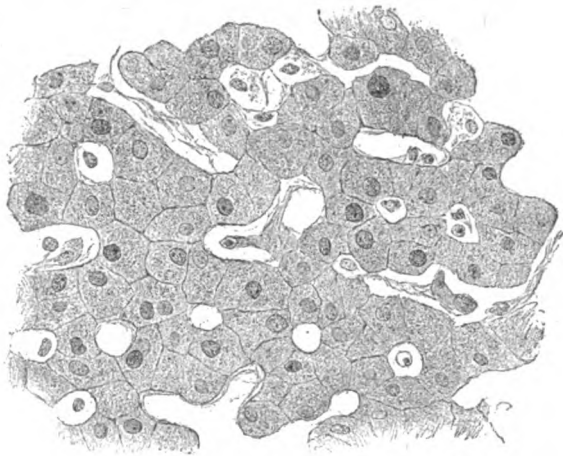


FIG. 222.—Section of uninjected liver, showing cords of hepatic cells between the capillary blood-vessels.  $\times 400$ .

stant throughout the lobule until the canaliculi reach the margin. Here the liver-cells abruptly diminish in size and become continuous with the low

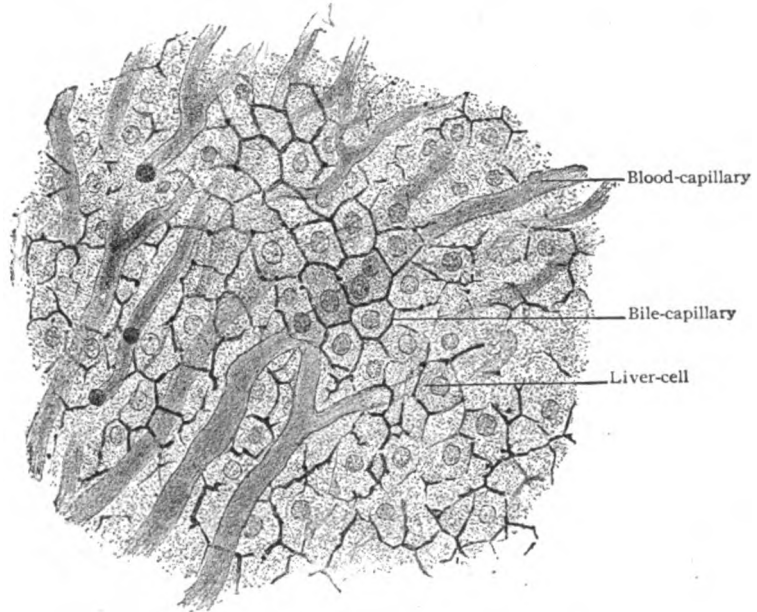


FIG. 223.—Section of liver in which both the blood and bile capillaries have been injected; the biliary channels surround the individual liver-cells.  $\times 300$ .

cuboidal cells that line the excretory tubes passing from the lobule into the surrounding connective tissue to become tributary to the larger interlobular

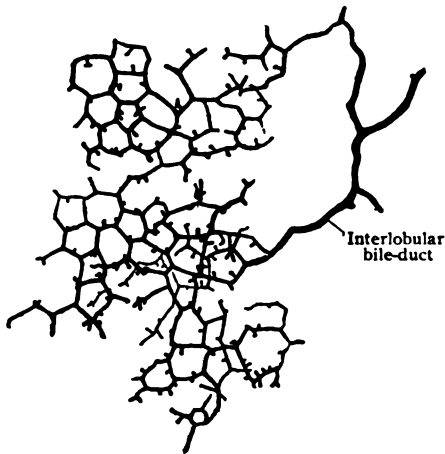


FIG. 224.—Section of liver treated with Golgi method, showing part of the intralobular network of bile-capillaries.  $\times 200$ .



FIG. 225.—Artificially digested section of liver, showing supporting interlobular fibrous tissue (below) and intralobular reticulum (above).  $\times 200$ .

bile-ducts. The ultimate relations between the bile-capillaries and the liver-cells is still a subject of discussion. According to some, extensions of the

capillaries normally exist within the substance of the cells, thus forming *intracellular secretion-canaliculi*. The latter are sometimes pictured as ending in minute dilatations, the *secretion-vacuoles*. It is highly probable that such appearances, while not artefacts, at least depend upon particular conditions of secretory activity and are, therefore, not constant details of the hepatic cells.

The **intralobular connective tissue** is very meagre in amount and consists of delicate prolongations of the interlobular fibrous tissue along the blood-capillaries. The tissue occurs only between the blood-channels and the cells and never between the latter. Although present in some quantity immediately around the central vein, in other parts of the lobule it is represented by lattice-works of fibres which surround the capillaries. The fibres are not elastic in nature, but correspond most closely to modified white fibres,

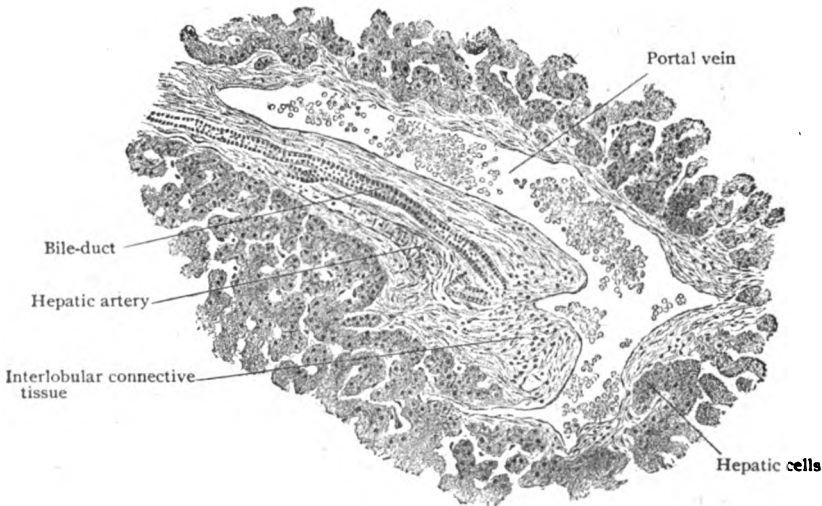


FIG. 226.—Section of liver, showing interlobular tissue and vessels.  $\times 160$ .

the entire intralobular connective tissue belonging to the variety known as reticulum. The small spindle or stellate elements seen in gold preparations, known as the *cells of Kupffer*, have been shown to belong to the capillary wall (perhaps distorted endothelial cells) and not to the perivascular fibrous tissue.

**The Biliary Passages.**—The **interlobular bile-ducts**, which receive the canals that pierce the periphery of the lobule as outlets of the intralobular network, accompany the branches of the portal vein and of the hepatic artery within the connective tissue between the lobules. The ducts, from 30–50  $\mu$  in diameter, form a network over the exterior of the lobule and possess walls consisting of a delicate fibro-elastic coat, in the smallest tubes little more than a basement membrane, lined with low columnar epithelium continuous with the cuboidal cells clothing the emergent canals. The perilobular ducts are tributaries of larger bile-vessels, which increase in diameter as they pass towards the transverse fissure.

The large ducts join into two main lobar trunks, by whose union, within or just beyond the transverse fissure, the **hepatic duct** is formed, a tube from 4–6 mm. in diameter and about 2.5 cm. long. Its walls include a dense fibro-elastic *tunica propria*, covered with a single layer of columnar epithelium

and beset with scattered small tubular *glands*. These, as well as the surface epithelium, contain many goblet-cells producing a mucous secretion. Bundles of unstripped muscle occur within the deeper parts of the tunica propria; they are neither numerous nor regularly disposed in definite layers, the chief longitudinal ones being supplemented by circular and oblique bundles. As the duct-system is followed into the capsulè of Glisson, the muscle disappears from the walls of all but the larger interlobular bile-vessels, while the fibro-elastic coat also gradually diminishes. Apart from the reduction in height of the cells, the lining of the ducts retains throughout its character of simple columnar epithelium, thus affording a ready means of distinguishing the bile-ducts from the blood-vessels as they course together between the lobules. The existence of former masses of hepatic tissue, which have disappeared during development and growth, is indicated by the blind ducts, known as the *vasa aberrantia*, found outside the liver-substance along the left border of the liver, around the inferior vena cava and in the vicinity of the transverse fissure.

The **gall-bladder**, the pear-shaped receptacle for the bile attached to the under side of the liver near its anterior border, possesses strong walls consisting of three coats: the *mucous*, the *muscular* and the *fibrous*, the

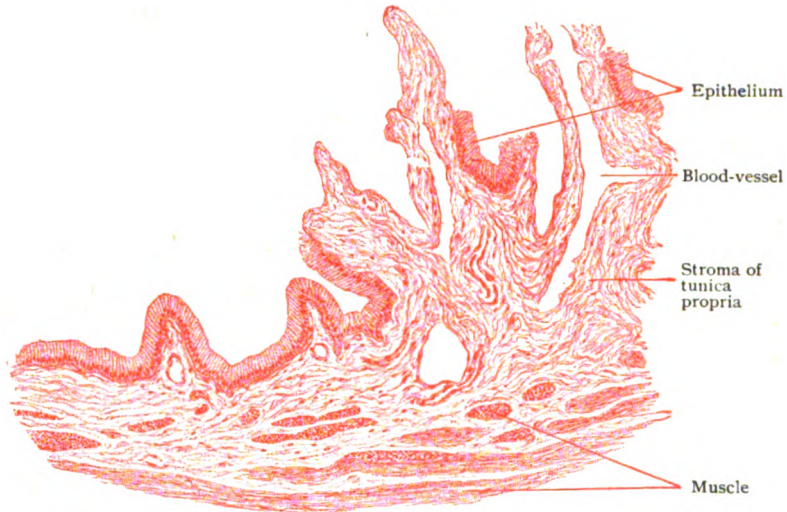

FIG. 227.—Section of wall of gall-bladder, showing plicated condition of mucous membrane.  $\times 100$ .

latter supplemented by a more or less extensive investment of peritoneum. The *mucous coat*, covered with a single layer of columnar epithelium about  $5 \mu$  thick, is modelled by a network of slightly raised ridges that mark off irregular polygonal areas some  $5 \text{ mm.}$  in diameter. These areas are often marked by minute tubular depressions of the mucosa which have been mistaken for glands. True branched mucous glands occur in the neck of the gall-bladder, but are so few in other parts of the sac as to be practically wanting. The epithelial cells exhibit a cuticular border and are often of the goblet type and concerned in producing a mucous secretion. The tunica propria contains a profusion of elastic fibres intermingled with the white fibrous tissue. The *muscular coat* is composed for the most part of circular bundles of unstripped fibres, but with these are interwoven longitudinal

and oblique ones. Outside the muscle lies a dense *fibrous coat* of fibro-elastic connective tissue. Where invested with peritoneum, the latter is attached to the proper wall of the sac by a layer of fat-laden subserous tissue.

The **cystic and common bile-ducts** possess walls that in structure correspond with the hepatic duct above described, consisting of a mucous tunic strengthened by bundles of unstriped muscle. At the lower end of the common bile-duct, the circular fibres are greatly augmented and form a sphincter-like ring around the orifice of the tube where it opens into the duodenal ampulla. The **bile**, the secretion of the liver, contains no distinctive cells, numerous minute oil drops and granular masses of biliary pigment, with occasional remains of the epithelial cells lining the ducts, being the more common objects encountered when the fresh fluid is examined microscopically.

The **blood-vessels** of the liver—the functional portal vein, the nutrient hepatic artery and the emergent hepatic veins—have been sufficiently described. It should be noted, however, that the blood conveyed to the organ by the hepatic artery is destined for the nutrition of the interlobular structures, the capsule of Glisson and the walls of the blood-vessels and of the bile-ducts. After supplying these through numerous although small twigs, the blood is collected by venous radicles and emptied either into interlobular branches of the portal vein or into the intralobular capillary network.

The **lymphatics** of the liver are represented within the lobules by minute lymph-spaces between the blood-channels and the liver-cells. These spaces drain into the more definite lymphatic paths within the interlobular connective tissue, which as the *deep lymphatics* surround the blood-vessels and ducts with plexuses that condense into the fifteen or more trunks emerging at the transverse fissure. The *superficial lymphatics*, very numerous and freely communicating with the deep set, arise from a close-meshed network of lymph-channels within the fibrous capsule.

The **nerves** of the liver, from the solar through the hepatic plexus, consist mostly of nonmedullated fibres, very sparingly intermingled with medullated ones. The former are destined chiefly for the walls of the blood-vessels and of the larger ducts, which, after sending filaments to the capsule, they follow within the interlobular tissue, where occasional nerve-cells are found along their course. Some few fibres, probably secretory in function, penetrate the lobules to end between the liver-cells. The meagre medullated sensory fibres terminate within the interlobular connective tissue.

## THE PANCREAS.

The pancreas, sometimes called the abdominal salivary gland, is a large tubo-alveolar gland that lies behind the stomach, extending from the loop of the duodenum across the spine and left kidney often as far as the spleen. It is conventionally divided into the head, embraced by the duodenum, the body and the tail. The interlobular connective tissue is unusually abundant; hence the compartments of gland-tissue are loosely united and the entire organ lacks the compactness ordinarily seen in large glands. While agreeing in its general structure with other serous glands, as the parotid, the pancreas differs in certain particulars. The most important of these are: (*a*) the tubular, rather than saccular, form of the alveoli; (*b*) the marked differentiation of a granular zone in the cytoplasm of the secreting cells; (*c*) the absence of specialized intralobular ducts; and (*d*) the presence of the characteristic islands of Langerhans.

The chief **pancreatic duct**, whose walls consist of a single layer of unusually tall ( $12\ \mu$ ) columnar epithelium and a tunica propria of compact

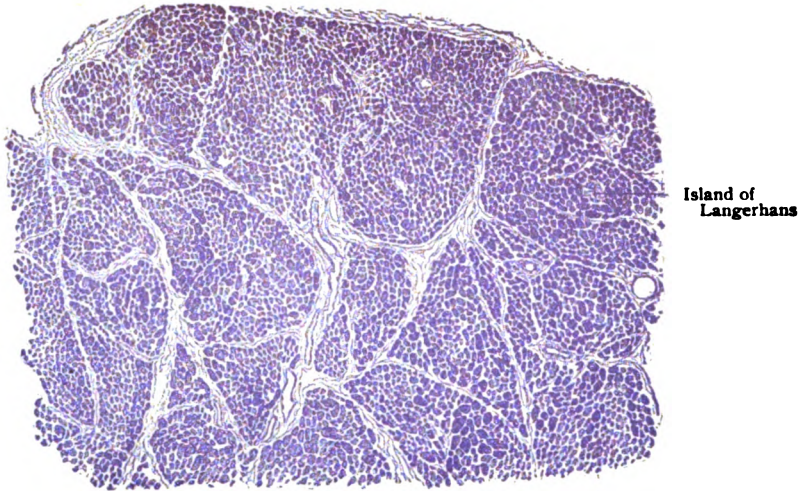


FIG. 228.—Section of pancreas, showing general arrangement of lobules.  $\times 30$ .

fibro-elastic tissue, gives off numerous lateral interlobular branches, also lined by a simple although lower epithelium. The canals springing from the

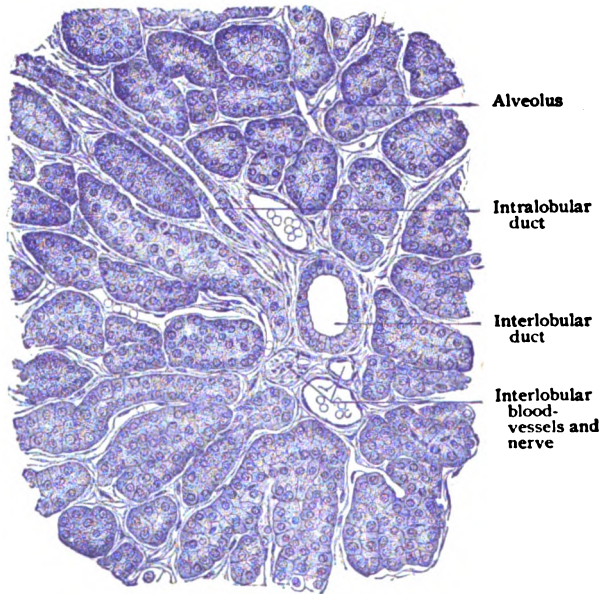


FIG. 229.—Section of pancreas, showing interlobular tissue with vessels, nerve and duct and surrounding tubular alveoli.  $\times 200$ .

interlobular ducts enter the lobules, where they are lined by flattened epithelial cells ( $3\ \mu$  high) and correspond to intermediate and not to the usual intralobular ducts. The latter being wanting, the uncommonly long inter-



mediate ducts pass directly to the tubular alveoli into many, but not all, of which their attenuated epithelium protrudes as the *centroacinal cells*. The relation of the latter to the secretory elements within the alveolus is such that the thinned-out duct-cells are surrounded externally by the gland epithelium, which is thus excluded from direct contact with the lumen of the alveolus.

The tubular **alveoli**, often tortuous and sometimes divided, possess a well-defined basement membrane, against which lie the gland-cells. The latter are usually blunt pyramidal in shape, with a length of about  $12\ \mu$ . Their cytoplasm exhibits two well differentiated zones, an inner granular one, next the lumen, filled with highly refracting zymogen granules, and an outer clear one, next the basement membrane, which is free from granules and contains the spherical nucleus.

The relative width of these zones varies with the functional condition of the cells. During rest, when the cells are stored with zymogen particles, the granular zone is very broad and the outer homogeneous one correspondingly narrow. With discharge of the pancreatic secretion during digestion, the granular zone diminishes and reaches its minimum, almost disappearing, when the gland is exhausted. The return to a condition of rest is accompanied by the formation and accumulation of a new store of zymogen particles until the granular zone is again at its maximum. Intercellular *secretion-canalliculi* are present in all alveoli in which the centroacinal cells exclude the gland-cells from the lumen. They extend between the cells almost, but not quite, to the basement membrane (Fig. 230) and serve to convey the secretion-products through the obstructing central cells into the lumen of the alveolus.

The **interalveolar cell-areas**, or **islands of Langerhans**, appear as small collections of modified gland-tissue, some 3 mm. in diameter, lying between the tubular alveoli, from which they are separated by delicate envelopes of fibrous tissue. These bodies consist of anastomosing solid cords or trabeculae of small polyhedral cells, faintly granular and without zone differentiation, separated by wide capillary blood-vessels, the whole recalling the arrangement of the liver-substance.

No extension of or connection with the duct-system of the organ has been demonstrated within these areas, secretion-canalliculi likewise being wanting. In view of their isolation from the surrounding glandular tissue and their intimate relation with the blood-channels, the interalveolar cell-areas are now generally believed to be concerned in producing some special substance that passes directly into the circulation; they may be regarded, therefore, as



FIG. 230.—Portion of pancreas, treated with Golgi method, showing secretion-canalliculi extending between the gland-cells.  $\times 50$ .

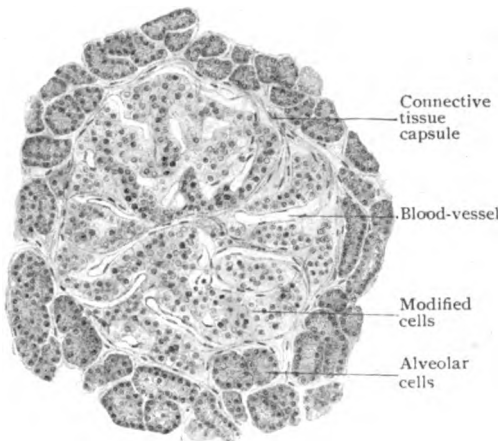


FIG. 231.—Section of pancreas, showing details of island of Langerhans.  $\times 190$ .

No extension of or connection with the duct-system of the organ has been demonstrated within these areas, secretion-canalliculi likewise being wanting. In view of their isolation from the surrounding glandular tissue and their intimate relation with the blood-channels, the interalveolar cell-areas are now generally believed to be concerned in producing some special substance that passes directly into the circulation; they may be regarded, therefore, as

minute multiple organs of internal secretion. They are developed from the same tissue which gives rise to the ordinary glandular elements of the pancreas and are constant features not only of the human organ, but also of the pancreas of a wide range of animals representing mammals, birds, reptiles and amphibians. Their distribution throughout the pancreas is by no means uniform, since, although about equally numerous in the head and adjacent part of the body, they may be almost double in number towards the tail.

The **pancreatic duct**, or *duct of Wirsung*, empties into the second part of the duodenum, usually by an orifice common to it and the common bile-duct. This relation is explained by the fact, that the beginning of the later pancreatic duct is derived from an outgrowth of the wall of the primary

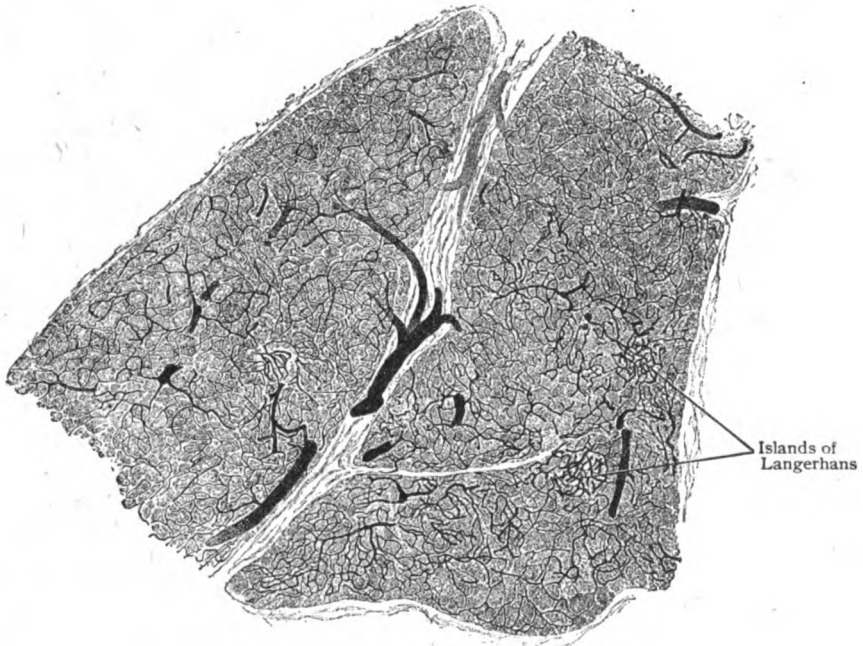


FIG. 232.—Section of injected pancreas, showing intralobular capillary network; also vascular convolutions of islands of Langerhans.  $\times 50$ .

liver-diverticulum that becomes the bile-duct, both excretory canals being thus closely connected from the first. The walls of the main duct and its larger branches contain numerous small tubular mucous glands and bundles of unstriated muscle. At its lower end, the circular bundles are condensed and augmented into a sphincter-like band that encircles its duodenal orifice.

The **blood-vessels** supplying the pancreas are distributed to the glandular tissue in accordance with the usual plan for such structures. The positions of the interalveolar cell-areas, however, are indicated in minutely injected organs by corresponding areas in which the capillary network is exceptionally dense (Fig. 232). The **lymphatics** are represented by definite channels accompanying the interlobular blood-vessels to which the intralobular lymph-spaces are tributary. The **nerves** are composed chiefly of nonmedullated sympathetic fibres distributed to the walls of the blood-vessels and of the larger ducts, some passing to the alveoli. Ganglion-cells, scattered or grouped, lie along the interlobular trunks.

## THE ORGANS OF RESPIRATION.

THE respiratory tract proper, that is excluding the nasal fossæ (through which the air passes when the mouth is closed) and the pharynx, includes the organs concerned in effecting the interchange of the gases between the blood and the inspired air and, in addition, the production of voice. It comprises the *larynx*, the *trachea* and its subdivisions—the *bronchi*, and the *lungs*, together with the serous membranes, the *pleuræ*, which surround the lungs and line the spaces containing them. The respiratory tract is developed as a ventral outgrowth from the primitive gut-tube and is lined, therefore, by entodermic epithelium, all other parts of the organs being derived from the mesoderm.

### THE LARYNX.

The larynx consists of a fibro-cartilagenous framework lined with mucous membrane and surrounded by muscles. By the action of the latter the relative position of the cartilages is modified, thereby affecting the approximation and tension of two folds of mucous membrane, known as the vocal cords, that cover the free edges of fibro-elastic membranes and bound the cleft through which the air passes to and from the windpipe.

The **cartilages** of the larynx include three single ones: the *cricoid*, the *thyroid* and the *epiglottis*; and three paired ones: the *arytenoid*, the *cornicular* and the *cuneiform*, the last being small and sometimes wanting. Other minute masses of cartilage will be noted in connection with the structures in which they occur. In structure the laryngeal cartilages correspond to the hyaline variety, with the exception of the epiglottis, the tip and vocal process of the arytenoid, the cuneiform, the corniculate and often, but not always, the median part of the thyroid, which exceptions consist of elastic cartilage. Beginning about the twentieth year, more or less extensive ossification of the cartilages, especially the thyroid and cricoid, occurs as a normal change. The arytenoid cartilages are less affected and the median part of the thyroid is said to remain unchanged in women.

The **mucous membrane** lining the larynx is a prolongation of that of the pharynx, and consists of the epithelium and tunica propria, with the underlying submucous tissue by which the mucosa is attached to the surrounding framework. The *epithelium* is, for the most part, stratified ciliated

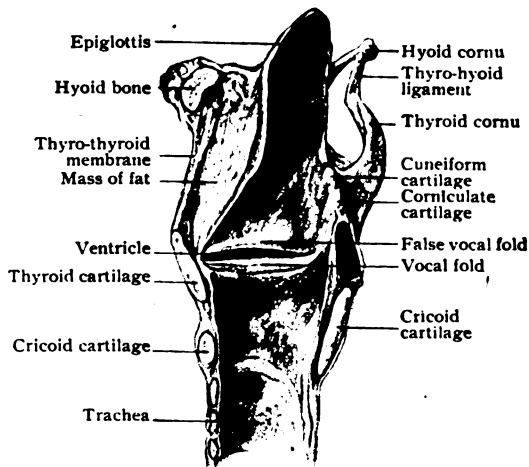


FIG. 233.—Median sagittal section of larynx; right half, seen from within.  $\times \frac{3}{4}$ .

columnar, except over the laryngeal surface of the epiglottis, the anterior aspect of the arytenoid cartilages and the true vocal cords, where the epithelium is of the stratified squamous variety. In this respect, however, the mucosa of the upper half of the larynx presents many individual variations, since patches of squamous epithelium are often observed within the more general lining of columnar cells. Small scattered taste-buds are often seen in the epithelium covering the epiglottis. The *tunica propria* consists of closely packed bundles of fibrous tissue, with an abundance of elastic fibres. It contains many lymphoid cells which in certain locations, as over the epiglottis and especially in the ventricle of the larynx (the lateral diverticulum

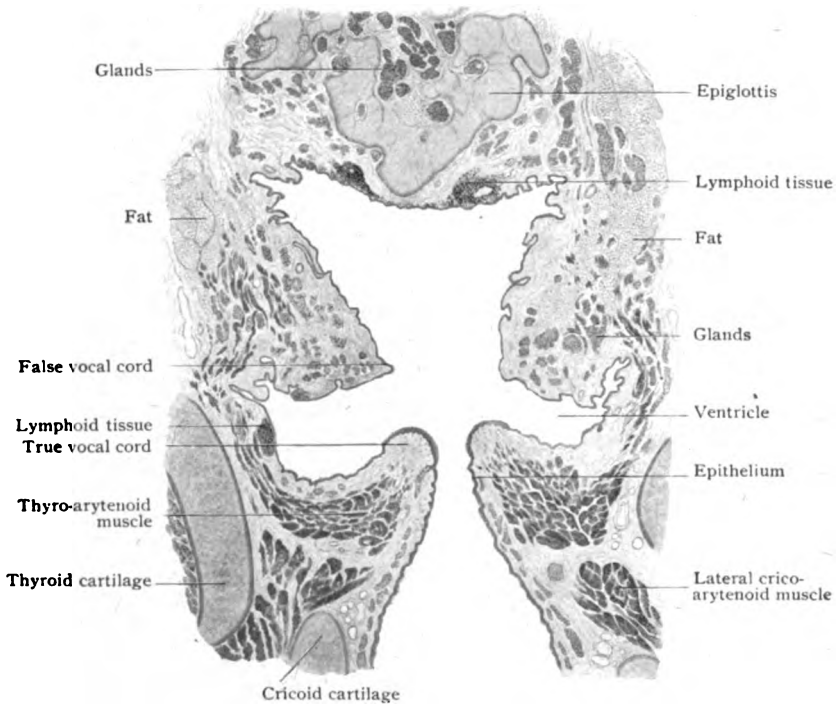


FIG. 234.—Frontal section of larynx passing through epiglottis, vocal folds and ventricle; the plane of section is at right-angles to that of preceding figure.  $\times 2\frac{1}{2}$ .

between the false and true vocal cords), are aggregated into distinct although small lymph-nodules (Fig. 234).

The *submucous layer*, composed of loosely disposed bundles of fibro-elastic tissue, varies in amount in different parts of the larynx, with corresponding modifications in the intimacy of attachment of the mucous membrane to the surrounding structures. Thus, it is meagre over the free part and laryngeal surface of the epiglottis, the arytenoid and lower part of the cricoid cartilages, in which positions the mucosa is closely attached. Over the true vocal cords the submucosa is practically wanting. On the other hand, in the aryepiglottic folds (which bound laterally the superior laryngeal orifice) and in the ventricle it is abundant, with consequent mobility of the mucosa. The submucous layer contains many groups of small mixed mucous tubo-alveolar *glands*. They occupy pits in the cartilage of the epiglottis, and

are numerous and relatively large over the false vocal cords (*plicæ ventriculares*) and plentiful in the ventricles. They do not occur on the upper surface of the true vocal cords within 3-4 mm. of their free margins, but beneath the latter the glands form almost a continuous layer.

The **vocal cords**, more appropriately called the *plicæ vocales*, are two duplicatures of mucous membrane which cover the free median margins of the lateral crico-thyroid membranes. This part of the membrane, often designated the thyro-arytenoid ligament, is attached to the thyroid cartilage in front and to the vocal process of the mobile arytenoid cartilage behind,

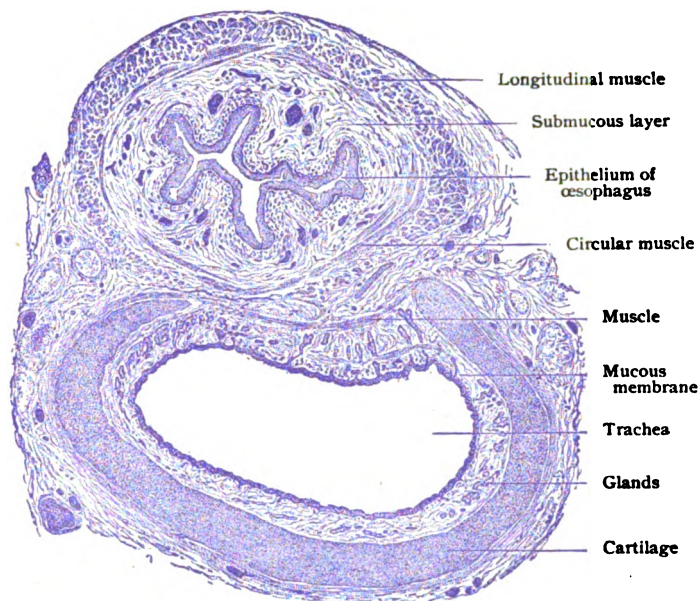


FIG. 235.—Transverse section of trachea and oesophagus of child.  $\times 15$ .

and is directly influenced by the contractions of the thyro-arytenoid muscle, which lies against the membrane externally and inserts many of its fibres directly into the fibrous band. The submucous tissue being wanting over the vocal cord, the here thin mucous membrane is intimately attached to the underlying fibrous stratum of the thyro-arytenoid ligament, thus insuring accurate response to the changes induced by muscular action. Small masses of elastic cartilage, from 2-3 mm. long, are occasionally found in the anterior ends of the vocal cords; smaller pieces of similar tissue are quite common in the ventricular *plicæ*.

The numerous **blood-vessels** supplying the larynx are distributed chiefly to the mucous membrane, in which the main capillary network lies close beneath the epithelium. Other branches are given off within the submucous layer and provide the capillary supply for the numerous glands. The **lymphatics** are well represented throughout the greater part of the laryngeal mucous membrane, especially in the region of the ventricle and false vocal folds. Over the true cords, however, they are very feebly developed, but below them the lymphatics are again numerous. Where abundant, the lymph-channels are present within the mucosa as a superficial and a deeper network, which communicate and pass to the cervical lymph-nodes.

The **nerves** supplying the larynx are chiefly from the vagi, intermingled with fibres from the sympathetic. They consist, therefore, of medullated and nonmedullated fibres, groups of ganglion-cells occurring along the course of the sympathetic fibres. The latter are destined for the blood-vessels and glandular tissue. The muscles being of the striated variety are supplied by fibres bearing motor end-plates. The sensory fibres are distributed principally to the mucous membrane, in which they form plexuses. From the latter nonmedullated fibres pass towards the free surface to terminate either in sub-epithelial end-arborizations, bearing enlargements or end-bulbs, or in intra-epithelial filaments ending free between the cells. Special end-organs have been described as existing within the true vocal cords.

### THE TRACHEA AND BRONCHI.

Beginning at the lower border of the cricoid cartilage, the trachea or windpipe extends into the thorax, a distance of some 10–12 cm., and divides into two bronchi, one proceeding downwards and outwards into each lung.

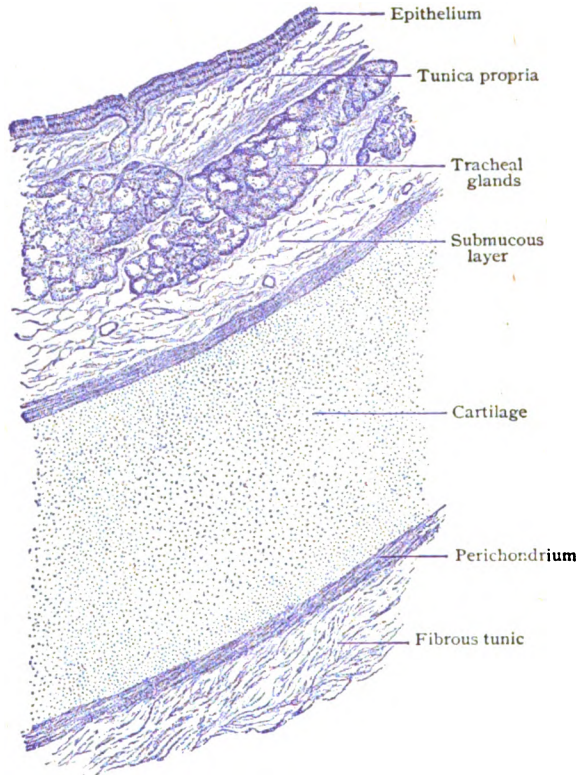


FIG. 235.—Transverse section of trachea, showing general arrangement of the coats.  $\times 80$ .

Until the latter is reached, the walls of the air-tubes are constant in structure and consist essentially of a fibro-cartilaginous framework, lined with mucous membrane and covered externally with areolar tissue.

The **cartilage** is represented by a series of from sixteen to twenty C-shaped pieces, of the hyaline variety and from 2–5 mm. in width, which

are united with one another by a fibro-elastic sheath continuous with the perichondrium of the segments. This membrane likewise connects the ends of the "rings," as the pieces are called, and thus completes the tube behind, where otherwise the framework of the posterior wall of the trachea and bronchi would be deficient. In order to maintain the proper tonicity of the fibro-cartilaginous tube, especially of its membranous portion, bundles of unstriated muscle, the *trachealis muscle*, lie between the ends of the cartilages. In the main these bundles are disposed circularly, connecting the ends of the rings, but some run longitudinally.

The **mucous membrane**, smooth and attached with considerable firmness to the cartilages by the submucous tissue, but looser and thrown into longitudinal folds over the posterior wall, is clothed with stratified ciliated columnar *epithelium*. Many of the surface cells contain mucus and are of the goblet variety. The *tunica propria* is rich in elastic fibres and contains numerous lymphoid cells, which are so abundant in places, particularly around the openings of the tracheal glands, as to suggest lymph-nodules. The **submucous layer**, composed of fibro-elastic tissue, lodges, in addition to the larger blood-vessels and lymphatics, the *tracheo-bronchial glands*. These occur as considerable masses (Fig. 236) and belong to the mixed mucous tubo-alveolar type. Their ducts pierce the tunica propria and open on the free surface by minute funnel-like depressions in the epithelium. The blood-vessels, lymphatics and nerves follow essentially the same plan of distribution as described in connection with the larynx.

## THE LUNGS.

In their mode of development and architecture, the lungs resemble compound alveolar or saccular glands, the repeatedly subdividing air-tubes (the bronchioles) representing the duct-system of a gland and the ultimate compartments of the respiratory tissue (the alveoli) corresponding to the glandular alveoli. Instead of being almost filled with secreting cells, however, after birth the pulmonary alveoli are distended with air and the cells reduced in thickness to endothelium-like plates.

**The Lobule and Lung-Units.**—The surface of the lung (Fig. 237) is marked with small polygonal areas, 10–25 mm. in diameter, which are defined by lines of connective tissue, often darkened by pigment. These areas are the bases of pyramidal masses of pulmonary tissue, the **lobules**, each of which is entered by and surrounds a minute air-tube, *intralobular bronchiole*, from .5–1 mm. in diameter, accompanied by a branch of the pulmonary artery. The bronchiole enters the lobule near, but not quite at, its apex and divides into two a little above the middle of the lobule, having previously given off two or three collateral branches to its upper part. In the third quarter of the lobule, the two branches subdivide in a plane at right-angles to the preceding splitting. Such division is repeated in three or four successive bifurcations, a varying number of collaterals being given

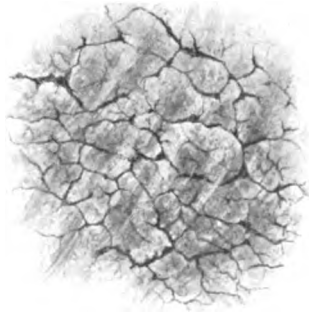

FIG. 237.—External surface of lung, showing polygonal areas, corresponding to the lobules, mapped out by pigment within the connective tissue.

off in addition. Although the number of branches of the air-tubules is much increased in the third quarter, it is in the last one and towards the periphery of the lobule throughout, that the tubules break up into a profusion (50-100) of truly *terminal bronchioles*. Each terminal bronchiole

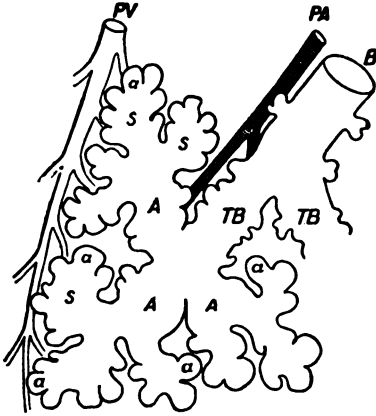


FIG. 238.—Diagram illustrating relations of terminal divisions of air-tubes. *B*, bronchiole ending in terminal bronchi (*TB*); latter divide into atria (*A*), each of which communicates with several air-sacs (*s*) into which open the alveoli (*a*); *PA*, branch of pulmonary artery following bronchiole; *PV*, pulmonary vein at periphery of lung-unit. (Miller.)

communicates by its slightly dilated distal extremity with from three to six spherical cavities, the *atria*, each of which, in turn, communicates with a group of larger irregular cavities, the *alveolar sacs*, into which directly open the ultimate air-spaces, the *pulmonary alveoli*. The latter open not only into the alveolar sacs but also into the atria and even the distal part of the terminal bronchiole, which is beset with scattered alveoli. The mass of pulmonary tissue connected with each terminal bronchiole, including the air-spaces and accompanying blood-vessels and nerves, constitutes a *lung-unit*, by the aggregation of which the lobule is formed. The lobules are separated by distinct tracts of interlobular connective tissue, in which the air-tubes and accompanying blood-vessels course until they enter the lobules.

**The Bronchioles.**—After the bronchus begins to give off branches gradually decrease in size and thickness until replaced by irregular angular plates, which appear at increasingly longer intervals until they finally cease, cartilage being seldom present in bronchioles of less than 1 mm. in diameter. As the cartilage tends to disappear, the unstriped muscle broadens into a continuous layer, which, in turn, becomes thinner as the air-tube diminishes and extends only as far as the terminal bronchioles. The muscle is arranged as a sphincter-like band around the openings by which the terminal bronchioles communicate with the atria.

The walls of bronchioles of medium size (2-3 mm.) consist of three coats, which from without in are: (1) an external *fibrous tunic*, composed of fibro-elastic tissue, which encloses the cartilage (often elastic in type) and accompanying blood-vessels and blends with the adjoining lung-tissue; (2) a thin layer of *unstriped muscle*, sometimes incomplete and composed of circularly disposed bundles; and (3) the *mucous membrane*, thrown into longitudinal folds and consisting of ciliated columnar epithelium, with numerous goblet-cells, and a tunica propria made up chiefly of meshes of elastic

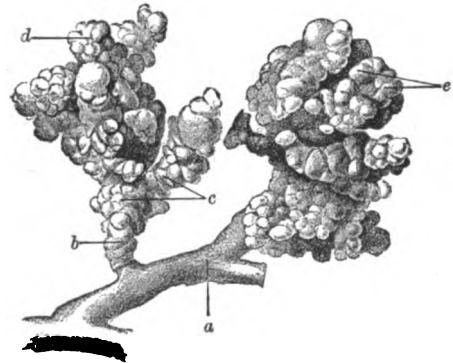


FIG. 239.—Corrosion-preparation of lung, showing lung-units; *a*, minute bronchus ending in terminal bronchi (*b*); *c*, atria; *d*, air-sacs; *e*, alveoli.  $\times 8$ .



fibres and intervening lymphoid cells. As in the trachea and the bronchi, the current produced by the cilia is directed centrally, and thus tends to

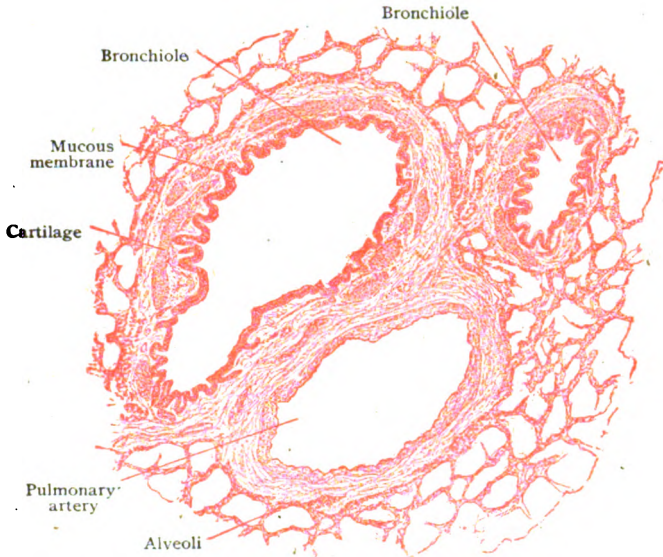


FIG. 240.—Section of lung, showing small air-tubes and branch of pulmonary artery.  $\times 35$ .

carry mucus and particles of dust from the smaller tubes towards the bronchi and trachea. Mucous glands, similar to those of the trachea, are present in decreasing number and size until the bronchiole attains a diameter of 1 mm., after which they usually disappear. Their chief location is outside the muscle, which is pierced by the ducts on their journey to gain the free surface where they open in minute depressions within the epithelium. In addition to the lymphoid cells diffused through the mucosa, more definite aggregations occur as minute lymph-nodules along the bronchi, the points of bifurcation being their favorite seats. The epithelium lining the air-tubes retains the ciliated columnar type as far as the smaller bronchioles. Within the latter the ciliated cells are replaced by simple columnar elements, which, in turn, give way to low cuboidal cells within the proximal part of the terminal

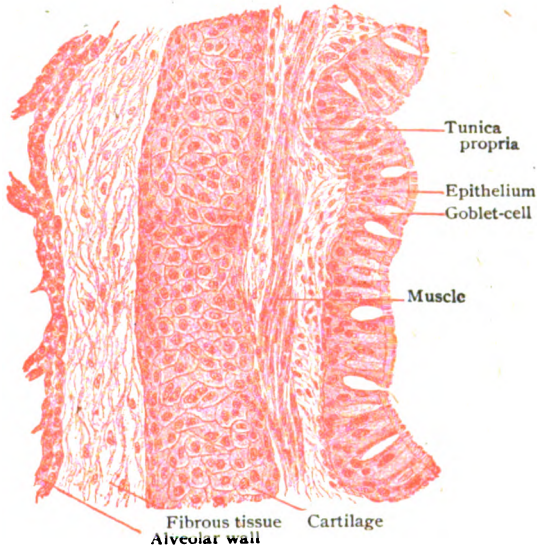


FIG. 241.—Portion of wall of small bronchus.  $\times 180$ .

bronchioles. Towards the distal ends of the latter partial transition into patches of simple squamous epithelium occurs, these tubules containing, therefore, both cuboidal and plate-like cells.

**The Air-Spaces.**—The walls of the air-spaces—the atria, the alveolar sacs and the pulmonary alveoli—have essentially the same structure and consist of a delicate fibro-elastic framework supporting the blood-vessels and the epithelium. The latter, the *respiratory epithelium*, is made up of a single layer of polygonal plates, mostly without nuclei, and includes groups of large and small cells. The number of the smaller cells, as seen in silvered preparations of adult lung (Fig. 243), progressively decreases towards the alveoli, in which they are reduced to small groups of isolated elements surrounded by the larger plates. In the fœtus and in the still-born child, the alveoli are lined entirely by low cuboidal cells; after inflation of the lung-

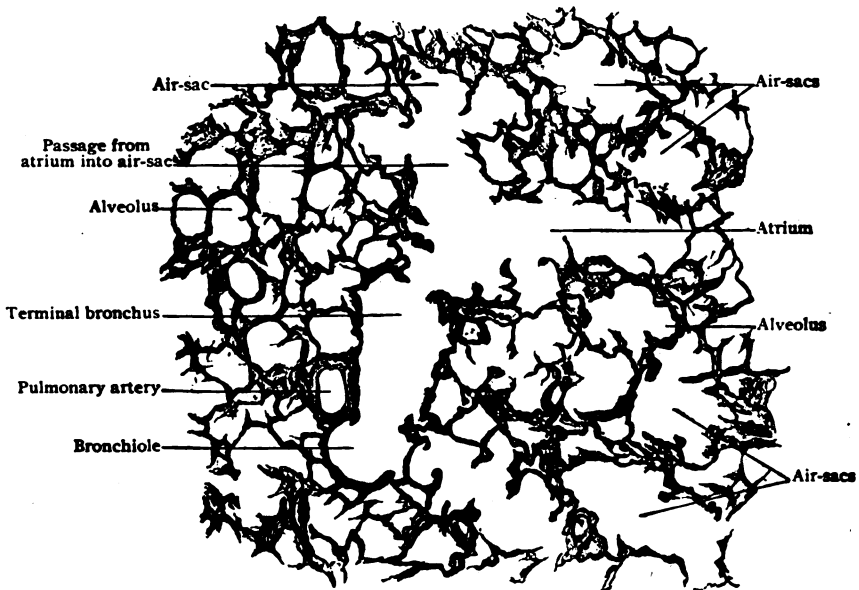


FIG. 242.—Section of lung, showing relations of terminal divisions of air-tubes.  $\times 50$ .

tissue has been completed, the cuboidal cells become expanded into the small plates. The larger plates arise by the subsequent fusion of several of the small ones, groups of the latter, which retain their independence, appearing, in decreasing numbers as age advances, as the islands of one or more small cells.

The **framework** of the pulmonary alveoli is almost exclusively elastic fibres that are condensed into rings around the openings or bases of the alveoli and elsewhere enclose the spaces with elastic networks. Where these rings come into contact and fuse, the alveoli are separated by partitions of some thickness; beyond these septa the walls between the adjoining air-spaces are very thin and include the two layers of epithelial plates and the dense capillary network supported by the elastic reticulum. Owing to the elastic character of their walls, the alveoli expand during inspiration to two or three times their usual diameter (.1–.3 mm.), the lining epithelial plates and the blood-vessels stretching to the necessary degree. The *capillary networks*

surrounding the alveoli are in many places common to the opposed spaces belonging to the same unit. These networks, the terminations of the pulmonary artery and the beginnings of the pulmonary veins, possess exceedingly small meshes, the distance between the capillaries often being less than the diameter of the vessels. The latter, not confined to one plane but sinuous, are excluded from the interior of the alveoli by practically only the thin layer of respiratory epithelium, an arrangement manifestly advantageous in effecting the interchange between the carbon dioxide of the venous blood and the oxygen of the inspired air.

Although preformed openings or stomata do not exist between the alveolar epithelial elements, particles of foreign materials pass through the wall of the air-spaces and eventually into the interlobular connective

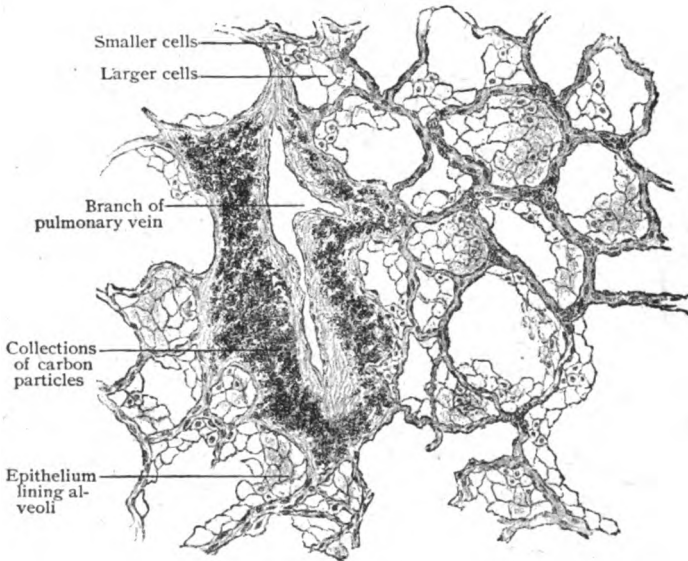


FIG. 243.—Section of lung, showing alveolar epithelium and collections of colored particles in connective tissue.  $\times 140$ .

tissue, where they accumulate as the more or less conspicuous collections of pigment which aid in defining the outlines of the lobules. A certain amount of such pigmentation is always found in adult lungs and may be regarded as normal; when, however, individuals are subjected to an atmosphere unduly laden with colored particles, as coal dust, the pulmonary tissues may be so filled with pigment as to be in places almost black. It is probable that the migratory leucocytes are an important means of transporting the colored particles from the alveoli into the connective tissues.

The **blood-vessels** of the lung, as those of the liver, include two sets, one for the function of the organ, the other for the nutrition of its tissues. The former are the branches of the pulmonary artery and veins; the latter are the bronchial vessels. The nutrient arteries arise from the aorta, not directly from the heart. The branches of the *pulmonary artery* follow closely the ramifications of the air-tubes, entering the lobules near their apices, along with the intralobular bronchioles, and finally breaking up into the close capillary networks in the walls of the alveoli. From these networks

arise the radicles of the *pulmonary veins* which carry away the oxygen-renewed blood. These vessels, however, do not immediately join the arteries, but, running first on the outside of the lung-units, unite with others and then emerge at the periphery of the lobules and run in the interlobular connective tissue, later meeting the interlobular parts of the arteries and bronchi which they thence accompany to the hilum of the lung. At the surface, where the pulmonary tissue is in contact with the overlying serous membrane, twigs from the pulmonary artery communicate with the pleural capillaries. The *bronchial arteries*, the nutrient vessels of the lungs, supply the walls of the air-tubes as far as the terminal bronchioles, as well as the walls of the branches of the pulmonary artery and veins, the bronchial lymph-nodes and the visceral pleura. Within the walls of the bronchial tubes they form a deeper capillary network for the muscle and glands and a superficial one for the tunica propria. The

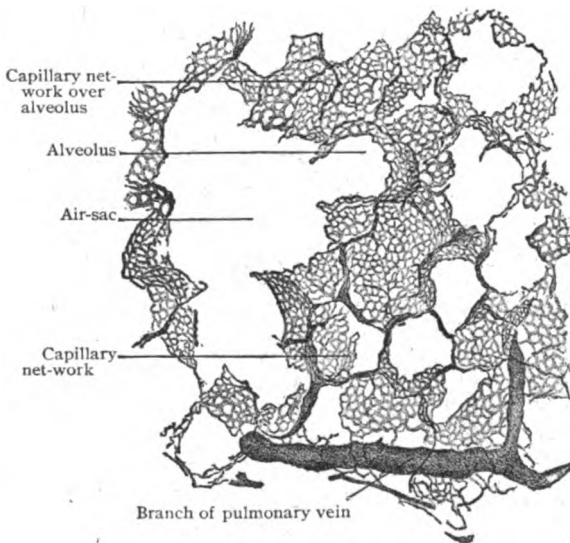


FIG. 244.—Section of injected and inflated lung.  $\times 80$ .

bules definite lymphatics first appear. The superficial vessels are connected with small uncertain subserous lymph-nodes, subsequently joining the interlobular trunks, which ultimately are efferent to the larger nodes situated in the hilum and roots of the lungs. The pulmonary lymph-nodes are deeply pigmented owing to the accumulation of inspired colored particles. Where cartilage exists, the plates are enclosed by double networks of lymphatics, the inner one lying within the submucosa.

The *nerves* of the lungs, from the vagi and sympathetics, are numerous and include both medullated and nonmedullated fibres. The latter are associated with minute groups of ganglion-cells along their course and are destined chiefly for the walls of the blood-vessels and of the air-tubes, some fibres finding their way into the interalveolar septa. Free terminal filaments within the tunica propria and between the epithelial cells are described as sensory endings in the mucous membrane of the air-tubes.

**The Pleuræ.**—The pleuræ, the serous membranes lining the cavities containing the lungs and covering the latter except at the roots, where enter the bronchi and the blood-vessels, in structure closely resemble other serous

the tunica propria. The *bronchial veins* are tributary for the most part to the pulmonary veins; to a small extent, however, blood passes from them into the azygos system. Both the bronchial arteries and veins communicate with the pulmonary vessels at many points.

The *lymphatics* include a superficial network, well developed and beneath the pleura, and a deep interlobular plexus surrounding the bronchi. The deep ones probably begin as lymph-spaces distal to the terminal bronchioles, around which tu-

membranes. The visceral pleura consists of a *stroma-layer*, composed of fibrous tissue intermingled with an abundance of elastic fibres, and a single surface layer of *mesothelial plates*. The existence of definite openings or stomata between these cells is doubtful.

The parietal pleura possesses a like structure, but is less rich in elastic fibres. The *subserous layer* is scanty over the lung, where it is continuous with the interlobular connective tissue; over the mediastinum it is firm and dense and on the costal wall acquires the character of a fascia, which is particularly dense beneath the apical pleura.

The **blood-vessels** supplying the visceral pleura are derivations of the pulmonary trunks; those of the parietal pleura are from various adjacent systemic branches. In neither case is the ultimate distribution a generous one, the twigs being small and the capillaries comparatively few. The **lymphatics** are most abundant over the lungs and the intercostal spaces, where they form meshworks within the stroma and the subserous tissue. The **nerves** of the visceral pleura include fibres from the vagi and sympathetics by way of the pulmonary plexuses. Those of the parietal pleura receive fibres from the intercostal and phrenic nerves and, additionally, some from the vagi and the sympathetics. Many of the sensory fibres are connected with special end-organs, as the Pacinian and Golgi-Mazzonian corpuscles, while others terminate in free varicose endings.

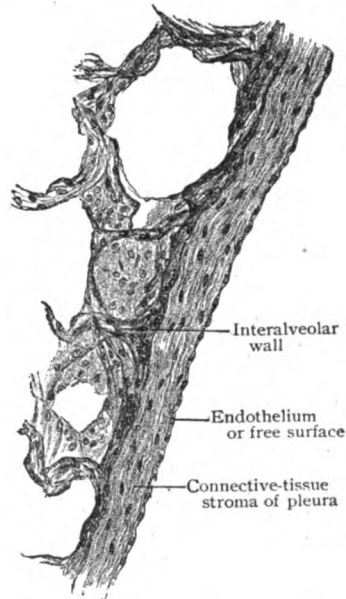


FIG. 245.—Section through free edge of lung, showing visceral pleura.  $\times 150$ .

Solely as a matter of convenience, in view of their contiguity, the Thyroid, Parathyroid and Thymus Bodies may be described in connection with the respiratory tract. It must be clearly understood, however, that these organs have neither morphological nor functional relations with the organs of respiration; they are, probably, to be regarded as accessory organs of nutrition.

### THE THYROID BODY.

The thyroid body is developed from an unpaired median rudiment. This median rudiment or anlage is an entodermic epithelial outgrowth from the anterior wall of the primitive pharynx, in the region of the second visceral arch and in close relation with the posterior part of the tongue. The position of this outgrowth is later indicated by a depression on the tongue, the foramen cæcum, just behind the apex of the row of circumvallate papillæ. The lateral outgrowths from the ventral wall of the fourth pharyngeal furrow do not take part in forming the thyroid, as formerly supposed, but usually disappear. The true anlage grows ventrally and subsequently forms the definite thyroid surrounding the respiratory tube. The histogenesis of the organ includes: (a) numerous cylindrical epithelial cords from which grow out lateral branches; (b) fusion of these cords into a network whose

meshes are filled with vascular mesodermic tissue; (*c*) severance of the epithelial reticulum into masses corresponding to the later follicles; (*d*) the appearance within these masses of lumina, around which the cells become arranged as the epithelial lining of the compartments subsequently containing the characteristic colloid substance. The thyroid body agrees with the parathyroids and the thymus in arising from the walls of the primitive pharynx and in deviating during its later development from its original likeness to a typical gland.

The thyroid body is situated in the neck, in front and at the sides of the upper end of the trachea, and consists of two *lateral lobes* connected by a narrow strip, the *isthmus*. Although during its early development cor-

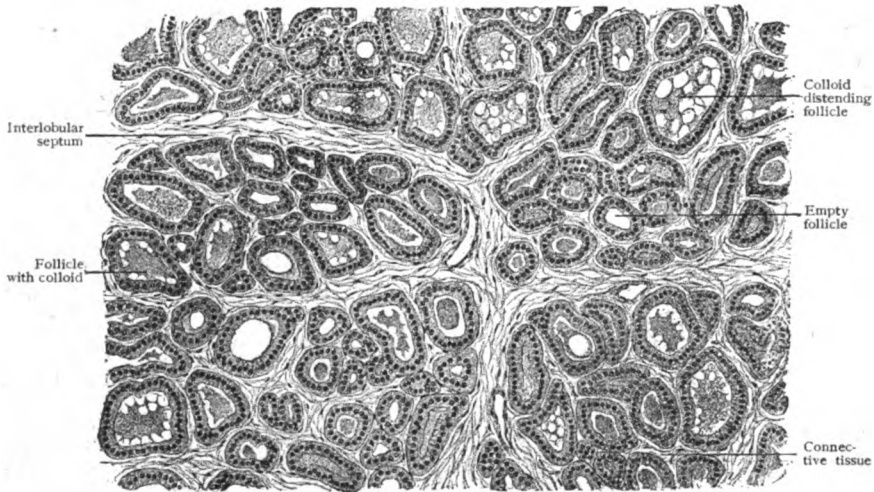


FIG. 246.—Section of thyroid body, showing follicles in various degrees of distention.  $\times 100$ .

responding in principle with compound alveolar glands, the fully formed thyroid body possesses no excretory ducts and varies in the details of its terminal compartments. The fibro-elastic *capsule* investing the organ gives off septa which subdivide the lobes into a number of tracts, each composed of smaller masses, the *primary lobules*, separated by thin partitions of connective tissue. These subdivisions (.5–1 mm. in diameter) contain a variable but usually large number of *follicles*, which correspond to the alveoli of ordinary glands and are supported by a highly vascular fibro-elastic framework.

The **follicles**, ellipsoidal or cylindrical sacs, vary greatly in size (50–200  $\mu$ ), depending upon the amount of the contained secretion and distention. They are lined by a single layer of fairly regular epithelial cells, usually cuboidal, although they may approach the columnar or flattened type. Their spherical nuclei are surrounded by clear cytoplasm, which often contains granules of a fatty nature. The epithelial cells are the source of the peculiar soft gelatinous material, the *colloid substance*, that fills and distends to a variable degree the follicles. Some of the latter may appear very small and tubular and contain no secretion, while the neighboring follicles are enormously distended with masses of colloid. As usually seen in sections, the colloid substance is homogeneous or finely granular and often partly detached from the lining cells by shrinkage. Vacuoles are also

common and contain materials of a mucous or fatty nature. Large granular elements, *interstitial cells*, occur within the connective tissue between the follicles.

The **blood-vessels** supplying the thyroid tissue are unusually plentiful, the interlobular arteries, branches from the superior and inferior thyroids, breaking up into close networks that surround the follicles and lie immediately beneath the epithelium. The **lymphatics**, also abundant, begin as perifollicular lymph-spaces, from which are formed the interlobular lymphatics accompanying the blood-vessels. The deeper lymphatics join the superficial plexus, on the surface of the organ, from which the larger trunks

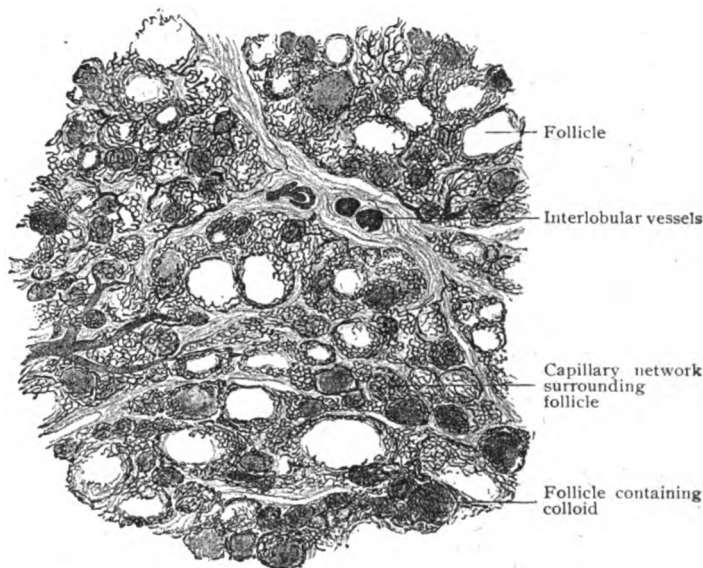


FIG. 247.—Section of injected body, showing rich capillary networks surrounding follicles.  $\times 46$ .

pass in different directions. The **nerves** are, for the most part, sympathetic fibres supplying the walls of the blood-vessels and enclosing the follicles in plexuses of nonmedullated filaments, which end in close relation with the epithelial cells.

### THE PARATHYROID BODIES.

These little organs, also called the *epithelial bodies*, when typically present are arranged as two pairs, an upper and a lower. The upper ones are the more constant and usually lie against the posterior surface of the lateral thyroid lobes. The inferior bodies are less constant, both as to position and presence, sometimes lying against the side of the trachea under cover of the lower part of the thyroid lobes, or upon the latter, and at other times being placed entirely below the thyroid. The disposition of the parathyroids may be asymmetrical, in some cases as many as four, in others none, lying on one side. The bodies are 6–7 mm. long, 3–4 mm. broad, and 1.5–2 mm. thick, but may be larger or smaller. They arise from the dorsal wall of the third and fourth pharyngeal furrows and thus differ from the thyroid body in origin, as well as structure.

Each organ is invested by a thin fibro-elastic *capsule* and subdivided into uncertain *lobules* by delicate septa, which support the larger blood-

vessels. The distinctive tissue consists of closely placed polygonal *epithelial cells* ( $10\ \mu$  in diameter), disposed as continuous masses or as imperfectly separated cords and alveoli. The cells have round nuclei and are lodged within a reticulum composed of wide capillaries and delicate strands of fibro-

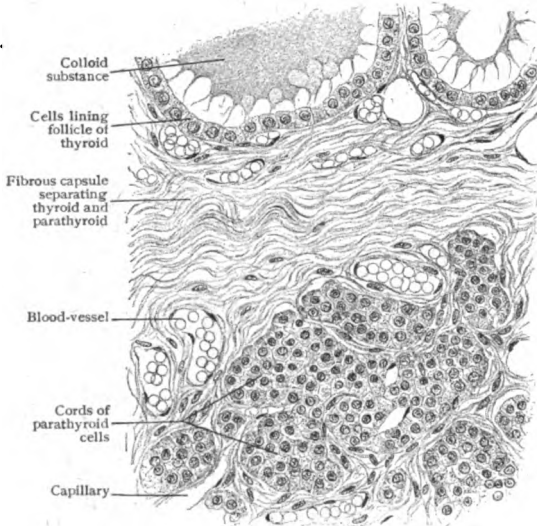


FIG. 248.—Section including adjacent portions of human thyroid (above) and parathyroid (below).  $\times 220$ .

elastic tissue, the whole often bearing a striking likeness to the anterior lobe of the pituitary body (page 309), even to the presence of colloid substance within some of the alveoli. When the cell-masses tend towards the alveolar type, the epithelium and the blood-channels are in intimate relation, an arrangement probably facilitating the distribution of the particular product of the cells. The significance of the parathyroid bodies as distinct organs, and not as merely masses of modified thyroid tissue, has been established by both anatomical and physiological investigations; like the

thyroid, they are "ductless glands" and organs of internal secretion. The *blood-vessels* supplying the organs are the minute parathyroid arteries, usually from the branches of the inferior thyroid, to each one of which a body is attached. The capillaries are relatively wide and ramify between the nests of cells. Little is known concerning the *lymphatics* and *nerves*; the latter, however, are chiefly sympathetic fibres for the walls of the blood-vessels.

### THE THYMUS BODY.

Although actually increasing in size and weight until towards puberty, the thymus body is essentially an organ of very early childhood, attaining its highest development about the second year. At that time it stretches from the root of the neck downwards into the thorax, behind the sternum and over and in front of the pericardium, to about the line of the fourth costal cartilage. It is thickest above and descends as two flattened irregular lobes, separated by fibrous tissue, of which the left one is more often the larger. Subsequently more or less extensive atrophy and replacement of the thymus-tissue occurs, variable islands of the latter surrounded and invaded by fat-cells being the usual condition of adolescence. Notwithstanding this replacement by adipose and connective tissue, the thymus never entirely disappears, remains of its tissue being present even in extreme old age.

The thymus body develops from paired epithelial outgrowths from the ventral wall of the third pharyngeal furrows. From these result long cylindrical masses of closely packed epithelial cells, which grow downwards and for a time enclose a lumen that later disappears. The masses increase by solid outgrowths, resembling those of an immature tubo-alveolar gland, so



that by the middle of foetal life the organ has acquired a lobulated structure, a condition intensified by the ingrowth of vascular mesodermic tissue. Meanwhile, the original closely packed epithelial elements undergo marked change, most being converted into stellate cells that form a reticulum. From other cells arise by repeated division a profusion of very small cells that fill the meshes of the reticulum produced by the transformation just mentioned. The genetic relation of the small cells to the original entodermic epithelium is still disputed. According to Stöhr, Bell and others, they arise from the epithelial elements; according to Hammar and others, they are mesodermic cells that early enter the thymus and correspond to

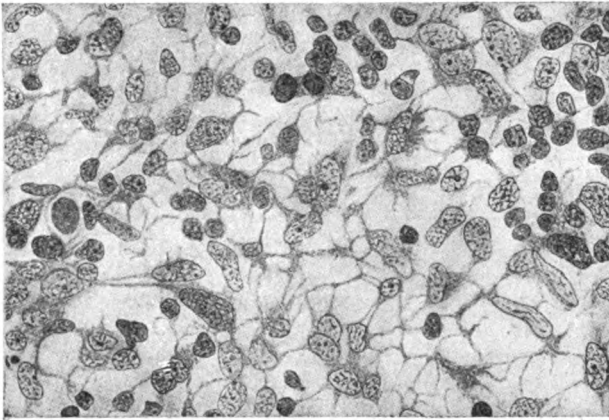


FIG. 249.—Section of developing thymus from human foetus of third month; among the stellate reticulum-cells are seen the small thymic lymphocytes.  $\times 690$ . (Hammar.)

true lymphocytes. All are agreed, however, that the “small cells”—the thymic lymphocytes—closely resemble morphologically the ordinary lymphocytes.

The thymus is invested by a loose fibro-elastic *capsule*, from which septa, rich in blood-vessels and lymphatics, pass inwards and subdivide the organ into a number of indefinite *lobes*. The latter are broken up by partial partitions into *lobules*, in which a denser peripheral tract, the *cortex*, and a lighter central one, the *medulla*, can be distinguished, although these divisions are often not sharply defined. The thymus possesses no duct-system and, hence, is often classed as a “ductless gland.”

The *cortex* consists of closely packed *small cells* (7–10  $\mu$  in diameter), whose cytoplasm is so meagre that the deeply staining nuclei are their most evident parts. The small cells are supported by a delicate meshwork formed by the stellate *reticulum-cells*. Numerous capillary blood-vessels, with accompanying scanty strands of fibrous tissue, are intermingled with the cortical elements. The *medulla* is of looser texture and contains, in addition to the small and reticulum-cells, much larger epithelial cells, either singly or in limited groups and cords.

The most distinctive feature of the medulla—and, indeed, of the entire organ, which otherwise bears a general resemblance to lymphoid tissue—is the presence of the irregularly spherical or elongated **thymic bodies, or corpuscles of Hassall**, which appear as small lighter areas scattered throughout the medulla. They first appear about the middle of foetal life and

increase in number and size until, at the end of the first year, they are plentiful and may attain a diameter of from .2-.3 mm., although usually they measure

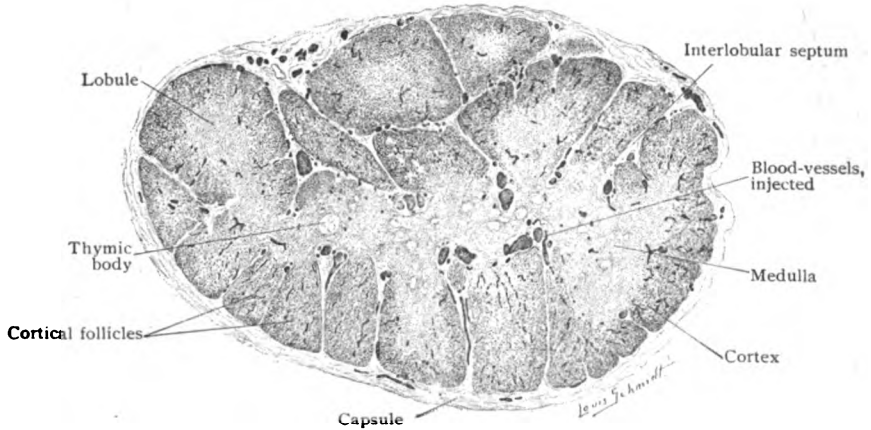


FIG. 250.—Transverse section of lobe of thymus body of child, showing general arrangement of lobules.  $\times 20$ .

much less ( $40-60 \mu$ ). These bodies, present only in the medulla, are composed of large concentrically disposed epithelial elements, which, flattened

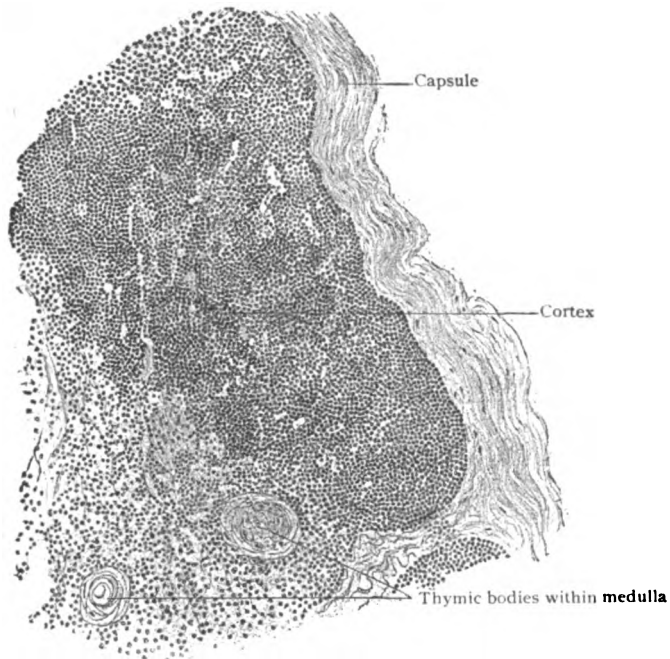


FIG. 251.—Section of thymus, showing details of cortical and medullary substance.  $\times 200$ .

and connected with the reticulum-cells at the periphery of the corpuscle, at its centre exhibit evidences of degeneration, such as nuclei poor in chromatin or disappearing, breaking down of cytoplasm or invasion of the cells by

leucocytes. The centres of the bodies may enclose vacuoles containing fat, or mucus-reacting or colloid substance—the latter by some being regarded as representing the special production of the organ.

The significance and genetic relations of the thymic bodies have long been the subject of discussion. Formerly they were regarded as the remains of the original epithelial elements of the organ, all other parts being the products of the invading mesoderm. In the light of present embryological data, it is probable that the corpuscles result from the aggregation of hypertrophied and otherwise modified reticulum-cells and, therefore, that they are new and special formations, distinctive of the organ, and not merely the atrophic remains of the original epithelial elements. It is evident, however, that they are indirectly, through the reticulum-cells, derivatives of the primary epithelium. Since new corpuscles are being continually formed and those existing increase in size, during the active period of the thymus, it is possible that they are concerned in producing a substance serving some particular purpose during early life.

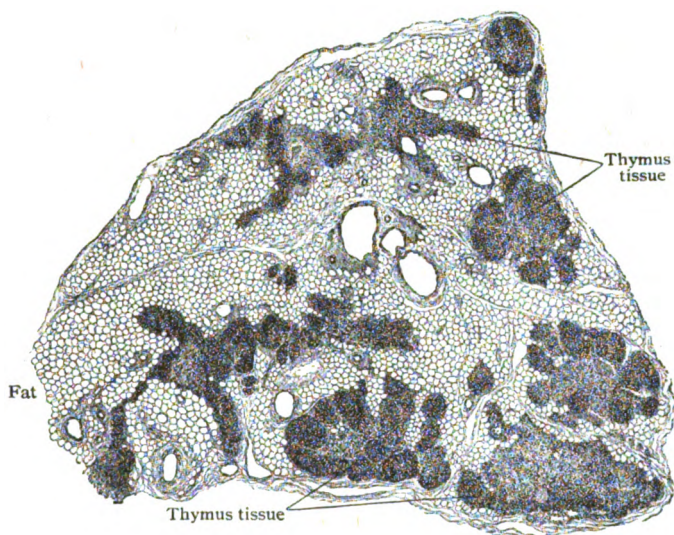


FIG. 252.—Section of thymus body of man of twenty-eight, showing invasion and replacement of thymus-tissue by fat.  $\times 20$ .

The assumed importance of the thymus as the producer of the first lymphocytes, credited to the organ by some, is doubtful. There is no convincing evidence that the thymus is the seat of red blood-cell formation after birth.

In addition to numerous capillaries, leucocytes and eosinophiles are present among the constituents of the medulla. As age advances, the small cells become less numerous and the cortex markedly diminishes in thickness, so that the medullary substance comes into relation with the surrounding vascular interlobular connective tissue with increasing frequency and extent. At a variable time, in some cases before the second year and in others not until much later, an active general regression and atrophy of the thymus becomes established. The general process, however, is often antedated by reduction in the thymus, probably associated with impaired nutrition, whereby the number of the small lymphoid cells is greatly decreased and the distinction between cortex and medulla disappears. The medulla is the seat of occasional small cysts, of uncertain form and size, lined with epithelial elements that often bear groups of cilia-like processes.

Coincident with the atrophy of the thymus-tissue, fat-cells progressively appear in the interlobular tracts, which latter, in consequence, become in-

creasingly more voluminous, with separation of and encroachment upon the diminishing thymic tissue. Gradually the latter is replaced by the adipose tissue, until only isolated islands of the characteristic thymus-tissue remain (Fig. 252). Complete disappearance of this structure, however, is very exceptional, even in advanced age a certain amount of it being recognizable upon microscopical examination.

The **blood-vessels** distributed to the thymus send their twigs into the organ in such manner, that these lie at the junction of the cortex and medulla (Fig. 250). Capillaries thence proceed to the cortex and medulla, those within the former being more abundant than those distributed to the medulla. The venous radicles begin in the thymus-stroma, some passing through the medulla while others become more directly tributaries of the interlobular veins. The **lymphatics** are numerous and represented by networks of lymph-spaces close to the periphery of the lobules, from which are formed the more definite interlobular lymphatic vessels, that in turn drain into the large efferent trunks. The existence of intralobular passages, corresponding to lymph-sinuses, has not been established. The **nerves** are small and are derived from the sympathetic and the vagus. The fibres are traceable along the interlobular septa, in company with the blood-vessels, to whose walls they are chiefly distributed. A very meagre number of nonmedullated fibres have been described as terminating within the medulla as free endings.

## THE URINARY ORGANS.

THESE organs include the *kidneys*, the glands which secrete the urine, the *ureters*, the canals which collect the urine and convey it from the kidneys to the *bladder*, the receptacle in which the urine is temporarily stored, and the *urethra*, the passage through which the urine is discharged.

### THE KIDNEYS.

The kidneys are two flattened ovoid glands, of peculiar bean-shaped form, deeply placed within the abdominal cavity against its posterior walls, one on each side of the lumbar spine. They are invested by a thin *fibrous capsule*, which is distinct from the renal tissue that it covers and is exposed only after its removal. The mesial border of each kidney is interrupted by a slit-like opening, the *hilum*, which leads into a more extended but flattened space, the *sinus*, enclosed by the surrounding substance of the kidney. In addition to the blood-vessels, lymphatics, and nerves passing to and from the kidney through the hilum, the sinus contains the upper expanded end of the ureter, which also emerges at the hilum. The interspaces between these structures are filled with loose fatty areolar tissue.

**Architecture of the Kidney.**—Before describing its histological details, it will be of advantage to consider the general plan upon which the kidney is built—its architecture as contrasted with its structure. The entire organ—a conspicuous example of a compound tubular gland—is made up of a number of divisions which in the mature condition are so closely blended as to give little evidence of the striking subdivision or lobulation of the foetal kidney. The external surface of the latter (Fig. 253) is broken up by furrows into a number of polygonal areas, each of which represents the base of a pyramidal mass of renal substance, the *kidney lobe*, separated from its neighbors by connective tissue. It includes the entire thickness of the organ, between the exterior and the sinus, and ends internally in a conical apical projection, the *renal papilla*. Shortly after birth, the lobulation gradually disappears on the surface, which becomes smooth, the interlobar connective tissue septa within the organ likewise disappearing, while the papillæ alone remain as indications of the original subdivisions. Although the outlines of the lobes occasionally persist on the surface of the adult human kidney, in many of the lower animals (reptiles, birds, ruminants, cetaceans and certain carnivora) the subdivisions are normally retained. In some mammals (rodents and insectivora) the entire kidney corresponds to a single papilla, while in others (elephant and horse) no distinct papillæ exist.

On examining the cut surface of the kidney, opened by a longitudinal section passing from the convex border through the sinus (Fig. 254), the papillæ are seen to form the free apices of conical areas, the *renal pyramids*, whose bases lie embedded within the surrounding kidney-substance composing the outer third of the organ. This peripheral zone, which in the fresh kidney appears darker and granular when compared with the lighter and



FIG. 253.—Kidney of new-born child, showing areas on surface corresponding to primary lobes.

striated renal pyramid, is the *cortex*. The *medulla* includes the conical areas of the pyramids and partially occupies the inner two thirds of the thickness of the organ. The cortex constitutes the bulk of the kidney, forming the entire surface, including the lips of the hilum, and receiving and surrounding the bases of the pyramids. The cortical tissue, further, penetrates between the pyramids, separating them and in places gaining the sinus. These interpyramidal extensions are the *renal columns*, or *columns of Bertin*, and consist of typical cortical substance. Since the branches of the renal blood-vessels lie within the interlobar connective tissue separating the primary subdivisions of the foetal organ, these vessels never enter the kidney-substance by passing into the papillæ, but always at the side of and

between these. They sink into the renal substance, therefore, through the areas occupied by the renal columns, the free surfaces of which are pitted by the vascular foramina.

On inspection with a hand-glass, it will be seen that the cortex is not uniform, but subdivided into radially disposed darker and lighter tracts. The latter, longitudinally striated and wedge-shaped, are the *medullary rays*, or *pars radiata*, since they are apparently continuations of the medullary tissue. The darker tracts, between the medullary rays, constitute the *labyrinth*, or *pars convoluta*, and appear granular owing to the tortuous course of the component uriniferous tubules. The labyrinth

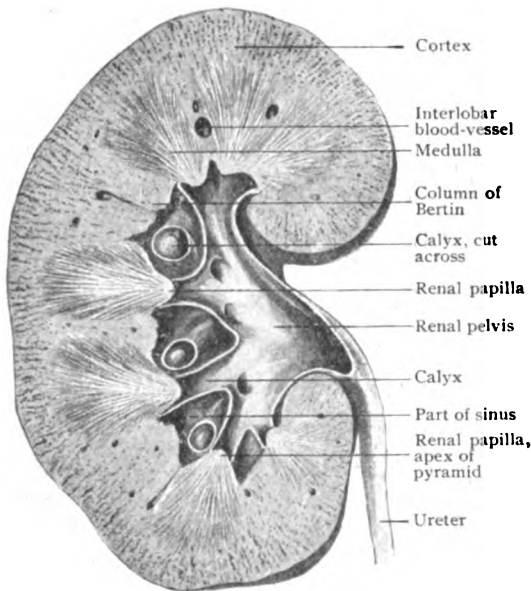


FIG. 254.—Longitudinal section of kidney, showing divisions of renal substance and relations of pelvis and calyces.

is studded with bright red points marking the position of minute vascular tufts or *glomeruli*; these are limited to the labyrinth and, therefore, never present within the medullary rays or the renal pyramids, although found within the columns of Bertin.

On sectioning minutely injected organs, it will be observed that the larger interlobar arteries, on gaining the boundary zone between the cortex and the medulla, break up into smaller branches, some of which pass towards the surface, while others change their direction and assume a more horizontal course. The terminal twigs—"end-arteries," since anastomoses are wanting—run generally perpendicular to the exterior of the kidney and occupy the centres of the tracts separating the medullary rays. The latter are, therefore, the axes of minute conical masses of renal substance, the *cortical lobules*, whose bases lie at the surface of the kidney and the apices within the pyramids of the medulla. From the foregoing it is evident that each renal pyramid receives a group of cortical lobules, the component tubules of which, on entering the pyramid, become progressively less

numerous but larger, in consequence of repeated union, until, as the wide *papillary ducts*, they end at the summit of the renal papilla.

**The Kidney-Substance.**—The fundamental components of the vertebrate excretory organ, both in the foetal and mature condition, include: (1) a tuft of arterial capillaries derived more or less directly from the aorta; (2) tubules lined with secretory epithelium; and (3) a duct for conveying the excretory products.

These constituents are represented in the kidney of man and the higher animals by: (1) the *glomerulus*, (2) the convoluted *uriniferous tubules*, and (3) the collecting tubules and the ureter composing the *duct-system*. Since, in a general way, to the epithelium may be ascribed the function of taking from the circulation the more solid constituents of the urine, and to the glomerulus the secretion of the watery parts, obviously the most favorable arrangement to secure the removal of the excretory products is one insuring flushing of the entire tubule with the fluid secreted by the glomerulus. Such an arrangement implies the location of the vascular tuft at the very beginning of the tubule—a disposition which in fact is found in the kidneys of all higher animals. The number of the glomeruli, therefore, corresponds with that of the uriniferous tubules, each of which begins in close relation with a vascular tuft. The kidney-substance consists of an intricate, although definitely arranged, complex of uriniferous tubules, supported by an interstitial connective tissue stroma, which have their commencement in the cortex and their termination at the apices of the papillæ, their intervening course being marked by many and conspicuous variations in the character, size, and direction of the tubules.

The **uriniferous tubule** begins as a greatly expanded blind extremity, the *capsule* (1), which surrounds the vascular tuft or *glomerulus*, the two together constituting the *Malpighian body* or *renal corpuscle*, which lies within the labyrinth. On leaving the Malpighian body, the tubule becomes

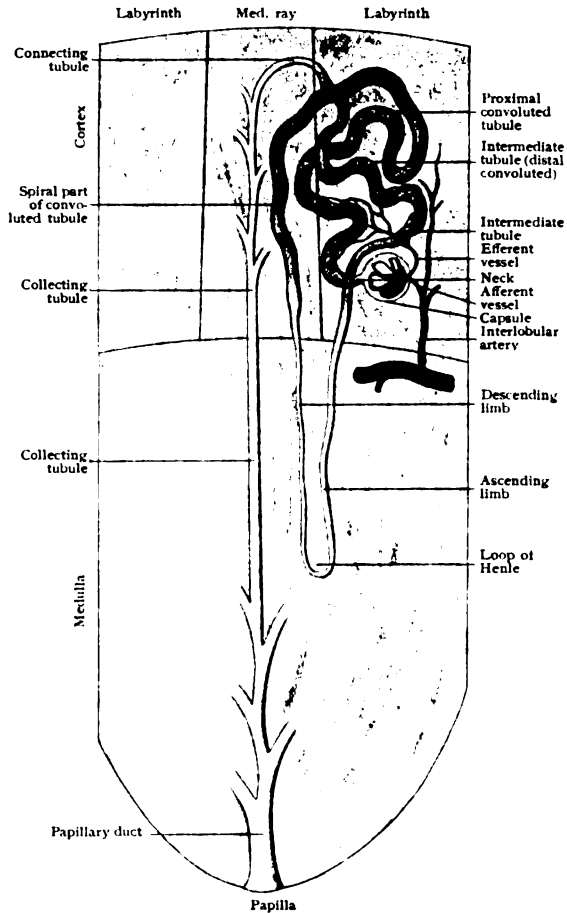


FIG. 255.—Diagram illustrating the course of a uriniferous tubule.

very tortuous and arches towards the free surface as the *proximal convoluted tubule* (2); this, after a course of considerable length, usually leaves the labyrinth and enters the medullary ray, which it traverses, somewhat reduced in diameter and slightly winding in course, and passes into the medulla. Immediately upon gaining the latter, the tubule becomes markedly nar-

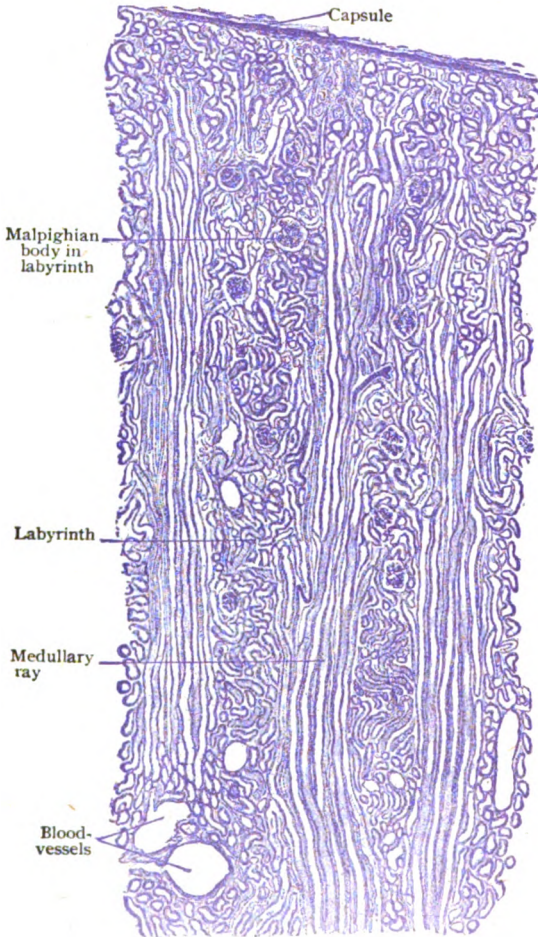


FIG. 256.—Section of cortex, showing relation of labyrinth to medullary rays.  $\times 50$ .

rowed, penetrates the renal pyramid for a variable distance towards the papilla, then bends sharply upon itself and retraces its course to enter once more the labyrinth. Its excursion into the medulla includes the *descending limb* (3) and *ascending limb* (4) of the *loop of Henle*. The ascending limb—the longer and wider of the parallel limbs of the loop—rises within the labyrinth to the immediate vicinity of the corresponding Malpighian body and then, after arching over or around the body, gives place to the *distal convoluted tubule* (5), a segment which, marked by increased diameter and tortuosity, crosses the general path of the proximal convoluted tubule and is succeeded by the narrower arching *connecting tubule* (6). The latter soon enters the medullary ray and joining with similar canals, takes part in forming the straight *collecting tubule* (7), which, progressively increasing in size by junction with others, traverses the remaining length of the medullary ray and enters the pyramid. Within the deeper part of the latter, the collecting tubules fuse into larger and larger canals until, as the relatively wide *papillary ducts* (8), they terminate at the apex of the papilla at the orifices, the *papillary foramina*, which open into the *calyces*, as the subdivisions of the expanded beginning of the renal duct are called.

Although as a matter of convenience the entire canal, from its commencement at the Malpighian body to its termination on the papilla, has been described as the uriniferous tubule, both genetically and functionally two distinct parts should be recognized. These are (a) the *uriniferous tubule*

rowed, penetrates the renal pyramid for a variable distance towards the papilla, then bends sharply upon itself and retraces its course to enter once more the labyrinth. Its excursion into the medulla includes the *descending limb* (3) and *ascending limb* (4) of the *loop of Henle*. The ascending limb—the longer and wider of the parallel limbs of the loop—rises within the labyrinth to the immediate vicinity of the corresponding Malpighian body and then, after arching over or around the body, gives place to the *distal convoluted tubule* (5), a segment which, marked by increased diameter and tortuosity, crosses the general path of the proximal convoluted tubule and is succeeded by the narrower arching *connecting tubule* (6). The latter soon enters the medullary ray and joining with similar canals, takes part in forming the straight *collecting tubule* (7), which, progressively increasing in size by junction with others, traverses the remaining length of the medullary ray and enters the pyramid.



*proper*, which includes all the conventional subdivisions from the Malpighian body to the termination of the distal convoluted tubule; and (*b*) the *duct-tube*, which, when traced from the papilla towards the cortex, undergoes repeated division until, from the single main stem, the number of connecting tubules is sufficient to provide each uriniferous tubule proper with an excretory canal.

**Details of the Uriniferous Tubule.**—The general course and relations of the tubule having been sketched, a brief account of its more important structural details may here find an appropriate place.

1. The **Malpighian body**, irregularly spherical and from .12–.20 mm. in diameter, consists of the glomerulus and the capsule. The *glomerulus* is an aggregation of tortuous capillary blood-vessels derived from the lateral terminal branches given off from the cortical arteries as these pass between the lobules towards the free surface of the kidney. One of the lateral branches, very short and often arched, enters the adjacent Malpighian body as the *vas afferens*, where it divides into from four to six twigs, each of which breaks up into capillaries. These may anastomose and form a vascular complex, or each terminal twig may give rise to an isolated capillary territory,

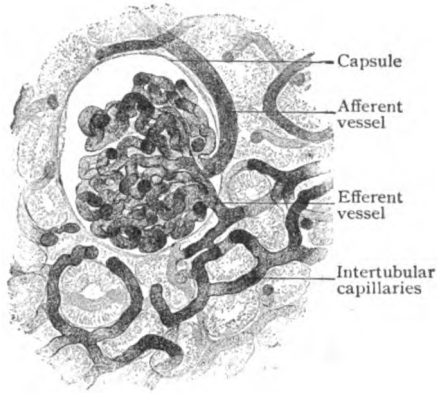


FIG. 257.—Injected glomerulus, showing afferent and efferent vessels and continuation of the latter into the intertubular capillary network.  $\times 180$ .

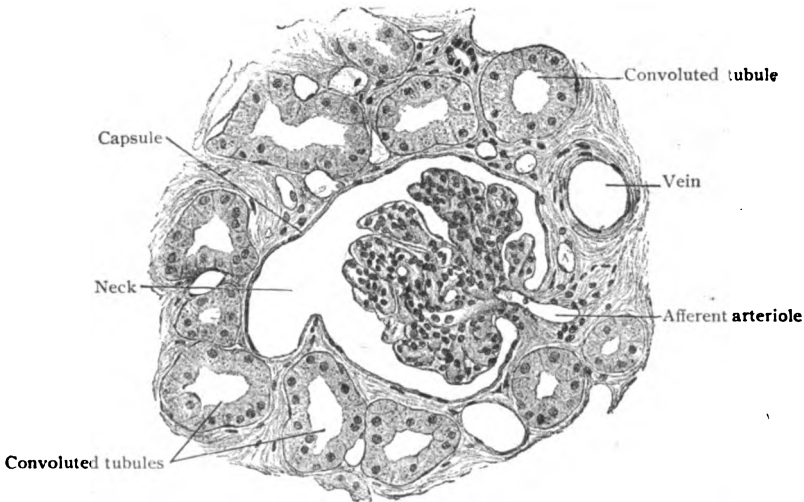


FIG. 258.—Section of cortex, showing details of a renal corpuscle or Malpighian body; the glomerulus is surrounded by capsule which passes into obliquely cut neck of tubule.  $\times 200$ .

the entire glomerulus then consisting of a group of vascular lobules. The channels of exit unite to form the single *vas efferens*, through which the blood from the glomerulus escapes. As the efferent emerges from the body, it is close to the afferent vessel, both usually lying on the side opposite to that from which the tubule springs. The *capsule*, the dilated beginning of the uriniferous tubule, almost completely invests the glomerulus with a double layer, the prolonged wall of the tubule. The outer and inner layers are

continuous around the narrow stalk, through which the vessels pass and at which the reflection of the capsule is incomplete. The inner ("visceral") layer is firmly attached to the glomerulus by delicate strands of connective tissue which likewise hold together the capillaries. The capsule consists of a membrana propria lined with a single layer

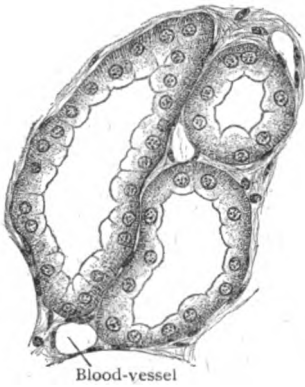


FIG. 259.—Convoluted tubules, cut transversely and obliquely, showing character of epithelial lining.  $\times 280$ .

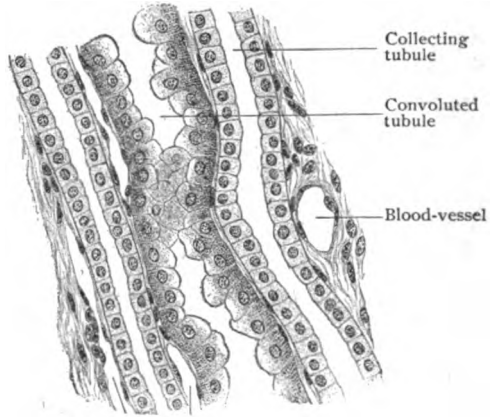


FIG. 260.—Portion of medullary ray, showing "spiral" part of convoluted and collecting tubules.  $\times 280$ .

of flat polyhedral epithelial cells, directly continuous with the epithelium of the tubule.

2. The proximal convoluted tubule begins at the constriction, the *neck*, of the capsule and abruptly widens into the tortuous segment that forms approximately one fifth of the entire length of the tubule. Its diameter varies from 40–60  $\mu$ .

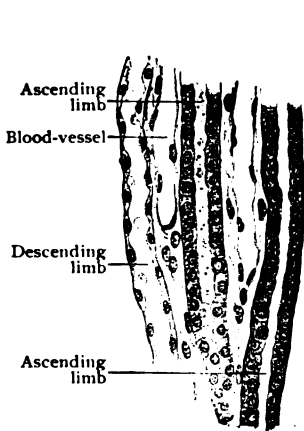


FIG. 261.—Longitudinal section of medulla, showing parts of limbs of Henle's loop.  $\times 280$ .

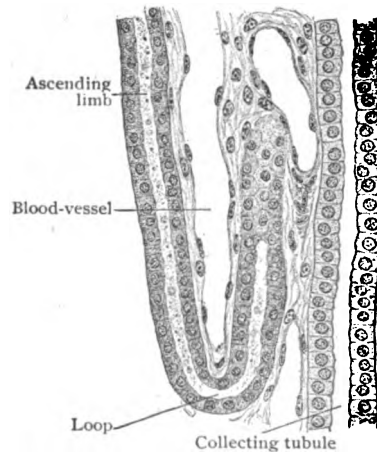


FIG. 262.—Longitudinal section of medulla passing through Henle's loop.  $\times 280$ .

In common with other parts of the renal tubule, its wall consists of a homogeneous basement membrane lined with a single layer of epithelial cells. The latter, in the convoluted tubule, are not defined by sharp outlines, but more or less blended into a continuous protoplasmic sheet, a form of syncytium, in which the spherical nuclei, which lie near the basement membrane, indicate the approximate extent of the individual low columnar cells. Although subject to much and inconstant variation, their cytoplasm exhibits a differentiation into a broad darker *outer* and a narrow

lighter *inner zone*. The former is marked by coarse radial striations, the so-called rods, produced by parallel rows of granules along the protoplasmic threads. The narrow inner zone, next the lumen, is relatively clear, containing few granules and showing a faint striation, due probably to the arrangement of the protoplasmic threads. This "bristle border," as it is sometimes called, is seen only in very well preserved tissue; since it is prone to disintegrate, the partially destroyed border may give rise to appearances mistaken for cilia. During active secretion, the epithelial cells are relatively low and the lumen of the tubule is wide, these relations being reversed during periods of functional inactivity.

3. The loop of Henle begins in the boundary zone between the cortex and medulla by the passage of the end-segment of the convoluted tubule into the *descending limb*, which is distinguished not only by the conspicuous reduction in its diameter ( $12-15\ \mu$ ), being the narrowest part of the entire renal tubule, but also by the character of its epithelium. The latter consists of low flattened elements, in which the ellipsoidal nuclei equal or surpass the thickness of the cells, whose cytoplasm is clear or slightly granular. The *ascending limb* differs from the descending in its increased diameter ( $24-28\ \mu$ ), thicker epithelium, which is dark and striated, and extension into the cortex. Since the cuboidal cells are often irregular in height, the lumen correspondingly varies, in places being almost obliterated. The length of Henle's loop is influenced by the level of the corresponding Malpighian body within the cortex—the nearer the medulla the body lies the greater the descent of the loop towards the papilla, and *vice versa*. On entering

the cortex the ascending limb rises to the immediate vicinity of its Malpighian body, around or over which it curves to end in the succeeding distal convoluted tubule. The usual position of the sudden transition from the narrow into the wider part of Henle's loop is in the descending limb a short distance above the loop, although the change may occur beyond the turn, or even within the bend itself.

4. The distal convoluted or intermediate tubule, from  $40-45\ \mu$  in diameter, pursues a moderately tortuous path, marked by a number of abrupt changes in direction, but in a general way is enclosed by the arch of the proximal convoluted segment which it finally crosses. Its epithelium, which at first resembles that of the ascending limb, becomes clearer and less distinctly striated, the cells having a more definitely defined low cylindrical or pyramidal form, although presenting local variations in height.

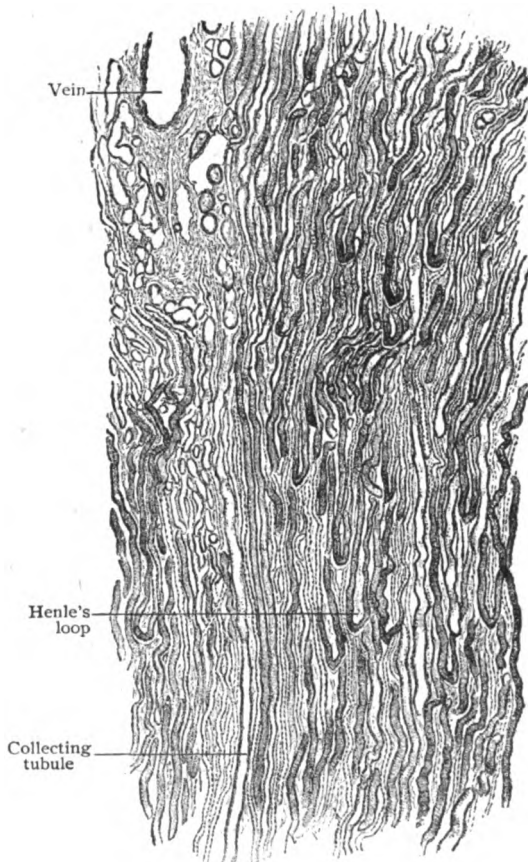


FIG. 263.—Longitudinal section of renal pyramid, showing general structure of medulla with Henle's loops and collecting tubules.  $\times 45$ .

5. The connecting or junctional tubule effects the union of the uriniferous tubule proper with the duct-system. It is narrower ( $23-25 \mu$ ) than the preceding segment and lined with well defined cuboidal cells, which being lower afford an increased lumen.

After an usually short and somewhat arched course, the connecting tubule enters the medullary ray and, uniting with similar canals, joins in forming the collecting tubule.

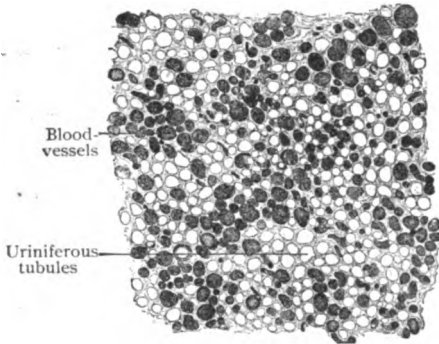


FIG. 264.—Section across upper part of renal pyramid, showing groups of blood-vessels surrounded by uriniferous tubules.  $\times 50$ .

6. The collecting tubule at first lies within the medullary ray, where it represents the beginning of the system of straight duct-tubes opening on the papilla, and then passes into the renal pyramid. During their course through the medullary ray, the collecting tubules repeatedly unite to produce stems, which, while increasing four- or five-fold in diameter, diminish in number as they descend in the medulla.

In consequence of this fusion, within the pyramid the collecting tubules are disposed in groups, each of which corresponds to the tubules prolonged from a single medullary ray, surrounded by the limbs of the loops of Henle. The groups are further separated by the bundles of straight blood-vessels (*vasa recta*) of the medulla. The epithelium lining the collecting

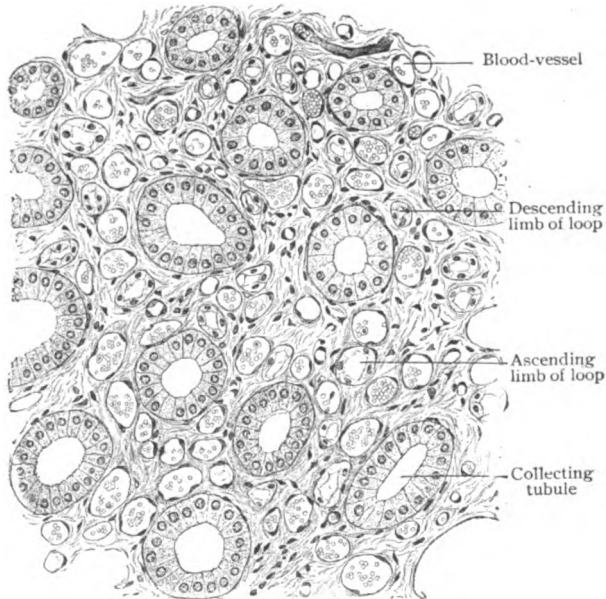


FIG. 265.—Section of medulla across renal pyramid, showing large collecting tubules, limbs of Henle's loops, blood-vessels and intertubular stroma.  $\times 130$ .

tubules consists of clear, distinctly defined, cuboidal cells, whose height gradually increases as the medulla is traversed. After converging to within about 5 mm. of the apex of the papilla, the now large collecting tubules undergo repeated junction, increasing in diameter ( $50-60 \mu$ ) but rapidly diminishing in number, to form the wide papillary ducts.

7. The **papillary ducts**, the final segment of the renal tubule, number from ten to eighteen for each papilla, at the apex of which they open into the calyx. Each is formed by the junction of from ten to thirty of the larger collecting tubules and attains a diameter from 200–300  $\mu$ . The lining epithelium is composed of conspicuous clear columnar cells, about 20  $\mu$  in height and one-third as much in width, which rest upon a basement membrane almost as far as the end of the canal. At this point the simple columnar epithelium of the duct becomes continuous with the stratified squamous epithelium that covers the free surface of the papilla and lines the calyx.

**The Supporting Tissue.**—The uriniferous tubules and the blood-vessels are held in place by a delicate interstitial stroma of reticular connective tissue, elastic fibres being relatively very few. At the surface of the kidney this tissue is condensed into a compact fibrous stratum, the *tunica albuginea*, containing scattered bundles of unstriated muscle and an increasing number of elastic fibres, not to be confounded with the fibrous tunic that envelops the organ and may be stripped off without disturbing the renal substance. Although forming a continuous framework throughout the kidney, the interstitial stroma is not uniformly distributed, being most abundant along the path of the interlobar and the larger blood-vessels, from whose adventitia delicate trabeculae extend in all directions to form the meshes lodging the tubules, the smaller vessels and the capillaries. Within the cortex the supporting tissue is meagre, being best developed along the interlobular vessels and around the Malpighian bodies. The interstitial tissue is much more plentiful within the medulla than the cortex, its amount increasing towards the apex of the papilla, where considerable tracts of stroma-tissue separate the papillary ducts. Not only the blood-vessels, but also the nerve-trunks are provided with sheaths of renal stroma.

The **blood-vessels** supplying the kidney, branches of the renal artery, enter the renal substance through the vascular foramina surrounding the papillae on the wall of the sinus. As they pass along the sides of the papillae, their positions correspond to the primary interlobar tracts of connective tissue of the foetal kidney. On reaching the level of the bases of the renal pyramids, each *interlobar artery* breaks up into twigs, some of which pursue an irregularly arched course across the bases of the pyramids, thereby producing in places the impression of “arcades” at the junction of the medulla and cortex. From these arcuate arteries or their divisions arise the terminal branches which supply the cortex. The cortical twigs radiate generally perpendicular to the free surface, towards which, as the *interlobular arterioles*, they pass, giving off the short lateral twigs that end in the vasa afferentia of the glomeruli. These are arranged in columnar groups along the path of the interlobular cortical arterioles. Some of the latter continue to the free surface where, in conjunction with direct *capsular branches* from the renal artery, they supply the capsule of the kidney. After traversing the capillary complex of the glomerulus, the blood is carried off by the vas efferens, which on its exit immediately resolves into the *cortical capillaries*, whose meshes about the convoluted tubules are round and about the tubules of the medullary rays are elongated. In addition to the usual path through the glomerulus, the kidney substance is supplied also by terminal vessels that pass directly into the intertubular network. The course of the medullary twigs is influenced by the radial disposition of the tubules between which they run; they are, therefore, relatively straight and, hence, known as *arteriola rectae*. They arise only exceptionally from the arcuate arteries, and chiefly from the afferent branches of low lying, perhaps atrophic (Huber), Malpighian bodies. The supply of the medulla is, therefore, less independent than formerly believed.

The **veins** of the kidney are also disposed as cortical and medullary branches, which empty into larger stems, the so-called *venae arciformes*, that

cross the bases of the pyramids and become tributary to the large intralobar trunks. The blood within the cortical capillaries escapes by three paths: (1) through small veins that pass from the outer third of the cortex towards the capsule, beneath which they empty into stems running parallel to the

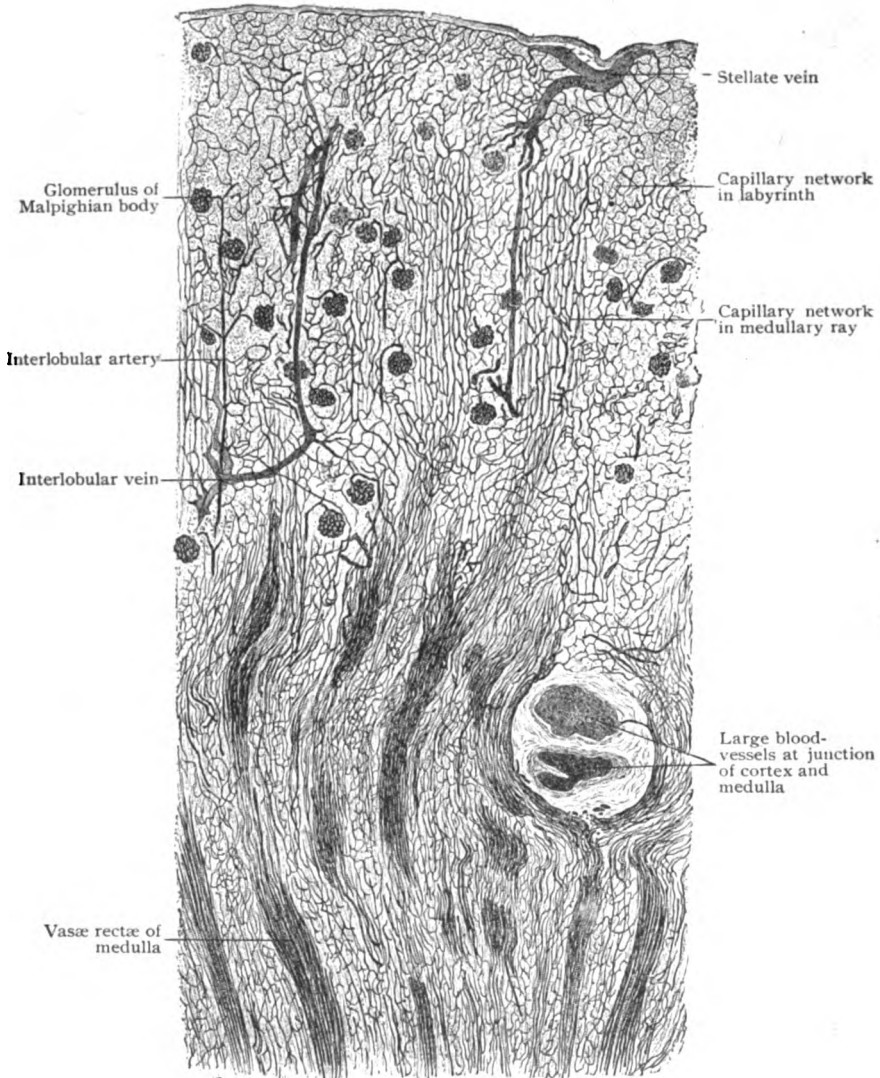


FIG. 266.—Longitudinal section of injected kidney of dog, showing general arrangement of blood-vessels of cortex and adjoining medulla.  $\times 40$ .

free surface of the kidney; from three to five of these horizontal vessels converge to form a star-like channel, the *vena stellata*, which is the beginning of the *interlobular vein* that passes through the cortex with the corresponding arteriole to the arcuate veins at the base of the pyramid; (2) through small veins that empty directly into the interlobular veins at various levels;

(3) through the deep cortical veins that traverse the inner third of the cortex and are direct tributaries of the venæ arciformes. The medulla is drained by the venulæ rectæ, straight vessels that begin in the medullary capillary network and empty, for the most part indirectly, in the arcuate veins. The latter terminate in the larger interlobar veins, which accompany the corresponding arteries along the sides of the pyramids and emerge into the sinus around the papillæ to become tributary to the renal vein. This vessel and its branches are without valves.

The **lymphatics** of the kidney occur as deeper and superficial networks. The *deep lymphatics* arise as networks of capillaries within the cortex and medulla, the general path of the more definite lymph-channels being that of the blood-vessels, from four to seven large trunks emerging at the hilum. The *superficial lymphatics* include two networks, one situated within or beneath the fibrous capsule and the other within the perirenal fatty areolar tissue (*capsula adiposa*). The subcapsular channels communicate with the peripheral parts of the cortical network, as well as with the vessels outside the fibrous capsule.

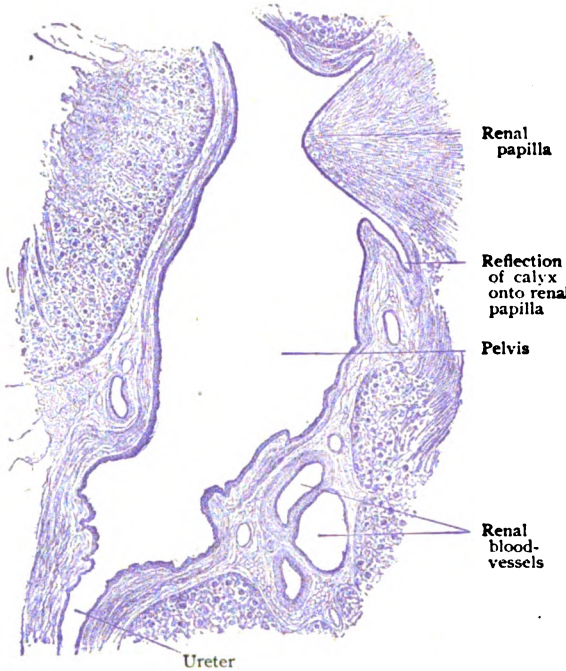
The **nerves** supplying the kidney are derived from the renal sympathetic plexus and consist, therefore, principally of nonmedullated fibres. These accompany the blood-vessels, around which they form plexuses containing ganglion-cells, and to which they send filaments for the walls. The smaller arteries are accompanied by the nerves as far as the glomeruli and capillaries. The relation between the nerve-fibres and the tubules is intimate, delicate filaments enclosing the convoluted canals with a network outside the basement membrane (epilemmar plexus), from which filaments pass to the inner side of the membrane (hypolemmar) and end partly between the epithelial cells.

## THE RENAL DUCTS.

Each canal consists of the greatly expanded upper end, the *renal pelvis* with its subdivisions, the *calyces*, and the main part of the duct, the *ureter*, the whole serving for the collection of the urine as it escapes from the kidney and its transmission to the bladder.

The wall of all parts of the renal duct is the same in its general structure and consists of three layers: (1) the *mucous membrane*, (2) the *muscular tunic*, and (3) the *fibrous coat*; the mucous and muscular layers are more or less blended, so that a distinct submucosa is wanting. The **mucous membrane** is clothed with transitional epithelium consisting of several strata of cells, the deepest elements being irregularly columnar and the superficial ones to a varying degree flattened. The tunica propria is made up of bundles of fibrous tissue, intermingled with comparatively few elastic fibres, and is often directly attached to the muscular coat, a meagre amount of loose fibro-elastic tissue in places suggesting a submucous layer. Within the ureter, the mucous membrane is usually thrown into longitudinal folds and, hence, the lumen appears stellate in transverse sections. Neither well marked papillæ nor true glands are present, although in places the tunica propria encroaches upon the epithelium and subdivides the latter into nest-like groups of cells. Numerous scattered colorless blood-cells are ordinarily encountered within the tunica propria; sometimes, particularly in the vicinity of the calyces, they are aggregated into distinct minute lymph-nodules. On the papillæ, the epithelium lining the calyces is continuous with that of the papillary canals, while the tunica propria blends with the intertubular renal stroma.

The **muscular tunic** consists of loosely connected bundles of unstriped tissue whose continuity as definite sheets is interrupted by often considerable intervening fibrous tissue.



The muscle-bundles are arranged as a thin and imperfect *longitudinal* and a thicker and chief external *circular* layer. Within the renal pelvis and its larger subdivisions, the infundibula, both layers are well represented, but are reduced on the calyces, except at the junction of the latter with the renal papillæ where the circular muscle is augmented and surrounds each papilla with a minute sphincter-like bundle. In the lower half of the ureter, an additional but incomplete external longitudinal layer is found outside the circular one. At its end, where the ureter meets and traverses the wall of the bladder, the muscular tissue is represented almost exclusively by a well developed layer of longitudinal fibres, which retain their independence

FIG. 267.—Longitudinal section through sinus of child's kidney, showing lower part of pelvis and commencement of ureter.  $\times 10$ .

well developed layer of longitudinal fibres, which

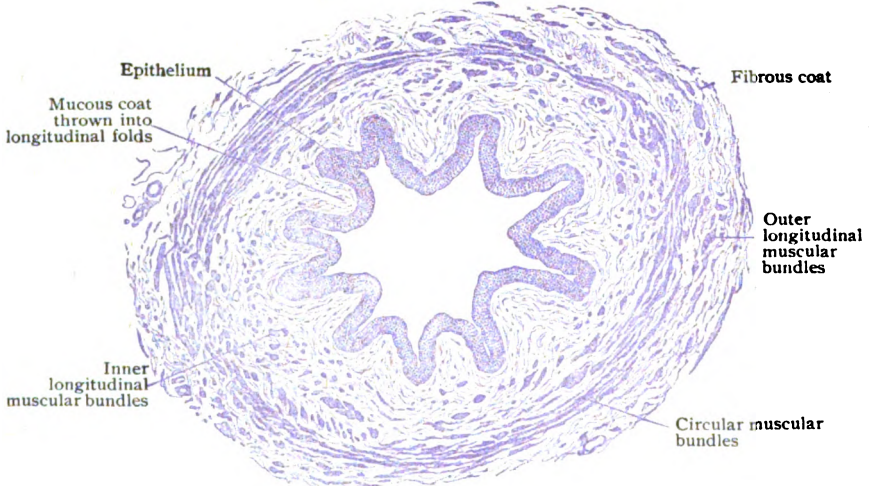

FIG. 268.—Transverse section of ureter.  $\times 25$ .

and do not blend with the vesical muscle but end in the mucosa of the bladder. Contraction of these fibres tends to dilate the ureteral orifices.



The **fibrous coat**, or *tunica adventitia*, composed of bundles of fibro-elastic tissue, invests the entire renal duct as its outermost tunic and connects it, through the surrounding areolar tissue, with the adjacent structures. Within the sinus of the kidney, the outer coat of the renal duct blends with the tunica fibrosa that invests the renal substance where the latter is not embraced within the calyces. Just above the bladder the fibrous coat of the ureter becomes thicker and, in conjunction with the longitudinal muscle, forms the *ureteral sheath*, giving independence to the duct as it passes through the wall of the bladder.

The **blood-vessels** supplying the renal duct, derived from several sources during its long course through the abdomen and pelvis, break up into capillaries which are especially numerous within the tunica propria immediately beneath the epithelium. The veins begin within the mucosa, beneath which they form an inner plexus that communicates with a wider meshed outer plexus, lying within the fibrous coat and giving rise to the larger emergent venous trunks. The **lymphatics** within the mucous membrane are indefinite lymph-channels, but within the muscular coat and on the surface are present as distinct networks, from which afferent vessels pass to various groups of lymph-nodes. The **nerves** distributed to the renal duct are brought by branches from the neighboring sympathetic plexuses. While consisting chiefly of nonmedullated fibres destined for the muscular tissue and blood-vessels, many sensory fibres find their way into the mucous membrane, where some end within the tunica propria in free arborescent endings and others between the epithelial cells.

## THE BLADDER.

The bladder, the reservoir in which the urine is received from the renal ducts and retained until discharged through the urethra, is essentially a muscular sac, lined with mucous membrane and partly covered with peritoneum, a layer of connective tissue loosely uniting the mucous and muscular coats. From within outwards, four coats are distinguishable—the *mucous*, the *submucous*, the *muscular* and the *fibrous*.

The **mucous coat** closely resembles that of the renal duct, consisting of a fibro-elastic tunica propria covered by transitional epithelium. The details of the latter are materially affected by the degree of contraction or distention to which the mucosa is subjected, since it is probable that the impression of a many-layered epithelium is based on the examination of sections of the strongly contracted organ. As ordinarily seen, the deepest cells are irregularly columnar, the ones of the middle layers polyhedral or club-shaped, and the surface cells somewhat flattened, with their deeper aspect modelled by the subjacent elements, over and between which fit depressions and projections. Although definite glands can hardly be said to exist, in the vicinity of the vesical trigone and of the urethral orifice the tunica propria contains small epithelial pockets or crypts, from the bottom of which short branched tubules, lined with low columnar cells, extend into the surrounding stroma. These rudimentary glands have been interpreted as representing abortive prostatic tubules, which have become displaced during the development of the lower segment of the bladder from the uro-genital sinus.

The **submucous coat**, loose and elastic, permits free gliding of the mucous membrane over the muscular tunic when readjustment becomes necessary during contraction and the mucosa is strongly wrinkled. It is composed of bundles of fibrous tissue, interwoven with numerous elastic

fibres, and supports the blood-vessels and nerve-plexuses, and occasionally contains small lymph-nodules. The submucosa is not sharply defined from the adjacent coats, but blends with the tunica propria on the one side and penetrates between the tracts of muscle-bundles on the other. Beneath the trigonum a distinct submucous layer is wanting, or replaced by a sheet of muscular tissue.

The **muscular coat**, thicker than the mucous and comparatively robust, varies according to the condition of the bladder, being thin during distention and very thick during strong contraction, when it may measure as much as 1.5 cm. The bundles of involuntary muscle are arranged as two fairly distinct chief layers—a thick circular and a thin outer longitudinal. Inside the circular, virtually within the mucosa, lies an incomplete additional

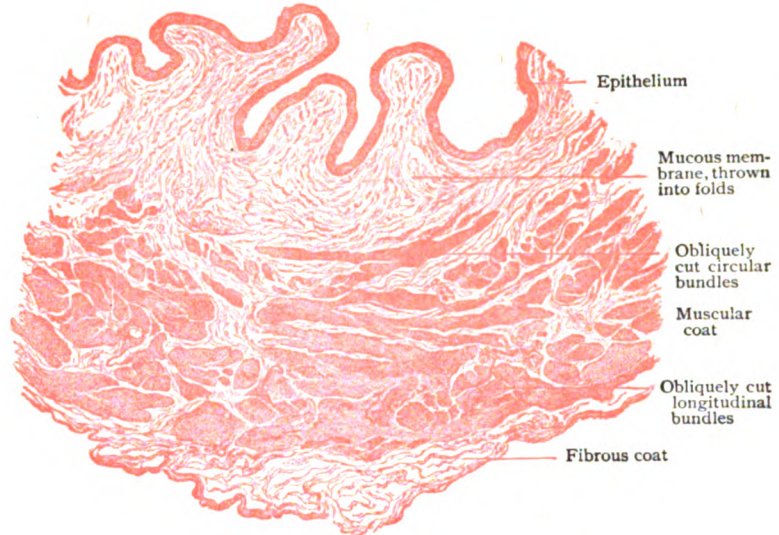


FIG. 269.—Section of wall of bladder, showing general disposition of coats.  $\times 12$ .

layer of mostly oblique bundles. The *longitudinal bundles*, best developed on the upper and lower surfaces of the bladder, do not form a continuous sheet but interlace, leaving intervals occupied by connective tissue. The *circular layer*, although more robust and uniform than the outer one, is weak and imperfect over the trigonal region and is well developed only above the level of the orifices of the ureters, towards the apex of the bladder becoming oblique and less regular. The innermost layer, largely represented by isolated and indefinite bundles intermingled with connective tissue, is condensed over the trigone, where it exists as a compact muscular sheet closely united with the overlying mucous membrane, and surrounds the orifices of the ureters and of the urethra with sphincter-like bands.

The **fibrous coat**, composed of fibro-elastic bundles, is blended over the upper and lateral surfaces of the bladder with the serous (peritoneal) covering; where this is wanting, it is continuous with the areolar tissue connecting the bladder with the surrounding pelvic wall and organs. It is strongest over the inferior surface, where it receives additions from the pelvic fascia, while towards the apex and beneath the peritoneum it is less definite and intermingled with adipose tissue.

The **blood-vessels** enclose the bladder with an arterial network within the fibrous coat, from which twigs enter the muscular coat and break up into capillaries, while others gain the submucous layer and form a network of the larger stems; from this branches pass into the mucous membrane and give rise to a rich capillary meshwork immediately beneath the epithelium. The veins form a submucous plexus that drains the mucosa and empties into a muscular plexus which, in turn, is tributary to the external subperitoneal plexus. With the exception of the smaller ones on the inferior surface, the vesical veins possess valves. The **lymphatics** begin as a close-meshed plexus within the muscular coat, distinct lymph-channels being absent within the mucous membrane. Outside the muscular coat they form a loose plexus within the fibrous tissue (subperitoneal), the lymphatics from the apex and body of the bladder coursing downwards and laterally and those from the fundus upwards.

The **nerves** include both spinal and sympathetic fibres, medullated and nonmedullated, and within the fibrous coat are connected with ganglia, particularly in the vicinity of the ureters, from which twigs enter the muscular coat and break up into smaller ones bearing microscopic ganglia. Other branches gain the submucous layer, where they form plexiform enlargements, containing numerous groups of ganglion-cells; in addition to sympathetic filaments to the blood-vessels, fine bundles of fibres proceed to the mucous membrane to end in free terminations partly within the tunica propria and, probably, to some extent between the epithelial cells. The general sensibility of the normal bladder is comparatively slight, being greatest in the trigonal region, especially at the ureteral openings.

## THE URETHRA.

The urethra—the canal through which the urine is conveyed from the bladder to the exterior of the body—differs in the two sexes, since in the male, in addition to its common function of conducting the urine, it serves for the escape of the secretions of the sexual glands.

**The Male Urethra.**—Considered with regard to the regions of the body in which it lies, the male urethra may be divided into a *pelvic*, a *perineal* and a *penile* portion. It is more usual, however, to describe the canal as consisting of the *prostatic*, the *membranous* and the *spongy* portions—a division based on the anatomical relations to the structures through which it passes.

The wall of the urethra consists of a **mucous membrane** containing a rich venous plexus and supplemented, in the prostatic and membranous portions, by considerable tracts of muscular tissue. The tunica propria possesses an unusual number of fine elastic fibres and is covered with an epithelium that varies in different parts of the canal. Throughout the upper two-thirds of the prostatic portion, the epithelium resembles that of the bladder, being of the transitional variety; on approaching the membranous portion, the epithelium becomes stratified columnar in type, small reserve cells lying between the outer ends of the superficial elements, which are often goblet-cells. Except within the beginning of the spongy portion (*pars cavernosa*), where the lining is reduced to practically a single stratum of cells, the columnar epithelium retains its stratified character as far as the navicular fossa, the dilated distal end of the urethra. Here the epithelium becomes stratified squamous and at the external urethral orifice is directly continuous with the epidermis covering the glans penis. Within the

urethral crest, the fusiform ridge modelling the posterior wall of the prostatic portion of the canal, the mucous membrane acquires the character of erectile tissue on account of the abundance of the venous channels occupying the deeper layer of the tunica propria.

The **muscular tissue** associated with the male urethra includes intrinsic and extrinsic fibres, the former being involuntary and directly incorporated with the wall of the canal and the latter being accessory strands of striped muscle derived from structures surrounding the urethra. The intrinsic muscle is arranged as an inner longitudinal and an outer circular layer, of which the longitudinal is thinner but more widely distributed, extending from the internal urethral orifice at the bladder as far forwards as the openings of the bulbo-urethral glands in the pars cavernosa. The circular fibres, outside the longitudinal ones, are best developed at the internal urethral orifice, where they are three or four times as thick as those running lengthwise. They gradually diminish and just beyond the mem-

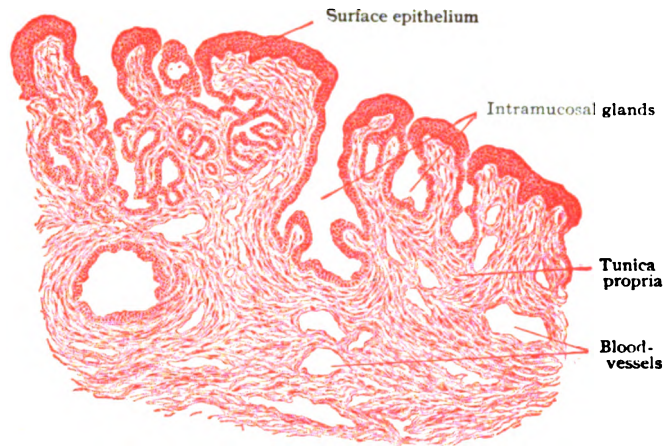


FIG. 270.—Section of mucous membrane of prostatic urethra, showing gland-like crypts in mucosa.  $\times 45$ .

branous urethra disappear, first on the lower and last on the upper wall of the dilatation, the fossa bulbi. In advance of the posterior third of the spongy portion, the intrinsic muscle is wanting, the unstripped muscular tissue surrounding the remainder of the canal belonging to the erectile tissue of the corpus spongiosum which the urethra traverses. The *internal vesical sphincter*, encircling the commencement of the urethra, is derived from the muscular sheet of the trigonum of the bladder. At the apex of the prostate gland, the urethra is surrounded by bundles of striped muscle, known as the *external vesical sphincter*, prolonged upwards from the compressor urethræ muscle.

The **urethral glands**, or *glands of Littré*, embrace two groups, those within the mucous membrane and those immediately outside, whose ducts are seen with a magnifying glass as minute openings on the mucous surface. The former, the *intramucosal glands*, are small and simple, consisting usually of a single alveolus, less frequently of two or three. They are lined with columnar epithelium and occur in all parts of the urethra, but are most numerous in the spongy portion. The *extramucosal glands*, although small, are larger than the preceding but less widely distributed, since they are absent in the distal half of the membranous and the proximal third of the

spongy portion. They are most abundant and best developed in the upper wall of the spongy portion distal to the openings of the ducts of the bulbo-urethral (Cowper's) glands. Their ducts often extend several millimeters obliquely backwards, more or less parallel to the urethra, and divide into several slightly expanded alveoli, lined with columnar epithelium. In addition to the foregoing true, although small glands, the urethral mucosa is beset, along its upper wall, with small diverticula, the *lacunæ urethrales*, which are little more than tubular depressions, or *crypts*, within the mucous membrane and can not be regarded as glands, although they often receive the ducts of the extramucosal glandules. One crypt of exceptional size

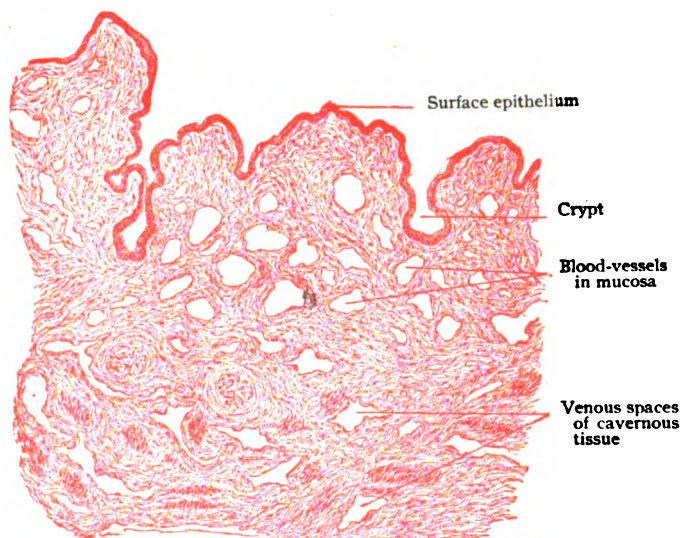


FIG. 271.—Section of wall of urethra, spongy portion, showing crypts and blood-spaces in mucosa.  $\times 35$ .

(4–12 mm. in depth) is commonly found on the roof of the navicular fossa, its orifice being guarded by a fold of mucous membrane.

**The Female Urethra.**—The wall of this canal, much shorter than the urethra in the male, consists essentially of a mucous membrane supplemented by a robust outer muscular tunic. The **mucous membrane**, thrown into longitudinal folds, is composed of a tunica propria, rich in elastic fibres, wandering cells and plexiform veins, and a layer of epithelium. The latter resembles that of the bladder above and that of the vestibule, into which the canal opens, below, but in places the stratified squamous epithelium gives way to one approaching the simple columnar in type. In the female the *urethral glands* are represented by small tubular alveoli that open by minute ducts on the mucous surface and correspond to Littré's glands in the male. They are most plentiful in the upper part of the urethra and in aged subjects may contain concretions. The mucosa is also pitted with small crypts, similar to those in the male canal, into which the ducts of the glands often open.

The intrinsic **muscular tissue** of the female urethra is disposed as an inner layer of longitudinal and an outer one of circular fibres, the two being separated by a thin connective tissue stratum with many elastic fibres. At the internal urethral orifice, in conjunction with fibres from the trigonum of

the bladder, the circular fibres aid in forming the internal vesical sphincter. The lower end of the urethra is embraced by the anterior fibres of the sphincter vaginæ muscle, and higher, between the layers of the triangular ligament, the canal is surrounded by the bundles of the compressor urethræ. The deepest part of the mucosa and the adjacent portion of the longitudinal

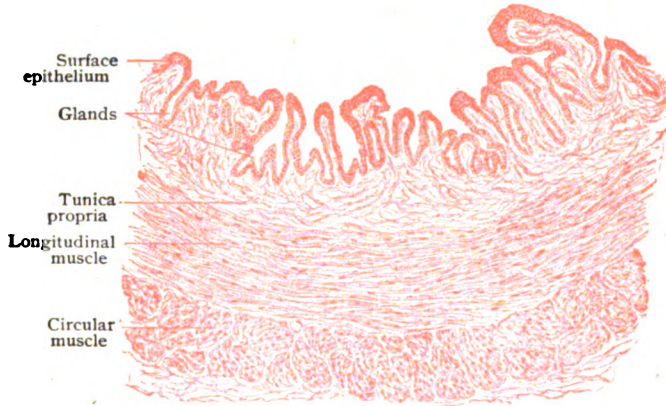

FIG. 272.—Longitudinal section of wall of female urethra.  $\times 50$ .

muscle layer in places contain such a rich venous plexus that the tissue resembles a cavernous structure.

The **blood-vessels** supplying the urethra provide a generous capillary network beneath the epithelium; it is, however, the unusual abundance of the venous channels that confers the exceptional cavernous character to the wall of the canal. The **lymphatics** are also numerous within the deeper parts of the mucosa in the male, especially in the region of the glans penis; towards the upper end of the urethra they diminish, those from the prostatic portion communicating with the intramuscular network at the neck of the bladder. The lymphatics of the female urethra correspond with those of the membranous and prostatic portions of the male duct. The **nerves** include branches from the pudic (sensory fibres to the mucous membrane and motor fibres to the associated striped muscle) and from the hypogastric plexus of the sympathetic by way of the prostatic and cavernous plexus. The plexiform sympathetic fibres, associated with numerous ganglion-cells along their course, supply the involuntary muscle and the walls of the blood-vessels. The sensory fibres are distributed to the mucous membrane in which they end mostly as free, but to some extent as special terminations within the tunica propria, although some filaments penetrate between the epithelial cells.

### THE SUPRARENAL BODIES.

These are a pair of cocked-hat-shaped organs, about 6.5 cm. long and half as broad, situated at the back of the abdominal cavity, on the inner aspect of the upper ends of the kidney. This proximity suggests, as a matter of convenience, the description of the suprarenal body in connection with the urinary organs; it must be understood, however, that the suprarenal has neither morphological nor functional relations to the kidney which warrant such association.

The suprarenal body is invested by a distinct fibrous *capsule*, from which delicate septa pass into the organ, forming a framework of connective tissue for the support of the blood-vessels and the cellular constituents. Section across the thicker parts of the body displays an outer zone, the *cortex*, from .25–1.25 mm. in thickness, which encloses a central area, the *medulla*. Towards the borders of the organ, the medulla is reduced to a narrow zone, or may be entirely wanting; where best developed, as in the middle, it may attain a thickness of over 3 mm. The cortex is usually of a dirty yellow color, next the medulla presenting a narrow band of varying shades of brown. The medulla is of a grayish tint and generally lighter than the cortex. Its exact color, however, varies with the amount and condition of the contained blood, when engorged with venous blood being dark. Embryology and comparative anatomy indicate that the mammalian suprarenal body includes two entirely distinct organs, which, although intimately united as the cortex and medulla, possess different origins and functions. The cortex arises in close relation with the Wolffian body, the foetal excretory gland, and later migrates into secondary relation with the kidney. The medulla is derived from the adjacent embryonic sympathetic ganglia, the medullary cells closely corresponding with the chromaffin elements elsewhere originating from the sympathetic.

The **cortical substance** consists of a delicate framework of connective tissue, prolonged from the capsule, in whose meshes lie the tracts of the distinctive epithelial cells. The cortex is not always uniform, but often subdivided into indistinct subcapsular lobules by thicker septa continued from the overlying fibrous investment. The arrangement of the cortical cells, although in a general way columnar or slightly radial in the peripheral lobular areas, varies at different levels, three zones being distinguished within the cortex (Fig. 274). The narrow *zona glomerulosa* lies next the capsule and consists of rounded masses of somewhat tortuous groups of cells. The *zona fasciculata* forms the major part of the cortex and is made up of parallel or slightly radially disposed cell-columns. The *zona reticularis*, next the medulla and narrow, includes the networks of epithelial elements formed by the union of the inner ends of the columns of the preceding zone. The cells throughout the cortical strands are fairly similar, being rounded polygonal elements,

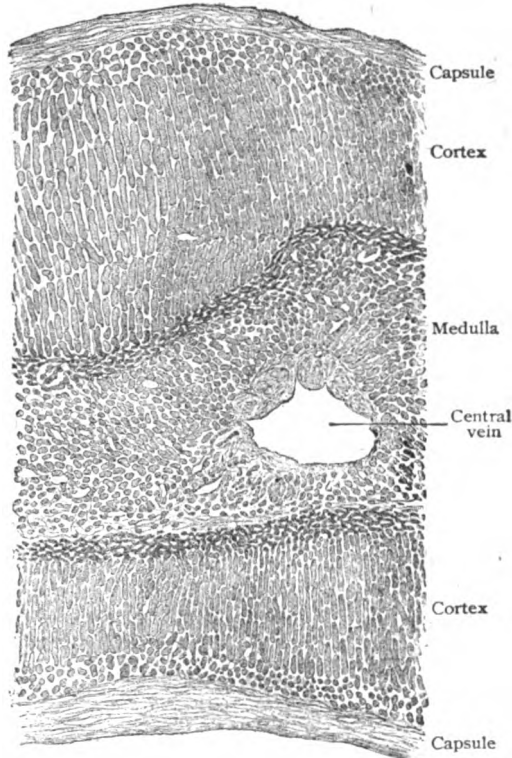


FIG. 273.—Section of suprarenal body including entire thickness of the organ, showing the general arrangement of cortex and medulla.  $\times 27$ .

15–20  $\mu$  in diameter, whose cytoplasm lodges a variable, but usually large number of fat granules. The latter are very abundant in the cells of the zona fasciculata, but few or entirely absent in those of the zona reticularis. Within the last named region, however, the cells are more or less pigmented, a peculiarity accounting for the darker tint of this part of the cortex (Fig.

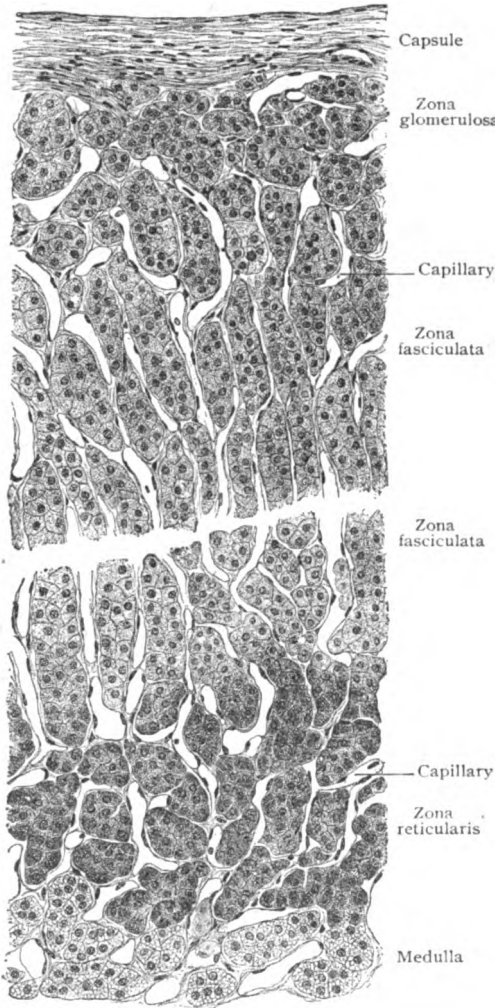


FIG. 274.—Section of suprarenal body, showing details of superficial and deep portions of cortex.  $\times 225$ .

274). The cells composing the cords and columns are in direct contact with one another; neither are they, as groups, surrounded by a basement membrane, but come into close relation with the capillary blood-vessels that enclose the cell-islands, a few delicate strands of supporting tissue alone intervening.

The **medullary substance** consists chiefly of networks of anastomosing cords of polyhedral cells (20–30  $\mu$  in diameter), so prone to post-mortem change that, as usually seen, they are very irregular and often stellate. They are distinguished from the cortical elements by the affinity of their cytoplasm for chromic acid and its salts, staining yellow or brown. They are known, therefore, as *chromaffin cells*, and regarded as akin to sympathetic elements. In addition to these cells, the medulla contains numerous blood-vessels, particularly venous channels, and many bundles of nerve-fibres and ganglion-cells. The latter (Fig. 275) occur singly or in small groups, are multipolar or stellate, and resemble the cell-bodies of sympathetic neurones.

The **blood-vessels** supplying the suprarenal body divide into a dozen or more fine branches which enter by piercing the capsule at various points, some penetrating directly as far as the medulla, but most of them terminating within the cortex. These last form a superficial network from which the capillaries extend between the cell-cords, which are thus enclosed within vascular meshes of corresponding form. Thus, within the cortex the meshes are elongated and within the medulla of rounded form. In large part the medulla is supplied by arterioles passing directly to the interior of the organ. These break up into capillaries which



surround the medullary cords and, in conjunction with the capillaries of the deeper part of the cortex, pass over into an unusually rich plexus of veins terminating in the large central vessel, the beginning of the chief suprarenal vein. Superficial veins claim as tributaries the peripheral portions of the capillary network.

The **lymphatics** are represented by a network within the zona glomerulosa which communicates with the subcapsular plexus, on the one hand, and, by means of centrally directed stems, with the rich medullary plexus on the other. The larger trunks from the medullary network follow the veins

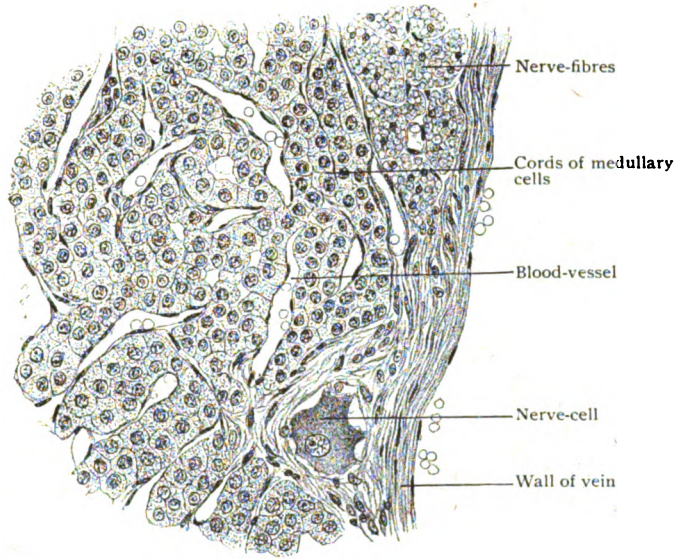


FIG. 275.—Portion of medulla of suprarenal body, from vicinity of central vein.  $\times 280$ .

and emerge at the hilum of the organ as several efferents that pass to adjacent lumbar lymph-nodes.

The **nerves** are remarkable for their abundance and derived principally from the solar and renal sympathetic plexuses, fibres from the vagus being included. They form a plexus within the capsule from which bundles of chiefly nonmedullated fibres pierce the capsule, along with the arteries, and give off fibres that pass between the cell-cords of the zona glomerulosa and fasciculata to end in the walls of the blood-vessels and on the surface of the cell-groups. Other branches penetrate to the zona reticularis to form a still closer plexus, but it is for the medulla that the most striking abundance is provided. Here the numerous nerves join into plexuses from which fibres pass to the blood-vessels and cords of medullary cells. In contrast to their superficial relation to the cortical cell-groups, within the medulla the fibrils penetrate between the cells, so that almost each of the latter comes into direct relation with a nerve-fibre. Numerous sympathetic ganglion-cells, isolated or in small groups, are also present.

**Accessory Suprarenals.**—These are usually very small, rarely surpassing a pea in size. They may be found near the suprarenal body, in the kidney, in the liver, in the solar and renal plexuses, or beside the testis or the ovary. The accessory suprarenal situated in the broad ligament of the

uterus, in the vicinity of the ovary, is known as *Marchand's organ*, and regarded as a normal and almost constant organ. These "accessory" bodies include two groups of different origin and morphological significance. Those

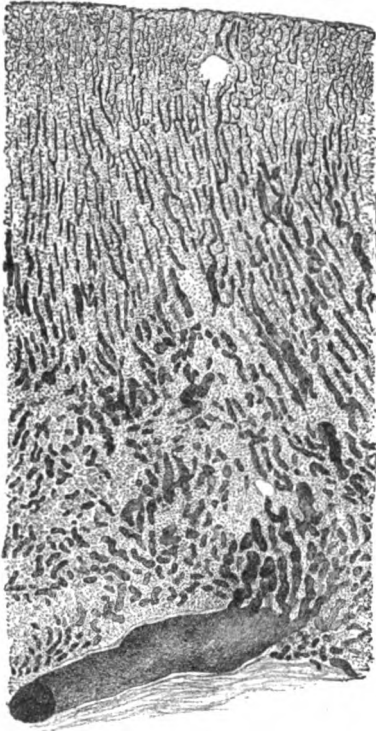


FIG. 276.—Section of injected suprarenal body: the vessels in the lower third of figure are chiefly tributary to the central vein.  $\times 25$ .

associated in position with the chief organ, as when in the liver or kidney, are derived from separated and isolated portions of the principal embryonic area of the suprarenal and, therefore, are supernumerary. The bodies situated in the broad ligament, or in relation with the epididymis, are, on the contrary, probably developed from the atrophic tubules of the Wolffian body and, hence, must be regarded as structures independent of the main suprarenal. The independent bodies never, and the supernumerary ones only in very exceptional cases, possess more than cortical substance, a medulla being wanting.

tical substance of the suprarenal medulla in producing adrenalin seems established.

The suprarenal bodies are conceded membership in the group of viscera now termed *organs of internal secretion*. The other members of this group are the thyroid, the parathyroids, the anterior lobe of the pituitary and, perhaps, the thymus. The specialized areas within the pancreas, the islands of Langerhans, are also regarded as producing a particular substance and, hence, are minute organs of internal secretion. That the substances elaborated within these viscera are of importance is evident from the fact that removal of either the suprarenals, the parathyroids, or the pituitary results in death. Although at present the rôle of the cortex is unknown, the special activity of its

## THE MALE REPRODUCTIVE ORGANS.

THESE include: the sexual glands (the *testes*), the spermatic ducts (*epididymes* and *vasa deferentia*) and their appendages (the *seminal vesicles*), the copulative organ (the *penis*), and certain accessory glands (the *prostate* and the *bulbo-urethral glands*). At first situated within the abdomen, the testes migrate during the last few weeks of foetal life through the inguinal canal into the scrotum, gaining the latter usually shortly before birth. In their descent they are accompanied by blood-vessels, lymphatics, nerves and their ducts, which structures, with the supporting and investing tissue, constitute the *spermatic cord* that extends through the abdominal wall to the scrotum.

### THE TESTIS.

As often employed, the term "testicle" includes two essentially different parts, the *testis*, the true sexual gland, and the *epididymis*, the highly convoluted commencement of the spermatic duct. The testes or testicles proper, the glands producing the seminal elements, are two ellipsoidal bodies obliquely suspended within the scrotum. Each testis measures about 4 cm. in length, 2.5 cm. in breadth and 2 cm. in thickness. With the exception of the posterior border, where the vessels, nerves and ducts enter and emerge, the testis is covered with a serous membrane, the *tunica vaginalis*.

#### Architecture of the Testicle.

—The **framework** of the testicle proper includes a stout fibro-elastic capsule, the *tunica albuginea*, .4–.6 mm. in thickness, that gives form to the organ and protects the enclosed soft glandular tissue. Along the posterior border of the testis the capsule is greatly thickened and projects forwards as the *mediastinum testis*, a wedge-shaped body (2.5–3 cm. long) from which radiate a number of membranous *septa* that pass to the inner surface of the tunica albuginea. In this way the space enclosed by the capsule is subdivided into pyramidal compartments (Fig. 277), the bases of which lie at the periphery and the apices at the mediastinum. These spaces contain collectively from 150 to 200 pyriform masses of glandular tissue, more or less separated from one another, which are the *lobules*. Each of the latter is made up of from one to three greatly convoluted *seminiferous tubules*, held together by delicate vascular intertubular connective tissue. The seminiferous tubules, from .15–.25 mm. in diameter and from 25–70 cm. (10–28 inches) in length, begin as blind canals which are moderately branched and very tortuous

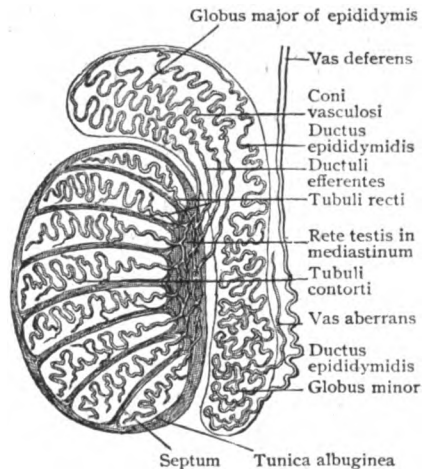


FIG. 277.—Diagram illustrating architecture of the testicle.

(*tubuli contorti*) throughout their course until they converge at the apex of the lobule. Here they pass over, directly or after union with another canal, into the straight tubules (*tubuli recti*) that enter the mediastinum and join to form a close network, the *rete testis*. The latter extends almost the entire length of the mediastinum and consists of a system of irregular

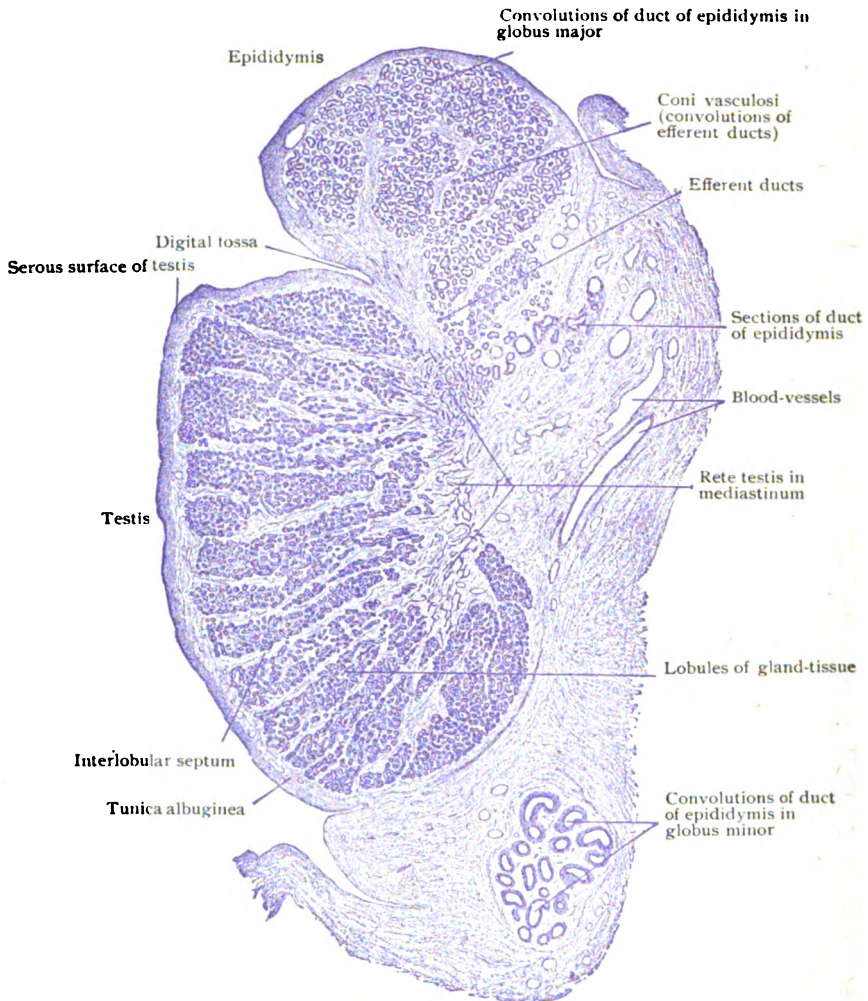


FIG. 278.—Longitudinal section of testicle of child, showing arrangement of framework and gland-tissue and of canals connecting testis with epididymis.  $\times 10$ .

intercommunicating channels lined with cuboidal epithelium. With these passages the canals of the testicle proper end, the immediate continuation of the spermatic path being from 15–20 tubules, the *ductuli efferentes*, that pierce the tunica albuginea along the posterior border of the testis near the upper pole and, forming the progressively tortuous *coni vasculosi*, connect the sexual gland with the beginning of the spermatic duct, the highly convoluted *ductus epididymidis*.

In contrast to the dense fibro-elastic tissue of the framework of the testis, the **interstitial connective tissue** between the seminiferous tubules is

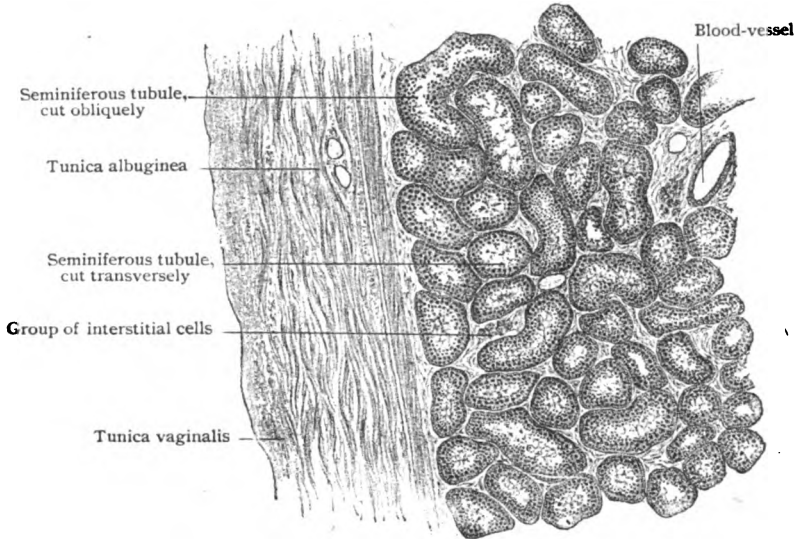


FIG. 279.—Transverse section of testis, showing dense fibrous capsule and adjacent seminiferous tubules.  $\times 30$ .

loose, consisting of delicate bundles of white fibrous tissue with few elastic fibres. In addition to plate-like connective tissue cells, leucocytes and eosinophiles that occur in varying numbers, the intertubular or interstitial stroma contains groups or cord-like masses of peculiar rounded polygonal elements, the *interstitial cells*. These cells ( $15-20 \mu$  in diameter) possess relatively small eccentric nuclei and finely granular cytoplasm that usually lodges numerous brownish droplets, pigment particles and, often, crystalloid bodies in the form of minute needles or rods. The significance of these cells is uncertain, but they are probably modified connective tissue elements concerned in the production of an internal secretion.

**The Seminiferous Tubules.**—The secreting tubules consist of a tunica propria, or basement membrane, which encloses several layers of epithelial cells. These vary not only before and after the attainment of sexual maturity, but subsequent to the latter with functional activity or rest.

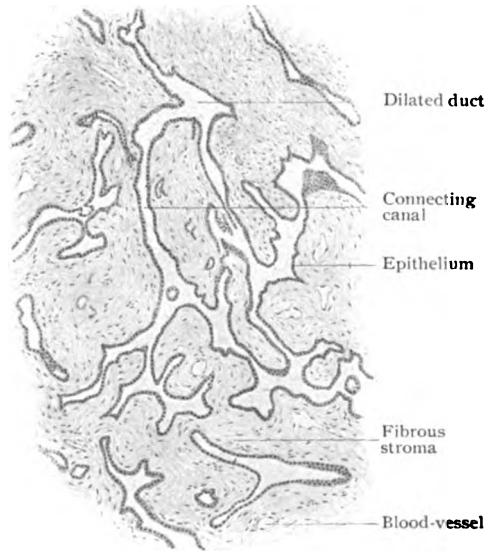


FIG. 280.—Section of mediastinum, showing irregular channels of rete testis.  $\times 60$ .

As seen in sections of the mature human testicle (Fig. 281), the epithelial lining of the seminiferous tubules includes two chief varieties of cells, the *supporting* and the *spermatogenic*. The former, the **Sertoli cells**, take no active part in the production of the spermatozoa, but serve as temporary supports for the more essential elements during certain stages of spermatogenesis. They are elongated irregularly pyramidal in form and rest by expanded bases upon the membrana propria, projecting between the surrounding spermatogenic cells towards the lumen of the tubule. Their large oval nuclei are meagre in chromatin and often lie at some distance from the bases. The outer part of the cytoplasm contains fat-droplets, the inner zone being

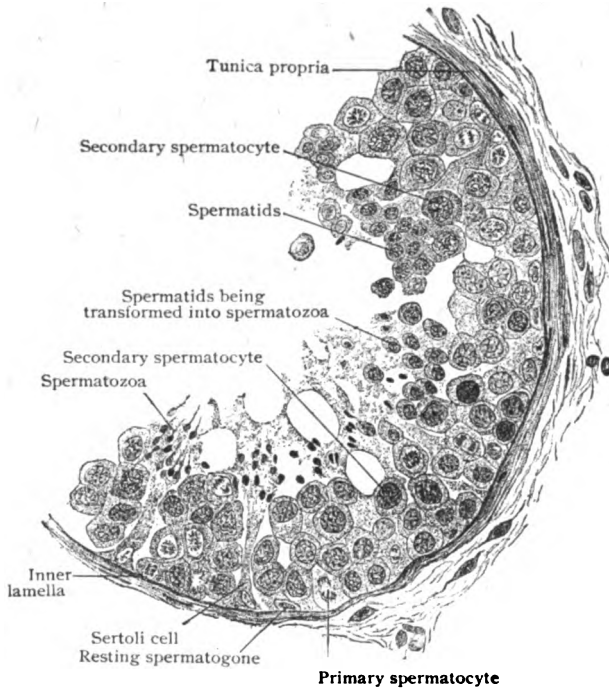


FIG. 281.—Portion of a seminiferous tubule, cut transversely, showing the lining cells in various stages of spermatogenesis.  $\times 350$ .

granular or longitudinally striated. Where the convoluted tubules pass into the straight ones, the Sertoli cells become reduced in height and form a layer of simple columnar cells continuous with the low cuboidal epithelium that lines the rete testis in the mediastinum.

The **spermatogenic cells** are concerned in the cytological cycle, known as *spermatogenesis*, whereby the spermatozoa are produced from the cells lining the seminiferous tubules. They include four forms that stand in the relation of succeeding generations to one another, those representing the oldest lying nearest the membrana propria and the youngest, from which the spermatozoa are directly derived, next the lumen of the tubule.

The first generation, the *spermatogones*, lie at the periphery between the Sertoli cells and, although small round elements, possess nuclei exceedingly rich in chromatin.

The division of the spermatogone results in two cells, of which one retains the position of the parent cell (which it replaces as a new spermatogone destined for a succeeding division), while the other passes inwards, enlarges and becomes a mother cell or *primary spermatocyte*. This element, conspicuous by reason of its size and large nucleus, undergoes mitotic division and gives rise to two daughter cells, the *secondary spermatocytes* or *prespermatids*. The latter almost immediately divide and produce smaller cells, the *spermatids*, by whose transformation the spermatozoa directly arise. It is important to note that the spermatids contain only one-half of the number (probably twenty-four) of chromosomes normal for the ordinary (somatic) cells of the human body, a like reduction (page 9) occurring during the maturation of the ovum. The spermatids, at first small cells with round nuclei, elongate; their nuclei coincidentally become oval and smaller, but rich in chromatin, and shift to the end

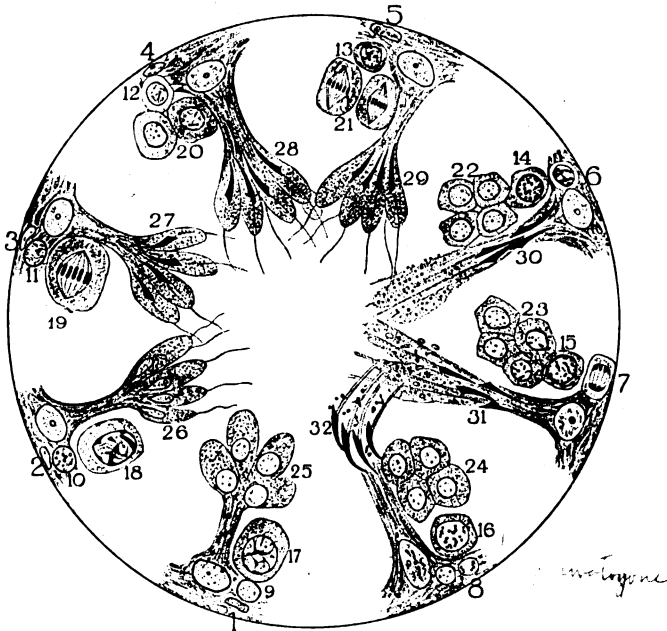

FIG. 282.—Diagram illustrating phases of one complete cycle of spermatogenesis. Sequence of figures shows in detail growth (1-6) and division (7-8) of spermatogone; growth and division of primary spermatocyte (9-19) into secondary spermatocytes; division of latter (20-21) into spermatids (22-24); fusion of these with Sertoli cell to form spermatoblast (25-26); differentiation (27-31) and final liberation (32) of spermatozoa. (After Ebner.)

of the cell most removed from the lumen of the tubule. The modified spermatids now become closely related to a Sertoli cell, with whose cytoplasm they fuse. The structure thus formed, known as the *spermatoblast*, consists of an irregular nucleated conical mass of protoplasm, with the inner end of which the radiating clusters of partially fused spermatids are blended (Fig. 282). The succeeding changes include the transformation of the elongated nucleus of the spermatid into the head, and of its double centrosome (diplosome) into the neck-granules and (according to some) the axial filament of the spermatozoon, while from the cytoplasm of the spermatid its remaining parts are derived. As the spermatozoa become more and more differentiated, they appear as fan-shaped groups in which the heads are always buried within the spermatoblast and the tails directed towards the lumen of the canal. After subsequent separation, the liberated spermatic filaments occupy the centre of the tubule as masses which often occlude the lumen and in which the spermatozoa are disposed in peculiar whorl-like groups. Their completed development, however,

is deferred until they reach the canal of the epididymis, during the passage of which long and highly tortuous path they attain maturity and lose the cytoplasmic remains of the spermatids that adhere for a time to the middle-piece. Production of spermatozoa, which occurs only within the convoluted seminiferous tubules, does not involve uniformly all parts of the tubule, but proceeds with wave-like periodicity; consequently, cross-sections of the same tubule taken a few millimeters apart exhibit different stages of the spermatogenetic cycle.



FIG. 283.—Human spermatozoa; one head is seen in profile.  $\times 560$ .

cells, and, apart from size and minor distinctions, fairly similar in all vertebrates, the spermatozoa present great diversity in size, form and detail and exhibit a high degree of specialization. As ordinarily seen under moderately high magnification (Fig. 283), three parts may be recognized—the *head*, the *neck* and the *tail*. The head is ovoid, flattened in front, so that when viewed in profile it appears pyriform. Although rich in chromatin, the latter is not arranged as threads or networks but is distributed uniformly, so that the head appears homogeneous. Of the 50–60  $\mu$  representing the approximate entire length of the human spermatozoon, the head contributes about one-tenth (5–6  $\mu$ ). The *neck*, uniting the head and the tail, is in man slightly constricted and, therefore, not easily seen, its position being indicated by the ready separation of the head from the tail at this point. It contains the minute anterior and posterior centrosomes or *neck-granules*. The *tail* is regarded as composed of three segments: the *connecting piece* (6  $\mu$ ), the *chief piece* (40  $\mu$ ) and the *end piece* (10  $\mu$ ). The tail is traversed throughout its length by an extremely delicate *axial fibril*, which, with the exception of in the end piece, where the axial fibril is naked, is invested by an attenuated protoplasmic sheath. In the connecting piece (middle piece) the axial fibre is supposed to be surrounded by a spiral fibre, the posterior limit corresponding with a minute *end-disk*. Beyond the recognition of the chief parts of the spermatozoon—the head, neck and tail, little can be seen of the above noted details unless the observer be provided with specially stained preparations and lenses of the highest power and most perfect definition. The living spermatozoa, as seen in fresh semen, display active movements, rapidly changing their position in consequence of the vibrations of the

The **spermatozoa** or **spermatic filaments**, the essential male reproductive elements, are, like the ova, direct derivations of the descendants of the primary indifferent germ-cells. Unlike the ova, however, which are relatively large and often absolutely huge

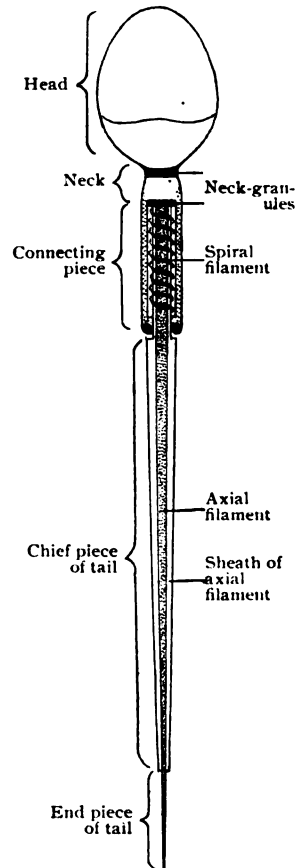


FIG. 284.—Diagram illustrating structural details of human spermatozoon. (Meves.)



long motile flagellum, the tail. The actual rate of their unobstructed progress has been estimated at from 1.5–3.5 mm. per minute. Although less vigorous than in the semen, the spermatozoa often display motion in the secretion of the testicle, as taken from the epididymis. Spermatozoa may continue to exhibit motion for a long time—in the body for several days after death; in properly guarded microscopical preparations of fresh semen movements have been observed after the lapse of over eight days. They may remain active probably for even a longer period within the female generative tract. Although resisting a wide range of temperature, spermatozoa immediately succumb to aqueous solutions containing acids or metallic salts; alkaline solutions, on the other hand, stimulate their motion. Ejaculated **semen** is a composite fluid, consisting of the secretions of the testicle diluted with those from the seminal vesicles, the prostate and the bulbo-urethral glands. It has been estimated that each cubic millimeter of semen contains approximately 60,000 spermatozoa.

### THE EPIDIDYMIS.

The epididymis, the greatly convoluted beginning of the spermatic duct, is a crescentic body that covers the posterior border and part of the outer surface of the testis. Its enlarged upper end or head, the *globus major*, is succeeded by the tapering *body*, at the lower end of which is a second but smaller enlargement, the *globus minor*. The bulk of the *globus major* depends upon the aggregation of from twelve to fifteen conical masses, the *lobuli epididymidis*, formed by the *efferent ducts* and their tortuosities, the *coni vasculosi*, that pass from the upper end of the testis and connect the rete testis with the *canal of the epididymis*. The latter, also called the *ductus epididymidis*, begins in the *globus major*, receives the efferent ducts and becomes greatly convoluted, the remarkably wound single tube measuring, when unravelled, from 5–5.5 meters or from 18–20 feet.

The **efferent ducts** form the conical lobules of the *globus major*, which masses, together with the convolutions of the canal of the epididymis, are enclosed by a fibrous envelope resembling but less robust than the capsule of the testis. The individual tubules and convolutions are held together by delicate vascular connective tissue. The transition of the irregular channels of the rete testis into the efferent ducts (.2–.5 mm. in diameter) is marked by an abrupt change in the character of the lining epithelium, the low cuboidal cells of the former giving place to irregularly ciliated columnar ones within the efferent ducts. This epithelium, moreover, is composed of cells of unequal height, some forming groups of tall cylindrical elements, with or without cilia and variably pigmented, while others occur as groups of low cuboidal cells. In consequence of this inequality, the lumen of the efferent ducts is irregular and the surface of the mucous membrane modelled with minute depressions corresponding to the areas covered by the lower cells. In some cells the border of cilia is replaced by clear caps, which have been interpreted as secretion. Outside a well defined basement membrane the tubules are surrounded with a layer of circularly disposed unstriped muscle, intermingled with numerous elastic fibres.

The **canal of the epididymis**, from .4–.5 mm. in diameter, is lined throughout with stratified columnar epithelium, consisting of a deep layer of small rounded cells, next the well defined basement membrane, and a superficial layer of tall columnar elements, that contain pigment particles and secretion granules. The free surfaces of the columnar cells bear exceptionally long cilia, which, however, are not motile and adhere into conical tufts sur-

mounting the cells. In places the epithelium contains minute tubular diverticula that are regarded as abortive glands. Outside the membrana propria the duct is enclosed by a robust circular layer of unstriped muscle (15–30  $\mu$  thick), which attains its greatest development within the globus minor, near

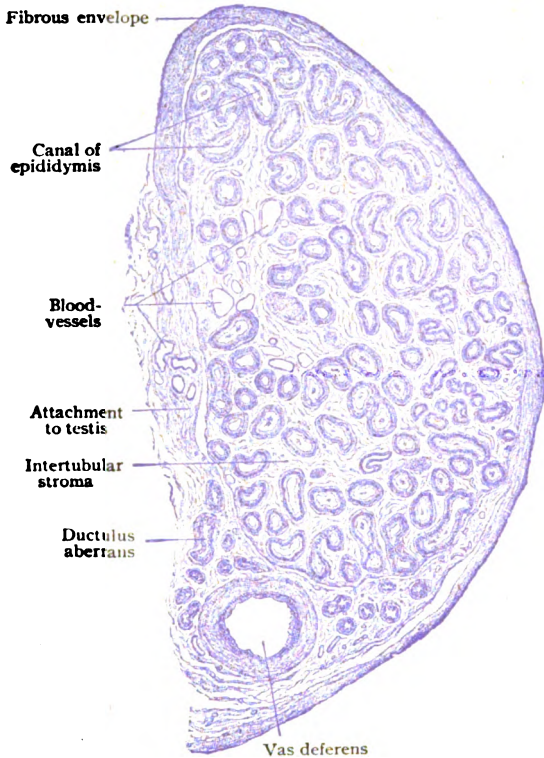


FIG. 285.—Section across lower part of epididymis.  $\times 15$ .

the beginning of the vas deferens. The convolutions of the canal are held together and in place by intervening fibro-elastic tissue. The **blood-vessels** supplying the testicle are branches from the spermatic and deferential arteries, those from the former being distributed especially to the testis and those from the latter to the epididymis. The spermatic branches enter the mediastinum and break up into superficial and deep twigs that follow the tunica albuginea and the septa respectively. They continue within the tracts of intertubular connective tissue and ultimately form rich capillary networks enclosing the seminiferous tubules, immediately outside the basement membrane. The arteries distributed to the epididymis course within the intertubular stroma and likewise resolve into capillaries that

enclose the efferent ducts and the convolutions of the canal of the epididymis. The *veins* arise from the capillary networks; those from the testis, superficial and deep, emerge at the mediastinum and, joining with those from the globus major, concentrate into several stems of considerable size that ascend within the spermatic cord in the anterior part of the pampiniform plexus. The veins from the body and tail of the epididymis unite into a smaller group that ascend in the posterior part of the plexus. The **lymphatics** of the testis begin in the connective tissue surrounding the tubules and follow, in a general way, the course of the veins as a superficial and a deep set. They emerge from the mediastinum as six to eight relatively large trunks, to which the lymphatics of the epididymis are tributary, and accompany the veins in the cord.

The **nerves** of the testicle are chiefly sympathetic fibres destined for the walls of the blood-vessels and the unstriped muscular tissue of the epididymis. They form plexuses enclosing microscopic ganglia around the larger vessels. The relation between the terminal fibres and the tubules includes epilenmar fibrils on the exterior of the basement membrane and, perhaps, a few hypolemmar ones that penetrate between the epithelial cells.

## THE APPENDAGES OF THE TESTICLE.

Under this heading are included several vestigial organs that remain for a variable period, some throughout life, as more or less conspicuous bodies attached to the testis or the epididymis. They claim attention not only on account of their morphological relations, but also because they may become the seat of pathological changes. The most important are: the *appendix testis*, the *appendix epididymidis*, the *paradidymis* and the *ductuli aberrantes*.

The **appendix testis**, also called the *unstalked* or *sessile hydatid*, is a small but fairly constant body, 5–10 mm. in length and less than half as broad, fixed to the upper pole of the testis. It consists of a vascular connective tissue stroma in which lies a minute canal of variable size and extent, lined with columnar epithelium. The appendage represents the atrophic upper end of the Müllerian duct, one of a pair of foetal tubes that in the female embryo give rise to the oviducts, the uterus and the vagina.

The **appendix epididymidis**, or *stalked hydatid*, is a small pyriform sac, from 3–4 mm. in length, containing a clear fluid and lined with cuboidal epithelium. It is variable in form, size and number, two or more sometimes being present, and is probably derived from the tubules of the foetal Wolffian body.

The **paradidymis**, or *organ of Giraldès*, consists of an irregular group of blind tubules, from 5–6 mm. in length, that lies within the lower end of the spermatic cord, above but close to the head of the epididymis. The tubules are lined with cuboidal or columnar ciliated epithelium and are derivatives of the Wolffian tubules.

The **ductuli aberrantes** include tubular appendages, usually an upper and a lower, that extend for an uncertain distance within the epididymis among the convolutions of its duct. The tubules are lined with ciliated columnar or cuboidal epithelial cells and are regarded as originating from the atrophic tubules of the Wolffian body.

## THE SPERMATIC DUCTS.

The spermatic duct, in the more usual and restricted sense, is one of a pair of tortuous canals that connect the epididymis with the urethra and thus provide channels for the escape of the secretion of the sexual glands. Each duct is conventionally described as composed of the *vas deferens* and its *ampulla* and the *ejaculatory duct*; at the upper end of the latter the spermatic duct is connected with the *seminal vesicle*, a saccular organ derived as an outgrowth from the main canal.

**The Vas Deferens.**—This tube extends from the epididymis to the ejaculatory duct and, when straightened out, measures some 45 cm. (18 in.), thus contributing almost the entire length of the spermatic duct. Its diameter is from 2–3 mm. Within the spermatic cord (*pars funicularis*) the *vas* occupies a position behind the other constituents of the cord and may be recognized by the hard cord-like feel imparted by its thick fibro-muscular wall. The latter (1–1.5 mm. thick) encloses a narrow lumen and consists of three coats—the mucous, muscular and fibrous. The *mucous coat* is clothed with epithelium which for a considerable distance resembles that of the canal of the epididymis, being made up of a superficial layer of columnar and a deep one of small rounded cells. Throughout the upper part of the duct, however, the cells are lower, without cilia, and approach a simple

cuboidal type. Numerous particles of pigment are common in their cytoplasm. The tunica propria contains a dense network of elastic fibres within its outer zone. The unusually robust *musculature* of the vas, from .8-1.2 mm. thick, constitutes approximately four-fifths of the entire wall and includes

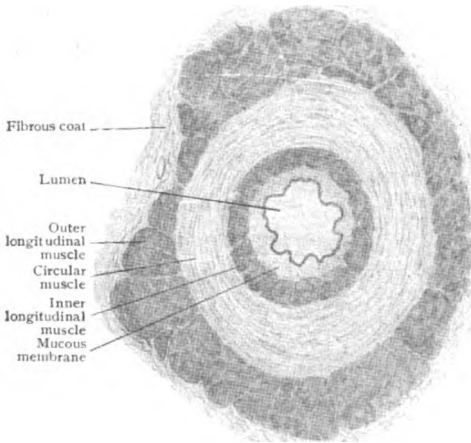


FIG. 286.—Cross-section of vas deferens.  $\times 15$ .

before it becomes the ejaculatory duct, is uneven and humpy in contour owing to the sacculations and tortuosity of the canal and the short diver-

unstripped fibres arranged as an outer longitudinal, a middle circular, and an inner longitudinal layer, the last mentioned layer being much less developed than the outer and middle strata. The *fibrous coat* is composed of closely arranged bundles of fibrous tissue and many elastic fibres. In the funicular part of the duct, between the epididymis and the abdominal wall, the fibrous coat contains strands of unstripped muscle, which belong to the coverings of the cord and constitute the so-called internal cremaster.

The *ampulla*, the somewhat flattened fusiform enlargement of the vas just

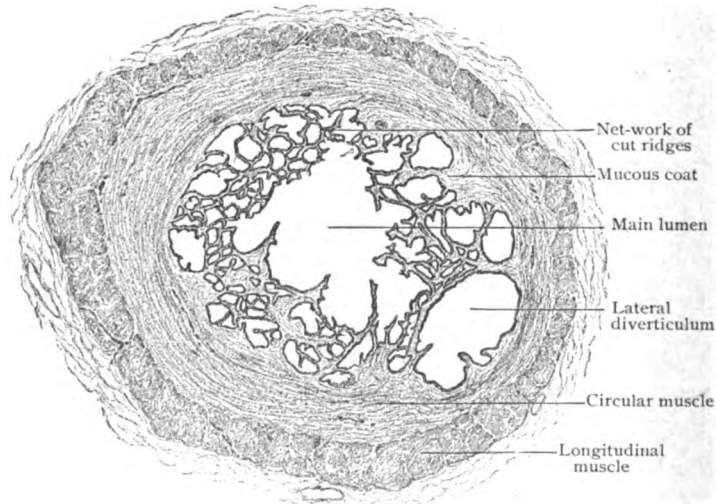


FIG. 287.—Transverse section of ampulla of spermatic duct (vas deferens).  $\times 18$ .

tacula that pass from the main duct at various angles. In its general structure the ampulla corresponds with the vas deferens, its walls, however, possessing a much thinner and less regular muscular coat—the inner longitudinal layer disappearing, the outer one being imperfect, and the orderly

disposition of the circular fibres being disturbed by oblique bundles. The mucous membrane is modelled by numerous ridges and depressions and covered with a single layer of low columnar nonciliated epithelial cells.

**The Ejaculatory Duct.**—This, the terminal segment of the spermatic canal, although apparently formed by the union of the duct of the seminal vesicle and the vas deferens, is the morphological continuation of the vas, from which, when still represented by the embryonic Wolffian duct, the seminal vesicle develops as an outgrowth. The ejaculatory duct penetrates part of the prostate gland and ends in the urethra by a minute opening situated on the urethral crest, at the side of the orifice of the prostatic utricle. It possesses a structure essentially the same as that of other parts of the spermatic canal, its walls, however, being thinner than in the ampulla in consequence of the diminished thickness and incompleteness of the muscle. On reaching the ejaculatory duct the longitudinal muscle disappears and even the remaining circular bundles become greatly reduced and intermingled with fibrous tissue which almost replaces them. The surface of the duct, particularly along its upper wall, is broken by minute depressions and diverticula which recall, in miniature, those modelling the seminal vesicles. Some of these are branched tubules and recall tubo-alveolar glands. The character of the epithelium is inconstant, in places the lining being a single and in others a double layer of low columnar cells; within a short distance of the end of the duct, the epithelium assumes the transitional type found in the prostatic urethra.

**The Seminal Vesicle.**—This organ, one of a pair of sacculated appendages of the spermatic ducts, lies behind the bladder and in front of the rectum. Its general form is pear-shaped, with the base directed upwards and outwards and the abruptly tapering lower end converging to join the spermatic duct. When divested of the fibro-muscular capsule that blends the divisions into a knobbed mass, the organ may be separated into a *chief duct* and *diverticula*, all of which, after repeated windings, end blindly. The lumen of the chief duct, as seen in section (Fig. 289), is irregular, constrictions and dilatations following one another with little order. The seminal vesicle contains a light brownish fluid in which spermatozoa are usually found during the period of sexual activity.

In its general structure, the seminal vesicle resembles closely the ampulla of the vas deferens, possessing a robust muscular coat composed of an inner circular and an outer longitudinal layer of unstriated tissue. The mucous membrane is conspicuously modelled by numerous ridges and pits, so that in sections it appears honeycombed (Fig. 288). The surface of the larger ridges is covered by two or three layers, that of the pits and diverticula by a single layer, of low columnar epithelial cells, many of which contain secretion-particles. Although definite glands are wanting, minute branched tubular canals, lined with low columnar epithelium containing goblet-cells

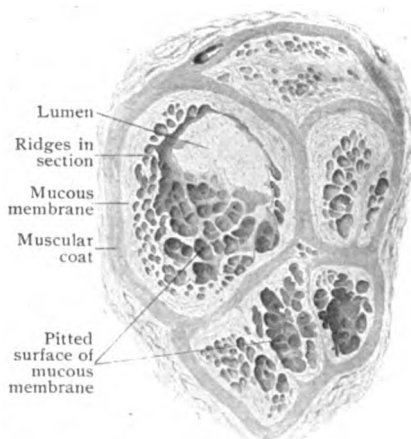


FIG. 288.—Cross-section of seminal vesicle, showing modelling of mucous surface.  $\times 12$ .

and other evidences of secretory activity, extend into the mucosa from the bottom of the deeper recesses. Pigment granules are also constant after the advent of sexual maturity. The tunica propria is rich in elastic fibres. The fluid produced within the seminal vesicles is of importance probably not only in diluting the secretion of the testicle and supplying a medium favorable for the motility of the spermatozoa, but also in completing the volume of fluid favorable for ejaculation (Waldeyer). The spermatic ducts, and not the vesicles, serve as the chief reservoirs for the spermatozoa.

The **blood-vessels** supplying the spermatic duct and the seminal vesicle give off twigs that enter the walls and break up into capillary networks within the muscular and mucous coats. That within the latter occupies the superficial part of the tunica propria, immediately beneath the basement membrane. The **veins** begin within the deeper part of the mucosa and, after piercing the walls of the duct and vesicle, unite into a

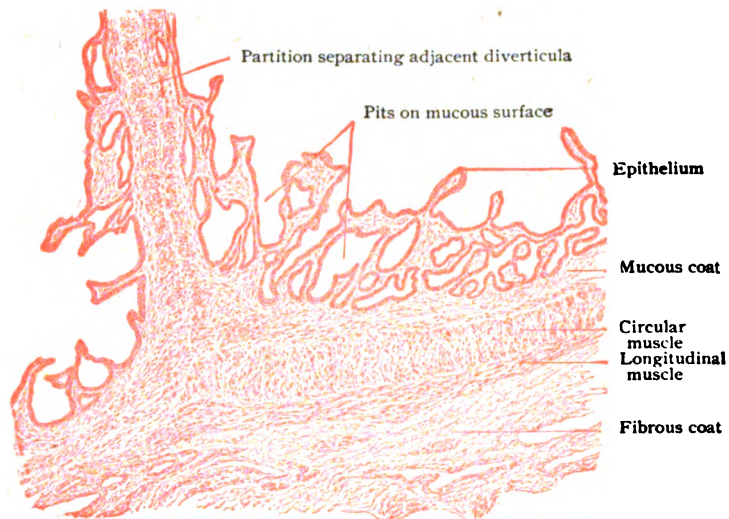


FIG. 289.—Wall of seminal vesicle in longitudinal section, showing pitting of mucous coat.  $\times 45$ .

superficial network, following the vas as the deferential plexus and surrounding the vesicle as the seminal plexus. Within the spermatic cord the former communicates with the pampiniform plexus, the component veins of which are distinguished by unusually well marked muscle.

The **lymphatics** of the seminal duct and vesicle are numerous and arranged as a deeper and a superficial set. The former arise from lymph-channels within the mucous and muscular coats and join the superficial network, outside the dense walls, from which efferent trunks pass to the lymph-nodes.

The **nerves** of the duct and vesicle are derived chiefly from the hypogastric sympathetic plexus; they surround the blood-vessels with plexiform meshes from which fibres pass into the muscular tissue where they form the dense *plexus myospermaticus*. The latter sends fibres to supply the unstriped muscle, while others penetrate the mucous membrane to end mostly within the tunica propria, some fibrils gaining, perhaps, an intraepithelial position.

## THE PENIS.

The male copulative organ consists of three cylinders of erectile tissue—the paired *corpora cavernosa* and single *corpus spongiosum*—united with one another and invested by coverings of fascia and skin. The anterior or upper and flattened surface of the penis is formed by the corpora cavernosa; the posterior or under surface corresponds to the corpus spongiosum, which is traversed by the urethra. The conical *glans penis*, forming the free end of the organ, is continuous with the spongy body which it resembles in structure.

Each of the cylinders of erectile tissue is enclosed by a robust sheath, the *tunica albuginea*, composed of dense fibrous tissue, intermingled with fine elastic fibres but no muscle. The sheath surrounding the corpora

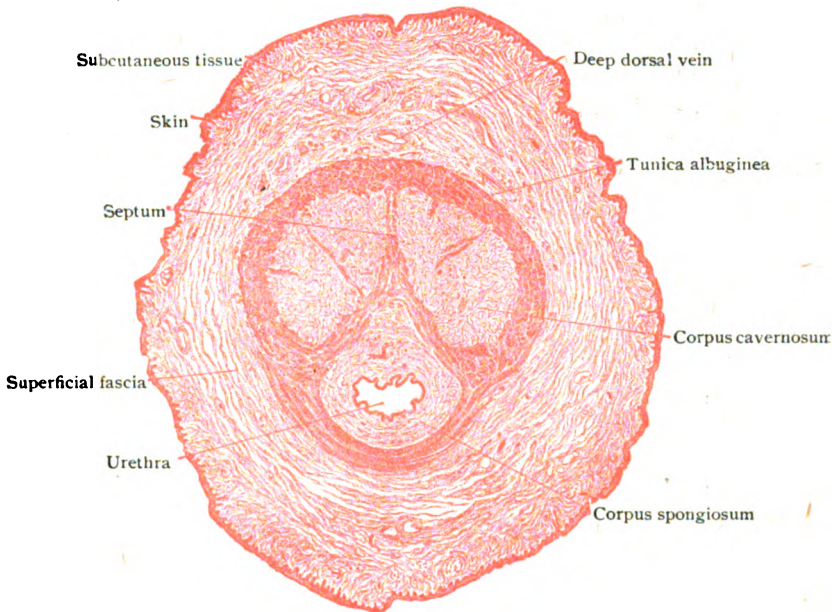


FIG. 290.—Transverse section of penis of child.  $\times 10$ .

cavernosa, which includes an outer longitudinal and an inner circular layer and in places attains a thickness of over 1 mm., is much stronger than that enclosing the spongy body; it is, however, imperfect along the opposed median surfaces of the two cylinders, where it forms the *pectiniform septum*. From the inner surface of the tunica albuginea fibrous septa and trabeculæ are given off which constitute the framework supporting the vessels and nerves and enclosing the characteristic blood-spaces of the erectile tissue. Numerous bundles of unstriped muscle, irregularly disposed, occupy the fibrous trabeculæ and plates that separate the venous spaces, which are thus surrounded by imperfect layers of contractile tissue. The trabecular muscle is most abundant within the cavernous and spongy bodies, and least so within the glans.

The **arteries** conveying blood to the erectile tissue are of two kinds: those coursing within the trabeculæ and nourishing the tissues, *vasa nutritia*, and those carrying blood primarily to the venous lacunæ. The latter are

connected with the arteries either directly, by minute channels, or by intervening capillaries. Within the trabeculae of the deeper parts of the erectile masses, short tortuous branches, *arteriæ helicinæ*, are given off; in the relaxed condition these are twisted and project into the blood-spaces. Both the *arteriæ nutritiæ* and *helicinæ* finally directly communicate by minute canals with the deeper lacunæ of the cavernous tissue. The arteries of the erectile tissue are remarkable for the unusual thickness of their circular

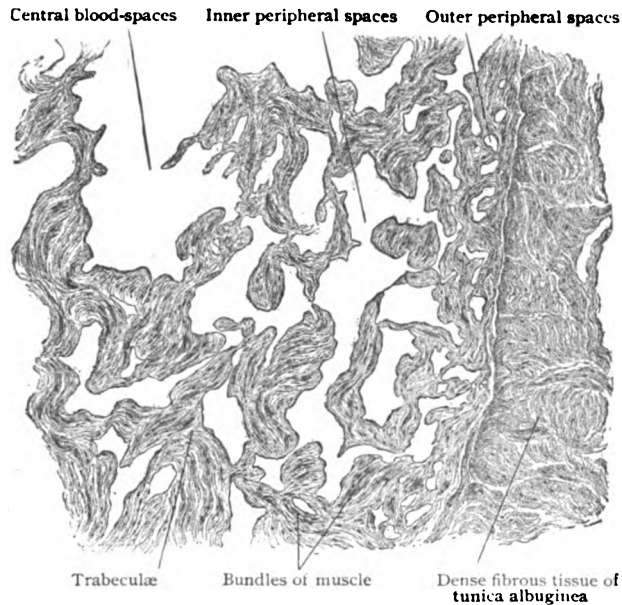


FIG. 291.—Transverse section through periphery of corpus cavernosum, showing erectile tissue.  $\times 50$ .

muscle. In places the intima likewise exhibits excessive thickness due to accumulation of longitudinal muscle, such local augmentations producing cushion-like bulgings that encroach upon the lumina of the arteries.

The **lacunæ**, the blood-spaces that occupy the interstices between the trabeculae, are regarded as venous networks which communicate with the arteries, on the one hand, and with the radicles forming the veins on the other. Beyond the single layer of lining endothelial plates they possess no special wall. Their form and size depend upon the degree of distention, when containing little blood being often mere slits or irregular stellate clefts, while when filled they become more cylindrical. Three tracts may be distinguished: (a) a narrow *outer peripheral zone* of almost capillary spaces, for the most part narrow and triangular in outline; (b) an *inner peripheral zone* of larger spaces of uncertain form and from .15–.20 mm. in diameter; and (c) a *central zone* of still more extensive spaces (1–3 mm.) enclosed by relatively thin lamellæ and trabeculae. The deep **veins** draining the erectile cylinders do not directly open from the blood-spaces, but are formed by tributaries of various size that begin as apertures in the walls of the lacunæ of which they are extensions. The tributaries of the superficial venous trunks, as the dorsal veins, arise chiefly from the venous networks of the peripheral zone. The veins possess unusually strong muscular coats and



exhibit local cushion-like thickenings of the intima, similar to but less marked than those seen in the arteries. The erectile tissue of the corpus spongiosum includes that of the urethral mucosa, produced by the unusual abundance of the venous channels, and that of the spongy body proper, a surrounding tract having much the character of the corpora cavernosa. The spongy body is distinguished by the stoutness of its trabeculæ and the small size of its venous spaces; further, by the absence of arteries opening directly into the lacunæ.

The **lymphatics** of the penis are disposed as superficial and deep vessels. The latter are particularly numerous in the periphery of the glans and send tributaries to aid in forming a deep dorsal lymph-stem along the corresponding vein. The superficial lymphatics are directed chiefly to a superficial dorsal trunk that accompanies the superficial vein and begins by the confluence of networks within the integument.

The **nerves** of the penis include both spinal and sympathetic fibres, the former from the ilio-inguinal and the pudic nerves and the latter from the hypogastric plexus. The integument of the body and glans and prepuce is supplied by the dorsal nerves. The cylinders of cavernous tissue also receive twigs from the pudic nerves, the bulbar branches of which pass to the bulbus urethræ and in addition supply the mucous membrane of the urethra. Each corpus cavernosum receives a deep branch from the dorsal nerve. The sympathetic fibres, destined for the blood-vessels and unstriated muscle of the erectile tissue, continue from the hypogastric to the cavernous plexus; here, joining the dorsal nerves of the penis, twigs are sent to the corpora cavernosa, some terminating in the spongy body. Close networks of nonmedullated fibres have been followed into the involuntary muscle within the blood-vessels and the trabeculæ of the erectile tissue. Certain cerebro-spinal fibres, known as the *nervi erigentes*, from the third and fourth sacral nerves, are supposed to be especially concerned in erection; they are conveyed, in company with the sympathetic fibres, along the paths of the cavernous plexus. In addition to the more usual terminations, the skin of the glans and prepuce is provided with special nerve-endings—tactile corpuscles and genital corpuscles—lying within the papillæ and the Pacinian bodies within the subcutaneous stratum. The path of the sensory impulses lies within the dorsal nerves of the penis.

## THE PROSTATE GLAND.

Although developed as an appendage of the urinary tract and not directly as part of the sexual apparatus, the prostate is functionally so closely related to the generative organs, that it may appropriately be regarded as one of the *accessory glands*, the others being the bulbo-urethral glands.

The prostate gland resembles in form an inverted Spanish chestnut, the base being attached to the under surface of the bladder and the small end, or apex, directed downwards. It is traversed from base to apex by the urethra, and from behind to the urethra by the ejaculatory ducts. The prostate is a tubo-alveolar gland and made up of three chief components—the connective tissue framework, the involuntary muscle, and the glandular tissue. Of these the glandular tissue constitutes a little more than one half of the entire organ and the connective tissue and the muscle each somewhat less than one quarter.

The connective tissue **framework** includes an external fibro-elastic envelope, the *capsule proper*, and a *median septum* which encloses and blends with the walls of the urethra. Between these denser lamellæ, numerous radiating partitions subdivide the organ into from thirty to forty pyramidal

lobules occupied by glandular tissue. The involuntary **muscle**, embedded within the capsule and the ramifications of the connective tissue framework, surrounds the gland-substance as a superficial layer, from which a median septum (about 2 mm. wide) extends ventro-dorsally and encloses the urethra in an annular thickening. The interior of the prostate, therefore, is occupied by a dense fibro-muscular core, or "nucleus," in which the glandular tissue is represented by the narrow prostatic ducts passing towards the

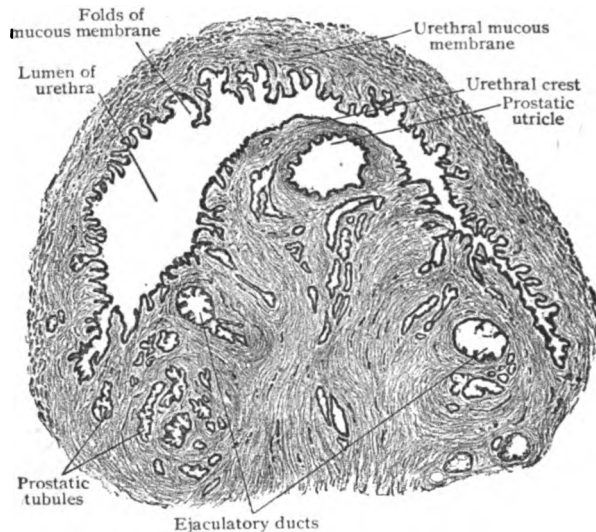


FIG. 292.—Section across prostatic urethra, above entrance of ejaculatory ducts, showing urethral crest with prostatic utricle.  $\times 10$ .

urethra. The muscle is not limited to the foregoing positions, but is found between the divisions of the gland-tissue, the interalveolar septa consisting in places largely of the variously disposed muscle-bundles.

The **glandular tissue** embraces from 30–50 lobules drained by a number (15–30) of excretory tubules, the *prostatic ducts*, that open into the prostatic urethra in the groove on either side of the median elevation, the colliculus. Beginning at their narrow orifices, the ducts pass outward into the lobules, after a course of about 1 cm. dividing into tubules that repeatedly branch and expand into the terminal alveoli. Throughout the greater part of their course the wavy ducts are beset with succular and tubular diverticula, simple or compound, that give the canals irregular lumina and constitute the *duct alveoli* as distinguished from the *terminal alveoli*. The latter form a series of irregularly branched tubular and saccular spaces lined with a single or imperfect double layer of columnar epithelial cells, the secreting elements of the gland. By communication the alveoli form in places networks of spaces of variable form and size. The epithelium of the prostatic ducts and their diverticula corresponds with that lining the terminal alveoli, the change into the transitional variety found in the prostatic urethra not occurring until very near the termination of the ducts.

Peculiar **concretions**, known also as "prostatic calculi" or "amyloid bodies," are almost constantly present within some of the alveoli of the adult organ, especially in advanced life. These bodies (Fig. 294), round or oval in outline and very variable in size (.2–1 mm. and more), usually exhibit a faint

concentric striation and a light brownish color. Their nature is uncertain, but they probably consist of modified secretion and contain a colloid substance.

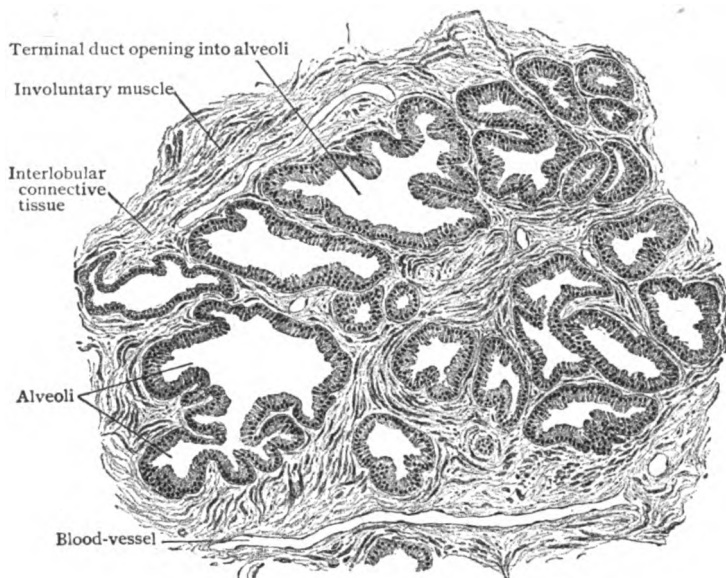


FIG. 293.—Transverse section of prostate gland.  $\times 75$ .

The **secretion** of the prostate gland is turbid or milky in appearance, thin in consistence, slightly alkaline in reaction and possesses a characteristic

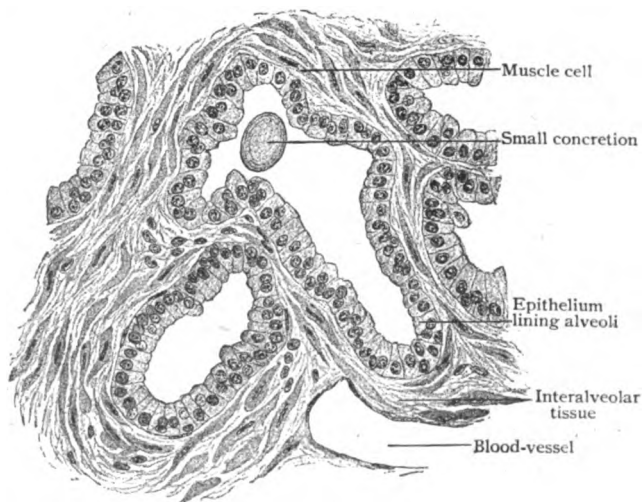


FIG. 294.—Section of prostate gland, showing details of alveoli.  $\times 270$ .

odor. It is discharged into the urethra and mingled with the fluid entering by the spermatic ducts during ejaculation, and probably serves an important purpose in facilitating and perhaps stimulating the motility of the sperma-

tozoa. The "sperm crystals," formed in semen on standing and attributed to the products of the prostate, are not found in the prostatic secretion during life, although frequently present in the gland after death.

The **blood-vessels** supplying the prostate enter the periphery of the gland at various points, particularly in company with the ejaculatory ducts. The interlobular twigs follow the septa and eventually break up into capillary networks that surround the alveoli. The numerous venous radicles form close meshworks within the glandular tissue and around the ducts. The larger veins leave the deeper parts of the organ on each side and unite into a plexus within the capsule, from which pass emergent trunks.

The **lymphatics** arise in lymph-channels around the alveoli. From the deeper networks stems pass to the surface, where they form a second and superficial network from which efferents course in various directions.

The **nerves** of the prostate are chiefly sympathetic fibres derived from the hypogastric plexus, numerous microscopic ganglia occurring along their course. Their ultimate distribution is largely to the walls of the blood-vessels and to the unstriped muscle, additional fibres being traceable into the glandular tissue, outside the basement membrane of the alveoli. Sensory endings include special terminations in the form of lamellated corpuscles, end-bulbs, and peculiar encapsulated endings, which are modifications of the Pacinian and Krause corpuscles. These peculiar end-organs are found chiefly within the fibrous capsule.

#### THE BULBO-URETHRAL GLANDS.

The bulbo-urethral or *Cowper's glands* are two small bodies situated on the under surface of the membranous portion of the male urethra, one on either side of and close to the mid-line. In general form and size (5-8 mm. in diameter) they resemble a pea, although their contour is irregular.

The **ducts** of the glands, about 1.5 mm. in diameter and from 3-4 cm. in length, run forwards and medially and open by small slit-like orifices, often by a common opening, on the lower wall of the bulbus part of the spongy urethra. The glands are mucous tubo-alveolar in type, their terminal divisions ending, after more or less branching, in irregularly sacculated compartments. In places the latter communicate by means of a reticulum of connecting canals. The **alveoli** are lined with low columnar or pyriform cells, among which mucus-secreting elements are plentiful. The cuboidal epithelium that lines the smaller ducts, as well as the dilatations connected with them, is succeeded by columnar cells within the larger ducts until near their termination, where the simple epithelium is replaced by two or more rows of cells. The divisions of the gland are united by intertubular connective tissue and invested by a fibrous envelope containing a considerable quantity of unstriped muscle intermingled with striated fibres derived from the surrounding compressor urethræ muscle. The **secretion** of Cowper's glands is clear and viscid and of alkaline reaction.

The **blood-vessels** supplying the bulbo-urethral glands, branches from the arteries of the bulb, form capillaries that enclose the alveoli and diverticula. The veins begin in the interalveolar tissue and are tributary to those from the bulbus part of the spongy body. The **lymphatics** arise from networks of lymph-channels in the interalveolar connective tissue and join into efferents to the internal iliac lymph-nodes. The **nerves** are from the pudic and include both medullated and nonmedullated fibres, the latter being principally from the sympathetic.

## THE FEMALE REPRODUCTIVE ORGANS.

THE reproductive organs of the female include two groups, the internal and the external organs. The **internal organs** are: the sexual glands, the *ovaries*, which produce the ova; the *oviducts* or *Fallopian tubes*, the canals conveying the ova after these are liberated from the ovaries; the *uterus* and the *vagina*, the passage which embraces the lower end of the uterus above and ends below within the genital cleft. The oviducts, uterus and vagina represent the excretory canals of the sexual glands which in the embryo, as the Müllerian ducts, for a time are separate. After fusion of their lower segments has taken place, the unpaired canal thus formed becomes the vagina and the uterus, the latter being a specialized segment for the reception and retention of the fertilized ovum during gestation. The **external organs**, termed collectively the *vulva* (pudendum muliebre) include: the *clitoris*, the *labia* and the thereby enclosed *vestibule* and *vaginal orifice*, and the *glands of Bartholin*. Although morphologically belonging to the integument, the *mammary glands* may be conveniently regarded as appendages to the reproductive organs.

### THE OVARIES.

The ovary, one on either side of the body, is the sexual gland proper, within and from which are developed and liberated the mature maternal germ-cells, the ova. It is a solid body, resembling in form a large almond, and in the adult lies against or near the lateral pelvic wall invested by modified peritoneum continued from the posterior surface of the broad ligament of the uterus. That portion of the attached anterior border through which the vessels and nerves enter and emerge is known as the *hilum*. The surfaces of the mature ovary are not even, as in early life, but modelled by rounded elevations of uncertain size and number and by irregular pits and scars. The elevations are due to the underlying egg-follicles in different stages of growth, while the scar-like areas indicate the position of corpora lutea which replace the ruptured egg-follicles. The average dimensions of the adult ovary are: 36 mm. in length, 18 mm. in breadth and 12 mm. in thickness. After cessation of menstruation, about the forty-fifth year, the ovary decreases in size and weight, in old women being reduced to one half or less of its normal proportions.

The ovary consists of two principal divisions: the *cortex* (zona parenchymatosa), a narrow peripheral zone, from 2–3 mm. thick, that forms the superficial part of the organ; and the *medulla* (zona vasculosa), that embraces the deeper and more central remaining portion of its substance. The cortex alone contains the characteristic Graafian or egg-follicles and the ova, while the medulla is distinguished by the number and size of the blood-vessels, especially the veins.

**The Cortex.**—Seen in sections of the functioning organ, the cortex appears to consist chiefly of the compact *ovarian stroma*, a modified connective tissue composed of spindle-shaped cells and fibrous tissue. The *stroma-cells* are arranged in bundles extending in all directions and, hence, are seen cut in different planes. Immediately beneath the modified mesothelium, the so-called *germinal epithelium*, that covers the free surface, the stroma is disposed with greater regularity and forms a narrow compact superficial stratum, the *tunica albuginea*, in which the ova are absent. Within the subjacent and looser stroma lie the most characteristic components of the cortex, the *Graafian* or *egg-follicles*, that represent what has been called the “gland-sub-

stance" (Stöhr) of the ovary. The follicles are in different stages of development, but, for the most part, are small, inconspicuous and immature. Corresponding with their development, the egg-sacs are divided into *primary*, *growing* and *maturing follicles*. In general, the youngest and least developed lie nearest the surface, the more advanced deep and towards the medulla, while those approaching full development appear as huge vesicles that may

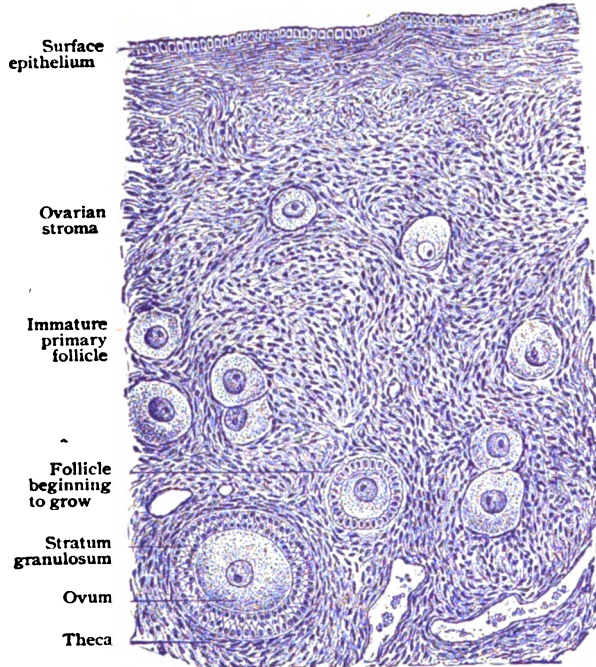


FIG. 295.—Section of cortex of ovary of young woman, showing primary and growing follicles within the ovarian stroma.  $\times 190$ .

occupy not only the entire thickness of the cortex, but produce marked elevation of the surface. The entire number of ova, as estimated from the ovaries of a seventeen-year-old subject, is approximately 35,000 for both ovaries.

The immature primary follicles are microscopic in size ( $40-60 \mu$ ) and, in the ovaries of young adults, form an incomplete and scattered single, or at most double layer. Each follicle includes the centrally situated young egg or *ovulum*, surrounded by a single row of flattened epithelial or *mantle cells*, which are directly lodged within the interstices of the stroma-tissue. The ova and the mantle cells are derived from the proliferation of the *germinal epithelium*, the modified mesothelium covering the germinal ridge on the median surface of the Wolffian body. Very early certain cells are distinguished by their exceptional size and large clear nuclei. These are the primary ova, around which the small descendants of the germinal epithelium become arranged as the mantle cells. Soon an active intergrowth occurs between the proliferating epithelium and the invading vascular connective tissue of the Wolffian body that becomes the ovarian stroma. The latter increases so rapidly that the primary follicles, single or in small groups, become separated by augmenting tracts of stroma-tissue.

The *primary ova*, approximately spherical and  $40-50 \mu$  in diameter, may remain for years, sometimes from early infancy to advanced age, practically unchanged, until they undergo either atrophy, as do most of them, or further growth leading, under

favorable conditions, to the production of mature germ-cells. Of the thousands of primary ova contained within the ovaries just before puberty, only comparatively few attain perfection, between 300-400 probably being the maximum number liberated during the usual period of sexual activity. When enclosing an ovum destined for complete development, the primary follicle enters upon a period of active growth, the flat mantle cells of the egg-sac changing into a single layer of cuboid epithelium.

The **growing follicles** are distinguished by the rapid proliferation of their cuboid epithelium that results in the production of a stratified *follicular epithelium* surrounding the ovum. Outside this polygonal epithelium, the stroma condenses into a connective

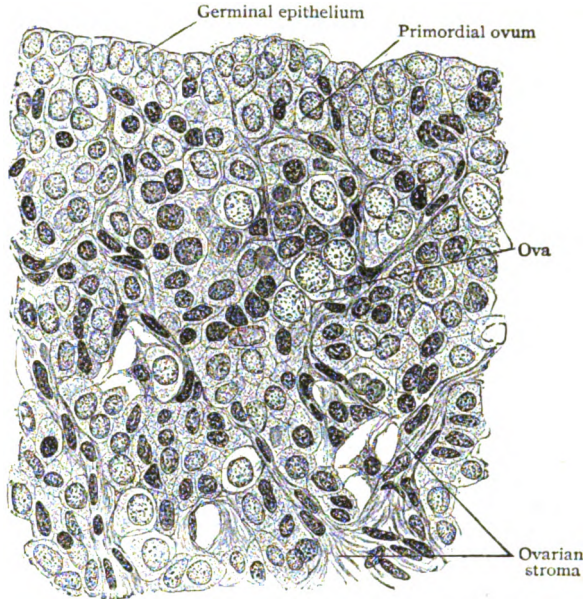


FIG. 296.—Section of developing ovary from human embryo, showing intergrowth between derivatives from germinal epithelium and stroma-tissue from Wolffian body.  $\times 560$ .

tissue envelope, the *theca*, which subsequently differentiates into an *outer* and an *inner tunic*, the former being composed of concentrically disposed fibrous tissue and the latter of round or spindle cells and numerous capillaries. After the formation of the follicular epithelium, the ovum itself begins to grow, the expansion proceeding uniformly and affecting all parts of the cell, including the nucleus and nucleolus. It attains its maximum diameter long before the follicle reaches full growth. Through the activity of the follicular epithelium the egg becomes invested with a protecting envelope, the *zona pellucida* or *radiata*, after which little or no further increase in the size of the egg occurs. At first solid, the growing follicle is converted into a vesicle containing fluid by, at first, the progressive vacuolation and breaking down of the cells of the middle layers of the follicular epithelium and, later, by the transudation from the surrounding blood-vessels. This fluid, the *liquor folliculi*, increases to such an extent that it soon occupies the greater part of the expanding egg-sac, now entering upon its final stage of growth.

The **maturing follicles**, also known as *vesicular*, occupy the deeper parts of the cortex and reach to the medulla. With their continued expansion they appropriate more and more of the cortex, until the entire thickness of the latter and, sometimes, part of the medulla are occupied by the ripe follicle, which just before its rupture attains a diameter of from 1-2 cm. and models the free surface of the ovary as a tense rounded elevation. After rupture and liberation of the ovum, the follicle is converted into a *corpus luteum*.

The wall of the ripe follicle consists of a well-developed capsule or *theca*, a delicate *membrana propria*, against whose inner surface lie the follicular cells, known as the *stratum granulosum*, surrounding the space filled with the liquor folliculi. Oppo-

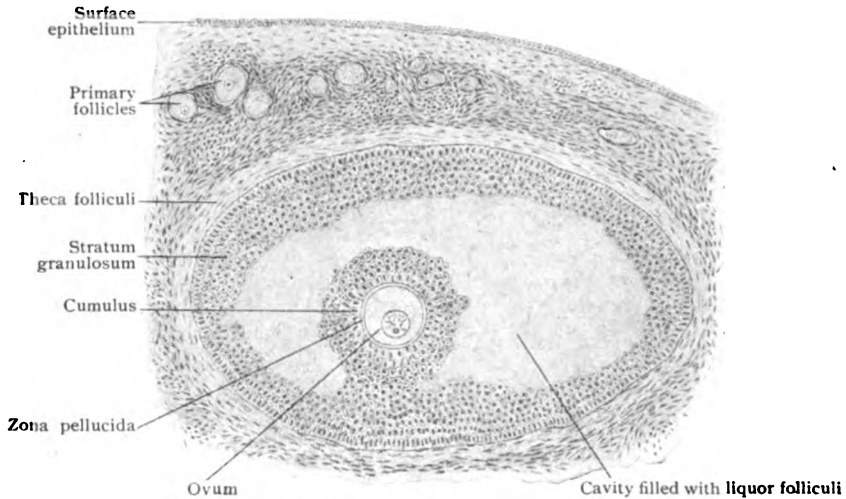


FIG. 297.—Section of ovary, showing partially developed Graafian follicles.  $\times 90$ .

site the point where rupture takes place, the stratum granulosum is prolonged into a pedunculated spherical mass of epithelial cells that projects into the cavity. This




FIG. 298.—Almost mature human ovum taken from fresh ovary. Ovum, with germinal vesicle and spot, is encircled by clear zona pellucida, which is surrounded by follicular epithelium.  $\times 250$ . (Waldeyer.)

mass, the *cumulus*, encloses the ovum and on section appears as an epithelial ring, the *corona radiata*, that encircles the zona pellucida and the ovum and consists of two or three layers of radially disposed cells. The membranous zona pellucida is the product of the follicular cells and, therefore, not a part of the ovum proper. It sometimes exhibits a radial striation, hence is often called *zona radiata*, probably due to penetrating processes from the superimposed epithelial cells.

The human ovum when about to be liberated from the Graafian or egg-follicle possesses a diameter of from .2-.3 mm. Its cytoplasm, the *vitellus* of the older writers, exhibits differentiation into a peripheral *ooplasmic* and a central *deu-*

*toplasmic* zone, the latter being dark and conspicuous on account of the irregular refraction of the enclosed yolk-particles. The presence of a distinct cell-wall, or *egg-membrane*, in the human ovum is doubtful, although



demonstrable in some mammals. The spherical egg-nucleus, the *germinal vesicle*, lies eccentrically placed within the deutoplasmic zone and measures from 30–45  $\mu$ . It is bounded by a sharply defined nuclear membrane and contains the nucleolus, or *germinal spot* (4–8  $\mu$ ), and the nuclear reticulum.

**Corpus Luteum:**—When the follicle approaches maturity, the inner layer of the theca becomes the seat of great activity, the blood-vessels increasing and the cells undergoing rapid proliferation and extraordinary growth, the enlarged elements becoming filled with a yellowish substance and transformed into *lutein cells*. Coincidentally the follicular epithelium suffers fatty change which results in the partial

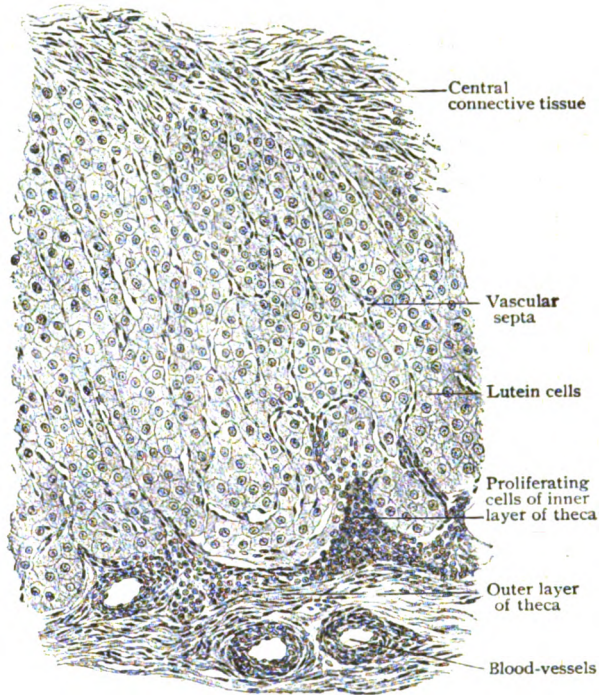


FIG. 299.—Section of human corpus luteum.  $\times 70$ .

disintegration of the cumulus and freeing of the ovum, enclosed by the cells of the corona radiata, into the cavity of the follicle. When the latter ruptures the expulsion of its contents is followed by hemorrhage into the cavity of the follicle and, soon afterwards, by closure of the opening in the sac. The position of the rupture corresponds to the place (*stigma*) where the wall of the follicle is most distended and least vascular and, hence, possesses least vitality and resistance. The rapid proliferation and growth of the lutein cells produces an irregularly plicated wall of increasing thickness that encloses the remains of the follicular epithelium and invades the hemorrhagic mass. The latter is gradually absorbed until the encroaching projections of lutein cells and invading vascular connective tissue meet and the cavity of the follicle is obliterated, its former position being subsequently indicated by a central core of connective tissue. The complex thus formed, composed of lutein cells and septa of vascular connective tissue, is the *corpus luteum*.

When the liberated ovum becomes fertilized, the corpus luteum grows to huge dimensions and forms a conspicuous oval mass that may approach 3 cm. in length and occupy a considerable part of the entire cortex. When associated with pregnancy it

is termed the *corpus luteum verum*. If impregnation does not occur, the yellow body, now called the *corpus luteum spurium*, is smaller and seldom exceeds from 1.5-2 cm. The classic distinction of "true" and "false" has no anatomical basis, since, apart from size, both forms are structurally identical. The assumption, that the presence of a large corpus luteum is proof of pregnancy, must be accepted with much caution, since yellow bodies, of unusual size are sometimes observed in ovaries of virgins. With the production of a solid corpus luteum and the absorption of the blood, evidences of the latter remaining for a long time as hematoidin crystals, the active rôle of the lutein cells is finished. These elements now lose their yellow pigment (*lutein*), undergo fatty change and finally entirely disappear. The connective tissue which now constitutes the entire mass, undergoes hyaline change, becoming clear and nonfibrous, while the aging corpus luteum loses its former appearance and is

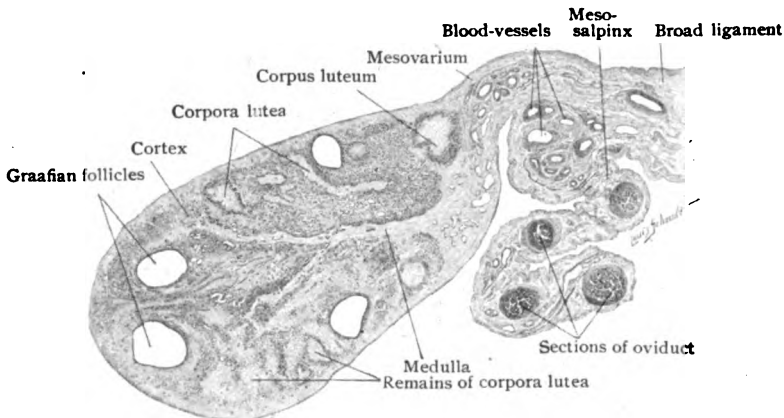


FIG. 300.—Cross-section through ovary, oviduct and part of broad ligament.  $\times 4$ .

transformed into an irregular body, light in color and sinuous in outline, sometimes termed the *corpus albicans*. The corpus luteum is now regarded as an organ of internal secretion, which produces a stimulant of the uterine mucosa, for the formation of the decidua, and of the mammary gland.

**The Medulla.**—The vascular central zone of the ovary, the medulla, consists of comparatively loose stroma-tissue, composed of irregularly felted bundles of fibrous tissue rich in elastic fibres, supporting the vessels and nerves. In the mature ovary, with the exception of occasional encroaching Graafian follicles that are ripening, egg-sacs are not found within the medulla. On the other hand, it contains many blood-vessels some of which, when seen in cross-section, may be mistaken by the inexperienced observer for sections of follicles. The larger vessels are surrounded by considerable tracts of involuntary muscle, which are continuous in part with those of the utero-ovarian ligament, through the hilum and mesovarium, the fold of peritoneum which attaches the ovary to the broad ligament. The veins are particularly large and appear in sections as huge blood-spaces of irregular outline, in consequence of their tortuosity and plexiform arrangement.

The **blood-vessels** supplying the ovary are four or five branches from the anastomotic arch formed by the ovarian and uterine arteries. These branches, the *arteriæ propriae*, reach the medulla through the hilum as closely grouped tortuous vessels. On gaining the interior of the ovary, each stem divides into two *medullary* or *parallel arteries* that proceed directly towards the opposite free margin of the organ, lying just beneath the cortex to which

they distribute *cortical branches* at regular intervals. In their course towards the periphery the cortical branches supply hundreds of *follicular twigs* to the egg-sacs, each of the latter being provided with a rich vascular network

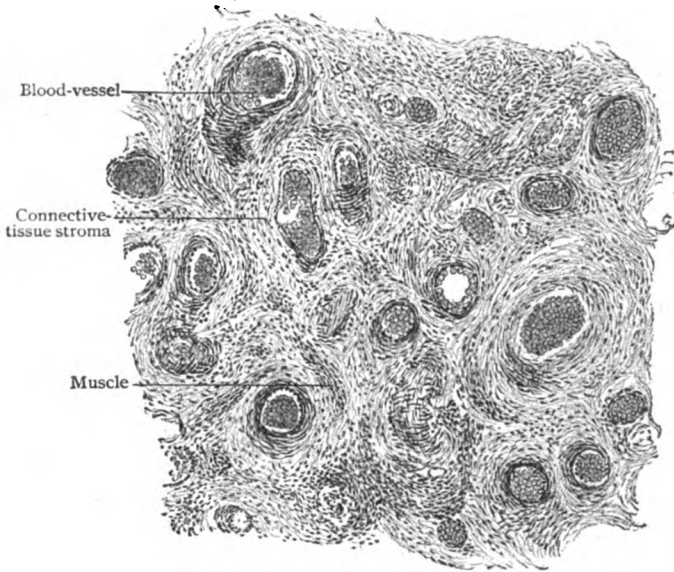


FIG. 301.—Section of medulla of ovary, showing numerous blood-vessels and fibro-muscular stroma.  $\times 75$ .

that anastomoses with two or more follicular twigs. At the periphery of the organ, the blood within the cortical arterioles reaches the veins through an intervening capillary network. The *veins* follow the general arrangement of the arteries in the cortex and medulla; the pairs of parallel veins, however, do not unite into single stems, but emerge from the hilum as independent trunks.

The **lymphatics** begin in the cortex as networks of spaces within the thecæ surrounding the enlarging follicles. From these radicles the larger and irregular channels enter the medulla, where they form converging stems that follow the blood-vessels and leave the hilum as 7-9 trunks.

The **nerves** supplying the ovary are from the sympathetic plexus surrounding the ovarian artery and are composed, for the most part, of non-medullated fibres. They accompany the arteries through the hilum into the ovary and are distributed chiefly to the walls of the blood-vessels, around the larger of which the terminal plexuses are formed. From the fairly close cortical plexus twigs pass to the larger follicles, the ultimate relation between

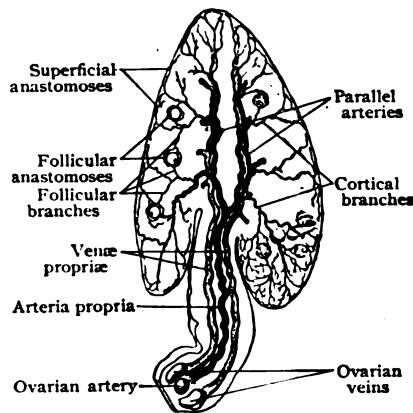


FIG. 302.—Diagram illustrating arrangement of ovarian blood-vessels. (Clark.)

the latter and the surrounding fibres being uncertain. It is probable, however, that the fibrils end mostly in the walls of the follicular blood-vessels, although some are said to penetrate to the follicular epithelium. The existence of sympathetic ganglia within the medulla has not been established.

#### RUDIMENTARY ORGANS REPRESENTING FŒTAL REMAINS.

In the male the Wolffian body and its duct play very important rôles in the development of the excretory canal for the sexual gland, while the Müllerian duct remains rudimentary. In the female the converse is true, the Müllerian ducts forming the excretory canals—the oviducts, the uterus and the vagina—while the Wolffian structures are of secondary importance and

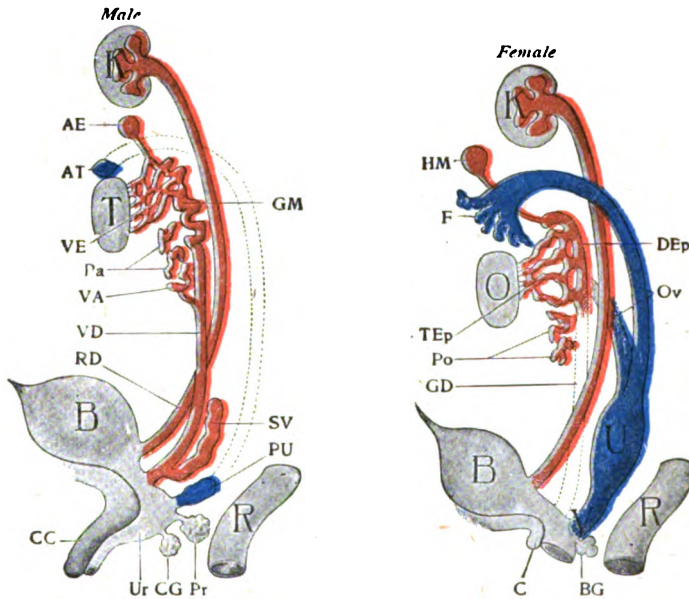


FIG. 303.—Diagrams illustrating differentiation of two sexes; derivatives from Wolffian body are red, those from Müllerian duct are blue. *Male*: T, testicle; VE, vasa efferentia; GM, globus major; VD, vas deferens; Pa, paradidymis; VA, vas aberrans; SV, seminal vesicle; AT, appendix testis; AE, appendix epididymidis; B, bladder; PU, prostatic utricle; Pr, prostate; Ur, urethra; CG, Cowper's gland; CC, corpus cavernosum; R, rectum; RD, renal duct; K, kidney. *Female*: O, ovary; Ov, oviduct; F, fimbria; U, uterus; V, vagina; DEp, duct of epoöphoron; TEp, tubules of epoöphoron; Po, paroöphoron; HM, hydatid of Morgagni; GD, Gartner's duct; BG, Bartholin's gland; C, clitoris; K, kidney; R, rectum. (Modified from Wiedersheim.)

give rise to rudimentary and functionless organs, situated chiefly in the vicinity of the ovary and the Fallopian tube between the layers of the broad ligament. These foetal remains include: the *epoöphoron*, *Gartner's duct*, the *paroöphoron*, and the *vesicular appendages*.

The **epoöphoron**, also called the *parovarium* or *organ of Rosenmüller*, lies between the layers of the broad ligament, in the area bounded by the ampulla of the oviduct, the ovarian fimbria and the tubal pole of the ovary. It is flat, triangular or trapezoidal in outline, and measures from 2–2.5 cm in length. It consists of from eight to twenty narrow wavy tubules, the *ductuli transversi*, which, beginning with closed and slightly dilated ends, diverge from the vicinity of the hilum of the ovary and join, almost at right angles, a common chief duct that lies close and parallel to the oviduct.

bearing to the smaller tubules the relation of the back of a comb to its teeth. The transverse tubules are the remains of the sexual tubules of the Wolffian body; the common canal, the *ductus longitudinalis*, is closed at both ends and represents a persistent portion of the Wolffian duct. The longitudinal duct may be interrupted and connected with the tubules in groups, or, on the other hand, it may be prolonged as Gartner's duct far beyond its usual length. In the child, the transverse tubules (.3-.4 mm. in diameter) usually possess a lumen, but later in life they may undergo partial or complete occlusion and may be the seat of cysts. The walls of the tubules and duct consist of a fibrous coat, which sometimes contains bundles of unstriated muscle, lined with a single layer of epithelial cells that vary in form from low cuboid to columnar and occasionally bear cilia.

**Gartner's duct** results from the more or less extensive persistence of portions of the Wolffian duct that usually disappear by the end of foetal life; it is, therefore, a continuation, direct or interrupted, of the longitudinal duct of the epoöphoron. When complete, as it very exceptionally is, the duct continues from the epoöphoron, along the oviduct and the side of the uterus, to the lower end of the vagina. Such extensive persistence is unusual, Gartner's duct being mostly limited to the lower part of the body and the upper cervix of the uterus. The canal is lined with a single layer of columnar epithelium and beset with uncertain lateral diverticula, which may be short branched tubules resembling glands. Accumulations of secretion within the duct or its diverticula may lead to the production of cysts.

The **paroöphoron** is an inconspicuous rudimentary organ, distinct at birth but usually disappearing after the second year, that lies within the broad ligament between the epoöphoron and the uterus. It consists of a small irregularly round group of blind canals, lined with a single layer of columnar epithelium, that often resemble the Wolffian tubules, which structures, in fact, they represent. A second group of similar rudimentary tubules lies lateral to the epoöphoron. It is this group, perhaps, that should be regarded as the paroöphoron proper and the homologue of the paradidymis in the male. The tubules may be the seat of cysts.

The **vesicular appendages** include the small vesicles or hydatids attached to the broad ligament by longer or shorter stalks. They comprise two groups, the one being represented by the conspicuous long-stalked hydatids of Morgagni and the other by the smaller vesicles, varying in form and size, connected by short stems. The *hydatid of Morgagni* is a spherical or pyriform thin-walled sac, that contains a clear fluid and usually measures from 4-8 mm. in diameter. The vesicle is attached by a slender stalk, from 1.5-4 cm. long, to the anterior surface of the broad ligament and is continuous with the upper blind end of the longitudinal duct of the epoöphoron. The hydatid consists of a fibrous coat, lined by a single layer of columnar epithelium, and covered externally by a delicate prolongation of peritoneal tissue. The *small vesicles* are attached to the anterior surface of the broad ligament, usually over the epoöphoron. The origin and morphological significance of the vesicular appendages have occasioned much discussion, but it may be accepted as established that the hydatid of Morgagni is derived from the upper end of the Wolffian duct, and is, therefore, the equivalent of the appendage of the epididymis. The smaller vesicles, which correspond in structure with the larger one, probably owe their origin to the distention and elongation of some of the transverse tubules of the epoöphoron, and, hence, are derivations of the Wolffian tubules.

## THE OVIDUCTS.

The oviduct or *Fallopian tube*, also called the *tuba uterinæ*, is, in principle, the excretory canal of the sexual gland, since it conveys the ova liberated from the ovary to the uterus, into which it opens. The relation between the ovary and its duct is exceptional, in that these organs are not continuous but only in apposition, the ova liberated from the ruptured Graafian follicles finding their way into the expanded end of the oviduct. This canal, one on each side of the body, lies within the free border of the broad ligament and extends laterally from the uterus to the ovary, in relation with the mesial surface of which it ends after repeated windings. The entire

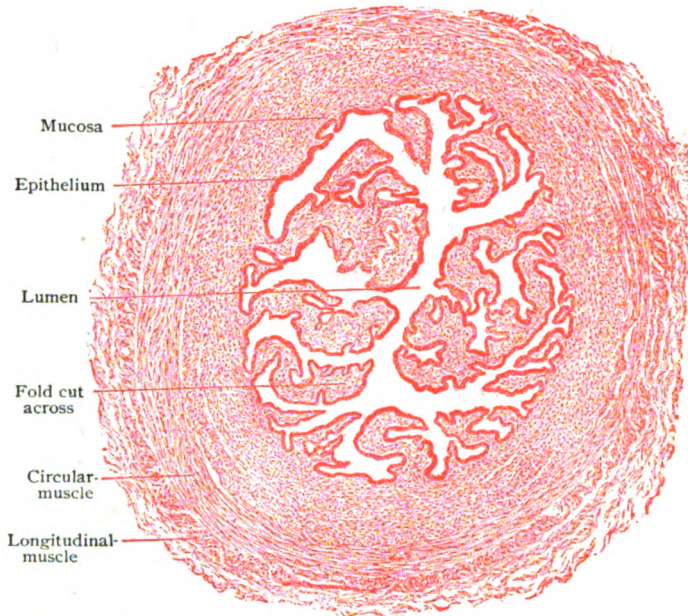


FIG. 304.—Transverse section of oviduct near outer end of ampulla.  $\times 35$ .

length of the tube is about 11.5 cm. ( $4\frac{1}{2}$  in.), its diameter increasing from 3–4 mm. at the *isthmus*, next the uterus, to from 6–8 mm. at the outer limit of the *ampulla*, where the canal suddenly expands into the terminal trumpet-shaped *infundibulum*. The mucous membrane lining the oviduct is thrown into longitudinal folds, which become progressively more marked towards the outer end, so that cross-sections of the ampulla present a lumen of complex outline owing to the projection of primary and secondary plications (Fig. 304). At the irregularly notched or fimbriated margin of the *infundibulum*, the mucous lining of the tube is directly continuous with the peritoneum. The exceptional relation of the tubal mucosa to the serous membrane, this being the only place in the body where a mucous tract directly communicates with a serous sac, is a persistence of the similar relation of the embryonal Müllerian duct, from which the oviduct is directly derived.

The **wall proper** of the oviduct consists of the *mucous* and *muscular coats* and is embedded within the loose connective tissue of the broad ligament (*tunica adventitia*), and surrounded by the *serous coat*, which completely invests the duct with the exception of the narrow interval through which the tubal vessels and nerves pass. The wall is thickest and firmest in the isthmus, less so in the ampulla, and thinnest and most relaxed in the infundibulum and fimbriæ. The mucous coat is thrown into longitudinal folds, which in the ampulla attain much complexity and in transverse sections appear as branching villus-like projections.

The **mucous membrane** is covered by a single layer of columnar epithelium provided with cilia, whose current is directed towards the uterus, thus favoring the progress of the ova along the tube but retarding the ascent of the spermatozoa. The tunica propria consists of bundles of fibrous tissue, is rich in cells and directly continuous with the intermuscular connective tissue. Its deepest layer often contains irregular strands of muscle-bundles, which suggest a *muscularis mucosæ*. The **muscular coat**, upon which the mucosa rests without the intervention of a submucous layer, is most robust towards the uterus and thinnest at the infundibulum. It includes an inner circular and an outer longitudinal layer of unstriated muscle. At the isthmus, where the firmness of the tubal wall depends chiefly on the muscular coat, the circular layer is the thicker (.5-1 mm.) and the longitudinal one is incomplete; towards the infundibulum the reverse is true, the longitudinal layer being better developed and the circular muscle reduced to .2 mm. or less. The surrounding fibrous tissue, sometimes described as a distinct coat, the *tunica adventitia*, blends with the fibro-elastic stroma of the investing peritoneum, which may be regarded as the **serous coat**. Since these structures consist of the usual connective tissue and mesothelial elements of peritoneum (page 175), a special description is unnecessary.

The **blood-vessels** supplying the oviduct, derived from the tubal branches of the uterine and ovarian arteries, gain the wall of the tube along the nonperitoneal tract and break up into numerous branches between the outer and inner muscular layers, from which capillaries pass to the muscular tissue and to the mucous membrane. The veins begin within the mucosa and join the many intermuscular channels, from which tributaries pass to the subserous meshwork. The **lymphatics**, after emerging from the wall of the tube within which they begin as irregular spaces between the fibrous bundles of the muscular coat, form three or four stems that accompany the blood-vessels. The **nerves** are numerous and chiefly sympathetic fibres from the ovarian and the uterine plexus. Within the subserous tissue they form a peritubal plexus, from which twigs penetrate the wall of the canal to supply chiefly the involuntary muscle, some fibres entering the mucosa.

## THE UTERUS.

The uterus or womb is a hollow pear-shaped muscular organ, receiving the oviducts above and opening into the upper part of the vagina below, in which the fertilized ovum is retained and develops, and from which the resulting fœtus is expelled at the completion of gestation. It measures about 7 cm. in length, of which the lower 2.5 cm. constitutes the neck, or *cervix*, and the remainder the *body*; its greatest breadth is about 4 cm. and its thickness 2.5 cm. The convex upper extremity of the organ is known as the *fundus*. Of the two surfaces, the anterior is only partially and the posterior almost completely covered with peritoneum.

The uterine wall is thickest at the fundus and posterior aspect of the body, where it measures 1–1.5 cm., and somewhat thinner (8–9 mm.) at the entrance of the oviducts and in the cervix. It comprises three coats—the mucous, the muscular, and the serous. The **mucous coat**, or *endometrium*, is .5–1 mm. thick and consists of a tunica propria of fibrous tissue, containing a large number of colorless blood-cells, and the surface epithelium. The latter is a single layer of columnar cells, about  $28\ \mu$  high, that in their typical condition possess cilia producing a current towards the cervix. The cilia,

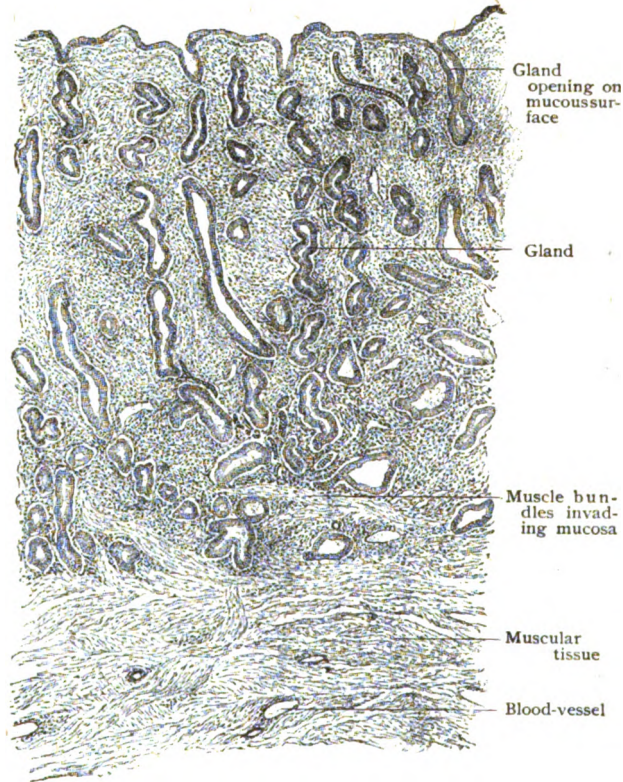

FIG. 305.—Section of mucous membrane of uterus, showing glands cut in various planes.  $\times 40$ .

however, are neither always present nor uniformly distributed, since they are lost during menstruation and often present only in patches (Gage).

The **uterine glands** are simple tubular or slightly bifurcated wavy invaginations, lined with a single layer of ciliated columnar cells resembling those covering the adjacent uterine mucosa. They are distributed at fairly regular intervals and extend the entire thickness of the mucosa, their tortuous blind extremities lying close to the subjacent muscle, since a submucosa is wanting. At the orifices of the oviducts, the uterine mucosa becomes thinner, the epithelium lower, and the glands shorter and fewer, until they finally disappear, glands being absent in the tubal mucous membrane.

The mucous membrane of the **cervical canal** is somewhat thicker and denser than that lining the body of the uterus. The single-layered columnar cells vary, in some places being taller ( $40\text{--}50\ \mu$ ) than those lining the body,



in others lower and more cuboidal. In addition to the usual tubular crypts, which although larger resemble those in the body, the cervical glands include wide diverticulated mucous follicles producing a clear peculiarly tenacious secretion. When the latter is retained, the glands are converted into cysts that appear as minute vesicles between the characteristically converging folds of the cervical mucosa and were formerly known as the *ovula Nabothi*. The abrupt transition of the columnar epithelium of the cervical canal into the stratified squamous cells covering the vaginal portion of the uterus takes place, before pregnancy has occurred, at the inner border of the external orifice. After the changes incident to pregnancy have affected the uterus, this transition lies

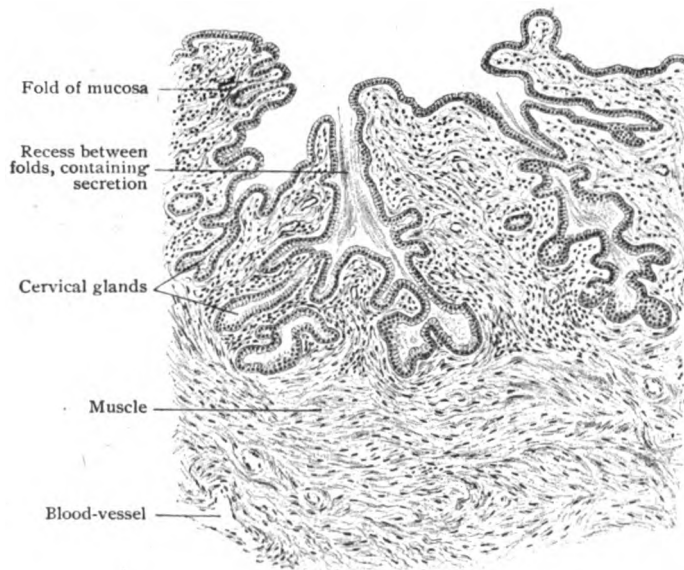


FIG. 306.—Longitudinal section of cervical mucous membrane, showing glands opening into recesses between the plicae.  $\times 50$ .

higher, approximately the lower half of the cervical canal then being clothed with the squamous epithelium. The change of the cervical mucosa into that lining the body of the uterus is gradual and without definite demarcation.

The muscular coat, or *myometrium*, is composed of bundles of involuntary muscle arranged with little regularity; it is possible, however, to distinguish two general strata—a robust *inner layer*, in which the bundles possess a circular disposition, and a thin imperfect *outer layer*, whose component bundles are for the most part longitudinal. The innermost bundles of the circular layer are oblique and longitudinal and sometimes described as a distinct submucous layer. The thick circular layer, the chief component of the myometrium, is distinguished by the number and size of the venous channels that traverse the intermuscular connective tissue; hence its designation as the *stratum vasculare*. At the orifices of the oviducts and the internal cervical opening, the disposition of the muscle-bundles suggests a sphincter. The longitudinal muscle is most distinct over the fundus and body, being unrepresented in the cervical segment. Here the circular and oblique bundles are intermingled with a considerable quantity of fibro-elastic tissue, an arrangement conferring greater resistance and hardness upon the

cervix. The longitudinal muscle-bundles are continued beyond the uterus into the oviducts and the broad, round, ovarian and utero-sacral ligaments. The component fibre-cells of the uterine muscle vary in form, in some places being short and broad and in others long and fusiform.

The **serous coat**, or *perimetrium*, continuous laterally with the peritoneal investment of the broad ligament, is closely adherent to the uterine muscle over the fundus and adjacent parts of the anterior and posterior surfaces.

The **blood-vessels** approach the uterus between the layers of the broad ligament. On gaining the muscular coat, the larger branches divide into twigs that penetrate the outer layer of the myometrium and within the cir-

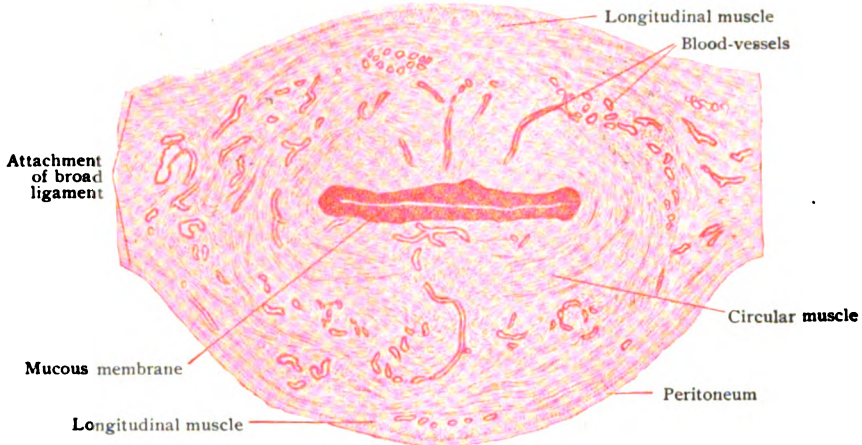


FIG. 307.—Transverse section of uterus through the body.  $\times 1\frac{1}{4}$ .

cular muscle break up into tortuous branches which in part pass to the mucous membrane and, in conjunction with the large veins, confer a highly vascular character to the stratum. Within the mucosa, the capillaries surround the glands and form a network beneath the epithelium. The *veins* begin in the mucosa, but within the middle of the muscular coat form large tortuous channels, sections of which appear as conspicuous irregular spaces between the muscle-bundles.

The **lymphatics** within the mucosa are represented by a network of lymph-spaces, from which stems pass through the muscular coat to join the close-meshed subserous network of larger lymphatics. The efferent trunks pursue various courses and communicate with the lymphatics of the neighboring organs—vagina, rectum, ovaries, and oviducts.

The **nerves** of the uterus are abundant and include both sympathetic and spinal fibres, nonmedullated and medullated. Since their chief destination is the involuntary muscle and blood-vessels, the nonmedullated fibres are associated with minute terminal ganglia from which the terminal filaments pass to the myometrium. Other fibres reach the mucosa, within which a close subepithelial plexus is formed, fibrils probably entering the epithelium.

**Changes During Menstruation and Pregnancy.**—Although liberation of a mature ovum may occur at any time, in the vast majority of cases ovulation and menstruation are synchronous processes, the uterine changes occurring regularly, every twenty-eight days, only when the ovaries are functionally active. In anticipation of the possible reception of a fertilized ovum, the uterine mucous membrane becomes

swollen, excessively vascular and hypertrophied, with conspicuous enlargement of the subepithelial blood-vessels and the glands. The resulting thickened and modified mucosa, now from 3-6 mm. thick, offers a soft velvety surface favorable for the implantation of the embryo-sac. Should this occur, the hypertrophy proceeds, and the lining of the uterus is converted into the deciduæ and takes an important part in the formation of the placenta. If, on the contrary, fertilization does not occur, the proliferative processes are arrested and the hypertrophied mucosa, now called the *decidua menstrualis*, enters upon regression. Incidental to the latter are subepithelial extravasation and rupture and partial destruction of the epithelium, followed by the characteristic discharge of blood. While usually the destruction of the mucosa is limited to the epithelium, it is probable that at times the superficial layer of the sub-jacent tissue is involved.

During pregnancy the most conspicuous changes are occasioned by the growth necessary to accommodate the rapidly augmenting volume of the uterine contents, by the provision of an adequate source of nutrition and protection for the fetus, and by the development of an efficient contractile apparatus for the expulsion of the same. The enormous increase depends especially upon the hypertrophy of the muscular coat, which during the first half of pregnancy becomes greatly thickened, but later thinner and membranous owing to stretching. The increase results from both the growth of the previously existing muscle-cells and, during the first half of pregnancy, the development of new muscle elements. The individual cells may increase tenfold in length and measure between .4-5 mm. During the first five months, the mucous membrane of the body also becomes greatly hypertrophied, in places attaining a thickness from 7-10 mm. The glands and blood-vessels, particularly the arteries, enlarge and, within the specialized area, are concerned in the formation of the placenta. The cervical mucosa takes no direct part in the formation of the deciduæ, although it thickens and is the seat of enlarged glands that secrete the plug of mucus that for a time occludes the mouth of the uterus. After the termination of pregnancy, the uterus enters upon a period of involution and repair, the excessive muscular tissue undergoing degeneration and absorption and the lacerated mucosa regeneration, the latter process being completed in from five to six weeks.

## THE VAGINA.

The vagina is a flattened muscular tube, lined with mucous membrane, that extends from the genital cleft enclosed by the labia below to the uterus above. Its walls, from 2-3 mm. thick, include a mucous and a muscular coat, supplemented externally by a less definite fibrous tunic.

The **mucous coat** consists of stratified squamous epithelium and a fibro-elastic tunica propria, exceptionally rich in veins and colorless blood-cells and beset with numerous conical papillæ that encroach upon the overlying epithelium, but do not model the free surface. Although normally moistened by a thin mucous secretion of acid reaction, the vagina is devoid of glands. Small lymph-nodules are scattered through the mucosa, especially in the upper part of the canal. The *hymen*, the membranous fold partly occluding the vaginal orifice, consists of a basis of vascular fibrous tissue covered by a prolongation of the mucous membrane.

The **muscular coat**, which supports the mucous membrane without the intervention of a distinct submucous layer, is composed of bundles of unstripped muscle arranged, although not with precision, as an inner circular and an outer longitudinal layer. The latter is best developed over the anterior vaginal wall, from which strands of muscular tissue are continued into the urethro-vaginal septum. Behind, bundles are prolonged into the recto-vaginal partition; above, the vaginal muscle is continuous with that of the uterus and below penetrates the perineal body. Within the conspicuous elevations, the *columnæ rugarum*, marking the vaginal wall, both mucous and

muscular coats are thickened, the elevations acquiring somewhat the character of erectile tissue owing to the abundance of veins intermingled with irregularly disposed muscle-bundles. The **fibrous coat**, outside the muscular, is composed of closely felted bundles of fibrous tissue and plentiful elastic fibres.

The **blood-vessels** supplying the vagina, derived from several sources, form a network between the mucous and muscular coats from which some twigs pass to the muscle and others enter the mucosa, where they break up

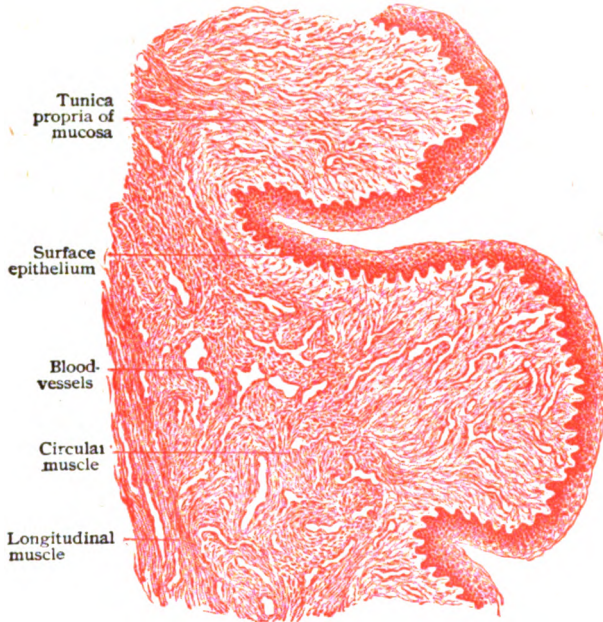


FIG. 308.—Section of wall of vagina, showing the rugæ cut across.  $\times 80$ .

into a capillary network. The veins are very numerous, and unite into a close plexus within the muscular tunic, from which large emergent trunks extend along the sides of the canal.

The **lymphatics** are numerous and represented by an exceptionally close network within the mucosa, one less dense within the muscular coat and a superficial network over the exterior from which the larger main efferent stems arise.

The **nerves** of the vagina are chiefly sympathetic efferents, associated with minute ganglia as they traverse the fibrous coat, for the supply of the blood-vessels and involuntary muscle. The sensory fibres distributed to the mucous membrane lining the upper part of the vagina are meagre, the pudic nerves endowing the mucosa of the lower third of the canal with greater sensibility. Sensory nerve-endings of different kinds have been observed within the mucous membrane.

#### THE EXTERNAL ORGANS.

The **labia majora** are rounded cutaneous folds, the homologue of the scrotum, the integument covering the outer surface being thick, dark hued and beset with large hair-follicles. That covering the medial surface is much more delicate in texture, with few and minute hairs. Sweat- and

sebaceous glands are numerous. In addition to the investment of skin, each labium majus contains a layer of subcutaneous fat, between which and the integument lies a thin stratum of involuntary muscle, *tunica dartolabialis*, continued forwards from the dartos of the perineum. The centre of the labium is occupied by a fairly well defined mass of fat, the *corpus adiposum*, that is separated from the subcutaneous tissue by a delicate fibro-elastic membrane.

The labia minora or nymphæ are thin folds of delicate skin, continuous with the greater labia at the bottom of the interlabial groove, on the one hand, and with the mucous membrane lining the vestibule, on the other. Although both surfaces are covered with integument, the protection and

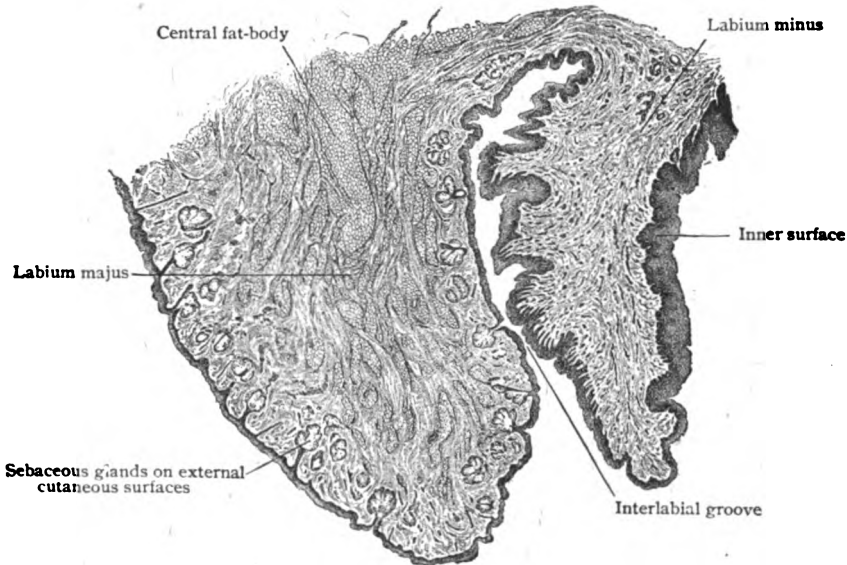


FIG. 309.—Section across the labia of young child.  $\times 18$ .

contact with the vaginal secretions to which the median aspect of the fold is subjected, modify the skin on the inner side so that it assumes the color and appearance of a mucous membrane. The line of transition into the vestibular mucosa follows the medial attachment of the fold. The absence of mucous glands and the presence of sebaceous follicles on both surfaces are differential characteristics of skin as contrasted with the adjacent mucous membrane. In addition to the two cutaneous layers, the nymphæ are composed of an intermediate stratum of loose connective tissue, rich in blood-vessels and bundles of unstripped muscle, that resembles erectile tissue. Hairs and fat are entirely wanting on the labia minora, but sebaceous and sweat-glands are plentiful after the first few years.

The vestibule, the space enclosed by the nymphæ, is lined with mucous membrane covered by stratified squamous epithelium and containing many mucous glands. Close to the posterior margin of the urethral orifice, or on the papilla that usually marks this opening, lie the small apertures of the *paraurethral ducts*. These canals, also known as the *tubes of Skene* and from 1–2 cm. long, lead into smaller groups of branched tubules, which are regarded as the homologues of the prostatic tubules. The ducts are lined with stratified

squamous epithelium for a short distance from the vestibule, the remainder of the passage and its subdivisions being clothed with columnar cells.

The **glands of Bartholin**, the largest of the vestibular and the homologues of the bulbo-urethral (Cowper's) glands, are two small organs, 1-1.5 cm. in length, situated one on either side of the vaginal orifice. They are tubo-alveolar mucous in type and produce a whitish viscid secretion. The small component lobules are separated by considerable tracts of fibro-muscular tissue and lined with columnar epithelium containing many mucus-bearing cells. The lobular ducts unite to form the single excretory canal, which is beset with minute mucous follicles. The main duct, sometimes provided with an ampullary dilatation, is lined with columnar epithelium until near its termination, where the epithelium becomes stratified squamous to correspond with that of the vestibule.

The **clitoris**, the homologue of the penis, possesses in reduced and modified form the chief components of the male organ. It consists essentially of two miniature corpora cavernosa and an imperfectly developed and cleft corpus spongiosum, known as the *bulbus vestibuli*. The latter consists of two converging elongated masses of cavernous tissue—a complex of tortuous veins and fibro-muscular tissue. The glans and cavernous bodies repeat, although in less typical manner, the histological details described in connection with the corresponding parts of the male (page 239).

### THE MAMMARY GLANDS.

Although morphologically modified cutaneous glands and developed in both sexes, the functional importance of the mammary glands, or *mammæ*, in the female entitles them to be regarded as organs accessory to the reproductive apparatus.

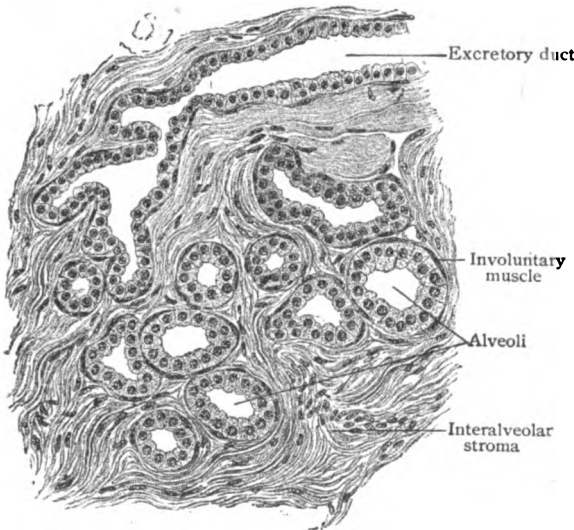


FIG. 310.—Section of mammary gland before lactation.  $\times 170$ .

Each mamma, or breast, comprises a group of some twenty individual and separate glands, opening on the nipple by independent ducts, that collectively constitute the secreting organ, the *corpus mammæ*, as distinguished from the enveloping fat and areolar tissue. Prior to the changes incident to pregnancy, the secretory tissue is relatively meagre and overshadowed by the fat-laden connective tissue in which the still rudimentary alveoli are embedded.

The **corpus mammæ** consists of from 15-20 or more flattened pyramidal *lobes*, radially disposed, with the bases directed towards the periphery and the excretory canals, the *lactiferous ducts*, converging towards the nipple upon which they

open. Each lobe is subdivided by connective tissue into several *lobules*, which in turn are made up of the ultimate divisions of the secreting tissue, the *alveoli*. The walls of the latter consist of a membrana propria, lined, in the resting condition, by a double layer of cells. Those next the membrana propria are flat and probably muscular in nature, thus emphasizing the resemblance between the mammary and sweat-glands. The inner cells, the secretory elements, are cuboid or low columnar.

During lactation, the alveoli become greatly enlarged and distended and the intervening connective tissue correspondingly reduced, so that the alveoli are pressed closely together. The cytoplasm of the cells engaged in the production of milk contains minute oil droplets, which, as they increase in size, displace the nucleus towards the membrana propria and project into the lumen of the alveolus, being separated from the latter by only a thin protoplasmic envelope. With the rupture of the cells the oil drops escape into the albuminous fluid, additionally secreted by the cells, that occupies the alveolus. After liberation of the oil droplets, the epithelial cells are much reduced; after a time, however, they again become the seat of renewed secretory activity, the accumulation of fat and the production of milk. Destruction of the secreting cells, therefore, does not take place.

The **excretory ducts** begin as the small canals into which the alveoli open and, at first, resemble the terminal compartments of the gland, being lined with a delicate stratum of striped muscle, upon which rests a simple cuboidal epithelium.

Within the *lactiferous ducts*, formed by the junction of the smaller canals, the cuboid cells are succeeded by columnar ones. On approaching the base of the nipple, beneath the colored areola, each milk-duct enlarges into a spindle-form *ampulla* or *sinus lactiferus*, from 10-12 mm. long and about half as wide, that serves as a temporary reservoir for the secretion of the gland. Beyond the ampulla the duct narrows (2 mm.), passes into the nipple, and ends, after ascending the latter parallel with the other ducts, in a minute orifice (.5-.7 mm.) at the summit of the nipple. Just before terminating, the epithelium lining the duct assumes the stratified squamous character of the adjacent epidermis.

The skin covering the **areola** and **nipple**, delicate but more or less pigmented, contains well marked bundles of unstriped muscle, whose contractions cause the nipple to become prominent and erect. Within the areola, this contractile tissue forms a layer, in places almost 2 mm. thick, that encircles the base of the nipple and extends into its substance as a muscular network through which the milk-ducts pass. Deeper longitudinal strands of unstriped muscle occupy the axis of the nipple.

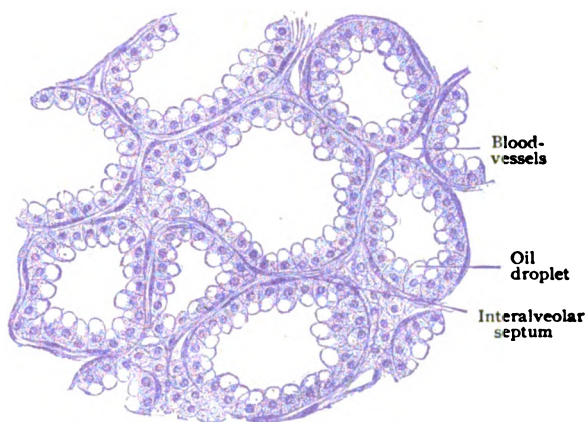


FIG. 311.—Section of mammary gland during lactation, showing distended alveoli lined with fat-bearing cells.  $\times 170$ .

Over both areola and nipple the skin is provided with large *sebaceous glands*, the secretion of which is increased during lactation and serves as protection during nursing. Sweat-glands are wanting over the nipple but large and modified in the periphery of the areola. The surface of the latter is modelled, especially towards the close of pregnancy, by low rounded elevations that mark the position of the subcutaneous **areolar glands** of Montgomery. The latter are rudimentary accessory masses of glandular tissue, from 1-4 mm. in diameter, and correspond in general structure with the mammary glands. Their ducts open by minute orifices on the surface of the areola.

**Milk.**—The fully established secretion of the mammary gland is an emulsion, the fat-globules being suspended in a clear colorless watery plasma. The composition of human milk includes over 86 per cent. of water, about 3 of albuminous substances, 5.3 of fat, 5 of sugar, and less than 1 per cent. of salts. The chief morphological constituents of milk are the *milk-globules*, as oil droplets liberated from the alveolar cells are called; these vary in size from the most minute spherules to those having a diameter of 3-5  $\mu$  or more.




FIG. 312.—Human milk; *A*, ordinary secretion; *B*, showing colostrum corpuscles and oil-drops.  $\times 400$

Their average number per cubic millimeter is something over one million (Bouchut). Whether the milk-globules are enclosed within extremely thin envelopes of casein is uncertain. It is probable that the fat-particles are not produced within the gland-cells, but are taken up and temporarily stored by their cytoplasm. A variable number of migratory leucocytes, more or less filled with fat-particles, are usually present in milk.

During the last weeks of gestation and for two or three days after its termination, the breasts contain a clear watery secretion, known as **colostrum**, that differs from milk in possessing relatively little fat and numerous conspicuous bodies, the *colostrum corpuscles*. The latter are spherical, but may be irregular in outline, and measure from 12-18  $\mu$ , although they may attain a diameter of more than 40  $\mu$ . The corpuscles are composite bodies and consist of a complex of leucocytes greatly distended with fat-particles and of modified alveolar epithelial cells. Their cytoplasm is markedly granular and often of a yellowish or reddish-yellow tint. They appear after lactation has ended and may be expressed from the regressing gland for months or, in exceptional cases, for even years. Quite commonly the mammary glands in both sexes, during the first few days after birth, yield a secretion resembling colostrum, popularly known as "witch-milk."

At birth the gland is represented by the lactiferous ducts with their ampullæ, the smaller collecting ducts and the rudimentary alveoli. The mammæ remain small and immature during childhood until the approach of



sexual maturity, when they increase in size and rotundity in consequence chiefly of the deposition of fat. The full development of the true gland is deferred until the occurrence of pregnancy, when active proliferation and increase of the gland-tissue takes place in preparation for its activity as a milk-producing organ. After lactation has ended, the mammæ undergo involution, the glandular tissue being reduced and returning to a condition resembling that before pregnancy. With the recurrence of the latter, the gland again enters upon a period of renewed growth and preparation, to be followed in time by return to the resting condition, in which the amount of glandular tissue is inconspicuous. After cessation of menstruation, the mammary gland gradually decreases in size, and in advanced age the corpus mammæ may be reduced to a fibrous disk in which gland-tissue is almost, if indeed not entirely, wanting.

The **blood-vessels** supplying the mammary gland, in addition to their distribution to the skin and more superficial parts of the breast, send deeper twigs to the glandular tissue which break up into capillary networks surrounding the alveoli. During lactation the vascular supply is materially increased. The veins from the corpus mammæ join the superficial vessels and, in the main, follow the arteries. Within the areola, the subcutaneous veins form a plexus that encircles the nipple and receives its blood. The **lymphatics** are exceptionally numerous and important. The deeper ones lie within the interlobular connective tissue and pass towards the surface, where they join the rich subareolar network. With the exception of a few trunks that follow the perforating arteries and become efferents of the internal mammary lymph-nodes, the lymphatics of the breast form two or three large trunks that pass to the axillary nodes. The **nerves** supplying the glandular tissue are chiefly sympathetic fibres, some ending in the blood-vessels and others forming plexuses upon the membrana propria of the alveoli, a few fibrils terminating between the secreting cells.

## THE CENTRAL NERVOUS SYSTEM.

THE central nervous system includes the spinal cord and the brain. In principle these are the walls of the primary *neural tube*, modified by unequal growth and expansion, which even after acquiring definite relations enclose the remains of the tube, as represented by the brain-ventricles and the central canal of the cord. In contrast to the spinal segment of the neural tube, which always remains a relatively simple cylinder, the cephalic segment early differentiates into the *cerebral vesicles*, marked flexure occurring coincidentally at certain points. From the sinuously bent cephalic segment are developed the fundamental parts of the brain, while from the relatively straight spinal segment proceeds the development of the spinal cord, during which process growth and differentiation convert the originally thin-walled tube into an almost solid cylinder, the minute central canal alone remaining as the representative of the once conspicuous lumen.

### THE SPINAL CORD.

The spinal cord, or *medulla spinalis*, is that part of the central nervous system, or cerebro-spinal axis, which lies within the vertebral canal. After removal of its protecting membranes and the attached root-fibres of the

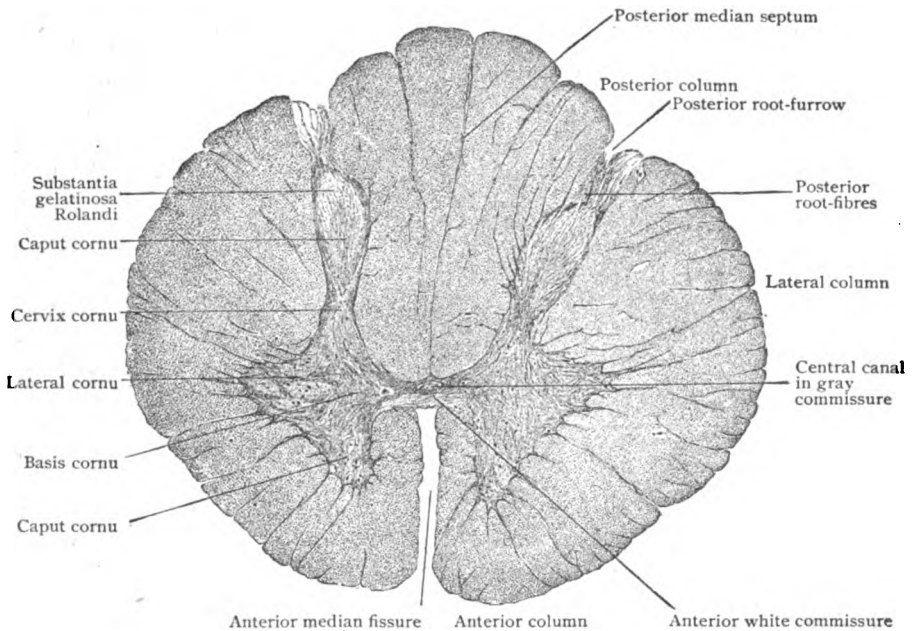


FIG. 313.—Cross-section of child's cord through thoracic region, showing arrangement of gray and white matter and subdivision of the latter into columns.  $\times 13$ .

spinal nerves, the spinal cord is seen to be a flattened cylinder, so that the antero-posterior diameter is always less than the transverse one; its outline in cross-sections, therefore, is not circular but more or less oval. Its width,

moreover, is not uniform on account of two fusiform swellings, the *cervical* and *lumbar enlargements*, associated with the origin and reception of the large nerves supplying the limbs. Where least expanded, opposite the middle of the thoracic spine, the cord measures 8 mm. in its sagittal and 10 mm. in its transverse diameter. Through the cervical enlargement these respective dimensions are 9 mm. and 14 mm., and through the lumbar swelling they are 8.5 mm. and 12 mm.

Cross-sections of the spinal cord (Fig. 313) show it to be imperfectly divided into symmetrical halves by a narrow cleft, the *anterior median fissure*, in front and a partition, the *posterior median septum*, behind. Further, the cord is seen, even with the unaided eye, to be composed of an irregular H-shaped core of gray substance enclosed by a mantle of white matter.

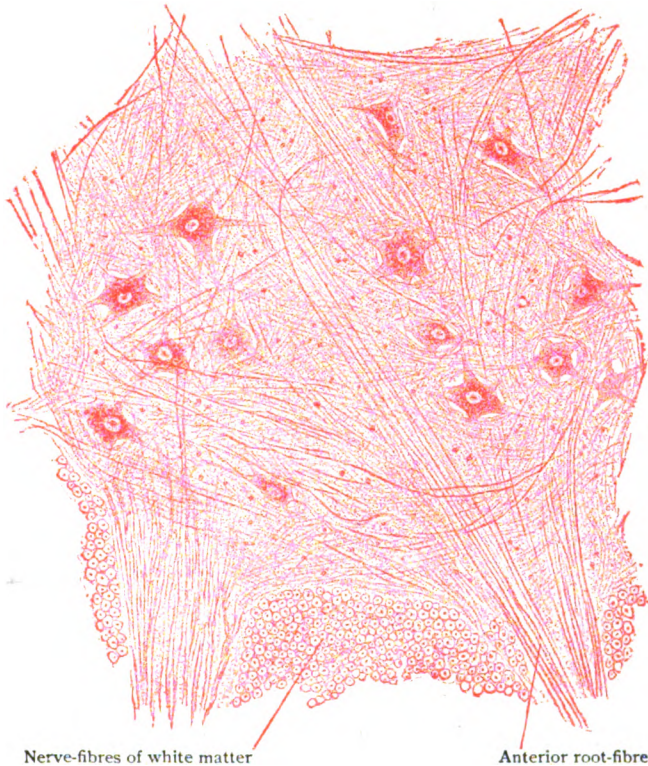


FIG. 314.—Portion of anterior horn of gray matter, showing multipolar nerve-cells and root-fibres.  $\times 120$

The latter, in each half of the cord, is partially subdivided into three general tracts by the lines along which the root-fibres of the spinal nerves are attached. The *dorsal root-line* of the sensory fibres is marked by a slight furrow, the *postero-lateral sulcus*, that lies from 2.5–3.5 mm. lateral to the posterior median septum. The *ventral root-line*, marking the emergence of the anterior (motor) fibres, is much less evident on account of the scattered manner in which these root-fibres make their exit. In this manner three longitudinal tracts, the *columns of the cord*, are marked off on each side—the *posterior* between the median septum and the postero-lateral sulcus,

the *lateral* between the dorsal and ventral root-lines, and the *anterior* between the ventral root-line and median fissure. The conventional division between the anterior and lateral columns, however, is largely artificial, since neither superficially nor internally is there a definite demarcation between these tracts. In the lower cervical and upper thoracic cord, the posterior column is subdivided by the superficial *paramedian sulcus* and a septum of neuroglia into two wedge-shaped tracts, of which the median and smaller is the *funiculus gracilis* or *tract of Goll* and the lateral and larger is the *funiculus cuneatus* or *tract of Burdach*.

**The Gray Matter.**—Within each half of the cord the gray matter forms a comet-shaped area, the broader end of which lies in front and the narrow one behind, with the concavity directed laterally. The convex mesial surfaces of the areas of the two sides are connected by a transverse band of gray matter, the **gray commissure**, that extends across the mid-line and encloses the minute *central canal* of the cord. The connecting band is subdivided by the canal into the *posterior* and the *anterior gray commissure*, which lie behind and in front of the tube respectively. The posterior median septum reaches the dorsal surface of the gray commissure, but the ventral margin of the latter is separated from the bottom of the anterior median fissure by an intervening bridge of white matter, the **anterior white commissure**, which connects the anterior columns and provides an important pathway for fibres passing from one side of the cord to the other.

Each crescent of gray matter is divided conventionally into three parts: the *anterior* and *posterior cornua*, the ventral and dorsal extremities of the crescent that project beyond the line of the transverse gray commissure, and the *pars intermedia*, that connects the cornua and receives the commissure. The two horns differ markedly and, although varying in details at different levels, retain their distinctive features throughout the cord. The **anterior cornu**, or *columna grisea anterior*, is short thick and rounded and separated from the surface by a considerable layer of white matter, through which the ventral root-fibres pass to their points of emergence from the cord. The blunt tip of the anterior horn is known as the *caput cornu* and the dorsal portion, by which it joins the commissure and the *pars intermedia*, as the *basis cornu*. The **posterior cornu**, or *columna grisea posterior*, is relatively long narrow and pointed and extends almost to the postero-lateral sulcus. The tip or *apex* of the dorsal horn is formed of a  $\Lambda$ -shaped stratum, the *substantia gelatinosa Rolandi*, that appears lighter and somewhat less opaque than the subjacent *caput cornu*, which it covers as a cap. The slightly contracted ventral portion of the posterior horn is the *cervix cornu*.

The fairly sharp demarcation between the gray and white matter is interrupted along the lateral border of the crescent by prolongations of gray matter into the adjacent lateral column (Fig. 322). The subdivisions of these processes unite into a reticulum of gray matter, the meshes of which are occupied by longitudinally coursing nerve-fibres, the whole interlacement being known as the *formatio reticularis*. This structure is best developed in the upper cervical region, where it is a conspicuous network filling the recess between the *pars intermedia* and the neck of the posterior cornu. In the thoracic region, the *formatio reticularis* is condensed into a compact lateral projection of gray matter, the *lateral cornu*, or *columna lateralis*.

The **histological components** of the gray matter include the nerve-cells, the nerve-fibres and the supporting neuroglia. Of these the most distinctive elements are the multipolar nerve-cells, which lie embedded

within a complex sponge-like matrix formed by the feltwork of various processes—dendrites, axones and collaterals—from mostly other neurones, the supporting neuroglial reticulum and the blood-vessels. In two localities, immediately around the central canal and capping the dorsal cornua, the gray matter varies in appearance and constitution and exhibits the modifications peculiar to the central and Rolandic substantia gelatinosa.

The **nerve-cells of the anterior cornu** are multipolar, the cell-bodies appearing irregularly polygonal in cross-sections and fusiform in longitudinal ones, and measure from 65–135  $\mu$  in diameter unless unusually small, when their diameter may vary from 30–80  $\mu$ . The most conspicuous and important elements of this region of the gray matter are the motor **radicular cells**,

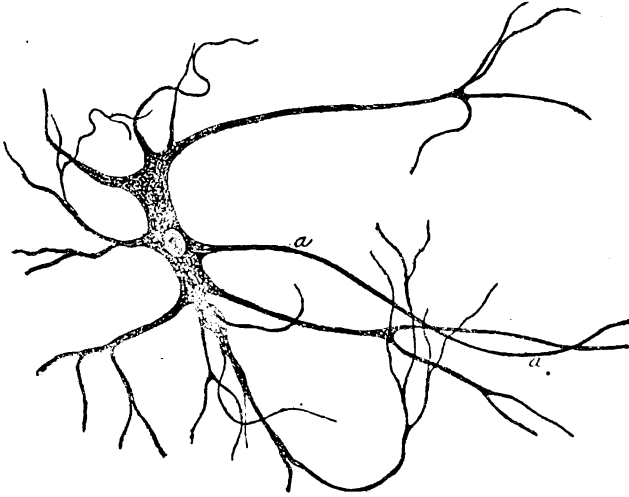


FIG. 315.—Isolated root-cell from anterior horn of cord of calf; *a*, axone.  $\times 210$ .

whose axones pass from the apex of the cornu, traverse the white matter (meanwhile becoming medullated), and emerge from the cord as the axis-cylinders of the efferent (motor) root-fibres of the spinal nerves. These cells possess from three to ten dendritic processes, which radiate in various planes, divide dichotomously and finally end in terminal arborizations that may reach the posterior horn and other parts of the gray matter. In contrast to the robust dendrites beset with spines, the axone is slender smooth and directly continuous with a root-fibre of a spinal nerve. With the exception of delicate collaterals, which may be wanting, the axone is unbranched. Each nerve-cell possesses a spherical or ellipsoidal nucleus (10–20  $\mu$ ), enclosed by a distinct nuclear membrane, and usually a single nucleolus, exceptionally more than one. In addition to accumulations of deeply staining tigroid substance, the cytoplasm contains brownish-yellow pigment granules, often in the vicinity of the implantation cone from which the axone springs.

In addition to the foregoing radicular cells, the anterior cornu contains other nervous elements, the commissural and strand-cells. The **commissural cells** occur chiefly within the median part of the anterior horn and resemble in size and form the radicular cells, but possess smaller nuclei. Their axones traverse the anterior white commissure to gain the opposite anterior column, in which they divide T-like into ascending and descending fibres, or undivided turn brainwards. The **strand-cells**, variable in form and generally smaller than the root-cells, are only sparingly repre-

sented in the anterior cornu. Their axones usually pass to the anterior column of the same side, but sometimes an axone divides, one fibre crossing by way of the anterior white commissure to the opposite anterior column, while the other passes to the column of the same side.

Although the nerve-cells of the anterior cornu are widely scattered, they are not uniformly distributed through the gray matter, but are collected into more or less definite groups that recur in consecutive sections. It is evident, therefore, that the cell-groups are not limited to a single plane, but are continuous as cell-columns for longer or shorter stretches within the gray matter. The **grouping of the nerve-cells**

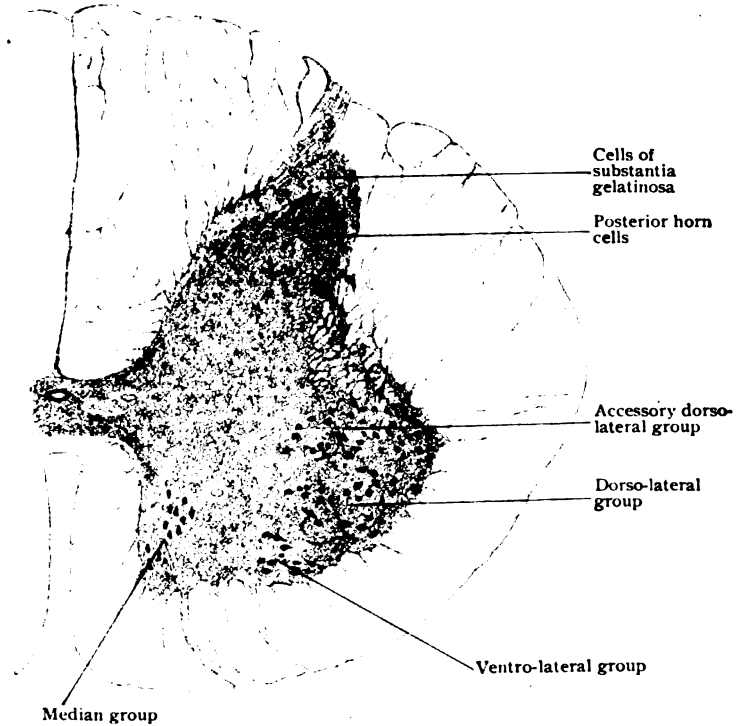


FIG. 316.—Half-section of lower cervical cord, showing grouping of the nerve-cells.  $\times 20$ .

of the anterior cornu includes two general collections, a *mesial group*, containing many commissural cells, and a *lateral group*, composed chiefly of ventral radicular cells. These collections, moreover, vary in extent and definition in different parts of the cord, and, where well marked, are often made up of more than a single aggregation of cells. This is particularly true of the lateral collection, in which an anterior and a posterior subdivision are recognized as the *ventro-lateral* and the *dorso-lateral group* (Fig. 316). The mesial collection, situated within the ventral angle of the horn, is sometimes, but much less clearly, divisible into a *ventro-mesial* and a *dorso-mesial group*, the latter being variable and at many levels wanting.

The **nerve-cells of the posterior cornu** are neither as large nor as regularly disposed as the anterior horn cells. Only in one locality, along the median border of the base of the posterior cornu, are they collected into a distinct tract—the column of Clarke; elsewhere, they are scattered without order throughout the gray matter of the dorsal horn. In a general way,

however, they may be divided into: (1) the *cells of Clarke's column*, (2) the *cells of the substantia gelatinosa Rolandi*, and (3) the *inner cells of the caput cornu*.

The **cells of Clarke's column** form a conspicuous collection that occupies the mesial border of the base of the posterior horn (Fig. 317), and correspond to an elevation on the surface of the gray matter. The cells are about  $50\ \mu$  in diameter, polygonal in outline and possess many richly branched dendrites that radiate chiefly within the limits of the group. The axones course ventrally for some distance before bending outward toward the lateral column within which, as the constituent fibres of the direct cerebellar tract (*fasciculus cerebello-spinalis*), they turn brainwards.

The **nerve-cells of the substantia gelatinosa** include innumerable small stellate elements, less frequently fusiform or pear-shaped, that measure only from  $6-20\ \mu$ , although exceptionally larger. Their numerous short dendrites are irregularly

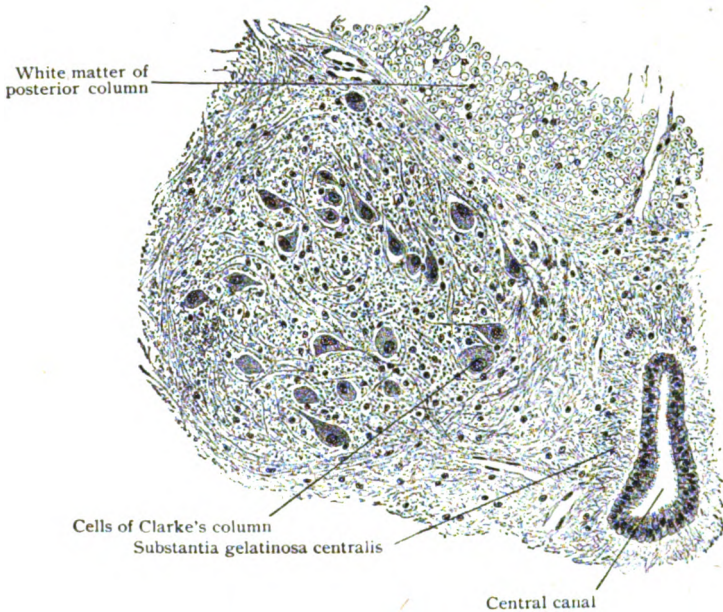


FIG. 317.—Part of cord, showing cells of Clarke's column in base of posterior horn.  $\times 110$ .

disposed and branched. The axones are continued partly into the adjacent white matter of the posterior column, where they divide into ascending and descending limbs, and partly into the gray matter, in which they run as longitudinal fibres. The *marginal cells* are fusiform or pyramidal and larger ( $35-55\ \mu$ ) and occupy the border of the substantia gelatinosa. Their axones traverse the substantia gelatinosa and probably continue, for the most part, within the lateral column, although some enter the posterior. Many of the nerve-cells within the substantia gelatinosa were formerly regarded as glia cells, an exceptionally large amount of neuroglia being credited to this substance; instead of such being the case, this region of the gray matter is relatively poor in neuroglia and numerically rich in nerve-cells.

The **inner cells** of the posterior cornu, intermingled with numerous nervous elements of small size, are triangular or spindle-shaped and usually measure about  $50\ \mu$ ; they are, therefore, larger than the ordinary cells of the substantia gelatinosa. Their axones pass mostly into the lateral column of the same side; some, however, have been traced into the posterior or anterior columns of the same and, rarely, into

the opposite anterior column. A few cells of type II—those whose axones are not prolonged into nerve-fibres but soon break up into elaborate end-arborizations confined to the gray matter—are found within the gray matter of the posterior cornua.

The nerve-cells of the *pars intermedia*, the gray matter which connects the horns and lies opposite the gray commissure, may be divided broadly into two classes, the *lateral* and the *middle cells*, that occupy respectively the outer border and the more central area of this part of the gray matter. Those of the first class, or *intermedio-lateral cells*, are associated with the *formatio reticularis* and the lateral horn and, hence, are also called the *group* or *column of the lateral horn*. Where there is a distinct lateral horn, as in the thoracic region, the cells occupy this projection, but elsewhere lie within the base of the gray network. The cells are multipolar or fusiform, from 15-45  $\mu$  in diameter, and provided with a variable number of dendrites. The axones pass directly into the lateral column and become ascending or descending fibres; a few axones may enter the anterior column of the same side. The cells of the second class, the *intermediate cells*, are irregularly disposed and only in the upper

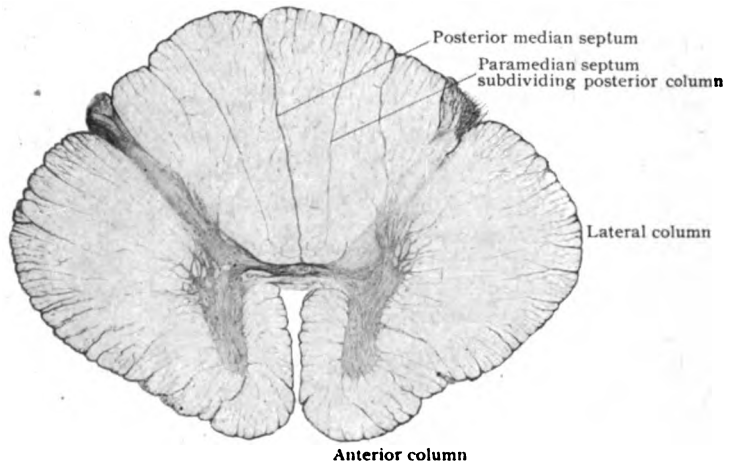


FIG. 318.—Transverse section of spinal cord, showing general arrangement of neuroglia.  $\times 9$ .

part of the cord present a fairly distinct middle group. They are polygonal or fusiform, small in size, and provided with irregular dendrites. The axones are continued chiefly within the lateral column of the same side, although some pass to the anterior column and a few probably cross to the opposite side.

A few isolated nerve-cells are usually to be found within the white matter in the vicinity of the more superficially placed cell-columns. These, the so-called *oulying cells*, are regarded as elements displaced from their usual position during the differentiation and growth of the white and gray matter. Similar displacement sometimes affects the cells of the spinal ganglia, which then may be found within the cord.

The **neuroglia of the gray matter** is everywhere present as a delicate reticulum supporting the nerve-cells and fibres. The structure of neuroglia having been described (page 70), the special features of its arrangement may be noted. The feltwork of neuroglia fibrils within the gray matter is, in general, more compact than within the white matter and, further, somewhat denser at the periphery than in the deeper parts of the gray core. There is, however, no sharp boundary between the supporting tissue of the white and gray tracts, since numerous glia fibrils extend outwards from the framework of the gray substance to be lost between the nerve-fibres of the adjoining columns. This feature is marked in the anterior



cornu, where the glia fibrils form septa of considerable thickness that diverge into the surrounding white columns; moreover, the conspicuous processes of the formatio reticularis and the projecting lateral horn consist largely of neuroglia. The larger nerve-cells and their more robust processes are ensheathed by interlacings of neuroglia fibrillæ. The amount of neuroglia varies in the several parts of the posterior horn; thus, the extreme apex consists almost entirely of glia tissue, although within the substantia gelatinosa Rolandi the number of glia fibres is unusually meagre. Within the caput and remaining parts of the posterior horn, the neuroglial elements are similar in quantity and disposition to those in the anterior cornu.

**Substantia gelatinosa centralis** is the name given to a zone of peculiar translucency that immediately surrounds the central canal. This annular area consists of modified neuroglia in which radial ependymal fibres, continued from the ependymal cells lining the central canal, are interwoven with circularly disposed neuroglia fibrillæ, the whole being a compact stratum interspersed with an unusual number of glia cells. In marked contrast to the substantia gelatinosa which caps the posterior horns, that surrounding the central canal contains few nerve-cells and chiefly glia elements.

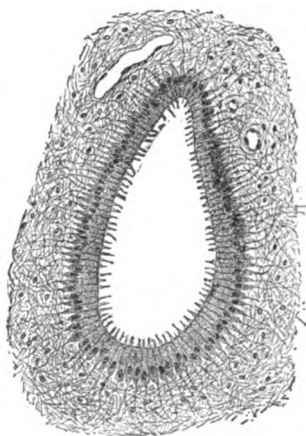


FIG. 319.—Central canal and surrounding substantia gelatinosa centralis from child's cord; the canal is lined with ependymal cells, outside of which lies the neuroglia.  $\times 135$ .

The nerve-fibres of the gray matter constitute a considerable part of the intricate groundwork in which the nerve-cells are embedded. The fibres, seen traversing the gray matter in all directions, are the processes contributed by neurones situated at the same, different or even remote levels, and include: (1) the collaterals and terminal stems of the dorsal root-fibres that enter the gray matter; (2) terminal fibres of the descending tracts that end in relation with the ventral (motor) radicular cells; (3) the axones and collaterals from the numerous cells of the posterior horn that

traverse the gray matter to and from the respective columns in which they course. The dendritic processes also contribute to the complex.

**The White Matter.**—Since the predominating components of the white substance are longitudinal nerve-fibres that pass for a longer or shorter distance up and down in the columns of the cord, in transverse sections the field between the gray core and the surface is made up chiefly by the cross-sections of the medullated nerve-fibres. These appear as small, closely set and somewhat compressed rings (Fig. 320), enclosing deeply stained dots, surrounded by faint annular striations. The dots are sections of the axis-cylinders, the annular striations the remains of the framework of the medullary coat, and the rings the slight condensations of the neuroglia that take the place of a neurilemma, which is wanting on the fibres of the cerebro-spinal axis. The individual nerve-fibres vary greatly in size, even within the same tract large and small ones often lying side by side. The smallest may be less than  $5\mu$  in diameter and the largest over  $25\mu$ . In general, the thickest fibres are found in the anterior and in the lateral part of the posterior columns, and the thinnest ones in the posterior and lateral columns in the immediate vicinity of the gray matter.

The immediate surface of the white matter, beneath the investing pia mater, is formed by a tract of condensed neuroglia, the *subpial layer*, that is devoid of nervous elements and constitutes the definite outer boundary of the cord. This zone consists of a dense interlacement of circular, longitudinal and radial neuroglia fibrils, along with many glia cells. From the deeper surface of this investment numerous bundles of fibrillæ penetrate between the nerve-fibres and become lost in the general supporting ground-work. At certain points the bundles are replaced by robust septa which imperfectly separate the nerve-fibres into groups or tracts, as conspicuously exemplified by the paramedian septum subdividing the posterior column. The

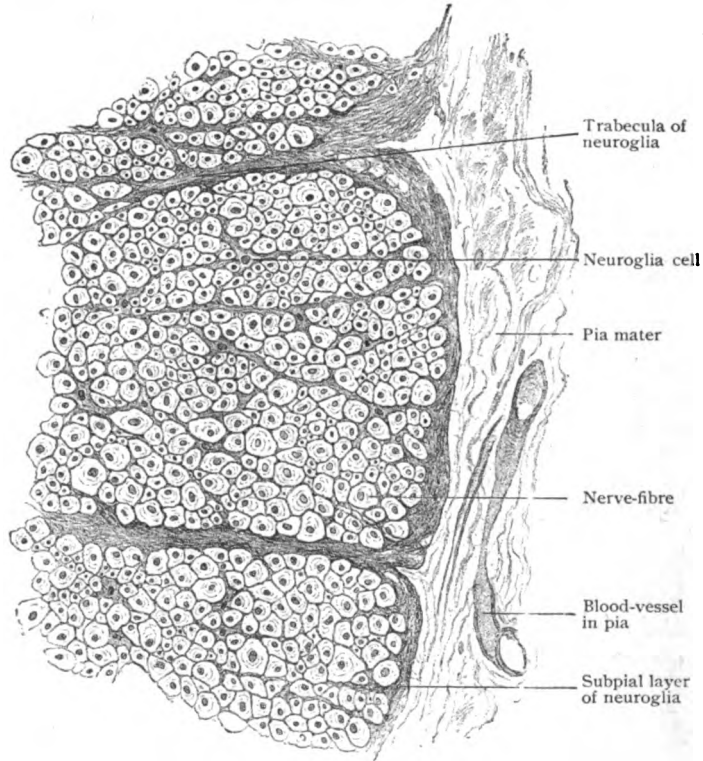


FIG. 320.—Part of periphery of cord, showing subdivision of white matter by ingrowths of subpial layer of neuroglia.  $\times 230$ .

blood-vessels that enter the nervous substance of the cord from the pia mater, accompanied by connective tissue, are surrounded by tubular sheaths of neuroglia, and the same is true of the bundles of root-fibres of the spinal nerves. With the exception of the connective tissue that enters with the blood-vessels, the amount of mesodermic tissue included in the supporting framework of the cord is inconsiderable, if, indeed, not wanting.

**The Fibre-Tracts.**—Although microscopical examination of ordinary sections of the cord affords slight indication of a subdivision of the columns of white matter into areas corresponding with definite fibre-tracts, yet the combined evidence contributed by anatomical, pathological, embryological and experimental investigation establishes the existence of a number of such paths of conduction. With few exceptions, however, they are without sharp

boundaries and illy defined, adjoining tracts often overlapping, and depend for their presence upon the fact that nerve-fibres having the same origin,

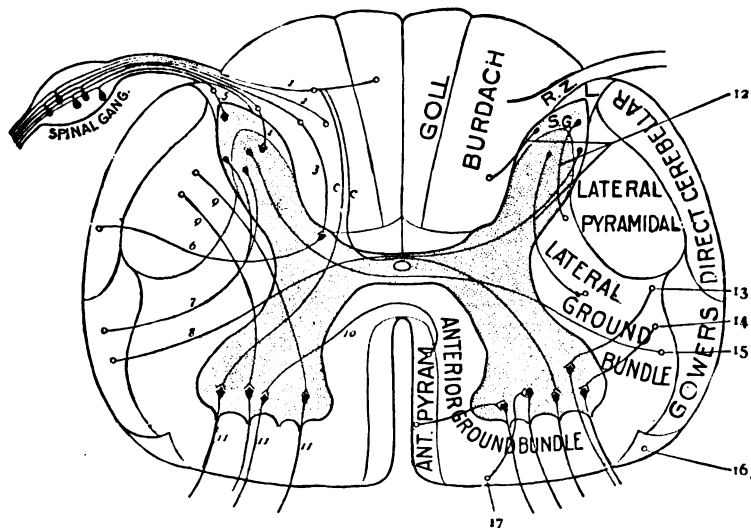


FIG. 321.—Diagram of spinal cord, showing position of chief tracts and relations of their component fibres to nerve-cells; 1-5, posterior root-fibres entering root-zone (R.Z.) and Lissauer's tract (L.), open circles (o) indicate that fibres pass up and down; c. c. collaterals from long ascending tracts (1, 2) to anterior root-cells; 3, fibres ending around cells of Clarke's column; 6, fibres forming direct cerebellar tract; 7, 8, fibres forming Gowers' tract; 9, 10, fibres from lateral and direct pyramidal tract; 11, 11, 11, anterior root-fibres; 12, association tracts; 13, rubro-spinal; 14, tecto-spinal; 15, spino-thalamic; 16, olivospinal tracts; 17, vestibulo-spinal.

function and destination usually proceed along a similar path. In addition to being provided with paths of conduction necessary for the performance of its function as a centre for independent or reflex impulses in response to external stimuli, the cord contains tracts that connect it with the brain, as well as those that bring the various levels of the cord itself into association. The white matter contains, therefore, three classes of nerve-fibres: (1) those entering the cord from the periphery and other parts of the body; (2) those entering it from the brain; and (3) those arising from the nerve-cells situated within the cord itself. It is evident that some of these fibres constitute pathways for the transmission of impulses from lower to higher levels and hence form *ascending tracts*, while others, which conduct impulses in the opposite direction, form *descending tracts*.

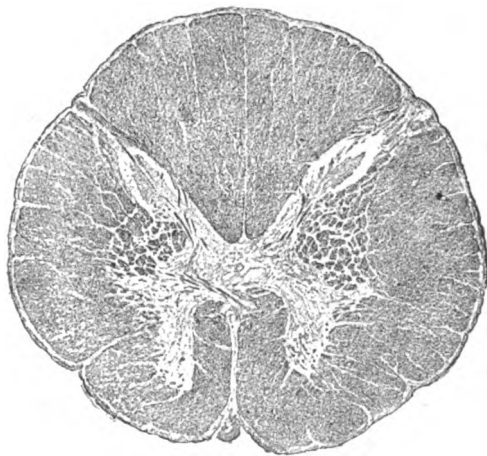

FIG. 322.—Section of spinal cord at level of second cervical segment; formatio reticularis fills bay between posterior and anterior cornua; substantia gelatinosa caps apex of posterior cornu. (Drawn from Weigert-Pal preparation made by Professor Spiller.)  $\times 6$ .

Based on the collective results of the anatomical, physiological and developmental methods of study, it is possible to locate and trace with fair accuracy a number of fibre-tracts in the cerebro-spinal axis. Since they are undergoing continual augmentation or decrease, their actual area and position are subject to variation, so that the detailed relations in one region of the cord differ from those at other levels. The accompanying schematic figure (Fig. 321), therefore, is to be regarded as showing only the general relations of the most important paths of the cord, and not as accurately representing the actual form and size of the fibre-tracts. Further, it must be appreciated that the definite limits of these tracts in such diagrammatic representations seldom exist in reality, since the fibres of the adjacent paths in most cases overlap, or, indeed, extensively intermingle, so that the fields marked in cross-sections may be shared by fibres belonging to different systems.

The constitution of the fibre-tracts of the cerebro-spinal axis is manifestly beyond the province of these pages. For such information the reader

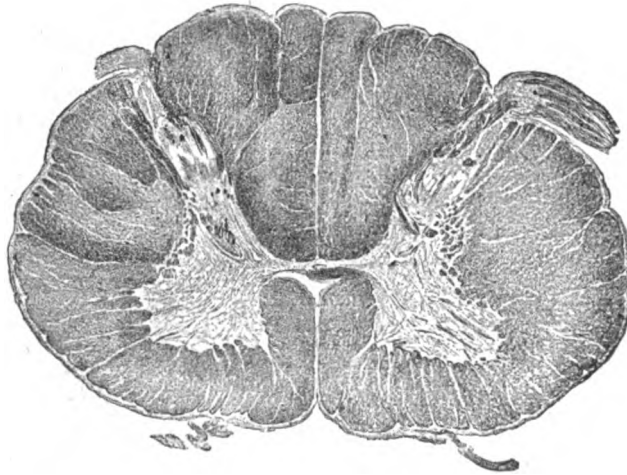


FIG. 323.—Section of cord through lower part of cervical region.  $\times 6$ . (Preparation by Professor Spiller.)

is referred to the systematic text-books of anatomy and the special works on the nervous system. A few considerations of importance, however, may here find appropriate mention.

All afferent or sensory impulses entering the cord do so by way of the posterior root-fibres. The latter are the centrally directed processes (axones) of the neurones whose cell-bodies are the ganglion-cells within the spinal ganglia situated on the dorsal roots of the spinal nerves. These root-fibres convey to the cord the various impulses collected by the peripherally directed processes (the sensory nerves) from the integument, mucous membranes, muscles, tendons and joints from all parts of the body, with the exception of those served by the cranial nerves. Some of the afferent impulses thus conducted are transformed in the cerebrum into impressions of touch, muscle-sense and temperature, while others are carried to the cerebellum, which responds by efficient impulses that exercise the restraint necessary to maintain coördination.

On entering the spinal cord along the postero-lateral sulcus, most of the dorsal root-fibres penetrate the fasciculus cuneatus (tract of Burdach)

and, with few exceptions, undergo a  $\succ$  or  $\dashv$  like branching into ascending and descending limbs, which assume a longitudinal course and pass up and down in the cord for a variable distance. During their course both limbs give off collateral branches which bend sharply inward and pass horizontally into the gray matter to end chiefly in relation with the cells of the posterior horns, from which cells new secondary paths arise. The main stem-fibres of the descending and of the short ascending limbs also end in the manner just described. In addition to the short collaterals destined for the cells of the dorsal horn, others, the *ventral reflex collaterals*, traverse the posterior horn and intermediate gray matter to end in arborizations around the ventral radicular cells, and thus complete important reflex arcs by which impulses transmitted through the dorsal roots directly impress the motor neurones. With possibly the exception of certain fibres said to pass directly to the cerebellum, all the sensory root fibres end around neurones situated either within the gray matter of the spinal cord or within the nuclei of the medulla. Thence the impressions are conveyed by axones of these secondary neurones to higher centres, to be taken up in turn by tertiary neurones, in the sequence of the chain required to complete the path for the conduction and distribution of the impulse.

The long **ascending posterior tract** includes the dorsal root-fibres that pass uninterruptedly upwards within the posterior column (within the tracts of Goll and of Burdach) as far as the nuclei (gracilis and cuneatus) of the medulla. Many other root-fibres, however, ascend for only a short distance and then bend inwards to end around the cells of the posterior horn. Among the most important of such fibres are those that pass to the neurones of Clarke's column (page 271), around which they end in telodendria. The axones of these neurones continue the path for the impulses received from the dorsal root-fibres by cutting across the gray matter and lateral column to the periphery where, bending brainwards, they form the important **direct cerebellar tract** (*fasciculus spino-cerebellaris dorsalis*).

Among the many neurones of the posterior horn around which the dorsal root-fibres end, some send their axones into the lateral columns to form the ascending **tract of Gowers** (*fasciculus spino-cerebellaris ventralis*), which occupies the periphery of the cord immediately in advance of the direct cerebellar tract. Others send their axones into the antero-lateral column of the opposite side and ascend as the **spino-thalamic tract**, a sensory pathway of importance but diffuse.

The foregoing tracts are all concerned in transmitting, directly or indirectly, the impulses brought by the dorsal root-fibres to higher levels; they are all, therefore, ascending paths. In order, however, that the spinal cord with its long series of motor nerves shall be brought under the influence of the volitional and coördinating impulses arising within the cerebrum and cerebellum respectively, it is evident that descending tracts composed of

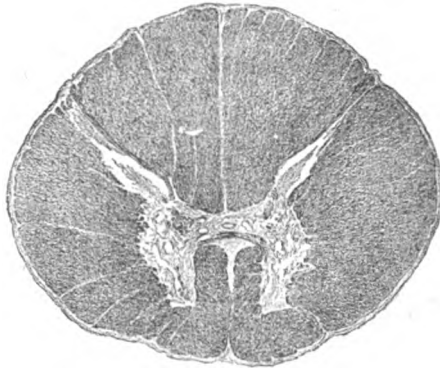


FIG. 324.—Section of cord through middle of thoracic region.  $\times 6$ . (Preparation by Professor Spiller.)

fferent fibres exist. Such fibres, connecting the motor cells of the cerebral cortex with the motor root-cells of the spinal nerves, are condensed into two chief strands, the **anterior** and **lateral pyramidal tracts**. The latter (*fasciculus cerebro-spinalis lateralis*) occupies an oval area between the lateral aspect of the posterior horn and the direct cerebellar tract. The component fibres are the axones of the motor cortical neurones, which have descended from the white core of the cerebrum, through the ventral part of the brain-stem (cerebral peduncle, pons and medulla), to the lower part of the medulla and thence, after crossing in the *pyramidal decussation* (page 283), into the lateral column of the cord. On reaching the level corresponding to the cord-segment to be influenced, the cerebro-spinal fibres bend inwards, enter the gray matter, and end around the motor root-cells in arborizations. The fibres of the **anterior** or **direct pyramidal tract** (*fasciculus cerebro-spinalis anterior*) correspond in origin and course with those of the lateral tract until they reach the lower part of the medulla, where, instead of crossing in the pyramidal decussation, they continue into the anterior column and descend within a narrow zone along the anterior median fissure of the cord. Although not sharing the decussation in the medulla, practically all of these fibres cross somewhere, by way of the anterior

white commissure, and pass at the appropriate level into the anterior cornu of the opposite side, to end in arborizations around the radicular cells. In no case does a motor impulse pass directly from the cerebral cortex to the muscle fibre, since always at least two links—the cortical and the spinal neurone—are required to complete the chain.

The existence of direct paths from the cerebellar cells to those of the spinal cord is uncertain, the impulses from the cerebellum being usually carried by the axones of the cerebellar neurones to cells within the brain-stem (red, vestibular and olivary nuclei) and thence by secondary

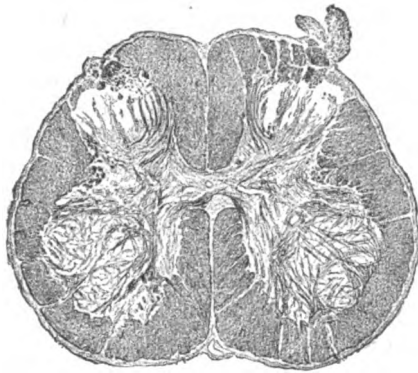

FIG. 325.—Section of cord through lower part of lumbar region.  $\times 6$ . (Preparation by Professor Spiller.)

axones (rubro-, vestibulo-, and olivo-spinal fibres) through the antero-lateral columns to the gray matter of the cord.

Although the tracts above described include the more definite and evident of the paths of conduction, a glance at Fig. 321 shows that a considerable part of the anterior and lateral columns of the cord is still unaccounted for. Concerning this extensive area, to which the name **antero-lateral ground-bundle** is conveniently applied, much uncertainty exists; suffice it to point out, that within its complex are many fibres of importance, some of which connect the cord with distant parts of the brain, while others serve as links binding together different levels of the cord itself. These last, the **intersegmental association fibres**, are for the most part short, passing as the axones of the posterior horn cells into the adjacent white matter and, after a limited course, bending inwards to enter once more the gray matter and end around the nerve-cells at some different level. The shorter association tracts lie close to the gray matter, while the longer ones run within the more peripheral part of the antero-lateral ground-bundle.

The **blood-vessels** supplying the spinal cord, derived from many sources, form an arterial network within the pia mater that accompanies the nervous cylinder throughout its length. The gray matter receives its principal supply from the series of *anterior fissural arteries*, over two hundred in number, that pass from the anterior spinal trunk backwards within the anterior median fissure to its bottom and there divide into right and left branches, which traverse the anterior white commissure to gain the gray matter on either side of the central canal. These vessels, the *sulco-marginal arteries*, divide into ascending and descending branches that provide a rich capillary network for the entire gray matter, with the exception of its most peripheral zone. The latter, together with the white matter, receives its supply from the *penetrating arterioles* that come from the surrounding intrapial trunks and enter the subjacent surface of the cord. Unpaired horizontal twigs, the *posterior sulcal arteries*, follow the posterior median septum at different levels for some distance, but before reaching the posterior gray commissure usually break up into terminal ramifications, some of which pass to the gray matter of the posterior horns. Notwithstanding the capillary anastomoses within the nervous tissue, each artery provides the sole available supply for some definite territory; they are, therefore, "end-arteries," a fact which explains the extensive and elaborate system of vessels necessary to maintain the nutrition of the cord. The plexiform veins within the spinal pia are formed by the union of the small radicles, that collect the blood from the intraspinal capillaries and emerge at the surface of the cord. Definite lymphatics within the spinal cord are unknown.

The **investing membranes** or **meninges** of the spinal cord are described in connection with those of the brain (page 311).

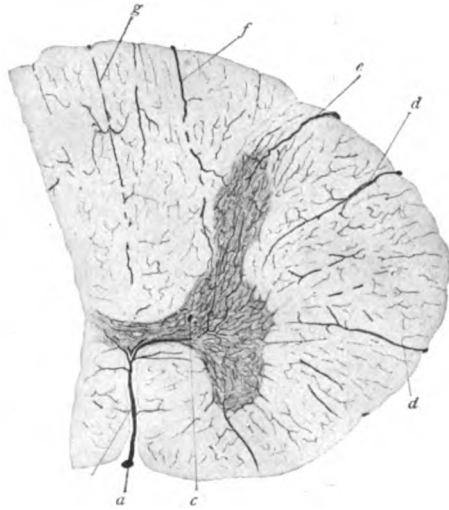


FIG. 326.—Transverse section of injected cord, showing vascular supply of white and gray matter; *a*, anterior spinal giving off anterior sulcal (*b*); *c*, ascending branch; *d*, perforating arteries; *e*, postero-lateral, *f*, parasulcal; *g*, posterior sulcal.  $\times 10$ .

## THE BRAIN.

Before entering upon the description of the histological details of the more important parts of the brain, it is most desirable to have some notion of their general position and relations. A brief survey of the gross anatomy of the human brain, therefore, is an advantageous introduction to the study of its structure.

Denuded of its investing membranes and the attached cranial nerves, and viewed from below (Fig. 327), the brain, or *encephalon*, is seen to consist of a median **brain-stem**, that inferiorly is directly continuous with the spinal cord, through the foramen magnum, and above divides into two diverging arms that disappear within the large overhanging mass of the cerebrum. The brain-stem includes three divisions, the inferior of which, the *medulla*

*oblongata*, is the uninterrupted upward prolongation of the spinal cord and above is limited by the projecting lower border of the quadrilateral mass of the next division, the *pons Varolii*. Beyond the upper margin of the pons, the brain-stem is represented by a third division that ventrally is separated by a deep recess into two diverging limbs, the *cerebral peduncles*, or *crura cerebri*, to correspond with the halves or *hemispheres* of the **cerebrum**. Each of these receives one of the crura and in this manner is connected with the lower levels of the cerebro-spinal axis. The greater part of the medulla and pons is covered dorsally by the **cerebellum**, whose large lateral expansions, or *hemispheres*, project on either side as conspicuous masses, distin-

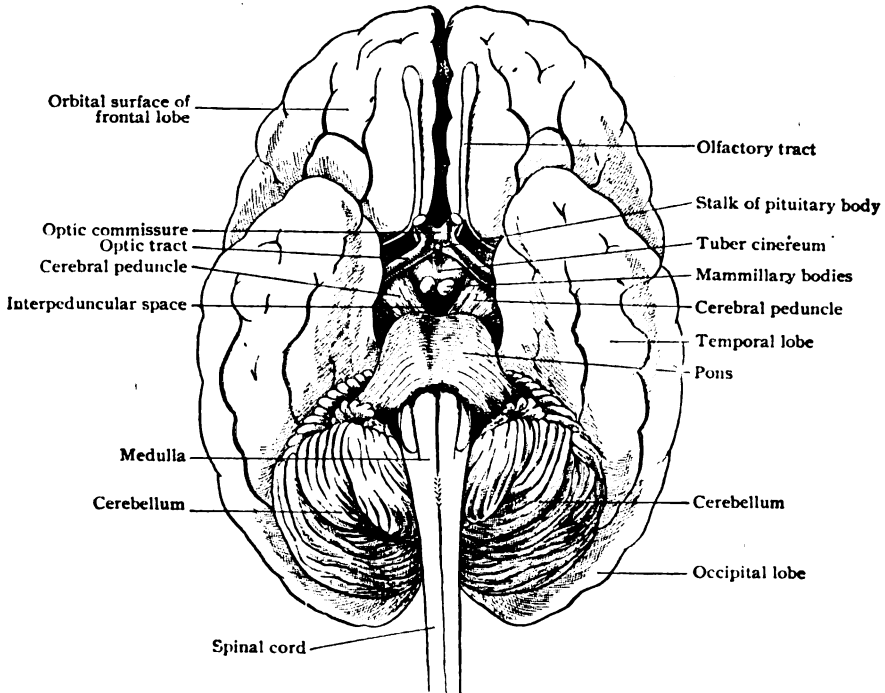


FIG. 327.—Human brain, viewed from below, showing relations of brain-stem to spinal cord and cerebellum, as well as more prominent details of brain.

guished by the closely set plications and intervening fissures that mark their surface. Of the five component parts of the brain—medulla, pons, cerebral peduncles, cerebrum, and cerebellum—the last two are coated with the cortical gray matter, in which, broadly speaking, are situated the neurones that constitute the end-stations for the sensory impulses conveyed by the various corticopetal paths and the centres controlling the lower-lying nuclei of the motor nerves. The brain-stem, on the other hand, whilst containing numerous stations for the reception and distribution of sensory impulses, is primarily the great pathway by which the cerebrum and the cerebellum are connected with each other and with the spinal cord.

Viewed in a mesial sagittal section (Fig. 328), each of these divisions is seen to be related to some part of the system of communicating spaces that, as the *lateral* and *third ventricles*, the *aqueduct of Sylvius* and the *fourth ventricle*, extend from the cerebral hemispheres above, through the brain-



stem and beneath the cerebellum, to the *central canal* of the spinal cord below. Both the roof and the floor of the irregular **third ventricle** are thin, while its lateral walls are formed by two robust masses, the *optic thalami*, the mesial surface of one of which forms the background of the space when viewed in sagittal section. The *roof* of the ventricle is very thin and consists of the delicate layer of *ependyma*, as the immediate lining of the ventricular spaces is designated, supported by the closely adherent fold of pia mater which in this situation pushes before it the neural wall and contains within its lateral border a thickened fringe of blood-vessels, the *choroid plexus*. The two structures, the ependyma and the pia mater, together constitute the membranous *velum interpositum* that forms the roof of the ventricle. Behind, just over the upper end of the Sylvian aqueduct, lies the cone-

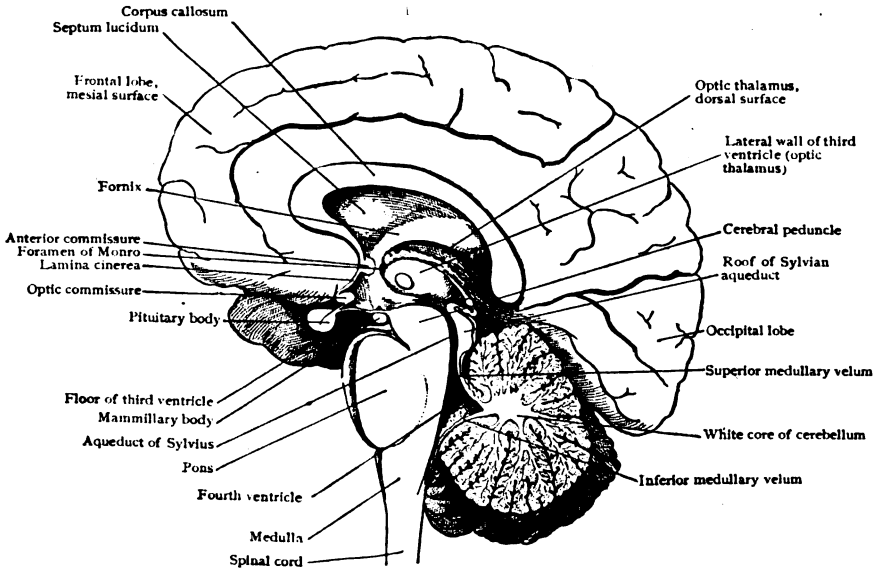


FIG. 328.—Human brain seen in mesial sagittal section, showing relations of brain-stem, cerebrum and cerebellum and the ventricles.

shaped *pineal body*. The floor of the third ventricle is also, for the most part, thin and irregular. It corresponds to the median part of the lozenge-shaped area, the *interpeduncular space*, bounded behind by the diverging cerebral peduncles and in front by the *optic chiasm* and *optic tracts*. Passing forwards from the deep recess between the cerebral peduncles, the paired *corpora mammillaria*, the *tuber cinereum* and the stalk of the *pituitary body* occupy the interpeduncular space.

The *Sylvian aqueduct*, the narrow canal connecting the third and fourth ventricles, is surrounded ventrally and laterally by the dorsal part or *tegmen- tum* of the cerebral peduncles. Above it lies a plate of some thickness, whose free dorsal surface is modelled by two pairs of rounded elevations, the *corpora quadrigemina*. The *fourth ventricle* in sagittal section appears as a triangular space, the anterior or basal wall being the dorsal surface of the pons and medulla and the posteriorly directed apex lying beneath the cerebellum. When viewed from behind, the ventricle is rhomboidal in outline, the lateral boundaries above being the *superior cerebellar peduncles*, that

divergingly descend from the sides of the corpora quadrigemina to the cerebellum; similar arms, the *inferior cerebellar peduncles*, also known as the *restiform bodies*, convergingly descend from the cerebellar hemispheres to the posterior columns of the medulla and form the lower lateral boundaries of the fourth ventricle. Along the floor of the fourth ventricle and of the Sylvian aqueduct lies an important sheet of gray matter, continuous with that surrounding the central canal of the spinal cord, while within the white matter of each cerebral hemisphere are embedded two large gray masses, the *corpus striatum* and the *optic thalamus*, often together termed the *basal ganglia*. The optic thalamus is of especial importance as the station towards which, in a general way, all afferent (sensory) impulses destined for the brain converge.

### THE MEDULLA OBLONGATA.

The medulla oblongata, sometimes called the *bulb* and usually designated by the convenient but indefinite name "medulla," is the lowest segment of the brain-stem and the direct upward prolongation of the spinal cord.

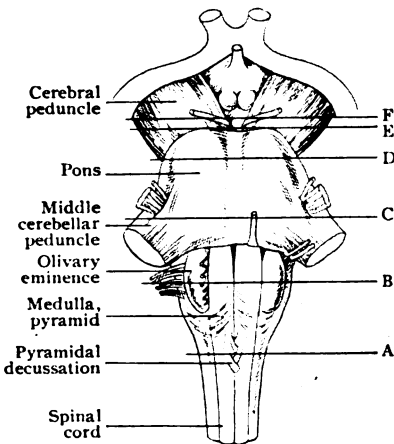


FIG. 329.—Ventral aspect of brain-stem; the lines lettered on right side indicate the levels of succeeding cross-sections.

It is regarded as beginning below at the lower border of the foramen magnum and extends upwards to the lower margin of the pons, a distance of about 2.5 cm. Its general form is tapering, increasing in breadth from the transverse diameter of the cord (10 mm.) below, to about twice as much (18 mm.) above, and in the antero-posterior dimension from 8 to 15 mm.

In many respects the medulla appears to be the direct continuation of the spinal cord. Thus, it is divided superficially into symmetrical halves by the anterior and posterior median fissures; each half is subdivided by a ventro-lateral and a dorso-lateral line of nerve-roots into tracts that seemingly are continuations of the columns of the cord. This correspondence, however,

is only superficial, cross-sections of the medulla revealing the presence of considerable masses of gray matter and important tracts of nerve-fibres not represented in the cord, as well as the rearrangement, modification or disappearance of spinal components prolonged into the bulb.

As just stated, each half of the medulla is subdivided into three longitudinal tracts, the *anterior*, *lateral* and *posterior areas*, by two grooves situated at some distance from the mid-line. Of these, the *antero-lateral furrow* marks the emergence of the root-fibres of the hypoglossal nerve, which are entirely motor and correspond to the ventral roots of the spinal nerves, with which they are in series. The other groove, the *postero-lateral furrow*, marks the attachment of the fibres of the ninth, tenth and bulbar part of the eleventh cranial nerves. These fibres are both afferent and efferent and do not correspond to the posterior roots of the spinal nerves.

Seen in transverse sections, the medulla, even at its lower end, presents new features, and towards its upper limit varies so greatly from the cord that only slight resemblance to the latter is retained. The characteristic

features displayed by sections of the medulla at different levels depend upon the changes induced chiefly by four factors: (1) the decussation of the pyramidal tracts, (2) the appearance of the dorsal nuclei, (3) the production of the formatio reticularis, and (4) the opening out of the fourth ventricle.

The **decussation of the pyramidal tracts**, assuming for convenience that the fibres pass from below upwards, produces conspicuous changes when followed in consecutive sections from the spino-bulbar junction upwards. The decussation first appears as strands of fibres that pass from the field of the lateral pyramidal tract, in the lateral column of the cord, obliquely through the adjacent anterior horn of gray matter and across the bottom of the anterior median fissure to gain the opposite anterior area of the medulla. At a slightly higher level (Fig. 330), where the decussation is fully estab-

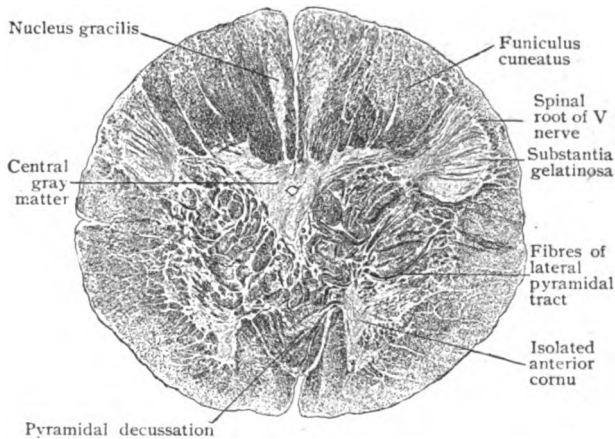


FIG. 330.—Section across medulla at level A, Fig. 329; fibres of pyramidal decussation almost fill anterior median fissure; posterior horns are displaced laterally by increased posterior columns.  $\times 5\frac{1}{2}$ . (Preparation by Professor Spiller.)

lished, the large strands of obliquely sectioned fibres are seen cutting through the gray matter, partly filling the median fissure, and collecting on either side of the latter as the large ventral bundles which thence upwards constitute the prominent pyramidal fields. In consequence of the greater space required by the pyramids, from 80–90 per cent. of the fibres having crossed, the isolated anterior horns of the gray matter (cut off by the crossing strands) and the adjacent anterior ground-bundles are displaced laterally. Higher, the ground-bundle assumes a position behind the pyramid and eventually becomes continuous with the posterior longitudinal fasciculus. The detached anterior cornu is pushed outwards and backwards and gradually becomes broken up by and interspersed among the fibres of the formatio reticularis.

The **posterior nuclei** include two new masses of gray matter, the *nucleus gracilis* and the *nucleus cuneatus* (Fig. 331), into which the long posterior tracts of the cord (Goll and Burdach) are prolonged. The **gracile nucleus**, the first encountered in passing upwards, begins on a level with the pyramidal decussation and rapidly increases in bulk until it invades the entire funiculus gracilis. The superficial stratum of spinal fibres, prolonged from Goll's tract, gradually diminishes as more and more of its components end in arborizations around the cells of the gracile nucleus, until, finally, all are interrupted. These neurones are multipolar and of varying

size; some are small, with dendrites ramifying close to the cell-body, and others, both large and small, with widely spreading branched processes. Meanwhile the **cuneate nucleus** appears within the funiculus cuneatus as a club-shaped mass of gray matter, which soon becomes a prominent mottled area. This nucleus, also composed of neurones with contracted or with widely spreading dendrites, extends to a higher level than the nucleus gracilis.

Owing to the increased bulk of the fasciculi of the posterior area occasioned by the appearance and expansion of the gracile and cuneate nuclei, the dorsal horns of the gray matter are displaced laterally and ventrally, so that they come to lie on a level with the central canal. Moreover, the posterior cornua themselves, particularly the capping *substantia gelatinosa*,

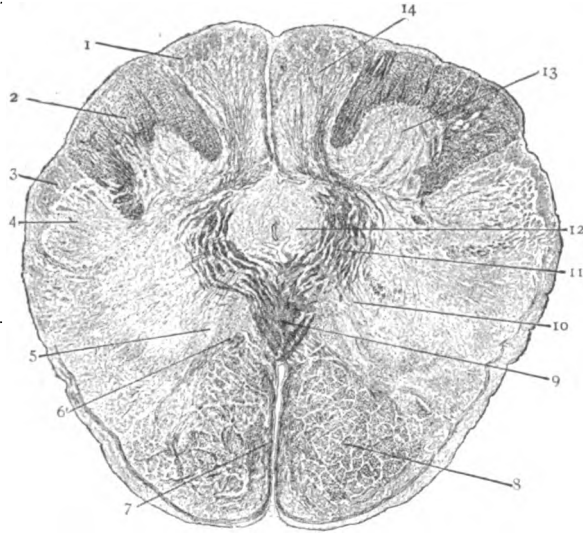


FIG. 331.—Section across medulla a few millimeters above level A, Fig. 329, showing increased posterior nuclei and *substantia gelatinosa*, sensory decussation and pyramidal tracts. 1, funiculus gracilis; 2, funiculus cuneatus; 3, spinal root of fifth nerve; 4, *substantia gelatinosa*; 5, accessory olivary nucleus; 6, displaced antero-lateral ground-bundle; 7, superficial arcuate fibres; 8, pyramidal tracts; 9, sensory (fillet) decussation; 10, fibres of twelfth nerve; 11, deep arcuate fibres; 12, central gray matter, surrounding canal; 13, nucleus cuneatus; 14, nucleus gracilis.  $\times 5\%$ . (Preparation by Professor Spiller.)

gain materially in bulk and now appear as two club-shaped masses of gray matter (Fig. 331) that cause the dorso-lateral projections, the *tubercula Rolandi*, seen on the surface. Beneath these elevations and closely overlying the areas of the *substantia gelatinosa*, crescentic tracts of longitudinally coursing nerve-fibres mark the position, one on each side, of the spinal roots of the trigeminal nerves.

The chief purpose of the gracile and cuneate nuclei being the reception of the long afferent tracts continued from the cord and the distribution of impulses so received to the cerebellum and to the higher centres, new paths arise within these nuclei. About the level of the upper limit of the pyramidal decussation, axones of their neurones emerge from the gracile and cuneate nuclei as the *deep arcuate fibres*, sweep forwards and inwards in bold curves and cross the mid-line to the opposite side of the medulla. Most of them then turn sharply upwards and form the beginning of the important sensory pathway known as the **median fillet** (*lemniscus medialis*). The lowest fibres that cross in this manner constitute a fairly well defined strand, the *sensory decussation* or *decussation of the fillet*. The crossing does not cease

with this decussation, for, on the contrary, it is only the beginning of an extended series of afferent arcuate fibres that pass across the mid-line at various levels throughout the brain-stem. Since many longitudinal fibres are encountered by those sweeping from side to side, an interweaving of vertical and horizontal fibres takes place, which results in the characteristic **formatio reticularis** that constitutes a large area within the medulla (Fig. 333), as well as within the dorsal or tegmental portions of the pons and cerebral peduncles.

The **olivary nuclei** include, in each half of the medulla, three masses of gray matter—the inferior olivary nucleus and the two accessory olivary nuclei. The *inferior olivary nucleus* is a corrugated sac-like lamina of gray matter which underlies and causes the conspicuous oval elevation, the *oliva*,

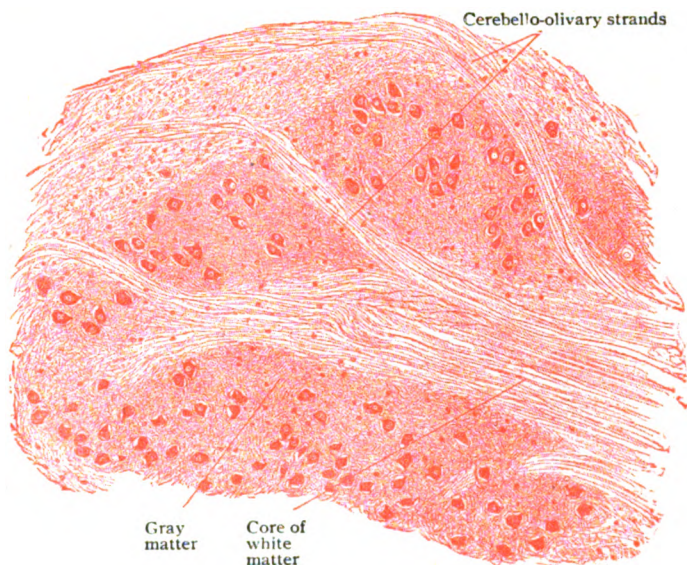


FIG. 332.—Section of inferior olivary nucleus, showing plicated sheet of gray matter traversed by strands of nerve-fibres.  $\times 100$ .

that occupies the upper half of the medulla at the outer side of the pyramid. In favorable cross-sections, the nucleus appears as a striking sinuous C-like figure (Fig. 333), the mouth of the sac or hilum looking mesially. The greatest length of the nucleus is from 12–15 mm. and the transverse diameter about half as much. The plicated lamina of gray matter, from .2–.3 mm. thick, contains numerous small rounded neurones, from 18–26  $\mu$  in diameter, each provided with from three to five branched dendrites and an axone, embedded within a complex of axis-cylinders and neuroglia. The interior of the gray sac is filled with white matter, consisting of nerve-fibres, that, for the most part, stream through the hilum and constitute the *olivary peduncle*. The *accessory olivary nuclei* are two irregular plates of gray matter that lie median and dorsal to the chief olive. The *median nucleus*, 10–11 mm. long, is sagittally placed between the tract of the fillet and the root-fibres of the hypoglossal nerve. The *dorsal nucleus* is less extensive than the median and lies close to and behind the hilum of the inferior olive. In structure the accessory nuclei resemble the gray matter of the chief one.

The **central canal** and surrounding **gray matter** are gradually displaced dorsally within the closed lower half of the medulla in consequence of the increasing space required by the pyramids, the fillet-tract and the posterior longitudinal fasciculi—tracts that lie close to the median raphe and enlarge as they are followed upwards. Where the central canal opens out into the fourth ventricle, the surrounding gray matter is correspondingly spread apart and becomes the lining of the ventricular floor (Fig. 333). Within this gray sheet and near the mid-line, on each side, lies the group of large richly branched nerve-cells ( $40-70 \mu$ ) constituting the *hypoglossal nucleus*, from which arise the fibres of the twelfth cranial nerve. These strands take a direct ventro-lateral course through the medulla and emerge on the anterior surface, in the groove between the pyramid and the olivary eminence or olive. Slightly lateral, and to the outer side of the hypoglossal

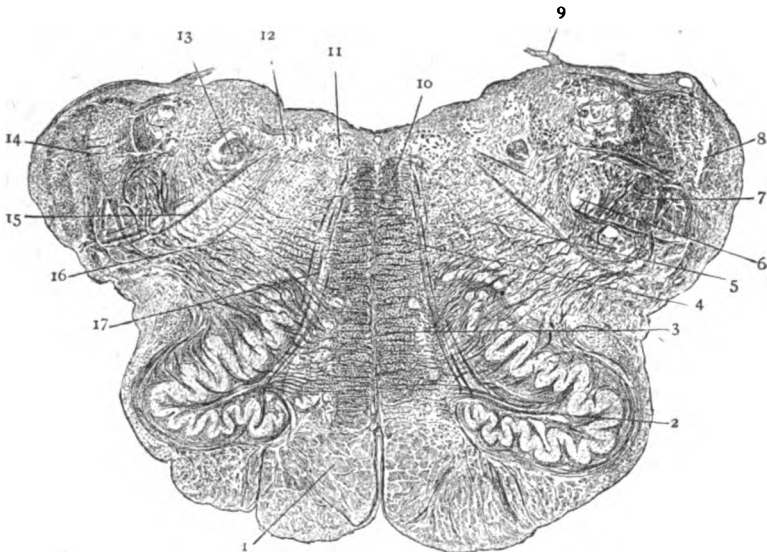


FIG. 333.—Section across medulla at level B, Fig. 329; 1, pyramidal tracts; 2, inferior olivary nucleus; 3, median fillet in ventral area; 4, formatio reticularis alba; 5, formatio reticularis grisea; 6, 7, trigeminal nucleus and root; 8, restiform body; 9, torn ventricular roof; 10, posterior longitudinal bundle; 11, nucleus of XII and (12) of X nerve; 13, fasciculus solitarius; 14, dorsal area; 15, fibres of X nerve; 16, lateral area; 17, fibres of XII nerve.  $\times 5$ . (Preparation by Professor Spiller.)

nucleus, another group of cells marks the position of the *dorsal vago-accessory nucleus*. These neurones are of small size ( $30-40 \mu$ ) and irregularly stellate or fusiform, and give origin to part of the motor fibres of the tenth and bulbar portion of the eleventh cranial nerves. The root-fibres of the vagus traverse the medulla obliquely and meet the surface in the dorso-lateral groove marking the junction of the posterior and lateral divisions of the medulla.

In this way, the diverging fibres of the tenth and twelfth nerves subdivide each half of the medulla, as seen in transverse sections, into three triangular areas—the dorsal, the lateral, and the ventral.

The **dorsal area**, between the dorsal surface of the medulla and the vagus-fibres, contains a number of important fibre-tracts: (1) The *restiform body*, or inferior cerebellar peduncle, appears as a large crescentic tract of transversely cut fibres that occupies the greater part of the periphery. (2)

The *descending root of the vestibular nerve* is seen as a field of loosely grouped bundles of cross-sectioned nerve-fibres to the inner side of the restiform body. (3) The *fasciculus solitarius* shows as a conspicuous transversely cut bundle that lies dorso-mesially to the vestibular root. (4) The *descending root of the trigeminal nerve* is readily identified as a superficial crescentic field enclosing on its mesial aspect the *substantia gelatinosa*.

The **lateral area**, between the diverging vagal and hypoglossal root-fibres, is occupied, in addition to (1) the *inferior olivary* and (2) the *dorsal accessory nucleus*, chiefly by the feltwork of fibres producing the *formatio reticularis*. In contrast to that within the ventral area, the reticulum of the lateral area contains considerable diffuse gray matter between its fibres and, hence, is known as (3) the *formatio reticularis grisea*. Accessions to the irregularly distributed nerve-cells, for the most part large and stellate or fusiform, occur as two more definite collections; one of these, (4) the *nucleus*

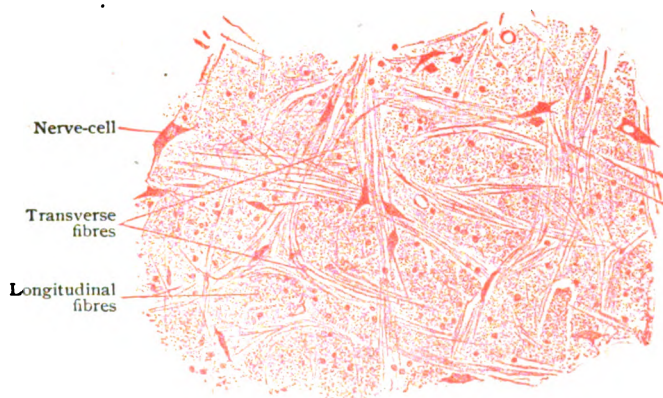


FIG. 334.—Portion of *formatio reticularis grisea* of medulla.  $\times 130$ .

*ambiguus*, consists of an inconspicuous group of large cells lying about the middle of the gray reticular substance; it is important as the ventral motor nucleus giving origin to at least a part of the motor fibres of the ninth and tenth nerves. The other collection, (5) the *nucleus lateralis*, includes an uncertain aggregation of medium-sized cells situated near the periphery, ventral to the trigeminal root. A separate group of somewhat larger neurones, near the ventral border of the trigeminus, is the *nucleus lateralis dorsalis*. In a general way, these nuclei (*ambiguus* and *lateralis*) of the *substantia grisea* may be regarded as homologues of the lateral horn cells of the cord, just as those of the hypoglossal nucleus resemble the anterior root-cells of the spinal nerves.

The **ventral area**, between the mid-line and the hypoglossal root-fibres, is occupied ventrally by (1) the *pyramidal tract*, which appropriates the entire width of the field with the exception of a very narrow peripheral zone that intervenes between the pyramid and the surface along the median fissure and the ventral aspect of the medulla. This zone is traversed by (2) the *anterior superficial arcuate fibres*, among which lies an irregular column of nerve-cells, (3) the *arcuate nucleus*. Dorsal to the pyramidal tract and next the mid-line, lies (4) the compact *tract of the median fillet*, composed of longitudinal strands that are the upward continuations of the deep arcuate fibres that at lower levels have bent brainwards, after crossing the mid-line.

The fillet-tracts are also known as the *interolivary stratum*, since they form a compact and compressed field between the inferior olivary nuclei. Between the fillet-tract and the hypoglossal fibres is (5) the *mesial accessory nucleus*. (6) The *posterior longitudinal fasciculus* appears in cross-section as a compact strand, next the raphe and immediately beneath the gray matter of the floor of the fourth ventricle. The remaining space of the ventral field, between the pyramid and the ventricular gray matter, is occupied by (7) the

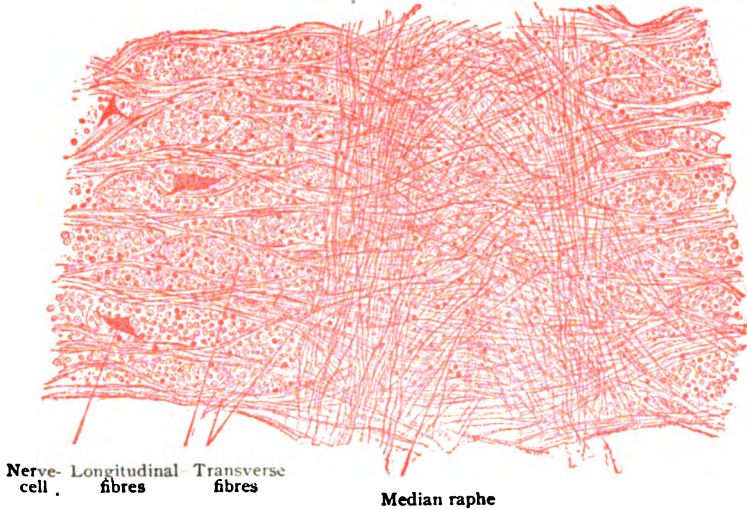


FIG. 335.—Portion of formatio reticularis alba of medulla.  $\times 130$ .

*formatio reticularis alba*, so designated, in distinction to the *formatio grisea*, on account of the meagre amount of its gray matter and small number of its nerve-cells, since, with the exception of in the immediate vicinity of the mid-line, where the *nucleus raphe* is found, these are almost wanting.

Although at higher levels additional and important masses of gray matter appear, especially those related to the auditory nerve, for the purpose of these pages the foregoing general description of the medulla, as seen in typical section, must suffice.

## THE PONS VAROLII.

Viewed from in front, the pons appears as a quadrilateral prominence, from 25–28 mm. long, interposed between the medulla below, the cerebral peduncles above, and the cerebellar hemispheres at the sides. Its lower and upper limits are well defined, but at the sides the narrowed mass of the pons is directly continued, downwards and backwards, into the cerebellum as *middle cerebellar peduncles*. The free portion of the dorsal surface of the pons forms the upper half of the floor of the fourth ventricle and is, therefore, not visible until the roof of that cavity is removed. Above the middle peduncles, the sides of the pons are blended with the overlying superior cerebellar peduncles, which, with the membranous superior medullary velum, complete the ring of tissue surrounding the narrow upper end of the fourth ventricle.

In transverse section (Fig. 336), the pons is seen to include two clearly defined areas, the ventral and the dorsal. The **ventral part**, or *pars*



*basalis*, is largely occupied by the bulky pyramidal tracts, which are now excluded from the surface by a conspicuous layer of superficial transverse fibres, the *stratum superficiale pontis*, that laterally sweeps backwards into

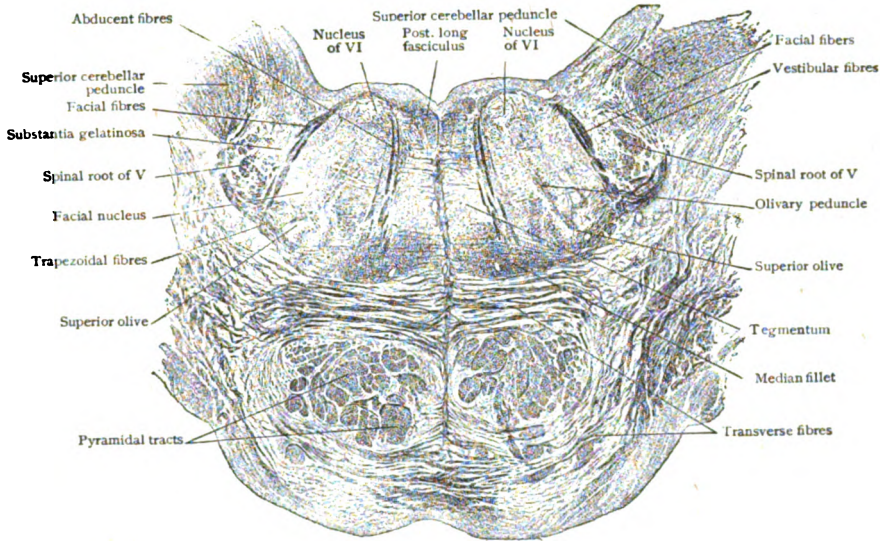


FIG. 336.—Section across pons at level C, Fig. 329, showing subdivision into ventral and dorsal areas.  $\times 3$ . (Preparation by Professor Spiller.)

the cerebellar peduncles. The pyramids, however, no longer appear as compact fields, as in the medulla, but are broken up into smaller bundles by the transverse strands of the *ponto-cerebellar fibres*. This subdivision is

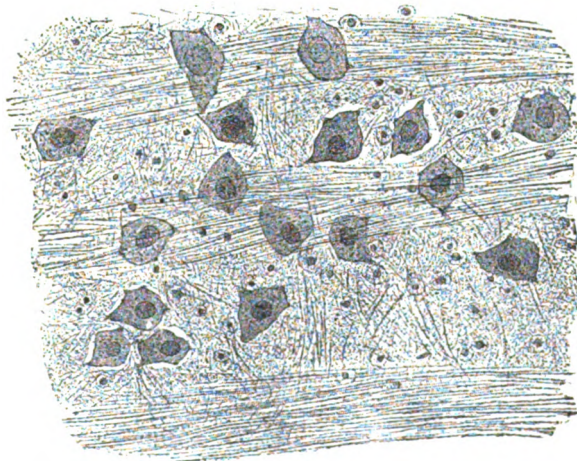


FIG. 337.—Portion of ventral area of pons, showing cells of pontile nucleus.  $\times 300$ .

more marked at higher levels of the pons, where the interweaving of the longitudinal and transverse bundles produces a coarse feltwork, the *stratum complexum*. At the upper border of the pons, the scattered pyramidal

bundles become once more collected into two compact strands, which are continued into the crusta of the cerebral peduncles. The dorsal limit of the ventral field is occupied by the *stratum profundum pontis*, a well marked layer of deep transverse fibres. A considerable amount of gray matter, collectively known as the *pontile nucleus*, is distributed within the interstices between the bundles of nerve-fibres. The numerous cells of this nucleus (Fig. 337), generally small in size and stellate in form, are related to the ponto-cerebellar fibres of the same and of the opposite side, many being stations of interruption in the cortico-cerebellar paths.

The **dorsal or tegmental part** of the pons resembles in its general structure to a considerable extent the *formatio reticularis grisea* of the

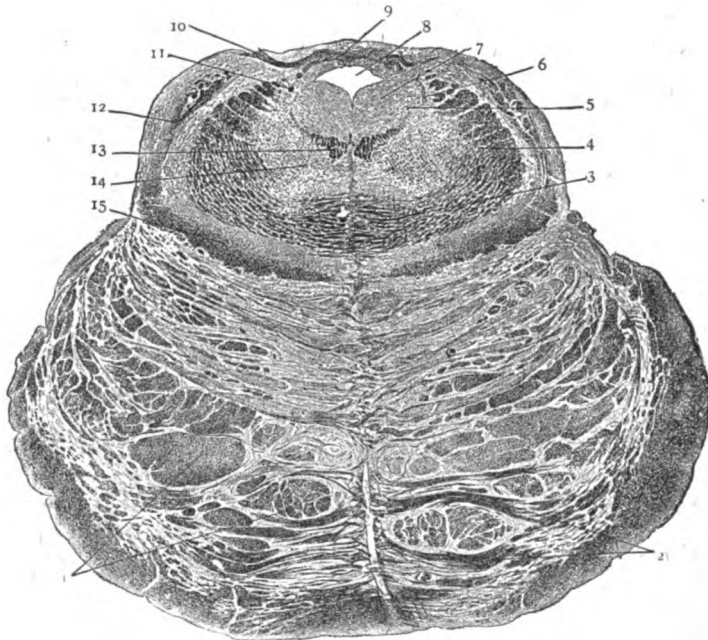


FIG. 338.—Section across pons at level D, Fig. 329; 1, pyramidal tracts; 2, transverse fibres; 3, decussation and (4) arm of superior cerebellar peduncle; 5, nucleus and (6) descending root of V nerve; 7, gray matter surrounding (8) Sylvian aqueduct; 9, 10, 11, parts of IV nerve and its decussation; 12, lateral fillet; 13, posterior longitudinal fasciculus; 14, tegmental area; 15, mesial fillet.  $\times 3$ . (Preparation by Professor Spiller.)

medulla, consisting for the most part of a reticulum of transverse and longitudinal fibres, interspersed with nerve-cells, on each side of the median raphe. The appearance of certain masses of gray matter and of nerve-fibres, together with changes in the position of the fillet, produces details that vary with the level of the section. When this passes just above the lower margin of the pons (Fig. 336), two diverging and obliquely cut strands of fibres mark the root-fibres of the sixth and seventh cranial nerves and divide the tegmental region, on each side, into three areas. The **middle area**, between the abducent fibres mesially and the facial ones laterally, contains three important collections of nerve-cells. One of these, the *nucleus of the sixth nerve*, lies close to the floor of the ventricle and near the mid-line. The axones of these neurones, the root-fibres of the abducent (sixth) nerve, take an oblique ventral path and cut through not

only the tegmental but also the ventral part of the pons to gain its lower border, along which they emerge. Another nucleus of the middle area, the *superior olivary nucleus*, lies near the ventral limit of the tegmental area, partly lodged within an indentation on the dorsal aspect of the conspicuous tract of transverse fibres, the *corpus trapezoides*. This nucleus, often called the *superior olive*, is an irregular spherical collection of neurones interposed in the path connecting the auditory nuclei with the cerebral cortex and closely related with the tract of the *lateral fillet*. A small collection of nerve-cells between the fibres of the trapezoidal tract constitutes the *nucleus trapezoides*. The *facial nucleus* is a broken mass of gray matter that includes several groups of large stellate motor neurones lying to the inner side of the emerging facial root-fibres.

The ventral part of the **inner area** and the adjoining portion of the middle one are occupied by the field of the *median fillet*, which, at the level under consideration, no longer lies with its long axis directed dorso-ventrally, but approximately horizontal (Fig. 336). The tract now appears as a compressed and modified oval, with the thicker inner end close to the raphe and the tapering outer one near the superior olive. The *posterior longitudinal fasciculus* is seen as a compact strand, immediately beneath the gray matter of the ventricular floor and at the side of the raphe. Within the **outer area**, lateral to the facial fibres, appear the *substantia gelatinosa* and the associated *descending root of the trigeminal nerve*. Just dorsal to the latter, the *descending vestibular root* lies close to the inner side of the *restiform body*.

### THE CEREBRAL PEDUNCLES.

That part of the brain-stem which encloses the Sylvian aqueduct corresponds approximately with the morphological division of the brain known as the *mesencephalon*. The latter includes two main subdivisions: (1) the smaller dorsal part, the *quadrigeminal plate*, which roofs the Sylvian aqueduct and bears the corpora quadrigemina, and (2) the much larger ventral part made up by the *cerebral peduncles*.

The latter, also called the *cerebral crura*, are fused dorsally into a continuous tract, the *tegmentum*, which contributes the side-walls and floor of the Sylvian aqueduct and blends with the overlying quadrigeminal plate. Ventrally the peduncles are unfused and appear on the inferior surface of the brain (Fig. 327) as two robust diverging stalks, enclosing the lower half of the interpeduncular space. In transverse sections (Fig. 339), each stalk is seen to include a ventral zone composed of cross-cut nerve-fibres, the *crusta*, and a crescentic area of deeply pigmented gray matter, the *substantia nigra*, that separates the crusta from the tegmentum.

Disregarding the several small nuclei, the nuclei of the corpora quadrigemina and the red nuclei, the **gray matter** within the mesencephalon is disposed as three tracts that extend its entire length. These are the tubular mass of the *central gray matter*, which surrounds the aqueduct, and the two crescentic columns of the *substantia nigra*, which subdivide the peduncles into the tegmental and crustal parts.

The **central gray matter** (*stratum griseum centrale*) encloses the Sylvian aqueduct and contains numerous irregularly scattered nerve-cells of uncertain form and size and, along its ventral border, the nuclei of the *oculomotor* and *trochlear nerves*; within its lateral parts lie the nuclei from which proceed the fibres of the mesencephalic roots of the trigeminal nerves.

The **substantia nigra** owes its dark color to the deep pigmentation of its numerous nerve-cells. The latter are of medium size and of various form, spindle-shaped elements, interspersed with some stellate and a few pyramidal ones, predominating. They enclose accumulations of dark brown pigment that render the cells unusually conspicuous. The concave dorsal margin of the pigmented crescent is continuous and even, but the convex boundary is broken into irregular scallops by processes of gray matter that penetrate the subjacent crusta.

The **crusta**, the bold sickle-shaped field that occupies the most ventral part of the peduncle (Fig. 340), consists chiefly of longitudinal fibre-tracts, which are passing from the cerebral cortex, by way of the internal capsule,

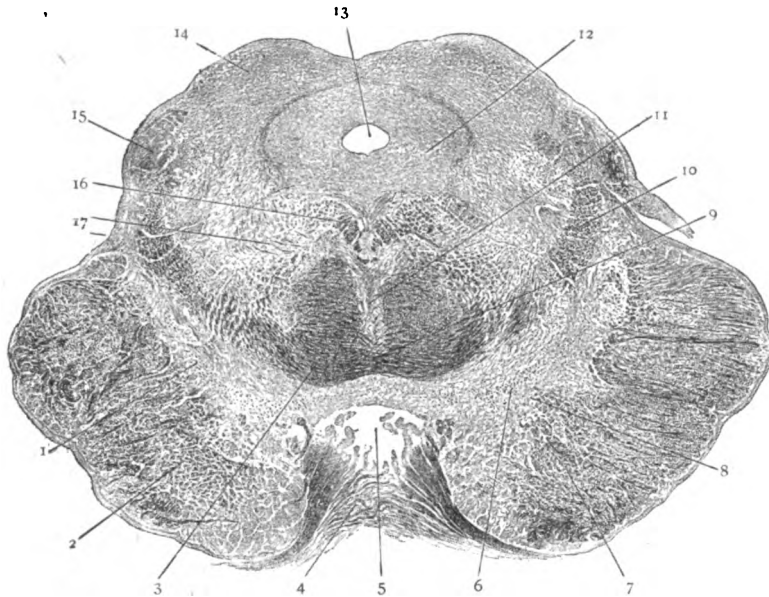


FIG. 339.—Section across brain-stem (mid-brain) at level E. Fig. 329. 1, substantia nigra, separating crusta from tegmentum; 2, crusta of cerebral peduncle; 3, superior cerebellar peduncle and (9) its decussation; 4, part of pons; 5, interpeduncular space; 6, substantia nigra; 7, motor tracts in crusta; 8, stratum intermedium; 10, mesial fillet; 11, fountain decussation; 12, central gray substance; 13, Sylvian aqueduct; 14, inferior colliculus of corpora quadrigemina; 15, inferior brachium; 16, posterior longitudinal fasciculus; 17, tegmental field.  $\times 3$ . (Preparation by Professor Spiller.)

to lower levels in the brain-stem and the spinal cord. The longitudinal fibres are separated into bundles by the invasion of numerous strands from the fibre-complex known as the *stratum intermedium*, which lies along the ventral border of the substantia nigra. The fibres of the crusta include three general sets: (1) the *cortico-pontile fibres*, passing from the cells of the cerebral cortex to the cells of the pontile nucleus as links in the cortico-cerebellar paths; (2) the *cortico-bulbar fibres*, passing as axones from the motor neurones of the cerebral cortex to the nuclei of motor fibres originating within the pons and medulla; (3) the *cortico-spinal fibres*, passing as axones from the cerebral motor neurones, through the ventral tracts of the brain-stem, into the pyramidal tracts of the spinal cord, to end around the radicular cells.

The **tegmentum** of the mid-brain includes, as seen in transverse sections (Fig. 339), the area bounded by the corpora quadrigemina behind

and the crescents of the substantia nigra in front. In the vicinity of the central gray matter, the tegmentum consists chiefly of a *reticular foundation* resembling the *formatio reticularis* seen at lower levels. This substance is produced by the intermingling of transverse or arcuate and longitudinal fibres, together with a meagre amount of gray matter, with irregularly distributed cells, that fills the interstices between the strands of fibres. The more lateral and ventral parts of the tegmentum are occupied to a large extent by the prominent fibre-tracts belonging to the mesial and lateral *fillets* and to the *superior cerebellar peduncles*, or by collections of gray matter, the *red nuclei*.

The **nucleus ruber**, or *nucleus tegmenti* (Fig. 340), is of ovoid form and reddish tint, when fresh, and consists of a complex of gray matter and nerve-fibres. The latter preponderate below, where the red nucleus receives

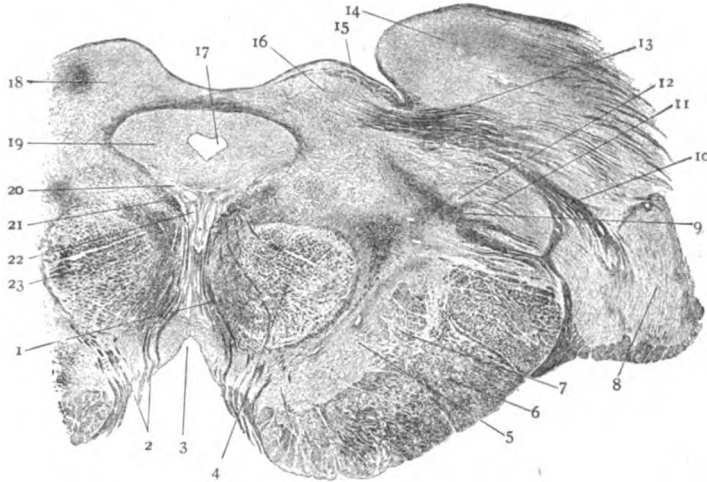


FIG. 340.—Section across brain-stem (mid-brain) at level F, Fig. 329. 1, 2, root-fibres of oculomotor nerve; 3, interpeduncular space; 4, red nucleus; 5, substantia nigra; 6, crista of cerebral peduncle; 7, stratum intermedium; 8, lateral geniculate body; 9, fillet fibres; 10, superior brachium; 11, median geniculate body and (12) its nucleus; 13, optic fibres; 14, pulvinar of optic thalamus; 15, stratum zonale of (16) superior colliculus; 17, Sylvian aqueduct; 18, sup. colliculus; 19, central gray substance; 20, 22, nucleus of oculomotor nerve; 21, posterior longitudinal fasciculus; 23, red nucleus.  $\times 2\frac{1}{4}$ . (Preparation by Professor Spiller.)

the fibres of the superior cerebellar peduncle, but are much less numerous above, since many fibres come to an end around the rubral neurones. These elements are very variable in size (20–60  $\mu$ ) and shape, but are mostly irregularly triangular or stellate. The red nuclei not only constitute important stations in the path connecting the cerebellum with the spinal cord (*cerebello-rubro-spinal fibres*), but also probably contribute links in the chain uniting the cerebral cortex with the cord (*cerebro-rubro-spinal fibres*). While some of the constituents of the superior cerebellar peduncle pass around the red nucleus and continue, as *cerebello-thalamic fibres*, uninterruptedly to the optic thalamus, the majority of the fibres of the peduncle end around the neurones of the nucleus, from which then proceed axones as the *rubro-thalamic fibres*. It is important to remember that, in a general way, the ventral part of the brain-stem transmits the great efferent or motor paths, while within the dorsal or tegmental part ascend the chief afferent or sensory tracts. The posterior longitudinal fasciculus serves as an association-path linking together the nuclei of the cranial nerves.

## THE CEREBELLUM.

The cerebellum occupies the posterior fossa of the skull and lies behind the pons and medulla and the fourth ventricle (Fig. 328). By means of its three peduncles—inferior, middle and superior—the cerebellum is connected with the medulla, the pons and the mid-brain respectively. Its surface is divided by the deeper fissures into *lobules*, each of which is subdivided by shallower clefts into narrow tracts, the *folia*, from 2–4 mm. wide, that, within a given lobule, in a general way parallel one another.

With the exception of where the robust peduncles enter the hemispheres and immediately above the dorsal recess of the fourth ventricle, the cerebellum is everywhere covered by a continuous sheet of *cortical gray matter* which follows and encloses the subdivisions of the *medullary layer*. The latter, as exposed in sagittal sections (Fig. 341), appears as a compact

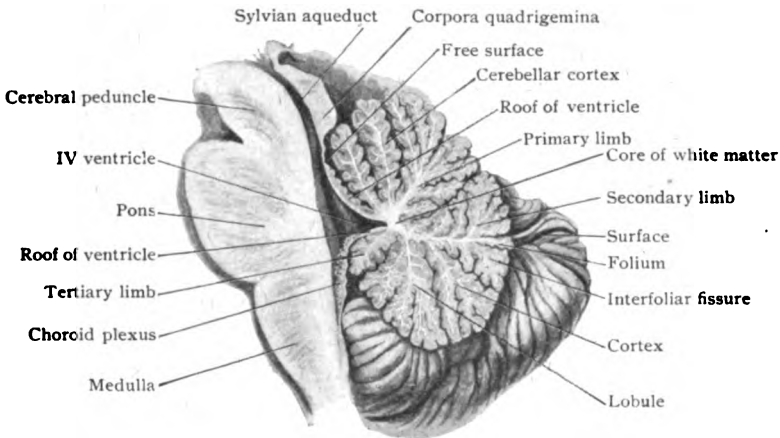


FIG. 341.—Mesial sagittal section of brain-stem and cerebellum, showing fourth ventricle and relations of the central white matter and its limbs to the continuous sheet of gray cortex.

central mass of white matter, from which stout stems radiate into the various lobules. From these primary stems, secondary branches penetrate the subdivisions of the lobules, and from the sides of these, in turn, smaller tracts of white matter, the tertiary branches, enter the individual folia. Over these ramifications of the white core, the cortical gray matter stretches as a fairly uniform layer, about 1.5 mm. thick, that closely follows the complexity of the folia and fissures. The resulting arborization and the contrast between the white and gray matter, best seen in sections passing at right angles to the folia, produce a picture known as the *arbor vitæ cerebelli*.

**The Cerebellar Cortex.**—The cortical gray matter (Fig. 342) includes two very evident strata—the outer and lighter *molecular layer* and the inner and darker *granule layer*.

The **molecular layer** is of uniform thickness, about .4 mm., and contains three varieties of nerve-cells: the Purkinje cells, the basket-cells and the small cortical cells. The **Purkinje cells**, the most distinctive elements of the cerebellum, occupy the deepest part of the molecular layer, where they are disposed in a single row along the junction of the outer and inner layers. The cells are more numerous and closely placed upon the summit

of the folium than along the fissures, in which latter situation they are often less typical. They possess a large flask-shaped body, about  $60\ \mu$  in diameter, from the pointed and outwardly directed end of which usually a single robust *dendrite* arises. The chief process, relatively thick and very short, divides into two branches, which at first diverge and run more or less horizontally and then turn sharply outwards to assume a course vertical to the surface and to undergo repeated subdivision. The arrangement of the larger dendrites is very striking and recalls the branching of the antlers of a deer. The smaller processes arise at varying and often acute angles, the completed branching resulting, as seen in silver preparations (Fig. 343), in an arborization of astonishing richness and extent, that may reach almost to the outer boundary of the molecular layer. The dendritic ramification of each cell is

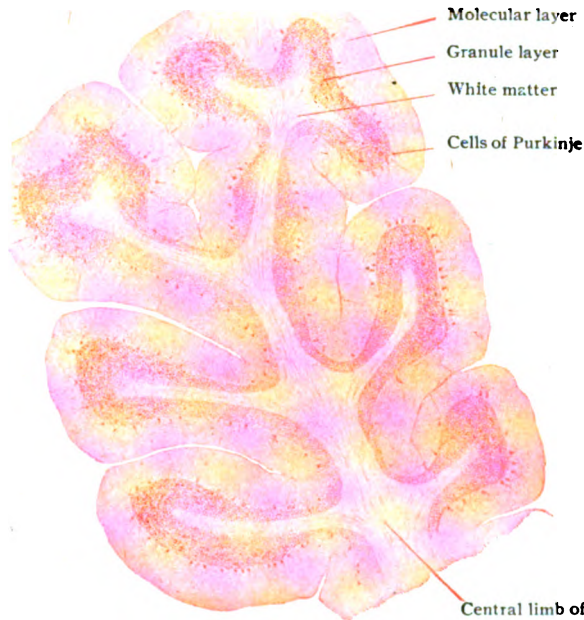


FIG. 342.—Section across cerebellar folium, showing relations of cortex to underlying white matter.  $\times 10$ .

limited, however, to a narrow zone extending across the folium and, hence, when examined in sections cut parallel with the plane of the folium, the expansions of these cells are found to be confined to tracts separated by zones of the molecular layer that are uninvaded by the dendrites. The *axone* of the Purkinje cell arises from the rounded basal or deeper end of the body and at once enters the subjacent granule layer, which it traverses to gain the white medullary substance of the folium. During their course the axones give off a few recurrent collaterals that lose themselves within the granule layer or end, in part, within the molecular stratum.

The **basket-cells** lie chiefly within the deeper half of the molecular layer. They possess an irregular stellate body ( $10\text{--}20\ \mu$ ), from which several dendrites radiate. Their chief feature is the axone, which extends across the folium along and to the outer side of the Purkinje cells. During this course, the axone gives off from three to six collaterals that descend to the cells of Purkinje, whose bodies they surround and enclose with a basket-

like arborization, the terminal ramification of the main process itself ending in like manner. By this arrangement each basket-cell is brought into close relation with several of the Purkinje cells, an association probably of consequence in insuring coördination.

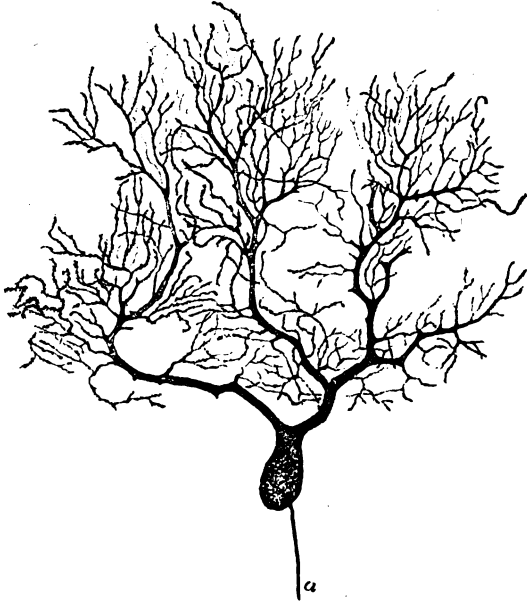


FIG. 343.—Purkinje cell from human cerebellar cortex; silver preparation; *a*, axone.  $\times 180$ .

The **small cortical cells** include two varieties. One is represented by neurons of about the size of the basket-cells, or slightly smaller, provided with few dendrites and an axone distinguished by its delicacy, great length and tendency to ramify in curves or even loops. The other kind is somewhat smaller and possesses axones that are short and soon branch.

The **granule layer**, of a rust-brown tint when fresh and deeply colored in stained preparations, is thickest on the summit of the folia and thinnest opposite the bottom of the fissures. While sharply defined from the overlying molecular layer, it is

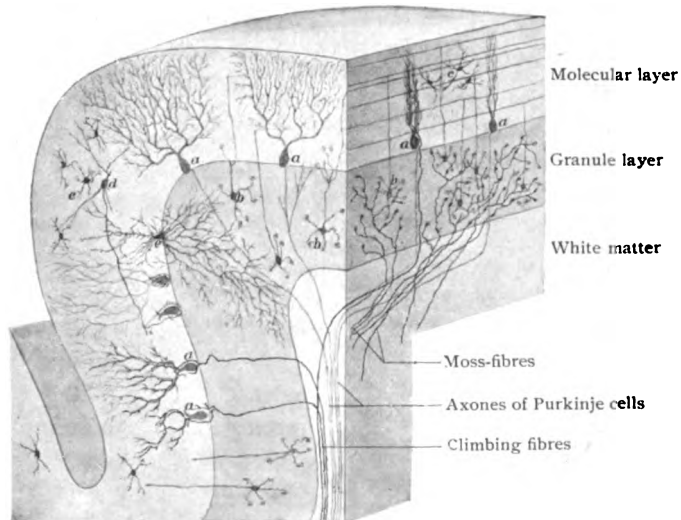


FIG. 344.—Diagrammatic reconstruction of part of folium, illustrating relations of nerve-cells and fibres of cerebellar cortex; transverse (left) and longitudinal (right) cut surfaces of folium are shown; *a*, Purkinje cells; *b*, granule cells; *c*, small cortical cells; *d*, basket-cells; *e*, large association cell of type II.

less clearly demarcated from the medullary substance, with which it some-



what blends. The granule layer contains two varieties of nerve-cells—the granule cells and the large stellate cells.

The **granule cells** are very small ( $7-10\ \mu$ ) and numerous and so closely packed that they confer a distinct density on the stratum, of which they are the chief components. They are provided with from three to six short radiating dendrites that end in peculiar claw-like arborizations (Fig. 344) in relation with other granule cells. Their axones, directed towards the surface, enter the molecular layer, within which they undergo T-division at various levels, corresponding to the depth at which the cells lie. The two resulting branches run horizontally and lengthwise in the folium, that is, parallel to the surface and at right angles to the plane of expansion of the Purkinje dendrites, through whose arborizations they find their way and with which they probably come into close relation. The axones apparently end free and without arborizations.

The **large stellate cells** are present in varying number, but are never many. They lie close to the outer limit of the granule layer and possess a cell-body of uncertain and irregular form, from  $30-40\ \mu$  in diameter, from which usually several richly branched dendrites pass in different directions, but largely into the molecular layer. The axone is most distinctive, since very soon after leaving the cell-body it splits up into an arborization of unusual extent and complexity, which, however, is confined to the granule layer. These cells, therefore, belong to type II (page 66). Since their processes are brought into intimate relation with a number of other neurones, these elements are probably association cells. Additional nervous elements within the granule layer, few in number and fusiform in outline, are described as the *solitary cells*, concerning which little is known.

The **cortical nerve-fibres** include three chief varieties. (1) The *axones of Purkinje cells* contribute an inconsiderable portion of the fibres passing between the cerebellar cortex and medullary substance. They end, for the most part, in the dentate nucleus within the white core

near the root of the superior cerebellar peduncles, some probably terminating in the smaller internal nuclei and, perhaps, in relation with the cells of the vestibular and inferior olivary nuclei. (2) The so-called *moss-fibres*, which ascend from the medullary into the granule layer, within the latter repeatedly branch and bear moss-like tufts that end in large part in irregular small masses of stainable substance, known as the *eosin-bodies*, that lie between the granule cells (Fig. 345). According to Cajal, these bodies are formed by the intricate interlacement of the terminal ramifications of the afferent axones and the dendrites of the granule and, perhaps, also of the axones of the Golgi cells. In view of their convoluted complexity they have been called the *glomeruli* of the cerebellum. Other filaments of the moss-fibres are continued into the molecular layer, bending horizontally and repeatedly branching. (3)

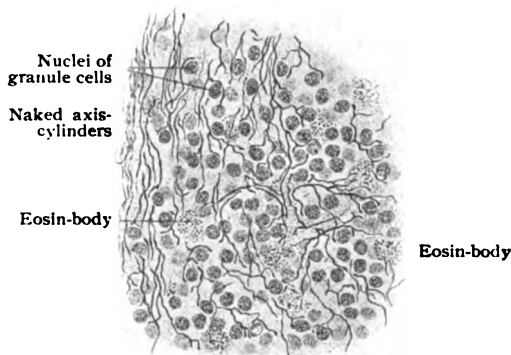


FIG. 345.—Portion of granule layer of young cerebellum, showing eosin-bodies and nerve-fibres.  $\times 220$ .

The *climbing-fibres* ascend through the granule to the molecular layer, where their tendril-like ramifications entwine and cling to the principal dendrites of the Purkinje cells. Additional fibres within the granule layer are, evidently, the axones of the granule cells and the collaterals of the cells of Purkinje, whilst a large proportion of the fibres within the molecular layer are the ramifications of the axones of the granule, the basket and the smaller cortical cells.

The **neuroglia** forms a supporting framework of considerable density within both the cortex and the medulla. In preparations colored with nuclear stains, the neuroglia cells are conspicuous within the granule layer, to whose numerous small nuclei they materially contribute. A number of relatively large neuroglia cells lie within the outer part of the molecular layer, near the Purkinje cells; in addition to short and irregular centrally directed processes, these elements give off brush-like groups of fibres which penetrate the molecular layer, seldom branching, as far as the surface of the folium, where they end in minute triangular expansions. By the apposition of the latter a delicate subpial condensation, a sort of limiting membrane, is produced. The radial disposition of the neuroglia fibres, as well as of the Purkinje dendrites, climbing fibres and larger blood-vessels, confer upon the molecular layer a vertical striation. Other neuroglia cells, stellate with spider-like radiating fibres, occupy all levels of the molecular layer; similar cells, with more extended processes, occur between the nerve-fibres of the medullary substance.

**The Internal Nuclei.**—In addition to and unconnected with the cerebellar cortex, four paired masses of gray matter, the *internal nuclei*—one of considerable size and the others small—lie embedded within the white matter.

The **nucleus dentatus**, or *corpus dentatum*, the largest and most important of the internal nuclei (Fig. 346), consists of a plicated sac of gray matter, enclosing nerve-fibres, and resembles in many respects the inferior olivary nucleus. It lies within the anterior part of the median half of the hemisphere and measures from 15–20 mm. in its longest dimension.

Of the other paired internal collections of gray matter—the nucleus fastigii, the nucleus emboliformis and the nucleus globosus—the **nucleus fastigii**, or the *roof-nucleus*, is the best defined. It is an egg-shaped mass, about 10 mm. long, and lies within the core of the worm (the tract connecting the hemispheres) close to the mid-line and to its fellow of the opposite side.

The **nucleus emboliformis** and the **nucleus globosus** are irregular masses of gray matter lying between the dentate and roof-nuclei, with which they are respectively united, as well as with each other.

In **structure** the internal nuclei differ markedly from the cerebellar cortex, since in the main they are composed of irregularly disposed nerve-cells of one kind, interspersed with nerve-fibres. The *dentate nucleus* contains cells (20–30  $\mu$ ), angular or stellate in outline and pigmented. Their processes are usually so disposed that the axones pass into the medullary substance enclosed by the plicated lamina and the dendrites into the surrounding white matter of the hemisphere. Numerous fibres enter the dentate body from without, many being the axones of Purkinje cells, and ramify within the folded sheet of gray substance. Since the nuclei emboliformis and globosus are only incompletely separated parts of the dentate nucleus, their structure corresponds closely with that of the chief mass. The *roof-nuclei*, on the contrary, possess cells of much larger size (40–80  $\mu$ ), more rounded form and greater uniformity in tint, although they are distinctly

pigmented. Numerous strands of nerve-fibres subdivide the nucleus into secondary areas, while some large transversely coursing bundles establish a decussation with the roof-nucleus of the opposite side. Notwithstanding

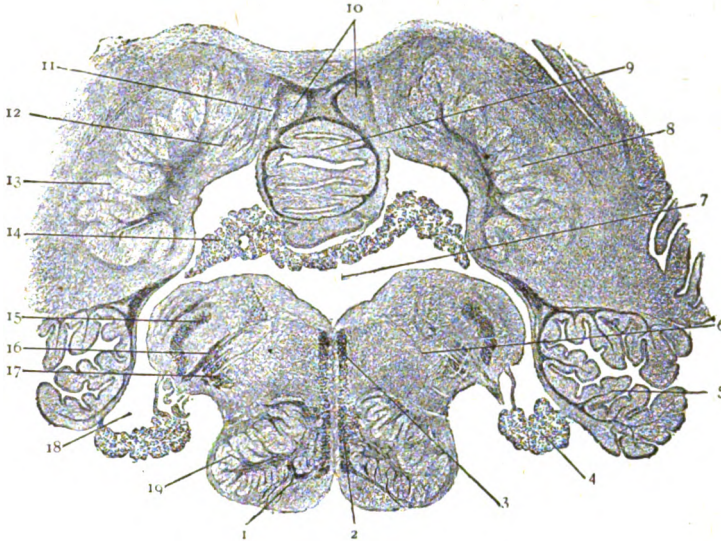


FIG. 346.—Transverse section through fourth ventricle and surrounding parts of brain-stem and of cerebellum and its internal nuclei: 1, pyramidal tracts; 2, mesial fillet; 3, posterior longitudinal fasciculus; 4, choroid plexus; 5, cerebellar folia; 6, medulla; 7, fourth ventricle; 8, nucleus dentatus; 9, inferior horn; 10, nucleus fastigii or roof-nucleus; 11, nucleus globosus; 12, nucleus emboliformis; 13, nucleus dentatus; 14, choroid plexus; 15, restiform body; 16, fibres of vagus nerve; 17, spinal root of fifth nerve; 18, lateral recess; 19, olivary nucleus.  $\times 3\frac{1}{2}$ . (Preparation by Professor Spiller.)

their small relative size, the dentate and roof-nuclei are important stations, since from their cells arise the fibres composing the greater part of the superior cerebellar peduncle. The dentate nuclei are of additional interest as the destination of many axones from the Purkinje cells.

### THE CEREBRUM.

The cerebrum—the “great brain” as distinguished from the cerebellum—comprises, in a general way, the large hemispheres and the parts surrounding the third ventricle. With the exception of where the peduncles enter and the portion of the mesial surface below the great bridge, the corpus callosum, connecting the hemispheres, the cerebrum is everywhere invested with a continuous sheet of gray matter, the **cerebral cortex**. On account of the complex convolutions of the surface, the cortex is thrown into conspicuous folds that mark the convolutions and the intervening fissures and enclose the penetrating tracts of white matter prolonged from the general medullary substance. The cortical sheet varies in thickness not only in the same area, being thicker over the summit than along the sides of the convolutions or at the bottom of the fissures, but in different regions. Its average thickness is about 3 mm., but where it borders the upper end of the Rolandic fissure, this increases to almost 5 mm., whilst over the occipital poles the thickness of the cortex is reduced to about 2 mm. The entire superficial extent of the cortex has been estimated to be about 2000 sq. cm., of which scarcely one third is exposed surface, the remainder being sunken. According to Donaldson, the cortex contributes about one half of the weight of the brain.

The essential histological elements of the cerebral cortex are the nerve-cells and the nerve-fibres. The importance of the former is evident when their three-fold activity is recalled—(1) as receptors of afferent or corticopetal impulses, (2) as distributors of the impressions so received to other parts of the brain, and (3) as originators of efferent or corticofugal impulses which control the nuclei from which immediately arise the motor nerves. No single method of preparation suffices to display satisfactorily both groups of structural elements, for when stains are employed which best bring out the cells, the fibres are inadequately shown; and, conversely, when methods adapted for the demonstration of the fibres are followed, the cells are but imperfectly displayed. It is advantageous, therefore, to study the histological details of the brain by more than a single method, combining the results obtained by the use of cellular stains with those yielded by procedures exhibiting the fibres. Among the latter, the well-known method of Weigert, or its modifications, has been of great service in extending our knowledge concerning the various fibre-tracts. The methods of silver-impregnation introduced by Golgi, although not producing true staining but only incrustations on the cell and its processes, have materially advanced our knowledge concerning the form of the cell-bodies and the number and extent of the processes of the neurones.

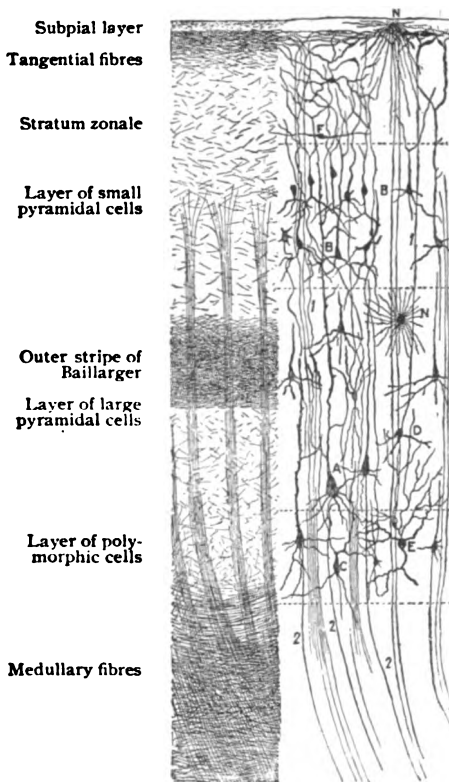


FIG. 347.—Diagram illustrating composition of cerebral cortex; cells in right half, fibres in left half of figure; *A, B*, large and small pyramidal cells; *C*, polymorphic cells; *D*, cell of Martinotti; *E*, cell of type II; *F*, association cell; 1, 1, fibres passing to cortex; 2, 2, 2, fibres passing from cortex; *N*, neuroglia cells.

While varying as to details in different regions, the cerebral cortex presents a general plan of structure which may be considered: (*a*) in relation to the nerve-cells and (*b*) in relation to the nerve-fibres.

**The Nerve-Cells of the Cortex.**—When sections cut perpendicular to the surface of the convolution are stained with basic stains (Fig. 348) or prepared after silver impregnation (Fig. 349), the cerebral cortex exhibits four principal layers, which, from without inwards, are: (1) the stratum zonale, (2) the layer of small pyramidal cells, (3) the layer of large pyramidal cells, and (4) the layer of polymorphic cells. Although each presents characteristics which are distinctive, with the exception of the junction between the first and second layers, where the change is well defined, no sharp demarcation separates the strata, each passing insensibly into the adjoining layer. Neither are the modifications which distinguish the cortex of certain regions abruptly assumed, one type of cortical structure being gradually replaced by another without sudden transition.

The **stratum zonale**, also known as the *molecular stratum*, underlies the pia and measures about .25 mm. in thickness. The layer contains few nerve-cells and appears subdivided into (a) a narrow peripheral zone, from 10–30  $\mu$  in width, composed of a subpial condensation of neuroglia and (b) a deeper zone characterized by numerous fibres or processes, which course parallel to the surface, and a meagre number of nerve-cells whose most distinctive representatives are small fusiform elements (*Cajal's cells*) provided with long tangentially directed processes. The latter give off short collaterals, which ascend towards the surface, and intermingle with the numberless terminal filaments derived from the peripherally coursing processes of the pyramidal and other cells lying at deeper levels and from the corticopetal fibres which continue from the white core of the gyrus into the outermost layer of the cortex.

The **layer of small pyramidal cells** is marked off from the stratum zonale, which it about equals in thickness, with some distinctness since, in contrast to the last-mentioned zone, it contains very many cells. These, as indicated by the name of the stratum, are of small size (7–10  $\mu$ ) and pyramidal form, at least in the deepest part of the layer. In the superficial part the cells are rounded or irregularly triangular, but they assume the distinctive pyramidal outline as they approach the subjacent layer, whose elements they resemble in possessing apical and lateral processes.

The **layer of large pyramidal cells** contains the most distinctive neurones of the cerebral cortex. It measures usually about 1.25 mm. in thickness, but in some localities much more, and blends with the adjoining layers without sharp boundaries. The cells increase in size but diminish in numbers as they are traced from the second layer inwards, the largest (20–40  $\mu$  in width) and most characteristic lying in the deepest part of the stratum. The typical pyramidal cell possesses a conical body, triangular in section, the apex of which is continued into a long tapering dendrite, the *apical process*, which extends towards the periphery for a variable but usually considerable distance, depending upon the position of the cell. Upon gaining the stratum zonale, towards which the apical dendrite is always directed, the process breaks up into a number of end-branches that run parallel with the surface and contribute to the fibre-complex of the outer layer. During its

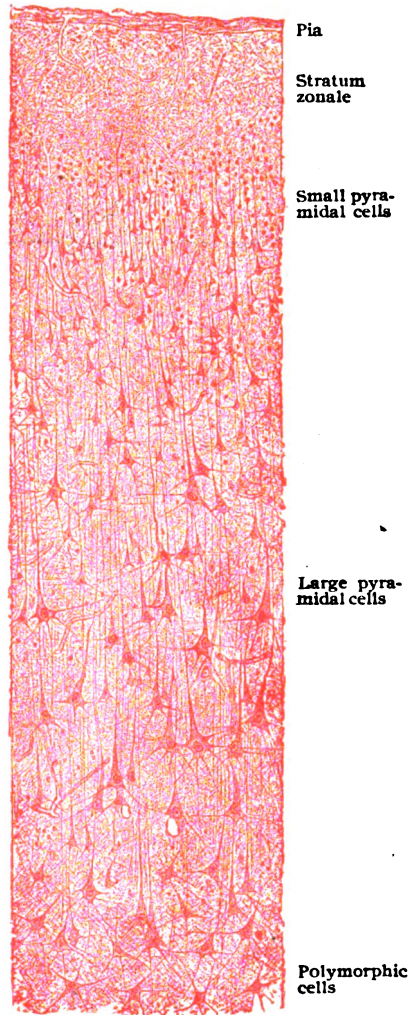


FIG. 348.—Section of cerebral cortex.  $\times 90$ .

journey to the surface, the apical dendrite gives off an uncertain number of branches that continue horizontally and, with the collaterals and similarly directed processes from other cells, take part in producing the feltwork giving rise to a thin light band, known as the *outer stripe of Baillarger*. From the deeper or basal surface of the cell arises the delicate centrally directed *axone*, which, penetrating the intervening fourth layer, acquires a medullary coat and enters the white core of the convolution as one of the component nerve-fibres. The axone gives off one or more *collaterals* which, after a shorter or longer course, establish relations with other and often remote cells.

In addition to the two chief processes, the peripherally directed apical dendrite and the centrally coursing axones, a variable number—from four to twelve—of secondary *lateral dendrites* spring from the basal angles of the cell. These processes usually divide dichotomously, each succeeding pair of branches in turn splitting into twigs, until the dendrite is resolved into an end-brush of fibrillæ which aid in producing an intricate feltwork of finest threads. Each pyramidal cell contains a conspicuous spherical or ellipsoidal nucleus, within which a distinct nucleolus is usually distinguishable. The cytoplasm exhibits a striation and, in addition to the masses of tigroid substance, the Nissl bodies, a mass of brownish pigment granules. The larger pyramidal cells are surrounded by an evident pericellular lymph-space.

The layer of **polymorphic cells** includes a large number of small nerve-cells, from 8–10  $\mu$  in diameter, whose forms vary greatly, irregular, spherical, triangular, stellate

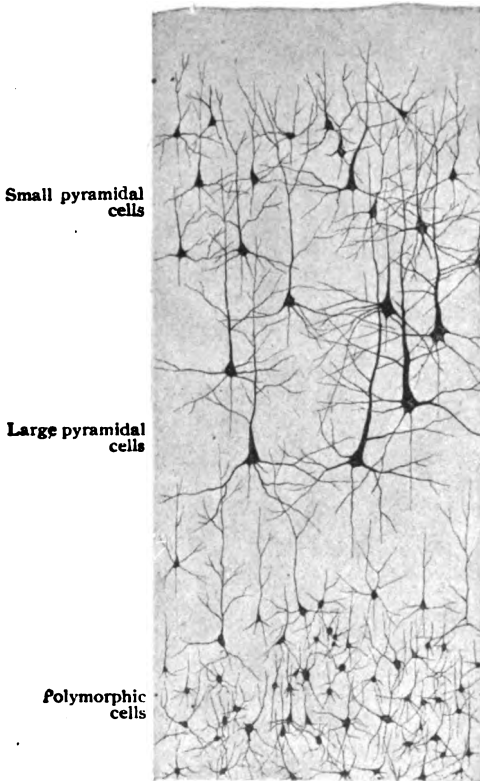


FIG. 349.—Nerve-cells of cerebral cortex, after silver impregnation.  $\times 70$ . (Preparation by Prof. T. G. Lee.)

and fusiform elements being present. Small pyramidal cells are also often seen within this layer. In contrast to dendrites of the typical pyramidal cells, those of the polymorphic elements, although peripherally directed, do not reach the stratum zonale but end before gaining the outermost layer. Their axones pass into the subjacent fibre-layer. The radial disposition of the groups of fibres within the deepest stratum of the cortical substance, limits the polymorphic cells chiefly to the interfascicular areas, within which the cells consequently appear arranged in a somewhat columnar order.

Within the deeper layers of the cortex, therefore among the polymorphic and the pyramidal elements, two additional varieties of nerve-cells are encountered. These are the cells of Martinotti and the cells of Golgi.

The cells of **Martinotti** are of small size and triangular or spindle-form in outline and particularly distinguished by the unusual direction of their axones. These processes pass towards the surface and within the stratum zonale divide into branches, which are continued horizontally in the feltwork of tangential fibres. As in other parts of the central nervous system, so too in the cerebral cortex there is found a sprinkling of **Golgi's cells** of type II. Although both dendrites and axones of these cells undergo elaborate arborization, the axone is confined to a limited territory in the vicinity of the cell and, therefore, never reaches the stratum zonale.

**Neuroglia cells** are present in all parts of the cerebral cortex and, while in a general way they send fibrils in all directions between the nervous elements, which they then support, the arrangement of the fibrillæ is fairly definite in certain strata. Thus within the subpial condensation of the neuroglia, the glia cells send most of their processes as inwardly directed brushes. The cells within the deeper part of the cortex give off their processes in two chief groups, one extending towards the periphery and the other towards the white core.

**The Nerve-Fibres of the Cortex.**—When viewed in suitably stained sections cut parallel with their general course, the cortical nerve-fibres do not appear as a uniform layer, but as radially disposed bundles which gradually become less distinct as they traverse the cortex and finally disappear at about the level of the outer border of the layer of large pyramidal cells. The **radial fibres** are partly afferent and partly efferent. The *corticifugal components*, which predominate, are largely the centrally directed axones of the pyramidal and the polymorphic cells which are continued as the axis-cylinders of the fibres composing the subcortical white matter. The peripherally coursing axones of the cells of **Martinotti** also contribute to the production of the fibre-radial. The *corticipetal constituents* of these tracts include the nerve-fibres which are derived from cells situated more or less remote from the convolution in which the fibres (their axones) end. Such, for example, are the thalamo-

cortical and the tegmento-cortical fibres, as well as the many commissural fibres that arise in the opposite hemisphere and cross by way of the corpus callosum. Although for the most part the corticipetal fibres end at various levels in arborizations around the pyramidal cells, some are continued into the stratum zonale where they assist in producing the tangential zone.

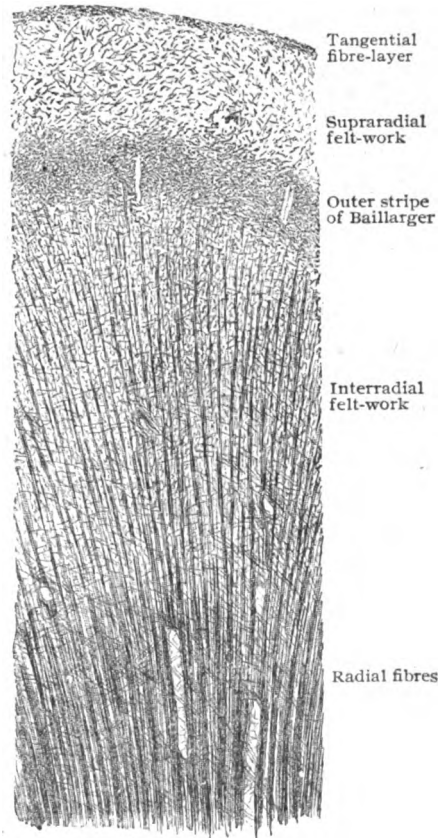


FIG. 350.—Section of cerebral cortex stained to show nerve fibres; the cells are not seen but lie between the strands of fibres.  $\times 21$ .

The spaces between these radial bundles are occupied by a delicate interlacement, the **interradial feltwork**, which is composed in large part of the lateral and collateral processes of the cells. Within the third layer, the horizontally coursing collaterals and processes of the large pyramidal cells form a complex of unusual intricacy, which condensation gives rise to the outer stripe of Baillarger. Beyond the outer ends of the radial fibre-bundles, the intercellular ground-work is occupied by a second delicate interlacement of processes and collaterals, the **supraradial feltwork**; while immediately beneath the narrow subpial neuroglial zone innumerable delicate terminal fibrillæ course horizontally and parallel with the surface and constitute the **tangential fibre-layer**. The components of this layer are the terminal branches of the dendrites of the pyramidal and polymorphic cells and the axones of the cells of Martinotti, as well as the main and secondary processes of the fusiform elements of the stratum zonale.

**Local Variations in the Cerebral Cortex.**—While in the main certain features are common to the cortex wherever well developed, more or less evident variations occur in different localities. Such variations are, for the most part, slight and depend upon the size and number of the nerve-cells and the richness and direction of the nerve-fibres—changes which produce alterations in the relative proportions of the strata. The width of the stratum zonale is almost constant and subject to little modification, being usually well defined from the layer of small pyramidal cells. The layer of the large pyramidal cells, on the contrary, exhibits considerable variation, either in increased thickness, as in the precentral gyrus, or in diminished breadth, as in the occipital lobe. The layer of polymorphic cells is fairly uniform, but within the precentral convolutions is reduced almost to disappearance, although the pyramidal cells of the superimposed (third) layer are here of unusual size. Such variations in the histological features of the cortex are probably correlated with differences in the function of its various regions, although the exact relations between such differences are in many cases still obscure. Disregarding the cortical regions which are profoundly modified by their rudimentary character, such as the olfactory lobe, apart from minor variations in details, the cortex of the greater part of the frontal, parietal, occipital, temporal and limbic lobes and of the insula closely corresponds in its structure. That of the motor (Rolandic) region, of the calcarine (visual) area of the occipital lobe, and of the hippocampus, dentate gyrus and adjacent part of the hippocampal gyrus, however, presents very evident modification.

The **Rolandic cortex** of the precentral gyrus, particularly towards the upper margin of the hemisphere, of the paracentral lobule and of the adjoining part of the postcentral gyrus—the great cortical motor area of the hemisphere—is distinguished by the great breadth of the layer of large pyramidal cells, the unusual size of the last-named elements and the feeble development of the layer of polymorphic cells. The pyramidal cells collectively tend to larger size as the upper end of the precentral convolution is approached and, in addition, cells of extraordinary dimensions appear. These elements, the *giant pyramidal* or *Betz's cells*, reach their maximum size within the paracentral lobule, where some attain a breadth of  $65\ \mu$  or almost double that of the pyramidal elements in other regions. The giant cells are further distinguished by their robust and rounded form, their distribution in small groups of from three to five in the deeper layers of the cortex, and the exceptional thickness of their axones.

**The Internal Nuclei.**—Embedded within the white matter of the cerebrum, for the most part completely separated from the cortex, lie certain paired masses of gray matter collectively known as the **basal ganglia**.



These include: the two parts of the corpus striatum, the *caudate* and *lenticular nuclei*, the *claustrum*, the *amygdaloid nucleus*, and the *thalamus*. Of these, two, the corpus striatum and the thalamus, will be briefly described.

**The Corpus Striatum.**—This large mass of gray matter, which extends from the outer wall of the lateral ventricle to almost the cortex, consists of two parts, the caudate nucleus or inner division and the lenticular nucleus or outer division. Although continuous in front and below, the two parts are separated almost completely by the intervening important tract of white matter, the *internal capsule*, which is the great pathway for nerve-fibres between the cerebral cortex and the lower portions of the brain.

The **caudate nucleus** is an elongated comet-shaped mass of gray matter, well seen from the lateral ventricle, and invested throughout the

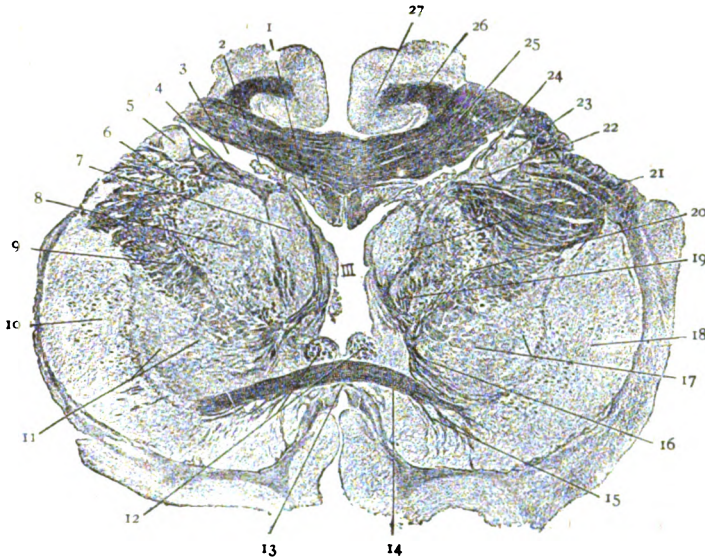


FIG. 351.—Portion of oblique frontal section of cerebrum, showing the ventricles, the basal ganglia (caudate and lenticular nuclei and optic thalami) and the internal capsule. 1, fornix, below corpus callosum (25); 2, choroid plexus; 3, lateral nucleus; 4, stratum zonale; 5, caudate nucleus; 6, internal capsule, knee; 7, mesial and (8) lateral nucleus of thalamus; 9, internal capsule; 10, putamen and (11) globus pallidus of lenticular nucleus; 12, anterior pillars of fornix; 13, lamina terminalis; 14, anterior commissure; 15, olfactory fibres; 16, thalamo-tegmental tract; 17, globus pallidus; 18, putamen; 19, mamillo-thalamic tract; 20, external and (21) internal medullary lamina; 22, stria terminalis; 23, caudate nucleus; 24, striate vein; 25, corpus callosum; 26, cingulum; 27, gyrus callosus.  $\times \frac{1}{4}$ . (Preparation by Professor Spiller.)

greater part of its periphery by a dense layer of fibres, the *stratum zonale*, covered on its ventricular surface by the cuboidal ependymal epithelium. The nerve-cells of the nucleus are, for the most part, rather small pigmented and stellate or fusiform and belong to type II, with short axones. Some cells, however, are very large and provided with long axones which may pass into the internal capsule.

The **lenticular nucleus** lies to the outer side of the internal capsule and is subdivided by two narrow tracts of white matter, the *medullary laminae*, into three segments. Of these the outer one, the *putamen*, is the darkest and corresponds in structure closely with the nucleus caudatus. The middle and inner zones together constitute the *globus pallidus* and are lighter in tint, owing to the excessive number of pervading bundles of nerve-fibres. All three zones of the nucleus lenticularis consist of gray matter

intermingled with many nerve-fibres. The cells of the globus pallidus, save for their somewhat smaller size ( $20-40\ \mu$ ) and a lighter pigmentation, resemble the smaller neurones of the caudate nucleus, but are less generally cells of type II. Large neurones ( $35-70\ \mu$ ) are common in the putamen, having a slender cell-body and giving off at the poles two or more dendrites. The axone often arises from the base of a dendritic process.

**The Thalamus.**—This large ovoid ganglionic mass lies between the third ventricle mesially, of which cavity it constitutes the lateral wall, and the internal capsule laterally. Its free dorsal surface, and to a less degree the mesial as well, is covered with a thin layer of nerve-fibres, the *stratum zonale*, whilst ventro-laterally the thalamus is separated from the internal capsule by a denser layer of fibres, the *external medullary lamina*. The gray matter is subdivided into two general parts, the *lateral* and the *mesial nucleus*, by a vertical sheet of white matter, the *internal medullary lamina*. The periphery of the lateral nucleus is broken up by numerous fibres passing

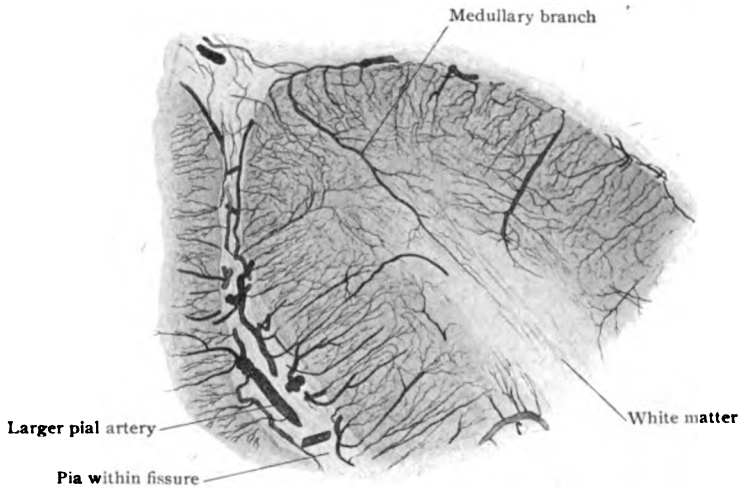


FIG. 352.—Injected cerebral cortex, showing capillary supply of gray and white substance.  $\times 18$ .

from the thalamus into the internal capsule into a reticular zone, sometimes called the *latticed layer*. The nerve-cells of the thalamic nuclei include three chief varieties: (1) the *stellate cells* ( $35-50\ \mu$ ), distinguished by their richly branched dendrites that radiate in all directions; (2) the *brush-cells*, so called on account of the brush-like expansions of their dendrites, spindle or triangular and from  $20-40\ \mu$  in diameter; and (3) the *polygonal cells*, few but large ( $50-60\ \mu$ ), with a number of long slender tortuous dendrites. The thalamic cells are by no means uniformly distributed, but, on the contrary, are aggregated into larger and smaller groups, the *subsidiary nuclei*; of these eleven are distinguished by Cajal, by whom they are described as lying in three general planes and constituting a lateral, an intermediate and an inner series. Of these the *ventro-lateral nucleus* is of especial importance, since it probably receives the afferent fibres of the great sensory fillet-tract. In a general way, the neurones of the thalamus may be regarded as receptors of a large part of the afferent impulses carried to the cerebrum from the cerebellum, brain-stem and spinal cord, such impulses being distributed by the *thalamo-cortical fibres*, the axones of the thalamic cells, to the

cerebral cortex. Since, moreover, the cells of the latter send *cortico-thalamic* fibres centrally, the intricate character of the connections of the thalamus, which also gives off many additional fibres to lower lying levels, is evident.

**Blood-Vessels of the Brain.**—The **arteries** supplying the brain are derived from the internal carotid and vertebral stems. Their immediate distribution to the cerebral and cerebellar cortex is everywhere through the agency of the pia mater, within which the larger trunks, after frequent anastomoses, give off the abundant small *end-arteries* that penetrate the subjacent nervous substance. On entering the gray matter, these *cortical branches*, whose general course is parallel to one another and at right angles to the surface, break up into rich networks of capillaries coming into direct relation with the nervous elements. The vascular supply of the gray matter is more generous than that of the white substance, which latter receives, however, in addition to continuations from the cortical capillary network, a number of *medullary branches*. These contribute few twigs to the gray substance but traverse the latter and have their chief distribution as long-meshed capillary networks within the white matter. The arteries are accompanied by connective tissue envelopes, prolonged from the pia mater, which enclose ensheathing *perivascular lymph-spaces*.

The **cortical veins** begin in the white matter and pass through the gray sheet to reach the pia mater, within whose external part they ramify, the arteries usually lying deeper. The larger emergent stems, however, do

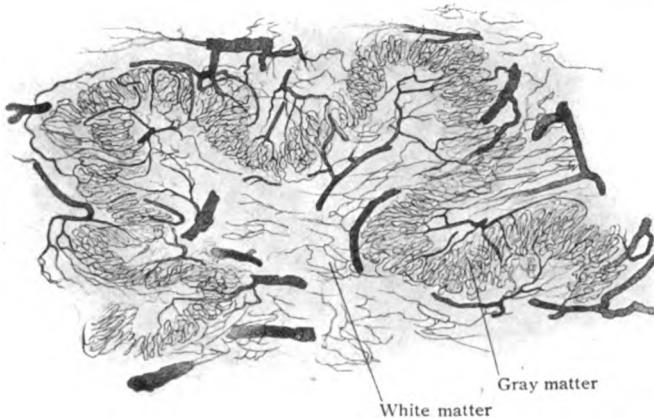


FIG. 353.—Injected dentate nucleus of cerebellum, showing rich capillary supply of plicated gray matter.  
X 20.

not follow the main branches of the cerebral arteries, but converge towards the lines of the principal adjacent dural sinuses into which they open. The cerebral veins are among those possessing little or no muscular tissue and no valves.

True **lymphatics** are found neither within the brain nor spinal cord. Lymph-paths, however, are represented by the *perivascular sheaths* surrounding the blood-vessels within the nervous substance; these tracts communicate with the subarachnoid space. The *pericellular spaces* enclosing the larger nerve-cells, as well as uncertain *subpial spaces* between the pia mater and the surface of the nervous substance, are closely related to the lymphatic system, although not directly communicating with it.

## THE PINEAL BODY.

The pineal body, also called the *epiphysis* and the *conarium*, is a cone-shaped organ, from 8–10 mm. in length, attached to the posterior extremity of the roof of the third ventricle.

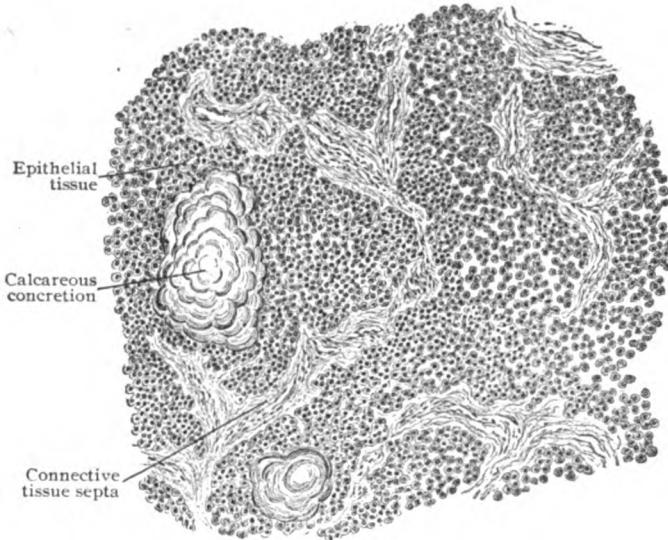


FIG. 354.—Section of pineal body, showing general structure and calcareous concretions.  $\times 130$ .

As seen in sections of the adult human organ, its structure includes a reticular framework of vascular connective tissue trabeculae, the meshes of

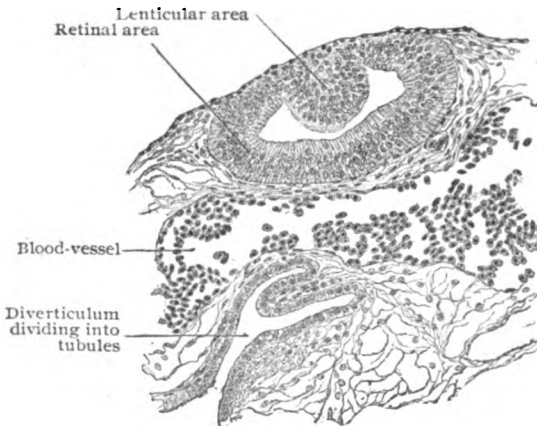


FIG. 355.—Sagittal section of pineal organ of lizard embryo.  $\times 175$ .

which are filled with rounded or elongated epithelial cells, which often contain brownish pigment. With the exception of a few nerve-fibres in the anterior part, probably sympathetic in origin and destined for the walls of the blood-vessels, and a dense network of neuroglia-fibres in the under part, the pineal body contains no elements of a nervous character, nerve-cells being absent. Very commonly the adult organ encloses a variable number of concretions,

called *brain-sand* or *acervulus cerebri*, which consist of laminated masses composed of calcium carbonate and phosphate, mingled with organic material. They may be of microscopic dimensions, or reach the size of a millet seed, and by aggregation assume a mammillated form.

The significance of the pineal body in man, long an unsolved riddle, has been shown by embryological and comparative studies of the organ in the lower vertebrates, especially in lizards, to be that of a very imperfectly developed and greatly modified rudimentary sense-organ. In certain lizards, in which it reaches a high development, the pineal body is a flattened cup-shaped organ (Fig. 355) connected with the brain by a stalk containing nerve-fibres. The structural resemblance to an invertebrate visual organ, a sort of lens overlying a retina-like layer, suggested a possible similarity of purpose in the higher types. The organ was designated, therefore, the *pineal eye*, although probably in no existing animal a functioning structure. The embryonic relations in many reptiles are most suggestive of the significance of the pineal body as a rudimentary sense-organ, although not necessarily an eye.

## THE PITUITARY BODY.

The pituitary body, or *hypophysis cerebri*, is attached to the dependent tip of the infundibulum, the narrow funnel-like projection from the floor of the third ventricle. It is of flattened oval form, somewhat mushroom-shaped, and measures about 12 mm. in the transverse and about 7 mm. in the sagittal diameter. The pituitary body includes two entirely distinct parts, the *anterior* and *posterior lobes*, which differ both in origin and structure.

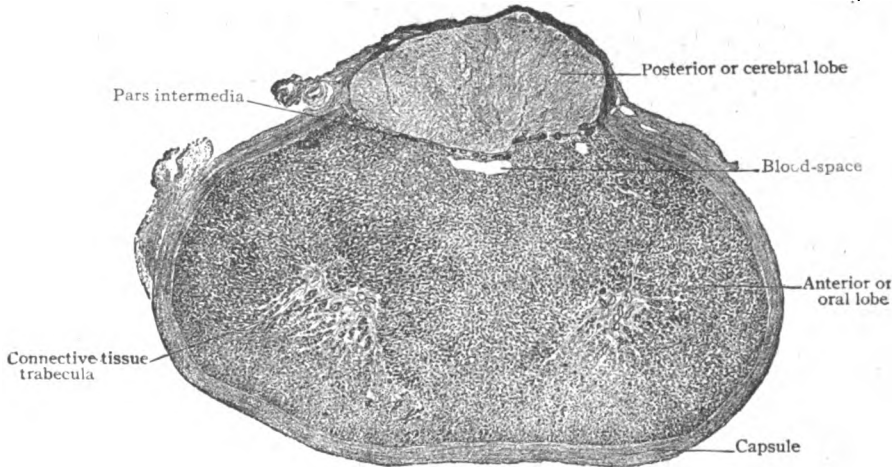


FIG. 356.—Horizontal section of pituitary body, showing relation of anterior (oral) and posterior (cerebral) lobes.  $\times 7$ .

ure. The former is derived as an outgrowth from the roof of the primitive oral cavity, while the latter is developed as a tubular evagination from the floor of the second brain-vesicle, the diencephalon.

**The Anterior Lobe.**—The anterior and glandular division, which constitutes the major part of the hypophysis, is surrounded by a robust fibrous capsule that is continuous with the thinner investment enclosing the posterior lobe. From the deeper surface of the capsule, as well as from a condensation of connective tissue on each side of the mid-line that marks the position of large blood-vessels, fine processes extend inwards and form a delicate supporting fibrous reticulum, rich in capillaries, whose meshes are filled with spherical or cord-like masses of cuboidal or polygonal epithelial cells. The latter are principally of two kinds—the smaller *chief cells* (30–40  $\mu$ ),

which color best with basic and only slightly with acid stains, and the larger *chromophile cells* (50-80  $\mu$ ), so named because of their affinity for certain acid dyes (eosin). The two varieties of cells are intermingled in the anterior lobe; the eosinophilic cells occupy, in a general way, the periphery and the chief cells the centre of the cords.

The aggregations of the cells, cord-like or spherical in form and usually without a distinct lumen, lie in close relation to the capillary blood-vessels that ramify between them, supported by the delicate connective tissue framework. Here and there, however, the glandular epithelium surrounds a lumen which may contain colloid material, and thus resemble the alveoli of the thyroid body. Such colloid-containing spaces are especially numerous and large in the boundary zone, or *pars intermedia*, between the anterior

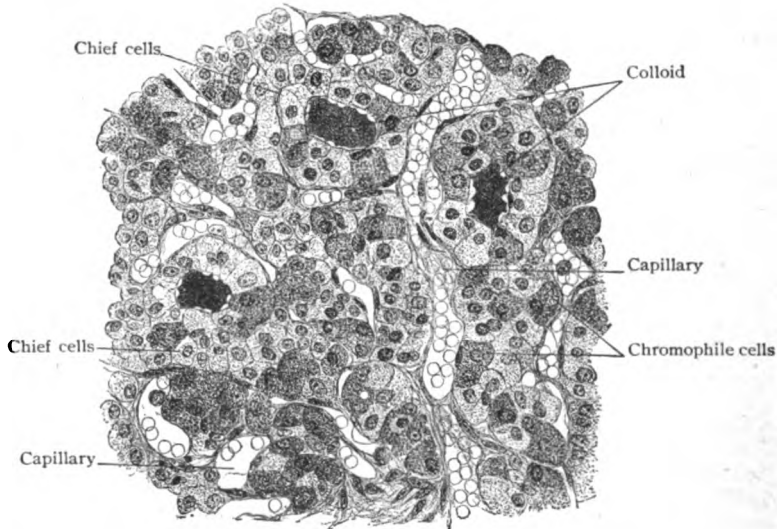


FIG. 357.—Section of anterior lobe of pituitary body, showing details of structure; three alveoli contain colloid material.  $\times 250$ .

and posterior lobes. Even in man, but to a very much more marked degree in many of the lower mammals, this zone contains large spaces lined with cuboidal cells and more or less filled with semifluid material. The posterior wall of the interlobar space consists of several layers of cells which varyingly invade the adjoining zone of the posterior lobule. The colloid material is to be regarded, perhaps, as the particular secretion of the glandular segment of the hypophysis, which, moreover, is usually conceded a place among the organs of internal secretion.

**The Posterior Lobe.**—The posterior and smaller division of the pituitary body is directly attached to the floor of the third ventricle by means of its stalk prolonged from the infundibulum. During the early stages of its development, this lobe is represented by a tubular outgrowth, whose walls partake of the general character of the parent brain-vesicle. In man the lumen within the lower end of the diverticulum later entirely disappears, the posterior lobe being solid. In some lower mammals, notably in the cat, the lumen is retained and, in rare instances, may even communicate with the interlobar space. In the adult condition, the posterior or nervous segment retains few histological features suggesting its cerebral origin. Of the demon-

strable interlacing fibres, with fusiform enlargements and elongated nuclei, none can be identified as nerves, while of the numerous cells which the lobe contains, only a few of large size and pigmented cytoplasm uncertainly

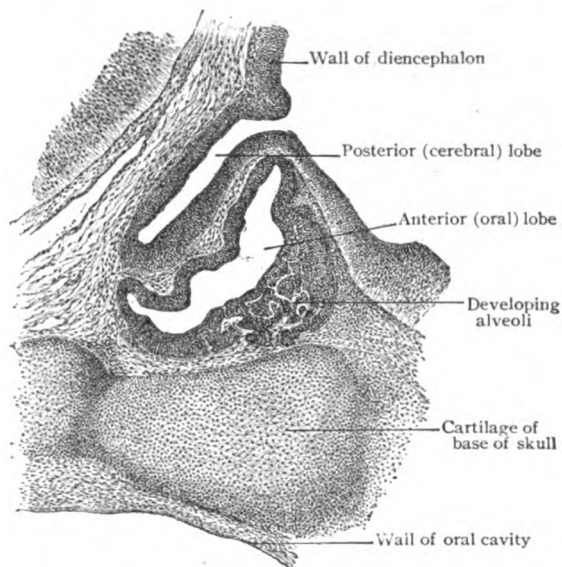


FIG. 358.—Portion of sagittal section of rabbit embryo, showing developing pituitary body; alveoli are sprouting from wall of oral diverticulum.  $\times 50$ .

resemble nervous elements. With the exception of neuroglial cells, the existence of definite nervous tissue within the cerebral lobe of the mature human hypophysis is very doubtful.

### THE MENINGES.

The entire cerebro-spinal axis is surrounded by three membranes, or meninges. These are: (1) an external dense fibrous membrane, the *dura mater*, which is closely attached directly to the inner surface of the skull and in the vertebral canal forms an independent loose sheath for the spinal cord; (2) an internal connective tissue tunic, the *pia mater*, which contains the blood-vessels supplying the nervous tissue and, therefore, is adherent to every part of the free surface of the brain and spinal cord; and (3) an intermediate delicate nonvascular membrane, the *arachnoid*, which usually lies close to the *dura* and varies in its relation to the *pia mater*.

Between the *dura* and the *arachnoid* lies a narrow, for the most part capillary cleft, the *subdural space*, which contains a small quantity of clear straw-colored fluid, of the nature of lymph. The *arachnoid* and the *pia mater* are separated by a much larger cavity, the *subarachnoid space*, which in certain places, especially on the basal surface of the brain, reaches extensive dimensions. It contains the *cerebrospinal fluid*, that is absolutely limpid or slightly yellowish, and may show a very few lymphocytes (estimated normally as 5 cells per cubic millimeter of fluid). The cerebro-spinal fluid is produced within the brain-ventricles, from the tufts of blood-vessels of the several choroid plexuses, and, after filling the ventricular spaces and the central canal of the cord, escapes through the thin roof of the fourth ventricle into the subarachnoid spaces.

**The Dura Mater.**—Within the skull (*dura mater encephali*), the membrane consists of an *outer* and an *inner layer*. The former replaces the periosteum and is intimately attached to the bones to which it carries nutritive blood-vessels (branches of the meningeal arteries). The inner layer forms the incomplete fibrous partitions, as the falx and tentorium, which separate and support the several subdivisions of the brain. Along the attachments of these partitions, the inner layer splits to form the walls of the large venous spaces, the *dural sinuses*, which are lined with endothelium and constitute the channels into which the blood returned by the veins from the nervous tissue is poured.

Within the vertebral canal (*dura mater spinalis*), the dura forms a loose sac for the cord which corresponds to a prolongation of the inner cranial layer. It loses its intimate relation to the bones at the foramen magnum and lies within the vertebral canal often separated from the periosteum by considerable tracts of areolar tissue.

In **structure**, the dura consists of closely placed bundles of unusually rigid fibrous tissue; intermingled with elastic fibres. Although the latter exist in considerable numbers, especially in the inner layer of the brain-dura, they are so overshadowed by the preponderance of the fibrous tissue that the membrane as a whole is relatively inelastic. Within the outer layer in the skull, the fibres pursue a general antero-lateral to postero-medial direction, while those of the inner layer follow an opposite, antero-medial to postero-lateral, course. Within the spinal sac, their disposition is chiefly longitudinal. The connective tissue cells are represented by flattened plate-like elements between the fibrous bundles and some plasma cells in the vicinity of the blood-vessels. The inner surface of the dura, the outer wall of the subdural space, is covered by a continuous layer of endothelial cells. The existence of isolated patches of endothelium on the outer surface of the membrane within the skull, is regarded as evidence of the existence of limited *epidural spaces*.

The **blood-vessels** of the brain-dura, not taking into account the large venous sinuses, are all branches from the various meningeal arteries. In addition to supplying the dural tissue, their purpose is to provide nourishment to the bones of the cranium, which, therefore, are the objective distribution for the larger part of the terminal vessels. The outer layer, being virtually the periosteum, contains many more vessels than the inner, the larger trunks showing as elevated ridges on the cranial surface. Meningeal veins are also present, but, in many cases, do not accompany the arteries and pursue an independent course. The spinal dura contains comparatively few blood-vessels.

The **nerves** within the dura are numerous and include two sets—those destined for the walls of the blood-vessels, the more plentiful and sympathetic in character, and the less numerous *nervi proprii* which contain sensory fibres derived from the cranial and spinal nerves. They end in free filaments or in bulbous expansions.

**The Pia Mater.**—This membrane, the vascular tunic, lies in contact with all parts of the cerebro-spinal axis and, since it contains the blood-vessels supplying the nervous substance, accurately follows all the irregularities of the surface of the brain, with its many convolutions and fissures, and of the spinal cord. Additionally, in certain places where the wall of the brain-tube is always very thin, the pia pushes before it the attenuated brain-layer and seemingly gains entrance into the ventricles. Examples of such invagination are afforded in the relations of the velum interpositum and the



choroid plexuses to the lateral and third ventricles and of the similar plexuses in the roof of the fourth ventricle. The pia mater further contributes a sheath to each nerve, or its larger component bundles, as the nerve leaves the brain or spinal cord, which sheath surrounds the nerve as it crosses the subarachnoid space and for a variable distance beyond its emergence from the dural sac.

The **spinal pia** consists of two layers, of which the dense outer is composed of interlacing stout bundles of fibrous tissue mixed with elastic fibres and covered externally by endothelium, and the looser inner one of less closely packed fibro-elastic strands. These layers are separated here and there by lymphatic clefts and enclose between them the blood-vessels. The latter subdivide within the pia into numerous small arteries which, although the larger trunks frequently anastomose, enter the subjacent nervous substance as "end-arteries," each providing the entire available blood-supply for a definite territory.

The **brain-pia** consists of only a single layer which corresponds to the inner one of the spinal membrane both in structure and relations. The larger vessels lie in or on its outer part and in certain places where they are of large diameter, as at the base of the brain, project within the subarachnoid space, although covered by a thin envelope of pial tissue. As the vessels penetrate the nervous tissue, they carry with them a sheath of pia mater, at first loosely but later closely applied. These constitute the *perivascular lymph-sheaths* that follow the arteries to their smallest ramifications and communicate, through the *intrapial lymph-clefts*, with the subarachnoid space. Since the arteries entering the nervous tissue, especially the cerebral and cerebellar cortex, are very abundant, collectively a considerable amount of connective tissue is carried with the vessels into gray matter, the larger vascular septa containing fibro-elastic tissue as well as neuroglia. The ultimate distribution of the arteries entering the spinal cord and the brain is described in connection with those organs (pages 279 and 307). In certain locations, particularly the base of the brain and over the cervical and lumbar enlargements of the cord, the pia sometimes, especially in aged subjects, contains deeply pigmented branched connective tissue cells.

The **choroid plexuses** of the ventricles comprise two morphologically distinct parts—the vascular pial tissue and the thin covering of brain-wall. The vascular fringes consist of numerous capillary convolutions, the *choroidal glomeruli*, from 1–2 mm. in diameter, embedded in the pial connective tissue stroma and covered with a single layer of cuboid ependymal cells. The latter contain fat and pigment particles and during foetal life bear cilia.

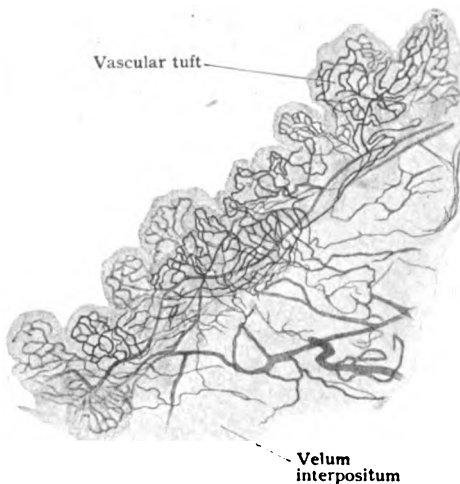


FIG. 359.—Small portion of injected choroid plexus of lateral ventricle; surface view.  $\times 25$

The numerous **nerves** within the pia mater are chiefly sympathetic fibres destined for the walls of the blood-vessels. Within the skull they are derived chiefly from the plexuses surrounding the internal carotid and vertebral arteries; within the spinal pia they are contributed directly from the gray sympathetic rami. Additional nerve-fibres, probably sensory in function, occur in small numbers. Their mode of termination is uncertain, although free and bulbous endings have been described.

**The Arachnoid.**—The intermediate membrane is, for the most part, a thin connective tissue envelope that intervenes between the dura and the pia and, notwithstanding its delicacy, completely separates the subdural from the subarachnoid space. It contains neither blood-vessels, lymphatics nor nerves and consists of an interlacement of flattened bundles of fine fibrous tissue interspersed with elastic fibres and plate-like cells. In addition to the main sheet, the partition, both sides of which are covered with endothelium, numerous trabeculæ, also covered with endothelium, extend across the subarachnoid space and in places are so plentiful as to convert the cleft into a sponge-like structure. In contrast to the pia mater, which closely follows the surface of the brain and cord, the arachnoid is separated from the cerebro-spinal axis and its immediate covering by a more or less extensive space. Over the convexities of the convolutions, however, the arachnoid and the pia are fused into a single membrane; elsewhere the subarachnoid space, filled with cerebrospinal fluid, is considerable and on the basal surface of the brain very extensive and represented by the *cisternæ*.

Not only by lymph-paths along the nerve-trunks and larger veins, the cerebro-spinal fluid also escapes into the dural sinuses by filtration through local tuft-like accumulations of arachnoid tissue, situated particularly along the superior longitudinal sinus. These tufts, known as the **Pacchonian bodies**, consist of spongy masses of arachnoid tissue, covered externally with endothelium, which push before them the greatly attenuated dura and, overlaid by the latter and the endothelial lining of the blood-space, project into the sinus or its lateral diverticula. By this arrangement the cerebrospinal fluid that occupies the interstices of the arachnoid tissue filters through the interposed structures and finds its way into the venous current within the dural sinuses.

## THE ORGANS OF SENSE.

THE cells directly receiving the stimuli producing the sensory impressions of touch, smell, taste, sight and hearing are all derivations of the ectoderm—the great primary sensory layer from which the essential parts of the organs of special sense are differentiations. The olfactory cells—nervous elements that correspond to ganglion-cells—retain their primary relation, since they remain embedded within the invaginated peripheral epithelium lining the nasal fossæ, sending their dendrites towards the free surface and their axones into the brain. Usually, however, the nerve-cells connected with the special sense-organs abandon their superficial position and lie at some distance from the periphery, receiving the stimuli not directly, but from the epithelial receptors by way of their dendrites. In the case of the most highly specialized sense-organs, the eye and the ear, the percipient cells lie enclosed within capsules of mesodermic origin, the stimuli reaching them by way of an elaborate path of conduction.

### THE SKIN.

Since the extensive integumentary sheet that clothes the exterior of the entire body not only serves as a protective investment, an efficient regulator of body temperature and an important excretory structure, but also contains

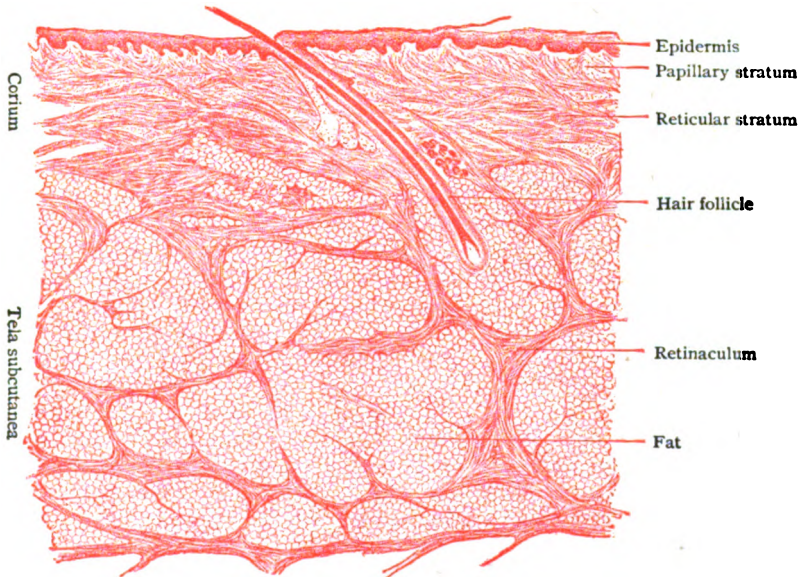


FIG. 360.—Section of skin, showing its chief layers—epidermis, corium and tela subcutanea.  $\times 17$ .

the special end-organs and the peripheral terminations of the sensory nerves that receive and convey the stimuli producing tactile impressions, the skin may be appropriately considered along with the other sense-organs, of which it may be regarded as the primary and least specialized. On the other hand,

the correspondence of its structure with that of the mucous membranes, with which it is directly continuous at the orifices on the exterior of the body, emphasizes the close relation of the skin to the alimentary and other mucous tracts.

This general investment, the **tegmentum commune**, includes the *skin proper*, with the specialized tactile corpuscles, and its *appendages*—the *hairs*, the *nails* and the *cutaneous glands*. Its average superficial area is approximately one and a half square meters.

The **skin (cutis)**, using the term in a more restricted sense as applied to the covering proper without its appendages, everywhere consists of two distinct portions, a superficial *epithelial* and a deeper *connective tissue stratum*, which are derivatives of the ectoderm and the mesoderm respectively. The former, the *epidermis*, is devoid of blood-vessels, the capillary loops never reaching farther than the subjacent *corium*, as the outermost layer of the connective tissue stratum is called. The *thickness* of the skin, from .5-4 mm., varies greatly in different parts of the body, being least on the eyelids, penis and nymphæ, and greatest on the palms of the hands and soles of the feet and on the shoulders and back of the neck. Of the entire thickness, the proportion contributed by the epidermis is in most localities about .1 mm.

**The Connective Tissue Stratum.**—The connective tissue stratum, usually much the thicker portion of the skin, includes two layers, the *corium* and the *tela subcutanea*, which, however, are so blended with each other as to be without sharp demarcation.

The **corium** or **derma**, the more superficial and compact of the connective tissue layers, lies immediately beneath the epidermis from which it is always well defined. With the exception of within a few localities, as over the forehead and the external ear, the outer surface of the corium is not even but beset with elevations, ridges, or papillæ, which produce corresponding modelling of the opposed under surface of the overlying epidermis. The

best developed papillæ are on the flexor surfaces of the hands and feet, where they attain a height of .2 mm. or more and are disposed in the closely set double rows that underlie the *cutaneous ridges* on the palms and soles. The patterns formed by the cutaneous ridges remain throughout life unchanged and, as seen in imprints of the fingers, are so distinctive for each individual that they afford a reliable and practical means of identification. The markings of the two hands are symmetrical and sometimes identical. The papillæ afford favorable positions for the lodgement of the terminal capillary loops and the special organs of touch; they are accordingly grouped as *vascular* and *tactile*.

The corium is subdivided into an outer *papillary stratum*, containing the papillæ, and a deeper *reticular stratum*, composed of the closely inter-



FIG. 361.—Portion of corium from palmar surface of hand after removal of epidermis; each range includes a double row of papillæ, which underlie the surface ridges and the openings of the sweat-glands; the latter appear as dark points along the ranges of papillæ.  $\times 5$ .

lacing bundles of fibrous and elastic tissue that are continued into the more robust and loosely arranged trabeculæ of the tela subcutanea. The strata of the corium, however, are so blended that they pass insensibly and without definite boundary into each other. Although composed of the same histological factors—bundles of fibrous tissue, elastic fibres and connective tissue cells—their disposition is much more compact in the dense reticular stratum than in the papillary layer. While the general course of the fibrous bundles within the corium is parallel or oblique to the surface, some strands, continued upwards from the underlying subcutaneous sheet, are vertical and traverse the stratum reticulare either to bend over and join the horizontal bundles, or to break up and disappear within the papillary stratum. The elastic tissue, which constitutes a considerable part of the corium, occurs as fibres and networks. Within the reticular stratum these form robust tracts corresponding with the general arrangement of the fibrous bundles. Towards the surface of the corium, the elastic fibres become finer and more branched and beneath the epidermis anastomose to form the delicate but close *subepithelial elastic network*.

The *tela subcutanea*, the deeper layer of the connective tissue portion of the skin, varies in its thickness and in the density and arrangement of its component bundles of fibro-elastic tissue, with the amount of fat and the number of hair-follicles and glands lodged within its meshes. The latter are irregularly round and enclosed by tracts of fibrous tissue, some of which, known as the *retinacula cutis*, are prolonged from the corium to the deepest parts of the subcutaneous stratum. Here they often blend into a thin but definite sheet, the *fascia subcutanea*, which forms the innermost boundary of the skin and is connected with the subjacent structures by strands of areolar tissue. Where such loose connection is wanting, as on the scalp, face, palms and soles, the skin is intimately bound to the underlying muscles or fasciæ and lacks the independent mobility that it elsewhere enjoys. The integument covering the eyelids and penis is peculiar in retaining to a conspicuous degree its mobility although devoid of fat. Where the latter is present in large quantity, the term *panniculus adiposus* is often applied to the tela subcutanea.

In places in which the skin glides over unyielding structures, the inter-fascicular lymph-spaces of the tela subcutanea may undergo enlargement and fusion, resulting in the production of the subcutaneous *mucous bursa*.

In addition to the strands of *involuntary muscle* associated with the hairs as the *arrectores pilorum*, unstriped muscular tissue is incorporated with the skin in the mammary areolæ and over the scrotum and penis (*tunica dartos*). The facial muscles having largely cutaneous insertions, the skin covering the face is invaded by tracts of striated muscular tissue that penetrate as far as the corium.

**The Epidermis.**—The epidermis or *cuticle*, the outer portion of the skin, consists entirely of epithelium and, being partly horny, affords protection to the underlying corium with its vessels and nerves. The thickness of this layer varies in different parts of the body. Commonly from .08–.10 mm., it is greatest on the flexor surfaces of the hands and feet, where it reaches from .5–.9 mm. and from 1.1–1.3 mm. respectively. Where exposed to unusual pressure, as on the palms of laborers or on habitually unshod soles, the epidermis may attain a thickness of 4 mm.

The cuticle consists of two chief layers, the deeper *stratum germinativum*, containing the more active elements, and the *stratum corneum*, the cells of which undergo cornification. Between these layers lies a third, the

*stratum intermedium*, that is ordinarily represented by only a single row of cells to which the name *stratum granulosum* is usually applied. This layer marks the level at which the conversion of the epithelial elements into horny plates begins and also that at which the separation effected by blistering usually occurs. On the palms and soles, where the epidermis attains not only great thickness but also higher differentiation, an additional layer, the *stratum*

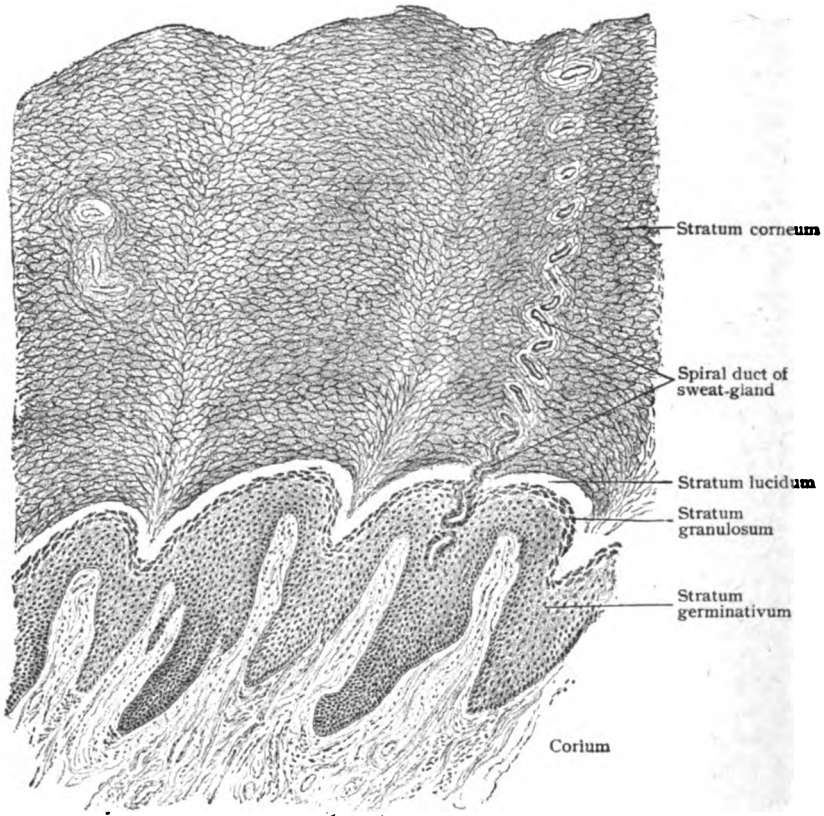


FIG. 362.—Section of skin from sole of foot, showing layers of epidermis.  $\times 70$ .

*lucidum*, making four in all, may be recognized. The first two represent the portion of the epidermis endowed with the greatest vitality and powers of repair, and the last two the horny and harder part.

The *stratum germinativum*, or *stratum Malpighi*, rests upon the outer surface of the corium, by the papillæ of which it is impressed and, hence, when viewed from beneath after being separated, commonly presents a more or less evident network of ridges and enclosed pits, the elevations corresponding to the interpapillary furrows and the depressions to the papillæ. In recognition of this reticulation the name, *rete Malpighi*, is sometimes applied to the deepest layer of the epidermis. As in other epithelia of the stratified squamous type, the deepest cells are columnar and lie with their long axes perpendicular to the supporting connective tissue. The basal ends of the columnar cells are often slightly serrated and fit into cor-

responding indentations on the corium. Succeeding the single row of columnar elements, the cells of the stratum germinativum assume a pronounced

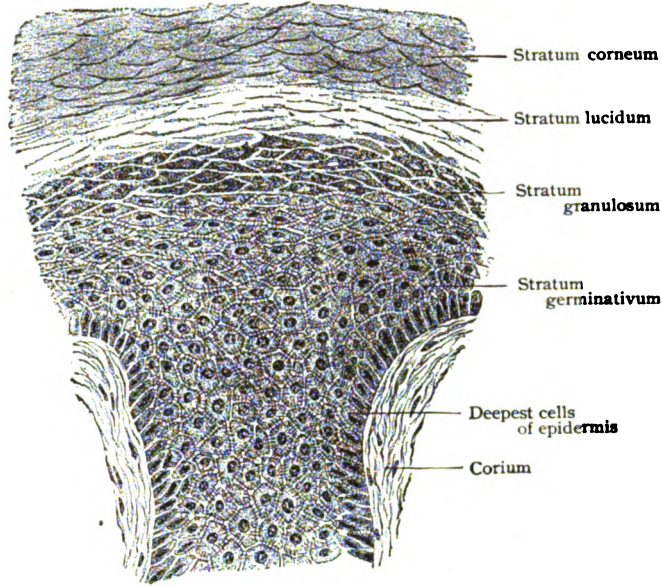


FIG. 363.—Portion of preceding section, showing layers of epidermis in more detail; only the deeper part of the epidermis is represented.  $\times 280$ .

polygonal form, but become somewhat flatter as they approach the stratum granulosum. The number of layers included in the germinal stratum is not only uncertain, but varies with the relation to the papillæ, being greater between than over these projections. The finely granular cytoplasm of the cells of the stratum germinativum contains delicate *fibrillæ*, which radiate from the nucleus towards the periphery. The fibrillæ are not confined to the cells, but extend beyond and pass across the intercellular clefts as delicate protoplasmic bridges (Fig. 364).

The **stratum granulosum** is exceptionally well marked on the palms and soles and in these localities includes

from two to four rows of polygonal cells, that stand out conspicuously in stained sections by reason of the intensely colored particles of *keratohyalin* within their cytoplasm. The nature of this peculiar substance, deposited within the body of the cells as particles of irregular form and size, is still uncertain. It is probable that keratohyalin is in some way derived from disintegration of the cytoplasm and represents an initial stage in the process ending in cornification of the succeeding layers of the cuticle.

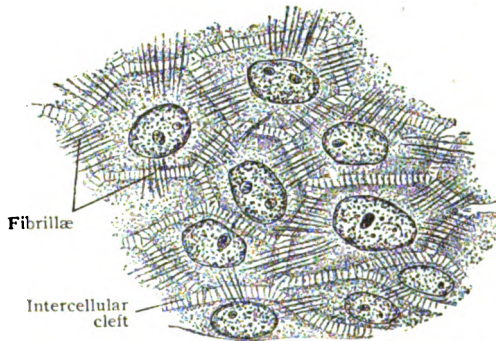


FIG. 364.—Horizontal section, showing intracellular fibrillæ within cells of stratum germinativum.  $\times 800$ .

The **stratum lucidum**, usually wanting in other localities, in the palm and sole appears as a thin, almost homogeneous layer, separating the corneum from the granular layer. With the latter it constitutes the stratum intermedium. As indicated by its name, the stratum lucidum appears clear and without distinct cell boundaries, although suggestions of these, as well as of the nuclei of the component elements, are usually distinguishable. The cells of the stratum lucidum contain a substance, *eleidin*, derived from the keratohyaline particles, which soften and coalesce into a homogeneous semifluid material that fills the cells.

The **stratum corneum** includes the remainder of the epidermis and consists of many layers of horny epithelial cells, that contain *pareleidin* and form the exterior of the skin. Where no stratum lucidum exists, as is usually the case, the corneous layer rests upon the stratum granulosum, from which its horny elements are being continually recruited. During their migration towards the free surface, the cells lose their vitality and moisture and become more flattened, until the most superficial ones are converted into the dead horny scales that are being constantly displaced by abrasion.

The **pigmentation** of the skin, which even in white races is conspicuous in certain regions, as on the external genital organs and around the anus,

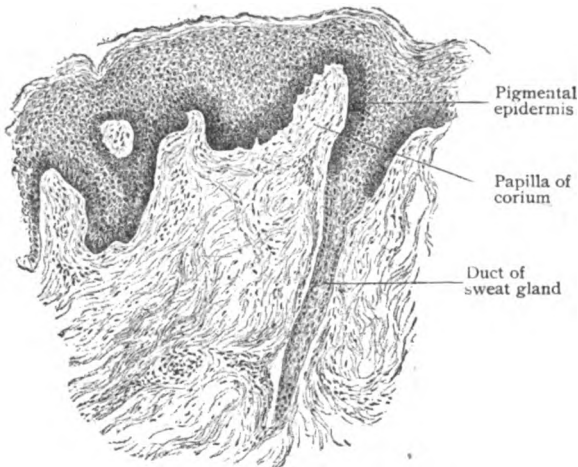


FIG. 365.—Section of skin surrounding anus, showing pigmentation of deep layers of the epidermis.  $\times 50$ .

depends upon the presence of colored particles. These lie chiefly within the epidermis, although, when the dark hue is decided, a few small branched pigmented connective tissue cells may appear within the subjacent corium. The distribution of the pigment particles varies with the intensity of color, in skins of lighter tints being principally limited to the columnar cells next the corium. With increasing color the pigment particles invade the neighboring layers of

epithelium until, in the dark skin of the negro, they are found within the cells of the stratum corneum, in diminishing numbers towards the free surface. Even when the cells are dark and densely packed, the colored particles never encroach upon the nuclei, which appear as pigment-free areas. The source of the pigment within the epidermis is disputed, some assuming a transference of the colored particles by means of wandering cells or of the processes of pigmented connective tissue cells that penetrate the cuticle, and others accepting an independent origin *in situ* within the epithelial elements. While it is established that at times the connective tissue cells are capable of modifying pigmentation, it is equally certain that the earliest, and probably also later, intracellular pigmentation of the epidermis appears without the assistance of the connective tissue or migratory cells, minute colored particles first becoming evident within the epithelial cytoplasm.



The **blood-vessels** of the skin are confined to the connective tissue portion and never enter the cuticle. The *arteries* are derived either from the trunks of the subjacent layer as special cutaneous branches destined for the integument, or indirectly from muscular vessels. When the blood-supply is generous, as in the palms and soles and other regions subjected to unusual pressure or exposure, the arteries ascend through the subdermal layer to the deeper surface of the corium where, having subdivided, they anastomose to form the *subcutaneous plexus*.

From the latter some twigs sink into the subdermal layer and contribute the capillary networks that supply the adipose tissue and the sebaceous glands. Other twigs, more or less numerous, pass outwards through the deeper part of the corium and within the more superficial stratum unite into a second, *subpapillary plexus*, that extends parallel to the free surface and beneath the bases of the papillæ. The latter are supplied by the terminal twigs which ascend vertically from the subpapillary network and break up into capillary loops that occupy the papillæ and lie close beneath the epidermis (Fig. 366). The arrangement of the cutaneous *veins*, more complex than that of the arteries, includes four plexuses lying at different levels within the corium and extending parallel to the surfaces. The first and most superficial one is formed by the union of the radicles returning the blood from the papillæ. The component veins lie below and parallel to the rows of papillæ and immediately beneath the bases of the latter. At a slightly lower level, in the deeper part of the stratum papillare, the venous channels proceeding from the subpapillary network join to form a second plexus. A third occurs about the middle of the corium, while the fourth shares the position of the subcutaneous arterial plexus at the junction of the corium and subdermal strata. The deepest plexus receives many of the radicles returning the blood from the fat and the sweat-glands, the remainder being tributary to the veins accompanying the larger arteries as they traverse the tela subcutanea.

The **lymphatics** of the skin are well represented by a close *superficial plexus* within the papillary stratum of the corium into which the terminal lymph-radicles of the papillæ empty. The relation of these channels to the interfascicular connective tissue spaces is one only of indirect communication,

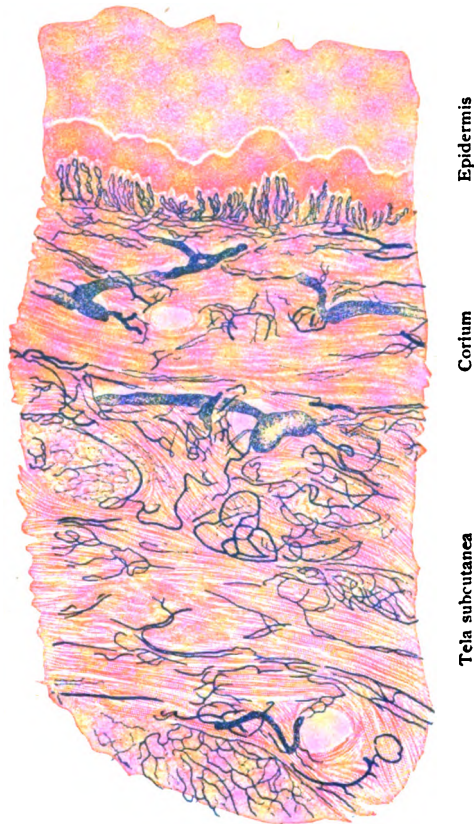


FIG. 366.—Section of injected skin, showing general arrangement of the blood-vessels; the terminal loops occupy the papillæ.  $\times 30$ .

since the lymphatics are provided with fairly complete endothelial walls. It is probable that the lymph-paths within the papillæ are closely related to the intercellular clefts of the epidermis. Migratory leucocytes often find their way into the cuticle where they then appear as the irregularly stellate *cells of Langerhans* seen between the epithelial elements. A wide-meshed *deep plexus* of lymphatics is formed within the subdermal layer, from which the larger lymph-trunks pass along with the subcutaneous blood-vessels.

The numerous *nerves* within the highly sensitive integument are chiefly the peripheral processes of sensory neurones which terminate in free arborizations between the epithelial elements of the cuticle, or in relation with special endings located, for the most part, within the corium or subdermal connective tissue. Some sympathetic fibres, however, are present to supply the tracts of involuntary muscle that occur within the walls of the blood-vessels or in association with the hairs and the sweat-glands.

On entering the skin the medullated nerves traverse the subdermal layer, to which they give off twigs in their ascent, and, passing into the corium, within the papillary stratum divide into a number of branches. Those destined for the epidermis beneath the latter break up into many fibres which, losing their medullary substance, enter the cuticle and end in ramifications between the epithelial cells as far as the outer limits of the stratum germinativum. The ultimate endings of the fibrillæ, whether tapering or slightly knotted, always occupy the intercellular channels and are never directly connected with the substance of the epithelial elements. Special *tactile cells* (Fig. 110) occur in the human epidermis, particularly over the abdomen and the thighs. They are spherical or pyriform and occupy the deeper layers of the cuticle; on the side directed towards the corium, they are in contact with the end-plate or meniscus of the nerve. The nerve-fibres particularly concerned with the sense of touch terminate within the connective tissue portion of the skin in special *end-organs*. The structure of these end-organs is elsewhere described (pages 79-83), their chief locations being here noted.

*Meissner's corpuscles* (Fig. 112) are especially numerous in the tactile cushions on the flexor surface of the hands and feet. While much more plentiful in all the tactile pads than in the intervening areas, the touch corpuscles are most abundant in those on the volar surface of the distal phalanges, where they approximate twenty to the square millimeter (Meissner). Their favorite situation is the apex of the papillæ, where they appear as elongated elliptical bodies, sometimes in pairs, whose outer pole lies immediately below the epidermis. These corpuscles are additionally, although sparingly, distributed on the dorsum of the hand, the flexor surface of the forearm, the lips, the eyelids, the nipple and the external genital organs.

The *Vater-Pacinian corpuscles* (Fig. 117) are well represented in the hands and feet and usually occupy the subdermal tissue, although sometimes found within the corium. Their distribution corresponds closely to that of Meissner's corpuscles, being most generous beneath the tactile cushions.

The *Golgi-Mazzoni corpuscles* are modifications of the Pacinian bodies and, like the latter, are found within the subdermal tissue.

The *end-bulbs of Krause* (Fig. 113) occur within the corium, either slightly below or within the papillæ, on the lips and external genital organs, as well as probably in other regions.

The *genital corpuscles* (Fig. 114) lie within the corium of the modified skin covering the glans penis and the prepuce and the clitoris and surrounding parts of the nymphæ.

The *end-organs of Ruffini* resemble the sensory terminations in tendons (page 85) and lie within the deeper parts of the corium, often associated with the Pacinian bodies.

The mode of ending of the nerves supplying the hairs and sweat-glands will be described in connection with those structures (pages 328 and 336).

## THE HAIRS.

The appendages of the skin—the hairs, nails, and cutaneous glands—are all specializations of the epidermis; they are, therefore, exclusively of ectodermic origin.

The **hairs** are present over almost the entire body, the few localities in which they are absent being the flexor surface of the hands and feet, the extensor aspect of the terminal segment of the fingers and toes, the inner surface of the prepuce and of the nymphæ and the glans penis and clitoridis. With the exception of those regions in which the growth is sufficiently long to constitute a complete covering, the hairs are for the most part short and scattered, although subject to great individual variation. The closest set hairs are on the scalp, on the top of the head numbering from 300–320, and in the occipital and frontal regions from 200–240 per square centimeter. On the chin they number about 45, on the mons pubis 35, on the extensor surface of the forearm 24 and on the back of the hand 18 for like areas. Even where their distribution is seemingly uniform, close inspection shows the hairs to be arranged in groups of from two to five.

In their *thickness* the hairs show much variation, not only in different races, individuals and regions, but also in the same person and part of the body, as on the scalp where fine and coarse hairs may lie side by side. The thickest scalp-hairs have a diameter of 162  $\mu$  and the finest one of 10  $\mu$  with all intermediate sizes. The hairs of the beard vary from 100–200  $\mu$ , and those on the pubes from 50–135  $\mu$ . In a general way, hairs of light color are finer than dark ones. On attaining their full growth without mutilation, hairs do not possess a uniform thickness throughout their length, since they diminish not only towards the tip, where the shaft ends in a point, but also towards the root. This feature is most evident in short hairs, as in those of the eyebrows. The straight and curly varieties of hair depend chiefly upon differences in the curvature of the follicle and the form of the hair. In the case of straight hairs the follicle is unbent and the shaft is cylindrical, and therefore circular in cross-section; hairs that are wavy or curly spring from follicles more or less bent and are flattened or grooved, with corresponding oval, reniform, or irregularly triangular outlines when transversely cut.

Each hair consists of two parts, the *shaft*, which projects beyond the surface, and the *root*, which lies embedded obliquely within the skin, the deepest part of the root expanding into a club-shaped thickening known as the *bulb*. The root is covered with a double investment of epithelial cells, the inner and outer *root-sheaths*, which, in turn, are surrounded by a connective tissue envelope, the *theca*. The entire sac-like structure, consisting of the hair-root and its coverings, constitutes the **hair-follicle**. At the bottom of the latter, immediately beneath the bulb, the wall of the follicle is pushed upwards to give place to a projection of connective tissue, the *hair-papilla*, which carries the capillary loops into close relation with the cells most active in the production of the hair. Save in the case of the finest hairs (lanugo), which are limited to the corium, the hair-follicles traverse

the latter and end at varying levels within the fat-laden subdermal layer (panniculus adiposus). In a general way the follicle may be regarded as a narrow tubular invagination of the epidermis, at the bottom of which the

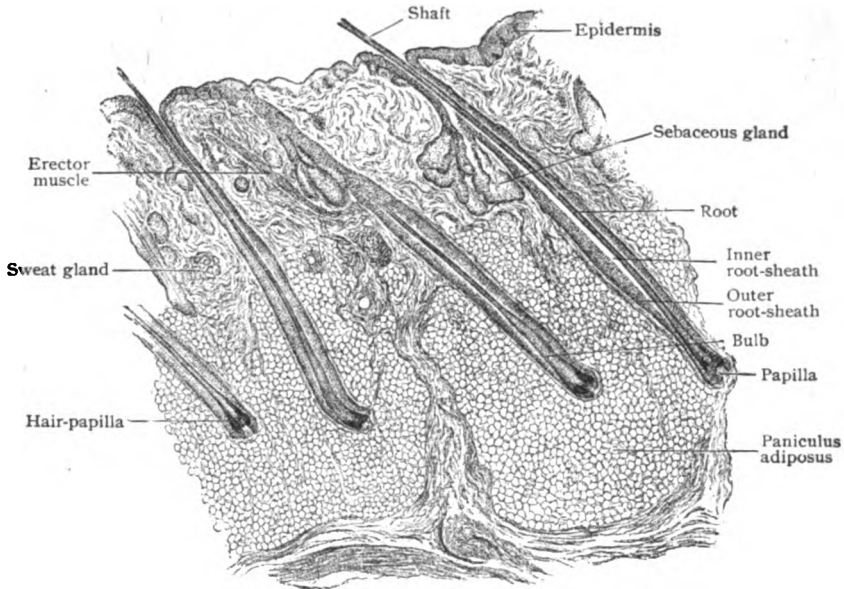


FIG. 367.—Section of scalp, showing longitudinally cut hair-follicles.  $\times 14$ .

hair is implanted and from the entrance of which the shaft projects. The most contracted part of the follicle, the *neck*, lies at the deeper end of the relatively wide funnel-shaped *mouth* of the sac. Closely associated with the hair-follicle, which they often surround, are the *sebaceous glands* that pour their oily secretion at the upper third of the follicle into the space between the shaft and the wall of the sac.

**The Hair-Shaft.**—In many thick hairs, but by no means in all, three parts can be distinguished—the *cuticle*, the *cortex*, and the *medulla*. The latter, however, is usually wanting in hairs of ordinary diameter, being often also absent in those of large size.

The *cuticle* of the hair appears as a transparent outermost layer marked by a network of fine sinuous lines, the irregular meshes of which have their longest diameter placed obliquely transverse. These lines correspond to the free borders of extremely thin glassy *cuticle-plates* that overlie the hair as tiles on a roof, the imbrication involving from four to six layers. The *cortical substance*, often constituting practically the entire shaft, consists of elongated fusiform cells so compactly arranged that the individual elements are only distinguishable after the action of disassociating reagents. In addition to the remains of the shrunken nuclei, the *hair-spindles*,

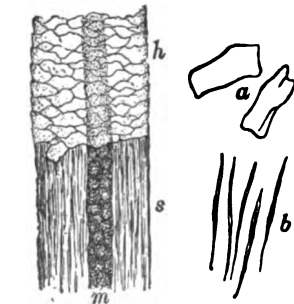


FIG. 368.—Portion of shaft of hair; *h*, shaft covered with cuticle; *s*, cortical substance exposed by removal of cuticle; *m*, medulla; *a*, *b*, isolated cells of cuticle and cortical substance respectively.  $\times 240$ .

as these modified epithelial cells are called, possess fibrillæ that pass between adjacent cells similar to the intercellular bridges in the epidermis. A variable amount of *pigment*, either diffuse, or as granules within or between the spindles, is a constant constituent of the cortical substance. In blond hair the color is chiefly diffuse, the pigment granules being often entirely wanting; in hair of darker shades, the granules predominate and increase in intensity of color as well as in quantity. As the hair grows outwards from the bulb, it loses much of its moisture, and in consequence later contains minute air-vesicles that replace the fluid previously occupying the clefts between the hair-spindles.

The **medulla**, when well represented, is seen as an axial stripe, somewhat uneven in outline, that varies with illumination, with transmitted light appearing as a dark band and with reflected light as a light one. This peculiarity depends upon the presence of air imprisoned between the shrunken and irregular *medullary cells*—dried and cornified epithelial elements which are connected by branching processes into a network incompletely filling the medulla. The air within the shaft modifies the color of the hair, since the resulting reflex tends to lessen the intensity of the tint directly referable to the pigment. Even when conspicuous, the medulla does not extend the entire length of the hair, often being interrupted and always disappearing before reaching the tip.

**The Hair-Follicle.**—This structure includes: (1) a connective tissue sheath, the *theca*, contributed by the corium; (2) an epithelial lining, the

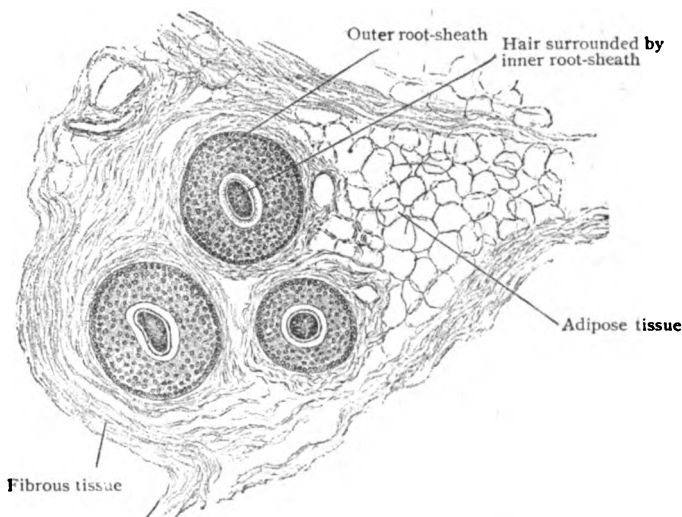


FIG. 369.—Horizontal section of scalp, showing group of transversely cut hair-follicles.  $\times 65$ .

*outer root-sheath*, continued from the deepest layer of the epidermis; and (3) the *inner root-sheath*, an epithelial investment probably differentiated within the follicle, and not a direct prolongation from the cuticle.

The **theca folliculi** includes three strata: an *outer*, composed of loosely disposed longitudinal bundles of fibrous tissue with a few cells and elastic fibres; a *middle* one, made up of closely placed circular bundles; and a very thin, homogeneous *inner* coat, the *glassy membrane*, which represents an unusually well developed basement membrane separating corium

from cuticle. Greatly attenuated, it is prolonged over the hair-papilla, which, as a special vascularized thickening of the connective tissue of the follicle, carries nutrition to the bulb of the growing hair.

The **outer root-sheath** is the continuation of the stratum germinativum alone, the other layers of the epidermis thinning out and disappearing before reaching the neck of the follicle. Its cells present the characteristics of those of the germinating layer, with exceptionally well marked fibrillæ. On approaching the level of the papilla, the outer root-sheath, which farther above consists of numerous layers, rapidly diminishes in thickness until, on the sides of the papilla, it is reduced to a single row of columnar cells.

The **inner root-sheath**, which is best developed over the middle third of the hair-root and fades away on reaching the upper third, includes three

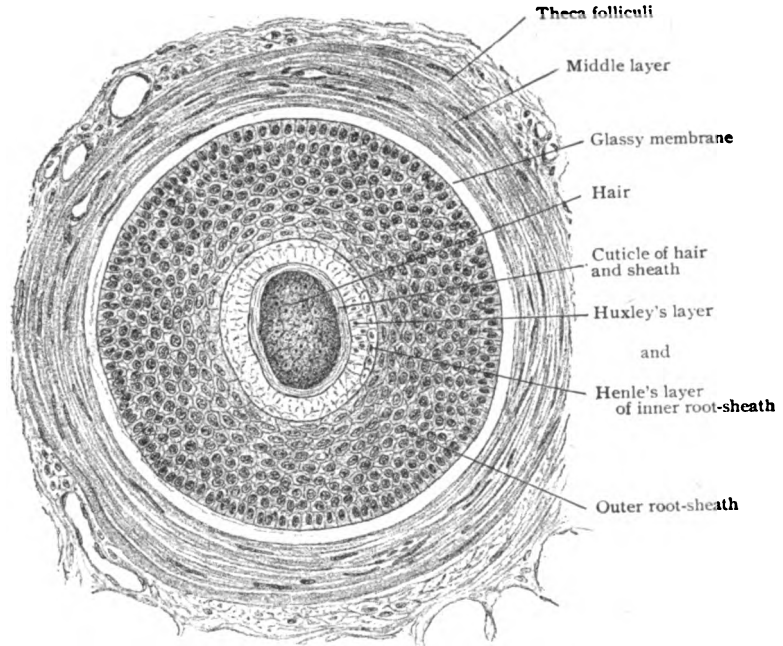


FIG. 370.—Hair-follicle cut across about the middle, showing hair surrounded by the root-sheaths.  $\times 285$ .

layers. The outer, known as *Henle's layer*, consists of a single row of flat polygonal cells, often partially separated by oval spaces. Their nuclei are very indistinct or invisible within the cornified cytoplasm. The middle or *Huxley's layer*, also horny in nature, often comprises only one stratum of nucleated cuboidal cells, but in the thicker hairs two or even three rows of irregularly interlocked cells may be present. The third layer, known as the *sheath-cuticle*, resembles the external coat of the hair, against which it lies, in being extremely thin and composed of flat horny plates. The latter, however, are always nucleated and so disposed that they are opposed to the serrations of the thicker hair-cuticle.

Traced towards the bottom of the follicle, the root-sheaths and the hair, which above are sharply defined from one another, become more and more alike until, in the immediate vicinity of the hair-papilla, they blend into a still imperfectly differentiated mass of cells. The deepest elements of this

complex, however, are cuboidal or low columnar and form an uninterrupted tract over the papilla, continuous with the outermost cells of the outer root-sheath. It is from the proliferation of these deepest cells that the formative material, or *matrix*, is provided to meet the requirements of growth and

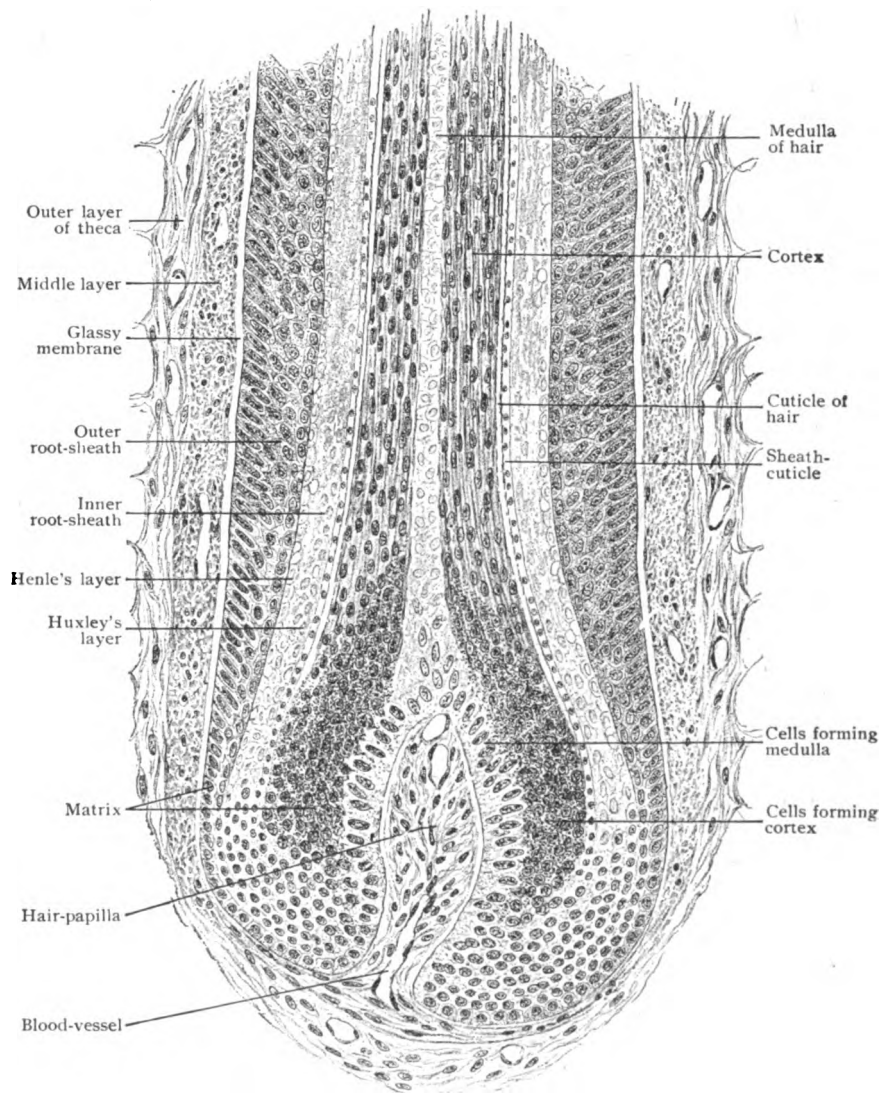


FIG. 371.—Longitudinal section through deepest part of hair-follicle.  $\times 285$ .

replacement of the hairs. Of the three parts of the hair, the medulla is produced by the cells overlying the summit of the papilla, while those converted into the cortical substance, cuticle and inner root-sheath occupy the sides of the papilla and deepest part of the follicle.

With few exceptions, the hair follicles are associated with two or more **sebaceous glands**, rarely with only one, the ducts of which open into the

sac in the vicinity of the neck. The glands usually lie on the side towards which the hair inclines, but sometimes, especially in the case of the smaller hairs, they may completely surround the follicle. Since these glands are outgrowths from the same tissue that lines the follicles, their ducts pierce the outer root-sheath, bringing their oily secretion into direct relation with the hairs.

Most of the larger hair-follicles, particularly those of the scalp, are provided with ribbon-like bundles of involuntary muscle, called the **arrectores pilorum** in recognition of their effect on the hairs. They arise from the superficial part of the corium, pass obliquely downwards to be inserted into the sheath of the hair-follicle near the junction of corium and subdermal tissue, and on the side corresponding with the inclination of the hair and the situation of the sebaceous glands. Since the latter are closely embraced by the muscular bands, contraction of the muscles exerts pressure upon the

glands and facilitates the discharge of their secretion, the *sebum*.

The **blood-vessels** supplying the hair-follicle, which in a sense constitute a special system for each sac, include the capillary loops ascending within the hair-papilla and the network of capillaries surrounding the follicle immediately outside the glassy membrane. The first are derived from a small special twig that ascends to the follicle, and the second from the subpapillary network of the corium. With the exception of those draining the papilla, which are tributary to the deeper stems, the *veins* join the subpapillary plexus.

The **nerves** distributed to the follicles follow a fairly

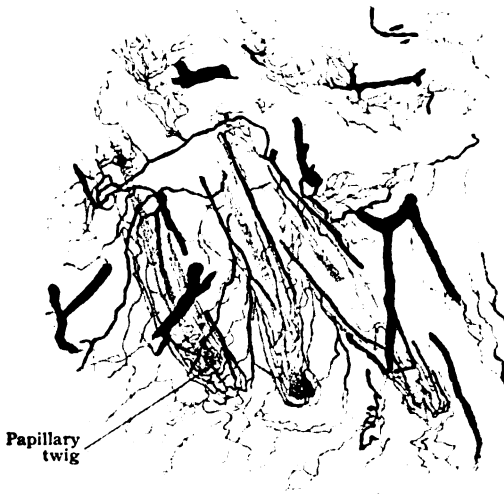


FIG. 372.—Section of injected scalp, showing capillary networks surrounding hair-follicles and twigs entering papillæ. X 20.

definite arrangement. Usually each hair-sac is supplied by a single fibre, sometimes by two or more, which approaches the follicle immediately below the level of the mouth of the sebaceous glands. After penetrating the fibrous sheath as far as the glassy membrane, the nerve-fibre separates into two divisions that encircle more or less completely the follicle and on the opposite side break up into terminal arborizations. The nerve-endings usually lie on the outer surface of the glassy membrane within the middle third of the follicle and only exceptionally are found within the outer root-sheath or the hair-papilla.

**Development.**—The primary development of the hair begins, about the end of the third month of fetal life, as localized proliferations of the epidermis. In section these appear as lenticular thickenings and on the surface as slight projections. Very soon solid epithelial cylinders sprout from the deeper surface of these areas and invade the subjacent corium to form the rudiments of the *hair-follicles*. The original uniform outline of these processes is early replaced by a flask-shaped contour in consequence of the



enlargement of their ends, which in their growth surround connective tissue processes to form the *hair-papilla*. The embryonal connective tissue immediately surrounding the epidermal ingrowth differentiates into the fibrous sheath and the glassy membrane.

Meanwhile and even before the formation of the papilla, the epithelial contents of the young follicle differentiate into an axial strand of spindle cells, that later undergoes keratinization and becomes the *hair-shaft*, which grows by subsequent additions from the matrix surrounding the papilla. In addition to forming the outer root-sheath, the peripheral elements contribute the matrix-cells that occupy the fundus of the follicle and surround the papilla. The cells covering the summit and adjacent sides of the papilla are converted into elongated spindles that gradually become horny and assume the characteristics of the cortical substance of the hair. When present,

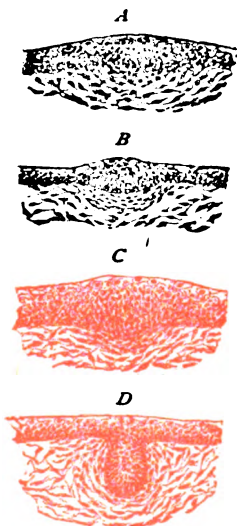


FIG. 373.—Sections of developing skin showing earliest stages in formation of hair-follicle; in *D* epithelial cylinder is invading mesoderm.  $\times 90$ .

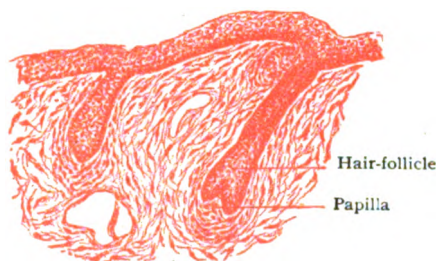


FIG. 374.—Developing skin, showing later stages of hair-follicles; mesoderm is forming hair-papilla and fibrous sheath of follicle.  $\times 90$ .

the medulla is developed by the transformation of the cells occupying the summit of the papilla, which enlarge, become less granular and grow upwards as an axial strand that invades the chief substance of the hair and accumulates keratohyalin within its cells. The pigment particles, which appear later, are first evident in the hair-bulb and probably arise within the epithelial tissue. The elements of the hair-cuticle and of the inner root-sheath are differentiated from the matrix-cells at the sides of the papilla. The tall columnar elements become elongated and converted into the cornified plates of the cuticle both of the hair and of the inner root-sheath. The layers of Huxley and of Henle are derived from cells that soon exhibit granules of keratohyalin, so that on reaching the level of the summit of the papilla the process of cornification has been established.

The **growth of the hair** takes place exclusively at the lower end of its bulb, where, so long as the hair grows, the conversion of the matrix-cells into the substance of the hair is continuously progressing. By this process the substance already differentiated is pushed upwards by the cells undergoing transformation and these, in turn, are displaced by the succeeding elements. In this way, by the addition of new increments in its bulb, the hair is forced onwards and, in the case of those first formed, through the epidermis that still blocks the mouth of the follicle. This eruption begins on the scalp and regions of the eyebrows about the fifth foetal month and on the extremities about a month later.

The hairs covering the fetus are soon shed, during the last weeks of gestation and immediately following birth, and are replaced by the stronger hairs of childhood. These latter, too, are continually falling out and being renewed until puberty, when in

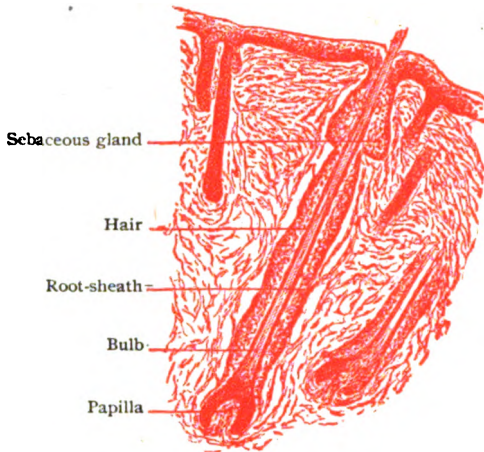


FIG. 375.—Later stage of developing follicle; the hair is now differentiated.  $\times 80$ .

many localities, as on the scalp, face, axillæ and external genital organs, they are gradually replaced by the much longer and thicker hairs that mark the advent of sexual maturity. Even after attaining their mature growth, the individual life of the hairs is limited, those on the scalp probably retaining their vitality for from two to four years and the eyelashes for only a few months. The change of hair, that is continually and insensibly occurring in man, includes the atrophy of the old hair and the development of the new one.

The earliest manifestations of this atrophy are reduction in the size and differentiation of the mass of matrix-cells at the bottom of the follicle and the diminution of the hair-papilla. The progressive reduction of the matrix is accompanied by the production of a club-shaped enlargement of the hair, between which and the shrunken matrix a strand of atrophic epithelial cells for a time remains. With the continued progress of these changes, the root of the *club-hair*, as the degenerating hair is termed, shortens so that the bulbous enlargement recedes from the bottom of the hair-sac until it lies just below the narrow neck of the follicle, where it remains for a longer or shorter period until the hair is dislodged and finally discarded. While the old hair is still lodged in the upper part of the follicle, the first steps towards its replacement are initiated by the stratum germinativum of the old hair-sac, the deepest follicle-cells contributing by proliferation the material from which the new hair is developed in a manner essentially the same as that by which its predecessor was formed.

### THE NAILS.

The nails, the horny plates overlying the ends of the dorsal surfaces of the fingers and toes, correspond to the claws and hoofs of other animals and, like them, are composed exclusively of epithelial tissue. They are specializations of the epidermis and, therefore, may be removed with the cuticle without mutilation. The entire nail-plate is divided into the *body*, which includes the exposed portion, and the *root*, which is embedded beneath the skin in a pocket-like recess, the *nail-groove*. The modified skin supporting the nail-plate, both the body and the root, constitutes the *nail-bed*, the cutaneous fold overlying the nail being the *nail-wall*. During life the nail shows *color-zones*, its projecting portion being immediately followed by a very narrow yellow band that corresponds to the line along which the stratum corneum of the underlying skin meets the under surface of the nail-plate. The succeeding and larger part of the nail is occupied by the broad pink zone which owes its rosy tint to the blending of the color of the blood in the underlying capillaries with that of the horny substance. On the thumb constantly, but on the fingers often only after retraction of the cuticle, is seen a transversely oval white area, the *lunula*, which marks the position of the underlying matrix.

The substance of the **nail-plate** consists entirely of flattened horny epithelial cells, very firmly united and containing the remains of their shrunken nuclei; hence it is also called *stratum corneum unguis*. These cornified scales are disposed in lamellæ, which, in transverse section, pursue a course in general parallel with the dorsal surface. In nails which possess the longitudinal ridges, however, the latter coincide with an upward arching of the lamellæ dependent upon the conformation of the nail-matrix. In longitudinal section the lamellation is oblique, extending from above downwards and forwards. Minute air-vesicles, imprisoned between the horny scales, are constant within the nail-substance. When these occur in unusual quantities, they give rise to white spots in the nail.

The **nail-bed** is divided into a proximal, a middle and a distal region, each of which exhibits structural peculiarities and corresponds respectively to the white, rosy or yellow zone seen from the dorsal surface of the nail. The most important of these regions is the proximal, known as the **matrix**, which lies beneath the white area and alone is concerned in the production of the nail. So long as the matrix is healthy, it is capable of replacing even an entire lost nail by a new one.

The *corium of the nail-bed* varies in the different regions in the arrangement and size of its elevations. Within the proximal third of the matrix, these elevations occur

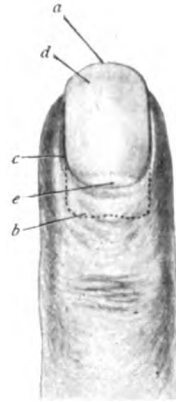


FIG. 376.—Part of finger, showing relations of the nail; *a, b*, distal and proximal borders of nail; *c*, nail-wall; *d*, line along which epidermis passes to under surface of nail-plate; *e*, lunula.

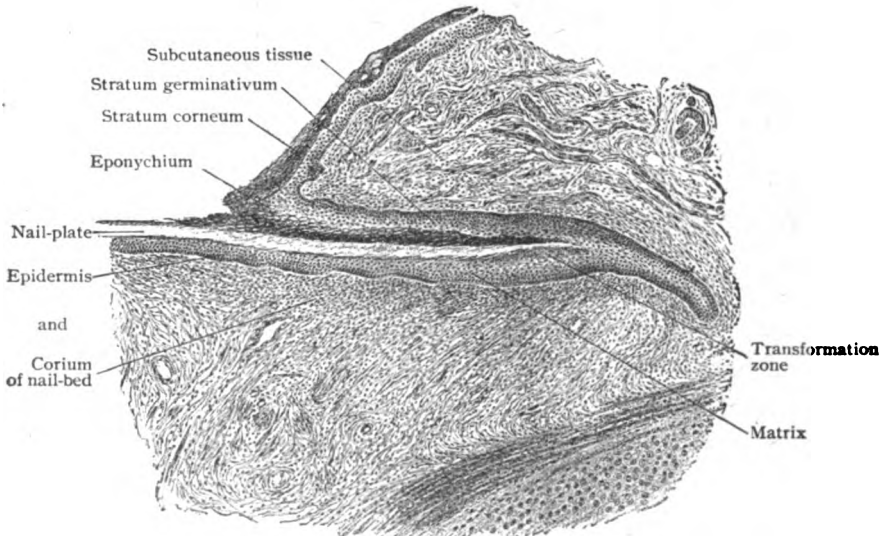


FIG. 377.—Longitudinal section of proximal part of nail lying within the nail-groove.  $\times 30$ .

as low papillæ, which decrease in height and number until they disappear, an even field occupying the middle of the matrix. This field is succeeded by one possessing

closely set low narrow longitudinal ridges, that at the distal margin of the lunula suddenly give place to more pronounced, but less numerous broader lineal elevations. These continue as far as the distal end of the nail-bed and are then replaced by papillæ. Owing to strong fibrous bands and the absence of the usual layer of fatty subdermal tissue, the corium of the nail-bed is closely attached to the bone.

The *epidermis underlying the nail* is of especial interest in view of its genetic activity. While the stratum germinativum of the skin covering the finger-tip passes directly and insensibly onto the nail-bed, the entire extent of which it invests (*stratum germinativum unguis*), the stratum corneum ends on reaching the under surface of the nail-plate, the line of apposition corresponding to the narrow yellow zone which

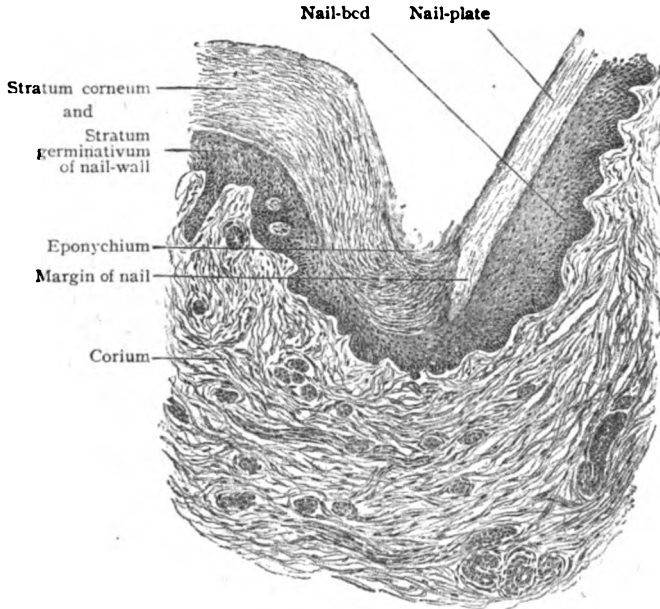


FIG. 378.—Section across nail-wall and adjoining part of nail-plate and nail-bed.  $\times 90$ .

defines the distal boundary of the rosy area. Beneath the latter, therefore, the epidermis of the nail-bed consists of the stratum germinativum alone, which, without cornification of any of its cells, rests against the under surface of the nail. Beneath the white zone, that is, within the matrix, the epidermis includes a half-dozen or more layers of the usual elements of the stratum germinativum, surmounted by a like number of strata of cells distinguished by a peculiar brownish color. On reaching the nail these modified epithelial elements pass into the substance of the plate, the constituent cells of which they directly become. Since the transformation of the cells of the stratum germinativum into those of the nail-plate is confined to the matrix, it is evident that the continuous growth of the nail takes place along the floor and bottom of the nail-groove, the last formed increment of nail-substance pushing forwards the previously differentiated material and thus forcing the nail towards the end of the digit. As the nail leaves the groove, a part of the stratum germinativum of the nail-wall blends with the epidermis and is prolonged for a variable distance over the dorsal surface of the nail-plate as a delicate membranous sheet, the *eponychium*, which usually ends in a ragged and abraded border.

#### THE CUTANEOUS GLANDS.

These structures include two chief varieties, the *sebaceous* and the *sweat-glands*, together with certain modifications, as the ceruminous glands within the external auditory canal, the circumanal glands, the tarsal and ciliary

glands within the eyelid and the mammary glands. In all, the epithelial tissues—the secreting elements and the lining of the ducts—are derivatives of the ectoderm and, therefore, genetically related to the epidermis.

**The Sebaceous Glands.**—Although these structures, the *glandule sebaceæ*, are chiefly associated with the hair-follicles, they also occur, although

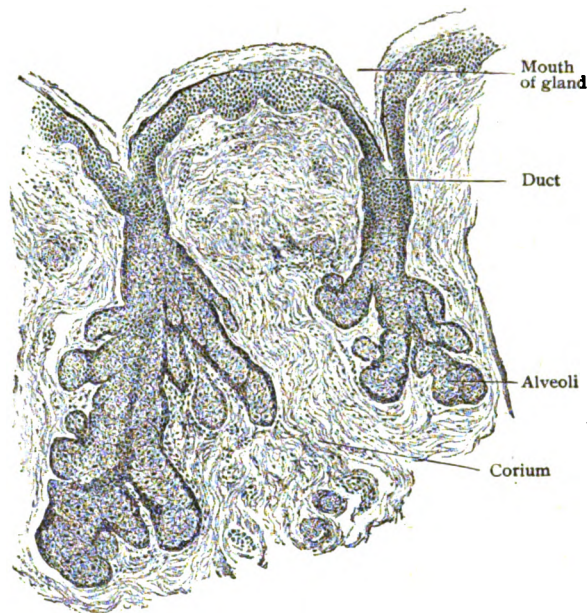


FIG. 379.—Sebaceous glands in skin covering ala of nose.  $\times 60$ .

less frequently, independently and in those parts of the skin in which the hairs are wanting, as on the lips, prepuce, and labia minora. The size of these glands bears no relation to that of the hairs, since among the smallest (.2-.4 mm.) are those on the scalp. The largest (.5-2. mm.) are found on the mons pubis, scrotum, external ear and nose. Conspicuous aggregations, modified in form, occur in the eyelids as the Meibomian glands.

The smallest sebaceous glands are each little more than tubular diverticula, dilated at the closed ends. In those of the larger size, the relatively short duct subdivides into several expanded compartments, which, in the largest glands, may be replaced by groups of irregular alveoli, with uncertain ducts that converge into a short wide common excretory passage.

The structural components of these glands include a *fibrous envelope*, a *membrana propria*, and the *epithelium*, the first two being continuous with the corresponding coverings of the hair-follicle. The *epithelium* continued into the ducts and alveoli of the sebaceous glands is directly prolonged from the outer root-sheath of the epidermis, where associated with the hair-follicles, or from the epidermis where the hairs

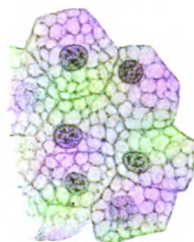


FIG. 380.—Cells from alveoli of sebaceous glands, conspicuously showing reticulated cytoplasm.  $\times 650$ .

are wanting. The periphery of the alveolus is occupied by a single, or incompletely double, layer of flattened and imperfectly defined basal cells. These rest immediately upon the *membrana propria* and are distinguished by their dark cytoplasm and outwardly displaced oval nuclei. Passing towards the centre of the alveolus, the next cells contain a number of small oil drops which, with each successive row of cells, become larger and appropriate more and more space at the expense of the protoplasmic reticulum in which they are lodged. In consequence, the cells occupying the centre of the alveoli, which are completely filled and without a lumen, contain little more than fat. As the cells are escaping from the glands they lose their nuclei and individual outlines and, finally, are merged as débris into the secretion, or *sebum*, with which the hairs and skin are anointed. The necessity for new cells, created by the continual destruction of the glandular elements that attends the activity of the sebaceous glands, is met by the elements recruited from the proliferating basal cells, which in turn pass towards the centre of the alveolus and so displace the accumulating secretion.

**The Sweat-Glands.**—These structures, the *glandulæ sudoriferæ*, occur within the integument of all parts of the body, with the exception of that covering the red margins of the lips, the inner surface of the prepuce and the glans penis. They are especially numerous in the palms and soles, in the former locality numbering more than 1100 to the square centimeter, and fewest on the back and buttocks, where their number is reduced to about 60 to the square centimeter; their usual quota for the same area is between two and three hundred.

Modified simple tubular in type, each gland consists of two chief divisions, the *body* or *gland-coil*, the tortuously wound tube in which secretion takes place, and the *excretory duct*, which opens on the surface of the skin, exceptionally into a hair-follicle, by a minute orifice, the *sweat-pore*, often distinguishable with the unaided eye.

The *body* of the gland, irregularly spherical or flattened, consists of the windings of a single or rarely branched tube. It commonly occupies the deeper part of the corium, but sometimes, as in the palm and scrotum, lies within the subdermal connective tissue. The coiled portion of the gland is not entirely formed by the secretory segment, since, as shown by the reconstructions of Huber, about one fourth is contributed by the convolutions of the first part of the duct.

The secreting portion of the gland-coil, called the *ampulla* on account of its greater diameter, possesses a wall of remarkable structure. The thin *external sheath*, composed of a layer of dense fibrous tissue and elastic fibres, supports a well defined *membrana propria*. Immediately within the latter lies a thin but compact layer of *involuntary muscle*, whose longitudinally disposed spindle-shaped elements in cross-section appear as irregularly nucleated cells that encircle the secreting epithelium and displace it from its customary position against the basement membrane. This muscular tissue enjoys the distinction, which it shares with the dilator of the pupil, of being developed from the ectoderm. The *secreting cells* constitute a single row of low columnar epithelial elements, that lie internal to the muscle and surround the relatively large lumen. Their finely granular cytoplasm contains a spherical nucleus, situated near the base of the cell, and in certain of the larger glands, as the axillary, includes fat droplets and pigment granules. These are liberated with the secretion of the gland and, when present in unusual quantity, account for the discoloration produced by the perspiration of certain individ-

uals. In the case of the ceruminous glands, the amount of oil and pigment is constantly great and confers the distinguishing characteristics of the ear-wax.

On leaving the gland-coil, in close proximity to the blind end of the gland, the duct ascends through the corium with a fairly straight or slightly wavy course as far as the epidermis. On entering the latter its further path is marked by conspicuous corkscrew-like windings, which terminate on the surface by a trumpet-shaped orifice, the *sweat-pore*. In its

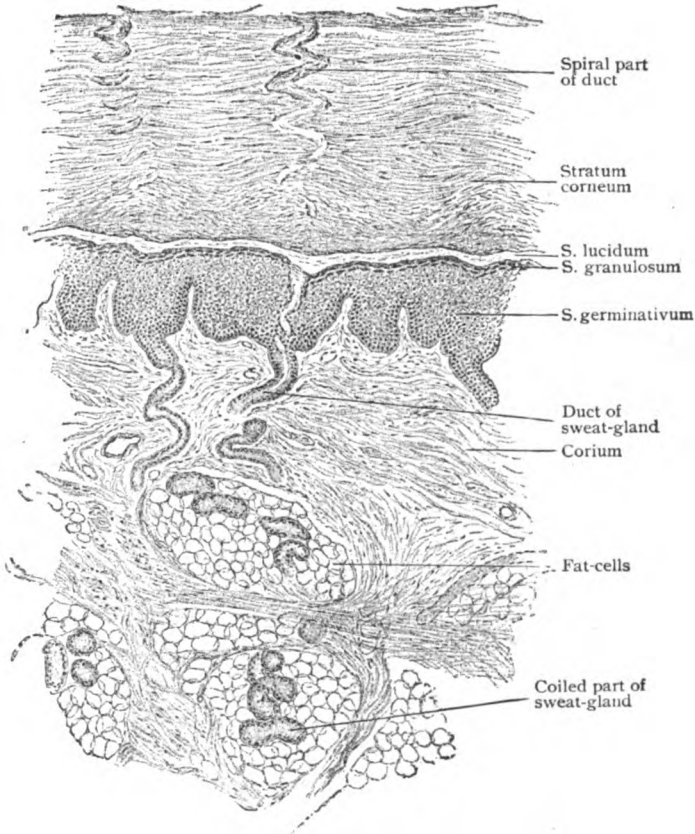


FIG. 381.—Section of skin from palm, showing layers of epidermis and parts of sweat-glands extending from surface into tela subcutanea.  $\times 65$ .

course through the corium the duct never traverses a papilla or ridge, but always enters the cuticle between the elevations. On the palms and soles, where the pores occupy the summit of the cutaneous ridges, the ducts enter the cuticle between the double rows of papillæ.

The sudden and conspicuous reduction in the size of the tube, which marks the termination of the secreting segment and the beginning of the duct, is accompanied by changes in the structure of its wall. In addition to a reduction of its diameter to one half or less of that of the ampulla, the duct loses the layer of muscle and becomes flattened, with corresponding changes in the form of its lumen. The single row of secreting elements is replaced by an irregular double or triple layer of cuboidal cells, which exhibit a

homogeneous zone, sometimes described as a cuticle, next the lumen. On entering the epidermis, the duct not only loses its fibrous sheath and *membrana propria*, but the epithelial constituents of its wall are soon lost among the cells of the *stratum germinativum*, so that its lumen is continued to the surface as a spiral cleft bounded only by the cornified cells of the cuticle.

Apart from mere variations in size, certain glands—the *circumanal*, the *ciliary*, and the *ceruminous*—depart sufficiently from the typical form of the coiled glands to entitle them to brief notice. The **circumanal glands**, lodged chiefly within a zone from 12–15 mm. wide and about the same dis-

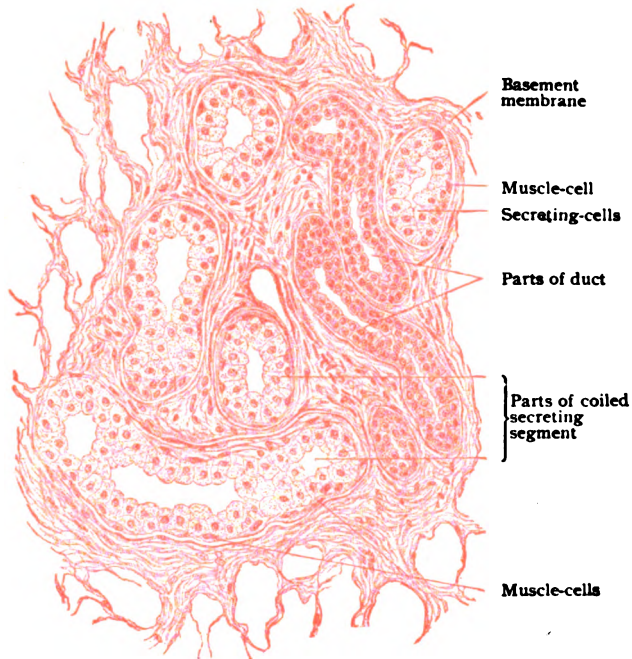


FIG. 382.—Section of coiled portion of sweat-gland.  $\times 325$ .

tance from the anus, are not all the same, but include, according to Huber, four varieties. In addition to (1) the usual sweat-glands and (2) some (Gay's) of exceptional size, (3) others have relatively straight ducts that end in expanded saccules, from which secondary alveoli arise; finally (4) branched glands of the tubo-alveolar type are present. The **ciliary glands** (*Molls's*) of the eyelid are not typical coiled structures, but belong to the branched tubo-alveolar groups. The **ceruminous glands**, distinguished by the large amount of oil and pigment mingled with their secretion, are likewise referable to the branched tubo-alveolar type.

The **blood-vessels** of the sweat-glands include arterial twigs given off from the cutaneous rete, a capillary network outside the *membrana propria*, best developed within the coiled portion of the tube, and the veins that join the deeper plexus within the corium.

The **nerves** are especially numerous and consist of nonmedullated sympathetic fibres that traverse the fibrous sheath and form a close epilem-



mar plexus on the outer surface of the *membrana propria*. From this network fibrils penetrate the basement membrane and end in close relation with the gland-cells and muscle-elements.

## THE EYE.

The organ of sight proper includes only the eyeball or globe of the eye; with it, however, are closely associated other structures, as the eyelids, the lachrymal apparatus, the orbital fascia and fat, and the ocular muscles, which serve for its protection, support and change of axis. The structure of the eyeball, therefore, will be described first; afterwards, that of some of the accessory organs.

### THE EYEBALL.

The human eyeball is an approximate sphere with an antero-posterior diameter (24.2 mm.) of slightly less than one inch. It is, however, somewhat flattened from above downwards and from side to side. Its shape,

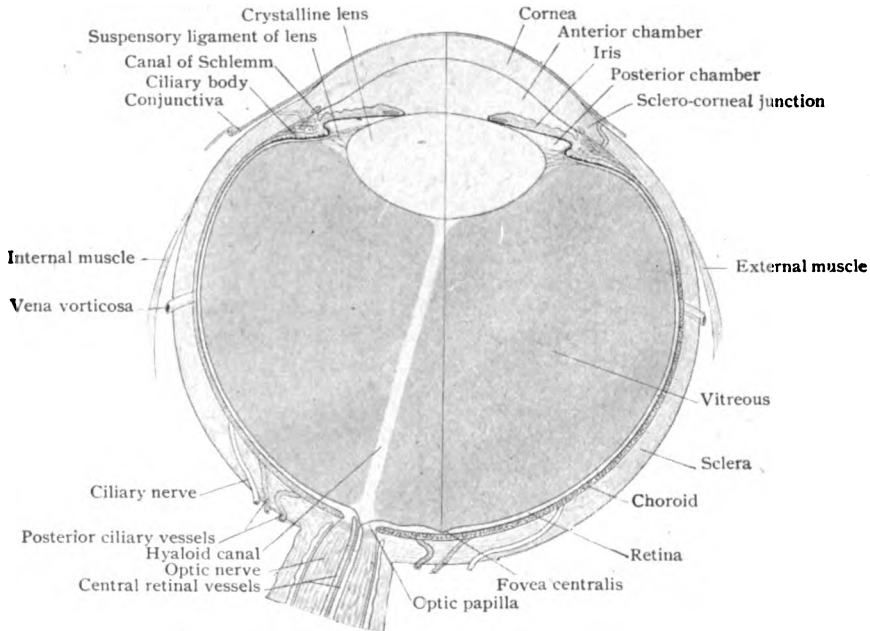


FIG. 383.—Diagrammatic horizontal section of right eye.  $\times 2\frac{1}{2}$ .

therefore, is spheroidal, with the vertical diameter (23.2 mm.) the shortest. The eyeball consists of three concentric tunics or coats: (1) the *external* or *fibrous tunic*, composed of the *sclera* and the *cornea*; (2) the *middle* or *vascular tunic*, which is pigmented, partly muscular and composed, from behind forwards, of the *choroid*, the *ciliary body*, and the *iris*; and (3) the *inner* or *nervous tunic*, usually called the *retina*, which is an expansion from the brain and contains the nerve-cells, the nerve-fibres and the special neuro-epithelium for the reception of the visual stimuli. Within these tunics are enclosed the refracting media—the *aqueous humor*, the *crystalline lens*, and the *vitreous body*.

## THE FIBROUS TUNIC.

**The Sclera.**—The sclera, or *sclerotic coat*, is a firm, dense fibrous tunic which forms the posterior four-fifths of the outer coat of the eye, being closely connected with the sheaths of the optic nerve posteriorly, and joining in front with the cornea. In the neighborhood of the optic nerve it measures 1 mm. in thickness, gradually becoming thinner towards the equator, until, just posterior to the attachment of the tendons of the ocular muscles, it measures only .4 mm. After receiving the expansions of these tendons it increases and reaches a thickness of .6 mm. The optic nerve passes through this tunic at a position 1 mm. below and from 3–4 mm. to the inner side of

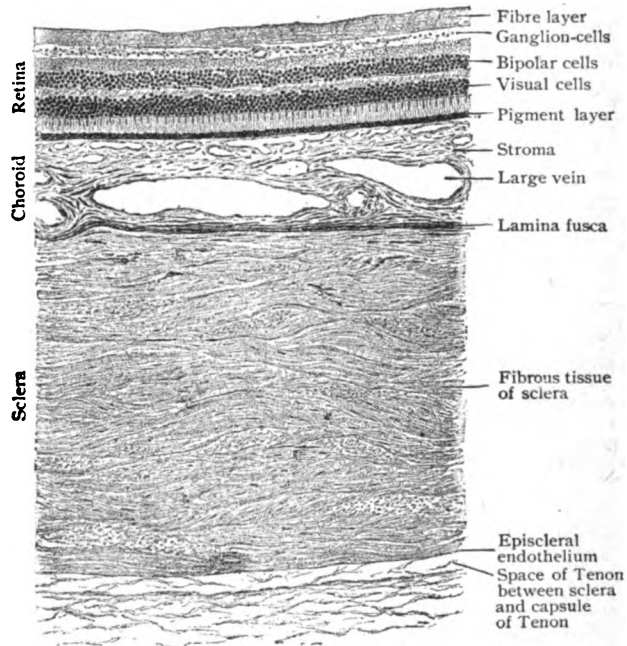


FIG. 384.—Section through posterior wall of eyeball, showing relative thickness of the fibrous, vascular and nervous coats.  $\times 40$ .

the posterior pole of the eye; the canal is partially bridged over by interlacing fibrous bundles, the *lamina cribrosa*, which are intimately associated with the supporting tissue of the nerve.

The sclera is composed of interlacing bundles of white fibrous tissue, which in the outer and inner layers have chiefly a meridional direction, while the central bundles are alternately circular and meridional. With the fibrous bundles is associated a rich network of fine elastic fibres. The clefts between the lamellæ contain irregularly, stellate connective tissue cells, the *scleral corpuscles*. On the inner surface of the sclera many of these cells are pigmented and give it a brownish color. This layer, the *lamina fusca*, with the underlying choroid encloses a narrow cleft, the *suprachoroidal lymph-space*, both walls of which, together with the fine connective tissue trabeculæ which cross it, are lined with endothelial cells. The outer surface of the sclera, from the optic nerve entrance to the attachment of the ocular muscles, is

similarly covered with endothelial plates, and forms part of the lining of Tenon's lymph-space. Anterior to the muscle-insertions it is covered with a loose-meshed connective tissue, the *episcleral tissue*, richly supplied with blood-vessels, nerves and lymph-vessels, and continuous with the subconjunctival tissue of the *conjunctiva scleræ*.

The *blood-vessels* of the sclera arise from the arteries which perforate it to supply the vascular coat of the eye. They form a wide-meshed network on the surface of the sclera, which sends anastomosing vessels to a deeper lying set in the scleral substance. In the neighborhood of the optic nerve entrance, the branches of the short posterior ciliary arteries form an arterial circle, the *circulus Zinni*, which sends branches to the optic nerve and choroid, and is, therefore, of great importance in establishing an anastomosis between the choroidal circulation and the *arteria centralis retinae* which supplies the retina. The *veins* of the sclera empty into the anterior and posterior ciliary veins, and into the *venæ vorticosæ*. At the junction of the cornea and sclera is an important circular venous channel, the *canal of Schlemm*, which will be described later.

**The Cornea.**—The cornea forms the anterior one-fifth of the fibrous tunic of the eyeball, and, although composed, like the sclera, of bundles of connective tissue, is transparent and allows rays of light to enter the eyeball.

The cornea is composed of five distinct layers, which from without in are: (1) the *anterior epithelium*, (2) the *anterior limiting membrane*, (3) the *substantia propria*, (4) the *posterior limiting membrane*, and (5) the *endothelium*.

The *anterior epithelium* of the cornea is continuous with that covering the surface of the adjacent scleral conjunctiva. It is of the stratified squamous variety, usually five cells deep in man, and measures  $45 \mu$  in thickness at the centre, and  $80 \mu$  at the periphery. The deepest cells are columnar in form, with broad bases resting upon the anterior limiting membrane, to which they are firmly attached by means of minute projections that roughen the anterior surface of the latter. The outer parts of the basal cells contain the nucleus and fit into corresponding depressions in the cells of the superimposed layers. The middle layers are composed of irregular polyhedral cells, possessed of fine protoplasmic intercellular processes. The superficial layers consist of flattened cells which lie parallel to the free surface and contain nuclei.

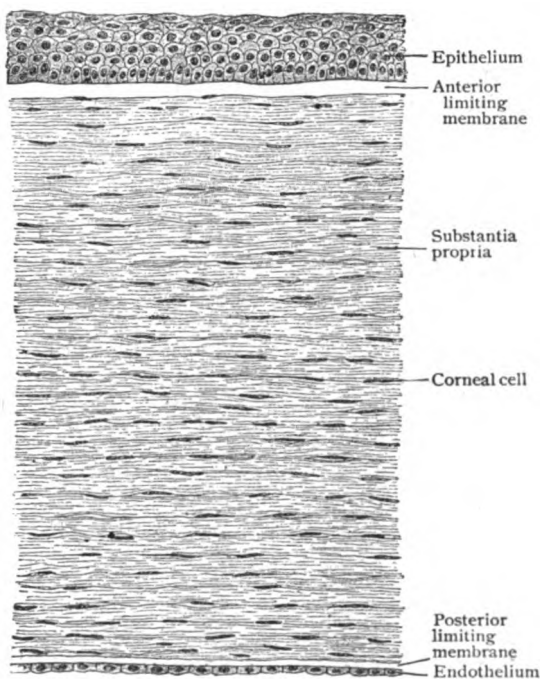


FIG. 385.—Section of human cornea.  $\times 85$ .

The **anterior limiting membrane**, or *Bowman's membrane*, is situated immediately below the epithelium and appears as a homogeneous band, about  $20\ \mu$  in thickness at the centre and thinner at the periphery, where it terminates without extending into the conjunctiva of the sclera. The membrane may be resolved into fine fibrillæ by suitable reagents, is connected firmly with the cornea proper, and is to be considered a special condensation of the latter. It contains no elastic tissue.

The **substantia propria** constitutes the main portion of the cornea and is made up of interlacing bundles of fibrous connective tissue, directly continuous with those of the adjacent sclera. The bundles are composed of fine fibrillæ, have a flattened form, and are so disposed as to produce regular lamellæ, about sixty in number, running parallel with the surface. The alternating lamellæ have a direction approximately at right angles to each other and are frequently joined together by strands, the *fibræ arcuatæ*, which

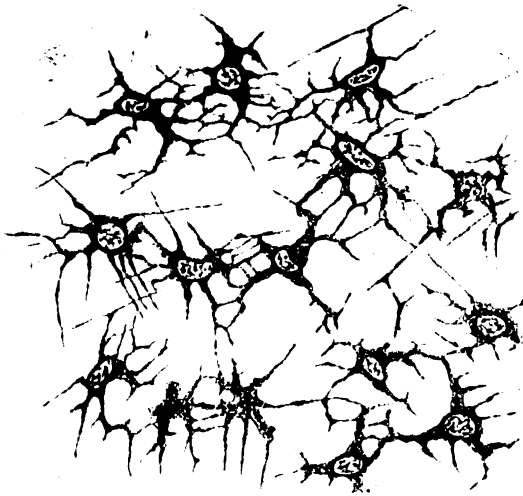


FIG. 386.—Thin sheet of corneal tissue stained to show the corneal corpuscles; surface view.  $\times 350$ .

are especially numerous in the anterior lamellæ. The fibrillæ and bundles are held together by an interfibrillar cement-substance, in which are embedded the cellular elements, the *corneal corpuscles*. These are flattened connective tissue cells, with faintly granular cytoplasm, whose nuclei are irregular and show nucleoli. The cells are provided with branching processes which anastomose with those of other cells, both on the same and adjacent levels, and so constitute a continuous network of protoplasm, upon which the nutrition

of the cornea largely depends. They occupy a system of intercommunicating lymph-clefts, the *corneal spaces*, which during life they fill completely. Occasional leucocytes or wandering cells are found between the fibrous bundles.

The **posterior limiting membrane**, also known as *Descemet's membrane*, the *membrane of Demours*, or the *posterior elastic membrane*, is a homogeneous band, which varies in thickness from  $6\ \mu$  at the centre to  $12\ \mu$  at the periphery. It is less firmly united to the substantia propria than is the anterior limiting membrane, and is less easily affected by acids, alkalis, boiling water and other reagents. It resembles elastic tissue and is very firm and resistant to injury or perforation from inflammation. At the periphery the membrane splits up into bundles of fine fibres, which are gradually strengthened into a series of firm connective tissue trabeculæ. Some of these form the point of attachment of the ciliary muscle; others run into the iris, and still others constitute the inner wall of a circularly disposed venous channel, the *sinus circularis iridis*, or *canal of Schlemm*. These fibres are known as the *ligamentum pectinatum iridis* and mark the lateral limit of the

anterior chamber. They are incompletely covered with endothelial cells and enclose the *spaces of Fontana*. These spaces, better developed in lower animals than in man, directly communicate with the aqueous chamber, and thus form an important point for filtration of fluid from the interior of the eye, by way of the canal of Schlemm, into the anterior ciliary veins.

The **endothelium** covers the free inner surface of the posterior limiting membrane. It consists of a single layer of flat polygonal cells, whose nuclei often extend above the level of the cell-body. The cells are connected by delicate protoplasmic processes and are continuous with the cells lining the spaces of Fontana and the anterior surface of the iris. With Descemet's membrane they constitute a barrier to the filtration of fluid from the anterior chamber into the cornea.

The *blood-vessels* of the normal cornea are limited to a peripheral zone, from 1-2 mm. in width, in which the terminal twigs of the episcleral arteries end in loops. The remainder of the cornea is free from blood-vessels. The *nerves* of the cornea are exceedingly numerous. They are branches of the

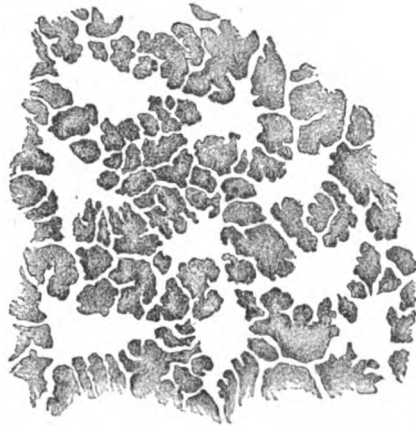


FIG. 387.—Substantia propria stained with silver to show the spaces containing the corneal cells.  $\times 350$ .

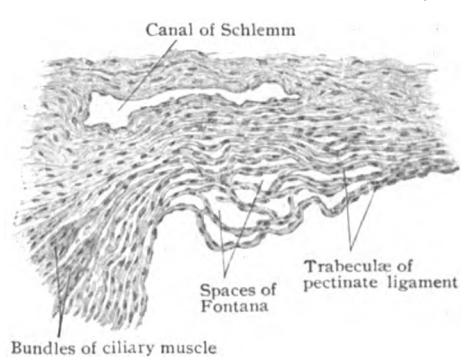


FIG. 388.—Section through margin of anterior chamber, showing spaces of Fontana, between the relaxed trabeculae of the pectinate ligament, and the canal of Schlemm.  $\times 65$ .

long and short ciliary nerves, from 40 to 45 in number, and form an *annular plexus* that surrounds the margin of the cornea. Entering the latter, they are accompanied for a short distance by perineural lymph-sheaths and, losing these and their medullary substance, they form a number of plexuses within the corneal stroma at various depths. A few of the fibres pass backwards and supply the posterior layers. Fully two thirds, however, after forming a *fundamental plexus*, push forwards and send *perforating branches* through the anterior limiting membrane and

unite into a *subepithelial plexus*, the minute radial fibres passing towards the centre of the cornea. From this plexus fibrils ascend between the epithelial cells and end either as varicose fibrils, or in connection with special end-bulbs (the *intraepithelial plexus*). After forming complex secondary plexuses, branches from the fundamental plexus end within the substantia propria as naked fibrillae between the lamellae.

THE VASCULAR TUNIC.

The middle or vascular coat, sometimes called the *uveal tract*, consists of a connective tissue sheath supporting blood-vessels, which lies internal to the outer fibrous tunic. It extends from the entrance of the optic nerve

to the pupil and includes three portions, which from behind forward are: the *choroid*, the *ciliary body*, and the *iris*. The choroid and ciliary body are in contact with the sclera, but the iris bends sharply inwards and floats in the aqueous humor, incompletely dividing the space anterior to the crystalline lens into the posterior and the anterior chamber.

**The Choroid.**—The choroid contributes the posterior two-thirds of the vascular coat. It lies between the sclera and the retina and extends from the optic nerve entrance to the anterior limit of the visual part of the retina at the ora serrata, its main function being to supply nutrition to the nervous tunic. It is a delicate coat, with a thickness of .2 mm. near the nerve and about half as much at the ora serrata. The *outer surface* is roughened by the

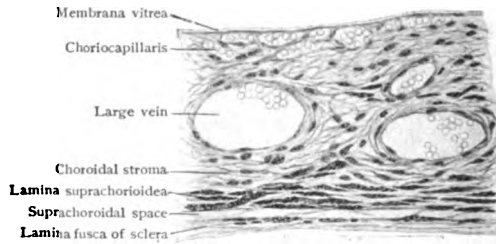


FIG. 389.—Section of choroid, showing capillary layer and large vessels.  $\times 200$ .

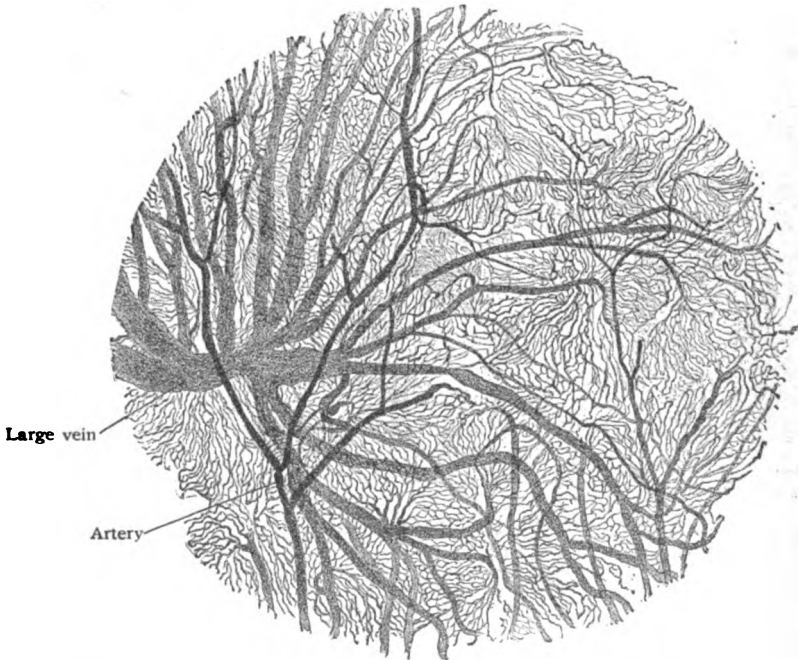


FIG. 390.—Surface view of injected human choroid, showing venous radicles converging to form large vein.  $\times 18$ .

trabeculae of connective tissue which cross the suprachoroidal lymph-space and connect the choroid with the overlying sclera. Its *inner surface* is smooth and covered by the pigmented cells of the retina, which are so closely attached that they frequently adhere to the choroid when the membranes are separated.

The choroid consists of four layers, which from without inwards, are: (1) the *lamina suprachorioidea*, (2) the *choroid proper*, which contains the larger vessels, (3) the *choriocapillaris*, or layer of fine capillaries, and (4) the *membrana vitrea*.

The *lamina suprachorioidea* is the outer boundary of the choroid and connects it with the sclera. It is composed of interlacing bundles of fibrous tissue, which are strengthened by rich networks of elastic fibres. The cellular elements consist of (a) flattened endothelial plates, which line the lymph-clefts and cover the connective tissue trabeculae connecting the choroid and the sclera; and (b) large irregularly branched connective tissue cells, the *chromatophores*, which are conspicuous on account of their deep pigmentation. The lamellae of the suprachoroid continue, without definite boundary, into the subjacent choroidal stroma.

The **choroid proper**, as the choroidal stroma is called, has the same general structure as the suprachoroidal layer, but the connective tissue elements are denser and support a large number of blood-vessels, between which are placed the stellate chromatophores. The largest vessels occupy the outer part of the coat and are chiefly venous. They are surrounded with perivascular lymph-sheaths, and converge in peculiar whorls to form four or five large trunks, the *venae vorticosae*, which pierce the sclera in the equatorial region and drain not only the choroid, but partly also the ciliary body and iris. The arteries, derived from the short ciliary vessels, lie internal to the veins. Their walls contain longitudinally disposed muscle-fibres in addition to the customary circular ones.

The **choriocapillaris**, or *membrane of Ruysch*, is composed of capillaries which form an extremely close meshwork embedded within a homogeneous nonpigmented matrix. Between the choriocapillaris and the layer of larger vessels is a narrow boundary zone of closely woven fibro-elastic strands, which is nearly free from pigment. In some animals this layer possesses a peculiar metallic reflex and is known as the *tapetum fibrosum*; in carnivora its iridescent appearance is due to the presence of cells containing minute crystals (*tapetum cellulosum*).

The **membrana vitrea**, or *membrane of Bruch*, the innermost layer of the choroid, measures only  $2\ \mu$  in thickness.

It separates the choriocapillaris from the retina and consists of two strata, an inner homogeneous one, probably a product of the retinal pigment cells, and an outer highly elastic portion. The *nerves* of the choroid form a plexus within the lamina suprachorioidea, which contains groups of ganglion-cells and sends numerous nonmedullated fibres chiefly to the muscular coats of the arteries. The choroid contains no sensory nerve-fibres.

**The Ciliary Body.**—The ciliary body, the middle portion of the vascular tunic, extends from the ora serrata to the sclero-corneal junction. Sections through the eyeball in a meridional direction (Fig. 392) show its triangular form. The outer side is in apposition to the sclera, the inner is covered by the pigmented extension of the retina, and the short anterior

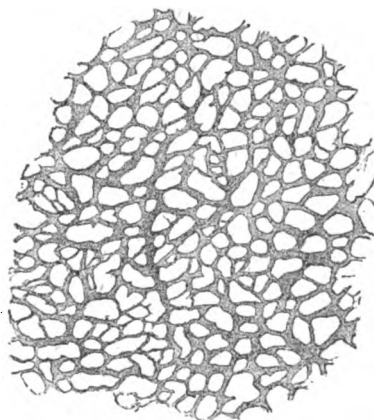


FIG. 391.—Portion of injected choroid, showing surface view of choriocapillaris layer.  $\times 130$ .

side, at right angles to the outer, extends inwards from the pectinate ligament towards the lens. The ciliary body presents three subdivisions: the *ciliary ring*, the *ciliary processes*, and the *ciliary muscle*.

The **ciliary ring**, or *orbiculus ciliaris*, consists of a smooth band of tissue, 4 mm. in width, in advance of the ora serrata. It differs in structure from the choroid in the absence of the choriocapillaris, its vessels running in a longitudinal direction and returning the blood from the iris and ciliary

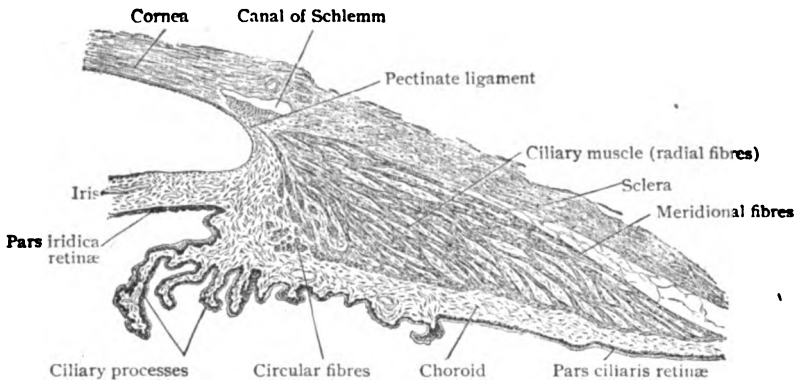


FIG. 392.—Meridional section of ciliary region, showing ciliary body with its muscle and processes.  $\times 40$ .

body to the venæ vorticosæ. On its inner surface, delicate meridionally placed folds make their appearance, by the union of which the ciliary processes are formed.

The **ciliary processes** constitute the remainder of the inner portion of the ciliary body. They form an annular series of folds, about seventy in number, which surround the lens and act as points of attachment to its suspensory ligament. Commencing by the union of several plications of the orbiculus ciliaris, they rapidly increase in height and breadth, until they reach an elevation of from .8–1 mm., and then fall suddenly to the iris-level. They consist of a rich network of vessels embedded in a pigmented connective tissue stroma, like that of the choroid. The inner surface is covered with a homogeneous membrane, continuous with the membrana vitrea of the choroid, on the inner surface of which is placed the double layer of cells representing the ciliary portion of the retina (*pars ciliaris retinae*). Each ciliary process is composed of a number of irregularly projecting folds which increase in height as the iris is approached.

The **ciliary muscle** occupies the outer portion of the ciliary body, lying between the sclera and the ciliary processes. It forms an annular prismatic band of involuntary muscle, which in meridional sections has a triangular form. Its main fibres arise from the sclera and pectinate ligament, at the sclero-corneal junction internal to the canal of Schlemm, and run in a *meridional* direction backwards along the sclera to be inserted into the choroidal stroma. The inner angle of the triangle, at the base of the iris, is occupied by a band of *circularly* disposed fibres, the *circular ciliary muscle of Müller*. Between the circular and meridional portions, the fibres assume a *radial* direction and are separated by considerable connective tissue, which in the deeply pigmented races may contain many branched pigmented cells, but in the white races is free from pigment. Acting from its origin, the ciliary muscle draws forward the ciliary processes and relaxes the lens-capsule.



The *blood-vessels* of the ciliary body, from the anterior and the long ciliary arteries, form a ring around the root of the iris, the *circulus arteriosus iridis major*, from which vessels are sent inwards to supply the iris, ciliary muscle and ciliary processes. The *veins* from the ciliary muscle empty chiefly into the anterior ciliary veins; those from the ciliary processes and a few from the ciliary muscle pass backwards and become tributary to the *venæ vorticosæ*. The *nerves* of the ciliary body form an annular plexus within the ciliary muscle and include sensory and sympathetic fibres, the latter being distributed to the walls of the blood-vessels and to the involuntary muscle.

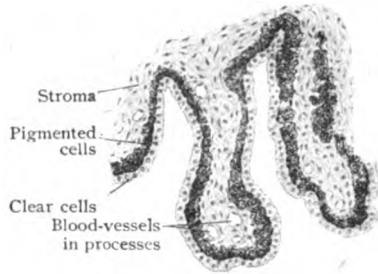


FIG. 393.—Section of ciliary processes, showing layers of ciliary part of nervous tunic.  $\times 80$ .

**The Iris.**—The iris forms the anterior segment of the vascular tunic and is visible through the cornea. Slightly to the inner side of its centre is placed an approximately circular opening, the *pupil*. The periphery of the iris is attached to the ciliary body behind and receives fibres from the pectinate ligament in front. The color of the iris varies in different individuals and gives the “color of the eye.” It is dependent partly upon the amount of pigment within the iris-stroma, and partly upon the density of the pigmentation of the cells on its posterior surface. In light blue eyes, the stroma contains very little pigment and the posterior pigment layer, seen through it, gives a bluish tint; whereas in brown eyes the stroma contains so much pigment that the posterior pigment layer is totally obscured and the iris appears brown.

The **stroma** of the iris encloses numerous thick-walled blood-vessels, radiating from the ciliary border towards the pupil. They are supported by a delicate connective tissue framework, which contains irregularly shaped,

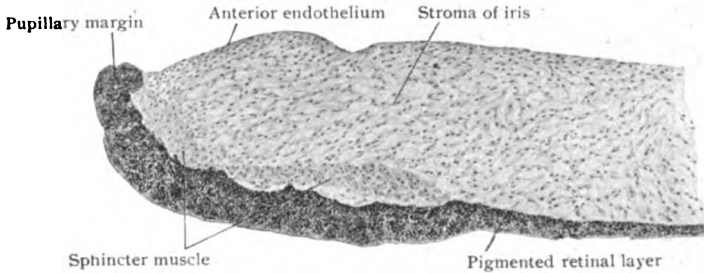


FIG. 394.—Section of pupillary end of iris.  $\times 210$ .

branching pigmented cells, many nerves and lymph-spaces. The anterior surface is covered with a single layer of polygonal *endothelial cells*, continuous with those lining the cornea. Beneath these cells is a condensation of the connective tissue stroma, the *anterior boundary layer*, in which the cells are closely placed. Minute clefts in the tissue form a direct communication between the anterior chamber and the interfascicular lymph-clefts. In very dark irides pigment is found not only within the branched cells, but heaped in irregular masses within the stroma. The **muscular tissue** of the iris includes two distinct masses, the sphincter and dilatator of the pupil.

The *sphincter muscle* is a band of involuntary tissue about .7 mm. in width, surrounding the pupil and situated in the vascular stroma, back of the blood-vessels.

The *dilatator muscle* is a sheet of smooth muscle-fibres in the position formerly described as the posterior limiting lamella, or membrane of Bruch.

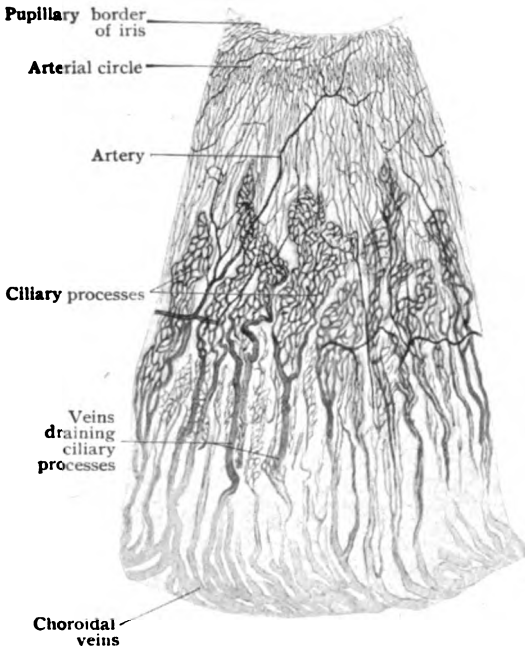


FIG. 395.—Injected ciliary processes and Iris; posterior surface.  $\times 20$ .

Investigations have settled definitely the question of its existence and shown that its fibres arise from the outer cells of the retinal pigment layer, on the posterior surface of the iris. They do not reach quite to the pupillary border.

The posterior surface of the iris is covered by the **pigmented layer**, which morphologically represents the anterior segment of the atrophic nervous tunic (*pars iridica retinae*). This is continuous with the pigmentary layer covering the ciliary processes, but the cells, disposed as a double layer, are so deeply pigmented as to be indistinguishable without bleaching the tissue. Since the dilatator muscle is developed from the fusiform cells of the outer layer it represents an epithelial (ectodermic) muscle. The inner

cells are larger polygonal elements, which gradually lose their pigment as they approach the ciliary processes. Over the latter they contain no pigment, whereas the outer cells remain pigmented.

The *blood-vessels* of the iris pass radially inwards from the *circulus arteriosus iridis major* at the periphery. Near the pupillary border, they form a second ring, the *circulus arteriosus iridis minor*, branches from which supply the sphincter muscle and the pupillary zone. The *venous radicles* unite to form trunks which accompany those from the ciliary processes to empty into the *venae vorticosae*. The *lymphatics* are represented by the interfascicular clefts which communicate with the anterior chamber, with the spaces within the ciliary body, and with the spaces of Fontana. The *nerves* of the iris, branches of the ciliary nerves, follow the course of the blood-vessels and, branching, form a plexus of nonmedullated fibres, which supply chiefly the involuntary muscle, including that of the vessels.

#### THE NERVOUS TUNIC.

**The Retina.**—The retina, the light-perceiving portion of the eye, represents a modified portion of the brain itself, with which it develops in close connection. It is a delicate membrane and extends from the optic

nerve entrance to the pupillary border. The functioning portion, or *pars optica retinae*, reaches as far forwards as an irregular wavy line, the *ora serrata*; anterior to this, the retina is represented by an atrophic portion, consisting of a double layer of cells covering the ciliary body and the iris, respectively the *pars ciliaris* and *pars iridica retinae*. The *pars optica retinae* is closely applied to the inner surface of the choroid and is in contact with the hyaloid membrane investing the vitreous body. It gradually di-

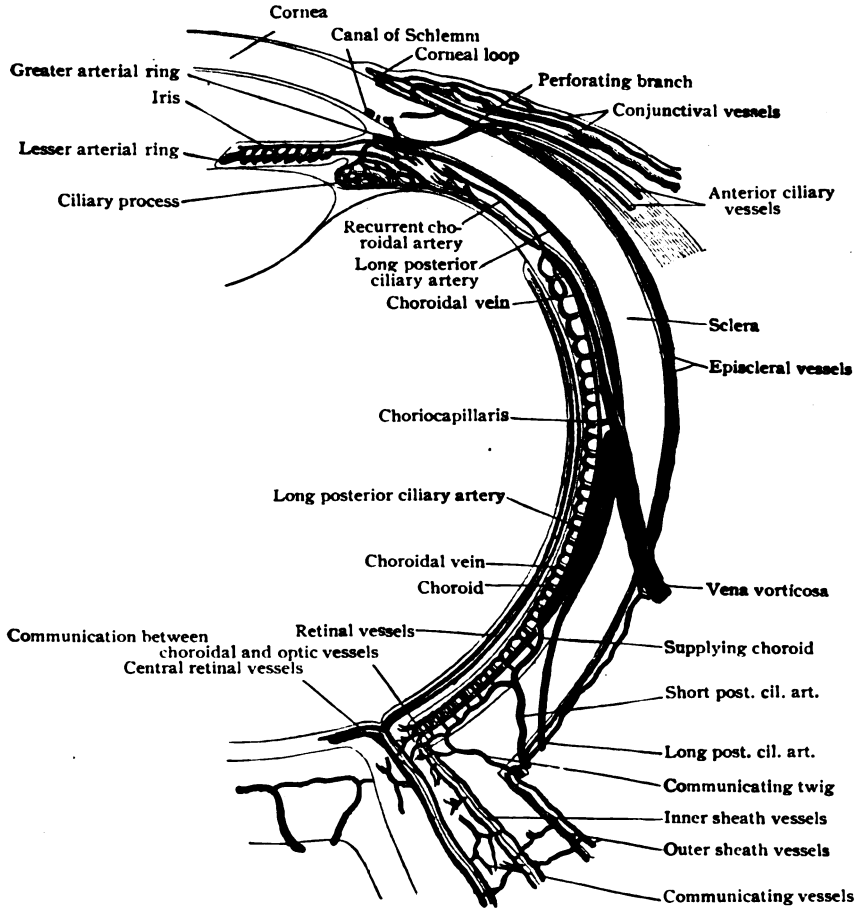


FIG. 396.—Diagram illustrating circulation of eyeball. (Leber.)

minishes in thickness from .4 mm. at the posterior pole to .1 mm. near the ora serrata. At the posterior pole of the eyeball, 3 mm. to the outer side of the optic nerve entrance, the retina exhibits an oval area, the *yellow spot* or *macula lutea*; the centre of the latter is marked by a small depression, the *fovea centralis*, which corresponds to the region of sharpest vision.

The retina is composed of nervous elements which are supported by a specialized sustentacular tissue or neuroglia. Morphologically it must be considered as composed of two lamellæ, which correspond to the outer and inner walls of the optic vesicle, the hollow outgrowth of the brain-sac from

which it is developed. The fundamental divisions of the retina are: (1) the external lamella, the *pigmented layer* on the outer surface; and (2) the internal lamella, which includes the remaining layers of the retina. The inner lamella may be subdivided further into the *neuroepithelial* and the *cerebral* layers. Sections of the retina (Fig. 397) show under the microscope from without inwards the following layers:

I. OUTER LAMELLA OF OPTIC VESICLE	{	I. Pigmented layer	}	Pigmented layer
		2. Layer of rods and cones		
		3. Layer of bodies of visual cells, or outer nuclear layer		} Neuro-epithelial layer
		4. Outer plexiform layer		
II. INNER LAMELLA OF OPTIC VESICLE	{	5. Layer of bipolar cells, or inner nuclear layer		} Cerebral layer
		6. Inner plexiform layer		
		7. Layer of ganglion-cells		
		8. Layer of nerve-fibres		

To these nervous layers must be added two delicate membranes, (1) the *membrana limitans interna*, which bounds the inner surface of the retina, and (2) the *membrana limitans externa*, which lies between the outer nuclear layer and the layer of rods and cones. These membranes represent the terminal portions of the supporting neuroglial fibres, or *fibres of Müller*.

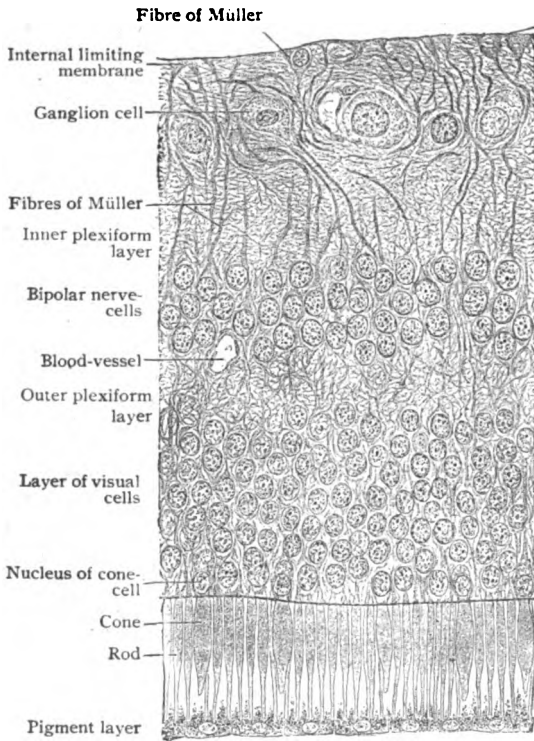


FIG. 397.—Section of human retina, near posterior pole of eyeball. X 230.

The **pigmented layer**, formed of deeply pigmented cells, constitutes the most external layer of the retina and represents the outer wall of the foetal optic vesicle. It is composed of hexagonal cells, from 12–18  $\mu$  in diameter, the protoplasm of which is loaded with fine, needle-shaped crystals of pigment (*fuscin*). The outer portion of the cells is almost free from pigment and contains the nucleus. From the inner border fine protoplasmic processes extend inwards between the rods and cones of the neuroepithelial layer, and under the influence of light the pigment particles

wander into these processes and thus surround the percipient elements.

The **layer of rods and cones**, although usually described as a distinct stratum, is only the highly specialized outer zone of the layer of visual cells

and, therefore, constitutes the outer portion of the neuroepithelial division of the retina. It is composed, as its name indicates, of two elements, the *rods* and the *cones*, which are the outer ends of the rod- and cone-visual cells. They are closely set, with their long axes perpendicular to the surface of the retina. The rods far outnumber the cones, except in the fovea centralis, in which location cones alone are found. In the macula each cone is surrounded by a layer of rods; elsewhere the cones are separated by intervals occupied by three or four cones.

The *rods* of the human retina (Fig. 399, B) have an elongated cylindrical form and measure approximately  $60\ \mu$  in length and  $2\ \mu$  in diameter. Each rod is composed of an *outer* and an *inner segment*, of about equal length. The outer segment possesses a uniform diameter, is doubly refracting, and readily breaks up into minute disks. It is invested with a delicate covering of neurokeratin, contains *myeloid* and is the situation of the *visual purple* that tinges the living retina. The inner rod-segment is somewhat thicker and has an ellipsoidal form. It is singly refracting, homogeneous in structure and from its inner extremity sends the delicate *rod-fibre* through the external limiting membrane into the outer nuclear layer, where the nucleus of the rod-visual cell is found.




FIG. 398.—Pigmented cells from outer layer of retina; surface view.  $\times 350$ .

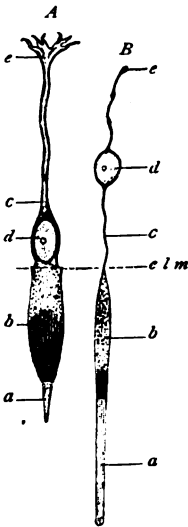


FIG. 399.—Visual cells from human retina; A, cone-cell, B, rod-cell; a, b, outer and inner segments; c, attenuated bodies (fibres), with nucleus (d) and central ends (e); e l m, external limiting membrane. (Greeff.)

The *cone-visual cell* is composed of the same general divisions as the rod-cell, including the specialized outer part, the *cone*, and the body within the external nuclear layer. The cones are shorter than the rods and have a length of  $35\ \mu$ . Each one (Fig. 399, A) is composed of an outer narrow cone-shaped segment, and an inner broader one, which is distinctly ellipsoidal, with a diameter of  $7\ \mu$ . The inner segment is double the length of the outer and continuous, as the *cone-fibre*, with its nucleus in the outer nuclear layer.

The *outer nuclear layer*, the inner portion of the neuroepithelial layer, is about  $60\ \mu$  thick and composed of the bodies of the rod- and cone-visual cells, which show chiefly as the nuclei, the rod- and cone-granules. The *rod-granules* occupy an elliptical enlargement of the attenuated rod-fibres, exhibit a transverse striation and are placed at varying levels within the layer. The rod-fibres are continued as a thin protoplasmic process into the outer reticular layer, where they form small end-knobs which are associated with the outer terminals of the small nerve-cells, the rod-bipolars. The *cone-granules* are less numerous than those of the rods, display no transverse markings, and are found only in the outer portion of the nuclear layer. The cone-fibres, the attenuated bodies of the cone-visual cells, are broader than the corresponding parts of the rods and continued through the outer nuclear layer as far as the outer portion of the external plexiform layer. Here they end with broad bases, from which delicate processes extend inwards to interlace with the terminal arborizations of the cone-bipolars.

The **outer plexiform layer** is a narrow granular looking stratum, between the outer and the inner nuclear layer, and constitutes the first of the cerebral layers of the retina. It is composed of the dendritic arborizations of the bipolar nerve-cells of the succeeding layer, which lie in close relation with the foot-plates of the cone-cells and with the end-knobs of the rod-fibres.

The **inner nuclear layer**, the most complicated of the retinal strata, measures  $35\ \mu$  in thickness, near the optic disk. It contains nervous elements of three main types—the *horizontal cells*, the *bipolar cells*, and the *amacrine cells*.

The *horizontal cells* have flattened cell-bodies and send out dendrites, which terminate in close association with the bases of the rod- and cone-visual cells. Each horizontal cell possesses also an axone, which ends in a richly branched arborization about the visual cells. The function of the horizontal cells is not well understood, but they probably serve as association fibres between the visual cells.

The *bipolar cells*, the ganglion-cells of this layer, are of two chief varieties, the *rod-bipolars* and the *cone-bipolars*. They are oval cells, each sending an axone inwards, which ends in relation with the large nerve-cells of the ganglion-cell layer, and a dendrite outwards, which is associated with the visual cells.

The *amacrine cells* are placed in the inner portion of the nuclear layer. They are nerve-cells, although no distinct axone can be demonstrated. They possess, however, richly branched dendritic processes, which ramify in the inner plexiform layer.

The **inner plexiform layer**,  $40\ \mu$  thick, appears granular, similar to the corresponding outer zone, and is composed of the interlacing axones of the bipolar, amacrine and horizontal cells from the inner nuclear layer and the dendrites of the large ganglion-cells in the subjacent retinal layer. Intermingled with these are the fibres of Müller, which show as conspicuous vertical striæ, with lateral offshoots.

The **layer of ganglion-cells** consists, throughout the greater part of the retina, of a single row of large multipolar neurones, each with a cell-body containing a vesicular nucleus and nucleolus and exhibiting typical Nissl bodies and a fibrillar structure. Their axones pass inwards and become the nerve-fibres of the fibre layer. Converging towards the optic entrance, they become consolidated into the optic nerve and continue to the brain. The dendrites of the ganglion-cells, one to three in number, run outwards into the inner plexiform layer and end as richly branched arborizations in connection with the centrally directed processes from the bipolar cells.

The **nerve-fibre layer** is composed almost entirely, but not exclusively, of the axones of the ganglion-cells of the preceding layer. The individual fibres are collected into bundles of varying size, which take a horizontal course and converge towards the optic disk. Within the retina they are devoid of medullary sheaths, but acquire them after passing through the lamina cribrosa of the sclera. A few of the fibres are *centrifugal*, arising from ganglion-cells within the brain, and terminate apparently in relation with the amacrine of the inner nuclear layer.

The **sustentacular tissue**, the neuroglia of the retina, exists in two forms—as the *fibres of Müller* and the *spider cells*.

The **fibres of Müller** are modified neuroglia-fibres, which pass vertically from the inner surface of the retina through the succeeding layers as far as the bases of the rods and cones (Fig. 400). The inner extremities of the fibres are conical expansions, that by apposition form an incomplete

sheet, the *membrana limitans interna*. As the fibres traverse the retinal layers, they give off delicate lateral offshoots, which break up into a fine supporting reticulum. Within the inner nuclear layer each fibre presents a broad expansion containing the oval nucleus of the sustentacular cell. After

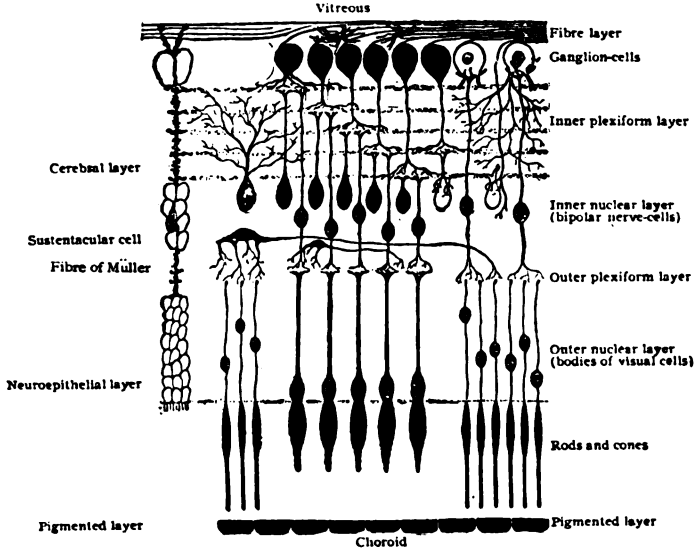


FIG. 400.—Diagram illustrating structure of retina and relations of three fundamental layers. (Greiff.)

traversing the outer nuclear layer their broadened peripheral ends come into contact and form a continuous sheet, the *membrana limitans externa*. From the latter delicate offshoots continue outwards and embrace the bases of the individual rods and cones. In addition to the robust fibres of Müller, neuroglia cells, in the form of *spider cells*, are found in the nerve-fibre and ganglion-cell layers.

**The Macula Lutea.**—The structure of the retina undergoes important modifications in two areas, at the macula lutea and at the ora serrata. In the

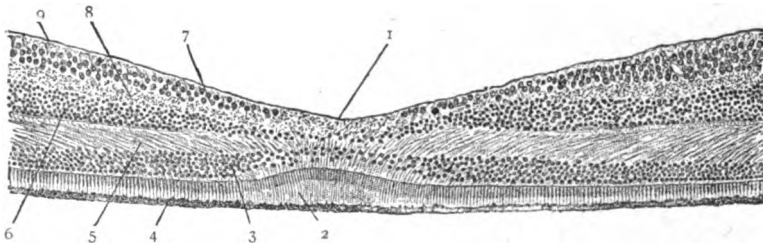


FIG. 401.—Section of human retina through the fovea centralis. 1. fovea; 2, 3. cones and nuclei of visual cells; 4. pigmented layer; 5. outer plexiform layer; 6. bipolar cells; 7. ganglion-cells; 8. inner plexiform layer; 9. internal limiting membrane.  $\times 80$ .

former the ganglion-cells increase rapidly in number as the macula is reached, so that instead of forming a single layer they are distributed in from eight to ten strata. The inner nuclear layer is also increased in thickness. Within the **fovea centralis**, however, in order to reduce to a minimum the layers traversed by the light-rays, the cerebral layers are almost entirely displaced,

only the absolutely essential retinal strata—the pigment cells and the visual cells with their necessary connections—being retained within the area of sharpest vision (Fig. 401). On approaching the fovea, the ganglion-cells rapidly decrease in number, until, at the centre of the depression, they and the nerve-fibre layer are entirely absent. The bipolar cells are present as an irregular layer within the fused remains of the two plexiform layers. The most conspicuous elements are the visual cells, in this position represented solely by the cones, that have about twice their usual length and thickness, the increase in length being contributed by the outer segments. The cone-cell nuclei become removed from the external limiting membrane; the cone-fibres are therefore lengthened, pursue a radial direction, and constitute the so-called *fibre-layer of Henle*. Opposite the centre of the fovea, the choroid is thickened by an increase in the choriocapillaris. The yellow color of the macula is due to a diffuse coloration of the inner retinal layers.

**The Ora Serrata.**—The visual part of the retina ends anteriorly in an irregular line, the ora serrata. The retina diminishes in thickness in consequence of the abrupt disappearance of its nervous elements. The rods disappear first; then the cones become rudimentary, and finally cease; the ganglion-cells, nerve-fibre layer and inner plexiform layer fuse, and the two nuclear layers unite and lose their characteristics, most of the nuclei present being those of the supporting fibres of Müller, which are here highly developed. These elements continue beyond the ora serrata (Fig. 402) as the transparent cylindrical cells composing the inner layer of the *pars ciliaris*

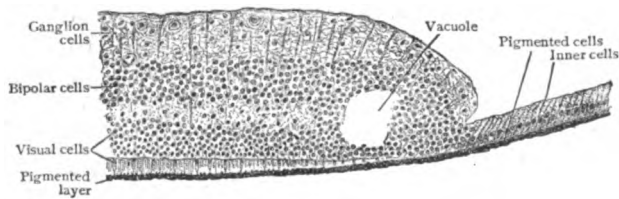


FIG. 402.—Section of human retina (through ora serrata, showing transition of pars optica into pars ciliaris.  $\times 165$ .

*retinae*, the densely pigmented cells of the outer layer being a direct continuation of the retinal pigmented cells. These two strata of cells are prolonged over the ciliary body and the iris as far as the pupil, over the iris constituting the *pars iridica retinae*. As the columnar cells pass forwards, they gradually decrease in height, and at the junction of the ciliary body and the iris the cells of both layers become deeply pigmented.

The **blood-vessels** of the retina are derived from the central artery, which enters the optic nerve behind the eyeball, and, with its accompanying vein, runs in the axis of the nerve until it emerges slightly to the nasal side of the centre of the optic disk. Here the artery divides into two short superior and inferior branches, each of which subdivides into nasal and temporal branches which give off *end-arteries*, no anastomosis existing. The macular region is supplied by special twigs, the centre of the fovea, however, being free from blood-vessels. The larger branches course within the nerve-fibre layer, and send fine twigs to form an *inner* and an *outer plexus*, the former on the outer surface of the inner plexiform layer, and the latter within the inner nuclear layer. Beyond the outer plexiform layer the vessels do not penetrate, the visual cells being dependent for their nourishment upon the choriocapillaris of the choroid. The **lymphatics** of the retina are repre-



sented chiefly by the perivascular lymph-spaces which surround the blood-vessels. These spaces may be injected from the subpial lymph-space of the optic nerve, and by the same method communications may be demonstrated between (1) this space and the interstices between the nerve-bundles which converge towards the optic papilla, (2) a space between the membrana limitans interna and the hyaloid membrane of the vitreous, and (3) a narrow cleft between the pigmented cells and the layer of rods and cones.

**The Optic Nerve.**—The optic nerve is surrounded by the three sheaths—the dural, the arachnoidal, and the pial—which, with the subdural and the subarachnoidal lymph-spaces, are continued over the nerve as prolongations of the corresponding brain-membranes. On reaching the eyeball, the dural sheath bends directly outwards, its fibres commingling with those of the outer third of the sclera (Fig. 403); the arachnoid ends abruptly on

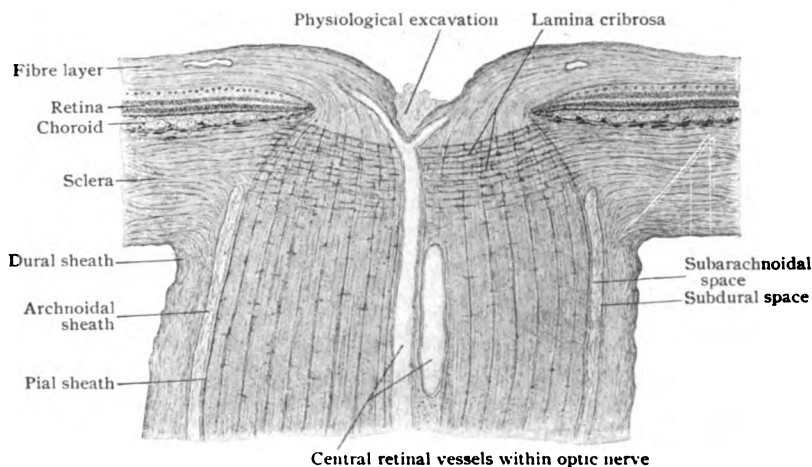


FIG. 403.—Section of eyeball through entrance of optic nerve.  $\times 20$ .

the inner wall of the intervaginal space; whilst the pia arches outwards to form part of the inner third of the sclera, sending longitudinal fibres as far as the choroid. As the nerve-fibres enter the eyeball, for convenience assuming that they are passing from the brain towards the retina, they traverse a fenestrated membrane, the **lamina cribrosa**, which is formed by interlacing bundles from the inner third of the sclera and from the pial sheath. As the nerve-fibres penetrate the lamina cribrosa they lose their medullary sheaths and, in consequence, the optic nerve is reduced one third in diameter. The nerve projects slightly into the eyeball on account of the thickness of the layer of arching nerve-fibres and forms, therefore, a circular elevation, known as the **optic papilla**, about 1.5 mm. in diameter, the centre of which is modelled by a funnel-shaped depression, the so-called *physiological excavation*. The axis of the nerve is occupied by the central artery of the retina, which gives off minute branches for the nutrition of the nerve, that anastomose with the pial vessels, and, through the circulus arteriosus Zinni, with branches of the posterior ciliary arteries. In transverse sections (Fig. 404), the optic nerve appears as a mosaic of irregular polygonal areas composed of bundles of medullated nerve-fibres surrounded by connective tissue envelopes. Although provided with medullary sheaths, the optic fibres are devoid of a neurilemma, in this respect agreeing

with the nerve-fibres composing the central nervous system. The entire nerve corresponds to a huge funiculus, the perineurium being represented

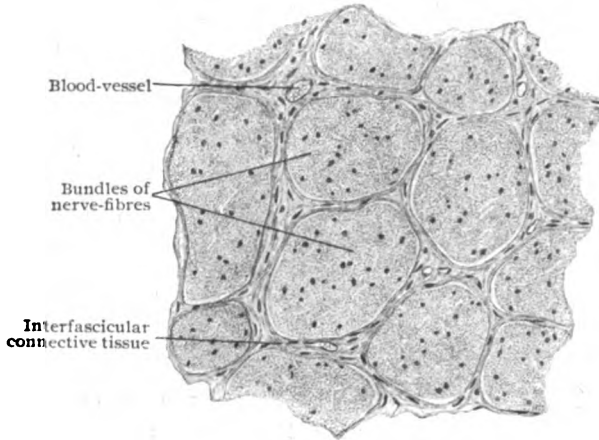


FIG. 404.—Transverse section of part of optic nerve, showing bundles of nerve-fibres.  $\times 125$ .

by the pial sheath, and the endoneurium by the interfascicular septa of connective tissue prolonged from the pia between the bundles of fibres. Numerous connective tissue cells occur along the strands of fibrous tissue.

#### THE CRYSTALLINE LENS.

The lens, the most important part of the refractive apparatus of the eye, is a biconvex body suspended from the ciliary body by the *suspensory ligament* or *zonule of Zinn*. Its anterior surface supports the pupillary margin of the iris, its posterior surface resting in a depression, the *patellar fossa*, on the anterior surface of the vitreous body. It is completely transparent and

enclosed in a transparent elastic membrane, the *lens capsule*. Together with the capsule, the lens measures from 9–10 mm. in its transverse diameter, and about 4 mm. in thickness from pole to pole.

The **capsule**, which entirely surrounds the lens, is a transparent, structureless, highly elastic membrane, which, while resistant to chemical reagents, cuts easily and then rolls outwards. It is thickest on the anterior surface, where it measures from 10–15  $\mu$ , and thinnest at the posterior pole (5–7  $\mu$ ). In the adult the lens is devoid of blood-vessels, but during a part of foetal

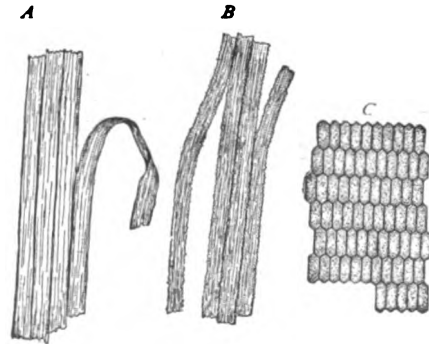


FIG. 405.—Fibres of crystalline lens; A, B, fragments of isolated fibres; C, fibres in cross-section.  $\times 275$ .

life it is surrounded by a vascular network, the *tunica vasculosa lentis*, which is supplied chiefly by the hyaloid artery. This temporary vessel is the terminal branch of the central artery of the retina and passes from the optic disk forwards through the *hyaloid canal* or *canal of Cloquet* in the vitreous to the surface of the lens (Fig. 383). The vascular lens-tunic and the hyaloid

artery are temporary structures and usually disappear before birth. Exceptionally they may persist, the tunic being represented by the pupillary membrane and the artery by a fibrous strand within the vitreous, stretching from the optic disk towards the lens.

The anterior portion of the capsule is lined by a single layer of flat polygonal cells, the *epithelium of the lens capsule*, which represents morphologically the anterior wall of the original lens-vesicle. On approaching the equator of the lens, these cells become elongated and gradually converted into the young lens-fibres, whose nuclei lie in the superficial part of the lens.

The **lens-substance** is composed of long flattened fibres, in cross-sections of compressed hexagonal outline,  $5-11 \mu$  broad and  $2-4 \mu$  thick, held together by an interfibrillar cement-substance. These fibres are modified epithelial elements, which develop by the elongation of the original ectodermic cells of the posterior layer of the primary lens-vesicle. The subsequent growth of the lens depends upon a similar modification of the anterior capsule-cells, the region where this transformation

occurs being known as the *transitional zone*. The individual lens-fibres vary greatly in length, those forming the outer layers being longer and thicker than those which constitute the centre of the lens. The edges of the fibres are finely serrated, and, as the points of the serrations of adjacent fibres are in contact, fine intercellular channels are left for the passage of nutritive fluid.

#### THE VITREOUS BODY.

The vitreous body fills the space between the lens and the retina, being in close contact with the retina and acting as a support to it as far forwards as the ora serrata. Here it separates from the retina and passes to the posterior surface of the lens, presenting a shallow depression, the *hyaloid* or *patellar fossa*, on its anterior surface for the reception of the lens. The fresh vitreous is semifluid, perfectly transparent and consists of about 98.5 per cent. of water.

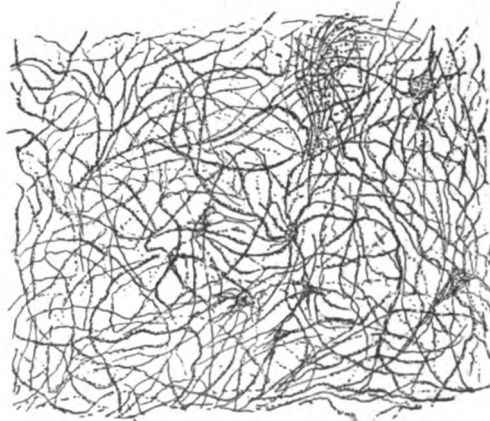


FIG. 407.—Portion of vitreous body, showing feltwork of fibres and remains of cells  $\times 450$ . (Retzius.)

The surface of the vitreous is enclosed by a delicate boundary layer, called the **hyaloid membrane**, formed by condensations of the fibrils, arranged parallel to the surface and

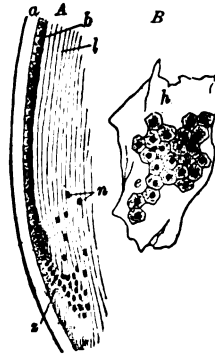

FIG. 406.—Portion of lens and its capsule; A, section through equator; a, capsule; b, epithelial cells, which at x transform into lens-fibres (l) with nuclei ( $\mu$ ); B, fragment of capsule (h) with epithelium (e), surface view.  $\times 130$ .

closely felted. It is, however, not a true membrane, but only a condensation of the vitreous fibres. The vitreous is attached firmly to the retina at the nerve-entrance and at the ora serrata, between these points the hyaloid being indistinct. As the vitreous leaves the retina, the boundary layer becomes thicker, in some cases to become thin again or absent in the region of the patellar fossa. The adult vitreous ordinarily contains no cells, but some small round ones are occasionally seen near the surface, beneath or on the hyaloid membrane. They are amœboid, often contain vacuoles and are modified leucocytes. In addition a few branched connective tissue cells may be present, as the remains of the mesodermic elements gaining entrance along with the blood-vessels during foetal life. The central part of the vitreous is occupied by a channel, the **hyaloid canal**, also known as the *canal of Stilling* or the *canal of Cloquet*, which is about 1 mm. wide and extends from the optic entrance towards the posterior pole of the lens. During foetal life this canal lodges the *arteria hyaloidea*, the continuation of the central artery of the retina.

#### THE SUSPENSORY APPARATUS OF THE LENS.

The lens is held in position by a series of delicate bands, which pass from the vicinity of the ora serrata over the ciliary processes to be attached to the periphery of the lens. These fibres collectively constitute the **sus-**

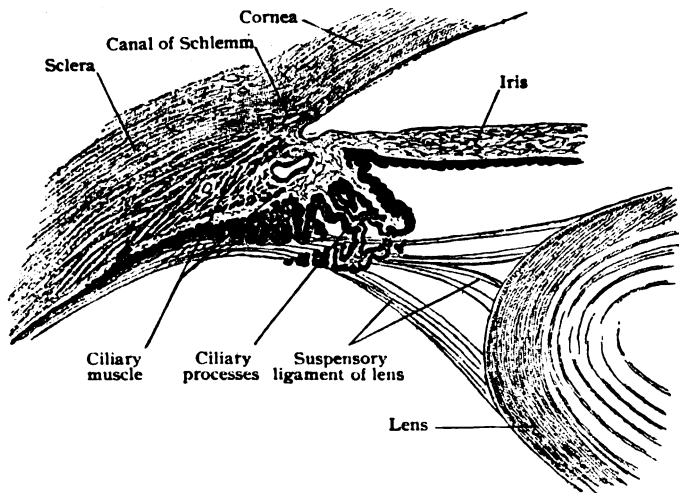


FIG. 408.—Meridional section of ciliary region, showing ciliary processes and suspensory ligament of lens.  $\times 20$ .

**suspensory ligament**, or *zonule of Zinn*, a structure of importance not only for the support of the lens, but also in assisting the ciliary muscle in effecting the changes in the curvature of the lens incident to accommodation. The zonule is not, as formerly believed, a continuous membrane, but is composed of a complicated system of fibres. The latter, varying in thickness from  $5-22\mu$ , arise chiefly from the cuticular membrane covering the pars ciliaris retinae in the vicinity of the ora serrata. Some fibres arise also from the membrana limitans interna of the retina, whilst others end within the vitreous body. The greater number of the fibres pass forwards in the depressions between and along the sides of the ciliary processes; they then proceed in-

wards across the circumlental space to be attached to the capsule of the lens. Some of the fibres are inserted anterior to the equator, others posterior to the equator, and some directly into the lens margin. Those inserted anteriorly arise behind and chiefly from the valleys between the ciliary processes, whilst those inserted back of the equator come from the ciliary processes in front. As they diverge to gain their insertion in the lens-capsule, the crossing fibres enclose an annular space, triangular in section, whose base is directed towards the lens equator. The fibres are so closely interlaced that it is possible to inject air between them and so produce a beaded ring surrounding the lens. This appearance was long interpreted as demonstrating the presence of a delicate channel, the *canal of Petit*, encircling the lens. The existence of a definite channel, however, is no longer accepted, the space capable of inflation being part of the larger circumlental space, which is filled with fluid and communicates, by means of fine clefts, with the posterior chamber.

#### THE AQUEOUS HUMOR AND ITS CHAMBER.

The aqueous humor is the transparent fluid which fills the space between the anterior surface of the vitreous body and the posterior surface of the cornea. In chemical composition it closely resembles water, containing only traces of albumin and extractives, and differing from lymph in its low percentage of albumin. It is derived chiefly from the blood-vessels of the ciliary processes by the action of the double layer of cells covering the *pars ciliaris retinæ*. The aqueous humor, constantly produced, is carried off through the spaces of Fontana into the canal of Schlemm, and also through the lymph-spaces in the iris. With the exception of a few migratory leucocytes, the aqueous humor is devoid of morphological elements.

The space occupied by the aqueous humor is incompletely subdivided by the iris into two compartments, the anterior and posterior chambers of the eye. The **anterior chamber** is bounded in front by the cornea and behind by the iris and lens, and has a depth at its centre of from 7.5–8.5 mm. The **posterior chamber** is the small annular space, triangular in cross-section, which has for its anterior boundary the iris, is limited laterally by the ciliary processes, and medially and posteriorly by the lens and the vitreous body. The spaces between the fibres of the suspensory ligament communicate with the posterior chamber, are filled with aqueous humor, and are, therefore, only a part of the posterior chamber.

#### THE EYELIDS AND CONJUNCTIVA.

The eyelids or *palpebræ* are two movable folds of integument—an upper and a lower—strengthened along their free margins by a lamina of dense fibrous tissue, the *tarsal plate*, and modified on their deeper aspect so that this surface resembles a mucous membrane, the *conjunctiva*. The free border of the lid presents a well-defined posterior margin, along which open the minute ducts of the *tarsal glands*, whilst the anterior margin is rounded and passes insensibly into the adjoining external skin-surface and is beset with the eyelashes. The latter, the *cilia*, are stiff outwardly curving hairs, which number from 100–150 in the upper lid and about half as many in the lower. That part of the narrow conjunctival sac which covers the posterior surface of the lids constitutes the *palpebral conjunctiva* and that reflected onto the eyeball is the *bulbar conjunctiva*, while the bottom of the groove, where these two portions are continuous, is known as the *fornix conjunctivæ*. The *lacrimal lake* is the shallow bay into which the conjunctival sac is pro-

longed for about 5 mm. between the medial ends of the eyelids. It contains an irregularly oval or comet-shaped elevation, the *lachrymal caruncle*. The latter consists of an islet of modified skin from which project usually about a dozen minute and scarcely visible hairs, provided with large sebaceous and smaller sweat-glands and embedded in a cushion of fatty tissue. Just to the outer side of the caruncle, lies a vertical crescentic fold, the *plica semilunaris*, which frequently contains a minute plate of hyaline cartilage as the vestige of the stronger bar in the nictitating membrane, which the fold represents. Likewise the small group of alveoli sometimes found within the base of the fold is regarded as the homologue of the Harderian gland. Where the boundaries of the lachrymal lake pass into the edges of the eyelids are little elevations, the *lachrymal papillæ*, each of which is pierced by a minute aperture, the *punctum lacrimale*, that marks the beginning of the canals by which the tears are normally carried off from the conjunctival sac.

**The Eyelids.**—The eyelid comprises five layers which, from without inwards, are: (1) the *skin*, (2) the *subcutaneous tissue*, (3) the *muscular layer*, (4) the *tarso-fascial layer*, and (5) the *conjunctiva*.

The **skin** covering the outer surface of the eyelids is characterized by its unusual delicacy, being thin and beset with very fine downy and widely scattered hairs, provided with sebaceous follicles; small sweat-glands also occur.

The **subcutaneous tissue** is distinguished by the entire absence of fat, its loose texture and great extensibility and elasticity. In consequence of these properties, it sometimes becomes the seat of extensive swelling after edema or hemorrhage.

The **muscular layer**, for the most part the annular bundles of the orbicularis palpebrarum, is so blended with the subcutaneous tissue as to be practically embedded within the latter. In vertical sections of the eyelid, (Fig. 409) the circularly arranged muscular bundles show as transversely cut groups of muscle-fibres enclosed by condensations of the surrounding areolar tissue. A distinct annular tract, the *ciliary bundle* or *muscle of Riolan*, lies close to the free border of the lid, chiefly between the tarsal plate and the hair-follicles, in part often also between the conjunctiva and the tarsus. In the upper lid, in addition to the circular bundles of the orbicularis palpebrarum, the terminal strands of the longitudinal fibres from the levator palpebræ superioris descend along the deeper surface of the first-named muscle. Some of these penetrate between the circular bundles and end in the deeper layer of the skin; others descend more vertically to find their insertion in the upper border of the tarsal plate. Under the name *tarsal muscles* or *muscles of Müller*, are described the uncertain bundles of involuntary muscle found in the vicinity of the convex borders of the tarsi. Those within the upper lid arise from the tendon and intermingle with the fibres of the levator palpebrarum and insert either into the upper border of the tarsal plate or into the adjacent fibrous tissue. In the lower lid, they are less numerous and regular, and extend from the fornix conjunctivæ to the adjacent border of the tarsus.

The **tarso-fascial layer** is represented next the margins of the lids by the tarsal plates and beyond the latter by a dense fascial sheet.

The **tarsal plates** are two crescentic lamellæ of dense fibrous tissue, one in each lid, that occupy the margins of the eyelids, to the maintenance of whose form they largely contribute. The upper tarsus is the larger. The plates are approximately 1 mm. in thickness and consist of densely felted fibrous tissue. They are blended in front and below with the subcutaneous tissue, above with the orbital fascia and the insertion of the lid-muscles,

and behind with the conjunctiva. The tarsal plates lodge the linear series of the **Meibomian** or **tarsal glands**. These structures, between thirty and forty in number in the upper lid and about one third less in the lower one, consist of a chief tubular duct, placed vertically and lined by stratified squamous epithelium, which is beset with numerous simple or branched, irregular, flask-shaped alveoli. The latter contain cuboidal epithelial elements that resemble in appearance and condition those found in sebaceous follicles, to which class, in fact, the tarsal glands belong. They secrete an

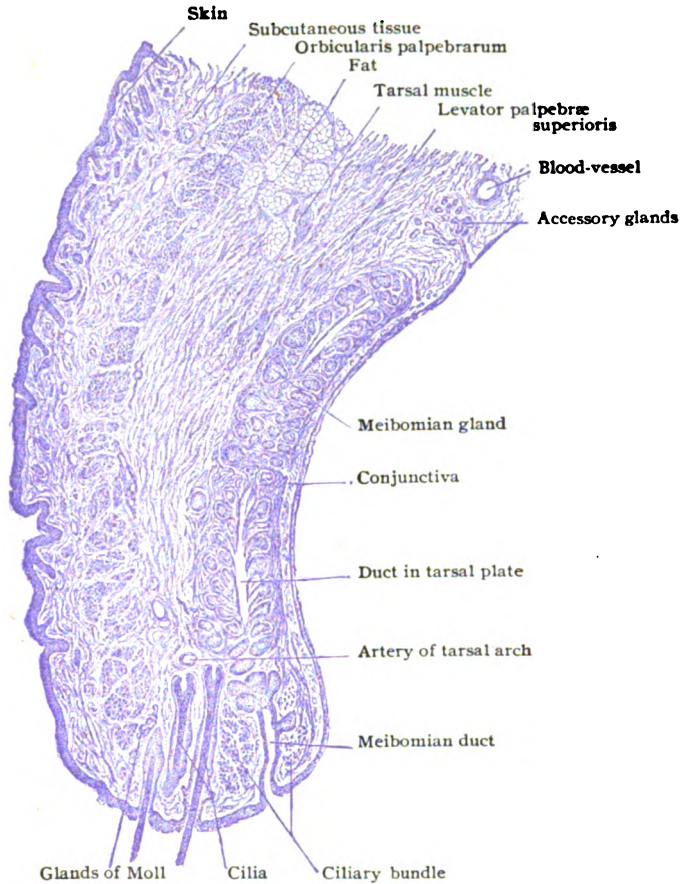


FIG. 409.—Sagittal section of upper eyelid of child.  $\times 15$ .

oily substance, *sebum palpebrarum*, which is discharged through the minute punctiform orifices of the ducts seen as a row of dark points just external to the sharp conjunctival border of the eyelid. In this manner the latter is kept lubricated, and thus, under usual conditions, maintains an effective barrier against the overflow of the tears from the conjunctival sac. Within the free edge of the eyelids, just in advance of the tarsal plates, lie the **glands of Moll** and the **glands of Zeis**. The former are coiled tubules, resembling modified sweat-glands, the latter sebaceous glands, the ducts of which usually open close to or into the mouths of the follicles of the eye-lashes.

The **palpebral conjunctiva** lines the ocular surface of the eyelids. Since the latter are developed as integumentary folds, at first the conjunctiva resembles the skin, but after the temporary closure of the lids, from the middle of the third month until shortly before birth, it loses its original character, and later, bathed continuously with the secretion of the tear-gland, assumes the general appearance of a mucous membrane. Over the tarsi the palpebral conjunctiva is so tightly adherent to the underlying fibrous plate, that the tunica propria is reduced to an insignificant layer and the Meibomian glands shimmer through the smooth translucent conjunctiva and appear as parallel stripes. On gaining the convex border of the tarsal plates, the conjunctiva becomes loose and movable since the tunica propria, which here connects the epithelium with the underlying fascial tissue, is plentiful. The small tubules, *glands of Henle*, occupy the subepithelial tissue of this part of the conjunctiva. In the fornix and its vicinity minute *lymph-nodules* occur, either discrete or in small groups. In the same locality and at the convex borders of the tarsi, small nests of tubular alveoli, known as *accessory tear-glands*, or *glands of Krause*, are found. They are much more numerous in the upper than in the lower lid.

The **bulbar conjunctiva** passes from the fornix onto the anterior part of the eyeball, over which it extends as far as the corneal margin, at which point (*limbus corneæ*) the tunica propria ends and the epithelium alone continues uninterruptedly over the cornea. During its passage from the free edge of the eyelid to the cornea, the character of the *conjunctival epithelium* varies in different parts of the sac. Thus, at the border of the lids and for a few millimeters over the tarsi, it resembles the epidermis in being stratified squamous. Towards the convex border of the tarsal plates the squamous type gives place to the cylindrical; in the retrotarsal fossa, throughout the fornix and for a short distance over the eyeball, the epithelium is exclusively columnar, varying in thickness and in the number of its layers; while over the cornea and adjacent parts of the sclera, the epithelium is again stratified squamous.

The **blood-vessels** form an arch in each lid along the base of each tarsus, between the latter and the orbicularis muscle, from which perforating twigs penetrate the tarsal plates for the supply of the Meibomian glands and adjacent conjunctiva. The *lymphatics* are arranged in two sets, a pretarsal and a post-tarsal, the networks of which are connected by vessels which pierce the tarsi. The former receives lymph from the skin and muscles, the latter from the Meibomian glands and the conjunctiva. The **nerves** supplying the eyelid include sensory, motor and sympathetic fibres. The main branches lie between the tarsi and the orbicularis muscle, sending branches forwards to the skin and backwards through the tarsi to the Meibomian glands and the conjunctiva. Those to the conjunctiva lose their medullary coat and terminate either in free arborizations, beneath or among the epithelial cells, or in the end-bulbs. The latter are particularly numerous along the lid-margin, but occur also in the palpebral and bulbar conjunctiva and at the corneal border. The sympathetic fibres supply the tarsal and other lid-glands and send filaments to the walls of the blood-vessels.

### THE LACHRYMAL APPARATUS.

The lachrymal apparatus consists of the gland secreting the tears, situated in the anterior and outer portion of the orbital cavity, and the system of canals by which the tears are conveyed from the mesial portion of the conjunctival sac to the inferior nasal meatus.



The **lacrimal gland** resembles in shape and size a small almond and consists of two fairly distinct parts, the superior *orbital portion* and the inferior *palpebral* or *accessory portion*. The former occupies the fossa lacrimalis in the frontal bone and is the larger portion, measuring 20 mm. in

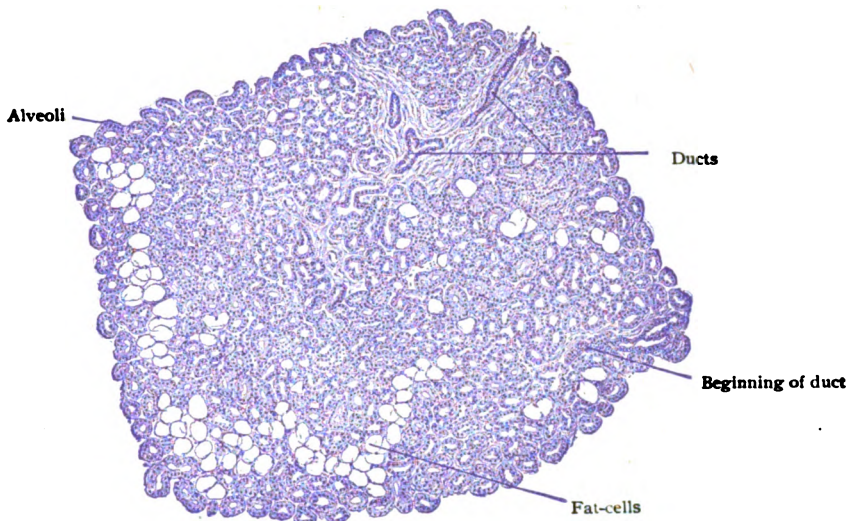


FIG. 410.—Section of lacrimal gland, showing general arrangement of alveoli.  $\times 20$ .

length and 12 mm. in breadth. The lower portion of the gland, *glandula lacrimalis inferior*, is smaller than the upper and separated from the latter by a fascial expansion.

The ducts from both portions of the gland are exceedingly fine, those from the upper portion, from three to six in number, passing downwards through the inferior portion. Some of the ducts from the lower gland join those coming from above, while others run independently. They are lined with a double layer of columnar epithelial cells. In all about a dozen ducts open into the conjunctival sac along a line just in front of the fornix. In structure the glands correspond to the tubo-alveolar type and resemble the serous glands in their general character. The tubular alveoli contain cells of two kinds—columnar elements in which the stored secretion particles occupy the inner half of the cells, and low elements whose cytoplasm may be almost completely filled with secretory products. The alveoli of the lower portion are separated by robust septa of connective tissue, which contain considerable lymphoid tissue.

*Accessory lacrimal glands* are found in both the upper and lower fornices, from eight to thirty being present in the upper lid and from two to four in the lower. They are very small and situated chiefly near the outer angle of the palpebral fissure.

The **lacrimal passages** begin by minute openings, the *lacrimal puncta*, which are usually placed at the summit of the conical *lacrimal papilla*. The puncta lead into the *lacrimal canaliculi*, which at first are vertically directed, then bend abruptly, take a nearly horizontal course, and empty into the lacrimal sac. Each canaliculus is from 8–10 mm. in length. Its lumen measures only .1 mm. in diameter at the punctum, presents a diverticulum of 1 mm. at the bend, and continues with an

approximately uniform calibre of .5 mm. in its horizontal portion. The canaliculus possesses a lining of stratified squamous epithelium, which rests upon a delicate tunica propria rich in elastic fibres, muscular fibres from the orbicularis palpebrarum affording additional support. The muscle-bundles run parallel to the horizontal portion of the canaliculus, but are arranged as a circular sphincter about the vertical portion.

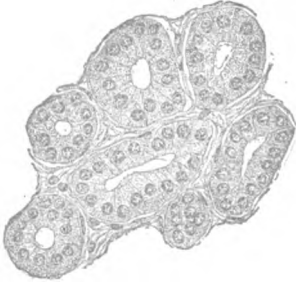

FIG. 411.—Alveoli of lacrimal gland more highly magnified.  $\times 235$ .

The **lacrimal sac** may be regarded as the upper dilated portion of the naso-lacrimal duct, the lower part of which passes through a bony canal and opens into the inferior nasal meatus. The sac is about 15 mm. long, and 6 mm. in diameter when distended. The wall of the sac is composed of a fibro-elastic tunica propria of lymphoid character and is loosely connected with the periosteum by a stratum rich in veins. A few small branched tubular glands are usually present. It is lined with a double layer of columnar epithelial cells, which in part are provided with cilia.

The **naso-lacrimal duct**, the lower portion of the tear-passage, varies from 12–24 mm. in length, and is from 3–4 mm. in diameter. The mucous membrane lining the duct is clothed with columnar epithelium and may contain small glands in the lower portion. It is separated from the periosteum by areolar tissue and a venous plexus.

## THE EAR.

The auditory organ is conventionally described as the external, middle and internal ear—structures lodged entirely or in part within the temporal bone. The *external ear* includes the auricle and the external auditory canal; the *middle ear* the tympanum, the Eustachian tube and the mastoid cells; and the *internal ear* the labyrinth, with the peripheral ramifications of the auditory nerve. Such division, moreover, is justified by the developmental history of the organ, since the internal ear is developed essentially from the highly differentiated otic vesicle which gives rise to the complicated membranous labyrinth; the middle ear largely from the first pharyngeal pouch; whilst the external ear represents the deepened and modified boundaries of the first external visceral furrow.

### THE EXTERNAL EAR.

The external ear, the outermost subdivision of the auditory organ, includes (1) the *auricle*, the funnel-shaped appendage attached to the side of the head for the collection of the sound-waves, and (2) the *external auditory canal*, which conveys these stimuli to the tympanic membrane, the flexible partition closing the canal and separating it from the middle portion of the ear.

**The Auricle.**—The outwardly directed external surface of the auricle is irregularly concave and presents several well-marked depressions and elevations, which depend, for the most part, upon the corresponding modelling of the underlying cartilage.

The auricle consists of integument and an enclosed plate of yellow elastic cartilage, continuous with that of the meatus. It is also provided with several unimportant ligaments and muscles. The lobule, however, contains no cartilage, but only fibrous tissue and fat enclosed within the integumentary fold. The skin of the auricle is thin and closely adherent to the cartilage, especially on the outer surface. In certain parts it contains fine hairs and sebaceous and sweat-glands. The hair-follicles are especially abundant over the tragus, antitragus and the notch lying between them, the hairs guarding

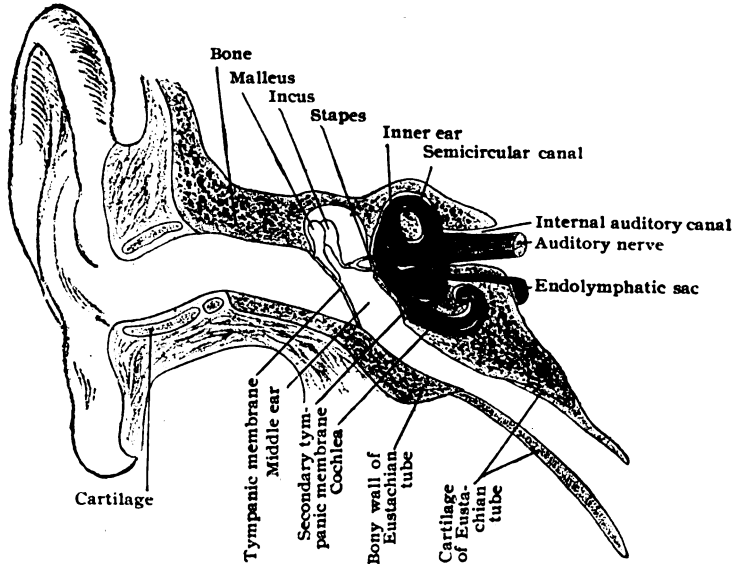


FIG. 412.—Diagram showing three subdivisions of ear; *m*, utricle; *s*, saccule; blue is the bony, red the membranous labyrinth of the internal ear. (Modified from Schwälbe.)

the entrance into the external auditory canal, known as **tragi**, being exceptionally long. The sebaceous glands are especially well developed in the cavity of the concha.

**The External Auditory Canal.**—The external auditory canal, or *meatus acusticus*, leads from the cavity of the concha to the tympanic membrane, which closes its inner extremity. It is composed of an outer cartilago-membranous (cartilaginous) and an inner bony portion, both of which, as well as the external surface of the tympanic membrane, are lined by skin. The cartilago-membranous part contributes something more than one third of the entire length of the canal, and is a continuation of the cartilage of the auricle. The cartilage of the canal, histologically of the elastic type, does not form a complete tube, but is deficient at its upper back part, where it is filled in by fibrous tissue. On approaching the bony portion, this deficiency in the cartilage is more marked and the fibrous tissue correspondingly increased.

The **skin** lining the outer portion of the canal is closely attached to the underlying cartilage and measures about 1.5 mm. in thickness. It is much thinner within the bony canal, except along the roof, where it remains relatively thick. Over the outer surface of the tympanic membrane, the skin is reduced to a very delicate and smooth investment, covered by correspondingly attenuated epidermis, and a very thin layer of subcutaneous tissue.

Numerous fine hairs and large *sebaceous glands* occur in the cartilaginous portion, but diminish in size and frequency towards the bony canal, in which they are entirely wanting. Within the cartilaginous meatus and along the roof of the bony tube, the skin is closely beset with the large coiled **ceruminous glands**, which resemble in structure modified sweat-glands. Like the latter, the ceruminous glands consist of a deeper and wider coiled portion, the *secretory segment*, and a long narrow *excretory duct*, which ends in most cases independently on the free surface of the skin.

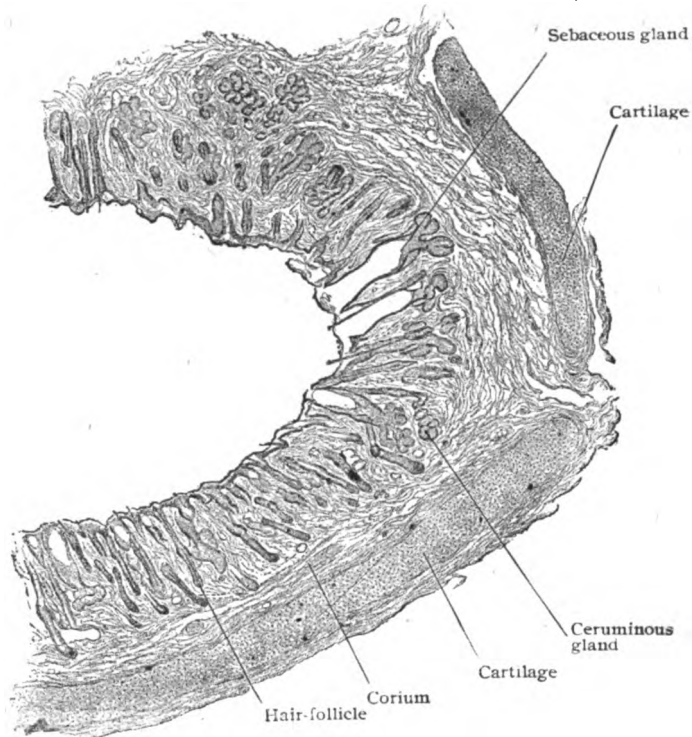


FIG. 413.—Section of skin lining cartilaginous part of external auditory canal.  $\times 30$ .

Sometimes, particularly in the very young child, it may open into the duct of a sebaceous gland. The cuboidal secreting cells contain yellowish brown pigment particles and granules resembling fat. The **ear-wax** or **cerumen** is, as usually found, the more or less dried mixture of the secretions derived from both varieties of glands, together with discarded squamous epidermal cells.

The **blood-vessels** distributed to the interior of the external auditory canal pierce the membranous roof of the cartilaginous meatus and the associated fibrous tissue and form capillary networks within the perichondrium and periosteum and, within the skin, around the glands and the hair follicles. The deeper *veins* of the meatus drain the bony and a small part of the cartilaginous meatus. The **lymphatics** of the external auditory canal arise from a cutaneous network, from which trunks pass in three general groups, as do those of the auricle. The **nerves** supplied to the external auditory canal,

derived from the auriculo-temporal branch of the trigeminus and from the auricular branch of the pneumogastric, are chiefly medullated and sensory. Sympathetic fibres end in connection with the glands.

## THE MIDDLE EAR.

The middle ear includes three subdivisions: the *tympanic cavity*, the *Eustachian tube*, and the *mastoid cells*.

It is an irregular air-chamber, beginning on the lateral wall of the nasopharynx with the Eustachian tube, which leads upwards, backwards and outwards, for about one inch and a half into the temporal bone. Opposite the external auditory canal, it widens into the tympanic cavity and continues backwards into the mastoid cells.

**The Tympanic Cavity.**—The tympanic cavity, also called the *tympanum*, is an irregular space within the temporal bone, lying between the

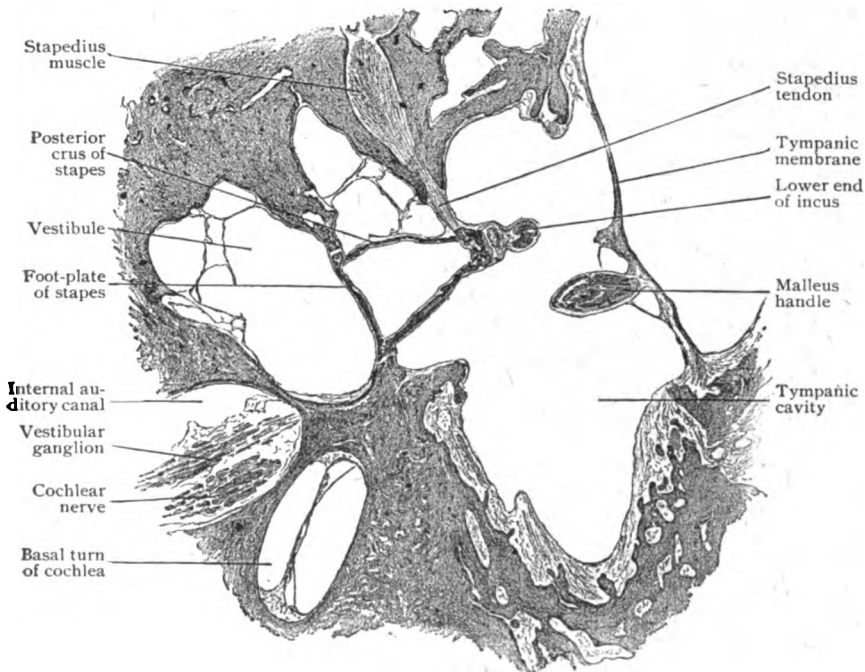


FIG. 414.—Horizontal section through human middle and internal ear; the malleus is attached to tympanic membrane and the stapes occludes the oval window.  $\times 5\frac{1}{2}$ . (Preparation by Dr. Ralph Butler.)

internal ear and the external auditory canal. It is lined with mucous membrane and contains, in addition to the air which enters by way of the Eustachian tube, the chain of ear-ossicles.

**The Membrana Tympani.**—The tympanic membrane or drum-head is a delicate transparent disk, irregularly oval or ellipsoidal in outline and concave on its outer surface. It is about .10 mm. thick, except at the periphery, where it is thickened.

Embedded in the tympanic membrane is the handle of the malleus (Fig. 415), which extends from a point near its middle, upwards and forwards

towards its periphery. At its lower end, the handle of the malleus is flattened laterally and broadened at the *umbo*, which corresponds to the deepest part of the concavity of the membrane.

The tympanic membrane includes three main layers: (1) the *middle* or *fibrous stratum*; (2) the *external* or *cutaneous layer*, the prolongation of the skin lining the external auditory canal; and (3) the *internal* or *mucous membrane*, a continuation of the mucous membrane clothing other parts of the tympanic cavity.

The **fibrous layer**, the membrane proper, represents the mesodermic portion of the drum-head and consists of an outer stratum of radially disposed fibres which diverge from the malleus towards the

periphery of the membrane, and an inner stratum of circular fibres, concentrically arranged and best developed near the periphery of the membrane but absent at the umbo. The radiating fibres, on the contrary, become more dense at the umbo. Connective tissue corpuscles, spindle-shaped in longitudinal and stellate in cross-section, lie between the fibres of the two layers. At the periphery of the membrane proper, the fibres, especially those of the radial stratum, are connected with those of a ring of thick connective tissue, the *annulus fibrosus*. The fibres of the annulus run in various directions, but for the most part radially, that is, towards the tympanic membrane proper (Fig. 416). Rounded connective cells lie between these fibres.

The **cutaneous layer** consists of a thin epidermal stratum, composed of two or three rows of cells and a delicate sheet of connective tissue;

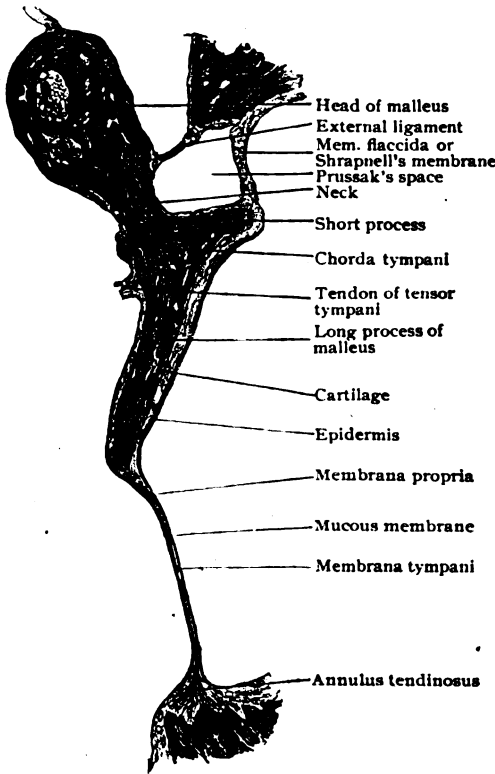


FIG. 415.—Frontal section through tympanic membrane and malleus, showing long process of the latter embedded within membrane.  $\times 8$ . (Preparation by Dr. Ralph Butler.)

neither a definite corium nor papillæ are present.

The **mucous membrane** covering the inner surface of the drum-head consists of a scanty layer of connective tissue, invested with a sheet of large low nonciliated epithelial cells.

The **blood-vessels** of the tympanic membrane include arteries arranged as an outer and an inner set, separated by the membrane proper. Each of these sets forms a plexus of vessels, with a large branch extending downwards along the malleus-handle and another around the periphery of the membrane, these two branches being connected by numerous radiating twigs. Perforating vessels connect the two sets of arteries, especially along the

malleus-handle and at the periphery of the membrane. The *veins* are most numerous at the handle of the malleus and periphery of the membrane and communicate with those of the external meatus and tympanic cavity. The **lymphatics** are arranged similarly to the blood-vessels in two sets, one under the skin and the other under the mucous membrane, which communicate freely with each other. The **nerves** supplying the tympanic membrane accompany, for the most part, the blood-vessels and, in addition to supplying the latter, form both a subcutaneous and a submucous plexus.

The **auditory ossicles** are three small bones that form a chain extending across the upper part of the tympanum from the tympanic membrane to the labyrinth. The outermost of these, the *malleus* (hammer), is

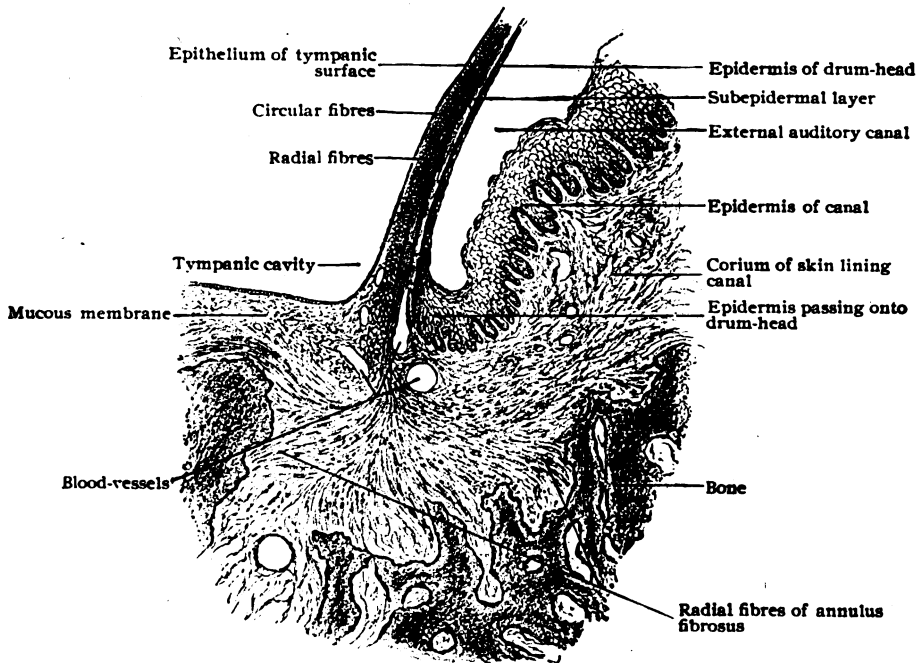


FIG. 416.—Section through attached margin of tympanic membrane, showing continuation of skin and mucous membrane over its outer and inner surfaces respectively.  $\times 75$ . (Preparation by Dr. Ralph Butler.)

attached to the tympanic membrane; the innermost, the *stapes* (stirrup), is fixed in the oval window, and between these two bones and connected with both of them, lies the third link in the chain, the *incus* (anvil). Their surfaces of contact are covered with articular cartilage and enclosed to form miniature true joints, provided with fibrous capsular ligaments and synovial membranes. The bones do not lie exposed within the tympanic space, but are invested with folds of the general mucous membrane lining the cavity.

**The Eustachian Tube.**—The Eustachian tube, or *tuba auditiva*, is a canal, partly bony and partly cartilaginous, extending from the lateral wall of the naso-pharynx backwards, upwards, and outwards to the anterior part of the tympanum. In the adult it measures about 37 mm. in length, of which approximately the upper third (tympanic portion) belongs to the bony division, whilst the remainder is contributed by the cartilaginous division of the tube.

The posterior wall of the pharyngeal portion is formed by a plate of cartilage, the upper margin of which is curled outwards upon itself to form a gutter, which appears as a hook on transverse section. The interval between the margins of this cartilaginous groove is filled with strong fibrous tissue, thus completing the canal. At birth the cartilage is entirely of the hyaline variety, but later this is more or less extensively replaced by fibrocartilage, except in the upper part where the hyaline cartilage persists.

The **mucous membrane** of the Eustachian tube lines the tube throughout its length, but differs somewhat in the cartilaginous and osseous portions. That in the former resembles the mucous membrane of the naso-pharynx,

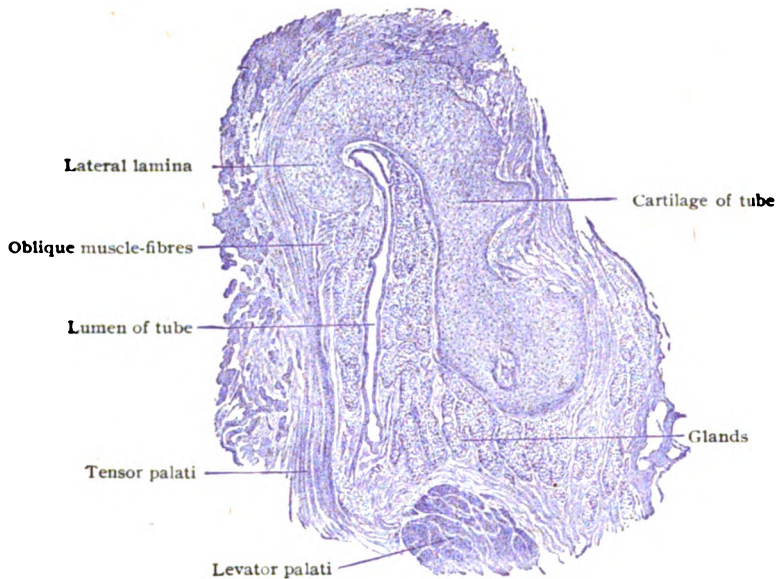


FIG. 417.—Section across cartilaginous part of Eustachian tube.  $\times 7$ .

with which it is directly continuous, while that of the osseous division resembles, to some extent, the mucous membrane of the tympanic cavity. The *epithelium* of both divisions is of the ciliated stratified columnar type, with some goblet-cells. The cells in the pharyngeal division, especially in the lower part, are taller than those of the tympanic portion, which are low cuboidal. In the tympanic portion the mucous membrane is closely united with the periosteum and contains very few mucous glands and little or no lymphoid tissue. In the cartilaginous division, on the contrary, the epithelium overlies a layer of such tissue, often called the **tubal tonsil**. This tissue is especially abundant in children, and beneath it are found numerous mucous glands, which open on the free surface of the tube. These glands extend nearly to the perichondrium and sometimes can be traced even through the fissures in the cartilage into the surrounding connective tissue. A considerable amount of adipose tissue often occupies the submucosa of the lower and lateral walls. The submucous layer is well developed in the cartilaginous division of the tube, particularly in the outer membranous wall. It consists of loosely arranged fibro-elastic tissue, which supports the mucous glands and the larger vessels and nerves.



The **muscles** of the Eustachian tube are the *levator* and the *tensor palati*, which lie beneath and to the inner side of the tube and to its outer side respectively. By reason of the intimate attachment which both muscles have to the cartilage of the tube, since both take partial origin from this structure, contraction of their fibres tends to draw apart the walls of the canal; they thus serve as dilators.

**The Mastoid Cells.**—The tympanic cavity communicates posteriorly, through the antrum, with a variable number of irregular pneumatic cavities, the mastoid cells, so called because the majority of these spaces occupy the mastoid process. Unlike the antrum, these cells are not developed at birth. As the mastoid process develops, the original diploetic structure is usually more or less replaced by larger cavities forming the pneumatic type. These spaces are filled with air and lined by a very thin mucous membrane, which is continuous with that of the antrum and of the tympanic cavity. It is closely united with the periosteum and possesses a layer of low nonciliated squamous epithelium.

### THE INTERNAL EAR.

The internal ear consists essentially of a highly complex membranous sac, connected with the peripheral ramifications of the auditory nerve, and a bony capsule, which encloses all parts of the membranous structure and is embedded within the substance of the petrous portion of the temporal bone. These two parts, known respectively as the *membranous* and the *bony labyrinth*, are not everywhere in close apposition, but in most places are separated by an intervening space filled with a fluid, the *perilymph*, the inner sac lying within the osseous capsule like a shrunken cast within a mould. The membranous labyrinth is hollow and everywhere filled with a fluid, called the *endolymph*, which nowhere gains access to the cavity occupied by the perilymph. The internal ear is closely related with the bottom of the internal auditory canal, which its inner wall contributes, on the one side, and with the inner wall of the tympanic cavity on the other. Its entire length is about 20 mm., and its long axis corresponds closely with that of the pyramidal or petrous portion of the temporal bone. The irregular cavity of the bony labyrinth comprises three subdivisions: a middle one, the *vestibule*; an anterior one, the *cochlea*; and a posterior one, the *semicircular canals*. Both the front and hind divisions communicate freely with the vestibule, but neither communicates with the membranous labyrinth nor, in the recent condition, with the tympanic cavity. Although corresponding in its general form with the bony compartments of the cochlea and semicircular canals, the membranous labyrinth less accurately agrees in its contour with the bony vestibule, since, instead of presenting a single cavity, it is subdivided into two unequal compartments, known as the *sacculle* and the *utricle*, which are lodged within the bony vestibule. The divisions of the membranous labyrinth are, therefore, four, which from before backwards are: the *membranous cochlea*, the *sacculle*, the *utricle*, and the *membranous semicircular canals*.

### THE OSSEOUS LABYRINTH.

The **vestibule**, the middle division of the bony labyrinth, lies between the cochlea in front and the semicircular canals behind and communicates freely with both. It is an irregularly elliptical cavity, measuring about 5 mm. from before backwards, the same from above downwards, and from 3-4 mm. from without inwards. The lateral (outer) wall separates it from the

tympanic cavity and contains the *oval window* with the foot-plate of the stapes. The margin of the window and the foot-plate are covered with hyaline cartilage and connected by fibro-elastic tissue, thus preventing the escape of the perilymph from the vestibule. The medial (inner) wall of the vestibule presents two depressions separated by a ridge, the *crista vestibuli*. The anterior and smaller of these depressions is the *spherical recess* and lodges the saccule. The posterior and larger depression is the *elliptical recess*. The anterior wall of the vestibule is pierced by the large opening leading into the *scala vestibuli* of the cochlea. Posteriorly the vestibule directly communicates with the semicircular canals by five round openings.

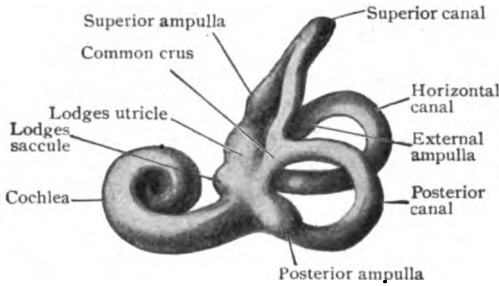


FIG. 418.—Cast of right bony labyrinth, mesial aspect.  $\times 2$ .

The three **bony semicircular canals**—the *superior*, the *posterior*, and the *horizontal*—lie behind the vestibule, their disposition being such that the planes of the three canals correspond with the sides of the corner of a cube. Each canal possesses at one end a dilatation, called the *osseous ampulla*. The semicircular canals open into the posterior part of the vestibule by five apertures, the undilated ends of the superior and posterior canals joining to form a common limb (Fig. 418). The horizontal canal alone communicates with the vestibule by two independent openings.

The vestibule and the bony semicircular canals are lined by a very thin periosteum composed of a feltwork of a resistant fibrous tissue, containing pigmented connective tissue cells. Endothelium everywhere lines the perilymphatic space between the membranous and osseous canals, covering the free inner surface of the periosteum, the fibrous trabeculæ, and the outer or perilymphatic surface of this part of the membranous labyrinth.

The **bony cochlea** constitutes the anterior part of the labyrinth and appears as a short blunt cone, about 5 mm. in height, whose base forms the anterior wall of the inner end of the internal auditory meatus. Its apex is directed horizontally outwards. The bony cochlea consists essentially of a tapering central column, the *modiolus*, around which the bony canal, about 30 mm. long, makes something more than two and a half spiral turns, the *basal*, *middle*, and *apical*. The conical modiolus has a broad concave *base*, which forms part of the base of the cochlea, and a small *apex*, which extends nearly to the apex of the cochlea or *cupola*. It is much thicker within the lowest turn of the canal than above, and is pierced by many small canals for the nerves and vessels to the spiral lamina. The axis of the modiolus, from base to apex, is traversed by the *central canal*, while a more peripherally situated channel, the *canalis spiralis*, encircles the modiolus and contains the spiral ganglion and a spiral vein. Projecting at a right angle from the modiolus into the canal of the bony cochlea is a thin shelf of bone, the *lamina spiralis ossea*, which is made up of two delicate bony plates between which are fine canals containing the branches of the cochlear nerve. The partial division of the canal of the bony cochlea effected by the osseous spiral lamina is completed by the membranous spiral lamina, which stretches from the free edge of the osseous lamina to the outer wall of the canal (Fig. 422). The upper division of the canal is called the *scala vestibuli* and com-

municates with the vestibule, whilst the lower division, the *scala tympani*, would open into the tympanic cavity, were it not separated from that space by the *secondary tympanic membrane*. The latter is a thin fibro-elastic

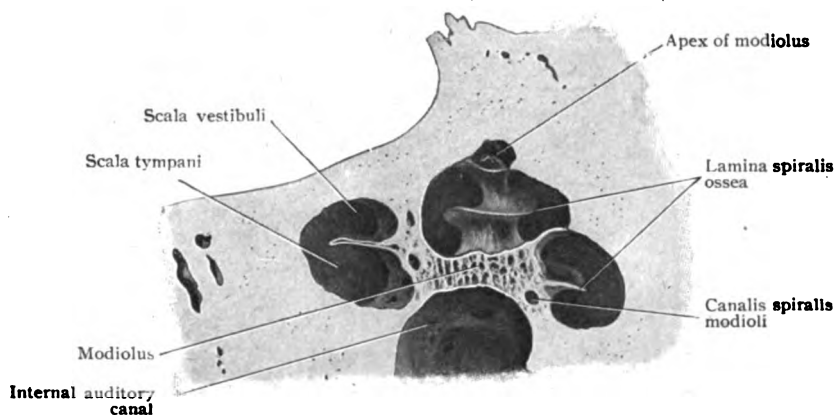


FIG. 419.—Cochlea and bottom of internal auditory canal exposed by vertical section; cochlea rests with its base downwards and apex pointing upwards.  $\times 5$ .

sheet, covered internally with endothelium and externally with epithelium. The scalæ communicate with each other through an opening, the *helicotrema*, at the apex of the cochlea.

#### THE MEMBRANOUS LABYRINTH.

The membranous labyrinth lies within the bony labyrinth, which it resembles in general form. This agreement is least marked within the vestibule, since here the single division of the bony capsule is occupied by two compartments of the membranous sac, the utricle and the saccule. The membranous labyrinth comprises: (1) the *utricle* and the *saccule*, which, with the *ductus endolymphaticus*, lie within the vestibule; (2) the three *membranous semicircular canals* lodged within the bony semicircular canals; and (3) the *membranous cochlea* enclosed within the bony cochlea. The membranous labyrinth is attached, especially in certain places, by connective tissue to the inner wall of the bony capsule. The interval between the membranous and bony labyrinths, largest in the scalæ tympani and vestibuli of the cochlea and in the vestibule, constitutes the *perilymphatic space* and contains a modified lymphatic fluid, the *perilymph*. The fluid within the membranous labyrinth, the *endolymph*, can pass from one part of the labyrinth to another, although the saccule and utricle are only indirectly connected through a narrow channel, the *ductus endolymphaticus*, and the saccule and cochlear duct communicate by means of a small tube, the *canalis reuniens*.

#### Structure of the Utricle, Saccule and Semicircular Canals.—

The walls of these subdivisions of the membranous labyrinth are made up of (a) an outer fibrous *connective tissue lamella* and (b) an inner *epithelial lining*, the latter consisting throughout the greater part of its extent of a single layer of thin flattened polyhedral cells. Beneath the epithelium, especially in the region of the maculæ, is (c) a thin almost homogeneous *hyaline membrane*, with few cells. This middle layer presents in places on its inner surface small papillary elevations covered by epithelium. On the concave

side of each of the semicircular canals, which occupy only about one third of the lumina of the bony tubes, is a strip, the *raphe*, of thickened epithelium in which the cells become low cylindrical in type. Over the regions receiving the nerve-fibres, the *maculæ acusticæ* and the *cristæ acusticæ*, the epithelium undergoes a marked alteration, changing from the indifferent covering cells into the highly specialized neuroepithelium.

The *maculæ acusticæ* are about 3 mm. long by 2 mm. broad, the macula of the saccule being a little narrower (1.5–1.6 mm.) than that of the utricle (2 mm.). At the margin of these areas the cells are at first cuboidal,

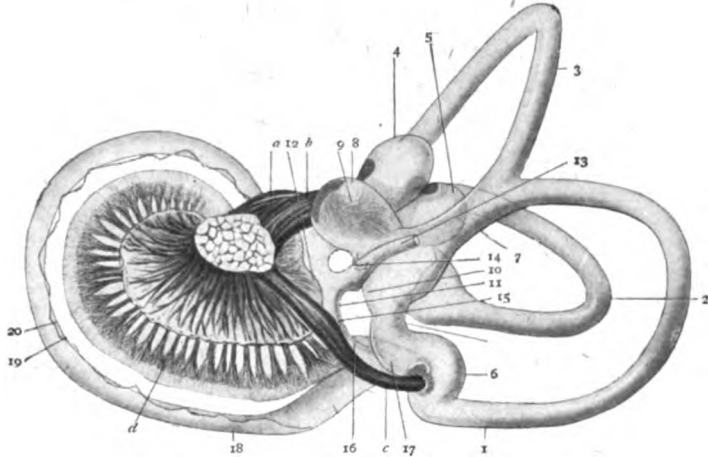


FIG. 420.—Membranous labyrinth of five-months fetus, postero-mesial aspect. 1, 2, 3, posterior, horizontal, and superior semicircular canals; 4, 5, 6, their ampullæ; 7, common crus of superior and posterior canals; 8, 9, recess and macula of utricle (10); 11, saccule and its macula (12); 13, ductus endolymphaticus; 14, utriculo-sacculus canal; 15, canalis reuniens, opening at 16 into cochlear duct; 17, blind sac of cochlear duct (18); 19, basilar membrane; 20, ligamentum spirale; a, facial nerve; b, vestibular nerve; c, branch of vestibular nerve to posterior canal; d, branches of cochlear nerve to Corti's organ.  $\times 6$ . (Retzius.)

next low columnar, and then abruptly increase in length, until they measure from 30–35  $\mu$ , in contrast with their usual height of from 3–4  $\mu$ . The acoustic area includes two kinds of elements, the sustentacular or fibre-cells and the hair-cells. The *sustentacular cells* are long, rather narrow, irregularly cylindrical elements and extend the entire thickness of the epithelial layer, resting upon a well-developed basement-membrane by their expanded or divided basal processes. They present a swelling enclosing an oval nucleus and terminate at the surface in a cuticular zone. The cylindrical *hair-cells* are broader but shorter than the sustentacular cells, and reach from the free surface only as far as the middle of the epithelial layer, where each cell terminates usually in a rounded or somewhat swollen end containing a spherical nucleus. The central end, next to the free surface, exhibits a differentiation into a cuticular zone, similar to that covering the inner ends of the sustentacular elements. From the free border of each hair-cell, a stiff robust hair (20–25  $\mu$  long) projects into the endolymph. This conical process, however, is resolvable into a number of agglutinated finer hairs or rods.

The free surface of the neuroepithelium within the saccule and the utricle is covered by a remarkable structure, the so-called **otolith membrane**. This consists of a gelatinous membrane in which are embedded numberless small crystalline bodies, the *otoliths* or *ear-stones*. Between it and the cuticular zone is a space filled with endolymph, through which the hair-cells pass

to the otolith membrane. The otoliths, also called *otoconia*, are minute crystals, usually hexagonal in form, with slightly rounded angles, and from 9–11  $\mu$  in length. They are composed of calcium carbonate with an organic basis.

On reaching the maculæ the nerve-fibres form a subepithelial plexus, from which fine bundles of fibres pass towards the free surface. The fibres usually lose their medullary substance in passing through the basement mem-

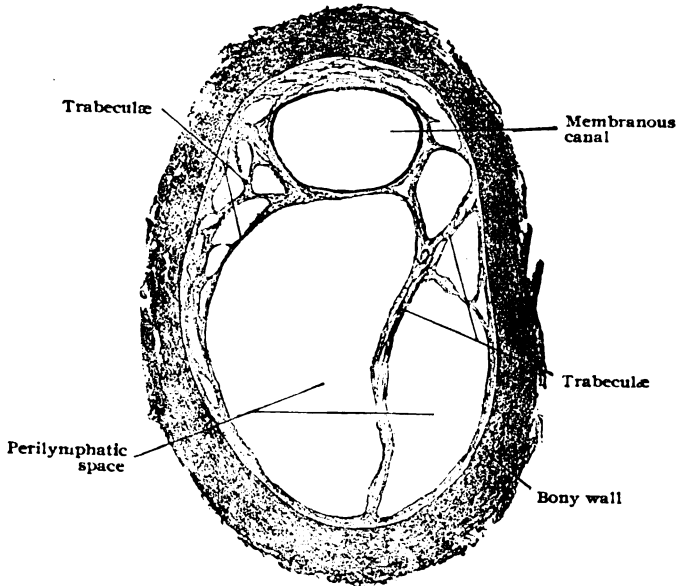


FIG. 421.—Transverse section of superior semicircular canal, showing relations of membranous to bony tube.  $\times 35$ .

brane and enter the epithelium as naked axis-cylinders. Passing between the sustentacular cells to about the middle of the epithelium, they break up into fine fibrillæ, which embrace the deeper ends of the hair-cells and give off fine threads that pass, as free axis-cylinders, between the cells to higher levels.

The **crista acustica** and the adjoining **planum semilunatum** are covered with neuroepithelium similar to that of the maculæ. The hairs of the hair-cells, however, are longer and converge to and are embedded within a peculiar dome-like structure, known as the **cupola**, which probably does not exist during life, but is an artefact formed by coagulation of the fluid in which the ends of the hairs are bathed. Otoliths are probably not present in the cristæ acusticæ.

**The Cochlear Duct.**—The membranous cochlea or *ductus cochlearis* lies within the bony cochlea and like it includes from two and one-half to two and three-quarter turns, named respectively the *basal*, *middle*, and *apical*, the latter being three-fourths of a turn at the apex of the cochlea. The tapering tube of the bony cochlea, winding spirally around the modiolus, is subdivided into three compartments by the osseous spiral lamina and two membranes, namely, the membranous spiral lamina and Reissner's membrane. The *membranous spiral lamina* or *basilar membrane* extends from

the free border of the lamina spiralis ossea to the outer wall of the cochlea, where it is connected to an inward bulging of the periosteum and subperiosteal tissue, called the *spiral ligament*. The lower of the two tubes thus formed is the *scala tympani* and communicates, in the macerated skull, with the tympanum through the round window. The upper tube is subdivided into two compartments by an exceedingly delicate partition, known as *Reissner's membrane*, which extends from the upper surface of the osseous lamina near its outer end, obliquely upwards and outwards, to the external wall of the cochlea. The compartment above this membrane is the *scala vestibuli* and communicates with the perilymphatic space of the vestibule. The *scalæ tympani* and *vestibuli* communicate only at the apex of the cochlea through the *helicotrema*. They contain perilymph and are brought into relation with

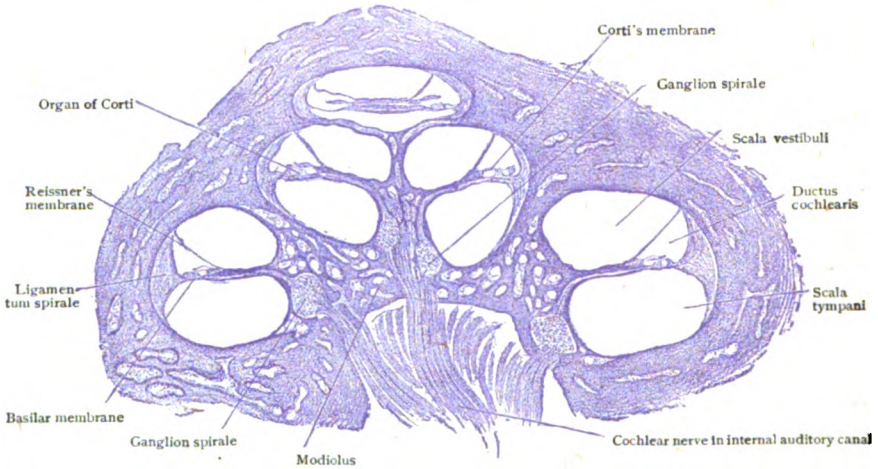


FIG. 422.—Section of human cochlea passing through axis of modiolus.  $\times 12$ .

the subarachnoid space through the aquæductus cochleæ. They are lined by a delicate fibrous periosteum, usually covered on the surface which is in contact with the enclosed perilymph by a single layer of endothelial plates. In some localities, however, as on the tympanic surface of the basilar membrane, the lining cells retain their primitive mesodermic character and never become fully differentiated into endothelium.

The third compartment, the ductus cochlearis, is triangular on cross-section (Fig. 423), except at its ends, and bounded by Reissner's membrane above, by the basilar membrane and a part of the osseous spiral lamina below, and by the outer wall of the bony cochlea externally. Save for the narrow channel, the *canalis reuniens*, by which it communicates with the sacculæ, the cochlear duct is a closed tube and contains endolymph. It begins below as a blind extremity, the *cæcum vestibulare*, lodged within the recessus cochlearis of the vestibule and, after making two and three-quarter turns through the cochlea, ends above at the cupola of the cochlea in a second blind extremity, the *cæcum cupulare*, which is attached to the cupola and forms a part of the boundary of the helicotrema.

**Architecture and Structure of the Cochlear Duct.**—Reissner's membrane or *membrana vestibularis*, the delicate partition separating the cochlear duct from the scala vestibuli, begins on the upper surface of the lamina spiralis, about .2 mm. medial to the free edge of the bony shelf, and extends at an angle of from 40-45° with the lamina

spiralis ossea to the outer wall of the cochlea, where it is attached to the periosteum. Notwithstanding its excessive thinness ( $.3\ \mu$ ), it consists of three layers: (a) a very delicate middle *stratum of connective tissue*, (b) the *endothelium* covering the vestibular side, and (c) the *epithelium* derived from the ectodermic cochlear duct. It also contains sparingly distributed capillary blood-vessels.

The outer wall of the cochlear duct (Fig. 423) is bounded by a part of a thickened crescentic cushion of connective tissue, whose convex surface is closely united with the bony wall and whose generally concave surface looks towards the cochlear duct. This structure, the *ligamentum spirale*, extends slightly above the attachment of Reissner's membrane and to a greater distance below the attachment of the basilar membrane, thus forming part of the outer walls of the *scalæ vestibuli* and *tympani*. At its junction with the basilar membrane it presents a marked projection, the *crista basilaris*, while a very slight elevation marks the point of attachment of the membrane

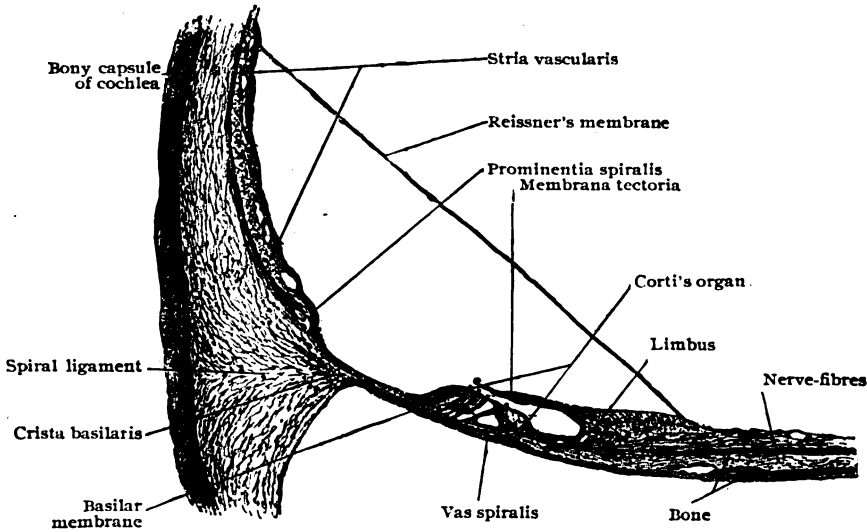


FIG. 423.—Part of section of human cochlea, showing cochlear duct with Corti's organ.  $\times 90$ . (Preparation by Dr. Ralph Butler.)

of Reissner. The part of this ligament lying between these projections corresponds to the outer wall of the cochlear duct. Its concave free inner surface is broken by a third elevation, the *prominentia spiralis*, or *accessory spiral ligament*, distinguished usually by the presence of one large (*vas prominens*) or several small blood-vessels. The lower and smaller of these two divisions of the outer wall is called the *sulcus spiralis externus* and is lined by cuboidal epithelium, while the larger upper division is occupied by a peculiar vascular structure, the *stria vascularis*, which contains capillary blood-vessels within an epithelial structure. Its surface is covered with pigmented irregular polygonal epithelial cells, and its deeper strata consist of cells which, especially in the superficial layers, resemble the surface epithelium, but in the deeper layers assume more and more the character of connective tissue. Over the prominentia spiralis the cells become flat and polyhedral.

The *ligamentum spirale* is composed of a peculiar connective tissue, rich in cells and blood-vessels. Its thin outer layer forms the periosteum and is denser than the adjacent loose connective tissue. The latter is broadest opposite the *scala tympani*, where its fibres converge towards the *crista basilaris*. Opposite the outer wall of the cochlear duct it again becomes more compact and is rich in cells and blood-vessels. An internal layer extending from near the prominentia spiralis to the basilar membrane consists of a hyaline noncellular tissue. Some authors claim to have found smooth muscle-fibres in the *ligamentum spirale*.

The tympanic wall or floor of the cochlear duct (Fig. 423) comprises the *basilar membrane*, extending from the basilar crest to the outer end of the bony spiral lamina, and the *limbus laminae spiralis*, which includes this wall from the attachment of Reissner's membrane to the end of the bony lamina. The limbus or *crista spiralis* is a thick mass of connective tissue upon the upper surface of the outer end of the osseous lamina spiralis. Its outer extremity is deeply grooved to form a gutter, the *sulcus spiralis internus*, the projections of the limbus above and below the sulcus forming respectively its *superior* (vestibular) and *inferior* (tympanic) *labia*. The upper surface of the limbus is marked by clefts and furrows which are most conspicuous near the outer margin of the upper lip, where the irregular projections between the furrows form the so-called *auditory teeth*, because of their fancied resemblance to incisor teeth. The lower lip is continuous externally with the basilar membrane and is perforated near its outer end by some 4000 apertures (*foramina nervosa*) transmitting minute branches of the cochlear nerve. The epithelium covering the elevated portions of the limbus, including the auditory teeth, is of the flat polyhedral variety, the intervening furrows and clefts being lined by columnar cells. The epithelium of the sulcus spiralis consists of a single layer of low cuboidal or flattened cells, continuous with the epithelium of the auditory teeth above and with the highly specialized elements of Corti's organ below.

The *basilar membrane* consists of a median (inner) and a lateral (outer) part. The former, known as the *zona arcuata*, is thin and supports the modified neuroepithelium constituting the organ of Corti; the outer part, named the *zona pectinata*, is the thicker division and lies external to the foot-plates of the outer rods of Corti. The basilar membrane is made up of three distinct layers—the epithelium, the *substantia propria*, and the tympanic lamella. The *substantia propria* is formed of an almost homogeneous connective tissue with a few nuclei and fine fibres, which radiate towards the outer edge of the spiral lamina. The fibres of the *zona arcuata* are very fine and interwoven, appearing to be an extension of those of the lower lip of the limbus, whilst straight and more distinct fibres stretch from the outer rods of Corti to the spiral ligament and constitute the so-called *auditory strings*. According to the estimate of Retzius, there are 24,000 of these special fibres. Their length increases from the base towards the apex of the cochlea, in agreement with the corresponding increase in breadth of the basilar membrane. The *tympanic lamella* contains numbers of fusiform cells of immature character interspersed with fibres. In this location the differentiation of the mesodermic cells lining the tympanic canal has never advanced to the production of typical endothelial plates, the free surface of the lamella being invested by the short fusiform cells alone. The inner zone of this layer contains capillaries which empty into one, or sometimes two, veins, frequently seen under the tunnel of Corti and known as the *vas spirale*. The *epithelium* covering the inner zone of the basilar membrane forms the organ of Corti, the highest example of specialization as neuroepithelium.

**The Organ of Corti.**—The organ of Corti, or *organon spirale*, consists in a general way of a series of epithelial arches formed by the interlocking of the upper ends of converging and greatly modified epithelial cells, the *pillars* or *rods of Corti*, upon the inner and outer sides of which rest groups of neuroepithelial elements—the *auditory* and the *sustentacular cells*. The triangular space included between the converging pillars of Corti above and the basilar membrane below constitutes the *tunnel of Corti*, which is, therefore, only an intercellular space of unusual size. It contains probably a soft semifluid intercellular substance serving to support the nerve-fibrils traversing the space (Fig 424). The *pillars* or *rods of Corti*, examined in detail, prove to be composed of two parts, the denser substance of the pillar proper, and a thin, imperfect protoplasmic envelope, which presents a triangular thickening at the base directed towards the cavity of the tunnel. Each pillar possesses a slender slightly sigmoid, longitudinally striated *body*, whose upper end terminates in a triangular *head*, and whose lower extremity expands into the *foot* resting upon the basilar membrane. The inner pillar is shorter, more perpendicular and less curved than the outer; its head exhibits a single or double concave articular facet for the reception of the corresponding convex surface of the head of the outer rod. The cuticular substance of both pillars adjoining the articular surfaces is distinguished by a circumscribed, seemingly homoge-



neous oval area of different nature. The upper straight border of the head of both pillars is prolonged outwardly into a thin process or *head-plate*, that of the inner lying uppermost and covering over the head and inner part of the plate of the outer pillar. The head-plate of the latter is longer and projects beyond the termination of the plate of the inner rod as the *phalangeal process*, which unites with the adjacent phalanges of the cells of Deiters to form the *membrana reticularis*. The inner pillars of Corti are more numerous, but narrower than the outer elements, from which arrangement it follows that the broader outer rods articulate with two and sometimes three of the inner pillars, the number of the latter in man being estimated by Retzius at 5600, as against 3850 of the outer rods.

Immediately medial to the arch of Corti, resting upon the inner rods, a single row of specialized epithelial elements extends as the *inner auditory* or *hair-cells*. These elements, little more than half the thickness of the epithelial layer in length, possess a columnar body containing an oval nucleus. The outer somewhat constricted end of each hair-cell is limited by a sharply defined cuticular zone, from the free surface of which project, in man, some twenty-five rods or *hairs*. The inner hair-cells are less

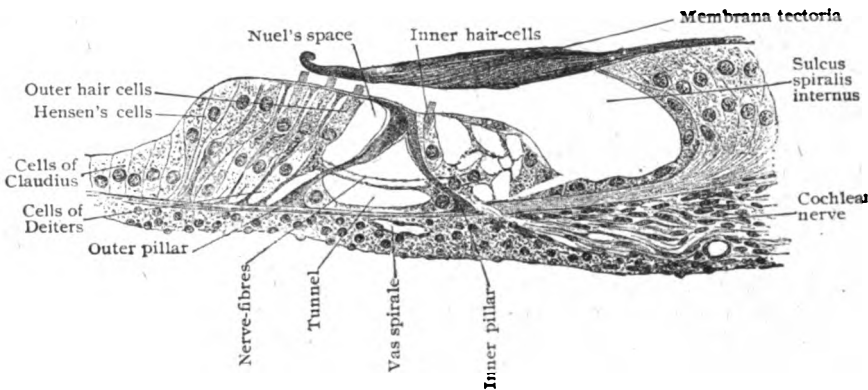


FIG. 424.—Section showing details of Corti's organ from human cochlea; section is slightly oblique, hence width is somewhat exaggerated.  $\times 375$ . (Preparation by Dr. Ralph Butler.)

numerous (according to Retzius about 3500), as well as shorter and broader, than the corresponding outer elements. Their relation to the inner rods of Corti is such, that to every three rods two hair-cells are applied. The *inner sustentacular cells* extend throughout the thickness of the epithelial layer and exhibit a slightly imbricated arrangement as they pass over the sides of Corti's organ to become continuous with the lower cells of the sulcus spiralis.

The cells covering the basilar membrane from the outer pillar to the basilar crest comprise three groups: (a) those composing the outer part of Corti's organ, including the *outer hair-cells* and *cells of Deiters*; (b) the *outer supporting cells*, or *cells of Hensen*; (c) and the low cuboidal elements, the *cells of Claudius*, investing the outermost part of the basilar membrane.

The *outer auditory* or *hair-cells* are about five times more numerous (approximately 18,000 according to Waldeyer) than the corresponding inner elements, and in man and apes are disposed in three or four rows. They alternate with the peculiar end-plates or "phalanges" of Deiters' cells, which separate the ends of the hair-cells and join to form a cuticular meshwork, the *membrana reticularis*, through the openings of which the hair-cells reach the free surface. The inner row of these cells lies directly upon the outer rods of Corti, so placed that each cell, as a rule, rests upon two rods. The cells of the second row, however, are so disposed that each cell lies opposite a single rod, whilst the third layer repeats the arrangement of the first. In consequence of this grouping, these elements, in conjunction with the phalanges, appear in surface views like a checker-board mosaic, in which the oval free ends of the auditory cells are included between the peculiar compressed and indented octag-

onal areas of the end-plates of Deiters' cells (Fig. 425). The outer hair-cells are cylindrical in their general form, terminating about the middle of the epithelial layer in slightly expanded rounded ends, near which the spherical nuclei are situated. The outer sharply defined ends of the cells are distinguished by a cuticular border supporting about twenty-five rigid auditory rods or hairs which project beyond the level of the *membrana reticularis*. The deeper end of each outer hair-cell contains a dense yellowish enclosure, known as the *body of Retzius*, which is triangular when seen in profile. The bodies are absent in the inner hair-cells.

The cells of Deiters have much in common with the rods of Corti, like these being specialized sustentacular epithelial cells which extend the entire thickness of the epithelial stratum to terminate in the peculiar end-plates or phalanges. It follows, that while the free surface of Corti's organ is composed of both auditory and sustentacular

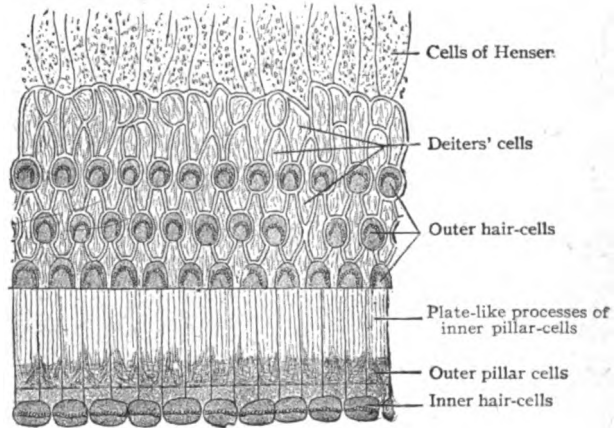


FIG. 425.—Corti's organ viewed from above, showing mosaic formed by pillars and Deiters' cells; outer ends of auditory cells occupy meshes of cuticular network. (*Retzius*.)

cells, the elements resting upon the basilar membrane are of one kind alone—the cells of Deiters. The bodies of the latter consist of two parts, the elongated cylindrical *chief portion* of the cell, containing the spherical nucleus and resting upon the basilar membrane, and the greatly attenuated pyramidal *phalangeal process*. A system of communicating intercellular clefts, the *spaces of Nuel*, lie between the auditory and supporting cells; like the tunnel of Corti, these spaces are occupied by a semifluid intercellular substance. The cells of Deiters are arranged, as a rule, in three rows, although in places within the upper turns four or even five alternating rows are sometimes found. Each cell contains a fine filament, the *fibre of Retzius*, which begins near the middle of the base with a conical expansion and extends through the cell-body to the apex of the phalangeal process.

The *membrana tectoria* or *Corti's membrane* stretches laterally from the upper lip of the limbus, above the sulcus spiralis and Corti's organ, as far as the last row of outer hair-cells. The membrane is a cuticular production, formed originally by the cells covering the region of the auditory teeth and the spiral sulcus. Medially it rests upon the epithelial cells, but farther outward it becomes separated from the free edge of the auditory teeth and assumes its conspicuous position over the organ of Corti. The membrane seems to be composed of fine resistant fibres, held together by an interfibrillar substance. During life the membrane is probably soft and gelatinous, and much less rigid than its appearance indicates after the effect of reagents. The lower surface of the free portion of the membrane, opposite the inner hair-cells, is modelled by a shallow furrow, which indicates the position of a spirally arranged band known as the *stripe of Hensen*. Like the basilar membrane, the *membrana tectoria* increases in width from the base towards the apex of the cochlea.

The **outer sustentacular cells** or **cells of Hensen** form a zone immediately external to the last Deiters' cells. These elements resemble the inner sustentacular cells, but differ somewhat in form and arrangement. In consequence of their oblique position, the bodies are not only greatly elongated, but also imbricated. The **cells of Claudius** are the direct continuations of Hensen's cells, and laterally pass uninterruptedly into the low columnar elements covering the remaining part of the basilar membrane. They consist of a single row of cuboidal cells possessing clear, faintly granular protoplasm and spherical nuclei.

**The Nerves of the Membranous Labyrinth.**—The branches of the **cochlear division** of the auditory nerve enter the base of the cochlea through numerous small foramina, those destined for the apical turn traversing the central canal of the modiolus. From the modiolus a series of stout lateral branches diverge at quite regular intervals through canals which communicate with the peripheral spiral canal within the base of the bony spiral lamina. Within the peripheral canal the nerve-fibres join numerous aggregations of bipolar nerve-cells, which continue along the spiral canal and collectively constitute the *ganglion spirale*. From these cells numerous dendrites are given off, which pass along the canals within the spiral lamina towards its margin, the twigs meanwhile subdividing to form an extensive plexus contained within corresponding channels in the bone. At the edge of the spiral lamina, bundles of fine fibres are given off, which enter the epithelial layer close to the inner rod of Corti. During or before their escape from the lamina, the nerve-fibres lose their medullary substance and proceed to their destination as fine naked axis-cylinders. The radiating bundles pass within the epithelium to the mesial side of the base of the inner pillar; here they divide into two sets of fibrillæ, one, the *mesial spiral fasciculus*, going to the inner hair-cells and the other, the *lateral spiral fasciculus*, passing between the inner pillars to reach the tunnel of Corti. Within this space fibrillæ are given off which, after crossing the tunnel, escape between the outer rods into the epithelium lying on the lateral side of the arch. The further course of the fibrillæ seems to be such that some extend between the outer pillar of Corti and the first rows of hair-cells, whilst succeeding groups of fibrillæ course between the rows of Deiters' cells to reach the remaining hair-cells. The relation between the nerve-fibrils and the auditory cells is in all cases probably close contact and not actual junction.

The nerves supplying the saccule, utricle, and the semicircular canals are all fibres from the **vestibular division** of the auditory nerve. They traverse the bony labyrinth through canals that open internally at certain areas, the *maculæ cribrosæ*, by numerous openings in close relation to the specialized areas in the wall of the membranous labyrinth. The relations of the nerve fibres to the receptive cells of these maculæ and cristæ have been described (page 373).

**Blood-Vessels of the Membranous Labyrinth.**—The auditory artery, a branch of the basilar, after entering the internal auditory meatus divides into three branches. (1) The *vestibular artery* accompanies the utriculo-ampullary nerve and supplies the upper part of the vestibule, including the posterior part of the utricle with its macula, the saccule and the cristæ of the upper and outer ampullæ of the corresponding semicircular canals. (2) The *cochlear artery* pursues a spiral course. It gives off three branches, two of which are distributed to the lower turn of the cochlea, while the third supplies the middle and apical turns. (3) The *vestibulo-cochlear artery* arises either from the cochlear artery or independently and divides, within the spiral lamina, into a cochlear and a vestibular branch. The

*cochlear branch* is distributed to the lower turn of the cochlea and anastomoses with the cochlear artery proper. The *vestibular branch* is distributed to the lower part of the vestibule, including the lower part of the saccule and utricle, to the crus commune and part of the semicircular canals, and to the lower end of the cochlea. The macula of the saccule receives its arterial supply from a blood-vessel which usually arises from the common stem of the vestibulo-cochlear artery, or, more rarely, runs independently through the whole internal meatus. A similar origin applies to the artery supplying the nerve of the posterior ampulla. In the base of the spiral lamina the arteries are connected by capillary loops especially in the lower turn of the cochlea. One or more spiral vessels are often seen under the tunnel of Corti within the tympanic covering of the basilar membrane. The region of the stria vascularis and prominentia spiralis is especially well supplied with blood-vessels. Those seen in the scala tympani are principally veins, while a larger number of arteries are found in the scala vestibuli. The blood-supply of the lower turn of the cochlea is much more generous than that of the others.

The *veins* from the cochlea include: (1) the vein of the vestibular aqueduct, which collects the blood from the semicircular canals; (2) the vein of the cochlear aqueduct, which collects from the whole cochlear canal through the anterior, posterior and middle spiral veins and from most of the vestibule through the anterior and posterior vestibular veins; and (3) the venous plexus of the inner auditory canal, which receives the large central cochlear vein.

## THE NOSE.

Although only a small part of the nasal chambers is occupied by the peripheral olfactory organ in man, the greater part forming the beginning of the respiratory tract, comparative anatomy and embryology establish the primary significance of the nasal groove and its derivations as the organ of smell, the relation of the nose to respiration being entirely secondary. The nose, therefore, is appropriately grouped with the organs of special sense.

The nose is conventionally divided into two portions: the **external nose**, consisting of a framework of bone, cartilage and fibrous tissue, which insures the maintenance of apertures for the passage of air, and the **nasal chamber**, divided by a septum into the right and left *nasal fossæ* and lined by mucous membrane. The junction of the latter with the skin is marked by a limiting ridge, the *limen vestibuli*, on the inner surface of the vestibule, a short distance above the nostril. Apart from the unusually large sebaceous glands surrounding and the hairs (*vibrissæ*) guarding the nares, the external nose presents little of especial histological interest. The description of the external nose and of the complicated modelling of the nasal fossæ fall within the province of gross anatomy. The present consideration of the nose, therefore, may be limited to the mucous membrane lining the nasal chamber.

### THE NASAL MUCOUS MEMBRANE.

Beyond the limit of the integument clothing the vestibule, the nasal fossa is lined by mucous membrane continuous with that of the naso-pharynx through the choanæ. Since in addition to lining the tract over which the respired air passes the nasal mucous membrane contains the cells receiving the impressions giving rise to the sense of smell, it is appropriately divided into a *respiratory* and an *olfactory* part.

**The Olfactory Region.**—The highly specialized regio olfactoria is quite limited in extent and embraces an area situated over the upper and adjoining part of the middle turbinate and the corresponding part of the septum. In fresh preparations the olfactory area usually, but not always, can be approximately mapped out by the yellowish hue, lighter or darker, that distinguishes it from the respiratory region in which the mucous membrane exhibits a rosy tint.

The **epithelium** contains two chief constituents—the supporting and the olfactory cells. The *supporting cells* are tall cylindrical elements, about 60  $\mu$  in height, that extend the entire thickness of the epithelium. Their outer and broader ends are of uniform width and contain the oval nuclei which, lying approximately at the same line and staining readily, form a deeply colored and conspicuous nuclear stratum at some distance beneath the free margin. Between the latter and the row of nuclei, the

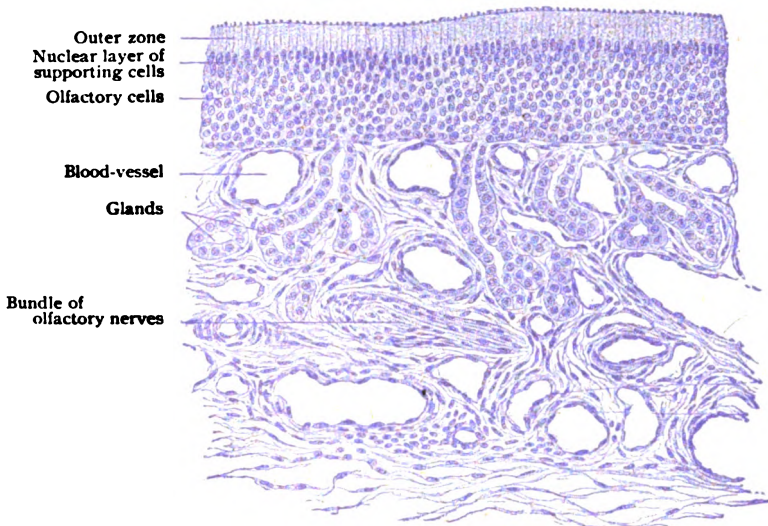


FIG. 426.—Section of olfactory mucous membrane.  $\times 300$ .

epithelium presents a clear zone devoid of nuclei. The inner part of the supporting cells is thinner and irregular in contour and often terminates by splitting into two or more basal processes that rest upon the tunica propria. Between these ends lie smaller pyramidal elements, the *basal cells*, that probably represent younger and supplementary forms of the sustentacular cells. The granular protoplasm of the basal processes often contains pigment particles.

The **olfactory cells**, the perceptive elements receiving the smell-stimuli, consist of a fusiform body, lodging a spherical nucleus enclosed by a thin envelope of cytoplasm, and two attenuated processes, a peripheral and a central. The olfactory cells are in fact sensory neurones that have retained their primitive position within the surface epithelium, as in many invertebrates, instead of receding, as is usual in the higher animals, to situations more remote from the exterior. The slender peripheral process of the olfactory cell, which corresponds to the dendrite of the neurone, is of uniform thickness and ends at the surface in a small hemispherical knob that projects

slightly beyond the general level of the epithelium and bears from 6–8 minute stiff cilia, the *olfactory hairs*. Being dependent upon the position of the nuclei, the length of the peripheral processes varies, since the nuclei occupy different levels within the epithelium in order to accommodate their great number. The central processes of the olfactory cells, much more delicate than the peripheral, are directly continued, as the axis-cylinders, into the subjacent nonmedullated nerve-fibres

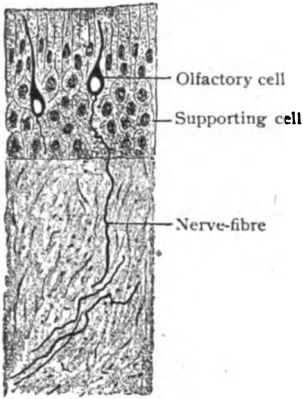


FIG. 427.—Section of olfactory mucous membrane, silver preparation; two olfactory cells are seen, one sending nerve-fibre towards the brain.  $\times 335$ . (Brunn.)

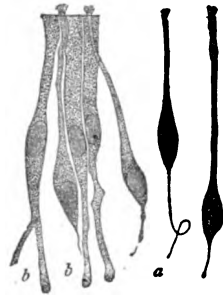


FIG. 428.—Isolated elements of epithelium of olfactory mucous membrane; *a*, olfactory cells; *b*, supporting cells.  $\times 600$ . (Brunn.)

within the tunica propria, from which they pass through the cribriform plate of the ethmoid to enter the brain and end in the arborizations within the olfactory glomeruli of the bulbus olfactorius.

The **tunica propria** is differentiated into a superficial and a deep layer by the lymphoid character of the stratum directly beneath the epithelium. The superficial layer, from 15–20  $\mu$  thick, consists of

closely packed irregularly round cells, resembling lymphocytes, and meagre bundles of delicate connective tissue. The deep layer, on the other hand, contains robust bundles of fibro-elastic tissue and relatively few cells. A distinct membrana propria is wanting within the olfactory region.

The **olfactory glands**, or *glands of Bowman*, are characteristic of the olfactory region and probably elaborate a specific secretion. They open onto the free surface by very narrow ducts that lead into saccular fusiform dilatations, the *ampullæ*, into which the tubular alveoli pass. The ducts possess an independent lining of flattened cells, that extend as far as the surface and lie between the surrounding epithelial elements. The dilatations are clothed with flattened or low cuboidal cells, which are replaced by those of irregular columnar or pyramidal form, often pigmented, within the tubular alveoli. From the character of their secretion, the glands of Bowman are probably to be reckoned as serous and not mucous.

**The Respiratory Region.**—The mucous membrane lining the respiratory region differs greatly in thickness in various parts of the nasal fossa. In situations where the contained cavernous tissue is well represented, as over the inferior turbinate, it may reach a thickness of several millimeters, while when such tissue is wanting, as on the lateral wall, it is reduced to less than a millimeter.

The **epithelium** is stratified ciliated columnar in type, from 50–70  $\mu$  thick, and includes the tall ciliated surface cells, between whose inner ends lie the irregularly columnar basal cells. Numerous elements exhibit various stages of conversion into mucus-containing goblet-cells. The current produced by the cilia is towards the posterior nares. Intraepithelial migratory lymphocytes are also common. Beneath the epithelium stretches the membrana propria, that varies greatly in thickness; although in certain localities feebly developed, it is usually well marked and measures from 2–10  $\mu$  in thickness. Under pathological conditions its thickness may increase four-

fold or more. In many places the *membrana propria* is pierced by minute vertical channels, the *basal canals*, in which connective tissue cells and leucocytes are found.

The **tunica propria** consists of interlacing bundles of fibro-elastic tissue which are most compactly disposed towards the subjacent periosteum. The

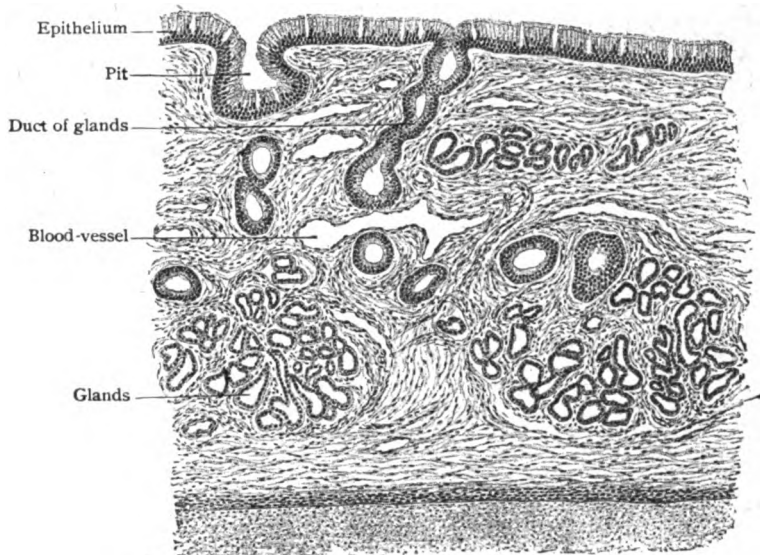


FIG. 429.—Section of respiratory mucous membrane covering nasal septum.  $\times 75$ .

looser superficial stratum is rich in cells and here and there contains aggregations of lymphocytes that may be regarded as masses of adenoid tissue. In certain parts of the nasal fossæ, the stroma of the mucous membrane contains vascular areas composed of numerous intercommunicating blood-spaces that confer the character of a true cavernous tissue. These specialized areas, the *corpora cavernosa*, as they are called, are especially well developed over the inferior and the lower margin and posterior extremity of the middle turbinate, and less so over the posterior end of the upper turbinate. Where typical, they occupy practically the entire thickness of the mucous membrane from periosteum to epithelium, the interlacunar trabeculæ containing the glands and blood-vessels destined for the subepithelial stroma. The blood-sinuses include a superficial reticular zone of smaller spaces and a deeper one of larger lacunæ.

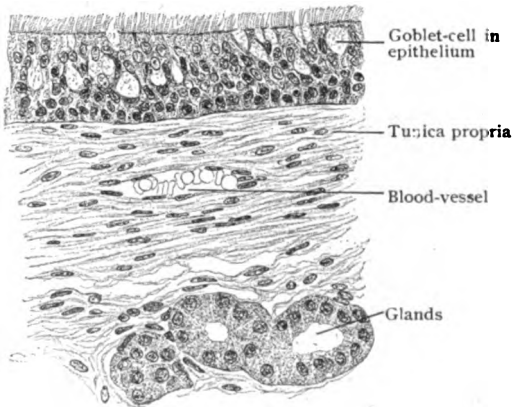


FIG. 430.—Section of mucous membrane lining maxillary sinus.  $\times 280$ . (Preparation by Dr. J. P. Tunis.)

The **glands** of the respiratory region are very numerous, although varying in size, tubo-alveolar in form and, for the most part, mixed mucous in type. The chief ducts open on the free surface by minute orifices barely

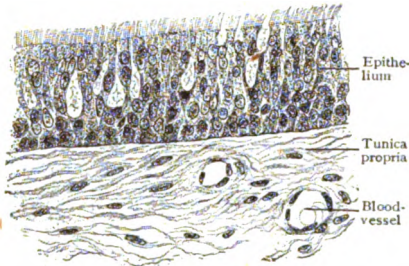


FIG. 431.—Section of mucous membrane lining frontal sinus.  $\times 280$ . (Preparation by Dr. J. P. Tunis.)

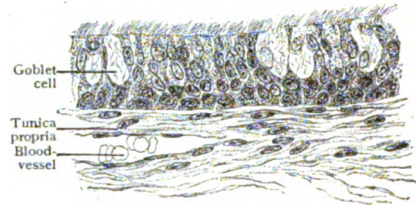


FIG. 432.—Section of mucous membrane lining sphenoidal sinus.  $\times 280$ . (Preparation by Dr. J. P. Tunis.)

distinguishable with the unaided eye. Their deeper ends branch irregularly into tubes that bear the ovoid terminal alveoli. The latter are lined with mucus-secreting cells, between which lie the crescentic groups of serous cells that stamp the glands as mixed (Stöhr). In exceptional cases exclusively serous glands are also encountered.

The nasal fossæ communicate with a number of remarkable cavities, the **accessory air-spaces**, hollowed out within the surrounding bones, which

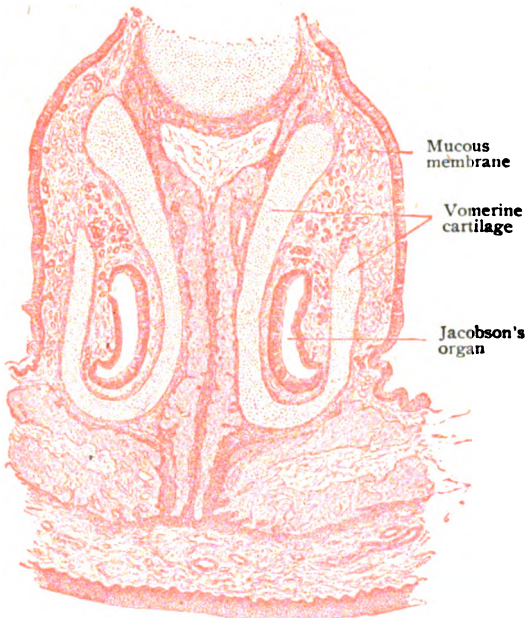


FIG. 433.—Part of frontal section through nasal fossæ of kitten, showing organs of Jacobson.  $\times 20$ .

are filled with air and lined by mucous membrane directly continuous with that of the meatuses. These pneumatic spaces include the *maxillary*, the *frontal* and the *sphenoidal sinuses* and the *ethmoidal air-cells*, all paired and within the corresponding bones. The mucous membrane lining these spaces resembles in general that of the adjoining nasal fossæ, but is very much thinner. It includes a stratified ciliated columnar epithelium, invaded by numerous lymphoid cells, a delicate basement membrane and a tunica propria, poor in elastic fibres and inseparably blended with the periosteum, of which, in fact, it is part. Small scattered mucous glands occur in meagre numbers in the maxillary sinus, being most

plentiful in the vicinity of the opening into the nasal fossa.

**Jacobson's Organ.**—Mention should be made of the rudimentary structure (*organon vomeronasale*) found in man, almost constantly in the new-born child and frequently in the adult, as a representative of the organ of



Jacobson that is present, in varying degrees of perfection, in all amniotic vertebrates (Peter). In many animals possessing in high degree the sense of smell, the organ is well developed and functions, serving possibly as an accessory and outlying surface by which the first olfactory impressions are received (Seydel).

In man the organ is represented by a laterally compressed tubular diverticulum, from 1.5–6 mm. in length, that passes backwards to end blindly beneath the mucous membrane on each side of the nasal septum. The median wall of the diverticulum is clothed with tall columnar cells resembling those of the olfactory region, the characteristic olfactory cells, however, being wanting. The epithelium covering of the lateral wall corresponds to that of the respiratory organ. In many animals possessing acute olfactory sense, branches of the olfactory nerve are traceable to Jacobson's organ in which are found olfactory cells.

### THE TASTE-BUDS.

In the description of the tongue and its papillæ (page 144), reference is made to the presence of specialized epithelial structures, the **taste-buds**, that serve for the reception of gustatory stimuli. These bodies collectively constitute the peripheral sense-organ of taste and as such will be here considered.

As implied by their name, the taste-buds or *calyculi gustatorii* are irregular ellipsoidal or conical bodies, sometimes broadly oval but more often

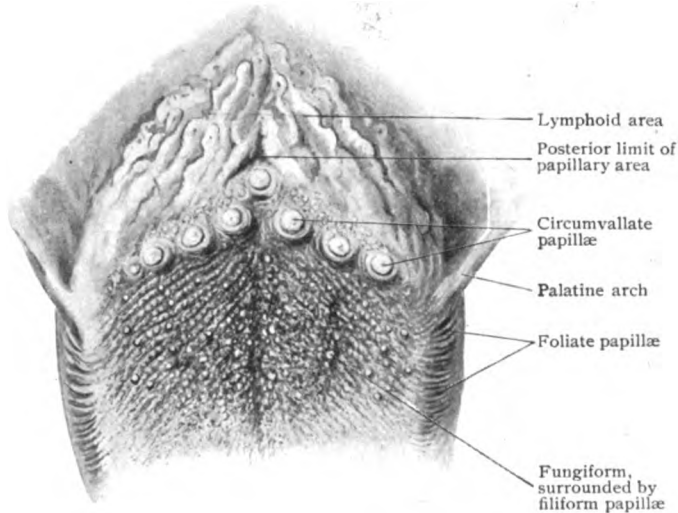


FIG. 434.—Part of dorsum of the tongue, showing varieties of the papillæ; natural size.

slender in outline, and in the adult measure from 70–80  $\mu$  in length and about half as much in breadth. Since they lie entirely within the epithelium clothing the mucous membrane, the necessary access to the interior of the buds is afforded by minute *pore-canals*, each of which, beginning on the free surface at the *outer taste-pore*, leads through the intervening layer of epithelium to the *inner pore* that caps the subjacent pole of the bud. By means of these canals the sapid substances dissolved in the fluids of the mouth

reach and impress the gustatory cells within the taste-buds. Pore-canals are not, however, invariably present, since, as pointed out by Graberg, certain taste-buds remain immature and retain their embryonal form and relations, being broad and conical and in contact with the free surface. In such buds the gustatory cells are few, only two or three, and so superficially placed that a distinct canal is absent. Occasionally double buds are encountered in which two gustatory bodies are implanted by a common base, but partly retain their independence in having separate distal poles, each provided with its separate taste-pore and canal.

The chief position of the taste-buds is within the epithelium lining the sides of the annular groove on the circumvallate papillæ, the buds being more numerous and closely placed on the median than on the lateral wall of the furrow. Their number has been variously estimated, but it is probable that from 100 to 150 represents the maximum for a single papilla. The local-

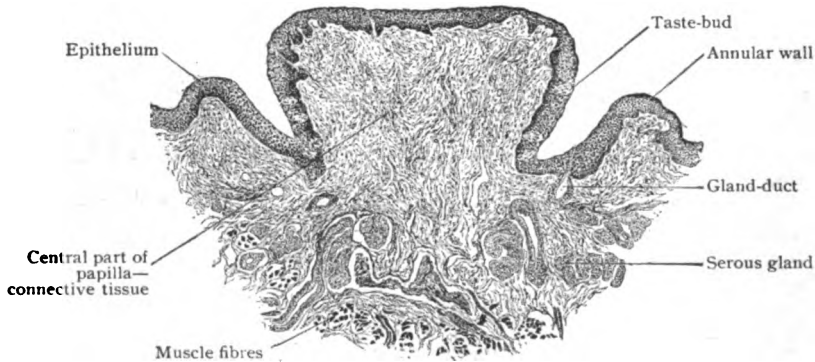

FIG. 435.—Section across circumvallate papilla from tongue of child; the taste-buds are seen within the epithelium.  $\times 45$ .

ity of next importance numerically is the papillæ foliatæ on the sides of the tongue in the furrows of which, even in man, the taste-buds are plentiful. Additional situations, in which, however, the taste-buds are very sparingly and uncertainly distributed, include the fungiform papillæ, the soft palate, the posterior surface of the epiglottis and the mesial surface of the arytenoid cartilages. Within the fungiform papillæ a few buds may be found on the free surface, where the epithelium is thinnest. Over the soft palate their distribution is irregular and uncertain, while in the larynx the buds are limited to the areas covered by squamous epithelium.

Wherever found, the taste-buds consist exclusively of epithelial tissue and, in correspondence with other sense-organs, include two chief varieties of elements—the *supporting cells* and the more highly specialized neuro-epithelium, the *gustatory cells*, among which lie the terminal fibrillæ of the nerve of taste.

The **supporting cells** are represented principally by elongated epithelial elements that occupy both the superficial and deeper parts of the taste-buds of which they contribute the chief bulk. They vary in their individual contour, being lanceolate, wedge-shaped or columnar, according to the modelling to which they are subjected by the neighboring cells. They possess large clear vesicular nuclei that contain little chromatin and, therefore, stain faintly. The position of the nucleus is inconstant, in some cells being near the base and in others in the middle or nearer the apex. The periph-

eral ends of the supporting cells, somewhat blunted and flattened and beset with a narrow cuticular zone, are closely grouped to bound the annular opening of the inner taste-pore, through which project the stiff hair-processes of the gustatory cells. Their deeper or central ends are prolonged into one or more protoplasmic processes which unite with similar extensions of the basal cells, as the peculiar supporting cells at the base of the bud are called. The *basal cells* are modified sustentacular elements, probably epithelial in nature, which occupy the lower fourth of the buds, resting upon the subjacent epithelium and, in turn, affording support for the elongated cells. Although differing in size and details of form, the basal cells are provided with oval nuclei and are generally more or less branched.

The **gustatory cells** are irregularly arranged between the more deeply placed supporting cells and enclosed within a shell formed by the more superficial ones. They are long and fusiform, reaching from the base of the bud to the inner taste-pore, through which the stiff hair-like processes that cap their outer ends project. Their slender nuclei, rich in chromatin and deeply staining, occupy the thickest parts of the cells, which beyond the nucleus are continued in either direction as thin processes. The peripheral ones, as noted, extend not only as far as the inner taste-pore, but through the latter and into the canal by means of the gustatory hairs into which the taste cells are prolonged. The centrally directed ends are usually much the

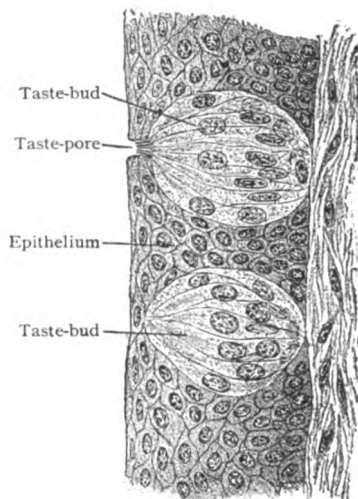


FIG. 436.—Taste-buds in section; upper one shows gustatory hairs projecting into taste-pore.  $\times 440$ .

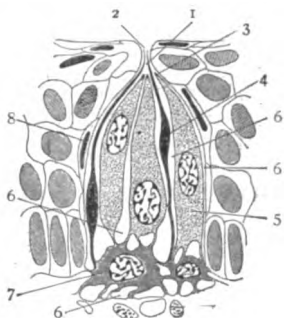


FIG. 437.—Diagram illustrating architecture of taste-bud; 1, pore-canal; 2, 3, outer and inner taste-pores; 4, gustatory cell; 5, supporting cell; 6, lymph-spaces; 7, basal cell; 8, sheath-cell. (*Graberg.*)

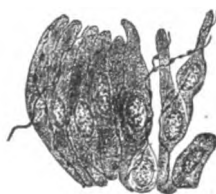


FIG. 438.—Partially separated cells of taste-bud with terminal filaments of gustatory nerve.  $\times 510$ . (*Arnstein.*)

shorter and join the processes of the basal cells. The number of gustatory cells within a single taste-bud varies, in exceptional cases only two or three being present, but more often they are almost as numerous as the supporting cells.

The **nerves** distributed to the gustatory bodies are the fibres of the glosso-pharyngeal, the nerve of taste. From the rich subepithelial plexus numerous twigs ascend into the epithelium, one set going directly into the taste-buds and the other ending within the surrounding tracts of epithelium.

The last set—the *interbulbar fibres*—probably have no concern with the impressions of taste and serve to convey sensory stimuli of other value. After repeated division, their ultimate fibrillæ terminate in minute bead-like endings that lie free between the epithelial cells. The nerves distributed to the taste-buds—the *intrabulbar fibres*—enter at the basal pole. Usually from two to five for each bud, on gaining the interior of the latter they undergo rapid division. A majority of the resulting fibrillæ ascend in tortuous windings towards the apex of the bud in the vicinity of which some end, while others recurve and end at lower levels. The fibrillæ terminate in free, usually minute knob-like endings, that lie between and in close contact with the supporting and gustatory cells. It is probable that in no instance do the nerve-fibrillæ actually unite with the gustatory cells, the relation being one of apposition and not of continuity.

## APPENDIX:

### INCLUDING THE MOST USEFUL METHODS OF HISTOLOGICAL TECHNIQUE.

WITH the exception of the fluid tissues, as blood and lymph, scrapings from organs, as the spleen and the liver, or "teased" fragments separated with needles, as connective tissue or nerve-fibres, the tissues and organs of the body are so compact and opaque that very thin sections, made transparent by artificial means, are necessary for satisfactory microscopical examination. Moreover, in order to display the structural units, it is usually desirable to stain such sections with suitable dyes, so that advantage may be taken of the differences in the color affinity of the various parts of the cells or of the intercellular substances to secure adequate differentiation. After being stained, the sections are rendered transparent and enclosed in some mounting medium, after which they may be preserved often for years without deterioration.

The methods devised or modified by the many engaged in histological work have resulted in the great mass of technical details described in the various books devoted to the subject. Notwithstanding the value of special processes for particular lines of investigation, by far the greater part of histological work is accomplished with a few well-tried standard methods. To describe the most useful of these methods, as carried out in the laboratory, for the assistance of the student who may wish to undertake the preparation of material for microscopical examination, these pages are added. No attempt is made even to mention, much less describe, many excellent methods for particular purposes. The few procedures here given, however, may be depended upon to yield excellent results, when properly carried out, and in the great majority of cases will be found to be adequate for the demonstration of structural details. The student undertaking independently such work for the first time is urged to persevere with the methods here given until he has repeatedly carried them to the successful results of which they are capable. Failures, sure to beset the beginner, should be carefully analyzed and be made to yield experience guarding against their repetition.

#### FIXATION AND PRESERVATION OF TISSUES.

It is evident, that, no matter how carefully subsequent manipulations be conducted, unless the tissue itself be successfully preserved, the finished preparation will not present a trustworthy picture of the normal structure. The tissue must be secured, therefore, as fresh as possible, since in the case of delicate structures, as the epithelium lining the digestive canal, the post-mortem changes occurring within a few hours are sufficient to destroy interesting details. Tissues from the lower animals are readily obtained from the recently killed animal, while still warm and the cells yet alive; those from man are less easily secured, the early autopsy and some favorable operation being the usual sources for the histologist's stock. The manifest desideratum being to retain, as far as possible, structural details in the condition in

which they existed during life, it is necessary to kill the tissue rapidly, otherwise all evidence of certain phases of cellular activity, as the figures of mitotic division, may disappear during the slow death of the cells.

This rapid killing of the tissues, known as **fixation**, is accomplished by plunging the fresh, preferably still warm, material into some suitable fixing solution. The solutions for this purpose are many, since some tissues fix well in certain fluids, while in the same ones other tissues may be only indifferently preserved. The general precautions to be observed in fixing include: material should be in as small pieces as practicable, never over 2 cm. thick and better not more than half as much. Otherwise the penetration is incomplete with corresponding imperfect fixation. The volume of fixing fluid should be many (fifty or more) times that of the tissue. Further, the fluid should be changed whenever it becomes turbid. This often happens within the first few hours after the introduction of the tissue. The latter should not be washed in water on being removed from the animal, but placed directly, with the minimum handling, in the fixing fluid. A cushion of absorbent cotton affords desirable support and insures access of the reagent on all sides. Among the most useful fixing reagents are the following.

#### Zenker's Fluid.

Potassium bichromate . . . . .	2.5 gm.
Sodium sulphate . . . . .	1 gm.
Mercury bichloride . . . . .	5 gm.
Distilled water, warm . . . . .	100 cc.

Just before using, to each 20 cc. of the above solution add 1 cc. of glacial acetic acid.

Place small pieces of tissue in a generous amount of the fluid for 10-24 hours; then wash in running water for 12-24 hours; transfer for a few hours to alcohol of increasing (50, 65, 80) strength, in the strongest of which keep until used. This fluid is an excellent fixative for cell-structure, but, in common with other solutions containing sublimate, has the disadvantage of requiring subsequent special treatment to remove the crystals of the mercuric chloride that are commonly deposited throughout the tissue. The removal of the deposits of mercury is conveniently effected by placing the unstained wet-cut sections for 15 minutes in iodine alcohol (3 drops tincture of iodine to 15 cc. 90 per cent. alcohol). An additional 15 minutes in a dilute solution of sodium hyposulphite (made by adding 10 cc. of a 2.5 per cent. aqueous solution of the salt to 100 cc. distilled water) insures, in turn, the removal of the iodine. If, however, the tissue is to be stained in bulk and cut in paraffin, the deposits of mercury must be eliminated by adding the iodine (from .25 to .5 per cent. of Lugol's solution) to the alcohol in which the tissue is kept after fixation. The manipulator must assure himself, preferably by an examination of a free-hand section, of the disappearance of the deposits, otherwise, their removal after the tissue has been embedded in paraffin is troublesome and often impracticable.

#### Tellyesnizcky's Fluid.

Potassium bichromate . . . . .	3 gm.
Distilled water . . . . .	100 cc.

To which is added just before using

Glacial acetic acid . . . . .	5 cc.
-------------------------------	-------

Moderate sized pieces of tissue remain in the solution 18–24 hours; then are washed in running water 3–5 hours; and carried through 50, 70 and 95 alcohol, each for one day. This fluid is excellent for large embryos.

#### Müller's Fluid.

Potassium bichromate . . . . .	25–30 gm.
Sodium sulphate . . . . .	10 gm.
Water . . . . .	1000 cc.

This classic fixing fluid requires prolonged action, from two to eight weeks or longer, and a large excess in proportion to the volume of the material. During the first week, the fluid should be changed daily, or in the beginning oftener if it becomes turbid; thereafter, each week. After a variable time, the tissue is washed in running water for 12–24 hours and then transferred to 70 alcohol and placed in the dark, with occasional renewal of the spirit. If, however, the material be nervous tissue intended for subsequent treatment with special methods, such as Weigert staining; it is transferred, after slight rinsing, directly to the alcohol. This classic fluid, although hardening evenly and without shrinkage large masses, as entire small brains and cords, has the disadvantage of being not only tedious but also lacking in accurate nuclear fixation. Since, however, it is the basis of several combinations of value, its preparation as a stock solution is desirable.

#### Orth's Fluid.

Müller's fluid . . . . .	100 cc.
Formalin (40 p.c. solution) . . . . .	10 cc.

The two solutions are mixed just before using and the tissue, cut into pieces 1 cm. or less in thickness, allowed to remain not over four days, with two changes. Thorough washing in running water for 18–24 hours is important, followed by 80 alcohol. This fluid yields excellent results, the cellular fixation being satisfactory and the required time not excessive. Small pieces of tissue, not exceeding 5 cm. in thickness, may be fixed and hardened within a few hours if kept at a temperature of 45° C. in an oven.

#### Formalin Solution.

Formalin (40 p.c. solution) . . . . .	10 cc.
Water . . . . .	90 cc.

Objects remain for 48 hours, or longer, and are then transferred to 95 alcohol for at least two days. This 4 per cent. aqueous solution of formaldehyde has convenience as its chief recommendation, since, when used alone, it is deficient as an accurate fixative and often does not favor staining. Where, however, the gross features of a specimen are to be supplemented by microscopic examination, formalin offers a satisfactory compromise for the anatomist or pathologist and the histologist. Another important use of this formalin solution should be remembered, namely, the preservation of embryos. The reagent is so readily obtained, that the obstetrician, upon whom the embryologist must depend for his supply of human material, can secure, with little trouble, valuable specimens which are too often lost.

#### Flemming's Solution.

Osmic acid (2 p.c. aqueous solution) . . . . .	4 parts.
Chromic acid (1 p.c. aqueous solution) . . . . .	15 "
Glacial acetic acid . . . . .	1 "

The mixture is best prepared just before using, although it will keep for some time without serious deterioration, if tightly stoppered. Owing to the cost of the osmic acid, the solution should be used with economy. The tissue, in pieces not over a few millimeters in size, remains in the mixture for 1-2 days, or even longer; is then washed in running water for 12-24 hours and transferred, by ascending strengths, to 80 alcohol, in which it may be preserved, the spirit being changed when cloudy. This reagent, although somewhat expensive, is of great value in studies concerning cell-structure and mitosis, being one of the most reliable and accurate means of fixation. Its power of uniform penetration, however, is very limited; it is necessary, therefore, to use pieces as small as possible, otherwise the desirable action of the osmic acid will be confined to the peripheral zone, whilst the deeper parts of the tissue will be influenced chiefly by the chromic acid alone.

**Absolute Alcohol.**—This reagent is useful for fixing and hardening certain tissues, as glands and blood-vessels, which remain in it at least 24 hours, although the time may be extended to several days. The alcohol should always be changed within 3-4 hours and the tissue supported by a layer of absorbent cotton. It is important that the alcohol be approximately "absolute," since, even when of 96 per cent. its action is very different.

The **hardening** of the tissues preparatory to cutting sections in the usual way, that is, after interstitial embedding, is of much less consequence than accurate fixation, since, unless the material be unduly hardened, the consistence of the mass sectioned is largely determined by that of the supporting material—the celloidin or paraffin.

#### EMBEDDING AND CUTTING SECTIONS.

Having secured properly fixed and preserved tissues by one or more of the preceding methods, such tissue must be cut into thin sections, stained, rendered transparent and mounted before it can be satisfactorily examined under the microscope. Whether sectioning or staining takes precedence depends upon the character of the object and the end in view. If the object be an embryo or some structure for whose study it is desirable to secure a series of sections in strict sequence, or sections of the least possible thickness, the *paraffin method* is chosen. If, however, these particular features are unimportant and the production of thoroughly good preparations for general histological study is the result in mind, the *celloidin method* offers advantages and is usually selected. Further, if it is desired to cut serial sections of tissue requiring only a single staple stain, as carmine or hematoxylin, to demonstrate satisfactorily its general structure, much labor is saved and risk of losing sections avoided by staining the object *in toto* before sectioning in paraffin. Unless this is done, the supporting paraffin must be removed by a solvent (xylol) and the sections, previously fixed to the slide, stained in position, a procedure requiring considerable time and care when long series are to be treated. Since, except for embryos and special work, the retention of the sections in strict sequence is not usually necessary, staining in bulk is much less frequently followed than staining after cutting. When cut in celloidin the sections may be conveniently treated in large numbers at one time and contrast dyes employed with little additional trouble.

Whichever method be chosen, celloidin or paraffin, the fundamental principle is the same—the complete impregnation or saturation of the object with the embedding mass, so that when the tissue is cut into thin sections even the most delicate and isolated parts shall be retained in position by the



support of the mass. This constitutes *interstitial embedding*, as distinguished from *superficial*, by which the object is merely surrounded with some material, as tallow and wax, that affords superficial support but does not bind together the structural components. In either case, whether celloidin or paraffin, the tissue must be carefully dehydrated before being placed in the fluid embedding material. Upon the proper carrying out of this step depends the success or failure of the embedding, since if water still remains within the object, the embedding substance fails to penetrate its deeper parts and the interstitial embedding is incomplete.

Dehydration must be thorough, for unless all the water be extracted from the object the subsequent penetration of the embedding substance will be imperfect and the sections uneven or torn. This essential step is effected by alcohol. Assuming that the tissue has been stored in 70 or 80 spirit, the usual strength for this purpose, it is transferred to a tightly-stoppered wide-mouth bottle, of 200 cc. capacity, containing 95 alcohol, for 24 hours. It is then placed in a similar bottle, of 100 cc. capacity, containing absolute alcohol, for 24-48 hours, during which the absolute alcohol should be changed. The exact length of time needed for complete dehydration varies with the density and the size of the object, delicate small objects, such as small embryos, evidently requiring much less time than compact and large ones. It is always better to allow ample time for the extraction of the water, since undue haste in this particular may require tedious retracing of subsequent steps.

**Celloidin Embedding.**—As now supplied by Schering, celloidin is purchased in small hard pieces, or "shreds," which are packed, surrounded by water, in ounce lots in wide-mouth bottles. Although immersed in water, the celloidin does not absorb the fluid and, after drying its surface, is really free from moisture and desiccated. In order to remove the adherent water, the shreds are allowed to dry in the air, protected from dust, or they are first washed with alcohol to hasten the process. When perfectly dry, the shreds of celloidin are broken into small pieces and dissolved and solutions prepared as follows:

*Solution A.*—Dried celloidin 16 grams, dissolved in mixture of absolute alcohol and ether, 100 cc. each. When completely dissolved, which requires some days with occasional stirring, the solution has the consistence of thick syrup; it is necessary, therefore, to prepare a less concentrated one. *Solution B* is made by taking half of solution A and diluting with 50 cc. each of absolute alcohol and ether. *Solution C*, made in a similar way by taking half of B and diluting with 25 cc. each of absolute alcohol and ether, is useful for dense tissue, as it insures thorough penetration. It is, however, often omitted, the object being placed at once into B.

The tissue having been thoroughly dehydrated, the actual embedding is accomplished by the following manipulations:

1. Dehydrated tissue placed in mixture of equal parts of absolute alcohol and ether for 24 hours.
2. Transfer to thin (C) celloidin solution for 24 hours.
3. Transfer to medium (B) celloidin solution for 24-48 hours or longer.
4. Transfer to thick (A) celloidin solution for at least 24 hours; may remain in this for much longer time, often with advantage for a week if the object be large.
5. Mount on small blocks of vulcanized fibre, one surface of which is first coated with a thin layer of thick celloidin solution. After arranging the object in position, making sure that it rests firmly on the block by a broad

surface, it is necessary to pour over it additional thick celloidin to insure its complete enclosure. Expose to the air for a few minutes, until the celloidin has set and the object is securely attached.

6. Place block with object in 80 alcohol to harden celloidin, which will require 12-24 hours, until sections are cut. Blocks are stored in 80 alcohol, where they may remain for years. Should the embedded object separate from the block, as sometimes happens during cutting, the surface of the block must be cleaned, a new layer of thick celloidin applied, and the hardening in 80 alcohol be repeated. In general, the smaller the object and the harder the celloidin the thinner can sections be cut. The advantages of the celloidin method include: (1) avoidance of heating the tissues, which if injudiciously done may distort or altogether ruin them; (2) simplicity of procedure, neither embedding oven and accessories nor close attention being required; and (3) ready application of various methods of staining. The chief disadvantages of the method are: (1) difficulty of obtaining extremely thin sections; (2) impracticability of preserving the sequence of sections, unless special means are employed; (3) length of time ordinarily required to prepare object for sectioning. All in all, the celloidin method is to be preferred for routine histological work of the beginner, although for many special purposes and for embryological material it is much less satisfactory than paraffin.

**Paraffin Embedding.**—Although invaluable for work demanding serial or very thin sections, the paraffin method requires some means of maintaining a constant temperature. With care and attention this may be done with a simple water bath, but for serious work a suitable embedding oven is almost a necessity. This should be made of copper, have double walls enclosing a water-space, and be supplied with a suitable door on one of the larger sides of the rectangular box. The water-space must be provided with at least one opening large enough to admit the bulb of a gas-regulator and the supporting perforated cork. A second aperture, with tubular collar, should lead through the water-space from the top into the interior of the warm chamber and serve for the passage and support of the thermometer. The bulb of the latter should occupy the approximate centre of the oven. One or two perforated copper shelves, not less than 6 cm. apart, provide space for half a dozen or more embedding capsules. Since the temperature to be maintained is from 50-55° C., some form of "micro" burner is necessary. If possible, a "blue flame" burner should be used to avoid the gradual accumulation of soot deposited from the ordinary gas jet. Even the miniature Bunsen burners often give too much heat unless the bottom of the oven be raised sufficiently high. Adequate protection of the flame from draughts is important. An efficient regulator to control the flow of gas is, of course, necessary. The usual inexpensive form (Reichert's) will answer, a daily variation of one or two degrees ordinarily doing no harm. Not infrequently the by-pass is too large and the opening must be reduced before a satisfactory temperature is maintained. On installing a new oven, usually some days are required in testing and adjusting it before valuable tissue should be entrusted to prolonged embedding.

Paraffin should be of two kinds, one—the soft—with a melting point of 45° C., and the other—the hard—melting at 54° C. It is important that the paraffin be of suitable quality, that supplied by Grübler being recommended. The quantity used is so inconsiderable, that the slightly increased cost is of little consequence in comparison with the satisfaction of having a dependable article. Neither of the above grades is used alone, but a mixt-

ure of the two, so proportioned that the resulting mass has a melting point of about  $52^{\circ}$  C. The proportions vary so with the season and temperature of the laboratory that no exact figures can be given, but, in a general way, about equal parts will yield a satisfactory mass for ordinary use. When the object is relatively hard and very thin sections are desired, harder paraffin is employed than usual. A nice adjustment of the consistence of the embedding mass to the character of the tissue and the particular purpose in view is an important factor in securing satisfactory results.

The manipulations in paraffin embedding are as follows :

1. The thoroughly dehydrated tissue is transferred from absolute alcohol to:

2. Chloroform, 4-24 hours, depending upon the size of the object, small delicate embryos requiring often only 1-2 hours. When the alcohol is completely replaced, the tissue floats below the surface or sinks.

3. Saturated solution of paraffin, in chloroform, 6-24 hours, depending upon the size and density of the object.

4. Melted paraffin in small open porcelain or glass round-bottom dish, 2-12 hours, in oven at  $52^{\circ}$ - $54^{\circ}$  C. The paraffin must be carefully guarded against overheating to prevent injury to the tissue. After 1-2 hours, the object should be transferred to a second capsule with fresh melted paraffin. So long as chloroform is present, the embedding is incomplete. In order to test these conditions, a rod may be judiciously heated and held for a few moments in the paraffin in the vicinity of the object, when, if still present, the chloroform is liberated as small bubbles. When the chloroform has been driven off, the object is transferred once more to fresh paraffin preparatory to embedding. This last transference is delayed until there is reason to believe that the object is completely saturated with the embedding mass and free from chloroform, since the presence of the latter is unfavorable to the desired homogeneity of the embedding mass.

5. Embedding is accomplished by surrounding the object with melted paraffin in a folded paper box or, still better, an adjustable metal frame. When an embedding frame is employed—and its convenience recommends it—it is adjusted to suitable size and placed upon a piece of glass resting on the flat bottom of a deep dish. The frame and sheet of glass should be warmed to prevent the too rapid solidifying of the paraffin. The object may be transferred to the embedding box by pouring when the box is filled, or by transferring with a warmed loop of platinum wire. Before the paraffin ceases to be fluid, the position of the object, with regard to the desired planes of section, must be carefully adjusted by means of heated needles.

When the proper orientation of the object has been secured, cold water is poured into the dish, care being taken neither to shake the object, and thereby disturb its position, nor to allow the water to rise above the sides of the frame. The mass is allowed to remain for a few moments, until the surface of the paraffin is completely covered by a thin pellicle of congealed substance. When this has occurred, the water is very gently added and the entire frame and contents submerged. If the water be allowed to come into contact with the still fluid paraffin, cavities containing water may be imprisoned within the block—an accident that may interfere with proper cutting. In order to secure homogeneous paraffin, a most desirable feature for satisfactory sectioning, it is necessary to solidify the melted mass as rapidly as may be done with prudence. If it be allowed to cool slowly, crystallization occurs and the mass becomes opaque and friable.

After thorough cooling and hardening, the frame is removed and the mass, if still adherent to the glass plate, carefully loosened. Tissue properly embedded in paraffin may be kept for years without deterioration, if guarded against dust and excessive temperatures. Indeed, delicate objects, as embryos, are much more satisfactorily preserved after being carefully embedded than if kept for a long period in alcohol. It is often convenient and economical to embed two or even more small objects at one time in the same block, care being taken to mark, by some ineffaceable label, the character and cutting planes of the enclosures.

Several methods of double embedding have been devised with a view of combining the advantages of celloidin with those of paraffin. For particular lines of work they are valuable and fairly satisfactory. Their description will be found in the special books on microscopical technique.

**Cutting Sections.**—Although thoroughly adequate sections may often be obtained "free-hand" with a razor or suitable knife, for the most satisfactory results an accurately constructed microtome is a necessity. If possible, a medium-sized instrument—neither too small and light nor too large and cumbersome—should be chosen. As an all-round microtome, the type made by Schanze leaves little to be desired, as it may be used with satisfaction for all kinds of cutting, wet or dry, and is accurate and simple. If only one knife is available, one of the Weigert form, with a straight slotted shank at an angle, is to be preferred. If much "ribbon-cutting" is to be done, a special holder should be provided, by which the knife can be clamped at different points and successive portions of the blade be brought into use. For serial sections, the Minot rotary microtome is most convenient.

**Celloidin sections** are cut wet, both object and knife being kept continuously moistened with 80 alcohol. Preparatory to using the microtome, it is advisable to remove the superfluous embedding material with a sharp razor or knife, leaving a narrow zone, 1–2 mm. in width, surrounding the object. One or more sections across the trimmed block are then made to expose the surface to be sectioned. The fibre-block bearing the embedded tissue is now securely clamped in the object holder and adjusted as to plane of section and height. It is important not to raise the object too much since, if the removal of a slice of too great thickness be attempted, the entire mass of celloidin may be torn from the fibre-block. The desired level of the tissue should be gained, therefore, by repeated thin sections, thereby giving the opportunity to adjust the knife and object in the mutually most favorable position. The knife is set at such an angle that, after striking the corner of the object, it passes through the latter obliquely and completes the section before coming to the end of the "track." The section is removed from the blade and placed in a dish containing 80 alcohol. The knife is returned to the beginning of its track, the object raised by the micrometer screw to the desired thickness of the next section, and the blade again drawn through the block with a steady unhesitating pull.

**Paraffin sections** are cut dry. When the object is large and not delicate, the paraffin block may be clamped directly in the jaws of the object holder. If, however, the object is of small size and great delicacy, as an embryo, the block of paraffin with the embedded tissue is fastened to one of the metal "tables" supplied with the microtome. This is best accomplished by covering the surface of the metal disk with a thin layer of melted paraffin, on which the embedded object is firmly pressed, additional security being given by running a heated knife or other convenient tool around the base of the block. After thorough cooling, the block is ready for trimming prepar-

atory to sectioning. This should be done with a sharp knife, care being taken that in shaping the block the slices of paraffin are not too thick, lest the enclosed object be subjected to undue pressure. While all superfluous embedding mass should be cut away, the trimming must not be too close, a margin of paraffin, one or two millimeters broad, being left around the object.

For ordinary purposes, the knife, scrupulously clean, is set at angle and carried obliquely through the tissue. For routine examinations, sections .007-.010 mm. thick will be sufficiently thin, particularly when of some size. If, however, cell-structure and other details requiring the use of high amplification are in view, the sections can not be too thin. Under the most favorable conditions, it is possible to obtain sections of small size which are not over .001 mm. in thickness.

If the consistence of the paraffin and tissue be just right and the sectioned surface not too large, the sections will lie flat and smooth on the knife, from which they are removed as cut and placed on a clean sheet of writing paper. Protected from dust and excessive temperature, they may be put aside for mounting at some future time. If, however, they be allowed to lie too long, particularly in a warm temperature, there is danger of their sticking to the paper; early mounting is, therefore, to be recommended. After the sections desired at the time have been cut, the block may be put aside for subsequent use. If the paraffin is hard the sections will roll up on the knife. This annoying feature may be prevented by lightly holding down the edge of the section with a small sable brush in the left hand as the knife is drawn through the tissue. In this manner flat sections may often be secured when, without the manipulation, they would be tightly and hopelessly rolled.

When the paraffin is too hard, still contains chloroform, or lacks homogeneity, it often is brittle and crumbling, so that the sections break before completed. Too little consistence of the embedding mass is also unfavorable for satisfactory cutting, since, if the paraffin be too soft, insufficient support is given the sections, which then come off more or less wrinkled and compressed with corresponding distortion of the object. If the compression is not excessive, the sections may often be restored to their normal form by floating them on judiciously warmed water, where they expand. Obviously care must be taken that the temperature of the fluid is not sufficiently high to dissolve the supporting paraffin. The temporary reduction of the temperature of the room, by opening an adjacent window, frequently serves to correct undue softness of the embedding mass. Similarly, bringing a gas-flame, or other source of heat, into the vicinity of the microtome sometimes enables satisfactory sections to be made with over-hard paraffin. Care must be observed to keep, by an occasional touch with a dry cloth, the knife clean and free from adherent particles of paraffin, especially the under surface of the cutting edge. If this precaution be neglected, an attached fragment of paraffin may ruin important sections by causing fissures and breaks. A properly ground and really sharp knife is an indispensable requisite for the production of successful preparations.

**Serial sections** are most easily cut in the form of "ribbons." While, of course, their sequence may be preserved by carefully arranging isolated sections in the order in which they are cut, much time and trouble are saved by adopting the ribbon-method, whereby the sections are caused to adhere and form a long chain. The method is particularly suitable for small and delicate objects stained *in toto*, as embryos, which are to be entirely cut into

sections. The knife is set at right angle to the microtome track and the paraffin block so trimmed (the desired plane of section being first secured by the microtome adjustments) that the two long sides of the rectangular block are exactly parallel, not only with each other but also with the edge of the knife. Since the mounted sections will be separated by twice the width of the border of paraffin surrounding the object, the block should be trimmed as close as possible to the tissue, a thin covering of paraffin, however, being left over the upper surface of the object.

Everything being in readiness, the object is raised to a height sufficient to allow several sections of the overlying paraffin being made without involving the object. After cutting a few sections that include the entire surface of the block, the knife is returned to the beginning of the track, the block elevated by the micrometer screw, and, without removing the section, the blade drawn across the block for the next section. If the consistence of the paraffin is proper, the last cut section pushes the preceding one before it on the blade and, at the same time, adheres to it. The manipulation is repeated and, if all goes well, each succeeding section adheres to its predecessor and advances the chain. For embryological work, in which ribbon-cutting is particularly useful, the sections should be of uniform thickness, .01 mm. being satisfactory for most purposes. Sections less than .005 mm. in thickness seldom yield good ribbons. The same is true of very thick ones. A small sable brush held in the left hand is useful in keeping the first few sections flat, in brushing away shreds of paraffin, and in supporting the ribbon after it has become too long to lie on the knife. Under favorable conditions and with careful support, ribbons one or two feet in length, or indeed much longer, may be cut readily. With the ordinary sliding microtome, it is safer to remove the chains to an adjacent sheet of clean paper when they reach a length of ten or twelve inches, care being taken that the last cut two or three sections remain undisturbed on the knife to guide the succeeding ones. The under surface and edge of the knife must be kept free from particles of paraffin, otherwise breaks and fissures in the sections may occur.

As the cutting proceeds, it may become necessary to retrim the block, since, unless the sides have been cut strictly vertical and not, as they often are, slightly sloping, the border of paraffin becomes gradually excessive. Then, too, the front and back edges of the block must be parallel, otherwise the ribbon will curve instead of remaining straight. After the cutting is well under way, any considerable change in the plane of section should be avoided if it is important to secure a complete series, as such change usually necessitates the loss of several sections. If the embedding mass be too hard, the sections will not adhere and, of course, the ribbon not form; if too soft, the sections will wrinkle and compress and, perhaps, not advance. These defects may often be overcome by appropriate changes in the temperature of the room, or by judicious local application of cold or heat to the block itself. When other means fail, coating the block with paraffin of appropriate consistence often affords relief. Now and then, especially when using rather hard paraffin on a cold, bright, dry day, the atmospheric conditions are such that sufficient electricity is liberated during sectioning to disturb seriously the sections. The latter may break apart and shorter or longer pieces of the ribbon attach themselves to one another or to the microtome or knife. A repetition of this exasperating accident may usually be avoided by charging the atmosphere with moisture, often conveniently accomplished by liberating steam.

## STAINING.

The object of staining is to bring out the various structural components of the tissues by taking advantage of their selective affinities for certain dyes. The differentiation usually sought has as its first object, the display of the nucleus; next, the tingeing of the cytoplasm; and thirdly, the exhibition of the intercellular substances. Of the large number of staining methods which from time to time have been devised to meet the requirements of particular lines of work, only a few of the most reliable and generally useful will be here given. For the ordinary needs of the histologist, staining with hematoxylin, followed by eosin, leaves little to be desired, since, when successful, the nuclear differentiation is sharp while the cytoplasm and intercellular substances are sufficiently tinged to produce clear and instructive pictures. When, as in the case of embryos, it is convenient to stain in bulk before sectioning in paraffin, borax-carminum will be found a most reliable dye, possessing penetration and uniformity of action in a highly satisfactory degree.

**Ehrlich's Hematoxylin.**

Hematoxylin crystals (Grübler) . . . . .	2 gm.
Absolute alcohol . . . . .	100 cc.
Distilled water . . . . .	100 cc.
Ammonium alum . . . . .	in excess
Glycerine . . . . .	100 cc.
Glacial acetic acid . . . . .	10 cc.

A. Dissolve the hematoxylin in the absolute alcohol and let stand in loosely corked bottle for a week, where the sunlight may reach it.

B. To the distilled water add ammonium alum to excess. Add A to B, while stirring vigorously. After several days add the glycerine and the glacial acetic acid and place the stain, in a corked bottle, in some suitable position insuring exposure to direct sunlight. During the next two weeks uncork for several days at a time. Direct sunlight is important. After three months the stain has "ripened" sufficiently for use. If kept in a well-stoppered bottle, with an excess of alum, the reagent retains its staining powers for years and, indeed, improves with age. Although requiring a long time until ready for use, Ehrlich's hematoxylin is most satisfactory, staining well after all the usual methods of fixation and, with proper precautions, being permanent.

This, as all other hematoxylin stains, should be filtered immediately before using. Depending upon the age of the solution and, to some extent, upon the method of fixation, sections require to be left in the stain from 5 to 10 minutes. They are then washed thoroughly in running water for one or two hours. If deeply colored they may be placed in a dish of 70 alcohol, acidulated by the addition of 5 drops of hydrochloric acid to each 100 cc. of alcohol. The sections remain in the acid bath, in which they turn reddish, so long as they discharge color, keeping them moving and not allowing them to adhere. During subsequent washing the blue color is restored, becoming brighter as the washing progresses. While the acid alcohol may be omitted with sections not too deeply tinted, full staining followed by the acid alcohol yields sharp nuclear differentiation and brilliant pictures. The employment of the acid bath may be recommended, therefore, as a routine

procedure. Since the permanency of all hematoxylin preparations depends upon the elimination of every trace of acid, prolonged and thorough washing is essential, otherwise fading will occur. If after short washing the sections are placed for a few minutes in water, to which a few drops of ammonia have been added, and then washed thoroughly in, preferably running, water, permanency of the staining is assured.

#### Böhmer's Hematoxylin.

Hematoxylin crystals (Grübler's) . . . . .	1 gm.
Absolute alcohol . . . . .	10 cc.
Ammonium alum . . . . .	10 gm.
Distilled water . . . . .	200 cc.

Dissolve the hematoxylin in the absolute alcohol and keep in stoppered bottle for 24 hours. Dissolve the alum in the warm distilled water. When cool, gradually add the dissolved hematoxylin while stirring. Place in an open wide-mouth bottle or dish, protected from dust, for one week, when, after filtering, the stain is ready for use. Keep in a tightly corked bottle and filter the required quantity on using. Immersion from 10 to 30 minutes usually suffices to stain to the required degree. This solution stains well, although not uniformly so intensely as Ehrlich's, and, if the sections are thoroughly washed, yields permanent results.

#### Delafield's Hematoxylin.

Hematoxylin crystals (Grübler's) . . . . .	4 gm.
Absolute alcohol . . . . .	25 cc.
Ammonium alum . . . . .	52 gm.
Distilled water . . . . .	400 cc.
Glycerine . . . . .	100 cc.
Methyl alcohol . . . . .	100 cc.

The hematoxylin is dissolved in the absolute alcohol and the alum in the heated distilled water. After the alum solution has cooled, the hematoxylin is slowly added while stirring and the fluid allowed to stand in a wide open vessel, as a beaker or jar, protected from dust but exposed to light and air, for about 15 days. Filter and add glycerine and methyl alcohol. Expose to the light until the stain acquires a dark purplish tint, then filter and keep tightly stoppered. The advantages of Delafield's hematoxylin are less for coloring sections than for staining tissue in bulk. For mass-staining, the freshly filtered solution is diluted with five to ten volumes of distilled water, in which the pieces of tissue remain from 24 to 48 hours, or longer, until uniformly darkly tinted throughout. The stained tissue is rinsed in distilled water and placed in acid 70 alcohol (5 drops hydrochloric acid to 100 cc. alcohol) from 4 to 8 hours. After this differentiation the tissue must be thoroughly washed in running water for 12 to 24 hours to remove every trace of acid and to bring out the rich blue color.

**Contrast staining after hematoxylin**, especially when the latter has been limited chiefly to the nuclei, adds much to the effectiveness of the preparation. Such double staining may be accomplished by treating the hematoxylin sections with solutions of acid fuchsin, Congo red, or eosin. The latter answers well and is convenient. The most satisfactory results are



obtained with "water soluble" eosin (not "alcohol soluble"), of which a .5 per cent. solution in 70 alcohol is preferable, the sections remaining until decidedly rosy, usually a matter of 1-2 minutes. They are then transferred to 70 alcohol, in which they remain so long as clouds of eosin are discharged; after one or two changes of 70 alcohol and no further color is given off, the sections are passed as rapidly as thorough dehydration will permit through 95 alcohol, then cleared in carbol-xylol, and mounted in balsam, as presently described.

#### Grenacher's Borax-Carmine.

Carmine (No. 40) . . . . .	3 gm.
Borax . . . . .	4 gm.
Distilled water . . . . .	100 cc.
70 alcohol . . . . .	100 cc.

The carmine and borax are rubbed together in a mortar in the warmed distilled water until dissolved. After cooling, the alcohol is added and the unfiltered solution placed in a stoppered bottle. The stain is not ready for use until it has stood for several weeks. The quantity required for staining, which may be repeatedly employed, should be decanted and filtered before using. Although sections may be stained with the solution, its chief value is for mass-staining, since its powers of penetration and uniform coloration are excellent. Assuming that the solution is to be put to this use, the object is transferred from 70 alcohol to the undiluted stain, in which it remains 24-48 hours and is then directly placed, that is without washing, into acid alcohol (8 drops of hydrochloric acid to 100 cc. of 70 alcohol) for 8-24 hours, or longer, depending upon the size and density of the object. The purpose of the acid bath is to differentiate the nuclei and fix the stain. Deep staining and thorough differentiation produce the most satisfactory preparations. After two changes of 70 alcohol, the object remaining from 2-3 hours in each, it is dehydrated in 95 and absolute alcohol preparatory to embedding.

**Contrast staining after carmine** may be carried out with .5-1 per cent. alcoholic solutions of such aniline dyes as methylene blue, methyl violet, or methyl green. The labor and time involved in staining serial sections on the slide, as of course must be done, as well as the limited endurance of the aniline tint, ordinarily deter from double staining. Although the second dye yields pleasing preparations, unless there is some special reason to warrant the additional labor, the contrast color may be omitted with serial sections of tissues stained in bulk.

**Staining sections on the slide** is necessary when it is desirable to tinge uncolored paraffin sections, or to add a contrast tint to those stained *en masse* before cutting. Since the paraffin must be removed from the section before the stain can act, it is evident that the support afforded by the embedding mass must be replaced by that of the slide before the paraffin may be removed with safety. The sections must, therefore, be fixed to the slide, so that subsequent manipulations will not disturb even the most delicate and isolated parts of the sectioned object.

All slides and cover-glasses used for mounting preparations must be thoroughly cleaned. This is readily accomplished by soaking the slides and cover-glasses in strong sulphuric acid for 5-10 minutes, care being taken to immerse the pieces separately and not to allow them to adhere. They are transferred, piece by piece, to a large vessel containing water and washed

thoroughly under the tap, with occasional separation and agitation until all traces of the acid are removed. The slides and covers are then placed in 95 alcohol and carefully dried by wiping with a clean linen cloth of appropriate thickness, from which all sizing and starch have been removed by previous laundering. Neglect to provide properly cleaned slides and covers mars many valuable preparations.

The method of **fixing to the slide** should be made, if possible, to serve an additional and important purpose, namely, to expand and to flatten out the paraffin sections, which very often are slightly compressed and wrinkled. To mount them in this condition may seriously interfere with their later use, as in the case of serial sections of embryos in making reconstructions. When the fixed sections are not to be treated with watery solutions, a convenient and satisfactory means is the *gum method*, carried out as follows: Of a saturated aqueous solution of best gum arabic (a crystal of thymol being added to prevent the growth of fungi) about 12 drops are added to 30 cc. of distilled water and thoroughly shaken. The clean slide is flooded with the solution, care being taken that the solution does not run over the edges, and the sections are floated on the liquid, all parts of the sections being separated from the slide by a stratum of the solution. When all the sections are arranged, the slide is placed on a warm metal plate and very cautiously heated, the temperature never being allowed to rise to the melting point of the paraffin, the object being to secure the expansion of the sections while swimming on the gum solution. They expand in a few minutes. The excess of fluid is then drained off, the sections are finally rearranged with a needle, and the slide, protected from dust, is set aside to dry. The latter must be thorough, and requires, therefore, some hours, a good plan being to leave the sections undisturbed over night.

The *albumen-glycerine mixture* is another excellent fixative, which has the advantage over the gum solution of being unaffected by water. This consists of equal parts of the strained white of a fresh egg and glycerine, thoroughly stirred with a glass rod. A small drop of the fixative is placed on the slide and spread out as evenly and thinly as possible. A number of slides may be prepared, dried, and suitably stored for subsequent use. The albumen-coated slide is now covered with a thin stratum of water, the sections arranged, and the slide then placed on the top of the oven, or other appropriate warm location, where the sections expand and the water evaporates.

*Removing the paraffin* is the next step preparatory to staining sections on the slide, whatever method may have been employed to secure their attachment. To accomplish this the slides with the securely affixed sections are immersed for a few minutes in xylol, which promptly dissolves the paraffin and leaves the cleared sections in place, freed from the embedding material. The slides are then transferred to 95 alcohol to displace the xylol, after a few minutes passed to fresh alcohol, and then carried through 70 per cent. spirit into the staining fluid, if that be an alcoholic solution, or into water, in case the stain be chiefly aqueous. The most convenient receptacles for exposing a number of section-loaded slides to the various solutions are the square glass "staining-jars," provided with grooves and covers, which allow several pairs of slides, placed back to back, to be stood on end and immersed at one time. The disadvantages of the square jars in common use are the danger of damaging the sections by contact with the grooves and the lack of a ground-joint cover to prevent evaporation, as when containing xylol or absolute alcohol. Although less readily procured, the small cylindrical

preparation jars, with ground stoppers, meet every requirement. When of the proper height and diameter, they permit three pairs of slides to be immersed at one time with convenience and safety and enable volatile fluids to be used repeatedly without deterioration. After the staining has been completed according to the details of the method selected, the sections are passed through jars containing 95 and absolute alcohol to insure complete dehydration prior to clearing and mounting.

**Clearing the sections** is necessary to render the otherwise more or less opaque tissue transparent and suitable for microscopical examination. If the tissue contains no trace of water, it may be mounted in pure Canada balsam, the usual medium in which objects are preserved as permanent preparations, directly from fresh absolute alcohol, the latter being gradually replaced by the highly refracting balsam and the required transparency thereby secured. If, however, the alcohol be of insufficient strength, as often occurs after exposure, it mixes with the balsam imperfectly and turbidity results. In order to obviate such accident, it is more convenient to employ some clearing agent of suitable refraction as a go-between, which will mix with the alcohol, on the one side, and with the balsam on the other.

The means employed to secure this transparency depends upon the condition of the tissue, whether infiltrated with the embedding mass, as in the case of celloidin sections, or free from such support, as in the case of paraffin sections attached to the slide.

*Celloidin sections* are best cleared in a *carbol-xylol mixture*, consisting of one part of pure carbolic acid to three parts of xylol. The dehydrated sections are transferred to this fluid from the strong alcohol and after a few minutes become transparent. If, however, the required transparency fails to appear after five or ten minutes, it may be concluded that the dehydration has been insufficient to allow the penetration of the clearing solution. The sections must be returned, therefore, to the alcohol. In all cases thorough dehydration must be insured by adequate treatment with strong alcohol.

*Paraffin sections*, after the removal of the paraffin by immersion in xylol, are transferred to some clearing fluid, oil of turpentine answering well and being inexpensive.

## MOUNTING AND FINISHING.

Unless required for only cursory examination, the sections are mounted in some medium suitable for further study and preservation. The most satisfactory medium for general use is pure Canada balsam, which is supplied in convenient collapsible metal tubes, from which the required amount may be pressed. In the case of tissues cut in celloidin, the individual sections are transferred from the dish of clearing solution (carbol-xylol) to a clean slide by means of a thin metal section-lifter, a clean mounted needle being used in guiding and holding the section on the lifter, as well as in transferring it on the slide from the lifter. When the latter is broad, the blade should be perforated to facilitate raising the section from the fluid, as well as draining off the clearing solution. After being placed on the slide, the superfluous carbol-xylol having been carefully removed by filter paper, the section is finally arranged by judicious use of the needle and a drop of balsam gently pressed out from the tube upon the middle of the preparation.

If the balsam has the proper consistence, about that of syrup, the slide is held for a few moments over a spirit flame, the slight heating facilitating the distribution of the balsam over the section. The cover-glass, previously scrupulously cleaned and in readiness, is grasped between the clean blades of the forceps, held for a moment over the spirit flame, and gently lowered on the slide in such manner that the left edge of the cover is brought first into contact with the balsam. As soon as this contact is made, a moment's pause is advantageous to allow the balsam to spread out beneath the cover, which is then steadily and slowly lowered into position over the specimen until the entire space between the slide and cover is filled with the mounting medium. If, after very gentle pressure on the cover-glass with a clean needle, part of this space remains unfilled, additional balsam must be run in until the space is completely occupied by the mounting medium. Care must be exercised lest any excess of balsam get on the surface of the cover; otherwise it does not interfere with the immediate examination of the preparation. A slight edging of balsam around the cover is useful, since it dries much sooner than the medium beneath the cover and thereby adds materially to the fixation of the latter. While avoiding as far as possible the imprisonment of air-bubbles, should these be present after the cover is in place, they need cause no concern, as they usually spontaneously disappear during the next twelve hours, unless enclosed within some recess or fold in the section.

While the preparation may be examined under the microscope as soon as properly mounted, care being taken to keep it horizontal to avoid possible slipping of the cover-glass, no attempt should be made to finish it until the balsam around the edges of the cover has sufficiently hardened to preclude displacement. Ordinarily this requires some weeks, but the process of hardening may be facilitated greatly by subjecting the freshly mounted specimen, in some suitable place protected from dust, to continuous gentle heat. After a few days of such drying, although the balsam in the centre of the preparation may remain fluid, the cover will be so securely fixed that the specimen may be finished and labelled. If the superfluous balsam be considerable, as much as possible should be removed by the knife, care being taken not to touch the cover-glass, and the slide finally cleaned with a cloth moistened with xylol. Disturbing the cover-glass will likely ruin the preparation and, hence, this danger is to be constantly borne in mind.

After the slide has been cleaned, not forgetting the under side, labels are attached at the ends. Data of importance, regarding tissue, source, method of fixation, staining, and date, should be noted on one label and never be entrusted to memory; failure to observe such precautions is often a constant source of uncertainty and regret in later years. When preparations include serial sections, numbers or letters on the labels should indicate the sequence of the slides. Much time may be saved by marking the slides as to order with a writing diamond before they receive the sections. The second label is convenient for memoranda concerning special features shown by the preparation. Where many specimens accumulate, some system of card-catalogue well repays in convenience for future reference. The various methods of storing microscopical preparations are matters of individual preference and expediency, provided two essentials are observed—that the slides lie horizontal and are protected from light. With proper precautions against the presence of acid in the sections, even hematoxylin preparations may be preserved for many years without deterioration.

## SYNOPSIS OF STANDARD METHODS.

Assuming that the tissue is of moderate density, has been fixed in Zenker's fluid and preserved in 70 alcohol, with due precautions for the removal of the deposits of mercury (page 390), and that the size of the piece to be cut is approximately a surface of 1 sq. cm. by .5 cm. thick, the steps in the two standard methods—the celloidin and the paraffin—are as follows:

## Celloidin.

1. 95 alcohol, 24 hours.
2. Absolute alcohol, 24 hours.
3. Mixture absolute alcohol and ether, 24 hours.
4. Thin (C) celloidin, 1-2 days.
5. Medium (B) celloidin, 1-2 days.
6. Thick (A) celloidin, 2-4 days.
7. Mount on fibre-block.
8. Harden in 80 alcohol, 24 hours.
9. Cut sections, wet with 80 alcohol.
10. Stain in Ehrlich's hematoxylin, 5-10 minutes.
11. Wash in water, 5-10 minutes.
12. Acidulated 70 alcohol, about one-half minute; wash in water.
13. Ammoniated water, until again blue.
14. Wash thoroughly in water.
15. Stain in eosin, 1-2 minutes.
16. 70 alcohol, until no color is discharged.
17. 95 alcohol, 5 minutes.
18. Clear in carbol-xylol.
19. Mount in balsam.

## Paraffin.

1. Stain tissue *en masse* in borax-carmin, 24-48 hours.
2. Acid alcohol, 24-48 hours. Delafield's hematoxylin may be used (page 400) instead of borax-carmin.
3. 70 alcohol, 24 hours.
4. 95 alcohol, 24 hours.
5. Absolute alcohol, 24 hours.
6. Chloroform, 3-6 hours.
7. Saturated solution of paraffin in chloroform, 6-12 hours.
8. Melted paraffin in oven at 52° C., 2 hours.
9. Fresh melted paraffin, 4-6 hours.
10. Embed in fresh paraffin.
11. Cut sections, dry.
12. Expand sections on slide.
13. Dry slides to attach sections, 12 hours.
14. Xylol to remove paraffin, 3 minutes.
15. Turpentine spirits, 3 minutes.
16. Mount in balsam.

If paraffin sections are to be stained on the slide, steps 1-3 are omitted, the tissue embedded and cut and the sections attached to the slides. The paraffin is then removed and the tissue prepared for the stain by placing the slides in:

- |   |   |
|---|---|
| <ol style="list-style-type: none"> <li>a. xylol, 3 minutes.</li> <li>b. 95 alcohol, 3 minutes.</li> <li>c. 80 alcohol, 3 minutes.</li> <li>d. 70 alcohol, 3 minutes.</li> </ol> | <ol style="list-style-type: none"> <li>e. Stain as desired.</li> <li>f. Dehydrate in ascending alcohols.</li> <li>g. Clear in turpentine.</li> <li>h. Mount in balsam.</li> </ol> |
|---|---|

## SOME USEFUL SPECIAL METHODS.

**Weigert's Stain for Medullated Nerve-Fibres.**—This method is especially adapted to display nerve-fibres invested with medullary substance, the latter appearing dark or slate-blue, while the gray matter and nerve-cells are stained a light yellowish tint. The nervous tissue, in pieces not too large and as fresh as possible, is suspended in a relatively large quantity of Müller's fluid (page 391) for 4-6 weeks, changed daily during the first week and occasionally thereafter. The pieces of spinal cord or brain are then transferred directly, without washing in water, into 70 alcohol, followed by 90, and kept in the dark for almost a week, the alcohol being renewed several times and always when turbid.

The Weigert method requires the employment of three solutions, the mordant (A), the stain (B), and the differentiation fluid (C), made respectively as follows:

- A. Saturated aqueous solution of neutral cupric acetate—  
approximately 10 gm. of the copper salt to 100 cc. distilled water.
- B. Hematoxylin crystals (Grübler) . . . . . 1 gm.  
Absolute alcohol . . . . . 10 cc.  
Distilled water . . . . . 100 cc.  
The hematoxylin is dissolved in the alcohol, added to the distilled water and boiled; after cooling, filter.
- C. Borax . . . . . 2 gm.  
Potassium ferric cyanide . . . . . 2.5 gm.  
Distilled water . . . . . 100 cc.

After being cut in celloidin, the sections are placed for 12 hours in the *copper-solution*, composed of equal parts of freshly filtered A and distilled water. They are then transferred directly to the *stain*, B, in which they remain for 12–36 hours, followed by *differentiation* in C. The over-stained sections remain in this fluid until color is no longer extracted and the contrast between the white and gray matter is well accentuated, ordinarily from 30–60 minutes sufficing. The sections are then thoroughly washed in running water for 8–12 hours and carried through ascending alcohols until dehydrated, when they are cleared in carbol-xytol and mounted in balsam. If the staining has been unsuccessful, the same sections may be placed in Müller's fluid for 24 hours, rinsed in distilled water, and treated with the copper and subsequent solutions as before.

**Sodium Carminate.**—Satisfactory as is hematoxylin-eosin for usual purposes, this stain is inadequate for really good demonstrations of the nerve-cells and nerve-fibres of the brain and spinal cord. Excellent preparations of these elements may be made by the following method: Small pieces of the fresh tissue, not over 1 cm. thick, are fixed in an excess of Müller's fluid, changed daily during the first week and occasionally afterwards. After four weeks the tissue is transferred directly, without washing, into a sufficient quantity (40–50 cc.) of 1 p.c. aqueous solution of sodium carminate, in which it remains 3 days with frequent shakings. The pieces of stained tissue are washed for 24 hours in running water, and then dehydrated in ascending alcohols, embedded in celloidin and cut. When successful, the cells and the axis-cylinders appear red and sharply differentiated on a light ground, the cells of Purkinje in such preparations being beautifully shown. Lack of penetration and over-staining at the surface are the most common sources of failure.

**Chrome-Silver Impregnation.**—The introduction by Golgi of methods of silver impregnation has added an important means of demonstrating the astonishing richness and extent of the ramifications of the neurones and of the neuroglia-cells. Of the several procedures suggested by Golgi the so-called *rapid method* is here given. It is most successful when applied to the nervous tissues of the foetal or new-born animal, and, at best, is capricious and uncertain.

The fresh young tissue is fixed either in *bichromate-formalin* (4 parts of 3.5 p.c. aqueous solution of potassium bichromate to 1 of 40 p.c. formalin), or in *Golgi's fluid* (9 parts of 3.5 p.c. aqueous solution of potassium bichromate to 1 part of 2 p.c. aqueous solution of osmic acid).

Depending upon the object in view and the age of the animal, the tissue remains in the fixing fluid from 2-15 days. If foetal or very young, 2-3 days suffice for the neuroglia-cells, 3-5 days for the nerve-cells, and 5-7 days for the collaterals. Older tissues require longer immersion, adult brain being left in the fluid from 8-15 days. After rinsing for a few moments with distilled water and quickly drying off with filter paper, the pieces, not over .5 cm. thick, are placed in 1 p.c. aqueous solution of silver nitrate. In this they remain 2-3 days or longer, during which a dark precipitate appears. In order to determine the probable success of the impregnation, free-hand sections are cut and examined in 95 alcohol under the microscope. If satisfactory, the tissue is dehydrated in absolute alcohol, embedded in celloidin as rapidly as possible, and cut in 95 alcohol into sections not too thin. The sections are passed to absolute alcohol for thorough dehydration, then to creosote for 10 minutes, and, after remaining 5 minutes longer in xylol, finally placed on the slide, dried rapidly with filter paper, and covered with a large amount of balsam. The slide is now heated carefully over a flame until the balsam will set as soon as cool. Before this occurs, however, a heated cover-glass is applied and the section permanently mounted. This manipulation, suggested by Huber, insures the removal of all moisture and the probable permanency of the preparation, thus avoiding the unsatisfactory plan of keeping the specimens covered with only balsam and unprotected by a cover-glass.

Should the preliminary examination disclose insufficient silver deposit, as is frequently the case, the block of tissue is returned to the bichromate-omic solution for 2-3 days and again subjected to the silver solution. If necessary, this procedure may be repeated a number of times with the same tissue until, perchance, the results are satisfactory. This may be regarded to be the case, if the desired nervous elements appear as sharply defined dark figures on a light, almost colorless background. Even in otherwise successful preparations, many parts of the section may be almost useless owing to disturbing deposits of silver-precipitate. Notwithstanding its uncertainty, the Golgi method yields such remarkable demonstrations of the nervous elements, that really successful results amply repay perseverance.

**Gold Staining.**—The gold-chloride method is useful to demonstrate nerve-endings, such as the motor plates in striated muscle. Small pieces of fresh tissue, not over 5 mm. in dimension, are treated with the gold solution prepared as follows: 4 parts of 1 per cent. aqueous solution of gold-chloride and 1 part of formic acid are heated to boiling three times. The tissue is placed in this solution when cool for 1 hour, in the dark. It is then rinsed in distilled water for half a minute and transferred to diluted formic acid (1 part acid to 4 parts distilled water) and allowed to stand in the light, but not direct sunlight, 18-48 hours. By the end of this period the exterior of the tissue has acquired a dark violet color. Small fragments may be teased in glycerine and if successfully stained may be mounted permanently in the same; or, if desirable, the entire piece may be hardened in ascending alcohols, sectioned and mounted in balsam. The use of steel instruments during these manipulations must be avoided, thin glass rods of suitable size being substituted. Admirable preparations, showing nerves and connective tissue cells, may be made from the corneæ of small animals, the tissue being separated into thin lamellæ before mounting.

**Silver Staining.**—Staining with argentic nitrate, as contrasted with Golgi impregnations, is employed especially to differentiate the cell-boundaries of endothelium, since by its employment the intercellular cement sub-

stance is demonstrated as dark lines. The method is of further use in bringing to view the lymph-spaces within the dense connective tissues, as the cornea, in which the spaces then appear as irregular light figures surrounded by the brown ground-substance.

When the mesothelium, covering for instance the mesentery, is to be displayed, the tissue is cut from the recently killed animal and carefully transferred by glass rods to 1 per cent. aqueous solution of argentic nitrate. After immersion for 5-10 minutes, according to the thickness of the object, the tissue is rinsed in distilled water, placed in a porcelain dish containing distilled water, and stood in the direct sunlight until reduction of the silver is completed. This is indicated by a decided reddish-brown tint and usually requires 8-15 minutes. The tissue is then transferred to a small dish of distilled water to which a few granules of sodium chloride have been added, the purpose of the latter being to arrest the action of the silver. After 10 minutes, the stained tissue is placed for 6-10 hours in 70 alcohol, in the dark, followed by dehydration in alcohol, clearing and mounting in balsam. After the reduction of the silver, staining with hematoxylin adds to the interest of the preparation by bringing out the nuclei, which otherwise are only faintly seen.

When the endothelium of the blood-vessels is to be stained, the method recommended by Huber may be followed with advantage. After the escape of the blood following incision of the exposed heart of an anesthetized animal, a glass or hard rubber canula is inserted into the thoracic aorta and the vessels injected with a 1 per cent. solution of argentic nitrate. After fifteen minutes, the inferior vena cava is cut immediately below the heart and a 4 per cent. solution of formalin (10 parts commercial formalin to 90 parts of distilled water) is injected into the aorta through the same canula. The injection of the formalin washes out the superfluous silver solution, thereby avoiding disturbing precipitates, and fixes the vessels while distended. The desired tissue is then cut from the animal, care being taken to remove the structures to be examined in pieces sufficiently supported to prevent undue distortion, immersed in 4 per cent. formalin and exposed to direct sunlight. While the latter is not necessary, reduction of the silver taking place slowly in diffuse daylight, the rapid reduction effected by sunlight is favorable to sharp and well differentiated histological pictures; it should, therefore, be employed whenever possible. After dehydration, small flat pieces of the tissue are cleared in carbol-xylol and mounted in balsam. If protected from strong daylight, such preparations may be preserved for years with little deterioration.

**Injecting Blood-Vessels.**—In order to demonstrate the distribution of the smaller blood-vessels and the capillaries, advantage is taken of some means to fill the blood-channels with a colored substance. The injection-mass must meet two requirements—be transparent and not diffuse through the walls of the smallest vessels. Successful, that is complete, injection of the capillaries requires considerable experience and, even at best, is attended with an element of uncertainty, since the condition of the tissues, particularly of the vessels, influences the freedom with which the injecting fluid runs.

Two injecting masses are commonly employed, *carmine-gelatin* and *Berlin blue*. When successful the former yields very beautiful preparations, but has the disadvantage of requiring to be used while hot and with heated tissue, in order to prevent untimely solidification. The beginner will find Berlin blue more convenient, since it is used cold, runs well in unwarmed tissues, and does not extravasate. The results, moreover, are equally instructive, although perhaps less striking. The injection fluid is readily pre-



pared by dissolving 3 gm. soluble Berlin blue (*Grübler*) in 600 cc. distilled water. A smoothly working syringe of 200-300 cc. capacity, with tightly fitting stop-cock and several appropriate canulæ, is the best instrument, since the educated hand of the operator is the surest gauge of the pressure that may be applied with safety.

A small animal, such as a young rabbit or kitten, is chloroformed and then bled to death by opening the heart or some large vein, so that the vessels are emptied as far as possible. It is advisable to undertake at first the injection of a single organ, as the liver, kidney, or lung, rather than of the entire animal. The organ is not removed and is disturbed only as much as may be necessary to expose sufficiently its chief artery. Into this a canula of appropriate size and fitted with a stop-cock is inserted through a small slit and securely tied. In order to avoid the introduction of air, the canula should be filled with the injecting fluid, and the stop-cock turned, before being introduced into the vessel. When the canula is in place and secured, the syringe is filled, fitted to the canula, the stop-cock opened, and the fluid gently forced into the vessels. Great care must be exercised lest sudden and excessive pressure rupture the delicate vessels and the fluid escape. If all goes well, the injected organ soon begins to assume a bluish tint, but until the tissue appears deeply and uniformly colored the capillary injection is incomplete. Before removing the canula, the large vessels should be secured with ligatures. The organ is then removed from the animal and placed in Müller's fluid or 70 per cent. alcohol for some days before cutting into pieces. Sections of injected organs must not be too thin, but sufficiently thick to include complete capillary loops or networks. In the case of the lungs, after injecting the blood-vessels, the tissue should be moderately distended by forcing the fixing fluid through the air-tubes, which are then ligated.

---

It may be repeated, that the purpose of these pages concerning microscopical technique is to present a few methods which are satisfactory and thoroughly trustworthy for the majority of histological examinations. The student is urged to persevere with those here given until he has repeatedly carried the manipulations to the successful results which they are capable of yielding.



# INDEX.

- Accessory spleens, 116  
Acervulus cerebri, 308  
Adamantoblasts, 140  
Adipose tissue, 29  
Alimentary canal, 129  
Ameloblasts, 140  
Amitosis, 10  
Amphiaser, 8  
Anabolism, 5  
Anaphases of cell-division, 9  
Aponeuroses, 63  
Appendage, vesicular of female, 253  
Appendix epididymidis, 235  
    testis, 235  
Arachnoid, 314  
    Pacchionian bodies, 314  
Arbor vitæ cerebelli, 294  
Areolar tissue, 27  
Arrectores pilorum, 328  
Artery, helicine of penis, 240  
Arteries, of large size, 90  
    structure of, 89  
Articulations, 51  
Atrio-ventricular bundle, 102  
Auditory ossicles, 367  
Auerbach's plexus, 163  
Axis-cylinder, of nerves, 68  
    processes, 65  
Baillarger's stripe, 302  
Bartholin's glands, 262  
Basement membrane, 121  
Basket-cells of cerebellum, 295  
Bertin's columns of kidney, 206  
Betz's cortical cells, 304  
Bladder, 217  
Blastodermic layers, 13  
    derivatives of, 15  
    vesicle, 12  
Blood, 94  
    clot, 98  
    colored cells, 94  
    colorless cells, 96  
    fibrin, 98  
    granules, 98  
    serum, 98  
Blood-crystals, 98  
Blood-plaques, 97  
Blood-plates, 97  
Blood-vascular system, 87  
Blood-vessels, development of, 99  
    endothelium of, 88  
    muscle of, 88  
    nerves of, 89  
    nutrient vessels of, 89  
    structure of, 87  
Bodies, Nissl's, 66  
Böhmer's hematoxylin, 400  
Bone, 34  
    absorption of, 46  
    blood-vessels of, 42  
    cancellated, 35  
    central spongy, 46  
    compact, 35  
    development of, 42  
    endochondral development, 43  
    growth of, 50  
    intracartilaginous, 43  
    intramembranous development, 49  
    membrane, 43  
    perforating fibres, 37  
    subperiosteal, 47  
Bone-marrow, 39  
    primary, 45  
    red, 40  
    yellow, 42  
Bowman's glands, 382  
    membrane, 340  
Brain, 279  
    blood-vessels of, 307  
    choroid plexuses, 313  
    general description of, 279  
Brain-sand, 308  
Brain-stem, 279  
Bronchi, 192  
Bruch's membrane, 343  
Brunner's glands, 166  
Buccal glands, 147  
Bulbo-urethral glands, 244  
Bulbus vestibuli, 262  
Bursæ, 64  
Capillaries, structure of, 92  
Cardiac muscle, 55  
    nerve-endings, 86  
Carotid body or gland, 117  
Cartilage, articular, 51  
    cells of, 31  
    elastic, 33  
    fibrous, 33  
    growth of, 32  
    hyaline, 31  
    matrix of, 31  
Cells, connective tissue, 23  
    ependymal, 71  
    fat, 30  
    free connective tissue, 24  
    general considerations of, 1  
    mast, 25  
    origin of, 11  
    of Paneth, 168  
    pigment, 24  
    plasma, 25  
    structure of, 2

- Cell-division, 6  
   amitotic or direct, 10  
   mitotic or indirect, 7  
 Cell-plate, 9  
 Central nervous system, 266  
 Centriole, 5  
 Centrioplasm, 5  
 Centrosome, 4  
 Centrosphere, 5  
 Cerebellum, 294  
   basket-cells, 295  
   cortex, 294  
   cortical nerve-fibres, 297  
   internal nuclei, 298  
   neuroglia, 298  
   Purkinje cells, 294  
 Cerebral crura, 291  
   peduncles, 291  
     crusta, 292  
     substantia nigra, 292  
     tegumentum, 292  
 Cerebrospinal fluid, 311  
 Cerebrum, 299  
   basal ganglia, 304  
   caudate nucleus, 305  
   cortical gray matter, 299  
   cortical nerve-cells, 300  
   cortical nerve-fibres, 303  
   cortical variations, 304  
   giant pyramidal cells, 304  
   internal nuclei, 304  
   lenticular nucleus, 305  
   optic thalamus, 306  
   pineal body, 308  
   Rolandic cortex, 304  
   stratum zonale, 301  
 Ceruminous glands, 364  
 Chondroclasts, 45  
 Choroid plexuses of brain, 313  
 Chromaffine cells, 118  
 Chromosomes, 8  
   reduction of, 9  
 Chromatin, 4  
 Clasmatocytes, 25  
 Claudius' cells of ear, 377  
 Clitoris, 262  
 Cloquet's canal in eye, 356  
 Coccygeal body or gland, 118  
 Cohnheim's fields, 59  
 Collagen, 25  
 Colostrum, 264  
 Conarium, 308  
 Conjunctiva, 357  
 Connecting fibres, 9  
 Connective tissue, 21  
 Contour lines of Owen, 133  
 Cornea, 339  
 Corneal corpuscles, 340  
 Corpus dentatus of cerebellum, 298  
   luteum, 249  
   striatum, 305  
   trapezoides, 291  
 Corpuscles, genital, 81  
   Golgi-Mazzoni, 83  
   Grandry's, 80  
   Herbst's, 83  
 Corpuscles, Meissner's, 80  
   Pacinian, 82  
   tactile, 80  
 Corti's membrane of ear, 378  
   organ of ear, 376  
 Cowper's glands, 244  
 Crusta petrosa, 135  
 Crystalline lens, 354  
 Cuticle of skin, 317  
 Cylindrical end-bulbs, 82  
 Cytoplasm, structure of, 2  
 Decidua menstrualis, 259  
 Deiter's cells of ear, 378  
 Delafield's hematoxylin, 400  
 Demours' membrane, 340  
 Dental papilla, 137  
 Dentine, 133  
 Descemet's membrane, 340  
 Deutoplasm, 11  
 Diploë, 35  
 Diplosome, 5  
 Duct, bile, ejaculatory, 237  
   Gartner's, 253  
   paraurethral, 251  
   spermatic, 235  
 Ductuli aberrantes, 235  
 Dura mater, 312  
 Ear, 362  
   auditory cells, 377  
   auditory ossicles, 367  
   auricle, 362  
   basilar membrane, 376  
   blood-vessels of, 379  
   bony cochlea, 370  
   bony semicircular canals, 370  
   canalis reuniens, 374  
   cerumen, 364  
   ceruminous glands, 364  
   cochlear duct, 373  
   cristæ acusticæ, 373  
   endolymph, 369  
   Eustachian tube, 367  
   external, 362  
   external auditory canal, 363  
   internal, 369  
   ligamentum spirale, 375  
   macula acusticæ, 372  
   mastoid cells, 369  
   membrana tectoria, 378  
   membranous labyrinth, 371  
   middle, 365  
   nerves of, 379  
   organ of Corti, 376  
   osseous labyrinth, 369  
   otolith membrane, 372  
   perilymph, 369  
   pillars of Corti, 377  
   Reissner's membrane, 374  
   scala tympani, 374  
   scala vestibuli, 374  
   spaces of Nuel, 378  
   tubal tonsil, 368  
   tympanic cavity, 365  
   tympanic membrane, 365  
   vestibule, 369  
 Ear-stones, 372

- Ectoderm, 13  
 Ehrlich's hematoxylin, 399  
 Ejaculatory duct, 237  
 Elastin, 27  
 Eleidin, 320  
 Elementary tissues, 16  
 Embryonic areæ, 13  
 Enamel, 131  
 Enamel-organ, 139  
 Encephalon, 279  
 End-bulbs, 81  
 Endocardium, 101  
 Endochondral development of bone, 43  
 Endolymph of ear, 369  
 Endometrium, 256  
 Endomysium, 59  
 Endoneurium, 72  
 Endoplasm, 3  
 Endoskeleton, 34  
 Endothelium, 20  
 End-plate of motor nerves, 85  
 Entoderm, 13  
 Eosinophiles, 97  
 Eosin-bodies of cerebellum, 297  
 Ependyma, 71  
 Epicardium, 103  
 Epidermis, 317  
 Epididymis, 233  
     canal of, 233  
     efferent ducts, 233  
 Epimysium, 59  
 Epineurium, 72  
 Epiphysis, 308  
     ossification of, 47  
 Epiploic appendages, 172  
 Epithelial bodies, 199  
 Epithelium, 16  
     ciliated, 19  
     columnar, 18  
     germinal, 245  
     glandular, 19  
     modified, 18  
     pigmented, 19  
     rod, 20  
     squamous, 16  
 Eponychium, 332  
 Epoöphoron, 252  
 Erythroblasts, 99  
 Erythrocytes, development of, 99  
     nucleated, 41  
     size of, 95  
     structure of, 94  
 Eustachian tube, 367  
 Eye, 337  
     anterior chamber, 357  
     aqueous humor, 357  
     canal of Schlemm, 340  
     choriocapillaris, 343  
     choroid, 342  
     ciliary body, 343  
     ciliary muscle, 344  
     ciliary processes, 344  
     ciliary ring, 344  
     conjunctiva, 357  
     cornea, 339  
     crystalline lens, 354  
     Eye, fibrous tunic, 338  
         fovea centralis, 347  
         hyaloid canal, 356  
         hyaloid membrane, 355  
         iris, 345  
         lachrymal passages, 361  
         lachrymal sac, 362  
         lamina cribrosa, 353  
         lamina fusca, 338  
         ligament of lens, 356  
         macula lutea, 349  
         Müller's fibres, 350  
         muscles of iris, 345  
         nervous tunic, 346  
         optic nerve, 353  
         ora serrata, 352  
         pectinate ligament, 340  
         posterior chamber, 357  
         retina, 346  
         rods and cones, 348  
         sclera, 338  
         spaces of Fontana, 341  
         tear-gland, 361  
         vascular tunic, 341  
         venæ vorticosæ, 343  
         vitreous body, 355  
         yellow spot, 347  
     Eyelids, 357  
         cilia, 357  
         tarsal glands, 359  
         tarsal plates, 358  
     Exoplasm, 3  
     Exoskeleton, 34  
     Fallopian tube, 254  
     Fasciæ, 63  
     Fasciculus antero-lateralis superfic., 277  
         cerebello-spinalis, 277  
         cerebro-spinalis, 278  
         cuneatus, 268  
         gracilis, 268  
         posterior longitudinalis, 288  
         solitarius, 287  
     Fat-cells, 30  
         serous, 31  
     Fat-organs, 31  
     Fibres, connective tissue, 25  
         elastic, 26  
         white, 25  
     Fibrin, 98  
     Fibrocartilage, 33  
     Fibrous tissue, 23  
     Fillet, median, decussation, 284  
     Fontana's spaces, 341  
     Formatio reticularis, of medulla, 285  
     Fovea centralis of eye, 347  
     Flemming's solution, 391  
     Frontal sinus, 384  
     Funiculi, of nerves, 72  
     Gall-bladder, 182  
     Ganglia, development of, 78  
         spinal, 74  
         sympathetic, 74  
     Ganglion-crest, 78  
     Gartner's duct, 253  
     Gay's glands, 336  
     Genital corpuscles, 81

- Germ-cells, 11  
 Germ-centres of lymph-nodes, 108  
 Germ-layers, 13  
 Germinal epithelium, 245  
 Giralde's organ, 235  
 Glands, 122  
   of Bartholin, 262  
   of Bowman, 382  
   of Brunner, 166  
   buccal, 147  
   bulbo-urethral, 244  
   bulbo-vestibular, 262  
   cardiac of stomach, 160  
   ceruminous, 364  
   ciliary, 336  
   circumanal, 336  
   compound alveolar, 127  
   compound tubular, 124  
   cutaneous, 332  
   development of, 127  
   epithelium of, 125  
   gastric, 158  
   of Gay, 336  
   labial, 147  
   lachrymal, 361  
   of Lieberkühn, 168  
   lingual, 145  
   of Littre, 220  
   mammary, 262  
   Meibomian, 359  
   molar, 147  
   of Moll, 359  
   mucous, 126  
   nerves of, 127  
   of Nuhn, 145  
   oesophageal, 155  
   olfactory, 382  
   oral, 146  
   palatal, 151  
   parotid, 148  
   sebaceous, 333  
   serous, 125  
   simple alveolar, 127  
   simple tubular, 124  
   sublingual, 149  
   submaxillary, 149  
   solitary of intestine, 168  
   sweat, 334  
   tubo-alveolar, 124  
   vessels of, 127  
   of Zeiss, 359  
 Glomeruli of cerebellum, 297  
   of kidney, 209  
 Glomus caroticum, 117  
   coccygeum, 118  
 Golgi-Mazzoni corpuscles, 81  
 Grandry's corpuscles, 80  
 Grenacher's borax-carmines, 401  
 Growth, 5  
 Gustatory cells, 387  
 Hairs, 323  
   development of, 328  
   erector muscle of, 328  
   follicle, 325  
   growth of, 329  
   root-sheaths, 326  
   structure of, 324  
 Hassall's corpuscles, 201  
 Haversian canals, 38  
   space, 49  
   system, 35  
 Heart, 101  
   blood-vessels of, 103  
   development of, 104  
   endocardium, 101  
   epicardium, 103  
   myocardium, 102  
   nerves of, 103  
   valves of, 102  
 Hematoconia, 98  
 Hematoidin crystals, 98  
 Hemin crystals, 98  
 Hemolymph nodes, 112  
 Hensen's cells of ear, 378  
 Herbst's corpuscles, 83  
 Henle's layer, hair-follicle, 326  
   sheath, of nerves, 72  
 His's bundle of heart, 102  
 Howship's lacunæ, 46  
 Huxley's layer, hair-follicle, 326  
 Hyaloplasm, 3  
 Hydatid of Morgagni, 253  
 Hypophysis cerebri, 309  
 Ileo-colic valve, 173  
 Incremental lines of Salter, 133  
 Interglobular spaces of tooth, 135  
 Intervertebral disk, 51  
 Intramembranous bone-development, 49  
 Involuntary muscle, 53  
 Irritability, 6  
 Islands of Langerhans, 185  
 Jacobson's organ, 384  
 Joints, structure of, 51  
 Karyokinesis, 7  
 Karyoplasm, 3  
 Karyosomes, 4  
 Katabolism, 5  
 Keratohyalin, 319  
 Kidney, 205  
   architecture of, 205  
   blood-vessels of, 213  
   columns of Bertin, 206  
   details of tubules, 209  
   glomeruli, 209  
   lymphatics of, 215  
   nerves of, 215  
   pelvis of, 215  
   substance of, 207  
   supporting tissue of, 213  
   uriniferous tubules, 207  
 Kupffer's cells in liver, 181  
 Labial glands, 147  
 Labra glenoidalia, 52  
 Lachrymal apparatus, 360  
   gland, 361  
   passages, 361  
   sac, 362  
 Lamina fusca of eye, 338  
 Langerhans' islands, 185  
 Large intestine, 171  
   epiploic appendages, 172  
   ileo-colic valve, 173

- Large intestine, vermif. appendix, 173  
 Larynx, 187  
   cartilages of, 187  
   vocal cords, 188  
 Lemniscus medialis, 284  
 Leucocytes, 97  
   development of, 100  
 Ligamentum circulare dentis, 136  
 Lingual glands, 145  
   tonsil, 145  
 Linin, 4  
 Lip, structure of, 129  
 Lipochromes, 24  
 Liquor folliculi, 247  
 Littre's glands of urethra, 220  
 Liver, 176  
   bile-capillaries, 179  
   biliary passages, 181  
   blood-vessels of, 177  
   cells of, 178  
 Lungs, 191  
   air-spaces, 194  
   architecture of, 191  
   blood-vessels of, 195  
   bronchioles, 192  
   lobule, 191  
   nerves of, 196  
   respiratory epithelium, 194  
   unit of, 192  
 Luschka's gland, 118  
 Lymph-nodes, 109  
 Lymph-nodules, 108  
 Lymph-spaces, 106  
   perivascular, 107  
 Lymph-vessels, 107  
 Lymphatic system, 105  
   development of, 112  
 Lymphatics, afferent, 109  
   efferent, 109  
 Lymphocytes, 97  
 Lymphoid tissue, 108  
   germ-centres of, 108  
   lymph-nodes, 109  
   lymph-nodules, 108  
 Macula lutea of eye, 349  
 Mammary glands, 262  
   milk, 264  
 Martinotti's cells, 303  
 Mast-cells, 25  
 Mastoid cells, 369  
 Maxillary sinus, 384  
 Medulla oblongata, 282  
   arcuate fibres, 284  
   decussation, motor, 283  
   decussation, sensory, 284  
   formatio reticularis, 285  
   pyramidal decussation, 283  
   posterior nuclei, 283  
 Medullary sheath of nerves, 68  
 Megakaryocytes, 41  
 Meibomian glands, 359  
 Meissner's corpuscles, 80  
   plexus, 163  
 Membrana propria, 121  
   tympani, 365  
 Membrane-bones, 43  
 Membrane, fenestrated, 27  
   of Nasmyth, 132  
   synovial, 52  
 Meninges, 311  
 Mesenchyma, 21  
 Mesoderm, 13  
 Mesodermic somites, 14  
 Mesothelium, 21  
 Metabolism, 5  
 Metaphase of cell-division, 8  
 Metaplastm, 3  
 Microscopical technique, 389  
   celloidin, embedding, 393  
   chrome-silver impregnation, 406  
   cutting sections, 396  
   fixation of tissues, 389  
   fixing sections, 402  
   gold staining, 407  
   injecting blood-vessels, 408  
   mounting and finishing, 403  
   paraffin, embedding, 394  
   preservation of tissues, 389  
   serial sections, 397  
   silver staining, 407  
   staining, 399  
   staining on slide, 401  
   Weigert's method, 405  
 Microsomes, 3  
 Mid-body, 9  
 Milk, 264  
 Mitosis, 7  
   synopsis of, 10  
 Mitotic figure, 8  
 Molar glands, 147  
 Moll's glands, 359  
 Morgagni's hydatid, 253  
 Motor nerve-endings, 85  
 Mouth, glands of, 146  
 Mucous membranes, 119  
   epithelium, 120  
   muscularis, 121  
   nerves of, 121  
   submucous tissue, 121  
   tunica propria, 120  
   vessels of, 121  
 Mucous tissue, 22  
 Müller's ciliary muscle, 344  
   fibres of retina, 350  
   fluid, 391  
 Muscles, attachment of, 62  
   cardiac, 55  
   contractile fibrillæ, 58  
   development of, 61  
   fasciculi, 59  
   fibre-cells, 54  
   fields of Cohnheim, 59  
   general considerations, 53  
   nonstriated, 53  
   red, 59  
   striated, 58  
   structure of striated, 58  
 Muscle-columns, 58  
 Muscle-nuclei, 59  
 Muscle-spindles, 83  
 Muscularis mucosæ, 121  
 Myeloblasts, 100

- Myelocytes, 41  
 Myelospongium, 76  
 Myocardium, 102  
 Myo-fibrils, 55  
 Myometrium, 257  
 Nails, 330  
   growth of, 331  
 Nasmyth's membrane, 132  
 Nerve-cells, 66  
 Nerve-endings, encapsulated, 80  
   free sensory, 79  
   motor, 85  
   sensory, 79  
 Nerve-fibres, 68  
   afferent, 64  
   efferent, 64  
 Nerve-terminations, 79  
 Nerve-trunks, 71  
 Nerves, development of, 77  
 Nervous system, essential parts, 64  
 Nervous tissue, 64  
   development of, 76  
 Neurilemma, 68  
 Neuroblasts, 77  
 Neuroepithelium, 20  
 Neuroglia, 70  
 Neuromuscular endings, 83  
 Neurone, motor, 64  
   sensory, 64  
   structure of, 65  
   types of, 67  
 Neurotendinous endings, 85  
 Nissl's bodies, 66  
 Nonstriated muscle, nerve-endings, 86  
 Normoblasts, 99  
 Nose, accessory air-spaces, 384  
   cavernous tissue of, 383  
   external, 380  
   Jacobson's organ, 384  
   mucous membrane of, 380  
   olfactory glands, 382  
   olfactory region, 381  
   respiratory region, 382  
 Nuclear spindle, 8  
 Nuclein, 4  
 Nucleolus, 4  
 Nucleus of abducens nerve, 290  
   ambiguus, 287  
   caudatus, 305  
   cuneatus, 284  
   dentatus of cerebellum, 298  
   dorsal vago-accessory, 286  
   emboliformis, 298  
   of facial nerve, 291  
   fastigii, 298  
   globosus, 298  
   gracilis, 283  
   of hypoglossal nerve, 286  
   lateralis, 287  
   lenticularis, 305  
   of oculomotor nerve, 291  
   pontile, 290  
   ruber, 293  
   structure of, 3  
   of trigeminus nerve, 291  
 Nuel's spaces of ear, 378  
 Nuhn's glands, 145  
 Odontoblasts, 136  
 Oesophagus, 154  
   glands of, 155  
 Oliva, 285  
 Olivary nuclei, accessory, 285  
   inferior, 285  
 Oolemma, 11  
 Optic thalamus, 306  
 Oral cavity, mucosa of, 129  
 Organs of internal secretion, 226  
   of respiration, 187  
   of special sense, 315  
 Orth's fluid, 391  
 Osseo-mucoid, 35  
 Osteoblasts, 41, 45  
 Otoconia, 373  
 Otoliths, 372  
 Ovary, 245  
   corpus luteum, 249  
   Graafian follicles, 245  
   medulla of, 250  
 Oviduct, 254  
 Ovula Nabothi, 257  
 Ovum, human, 248  
   parts of, 11  
   primary, 246  
 Owen's contour lines, 133  
 Pacchionian bodies, 314  
 Pacinian corpuscles, 82  
 Palate, 151  
   glands of, 151  
 Pancreas, 182  
   duct, 184  
   interalveolar cell-areas, 185  
   islands of Langerhans, 185  
 Paneth's cells, 168  
 Panniculus adiposus, 317  
 Papillæ, circumvallate, 143  
   filiform, 143  
   foliate, 144  
   fungiform, 143  
   of tongue, 143  
 Paradidymis, 235  
 Paraganglia, 75  
 Paraganglion caroticum, 118  
 Paralinin, 4  
 Parathyroid bodies, 199  
 Paraurethral ducts, 261  
 Pareleidin, 320  
 Parioöphoron, 253  
   inferior cerebellar, 286  
 Peduncle, middle cerebellar, 288  
   superior cerebellar, 293  
 Penis, 239  
 Pericardium, 104  
 Pericementum, 135  
 Perichondrium, 32  
 Perilymph of ear, 369  
 Perimetrium, 258  
 Perimysium, 59  
 Perineurium, 72  
 Periosteum, 38  
   osteogenetic layer, 47  
 Peritoneum, 175  
 Peyer's patches, 169



- Pharynx, 152  
 Pia mater, 312  
 Pigment cells, 24  
 Pineal body, 308  
     eye, 309  
 Pituitary body, 309  
     anterior lobe, 309  
     posterior lobe, 310  
 Plasma-cells, 25  
 Plasmosome, 4  
 Pleura, 196  
 Plexus of Auerbach, 163  
     choroid of brain, 313  
     of Meissner, 163  
     myspermatikus, 238  
 Polar field, 8  
 Pons Varolii, 288  
     tegmental part, 290  
     ventral part, 288  
 Prophases of cell-division, 8  
 Prostate gland, 241  
     secretion of, 243  
 Prostatic calculi, 242  
 Protoplasm, 2  
 Purkinje fibres of heart, 102  
     nerve-cells, 294  
 Pyramidal tracts, decussation, 283  
 Pyrenin, 4  
 Ranvier's nodes, of nerves, 69  
 Red muscles, 59  
 Red nucleus, 293  
 Reissner's membrane, 374  
 Remak's nerve-fibres, 70  
 Renal duct, 215  
 Reproduction, 5  
 Reproductive organs, female, 245  
     male, 227  
 Restiform body, 286  
 Rete Malpighi, 318  
 Reticular tissue, 22  
 Retina, 346  
 Retzius' stripes, 132  
 Riolan's muscle, 358  
 Roof-nuclei of cerebellum, 298  
 Rudimentary organs of female, 252  
 Ruffini's nerve-endings, 85  
 Ruysch's membrane, 343  
 Salivary corpuscles, 150  
     glands, 146  
 Salter's lines, 133  
 Sarcolemma, 57  
 Sarcostyles, 58  
 Sarcous substance, 57  
 Schlemm's canal in eyeball, 340  
 Schmidt-Lantermann segments, 69  
 Schreger's lines in dentine, 133  
     stripes in enamel, 132  
 Schwann's sheath, 68  
 Scleral corpuscles, 338  
 Sebaceous glands, 333  
 Segmentation, 12  
 Seminal vesicle, 237  
 Sertoli's cells of testicle, 230  
 Sharpey's fibres of bone, 37  
 Sheath of Henle, 72  
 Sinusoids, 93  
 Skene's tubes, 261  
 Skin, 315  
     corium, 316  
     cutaneous ridges, 316  
     epidermis, 317  
     glands of, 332  
     nerves of, 322  
     pigmentation of, 320  
     stratum germinativum, 318  
     tela subcutanea, 317  
     vessels of, 321  
 Small intestine, 163  
     aggregated nodules, 169  
     Brunner's glands, 166  
     glands, 166  
     lacteals, 165  
     Lieberkühn's glands, 168  
     lymph-nodules, 168  
     Peyer's patches, 169  
     plicæ circulares, 166  
     solitary nodules, 168  
     valvulæ conniventes, 166  
     villi, 164  
 Somatopleura, 14  
 Somites, mesodermic, 14  
 Spermatic duct, 235  
 Spermatoblasts, 231  
 Spermatocytes, 231  
 Spermatogenesis, 230  
 Spermatogones, 230  
 Spermatozoa, 232  
 Sperm-crystals, 244  
 Sphenoidal sinus, 384  
 Spinal cord, 266  
     blood-vessels, 270  
     Burdach's tract, 277  
     central canal, 273  
     Clarke's column, 271  
     direct cerebellar tract, 277  
     fibre-tracts, 274  
     Goll's tract, 277  
     Gowers' tract, 277  
     gray matter, 268  
     ground-bundle, 278  
     membranes, 311  
     nerve-cells, 269  
     neuroglia, 272  
     pyramidal tracts, 278  
     spino-thalamic tract, 277  
     substantia gelatinosa, 273  
     white matter, 273  
 Spireme or skein, 8  
 Splanchnopleura, 14  
 Splanchnoskeleton, 34  
 Spleen, 113  
     accessory, 116  
     lobules of, 114  
     pulp of, 115  
 Spongioblasts, 77  
 Spongiosplasm, 3  
 Stilling's canal of eye, 356  
 Stomach, 157  
     cardiac glands, 160  
     fundus glands, 158  
     pyloric glands, 159  
     pyloric sphincter, 161

- Stomata of serous membranes, 21  
 Stratum Malpighi, 318  
 Striated muscle, nerve-endings, 85  
 Stripes of Retzius, 132  
   of Schreger, 132  
 Subarachnoid space, 311  
 Subdural space, 311  
 Sublingual gland, 149  
 Submaxillary gland, 149  
 Substantia gelatinosa of medulla, 284  
   of spinal cord, 273  
 Substantia nigra, 292  
 Suprarenal body, 222  
   chromaffin cells, 224  
   cortex of, 223  
   medulla of, 224  
 Suprarenals, accessory, 225  
 Sweat-glands, 334  
 Sylvian aqueduct, 291  
 Synovial membranes, 52  
   villi, 52  
 Tactile cells, 80  
   corpuscles, 80  
 Tapetum cellulosum, 343  
   fibrosum, 343  
 Taste-buds, 385  
   nerves of, 387  
 Teeth, 131  
   alveolar periosteum, 135  
   cementum, 135  
   dentinal tubules, 134  
   dentine, 133  
   development of, 137  
   enamel, 131  
   interglobular spaces, 135  
   nerves of, 136  
   odontoblasts, 136  
   pericementum, 135  
   peridental membrane, 135  
   pulp, 136  
   vessels of, 136  
   tooth-sac, 141  
 Tellyesniczky's fluid, 390  
 Telophases of cell-division, 9  
 Tendon, 28  
   cells, 28  
   sheaths, 63  
   spindles, 85  
 Testicle, 227  
   appendages of, 235  
   seminiferous tubules, 229  
   spermatogenesis, 230  
 Thymus, 200  
   atrophy of, 203  
   Hassall's corpuscles, 201  
   thymic bodies, 201  
 Thyroid body, 197  
 Tigroid substance, 66  
 Tissue, adipose, 29  
   areolar, 27  
   connective, 21  
   dense fibrous, 27  
   elementary, 16  
   epithelial, 16  
 Tissue, fibrous, 23  
   mucous, 22  
   muscular, 53  
   nervous, 64  
   reticular, 22  
 Tomes's granule layer, 135  
   processes, 140  
 Tongue, 142  
   glands of, 145  
   muscles of, 142  
   papillæ of, 143  
 Tonsils, faucial, 153  
   lingual, 145  
   palatine, 153  
   pharyngeal, 154  
   tubal, 154  
 Tooth-development, cementum, 141  
   dentine, 137  
   enamel, 140  
   permanent teeth, 141  
 Trachea, 189  
   glands of, 191  
   muscle of, 191  
 Trophoblast, 12  
 Tuberculum Rolandi, 284  
 Tunica propria, 120  
 Ureter, 215  
 Ureteral sheath, 217  
 Urethra, 219  
   female, 221  
   glands of, 220  
   male, 219  
 Uterus, 255  
   cervical glands, 256  
   changes during pregnancy, 259  
   glands of, 256  
   menstrual changes, 258  
 Uveal tract of eyeball, 341  
 Vagina, 259  
 Valves, of veins, 92  
 Vas deferens, 235  
   ampulla of, 235  
 Vasa vasorum, 89  
 Vater-Pacinian corpuscles, 82  
 Vesicular appendages, 253  
 Veins, structure of, 91  
   valves of, 92  
 Vermiform appendage, 173  
 Vital phenomena, 5  
 Vitellus, 11  
 Volkmann's canals, 38  
 Vascular system, 87  
 Vulva, 260  
   labia majora, 260  
   labia minora, 261  
   tubes of Skene, 261  
   vestibule, 261  
 Wharton's jelly, 22  
 Witch-milk, 264  
 Zeiss' glands, 359  
 Zinn's arterial circle, 329, 339  
   zonula of lens, 354  
 Zona pellucida, 247  
   radiata, 248



t.5280  
Normal histology, with special 1916  
Countway Library AIV8481



3 2044 045 135 282