

COLUMBIA LIBRARIES OFFSITE  
HEALTH SCIENCES STANDARD



HX64147380

RC76 .L871 1897 Lessons in physical

**RECAP**

RC 76

L87

1897



COLUMBIA UNIVERSITY  
EDWARD G. JANEWAY  
MEMORIAL LIBRARY

# LESSONS

IN

# PHYSICAL DIAGNOSIS

BY

ALFRED L. LOOMIS, M.D., LL.D.

PROFESSOR OF THE PRACTICE OF MEDICINE AND PATHOLOGY IN THE UNIVERSITY  
OF THE CITY OF NEW YORK

---

TENTH EDITION—REVISED AND ENLARGED

---

NEW YORK  
WILLIAM WOOD & COMPANY

1897

RC  
76  
1817  
1888

---

ENTERED according to Act of Congress, in the year 1893, by  
WILLIAM WOOD & CO.,  
In the Office of the Librarian of Congress, at Washington.

---

ALL RIGHTS RESERVED.



## PREFATORY NOTE.

---


THE tenth edition of this volume has been thoroughly revised, and such corrections and additions have been made as seemed necessary to make it a more complete guide to the student of Physical Diagnosis. The section on the "Physiological Action of the Heart," and the lesson on the "Examination of Urine," have been entirely rewritten. A new lesson on "Clinical Microscopy" has been added.

In the work of revision and proof-reading I have received assistance from Drs. Egbert Le Fevre and Warren Coleman.

THE AUTHOR.

19 WEST THIRTY-FOURTH STREET,

February, 1893.



Digitized by the Internet Archive  
in 2010 with funding from  
Open Knowledge Commons

<http://www.archive.org/details/lessonsphysi00loom>

# CONTENTS.

---

	PAGE
LESSON I.	
INTRODUCTION—TOPOGRAPHY OF THE WALLS OF THE CHEST— CONTENTS OF THE VARIOUS REGIONS.....	3
LESSON II.	
INSPECTION, PALPATION, AND MENSURATION.....	11
LESSON III.	
PERCUSSION.....	19
LESSON IV.	
AUSCULTATION.....	29
LESSON V.	
ABNORMAL OR ADVENTITIOUS SOUNDS.....	40
LESSON VI.	
AUSCULTATION OF THE VOICE.....	47
LESSON VII.	
A SYNOPSIS OF PHYSICAL SIGNS IN THE DIAGNOSIS OF PULMONARY DISEASES.....	53
LESSON VIII.	
A SYNOPSIS OF PHYSICAL SIGNS IN THE DIAGNOSIS OF PULMONARY DISEASES—CONTINUED.....	66

LESSON IX.	
TOPOGRAPHY OF THE HEART AND AORTA—PHYSIOLOGICAL ACTION OF THE HEART.....	PAGE 81
LESSON X.	
METHODS OF CARDIAC PHYSICAL EXAMINATION.....	89
LESSON XI.	
ABNORMAL SOUNDS OF THE HEART .....	97
LESSON XII.	
SYNOPSIS OF THE PHYSICAL SIGNS OF PERICARDITIS—HYPERTROPHY, DILATATION, AND FATTY DEGENERATION OF HEART.....	113
LESSON XIII.	
ANEURISM OF THE THORACIC AORTA AND ARTERIA INNOMINATA—EPIGASTRIC PULSATION—SUB-CLAVIAN MURMURS—VENOUS PULSATIONS AND MURMURS.....	121
LESSON XIV.	
ABDOMEN—INTRODUCTION—TOPOGRAPHY OF THE ABDOMEN—CONTENTS OF THE VARIOUS REGIONS—ABDOMINAL INSPECTION, PALPATION, PERCUSSION, AND AUSCULTATION—DISEASED CONDITIONS OF THE PERITONEUM... ..	131
LESSON XV.	
PHYSICAL SIGNS OF THE ABNORMAL CHANGES IN THE DIFFERENT ABDOMINAL ORGANS—STOMACH—INTESTINES—LIVER—SPLEEN,	141
LESSON XVI.	
PHYSICAL SIGNS OF THE ABNORMAL CHANGES IN THE DIFFERENT ABDOMINAL ORGANS—CONTINUED.....	157
LESSON XVII.	
URINE—INTRODUCTION—PLAN OF EXAMINATION—PHYSICAL CHARACTERS—CHEMICAL CHARACTERS—NORMAL ELEMENTS—ABNORMAL ELEMENTS.....	175

## LESSON XVIII.

	PAGE
CLINICAL MICROSCOPY—BLOOD—SPUTUM—URINE—VOMIT—FÆCES,	199

## LESSON XIX.

MECHANICAL AIDS IN THE DIAGNOSIS OF DISEASES OF THE RESPIRATORY AND VASCULAR ORGANS—STETHOSCOPE—STETHOMETER—CYRTOMETER—CARDIOMETER—LARYNGOSCOPE—SPHYGMOGRAPH	235
--	-----

## LESSON XX.

MECHANICAL AIDS IN THE DIAGNOSIS OF DISEASES OF THE NERVOUS SYSTEM, AND IN GENERAL DISEASES—OPHTHALMOSCOPE—THERMOMETER—MICROSCOPE—DYNAMOMETER—ÆSTHESIOMETER—EXPLORING TROCAR—SPECULA.....	250
---	-----



## LIST OF ILLUSTRATIONS.

---

FIG.	PAGE
1. The anterior region of chest, the boundaries of its subdivisions, and the organs corresponding to these subdivisions, . . .	5
2. The posterior region of chest, the boundaries of its subdivisions, and the organs corresponding to these subdivisions, . . .	8
3. Diagram illustrating the production of rales, . . . . .	41
4. Cavernous respiration and gurgles, . . . . .	44
5. Roughening of the pleuræ, and slight pleuritic effusion, . . .	45
6. Diagram illustrative of the physical signs of the three stages of pneumonia, . . . . .	58
7. Diagram showing the pleural cavity completely filled with liquid, the lung being compressed, . . . . .	68
8. Diagram illustrative of the physical signs of hydro-pneumothorax, . . . . .	73
9. Diagram showing the changes in the valves and cavities of one side of the heart during a cardiac pulsation, . . . . .	84
10. Representation of the movements and sounds of the heart during a cardiac cycle, . . . . .	86
11. Representation of the altered relations of the sounds in slowed or accelerated heart action, . . . . .	87
12. Diagram illustrating the mode of production of cardiac murmurs in the left heart, and the condition of the valves and cavities during their production, . . . . .	100
13. Diagram showing the areas of cardiac murmurs, . . . . .	104
14. Diagram showing the pericardial sac partially filled with liquid, and plastic exudation upon the two surfaces of the pericardium above the level of the liquid, . . . . .	114
15. Hypertrophy of left ventricle, . . . . .	116
16. Hypertrophy of right ventricle, . . . . .	117
17. Diagram showing the different regions of the abdomen, and the organs contained in each, which are visible on the removal of the abdominal walls, . . . . .	133
18. The volume of the liver in various diseases, . . . . .	146
19. Diagram representing the different areas occupied by the spleen in its various enlargements into the abdominal cavity, . . . . .	154
20. Diagram showing the gradual enlargement of a tumor of the right ovary till it fills a large portion of the abdominal cavity, . . . . .	165

FIG.	PAGE
21. Urinometer, . . . . .	180
22. Ureometer, . . . . .	182
23. Albuminometer, . . . . .	188
24. Saccharometer, . . . . .	192
25. Cellular elements of human blood, . . . . .	200
26. Blood from case of leucocythæmia, . . . . .	201
27. Poikilo-, macro-, and microcytes, . . . . .	203
28. Spirillum of relapsing fever, . . . . .	204
29. Bacillus of anthrax, . . . . .	205
30. Bacillus of typhoid fever, . . . . .	205
31. Plasmodium malarix, . . . . .	206
32. Filaria sanguinis hominis, . . . . .	206
33. Curschmann's spirals, . . . . .	208
34. Bronchial cast, . . . . .	203
35. Elastic tissue, . . . . .	209
36. Tubercle bacilli from sputum, . . . . .	213
37. Actinomyces, or ray fungus, . . . . .	214
38. Pneumococcus, . . . . .	214
39. Echinococcus hooklets, . . . . .	215
40. Urate of soda, . . . . .	216
41. Urate of soda with spicula, . . . . .	216
42. Urate of ammonia, . . . . .	216
43. Uric acid, . . . . .	217
44. Calcium oxalate, . . . . .	218
45 and 46. Ammonio-magnesium, or "triple" phosphates, . . . . .	218
47. Calcium phosphate, . . . . .	219
48. Cystin, . . . . .	219
49. Leucin, . . . . .	220
50. Tyrosin, . . . . .	220
51. Pus corpuscles, . . . . .	221
52. Pus corpuscles treated with acetic acid, . . . . .	221
53. Epithelial cells, . . . . .	222
54. Spermatozoa, . . . . .	223
55. Types of hyaline casts, . . . . .	223
56. Epithelial casts, . . . . .	224
57. Granular casts, . . . . .	224
58. Fatty casts, . . . . .	225
59. Blood casts, . . . . .	225
60. Torula cerevisix, . . . . .	226
61. Penicilium glaucum, . . . . .	226
62. Sarcinæ, . . . . .	226
63. Gonococci, . . . . .	227
64. Hæmin crystals, . . . . .	228
65. Cholera bacilli from fæces, . . . . .	230
66. Amœbæ coli, . . . . .	231
67. Eggs of intestinal ova, . . . . .	232
68. Stethoscope, . . . . .	235
69. Stethometer, . . . . .	236



## LIST OF ILLUSTRATIONS.

xi

FIG.		PAGE
70.	Cyrtometer, . . . . .	237
71.	Cardiometer, . . . . .	239
72.	Laryngeal mirror, . . . . .	239
73.	Head mirror, . . . . .	240
74.	Nasal speculum, . . . . .	243
75.	Marey's sphygmograph, . . . . .	245
76.	Normal pulse tracing, . . . . .	247
77.	A dicrotic pulse tracing, . . . . .	247
78.	Pulse tracing in aortic regurgitation, . . . . .	248
79.	Pulse tracing in aortic stenosis, . . . . .	248
80.	Pulse tracing from a case of atheroma, . . . . .	248
81.	Tracing from frequent pulse, . . . . .	249
82.	Pulse tracing in mitral obstruction, . . . . .	249
83.	Pulse tracing in aneurism of ascending aorta, . . . . .	249
84.	Liebreich's ophthalmoscope, . . . . .	251
85.	Straight self-registering thermometer, . . . . .	257
86.	Microscope, . . . . .	262
87.	Dynamometer, . . . . .	263
88.	Æthesiometer, . . . . .	264
89.	Dieulafoy's exhausting syringe, . . . . .	266



LUNGS.



## LESSON I.

### INTRODUCTION—TOPOGRAPHY OF THE WALLS OF THE CHEST—CONTENTS OF THE VARIOUS REGIONS.

*Gentlemen.*

PHYSICAL DIAGNOSIS is a term used to designate those methods which are employed for detecting disease during life by the anatomical changes which it has produced. The nature and extent of such changes can be recognized and appreciated by the deviations which they cause in the affected organs from the known physical condition of these organs when in health. The significance of physical signs in disease can be determined, not by theory, but only through clinical observation confirmed by examinations after death.

There are five methods of eliciting these physical signs, termed "physical methods of diagnosis," viz., *Inspection, Palpation, Mensuration, Percussion, and Auscultation.*

The most important of these are *Auscultation* and *Percussion.* The other methods are only subsidiary to these two, and can seldom be regarded as furnishing positive evidence of disease. For a complete and accurate physical exploration you must sometimes employ all these different methods, and with all, therefore, you should become familiar.

In order to localize physical signs, the chest has been divided into artificial regions; but as the limits of these

regions are arbitrary, the boundaries adopted by different writers vary. The following divisions, which correspond very nearly to those proposed by many authorities, you will find, I think, sufficiently small and well defined for practical purposes. It is important that you should be familiar, not only with the boundaries of these regions, but with the relative position of the structures and organs or portions of organs included within them.

The surface of the chest may be divided into three general regions—*Anterior*, *Posterior*, and *Lateral*. The *Anterior region*, on either side, may be subdivided into *Supra-Clavicular*, *Clavicular*, *Infra-Clavicular*, *Mammary*, and *Infra-Mammary*. Between the two anterior regions we have the *Supra-Sternal*, *Superior Sternal*, and the *Inferior Sternal*. The *Posterior region*, on either side, may be subdivided into the *Supra-Scapular*, *Scapular*, and *Infra-Scapular*. Between these you have the *Inter-Scapular*. The *Lateral region*, on either side, may be subdivided into *Axillary* and *Infra-Axillary regions*.

The SUPRA-CLAVICULAR region is a triangle whose base corresponds to the trachea ; whose lower side, to the upper border of the clavicle ; and whose upper side, to a line drawn from the outer third of the clavicle to the upper rings of the trachea. This region contains, on either side, the apex of the lung, with portions of the subclavian and carotid arteries, and the subclavian and jugular veins.

The CLAVICULAR space is that which lies behind the inner three-fifths of the clavicle, and has the bone for its boundary. It is occupied on both sides by lung tissue; on the right side, at its outer extremity, lies the subclavian artery ; at the sterno-clavicular articulation, the *arteria innominata*. On the left side, almost at right

angles with the bone, and deeply seated, are the carotid and subclavian arteries.

The INFRA-CLAVICULAR region has for its boundaries the clavicle above, the lower border of the third rib below, the edge of the sternum inside, and outside a line falling vertically from the junction of the middle and

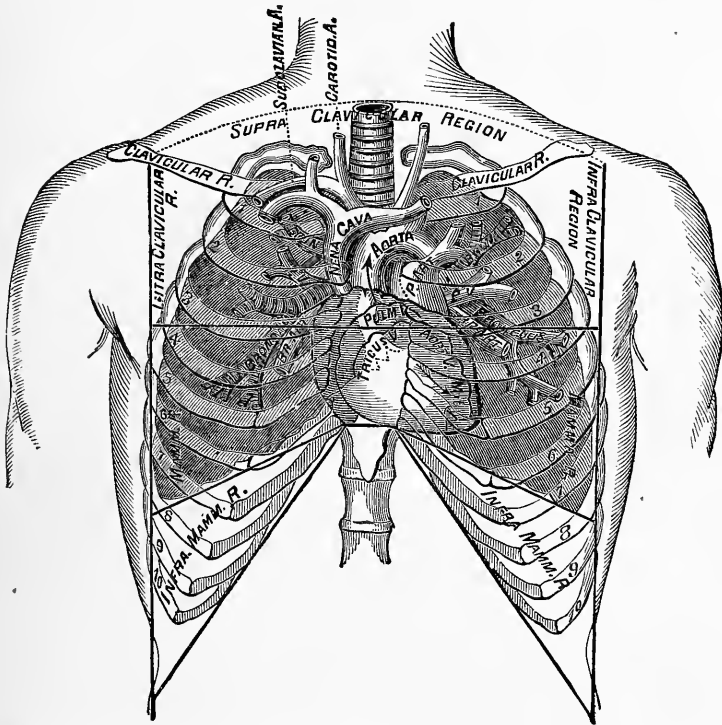


FIG. 1.—The Anterior Region, the Boundaries of its Subdivisions, and the Organs corresponding to these Subdivisions.

outer thirds of the clavicle. Within these limits, on both sides, you will find the superior lobe of the lung and the main bronchi; the right bronchus lies behind, and the left a little below the second costal cartilage. On the right side, close to the sternal border of the region, lie the superior cava and a portion of the arch of

the aorta; on the left, a portion of the pulmonary artery. The aorta and pulmonary artery are immediately behind the second sterno-costal articulations; the one on the right, the other on the left side of the sternum. On the left side the lower boundary of the region very nearly corresponds to the base of the heart.

The MAMMARY region is bounded above by the third rib; below, by the inferior margin of the sixth rib; inside, by the edge of the sternum ; and outside, by a vertical line, continuous with the outer border of the infra-clavicular region. You will find this region to differ materially in its contents on the two sides. On the right side the lung is found extending, in front, down to the sixth rib, where its thin, sharp border very nearly corresponds to the lower boundary of the region. The right wing of the diaphragm, though not attached higher than the seventh rib, is usually pushed up by the liver as high as the fourth interspace; a portion of the right auricle of the heart, and the superior angle of the right ventricle, lie close to the sternum, between the third and fifth ribs. On the left side the lung is in front as far as the fourth sterno-costal articulation, where its anterior border passes outward until it reaches the fifth rib (leaving an open space for the heart); then it crosses forward and downward as far as the sixth rib ; a small portion of the apex of the right ventricle is also found within this region.

The INFRA-MAMMARY region is bounded above by the lower border of the sixth rib; below, by a curved line corresponding to the edges of the false ribs; inside, by the inferior portion of the sternum ; and outside, by the continuation of the outer boundary of the mammary region. This region, on the right side, contains the liver, with a portion of the lung in front, on a full inspiration.



On the left, lying in front, near the median line, you have a portion of the left lobe of the liver, the stomach, and the anterior border of the spleen. The stomach and spleen usually rise to a level with the sixth rib.

The SUPRA-STERNAL region is the space which lies immediately above the notch of the sternum, and is bounded on either side by the sterno-mastoid muscle. It is occupied chiefly by the trachea, by the arteria innominata at its lower right angle, and by the arch of the aorta, which sometimes reaches to its lower border, where, on firm downward pressure with the end of the finger, you will often be able to feel it.

The UPPER STERNAL region is the space bounded by that portion of the sternum which lies above the lower margin of the third rib. In this region the lungs lie in front, but do not completely close in the space. Immediately behind them are the ascending and transverse portions of the aorta, and the pulmonary artery from its origin to its bifurcation. The left vena innominata crosses the sternum a little below its upper border. Situated deeply, at the junction of the first and second bones of the sternum, is the trachea, dividing into its two bronchi. The pulmonary valves are situated behind the left edge of the sternum, at its junction with the third costal cartilage. The aortic valves are about half an inch lower down, and midway between the median line and the left edge of the sternum.

The LOWER STERNAL region corresponds to that portion of the sternum which lies below the lower margin of the third rib. Throughout the whole extent of this region, on the right side, the lung is in front; it also extends down on the left side as far as the fourth sternocostal articulation; below this lies the greater part of the right ventricle, and a small portion of the left. The

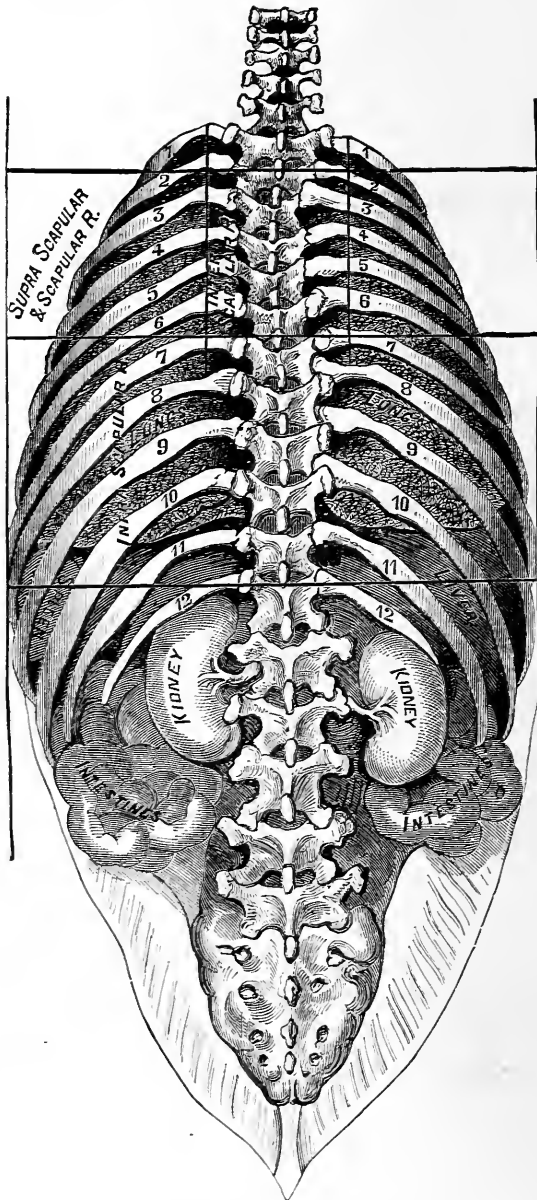


FIG. 2.—The Posterior Region, the Boundaries of its Subdivisions, and the Organs corresponding to these Subdivisions. (After SIMSON.)

mitral valve, deepest of all, is situated behind the third left intercostal space, about one inch from the sternum; the tricuspid valve is near the middle of the sternum, at the level of the fourth costal cartilage. Inferiorly is the attachment of the heart to the diaphragm; below this is a small portion of the liver, and sometimes of the stomach.

The SUPRA-SCAPULAR and SCAPULAR regions together occupy the space from the second to the seventh rib, and are identical in their outlines with the upper and lower fossæ of the scapula. These regions are occupied by lung substance.

The INFRA-SCAPULAR region is bounded above by the inferior angle of the scapula and the seventh dorsal vertebra; below, by the twelfth rib; outside, by the posterior border of the lower axillary region; and inside, by the spinous processes of the vertebræ. Immediately underneath the surface, as far as the eleventh rib, this region is occupied by the lungs. On the right side the liver extends downward beyond the level of the eleventh rib; on the left the intestine occupies the inner part of this region, and the spleen the outer. Close to the spine, on each side—more on the left than on the right—a small portion of the kidney is found; along the left side of the spine runs the descending aorta.

The INTER-SCAPULAR region is the space between the inner margin of the scapula and the spines of the dorsal vertebræ, from the second to the sixth. This region contains, on both sides, lung substance, the main bronchi, and the bronchial glands. It also encloses on the left side the œsophagus, and from the upper part of the fourth dorsal vertebra downward, the descending aorta. The bifurcation of the trachea will be found opposite the third dorsal vertebra.

The AXILLARY region has for its limits the axilla, above; below, a line carried backward from the lower boundary of the mammary region to the inferior angle of the scapula; in front, the outer margin of the infra-clavicular and mammary regions; and behind, the external edge of the scapula. This region corresponds to the upper lobes of the lungs, with the main bronchi deeply seated.

The INFRA-AXILLARY region is bounded above by the axillary region; anteriorly, by the infra-mammary; posteriorly, by the infra-scapular; and below, by the edges of the false ribs. This region contains, on both sides, the lower edge of the lung sloping downward and backward. On the right side is the liver, and on the left the stomach and spleen.

## LESSON II.

### INSPECTION, PALPATION, AND MENSURATION.

INSPECTION is the ocular examination of the external surface. Though usually secondary in importance to Auscultation and Percussion, it should not be lightly regarded, for it often furnishes you much information respecting the condition of the thoracic and abdominal viscera. By Inspection you recognize changes in the size, form, or symmetry of the cavities in which they are contained, and in the movements of their walls during respiration, as regards their rhythm, frequency, or force.

As students of anatomy you are familiar with the form of a well-proportioned chest ; a description of it is, therefore, unnecessary. Suffice it to say that, in a normal state, the two sides are symmetrical in every part ; the intercostal spaces are more or less distinct, according as the individual is more or less fat. Normal breathing is of two kinds, *costal* and *diaphragmatic*. In the costal the movements are chiefly thoracic ; in the diaphragmatic they are chiefly abdominal. In quiet respiration you will notice the abdominal wall rise with inspiration, and fall with expiration ; at the same time you will observe a lateral expansion of the lower ribs, and a slight upward movement of the upper part of the chest with inspiration, and a downward movement with expiration. The movements of respiration in these three situations are called, respectively, *abdominal*,

*inferior costal*, and *superior costal*. In the female, the costal breathing is most marked; in the male, the diaphragmatic. The number of respirations to the minute varies at different periods of life; in childhood it is about twenty-six; from the twentieth year, about sixteen to twenty.

Considerable alterations in the form and movements of the chest are compatible with a healthy condition of the thoracic viscera. You rarely meet with a perfectly symmetrical chest, even among the healthy. In my examination of fifteen hundred persons I found only one well-proportioned, symmetrical chest in seven. As you can easily recognize these healthy deviations from symmetry, I shall not enter into details concerning them. I would, however, mention that slight curvatures of the spine, either acquired or the result of former disease of the vertebræ, cause the majority of these deviations.

We will first consider only those changes in the size, form, and movements of the thoracic cavity which are the result of disease of the thoracic organs; confining ourselves, at present, to the lungs and pleuræ. The readiest way of presenting these changes to you, it seems to me, is to consider them as they occur in the different thoracic affections. First we will consider the signs obtained by inspection in pleurisy. In the first stage, prior to the occurrence of much liquid effusion, there is no apparent change in the size, but the movements of the affected side are diminished, and those of the healthy are increased; you have what is termed a catching respiration. This sign is not distinctive of pleurisy; it is present in intercostal neuralgia and in pleurodynia. In the stage of liquid effusion, if the liquid is sufficient to compress the lung and dilate the thoracic walls, the affected side will be increased in size, and, in

proportion to the dilatation, its movements are restricted or arrested. If the cavity is completely filled with liquid, there will be bulging and widening of the intercostal spaces, with more or less displacement of the adjacent viscera. As the liquid is absorbed the lung expands, but not to the same volume it had before. It remains more or less contracted, and the consequence is, retraction of the affected side from atmospheric pressure. Generally, if the liquid effusion shall have existed a considerable length of time previous to absorption, the subsequent retraction is marked, and you can determine at once by inspection that pleurisy has existed at some period more or less remote.

In pulmonary emphysema, if it is a well-marked case, on inspection you will notice a dilatation of the upper portion of the chest, while its whole aspect appears more rounded than in health, so that it has received the name "barrel-shaped" chest; the shoulders are elevated and brought forward; the movements in respiration are limited to the lower portions of the chest and to the abdomen. On inspiration there is no outward expansive movement of the ribs; the sternum and ribs seem to move up and down as if they were composed of one solid piece; in some cases of long standing you will have actual falling-in instead of expansion of lower ribs during inspiration. In a well-marked case of emphysema, *inspection* is quite sufficient for a diagnosis; but where the lungs are but slightly emphysematous, inspection furnishes no positive information. In pneumonia, the only sign furnished by inspection is that the movements of the affected side are restrained, as in the first stage of pleurisy. In pulmonary tuberculosis inspection furnishes you important information. Depression in the infra-clavicular region on the affected

side is an early sign of tubercular deposit. In advanced tuberculosis, the depression is still more marked, in some instances amounting almost to deformity. The expansive movements in inspiration on the affected side, in the infra-clavicular region, are diminished or entirely wanting, and this want of expansion is often noticeable at a very early period in the disease.

Bulging or partial enlargement of the chest, determinable by inspection, occurs in various affections. Enlargement of the præcordia is observed in certain cases of hypertrophy or dilatation of the heart, or from liquid effusion in the pericardium. Bulging occurs also over aneurismal and other tumors

In cases of membranous croup, acute and chronic laryngitis, and œdema glottidis, inspection will disclose to you the seat of the obstruction to the passage of air to the lung by a sinking-in during inspiration of the parts of the chest which yield most readily to atmospheric pressure. This sinking-in on inspiration you will notice first in the supra-clavicular spaces, then in the infra-clavicular spaces, and, as the obstruction increases, the sternum is depressed and the sides contracted.

Although furnishing few positive evidences of disease, you should always employ inspection prior to the other methods of physical exploration. This is important in all cases where the evidences furnished by the other physical signs are not conclusive.

**PALPATION**, or the act of laying on the hand and feeling the external surface of the body, is less useful than inspection in ascertaining deformities, and the amount of general movement; but it is more useful in determining the amount of local expansion, and the character of vibration or impulses communicated to the external surface.



In order to arrive at satisfactory results from its employment, you should observe the precautions already named as influencing accurate inspection ; beyond this, I need only mention that in thoracic examinations the hand or the fingers should be gently and evenly applied to the surface of the chest, and that corresponding portions of the two sides of the thorax should be examined simultaneously, the one with the right hand and the other with the left. If you lay your hand lightly upon the surface of the chest of a healthy person while speaking, a delicate tremulous vibration will be felt, varying in intensity with the loudness and coarseness of the voice and the lowness of its pitch ; this is called *normal vocal fremitus*. As a rule, vocal fremitus is more marked in adults than in children, in males than in females, and in thin than in fat persons. In the right infra-clavicular region it is more marked than in the left. Variations in the vocal fremitus are the most important evidences of disease furnished by palpation ; in fact, all other evidences of pulmonary disease afforded by palpation are better obtained by inspection.

In disease, the normal vocal fremitus may be *increased*, *diminished*, or *entirely absent*.

Increased vocal fremitus occurs in those affections in which lung tissue becomes more or less solidified, as in tuberculosis, pneumonia, pulmonary apoplexy, and œdema of the lung. When the consolidation is extreme, involving bronchial tubes of considerable size, the vocal fremitus may be diminished or even absent ; while increase in the size of the bronchial tubes, with the slight adjacent consolidation met with in chronic bronchitis, often gives rise to increased vocal fremitus.

Diminution or absence of the normal vocal fremitus occurs whenever the lung substance is separated from

the chest walls by gaseous or liquid accumulations in the pleural cavity, as in pneumothorax, serous, plastic, hæmorrhagic, or purulent pleuritic effusions. In vesicular emphysema, owing to the dilated condition of the air cells, vocal fremitus is diminished. Besides these valuable indications furnished by vocal fremitus, you may employ palpation to detect the friction caused in pleurisy by the rubbing together of the two roughened surfaces of the pleural membrane, and which is termed *friction fremitus*.

Sibilant and sonorous rales also sometimes throw the bronchial tubes into vibration, sufficiently strong to be felt on the surface of the chest ; this is termed *sonorous* or *rhonchial fremitus*. Cavernous gurgles produced in excavations near the surface may be accompanied with a marked fremitus.

Palpation may also be employed to detect points of tenderness, and to determine the density and condition of tumors.

MENSURATION is another method of physical exploration, employed for obtaining information similar to that furnished by inspection and palpation. We seldom employ it in physical examinations of the lungs unless great accuracy is required, as in the record of cases. The instruments which have been devised for the measurement of the chest, and the different lines of measurement, are numerous. The circular measurement is the only one that I have found of practical value in investigating pulmonary disease. The simplest and most accurate mode of measuring the circular dimensions of the chest is by means of the instrument devised by Dr. Hare, which consists of two pieces of tape similarly graduated, joined together, and padded on their inner surface close to the line of junction ; the saddle thus

formed, when placed over the spine, readily adjusts itself to the spinous processes, and becomes fixed sufficiently for the purpose of mensuration. For comparing the expansive movements of the two sides you will find Dr. Quain's stethometer<sup>1</sup> very useful. The object of the circular measurement of the chest is twofold—first, to ascertain the comparative bulk of the two sides; second, to ascertain the amount of expansion and retraction accompanying inspiration and expiration of the two sides. The points of measurement are the spinous processes behind and the median line in front, on the level of the sixth costo-sternal articulation.

The average circular dimension of the chest at this point in fifteen hundred healthy persons was thirty-two and a half inches. I also found in these examinations that about four-fifths of healthy adults have irregularity of the two sides. In right-handed individuals the right side is about one-half inch larger than the left; in left-handed, the left. This is true of both sexes.

The really important point of mensuration in pulmonary diseases is the comparison of the two sides of the chest, in rest and in motion. When a pleural cavity is distended with air or fluid, the measurement of the affected side may exceed that of the healthy side by two or three inches; after the removal of the fluid there may be an equal diminution in the measurement of the affected side, as compared with the healthy one.

Deficiency of expansion is also very marked in certain diseases. In empyema, for instance, you will often find the total difference between the fullest inspiration and the fullest expiration, on the affected side, will scarcely exceed one-sixteenth of an inch, while on the other side there may be a difference of two or three inches.

<sup>1</sup> See page 236.

The list of affections in which variations in expansion are to be estimated by measure are the same as those referred to under the head of Inspection.

The measurement of the capacity of the lungs for air, by means of Dr. Hutchinson's spirometer, or of the "vital capacity of the chest," as he terms it, has been shown by experience to be very unreliable, and his instrument has fallen almost entirely into disuse.

## LESSON III.

### PERCUSSION.

PERCUSSION, as a means of diagnosis, is not of recent date, for we find it mentioned by Hippocrates. But as the only mode of practising it was by striking the surface itself with the tips of the fingers, or knuckles, now termed, technically, *immediate* percussion, its uses were very limited. Within our time, however, M. Piorry gave it an entirely new value by introducing *mediate* percussion—the stroke being made, not on the surface, but on some intervening substance applied to it; and he so demonstrated, by experiments on living and dead bodies, its superior applicability for determining changes in the subjacent parts, that mediate percussion ranks now only second to auscultation among the methods of physical exploration.

To estimate the value of percussion and to understand its true significance, you must first learn to appreciate correctly the elements of sound. Authors have employed a variety of terms to designate them, such as clearness, dulness, emptiness, fulness, etc.; but I think that a classification based upon analysis of the elements of sound in general, will afford us the truest and most practical distinctions, especially in estimating the sounds in thoracic percussion. Those elements or acoustic properties of percussion sounds which concern us clinically are termed, respectively, *Intensity*, *Pitch*, *Quality*, and *Duration*.

The INTENSITY of a percussion sound may be increased or diminished by increasing or diminishing the force of the percussion blow. But in *pulmonary* percussion, you will find that the intensity depends not only on the force of the blow, but is further modified by the amount of air contained in the lung tissue, by the thickness of the soft parts covering the thoracic walls, and also by the elasticity of the costal cartilages.

The PITCH of the percussion sound is always low over healthy lung substance, and, as a rule, the greater the quantity of air contained in the corresponding pulmonary tissue, the lower the pitch; consequently, you will find the pitch of the percussion sound varying very perceptibly in the different regions of a healthy chest. You can, however, familiarize the ear with the characters of normal pitch only by constant practice.

QUALITY in sound is that element by which we distinguish any given sound from every other. Thus it is by the quality that you know the sound of one musical instrument from another. The quality of the note emitted on percussion over healthy lung substance, and termed normal vesicular resonance, is sufficiently marked and peculiar to be easily recognized, though it cannot be easily described, and is to be learned only by experience.

The DURATION of a given sound, you will find varying according to the pitch of that sound; the higher the pitch, the shorter the duration, and *vice versâ*. For example, the duration of the percussion sound is perceptibly longer in the infra-clavicular region of a healthy chest than over the heart.

You will find that a certain definable relationship exists between these respective elements of the percussion note, which has a correspondence to the different regions of the chest. Thus, after noting the intensity, pitch,

quality, and duration of the percussion sound in the infra-clavicular region, you will find that over the heart it has a higher pitch and harder quality, but a less intensity and a shorter duration.

The substance which receives the stroke in mediate percussion is termed a *pleximeter*, of which many varieties have been devised, made of wood, ivory, gutta percha, etc. They are in nowise superior, however, to the left index or middle fingers, when their palmar surface is applied evenly to the chest; for these, besides being the most *handy*, also answer best the chief requisite of a pleximeter in that they can be easily fitted with accuracy to any part of the thoracic walls. Moreover, their own proper sound, on being struck, is inappreciable, which is not the case with ivory, wood, etc. Likewise, you will discover nothing better to strike *with* than the finger tips of the other hand, brought into line; while, for gentle percussion, the middle finger alone may suffice.

Now, as the practice of percussion requires some manual dexterity, and the correctness of its indications depends in great measure upon the mode in which it is performed, you will find it useful to have recourse to the following rules as your guides :

*First.* You should attend as carefully to the position of your patient as a photographer would, if he were going to take his likeness. Whether lying, sitting, or standing, his body should rest on the same plane, and his limbs be disposed similarly, on either side, so as to render the muscular tissue covering the thoracic walls equally tense. In percussing particular regions, however, the first aim is to make the intervening tissue as firm and thin as possible. Thus, when you percuss the front of his chest, the arms should hang loosely down,

but the head be thrown back. On the contrary, the arms should be raised to the level of the head when you are percussing the lateral regions, and should be crossed in front, the patient leaning moderately forward, when you percuss the back. It is better to percuss on the naked skin, but various considerations may make this inadvisable. You should then aim to have the covering as soft, thin, and, especially, as even as possible.

*Second.* The two sides of the chest should, for comparison, be percussed at the same stages of the respiratory act. You should, also, take care to compare only corresponding portions in the two sides. Thus, you should not compare a note during inspiration on the right side with one during expiration on the left, nor that over a rib with that of an interspace.

*Third.* The finger, or pleximeter, should be applied with equal firmness, and in the same parallel, to both sides in succession, and the force of the percussion should be exactly the same; for the sound will vary considerably even on the same spot, whether you press lightly or firmly with your finger, whether it is across a rib or along it, and, finally, whether you strike gently or forcibly.

*Fourth.* The stroke in percussion should be made from the wrist alone, the arm and forearm not participating in it; and its force should be proportioned to the depth of the part to be examined—gentle if superficial, and forcible when deep seated.

PERCUSSION IN HEALTH.—The significance of the percussion sounds in disease depends so entirely on their variation from the sounds which are proper to the part in health, that you cannot pay too much attention to the various characters of *normal* thoracic percussion; for on this almost every deduction which results from



your examination is based. Now, the percussion sounds differ materially in a healthy thorax, according to the region percussed. Taking the percussion note of the infra-clavicular region as the standard for pulmonary percussion, we find each of the other regions has its own variations from it. In the *right infra-mammary* region you will get, by gentle percussion, the same note as in the infra-clavicular ; but forcible percussion, at and below the fourth interspace, will raise the pitch and harden the quality, owing to the presence of the liver behind the shelving border of the lung. Over the *left infra-mammary* region the pitch is similarly varied by the presence of the heart, until it reaches complete flatness at its inner border. The resonance of the *right infra-mammary* region has a harder quality, higher pitch, and shorter duration, from the presence of the liver immediately beneath. The *left infra-mammary* region is similarly affected at its inner part by the left lobe of the liver, and at its outer border by the spleen, while the intermediate space gives a tympanitic resonance from the subjacent stomach. Over both *clavicles* you will get a mixed pulmonary and osseous resonance, while in the *supra-sternal* region the percussion sound has a distinctly tubular character. In the *superior sternal* region it has a bony tubular resonance down to the second rib ; below this, to the third rib, it is raised in pitch and hardened in quality. The dulness on percussion becomes complete in the next region, or *inferior sternal*, owing to the presence of the heart and great vessels, together with the left lobe of the liver.

The SUPERIOR and MIDDLE AXILLARY regions are extremely resonant as far down as the fourth interspace ; the pitch is even lower than in the infra-clavicular region, but below the fourth interspace the pitch rises, till

complete dulness is found on a level with, and below, the seventh rib. This dulness continues through the *infra-axillary* regions on either side.

In the SUPRA-SCAPULAR and SCAPULAR regions the percussion sound is high-pitched and hard in quality, except in the supra-spinous fossæ, where it has the soft quality characteristic of pulmonary percussion. In the *infra-scapular* region you have pulmonary resonance as far down as the tenth rib, and complete flatness below. with left  
In the *inter-scapular* region the percussion is high-pitched and tubular in quality.

Besides variations in percussion sounds dependent on difference in regions, there are still others ascribable to age, sex, idiosyncrasies, etc. You will find the percussion sound in children of a softer quality and lower pitch than in adults ; while in the aged it rises in pitch, and measurably loses its pulmonary quality. In females the percussion sound is relatively more pulmonary in all its characters than in males. Marked deformity of the chest, whether congenital or acquired, also modifies the normal resonance. But it also varies materially in different individuals who are equally healthy. In some persons this difference may be accounted for, while in others it cannot ; but, as a rule, the thinner the chest walls, the greater is the intensity, the lower the pitch, and the more pulmonary the quality of the percussion sound.

PERCUSSION IN DISEASE.—It is obvious, from what precedes, that whatever modifies the density of the lung substance, and changes its proper elasticity, will cause a corresponding modification in the normal pulmonary resonance ; for as the lung texture is rendered more dense, or less so, than natural, the percussion sound passes through every gradation from marked resonance to complete dulness. These modifications, caused by dis-

ease, we would classify under the following heads, viz.: *Exaggerated Pulmonary Resonance, Dulness, Flatness, Tympanitic Resonance, Vesiculo-Tympanitic Resonance, Amphoric Resonance, and Cracked-Pot Resonance.*

EXAGGERATED PULMONARY RESONANCE consists in an increase of the intensity of the sound, the pitch being slightly lower, while the quality remains unchanged. This sign may exist to a slight degree over the whole or over a portion of a lung which is performing more than its usual share of labor. Thus, if one pleural cavity is filled with fluid, or if one lung is solidified by the exudation of pneumonia, or the seat of extensive tuberculous deposit, you will find the resonance of percussion increased on the opposite unaffected side, which is now doing double duty. Extensive anæmia, by lessening the quantity of blood in the lungs, may also give rise to slight extra resonance on percussion.

DULNESS.—This consists in a diminution of the pulmonary resonance, and may be slight, considerable, or complete, according as more or less air enters the affected part. In dulness the intensity is diminished, the pitch raised, the duration shortened, and the quality hardened. Dulness always indicates a decrease in the normal proportion of air in the part, and is an important physical sign in a number of diseases, as in pneumonia, tuberculosis, œdema of the lungs, etc.

FLATNESS.—This indicates the total absence of air, so that there is no proper pulmonary resonance, and its sound resembles that produced by percussing the thigh. We have examples of this when we percuss over liquid contained in the pleural or pericardial serous cavities, or when tumors are developed in the thorax, etc.

TYMPANITIC RESONANCE.—This is marked by the absence of proper pulmonary *quality* in the characters of its

resonance, the type being the resonance of a tympanitic abdomen on percussion ; in intensity it exceeds normal pulmonary percussion, and is lower in pitch.<sup>1</sup> As a physical sign in thoracic affections it usually indicates the presence of air in the pleural cavity, as in pneumothorax. In this affection we have air contained, not in small vesicles, but in a large free space, and hence we have not the vesicular but the tympanitic quality in the sound.

**VESICULO-TYMPANITIC RESONANCE.**—By this term (introduced by Prof. A. Flint) it is meant to denote a resonance in which we have both the tympanitic and vesicular qualities. It is lower pitched but more intense than normal pulmonary resonance, and is present when the increase of the volume of the lung, as in some cases of emphysema, is so great as to dilate and render extremely tense the thoracic walls.

**AMPHORIC RESONANCE**, unlike tympanitic resonance (which gives an impression of fulness), is suggestive of shallowness or emptiness ; it resembles the sound produced by flapping the cheek when the mouth is closed, and fully but not forcibly inflated. It is most frequently heard over a large superficial cavity having thin, tense walls, and hence is usually indicative of phthisis. In cases of pleuro-pneumonia, a sound more or less amphoric in character is sometimes heard.

**CRACKED-POT RESONANCE** is usually, though not invariably, heard in connection with amphoric resonance. It resembles the sound produced by striking the hands, loosely folded across each other, against the knee, the contained air being suddenly forced out between the fingers. If there exists a pulmonary cavity of large size,

---

<sup>1</sup> Many authorities speak of the pitch as raised. I regard it lower than normal. But pitch is not an essential element. We recognize the tympanitic sound by its quality, not its pitch.

with thin walls, communicating freely with a large bronchial tube, the chest walls being at the same time particularly yielding, forcible percussion, with the patient's mouth open, will yield cracked-pot resonance. Dr. Hughes Bennett states that a cracked-pot resonance may be elicited in various diseases of the chest, and even when the chest is perfectly sound. I have never obtained true cracked-pot resonance unless over a pulmonary cavity or in pneumothorax.

AUSCULTATORY PERCUSSION.—This is a combination of auscultation and percussion. It was first brought to the notice of the profession by Drs. Cammann and Clark in 1840.

Their method of performing it was as follows: Press the objective end of a stethoscope, constructed expressly for this purpose<sup>1</sup> (while the ear piece is accurately fitted to the ear), firmly and evenly on the surface, directly over that portion of the organ or tumor to be examined which is most superficial; then let percussion be performed in the usual way, one or two inches from the point at which the stethoscope is applied. The percussion sound communicated to the ear in this manner far exceeds in intensity and distinctness the same sound

---

<sup>1</sup>This instrument is a solid cylinder of wood, shaped in the direction of the woody fibres, six inches in length and ten or twelve lines in diameter; furnished with an ear piece which will allow nearly the whole cylinder to pass through it, so that it may apply directly to the tube of the ear, without change of medium. To avoid as much as possible the sound of the thoracic walls, as is desirable in some cases, this instrument has been modified by reducing it at its objective extremity to a truncated wedge, leaving the other extremity as before. This is applied between the ribs so as not to touch them, and at the same time approach somewhat nearer the object under examination.—New York Journal of Medicine and Surgery, July, 1840.

when communicated through the medium of the air. The slightest change in pitch and quality is also readily appreciated.

The benefits claimed for auscultatory percussion by its originators are: "*First.* That the heart can be measured in all but its antero-posterior diameters, under most, perhaps all circumstances of health and disease, with hardly less exactness than we should be able to do if the organ were exposed before us.

"*Second.* That the outlines of the liver can be traced with much greater certainty than by ordinary percussion, in circumstances of health; and to circumscribe it in many conditions of disease in which ordinary percussion is not applicable.

"*Third.* That the dimensions of the spleen can be ascertained in circumstances that baffle ordinary percussion.

"*Fourth.* That by it we can mark the superior, inferior, and external limits of the kidneys. Ascites presents no obstacle to the measurement of these organs; and from enlarged spleen the left kidney is easily distinguished."

SUCCESSION is the sudden, forcible shaking of the patient while your ear is applied to the chest wall. It is employed almost exclusively in the diagnosis of one disease, viz., pneumo-hydrothorax. The sound produced resembles that perceived on shaking a bottle, partly filled with water, close to the ear. It is a gurgling, splashing sound, and varies in tone according to the density of the fluid present and the relative quantities of fluid and air present. Succession is almost always accompanied by amphoric respiration and metallic tinkling. I shall reserve its further consideration until I detail the physical signs of pneumo-hydrothorax.

## LESSON IV.

### AUSCULTATION.

AUSCULTATION is a kind of eavesdropping, for in it you bend your ear to catch the significance of sounds that come from hidden quarters which no one may open. As in percussion, so here, auscultation may be *immediate*, when the ear is applied directly to the bared or thinly covered surface ; and *mediate*, when the sounds are conducted from the surface to the ear through a tubular instrument, called a stethoscope.

Both of these methods have their exclusive advocates, but, as each has its own advantages, I would strongly recommend your becoming equally practised in the use of them both. *Per se*, immediate auscultation answers best for pulmonary examinations ; but in examining the heart, where, as in valvular murmurs, you have to analyze circumscribed sounds, your ear will often be confused by the noise of its near neighbor, the left lung, or by other cardiac sounds than the one under examination, and you will find the stethoscope then assists you by measurably excluding the sounds which have their seat outside the rim of the chest piece. Besides, there are cases where the state of the surface may make you very reluctant to bring your ear into immediate contact with the patient's person, while in other cases you may not be allowed to do so, and in such, of course, you would have recourse to the stethoscope.

Stethoscopes of great variety as to form and material

have been recommended, each inventor claiming some superiority in principle, or shape, for his own instrument. They may all, however, be referred to two general classes, viz., flexible and solid. I regard as the best representatives of these two classes those devised by the late Dr. Cammann, of this city. For general use I would recommend his Binaural Stethoscope. It consists of two tubes, the lower extremities of which are connected to a cup-shaped piece of wood or hard rubber. It requires some practice to become adepts in its use, as it indiscriminately intensifies all sounds; but once accustomed to it, you will find, I think, it has no superior.

In the performance of auscultation, as of percussion, certain precautions are requisite in order to insure accurate results. The following rules will be found of service :

*First.* In immediate, but not in mediate auscultation, the chest should have some thin, soft covering which will not interfere with the transmission of sound, or itself produce sound from the movements of the thoracic walls to which it is applied. A soft towel smoothly spread over the surface will answer this purpose very well.

*Second.* The position of the patient should be regulated in the same manner as for the performance of inspection, care being taken that the parts should be in a state of perfect repose. The position of the examiner should be as unrestrained as possible, and he should by all means learn to concentrate his attention on the sounds which reach his ear.

*Third.* The ear, or the stethoscope, should be applied firmly, but not forcibly, to the surface; and, when the stethoscope is used, it is important that its rim press equally and evenly on the part.



*Fourth.* As in percussion, corresponding parts of the two sides of the chest should be compared, and the examination should not be considered complete unless it has included the entire chest. In acute thoracic affections auscultation should be frequently repeated.

*Fifth.* The examination should be commenced, if possible, during ordinary respiration. The patient should be directed to take a full inspiration, then to cough, and then again to breathe naturally. Some find the latter very difficult, when under examination, and they sometimes seem incapable even of completing a full inspiration. In such instances, our object may be attained by performing the act ourselves, and requesting the patient to imitate it, or by directing him to sigh. If these expedients fail, direct him to cough continually for some moments, whereupon a full, clear inspiration follows, and he does involuntarily what his previous efforts have failed to accomplish.

Let us now consider the important subject of the nature and causes of the respiratory sounds in health.

If the ear be applied to a healthy chest, a soft, breezy murmur will be heard, composed of two periods—one corresponding to the movements of inspiration, and the other, both fainter and shorter, to those of expiration. They are termed, respectively, the inspiratory and the expiratory sounds of respiration. The elements of these sounds are analogous to those of percussion, and, hence, we express them by the terms *Intensity*, *Pitch*, *Quality*, and *Duration*, to which, however, we add a fifth—*Rhythm*—which refers to the relative succession of the two periods in the respiratory act. As might be expected, we find variations among these elements, normally present in the various portions of the respiratory tract, and these constitute distinct varieties of respira-

tory sounds, which are named after those portions, in which they occur in health. Thus we speak of vesicular, bronchial, tracheal, and laryngeal respiration, each of these sounds having its own proper intensity, quality, pitch, etc. The left infra-clavicular region in a healthy chest furnishes the purest vesicular respiration; the inter-scapular region, the best normal bronchial respiration; and by placing the stethoscope or ear over the larynx or trachea, you will hear the tracheal and laryngeal breathing. These variations in the intensity, pitch, etc., are due to differences in the volume and velocity of the current of air, on the one hand, and, on the other, to the nature of the obstructions which it meets in its entrance to, or exit from, the pulmonary passages. Every complete respiratory sound, however, retains its division into inspiratory and expiratory murmurs.

Of the normal respiratory sounds, that which stands first in importance is the *Vesicular*. The best representative type of the normal vesicular murmur is found in the left infra-clavicular space, where you will hear during inspiration a sound of a gentle rustling character, most marked at the end of the act. The intensity and duration of this murmur vary in healthy persons, and form the least important of its elements. Its pitch, however, should be low. The expiratory sound, when present (it being absent in four out of five healthy persons when their attention is not directed to their respiration), is much shorter than the inspiratory, its relative duration varying in different individuals; its intensity is less than in inspiration, its pitch higher, and its quality harder; the breezy or vesicular character of the inspiratory sound being wanting. These two sounds follow each other so closely that they may be said to be continuous, and this fact is itself an important element

of normal vesicular respiration. It should be noted here, however, that the normal respiratory sounds do not exactly correspond in the two infra-clavicular regions. On the right side, the pitch of the inspiratory sound is higher than on the left, and less breezy in quality, while the expiratory is more pronounced and prolonged in duration. This disparity should be taken into account in all doubtful cases, such as in suspected small pulmonary consolidations. Age affects the character of normal vesicular respiration, taking for the standard of comparison the respiratory sounds in healthy middle-aged individuals. In infancy the intensity of both the inspiratory and expiratory sounds is increased, while the other elements remain the same. In old age, on the other hand, the intensity is diminished, the duration of the inspiratory sound shortened, and the expiratory prolonged. Sex also modifies the respiratory sounds. As a rule, the inspiratory and expiratory sounds have greater intensity in the female than in the male. The greatest intensity is in the upper anterior portions of the chest in the female, while in the male it is most marked in the lower and posterior portions.

If the ear or stethoscope be applied to the larynx or trachea, two sounds will be heard, one with inspiration, the other with expiration. These sounds constitute the *normal laryngeal* and *tracheal* respiration. It differs from the normal vesicular respiration in that its intensity is increased, its pitch raised, and its quality wholly tubular. The inspiratory sound does not continue quite to the end of the inspiratory act, so that an interval occurs between it and the expiratory sound.

The characters of the next variety, or *bronchial* respiration, are very important to the auscultator from their common occurrence and significance in disease. They

are those of tracheal respiration, only in a less marked degree, being less tubular in quality, while the interval between the inspiratory and expiratory sounds is shorter.

Now, the more thoroughly you learn these varieties of healthy respiration, the better you will be prepared to understand what respiratory sounds are abnormal. Very often you will hear in disease what you recognize as one of the normal sounds, but you know that this familiar sound has in this case a serious import, because it is not the natural sound of that locality. But you may also hear sounds whose character differs from any normal type. We may say, in general, that abnormal sounds consist in changes from the standard of healthy respiration as regards the three elements of *intensity*, *rhythm*, and *quality*, thus :

In <i>Intensity</i> the respiratory murmur may be ..	{	1. Exaggerated or increased.
		2. Diminished or feeble.
		3. Absent or suppressed.
In <i>Rhythm</i> the respiratory murmur may be ..	{	1. Interrupted.
		2. The interval between inspiration and expiration be prolonged.
		3. Expiration be prolonged.
In <i>Quality</i> the respiratory murmur may be...	{	1. Rude, termed rude respiration.
		2. Bronchial, " bronchial "
		3. Cavernous, " cavernous "
		4. Amphoric, " amphoric "

#### *Alterations in Intensity.*

EXAGGERATED RESPIRATION differs from the normal vesicular respiration only in an increase in the intensity and duration of the respiratory sounds. It is sometimes called puerile respiration, from its resemblance to the respiration of children. It occurs in a part where respiration is more active than usual, owing to deficient action elsewhere, as in the upper part of one lung whose

lower lobe is consolidated by pneumonia, or similarly where one lung does the duty of its fellow which is solidified by the pressure of a pleuritic effusion.

**DIMINISHED or FEEBLE RESPIRATION** differs from normal vesicular respiration only in a diminution in the intensity and duration of the respiratory sounds. It may arise from any cause which interferes directly or indirectly with the expansion of the lung, or which diminishes the elasticity of the alveolar walls. Of the first condition, we have illustrations in affections which restrain the movements of the thoracic walls, as pleuritic pain, rheumatism, paralysis, etc.; or when there is some obstruction to the entrance of air into the lungs, such as in diseases of the larynx, trachea, or bronchial tubes; or, again, when a pleuritic effusion or a tumor presses the lungs back from the chest walls, though not to a degree sufficient to prevent all air from entering them. Of the second condition, we have examples in pulmonary emphysema and in incipient tubercular deposits.

**ABSENT or SUPPRESSED RESPIRATION** occurs whenever, from some cause, the play of the lung is suspended. This may be either from external pressure, as when the lung is forced against the spinal column by the presence of fluid or air in the pleural cavity; or when a complete obstruction of any bronchus prevents the air from either entering or leaving the lungs.

#### *Alterations in Rhythm.*

**INTERRUPTED RESPIRATION.**—In health the respiratory sounds are even and continuous, with a brief interval between each act. This may be altered in disease, and both sounds, especially the inspiratory, may have an interrupted or jerking character, termed by some “cog-wheel respiration.” We have examples of this kind of

respiration in asthma, pleurodynia, first stage of pleurisy, and incipient phthisis. It is most frequently associated with phthisis, and may be due probably to some gelatinous mucus adhering to the walls of the finer bronchial tubes, which, though not sufficient to produce rales, still obstructs the free ingress and egress of the air.

PROLONGED INTERVAL BETWEEN INSPIRATION AND EXPIRATION.—Instead of the two sounds closely succeeding one another, they may be separated by a distinct interval. When this occurs, either the inspiratory sound is shortened, or the expiratory delayed in its commencement. In the first instance, it is the result of pulmonary consolidation, as in tubercle; in the second, the elasticity of the pulmonary tissue is impaired, as in emphysema, no sound being heard during the first portion of the expiratory act.

PROLONGED EXPIRATION.—Here the ratio between normal inspiration and expiration is inverted. The expiration, at times, is twice or three times as long as the inspiration.

It is always due to a want of freedom in the egress of air from the lungs. The most common, and therefore, practically speaking, the most important, cause of prolonged expiration is tubercular deposit in the lung. Excessively prolonged expiration is to be met with in vesicular emphysema, and this is to be distinguished from the prolonged expiration of phthisis by its *pitch*, which in emphysema is *low*, lower than the inspiration, while in phthisis it is *high*, higher than the inspiration, and tubular in quality.

#### *Alterations in Quality.*

RUDE RESPIRATION.—This is termed by Prof. A. Flint *broncho-vesicular respiration*. In this variety both in-

spiratory and expiratory sounds lose their natural softness ; the breezy or vesicular quality is lost ; the sounds are higher pitched and more tubular in character, while the expiration has more intensity, higher pitch, and longer duration than the inspiration. Rude respiration always indicates more or less consolidation of lung tissue. In normal vesicular respiration, the sounds produced by the vibrations of the air in the air cells and finer bronchi obscure that produced in the trachea and larger bronchial tubes (healthy lung substance being a poor conductor of sound) ; but so soon as any portion of lung becomes consolidated, the vesicular element of the respiratory sound is diminished and the bronchial element becomes prominent ; this change constitutes rude respiration. It embraces every degree of modification between complete bronchial respiration on the one hand and normal vesicular breathing on the other, the increase in bronchial characters corresponding with the degree of consolidation. Rude respiration is of practical value principally in the diagnosis of incipient phthisis.

**BRONCHIAL RESPIRATION** is characterized by an entire absence of all vesicular quality. The inspiratory sound is high-pitched and tubular in character ; the two sounds are separated by a brief interval ; the expiratory is still higher pitched and more intense than the inspiratory, is as long or longer, and of the same tubular quality. Whenever this modification of the respiratory sound is present, where in health normal vesicular murmur should be heard, consolidation of lung substance may be inferred. Consequently it is an important diagnostic sign in many pulmonary affections, such as pneumonia, pulmonary tuberculosis, pulmonary apoplexy, etc.

**CAVERNOUS RESPIRATION.**—In some respects this resembles bronchial respiration, and it is often difficult to

distinguish one from the other. Some distinguished auscultators declare that this sign does not exist.

Its distinguishing characteristics are, on inspiration, a soft, blowing, low-pitched sound, non-vesicular in character : as a rule, the expiratory sound is lower pitched than the inspiratory, and is always prolonged and puffing.

For its production, there must be a cavity of considerable size in the lung substance, having free communication with a bronchial tube. The cavity must be empty and near the surface, its walls must be sufficiently flaccid to expand with inspiration, and collapse with expiration. This sign is most frequently met with in the advanced stage of pulmonary tuberculosis.

AMPHORIC RESPIRATION.—Whenever the respiratory sound has a musical intonation or metallic quality, resembling that produced by blowing gently into the mouth of an empty bottle, it is called amphoric.

The amphoric character accompanies both acts of respiration, especially the expiratory.

It may be due to phthisical or other excavations in the lung substance, or to an opening from the bronchial tube into the pleural cavity, giving rise to pneumothorax. In both cases the sound is produced by vibrations of air in a cavity, which are excited by a current of air from a bronchial tube. The cavity in the lung substance which gives rise to amphoric respiration must be of large size, empty, with tense, firm walls so as not to collapse with expiration, and it must communicate freely with a large bronchial tube.

This sign is mainly of importance in the diagnosis of advanced tuberculosis and pneumothorax.

This completes the history of the most important alterations in the natural respiratory sounds produced



by disease. With few exceptions they are not new sounds, but are heard in the healthy chest, and become significant of disease only when heard in unnatural locations.

A new method of auscultation has recently been proposed by Dr. B. W. Richardson (vide *Lancet*, November 5th, 1892). It is termed "Intra-thoracic Auscultation: A New Departure in Physical Diagnosis." He employs "a good-sized [œsophageal] tube with a large lateral aperture at the extreme end. Apertures are essential in these tubes; if they are not made, there is little or no conduction of sound." The free end of the tube is connected to an ordinary binaural stethoscope. Dr. Richardson claims that by this means an early diagnosis of stricture of the œsophagus can be made from the friction sound produced as the tube passes over the induration, and that it may be of service in the diagnosis of diseases of the stomach itself; that, through the stomach, pulsating abdominal tumors could be diagnosed: "with the terminal of a full-sized œsophageal stethoscope in the stomach cavity, a loud murmur from an arterial source will be detected without the interposition of pressure, and an important difficulty in diagnosis removed"; and that this method will prove of service in the diagnosis of diseases of the heart and aneurisms of the large thoracic arterial trunks. In concluding he says: "I assume at once that this mode of research is not called for when by the ordinary auscultation diagnosis is clear."

I have not tried this method of examination, and therefore cannot recommend it from personal experience.

## LESSON V.

### ABNORMAL OR ADVENTITIOUS SOUNDS.

THE sounds which are now to be considered are termed Adventitious, because they are not heard in health, but are found in disease, either accompanying the normal respiratory sounds, or wholly supplanting them. They vary much in their character, according to their origin, that is, whether they are caused by changes in the lung itself or in its investments ; and, hence, in order to appreciate their significance you should know well their seat and mode of production.

The sounds which originate in the air passages, or in cavities abnormally communicating with them, are called *rales*, or *rhonchi* ; those which originate in the investments of the lung are called *pleuritic friction sounds*. In speaking of the former I shall use the term *rale*, and would classify the varieties which we meet in practice as follows ;

Rales.	{	Dry rales.	{	Sonorous rales.
			{	Sibilant rales.
		Moist rales.	{	Mucous rales (large and small).
				Sub-crepitant rales.
				Crepitant rales.
				Gurgles (large and small).
				Mucous click.

A rale may originate in the trachea, in the bronchi, large or small, in the air cells, or in abnormal cavities situated either within or without the lung substance.

It may be produced within the air tubes, either by a diminution of their calibre, by the vibrations of viscid matter collected in them, or by the air bubbling through fluid present in the bronchi and in the air vesicles, or in larger or smaller cavities. A rale may be either dry or moist in its character, and may be audible either in inspiration or in expiration, or in both.

DRY RALES are divided into sibilant, and sonorous according to the pitch and quality of the sound ; if a rale

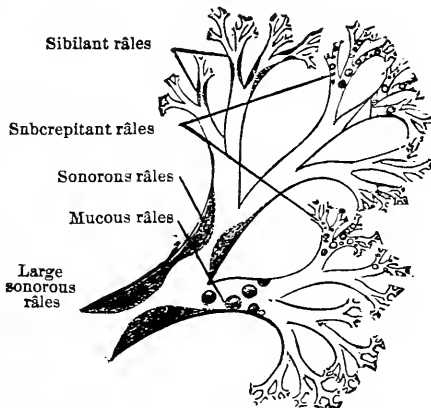


FIG. 3.—Diagram illustrating the Physical Signs of Bronchitis.

is high-pitched and whistling, it is termed sibilant ; if low-pitched and snoring in character, it is termed sonorous.

The *Sibilant* rale may be heard during both inspiration and expiration. It recurs irregularly, and sometimes is so high-pitched as to become hissing in its character. Its seat is the smaller bronchi, and it is caused either by the narrowing of these tubes from thickening of the mucous tissues lining them, or from the spasmodic contraction of their muscular coat ; or it may be

owing to the vibrations of viscid mucus adhering to their walls. In most instances it may be temporarily removed by violent coughing.

The *Sonorous* rale may also be heard during both inspiration and expiration. As above mentioned, it is a low-pitched, snoring sound, which varies, however, in intensity from a slight rale to one loud enough to be audible at a distance from the chest. It has for its seat the larger bronchial tubes, and is produced by conditions of those tubes similar to those which cause sibilant rales in the smaller bronchi, namely, lessened calibre from tumefaction of the mucous tissues, or from spasmodic contraction, or from pressure on the tube from without, by a tumor, an exudation, or a deposit; or it may be owing to the vibrations of a thickened fold of the lining membrane, or of viscid mucus adhering to the wall. This rale is specially frequent in bronchitis and spasmodic asthma, though it may be present in almost every pulmonary disease.

**MOIST RALES.**—Under this head may be included the *crepitant*, *sub-crepitant*, and *mucous rales*.

*Crepitant* rales consist of a series of minute, crackling sounds. They persist at the spot where first heard, and do not shift their position as the other moist rales. They are audible only toward the end of inspiration. There are several views as to the production of these sounds: that they are due to the bubbling of air through a liquid in the pulmonary vesicles or terminal bronchioles; that, at the end of expiration, a viscid secretion glues the walls of the vesicles together, and their separation on inspiration gives rise to the crackling sound; and that they are produced in the pleura independently of the pulmonary parenchyma. This rale is the characteristic sign of pneumonia in the first stage, though it is

not infrequent in some forms of pulmonary congestion, and in œdema of the lungs.

The *Sub-crepitant* rale is a moist bronchial sound, caused by the breaking of minute air bubbles of equal size and comparatively few in number. Its seat is the smallest bronchi, and the liquid through which the air passes may be mucus, serum, pus, or blood. It differs from the crepitant rale in the larger size of the bubbles, and is heard in expiration as well as in inspiration. This rale is present in a number of affections. When heard on both sides of the chest posteriorly, it indicates capillary bronchitis. It is characteristic of the resolving stage of pneumonia, and is termed the "rale redux." When present only in the apex of a lung, it indicates commencing tuberculosis. It accompanies the effusion of blood into the bronchial tubes, and is sometimes present in œdema of the lungs.

The *Mucous* rale is a moist bronchial sound, produced in the same manner as the sub-crepitant. Its seat is in the larger tubes, and, according to the size of the tube in which the sound originates, it is termed the *fine* or *coarse* mucous rale. Like the sub-crepitant rale, you may hear it during both inspiration and expiration, and it is modified, or entirely removed, by the act of coughing. Mucous rales occur in bronchitis during the stage of secretion; in bronchial hæmorrhage; whenever pus makes its way into the air passages from an abscess—in short, whenever the bronchial tubes become partially filled with liquid of any kind. If these rales, whether fine or coarse, are restricted to a circumscribed space at the apex of a lung, they indicate that the bronchitis is of tubercular origin.

*Gurgles* are produced in large or small cavities partly filled with liquid, below the level of which a bronchus

freely opens. The sound is due to the bubbling of air up through the liquid. It is a moist sound, but has a peculiar hollow, metallic quality. Gurgles may be heard both in inspiration and expiration, and according to the size of the cavity will they be "large" or "small." Small gurgles resemble large mucous rales, but may be distinguished from them by their above-mentioned hollow, metallic character.

The most frequent cause of pulmonary cavities is the

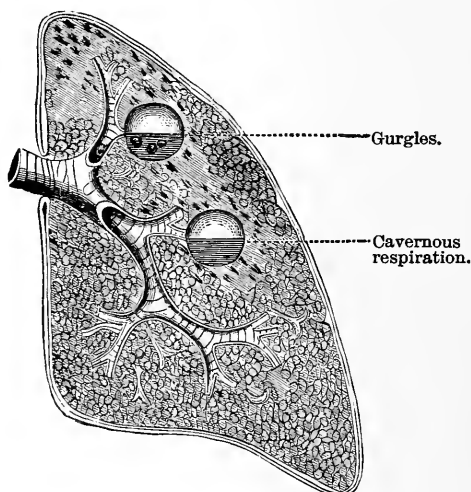


FIG. 4.—Cavernous Respiration and Gurgles

softening and expectoration of a cheesy pneumonia, but they may be owing to abscess, gangrene, perforating empyema, and excessive dilatation of the bronchial tubes. When pulmonary cavities exist without gurgles, it may be due to the filling of the cavity with liquid, or to its containing no liquid, or because the level of the liquid is below the opening of the bronchial tube.

*Mucous Click.*—This is a single, quick, clicking sound, not removed by coughing, and which resembles an isolated sub-crepitant rale. Authors differ as to the theory

of its production. It appears to me to be due to the sudden and forcible passage of air through a small bronchus, the sides of which have been brought together at one or more points, either by external pressure or by agglutination from within; as when a consolidated lobule presses unequally upon a bronchus, and excites a local inflammation of the mucous membrane with its consequent viscid secretion. It is therefore important as a symptom of incipient tuberculosis.

Pleuritic friction sound.

Flatness on percussion. Absence of vocal and respiratory sounds.

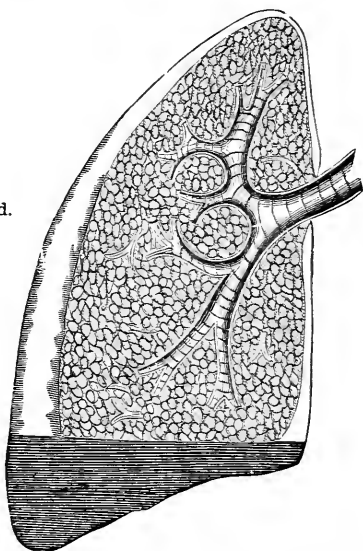


FIG. 5.—Roughening of the Pleuræ, and Slight Pleuritic Effusion.

PLEURITIC FRICTION SOUNDS.—In health the smooth pleural surfaces, moistened by their natural secretion, play noiselessly upon each other during the respiratory movements. When an inflammation roughens one or both of these surfaces, or dries up their natural secretion, it gives rise to a friction which produces the characteristic sounds to which the above name is given. These sounds consist of one or of a series of abrupt, jerking, rubbing noises, manifestly superficial,

and which are commonly heard over a limited extent of surface. They vary much in intensity, from a sound scarcely audible to one of extreme loudness ; and they usually accompany both inspiration and expiration, being seldom heard with expiration alone.

There are several varieties of pleuritic friction sounds, termed, respectively, grazing, rubbing, grating, creaking, and crackling ; all of which belong to the clinical history of pleurisy.

The grazing variety occurs at the onset of pleurisy, when dryness of the membrane is the only change yet produced. As soon as there is dulness on percussion, it is replaced by the rubbing variety, and therefore is of such short duration that it is not often heard, but may be more frequently noticed in the circumscribed pleurisy which often accompanies pulmonary tuberculosis. The other varieties are the forms in which the pleuritic friction sound most commonly presents itself ; and they occur both in the stage of plastic exudation and in the stage of absorption.

Sometimes the respiratory sound is attended by sounds resembling rales, which are doubtful both as to their situation and significance.

They are of two kinds : First, creaking sounds not infrequently heard at the apices of the lungs, produced either by the creaking of pleuritic adhesions or by crepitations in lung tissue. Second, dry crumpling sounds, resembling those produced by inflating a dried bladder, probably (as Laennec supposed) produced by the forcible distention of large air sacs in emphysematous lungs.



## LESSON VI.

### AUSCULTATION OF THE VOICE.

THIS is another method of obtaining information as to the condition of the lungs and their investing membranes. It is based on the fact that the vibrations of the voice are not transmitted upward only, but also downward, through the trachea and bronchi, to all parts of the lung. The resonance thus produced varies in character according to the situation in which it is heard. The different varieties are named after the parts where they occur in health.

If the stethoscope be placed over the larynx or trachea of a healthy person while speaking, the voice will be transmitted to the ear, imperfectly articulated, and with a force, intensity, and concentration almost painful. This is called *natural laryngophony* or *tracheophony*.

At the upper part of the sternum, and between the spines of the scapula, it is heard less intense, more diffused, and less distinctly articulated; and this is termed *bronchophony*. But when you listen over the lung substance itself, the voice sounds become distant, diffused, and without any approach to articulation. This is termed *normal vocal resonance*. Its intensity is usually greater on the right than on the left side, especially in the infra-clavicular region, but it varies considerably in this respect in different healthy persons. In females there is, not infrequently, no difference in the two sides.

The intensity over the whole chest is greater in those who have low-pitched voices, and in thin than in fleshy persons. You cannot rely on the vocal resonance of any one region of the chest as trustworthy evidence, by itself, either of health or of disease. Its indications are furnished only by comparisons of corresponding parts of the two sides, after allowance is made for natural differences.

In making your examination for this purpose the readiest way is to direct the patient to count one, two, three, or repeat the numeral 99. The modifications of the vocal resonance which you will find indicative of disease will consist of changes in intensity. 1. Its intensity may be diminished; or, 2, it may be increased; and I would classify them as follows:

- |                          |   |   |
|--------------------------|---|---|
| 1. Diminished intensity. | } | <ul style="list-style-type: none"> <li><i>a.</i> Vocal sounds may be weak or feeble.</li> <li><i>b.</i> " " " " suppressed or absent.</li> </ul>  |
| 2. Increased intensity.  | } | <ul style="list-style-type: none"> <li><i>a.</i> Vocal sounds may be simply exaggerated.</li> <li><i>b.</i> The resonance may be of the character termed Bronchophony.</li> <li><i>c.</i> The resonance may be of the character termed Pectoriloquy.</li> <li><i>d.</i> The resonance may be of the character termed Egophony.</li> <li><i>e.</i> The resonance may be of the character termed Amphoric Voice.</li> </ul> |

The varieties included under the head of diminished resonance require but little explanation. The vocal resonance may be faint or altogether wanting. The first often occurs in bronchitis with free secretion; in plastic pleuritic effusions, and, occasionally, when there is extreme pulmonary consolidation. There is absence of vocal resonance in pneumothorax and in copious serous pleuritic effusion. The modifications, however, which accompany increased intensity are more varied and complex.

EXAGGERATED VOCAL RESONANCE differs from normal vocal resonance only in a slight increase of intensity. It denotes a moderate amount of solidification of lung tissue, and is chiefly of importance in the diagnosis of tuberculosis.

The characters of BRONCHOPHONY, as contrasted with normal vocal resonance, are its greater intensity, higher pitch, peculiar vibrating quality, and approach to articulation of the voice sounds. When heard in abnormal situations it has the same significance as bronchial respiration, though more complete consolidation is necessary for the production of bronchial respiration than bronchophony. The best example of bronchophony is met with in the second stage of lobar pneumonia.

PECTORILOQUY (so named by Laennec, its discoverer) is a complete transmission of the voice to the ear. The words spoken are heard distinctly articulated. It closely resembles the resonance heard over the larynx, and is usually limited to a small space in the chest, where it also may, or may not, have a hollow, ringing character. It was formerly believed always to indicate the presence of a pulmonary cavity, but auscultators are now agreed that this is not necessarily the case in every instance, but that it is sometimes simply an exaggerated bronchophony; the only distinction between these two being that bronchophony is the transmission of the voice, pectoriloquy that of the speech. Well-defined pectoriloquy is not a common phenomenon.

EGOPHONY is the name given by Laennec to another form of vocal resonance, which is distinguished by its tremulous, nasal character, suggestive of the bleating of a goat. It also is a modification of bronchophony. Laennec considered it a sign of a limited amount of serous effusion in the pleura, over solidified lung. It

is rarely heard, and is of not much significance when heard.

AMPHORIC VOICE is a term applied to the vocal resonance whenever, in addition to its being of a hollow, metallic character, it has a distinct musical intonation. This musical sound follows the voice, is of high pitch, and is not articulated like pectoriloquy. It is sometimes produced in large cavities within the lung, but is more particularly a sign of hydro-pneumothorax.

In addition to vocal resonance, we have a true whisper resonance, the modifications of which by disease may afford us some valuable hints (as was first pointed out by Prof. A. Flint). If, while practising auscultation on a person in health (as I should strongly advise you to do with one another while studying this subject), you direct him to count in a loud whisper, you will usually hear a soft, blowing sound, accompanying each whispered word, which varies in intensity in different persons.

As a rule, it is heard only at the upper portion of the thorax, and is loudest over the primary bronchi. Dr. Flint calls this sound the normal bronchial whisper, and he classes its abnormal modifications into *exaggerated bronchial whisper*, *whispering bronchophony*, *whispering pectoriloquy*, *cavernous whisper*, and *amphoric whisper*.

The exaggerated differs from the normal whisper in having greater intensity and higher pitch. It indicates slight solidification of lung tissue. In whispering bronchophony, the blowing sound is intense, the pitch high, and the sound seems near to the ear. When heard in situations where it is not normally present, it indicates, like vocal bronchophony, more or less complete consolidation of the lung substance. The cavernous whisper is a hollow, low-pitched, blowing sound. It is a trustworthy indication of a cavity, and requires for its production

conditions similar to those which give rise to cavernous respiration. In whispering pectoriloquy, the whispered words are distinctly audible at the surface of the chest, and this constitutes a more sure indication of a cavity than vocal pectoriloquy. The character and the significance of the amphoric whisper are the same as those of the amphoric voice.

Another of the adventitious sounds is that which is termed *metallic tinkling*, its name being sufficiently descriptive of its character. It sounds like the dropping of a pin or a small shot into a metallic vessel. A single one, or a series of tinkling sounds, may be produced by the act of speaking, or by the movements of inspiration and expiration; but it is especially consequent on the act of coughing.

This sound announces the existence either of a very large pulmonary cavity or of hydro-pneumothorax. Dr. Walsh regards it as the echo of a bubble bursting in a liquid, shut up in a spacious cavity which also contains air.

RESONANCE OF COUGH.—In a healthy individual, the act of coughing is accompanied by a quick, sharp, indistinct sound, which jars through the whole chest. Over the larynx and trachea the cough is hollow, and varies in pitch and intensity with the voice of the individual. The modifications of the cough sound in disease are termed bronchial, cavernous, and amphoric. Bronchial cough has a quick, harsh character, attended by a marked thrill or fremitus of the chest. Cavernous cough is hollow and metallic (commonly it is termed sepulchral). It may be accompanied by gurgles, and its resonance is sometimes transmitted to the ear of the auscultator with painful intensity. Amphoric cough is a loud resounding sound, of metallic character, but not

forcibly transmitted to the ear. It conveys the impression of a large empty space. These varieties of cough are heard under the same conditions as the corresponding varieties of respiration. They are not of much utility in diagnosis.

## LESSON VII.

### A SYNOPSIS OF PHYSICAL SIGNS IN THE DIAGNOSIS OF PULMONARY DISEASES.

#### *Bronchitis.*

#### *Acute and Chronic Bronchitis affecting the Larger Tubes.*

*Inspection.*—The form and movements of the chest are not visibly altered.

*Palpation.*—Vocal fremitus is normal; occasionally a distinct bronchial fremitus is communicated to the surface of the chest.

*Percussion.*—Pulmonary resonance is normal, unless there is a very considerable accumulation of mucus in the bronchial tubes, in which case the normal resonance is diminished in the lower and posterior regions.

*Auscultation.*—The respiratory murmur is feeble or temporarily suppressed in the lung tissue corresponding to the affected tubes. In the dry stage, sibilant and sonorous rales may be heard on both sides of the chest (as shown in Fig. 3). In the stage of secretion, along with the sibilant and sonorous rales, mucous rales, large and small, are heard on both sides of the chest (see Fig. 3). These rales are inconstant, coming and going, and changing their situation. When the rales are intense and abundant, they altogether mask the respiratory murmur. In some cases of slight bronchitis of the larger tubes, there are no distinct rales, but the respiration has a sonorous character.

The *Vocal Resonance* is normal.

*Capillary Bronchitis.*

CAPILLARY BRONCHITIS, or bronchitis affecting the ultimate, or capillary, bronchial tubes.

*Inspection* and *Palpation* give the same signs as in simple bronchitis.

*Percussion* is normal, or it may be slightly exaggerated.

*Auscultation* shows, if the disease is extensive, that the vesicular murmur is weakened or suppressed. In its stead, sub-crepitant rales are heard on both sides of the chest, accompanied by sibilant rales of a markedly hissing character.

The *Vocal Resonance* is normal.

*Differential Diagnosis of Bronchitis.*—The diagnosis of bronchitis of the larger tubes is readily made. Sometimes, however, the gravitation of fluid from the larger to the smaller tubes may give rise to sub-crepitant rales over a circumscribed area posteriorly.

Capillary bronchitis may be confounded with pneumonia, and with acute or chronic tuberculosis. It is distinguished from pneumonia by its normal or exaggerated resonance on percussion, by the existence of sub-crepitant rales on both sides of the chest, and by the absence of bronchial breathing. The diagnosis of capillary bronchitis from tuberculosis will be considered under the head of the latter.

If the sub-crepitant rales are confined to the apex or base of one lung, and there is resonance on percussion, the bronchitis is either of a tubercular or emphysematous origin.

*Dilatation of Bronchi. (Bronchiectasis.)*

BRONCHIECTASIS is usually associated with fibrous induration of the lung or with emphysematous enlarge-



ment, and is recognized by the following physical signs :

*Inspection* shows defective expansive movements of the chest, and prolonged, labored expiratory movements.

*Palpation*.—Vocal fremitus varies, rhonchial fremitus frequently present.

*Percussion* is amphoric, unless the accumulation of thick secretion gives rise to obstruction of the tubes, and consequent local solidification of the lung ; in such cases there is temporary dulness. This dulness is to be distinguished from the dulness of pneumonia by its temporary character, and by the variations in vocal fremitus. From pneumonic consolidation it is distinguished by the presence of cavernous and amphoric breathing.

*Auscultation*.—The results of auscultation vary according to the condition of the cavity. When it is full, the respiratory sounds are more or less deficient over portions of the chest ; when it is empty, they become harsh and loud. They are accompanied by a variety of rales, chiefly sonorous. But after profuse expectoration, large mucous rales or gurgles may be present. The sounds in any portion of the lung are constantly changing in character, altered by cough or a full inspiration.

### *Pulmonary Emphysema.*

*Inspection* in a well-marked example of this disease reveals alterations in the shape and movements of the chest. The sternum is often abnormally prominent, as if from congenital deformity. There is bulging of the infra-clavicular and mammary regions, which gives to the upper portion of the chest a more rounded appearance than in health, or, as it is called, "barrel-shaped." The shoulders are elevated and brought forward ; there is

more or less anterior curvature of the spine, and the person appears to stoop. The lower portion of the chest seems contracted, and the intercostal spaces are widened in the upper, narrowed in the lower spaces. In some instances in which the general symptoms of emphysema are well marked, the lung is atrophied instead of being abnormally dilated, and no bulging or prominence of the chest occurs, either general or local.

The movements of the chest walls are also altered. At the upper portion, expansion on inspiration is diminished or entirely wanting. The whole chest moves vertically up and down with inspiration and expiration, as if it were passively lifted from the shoulders and composed of one solid piece; while below, the chest, instead of being dilated with inspiration, is contracted. The respiratory efforts are labored, and the breathing is chiefly abdominal.

*Palpation.*—The vocal fremitus varies; it may fall below, it may equal, or exceed, the average of health. The apex beat of the heart is often not perceptible in the precordial space; sometimes it is felt much lower than its normal position.

*Mensuration* shows a marked increase in the antero-posterior diameter of the chest.

*Percussion.*—The intensity of the percussion sound is increased, the pitch is lowered, the pulmonary quality of the sound is greatly diminished, and it becomes what has already been described as vesiculo-tympanitic. The percussion note is not materially affected either by forced inspiration or forced expiration.

*Auscultation.*—As a rule, the inspiratory sound is either short and feeble, or actually suppressed, and the expiratory sound is greatly prolonged: the ratio of the two sounds being as 1:4 instead of 4:1. The pitch of

both inspiratory and expiratory sounds is lower than in health.

In some extreme cases of emphysema, the respiratory sounds are of equal length, greatly exaggerated in intensity, and of a harsh, sibilant quality, the harsh quality, undoubtedly, being due to diminution in the calibre of the minute bronchial tubes.

*Vocal Resonance* varies greatly; sometimes it is diminished or altogether absent; at others its intensity is greatly increased. The heart sounds are feeble, and in rare instances the organ is pushed downward toward the epigastrium.

*Differential Diagnosis.*—The only disease with which emphysema is liable to be confounded is pneumothorax. The distinction, however, is not very difficult, for in emphysema the percussion sound, although tympanic, still retains a pulmonary quality, and there is a vesicular element to the respiratory sound; while in pneumothorax the percussion sound has a complete tympanic character, and the respiration, if audible, is amphoric. Besides, pneumothorax affects only one side, emphysema both.

*Spasmodic Asthma (during the Paroxysm).*

*Inspection* shows labored respiration.

*Palpation*, vocal fremitus normal.

*Percussion* is normal or exaggerated.

*Auscultation.*—The rhythm of the respiratory murmur is jerking and irregular; sometimes it is exaggerated, at others it is suppressed. Sibilant and sonorous rales, of a high-pitched, hissing and wheezing character, are diffused over the whole chest, often loud enough to be heard at a distance.

*Vocal Resonance* is normal.

*Acute Lobar Pneumonia.*

The physical signs of pneumonia vary with its different stages.

FIRST STAGE, OR STAGE OF ENGORGEMENT. *Inspection.*—The movements of the affected side are more or less restrained.

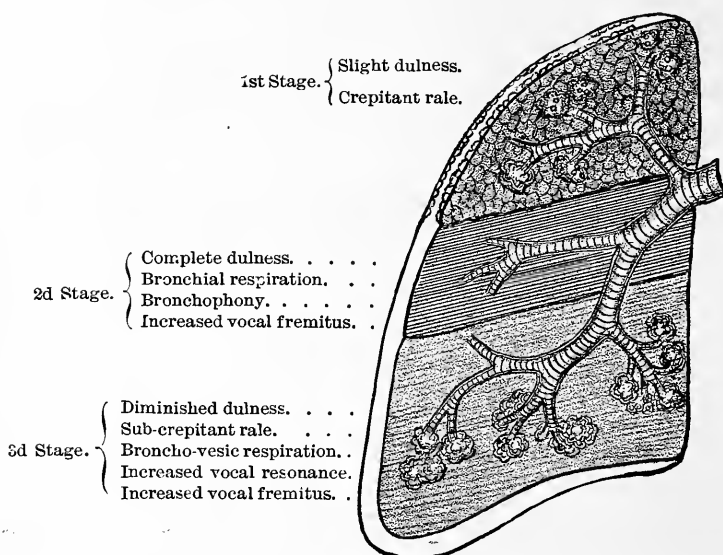


FIG. 6.—Diagram illustrative of the Physical Signs of the three stages of Pneumonia.

*Palpation.*—Vocal fremitus is slightly increased on the affected side.

*Percussion.*—There is slight dulness over so much of lung tissue as is involved in the pneumonic inflammation, the degree of dulness depending upon the amount of exudation into the lung substance.

*Auscultation.*—In the early period of engorgement, before the exudation takes place, the respiratory murmur is diminished in intensity in the affected part, and exaggerated in other portions of the affected lung, as

well as in the healthy lung. As soon as exudation takes place into the air cells, or on the pleural surface, the crepitant rale may be heard toward the end of inspiration. It is the characteristic sign of the first stage of pneumonia. In some cases, especially when pneumo-nia is developed in connection with acute articular rheu-matism, crepitation never occurs.

SECOND STAGE, OR RED HEPATIZATION. *Inspection.*—The expansive movements are diminished on the af-fected side, and increased on the healthy.

*Palpation.*—As a rule, vocal fremitus is increased; occasionally it is diminished.

*Percussion.*—There is marked dulness over a space corresponding to the consolidated lung tissue, and in-creased resonance over the healthy portion of the af-fected lung.\* The relation of the resonance and dulness is not affected by a change in the position of the patient. Absolute dulness or flatness on firm percussion very rarely exists.

*Auscultation.*—As the air cells become completely filled with exudation the crepitant rales cease, and *bron-chial respiration* is heard over the solidified lung tissue. The more complete the consolidation the more intense and tubular is the bronchial respiration.

*Vocal Resonance.*—There is marked bronchophony over all that portion of lung which is the seat of pneu-monic consolidation. The heart sounds are transmitted to the surface with unnatural intensity. The character-istic physical signs of this stage are *dulness on percus-sion*, *bronchial breathing*, and *bronchophony*.

THIRD STAGE, OR GRAY HEPATIZATION.—The physical signs in the early part of this stage are the same as those of the second stage. They are simply the signs of con-solidation. In the latter or resolving part of this stage,

*percussion* shows progressive diminution in dullness. It is often, however, a long time before normal pulmonary resonance is perfectly restored.

*Auscultation.*—The bronchial respiration of the second stage gradually gives place to rude (or bronchovesicular) respiration, and this in turn approximates to, and at length ends in, normal vesicular breathing. As the bronchial respiration diminishes, the crepitant and sub-crepitant rales, or “rale redux,” are developed, and remain audible until resolution is complete. Bronchophony gives place to exaggerated vocal resonance, and that in turn to *normal* vocal resonance. The physical signs of chronic pneumonia will be considered in connection with tuberculosis.

#### *Lobular Pneumonia.*

The areas of consolidation vary from the size of a pea to that of a hazelnut. They are usually scattered throughout both lungs, but in some instances isolated nodules may become confluent and the greater part of a lobe be consolidated.

Lobular pneumonia is associated, as a rule, with a catarrh of the smaller tubes, and occurs most frequently in children and old people.

*Inspection.*—In the severe lobular pneumonia of children, the respirations are hurried, shallow, and imperfect. There is only slight expansion of the chest, or in some cases there may even be retraction of its lower portion during a full inspiration. In adults inspection reveals only an increased frequency of the respiratory acts.

*Palpation* gives negative results unless the consolidated areas are of considerable size and situated near the surface of the lung.

• *Percussion*.—Dulness is present over circumscribed areas. It may be slight or complete, depending upon the extent and location of the consolidation.

Dulness in children can be elicited only by gentle percussion.

On *Auscultation* small mucous rales, resembling the sub-crepitant, having a fine crackling and metallic character, are heard over the areas of dulness. They are audible both with inspiration and expiration. The breathing is at first feeble, but gradually it becomes broncho-vesicular, or even bronchial. The vocal resonance is increased : it may be bronchophonic.

*Differential Diagnosis*.—Lobular pneumonia is most likely to be mistaken for capillary bronchitis. The dulness on percussion, the localization of the rales to circumscribed areas, and the broncho-vesicular or bronchial breathing, will readily distinguish it.

### *Pulmonary Œdema.*

In œdema of the lungs *inspection* and *palpation* furnish no positive information.

*Percussion*.—There is more or less dulness on percussion (never, however, complete), diffused over the posterior surface of the chest on both sides, and marked at the most dependent portion of the lungs.

*Auscultation*.—The respiratory murmur is feeble, sometimes almost entirely absent. With the inspiratory sound, crackling rales are heard over the seat of the œdema; the crackling resembles somewhat the crepitant rale of pneumonia, but is distinguished from it by its liquid character.

*Differential Diagnosis*.—Pulmonary œdema may be confounded with the first stage of pneumonia, with hydrothorax, and with capillary bronchitis. It is distin-

guished from pneumonia, as we mentioned above, by the liquid character of the crackling rales, and by its occurring on both sides, at the most dependent portions of the lungs, pneumonia usually being confined to one lung; from hydrothorax, by the presence of rales, and by the level of the dulness not being changed by a change in the position of the patient; from capillary bronchitis, by the slight dulness on percussion which attends it, and by the absence of the rales in the larger bronchial tubes.

#### *Pulmonary Gangrene.*

The physical signs of pulmonary gangrene are often obscure and never distinctive. They are those of local consolidation followed by the evidences of the breaking up of lung tissue and the formation of cavities in the lung substance. There are no special signs indicating the nature of the disorganizing process; sometimes it is preceded by the signs of pneumonia; generally it is accompanied by the signs of bronchitis, and late in the disease there are physical evidences of the formation of cavities in the lung substance.

#### *Pulmonary Hæmorrhage.*

The physical signs of a slight hæmorrhage from the lungs are very obscure. No information as to the seat or amount of the hæmorrhage is furnished by inspection, palpation, or percussion. Auscultation may, however, indicate the spot at which the hæmorrhage occurs, by the presence of moist rales. If the hæmorrhage is profuse and accompanied by pulmonary apoplexy, abundant moist rales will be heard at the seat of the effusions, and they remain audible until coagulation takes place or the effusion is removed. When pulmonary apoplexy occurs,



it is usually found in the lower and posterior portions of the lungs. If the nodules are few and small, there will be no positive physical evidences of their situation. When the nodules are large and lie superficially, percussion will give more or less dulness over a limited space corresponding to the extent of the hæmorrhage, and on auscultation there will be a diminution or absence of the respiratory murmur. When the extravasation is situated near a large-sized bronchial tube, bronchial breathing and increased vocal resonance are heard, and there is also increase in the vocal fremitus.

### *Pulmonary Cancer.*

Cancer of the lungs may be primary or secondary. In the primary form, only one lung is affected, and the growth occurs as a single mass. In the secondary, both lungs are involved, and the new growth usually takes the form of disseminated nodules of varying size. The latter variety cannot be distinguished by physical examination from simple bronchial catarrh, but pulmonary symptoms occurring a year or so after the removal of a cancer are very suggestive.

Where the growth is single and large

*Inspection* shows obliteration or bulging of the intercostal spaces. This may, however, be due to a complicating liquid effusion. Occasionally there is retraction of the chest wall. The movements of respiration are impaired.

*Palpation* gives diminished or absent vocal fremitus.

*Percussion* gives comparative or absolute dulness, according as whether the mass is deep-seated or superficial.

*Auscultation.*—The respiratory and voice sounds are usually absent over the affected portion of the lung. But if a large open bronchus passes through the mass,

bronchial breathing and voice will be heard. The signs on the healthy side may be exaggerated.

*Differential Diagnosis.*—The only disease with which pulmonary cancer is likely to be confounded is pleurisy with effusion. In cancer, however, the line of dulness does not change when the position of the patient is altered; the dulness does not begin at the lowest portion of the thorax and extend upward; and there may be one or more points where slight resonance on percussion is obtained. In cancer, the dulness is most marked in front, whereas in pleurisy it is greatest behind. Pain is present if the pleura is involved, and pressure symptoms are sometimes seen.

#### *Pulmonary Collapse.*

Complete collapse of large portions of lung may be produced either by bronchitis or compression. There are no physical signs to indicate its occurrence, unless the collapsed lung is in contact with the chest wall, and then the signs are not very distinctive. Usually there is over the space where it occurs some dulness on percussion, localized bronchial breathing, and increased vocal fremitus. When there is collapse of only a few vesicles, a deep inspiration may bring out a crepitant rale, audible during a few respirations, and then heard no more. Congenital atelectasis gives rise to no physical signs, unless there is marked inspiratory dyspnoea and retraction of chest walls.

#### *Pulmonary Congestion.*

There are no recognizable physical signs of simple pulmonary congestion, unless it is associated with pulmonary œdema or bronchial hæmorrhage.

It may be suspected when extreme dyspnoea comes on suddenly after violent physical exertion, or during the

inhalation of highly rarefied air met with in high altitudes, especially if, with the dyspnœa, you have the physical signs of pulmonary œdema, and a watery blood-stained expectoration.

Some auscultators have regarded intensification of the second sound of the heart over the pulmonary arteries as a diagnostic physical sign of pulmonary congestion ; but this evidence is fallacious, for greater intensity of the second pulmonary sound may be merely relative, and due to weakness of the aortic sound.

## LESSON VIII.

### A SYNOPSIS OF PHYSICAL SIGNS IN THE DIAGNOSIS OF PULMONARY DISEASES—CONTINUED.

#### *Pleurisy.*

THERE are three recognized varieties of pleurisy, *Acute, Sub-Acute, and Chronic or Empyema.* In acute, there is but little liquid effusion; in sub-acute, the liquid effusion is abundant, often completely filling the pleural cavity; in empyema, the effusion is purulent, comparatively small in quantity, and usually circumscribed. I shall consider the physical signs of the three varieties separately.

#### *Acute Pleurisy*

may be divided into four stages—a dry stage, a plastic stage, a stage of liquid effusion, and a stage of absorption.

DRY STAGE.—*Inspection* shows a diminution in the respiratory movements, especially in expansion of the affected side. They are also quick, catching, and irregular. *Palpation, mensuration, and percussion* yield only negative results.

*Auscultation.*—The respiratory murmur is feeble, jerking, and interrupted; occasionally a grazing friction sound is heard over the seat of the pleuritic inflammation.

STAGE OF PLASTIC EXUDATION. *Inspection.*—The respiratory movements of the affected side are still more

diminished, while those of the healthy side are increased.

*Palpation.*—Vocal fremitus is diminished.

*Percussion.*—There is more or less dulness over the seat of the plastic exudation. If the dulness is marked, the plastic matter is abundant. The dulness will be less at the end of a full expiration.

*Auscultation.*—The respiratory murmur over the seat of the pleuritic inflammation is feeble or entirely absent, and a rubbing or crepitating friction sound is heard, most distinctly at the end of the inspiratory act, as shown in Fig. 5, p. 45.

*Vocal Resonance.*—The intensity of the vocal resonance is diminished.

STAGE OF LIQUID EFFUSION. *Inspection.*—In acute pleurisy the quantity of liquid effusion is generally small, as shown in Fig. 5; consequently there is no dilatation of the affected side. When it appears, the jerking movements of the dry and plastic stages cease, and there is no visible motion at the seat of the liquid accumulation.

*Palpation.*—Vocal fremitus is absolutely suppressed over the effused liquid.

*Percussion.*—When the patient is sitting or standing, there is flatness on percussion, from the base of the lung on the affected side to the level of the liquid, as shown in Fig. 5. The line of the flatness may be changed by changing the position of the patient.

*Auscultation.*—The respiratory sounds below the level of the liquid are suppressed; above, they are exaggerated. The friction sounds disappear where the effusion prevents the pleural surfaces from coming in contact with each other; but above the liquid they continue to be heard, as shown in Fig. 5.

*Vocal Resonance.*—Below the level of the liquid the vocal sounds are feeble or entirely abolished.

**STAGE OF ABSORPTION.**—This stage is marked by the gradual return of pulmonary resonance on percussion, and of the normal vocal and respiratory sounds. As the effusion disappears creaking friction sounds are audible for a brief period.

*Sub-Acute Pleurisy.*

In this variety of pleurisy the pleural cavity may be partly or completely filled with liquid. In addition, there

Absence of respiratory sounds

“ “ vocal sounds.

“ “ vocal fremitus.

Flatness on percussion

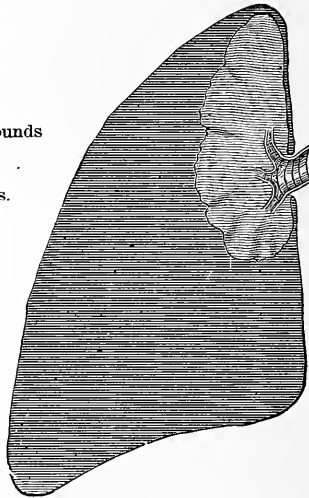


FIG. 7.—Diagram showing the Pleural Cavity completely filled with Liquid, the Lung being compressed.

is a moderate amount of plastic exudation, which thickens and roughens the pleural surfaces. When the cavity is partly filled, the presence and amount of the effusion are determined by the same physical signs that mark the effusive stage of acute pleurisy. When the pleural cavity is distended by accumulation of the liquid, the lung is compressed against the spinal column, and important changes in the physical signs occur.

*Inspection* shows perfect immobility of the chest walls, with general enlargement of the affected side. The intercostal spaces bulge more or less, and the cardiac impulse is visible in an abnormal position.

*Mensuration* shows an enlargement of the affected side, both in its circumference and in its antero-posterior diameter; the enlargement is greatest over the false ribs, the affected side often measuring one or two inches more than the healthy.

*Palpation* shows the vocal fremitus to be wanting.

*Percussion*.—There is general flatness on percussion over the affected side, the flatness extending beyond the natural limits of the lung. Under the clavicle the percussion sound sometimes has a tympanitic quality.

*Auscultation*.—There is entire absence of all respiratory and vocal sounds over the affected side, except at the upper portion of the compressed lung; here bronchial respiration and bronchophony are heard. Sometimes these sounds are diffused over the affected side. The respiratory sound over the healthy lung is exaggerated.

In the STAGE OF ABSORPTION, *inspection* informs us that the enlargement of the affected side is disappearing, that the intercostal spaces are regaining their normal condition, and that the respiratory movements of the chest walls are returning, although restricted.

*Palpation* shows a gradual return of vocal fremitus.

*Mensuration* shows a gradual diminution in the measurement of the affected side, until it becomes even less than the opposite side.

*Percussion*.—The percussion sound gradually recovers its normal resonance, first at the upper and then at the lower portion of the pleural cavity; sometimes in the inferior portion it never regains its normal resonance,

owing to the great accumulation of solid, plastic material, or condensation of lung tissue.

*Auscultation.*—The respiratory sounds are again heard, at first weak and distant; gradually they become more distinct, and sometimes harsh in character. As the absorption of the liquid takes place, and the two surfaces of the pleura again come in contact, a friction sound, of a creaking, crepitating character, appears, and remains audible for a variable period. The *vocal resonance* is at first bronchophonic, then exaggerated, and ultimately becomes normal. The heart, with the adjacent abdominal viscera, returns to its normal position, sometimes with singular promptness. If, as sometimes happens, the lung remains permanently impervious to air, then there is a permanent loss of motion on the affected side, and there is no return of the respiratory or vocal sounds, while dulness on percussion is persistent. A portion of the lung (usually the upper) sometimes becomes partially pervious to air; when this is the case, the percussion sound over it will have a tympanic quality, the vocal resonance will be exaggerated, and the respiratory sound coarse and blowing.

*EMPYEMA.*—The physical signs of empyema are the same as those of sub-acute pleurisy, when the pleural cavity is partially filled with liquid. In the majority of the cases of empyema that have come under my observation, a change in the position of the patient has not caused a change in the level of the liquid, owing probably to the firm adhesion that takes place above it between the pleura pulmonalis and pleura costalis. Excessively abundant empyematous effusions sometimes pulsate rhythmically with the heart—the “*pulsating empyemata.*”

*Differential Diagnosis.*—The diagnosis of pleurisy,



in the majority of cases, is easily made ; yet in all its different varieties there is some danger of confounding it with other diseases.

In the *dry stage* of acute pleurisy it may be confounded with pleurodynia and intercostal neuralgia. It is distinguished from them by the presence of the grazing friction sound, by the deep-seated character of the pain, and by the absence of tenderness on pressure over the seat of pain. It is further differentiated from intercostal neuralgia by not having the three points of tenderness, viz.: at the exit of the nerve from the spinal canal, over the greatest curvature of the rib, and in front.

The *plastic stage* of pleurisy on the left side may be confounded occasionally with the plastic stage of pericarditis. It is readily distinguished from it by the cessation of the friction sound during a temporary suspension of the respiratory movements.

The *effusive stage* may be confounded with consolidation of the lung from pneumonia and tubercular infiltration, with an enlarged liver or spleen extending upward, and with cancerous deposits in the lungs. It is distinguished from pneumonia and tubercular consolidation by the bulging of the affected side, by the absence of vocal fremitus, by the flatness of the percussion sound, by the change in the level of the liquid on change in the position of the patient, and by the absence of all vocal and respiratory sounds. The blowing respiration that is sometimes heard over a pleural cavity filled with liquid differs from the true tubular or bronchial breathing of pulmonary consolidation in being *more diffused* and *deep-seated*, and not accompanied by any moist sounds. In tubercular consolidation, the progress of the physical signs is usually from above downward ; in effusion, they advance from below upward. Besides,

pulmonary tuberculosis of an entire lung does not exist without involving the opposite lung, while any amount of pleuritic effusion may exist on one side while the other remains unaffected.

The physical signs of the stage of absorption will rarely be confounded with any other disease. Hypertrophy of the liver, enlarging upward, is distinguished from effusion into the right pleural cavity by the existence of pulmonary percussion and audible respiratory murmur at the posterior part of the chest. Deep inspiration also increases the area of the normal percussion and normal respiratory sound at the inferior portion of the pleural cavity ; it exerts no such influence when the loss of resonance and respiratory murmur depends upon pleuritic effusion.

Enlargement of the spleen affects but slightly the vocal or respiratory sounds at the inferior portion of the left pleural cavity. It causes no protrusion of the intercostal spaces, and does not, like pleuritic effusion, push the heart to the right, but raises it upward.

**PNEUMOTHORAX.**—Inspection shows distention of the affected side, widening and bulging of the intercostal spaces, and immobility of the chest walls, contrasting forcibly with the costal movements of the healthy side.

*Palpation.*—Vocal fremitus is diminished, or altogether wanting. *Mensuration* shows the affected side to be markedly increased in size.

*Percussion* elicits a tympanitic resonance, of an amphoric or metallic quality, over the whole of the affected side. When the dilatation of the chest is excessive, the adjacent viscera are more or less displaced. The tympanitic percussion sound assumes a muffled character, and extends considerably beyond the normal limits of the pleura.

*Auscultation* varies according to the amount of air contained in the pleural cavity. If the cavity is distended with air, so that the lung is completely compressed, the vocal and respiratory sounds are altogether absent, and the heart sounds are feebly transmitted through the distended pleura; if the quantity of air is small, the respiratory sounds are weak and distant, and the vocal sounds indistinct.

**HYDRO-PNEUMOTHORAX** usually results from the open-

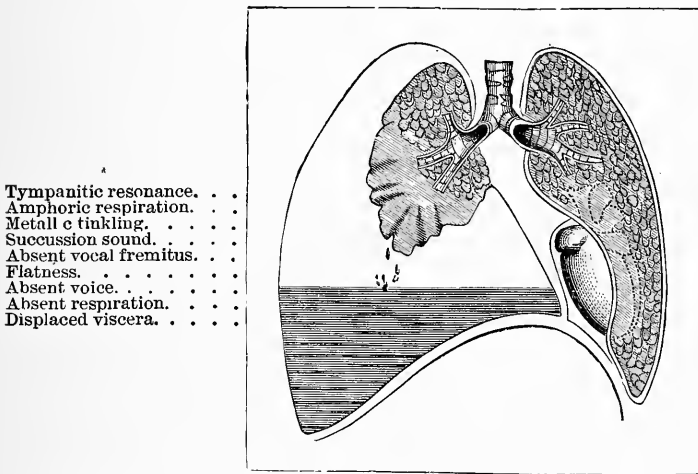


FIG. 8.—Diagram illustrative of the Physical Signs of Hydro-pneumothorax.

ing of a bronchus into the pleural cavity. The physical signs of this condition are a combination of those of pleuritic effusion and pneumothorax. As in pneumothorax, inspection reveals dilatation of the affected side, widening and bulging of the intercostal spaces, immobility of the chest walls, and displacement of the heart and adjacent viscera. There is entire absence of vocal fremitus.

*Percussion*.—When the patient is sitting or standing, there will be tympanitic resonance on percussion from

the summit of the affected side to the level of the liquid, and flatness below ; the relation of the flatness and tympanic resonance changing with the change in the position of the patient.

*Auscultation.*—Below the level of the liquid there is entire absence of all the respiratory and vocal sounds ; above its level there is usually amphoric respiration and metallic tinkling.

The characteristic physical sign of this disease is the *succussion sound*, which is a metallic, splashing sound, produced by abruptly shaking the chest while the ear is resting on its surface.

The respiration on the healthy side is exaggerated. When pneumothorax is secondary to advanced tuberculosis, the lung often remains adherent to the chest wall, and great distention of the affected side is prevented. Complete catarrhal obstructions in the main bronchi sometimes give signs similar to those of pneumothorax.

### *Pulmonary Tuberculosis.*

Tuberculosis of the lungs may be divided into *Acute* and *Chronic*. The Acute occurs in two forms, *Acute Miliary Tuberculosis* and *Acute Tubercular Pneumonia*.

#### ACUTE MILIARY TUBERCULOSIS.

Acute Miliary Tuberculosis, in which there is a dissemination of miliary tubercles throughout the lungs, cannot be differentiated, by the physical signs, from a catarrh of the smaller bronchial tubes. The diagnosis rests upon an examination of the sputum (see page 207), but is only of value when a positive result is obtained.<sup>1</sup>

---

<sup>1</sup> Von Jaksch states that the bacilli are never present in this form of the disease.

## ACUTE TUBERCULAR PNEUMONIA.

In this form of the disease, lobules or an entire lobe may rapidly become consolidated. The physical signs are the same as those of lobular or lobar pneumonia (see pages 58 and 60). Here again the microscope is necessary to complete the diagnosis.

CHRONIC PULMONARY TUBERCULOSIS. (*Chronic Phthisis.*)

**EARLY STAGE.**—The lesion is usually situated about an inch from the apex of the lung, and nearer the posterior than the anterior surface; consequently the physical signs will be best marked behind.

*Inspection* affords little information unless the consolidation is extensive and confined to one apex, where expansion in the infra- and supra-clavicular regions of the affected side will be diminished, and there will be some flattening of the upper part of the chest wall.

*Palpation.*—By palpation you will often detect deficient expansion in the infra-clavicular region of the affected side when it cannot be detected by inspection. There is also slight increase in the vocal fremitus; this increase, however, is less significant when it occurs on the right side than on the left.

*Percussion.*—The difference in the percussion note in the infra-clavicular region on the two sides, rather than the quality of the sound, is important. But it must be remembered that normally there exists a discrepancy in the two sides. On the right the pulmonary resonance is less marked and the pitch of the percussion sound is higher.

If the consolidation is slight and superficial, the pitch of the percussion sound on the affected side will be

slightly raised. But if healthy or emphysematous lung tissue intervene between the consolidated lung and the chest walls, the percussion sound may be normal, or extra resonant, over the affected portion. To detect pulmonary consolidation under such circumstances, the percussion blow must be forcible, and directed from, not toward, the trachea. If doubts exist, the percussion should be performed at the end of a full inspiration and at the end of a full expiration. As consolidation increases, the pitch of the percussion sound rises and its clearness diminishes, until, in some cases, absolute dullness is reached.

*Auscultation.*—The respiratory sound in the infra- and supra-clavicular regions of the affected side is weak or suppressed at some points, and exaggerated at others. It may be jerking, wavy, or “*cogged-wheel*” in its rhythm, and rude or bronchial in its quality. The inspiratory sound loses its soft, breezy character, and becomes higher pitched and tubular; while the expiratory becomes higher pitched than the inspiratory, and is prolonged. Prolonged expiration, however, if unattended with any alteration in quality, is insignificant. The value of these states of the respiration corresponds to their position. If they exist above and are imperceptible below the second interspace, they are seriously significant. Localized mucous or sub-crepitant rales, heard over a limited space at the apex of the lung, are always important signs of tuberculosis, and indicate the development of broncho- or catarrhal pneumonia. They are often present before any appreciable change in the respiratory murmur occurs. At first they are more or less obscure in proportion to the weakening of the respiration; gradually they become more distinct and numerous as the pulmonary consolidation increases. The

heart sounds over the affected lung will be increased in intensity.

Vocal resonance is subject to so many variations as to render it almost valueless as a means of diagnosis. Exaggerated vocal resonance at the left apex is of some importance.

The **ADVANCED STAGE** is marked by a greater involvement of lung tissue. The consolidation extends, and is attended by softening, and the formation of cavities. There is a diminution in the volume of the lung, with corresponding contraction of the chest walls.

The diagnosis of a cavity demands that it be near the surface, not smaller than a walnut, and for the most part contain air.

*Inspection.*—The respiratory acts are much increased in frequency, and marked depression will be noticed above and below the clavicles. There is deficiency in local expansion, especially during a full inspiration; or it may be that the respiratory movements are arrested in the supra- and infra-clavicular regions.

*Palpation.*—The vocal fremitus, as a rule, is increased over the consolidated area, and over a large superficial cavity when partially or completely filled. Sometimes a gurgling fremitus may be detected.

*Percussion.*—Before cavities are formed there is a widespread and more intense dulness than in the Early Stage. It often assumes a wooden or a tubular character. After the formation of cavities the percussion sound varies according to the condition of the cavities themselves and the lung tissue surrounding them. If the cavity is of small size and surrounded with consolidated lung tissue, the percussion sound will be absolutely dull or tubular in quality; if a layer of healthy lung tissue intervene between the chest walls and the

cavity, the latter being full, gentle percussion will give normal resonance, while forcible percussion will elicit deep-seated dulness. Large, empty, superficial cavities with thin, tense walls yield an amphoric or "cracked-pot" resonance.

*Auscultation.*—Over consolidated areas the respiration grows more intensely bronchial, and moist, crackling rales of a metallic character are heard. The rales sometimes are sticky in character, and do not change or disappear on coughing.

If a cavity is empty and communicates freely with a bronchial tube, and no healthy lung tissue lies between it and the chest walls, the respiration will be either cavernous or amphoric (as shown in Fig. 4, page 44)—*cavernous*, when the cavity is of small size, with a flaccid wall that collapses with expiration and expands with inspiration; *amphoric*, when the cavity is large and surrounded with consolidated lung, or with a thick, fibrous wall that does not collapse in expiration. If liquid has accumulated in the cavity in sufficient quantity to rise above the opening into it, large or small-sized gurgles will be heard (as shown in Fig. 4, page 44). Metallic tinkling will sometimes be heard over cavities of large size. Vocal resonance may be amphoric, bronchophonic, weak, or entirely absent; pectoriloquy may be present. Small cavities partially filled with liquid, and deeply seated, do not give rise to the signs characteristic of cavities, but simply furnish blowing respiration and small-sized gurgles, which resemble very closely mucous rales.

A cavity may be presumed to exist at the point where the bronchial breathing is most intense and the moist sounds are most metallic in quality. The difficulty with which tuberculosis is differentiated from some forms of pleurisy and pneumonia has already been indicated.



HEART  
AND  
THORACIC AORTA.



## LESSON IX.

### TOPOGRAPHY OF THE HEART AND AORTA—PHYSIOLOGICAL ACTION OF THE HEART.

THE diagnosis of many cardiac diseases rests upon our knowledge of the relations of the different compartments and orifices of the heart to the chest walls. It is therefore necessary to be familiar with this relationship, and with the physiological acts which constitute a complete cardiac cycle, before we can study intelligently the physical signs involved in the diagnosis of these diseases.

By referring to Fig. 1, page 5, the relations of the heart to the adjacent viscera will be readily appreciated.

In the healthy chest, the auricles are on a line with the third costal cartilages. The *right auricle* extends across the sternum, a little beyond its right border. The *left auricle* lies deeply behind the pulmonary artery. The middle portion of this auricle corresponds to the cartilage of the third rib. The *right ventricle* lies partly behind the sternum, and partly to the left of it; its inferior border is on a level with the sixth cartilage. The *left ventricle* lies for the most part to the left of the sternum, between the third and fifth intercostal spaces. Only a narrow strip of the ventricle is visible anteriorly. The heart, then, as a whole, extends vertically from the second space to the sixth costal cartilage, and transversely from about half an inch to the right of the sternum to within an inch of the left nipple line. Posteriorly,

the base lies opposite the sixth and seventh dorsal vertebræ. The left ventricle, the greater part of the left auricle, and a large portion of the apex of the right ventricle, lie to the left of the sternum. Behind the sternum lie a greater portion of the right auricle and ventricle, and a small portion of the left. To the right of the sternum lie a portion of the right auricle and the upper portion of the right ventricle. The whole of the anterior surface of the heart is overlapped by the lungs, except a triangular space corresponding to the lower portion of the right ventricle.

The SURFACE MEASUREMENTS of the heart are as follows: Vertical measurement from the second interspace to the fifth interspace, five inches; from the median line to the left, on the third rib, two and a half to three inches; on the fourth rib, from three and a half to four inches; in the fifth interspace, from three to three and a half inches.

#### *Relative Position of the Valves.*

The TRICUSPID VALVE lies behind the middle of the sternum, at the level of the fourth costal cartilage.

The MITRAL VALVE lies behind the third intercostal space, about one inch from the sternum. It is the deepest of all.

The AORTIC VALVES lie behind the sternum, near its left edge, a little below the junction of the third costal cartilage.

The PULMONARY VALVES lie behind the junction of the third left costal cartilage with the sternum. A circle of an inch in diameter with its centre at the left edge of the sternum, a little below the junction of the third rib with the sternum, will include a portion of all these four sets of valves.

The AORTA arises from the left ventricle behind the sternum, opposite the third intercostal space, and passes from left to right. The ascending portion of the arch comes to the right of the sternum between the cartilages of the second and third ribs. In this part of its course it is within the pericardial sac. Thence the transverse portion of the arch crosses the trachea just above its bifurcation (at the centre of the first bone of the sternum), and, passing backward and downward toward the left side of the third dorsal vertebra, becomes the descending portion. It rests ultimately upon the left side of the bodies of the fifth and sixth dorsal vertebræ. The arch of the aorta approaches most closely to the chest walls at the point where the arteria innominata is given off—that is, on a line with the junction of the cartilage of the second right rib with the sternum.

The PULMONARY ARTERY arises from the right ventricle, to the left and behind the sternum, on a line with the junction of the cartilages of the third ribs with the sternum. It passes upward and backward about two inches, when it bifurcates opposite the second costal cartilage.

The PERICARDIAL SAC encloses the heart, and may be represented as a cone, extending from the second to the seventh left costal cartilage. The base of the cone rests on, and is attached to, the diaphragm, and the apex embraces the lower two inches of the great vessels. The larger portion of the sac lies to the left of the median line, and is further from the anterior chest wall superiorly than it is inferiorly.

#### *Physiological Action of the Heart.*

A contraction of the heart begins in the great veins and proceeds as a peristaltic wave to the auricles. They

rapidly contract, and are immediately followed by the ventricular contraction, or systole. After a contraction the muscular tissue relaxes, and a period of rest ensues, the diastole. A complete cardiac cycle consists of the contraction and dilatation of each of the cavities of the heart. During the ventricular systole there is a change in its form, size, and position.

**AURICULAR DIASTOLE.**—The blood is pouring from the great veins into the auricles, and through the auriculo-ventricular openings into the ventricles below.

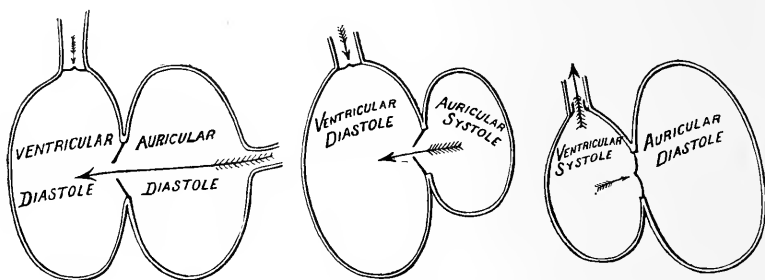


FIG. 9.—Diagrammatic representation of the Changes that occur in the Valves and Cavities of One Side of the Heart during a Cardiac Cycle.

The semilunar valves are closed, as seen in Fig. 9. When the auricles become distended the

**AURICULAR SYSTOLE** begins. As it progresses they become smaller, and their walls crowd toward the opening into the ventricles below, forcing a small quantity of blood before them. The semilunar valves still remain closed.

**VENTRICULAR SYSTOLE.**—The contraction of the auricles completely fills the ventricles with blood. At the same time, it is supposed, the flaps of the mitral and tricuspid valves are floated into place by reflex currents

along the sides of the cavities. Everything is now ready for contraction. Suddenly the ventricular walls become tense and hard, the shape of the heart becomes more distinctly conical, and it rotates on its long axis from left to right, bringing more of the left ventricle to the front. The systole is complete. The blood has been forced into the aorta and pulmonary arteries respectively. During its passage the cusps of the semilunar valves have been pressed toward, but not against, the arterial walls. Any reflux of blood into the auricles, or even bulging of the auriculo-ventricular valves, is prevented by the contraction of the muscular papillæ. They draw upon the chordæ tendineæ, and hold the flaps in close apposition. The cardiac impulse is synchronous with the ventricular systole, and is caused by the impact of the rigid heart against the chest wall. It is most distinctly felt in the fifth intercostal space, just to the median side of the mammillary line. The first sound of the heart is heard with the ventricular contraction, and is of a loud, "booming" character. It is probably of combined muscular and valvular origin.

VENTRICULAR DIASTOLE.—After a short interval the second sound is heard. It is sharp and sudden in character, and is caused by the closure of the semilunar valves. At its occurrence the ventricles have just finished their systole and are beginning to relax. Then succeeds the diastole. The ventricular walls become flaccid, the heart returns to its former position, the valves at the mitral and tricuspid orifices open, and the blood flows in from the auricles, preparatory to the commencement of another cycle. The semilunar valves are closed by the negative pressure produced at the end of the systole, or by the elastic recoil of the over-distended arteries.

DURATION OF THE DIFFERENT PHASES.—The ventricular systole occupies about three-eighths of an entire cardiac cycle; the auricular systole, about one-eighth; and the diastole of the auricles and ventricles, about one-half.

But it must be remembered that the ventricles are at rest also during the auricular systole; so it will be seen that they work less than one-half the time.

Fig. 10 well illustrates the sequence of events in a

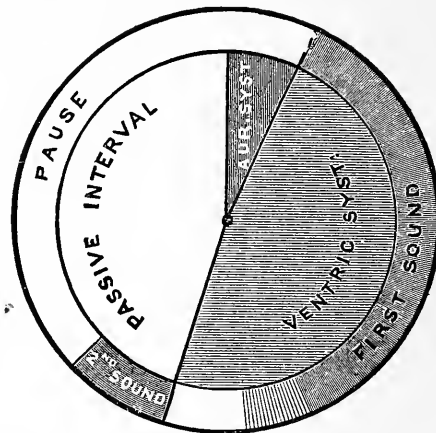


FIG. 10.—Representation of the Movements and Sounds of the Heart during a Cardiac Cycle — DR. SHARPEY.

cardiac cycle. It is not intended that its measurements shall be exact.

The normal pulse rate of the heart is 72 to the minute, though it varies considerably in different individuals, and in the same individual at different times. Thus, it is more rapid in women and children than in men, and it becomes accelerated after a full meal. A rapidly beating heart differs from a slowly beating heart chiefly in the length of its diastole. As the length of the diastole increases, the greater becomes the interval between the second and first sounds of the heart. Fig. 11 is a series of circles representing the altered relations of the sounds



in slowed or accelerated heart action. The first and second sounds correspond, respectively, to radii 1 and 2.

The larger circumference of each successive circle indicates the lengthening of the pause. The interval between the *first* and *second* sounds becomes relatively shortened as the heart's action is slowed, and is represented by a smaller arc; while the interval between the *second* and *first* sounds is lengthened. In the first and smallest circle, indicating the most rapid action, the two intervals are nearly equal, and each occupies about one-half the circumference; in the last or largest circle the interval between the *second* and *first* sounds is about four times as long as that between the first and second. Hence it is that, when the heart is acting rapidly, it is difficult to distinguish the *first* sound from the *second*, and *vice versa*; while with the slowly acting heart this difficulty does not occur. Attention to these varieties—physiological varieties they may be called—in the rhythm of the

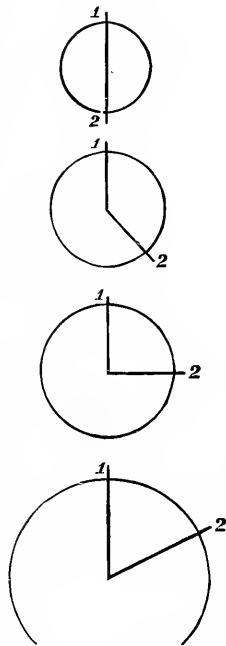


FIG. 11.

sounds is of very great importance in determining the attributes of a cardiac murmur, for the first step in the inquiry is to determine which is the second sound and which is the first. This, as I have said, is sometimes not an easy matter. Generally speaking, and in all cases when the action is slow and regular, there is no difficulty. You have only to remember that the longer interval is between the *second* and *first* sounds, and the shorter interval between the *first* and *second*. But when

the action is rapid or irregular, and when the first sound is indistinct at the apex, or cannot be identified with the apex beat, and also when the second sound is indistinct, or when it is audible only at the base, the first sound being audible only at the apex, as sometimes happens, the difficulty of recognition of the two sounds is very considerable.

## LESSON X.

### METHODS OF CARDIAC PHYSICAL EXAMINATION.

THE methods of physical examination of the heart include *inspection*, *palpation*, *mensuration*, *percussion*, and *auscultation*.

By INSPECTION you note the exact point of the heart's impulse against the chest wall, whether there is any unusual pulsation, or any change in the form of the cardiac region. In a perfectly normal chest, the infra-mammary regions on either side are very nearly symmetrical; but in disease the precordial region may be depressed, or arched forward, and the intercostal spaces may be widened. The most important information furnished by inspection relates to the cardiac impulse. This, in the majority of persons, is visible only in the fifth interspace, midway between the left nipple and the sternum, and its area does not exceed a square inch. You will find it most distinct in thin persons, while in fleshy persons it is sometimes not discernible. You will find also that it may be displaced by a change of position, by distention of the subjacent stomach, and by the movements of respiration. Thus, during a full inspiration you may see the impulse lowered an intercostal space, and then during a forced expiration see it elevated and more diffused.

*Change in the situation of the impulse* may result from disease of the heart itself, disease of the pericardium or of the adjacent viscera. In cardiac hyper-

trophy it is displaced downward and to the left, while in pericardial effusion it is displaced upward. It may be carried upward and to the left by enlargement of the left lobe of the liver, or downward and to the right by simple pleuritic effusion or emphysema. I have seen the impulse even external to the right nipple. Not infrequently in cases of pericardial agglutination, or dilatation of the ventricles, an undulating impulse will be visible.

When from any cause the impulse cannot be seen, its position must be determined by palpation.

**PALPATION.**—This is of much greater clinical importance than inspection. By it we determine the force of the cardiac pulsation, the frequency or slowness of the heart's action, and the regularity or irregularity of its movements. By it, also, we detect the presence of the friction fremitus, and what is termed the "purring thrill."

*The force of the cardiac impulse* may be diminished or increased.

*Diminution in the force of the impulse* may be due to degeneration of the heart wall, or to prostration of the whole system, as in collapse. It is also diminished when the apex is prevented from impinging against the wall of the chest with its customary force, as happens in disease of the lungs or pericardium.

*Increase in the force of the impulse.*—In the majority of instances, this is caused by hypertrophy of the walls of the left ventricle. A slow, progressive impulse can be produced by no other cause. In such cases, the area over which the cardiac impulse can be felt is much increased. In the early stage of endocarditis and pericarditis, and in palpitations from functional disorders, the impulse is slightly increased.

The frequency and regularity of the heart's action is of great importance in the diagnosis of cardiac disease. It can often be most accurately determined by palpation.

The *Purring Thrill* (the "*frémissement cataire*" of Laennec) is a peculiar vibratory sensation perceptible on making pressure at the precordium. In some the pressure need be but slight, while in others it should be firm. It may also be communicated by the large arteries, etc.

PERCUSSION.—By percussion we aim to determine the exact outline of the heart and of its investing membrane, to see whether it exceeds its normal area. In performing cardiac percussion you will find both care and patience necessary to obtain accurate results. The patient should be in a recumbent posture. You need tap but lightly over the part where the heart is not covered by lung tissue, to obtain a flat sound ; but where the lungs overlap the organ, you must percuss more forcibly to elicit cardiac dulness, and this sound will of necessity have more or less of a pulmonary quality. We have, therefore, two degrees of cardiac dulness—the superficial and the deep-seated. In *health* the area of the superficial dulness does not exceed two inches in any direction. It is triangular in form, with the apex immediately below the junction of the left third rib with the sternum, while the base is on a line with the cartilage of the sixth rib. The area of the deep-seated dulness in health extends transversely from the left nipple to half an inch to the right of the sternum, and vertically from the second to the sixth interspace.

The area of the heart's superficial dulness may be increased or diminished : increased, when the ventricles are hypertrophied, or when their cavities are dilated, and also when the pericardium contains liquid ; diminished, at the end of a full inspiration, and in pulmonary

emphysema where there is a general distention of the air cells. The area of the deep-seated dulness is increased by enlargement of the heart, whether this be due to ventricular dilatation or to hypertrophy of its walls. It is *apparently* increased by consolidation of the anterior border of the investing lung, and by liquid in the left pleural cavity. We are often, in certain cases, much assisted in determining the limits of the deep-seated dulness by *auscultatory* percussion.

AUSCULTATION.—For reasons already stated I prefer mediate to immediate auscultation in examining the heart, and in practising it you will find the following simple rules of service :

1. The posture of the patient should be recumbent when you begin your examination. Then, having carefully elicited all the auscultatory signs which this posture affords, repeat your examination with him sitting or standing, and note whether any variations in the sounds heard have occurred from the change in his position.

2. You should first listen to the heart sounds while the patient is breathing naturally ; having done so, then direct him to hold his breath for a moment ; and finally tell him to take three or four forced inspirations. All of these means are often requisite before we can correctly discriminate between the different signs of cardiac auscultation.

3. You should not confine your examination to the precordial region alone, but should explore the whole thoracic cavity, and endeavor to localize the points at which the heart sounds, both normal and abnormal, are heard with the greatest intensity. To this end proceed in your examination from below upward, and from left to right.

As in the case of pulmonary auscultation, so here, the normal characters must be the starting-point or standard to which every sound in cardiac auscultation is to be compared. You cannot, therefore, pay too much attention to acquiring a familiarity with the elements of the heart sounds in health. These elements are as follows : When the ear or stethoscope is applied to the precordial region, two successive sounds are heard, followed by an interval of silence. The first sound is softer, lower in pitch, and more prolonged than the second ; as has already been shown in Fig. 10, it coincides with the systole of the ventricles and with the apex beat. It immediately precedes the radial pulse, and has its maximum of intensity in the fifth interspace, a little to the right of the left nipple line. The second sound is sharper, or higher pitched, shorter and more superficial than the first. It marks the beginning of the ventricular diastole, occurs after the pulsation of the arteries, and has its maximum of intensity at the junction of the third left rib with the sternum.

The period of silence immediately following the second sound varies in length with the rapidity of the heart's action. The order and duration of the sounds, and the silence, you will be able to appreciate best by referring to diagrams Nos. 10 and 11 (pages 86 and 87).

The *intensity* of the heart sounds varies in health according to the force of the heart's action, or according to the conformation of the chest, or according to individual idiosyncrasies. These sounds are less intense in fleshy or muscular persons with capacious chests than in thin, narrow-chested, and nervous individuals.

The *extent* of surface over which the heart sounds are heard varies with the adaptation of the adjacent organs for transmitting sounds. Generally speaking, the sounds

produced on the right side of the heart are more audible on the right side of the precordial region, while those produced on the left are more pronounced on the corresponding side.

**PATHOLOGICAL MODIFICATIONS OF THE NORMAL SOUNDS.**—In disease the normal sounds of the heart present various alterations as regards their intensity, quality, pitch, seat, and rhythm. They may also be accompanied, preceded, or followed by adventitious sounds or murmurs.

An *increase of intensity* may be noted in cases of hypertrophy and dilatation of the ventricles, in cases of nervous irritability of the heart, or where there is consolidation of the adjacent lung tissue. A *diminution in intensity* may be found depending either upon dilatation of the ventricles without hypertrophy of their walls; upon fatty degeneration of the muscular tissue of the heart; upon the granular or hyaline changes occurring in infectious fevers; or it may be owing to a muffling of the heart sounds by pericardial effusion, or by emphysematous distention of the anterior border of the lung.

*Alterations in Quality and Pitch.*—The heart sounds in disease may become dull and low-pitched, or sharp and high-pitched. The first sound is dull, muffled, and low-pitched when hypertrophy is conjoined with a thickened condition of the auriculo-ventricular valves. On the other hand, where the ventricular walls are thin and the valves natural, the first sound becomes sharp and clicking in character, and the pitch is raised. The second sound is rendered dull and low-pitched by diminished elasticity of the arterial walls, and by thickening of the aortic valves, without regurgitation. Sometimes the heart sounds have a metallic or tinkling qual-



ity, which depends either upon an irritable action of the heart or on a gaseous distention of the stomach.

*Alterations in Seat.*—This refers to the points of maximum intensity of the respective sounds. They may be displaced *upward* by certain changes in the abdominal viscera ; or *downward* by tumors in the mediastinum, and by hypertrophy with dilatation of the auricles ; or *laterally* by the accumulation of air or liquid in the pleural cavities. Malformations of the thorax may likewise displace them in different directions.

*Alterations in Rhythm.*—It not infrequently happens that a distinct intermission occurs in the heart's action. After a certain number of regular beats, a sudden pause or silence occurs ; the heart's action seems to be suspended for an instant, and then to go on regularly. This intermission is often observed in individuals who are in perfect health. It also occurs in diseased states of the valves or orifices of the heart. It is difficult to explain its cause, and it has no precise pathological significance.

*Irregularity in the Heart Sounds*, however, constitutes another and different alteration in rhythm. The sounds become confused and tumultuous ; they are alternately loud and feeble ; at one time slow for two or three beats, and then they follow each other in rapid succession. When the irregularity is permanent, it is almost positive evidence of organic disease of the heart, the most frequent form being contraction of the mitral valves.

One or both of the heart sounds, as well as the period of rest, may be prolonged or shortened. In hypertrophy of the ventricular walls the first sound is prolonged, in dilatation of the cavities of the ventricles it is shortened. The first sound is also prolonged when the two surfaces of the pericardium are adherent. An obstacle to

the flow of the blood into the ventricles prolongs the period of repose. Another alteration in the rhythm of the heart sounds is named *reduplication*. Each systolic sound may be repeated twice for one diastolic, or the diastolic may occur twice for one systolic. Sometimes only one sound is audible.

The essential cause of the various reduplications seems to be a want of synchronism between the action of the two sides of the heart. It may occur at all ages, and is as common with one sound as with the other. Intermittence is an almost constant character of reduplication, the sound being doubled with some beats of the heart, and not with others. This intermittence in some instances is undoubtedly connected with the movements of respiration. In laborious respiration the first sound may be doubled at the end of inspiration and the beginning of expiration, and the second sound at the end of expiration and the beginning of inspiration. *Clinically*, it is important to distinguish true doubling of the sounds from those false reduplications which are in reality compounded of a sound and a murmur.

## LESSON XI.

### ABNORMAL SOUNDS OF THE HEART.

#### *Pericardial and Endocardial Murmurs.*

THE term *murmurs* has been applied to those adventitious sounds which accompany or replace the normal sounds of the heart, and which are not heard in health. Their seat may be either within the heart at the orifices of the ventricles, when they are called endocardial or valvular murmurs; or they may be external and in the pericardium, when they are termed exocardial or pericardial friction sounds.

PERICARDIAL FRICTION SOUNDS.—The pericardium is a serous membrane investing the heart, as the pleura invests the adjacent lung. We have, therefore, when it is inflamed, results analogous to those which we described as appertaining to pleurisy—namely, dryness, and then plastic exudation, with the different friction sounds which are caused by the rubbing of the roughened surfaces upon one another during the movements of the heart, and, lastly, the serous effusion. This similarity sometimes makes it a nice point in diagnosis to distinguish a pericarditis from a pleurisy. In pericarditis the sounds are limited to the precordial area; they are synchronous with the cardiac rather than the respiratory movements, and do not cease when the patient holds his breath.

The different forms of the pericardial friction sounds have been named, like those in pleurisy, grazing, rubbing, creaking, rasping, etc. Clinical experience, however, does not always show any definite connection between

the state of the serous surfaces and the quality of a friction sound. The grazing variety belongs to the initial stage of the inflammation; the other varieties occur after the plastic effusion, and while it is undergoing organization. These sounds vary in intensity from the slight rustling which can be heard only by close attention, to a loud rasping sound audible before your ear is applied to the chest. As a rule, they become more distinct during expiration than inspiration, and while the patient is sitting rather than while recumbent, owing to the greater approximation of the pericardium to the chest wall during these states.

Pericardial friction sounds may be single or double—that is, accompanying both the systolic and the diastolic movements, or either one singly. They may accompany the valvular sounds, or be independent of them. They usually convey the impression of being superficial in comparison with the endocardial murmurs. They are generally restricted to the pericardial space, the point of maximum intensity being usually at the junction of the fourth rib with the sternum. They do not often last long, disappearing frequently after a few hours, or at most in a few days.

A pericardial murmur is distinguished from an endocardial by its rubbing quality, by its superficial character, and by its *not being transmitted beyond the limits of the heart*, either along the arteries or round the left side to the back. It may also be distinguished from a valvular murmur by its intensity varying with a change in the position of the patient, and by its independence of the heart sounds.

#### *Endocardial or Valvular Murmurs.*

In endocardial murmurs the elements of quality and

intensity hold but a subordinate place as regards either diagnosis or prognosis. The same murmur may be, at different times, blowing, grating, rubbing, or musical in character, without its significance altering in the least through all these changes in its quality. "The mere fact that a murmur exists, and has a certain acoustic quality, tells very little as regards the true character of a case." Practically speaking, endocardial murmurs may be regarded as "audible announcements" that something has occurred to roughen the surfaces of the endocardium, or to constrict the orifices of the heart, or to render the valves insufficient so that they allow the blood to regurgitate, or to diminish the elasticity of the great vessels, or, finally, that some change has taken place in the natural constituents of the blood itself. Anomalous chordæ tendineæ, when crossing the cavity of the heart near its base, sometimes give rise to a musical murmur.

Having ascertained the existence of a cardiac murmur, the first question then is, What is its pathological significance, or in what way has it been produced? To determine this it is necessary to observe particularly two points: 1st, The *rhythm*; and, 2d, The *seat* of the murmur.

THE RHYTHM OF A MURMUR.—By rhythm we mean the relation of a murmur to the different phases of the cardiac cycle. We speak of the murmur as occurring with the auricular or ventricular systole, or during the rest which intervenes between the periods of activity. To determine its rhythm you must carefully note its relation to the normal sounds, the impulse, and the radial pulse.

Evidently, the first step is to determine which is the first and which is the second sound of the heart. When

the heart's action is slow and regular, this is an easy matter, but when it is rapid it is always difficult, and sometimes impossible, to distinguish the one sound from the other. It is important, therefore, not only to know theoretically all the appreciable phenomena of the physiological action of the heart, but to have a practical familiarity with them.

Having identified the two sounds, and noted their relation to the apex beat and radial pulse, the *rhythm* of a murmur is readily determined; for all *valvular* mur-

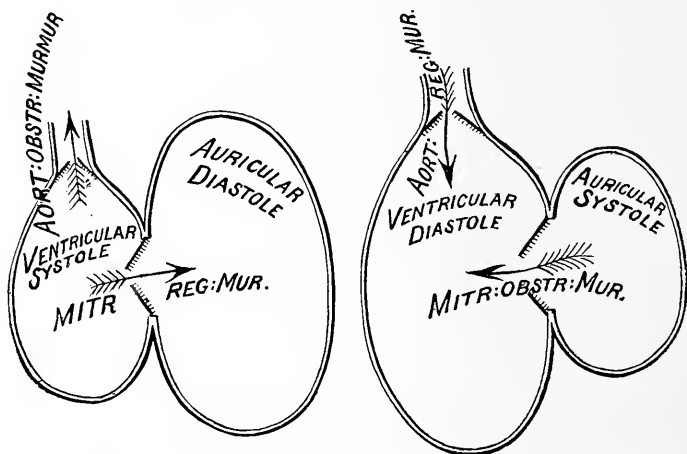


FIG. 12.—Diagram illustrating the mode of production of Cardiac Murmurs in the Left Heart, and the condition of the Valves and Cavities during their production. By substituting the words "tricuspid" and "pulmonary" for "mitral" and "aortic," the diagram will similarly illustrate murmurs occurring in the right heart.

murs either *precede*, or *take the place of*, or *immediately follow* one of the heart sounds.

*First.* A murmur may precede and run up to the first sound, ending at the commencement of the sound, and with the apex beat. In this case, as shown by Fig. 12, the murmur is simultaneous with the contraction of the auricles, and is either a *mitral* or *tricuspid obstructive murmur*, according as it is produced on the right or left side of the heart while the blood is passing from the

auricles to the ventricles. Such murmurs, therefore, depend upon contraction of the mitral or tricuspid orifices, or upon deposits on the auricular surface of these valves, causing obstruction to the outflow of blood from the auricle.

*Second.* A murmur may take the place of, or follow, the first sound, ending somewhere between the first and second sounds. In this case the murmur is coincident with the contraction and emptying of the ventricles, and must be caused, as is shown in Fig. 12, either by obstruction to the current of blood as it flows outward from the ventricles, in its natural direction into the aorta and pulmonary artery; or backward, by regurgitation, through the mitral or tricuspid valves. If it occur on the left side of the heart, it is either an *aortic obstructive* or a *mitral regurgitant* murmur; if it occur on the right side of the heart, it is either a *pulmonic obstructive* or a *tricuspid regurgitant* murmur.

*Third.* A murmur may take the place of, or follow, the *second* sound, ending somewhere during the interval between the second and first sounds: in some instances it may be prolonged through the whole period of rest. This murmur is simultaneous with the dilatation of the ventricles (Fig. 12), and is produced by regurgitation of blood through the aortic or pulmonary valves, and is either an *aortic regurgitant* or a *pulmonic regurgitant* murmur.

We may have, therefore, eight distinct endocardial murmurs, four systolic and four diastolic. Not infrequently we find in practice various combinations of these different murmurs in the same case. For instance, it is not unusual to have a mitral obstructive and mitral regurgitant murmur combined, so as to appear to constitute one murmur; the first sound of the heart

will, however, enable you to separate the two murmurs. In like manner, an aortic obstructive and regurgitant murmur are frequently combined; here also the sound intervenes, and makes the rhythm quite plain. The greatest difficulty is when the normal sound is merged into the murmur, as is often the case when the mitral obstructive and regurgitant are combined.

The precise pathological significance of endocardial murmurs is apparent from the following table :

		TABLE OF CARDIAC MURMURS. <sup>1</sup>	
Periods of Heart's Action.	Seat of Murmur.	Cause of Murmur.	
Systolic.	Left side of heart.	Aortic.....	Obstruction to the onward flow of blood through the aortic orifice, or through the aorta.
		Mitral.....	Regurgitation of blood through the mitral valve into the left auricle;
	Right side of heart.	Pulmonary.	Obstruction to the onward flow of blood through pulmonary orifice, or through pulmonary artery.
		Tricuspid..	Regurgitation of blood through the tricuspid orifice into right auricle.
Diastolic.	Left side of heart.	Aortic.....	Regurgitation of blood through the aortic orifice into left ventricle.
		Mitral.....	Obstruction to the flow of blood from left auricle to left ventricle.
	Right side of heart.	Pulmonary.	Regurgitation of blood through the pulmonary orifice into right ventricle.
		Tricuspid..	Obstruction to flow of blood from right auricle into right ventricle.

<sup>1</sup> After Fuller.



Although eight distinct valvular murmurs may occur in the heart, those on the right side are of such rare occurrence that they are of little clinical importance. If a murmur is heard with the first sound of the heart, it is almost certainly *aortic obstructive* or *mitral regurgitant*; if with the second sound, it is probably *aortic regurgitant*.

An obstructive mitral murmur is also of comparatively rare occurrence: the force with which the blood passes from the auricle into the ventricle is ordinarily insufficient to excite sonorous vibrations.

*Seat of Murmurs.*—Having determined the rhythm of a murmur, the next step in the investigation is to find, within as narrow limits as possible, the place of its origin. The points at which endocardial murmurs are produced being in the majority of cases one of the four valvular orifices, the first question to be settled under this head is, at which one of these valvular orifices it is produced.

At the commencement of the examination, every means should be taken to determine in each particular case the actual size and position of the heart, together with its relation to the thoracic walls and to the surrounding organs, the exact point of the apex beat, and the character of the impulse.

We must endeavor by careful stethoscopic examination to determine the exact seat, and the limits of diffusion, of the murmur under observation. If the murmur is very loud or diffused, or if there are several murmurs present in the same case, it may give rise to some difficulty; but in the large majority of cases the observer will be able to fix on a few points, or a few restricted spaces, over which each murmur is heard, there being

no murmur elsewhere ; or, if not so, areas within which each murmur is heard with greatest intensity.

As there are four valvular orifices at which the majority of endocardial murmurs are produced, so there are four distinct areas over which murmurs arising at these orifices may be diffused.

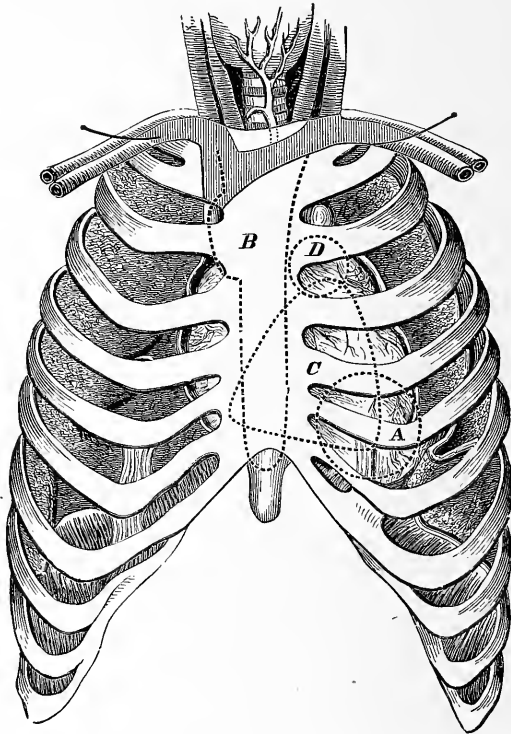


FIG. 13.—Diagram showing the Areas of Cardiac Murmurs. These several Areas correspond to the Different Spaces marked by the Dotted Lines, and a Capital Letter designates each Area. *A*, the Area of Mitral Murmurs; *B*, of Aortic; *C*, of Tricuspid; and *D*, of Pulmonic.—GAIRDNER.

The following rules will be found useful in recognizing these areas in actual practice:

I. *Area of Mitral Murmurs*.—The maximum of intensity of mitral murmurs corresponds generally with the apex of the left ventricle, represented in Fig. 13 by

the circle A. If it is produced by regurgitation of blood through the mitral orifice, it is transmitted to the left and backward on the line of the apex beat. The area of diffusion in front corresponds very nearly to the circle A, Fig. 13, but it is heard with nearly the same intensity behind, between the lower border of the fifth and upper border of the eighth vertebræ, at the left of the spines, as in front.

The area of diffusion of mitral obstructive murmurs is usually limited to a circumscribed space (circle A) around the apex of the heart. In some instances these murmurs are heard with equal intensity over the whole superficial cardiac region. To the left of the apex beat, they are always indistinct, and are never heard behind.

II. *Area of Tricuspid Murmurs*.—The area of tricuspid murmurs corresponds to that portion of the right ventricle which is uncovered by lung tissue, indicated in the diagram by the triangular space C. This murmur is distinct and superficial in character, rarely audible above the third rib, and thus readily distinguished from the aortic and pulmonic murmurs. It is heard loudest near the xiphoid cartilage, and along the margins of the sixth and seventh costal cartilages. In cases of hypertrophy and dilatation of the right side of the heart, usually its point of maximum intensity is at the junction of the fourth rib with the sternum.

III. *Area of Pulmonic Murmurs*.—A murmur in the pulmonary artery, or at the pulmonary valves, is carried to the ear nearly over the seat of the valves, as indicated by the circle D in the diagram, Fig. 13. Not infrequently its point of maximum intensity is an inch, or even an inch and a half, lower down. It is usually very superficial, and consequently very distinct. It is limited in its diffusion, being inaudible at the apex, and also along

the sternum. It is never heard in the neck, nor in the course of the great vessels.

IV. *Area of Aortic Murmurs.*—The law of diffusion of aortic murmurs is not easily explained: not only are they heard with great intensity over the base of the heart, at the junction of the third rib with the sternum on the left side, but frequently, and not less distinctly, along the whole length of the sternum, as is indicated by the dotted lines along the edge of the sternum, in the irregular space B, Fig. 13. Sometimes they are louder close to the xiphoid cartilage than at any other point. An aortic murmur is distinguished from all other cardiac murmurs by its propagation into the arteries of the neck. It is the most widely diffused of all cardiac murmurs, and can sometimes be traced to a very great distance from the heart. It may be heard behind near the lower angle of the scapula.

To complete the diagnosis of endocardial murmurs, it is necessary to consider their rhythm in connection with their area.

*First.* A murmur which immediately precedes the first sound of the heart may be either a mitral or tricuspid obstructive murmur, and is produced by obstruction to the current of blood as it passes from the auricles into the ventricles. If it is a mitral obstructive murmur, its maximum of intensity will correspond to the circle A, Fig. 13; if, on the contrary, it is a tricuspid obstructive murmur, its maximum of intensity will be within the triangle C.

*Second.* Murmurs accompanying or following the first sound, and occurring between the first and second sounds, may be produced either in the auriculo-ventricular or in the arterial orifices, and they have four distinct solutions.

*a.* If it has its origin at the mitral orifice, it is a *mitral regurgitant murmur*, and is produced by regurgitation of the blood backward from the left ventricle into the left auricle. Its maximum of intensity in front will correspond to the circle A, Fig. 13, and it will be heard behind.

*b.* If its origin is at the tricuspid orifice, it is a *tricuspid regurgitant murmur*, and is produced by regurgitation of the blood backward from the right ventricle into the right auricle. Its maximum of intensity will correspond to the triangle C, Fig. 13.

*c.* If its origin is at the aortic orifice, it is an *aortic obstructive murmur*, and is produced by obstruction to the current of blood as it passes from the left ventricle into the aorta. Its maximum of intensity will correspond to the irregular space B, Fig. 13.

*d.* If its origin is at the pulmonic orifice, it is a *pulmonic obstructive murmur*, and is produced by obstruction to the current of blood as it passes from the right ventricle into the pulmonary artery. Its maximum of intensity will correspond to the circle D, Fig. 13.

*Again*, murmurs accompanying or following the second sound of the heart may be produced at the aortic or pulmonic orifice, and in either case coincide with the dilatation of the ventricles.

*a.* If the murmur has its origin at the aortic orifice, it is an *aortic regurgitant murmur*, and is produced by the regurgitation of the blood from the aorta *backward* into the left ventricle. Its maximum of intensity corresponds to the space B, Fig. 13.

*b.* If a murmur following the second sound has its origin at the pulmonic orifice, it is a *pulmonic regurgitant murmur*, and is produced by the regurgitation of blood from the pulmonary artery into the right ventricle.

Its maximum of intensity corresponds to the space D, Fig. 13.

One, two, three, and even four of the murmurs we have been considering, may occur in combination in the same case. The most frequent combinations are the aortic obstructive and regurgitant, heard over the area B, Fig. 13; next, the mitral obstructive and regurgitant, heard over the area A; then we have various combinations of these, the aortic and mitral valves being both diseased.

Murmurs occurring on the right side of the heart are comparatively of rare occurrence. The tricuspid regurgitant is the only one that is of practical importance.

*Anæmic and Functional Murmurs* are soft and blowing in character, are always systolic, and almost always aortic. As regards their area, they are generally diffused, not only over the base of the heart, but along the course of the aorta and the vessels of the neck.

An anæmic is distinguished from an organic murmur by its blowing character, by always accompanying the first sound of the heart, by being audible in several of the arteries at the same time, by not being constantly present, occasionally disappearing when the circulation is tranquil and returning when it is accelerated, by the presence of the general signs of anæmia, by the absence of the physical or general signs of organic disease of the heart, by entirely disappearing under treatment for relief of the anæmic state of the system.

*Venous Murmurs* all come under the class of inorganic murmurs. The so-called venous hum is a continuous humming sound, having frequently a musical intonation. It is best heard over the jugular just above the clavicles, with the patient in a sitting or standing position. It is

characteristic of anæmia, and is almost always associated with an arterial anæmic murmur.

Before leaving the subject of cardiac murmurs, I will give you some rules in relation to them, copied from the unpublished writings of the late Dr. Cammann; they are the result of long and careful observation, and, although they differ in some respects from the teachings of many auscultators, I have found them of great service in diagnosis.

### *Cardiac Murmurs.*

#### AORTIC OBSTRUCTIVE : SYSTOLIC.

“When it reaches the apex it is with diminished intensity.

“When heard behind, it is most distinct at left of third and fourth vertebræ, close to their spines, and frequently extends downward along the spine in the course of the aorta, but with diminished intensity. Although the heart only extends as high as the fifth vertebra, the murmur is heard above that point, because here the aorta approaches the surface.

#### AORTIC REGURGITANT : DIASTOLIC.

“The intensity of the murmur from valve to *right* of apex may or may not increase downward, depending on the proximity of heart to parietes, the position of lungs, etc.; it may decrease downward, however, from emphysema, supine recumbency, etc., or may perchance be loudest at apex, depending on proximity of heart to the parietes, position of the parts, condition of the mitral valve, etc.

“Generally it is not heard behind, but *may*, toward inner side of lower angle of scapula, in thin subjects

especially, be heard in the same place where is heard the non-mitral regurgitant; this non-mitral regurgitant being the mitral regurgitant of Bellingham and others.

“It is sometimes conveyed to left axilla.

“The patient when recumbent may sometimes hear it himself.

#### MITRAL REGURGITANT : SYSTOLIC.

“To indicate regurgitation, the murmur must be heard between lower border of fifth and upper border of eighth vertebra, at left of spine, provided the transmission of the sound be not interfered with by thickness of integuments, or other conditions of the parts.

“When not heard in this place, but in ‘left axilla and in the region of the left scapula,’ regurgitation is not indicated; or, in other words, it is a non-regurgitant murmur, contrary to the teaching of Bellingham and others.

“If there be a systolic murmur with a maximum of intensity between fifth and eighth vertebræ, at left of spine, it indicates regurgitation.

“An aneurismal murmur, however, may be heard within the said limits, but it follows the aorta downward, gradually decreasing in intensity, without the *abrupt* termination of the regurgitant murmur.

“We occasionally meet with mitral regurgitant murmur posteriorly, yet absent anteriorly.

“The mitral regurgitant murmur may sometimes cease entirely, from such a change in the structural condition of the diseased valve, or from such contraction of the auriculo-ventricular opening, as will allow the valve to close so as to prevent regurgitation, there being actually in this case increased mechanical obstruction.

“The following complication may exist, viz., aortic



obstructive systolic, with aortic regurgitant diastolic extending *to* the apex, with the mitral regurgitant behind, without a corresponding murmur in front.

“All these murmurs are not infrequently heard to right of apex, and even over the whole chest.

“A mitral diastolic murmur we have not heard. If ever present, as stated by distinguished auscultators, it must depend upon physical condition external to the heart. Thus, pleuritic effusions or the like, in certain positions, by pressing suddenly and strongly upon the left auricle, may possibly force the blood with sufficient rapidity through an obstructed auriculo-ventricular orifice to cause an abnormal sound.

“Some auscultators, however, deny the possibility of the occurrence of this murmur under any contingency whatever.”

#### *Ventricular Murmurs.*

Not infrequently during the active progress of endocarditis, as well as after the acute stage is passed, a murmur is heard taking the place of, or following, the first sound of the heart. These murmurs are not conveyed to the left of the apex, nor heard along the course of the aorta. They are undoubtedly produced within the cavity of the left ventricle, either by the roughening of the chordæ tendineæ or the ventricular surface of the mitral valves, or perhaps by an abnormal direction to the current of blood as it passes through the ventricle. They may properly be called *ventricular murmurs*, and may be distinguished from other murmurs by the time of their occurrence and by their limited area of diffusion.

*Sounds produced by the Action of the Heart which  
are neither Endocardial nor Pericardial.*

Sounds sometimes are heard in the precordial region,

produced by the action of the heart on the lungs. These sounds are mostly systolic and inspiratory: they usually cease when the respiratory movements are arrested. A *blowing sound* resembling a cardiac murmur may be produced in the lung tissue covering the heart, during a cardiac systole. A pulmonary cavity near enough to the heart to be influenced by it sometimes affords a loud systolic murmur. Sounds resembling rales may be produced by the movements of the heart upon the bronchial tubes. Friction sounds generated in the pleura, of a crackling, rasping character, synchronous with the cardiac systole, are not infrequently heard. A friction sound heard behind and along the edge of the sternum from the second to the sixth rib is always pericardial; but when a friction sound is heard at other parts of the precordia, the diagnosis is often difficult. Pleuritic friction sound usually ceases when the breath is held, but this is not always the case.

## LESSON XII.

### SYNOPSIS OF THE PHYSICAL SIGNS OF PERICARDITIS— HYPERTROPHY, DILATATION, AND FATTY DEGENE- RATION OF HEART, AND ANEURISMS OF THORACIC AORTA.

#### *Synopsis of the Physical Signs of Pericarditis.*

THE physical signs of pericarditis vary with the different stages of the disease. In the early period of the attack, the only sign furnished by inspection and palpation is an irritable and forcible action of the heart, and there is no change in the area of the precordial dulness on percussion. For some time the only characteristic sign of its presence is the pericardial friction sound. After a time, as the inflammation progresses, effusions take place into the pericardial sac, and we have the second stage, or stage of effusion.

*Inspection* now discloses a prominence, or arching forward, of the precordial region, and a diminution in the respiratory movements of the left side.

*Palpation* shows the point of the apex beat to be raised and carried to the left of its normal position; or, if the quantity of the effusion be large, it is entirely suppressed. Sometimes, in extensive pericardial effusions, an undulatory impulse is felt. The position of the impulse will often be noticed to change with a change in the position of the patient. If the cardiac impulse is entirely absent when the patient is in the

recumbent posture, and becomes perceptible when he is placed in a sitting posture, you have strong presumptive evidence in favor of pericardial effusion. Sometimes when the pericardium is very greatly distended, the diaphragm is depressed, and bulging can be detected in the epigastrium.

*Percussion.*—The area of the precordial dulness is enlarged vertically and laterally. At the beginning, the

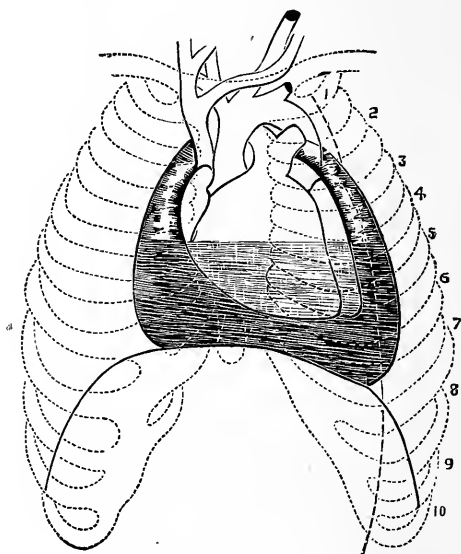


FIG. 14.—Diagram showing the Pericardial Sac partially filled with Liquid, and Plastic Exudation upon the two Surfaces of the Pericardium above the level of the Liquid.

dulness is principally increased upward, but any considerable amount of effusion is denoted by an increase in the width of the area of dulness at the lower portion of the precordial region. As the effusion increases, the shape of the enlarged area corresponds to the pyramidal form of the pericardial sac, as is represented in Fig. 14.

When the pericardial sac is distended with liquid, the dulness will reach as high as the first rib: not infre-

quently it reaches an inch or more to the right of the sternum, and occasionally it extends from nipple to nipple.

*Auscultation.*—The friction sound of the plastic stage becomes more and more indistinct until it ceases altogether. The heart sounds become feeble or are entirely lost, and the respiratory murmur and the vocal resonance are absent over the area of precordial dulness.

When recovery takes place and the liquid effusion is absorbed, the bulging of the precordial region, which was present in the stage of effusion, subsides, and the area of dulness on percussion decreases, the friction sound reappears, the heart sounds become distinct, the apex beat resumes its normal position, the impulse regains its natural force, and the respiratory and vocal sounds are again heard over the space formerly occupied by the distended pericardium.

Adhesion of the heart to the pericardium does not admit of diagnosis, unless firm adhesions have formed between the external surface of the pericardium and the adjacent tissues, which afterward cause dilatation and hypertrophy of the heart, accompanied by recession of the apex beat, retraction of the epigastrium, and diminished motion of the pericardial portion of the diaphragm during a full inspiration.

#### *Synopsis of the Physical Signs of Cardiac Hypertrophy.*

The physical signs of hypertrophy of the heart vary with the seat and extent of the hypertrophy. When the hypertrophy is general, *inspection* shows the action of the heart to be regular, and the visible impulse to be increased in extent and in force. In children there is a visible prominence of the precordial region.

*Palpation.*—The area greatly exceeds that within which the normal apex beat is felt, and the impulse has a heaving, lifting character. When the right ventricle is hypertrophied, the conducted epigastric impulse is strong. When the left ventricle is hypertrophied, the apex beat reaches further to the left than natural, sometimes three inches below and three or four inches to the left of the normal position.

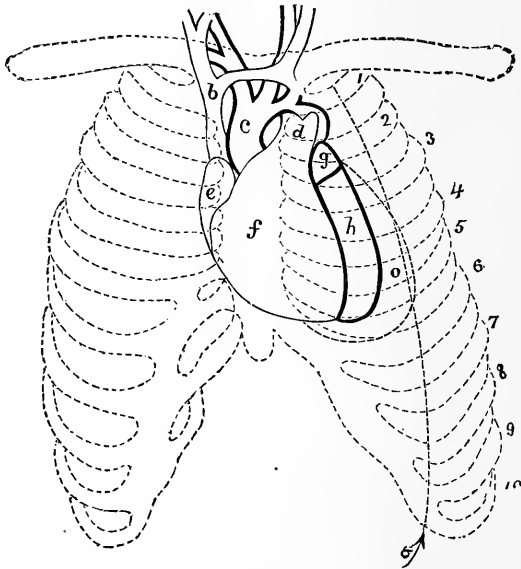


FIG. 15.—Hypertrophy of Left Ventricle. Heart *in situ*. *a*, the Mammery Line. *b*, Vena Cava Superior. *c*, Aorta. *d*, Pulmonary Artery. *e*, Right Auricle. *f*, Right Ventricle. *g*, Left Auricle. *h*, Left Ventricle (normal outline). *o*, Hypertrophied Ventricle.—RINDFLEISCH.

*Percussion.*—The area of both the superficial and deep-seated dulness increases laterally and downward. If the hypertrophy is confined to the left ventricle, the area of dulness on percussion may extend beyond the left nipple, as is shown in Fig. 15.

If, on the other hand, the hypertrophy is confined to the right ventricle, the area of dulness may extend

considerably to the right of the sternum, as is shown in Fig. 16.

*Auscultation.*—The first sound is dull, muffled, and prolonged, and in some cases greatly increased in intensity. The second sound is also increased in intensity and more diffused than in health, and there is a diminution or an entire absence of the respiratory murmur over the normal precordial region.

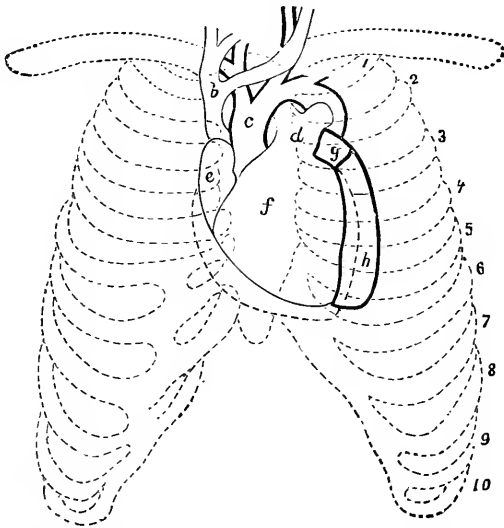


FIG. 16.—Hypertrophy of Right Ventricle. Heart *in situ*. Description as in the preceding figure. The contour of the Hypertrophied Right Ventricle is indicated by dots.—RINDFLEISCH.

When hypertrophy of the walls of the heart is attended with extensive dilatation of its cavities, the action of the heart is still regular, but the extent of the visible impulse is greatly increased, extending sometimes from the third intercostal space to the epigastrium. The apex beat may be felt as low as the ninth rib, and to the left of the nipple, and has a peculiar heaving character, so as sometimes to shake the bed of the patient.

The area of dulness may extend vertically from the third to the eighth rib, and, laterally, an inch to the right of the sternum and two or three inches to the left of the left nipple. Both sounds of the heart are prolonged, and are often audible over the whole chest, even to the right of the spine.

### *Dilatation of the Heart.*

*Inspection.*—The visible area of the apex beat is greatly increased, but it is difficult to determine its point of maximum intensity. Sometimes there is an undulating motion over the whole precordial space.

*Palpation.*—By palpation you readily distinguish *dilatation* from *hypertrophy* by the feebleness of the cardiac impulse; and although it sometimes can be felt as far to the left as the axillary line, there is an entire absence of the lifting, forcible impulse which attends cardiac hypertrophy. Sometimes a purring thrill attends cardiac dilatation, especially when mitral regurgitation is present.

*Percussion* shows a lateral increase in the area of precordial dulness; to the right when the right cavities are involved, and to the left when the left cavities are dilated. The shape of the dull space remains oval. This point is of importance in the diagnosis between cardiac dilatation and pericardial effusion.

*Auscultation.*—The sounds of a dilated heart are always short, abrupt, and feeble. The second sound is often inaudible at the apex, and the two sounds seem to be of equal duration. If endocardial murmurs have been present, as the dilatation becomes extreme, nothing is heard but a kind of swimming sound. The respiratory murmur is often feeble over the whole of the upper portion of the left lung.



*Asystolism.*

Asystolism is a term "employed to designate that remarkable group of symptoms which is characteristic of an enduring inability in the right ventricle to empty itself."<sup>1</sup> The physical signs are those of dilatation of the right side of the heart. A short time before death additional signs occur, viz. : On palpation the cardiac impulse is feeble; on auscultation the heart sounds, or any endocardial murmurs which may have been present, become gradually more and more feeble, until nothing is heard except a humming sound. A tricuspid regurgitant murmur frequently develops when asystolism becomes urgent, but before the heart is so weakened that it is not able to produce a murmur. If the symptoms of asystolism are moderate, the murmur disappears.

*Fatty Heart.*

The physical signs of fatty degeneration of the heart in many respects are identical with those of cardiac dilatation. The area of the precordial dulness is normal, the impulse weak or imperceptible, the apex beat indistinct and often invisible. The action of the heart is irregular, the first sound is short and feeble and sometimes inaudible, the second sound prolonged and intensified.

*Fibroid Heart.*

The physical signs of cardiac fibrosis are feeble, rapid, irregular, intermittent heart action; a diffused, feeble cardiac impulse; weak but sharp heart sounds. The first sound is like the second in tone and duration. They closely resemble the foetal heart sounds. On per-

---

<sup>1</sup> Beau, "Considérations générales sur les Maladies du Cœur," Arch. Gén. de Med., 1853.

cussion we find the area of dulness increased, chiefly to the left. The diagnosis of a fibroid heart cannot be made by the physical signs alone ; we must take them in connection with the symptoms and condition of the arterial system. By the physical signs we determine that the heart is chronically weak. If, then, we find evidence of a weak heart in one who has a strong fibroid history, and who gives signs of a general arterial fibrosis, the diagnosis is readily made.

## LESSON XIII.

### ANEURISM OF THE THORACIC AORTA AND ARTERIA INNOMINATA—EPIGASTRIC PULSATION— SUB-CLAVIAN MURMURS—VENOUS PULSATIONS AND MURMURS.

ANEURISMS OF THE THORACIC AORTA.—The thoracic aorta is affected by aneurism with varying degrees of frequency in the different parts of its course. According to Sibson, who has collected the statistics of 703 cases, 87 were at the commencement of the aorta in the sinuses of Valsalva; 193 of the ascending arch, extra-pericardial; 14 of the ascending and transverse arch; 12 of the transverse arch; 72 of the descending arch; and 71 of the descending aorta

The physical methods employed in ascertaining the existence of aneurisms are *inspection*, *palpation*, *percussion*, and *auscultation*.

*Inspection*.—If the aneurism presses on the superior vena cava, you will find the face, neck, and upper extremities swollen, livid, and occasionally œdematous, and the large veins of these regions turgid and varicose. But if the pressure is on an innominate vein, these effects will be observed only on the corresponding side.

In some instances there is a thick, fleshy collar surrounding the lower part of the neck, due to capillary turgescence. As you inspect the chest, a more or less

extensive bulging may be observed at some point along the course of the aorta. The bulging may in some cases attain the size of a cocoanut, while in others it may be perceptible only on close examination. The non-existence of a tumor does not, however, prove that there is no aneurism, for if the aneurismal enlargement springs from the posterior wall of the arch, or from the descending arch or descending aorta, parts which are deeply seated, there may be no visible anterior bulging.

When the bulging portion is of large size, it is generally conical in shape, the surface is smooth, and the skin looks tense and glazed. In most cases you will observe a pulsation of the tumor synchronous with the heart's systole; where this occurs in the anterior portion of the chest, there seem to be two beats within the thorax at the same time. Sometimes you can only detect the pulsation by bringing the eye to a level with, and looking across, the chest. If the aneurism is full of fibrin, there may be no visible pulsation.

The *position* of the bulging affords a clue to the seat of the aneurism. *Aneurism* of the *ascending* arch produces bulging to the right of the sternum, near the second costal cartilage; though when large it may extend into both mammary and infra-clavicular regions. Aneurism of the transverse arch causes protrusion of the upper part of the sternum. Aneurism of the descending arch protrudes to the left side of the sternum, though often, from the deep position of the artery in this part of its course, no tumor may be felt. Aneurism of the descending aorta shows itself on the left side of the spine, very rarely on the right.

*Palpation*.—By the application of the hand you can appreciate better the size of the tumor, the nature of its contents (whether mostly liquid or solid), the condition

of the walls as regards perforation of the sternum or ribs, and the character of the pulsation, which is usually that of a blow equally diffused in all directions. Besides the systolic impulse, a diastolic one sometimes occurs; generally it is slight, sometimes, however, it is quite forcible. In some cases you will obtain the impulse by pressing with one hand on the sternum, and the other on the back, when by ordinary palpation you would not detect it. Again, if the aneurism is at the upper portion of the arch, by pressing the fingers down behind the sternum a distinct impulse will be felt. You may also ascertain by palpation whether there is a cessation or diminution of the expansive movement over the whole or part of one lung, and whether the vocal fremitus is lost over that side and over the tumor.

The non-expansion and loss of vocal fremitus over the lung is due generally to the pressure of the aneurism on the air passages, or on the lung itself. When the aneurism presses on the carotid arteries, or when they are obstructed by coagula, a difference between the pulse of these arteries and their branches on the two sides will be noticed.

*Percussion.*—There will be dulness over the prominence, or over a circumscribed space, in the neighborhood of the course of the aorta, not, however, corresponding to the size of the aneurism, unless more forcible percussion be made than is safe. The resistance is increased in proportion to the amount of the fibrin in the sac. When the lung is condensed by inflammation, or collapsed by obstruction of the bronchus, there will be a greater area of dulness.

*Auscultation.*—There are usually certain sounds or murmurs connected with an aneurism. In some cases neither are audible, owing either to the position of the

aneurism, to the solidity of its contents, or to the nature of its orifice. These sounds resemble those of the heart, and are similarly called systolic and diastolic; they may be either equal to, or weaker, or louder than, those of the heart; the systolic may exist alone; either or both sounds may be replaced by a murmur—for instance, there may be a systolic murmur only, or you may have both a systolic and a diastolic sound. The character of the murmur varies. It is usually short, abrupt, of low pitch, and as loud or louder than the loudest heart murmur. It may be rasping, sawing, filing, etc. The diastolic murmur is rarer than the systolic, and is usually of a softer quality. Where the aneurism compresses a large bronchus, the respiratory murmur over the whole or a part of one side will be weak or suppressed; on the opposite side it will be exaggerated. There is also loss of vocal resonance over the aneurism, and over the lung whose bronchus is obstructed. Where the lung is condensed from pressure, the breathing will be bronchial; where there is pressure over the trachea or bronchi, the breathing may be stridulous, and be rightly referred to a lower point of production than the larynx. Where there is irritation of the recurrent laryngeal nerve, this type of breathing may come from spasm of the glottis.

*Differential Diagnosis.*—You will find that the principal difficulties in diagnosis are between aneurisms and intra-thoracic tumors.

The latter are rare. They rarely pulsate, or, if they should, they will communicate to the hand a mere lifting pulsation; in some instances malignant tumors have, however, a true expansive impulse. Again, intra-thoracic tumors are not usually developed entirely in the track of the aorta. Their area of dulness is large,

and the resistance communicated to the finger on percussion is usually great. As a rule, there are no sounds or murmurs connected with them, though in some cases where a tumor is placed over the aorta a murmur may occur. Tumors are more apt to produce persistent swelling and œdema of the upper extremities, neck, and face. In a case of aneurism, this latter sign may develop, and then disappear owing to a change in the direction of the pressure. Tubercular consolidation of one apex, if associated with a murmur in the sub-clavian or pulmonary artery, might be mistaken for an aneurism. In the former we have the physical signs of tuberculosis. The murmur is heard in the course of the pulmonary or sub-clavian artery. The dulness is not circumscribed, and extends outward, and not across the median line.

PULSATILE EMPYEMA, it seems to me, could hardly be mistaken for aneurism, although such instances are on record, for it does not occupy the position of an aneurism. Then you have the physical signs of effusion into the pleural sac, and it is attended by no sounds or murmurs.

ANEURISM OF THE ARTERIA INNOMINATA is distinguished from aneurism of the thoracic aorta by the fact that the tumor appears early on the right of the sternum. As it increases, it pushes forward the inner part of the clavicle, or extends upward into the neck. Its pulsation is diminished or suspended by pressure on the carotid or sub-clavian artery, while an aneurism of the aorta will not be affected by such pressure.

EPIGASTRIC PULSATION may be produced by an aneurism of the abdominal aorta involving the cœliac axis, by tumors seated on the abdominal aorta, by displacement of the heart to the right, by regurgitation of blood

into the hepatic veins consequent upon dilatation of the right side of the heart, and by pulsation of the abdominal aorta.

Not infrequently the impulse of the apex beat, the heart being normal and in its normal position, is communicated to the epigastrium, and is mistaken for epigastric pulsation of a dilated heart.

The right ventricle, in such cases, will usually be found lower than its normal position, and may even beat against the xiphoid cartilage.

SUB-CLAVIAN MURMURS.—Not infrequently just below the clavicles, especially on the left side, a systolic murmur is heard directly over or along the course of the sub-clavian artery. These murmurs resemble those produced by pressure on arteries. It is reasonable, therefore, to infer that they are produced in the same way—the exact anatomical condition, however, which causes them is still unsettled. Adhesions at the apex of the lung have been suggested, also pressure from pulmonary consolidation at the apex. One thing is certain, that they are more frequently met with in those persons who are tubercular than in others. They are often most intense during expiration.

I have known the presence of a sub-clavian murmur to be taken as an evidence of aneurism.

VEINS.—A state of permanent turgescence or distention of the jugular veins, as well as of the superficial veins of the upper part of the chest and neck, with or without pulsation, is frequently met with in the advanced stage of many forms of cardiac disease, in thoracic aneurism, and in any change in the thoracic organs which causes obstruction to the free passage of blood through the right side of the heart.

*Permanent turgescence* of the jugular veins is usually



due to the distention of the right auricle ; any obstruction, however, to the superior vena cava or innominata, such as compression, thrombosis, or stricture, will have the same effect. If the turgescence is temporary, a full inspiration will empty and collapse the distended veins, while a full expiration will increase their distention. On the other hand, if the turgescence is permanent, the condition of the veins is not affected by the respiratory acts.

VENOUS PULSATIIONS may be *presystolic* or *systolic*. They are most marked in the jugular veins immediately above the clavicles.

*Presystolic jugular pulsations* are due to the contractions of the right auricle, but they can seldom be appreciated except when the intra-thoracic veins are distended. Sometimes in a perfectly healthy person, when in a recumbent position, presystolic pulsation in the jugular veins can be seen.

*Systolic jugular pulsation* occurs with the systole of the ventricles and indicates regurgitation into the right auricle with the ventricular systole. Friedreich states that sudden collapse of the jugular veins occurs in some cases of pericardial adhesions. Pulsations in the carotid arteries often communicate systolic pulsations to the jugulars.

VENOUS MURMURS.—In auscultating the veins of the neck, besides the venous hum already referred to in Lesson XII., *presystolic*, *systolic*, and *diastolic* murmurs are sometimes heard over the jugulars.


*Presystolic venous* murmurs are only heard when the patient is in the recumbent posture, and are due to the passage of blood backward through the mouth of the internal jugular.

*Systolic venous* murmurs are sometimes heard just

above the clavicles, especially on the right side, in cases of tricuspid regurgitation.

*Diastolic venous* murmurs are only occasionally heard, and require for their production cardiac hypertrophy and dilatation with aneurism.

ABDOMEN.



## LESSON XIV.

INTRODUCTION—TOPOGRAPHY OF THE ABDOMEN—CONTENTS OF THE VARIOUS REGIONS—ABDOMINAL INSPECTION, PALPATION, PERCUSSION, AND AUSCULTATION—DISEASED CONDITIONS OF THE PERITONEUM.

THERE are *difficulties* in the physical exploration of the abdomen which are not met with in similar examinations of the thorax.

*First.* Thoracic diseases involve in their diagnosis the examination of only one or two organs, or their coverings, while an abdominal affection may require for its diagnosis the examination of ten or twelve organs. Thus a tumor in the left side may be either an enlarged mesenteric gland, or it may be connected with the stomach, spleen, kidneys, ovaries, or uterus; or it may be a hernia, an abscess, an hydatid cyst, an aneurism, or, lastly, only a lump of fæces.

*Second.* The action of the thoracic organs is regular and rhythmical, and their contents unvarying, while the action of the abdominal viscera is often irregular and intermittent. An abdominal organ may also at one time be greatly distended and soon after be empty; when filled, its contents may be solid, liquid, or gaseous, or all these together. The lungs and heart contain respectively the same quantities of air and blood during every five minutes of ordinary life, but the stomach and bladder can never remain long in one condition, either full or empty.

*Third.* The abdominal organs are packed loosely in a cavity with loose walls. They therefore can be increased or decreased in size, so as to alter wholly their relations to their fellow-organs. Thus the uterus, usually the smallest, will, in fulfilling its natural function, become much the largest of all, crowding even the thoracic organs. In disease, a single ovary may swell into a sac which will fill entirely the abdominal cavity. These constitute the chief difficulties in the physical examination of the abdomen, and they must always throw a certain degree of doubt upon all physical diagnoses directed to this part of the body.

To facilitate our examinations, and to render our inferences more certain, it is well to divide the abdomen into regions by passing imaginary planes through the body.

The divisions which have been proposed by different observers vary somewhat. The following, proposed by Dr. Bright, will, I think, be found most useful :

The abdomen may be divided into three general zones—the epigastric, the umbilical, and the hypogastric.

The **EPIGASTRIC** zone is bounded above by the diaphragm, and below by a horizontal plane passing through the anterior extremities of the tenth rib on either side; carried backward, this plane will pass between the bodies of the first and second lumbar vertebræ. In a well-formed chest the cartilage of the tenth rib on either side offers a projection at its lower convex border, which can be felt without difficulty. This zone is subdivided into the *epigastric* and the *right* and *left hypochondriac regions*, which correspond to the spaces bounded by the false ribs.

The **UMBILICAL** zone is bounded above by the lower boundary of the epigastric, and below by a horizontal

plane passing through the anterior and superior spinous processes of the ilia; this plane, if carried backward, will pass between the second and third sacral spines.

The HYPOGASTRIC zone is bounded above by the lower boundary of the umbilical zone, below, in the centre, by the upper margin of the pubes, on either side by Poupart's ligament. This zone occupies the whole cavity

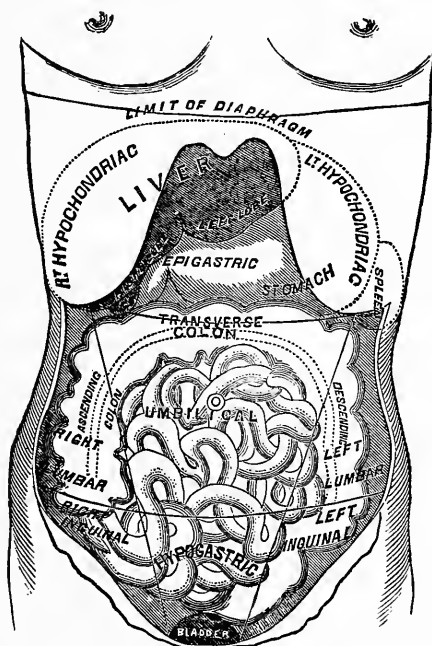


FIG. 17.—Diagram showing the different Regions of the Abdomen, and the Organs contained in each, which are visible on the removal of the Abdominal Walls.

of the true pelvis. The umbilical and hypogastric zones have each three subdivisions, made by two vertical planes passing backward through the spinous processes of the pubes and the points on the tenth ribs already alluded to. The subdivisions of the umbilical zone thus produced are termed the central or *umbilical*, and two lateral, or the *right* and *left lumbar*. The subdivisions

of the hypogastric thus produced consist of the middle or *pubic*, and the lateral or *right* and *left iliac*.

The organs contained in these regions in health are as follows :

The EPIGASTRIC region contains the whole of the left and a part of the right lobe of the liver, the gall bladder, the pyloric orifice of the stomach, the commencement of the duodenum, a portion of the colon, the pancreas, the abdominal aorta, and the cœliac axis. It is very necessary to understand the relative positions of these organs.

The RIGHT HYPOCHONDRIAC region contains nearly the whole of the right lobe of the liver, the angle of the ascending and a portion of the transverse colon, the greater part of the duodenum, the renal capsule, and the upper portion of the right kidney.

The LEFT HYPOCHONDRIAC region contains the rounded cardiac portion of the stomach, at all times, and a very large portion of the organ when distended, the left angle of the colon, the spleen, and a small portion of the left kidney with its renal capsule.

The UMBILICAL region is chiefly occupied by a portion of the transverse colon, the omentum, and the small intestines. It contains, likewise, the mesentery and its glands, the aorta, and the inferior vena cava.

The RIGHT LUMBAR region contains the cæcum, the ascending colon, the lower and middle portions of the kidney, and a portion of the ureter.

The LEFT LUMBAR region is occupied by the descending colon, the left kidney, and the ureter. A portion of the small intestine also occupies the lumbar region on each side.

The PUBIC or HYPOGASTRIC region, in children, contains the urinary bladder, with portions of the ureters (if they be distended, also in adults), the convolutions of



the small intestine, and, in the female, the uterus and its appendages.

The RIGHT ILLIAC region contains the "cul-de-sac" of the caput coli, the vermiform process, and the iliac vessels.

The LEFT ILLIAC region contains the sigmoid flexure of the colon and the iliac vessels of that side.

#### *Methods Employed in the Physical Examinations of the Abdomen.*

They are the same, with the exception of succussion, as those practised in exploration of the thorax, but they differ in their relative importance. In thoracic examinations, auscultation is the most important method, while in abdominal examinations auscultation is only employed in determining the existence of aneurisms and of pregnancy. Percussion and palpation are the means by which we gain the most useful information concerning the contents of the abdominal cavity.

Before considering the signs which indicate the changes occurring in the different affections of the abdominal organs, I will briefly notice the different methods of exploration.

INSPECTION.—By it we note alterations in the shape and movements of the abdomen. It is most satisfactorily performed with the patient lying on the back and the thighs slightly flexed. In health, the abdomen is of an oval form, marked by elevations and depressions corresponding to the abdominal muscles, the umbilicus, and in some degree by the form of the subjacent viscera; it is larger, relatively to the size of the chest, in children than in adults; more rotund, and broader inferiorly, in females than in males.

Alterations in its shape due to disease are, *first, en-*

*largement*, which may be general and symmetrical, as in ascites; or partial and irregular, from tumors, hypertrophy of organs, as the liver and spleen, or from tympanitic distention of portions of the intestines by gas, as of the colon in typhoid fever; *second, retraction*, as in extreme emaciation, and in several forms of cerebral disease; especially is this noticeable in the tubercular meningitis of children.

The respiratory movements of the abdominal walls bear a certain relation to the movements of the thorax. They are often increased when the latter are arrested, and *vice versa*. Thus, abdominal movements are increased in pleurisy, pneumonia, pericarditis, etc.; but decreased, or wholly suspended, when disease causes abdominal pain, or in peritonitis.

Not infrequently, when inspecting the abdomen, a distinct pulsation will be visible in the epigastric region, which frequently is mistaken for aneurism. The superficial abdominal veins are also at times visibly enlarged, indicating an obstruction to the current of blood either in the portal system, as in cirrhosis, or in the inferior vena cava.

MENSURATION is mainly useful in determining the exact increase or decrease of abdominal dropsies, visceral enlargements, and tumors. It is performed by means of a graduated tape.

PALPATION.—This method of exploration often furnishes important information. It may be performed with the tips of the fingers, with the whole hand, or with both hands, and the pressure may be slight or forcible, continuous or intermitting. In order to obtain the greatest amount of information by palpation, the patient should be placed in a horizontal position, with the head slightly raised and the thighs flexed; some-

times it is necessary to place him in a standing position or leaning forward.

*Indications furnished by Palpation.*—By it we can determine the size and position of the viscera, the existence of tumors and swellings, whether they are superficial or deep, large or small, hard or soft, smooth or nodulated, movable or fixed, solid or liquid, and whether or not they possess a motion of their own. We can also ascertain if tenderness exist in any portion of the abdominal cavity, and if pain is increased or relieved by firm pressure.

**PERCUSSION.**—In the performance of abdominal percussion, the patient should be placed in the same position as for palpation, and the percussion should be for the most part mediate. In exploring the abdomen by means of percussion, the pleximeter (the finger being the best) should first be placed immediately below the xiphoid cartilage, pressed firmly down and carried along the median line toward the pubes, striking it all the way, now forcibly, now gently. The different tones which the stomach, colon, and small intestine furnish will be distinctly heard. The percussion should then be made laterally, alternately to one side and then to the other, until the whole surface is percussed (Bennet). In this manner the different percussion sounds of the stomach, large intestine, small intestine, and the solid viscera will be readily distinguished. Thus, the percussion sound elicited over a healthy abdomen may be *dull*, *flat*, or *tympanitic*. Over the central portion of the liver, spleen, and kidneys the percussion sound is flat; over that portion of either of these organs where they overlap the intestines or stomach it is dull, with a tympanitic quality. Over the stomach and intestines it is tympanitic, more so over the former than the latter. When

liquid occupies the abdominal cavity, over the liquid the percussion sound will be flat. A distended bladder or uterus, an enlarged liver, spleen, kidney, or mesenteric gland, ovarian, aneurismal, and other tumors, are recognized and their limits determined by the unnatural and increased area of the percussion flatness; while, on the other hand, gaseous distention of the stomach or intestines is recognized by the increased area of tympanitic percussion.

AUSCULTATION.—For the physical exploration of the abdomen, auscultation is only of service, as we have said before, in the diagnosis of aneurisms, in detecting the foetal heart sounds and the utero-placental murmur in the pregnant state.

Our examinations of the *abdominal viscera* are sometimes interfered with and rendered uncertain by changes that occur in the abdominal walls. Generally the abdominal walls are sufficiently thin, soft, and movable for us to determine with considerable accuracy the situation and condition of the contained organs; if, however, everything is masked by layer upon layer of fat, as in some cases of obesity, abdominal examinations will be unsatisfactory. An *œdematous condition* of the abdominal walls, as in Bright's disease, may also prevent us from ascertaining the condition of the viscera. When this occurs, the surface of the abdomen presents a smooth, even, shiny, waxy appearance, and pits on firm pressure. *Superficial abscess* of the abdominal walls also occurs occasionally, and interferes greatly with the exploration of the abdominal cavity. You can recognize this by the circumscribed bulging, by tenderness on slight pressure, by the redness of the surface, and by the characteristic fluctuation of a superficial abscess.

The abdominal muscles are sometimes abnormally de-

veloped, or unnaturally rigid as in tetanus, rheumatic inflammation, and in the early stage of peritonitis, and this somewhat interferes with our examinations.

*Diseased Conditions of the Peritoneum.*

Under this head may be included the various results of inflammatory action, ascites, etc. They all give rise to more or less abdominal enlargement.

ACUTE PERITONITIS.—By *inspection* we recognize in acute peritonitis either a diminution or an entire suspension of abdominal respiration, the breathing becoming entirely thoracic. The abdomen enlarges, becomes unnaturally tympanitic, and there is marked tenderness on firm pressure. The comparative results of *firm* and *slight* pressure is one of the strong diagnostic marks of peritoneal inflammation.

CHRONIC PERITONITIS is almost always connected with tubercular or cancerous deposits in the substance and over the free surface of the peritoneum ; and in addition to the tympanitic distention of the abdomen, and the tenderness on firm pressure, noticed in acute peritonitis, liquid accumulations take place in the peritoneal cavity.

ASCITES.—A collection of liquid from any cause in the peritoneal cavity is termed ascites.

*Inspection.*—The abdomen is always *uniformly* enlarged, and the movements of the abdomen in respiration are either suspended or limited to the epigastric region. The superficial abdominal veins, if the ascites depend upon disease of the liver, will often be found enlarged.

*Palpation.*—If the palmar surface of the hand be applied to the side of the abdomen at the level of the liquid, and light percussion be performed on the oppo-

site side, a sense of fluctuation will be communicated to the hand.

*Percussion* gives flatness at the lower and most depending portion of the abdomen, while at the upper portion, above the level of the liquid, there is a drum-like, tympanitic resonance. When the patient is in the erect posture, the tympanitic resonance is confined to the epigastrium and upper portion of the umbilical region. If in a recumbent posture, the tympanitic resonance will extend into the hypogastrium ; if placed on either side, the lumbar region of the opposite side becomes tympanitic.

Other diseases that occur in the peritoneum consist of enlargements, and may be classed under the head of abdominal tumors.

## LESSON XV.

### PHYSICAL SIGNS OF THE ABNORMAL CHANGES IN THE DIFFERENT ABDOMINAL ORGANS—STOMACH— INTESTINES—LIVER—SPLEEN.

#### *Stomach.*

When this viscus is empty, or not distended with gas or food, there is on *inspection* no visible prominence to indicate its position, nor does *palpation* furnish us any information as to its condition.

*Percussion* gives a metallic or tympanitic resonance which enables us to distinguish it from the surrounding viscera. The line of dulness which marks the lower border of the liver and the inner border of the spleen determines the upper and lateral boundaries of the stomach. To ascertain the lower border, percuss gently downward from this line of dulness, until a slight change in the percussion sound indicates that you have reached the transverse colon (see Fig. 17, page 133). Opposite the inner border of the seventh rib, on the left side, the cardiac orifice of the organ is situated. At a point a little below the lower border of the liver, within a line drawn from the right nipple to the umbilicus, the pyloric orifice of the organ is situated. The lower margin of the great "cul-de-sac" is found, generally, near the umbilicus.

Diminution in the size of the stomach cannot be recognized by physical exploration. An increase in size or distention of the stomach may occur from an accumu-

lation of gas, from large quantities of liquids or solids taken into the stomach; or it may be enlarged within circumscribed spaces from cancerous deposit in its walls.

GASEOUS or TYMPANITIC distention of the stomach is recognized by an increase in the area of the characteristic tympanitic resonance of the organ. A *distended* condition of the stomach from food or drink is recognized by an absence of the normal resonance, and by a continuation of the dull percussion of the liver and spleen downward to the umbilicus. A moderate amount of liquid or solid in the stomach can be determined by a limited area of dulness corresponding to the "cul-de-sac" of the organ.

CANCER OF THE STOMACH most frequently has its seat at the pyloric extremity of the organ; but in whatever portion of the organ it may be developed, it can be recognized by circumscribed dulness on percussion, where in health, when the stomach is empty, we should have tympanitic resonance. The percussion dulness elicited over the cancerous mass, however, has a hollow character which is readily distinguished from the flat percussion sound of a solid organ.

By palpation a nodulated mass is readily detected, corresponding to the area of percussion dulness, which is movable, easily grasped, and readily separated from the surrounding viscera. These signs, taken in connection with the attendant symptoms, are almost always sufficient for a positive diagnosis.

#### *Intestines.*

In a normal condition the large intestine furnishes a more amphoric percussion sound than the stomach. When, however, it is filled with liquid or solid accumulations, the situation of these accumulations can be marked out on the surface by the dulness on percussion.



The peculiar feel of such enlargements will generally enable you to decide as to their true character: they feel like no other tumors. On examining them through the abdominal walls, they are felt to be hard and resistant; but if one finger be pressed steadily upon them for one or two minutes, they will at last indent like a hard snowball. There is not the slightest elasticity about them, and the indentation remains after the pressure is removed (Simpson). As these accumulations most frequently collect in the descending colon, the percussion sound over this portion is usually less resonant than over the ascending or transverse colon. According to Dr. Bennet, in a practical point of view it is often useful to determine whether a purgative by the mouth or an enema is likely to open the bowels most rapidly. If there is dulness in the left iliac fossa in the track of the descending colon, that portion of the intestine must be full of fæces, and an enema is indicated. If, on the other hand, the sound in the left iliac fossa is tympanic, and in the right dull, an enema is of little service, as it will not extend to the cæcum, and purgatives by the mouth are indicated. Sometimes the whole colon, or the transverse portion, or, what is more common, the sigmoid flexure of the large intestine, becomes distended with fæcal accumulations, giving rise to circumscribed abdominal enlargement and to flatness on percussion over that portion of the abdomen which corresponds to the situation of the intestines. Care must be taken not to confound this condition with an enlarged liver, spleen, tumors, etc. The percussion sound over the small intestine, unless it is distended with gas, is higher pitched and less amphoric than that of the surrounding large intestine. There are no physical signs to indicate the abnormal changes which occur in this portion of the ali-

mentary canal, except an increase in the tympanitic resonance which exists when it is distended with gas.

### *Liver.*

Our diagnosis in any case of hepatic disease rests mainly on the size, form, and position of the liver as determined by percussion and palpation. The first step, then, in studying the physical signs indicative of disease of this organ, is to become familiar with its normal boundaries. In its healthy state, the right lobe of the liver occupies the right hypochondrium, lying completely in the hollow formed by the diaphragm, rarely descending below the free border of the ribs, or extending upward above the fifth intercostal space; the left lobe reaches across to the left of the median line an inch or more (see Fig. 17, page 133).

The upper boundary of the organ is determined by percussing with moderate force from the right nipple downward until the flatness of the percussion sound indicates that a solid organ has been reached. Indicate this point with an aniline pencil. Then percuss downward from the axilla, and also from a point a little to the right of the median line in front, in the same manner, until a change occurs in the percussion sound. Indicate these points on the chest wall with the pencil. A line drawn through the three points marks the upper boundary of the liver. Generally it will be found to correspond to the base of the ensiform cartilage on the median line in front, to the fifth intercostal space on the line of the right nipple, to the seventh rib in the axillary region, and to the ninth rib in the dorsal region. The lower boundary of the organ is determined by percussing downward from the line of flatness already determined, and noting the points where the tympanitic sounds of the stomach

and large intestine occur. Usually it will be found to correspond, anteriorly, to the free border of the ribs, and to a point three inches below the ensiform cartilage on the median line ; laterally, in the axillary region, to the tenth intercostal space ; and posteriorly, in the dorsal region, to the twelfth rib. The flatness of the left lobe usually reaches two inches to the left of the median line. The whole margin of the liver, except where it comes in contact with the apex of the heart through the medium of the diaphragm, may thus be determined and marked out on the surface. The vertical measurements will be found very nearly as follows : On the right of the median line in front, three inches ; on a line with the right nipple, four inches ; in the axillary region, four and one-half inches ; and in the dorsal region, four inches. The smooth edge of the lower margin of the liver in health, especially in thin subjects, can be distinctly felt behind the free border of the ribs.

The healthy liver in its normal position influences very little the percussion sound over the soft portion of the abdomen. As already stated, the sound is tympanitic from the free borders of the ribs to the pubes when the abdominal organs are normal and empty. If, therefore, the percussion sound is flat, and the flatness is uninterrupted upward to the margin of the ribs on the right side, we have good reason for believing that the liver is the organ diseased.

The gall bladder is found where the lower border of the liver passes under the ribs on the right side, just within the nipple line.

The *normal boundaries* of the liver, already defined, may be greatly altered without any abnormal change occurring in the organ itself. These normal changes, unless remembered, may lead to errors in diagnosis. Thus,

congenital malformations may give rise to an increase in the area of hepatic dulness. An accurate history of the patient, however, will keep us from error in such cases. In the examination of children, also, it should be remembered that the liver is proportionately larger than in adults.

The practice of tight lacing may cause displacement

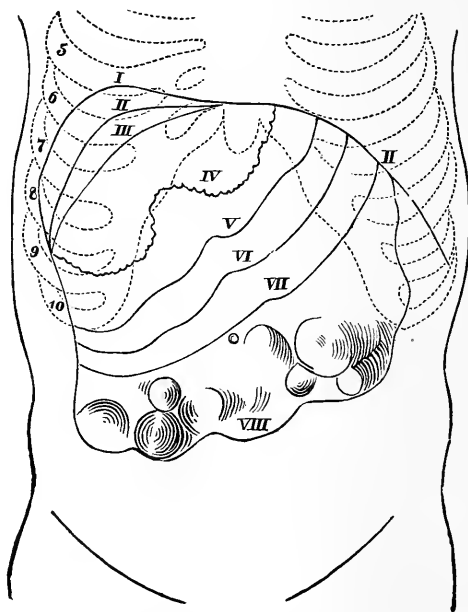


FIG. 18.—The volume of the Liver in Various Diseases. 5-10, Ribs. I, Position of the diaphragm in the highest degree of tumefaction of the liver (carcinoma). II, II, Normal position of the diaphragm. II, III, Relative dulness. III, Position of the diaphragm at the anterior wall of the chest, at the same time the line of dulness of the normal liver. IV, Edge of liver in cirrhosis. V, In the normal liver. VI, Fatty liver. VII, Amyloid liver. VIII, Cancer, leukæmia, adenoma. All of proportional size.—After RINDFLEISCH.

and malformation of the liver, and thus give rise to apparent hepatic enlargement. The marks which this practice leaves on the chest walls will be sufficient to attract our attention and so prevent mistake.

Diseases of the thoracic organs and abnormal conditions of the other abdominal viscera sometimes cause

displacement of the liver, simulating very closely hepatic enlargement: these we will consider under the head of *differential diagnosis* of diseases of the liver.

VARIATIONS IN THE SIZE OF THE LIVER IN HEPATIC DISEASES.

Variations in the size of the liver occur in almost every disease to which it is subject.

It is *increased* in size in *fatty liver*, in *waxy liver*, in *abscess of liver*, in *congestion*, in *acute hepatitis*, in *obstruction of the bile ducts*, in *cancer*, in *hydatid cyst* and other *tumors*. It is *diminished* in size in *atrophic cirrhosis* and in *acute yellow atrophy*. Enlargements of the liver were divided by Dr. Bright into smooth and irregular. Dr. Murchison has divided them into painless and painful enlargements. Both of these divisions, it seems to me, have their objections, and in giving the physical signs of the various diseases accompanied by enlargement of the organ, it is hardly practicable to adopt either of them exclusively.

FATTY LIVER.—In fatty infiltration of the liver the organ is uniformly enlarged, there are no circumscribed bulgings, its normal shape is unaltered, there is no expansion of the lower ribs, it *never* gives rise to ascites, and it is not attended by any visible enlargement of the superficial veins. On palpation a soft, cushion-like enlargement is readily detected below the margin of the ribs on the right side, and in the epigastrium, extending not infrequently as low as the umbilicus; its outer surface is smooth, and its lower margin is rounded and not well defined; it is *never tender* on pressure. On percussion there is flatness over the surface of the abdomen corresponding to the enlargement.

WAXY LIVER.—In waxy or amyloid degeneration, the organ undergoes greater enlargement than in fatty in-

filtration ; it often becomes so large as to fill the whole abdominal cavity ; its growth is slow, usually extending over a period of two or three years. The enlargement is uniform, and the area of hepatic dulness is consequently increased on percussion in every direction—more, however, in front than behind. There is often a visible tumor below the margin of the ribs, but there is no bulging of the ribs themselves. On palpation that portion of the organ below the ribs is dense, firm, and resistant ; the outer surface is smooth ; the lower margin is sharp and well defined. Pain and tenderness are rarely present, so that the portion of the organ below the ribs, as in fatty infiltration, can be manipulated without giving the patient any inconvenience. When excessive, it is *almost always accompanied by ascites*.

**ABSCESS OF THE LIVER.**—An abscess may occur in any part of the liver. It depends entirely upon its situation whether an external tumor is produced or not. If the abscess occupies the posterior portion of the right lobe, the liver is pushed down so that its margin is perceptible below the free border of the ribs, and the flatness on the right side, posteriorly, extends higher than normal. If the abscess is superficial and is pointing externally, a distinct tumor is felt, and there is always more or less bulging of the ribs if the right lobe is affected. Sometimes the organ is enormously enlarged, its free border extending below the umbilicus ; the surface of the enlargement is smooth, and it is usually tender on pressure. The sensation to the examiner on making light pressure will be soft and fluctuating, or that of elastic tenseness. In some rare instances abscesses produce an uneven or lobulated condition of the surface ; under such circumstances they may be mistaken for cancer, unless the rational symptoms and history of the case be

included in the elements of diagnosis. The enlargement goes on rapidly. With a correct history of the case, the diagnosis is easily made.

**CONGESTION OF THE LIVER.**—The most simple form of hepatic enlargement is that which results from congestion. When the liver is thus loaded with blood, a slight fulness is perceptible on the right side. On palpation the space immediately below the ribs is occupied by a smooth, hard, resisting enlargement corresponding to the natural shape of the liver. Usually it is not tender on pressure. There is no well-defined tumor.

On percussion a flat sound is elicited an inch or two below the margin of the ribs, on the right side.

**OBSTRUCTION OF THE BILE DUCTS** will produce an enlargement of the liver, similar to the one just noticed, by preventing the outflow of bile. Sometimes, in addition to the general enlargement detected by the slight uniform increase in the area of hepatic dulness, a globular projection is found at a point corresponding to the transverse fissure. It has the elastic feel of deep-seated fluid. This tumor is the distended gall bladder.

**ACUTE HEPATITIS.**—The physical signs of acute hepatitis do not differ materially from those of simple congestion, except in the excessive tenderness that exists on pressure over that portion of the organ which descends below the ribs.

**CANCER OF THE LIVER.**—In most cases of cancer the diagnosis is easily made.

On *Percussion* the area of the hepatic dulness is always increased, sometimes extremely so. The organ is found to occupy the greater portion of the epigastrium, extending beyond the median line into the left hypochondrium, pushing the diaphragm upward, and often descending below the ribs to the crest of the ilium.

On *Palpation* irregular nodules of various sizes are distinctly felt through the abdominal walls, projecting from that portion of the enlarged organ which is below the free border of the ribs. These prominences are usually harder than the surrounding hepatic tissue, and there is more or less *tenderness* on pressure over them. Cancer of the liver may, or may not, be accompanied by ascites.

Occasionally the surface of the liver in cancer is perfectly smooth, and in such cases you will be unable to detect the disease by the physical signs.

HYDATID TUMORS OF THE LIVER.—Hydatid cysts, when small or deep-seated, cannot be detected by physical examination; but, when large or superficially seated, they are recognized by abnormal increase in the area of hepatic dulness, and by the globular form of the enlargement on the surface of the organ. Sometimes these cysts are so large as to cause the organ to fill a large portion of the abdominal, and encroach on the right pleural, cavity. The natural form of the organ is greatly altered, the enlargement taking place more in one direction than in another. Sometimes percussion over a large hydatid cyst will give rise to a characteristic vibration known as hydatid fremitus. This vibration is produced by the impulse of the smaller cysts that are contained in a large one. A hydatid liver encroaching on the thoracic cavity gives rise to flatness on percussion, and absence of respiratory sound, from the base of the chest upward as far as the tumor extends: the upper boundary of the flatness is arched. It is distinguished from pleuritic effusion in that a change in the position of the body does not change the line of percussion dulness. On palpation, sometimes the enlarged portion below the ribs has an elastic or even fluctuating



feel, and if a large cyst be near the surface it may give rise to a sense of fluctuation. The surface over these enlargements is smooth, the organ is not *tender* on pressure, and its growth is slow.

#### DECREASE IN THE SIZE OF THE LIVER.

The liver is diminished in size in atrophic cirrhosis and in acute yellow atrophy.

**CIRRHOSIS OF THE LIVER.**—In fully developed cases of atrophic cirrhosis of the liver, the organ is always diminished in size, and there is more or less abdominal dropsy. The only evidence of this disease furnished by inspection is a visible enlargement of the superficial veins.

*Percussion.*—The normal area of the hepatic dulness is diminished. Its limits are determined as follows: if the abdominal cavity is distended with dropsical accumulations, the patient should be placed partly on the left side, so that the liquid will gravitate from the hepatic region; the percussion dulness then, instead of extending to the free border of the ribs, will often give place to tympanitic resonance an inch or more above their free margin, and instead, also, of extending across the median line into the left hypochondrium, will rarely reach that line; while the vertical measurement of hepatic dulness on a line with the right nipple often does not exceed two and a half inches.

*Palpation.*—Little nodules will often be felt on the under surface of the liver, by making firm pressure with the ends of the fingers under the free border of the ribs. Sometimes, when the distention of the abdomen from dropsical accumulation has been very great, we can get no information by palpation until after the performance of paracentesis.

**ATROPHY OF THE LIVER.**—The only physical sign of atrophy of the liver is the rapid diminution in size, determined by percussion. Its surface remains smooth. The diminution in size is never accompanied by ascites.

**DIFFERENTIAL DIAGNOSIS OF DISEASES OF THE LIVER.**

Conditions which may lead to the erroneous diagnosis that the liver is diseased are fæcal accumulations in the ascending and transverse colon, enlargement of the right kidney, diseases of the stomach, displacement of the liver by disease in the right side of the chest, enlargement of the spleen, tumors of the omentum, and ovarian tumors.

**FÆCAL ACCUMULATIONS.**—To distinguish these accumulations from enlargement of the liver, by physical examination, is always difficult and sometimes impossible. They give rise to a distinct tumor, below the border of the ribs, which by percussion and palpation seems to be continuous and connected with the liver. The feel of these fæcal enlargements, already referred to, is characteristic. The differential diagnosis sometimes, however, can only be made after the trial of remedies which, acting freely on the bowels, remove the accumulations and cause the disappearance of the supposed hepatic enlargement.

**DISEASE OF THE RIGHT KIDNEY.**—The right kidney sometimes enlarges in such a manner as to present itself as a tumor extending from the under surface of the right lobe of the liver. It may be distinguished from an hepatic tumor by carefully examining its relation to the ribs. As the patient lies on his back, the enlargement, instead of passing up under the ribs, dips down, so as to allow the finger to pass vertically between the ribs and the tumor. Furthermore, the position of an enlarged kidney is not altered by a deep inspiration.

DISEASES OF THE STOMACH.—The only disease of the stomach which we are likely to confound with enlargement of the liver is cancer. Usually, however, it can be readily distinguished from hepatic enlargement by the tympanitic quality of the percussion sound over the cancerous mass, and by the mobility of the mass.

DISPLACEMENTS OF THE LIVER downward from extensive pleuritic effusion, and from pneumothorax, are recognized by the presence of the physical signs which indicate these thoracic diseases.

ENLARGEMENT OF THE SPLEEN and OVARIAN TUMORS are distinguished from enlargements of the liver by the shape of the tumor, and by the continuous and increasing flatness of the percussion sound as we pass toward the normal position of these organs.

### *Spleen.*

The obscurity which surrounds the normal physiological action of the spleen is so great that its affections usually give rise to but negative general symptoms; and because of its relation to the surrounding organs, it often presents greater difficulties in the diagnosis of its morbid conditions than is the case with any other abdominal organ. In health this organ occupies the upper portion of the left hypochondriac region, its lower border touches the left kidney, while its convex surface occupies the concavity of the diaphragm. It is bounded posteriorly above by the lower border of the ninth rib; anteriorly by the stomach and left colon; and inferiorly by the free margins of the ribs. It is about four inches long and three wide. In its healthy condition, inspection and palpation furnish only negative results.

*Percussion.*—To determine the boundaries of the spleen by percussion, it is necessary that the patient

should lie on the right side. Its anterior border is readily determined because of its relation to the stomach and intestine. Inferiorly, where the organ comes in contact with the kidney, it is difficult and often impossible to determine its boundary. Its superior border corresponds to the line which marks the change from dulness to pulmonary resonance.

In disease the spleen may be increased or diminished

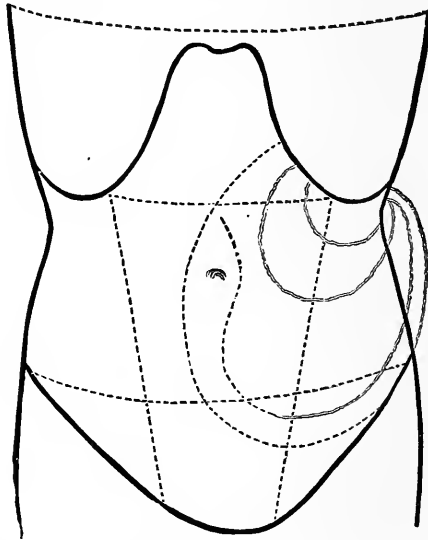


FIG. 19.—Diagram representing the different Areas occupied by the Spleen in its various Enlargements into the Abdominal Cavity.—BRIGHT.

in size ; but we are rarely, if ever, able to recognize diminution in its size during life. In most cases of splenic disease there is neither pain nor tenderness. The only reliable physical signs are those of enlargement. The tumor produced can scarcely be overlooked. Its characteristics are a smooth, oblong, solid mass, felt immediately beneath the integuments, extending from under the ribs on the left side, a little behind the origin of the

cartilages ; often advancing to the median line in one direction, and descending to the crest of the ilium in the other, filling the left lumbar region at its upper part. This tumor is usually movable, rounded at its upper portion, and presenting an edge more or less sharp in front, where it is often notched and fissured.

The principal tumors which may be mistaken for an enlarged spleen are, chronic abscess of the integuments, cancer of the stomach, enlargement of the left lobe of the liver, cancer of the omentum, fæcal accumulation in the colon, disease of the left kidney, and ovarian disease.

CHRONIC ABSCESS IN THE ABDOMINAL WALL sometimes occurs precisely in the situation of an enlarged spleen, but it is easily distinguished from it by the superficial character of the swelling, and by its being too soft to belong to an internal viscus.

CANCEROUS DEPOSIT in the cardiac extremity of the stomach sometimes gives rise to a tumor, which, descending from the margin of the ribs, might be mistaken for an enlarged spleen. One of the best distinctive marks will be found in the sound elicited by forcible percussion : it has more or less of a tympanitic resonance, while the tumor is harder to the feel than an enlarged spleen.

ENLARGED LEFT LOBE OF THE LIVER is easily distinguished from enlarged spleen ; for the margin of the tumor can be traced running toward the right, and not toward the left as is the case with enlarged spleen.

CANCEROUS and TUBERCULAR ENLARGEMENTS of the omentum are distinguished from an enlarged spleen by the fact that they extend across the abdomen, and cannot be traced backward ; they do not ascend behind the ribs, and are rough, hard, and uneven.

FÆCAL ACCUMULATION in the intestine is a source of very great difficulty in this diagnosis, for when it takes place in the descending colon, at the sigmoid flexure, the enlargement assumes very nearly the situation of an enlarged spleen, and is scarcely to be distinguished from it except by its peculiar feel, by its history, and by the results of cathartics; nor must we conclude that the intestines have been emptied, without the most persevering employment of purgatives and enemata.

The LEFT KIDNEY sometimes enlarges toward the left hypochondrium, and presents a tumor very nearly in the situation of an enlarged spleen; but by tracing it back toward the loins, we shall find that its chief bulk is situated posteriorly. It is much more fixed; is not forced downward by a full inspiration; and if the patient is placed on his hands and knees, it does not fall forward. In enlargements of the kidney, the intestine is always pushed forward; this is never the case with the spleen. By observing the rules for the diagnosis of ovarian tumors, we shall easily distinguish them from enlarged spleen (Bright).

## LESSON XVI.

PHYSICAL SIGNS OF THE ABNORMAL CHANGES IN THE  
DIFFERENT ABDOMINAL ORGANS—CONTINUED.

*Kidneys, Bladder, Uterus, Ovaries, Aneurisms,  
Omentum, Mesentery.*

### *Kidneys.*

THE kidneys in health are situated in the lumbar regions, as shown in Fig. 2, in the space corresponding to the two lower dorsal and the two upper lumbar vertebræ. The right is a little lower than the left. Superficially, they extend from the eleventh rib to the crest of the ilium. The right is bounded above, by the posterior and inferior portion of the right lobe of the liver; below, by the cæcum; anteriorly, by the descending portion of the duodenum and the ascending colon; and posteriorly, by the diaphragm and quadratus lumborum. The left is bounded above, by the spleen; anteriorly, by the stomach and descending colon; inferiorly, by the descending colon; and posteriorly, by the diaphragm and quadratus lumborum.

In disease the kidneys may be increased or diminished in size. Diminution in the size of the kidneys can rarely be determined by physical examination, so that enlargements are the only conditions to which physical exploration is applicable. The kidneys may be enlarged from pyelitis, which sometimes converts them into a sac of pus; cancerous and tubercular deposits, hydatid cysts, and simple distention, the result of an obstructed

ureter. A tumor is sometimes developed at the upper border of a kidney, from disease of the suprarenal capsule.

*Inspection* rarely furnishes any evidence of enlargement of a kidney.

*Palpation* of the kidney is to be practised as follows : The patient is placed in the dorsal position, with the thighs flexed. One hand is placed over the seat of the kidney in the lumbar region, and firm pressure is made. The fingers of the other hand are placed below the free border of the ribs, on a line running through the middle of Poupart's ligament. With each expiration the fingers are pressed deeper and deeper until the renal tumor is reached. The part of the abdomen in which the enlarged kidney is felt will vary according to the nature of the disease and the portion of the kidney involved.

*Percussion.*—Unless the kidney is much enlarged, the results of percussion are uncertain. In performing percussion, the patient should be placed on the abdomen and chest, which posture will allow liquid accumulations in the abdominal cavity to gravitate forward, and the intestines to float upward. The external margin of the kidney is determined when the tympanitic note of the intestine is reached. Any enlargement will be accompanied by a corresponding increase in the area of renal dulness. We can rarely establish by a physical examination the exact nature of the disease to which the increase in size is due.

The sources of error in the diagnosis of enlargements of the kidneys vary, according as the right or left kidney is the seat of disease.

Enlargement of the right kidney may be mistaken for a tumor of the right lobe of the liver, for cancer of the pyloric extremity of the stomach, for fæcal distention of the colon, and for enlargement of the right ovary. The



rules for distinguishing it from each of these have been already given in the previous section, as likewise for distinguishing enlargements of the left kidney from enlargement of the spleen, the left ovary, and from fæcal distention of the descending colon.

MOVABLE KIDNEY.—This is not properly a disease, but a structural peculiarity in certain individuals. The right kidney is more often affected than the left. The attachments of the kidney are so loose that the organ can be displaced, either vertically or laterally, to a considerable degree, and may so approach the anterior abdominal walls as to be readily felt through them. It may be found in the umbilical region, or even across the median line. It can be detected best by drawing up the feet to retract the abdomen, then grasping the tumor with the palm of the hand. It has a smooth, rounded feel, and differs from mesenteric tumors or fæcal accumulations in disappearing, on gentle pressure, into the abdominal cavity, so that it cannot be felt. When the kidney is displaced, the corresponding lumbar region gives a tympanitic sound on percussion.

### *Bladder.*

When the bladder is empty, its position cannot be determined by physical exploration. It can only be detected when it is distended and rises above the pubes. It then appears as a tumor in the hypogastric region, which on palpation is smooth and oval. Its rounded margin is easily made out by observing the tympanitic sound of the intestines on the one hand, and the dull sound of the bladder on the other. In infants, the bladder is not as deep in the pelvis as in adults, consequently a smaller quantity of urine in the bladder can be recognized. A distended bladder can only be mistaken in

the female for a gravid uterus or a uterine tumor: the use of a catheter removes all doubts.

### *Uterus.*

The unimpregnated uterus in its normal state is situated in the lower part of the hypogastrium, and is inaccessible to the touch, externally, or to percussion; but when normally enlarged by impregnation, or abnormally by disease, palpation, percussion, and auscultation furnish us with important information.

In pregnancy, at the end of the second month, a dull sound on percussion, just above the pubes, indicates the enlarging uterus; later, as the uterus increases in volume and rises into the abdomen, we are able, by the oval tumor felt in the hypogastrium, and by the circumscribed area of dulness corresponding to the situation of the tumor, to establish strong presumptive evidence of pregnancy. The presumption becomes strengthened if the area of the dulness increases with the regularity proper to gestation. But palpation and percussion are not sufficient to determine whether the enlargement of the uterus is due to pregnancy, or to some morbid deposit in its walls or cavity, as fibrous tumors, etc.

After the end of the fifth month, the evidence furnished by both these methods is inferior to auscultation.

**RULES FOR PERFORMING UTERINE AUSCULTATION.**—The female should be placed on her back, with her thighs slightly flexed so as to relax the abdominal muscles; sometimes it is well to incline the body from one side to the other, or forward so as to withdraw the pressure of the uterus from the pelvic arteries. The abdomen should be uncovered, as the sounds to be examined are of slight intensity and their area is very circumscribed. Their study demands close attention and perfect silence.

The stethoscope is always to be preferred, and the uterine tumor should be auscultated successively at different points.

After the fourth month of gestation, if the uterus contains a living foetus, we may hear three distinct sounds—the *Uterine Bruit*, which is evidently connected with the circulation of the mother; the *Foetal Heart Sound*, and the *Funic Souffle*, which are connected with the circulation of the foetus.

*Uterine Bruit*.—This sound is single, intermitting, and in character is a combination of the blowing and hissing sounds. It increases in intensity up to the period of labor. It is believed to depend upon the rapid passage of blood from the arteries into the distended venous sinuses of the uterus. It is synchronous with the maternal pulse, is subject to the same variations, and is always heard before the pulsation of the foetal heart.

The *Area* over which it is audible varies. In some instances it is limited to a single point, in others it is audible over a surface of three or four inches, and in a few it is heard over the whole uterine tumor, although there will always be one spot of greatest intensity, corresponding to the placental attachment. It is also intensified by uterine contractions, though at the height of the pain it may cease altogether. It may be modified or arrested by pressure on the stethoscope.

During the first half of pregnancy it is usually heard with greatest intensity in the median line, a little above the pubes; after the fifth month, at the lateral and inferior borders of the uterus; and next, in order of time, it will be heard at the fundus.

This sound may be confounded with the respiratory murmur of the mother, and with intestinal murmurs:

these murmurs, however, are not synchronous with the pulse of the mother, and if this fact is remembered there will be little difficulty in distinguishing them. As a proof of pregnancy, uterine bruit is not positive, as it is sometimes heard in connection with uterine and ovarian tumors. It does not prove that the foetus is alive, for it is heard for a long time after its death. Its negative evidence is of less value, for if the placenta is attached posteriorly we may not be able to hear it, although pregnancy exist.

*Funic Souffle.*—This sound is usually heard at a point quite remote from the uterine bruit. It is short, feeble, and blowing in character, and corresponds in pregnancy with the foetal pulsation. It is supposed to depend upon obstruction to the transmission of blood through the umbilical arteries, as from twirling or knotting of the funis, or from external pressure. It is not a constant, nor even a frequent sound, the conditions of its production being rarely met with.

*Foetal Heart Sound.*—This sound consists of a succession of short, rapid, double pulsations, varying in frequency from 120 to 140 per minute. The first sound is short, feeble, and obscure, while the second, the one we usually hear, is loud and distinct, and may be heard generally over the body of the child. This sound has been aptly compared to the ticking of a watch wrapped in a napkin, and usually is first heard at the middle of the fourth month. The frequency of the pulsations does not vary with the age of the foetus.

The extent over which the foetal heart sound is audible varies; usually it is transmitted over a space three or four inches square. The location of the sound is determined by the position of the foetus. It has been stated that whenever the maximum intensity of this

sound is below a horizontal line dividing the uterus into equal parts, it is a vertex presentation; when above, it is a breech; also, when the foetal pulsations are heard low down in front on the left side, that the foetus is in the first position; if heard below and in front, on the right side, it is in the second position.

Twin pregnancy may sometimes be determined by the presence of heart sounds heard at distant points over the uterine tumor, and by the absence of synchronism in the two pulsations. The sources of deception in exploring for the foetal heart sound are the liability of confounding the pulsation of the iliac arteries or abdominal aorta of the mother with it. In most cases their situation, comparative frequency, and absence of double pulsation will determine their character. But a difficulty will sometimes occur in discriminating between them when the natural pulse is very much increased in frequency and the foetal diminished. Under such circumstances we must be guided by the character of the sound, and whether it is, or is not, synchronous with the radial pulse.

Again, in the early stage of pregnancy, the intensity and impulse of the maternal pulsation may render the feeble foetal sound inaudible. This difficulty may be overcome by removing the pressure of the uterine tumor upon the subjacent arteries, by changing the posture of the mother.

During labor our examinations should be made in the interval between uterine contractions.

In protracted labors, auscultation is of value in indicating to us the time for manual or instrumental interference to save the life of the child. The indications of danger to the child are feebleness or excessive frequency of the foetal pulsation; irregularity in its rhythm; ab-

sence of the second sound ; its complete cessation during uterine contraction, and the slowness of its return in the interval. Irregularity and feebleness are the most threatening to the life of the child. When the sound of the foetal heart is heard it is a positive proof of pregnancy ; but its absence is not always proof that pregnancy does not exist, for the foetus may be dead, and in some rare cases the sounds may exist and be quite inaudible for a time, and then appear. This phenomenon is not easily accounted for.

TUMORS OF THE UTERUS, whether developed on its surface, in its walls, or within its cavity, give rise to enlargement of the organ, which causes it to occupy a position corresponding to that occupied by a gravid uterus. The position and extent of these enlargements are determined in the same manner as we determine the size and position of the uterus in pregnancy. Deposits in its walls or on its surface give rise to nodules, which feel through the abdominal walls like hard balls, varying in size and shape, seldom occurring singly. The whole mass can usually be moved from one side to the other. The connection of these tumors with the uterus, as determined by the uterine sound, leaves little doubt as to their true character, and by this means we readily distinguish them from all other abdominal tumors.

#### *Ovaries.*

The ovaries in a normal state lie in the pelvic cavity, and their position cannot be determined by physical exploration ; but when they become the seat of tumors, and have attained such dimensions that there is no longer room for them in the pelvic cavity, they ascend above its brim and occupy more or less space among the abdominal organs. As they pass out of the pelvis, they

are first noticed in the right or left iliac region, according as the right or left ovary is affected, and they are then recognized as ovarian tumors. Before these ovarian enlargements have attained sufficient size to attract the attention of the patient, they will have reached a central position in the abdominal cavity. They are of more frequent occurrence than any other forms of abdominal

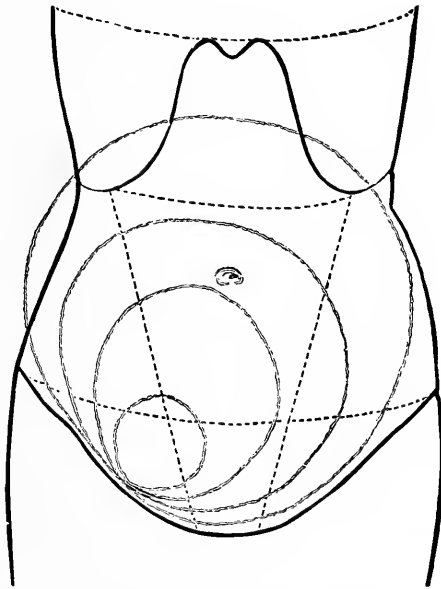


Fig. 20.—Diagram showing the Gradual Enlargement of a Tumor of the Right Ovary till it fills a large portion of the Abdominal Cavity.—BRIGHT.

tumor, and their existence is determined almost exclusively by the physical signs which they furnish.

*Inspection.*—In the early part of their development, an uneven projection or prominence of one part of the abdomen will disclose the seat of the tumor, occupying usually the iliac or lumbar region of one side, and extending upward to or beyond the umbilicus; while in more advanced cases no inequality will be visible, but

the rounded form of the abdomen, while the patient lies on her back, offers a strong contrast to the flattened oval appearance of ascites, or the central rounded form of a uterus distended by pregnancy.

*Palpation.*—Ovarian tumors, when small, have a firm, elastic feel ; but when large, they are soft and fluctuating. In some cases, by passing the hand gently over the abdomen, the extent of the tumor will be readily appreciated. At other times, the limits of the tumor cannot be ascertained by gentle palpation, for it occupies the whole of the abdomen except the concavity of the diaphragm. In such cases, by making firm, but not forcible, pressure on various parts of the abdomen, we often detect at once a general sense of fluctuation, and ascertain inequalities which neither the eye nor the hand when passed gently over the surface will enable us to detect ; sometimes, if the abdomen is not tense, we can feel masses which convey the impression of more or less flattened or spherical bodies attached to the inside of a fluctuating tumor. In some cases the sense of fluctuation is very indistinct ; in others it is even more evident than in cases of extensive ascites.

*Percussion.*—The sound elicited on percussion is flat over that portion of the abdomen where the tumor comes in contact with the inner surface of the abdominal wall ; while at the sides and above, where the intestines have been pushed aside and upward by the tumor, the percussion sound will be tympanitic ; by this change in the percussion sound we are enabled to mark out the boundaries of the tumor.

*Differential Diagnosis.*—Ovarian tumors may be confounded in their diagnosis with *uterine enlargements*, as pregnancy, fibroid tumors of the uterus, etc., *ascites*, *hydatids of the omentum*, *faecal accumulations in the*



*intestines, and enlargements of the liver, spleen, and kidneys.*

They are distinguished from pregnancy by a stethoscopic examination of the tumor, which reveals in the one case the sounds of the foetal heart, and in the other their absence. They are distinguished from uterine tumors by their consistence, by their outline, by the difference in their connection and relative position to the uterus, and by the fact that in uterine tumors the cavity of the uterus, as determined by the uterine sound, is always elongated. The diagnosis between ovarian and abdominal dropsy is made : *First.* By observing the difference in the shape of the abdomen when the patient lies on her back. Ovarian tumors project forward in the centre, while in ascites the abdominal enlargement is uniform. *Second.* In ovarian tumors, the percussion sound is dull as high as the tumor extends, while at the same time there will be tympanitic resonance in the most depending portion of the abdominal cavity ; in ascites, the most depending portion of the abdomen is always flat, the percussion resonance being confined to the epigastric and umbilical regions. *Third.* In ovarian dropsy, the relative line of flatness and resonance is not altered by change in the posture of the patient, which is not the case in ascites.

Hydatids of the omentum form a class of tumors which you will be unable to distinguish from ovarian tumors by the physical signs. The fact, however, that these omental enlargements are first noticed above the umbilicus and gradually enlarge downward, while ovarian are first noticed low down in the abdomen and gradually enlarge upward, will in most cases be sufficient for a diagnosis.

Faecal accumulations in the large intestine may be

mistaken for ovarian tumors. The peculiar feel of such enlargements, already described, will enable you to distinguish them from ovarian tumors.

*Abdominal Aneurism.*

Aneurism of the abdominal aorta usually occurs at or near that portion of the vessel from which the cœliac axis is given off, and the rupture is usually in the posterior wall of the artery. Aneurism of the cœliac axis, of the renal, hepatic, superior mesenteric, or splenic arteries, is of very rare occurrence, and there are no means by which, if they do occur, they can be distinguished from aneurism of the abdominal aorta.

*Inspection.*—On inspecting the abdomen in a case of abdominal aneurism, a tumor in the epigastrium, with an expansive impulse, usually is discovered; in some cases, however, the closest inspection reveals nothing abnormal. When a tumor is present, the surface of the abdomen over it will be rounded and smooth. When the aneurism is of large size, abdominal respiration may be diminished and thoracic increased. Enlargement of the superficial veins of the abdomen, and œdema of the lower extremities, are very rare phenomena.

*Palpation.*—By palpation we can determine approximately the size of the tumor, its position, and its impulse.

Aneurisms of the abdominal aorta are usually felt in the median line, or to the left of it, on the right side, or on both sides. They are *immovable*. The impulse, if one exist, is systolic and expansive, although when it is situated high up there also may be a slight diastolic movement. A thrill is rarely perceptible. By comparing the pulsation in the arteries of the lower extremities with that of the upper, a feebleness of pulsation may be

detected. The surface of the tumor, when not ruptured, is rounded and smooth. Effusions of blood into the surrounding tissues may produce lobulations.

*Percussion.*—Dulness or flatness will exist over the tumor, unless a distended intestine lie above it.

*Auscultation.*—A systolic murmur, resembling that produced in aneurisms of the thoracic aorta (page 123), is usually heard directly over the tumor in front, or opposite to it along the lumbar spine; rarely, if ever, is a diastolic murmur heard, though a prolonged second sound often exists. In some cases, the murmur is audible when the patient is in the recumbent posture, but disappears when he assumes the erect posture.<sup>1</sup> In other cases, all the physical signs of aneurism are absent, and still we are led to suspect its existence from the rational symptoms, the most prominent of which is a continuous, deep-seated, and at times paroxysmal pain in the lumbar region, which shoots down the thighs and around the abdomen.

Abdominal aneurism may be mistaken: *First.* For enlargement of various organs which by its size it has displaced, as the liver, kidney (especially the left), and the spleen. The presence, however, of the physical signs of aneurism in such cases will enable us to refer the apparent enlargement to its right source. *Second.* For neuralgia, rheumatism, renal colic, etc. The steady, persistent, long-continued, paroxysmal pain in the lumbar region, especially in male subjects, is strong presumptive evidence of aneurism; and if we have connected with this an immovable, although perhaps not pulsatile, tumor along the course of the artery, the diagnosis of aneurism becomes almost positive.

---

<sup>1</sup> See Intra-thoracic Auscultation, p. 39.

*Third.* For disease of the spine. Here the pain, and possibly a curvature produced by an aneurism, may mislead, but the physical signs of aneurism in most cases will correct the mistake. *Fourth.* For psoas or lumbar abscess. In this the shape of the tumor is elongated, and there is neither impulse nor murmur perceptible. *Fifth.* For aortic pulsation. In aortic pulsation there is, however, absence of a murmur, or a thrill, or percussion dulness, and the impulse is quick and jerking, and not expansive as in aneurism. *Sixth.* For abdominal tumors. The tumors which are apt to be mistaken for aneurism are enlarged left lobe of liver, cancer of the pylorus, enlarged mesenteric glands, fæcal accumulations, and hydro- or pyo-nephritic kidney. In tumors the feel is usually harder, the impulse lifting, rarely expansive, and they may be accompanied by ascites, œdema, or enlarged abdominal veins, the infrequency of which in aneurism has already been alluded to. If a murmur occur with a non-aneurismal tumor, it may be made to disappear in most instances by causing the patient to assume a posture on his hands and knees; the impulse may be diminished or cease at the same time. Tumors are also usually movable, aneurisms immovable. In many cases of abdominal aneurism the diagnosis is uncertain.

#### *Omental Tumors.*

The omentum may be the seat of a hydatid cyst, of cancer, or of tubercular deposits. These deposits or growths give rise to tumors which are readily detected through the abdominal walls, both by percussion and palpation. They are first recognized high up in the abdominal cavity, above the umbilicus, and gradually extend downward. If there are no adhesions, you can push the tumors upward and from right to left. They

are superficial, and their uneven surface is readily detected by passing the hand lightly over the surface of the abdomen. They are always more or less tender on firm pressure. The percussion sound elicited over these tumors is never flat, but has a tympanitic quality, caused by the subjacent intestines.

*Mesenteric Enlargements.*

Mesenteric enlargements occupy a position corresponding to that of the small intestine. They are beyond the reach of physical diagnosis, except as they occur in children in the last stage of tabes mesenterica; then their diagnosis is of little practical use, their cure being hopeless.



# EXAMINATION OF URINE.





## LESSON XVII.

INTRODUCTION—PLAN OF EXAMINATION—PHYSICAL CHARACTERS—CHEMICAL CHARACTERS—(a) NORMAL ELEMENTS, (b) ABNORMAL ELEMENTS.

GENTLEMEN :—You will find that the examination of the urine is of great service in the diagnosis of disease. In order that it shall be complete, the urine should be examined both chemically and microscopically.

I shall first direct your attention to the chemical examination. (For the microscopical examination, see the lesson on Clinical Microscopy.) This involves both qualitative and quantitative analyses—the former to ascertain the presence or absence of particular substances ; the latter to determine the quantity or proportion in which they exist when present.

The specimen to be examined should be taken from the urine passed on rising in the morning, and should be collected in a perfectly clean bottle holding from four to six ounces.

The examination should be conducted after the following plan:

### *Physical Characters.*

1. Quantity passed in twenty-four hours.
2. Condition (transparent or turbid).
3. Color.
4. Odor.
5. Reaction.
6. Specific gravity.
7. Character of deposit.

*Chemical Characters.*

## NORMAL ELEMENTS.

1. Urea.
2. Uric acid and the urates.
3. Phosphates.
4. Chlorides.
5. Sulphates.

## ABNORMAL ELEMENTS.

1. Albumin.
2. Sugar.
3. Bile.
4. Blood.
5. Pus.

The examination should be made within twelve hours after the urine is voided ; in warm weather, even earlier.

*Physical Characters.*

QUANTITY PASSED IN TWENTY-FOUR HOURS.—The amount of urine voided by a healthy person in twenty-four hours greatly varies. The mean daily discharge ranges between forty and fifty fluid ounces—it may rise as high as eighty ounces, and fall as low as twenty-five ounces, and still be within the limits of health, the variation depending in a great degree upon the quantity of fluid drunk.

In order accurately to determine the quantity passed in twenty-four hours, it should be carefully measured in a graduated urine glass.

Before determining the *clinical significance* of any deviation from the usual quantity of urine passed by an individual, Dr. Roberts states that the following points should be borne in mind:

When the urine is unusually scanty, it should be ascertained, before pronouncing it a morbid phenomenon, whether the patient has abstained from liquids above his habit, or whether water has been eliminated in excess by some other channel, as the skin or bowels. The urine is always *scanty* in fevers, cirrhosis of the liver, and in some forms of Bright's disease through their entire course. In the early stage of acute Bright's disease it is very scanty, sometimes approaching or reaching total suppression. It is also *scanty* in any condition of the heart which directly or indirectly causes passive congestion of the renal veins, whereby the circulation through the kidneys is impeded. It becomes scanty, or is suppressed, in the collapse stage of cholera.

Any diminution of the urinary secretion which approaches suppression is of most serious import.

The flow of urine is *abundant* when the surface of the body is cool, or when large quantities of fluid have been taken. In disease it is discharged in excessive quantity in two special maladies—diabetes and chronic interstitial nephritis. Temporary excess of urine occurs after hysterical paroxysms, certain other convulsive attacks in both males and females, and after mental worry or anxiety. An increased tension in the arterial system, as in some cases of hypertrophy of the left ventricle, is associated with increased secretion of urine.

CONDITION.—Normal urine is clear when first voided, but on standing a slight cloud of mucus forms. It comes from the urinary passages, generally the bladder. Urine is rendered cloudy by deposits of phosphates or urates, and by contamination with blood or pus. Alkaline fermentation produces a turbidity of the urine by bringing about the decomposition of urea and the precipitation of the earthy phosphates. The presence of fat

in the urine as an emulsion (chyluria) gives it a milky appearance.

COLOR.—In health the color of the urine varies from a pale-straw to a brownish-yellow tint. This is due to the presence of urobilin, a normal pigment of the urinary secretion. But the color may be altered and yet indicate no morbid condition. Certain drugs impart an abnormal color to the urine. Rhubarb and senna give it a brown or reddish color; logwood, a reddish or violet color; while creosote, carbolic acid, and tar color it black. Again, in cases of melanotic tumor the urine is dark. As a rule, the larger the quantity of urine passed the lighter the color, and *vice versa*. The darker color of the diminished amount is due to a relative excess of urobilin, as after great exertion which is attended by profuse perspiration. High-colored urine, when a normal amount is passed, is an indication of disease.

Bile communicates a dark olive-green tint to the urine. An admixture of blood gives the urine a smoky or distinctly reddish appearance.

The red color of rheumatic urine is due to a special pigment, uroerythrin.

Indican is a pigment normally found in the urine, but to what extent it influences the color is not known. Sometimes, when in excess, it breaks down and forms indigo-blue, which imparts its color to the urine. This may occur in Asiatic cholera and in typhus fever.

ODOR.—Healthy human urine, immediately after voiding, has a sweetish, aromatic odor. But the odor may be changed by the ingestion of certain kinds of food and the administration of certain medicines. Asparagus gives the urine a disagreeable stench; garlic imparts its odor. Turpentine produces the odor of violets. After alkaline fermentation the pungent odor of ammonia is

perceptible. A fruity, apple odor is present in diabetes mellitus, due to the presence of acetone.

REACTION.—When first passed, healthy urine is slightly acid in reaction. This is due to the presence of acid sodium phosphate. The degree of acidity varies in the twenty-four hours. After each meal it declines for about two hours until the urine is neutral or even alkaline, and then returns to the normal. The reaction is affected by the kind of food eaten: thus an animal diet makes the urine acid; a vegetable diet, alkaline. Fasting is marked by a decided increase in acidity.

After standing for some time, all urine becomes alkaline from the decomposition of urea and the formation of ammonium carbonate. The rapidity with which this takes place varies with the state of the temperature. In warm weather the fermentation begins a few hours after voiding.

In febrile and inflammatory affections, especially of the liver, heart, and lungs, the urine is strongly acid; while in affections of the brain and spinal cord, and certain diseases of the genito-urinary organs, it is often strongly alkaline. Urine that is ammoniacal when voided indicates chronic vesical catarrh or obstructive disease of the bladder or ureters.

When the urine is mixed with blood or pus<sup>1</sup> the reaction is generally alkaline. The administration of mineral acids gives the urine a strongly acid reaction.

SPECIFIC GRAVITY.—The specific gravity of urine in health varies from 1015 to 1025. When the quantity of urine is large the specific gravity is low, except in diabetes mellitus; and when the quantity is small the specific gravity is high.

The most convenient method of estimating the spe-

---

<sup>1</sup>In pyelitis and pyelonephritis the reaction is acid.

cific gravity is by means of the *urinometer*. It consists of a blown-glass float, weighted with mercury, and a graduated stem upon which the readings are to be made. A cylinder of convenient size is nearly filled with the urine and the instrument floated in it. The reading should be made at the lowest point of the concave surface of the urine.

From the specific gravity of urine a rough estimate may be made of the amount of solid matter contained in solution. The method was proposed by Trapp. If the reading is below 1018 the last two figures are to be multiplied by 2; if above, by 2.33. This will give the amount per thousand volumes. For example, in 1,500 grammes of urine whose specific gravity is 1030 there will be 104.85 grammes of solid matter. If, then, the quantity of urine voided in the twenty-four hours be known, the daily excretion of solids can be approximately ascertained.

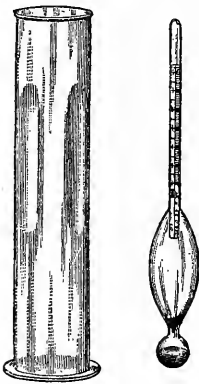


Fig. 21.—Urinometer.

*In disease* the average specific gravity of the urine may be increased or diminished. It is highest in diabetes, and lowest in hysteria. In inflammations, as pneumonia, pleurisy, etc., and in fevers, it often rises as high as 1035. On the other hand, when the average specific gravity is abnormally low you may suspect some exhausting, non-inflammatory complaint, as Bright's disease, in which it may fall so low as 1006. As a rule, the lower the average specific gravity of the urine in chronic Bright's disease, the more unfavorable the prognosis.

**CHARACTER OF DEPOSIT.**—The deposit may be scant or heavy, amorphous or crystallized, white or colored.

Deposits of urates are pink, reddish (brick-dust), brown, or white in color. Uric acid crystals form a scant reddish-brown sediment resembling grains of red pepper. When pus is present the sediment is heavy and of a yellowish-white color. Deposits of blood are reddish in color. Mucus, when present in large amount, forms a heavy, gelatinous deposit.

The naked-eye inspection is not to be relied upon. The deposit should always be examined chemically and microscopically.

### *Chemical Characters.*

#### NORMAL ELEMENTS.

UREA is a product of tissue metabolism. It is the chief form in which nitrogen leaves the system. The urea which passes off in urine is brought to the kidneys as such in the blood. It is not probable that the kidneys have the power of forming urea by a special function. The amount excreted by a healthy adult is about thirty grammes in the twenty-four hours, but it is subject to great variation, being dependent upon the amount and kind of food eaten. An animal diet increases the daily excretion, while a vegetable diet diminishes it. The amount excreted is not affected by exercise.

*Quantitative Estimation of Urea.*—A convenient *ureometer* has been devised by Dr. Charles Doremus for the rapid estimation of urea. It consists of a closed glass tube bent into two arms; the long arm is graduated, the short arm is dilated into a bulb (see Fig. 22). Sodium hypobromite is the reagent employed. When urea is brought in contact with sodium hypobromite, it is decomposed and nitrogen gas is given off. The solution is made by adding one cubic centimetre of bromine to ten cubic centimetres of a solution of sodium hydrate

(one hundred grammes to two hundred and fifty cubic centimetres of water), and diluting with ten cubic centimetres of water. It should be freshly prepared for each examination, as it deteriorates on keeping.

The method of using the instrument is as follows: Fill the ureometer to the mark = with the sodium hydrate solution, add one cubic centimetre of bromine by means of the pipette, and pour in sufficient water to fill

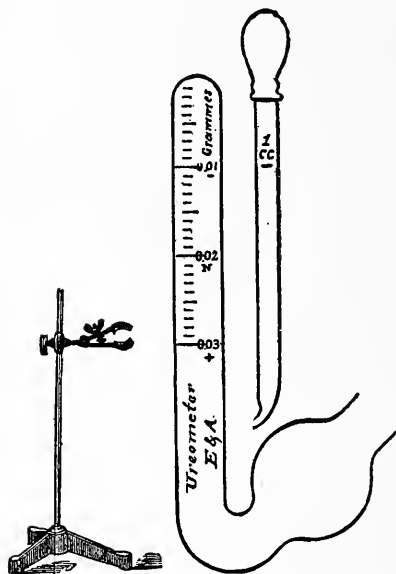


FIG. 22.—Ureometer.

the long arm and bend. Wash the pipette, and then draw up one cubic centimetre of the urine to be tested. Introduce the tip of the pipette well into the bend, and force the urine out gradually. As it passes into the hypobromite solution, nitrogen gas is evolved and collects at the top of the tube. The reading is made after twenty minutes. Each division of the scale indicates 0.001 gramme of urea for one

cubic centimetre of urine. If, then, the number of milligrammes to the cubic centimetre be multiplied by the number of cubic centimetres of urine passed, the result will be the amount of urea excreted in twenty-four hours. If the percentage by volume be desired, multiply the number of milligrammes found by one hundred.

As the amount of urea excreted at different times of the day varies, the specimen to be examined should be taken from the mixed urine of twenty-four hours.



*Clinical Significance.*—In disease, the quantity of urea contained in the urine may be abnormally increased or strikingly diminished. It is *abnormally increased* in all febrile affections (except yellow fever), in all nervous affections (especially in epilepsy), in pyæmia, in diabetes, and, as a rule, in acute inflammation of the thoracic viscera. It is *abnormally diminished* in cholera, in some cases falling as low as four grammes in twenty-four hours.

In *Bright's disease*, the diminution in the quantity of urea in the urine is marked and significant. As a rule, the more albumin in the urine the less the amount of urea, and *vice versa*. But not infrequently, in patients with waxy or cirrhotic kidneys, the quantity of albumin may be slight, or for a time entirely absent (the urine being of low specific gravity), and still the quantity of urea daily excreted falls far below the normal standard. In all forms and stages of those kidney changes included under the term Bright's disease, it is important to determine accurately the quantity of urea contained in each day's urine—it is not only an important element in diagnosis, but also in prognosis.

URIC ACID is a normal constituent of the urine. It is not present as the free acid, but in combination as urates. The daily excretion of uric acid varies from 0.5 to 1 gramme. Like urea, it is a product of tissue metamorphosis, and is increased by an animal diet. Its proportion to urea is as 1:45.

The presence of free uric acid is detected by the *murexide* test. Place the suspected deposit in a small crucible with a few drops of nitric acid, and evaporate nearly to dryness. On the addition of a drop of ammonia a rich purple color is produced. (For the microscopical examination see page 217.)

To estimate the quantity of uric acid in a specimen of urine, add one part of hydrochloric acid to twenty parts of the urine, and set it aside for a day or two. The uric acid in the bases is replaced by the hydrochloric, and thrown down as yellowish or brownish crystals. These should be carefully separated, dried, and weighed. The calculation is then made for the urine of twenty-four hours.

*Urates.*—The urates found in the urine are chiefly those of sodium and ammonium. In perfectly healthy urine they are held in solution. Sometimes, however, when the amount of water is diminished, as after excessive perspiration, they are precipitated as the urine cools. The deposition of urates usually occurs in strongly acid urine of high specific gravity. They form a heavy deposit, of a pink, reddish, brown, or even white color. Urates are readily dissolved by heat.

*Clinical Significance.*—Uric acid is not always in excess when it is readily precipitated. If the urine is very acid, it may be separated from its bases and thrown down. This may occur before the urine is voided, and be the basis of the formation of calculi.

The amount of uric acid excreted is diminished in anæmia, chlorosis, and the advanced stages of Bright's disease. It is increased in those diseases of the heart and lungs where there is deficient aëration of the blood, in many diseases of the liver, in fevers, and in acute rheumatism.

The urates are frequently separated with the uric acid. Persons who habitually pass urine containing deposits of urates and uric acid are generally the subjects of gastric and hepatic disorders. They are usually large eaters and drinkers, and take little exercise. Deficient oxidation is the chief cause of the uric acid diathesis.

PHOSPHATES.—The normal quantity of phosphates excreted in twenty-four hours has been found to be about 2.5 grammes. They are derived in part from the food, and in part from tissue metabolism—some have supposed, principally the nervous tissues. Phosphates of sodium, calcium, and magnesium are the salts present in largest amount. The calcium and magnesium salts constitute the earthy phosphates. As long as the urine is acid in reaction, the phosphates are held in solution. Sometimes, however, calcium phosphate is precipitated upon the application of heat. In alkaline fermentation, urea is decomposed by a special bacterium, with the formation of ammonium carbonate; the earthy phosphates are precipitated, and in the presence of ammonia the triple phosphate crystals are formed (see page 218).

Deposits of phosphates are readily dissolved by a few drops of nitric acid. The phosphates are not always in excess when they are readily precipitated; and, on the other hand, they may be in excess and yet remain in solution. They are increased in amount by a proteid diet and by mental or bodily exercise.

*Clinical Significance.*—Like most urinary ingredients, the quantity of phosphates eliminated in the urine undergoes a marked change in disease. It has been found to be abnormally increased in all inflammatory diseases of the nervous system, in paralysis, or any severe nerve lesion, in acute mania, delirium tremens, and in rickets. It is diminished in most febrile and inflammatory affections, especially pneumonia (unless nerves or nerve centres are involved), in Bright's disease, in gout, and in rheumatism.

CHLORIDES.—Sodium chloride is the only chloride present in the urine in sufficient amount to claim attention. The mean daily excretion has been computed at 11.5

grammes. But as it is derived chiefly from the food, it is subject to great change.

The test for sodium chloride consists in acidulating the urine with a drop or two of nitric acid, and the addition of a little silver nitrate solution. The chloride of silver is formed, which is insoluble in nitric acid, but readily soluble in ammonia.

*Clinical Significance of Chloride of Sodium.*—An increase of the chlorides in the urine in disease is rarely, if ever, met with, and has no clinical significance; but their diminution or absence is of so frequent occurrence in certain forms of disease as to become an important aid in their diagnosis. Their absence is most marked and constant in the exudative stage of acute inflammation, especially in pneumonia during the stage of hepatisation, when they may be absent for two or three days, but return as soon as resolution commences. They are often absent in fevers, especially in typhus. In acute rheumatism, as soon as the endocardium and pericardium become implicated they generally suddenly disappear. Chloride of sodium is absent or diminished in cholera, and its increase or return is regarded a very favorable symptom.

The SULPHATES are present in urine in large quantities. They are chiefly those of potassium and sodium, the former being present in greater amount. The test for the sulphates consists in adding a drop or two of nitric acid and a few drops of a saturated solution of barium chloride to some of the urine. A white precipitate, insoluble in acids, is formed.

An increased or diminished excretion of sulphates has little bearing clinically. They are generally increased in acute febrile affections when large quantities of urea are excreted.

*Abnormal Elements.*

## ALBUMIN.

Of the different forms of albumin which have been found in urine, serum-albumin is the one which at present has most clinical significance. Numerous tests have been proposed for its detection, but only three of them will be considered here.

Before applying a test the urine should be rendered clear by filtration. When the turbidity is due to a deposit of urates, a gentle heat will suffice to remove it.

QUALITATIVE TESTS. 1. *Heat and Nitric Acid.*—Pour the urine into a test tube until it is about three-quarters full, and boil the upper portion of it—the lower portion is used for comparison. If a precipitate forms, it may be due to the presence of albumin or to an excess of phosphates—the addition of a few drops of nitric acid will decide which. A precipitate of phosphates is readily dissolved, while albumin is not affected or increased in amount.

2. *Heller's Test.*—Pour a small quantity of nitric acid into a narrow test tube; draw some of the urine into a pipette and float it on the surface of the acid. If albumin is present, a clearly defined white band is formed at the junction of the two liquids. An excess of urates will likewise give a white band, but the upper border is not clearly defined, and it is dissolved by the application of a gentle heat.

This test is very accurate. But a color band formed at the junction of the two liquids must not be mistaken for albumin.

3. *Potassium Ferrocyanide and Acetic Acid Test.*—Mix some of the urine in a test-tube with an excess of acetic acid, and add a few drops of a ten-per-cent solu-

tion of potassium ferrocyanide. In the presence of albumin a precipitate will form ; or, if the amount be small, only a slight turbidity will appear.

It is especially necessary, in applying this test, to have the urine clear, otherwise the presence of a small quantity of albumin will be overlooked.

Albumin will be found in urine that is contaminated with blood, pus, or the menstrual discharge.

QUANTITATIVE ESTIMATION.—The *albuminometer* gives only an approximate result, but it is sufficiently accurate for clinical purposes. It consists of a thick glass cylinder the shape of a test tube (see Fig. 23). At its upper portion is the mark R ; about midway, down the mark U ; and below this, a graduated scale.

The reagent used is made by dissolving one gramme of picric acid and two grammes of citric acid in one hundred cubic centimetres of distilled water.

The urine is poured in to the mark U, and the reagent added to the mark R. The mouth of the instrument is closed with a rubber stopper and the two liquids thoroughly mixed by shaking. It is then set aside in the upright position for twenty-four hours.

The albumin is coagulated and falls to the bottom. The quantity present is read off on the scale, each division of which corresponds to 0.1 per cent.

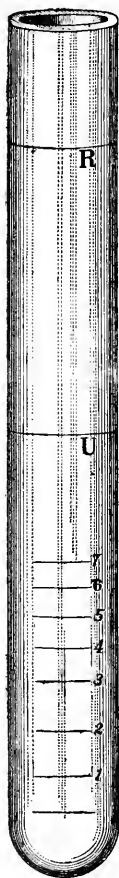


FIG. 23.

<sup>1</sup> When the exact amount is desired, the albumin must be coagulated, separated by filtration, and the precipitate dried and weighed.

*Clinical Significance of Albumin in the Urine.*—

When albumin is found in the urine, the first and important question to decide is, whether it indicates the existence of organic disease of the kidneys. This question may be decided by the temporary or permanent duration of the albuminuria, by the quantity of the albumin present, and by the presence or absence of any other disease which might give rise to it.

The following are the principal pathological states in which albumin appears constantly or occasionally in the urine :

1. Acute and chronic diseases of the kidney.
2. Acute infectious diseases.
3. Obstructed venous circulation, either general or local.

In the first group the albumin in the urine depends on structural changes in the kidneys. In the other groups, structural changes in the kidneys are not necessarily indicated by the albuminuria, but rather some abnormal condition of the circulation or of the circulating fluid.

SUGAR.

Various forms of sugar have been found in the urine, but grape sugar is the only one which possesses clinical interest. It is not present in normal urine in sufficient quantity to respond to the ordinary tests.

Urine containing sugar is usually light in color, of peculiar odor, and with a specific gravity varying from 1025 to 1045. If albumin is present, it must be coagulated and removed by filtration before examining for sugar.

The qualitative tests most conveniently applied are Trommer's, Fehling's, and the Fermentation Test.

*Trommer's Test.*—Pour a small quantity of the urine

into a test tube and add about one-third its volume of liquor potassæ. A ten-per-cent solution of copper sulphate is now added, drop by drop, until no more will dissolve. The mixture is then heated. If the urine contains sugar, a reddish-brown precipitate of copper suboxide is thrown down.

This test is not always reliable, for chloral, uric acid, and bile pigment give the same reaction.

*Fehling's Test.*—The reagent employed consists of two solutions—a copper solution and an alkali solution—which should be kept separate in well-stoppered bottles, and mixed when required. The copper solution is made by dissolving 34.64 grammes of pure crystallized copper sulphate in one hundred cubic centimetres of water and diluting to five hundred cubic centimetres; the alkali solution, by dissolving one hundred and seventy-three grammes of sodium tartrate and one hundred grammes of caustic soda, of a specific gravity of 1034, in five hundred cubic centimetres of water. Equal parts of these solutions should be mixed when required for use.

In applying the test, pour two or three cubic centimetres of the reagent into a test tube, and heat to the boiling point. (If a precipitate occurs, the reagent is useless.) Add an equal volume of urine and boil again. If sugar is present, a reddish-brown precipitate is formed.

*Fermentation Test.*—Fill a large test tube with the suspected urine, then add a small quantity of yeast, close the mouth of the tube with the finger, and invert it in a tumbler containing a considerable quantity of the same urine; remove the finger without permitting air to enter the tube, and support it in an upright position by means of a small wire triangle. Set the appara-



tus in a warm place for twenty-four hours. If sugar be present, it will be decomposed by fermentation into alcohol and carbon dioxide, the gas rising to the top of the tube and displacing the urine; if sugar be absent, no displacement will occur. This test is reliable, provided the yeast is good and the temperature suitable.

QUANTITATIVE ESTIMATION.—The urine used should be taken from that of the twenty-four hours.

Five centigrammes of sugar will reduce ten cubic centimetres of Fehling's fluid prepared as above. In making the estimate, proceed as follows :

Ten cubic centimetres of the fluid are diluted with forty cubic centimetres of water, and placed in a florentine flask. A burette is filled with some of the urine, diluted with nine parts of water. The flask is put upon a tripod, and the fluid boiled. A little of the urine is added from time to time until the light blue color is lost. It is well to remove the flask after each addition of urine, and examine it. Just when the color disappears is a nice point to decide, and upon it depends the accuracy of the test. The amount of diluted urine used is now read off. Suppose that the quantity is ten cubic centimetres. Now, if ten cubic centimetres of dilute urine contain 0.05 gramme of sugar, then one hundred cubic centimetres would contain 0.5 gramme, and one hundred cubic centimetres of the undiluted urine would contain five grammes, or five per cent of sugar.

In diabetes mellitus the percentage of sugar varies from a minimum of one-half per cent to a maximum of ten per cent.

The *fermentation saccharometer* of Max Einhorn gives approximately the amount of sugar contained in a specimen of urine. It is based on the principle that, in alcoholic fermentation, for a given quantity of sugar so

much carbon dioxide is evolved. The apparatus is shown in the accompanying cut. The method of using it is as follows : Shake one gramme of commercial compressed yeast with ten cubic centimetres of the urine to be examined, in a test tube, and fill the long arm of the instrument with the mixture. Set it aside for twenty-four hours in a room of ordinary temperature. As the carbon dioxide is given off it rises to the top and displaces the urine, giving the percentage of sugar present.

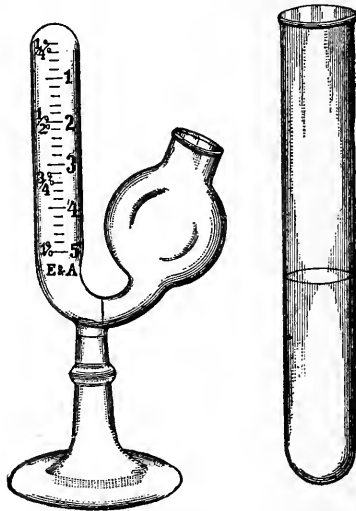


FIG. 24 — Saccharometer.

If the urine contain more than one per cent of sugar, it must be diluted with water and again tested. The degree of dilution must be taken into account in making the reading.

In applying this test, it is well to perform a control experiment with normal urine in order to prove the purity of the yeast. Fill a test tube with the urine and thoroughly mix a little of the yeast with it. Then invert the tube in a tumbler containing some of the same urine. If the yeast is pure, after twenty-four hours

there will be no accumulation of gas at the top of the tube, but perhaps a small bubble of air may be seen.

*Clinical Significance.*—The presence of sugar in the urine indicates that there is an excess in the blood. It may occur temporarily and in small quantity (glycosuria), or continually and in large quantity (diabetes mellitus). Persons who confine themselves largely to a carbohydrate diet may occasionally have sugar in their urine. It is almost constantly present during convalescence from acute infectious diseases, such as typhus fever, diphtheria, pneumonia, etc.

In lesions of certain parts of the central nervous system, sugar is found in the urine: injury to the medulla gives rise to a diabetes which may last for a considerable time.

Glycosuria follows poisoning by carbon dioxide and the administration of ether or chloroform. Gouty patients are subject to glycosuria at intervals.

#### BILE.

When bile is present in the blood, it is excreted by the kidneys. It imparts a dark olive-green tint to the urine. Gmelin's test for the bile pigments consists in placing a drop of the urine on a white surface and a drop of fuming nitric acid alongside of it. As the two come in contact a beautiful play of colors is observed, commencing with green and blue, changing rapidly to violet and red, and finally to yellow or brown.

The presence of biliary acids can be demonstrated by Pettenkofer's test. Add a few drops of a weak solution of cane sugar to a little of the urine in a porcelain capsule. Place the capsule in cold water. Now add an excess of concentrated sulphuric acid, drop by drop, taking care that the temperature is not raised above 70° C. A

beautiful violet color indicates the presence of the bile acids.

In cases of jaundice the bile coloring matter or the biliary acids are present in the urine in greater or less abundance.

#### BLOOD.

The blood cells may be present in the urine (hæmaturia), or only their coloring matter in solution (hæmoglobinuria). Blood may be intimately blended with the urine, and form little or no sediment. Urine containing blood is generally alkaline in reaction, and of a light smoky to a deep-red color. The most reliable test for blood is that furnished by the spectroscope. (For the microscopical examination, see lesson on Clinical Microscopy.) Hæmoglobin produces two characteristic absorption bands in the yellow and green between the lines D and E. If it is reduced hæmoglobin, only one broad band is seen.

The guaiacum test consists in adding a drop of the tincture of guaiacum and a few drops of ozonic ether to a little of the urine in a test tube. The mixture is shaken, and then the ether allowed to collect at the top. If blood be present, the ether will have a blue color. The test cannot be relied upon in the presence of saliva or the salts of iodine, or unless the tincture is freshly prepared.

Blood occurs in the urine after injury to any part of the genito-urinary tract, in acute congestion and inflammation of the kidneys, as a result of poisoning by carbolic acid, in cancer of the bladder, and in acute infectious diseases, such as small-pox, yellow fever, etc. It is present in malaria, scurvy, purpura, and hæmophilia.


## PUS.

Pus in the urine (pyuria) forms a heavy white or yellowish sediment, and the liquid above is generally turbid. The urine is alkaline in reaction, except in cases of pyelitis and pyelonephritis, where it is acid. Owing to the alkalinity, the phosphates are quickly thrown down. It is common to find the earthy phosphates and crystals of ammonio-magnesium phosphate associated with the pus cells (see page 221), in which case the urine has an ammoniacal odor.

When sodium hydrate is added to a deposit of pus, a thick, gelatinous mass is formed. But the test is not accurate. The presence of pus cells should always be demonstrated by a microscopical examination.

In cystitis an abundance of mucus is usually mixed with the pus.

Pyuria indicates suppuration somewhere in the genito-urinary tract. It occurs in pyelonephritis, pyelitis, in cystitis, and in gonorrhœa. Leucorrhœal discharges often contaminate urine. If an abscess opens into the urinary passages, pus suddenly appears in the urine in large quantity, and after a few days diminishes in amount or ceases altogether.



CLINICAL MICROSCOPY.





## LESSON XVIII.

CLINICAL MICROSCOPY—BLOOD, SPUTUM, URINE, VOMIT,  
FÆCES.

### *Examination of the Blood.*

For clinical purposes the microscopical examination of the blood is restricted to determining the number and condition of its cellular elements, and searching for pathogenic bacteria and animal parasites. To obtain a specimen of blood for examination, the tip of the finger or the lobe of the ear, after being thoroughly cleansed, is pricked with a needle, a slide is lightly touched to the apex of the drop of blood pressed out, a cover glass is immediately placed over the drop, and slight pressure made so as to have a thin layer for examination. If the specimen cannot be examined immediately after its removal, a small amount of melted paraffin or flexible collodion, run around the edge of the cover glass, will keep the blood unchanged for several days. To prepare a dried specimen, instead of covering with a cover glass, the end of another slide is lightly drawn across the first one, spreading out the drop in a thin layer, which is allowed to dry spontaneously. In a specimen so prepared the corpuscles are likely to lose their true form. When normal blood is examined under the microscope, three varieties of cells are noted.

**RED BLOOD CORPUSCLES** (Fig. 25).—These appear as flattened, bi-concave discs with a diameter of 0.007 milli-

metre. When the centre of the cell is in focus, the outer rim appears dark ; when the edge is in focus, then the centre appears dark. The cells show a tendency to adhere to each other, forming *rouleaux* or coin heaps. After exposure to the air for a short time, they lose their normal smooth contour and the periphery becomes uneven or crenated.

**BLOOD PLATES.**—These are small, colorless, ovoid bodies, about one-quarter the size of a red blood corpuscle.

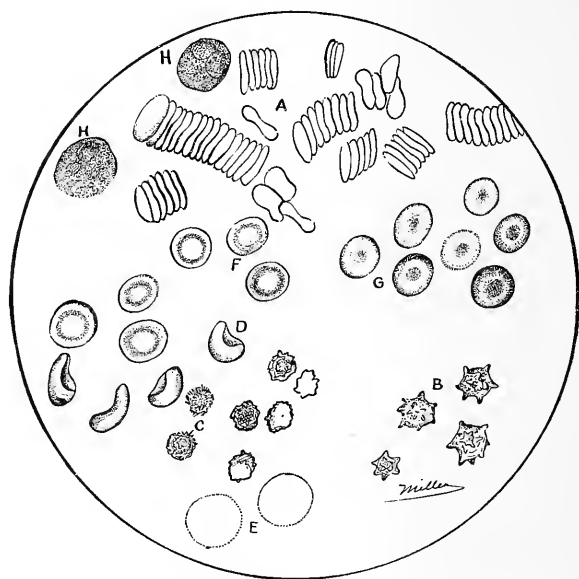


FIG. 25.—Cellular Elements of Human Blood. A, red blood cells forming rouleaux ; B, red blood cells crenated ; D and E, red blood cells having absorbed water ; F and G, red blood cells with surface in focus ; H, white blood cells.

**WHITE OR COLORLESS CORPUSCLES** (Fig. 25).—These appear as transparent cells, with a granular protoplasm. They are mono- or multinucleated. Their size varies from that of the red blood corpuscle to twice its size.

**DIMINUTION IN NUMBER OF RED BLOOD CORPUSCLES** (*Oligocythæmia*).—Normal blood contains from 4,500,000 to 5,000,000 red blood corpuscles to the cubic milli-

metre. In diseased conditions the number may fall to 2,000,000, and in extreme cases to less than 500,000. Marked decrease in number is readily detected with the aid of the microscope; the field is more transparent, the color of the corpuscles is paler,<sup>1</sup> they show their bi-concave form less characteristically, and the *rouleaux* are not as marked. The above appearances are generally sufficient for diagnostic purposes. When the exact

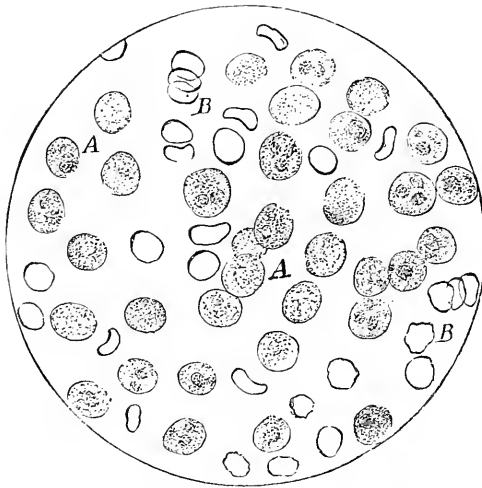


FIG. 26.—Blood from Case of Leucocythæmia. A A, white blood corpuscles; B B, red blood corpuscles.  $\times 300$ .

number is desired, the Thoma-Zeiss or some other counting apparatus is required.

INCREASE IN THE NUMBER OF WHITE BLOOD CORPUSCLES (*Leucocytosis*).—The proportion of white to red corpuscles in the blood varies from 1:400–700. Physiological increase occurs after a hearty meal, when the ratio may be raised to 1:125. In diseased conditions

---

<sup>1</sup> Oligocythæmia is usually associated with deficiency of coloring matter.

(infectious fevers, affections of lymphatic system, etc.) the colorless corpuscles are temporarily increased in number.

When the proportion of 1 : 20 is reached, the condition is called leucocythæmia or leukæmia (Fig. 26). In extreme cases the colorless corpuscles equal or even exceed the red in number.

It is often possible to determine whether the disease is of the lymphatic, splenic, or myelogenic type by observing what is the preponderating character of the leucocytes. When small, colorless cells, about the size of a red blood corpuscle, with a single nucleus and only a faint rim of surrounding protoplasm (lymphocytes), preponderate, then it is lymphatic. If larger cells alone are found, it is splenic. "If many corpuscles of a transitional form are found, nucleated red cells, and especially large white multinuclear corpuscles, there remains no doubt that the bone marrow is the seat of serious changes and the disease is of myelogenic type" (Von Jaksch). By staining a dried specimen of blood with a watery solution of methyl blue, the white cells are brought out more distinctly.

CHANGES IN SIZE, FORM, AND COLOR OF RED BLOOD CORPUSCLES.—At times the blood contains cells that are smaller than the normal red blood corpuscles, but which have the same shape and contain hæmoglobin. These cells are called *microcytes*, and the condition *microcythæmia*. It occurs in all forms of anæmia and has no diagnostic significance.

Colored corpuscles that are larger than normal (*macrocytes*) are also found, and, while they may be present in all anæmias, they are most common in the pernicious type.

Closely associated with variation in size is that of

form. The red blood corpuscle may assume a variety of shapes, as club, dumbbell, anvil, flask, etc., when they are called *poikilocytes* (Fig. 27), and the condition *poikilocytosis*. These cells are found in varying numbers in all anæmic conditions, but are most marked in pernicious anæmia.

As the color of the red blood corpuscles depends upon the amount of coloring matter they contain, a pale color of the blood may be due to a deficiency of hæmoglobin, as well as to a diminution in the number of cells. Both conditions may be appreciated under the microscope with

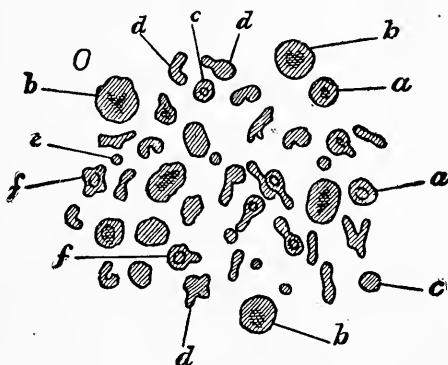


FIG. 27.—Poikilo-, Macro-, and Microcytes (*d, b, c*). *a*, normal red blood cell; *e*, broken-down red blood cell; *f*, nucleated red blood cell (marked anæmia). (After Quincke)

little practice. To estimate accurately the amount of hæmoglobin in the blood, Von Fleischl's hæmometer or Henocque's hæmatoscope is required.

CLINICAL SIGNIFICANCE OF BLOOD CHANGES.—The diagnostic value of changes in the number of white blood corpuscles has already been noted.

In simple anæmia, due to hæmorrhage, or dependent upon diseased conditions associated with a diminution in the number of red blood corpuscles, there is a corresponding decrease in the amount of hæmoglobin.

In chlorosis, although the number of red blood cor-

puscles is not notably reduced, the loss of hæmoglobin is excessive, and the individual cells appear pale and "washed out." Microcytes, macrocytes, and poikilocytes may be found in small number.

Pernicious anæmia is attended with a great diminution in number of all the cellular elements. Individual macrocytes may be found that have an excess of hæmoglobin. Marked poikilocytosis almost always attends the disease.

Free pigment, and white blood corpuscles containing

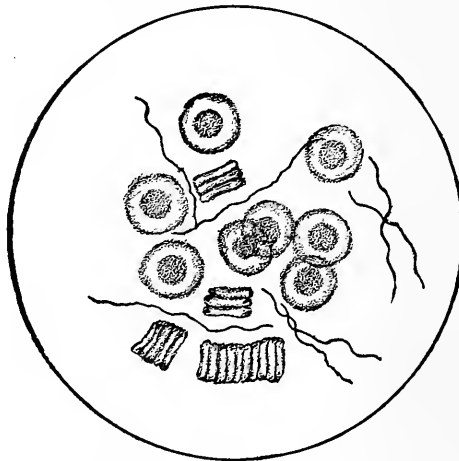


FIG. 28.—Spirillum of Relapsing Fever. (Drawn by J. M. Byron, M.D., Loomis Laboratory.)

pigment granules, are found in the melanæmia of malarial disease.

At the present time a few micro-organisms are recognized in the blood as diagnostic of existing diseased conditions.

**SPIRILLUM OF RELAPSING FEVER.**—To examine for spirilla a drop of blood is placed on a slide under a cover glass. They appear as fine, delicate spiral threads. Their length is about six times the diameter of a red blood corpuscle (Fig. 28). Attention is often called to their

presence in blood by the disturbance their motion causes in the red blood corpuscles. They should be sought for with an oil-immersion lens and Abbe's condenser. It is




FIG. 29.—Bacillus of Anthrax. (Drawn by J. M. Byron, M.D., Loomis Laboratory.)

almost impossible to stain them, as they are destroyed by most staining solutions.




FIG. 30.—Bacillus of Typhoid Fever.  $\times 700$ . (Drawn by J. M. Byron, M.D., Loomis Laboratory.)

**BACILLUS OF ANTHRAX.**—This bacillus appears as a rod, straight or but slightly curved; its length is from

one to two diameters of a red blood corpuscle, and its breadth about one-sixth its length (Fig. 29). They may be joined so as to form chains. They can be seen with-

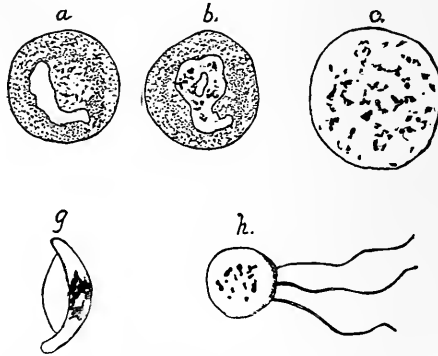


FIG. 31.—*Plasmodium Malariae*. (After Delafield and Prudden.)

out staining, or can be stained with a watery solution of methyl blue (two parts to the hundred). Mice and

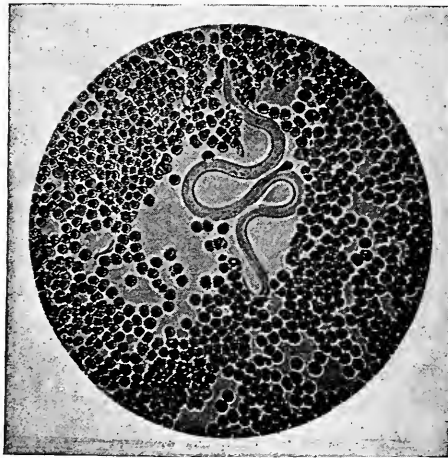


FIG. 32.—*Filaria Sanguinis Hominis*. (Instantaneous photograph by J. M. Byron, M.D.)

guinea-pigs are very susceptible to this disease. If blood from a case of anthrax (wool-sorter's disease) be injected into one of these animals, they show immense numbers of bacilli in their blood in a short time.



BACILLUS OF TYPHOID FEVER (Fig. 30).—This bacillus has been found in blood aspirated from the spleen. (See also Fæces.)

TUBERCLE BACILLUS.—In general miliary tuberculosis, tubercle bacilli are sometimes found in the blood. (For methods of staining, etc., see Sputum.)

PLASMODIUM MALARIÆ.—Amœboid bodies have been found in the blood during a malarial paroxysm by Laveran and other observers. They are found within the red blood corpuscles and also free in the blood. At times they show pigment granules. They stain with methyl blue (Fig. 31).

FILARIA SANGUINIS HOMINIS (Fig. 32).—The filaria is found in the blood of people living in the tropics, or who have become infected there. The worm may give no symptoms beyond the urinary. It is usually absent from the blood during the day.

### *Examination of the Sputum.*

#### CELLULAR ELEMENTS.

To examine for cells, a small portion of sputum may be put on a slide and covered, without staining, or the specimen may be double stained for tubercle bacilli, when all the cellular elements except red blood corpuscles retain their form.

EPITHELIUM.—Squamous cells from the mouth or vocal cords appear as large, flat cells, more or less granular. They may show fissures or folds. Columnar epithelium from trachea, bronchi, and nose is less often present; rarely are the cilia seen.

From a clinical point the “*alveolar*” cells are the most important variety found in sputum. They are polygonal, with a granular protoplasm, and often show granules of pigment (carbon, blood pigment, iron, etc.)

or fat globules ; their nuclei are made more distinct by the addition of acetic acid. The statement that they are the true alveolar cells is now questioned. Their presence indicates that the specimen of sputum is from deeper portions of the respiratory tract, whatever may be their origin.

**WHITE BLOOD CELLS OR PUS CELLS.**—These are always present in sputum. When an abscess ruptures into the lung, or in purulent bronchitis, they may constitute the entire cellular element. They give the characteristic re-

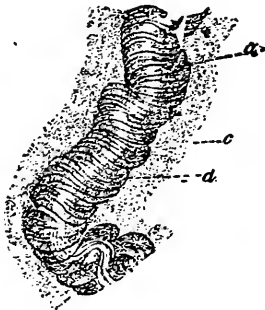

FIG. 33.

FIG. 33.—Curschmann's Spirals. *a*, central thread. (After Curschmann.)

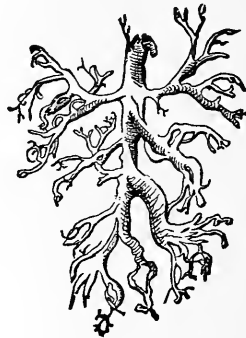


FIG. 34.

FIG. 34.—Bronchial Cast.

action to acetic acid. They often contain particles of pigment.

Liver cells may be found in sputum. They indicate the opening of an hepatic abscess into a bronchus.

**RED BLOOD CORPUSCLES.**—A few are always found. They show their characteristic appearance (see Blood), except when retained in the bronchi for some time, when hæmatoidin crystals may be present.

**CURSCHMANN'S SPIRALS** (Fig. 33).—These can often be seen by the naked eye. When magnified they are found to consist of a white central thread covered by fine

fibres spirally arranged. They occur most often during asthmatic paroxysms and in capillary bronchitis.

**BRONCHIAL CASTS OR FIBRINOUS COAGULA** (Fig. 34).—When the casts are of large size they are readily detected by the naked eye. Microscopic forms occur in pneumonia. In plastic bronchitis “they are long, and the terminal filaments may form a fine network in which epithelium and blood corpuscles are enclosed.”

**ELASTIC TISSUE.**—Elastic fibres occur generally in bundles, but they may retain the form of the alveoli (Fig. 35). They vary considerably in length and thick-

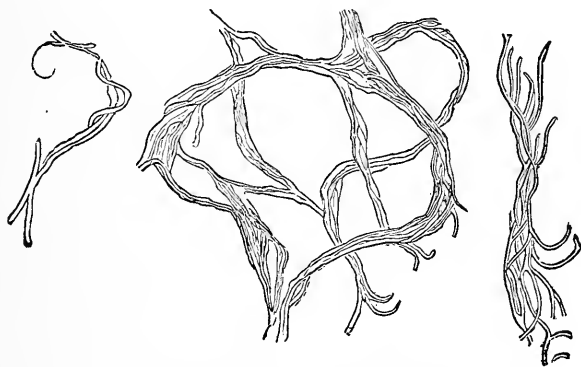


FIG. 35.—Elastic Tissue. (After Von Jaksch.)

ness, are curled, and have dark borders. To obtain these fibres free from mucus, etc., the sputum is put into a test tube, diluted with an equal bulk of water, and ten or fifteen drops of liquor potassæ added. The mixture is then heated below the boiling point for a few minutes, and thoroughly shaken. By this process all the cellular elements are destroyed, but elastic tissue and micro-organisms are not affected. After standing for one or two hours, a small portion of the sediment is placed on a slide, covered, and examined. The presence of elastic fibres merely shows that destruction of lung

tissue is taking place. They are found in tuberculosis, bronchiectasis, pulmonary abscess, and occasionally in pneumonia. In pulmonary gangrene the fibres are generally destroyed in the lung by the ferments that are formed in that disease.

#### PATHOGENIC BACTERIA.

**TUBERCLE BACILLUS.**—In collecting the sputum it is necessary to instruct the patient to expectorate into a clean cup or wide-mouthed bottle, being careful to save that portion which is raised *after coughing*. Frequently specimens are sent for examination that contain only the secretion from the pharynx and posterior nares. The diagnostic value of such sputum is of course *nil*, unless there is tubercular ulceration of these parts also.

**STAINING SOLUTIONS.**—A number of solutions have been proposed, and special advantages claimed for each. The following give satisfactory results and are the most stable :

##### No. 1. *Ziehl-Neelson Fuchsin Solution*—

Fuchsin <sup>1</sup> .....	1 part.
Alcohol, ninety-five per cent.....	10 parts.
Carbolic acid.....	5 “
Water (distilled).....	100 “

Filter and keep in a well-stoppered bottle.

##### No. 2. *For Decolorizing*—

Nitric acid.....	1 part.
Water.....	3 parts.

---

<sup>1</sup> Two kinds of fuchsin are in the market, the *basic* and *acid*. As tubercle bacilli only stain with the aniline dyes in *alkaline* solutions, the *acid fuchsin* is worthless. The bright, crystalline fuchsin is for the most part basic. Acid alcohol also destroys the solution.

No. 3. *For Double Staining*—

Methyl green or methyl blue..... 2 parts.

Water.....100 “

Filter and keep in a dark bottle.

PREPARATION AND STAINING OF SPECIMEN.—The portions of sputum most likely to contain the tubercle bacilli are the small, whitish, opaque masses. One of these is picked up with a clean platinum needle or steel pen in a holder, and transferred to a cover glass. Another cover glass is placed over it, and, after pressing out the excess of sputum, the two glasses are separated by quickly sliding one from the other. A thin film remains on each glass, and is allowed to dry spontaneously. When dry, the cover glass is passed slowly through the flame of a Bunsen burner or alcohol lamp three or four times to fix the film, so that it will not be washed off during the necessary manipulations. Care must be taken that the cover glass is not heated too hot, as then the bacilli lose their affinity for the dye. Either of the following methods may be employed for staining the specimen, but the second will be found more convenient :

I. A small amount of solution No. 1 is put into a watch crystal, and the cover glass floated on it with the film down. The crystal is held over a flame until steam arises (do not allow the solution to boil). After a few minutes the cover glass is removed, and the excess of dye rinsed off in clean water. It is then submerged in solution No. 2 for a few seconds, and immediately rinsed in another vessel of water. If the film still retains a bright-red color, it must be dipped again in No. 2 and immediately rinsed. This can be repeated until it shows only a slight pink or rose tint. If this

step is carried too far, then even tubercle bacilli will be decolorized and the distinctive test destroyed.

The cover glass is now floated for about a minute, film down, on solution No. 3, in another watch crystal, and the excess of dye washed off in clean water. It is then ready to be placed on a slide and examined.

II. The cover glass,<sup>1</sup> film up, is seized in forceps; with a medicine dropper a few drops of solution No. 1 are poured upon it, and heated, by slowly passing through the flame of a lamp or burner several times, until steam arises. After a few minutes the dye is washed off, as in I., and solution No. 2 added. This is allowed to remain for a few seconds only. If the specimen is still too deeply stained, the process can be repeated until the desired rose tint is obtained. Lastly, a few drops of solution No. 3 are allowed to remain on the glass for about a minute. This should be washed off in clean water. The preparation can be dried and permanently mounted in Canada balsam.

The tubercle bacilli can be detected with *good* No. 7 objective, but it is better to use an oil-immersion lens and Abbe's condenser.

The tubercle bacilli, stained red, appear as small, rod-like bodies, slightly curved. While individually they are about one-quarter the diameter of a red blood corpuscle in length, two or three may be so grouped as to appear much longer. Spores contained in them do

---

<sup>1</sup> Instead of using cover glasses to make the preparation, a number of specimens from different portions of the sputum can be placed on a slide, which is then treated as a cover glass, except that the cedar oil is placed directly on the film, no cover glass being used.

<sup>2</sup> Self-retaining forceps, made especially for this purpose, can be obtained from dealers in microscopes and supplies.

not stain, but are seen as clear spots, giving the bacilli a beaded appearance (Fig. 36).

The presence of bacilli in the sputum indicates tuberculosis of the lungs or larynx. But absence of the bacilli does not indicate that there is no tuberculosis, unless repeated examinations have been made. In acute miliary tuberculosis they are rarely found.

ACTINOMYCES, OR RAY FUNGUS.—These appear as bunches of pear-shaped bodies (Fig. 37). They are easily

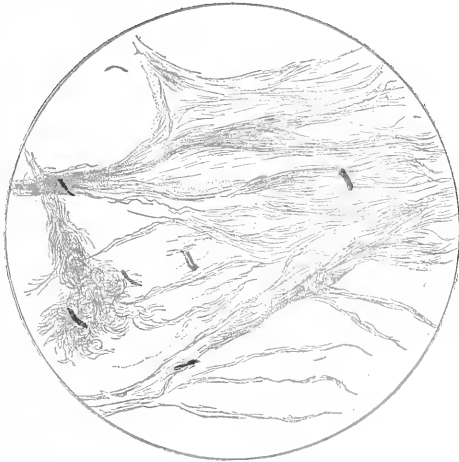

FIG. 36.—Tubercle Bacilli from Sputum.  $\times 900$ . (Drawn by J. M. Byron, M.D., Loomis Laboratory.)

detected without staining. To facilitate the examination, the suspected sputum may be treated with liquor potassæ (see Elastic Fibres above), and the actinomyces looked for in the sediment; or they may be stained by *Gram's* method. Their presence in the sputum indicates the involvement of the lungs by this disease, whose symptoms and early physical signs are similar to those of tuberculosis.

PNEUMOCOCCUS (Fig. 38).—The pneumococci of Friedländer and Fränkel are found in the sputum in croupous

pneumonia. Friedländer's method of staining them is to make cover-glass preparations of the sputum, as in the examination for tubercle bacilli. Treat the film for

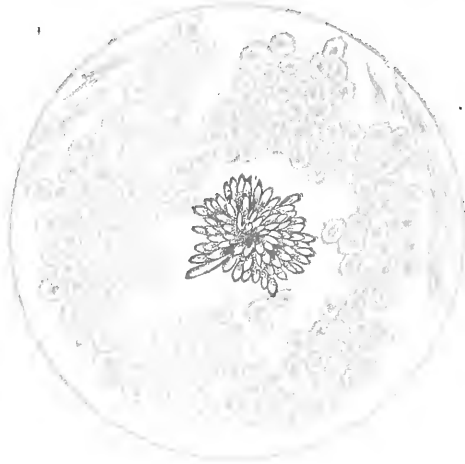


FIG. 37.—Actinomyces, or Ray Fungus.  $\times 850$ . (Drawn by J. M. Byron, M.D., Loomis Laboratory.)

a minute with a one-per-cent solution of acetic acid, after which the specimen is allowed to dry in the air ;

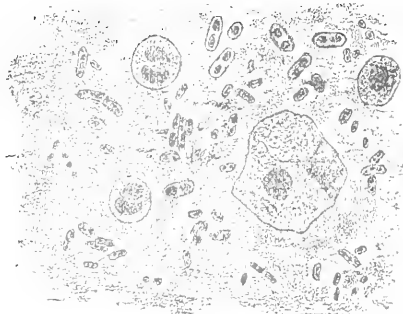


FIG. 38.—Pneumococcus. (After Von Jaksch.)

it is then placed for a few seconds in a saturated aniline-water-and-gentian-violet solution ; finally the dye is washed off with water and the cover glass mounted on a



slide. Fränkel treats the cover-glass preparation with a weak, watery solution of methyl blue. Micro-organisms, morphologically identical with the pneumococcus, have been found in the saliva of healthy persons and in the sputum of cases of bronchitis.

**ECHINOCOCCUS.**—Hooklets and portions of the cyst wall (Fig. 39) are found in the sputum when hydatid cysts in the lungs, pleura, or liver have ruptured into a bronchus.

**AMCEBÆ COLI** may be found in the sputum if an hepatic abscess has opened up through the lungs. (See Fig. 66.)

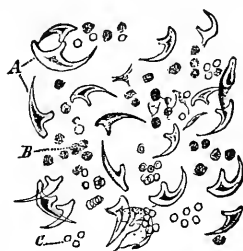

FIG. 39.—Echinococcus Hooklets.

### *Urine.*

The microscopical examination of the urine deals almost exclusively with those elements that form the sediment. The urine is allowed to settle in a conical glass; after a few hours a drop of the sediment is removed with a pipette and placed on a slide, under a cover glass, for examination. The constituents of the sediment may be divided into two groups: 1. Non-organized. 2. Organized.

#### I. (a) AMORPHOUS DEPOSITS.

**URATES.**—These usually appear as pale-pink, brown, or dark-red granular masses (Fig. 40), although at times the urate of soda has a globular form from which sharp spikes of uric acid project (Fig. 41). Urate of ammonia also at times assumes a spherical form, with or without small projecting spicula (Fig. 42).

The urates are held in solution in normal urine at or slightly below the body temperature. Their precipitation is favored by (a) acidity, (b) concentration, and (c)

cooling of the urine. They appear in the urine in disorders of the digestive tract, and when the ingestion of nitrogenous food is beyond the needs of the body; in febrile conditions; and in diseases of the heart and lungs that prevent proper oxygenation. Too little exercise, close rooms, and excessive use of wine and malt liquors predispose to their appearance in the urine. Their persistent presence without *adequate* cause is one of the diagnostic points of urinary calculi.

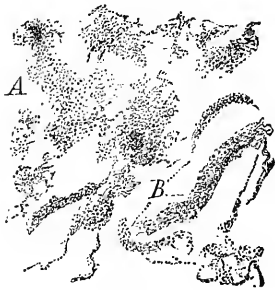

FIG. 40.

FIG. 40.—Urate of Soda. A, amorphous granules in clusters; B, granules in strings, sometimes mistaken for granular casts.  $\times 250$ .

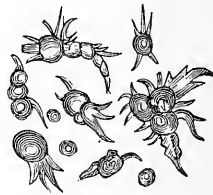

FIG. 41.

FIG. 41.—Urate of Soda with Spicula.

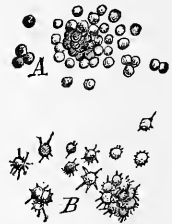


FIG. 42.

FIG. 42.—Urate of Ammonia. A, clusters of brown spherules; B, isolated spherule with spicula—"the chestnut-burr" crystals.  $\times 250$ .

**CALCIUM PHOSPHATE AND CALCIUM CARBONATE.**—These are found in alkaline urine only. Calcium phosphate occurs as minute granules and small spherical masses or as angular particles. Calcium carbonate is almost always amorphous. Both are usually associated with the triple phosphates.

**FAT.**—When fat occurs in the urine in small quantity, the condition is termed *lipuria*. The urine is turbid, but clears up on shaking with ether. The microscope discloses globules of varying size which strongly refract light.

In *chyluria*, fat is present in large quantity and in a

state of molecular subdivision. The urine has a milky appearance. Chylous urine most frequently depends on invasion of the urinary tract by the *Filaria sanguinis hominis*.

(b) CRYSTALLINE DEPOSITS.

URIC ACID.—Crystals of uric acid assume a great variety of forms, but as a rule they can be recognized by their color; the lozenge-shaped crystal is the commonest form. If doubt exists as to the nature of an unusual form, dissolve the crystals by adding a drop of caustic potash to the specimen, and then acidulate with a little hydrochloric acid; if they are uric acid, they will recrystallize in one of the commoner forms (Fig. 43). All crystals of uric acid, as they appear in the urine, have the characteristic *yellowish-red* color.

Uric acid appears in the urine under the same conditions that were mentioned for urates, with which it is usually associated.

Deficient action of the skin, from any cause, produces an excess of uric acid in the urine. It has a strong tendency to form around any small concretions in the urinary tract, giving rise to uric acid calculi.

CALCIUM OXALATE.—This is generally deposited as small octahedra which strongly refract light, and more rarely in the hour-glass or dumbbell form (Fig. 44). “The prism of the triple phosphates sometimes appears octahedral, and the diamond-shaped crystals of uric acid

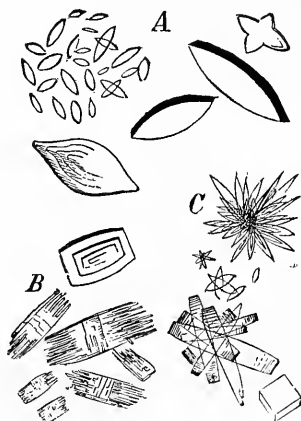


FIG. 43.—Uric Acid. A, the most common forms; B, disintegrated crystals; C, formation of stellate masses.

are occasionally so small as to simulate the oxalates. Acetic acid dissolves the crystals of triple phosphates, and caustic potash causes the uric acid to disappear, while oxalate of lime resists both reagents." Crystals of oxalate of lime appear in the urine after eating apples, pears, cauliflower, and the different varieties of sorrel,



FIG. 44. — Calcium Oxalate.  $\times 250$ .

and after the administration of rhu- barb; it is often present in diabetes mellitus, catarrhal icterus, gout, hypo- chondria, and after epileptic seizures. It is common in cases of mental ex- haustion from overwork and excite- ment. The term *oxaluria* has been ap- plied to that condition which, in addi-

tion to the abundant and persistent presence of calcium oxalate crystals, has a well-marked train of nervous and dyspeptic symptoms with a tendency to hypochondriasis. The mere finding of a few oxalate of lime crystals is not sufficient for this diagnosis.

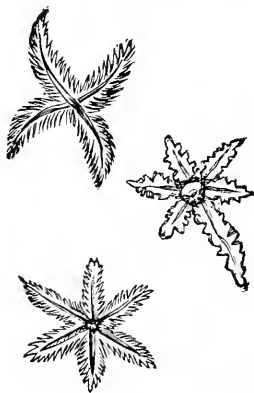


FIG. 45.

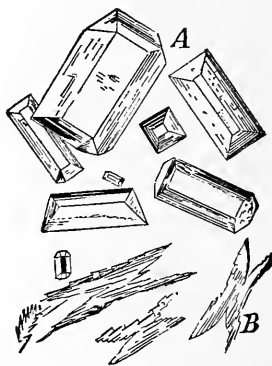


FIG. 46.

FIGS. 45 and 46.—Ammonio-Magnesium, or "Triple" Phosphates.  $\times 250$ .

AMMONIO-MAGNESIUM, OR "TRIPLE" PHOSPHATES.— These crystals are found only in alkaline urine. During alkaline fermentation, urea is decomposed with the for-

mation of ammonium carbonate; this combines with the magnesium phosphate present to form the so-called triple phosphate crystals. When slowly formed the crystals assume the shape of triangular prisms with bevelled edges (Fig. 46 A), but when produced rapidly they have a feathery outline (Figs. 45 and 46 B).

CALCIUM PHOSPHATE, although usually amorphous, may be deposited as angular crystals (Fig. 47).

The precipitation of these salts in crystalline form does not necessarily indicate that they are excreted in *excessive* quantities, but shows that there has been some change in the reaction of the urine, due to alteration in some of its constituents which ordinarily retain these salts in solution. Excessive mental work or anxiety, and certain forms of dyspepsia, reduce the acidity of the urine and favor the precipitation of the earthy phosphates. Alkaline fermentation of the urine in the urinary tract causes their deposition on the mucous membrane and the subsequent formation of calculi.

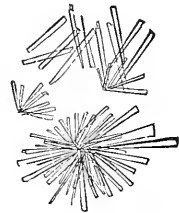


FIG. 47.—Calcium Phosphate.

CRYSTIN.—This body is occasionally found in the urine in crystalline form; it occurs as six-sided plates (Fig. 48).

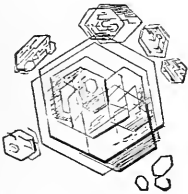


FIG. 48.—Cystin.  $\times 250$ .

Little is known of the conditions that cause its elimination by the kidneys. It is often hereditary. Brieger has called attention to the relation of certain ptomaines in the intestinal tract

and the appearance of cystin in the urine. It may lead to the formation of calculi.

LEUCIN, TYROSIN.—The urine may contain large quantities of these substances. Leucin appears in the form of spheres, resembling globules of fat (Fig. 49). When

these spheres are large they may show radiating lines and concentric rings.

Tyrosin crystallizes in the form of fine needles arranged as sheaves (Fig. 50). These bodies appear in those diseases in which oxidation is impaired, such as acute yellow atrophy of the liver, typhoid fever, small-pox, and in hepatic diseases generally.

XANTHIN rarely occurs in the urine. It is of interest clinically only as it may form calculi.

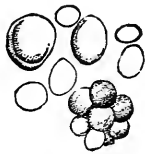

FIG. 49.—Leucin.  $\times 250$ .



FIG. 50.—Tyrosin.  $\times 250$ .

## II. ORGANIZED.

MUCUS.—In healthy urine it is almost impossible to detect, microscopically, the small amount of mucus that is present, as its refractive power is the same as that of the urine. When it holds cells or crystals its presence may be inferred from the arrangement of these bodies. When excessive in amount it is often seen as transparent threads or cylindroids. Pus is changed by alkaline fermentation to a condition that resembles mucus. If small mucus threads are found in markedly alkaline urine with an ammoniacal odor, this fact must be considered.

PUS.—In acid urine pus cells have a distinct, circular outline, the protoplasm is granular, and the nuclei are

more or less apparent. If acetic acid is allowed to flow under the cover glass, the corpuscles become slightly enlarged, they lose their granular appearance, and the nuclei become more prominent (Figs. 51 and 52). If the urine has undergone marked alkaline fermentation, the pus cells are destroyed (see Mucus, above).

Pus' in the urine may come from any part of the urinary tract, or from the rupture of an abscess into it. When its origin is in the kidney, the normal reaction of the urine is retained, while in suppurative inflammation of the bladder the reaction is alkaline when voided, or it soon becomes so. The epithelial elements associated with the pus cells often decide what portion of the tract



FIG. 51.—Pus Corpuscles.




FIG. 52.—Pus Corpuscles treated with Acetic Acid.

is involved. In women the accidental contamination of the urine with pus from the vagina and uterus must be considered. Vaginal epithelium is then usually present. The distinctive features of gonorrhœal pus will be considered under Micro-organisms (page 226).

**BLOOD.**—Red blood corpuscles are recognized by their size, color, and the peculiar change of light and shade in focussing. Frequently they become globular and pale,

<sup>1</sup> Frequently in examining urine a very few corpuscles, having all the appearances of pus cells, are found. These are claimed to be mucus corpuscles. Some observers affirm that while they react to acetic acid the same as pus cells, still if they exhibit only one or two nuclei they are mucus corpuscles. Their true character has an important financial bearing to persons under examination for life insurance.

or their edges become crenated and the protoplasm granular (Fig. 25). They are rapidly destroyed by ammoniacal changes in the urine. Their presence indicates hæmorrhage into the genito-urinary tract. The diseases

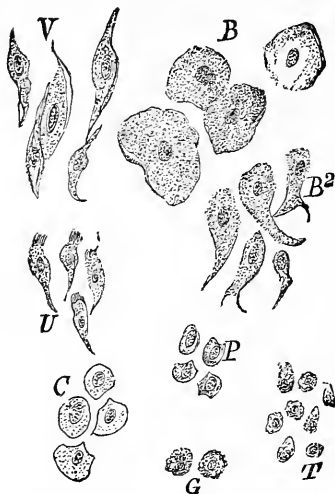


FIG. 53.—B, superficial layers of bladder; B<sup>2</sup>, deeper layers of bladder; V, cells from vagina; U, ciliated cells from cervix uteri; C, from uterine mucosa; P, from pelvis of kidney; T, from tubules of kidney; G, from prostatic portion of urethra.

of the kidney in which they most frequently occur are congestion, acute nephritis, calculus, cancer, and embolism. They may be found also in certain blood states, as purpura, scurvy, etc. In women the menstrual discharge may contaminate the urine. The other organic constituents (epithelium, casts, etc.) which may be associated with the blood corpuscles aid in determining their origin.

#### EPITHELIUM (Fig. 53).—

Three principal varieties of epithelial cells are found in the urine: *squamous* cells, from the bladder, vagina, or orifice of the urethra; *columnar* cells, from the deeper layers of the pelvis of the kidney, or from the uterus—they may be ciliated when from the uterus; and *spherical* cells, which have their origin in the tubules of the kidney, or from the deeper layers of the mucous membrane of the pelvis of the kidney, of the ureter, bladder, or urethra. Renal epithelium has a polygonal, well-defined outline, is slightly larger than a pus cell, and has a large oval nucleus. The presence of such cells in a cast at once determines their origin. Tailed cells from the superficial layer of the pelvis of the kidney are sometimes found.



**SPERMATOZOA.**—When found in urine, these bodies have the characteristic tadpole appearance (Fig. 54), but they no longer possess any power of motion.<sup>1</sup> They are present immediately after all seminal emissions; often after defecation, especially if constipation is extreme; and after epileptic seizures. They have been found in the urine of women after coitus. They are occasionally found in typhus and typhoid fevers.

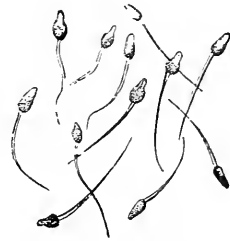

FIG. 54.—Spermatozoa.  
× 500.

**CASTS.**—These are moulds of the tubules of the kidney, formed by the effusion of materials that coagulate spontaneously. They often enclose formed elements. Their diameter varies from  $\frac{1}{3000}$  to  $\frac{1}{15000}$  inch, or even smaller.

*Hyaline.*—Hyaline casts are transparent, structureless cylinders, often invisible with strong illumination. Their extremities are generally rounded or slightly

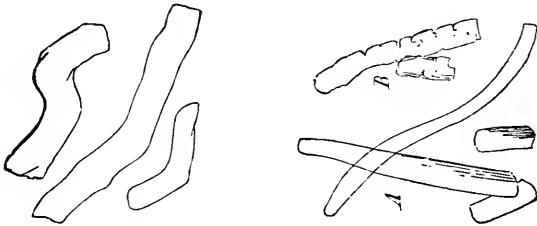


FIG. 55.—Types of Hyaline Casts.

clubbed, but, from a tendency to fracture transversely, fragments are often found with straight ends (Fig. 55).

<sup>1</sup> In medico-legal cases (rape) the vaginal discharge should be examined for spermatozoa. Pieces of clothing supposed to be stained with seminal fluid are macerated with distilled water in a test tube, for a short time; after shaking thoroughly, the pieces are removed, the sediment allowed to settle and examined.

Small hyaline casts are found in the acute (inflammatory) stage of nephritis, when they are generally associated with other varieties, and the urine is markedly albuminous. Large hyaline casts are found in the atrophic stages of all forms of Bright's disease. Hyaline casts may have pus cells or renal epithelium adhering to their surface. At times a few hyaline casts are found in urine that is non-albuminous and contains no other evidence of kidney disease. In such cases they have no diagnostic value.

*Waxy* casts are a variety of hyaline. Generally they are of yellowish color. At times they give the

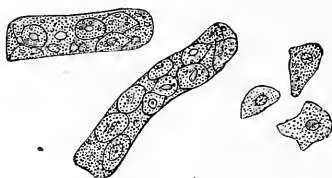


FIG. 56.—Epithelial Casts.



FIG. 57.—Granular Casts.

amyloid reaction with iodine and iodide of potash, but this is not pathognomonic.

*Epithelial.*—These show the characteristic epithelium of the tubules of the kidney. The cells may have a normal appearance, or are more or less broken down and degenerated. The casts may be composed entirely of renal epithelium, or a few cells only may be entrapped in a hyaline cast (Fig. 56).

Epithelial casts are present in desquamative nephritis. When pus cells are mingled with renal epithelium in casts, the inflammatory changes in kidney are extensive.

*Granular.*—Granular casts vary greatly in size, color, and appearance. Their outline is well marked, and one or both ends generally rounded (Fig. 57). The granular

matter may be composed of the debris of epithelium, pus, or blood. In the early stages of nephritis they are associated with epithelial casts. When granular casts only are present, they indicate the large, white kidney, or that extensive destruction of the parenchyma of the kidney is taking place.

*Fatty.*—The oil globules may be in degenerated epithelium (a variety of granular casts), or may themselves constitute the cast (Fig. 58). This variety is indicative of the large white kidney, or the contracted kidney with marked fatty degeneration.

*Blood* (Fig. 59).—The presence of a few red blood cor-



FIG. 58.—Fatty Casts.

FIG. 59.—Blood Casts.

puscles in an epithelial cast indicates the acute stage of kidney disease. When they constitute the entire cellular element they are diagnostic of renal hæmaturia. When they appear without other evidences of acute congestion of the kidney, or traumatism, disease of the renal blood vessels, especially amyloid or fatty degeneration of the Malpighian tuft, must be considered.

Casts composed of micrococci are often present in septic embolism of the kidney.<sup>1</sup>

<sup>1</sup> The microscopical appearance of extraneous matter, as hair, fibres of silk, linen, cotton, etc., should be so well known as not to be mistaken for casts.

## MICRO-ORGANISMS.

NON-PATHOGENIC.—These include those forms found in urine that has undergone fermentation. When present in freshly voided urine they indicate that this process is going on in the urinary tract.

The most common forms are: *Torula cerevisiæ* (Fig. 60), found in diabetic urine; *Penicillium glaucum* (Fig. 61); a small form of *Sarcina* (Fig. 62); and *Micrococcus ureæ*.

PATHOGENIC *Gonococci*.—These are spheroidal bodies, occurring in pairs (diplococci) or groups of pairs.

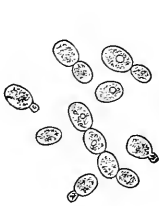


FIG. 60.—*Torula Cerevisiæ*.

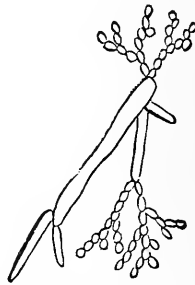


FIG. 61.—*Penicillium Glaucum*.  
× 300.

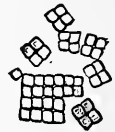

FIG. 62.—*Sarcinæ*.  
× 300.

Between the associated cocci there is a slight space. Their opposing sides are somewhat flattened, giving the characteristic coffee-bean appearance. They must be stained to be demonstrated.

A drop of pus from the urine, or direct from the meatus urinarius, is smeared upon a cover glass, which, after it has dried, is passed slowly through a flame to fix the film. A few drops of a solution of methyl blue (see Sputum) are placed on the specimen for a few minutes, the excess of dye is washed off, and the specimen examined with an oil-immersion lens or a No. 7 objective. Gonococci, stained blue, appear free on the epithelium and in the

pus cells (Fig. 63). The diagnostic feature is the presence of the gonococci *in the pus cells*. In the urethra *non-pathogenic* diplococci are sometimes found. They are slightly larger than gonococci, and may exist free or in the epithelial cells, but are *not* found in the pus cells.

Gonococci in pus, whether urethral, vaginal, or conjunctival, are diagnostic of gonorrhœal infection.

*Tubercle Bacilli* are indicative of tubercular ulceration somewhere along the genito-urinary tract. (For method of staining, etc., see Sputum.)



FIG. 63.—Gonococci. (After Sternberg.)

*Actinomyces* may appear in the urine when the genito-urinary tract is primarily or secondarily involved.

#### PARASITES.

*Filaria Sanguinis Hominis* (Fig. 32, page 206).—These bodies often appear in the chylous urine of patients whose blood is infected. In addition to the oil globules, pus and blood may be found in the urine.

*Echinococci*, *hooklets*, and portions of cysts may appear in the urine when a hydatid cyst has formed in the genito-urinary tract or ruptured into it from neighboring organs (Fig. 39, page 215).

*Vomit.*

The vomit may contain elements from the œsophagus and respiratory tract besides the contents of the stomach. The microscopical examination may show the presence of food masses, such as muscle fibres, with well-marked striations, oil globules, needle-shaped fat crystals, connective-tissue fibres, starch granules more or less altered, and vegetable cells. These, of themselves, are of no diagnostic value, but may give a hint as to the rapidity of the digestive process.

RED BLOOD CORPUSCLES, showing their characteristic appearance, may be found in the vomit where hæmorrhage into the stomach has been



FIG. 64.—Hæmin Crystals.

so great and its expulsion so rapid as not to allow the gastric juice to act upon them, or when blood is added to the vomited matter above the stomach. When acted on by gastric juice the corpuscles are destroyed, and their contents appear as masses of reddish-brown pigment (coffee-grounds).

To determine the presence of blood in such cases, some of the suspected matter is dried, ground into a powder, and placed on a slide. A few crystals of common salt are added, and a cover glass put on. A little glacial acetic acid is allowed to flow under the cover glass, and the slide is heated (not to boiling) for a few minutes. The salt is dissolved out in a little water. If the specimen contains blood, small, dark, rhombic crystals of hæmin will be seen (Fig. 64).

PUS CELLS are also destroyed by gastric juice. They only appear in the vomit when there is a suppurative

inflammation of the stomach walls, or when a large abscess has ruptured into the stomach.

The EPITHELIAL CELLS found in the vomit are of the squamous or columnar type. Squamous cells come from the œsophagus or mouth; columnar cells from the gastric mucous membrane.

SARCINÆ VENTRICULI, having the characteristic "wool pack" appearance (Fig. 62, page 226), are often found. They are present when the stomach retains its contents for a long time, especially in dilatation of the organ.

TUBERCLE BACILLI, when found in the vomit, indicate a tubercular ulceration in the food passages or contamination of the vomit by sputum.

#### *Fæces.*

The number and character of food residues found in the fæces depend upon the diet. In a general mixed diet there will be found vegetable cells, starch granules, muscle fibres, elastic and white fibrous tissue, and fat globules; while in the stools of children and adults fed exclusively upon milk large quantities of fat and crystals of fatty acids will be found.

RED BLOOD CORPUSCLES do not present their characteristic form unless a large quantity of blood has been thrown into the intestines and rapidly voided, or its origin is in the lower portion of the large intestine, as from hæmorrhoids (in women contamination with the menstrual flow must be considered). When blood has been retained for some time, no corpuscles can be detected, but it is changed to a "tarry" or dark-brown mass (see Vomit).

PUS CELLS are rarely present in healthy stools. In simple intestinal catarrh only a few are present. When found in large numbers they are due to ulceration of

some portion of the intestinal tract. Pure purulent discharges take place only when an abscess has ruptured into the intestines, and occasionally in dysentery.

EPITHELIUM, in small amount and more or less altered, is always found in healthy fæces and has no diagnostic significance. When found in large quantity it is indicative of intestinal catarrh.

#### MICRO-ORGANISMS.

Large numbers of micro-organisms are found in the fæces; most of them are *non-pathogenic*. Some which




FIG. 65.—Cholera Bacilli from Fæces.  $\times 900$ . (Drawn by J. M. Byron, M.D., Loomis Laboratory.)

are found in unhealthy stools are also present in the healthy—they seem to be concomitants, and not excitants, of the diseased condition. They have no diagnostic value.

The pathogenic bacteria are the—

**CHOLERA BACILLUS** (*Comma Bacillus*).—This appears as a short, curved rod that is thicker than the tubercle bacillus (Fig. 65). Two bacilli may be so placed as to give the peculiar S-like appearance. They are found



most abundantly in the free mucous flocculi of the rice-water discharges. A cover-glass preparation may be made and stained with methyl blue, as for gonococci.

**BACILLUS OF TYPHOID FEVER** (*Bacillus of Eberth*).—This appears as a rod with rounded extremities; its length is about one-third the diameter of red blood corpuscles, and its width one-third its length (Fig. 30, page 205). Spores are sometimes seen in the rods. They stain with a watery solution of methyl blue.

The bacilli of cholera and typhoid fever, as they appear in the fæces, cannot be differentiated by their appearance, or by their reaction with the staining solutions, from other bacteria having similar form. To decide their true nature it is necessary to make cultures.

**TUBERCLE BACILLI** may be found in the stool when there is tubercular ulceration of the intestine, or when tubercular sputum has been swallowed.

#### ANIMAL PARASITES.

**AMŒBÆ COLI.**—These are cellular bodies, three to four times as large as a pus cell, having a distinct nucleus. Their protoplasm is hyaline or coarsely granular and may contain vacuoles. When seen immediately after voiding, they often show amœboid movements (Fig. 66). They have important diagnostic significance in relation to dysentery and abscess of the liver.

The ova of only certain intestinal worms will be considered.

**DISTOMA HEPATICUM.**—The eggs are oval, 0.13 mm. long by 0.08 mm. broad. One extremity is broader than the other and opens with lid; the shell is brown and is composed of two layers.

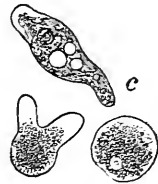


FIG. 66.—Amœbæ Coli. (After Von Jaksch.)

**TÆNIA SOLIUM.**—The eggs are nearly spherical, 0.036 mm. long by 0.03 mm. wide. The outer covering or shell has radiating lines. When fully formed, hooklets can be demonstrated on the embryo.

**TÆNIA MEDIOCANELLATA.**—The eggs are slightly more oblong than those of the solium, and exhibit a primordial yolk membrane. The embryo does not show hooklets.

**BOTHRIOCEPHALUS LATUS.**—The eggs are oval, 0.07 mm. long by 0.045 mm. broad; the shell is brown, and

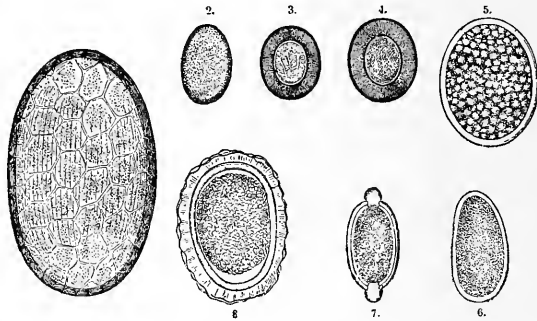


FIG. 67.—Eggs of Intestinal Ova. 1, Egg of *Distoma hepaticum*; 2, *Distoma lanceolatum*; 3, *Tænia solium*; 4, *Tænia mediocanellata*; 5, *Bothriocephalus latus*; 6, *Oxyuris vermicularis*; 7, *Trichocephalus dispar*; 8, *Ascaris lumbricoides*. (After Strümpell.)

one end is small, opening with a lid. The protoplasm of the egg is divided into small masses of uniform size.

**TRICHOCEPHALUS DISPAR.**—The eggs are characterized by a well-marked swelling at each end of the shell.

**ASCARIS LUMBRICOIDES.**—The eggs are nearly spherical, 0.06 by 0.07 mm.; the shell is of a brownish-yellow color, and encloses granular contents.

**ANCHYLOSTOMA DUODENALE.**—The eggs are oval, 0.05 by 0.06 mm., and are enclosed within a shell. They often contain daughter-cells.

MECHANICAL AIDS TO  
DIAGNOSIS.



## LESSON XIX.

MECHANICAL AIDS IN THE DIAGNOSIS OF THE DISEASES  
OF THE RESPIRATORY AND VASCULAR ORGANS—  
STETHOSCOPE—STETHOMETER—CYRTOMETER—  
CARDIOMETER—LARYNGOSCOPE—  
SPHYGMOGRAPH.

I WILL now briefly describe the different instruments which may be employed as aids in physical diagnosis, and give some rules to guide you in their use.

### *Stethoscope.*

In the diagnosis of diseases of the respiratory and vascular organs, a *stethoscope* is not only often convenient, but at times absolutely essential. A great variety of stethoscopes have been devised, each inventor claiming for his own instrument some superiority in principle or shape. They may all be referred to two general classes, viz., flexible and solid. For general use I would recommend the binaural stethoscope devised by the late Dr. Cammann, of this city. It has two flexible tubes fitted into the cup that is applied to the surface. These are continuous with two metal tubes so curved that they fit into each ear, and are connected

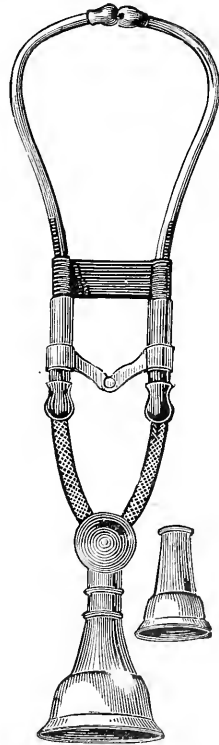


FIG. 68.—Stethoscope.

with each other by means of a metal bar with a toggle joint in its centre. An elastic band holds them in position (see Fig. 68).

It requires some practice to become adepts in its use. But, once accustomed to it, you will find it has no superior. It closes both ears to all but the desired sounds.

In selecting a stethoscope you should be careful that the ear pieces exactly fit your ears. If they are too large, they will cause pain; and if too small, they will produce a roaring noise which will obscure the sounds you desire to examine.

In cardiac auscultation, and in determining abnormalities of the blood vessels, this instrument will be found almost indispensable; for pulmonary auscultation it is only occasionally of service.

#### *Stethometer.*

The simplest way to ascertain the circular measurement or amount of motion of the chest or abdomen is by means of an ordinary pocket tape. But Dr. Quain has devised an instrument for this purpose, called the stethometer.

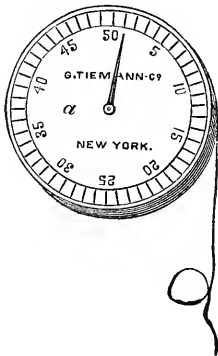


FIG. 69.—Stethometer.

It consists of a brass box with a dial, and an index which is moved by a rack attached to a silken cord. One revolution of the index indicates an inch of motion, the intervening space being graduated, as shown in Fig. 69.

It may be employed when the patient is in a standing, sitting, or recumbent posture. *The mode of its application* is as follows: Place the box on the sternum with the index pointing to the median line; carry the silken

cord around the chest to the spines of the vertebræ, where it should be held firmly with the thumb or finger.

The amount of motion of the side under examination, from the end of an expiration to the end of a full inspiration, will be accurately shown by the index.

This instrument is of great utility in determining the exact amount of difference in the expansion of the two sides of the chest, as well as for determining the amount of local expansion in any region.

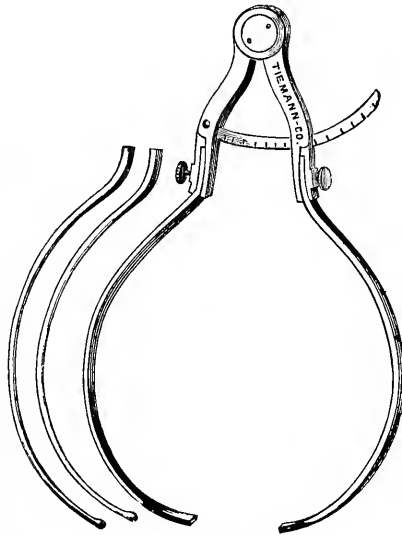


FIG. 70.—Cyrtometer.

### *Cyrtometer.*

It frequently happens that the exact shape of the chest or abdomen is far more important than the amount of motion. An instrument to determine this was made in 1860 by G. Tiemann & Co. from suggestions given them by Prof. Austin Flint. It resembles in principle the cyrtometer of Woiller, invented in 1857.<sup>1</sup>

<sup>1</sup> Vide Gazette des Hôpitaux, 1857, p. 134.

It consists of an ordinary compass with short arms; slits are made in the ends of these arms to receive narrow strips of lead, which are made long enough to encircle the chest and meet in the median line in front; they are fastened into the arms of the compass by means of thumb screws. An indicator is attached to the centre of one arm, and slides through the other; this is arrested at any point by means of a thumb screw (Fig. 70).

When applied, the arms of the compass are pressed on each side of the vertebral column and fastened by means of the thumb screw pressing on the indicator; the strips of lead are moulded so as to fit any depression or elevation of the chest; the thumb screw is then loosened and the instrument removed. After its removal, bring the arms of the compass together until they reach the same notch in the indicator as when the instrument was applied to the chest; fasten it with the thumb screw, place it upon paper, and you can easily trace the exact shape of the chest.

#### *Cardiometer.*

The cardiometer was devised by the late Dr. Cammann to determine accurately the distance of the apex beat from the median line. It resembles a pocket knife in shape, with one extremity rounded and the other slightly pointed. On its handle is a scale of inches which may be used as an ordinary rule. Enclosed in the handle is a graduated blade, which runs its whole length and is attached by a pivot to the rounded extremity. This blade is pointed at its free extremity and has a slit through its centre. A small arm is connected to one side of the handle, by means of a pivot, near its rounded extremity; the free end slides along



the slit in the blade and has a small indicator attached to it. As the instrument is opened the indicator marks the number of inches between the extremity of the blade and the extremity of the handle (see Fig. 71).

In using this instrument, place the pointed extremity of the handle on the median line and open the blade to

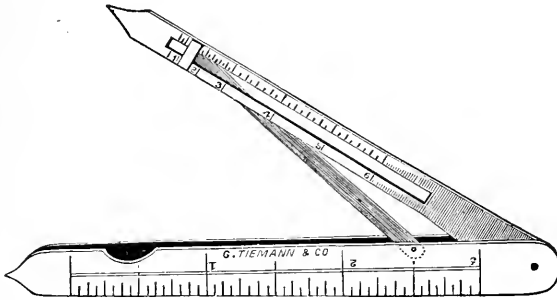


FIG. 71.—Cardiometer.

a point corresponding to the apex beat. By reading the scale, the distance of the apex beat from the median line is determined.

In recording cases, and in accurately determining slight changes in the position of the apex beat, this instrument will be found of service.

### *Laryngoscope.*

The apparatus consists of three parts—the throat mirror, the head or reflecting mirror, and the source of

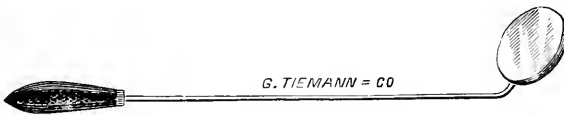

FIG. 72.—Laryngeal Mirror.

illumination. It is used to examine the nose and upper air passages.

The *throat* or *laryngeal mirror* is a small mirror

mounted in a German-silver frame and attached to a delicate handle from six to seven inches long. It is made in six sizes, varying from three-eighths of an inch to one inch in diameter. There are several different shapes, but the round mirror is best adapted to general purposes. For laryngoscopic work the mirror is attached to the handle at an angle of  $135^{\circ}$ ; for rhinoscopic, at an angle of  $105^{\circ}$ .

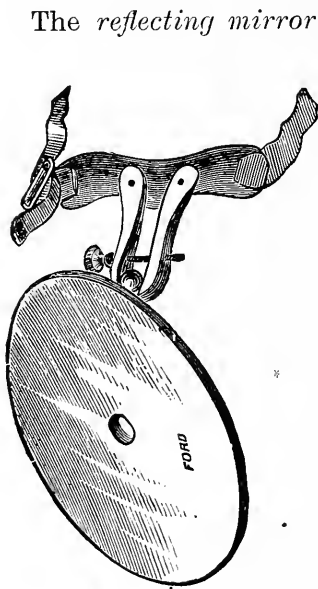


FIG. 73.—Head Mirror.

The *reflecting mirror* is a large concave mirror, perforated in its centre so that the illuminating and visual rays will be in the same axis. It should not be too large, or its weight will become objectionable. The mirror is attached to a head band by means of a ball-and-socket joint, to give perfect freedom of motion.

*Source of Illumination.*—Sunlight is to be preferred because of its whiteness, but the Argand burner or a coal-oil lamp may be used. Sajous states that a small piece of camphor dissolved in the oil

will make the light whiter. A condenser may be used to increase the intensity of the light.

**METHOD OF EXAMINING THE LARYNX.**—So adjust the reflecting mirror that the opening in its centre corresponds to the line of vision, and that the light is thrown into the patient's mouth. Then direct the patient to catch the tip of his tongue in a napkin and draw it well forward. Take the throat mirror, previously warmed over the lamp (to prevent the condensation of moisture

on its surface), lightly in the right hand, and introduce it into the back of the throat with its face directed downward. It should not touch the base of the tongue, or retching may be excited. Let the posterior surface of the mirror rest against the base of the uvula, and push it upward and backward toward the vault of the pharynx. The plane of the mirror should form an angle of about  $45^{\circ}$  with the horizon.

If the throat is irritable, the mirror should be removed and the patient allowed to rest a few minutes before another attempt at examination is made. It may be necessary to produce local anæsthesia by means of a ten-per-cent solution of cocaine ; but this procedure is to be avoided, as a sense of choking is thereby produced. The administration of a small dose of potassium bromide a few hours previous to the examination will be found of service in rendering the parts less irritable.

LARYNGOSCOPICAL VIEW OF THE LARYNX IN A NORMAL CONDITION.—In the laryngeal mirror, when it has been introduced into the pharynx as already directed, the *first* thing that comes into view is the back of the tongue with its large follicles, *then* the hollow space between it and the anterior or glossal surface of the epiglottis, which is of a dark-pink color.

*Next*, the apex and laryngeal surface of the epiglottis, the free surface being of a yellow color, while the laryngeal or under surface is invariably of a bright-red color.

*Next*, the *ary-epiglottic folds*, which are of about the same color as the mucous membranes of the gums.

*Next*, the *ventricular bands*, having about the same color as the mucous lining of the lips.

*Next*, the *vocal cords*, which are pearly white, like the sclerotic coat of the eye.

*Next*, the *tracheal rings*, which are of a decidedly

yellow color, the mucous membrane between them being of a bright red.

*Lastly*, the bifurcation of the trachea and the bronchi.

In making your laryngeal observations, as soon as the posterior wall of the larynx is brought into view, note carefully the *form, size, color, position, and mobility* of the *true and false vocal cords*, as well as all their relations and form of motion, also the appearance of the anterior wall of the larynx from the free border of the epiglottis down to the trachea.

For the purpose of investigating the action of the vocal cords, the patient should be directed to inspire deeply or to produce a vocal sound, as *ah* or *eh*.

You must remember that the objects seen in the laryngeal mirror are reversed : the anterior part of the larynx becomes the posterior ; but the right side remains the right, and the left remains the left. This reversed picture is somewhat troublesome to the beginner. By frequently examining the different parts in the order already given, you will become familiar with their normal appearance and motions, and be prepared to recognize abnormalities.

The laryngeal diseases in which the laryngoscope is of special service as an aid in diagnosis, are *thickening, induration, and ulcerations* of the vocal cords, *paralysis* of the vocal cords, *polypi* or *malignant growths* springing from any portion of the larynx, *exudation* on the mucous surface of the epiglottis or larynx, *follicular enlargements*, and *ulcerations* of the larynx, as well as other changes which may occur in the course of chronic laryngitis or tracheitis.

### *Rhinoscopy.*

The examination may be made through the anterior

or posterior nares, and is called, accordingly, anterior or posterior rhinoscopy. The anterior examination is by far the more satisfactory.

**ANTERIOR RHINOSCOPY.**—Dilate the nostril by means of a nasal speculum (Fig. 74), and throw the light from the reflecting mirror into the cavity. By placing the fingers of the left hand on the forehead of the patient, and pressing the tip of the nose upward with the thumb, the opening is much enlarged. The head of the patient should be on a level with that of the examiner. Inspect the inferior meatus first. Then, by turning the head of the patient slightly from side to side, the surface of the septum and that of the inferior turbinated body will be brought successively into view. Now tilt the head backward until the middle turbinated body is seen, and examine its surface and that of the septum opposite. By further tilting, the anterior end of this body and the vestibule of the nose can be seen.

A ten- or twenty-per-cent solution of cocaine is now thrown into the cavity, and, after allowing sufficient time for the contraction of the blood vessels, the same procedure is repeated.

**POSTERIOR RHINOSCOPY.**—Pass the tongue depressor well over the arch of the tongue and pull its base forward, depressing it at the same time. You must be careful not to crowd it back into the throat, or retching may

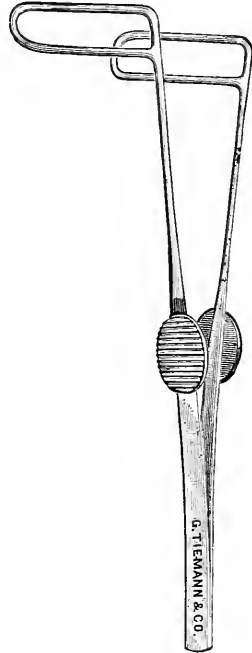


FIG. 74.—Nasal Speculum.

thereby be excited. Warm the rhinoscopic mirror and introduce it sidewise between the uvula and left pillar of the fauces. When it is well in the pharynx, with its face directed forward and slightly upward, turn it gently until the posterior nares are brought into view.

The septum is seen in the median line separating the oval openings of the nares. On each side of the septum the nasal passages appear as dark cavities. The superior turbinated body is visible in the upper part of each cavity as a faint reddish band; below it is the middle turbinated body, appearing as an elongated mass of a yellowish-red color; while between the two posteriorly is a dark line—the superior meatus. Passing further downward you come to the middle meatus and the inferior turbinated body, only the upper half of which can be seen. It appears to rest on the floor of the nose. The inferior meatus cannot be brought into view.

By turning the mirror to the side, the opening of the Eustachian tube may be seen as a dark slit. If the handle of the mirror be raised, the vault of the pharynx is brought into view. It presents an irregular surface, indicating the site of the pharyngeal tonsil.

These various parts making up the complete image can be seen only in detail.

This examination discloses the condition of the nasal mucous membrane, and such morbid alterations as may exist there, as necrosis, ulceration, polypi, etc. In the vault of the pharynx one can see the condition of the pharyngeal tonsil, and such hypertrophy as may be present.

#### *Sphygmograph.*

Various modifications of the sphygmograph have been devised by different experimenters, but the one which seems to me to be the best is that which was invented

by M. Marey, of Paris, to determine various points in the physiology of the circulation of the blood.

*This instrument* consists of a brass frame with a wing fastened to each side by hinges, so as to spread out upon the arm when the instrument is applied. Enclosed in this frame is a flexible steel spring, covered on the under surface of its free extremity with an ivory button, which rests upon the artery or vein to be examined, and is connected by means of a bar of metal, which has a vertical plate attached to it, with a very light lever moving upon a pivot; the vertical plate is brought in contact with the lever by means of a screw. The free extremity of the lever registers its movement up a blackened strip of

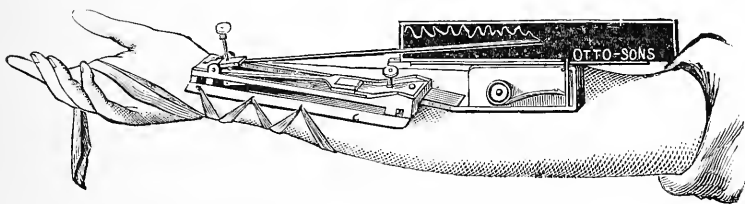


FIG. 75.—Marey's Sphygmograph.

paper that covers the brass plate. This plate is moved at a uniform rate by means of watchwork placed in the small box beneath. Ten seconds are occupied in the passage of the plate. A thumb screw winds up the watchwork, and a small lever starts the plate or stops it, as desired. Silk bands embrace the arm and hook on to projecting points on each wing, as seen in Fig. 75.

The sphygmograph was proposed as an aid in the diagnosis of diseases of the heart, arteries, and veins. When properly adjusted, it is claimed that it gives an exact representation of the *pulse curve*, the *frequency* and *regularity* of the pulsations, and any *peculiarity* of the pulsation. But it has not fulfilled the expectations that were entertained of it, for it has been found that

the characters of a sphygmogram may be entirely changed by merely altering the amount of pressure on the arterial wall. During the excitement, too, which is sometimes brought on by adjusting the instrument, the tracing obtained is very different from that taken when the heart is beating tranquilly.

Sphygmograms are of more importance in the recording of cases and clinical teaching than in diagnosis. By means of them we can demonstrate elements of the pulse that would otherwise escape detection.

Care must be used in adjusting the instrument, for if too much pressure is made the arterial wall will be so compressed as to interfere with its free movement; and if the pressure be too slight the full movement of the wall will not be registered. In taking a tracing from the radial artery, the instrument should be applied to the arm with the ivory button resting on the artery just beyond the lower extremity of the radius.

The pulse is a wave of increased arterial pressure, started by the systole of the heart, and passing over the arteries of the body. A graphic record of this wave, taken at any point of an artery, is called a *pulse curve*. It consists of three parts—the *up-stroke* or anacrotic limb, the *crest*, and the *down-stroke* or katacrotic limb.

The *up-stroke* represents the flow of blood into the arteries and the consequent distention of their walls. It is nearly synchronous with the ventricular systole.

The *crest* of the pulse curve designates the period during which the artery reaches its greatest degree of distention and begins to recoil. It is usually pointed, but may be rounded, as in certain aneurisms and aortic stenosis (see Figs. 79 and 83).

The *down-stroke* represents the return of the artery



to its original calibre. Its descent to the base line is gradual. It is broken by one or more undulations, the most prominent of which is the *dicrotic crest*. This crest is sometimes so marked as to be perceptible to the finger, giving rise to the dicrotic or "double" pulse.

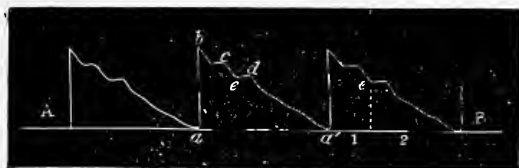

FIG. 76.—Normal tracing. (After Bramwell.)

The up-stroke is from *a* to *b*.

The crest is at *b*.

The down-stroke is from *b* to *a'*, with *c* the predicrotic, and *d* the dicrotic crest.

In a normal pulse curve the up-stroke is nearly or quite vertical, the crest is pointed, and the down-stroke slopes gradually to the base line. The predicrotic and dicrotic crests are visible on the down-stroke (see Fig. 76).

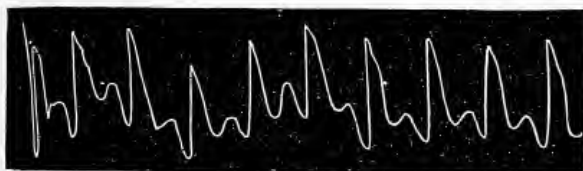

FIG. 77.—A Dicrotic Pulse Tracing. (After Eichhorst.)

*Dicrotism* is favored by a low arterial tension, a sufficiently powerful heart, elasticity of the vessel walls, and a diminished resistance in the small arteries. It occurs in cases where there is loss of vaso-motor tone, and in typhus and typhoid fevers.

The prominent features of the tracing of *aortic regurgitation* are the suddenness of the down-stroke and the almost complete absence of the dicrotic crest (Fig. 78).

In *aortic stenosis* (Fig. 79) the blood is not propelled into the artery suddenly, owing to the resistance it meets,

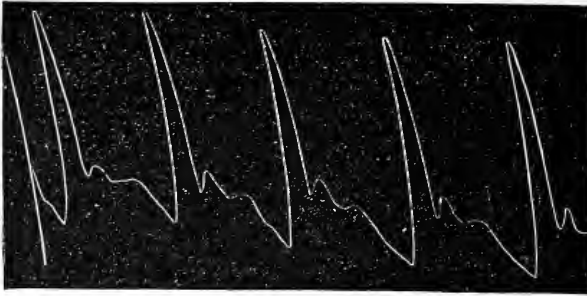


FIG. 78.—Pulse Tracing in Aortic Regurgitation. (After Strümpell.)

and hence the up-stroke is gradual. The crest in this instance is rounded.

If *atheroma* is sufficiently advanced to cause much impairment in the elasticity of the arterial walls, the




FIG. 79.—Aortic Stenosis. (After Bramwell.)

tracing will be as represented in Fig. 80. Owing to slowness of expansion the up-stroke is gradual. The crest is rounded in this case, though it may sometimes




FIG. 80.—Tracing from a Case of Atheroma. (After Eichhorst.)

be pointed. The loss in elasticity prevents the occurrence of secondary crests.

The *frequency* of the pulse may also be studied by

means of the sphygmograph. As the plate moves at a given rate of speed, the number of pulse curves traced during its passage indicates the number of heart beats in a given number of seconds.<sup>1</sup>

Fig. 81 is a tracing from a case of mitral regurgitation with a rapid pulse. It will be seen that the pulse curves follow each other in quick succession.



FIG. 81.—Frequent Pulse (120 to 130). (After Bramwell.)

The pulse may be *irregular* in time or volume, or in both. Irregularities in volume are usually associated with irregularity in time.



FIG. 82.—Mitral Obstruction. (From a patient in Bellevue Hospital.)

In Fig. 82, from a case of mitral obstruction, irregularity both in time and volume is represented.



Right Arm.



Left Arm.

FIG. 83.—Aneurysm of Ascending Aorta. (From a patient in Bellevue Hospital.)

The passage of the blood through an aneurismal sac usually leads to a flattening of the pulse curves (see Fig. 83) and a retardation of the pulse on the corresponding side.

<sup>1</sup> Mahomed's modification of Marey's sphygmograph is so constructed that four inches of the plate pass by the point of the pen in ten seconds.

## LESSON XX.

MECHANICAL AIDS IN THE DIAGNOSIS OF DISEASES OF THE  
NERVOUS SYSTEM, AND IN GENERAL DISEASES—OPH-  
THALMOSCOPE—THERMOMETER—MICROSCOPE—  
DYNAMOMETER—ÆSTHESIOMETER—EX-  
PLORING TROCAR—SPECULA.

### *Ophthalmoscope.*

THE simplest and least expensive ophthalmoscope is Liebreich's.<sup>1</sup> It consists of a concave circular mirror about one and one-half inches in diameter, and from ten to twelve inches focal distance, perforated in the centre by a small circular aperture. Behind the mirror is a hinged clip, into which eye pieces may be adapted, three of which are concave and two are convex, from six to twelve inches focal distance. On the side of the mirror is a shank which fits into a handle about six inches in length, by which the mirror can be held in any position desired. In addition to these there is a convex object lens of two and one-half inches focus (shown in Fig. 84).

The examination is best made in a darkened room, the examiner and patient sitting or standing face to face.

---

<sup>1</sup>The best instrument for the direct method of examination is that of Dr. Loring, of this city. The refraction of the eye examined may be determined by its use, it having a complete series of convex and concave glasses, which, by an ingenious revolving disc arrangement in the mirror, may be placed before the eye of the observer. The student who desires to give much attention to ophthalmoscopy will probably prefer this instrument, although it is more expensive than that of Liebreich.

There are two methods of examining the eye with this instrument, the *direct* and *indirect*. In both a lamp is placed at the side and a little behind the patient's head, the flame being on a level with his eyes. The handle of the mirror is held between the thumb and forefinger, and the eye piece at the aperture of the mirror is brought close to one of your own eyes in such a manner that the light from the lamp is reflected into the eye under observation. If you desire to make a *direct* examination, bring your eye which is armed with the mirror very close to the patient's eye, at the same time adjusting your eye for objects at an infinite distance, that is to say, having the accommodation at rest. The ex-




FIG. 84 — Liebreich's Ophthalmoscope.

aminer should use the corresponding eye in examination with the one being examined. If the eye of the observer and that of the patient be of normal length, a clear image will be obtained; if not, the proper correcting glass, convex or concave, may be used. The patient should turn his eye a little outward and across the room upon some object.

In *indirect* examinations the lamp and mirror are arranged the same as for the direct, but the mirror is only brought sufficiently near the eye to be examined to bring the focus of the reflection upon the optic disc; having done this, take the convex lens between the thumb and first finger of the hand not engaged with the mirror; rest the second and third fingers of this hand

on the patient's forehead, so as to steady the lens, and move it to and fro directly in front of the eye under examination until you find the focus—your little finger remains free to raise the lid, if necessary, or to press upon the eyeball.

When by practice you have acquired dexterity in manipulating this instrument, and by repeated examinations of the normal eye have become familiar with the appearance of the normal retina, optic disc, and choroid, you will be able readily to recognize many of the pathological changes in those structures which are now becoming important elements in the diagnosis of diseases of the brain, spinal cord, and other vital organs.

The importance of this instrument in the diagnosis of diseases of the eye is universally admitted, so that no ophthalmic surgeon of the present day regards the examination of an eye complete without an ophthalmoscopic examination. I shall not attempt to detail its diagnostic uses in this branch of surgery, but will briefly state its uses in medical diagnosis, as it is coming to be regarded of no little importance.

An ophthalmoscopic examination of an eye may show the *optic disc* to be the seat of *simple hyperæmia*, *anæmia*, *ischæmia*, or congestion and effusion within and around it; of *inflammation* of its sheath or of its substance; and, lastly, of *atrophy*.

It may show the *retina* to be the seat of *hyperæmia*, *anæmia*, of *fatty exudation patches*, or of *hæmorrhages*.

It may show the *choroid* to have partially or altogether *lost its pigment* and to be the seat of *hæmorrhages*, to have undergone *atrophy*, etc.

It may show the *blood vessels* within the eye *diminished*, *obstructed*, *dilated*, *tortuous*, *varicose*, *pulsating*, or to be the seat of *embolism*, *thrombosis*, or *rupture*.

**HYPERÆMIA OF THE DISC** may occur in the vessels of the disc, in the retinal veins, or in both retina and papillæ together. The larger vessels, and chiefly the retinal veins, are seen dilated, darker in color than natural, slightly tortuous, or even varicose.

To pronounce upon *slight* hyperæmia of the disc or retina is a delicate and difficult task; generally the hyperæmia is to be first seen on the inner half of the disc. In states of hyperæmia, when pressure is made on the ball of the eye, pulsations in the veins are more marked than in the normal condition. Direct examination is important in these cases.

*Clinical Significance of Hyperæmia of the Disc or Retina.*—Its causes are many. *First*, it is frequent in the first stage of ischæmia, of neuritis, or of an atrophic process. It may be due to orbital disease, to choroiditis, to Bright's disease, to alcoholism, to cerebral tumors, to acute or chronic meningitis, and to active cerebral hyperæmia; transient hyperæmia may be seen in forms of cardiac disease which obstruct the venous circulation, and in Grave's disease.

**ANÆMIA OF THE DISC AND RETINA** is the opposite of hyperæmia. It is always accompanied by anæmia of the retina and choroid. It is liable to be mistaken for atrophy of the disc; but the edges of the disc are not so sharp and well defined as in atrophy, and it is possible to distinguish the arteries from the veins; again, anæmia is equal in both eyes, atrophy is not; besides, atrophy rarely involves a whole disc equally, as does anæmia.

*Clinical Significance.*—The causes of anæmia of the disc or retina are the same as those of general or local anæmia.

**ISCHÆMIA OF THE DISC** is a mechanical venous conges-

tion, œdema, and punctate extravasation of the disc ; the disc is swollen, rising abruptly on one side and sinking gradually on the other ; its color varies from a bright transparent gray to a dirty red ; the margin of the disc is wholly concealed by infiltration and excessive vascularity, which gives it a mossy appearance ; the veins of the retina are tortuous—they may be *very* tortuous.

It is difficult and sometimes impossible to distinguish this condition from optic neuritis ; the two are frequently associated.

*Clinical Significance.*—The causes of ischæmia of the disc are all those changes within the skull which more or less directly distend the ophthalmic veins. The three main causes are, *chronic meningitis*, *hydrocephalus*, and *tumors*.

The lesions of the *optic disc* which seem to have the closest connection with cerebral, spinal, and general diseases are *hypercæmia* and *anæmia of disc and retina*, *optic neuritis* with its consecutive atrophy, and primary or progressive atrophy.

In OPTIC NEURITIS the disc becomes larger than usual, its edges indistinct, irregular, and puffy, the infiltration casting a veil over it, so as to change its color into a lilac gray, and more or less to conceal the vessels as they pass within its margin. The veins increase in size, become tortuous or even varicose ; they darken in color and seem to be gorged with blood. The capillaries, which in their normal state ought not to be seen, also become evident, and give a mossy or woolly appearance to the disc (Von Graefe).

*Clinical Significance.*—*Optic neuritis* is very generally coexistent with *meningitis* at the base of the brain, with *cerebral tumors* and *large cerebral hæmorrhages*.



It can only be distinguished from the *retino-neuritis* of albuminuria, and from the *retino-choroiditis* of syphilis, by the history of the case, by its limitation for the most part to the papillæ and the conveying vessels. Its resemblance to ischæmia has already been stated.

In the *consecutive atrophy* of optic neuritis, the intense vascularity in and about the disc subsides, the infiltrations are absorbed, the nerve whitens, and the capillaries slowly shrivel and vanish. The edges of the disc become distinct but are deformed, and patches of organized lymph are to be seen upon and about them.

In *progressive atrophy* of the optic disc, the fine capillaries which give the rose tint to the healthy disc slowly disappear, and a dead or pearly white is left. The border of the disc is sharp, clearly defined, flat, and even.

This lesion generally depends upon some disease of the cerebrum, cerebellum, or spinal cord.

The most *important* indications of organic disease capable of being recognized by an ophthalmoscopic examination of the eye have been summed up by Dr. T. C. Allbutt as follows :

In the *first stage of meningitis* there is dilatation of the veins of the retina, peripapillary congestion, and often external effusion. In the second stage the veins become tortuous, thrombotic, and sometimes rupture.

In *basilar meningitis* optic neuritis is present, but not in meningitis of the convexity.

*Intercranial* affections which directly distend the ophthalmic veins, as hydrocephalus and intracranial tumors, cause ischæmia of the discs, and, if the pressure is extreme, atrophy of the optic nerves.

*Acute and chronic cerebral softening* causes acute or chronic optic neuritis and atrophy. Cerebral hæmor-

rhage, when large, by its obstruction causes stasis in the vessels and effusion in and about the optic disc.

*In diseases of the spinal cord*, as progressive atrophy, sclerosis, and chronic myelitis, simple progressive atrophy of the optic disc is not uncommon.

*In Bright's disease* the nutrition of the optic nerve, as well as that of the retina, is interfered with; upon the retina extravasations are seen in the course of the vessels; these extravasations are slowly effused and pass into degenerative states, forming white patches or striations along the margins of the veins; most of these patches have evidently been clots; some may be due to the degeneration of retina.

*In syphilis* the choroid is the chief seat of lesion, and patches of many colors are to be seen at the back of the eye; some of brilliant white and others of darker tints, as red or brown. We also have intense neuroretinitis in syphilis, but its appearances cannot positively be distinguished from those of any other forms of neuroretinitis.

#### *Thermometer.*

The *thermometer* is now regarded an indispensable mechanical aid in the diagnosis of disease. I prefer (and would recommend to you) the *straight, self-registering clinical thermometer* represented in Fig. 85.

This thermometer consists of a glass stem, having on it a graduated scale varying from 95° to 112° F., exhibiting .2° F. The upper extremity of the stem is closed. At the lower end there is a bulb of mercury as thick as the diameter of the stem. Within the stem is a bit of mercury, detached from that in the bulb, called the index; this index is set by taking the bulb and stem of the instrument firmly in the hand, when, by repeated

sudden blows of the wrist upon the knee, the index is brought down the stem to a point just below the lines which indicate the degrees. After the index has thus been set, the bulb of the instrument may be applied to the *axilla*, *between the thighs*, *in the mouth*, *rectum*, or *vagina*, or to any *part* where it can be *completely covered*.<sup>1</sup> Before introducing the bulb it is well to hold it in the closed hand until the mercury shows a temperature of  $98^{\circ}$ . Neglect of this precaution is apt to lead to an under-statement of temperature. When the instrument has been in perfect contact with the parts for five or seven minutes, gently remove it, and the top of the index will denote the maximum temperature of the part. The patient should be in bed one hour before the temperature is taken.

If the *axillary temperature* is to be taken, the axilla should first be thoroughly dried, and the bulb of the instrument placed directly beneath the fold of the pectoralis major muscle, the forearm on that side being carried across the chest, and the elbow held by the other hand of the patient or by an assistant.

If the *rectal or vaginal temperature* is to be taken, the parts should first be thoroughly cleansed with warm water, and the patient placed on the side.



FIG. 85.—  
Straight, Self  
Registering  
Thermometer.

<sup>1</sup> Dr. E. Seguin, of this city, has devised a thermometer for determining localized surface temperatures. The peculiarity of this instrument is that the mercurial bulb is flattened, so as to furnish a large surface at its base. Dr. Seguin claims for this instrument *facility* and *accuracy* in determining the surface temperature of different parts of the body.

The *mouth* is the least reliable place at which the temperature can be taken, for the temperature in this cavity is constantly varying according to the quantity and temperature of the respired air.

Thermometrical observations, if possible, should be continuous, and be taken at least twice in the twenty-four hours—from 7 to 9 A.M. and from 4 to 7 P.M.

In cases of doubtful diagnosis, and in very active disease, they also should be taken at noon and at midnight.

The *pulse* and *number of respirations* should be noted at the time the temperature is taken. The *rate of rise* in the temperature indicates the degree of heat, and should be noted.

RANGE OF TEMPERATURE IN HEALTH.—The normal temperature, taken in any of the above-named localities, varies from 97.5° F. to 98.4° F. Any rise above 99.5° F., or depression below 97.3° F., *if persistent*, is a *sure index of disease*. A temporary elevation takes place after meals and after violent exercise.

But there is a diurnal variation of temperature amounting to one degree usually, sometimes two. The minimum occurs between 2 and 6 in the morning, and from that time there is a rise until the maximum is reached between 5 and 8 in the evening.

RANGES OF TEMPERATURE IN DISEASE.—The greatest range of temperature in disease is 17.0° F., the minimum being about 95° F., and the maximum 112.55° F. The highest recorded temperature was made by Wunderlich. The highest temperature ordinarily met with in severe and fatal cases rarely exceeds 107° F.

*A single thermometrical observation* is an important element in differential diagnosis *when taken in connection with other symptoms*, but it has no independent diagnostic value.

*Axillary temperature* below  $100^{\circ}$  F. excludes the existence of fever; above  $101^{\circ}$  F., leads to the probability of fever; when it exceeds  $108^{\circ}$  F., you may probably exclude fever.

A temperature of  $107^{\circ}$  F. indicates malignancy, and when met with for two consecutive days in typhus, scarlatina, measles, pneumonia, pyæmia, meningitis, or rheumatic affections, death is almost certain to follow. In relapsing and in pernicious intermittent fevers, the temperature may rise to  $107^{\circ}$  without indicating great danger.

In many diseases, during the last few hours of life, the temperature suddenly rises as high as  $109^{\circ}$  F., or even  $111^{\circ}$  F.; especially is this true in tetanus, sunstroke, typhus, pyæmia, etc. A temperature below  $98^{\circ}$  does not necessarily indicate collapse, but is more likely to be met with in the aged and feeble when subjects of grave disease.

Thus it is evident that a given temperature without its antecedents is apt to mislead in diagnosis. When isolated, the highest temperature only portends danger, and with a temperature of  $95^{\circ}$  F. collapse is not certain.

DAILY VARIATION OF TEMPERATURE IN DISEASE.—Daily thermometrical variations in disease depend upon the *elements which constitute the morbid processes, the intensity of these processes, and the stage they have reached*; also somewhat on the *idiosyncrasy of the patient*.

A single day's variations may determine the severity and stage of a disease; but you must compare the variations of a number of days before (in a large proportion of cases) you can reach a diagnosis.

*High average temperature*, above  $104^{\circ}$  F., is met with

in remittent, typhus, typhoid, and relapsing fevers, in severe pneumonia, etc.

*A moderately high average temperature* above  $102^{\circ}$  F. is met with in catarrhs, cerebro-spinal meningitis, diphtheria, dysentery, pleurisy, pericarditis, acute rheumatism, peritonitis, etc.

*A slight average rise in temperature* above  $100^{\circ}$  F. has a varied significance, and is met with in a large class of chronic affections, and at the commencement of acute inflammations and mild types of fever.

When your thermometrical observations follow regular diurnal variations, with a rise each day of one degree—as, first day, morning  $99.5^{\circ}$  F., evening  $101.5^{\circ}$  F.; second day, morning  $100.5^{\circ}$  F., evening  $102.5^{\circ}$  F.; third day, morning  $101.5^{\circ}$  F., evening  $103.5^{\circ}$  F.—you have almost certain evidence of typhoid fever. If the temperature does not exceed on any evening  $103.5^{\circ}$  F., the fever will probably have a mild course; if it reaches  $105^{\circ}$  F. in the evening, it shows that the attack is a severe one, and forebodes danger. A sudden and marked reduction of temperature to  $95^{\circ}$  F. during the third week of typhoid fever, denotes hæmorrhage from the sloughs of Peyer's patches.

If a patient with *measles* retain a high temperature after the eruption has faded, it indicates some complication.

Whatever differences of opinion may exist in regard to the importance and reliability of thermometrical observations as elements of diagnosis, the following propositions, it seems to me, may be regarded as established:

1. An abnormal temperature denotes the presence of some disturbance in the animal economy.
2. Certain degrees of temperature indicate fever.
3. The height of the temperature decides the severity and danger of a disease.

4. Thermometrical observations aid us in discovering the laws which regulate the course of certain diseases.

5. When the normal thermometrical course of a disease has been determined, its diagnosis is simplified.

6. The *thermometer* indicates quickly and certainly any deviation in the regular course of many diseases, the transition from one stage to another, and the commencement of convalescence.

7. It reveals the occurrence of complications.

8. It often reveals the imminence of a fatal termination.

9. It sometimes shows the impossibility of the continuance of life.

10. It is an important guide as regards the effects of remedial agents.

### *Microscope.*

The compound microscope consists essentially of a tube (T) having a system of lenses at each end ; the upper system is called the ocular (Oc), the lower the objective (Obj). Within this is a smaller or draw tube. The whole is attached to the stand (S). At St is the stage on which the object to be examined is placed. In its centre is a diaphragm for the purpose of regulating the amount of light. Below the stage a mirror (M), with a plane and concave surface, is suspended. It is for the purpose of illuminating the specimen, and is so adjusted as to admit of movement in any direction. The lenses are focussed by means of the coarse (C. adj) and fine (F. adj) adjustments. The coarse adjustment has a rack-and-pinion movement ; the fine adjustment consists of a finely cut screw acting against a spring. There should be at least two objectives—a low power having a focal distance of half an inch, and a high power with a focal

distance of one-sixth of an inch. For bacteriological work a homogeneous oil-immersion lens (one-twelfth) is required.

A good microscope should magnify from fifty to four hundred linear diameters.

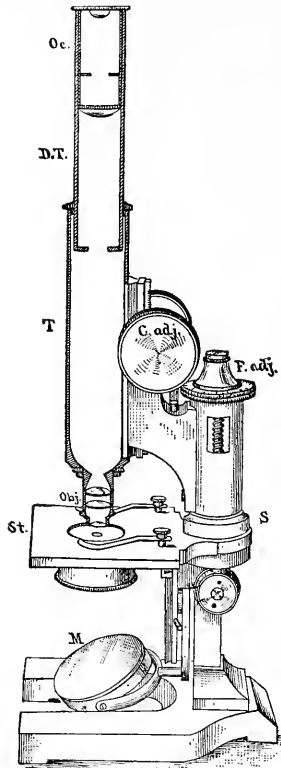


FIG. 86.—The Microscope.

**METHOD OF USING THE MICROSCOPE.**—For the examination of blood, pus, urine,<sup>1</sup> etc. (for sputum see page 207), all that is necessary is to place a drop of the specimen in the centre of a slide, cover it with a cover glass, and put it under the microscope. Small pieces of tumors, and curettings from the uterus and cervix uteri, may be teased out on a slide with fine needles and examined for their component cells. But when it is remembered that a diagnosis is based in many instances upon the arrangement as well as the appearance of the cells, it will be seen that this method is open to serious objections.

Tissues should always be hardened, embedded, and cut into thin sections. The sections should then be stained and mounted. For the methods of hardening, staining, etc., the student is referred to Stirling's Practical Histology."

<sup>1</sup> For obtaining the sediment from urine, it is convenient to close the upper end of a pipette with the finger, pass its tip down through the urine, and then remove the finger.



*Dynamometer.*

The best *dynamometer* is that of M. Mathieu, an instrument maker of Paris. It is very simple, and for measuring the strength of the hands leaves nothing to be desired.

It consists (as shown in Fig. 87) of an elliptical steel spring, to which is attached a semicircle of brass upon which a scale is marked. The indicator terminates at its central end in a cogwheel which works upon a steel arm. When it points to zero of the scale, the lower end of the arm touches the elliptical spring. A brass sheath upon the under side of the scale keeps

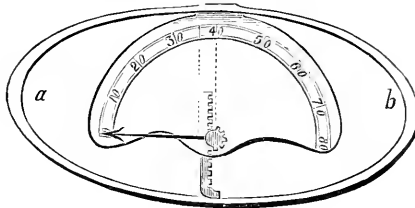


FIG. 87.—Dynamometer.

this arm in place, at the same time allowing it to move freely.

When the dynamometer is grasped in the hand, and the two sides of the spring approximated, the indicator is turned by the upward movement of the arm. One great advantage of this instrument is that, when the pressure is taken off, the indicator does not return to zero, but remains at the point to which it has been carried by the muscular power of the individual.

*Clinically*, you are able to measure the strength of partially paralyzed muscles of the upper extremities, to determine the slightest difference in the muscular power of the two hands, as well as to determine any changes that may occur from time to time in the course of a case of paralysis.

*Æsthesiometer.*

This instrument was invented by Dr. Sieveking in 1858 for the purpose of determining the degree of tactile sensibility of any part of the body.

It consists of a graduated bar of metal four or five inches in length. At one end is a fixed steel point. Another steel point is made to slide upon the bar, and can be fixed at any distance from the first by a screw which works at the top of the slide (Fig. 88).

It will be found that in a perfectly healthy person, when two impressions are simultaneously made upon the skin, the power of distinguishing them varies greatly in different parts of the body.

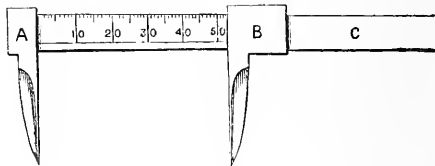


FIG. 88.—Æsthesiometer.

The following table of Weber gives the distances at which the two points of the æsthesiometer are normally felt in the different regions of the body :

	Mm.
Tip of the tongue.....	1.1
Palm of distal phalanx of finger..	2.2
Palm of second phalanx of finger...	4.4
Tip of nose.....	6.6
White portion of the lips.....	8.8
Back of second phalanx of finger .....	11.1
Skin over the malar bone.....	15.4
Back of the hand... ..	29.8
On the forearm.....	39.6
On the sternum.....	44.0
On the back.....	66.0

In using the instrument, first fix the two points at the distance which is normal for the part of the skin to be inquired into. The points must be applied simultaneously.<sup>1</sup> If the patient feels only one point when both points touch the skin, the two points must be gradually separated from each other, and reapplied to the part until both points are felt; in this way you will determine the amount of *anæsthesia* present. If, on the other hand, the two points are each distinctly felt at the normal distance limit, they must be brought gradually toward each other until one point is felt; thus you determine the amount of *hyperæsthesia* present.

The patient ought not to see the instrument, or know for what purpose it is applied.

This instrument aids you in determining the amount and extent of sensational impairment in cases of paralysis, as well as for determining if the loss of sensation is progressive. In the record of cases it is also of service.

### *Exploring Trocar.*

This instrument is an aid to positive diagnosis, as it enables you to determine the character of fluid contained in a distended pleural, pericardial, or abdominal cavity, or of that contained in any fluctuating tumor or deep-seated abscess.

There are three instruments which may be used as exploring trocars, viz.: the ordinary *Hypodermic Syringe*, *Dieulafoy's Aspirator*, and *Dieulafoy's Exhausting Syringe*.

The objection to the hypodermic syringe is that the needles are so small, and the exhausting power of the

---

<sup>1</sup> Care must be taken not to press too heavily, or the sensation of two points will be converted into the sensation of one.

syringe so slight, that you are not always able to draw the fluid through them.

The *Aspirator* is the best instrument for the purpose, but its price places it beyond the reach of many.

The *Exhausting Syringe* is much larger than the hypodermic syringe. It consists of a glass cylinder encased in a metal mounting, which is fenestrated so that the fluid can be seen as it is drawn into the syringe. There are two branches upon which the needles may be fitted. A valve is placed at their junction, and connected, by means of small bars and joints, with a handle running along the

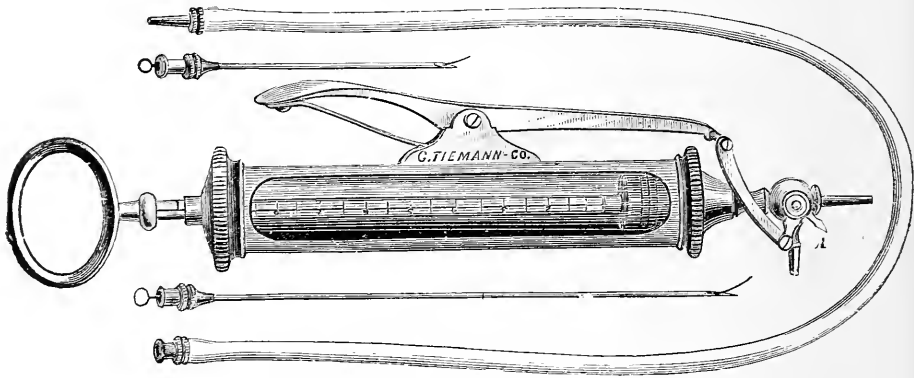


FIG. 89.—Dieulafoy's Exhausting Syringe

side of the cylinder. When the handle is depressed, the valve rotates, closing one of the branches; when the pressure is taken off, a spring returns the handle to its former position, the valve closing the branch previously opened (see Fig. 89). By this means the entrance of air into the needle is prevented.

Two needles accompany the instrument—a large and a smaller one; the former to be used when pus is suspected, the latter when you expect to find serum.

The needles are first introduced into the part to be examined, and then connected with the syringe, either directly or by means of a small rubber tube.


Dr. Dieulafoy, of Paris, the inventor of this instrument, says that it is always possible to introduce the needle without danger in searching for fluid, no matter where it is situated or what its nature, and that he has never met with an accident in using it.

If, after obtaining the fluid, any doubt remains as to its character, a drop should be placed on a slide and examined under the microscope. The diagnostic value of such an instrument is so readily appreciated that it is not necessary to enter into the details of its application.

### *Specula.*

*Various specula* have been devised for exploring the nose, the ear, the vagina, the rectum, and the urethra, and, in the hands of those accustomed to their use, are of material aid in arriving at a more positive diagnosis than could otherwise be obtained.

The *endoscope*, an instrument constructed for the purpose of exploring and making applications to the urethra, bladder, and rectum, has a series of dark-lined metallic tubes, which are employed as *specula*, and may be used with solar or artificial light. The uses of this instrument are almost exclusively confined to the domain of surgery; I shall not, therefore, include it in the list of mechanical aids to medical diagnosis.



## INDEX.

### A

- Abbe, 205
- Abdomen, 129
- difficulties of physical examination, 131, 138
  - epigastric zone, 132
  - hypogastric zone, 133
  - methods of physical examination, 135
  - umbilical zone, 132
  - zones of, 132
- Abdominal aneurism, errors in diagnosis of, 169
- aneurism, murmur in, 169
  - aneurism, physical signs, 168
  - tumors, diagnosed from abdominal aneurism, 170
- Abnormal or adventitious sounds, 40
- Abscess, chronic, of abdominal wall, diagnosed from enlarged spleen, 155
- of liver, physical signs, 148
- Absent or suppressed respiration, 35
- Actinomyces in sputum, 213
- in urine, 227
- Acute hepatitis, physical signs, 149
- lobar pneumonia, 58
  - peritonitis, 139
  - pleurisy, 66
  - tubercular pneumonia, 75
- Æsthesiometer, description of, 264
- table of normal distances, 264
- Albumin in urine, tests for, 187
- in urine, pathological states in which it appears, 189
  - in urine, significance of, 189
- Albuminometer, 188
- "Alveolar" cells, 207
- Ammonio-magnesium phosphate in urine, 218
- Ammonium urate, 215
- Amœba coli in fœces, 231
- in sputum, 215
- Amphoric cough, 51
- resonance, 26
  - respiration, 38
  - voice, 50
- Anchylostoma duodenale, ova of, 232
- Aneurism of arteria innominata, diagnosis, 125
- of thoracic aorta, differential diagnosis, 124
  - of thoracic aorta, physical signs, 121-124
  - of thoracic aorta, statistics, 121
- Anterior rhinoscopy, 243
- Anthrax, bacillus of, 205
- Aorta, course of arch, 83
- thoracic, aneurism, 121
  - topography of, 81
- Aortic regurgitation, sphygmograph in, 247
- stenosis, sphygmograph in, 248
  - valves, 82
- Arteria innominata, aneurism of, diagnosis, 125
- Ascaris lumbricoides, ova of, 232
- Ascites, diagnosis from ovarian dropsy, 167
- physical signs, 139
- Asthma, spasmodic, 57
- Asystolism, 119
- Atheroma, sphygmograph in, 248
- Atrophy of liver, 152
- Auricular diastole, 84
- systole, 84
- Auscultation, 29
- elements of, 31
  - immediate, 29
  - intra-thoracic, 39
  - mediate, 29
  - rules for, 30
  - of voice, 47
  - of voice in health, 47
- Auscultatory percussion, 27
- percussion, benefits claimed for, 27
  - percussion, method of performing, 27

- Auscultatory percussion, stethoscope for, 27
- Axillary, infra-, region, 10  
 region, 10  
 region, superior and middle, percussion of, 23  
 temperature, 256
- B**
- Bacillus of anthrax, 205  
 of Eberth, 231  
 of typhoid fever, 207  
 "Barrel-shaped" chest, 13
- Bennett, 27
- Bile in urine, 193  
 in urine, effect on color, 178  
 Gmelin's test for, 193  
 Pettenkofer's test for, 193
- Bladder, 159
- Blood, anthrax bacilli in, 205  
 bacillus of typhoid fever in, 207  
 casts, 225  
 changes in form, etc., of red cells, 203  
 changes, significance of, 203  
 diminution in number of red cells, 200  
 examination of, 199  
 in fæces, 229  
 filaria sanguinis hominis in, 207  
 increase in number of white cells, 201  
 method of determining presence in vomit, 228  
 method of obtaining for examination, 199  
 plasmodium malarix, 207  
 plates, 200  
 red corpuscles, 199  
 spirillum of relapsing fever, 204  
 in sputum, 208  
 tubercle bacillus in, 207  
 in urine, 194  
 in urine, effect on color, 178  
 in urine, microscopical examination, 221  
 white corpuscles, 200
- Bothriocephalus latus, ova of, 232
- Breathing, normal, 11
- Brieger, 219
- Bright, 132, 147, 156
- Bright's disease, specific gravity in, 180
- Bronchi, dilatation of (bronchiectasis), 54
- Bronchial casts, 209  
 cough, 51  
 respiration, 33, 37

- Bronchitis, acute and chronic, of larger tubes, 53  
 capillary, 54
- Bronchophony, normal, 47
- Bruit, uterine, 161

**C**

- Calcium oxalate in urine, 217  
 phosphate and carbonate in urine, 216  
 phosphate in urine, 219
- Cammann, 27, 30, 235, 238
- Cancer of liver, physical signs, 149, 150  
 of omentum, diagnosed from enlarged spleen, 155  
 pulmonary, 63  
 of stomach, 142  
 of stomach, diagnosed from enlarged spleen, 155
- Carbolic acid, effect on color of urine, 178
- Cardiac cycle, 84  
 duration of different phases, 86  
 dilatation, 118  
 hypertrophy, physical signs, 115  
 hypertrophy with dilatation, 117  
 sounds, simulating murmurs, 111
- Cardiometer, description of, 238
- Casts in urine, 223
- Cavernous cough, 51  
 respiration, 37
- Cavities, pulmonary, causation, 44
- Changes of normal respiration, 34
- Chest, "barrel-shaped," 13  
 bulging of, 14  
 deficiency of expansion, 17  
 dimensions of, 17  
 healthy alterations in form, 12  
 sinking in, 14  
 surface of, division into regions, 4
- Chloride of sodium, clinical significance in urine, 186
- Cholera bacillus, 230
- Chronic abscess of abdominal wall diagnosed from enlarged spleen, 155  
 peritonitis, 139
- Chyluria, 216  
 (condition of urine), 178
- Cirrhosis of liver, 151
- Clark, 27
- Clavicular, infra-, region, 5  
 region, 4  
 region, percussion of, 23  
 supra-, region, 4



“Cogged-wheel” respiration, 35, 76  
 Comma bacillus, 230  
 Congestion of liver, physical signs, 149  
   pulmonary, 64  
 Costal breathing, 11  
 Cough, amphoric, 51  
   bronchial, 51  
   cavernous (sepulchral), 51  
   resonance of, 51  
   sepulchral, 51  
 Cracked-pot resonance, 26  
 Cresote, effect on color of urine, 178  
 Crepitant rale, 42  
 Crystals in urine :  
   ammonio-magnesium phosphate, 218  
   ammonium urate, 215  
   calcium oxalate, 217  
   calcium phosphate, 219  
   cystin, 219  
   leucin, 219  
   sodium urate, 215  
   triple phosphate, 218  
   tyrosin, 220  
   uric acid, 217  
   xanthin, 220  
 Curschmann's spirals, 208  
 Cytometer, description of, 237  
 Cystin in urine, 219

## D

Diabetes mellitus, 193  
   specific gravity in, 179  
 Diaphragmatic breathing, 11  
 Diastole, auricular, 84  
   ventricular, 85  
 Diastolic venous murmurs, 128  
 Dicrotism, 247  
 Dieulafoy's aspirator, 265  
   exhausting syringe, description of, 266  
 Dilatation of bronchi, 54  
   of heart, 118  
 Diminished or feeble respiration, 35  
   vocal fremitus, 15  
 Distoma hepaticum, ova of, 231  
 Doremus, 181  
 Dropsy, abdominal, diagnosis of ovarian from ascites, 167  
 Dulness, 25  
 Dynamometer, description of, 263

## E

Eberth, 231  
 Echinococci in sputum, 215  
   in urine, 227

Egophony, 49  
 Einhorn, 191  
 Elastic tissue in sputum, 209  
 Emphysema, inspection in, 13  
   physical signs, 56  
 Emphyema, physical signs, 70  
   pulsatile, diagnosis from aneurism, 125  
 Endoscope, 267  
 Enlarged left lobe of liver, diagnosed from enlarged spleen, 155  
 Epigastric pulsation, diagnosed from abdominal aneurism, 125  
   region, 132  
   region, contents of, 134  
   zone, boundaries of, 132  
   zone, divisions of, 132  
 Epithelial casts, 224  
 Epithelium in fæces, 230  
   in sputum, 207  
   in urine, 222  
   in vomit, 229  
 Exaggerated pulmonary resonance, 25  
   respiration, 34  
   vocal resonance, 49  
 Expiration, prolonged, 36  
 Exploring trocar, 265

## F

Fæcal accumulations, characteristics of, 143  
   diagnosed from disease of liver, 153  
   diagnosed from enlarged spleen, 156  
   diagnosed from ovarian tumors, 167  
 Fæces, 229  
   amœba coli in, 231  
   comma bacilli in, 230  
   epithelium in, 230  
   micro-organisms in, 230  
   ova in, 231  
   pus in, 229  
   red blood corpuscles in, 229  
   tubercle bacilli in, 231  
   typhoid bacilli in, 231  
 Fat in urine, 216  
 Fatty casts, 225  
   heart, physical signs, 119  
   liver, physical signs, 147  
 Fehling's fluid, 190  
 Fermentation test for sugar, 190  
 Fibroid heart, physical signs, 119  
 Filaria sanguinis hominis, 207  
   in urine, 227  
 Flatness, 25  
 Fleischl. von, 203  
 Flint, 26, 36, 50, 237

Fœtal heart sound, 162  
 Fränkel, 213  
 Fremitus, changes in, 15  
   friction, 16  
   normal vocal, 15  
   ronchial, 16  
   sonorous, 16  
 Friction fremitus, 16  
   sounds, pericardial, 97  
 Friedländer, 213  
 Fuchsin, 210  
 Funic souffle, 162

## G

Gall bladder, position of, 145  
 Gangrene, pulmonary, 62  
 Glycosuria, 193  
 Gmelin's test for bile, 193  
 Gonococci, method of staining, 226  
   in urine, 226  
 Gram, 213  
 Granular casts, 224  
 Guaiacum test for blood, 194  
 Gurgles, 43

## H

Hæmaturia, 194  
 Hæmin crystals, 228  
 Hæmoglobi uria, 194  
 Hæmorrhage, pulmonary, 62  
 Hare, 16  
 Heart, abnormal sounds of, 97  
   astylolism, 119  
   auscultation of, rules for, 92  
   diastole, auricular, 84  
   diastole, ventricular, 85  
   dilatatio of, 118  
   fatty, physical signs, 119  
   fibroid, physical signs, 119  
   fœtal sounds, 162  
   hypertrophy of 115  
   hypertrophy with dilatation,  
   17  
   impulse, change in situation  
   of, 89  
   impulse, diminution of force,  
   90  
   impulse, effect of respiration  
   on, 89  
   impulse, increase of force, 90  
   impulse, production of, 85  
   inspection of, 89  
   methods of physical examina-  
   tion, 89  
   murmur, rhythm of, 99  
   murmurs, definition, 97  
   palpation of, 90  
   percussion of, 91  
   physiological action of, 83  
   "purring thrill," 91

Heart, sounds of, 85  
   sounds, alterations in quality  
   and pitch, 94  
   sounds, alteration in rhythm,  
   95  
   sounds, alteration in seat, 95  
   sounds, diminished intensity,  
   94  
   sounds, increased intensity, 94  
   sounds, intensity of, 93  
   sounds, irregularity in, 95  
   sounds, modifications of, 94  
   sounds, normal, 93  
   sounds, reduplication of, 96  
   sounds, rhythm of, 86, 87  
   systole, auricular, 84  
   systole, ventricular, 84  
   topography of, 81  
   valves, closure of, 84, 85  
   valves, relative positions of,  
   82  
 Heller's test, 187  
 Henocque, 203  
 Hepatitis, acute, physical signs, 149  
 Hippocrates, 19  
 Hutchinson, 18  
 Hyaline casts, 223  
 Hydatid tumors of liver, physical  
   signs, 150  
 Hydatids in sputum, 215  
   of omentum, diagnosed from  
   ovarian tumors, 167  
 Hydro-pneumothorax, 73  
 Hypertrophy, cardiac, physical  
   signs, 115  
   cardiac, with dilatation, 117  
 Hypodermic syringe for explora-  
   tion, 265  
 Hypogastric region, 134  
   zone, 133  
   zone, subdivisions, 133, 134

## I

Increased vocal fremitus, 15  
 Indican in urine, 178  
 Inferior sternal region, percussion  
   of, 23  
 Infra-axillary region, 10  
 Infra-mammary region, left, per-  
   cussion of, 23  
   region, right, percussion of, 23  
 Infra-scapular region, 9  
 Inspection, 3, 11  
   in pleurisy, 12  
   in pulmonary emphysema, 13  
   in pulmonary tuberculosis, 13  
 Interrupted respiration, 35  
 Inter-scapular region, 9  
 Intestinal ova, 231  
 Intestines, fecal accumulations in,  
   142

Intra-thoracic auscultation. 30  
tumors, diagnosis from aneurism, 124

## J

Jaksch, von, 202

## K

Kidney, disease of left, diagnosed from enlarged spleen, 156  
disease of right, diagnosed from disease of liver, 152  
enlargement of, 157  
method of determining enlargement, 158  
movable, 159  
normal boundaries of, 157  
sources of error in diagnosis of enlargement, 158

## L

Laennec, 46, 49  
Laryngeal image, 241  
mirror, 239  
Laryngophony, natural, 47  
Laryngoscope, description of, 239  
Larynx, method of examining, 240  
Left hypochondriac region, 132  
contents of, 134  
Left iliac region, 134  
contents of, 135  
Left lumbar region, 133  
contents of, 134  
Left kidney, disease of, diagnosed from enlarged spleen, 156  
Leucin in urine, 219  
Leucocythæmia, 202  
Leucocytosis, 201  
Leukæmia, 202  
Liebreich, 250  
Lipuria, 216  
Liver, abscess of, physical signs, 148  
acute hepatitis, physical signs, 149  
alteration of normal boundaries in health, 145  
atrophy of, 152  
cancer of, physical signs, 149, 150  
cirrhosis of, physical signs, 151  
congestion of, physical signs, 149  
decrease in size, 151  
differential diagnosis of diseases, 152  
diseases producing increase in size, 147

Liver displacement diagnosed from disease, 153  
displacement from lacing, 146  
displacement of, in thoracic diseases, 146  
fatty, physical signs, 147  
hydatids, physical signs, 150  
method of determining boundaries, 144, 145  
normal boundaries of, 144  
obstruction of bile ducts, physical signs, 149  
vertical measurements of, 145  
waxy, physical signs, 147, 148  
Lobular pneumonia, 60  
Loring, 250  
Lower sternal region, 7

## M

Macrocytes, 202  
Mammary, infra-, region, 6  
region, 6  
Marey, 245  
Mathieu, 263  
Mechanical aids to diagnosis, 235  
Mensuration, 3  
Hare's method of performing, 16  
method of performing, 16  
object of, 17  
Mesentery, enlargements of, 171  
Metallic tinkling, 51  
Method of examining larynx, 240  
Micrococcus ureæ, 226  
Microcytes, 202  
Microcythæmia, 202  
Micro-organisms in fæces, 230  
in urine, 226  
Microscope, description of, 261  
method of using, 262  
Mineral acids, effect on reaction of urine, 179  
Mitral valve, 82  
Moist rales, 42  
Movable kidney, 159  
Mucous click, 44  
corpuscles, 221  
cylindroids, 220  
rale, 43  
Mucus in urine, 220  
Murchison, 147  
Murexide test, 183  
Murmur of abdominal aneurism, 169  
veicular 32  
Murmurs, anæmic and functional, 108  
area of aortic, 106  
area of mitral, 104  
area of pulmonic, 105  
area of tricuspid, 105

Murmurs, cardiac, definition of, 97  
 cardiac, number of, 101  
 cardiac, rhythm of, 99  
 cardiac, seat of, 103  
 diagnosis of, 106  
 diastolic venous, 128  
 Dr. Cammann's rules regarding, 109  
 endocardial or valvular, 98  
 presystolic venous, 127  
 rhythm, rules for determining, 100  
 sub-clavian, 126  
 systolic venous, 127  
 table of cardiac, 102  
 venous, 108, 127  
 ventricular, 111

## N

Normal alterations in form and movements of chest, 12  
 laryngeal and tracheal respiration, 33  
 vocal fremitus, 15  
 vocal resonance, 47

## O

Obstruction of bile ducts, physical signs, 149  
 Oedema, pulmonary, 61  
 Oligocythæmia, 200  
 Omentum, cancer of, diagnosed from enlarged spleen, 155  
 hydatids of, diagnosed from ovarian tumors, 167  
 tubercular enlargements, diagnosed from enlarged spleen, 155  
 tumors of, diagnosis, 170  
 Ophthalmoscope, description of, 250  
 in diagnosis, 253-256  
 methods of using, 251  
 Ovarian dropsy, diagnosed from ascites, 167  
 tumors, diagnosed from disease of liver, 153  
 Ovaries, normal position, 164  
 tumors of, differential diagnosis, 166  
 tumors of, physical signs, 165  
 Oxaluria, 218

## P

Palpation, 3, 14  
 Pectoriloquy, 49  
 Penicilium glaucum, 226  
 Percussion, 3, 19  
 auscultatory, 27

Percussion, duration of sound, 20  
 elements of, 19  
 immediate, 19  
 in disease, 24  
 in health, 23  
 intensity of sound, 20  
 mediate, 19  
 method of performing, 21  
 pitch of sound, 20  
 quality of sound, 20  
 rules for performing, 21  
 variations in health, 24  
 Pericardial friction sounds, diagnosis of, 98  
 friction sounds, varieties of, 97  
 sac, position of, 83  
 Pericarditis, physical signs of, 113  
 Peritoneum, diseased conditions of, 139  
 Peritonitis, acute, 139  
 chronic, 139  
 Pettenkofer's test for bile, 193  
 Physical diagnosis, definition and methods of, 3  
 Physiological action of heart, 83  
 Piory, 19  
 Plasmodium malariae, 207  
 Pleurisy, acute, differential diagnosis of, 70  
 acute, stage of absorption, 68  
 acute, stage of liquid effusion, 67  
 acute, stage of plastic exudation, 66  
 inspection in, 12  
 subacute, stage of absorption, 64  
 subacute, stage of effusion, 68  
 varieties of, 66  
 Pleuritic friction sounds, 40, 45  
 friction sounds, varieties of, 46  
 Pleximeter, 21  
 Pneumococcus, 213  
 method of staining, 214  
 Pneumothorax, 72  
 Pneumonia, acute lobar, first stage, 58  
 acute lobar, second stage, 59  
 acute lobar, third stage, 59  
 acute tubercular, 75  
 inspection in, 13  
 lobular, 60  
 Poikilocytes, 203  
 Poikilocytosis, 203  
 Posterior rhinoscopy, 243  
 Pregnancy, diagnosis of, 160  
 diagnosed from ovarian tumors, 167  
 twin, 163  
 Presystolic jugular pulsation, 127  
 venous murmurs, 127  
 Prolonged expiration, 36

- Pubic region, 134  
 region, contents of, 134
- Pulmonary artery, course of, 83  
 cancer, physical signs, 63  
 cavities, causation, 44  
 collapse, physical signs, 64  
 congestion, physical signs, 64  
 emphysema, 56  
 gangrene, physical signs, 63  
 hæmorrhage, physical signs, 62  
 œdema, 61  
 tuberculosis, 74  
 valves, 82
- Pulsatile empyema, diagnosed from  
 aneurism, 125
- Pulsation, epigastric, diagnosed  
 from aneurism, 125  
 presystolic jugular, 127  
 systolic jugular, 127  
 venous, 127
- Pulse curve, 246  
 rate, normal, 86
- "Purring thrill," 91
- Pus in fæces, 229  
 in sputum, 208  
 in urine, 195  
 in urine, microscopical exami-  
 nation, 220  
 in vomit, 228
- Pyelitis, reaction of urine in, 179
- Pyelonephritis, reaction of urine  
 in, 179
- Pyuria, 195

## Q

- Quain, 17, 236

## R

- Rale, crepitant, 42  
 moist, 42  
 mucous, 43  
 redux, 43  
 sonorous, 42  
 subcrepitant, 43
- Rales, classification of, 40
- Ray fungus, in sputum, 213
- Rectal temperature, 256
- Red blood corpuscles, 199  
 in fæces, 229  
 in vomit, 228
- Reflecting mirror, 240
- Region, epigastric, 132  
 epigastric, contents of, 134  
 hypogastric, 134  
 left hypochondriac, 132  
 left hypochondriac, contents  
 of, 134  
 left iliac, 134  
 left iliac, contents of, 135  
 left lumbar, 133

- Region, left lumbar, contents of,  
 134  
 pubic, 134  
 pubic, contents of, 134  
 right hypochondriac, 132  
 right hypochondriac, contents  
 of, 134  
 right iliac, 134  
 right iliac, contents of, 135  
 right lumbar, 133  
 right lumbar, contents of, 134  
 umbilical, 133  
 umbilical, contents of, 134
- Regions of chest, 4  
 axillary, 10  
 clavicular, 4  
 infra axillary, 10  
 infra-clavicular, 5  
 infra-mammary, 6  
 infra scapular, 9  
 inter-scapular, 9  
 lower sternal, 7  
 mammary, 6  
 scapular, 9  
 supra-clavicular, 4  
 supra-scapular, 9  
 supra sternal, 7  
 upper sternal, 7
- Relapsing fever, spirilla in, 204
- Renal epithelium in urine, 222
- Resonance, amphoric, 26  
 of cough, 51  
 cracked-pot, 26  
 pulmonary, exaggerated, 25  
 tympanitic, 25  
 vesiculo-tympanitic, 26  
 whisper, 50
- Respiration, absent or suppressed,  
 35  
 alteration in intensity, 34  
 alteration in quality, 36  
 alteration in rhythm, 35  
 amphoric, 38  
 bronchial, 33, 37  
 cavernous, 37  
 changes from normal, 34  
 "cogged-wheel," 35, 76  
 diminished or feeble, 35  
 exaggerated, 34  
 interrupted, 35  
 interval between inspiration  
 and expiration prolonged, 36  
 movements of, 13  
 normal laryngeal and tra-  
 cheal, 33  
 rude, 36
- Rhinoscopic image, 244  
 mirror, 240
- Rhinoscopy, 242
- Rhubarb, effect on color of urine,  
 178
- Richardson, 39

- Right hypochondriac region, 132  
 contents of, 134  
 Right iliac region, 134  
 contents of, 135  
 Right lumbar region, 133  
 contents of, 134  
 Roberts, 176  
 Ronchial fremitus, 16  
 Rude respiration, 36  
 Rules for performing percussion,  
 21

## S

- Saccharometer, 191  
 Sarcinæ in urine, 226  
 ventriculi in vomit, 229  
 Scapular, infra-, region, 9  
 inter-, region, 9  
 supra-, region, 9  
 Seguin, 257  
 Senna, effect on color of urine, 178  
 Sepulchral cough, 51  
 Sieveking, 264  
 Simpson, 143  
 Sodium urate, 215  
 Sonorous fremitus, 16  
 rale, 42  
 Sounds, cardiac. simulating mur-  
 murs, 111  
 Spasmodic asthma, 57  
 Specula, 267  
 Spermatozoa in urine, 223  
 in urine, medico-legal cases,  
 223  
 Sphygmograph, description of,  
 244, 245  
 in aortic regurgitation, 247  
 in aortic stenosis, 248  
 in atheroma, 248  
 Sphygmograms, value of, 246  
 Spirillum of relapsing fever, 204  
 Spirometer, Hutchin-on's, 18  
 Spleen, diagnosis of diseases, 155,  
 156  
 enlargement of, 154, 155  
 enlargement diagnosed from  
 disease of liver, 153  
 method of determining bound-  
 aries, 153, 154  
 normal boundaries of, 153  
 Sputum, actinomyces in, 213  
 amœba coli in, 215  
 cellular elements, 207  
 Curschmann's spirals in, 208  
 elastic tissue in, 209  
 epithelium in, 207  
 hydatids in, 215  
 liver cells in, 208  
 pneumococcus in, 213  
 pus cells in, 203  
 red blood cells in, 203  
 tubercle bacillus in, 210

- Sputum, white blood cells in, 208  
 Sternal, lower, region, 7  
 supra, region, 7  
 upper region, 7  
 Stethometer, description of, 236  
 Quain's, 17  
 Stethoscope, 29  
 description of, 235  
 Stirling, 262  
 Stomach, cancer of, 142  
 diseases of, diagnosed from dis-  
 ease of liver, 153  
 gaseous or tympanitic disten-  
 tion of, 142  
 normal boundaries of, 141  
 Subacute pleurisy, 63  
 Sub clavian murmurs, diagnosed  
 from aneurism, 126  
 Subcrepitant rale, 43  
 Succussion, 23  
 Sugar in urine, 189  
 in urine, Fehling's test for,  
 190  
 in urine, Trommer's test, 189  
 Superior sternal region, percussion  
 of, 23  
 Supra-clavicular region, 4  
 Supra-scapular and scapular re-  
 gions, percussion of, 24  
 Supra-sternal region, percussion  
 of, 23  
 Surface thermometer, 257  
 Systole, auricular, 84  
 ventricular, 84  
 Systolic jugular pulsation, 127  
 venous murmurs, 127

## T

- Tænia mediocanellata, ova of, 232  
 solium, ova of, 232  
 Tailed cells from pelvis of kidney,  
 222  
 Temperature, axillary, 257  
 daily variation in disease, 259-  
 261  
 range of, in disease, 258  
 range of, in health, 258  
 rectal, 257  
 Thermometer, axillary tempera-  
 ture, 257  
 description of, 256  
 precautions in using, 257  
 rectal temperature, 257  
 surface, 257  
 Thoma-Zeiss, 201  
 Throat mirror, 239  
 Tinkling, metallic, 51  
 Topography of heart, 81  
 Torula cerevisiæ, 226  
 Tracheophony, 47  
 Trapp, 180

- Trichocephalus dispar, ova of, 232  
 Tricuspid valve, 82  
 Triple phosphates in urine, 218  
 Trommer's test for sugar in urine, 189  
 Tubercle bacillus in blood, 207  
   bacillus in fæces, 231  
   bacillus, methods of staining, 210, 211, 212  
   bacillus in sputum, 210  
   bacillus in urine, 227  
   bacillus in vomit, 229  
 Tuberculosis, pulmonary, 74  
   pulmonary, acute miliary, 74  
   pulmonary, acute pneumonic, 75  
   pulmonary, chronic, advanced stage, 77  
   pulmonary, chronic, early stage, 75  
   pulmonary, inspection in, 13  
 Tumors, abdominal, diagnosed from abdominal aneurism, 170  
   melanotic, color of urine in, 178  
   of ovary, 165  
   ovarian, differential diagnosis, 166  
   of uterus, 164  
 Turgescence of veins, 126  
 Turpentine, effect on odor of urine, 178  
 Tympanitic resonance, 25  
 Typhoid bacillus, 207, 231  
 Tyrosin in urine, 219

## U

- Umbilical region, 133  
   region, contents of, 134  
   zone, boundaries of, 132  
 Upper sternal region, 7  
 Urates, effect on color of urine, 181  
   in urine, 215  
   in urine, significance of, 216  
 Urea in urine, 181  
 Ureometer, description of, 181  
   method of using, 182  
 Uric acid in urine, 217  
 Urine, actinomyces in, 227  
   albumin, qualitative tests for, 187  
   albumin, quantitative test, 188  
   ammonio-magnesium phosphates in, 218  
   amorphous deposits, 215  
   bile in, 193  
   blood in, 194  
   blood in, guaiacum test, 194  
   blood in, microscopical examination, 221  
   blood in, significance of, 194  
 Urine, blood in, spectroscopic test for, 194  
   calcium oxalate in, 217  
   calcium oxalate in, significance of, 218  
   calcium phosphate in, 219  
   calcium phosphate and carbonate in, 216  
   casts in, 223, 224, 225  
   character of deposit, 180  
   chemical characters, 181  
   chlorides in, 185  
   color of, 178  
   condition of, 177  
   cystin in, 219  
   diabetic, color of, 189  
   diabetic, specific gravity of, 189  
   echinococci in, 227  
   epithelium in, 222  
   fat in, 216  
   Felling's test for sugar in, 190  
   fermentation test for sugar, 190  
   filaria in, 224  
   gonococci in, 226  
   introductory remarks, 175  
   leucin in, 219  
   micrococcus ureæ in, 226  
   mucous cylindroids in, 220  
   mucus in, 220  
   odor of, 178  
   penicillium in, 226  
   phosphates in, 185  
   phosphates, clinical significance of, 185  
   physical characters of, 176  
   plan of examination, 175  
   pus in, 195  
   pus in, microscopical examination, 220  
   pus in, origin of, 221  
   quantity passed in twenty-four hours, 176  
   reaction, 179  
   sarcoma in, 226  
   significance of albumin in, 189  
   specific gravity of, 179  
   specific gravity, amount of solids calculated from, 180  
   specific gravity in disease, 180  
   spermatozoa in, 223  
   sugar in, 189  
   sugar in, clinical significance of, 193  
   sugar, fermentation saccharometer, 191  
   sugar, quantitative estimation of, 191  
   sulphates in, 186  
   torula in, 226

Urine, triple phosphates in, 218  
 Trommer's test for sugar in, 189  
 tubercle bacilli in, 227  
 tyrosin in, 219  
 urates in, 184, 215  
 urates in, clinical significance of, 184  
 urea, 181  
 urea, clinical significance of, 183  
 urea, quantitative estimation of, 181  
 uric acid in, 183, 217  
 uric acid, clinical significance of, 184, 217  
 uric acid, quantitative estimation of, 184  
 xanthin in, 220

Urinometer, 180

Urobilin, 178

Uroerythrin, 178

Uterine bruit, 161

Uterus, 160  
 diagnosis of pregnancy, 160  
 foetal heart sounds 162  
 funic souffle, 162  
 rules for performing auscultation, 160  
 tumors of, 164  
 twin pregnancy, 163

## V

Vaginal temperature, 257

Veins, turgescence of, 126

Venous murmurs, 127  
 murmurs, diastolic, 128  
 murmurs, presystolic, 127  
 murmurs, systolic, 127

Venous pulsation, 127

Ventricular diastole, 85  
 systole, 84

Vesicular murmur, 32

Vesiculo tympanic resonance, 26

Vocal fremitus, absent, 15  
 fremitus, diminished, 15  
 fremitus, increased, 15  
 fremitus, normal, 15  
 resonance, exaggerated, 49  
 resonance, diminished intensity, 48  
 resonance, increased intensity, 48  
 resonance, normal, 47

Vomit, 228  
 epithelium in, 229  
 pus in, 228  
 red blood corpuscles in, 228  
 sarcinæ ventriculi in, 229  
 tubercle bacilli in, 229

## W

Walsh, 57

Waxy casts, 224  
 liver, physical signs, 147, 148

Weber, 264

Whisper resonance, 50

Woiler, 237

"Wool-sorter's" disease, 206

## X

Xanthin in urine, 220

## Z

Ziehl-Neelson fuchsin, 210

Zones of abdomen, 132







COLUMBIA UNIVERSITY



0027717348

RC76

L87

1897

