






LIBRARY OF CONGRESS.

Class. .... Copyright No. ....  
Shelf .. RF 121  
B92

UNITED STATES OF AMERICA.







RF546  
~~B72~~

RF121  
B92

COPYRIGHT  
WILLIAM WOOD & COMPANY  
1880

Trow's  
PRINTING AND BOOKBINDING COMPANY  
201-213 East 12th Street  
NEW YORK


1350  
E. O. W. Feb. 12/14.

## PREFACE.

---

IN the following treatise my aim has been to present, in text-book form, a picture of diseases of the ear as they have appeared to me in private and hospital practice. I have occasionally, it is true, drawn my illustrations from the published experience of others, but in the main I have followed closely the plan of using only the material stored up in my own case-books, and of describing only those methods of treatment which I have tested and found both safe and efficient.

A. H. B.





# CONTENTS.

---

## CHAPTER I.

	PAGE
SKETCH OF THE PHYSIOLOGY OF THE ORGAN OF HEARING.....	1

## CHAPTER II.

EXAMINATION OF THE PATIENT.....	17
Tests of the hearing-power.....	17
Instruments and methods of examination.....	20
<i>Ear-specula</i> .....	20
<i>Reflectors</i> .....	22
<i>Introduction of the speculum and use of the reflector</i> .....	24
<i>Accessory instruments used in the examination of the ear</i> .....	28

## CHAPTER III.

DISEASES OF THE AURICLE.....	35
Eczema.....	35
Inflammation of the auricle.....	39
Hæmatoma auris.....	40
New-growths.....	51
Miscellaneous diseases.....	53
Congenital malformations.....	55

## CHAPTER IV.

DISEASES OF THE EXTERNAL AUDITORY CANAL.....	57
Impacted cerumen.....	57
Acute circumscribed inflammation.....	65
Acute and chronic diffuse inflammation.....	74
Desquamative inflammation.....	86
Ulcers, polypoid growths, and caries.....	92
<i>False membranes in the auditory canal</i> .....	98

	PAGE
Syphilitic ulcers and condylomata.....	104
Foreign bodies.....	109
Wounds.....	113
New-growths.....	114
<i>Hyperostosis; exostoses; bony closure</i> .....	114
<i>Cancer</i> .....	118
<i>Sarcoma</i> .....	120
Cysts.....	123

## CHAPTER V.

METHODS OF EXAMINING THE MIDDLE EAR.....	125
--	-----

## CHAPTER VI.

DISEASES OF THE MIDDLE EAR (NON-PURULENT FORMS).....	141
Preliminary remarks.....	141
Affections of the Eustachian tube.....	142
Acute and subacute inflammation of the middle ear.....	151
Catarrhal inflammation of the middle ear.....	153
Chronic subacute catarrh.....	193

## CHAPTER VII.

DISEASES OF THE MIDDLE EAR (PURULENT FORMS).....	196
Acute purulent inflammation.....	196
<i>Acute inflammation of the posterior fold</i> .....	224
Syphilitic disease.....	227
Chronic purulent inflammation.....	230
<i>Simple uncomplicated cases</i> .....	237
<i>Proliferative cases</i> .....	246
<i>(Foreign bodies in the middle ear)</i> .....	258
<i>Cases in which the bone is involved</i> .....	259

## CHAPTER VIII.

FRACTURES OF THE TEMPORAL BONE.....	278
-------------------------------------	-----

## CHAPTER IX.


DISEASES OF THE MASTOID PROCESS.....	296
I. Affections in which the antrum is the part chiefly involved.....	301
II. Acute inflammation of both the antrum and the pneumatic spaces....	328
III. Inflammation of the external periosteum of the mastoid process.....	355

## CHAPTER X.

	PAGE
MISCELLANEOUS CONDITIONS OF THE DRUM-MEMBRANE, OSSICLES, AND TYM- PANIC CAVITY .....	370
Atrophy of the membrana tympani.....	370
Horny growth of the membrana tympani.....	371
Vascular growth of the membrana tympani.....	372
Deformed drum-membrane.....	372
Absence of the hammer.....	372
Hook-shaped manubrium mallei.....	373
Ruptures of the drum-membrane.....	373
New-growths of the middle ear.....	374
<i>Hyperostosis</i> .....	374
<i>Vascular growths</i> .....	375
<i>Malignant tumor</i> .....	382
Subjective and objective systolic murmurs.....	386
Otalgia.....	387

## CHAPTER XI.

DIFFERENT FORMS OF AURAL DISEASE IN WHICH THE LABYRINTH IS BELIEVED TO BE INVOLVED.....	388
INDEX.....	405



## DIAGNOSIS AND TREATMENT

OF

# DISEASES OF THE EAR.

---

### CHAPTER I.

#### SKETCH OF THE PHYSIOLOGY OF THE ORGAN OF HEARING.

It has often been said, and with entire justice, that no other part or organ of the human body is so beautiful in structure as the ear. Its tympanic membrane, its chain of ossicles, its wondrous labyrinth containing cavities within cavities and thousands of vibratile cords—all these together go to make up an organ of exquisite architectural beauty, and one that is marvellously adapted to the purpose for which it is designed. This delicate organ, with its multitude of fragile elements, needs the most ample protection, and we find it, accordingly, buried deep in the bone whose name (*petrous*) tells the story of its hardness. Inaccessible, as it is, to the eye, the wondrous interior of the labyrinthine cavities for a long time remained an almost unexplored territory. What we know to-day is the result of years spent in untiring researches, attended with repeated failures. One, by one, however, the disputed points have been made clear, and we may now safely assume that the minute anatomy of the semicircular canals, vestibule, and cochlea is as accurately determined as that, for example, of the eye.

The ear in mammals consists of three different cavities—the *external auditory canal*, the *tympanum*, and the *labyrinth* (Fig. 1). The first cavity is nearly cylindrical in shape; at one end it communicates with the outer world by a broad, free opening, while at the other it is entirely shut off from the cavity beyond (tympanum) by a thin, inelastic membrane—the *membrana tympani* (*M T*). The second cavity, so far as the naked eye can see, is a closed cavity, filled with air, which, through the medium of a minute canal (the safety-tube of the Eustachian canal), remains at the same de-

gree of density as the air on the outer side of the membrana tympani (Rüdinger); or, in other words, the atmospheric pressure upon the outer side of the membrana tympani and that upon the inner side exactly counterbalance

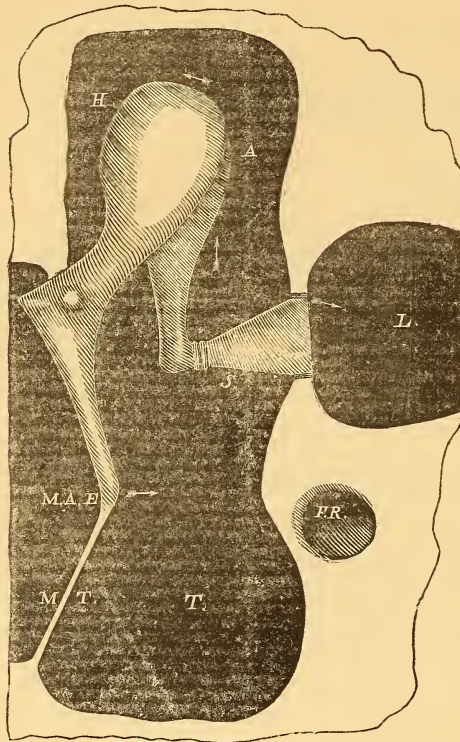


FIG. 1.—Diagram showing the Relations of the Ossicles to the External Auditory Canal and Labyrinth: *T*, cavity of the tympanum; *L*, labyrinth; *M A E*, meatus auditorius externus; *H*, hammer; *A*, anvil; *S*, stirrup; *M T*, membrana tympani; *F R*, fenestra rotunda.

each other. The length and height of this cavity are very nearly equal, but the breadth is much less than either. The outer side of this peculiarly shaped cavity is composed chiefly of the membrana tympani, while the inner is a somewhat dome-shaped surface of bone, covered of course with mucous membrane. In this inner wall of the cavity are two openings—the one oval in shape, the other round—which lead by separate passages into the last cavity or system of cavities of the ear—the *labyrinth*. In the natural state these openings are closed, the upper one by the foot-plate of the stirrup, the lower by a delicate membrane (*membrana tympani secundaria*). The connecting link between the vibrations of *a'* in the first cavity (or external auditory canal) and the auditory nerve, which is spread out in a portion of the third cavity (labyrinth), is formed by a chain of three ossicles, which arch the space separating

the inner from the outer wall of the second cavity (tympanum). It is therefore essential to clearly understand the mechanism of these ossicles before we can discuss intelligently the more complicated mechanism of the labyrinth, and especially of that part of it called the cochlea.

Let us first take the sea-turtle and examine the simpler auditory apparatus (see Fig. 2) which we find in that animal. Here the substitute for the membrana tympani is situated almost immediately beneath the surface of the hard skin or shell on the side of the head, this animal having no external auditory canal. This substitute is nothing more nor less than the flaring end of a slender bone, about two inches in length, whose other end, likewise somewhat flaring, terminates in the labyrinth. This slender rod

(*columella*) lies, throughout almost its entire length, in a bony canal, and fits it so accurately that the only possible motion which can be communicated to the rod must be in the direction of its length. Pressure made at

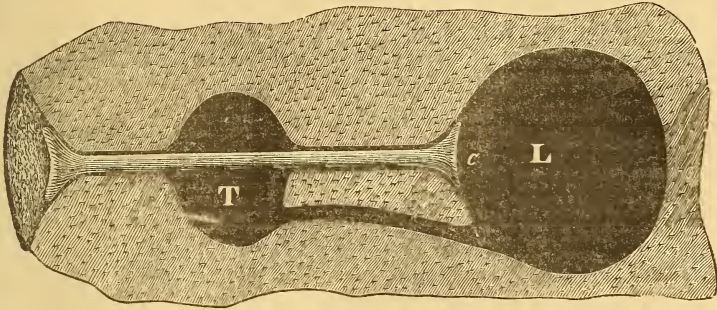


FIG. 2.—Diagram of Sea-Turtle's Ear: *T*, tympanum; *L*, labyrinth; *c*, columella.

the outer end causes the inner end of the rod to project to a corresponding degree into the labyrinth; and, the moment the pressure is withdrawn, the rod, by reason of the highly elastic ligaments which hold it in place, instantly returns to its original position.

The sea-turtle, then, furnishes us with a good example of the simplest substitute for the chain of ossicles, while at the same time the piston-like action of the rod throws out a hint as to the possible mechanism of the more complicated apparatus in the human ear.

Instead of a single rod, we find in the mammalian ear three distinct ossicles, called respectively the *hammer*, the *anvil*, and the *stirrup*. The three are connected together in a peculiar manner.

The hammer, the first of the series, occupies such a position on the outer side of the tympanum that its handle (*sp* to *U*, in Fig. 3) projects from above downward as far as to the centre (*U*) of the membrana tympani, with which it is intimately united (see also Fig. 1). In the next place the upper limit of this membrane consists of a band of fibres, which holds the hammer very firmly at a point midway between the end of the handle and the top of the head, and allows it to perform only limited rotary motions, inward and outward. The second ossicle, the anvil, grasps as it were the head of the hammer by means of a peculiar interlocking of their respective articular surfaces.<sup>1</sup> From the

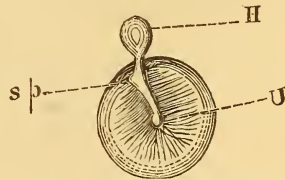


FIG. 3.—Diagram showing the Relations of the Hammer to the Membrana Tympani: *H*, head of hammer; *U* (umbo), the tip of the handle of hammer, corresponding to the centre of the membrane; *sp*, the short process of the hammer.

<sup>1</sup> Helmholtz, who was the first to describe the real nature of the malleo-incudal joint, compared it to "the joint used in certain watch-keys, where the handle cannot be turned in one direction without carrying the steel shell with it, while in the opposite direction it meets with only slight resistance."

body of the anvil two processes project, the one backward to articulate with the posterior wall of the cavity, the other downward to articulate with the head of the third ossicle, the stirrup. While the articulation between the hammer and the anvil is of such a nature as to admit of almost no play of the articular surfaces upon each other, that between the long process of the anvil (see Fig. 1) and the head of the stirrup,<sup>1</sup> on the contrary, admits of full play between the two surfaces.

Finally, the articulation between the foot-plate of the stirrup and the margin of the oval opening, which leads to the labyrinth, consists simply of a band of elastic fibres that span the narrow space which separates the border of the foot-plate from the margin of the window in which it fits.

What part, then, does this apparatus play in the function of hearing, and what are the mechanical effects of its action upon the fluid of the labyrinth? Obviously, to transmit accurately to this fluid body the same impulses which the membrana tympani receives. The mechanism may be thus described :

Let us suppose that a purely simple tone of one hundred vibrations per second is sounded within hearing distance. The air in the immediate vicinity of the membrana tympani will be alternately condensed and rarefied one hundred times during the period of a second ; or, in other words, the membrane itself will vibrate inward and outward the same number of times. But, inasmuch as the handle of the hammer is, so to speak, an integral portion of the membrana tympani, it, too, will perform the same number of excursions inward and outward. In the next place, the firm union between the head of the hammer and the body of the anvil will oblige the latter to follow the direction communicated to the head of the hammer by the excursion of its handle. A glance at the figure (Fig. 1) will show that on the anvil the direction of the motion imparted to it will vary according to the locality : thus, if the handle of the hammer be in the act of making an excursion inward, the top of the body of the anvil will be found moving in an outward and somewhat upward direction, while at the extremity of its long process (near the head of the stirrup) the motion will be chiefly upward, with somewhat of an inclination inward. The stirrup, whose head plays freely within the articular capsular ligament upon the end of this long process, will convert the impulse thus received into a motion, partly hinge-like and partly piston-like in its character.

It is therefore the function of the chain of ossicles to transmit to the fluid of the labyrinth whatever impulses may be communicated to the membrana tympani by sonorous vibrations in the air of the external auditory canal.<sup>2</sup>

<sup>1</sup> This articulation is not unlike the knee-joint, where the articular surfaces are separated by an interarticular cartilage (called *meniscus*, in the stapedo-incudal joint).

<sup>2</sup> This doctrine, which was first put forth by Edward Weber, in 1851, was confirmed experimentally by Politzer, in 1868, and afterward by other observers.



Whatever then may be the nature of these vibrations, it is evident, from the character of the attachments which hold the hammer *in situ*, that the only impulses which this ossicle is capable of transmitting are such as may be communicated to a single point in the handle, as, for instance, the tip. In the case, therefore, of a purely simple tone—by which is meant one that is perfectly free from all admixture of overtones—the point referred to would be subjected to a simple, pendulum-like motion.<sup>1</sup> In the case of a

<sup>1</sup> During the winter of 1869-70, I made a series of experiments for the purpose of determining accurately the behavior of the different ossicles, the drum-membrane, and the membrane of the round window, under the influence of somewhat violent sonorous impulses. I will give here a brief account of these experiments.

Eleven human adult temporal bones were removed from the bodies as soon as possible after death, and preserved in a very weak solution of spirits of wine. A portion of the cartilaginous external auditory canal was left attached to each temporal bone, sufficient to admit of the introduction of a suitable sound-conducting tube. The roof of the drum was then carefully chiselled away until a good view could be obtained of the greater part of the hammer and anvil, and of the head of the stirrup. The labyrinth and all the connections of the membrane of the drum and ossicles, with the exception of the *ligamentum mallei superius*, were left undisturbed. As sound-producing media, organ-pipes were found to answer the purpose best. To connect these with the ear in such a way that the vibrations within the pipe might be conveyed with the least possible loss to the air contained in the external auditory canal, the open end of the pipe was closed with a thin board cover, and a glass tube 17 ctm. long, and with a lumen of 14 mm., was firmly inserted into an opening in the centre of the board. The free end of the glass tube had been previously drawn out so as to present a lumen of 5 mm. This was made to fit tightly in the external ear by surrounding the end with sealing-wax. For light, an ordinary kerosene lamp was used, the rays from which were concentrated by means of a convex lens on the spot to be observed. This had been previously dried with the end of a heated wire, and then sprinkled with powdered starch. These fine masses of starch, when examined with a low power of the microscope (24 diam.), appeared as sharply defined luminous points, or, when set in rapid motion, as luminous lines. In the course of the experiments, however, it was ascertained that starch could be dispensed with, as the simple irregularity and moisture of the parts offered a sufficient number of luminous points for all purposes of observation.

*Measurements.*—The average measurements obtained in the manner described above show that an impulse given to the centre of the drum-membrane is communicated from ossicle to ossicle with a loss in the following ratio:—

Hammer	= 4
Anvil	= 2
Stirrup	= 1

In two instances where the membrane of the drum was caused to vibrate feebly, scarcely any loss took place in the transmission of the impulse from the hammer to the stirrup. If we take into consideration, moreover, that all these measurements may be looked upon as representing rather the maximal than the ordinary excursions of the ossicles, it may well be doubted whether during life the loss in transmission be not much smaller than that given above.

*Direction of luminous lines on different parts of the ossicles.*—As observed from above, the luminous lines on the heads of the hammer and anvil appeared slightly divergent outward. This divergence was found to be the same on all the specimens. As ob-

complex tone, or of two or more tones produced simultaneously, it is not so easy to represent clearly to the mind's eye the movements which the point in question must execute. Prof. Alfred Mayer, of the Stevens Institute of Technology (Hoboken, New Jersey), has devised an experiment which almost renders these movements visible to the eye. It was executed in the following manner :

Placing a stretched membrane in a vertical position, and attaching fine threads of silk to its centre, Prof. Mayer put them moderately upon the stretch, and fastened them, each one to a tuning-fork (to one branch only) of different pitch. Upon sounding an organ-pipe (an instrument rich in overtones) on the other side of the membrane, he distinctly heard the tones of some of the forks. The moment the threads were cut, the tones ceased. After the threads had been reattached, the forks again vibrated audibly. When the organ-pipe was changed for one of a different pitch, it was observed that a different set of forks were excited to vibration.

served from the side, in a direction at right angles to the long axis of the hammer, they presented the following appearance : On the hammer the luminous lines appeared to be arcs of circles whose common centre lay in the immediate neighborhood of the *processus Folianus*. On two of the specimens it was noticed that the luminous lines, measured at the very end of the handle of the hammer, were 0.43 mm. and 0.38 mm., whilst those measured at the head were 0.31 mm.; in other words, that in these instances, at least, the axis of rotation did not pass through the middle of the ossicle, but somewhat above it. On the lower part of the long process of the anvil the luminous lines seemed to be nearly or quite vertical, but on approaching the body of the bone they became more oblique.

As observed from above, the luminous lines on the stirrup appeared in the majority of cases to be directed nearly, though not quite, at right angles to its base. In only two cases was it found possible to obtain a view of both arms of the stirrup at once. In one of these cases the luminous lines were directed at right angles to the base, while in the other they ran somewhat obliquely toward it. The inclination in all cases was toward the anterior extremity of the base. Viewed from the side, the luminous lines on the stirrup were in all instances directed obliquely upward and inward across the head and anterior arm. In one specimen the upper and inner wall of the vestibule was carefully chiselled away, so as to present an inner view of the base of the stirrup. When it was put in vibration the luminous lines on the upper border of the base measured 0.03 mm. and were vertical, but on the lower border there was not sufficient motion to admit of measurement.

*Fenestra Rotunda.*—Enough of the lower wall of the drum-cavity was removed in one specimen to admit of a good view of the *membrana tympani secundaria*. The moment the organ-pipe was sounded the bright spot in the centre of the membrane lengthened out into a distinct luminous line of 0.04 mm. On the head of the stirrup, as seen from above, the luminous lines measured only 0.03 mm. The superficial area of the *fenestra rotunda* being smaller than that of the base of the stirrup, a greater excursion might rightly be expected from the membrane of the former. In the present case the membrane was observed obliquely from the side and not directly in profile, so to speak; hence the measurement would represent only a portion of the true length of the excursion. The measurements on different parts of the ossicles, before and after breaking up the membrane of the round window, were the same.

While this experiment, then, furnishes us with a most valuable means of analyzing sound, it also clearly demonstrates that a given point in a solid body can be made to perform, at one and the same instant of time, the vibrations belonging to a number of tones of different pitch; in the present instance these were the fundamental note of the organ-pipe, together with its overtones. This complex vibration has often been compared to the changes which take place on the surface of a body of water. Thus, for instance, in looking at the ocean, we often observe that the surface is thrown into undulations by long and heavy swells; while upon them are numerous waves and smaller wavelets. Here, then, we see an illustration of the manner in which several kinds of waves may set in motion the same body of water at the same moment of time, without interfering with each other in any way.

If we admit that the ossicles can vibrate in this manner in response to four or five tones, sounded simultaneously, there remains no serious obstacle to the belief that they can also vibrate in response to an almost indefinite number of tones. In listening to conversation, to music, and to simple noises, our *ossicula auditus* are simply called upon to transmit at one and the same moment of time a varying number of impulses—for music, noises, and conversation, are all reducible to combinations of purely simple tones.

In the last place, how is it possible for the terminal filaments of the auditory nerve to analyze these impulses of such varying rates of vibration? Before I attempt to answer this question, it will be necessary to take a glance at the anatomy of the last cavity mentioned above,—the labyrinth,—and to inquire into the mechanical effects produced upon its contents by the piston-like motion which we have attributed to the stirrup.

If we take a temporal bone, either in its natural condition or in the dried state, and endeavor by simple inspection to get some idea of the form, size, and relations of the labyrinth, we shall fail completely. There are only two points where we can get a glimpse of this portion of the ear, and these are at the two openings mentioned above as being situated in the inner wall of the middle cavity or tympanum. At all other points the various channels and cavities of the labyrinth are deeply imbedded in the substance of the petrous portion of the bone. It is only by the aid of the hammer, the chisel, and the knife, that we can obtain the thin shell of bone which represents, as it were, the mold of the contained cavities. In this way we find that the labyrinth—we are speaking now only of its osseous boundaries—consists of a central cavity, not more than two lines in diameter, from one side of which spring, like arches, the three semicircular canals, while from the other side a canal leads into the snail-shaped body called the cochlea. In their natural state these bony cavities are filled with membranous structures and fluid. Thus, for example, the central cavity—or *vestibule*, as it is technically called—contains two distinct membranous sacs (see Fig. 4),

which together do not quite take up the entire space of the cavity, but leave room, in the immediate vicinity of the foot-plate of the stirrup, for a certain amount of free fluid (Henle). The smaller of the two sacs, the *sacculæ* (*S*, Fig. 4), communicates with one of the membranous tubes of the cochlea, the *ductus cochlearis*. The larger one, the *utricle* (*U*, Fig. 4), is continuous with the membranous tubes, which partially fill the semicircular canals: in fact, the two constitute an intercommunicating system of cavities, containing fluid, and bounded by membranous walls, so that pressure made upon the utricle will result in an increase of tension in the walls of the membranous semicircular canals.

If we uncoil the cochlea, and so convert it into a single straight bony tube, we shall find that its shape resembles that of an elongated truncated cone, whose base corresponds to the vestibular end of the cochlea, while

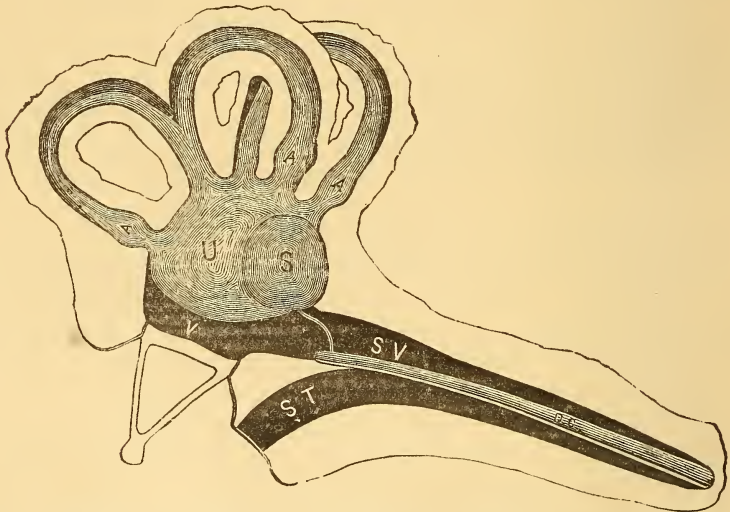


FIG. 4.—Diagram of the Labyrinth: *V*, the vestibule, or central cavity, which is nearly filled by the utricle (*U*) and the sacculæ (*S*). Near the foot-plate of the stirrup, there is free fluid, which also extends up into the scala vestibuli (*SV*) of the cochlea. *DC*, the ductus cochlearis, which communicates by a slender membranous channel (canalis reuniens) with the sacculæ. Between the cochlear duct and the scala tympani (*ST*) is a narrow white band, representing the membrana basilaris. At the extreme tympanic end of the scala tympani, a faint white line indicates the position of the membrana tympani secundaria. *A, A, A*, ampullæ of the membranous semicircular canals, which, in these regions, fit pretty closely their surrounding bony walls.

the smaller end would represent the cupola, or highest point of the cochlea in its natural position. There are certain membranous<sup>1</sup> septa which divide this single conical tube into three distinct and entirely separate channels, one communicating directly with the vestibule, while the other two are entirely shut off from any communication with it. In the first

<sup>1</sup> In one instance partly membranous and partly osseous.

place, a sort of diaphragm divides the tube horizontally into an upper and a lower passage, each of nearly equal size. The upper one communicates by a broad mouth with the cavity of the vestibule, and for this reason has been named the vestibular channel or *scala vestibuli*; the lower follows its course toward the tympanum, but at the round window is shut off from it by a thin membrane—the *membrana tympani secundaria*. This lower channel is called the *scala tympani*. (Follow Fig. 4 for all these points.) A second diaphragm, which runs at an angle of  $45^\circ$  with the first (see Fig. 6), divides the upper channel into the *scala vestibuli* proper and the *ductus cochlearis*. This last-named duct or channel is in reality a closed sac; its shape being that of an elongated truncated cone, whose base occupies the cupola, while the smaller end lies at the very entrance to the cochlea in the vestibule. The *ductus cochlearis* may therefore be described as a body of fluid imprisoned within membranous walls, and containing certain peculiar structures, which will be mentioned in detail hereafter; and it may also be described as playing the part of a diaphragm between the fluid of the *scala vestibuli* and that of the *scala tympani*.

We have now completed our hasty sketch of the labyrinth as a system of channels and closed sacs containing fluid, and it still remains for us to speak of the peculiar structures contained within the *ductus cochlearis*,—structures which have been shown to stand in direct communication with filaments of the auditory nerve, and which must therefore be considered as constituting the real terminal apparatus of hearing, in the same sense as the retina is held to be the terminal organ of sight.

In the first place, the diaphragm, mentioned above as dividing the entire cochlear tube into an upper and a lower passage, will be found on microscopic examination to consist partly of bone and partly of membrane. The membranous portion of this diaphragm—if it were possible to dissect it out entire and spread it out before us—would be found to have a shape something like that given to it in Fig. 5. The small end *V* represents the commencement of the membrane near the round window, and the large end *c* its termination in the cupola. If we remove all the superimposed structures and examine this membrane under the microscope, we shall find it to




FIG. 5.—Diagram of the Membrana Basilaris: *V*, its vestibular end; *c*, that in the cupola.

consist of an almost countless number of rods, separated one from another by a glue substance of but slight adhesive power. If we leave the superimposed structures *in situ*, and make a transverse section through the mem-

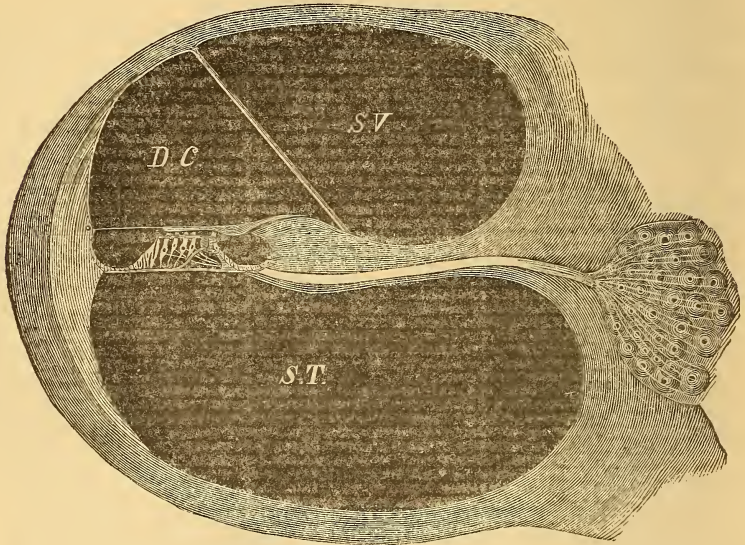


FIG. 6.—Transverse Section of a Cochlear Whorl. On the right, embedded in the substance of the bone, is a group of *ganglion cells*, through which the fibres of the auditory nerve pass before entering the *lamina spiralis ossea*. This latter is represented in the figure as a broad septum, separating the *scala vestibuli* (*S V*) from the *scala tympani* (*S T*), and containing a canal for the passage of the auditory nerve-fibres. In the canal these fibres still possess a medullary sheath, but, on emerging therefrom into the *ductus cochlearis* (*D C*), they break up into naked axis-cylinders and terminate (as white threads in the drawing) in the single *inner* and four *outer hearing cells*. The cilia of the four *outer hearing-cells* may be seen projecting through the *lamina reticularis*; those of the single *inner cell* (invisible in the drawing) project above the head of the *inner pillar of Corti*. The *lamina reticularis* is drawn as an horizontal projection (outward) of the upper portion of the head of the *outer pillars of Corti*. Underneath, these pillars rest upon the *membrana basilaris*, which terminates on the outer side in the *ligamentum spirale* (represented in the figure as a pale, crescent-shaped pad of connective tissue, fitting accurately to the surrounding shell of bone). The cilia of the hearing-cells come into contact above with the *membrana tectoria* or *Corti's membrane*, which springs from the upper side of the *lamina spiralis ossea*, near its free extremity, and terminates, by a thin extension, in the *ligamentum spirale*. *Reissner's membrane* is represented as a straight band, which stretches from the bony wall above, down to the upper side of the *lamina spiralis ossea*, and separates the *ductus cochlearis* from the *scala vestibuli*.

brane, we shall find that it carries upon its upper surface the following peculiar anatomical elements (see Fig. 6).

1. A nearly central<sup>1</sup> arch, composed of two pillars, called respectively the *inner* and *outer pillars of Corti*. The shafts of these pillars are compara-

<sup>1</sup> The arch occupies such a position that the bases of the outer pillars stand very nearly in the centre or median line of the membrane. It is a significant fact that the outer rows of hearing-cells also occupy the central portion of the membrane, or that part which performs the greatest amplitude of excursion.

tively slender, but their bases and their heads are broad. The points to which attention should be called in the anatomy of these pillars, are their great strength and stiffness as compared with the other structures to be found in the ductus cochlearis; the constantly increasing distance between the bases of the inner and outer pillars, as you go from the vestibule to the cupola; and, finally, the rounded character of the articular surfaces, where the heads of the inner and outer pillars come together—a peculiarity of connection which would indicate that a certain amount of play would be possible between the opposite heads of the pillars, in case the vibrations of the entire apparatus take place in a vertical plane.

2. A peculiar fenestrated membrane, the *lamina reticularis*, which extends in a horizontal direction some little distance outward from the heads of the pillars of Corti, to which it seems to be in some way attached.

3. Five rows of ciliated cells, four on the outer side of the arch, and one on the inner side, close to the inner pillars of Corti. The four outer rows insert their heads into the openings of the fenestrated lamina reticularis in such a manner that the cilia stand up like bunches of hair at regular intervals along the surface of the membrane. Bundles of primitive nerve-fibrils from the cochlear branch of the auditory nerve have been traced to all five rows of ciliated cells, but to no other structures in the ductus cochlearis. Hence the name of *hearing-cells*, which has very appropriately been awarded to these evidently the most important elements in the apparatus we are endeavoring to describe.

4. Simple epithelial cells, destined apparently to serve as a support to the lamina reticularis and to the outer and inner rows of hearing-cells.

5. A peculiar membranous structure, which starts from the upper side of the hooked shaped process of the *lamina spiralis ossea* and extends outward over the lamina reticularis. This membrane is mucoid (or doughy) in consistency, and, from the fact that it lies like a gelatinous veil over, and perhaps in contact with, the cilia of the hearing-cells, it is called the *membrana tectoria*<sup>1</sup> or covering membrane. As far as to the outer limit of the hearing-cells, this membrane retains its thick, doughy consistency, but beyond this region it is continued in the form of a very thin lamina to its line of insertion in the *ligamentum spirale*.

It is not necessary to a clear understanding of the mechanism of the final act of hearing, that we should enter, any more fully than we have done, into the minute anatomy of the ductus cochlearis. What remains for us to do is to follow out, step by step, the mechanical effects upon the various labyrinthine structures of the piston-like vibrations of the stirrup; for it was here that we left off in our efforts to trace the effects of sound upon the apparatus of hearing.

The theory which is universally accepted by physiologists in explanation

<sup>1</sup> Also *membrane of Corti*.

of this point is the one given by Prof. Helmholtz, and called, in honor of that distinguished physicist, "the Helmholtz theory of hearing."<sup>1</sup> The essential points in it are these: the component fibres of the membrana basilaris (Fig. 5) are to be considered in very much the same light as separate strings, which by a process of loading—that is, weighing them down with the pillars of Corti, the hearing-cells, etc.—have been tuned so as to vibrate in sympathy with all the appreciable tones, from the highest to the lowest.<sup>2</sup> In fact, for every half-tone of our present musical scale there must be in the cochlea at least thirty-three strings to represent all its possible shades. When the stirrup, for instance, vibrates one hundred times in the second, it must excite to action that particular string, or group of strings, which is tuned to vibrate one hundred times per second. The vibration thus caused makes an impression upon the nerve supplying the vibrating part, and this in turn produces in the brain the sensation of sound. The damping of the vibrations, at the instant the irritation which produced them ceases, is attributed partly to the presence of a fluid medium, and partly to the fact that the vibrating structures proper (the strings of the membrana basilaris and the pillars of Corti) are pressed upon by cell-bodies which are not adapted for vibration.

The vertical vibration of the basilar membrane is distinctly recognized in this theory; but, in the preliminary description of the anatomy of the cochlea, mention is made of the existence of a small opening (*helicotrema*) in the cupola, through which a communication is established between the scala vestibuli and the scala tympani. According to Kölliker and Reichert, the blind sac of the ductus cochlearis entirely fills the cupola (the vestibular half of it). This statement would seem, then, either to throw doubt upon the existence of such an opening, or to make it a channel of communication between the ductus cochlearis (instead of the scala vestibuli) and the scala tympani. The latter supposition, however, involving as it necessarily does a certain degree of longitudinal current in the fluid of the ductus cochlearis, cannot for a moment be entertained, as it would utterly overthrow any theory based upon the sympathetic vibration of the fibres of Corti's organ. On the other hand, if the blind termination of the ductus cochlearis does not entirely fill the cupola—as some authorities maintain—but leaves room for the fluid of the scala vestibuli to pass through a small opening in the septum into the scala tympani, the theory of a vertical motion for the membrana basilaris is still tenable, as the existence of the *helicotrema* will simply serve to diminish the force of the vertical motion, but not to annul it. My own investigations, so far as they go, favor the view that no communication exists between the two scalæ in the immediate vicinity of the

<sup>1</sup> See his work entitled *Die Lehre von den Tonempfindungen*, Braunschweig, 1870.

<sup>2</sup> The highest tones corresponding to the short strings near the vestibule, the lowest to the long ones in the cupola.



cupola, unless the opening, spoken of so vaguely by the authors, be microscopic in size.<sup>1</sup>

In the light of the histological discoveries made since the time when Helmholtz published his "Tonempfindungen" (1870), we would, with all due reserve, venture upon the following explanation of the mechanism of hearing in the cochlea:

We have described the labyrinth as a closed cavity, having but two channels of approach—the round and the oval windows—one of which is filled up tightly by the foot-plate of the stirrup. Since, according to physical laws, the fluid contents of the labyrinth cannot be supposed to undergo diminution in bulk, under the pressure made by the foot-plate of the stirrup, we must assume—what has now been proved by direct observation—that the elastic membrane of the round window affords the required yielding-point for this displacement.<sup>2</sup>

The first body to receive the impulse of the stirrup is the free mass of fluid which fills those portions of the vestibule and the scala vestibuli, which are not occupied by membranous sacs. Without stopping here to discuss the effects of the stapelial<sup>3</sup> impulse upon the utriculus and semi-circular canals, let us proceed at once to the consideration of the effects which this impulse will produce upon the cochlear structures.

In the first place a moment's thought will convince us that, in estimating the effects of the stapelial impulse upon the ductus cochlearis, we may totally disregard the sacculus and the *canalis reuniens*.<sup>4</sup> The uniform pressure of the fluid upon all sides of these last-named cavities will effectually prevent anything like a current from the ductus cochlearis to the sacculus, or the reverse, through the *canalis reuniens*. The ductus cochlearis—that

<sup>1</sup> To satisfy myself, if possible, on this point, I removed the cochleæ entire from the temporal bones of an infant, and softened them in a solution of chromic acid and hydrochloric acid (not more than five per cent. of each). When the earthy materials had been entirely removed from the bone, I placed the specimens in ordinary alcohol for a few hours, and with the razor divided them each into two unequal parts, the plane of section being at right angles to the base of the cochlea. In one of the cochleæ, the section passed so close to the bottom of the *cul-de-sac* of the cupola, that it was difficult to determine anything satisfactory with regard to the opening in question. In the other it was a comparatively easy matter, with an ordinary magnifying-glass, and after blowing out the free alcohol, to survey both the vestibular and tympanic surfaces of the septum, which in the cupola divides the two channels from each other. No trace whatever of any communication between the two passages could be detected.

The results of a single examination like this cannot, of course, be considered as sufficient to overthrow the statements of the anatomists. Nevertheless, the lack of definiteness in their descriptions of this opening (*see* Henle's Anatomy and Waldeyer's article on the Labyrinth in Stricker's Histology), taken in connection with its apparent absence in this one case, should lead to new investigations on this point.

<sup>2</sup> This statement will be slightly modified farther on.

<sup>3</sup> *Stapes*—a stirrup.

<sup>4</sup> The little canal (Fig. 4) which unites the sacculus and the ductus cochlearis.

is to say, the upper and inner wall of it, or *Reissner's membrane*—is therefore subjected to a uniformly distributed pressure from above downward by the *centrifugal* (if I may so use the term) force of the fluid of the *scala vestibuli*. As it yields beneath this force, the incompressible body of fluid which fills the *ductus cochlearis* must in turn find its yielding-point in the entire *membrana basilaris*; for this and *Reissner's membrane* are the only two portions of the wall of the duct which are membranous, and therefore capable of yielding. Finally, the displacement caused in the contents of the *scala tympani*, by the depression of the entire *membrana basilaris*, is provided for by the presence of an elastic membrane (*membrana tympani secundaria*) at the larger end of this channel.

This brings us, then, face to face with the fact that the *entire membrana basilaris* (including high and low notes alike) is obliged to perform all the excursions which may be communicated to the stirrup or the *membrana tympani* by sonorous vibrations; or, to speak more minutely, with every tone sounded, every "organ of Corti"<sup>1</sup> must perform the excursions which belong to that particular tone. But if that be true, it will be asked, why should not *all* the nerve-filaments send communications to the brain; or, in other words, why should we not hear all the notes of the scale whenever any one of them happens to be sounded? This is our answer, and we might add that it has been suggested to us by the peculiar relations of the *membrana tectoria* to the hearing-cells, and by the passing remark of *Waldeyer* (in the article referred to above) that "no portion of the labyrinth could be better adapted, by reason of its anatomical construction and position, to perform this function [that of a damper] than the *membrana tectoria*."

Although it be true that, with every note sounded, all the organs of *Corti* must perform the excursions belonging to that note, yet it must be remembered that the semi-gelatinous *membrana tectoria*, which rests upon the cilia of the hearing-cells, will likewise be obliged to perform these same excursions. Over one particular region, however, of the *membrana basilaris*, this will not be the case, namely, in that portion where the thirty or more *basilaris fibres* are tuned to vibrate in sympathy with the note sounded. At this point the vibrations will be of sufficient vigor to throw off the *membrana tectoria*. So long, then, as that particular note is sounded, the cilia of the hearing-cells, in the region referred to, will receive a succession of taps from the *membrana tectoria*, or, to speak more strictly, will strike against this membrane. These blows constitute the true irritation of the auditory nerve. Wherever the blows do not take place, although the auditory nerve-filaments may be agitated in a direction at right angles to their length, there no sensations of sound will be communicated to the brain.

Still, another theory may be put forward in explanation of the mechan-

---

<sup>1</sup> The term "organ of Corti" is used to designate the entire group of structures built upon the *membrana basilaris*.

ism of the membrana tectoria. This membrane, in the natural relations of these parts, may not lie stretched out like a semi-gelatinous covering over, and in contact with, the cilia of the hearing-cells. It may, instead, be stretched like a canopy, a very short distance above them,—so short a distance, in fact, that, when any given group of organs of Corti is excited to sympathetic vibration, the cilia of the hearing-cells belonging to that group will strike against it, and so will experience the irritation necessary to the perception of sound. This theory does away with the necessity of a

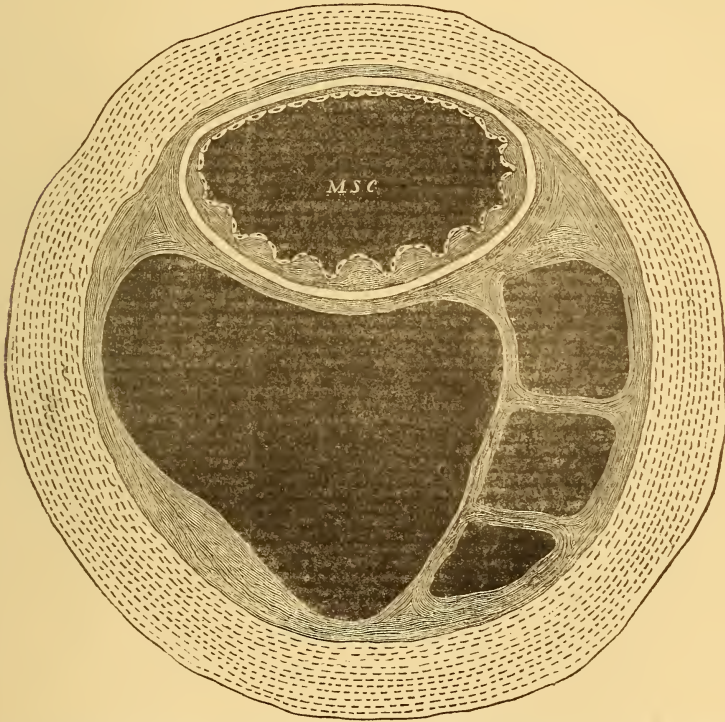


FIG. 7.—Transverse Section of Semicircular Canal. (Copied from Rüdinger.) *M S C*, membranous semicircular canal. (For further details, see the text.)

dampener, but calls for a semi-soft, tense membrane (like that of the membrana tectoria) against which the cilia may strike without danger of being injured by the blow.

Before leaving the subject, we should like to venture a suggestion as to the function of the semicircular canals.

As is well known, the doctrine is almost universally upheld, that these canals contain organs which govern the function of equilibrium (Flourens's theory). About eight years ago Arthur Boettcher,<sup>1</sup> of Dorpat, demonstrated

<sup>1</sup> Dorpater med. Zeitschrift, Vol. III., Part II., 1872.

by experiments upon living animals that this theory is probably incorrect (See Chapter XI.). He proposed no new theory, but opened the way for others to do so if they wished.

The first thing that attracts our attention in the anatomy of these organs is the peculiar relation of the membranous to the bony canals, the former occupying scarcely a third of the calibre of the latter. Then, in the next place, the space between the membranous canal and the bony walls is filled, not with free fluid, as is the case, for example, in the cochlea, but with a reticulated connective tissue, rich in blood-vessels and made up of large meshes containing fluid. In the vicinity of the mouths of these canals, however, it should be noticed that the membranous tubes hug the bone more closely (*see* Fig. 4). If we examine the mode of construction of the membranous canals, we find that the outer elastic wall (*see* Fig. 7) is lined with a sort of mucous membrane whose free surface undulates or is thrown into mounds, and carries a lining of ordinary pavement epithelium. Another point worthy of notice is the absence of the undulations or mounds on that side of the canal which lies next to the bone—the side where dilatation cannot take place. These anatomical relations and the absence of nerves are certainly suggestive of the thought that the function of these canals must be a mechanical one. Is it not their function, we would ask, to protect the ductus cochlearis and the organs of Corti from injury in cases where the stirrup is driven too violently into the oval window? Any pressure made upon the utriculus can only find a yielding point in the elastic walls of the membranous semicircular canals; and, furthermore, if the latter were lined with a smooth instead of an undulating epithelial surface, their distention would be followed by a rupture of the epithelial lining.<sup>1</sup> Any sudden and loud noise, like the report of a cannon or a peal of thunder, would be likely to injure the cochlear structures, were not some provision made in the labyrinth for extraordinary events of this kind. As we have shown, the semicircular canals are not only admirably fitted to serve in the capacity of safety-valves, but their entire mode of construction, especially the absence of all nervous structures (except in the ampullæ), would seem to exclude them from any higher office in the mechanism of hearing.

The suggestion of a recent writer (Hensen), that their function is that of secreting the labyrinthine fluid, has against it the fact that the epithelial cells lining the canals are of the pavement and not of the cylindrical or glandular variety.

---

<sup>1</sup> To establish this theory, it will be necessary to ascertain the circulation of blood in these parts, for the anastomosis of the veins surrounding the membranous canal with the veins of the bony walls is apparently essential to it.

## CHAPTER II.

### EXAMINATION OF THE PATIENT.

#### TESTS OF THE HEARING-POWER.

As a large proportion of the diseases of the ear are associated with impairment of the function of hearing, we constantly find it desirable to measure the degree of this impairment. Furthermore, this part of our examination of the case is usually carried out before the condition of the ear has been disturbed by the manipulations incident to the further examination of the patient. It seems proper, therefore, to consider this branch of our subject first, and to describe afterward the more strictly instrumental methods of examining the ear.

There are two tests in common use for estimating the acuteness of a person's hearing-power. These are, the ticking of a watch and spoken or whispered words or sentences. Both of these tests are unsatisfactory in very many cases. Thus, for example, one patient will distinguish the ticking of a watch when held at a certain distance from the ear, and yet he will not be able to understand ordinary conversation. Another will hear conversation with perfect ease and yet be unable to distinguish the ticking of a watch except when it is pressed against his ear. Again, a patient will at one time, *e.g.*, during a subacute inflammation of the middle ear, hear the ticking of a watch only a very short distance, perhaps an inch or two, and will experience considerable difficulty in understanding spoken words. As the inflammation subsides, and the fluid exudation undergoes absorption, he will experience a very decided improvement in his power to understand conversation, but little or no improvement in his power to distinguish the ticking of the watch. On the other hand, an appreciable improvement in the power to distinguish the ticking of a watch is commonly associated with some (not a corresponding) degree of improvement in the power to hear spoken words. This last experience, coupled with the great convenience of the watch as a source of sound of uniform intensity, has led to its being generally used as a test, notwithstanding all its imperfections.

Theoretically it would seem as if the only proper test must be that by means of spoken or whispered words or sentences. Thus, for example, when a person, who is suffering from deafness, applies to a physician for

relief, his principal object is, not merely to regain the power of hearing certain delicate sounds (like the ticking of a watch), or of clearly distinguishing each individual tone in the musical scale, from the lowest to the highest, but rather to secure an improvement in, or a restoration of, the power to understand spoken language. Very few physicians, however, have office accommodations of sufficient extent to render such a mode of testing the hearing possible in any but the aggravated forms of deafness. In the next place, it is difficult to use the voice at the same pitch and with the same intensity on all occasions. Finally, certain words are distinguished by the ear much more readily than others. Take, as examples, such words as "distinguished" and "difficulty," and it will be found that a patient who can readily hear words like "alarm," "rider," "create," at a given distance, will fail utterly, at the same distance, to distinguish correctly these less resonant ones. In other words, we may test our patient's hearing at different times by means of spoken words, and obtain very different results each time, according to the character of the words used. If the test were trustworthy, the conclusions would be that our patient had improved or lost ground, according to the increase or diminution in the apparent hearing distance. The truth, however, might be that no change whatever had taken place in his hearing-power. Attempts have been made to remove these objections by preparing a series of test-sentences of uniform value as regards the prevalence of vowel-sounds. It is undoubtedly possible to prepare, in a rough sort of manner, such a series of test-sentences; but unfortunately the remaining objections to the employment of the voice as a means of testing the hearing, viz., inadequate size of room, difficulty of excluding outside noises, impossibility of always using the same pitch, loudness, and distinctness of voice, are still so serious, that in our large cities, at least, this mode of testing the hearing is not likely ever to be used to any great extent. In many cases, therefore, we are compelled to base our judgment with regard to the condition of the hearing, upon the patient's own statements or those of his friends. This is especially true in the case of young children, whose answers, when the watch is being used as a test, are generally untrustworthy. An observing mother or nurse, however, will be very likely to discover the first evidences of improvement in the child's hearing, and upon her statements we may safely base our judgment with regard to the progress of the case in this respect.

In the employment of both the tests mentioned, it will be found desirable to observe certain precautions. Thus, for example, if we wish to test the hearing of one ear by means of spoken words, it is absolutely necessary that the other ear should be closed quite firmly. The patient should also sit in such a position that the physician's voice may be thrown directly against the ear which remains open, *i. e.*, at right angles to that side of the head. If we desire to test the hearing-power of both ears, the patient should sit facing us, but with both his eyes closed. Deaf people sometimes

possess the power of "reading the lips" to such a remarkable degree that the test can hardly be considered a fair one unless the patient has kept his eyes closed. It is also not sufficient for the patient to answer that he has understood what was said to him; he should be required to repeat the exact words spoken by the physician.

In testing with the watch, it is not necessary to close the ear which is not being examined, as the ticking of an ordinary watch, or the click of Politzer's acoumeter, is too feeble a sound to reach the opposite ear through the head and intervening mass of air. When the watch is pressed against the ear, it is quite possible that the sound of its ticking may reach the other ear. At the same time I do not remember ever to have met with such an instance, and yet my watch ticks with such vigor that in a quiet room it can usually be heard at a distance of twelve feet. In carrying out the test it is better to bring the watch nearer and nearer to the patient's ear, until he says that he can hear it, than to remove it farther and farther away, until he says that he can no longer distinguish the ticking.

Thus far, the ticking of a watch has been found to afford the best practical means of testing the capacity of the ear for distinguishing delicate sounds. If Politzer's acoumeter could be surrounded by a solid metallic case, and if some better contrivance could be devised for producing the blows, the instrument might come into general use as a substitute for the watch. If measurements of the hearing distance could be universally made with some standard source of sound of fixed intensity, the necessity for recording our measurements in fractions (Prout's method) would be done away with; it would be sufficient to merely state the actual distance measured, and every physician who was familiar with such tests would appreciate at once the degree of impairment of the hearing reported. Politzer's idea in producing the "acoumeter" undoubtedly was to furnish such a standard test. Unfortunately, in its present shape this instrument costs too much, is likely to get out of order too easily, and cannot be manipulated with comfort. On the other hand, its click can easily be heard a distance of thirty feet in a quiet room, and the instrument can therefore be used in certain cases where the watch would fail to show even a fair degree of improvement in the hearing.

So long as we continue to use the watch as a means of testing the hearing, the fractional method of recording the hearing distance is undoubtedly the best. This method, which was first suggested by Dr. Prout, of Brooklyn, N. Y., requires that the numerator of the fraction should represent the distance at which the watch is heard by the person whose hearing is being tested, while the denominator indicates the average distance at which a reasonable number of persons with good hearing can distinguish the ticking of the same watch. It is only when we have occasion to report a case that it is desirable to designate the hearing distances in fractional terms. In our own private records the actual distances are alone sufficient.

## INSTRUMENTS AND METHODS OF EXAMINATION.

In the examination and treatment of patients suffering from ear disease we are in very great measure dependent for success upon the instruments which we use. If they are of clumsy or faulty construction, we are not likely to obtain all the information that we have a right to expect from their use, or our patients are subjected to unnecessary discomfort or even pain, which properly constructed instruments would not inflict. Two or three years ago I had occasion to inspect the ear-instruments kept for sale by several of our leading instrument-makers, and was amazed to find in how many important particulars these instruments were defective. Many were in fact entirely useless; and yet I was assured that these were the same as those which they had sold for several years past and were still constantly selling to physicians who asked to be supplied with the instruments usually required in the examination and treatment of the ear. In view of this fact I think I may very properly devote considerable space to the consideration of the subject of instruments.

Some individuals possess external auditory canals so large and straight that the physician can easily obtain a view of the drum-membrane without the assistance of instruments of any kind. In the great majority of adults, however, and in all young children, two kinds of instruments are required for the attainment of this object: one to push aside the soft walls of the orifice and render the canal approximately straight; the other to illuminate the parts thus rendered accessible. Different forms of specula supply the first want, and concave reflectors the second.

*Ear-Specula.*

There are practically four kinds of ear-specula now in general use, and they may all be purchased in three different materials: hard rubber, German silver, and coin silver. If nitric acid or nitrate of silver is to be applied to some particular part of the drum-membrane or auditory canal, a hard-rubber speculum will be found a very useful instrument, as these corrosive substances destroy the brightness of the inner surface of the metal specula. Under ordinary circumstances, however, they will be found decidedly inferior to the metal instruments, and especially to those made of coin silver. The dark inner surface of the rubber speculum absorbs much of the light which in the metal instrument is reflected down upon the deeper parts of the auditory canal. So, far, therefore, as the choice of materials is concerned, the gain in the degree of illumination decides the question in favor of the coin silver.

Of the four different forms of specula usually to be found in the shops, two seem to me to be unpractical, and well adapted in inexperienced hands



to cause pain. I refer to the instruments which bear the names of Toynebe and Von Troeltsch. Of the remaining two, those of Wilde and Gruber, I may say that, while I employ both, I think the preference should be given to the short conical Wilde's specula. There are very few cases in which the advantages claimed for Gruber's specula are likely to be appreciated. These advantages are: first, with a meatus of a given size, a larger field of view can be obtained than with a conical instrument; second, the broad external mouth of the speculum leaves more room for instrumental manipulations than is afforded by any other form of speculum. These two advantages must be conceded to Gruber's instrument, whose oval shape corresponds with that of the average adult meatus; but, as I have just said, it is not often the case that we miss these advantages in using the conical Wilde's specula. On the other hand, the latter instruments possess certain advantages which may be observed in every-day practice and which are likely to make them permanently the most popular of the different aural specula. In the first place, the conical instruments can be kept polished on the inside much more easily than those of the Gruber pattern. This is an important advantage, which the physician will appreciate just in proportion to the degree of use which he makes of the instrument. A second advantage is to be found in the good purpose which the instrument serves as a dilator. In cases of œdematous swelling of the outer portion of the meatus it is sometimes astonishing to what an extent the calibre of the canal may be enlarged by the judicious employment of these specula. Beginning with the smallest size of instrument, and pushing it inward with a rotatory movement, we may introduce one after another of the different sizes until we are able to employ one with an aperture of even five millimetres. The oval shape of Gruber's speculum renders its use as a dilator less easy to the physician, and decidedly more painful to the patient.

The practitioner should possess at least three sizes of ear-specula. The smallest size should have an aperture of not less than three and a half millimetres. An expert, it is true, can use one with an aperture of only three millimetres, but the task of seeing anything through it is far from easy. On the other hand, it is rare that he will find any advantage from using an instrument with an aperture of more than seven millimetres. With regard to the proper length of an ear-speculum, I should place it at from three and a quarter to three and a half centimetres. In selecting a set of specula, preference should be given to those which have the thinnest walls. The great majority of ear-specula sold in the shops are of too solid construction. The thick walls of the instrument greatly diminish its internal calibre, and thus narrow the field of vision attainable with a meatus of a given size. It is safe to say that the thickness of the walls of the average ear-speculum might be diminished one-half without rendering the instrument unduly liable to bend. The blackening of the inner surface of the speculum simply diminishes the degree of illumination obtainable with a given source of

light. Polished specula are therefore preferable—certainly for purposes of diagnosis.

*Reflectors.*

Two kinds of contrivances are generally used for the purpose of reflecting light into the external auditory canal, *viz.*, the *hand-mirror* and the *forehead-mirror*. So far as the mirror itself is concerned, these two are one and the same thing. In practice it has been found that the best illumination is obtained with a concave mirror of circular form, whose focal distance may vary from twelve to thirty centimetres, according to the visual power of the observer. The majority of men will find a focal distance of about twenty centimetres the best adapted to their purposes. With regard to the size of the mirror, it may be said that one having a diameter of seven centimetres is as large as the observer can conveniently handle. Almost all the mirrors offered for sale have a central aperture, or unsilvered spot, through which the observer can see the parts illuminated directly in the focal line. If the hand-mirror be used, it is probably better to place the eye in the focal line than to look over the edge of the mirror. At the present day, however, all students of otology who are not near-sighted should be taught to use only the forehead-mirror. While at first it may be found more difficult to manipulate than the hand-mirror, its advantages over the latter are so great as to more than compensate for the difficulties encountered in learning how to use it properly. These difficulties once overcome, the physician no longer requires an assistant, but has both hands free for the various manipulations which are required in even the simplest case. The forehead-mirrors usually sold in the shops, and commonly pictured in the text-books, are very poorly adapted to the wants of an aural surgeon; some of them are in fact absolutely useless for his purposes. If we examine these instruments carefully, we shall find that they are fundamentally wrong in two respects: first, no space—or insufficient space—is left between the forehead-plate and the upper edge of the mirror, thus rendering it either difficult or impossible for the observer to see the ear; second, the ball and socket joint, by which the mirror is attached to the forehead-plate, allows the former to be rotated to such a limited extent, both from side to side and from before backward, that the observer will often find himself unable to use the source of light that may happen to be available, unless he changes its position or that of the patient, or both. If the forehead-mirror, however, be properly constructed, the observer will find comparatively little difficulty in placing himself in such a position that he can utilize almost any source of light that he may find at hand. The accompanying cut (Fig. 8) gives a correct representation of a forehead-mirror well adapted to the wants of the aural surgeon. The details of construction are as follows: The forehead-plate is made of hard rubber,  $9\frac{1}{2}$  ctm. long,  $2\frac{1}{2}$  ctm. broad at the broadest part, a trifle more than a millimetre in thickness, and curved flatwise, so as to lie

at all points in firm contact with the forehead. This concave side should not be padded, partly for reasons of cleanliness, and chiefly because such padding materially diminishes the stability of the mirror when once adjusted to the observer's forehead. At both ends of the plate there is a long and narrow opening, through which the forehead band or strap is to be inserted. A word or two with regard to the latter. The dealers are in the habit of furnishing forehead-bands of elastic material covered with black cotton or silk. In summer time, or in a warm room, the dye is set free by the perspiration, and the physician finds a black stain on his temples wherever the band has touched the skin. To obviate this annoyance the fore-

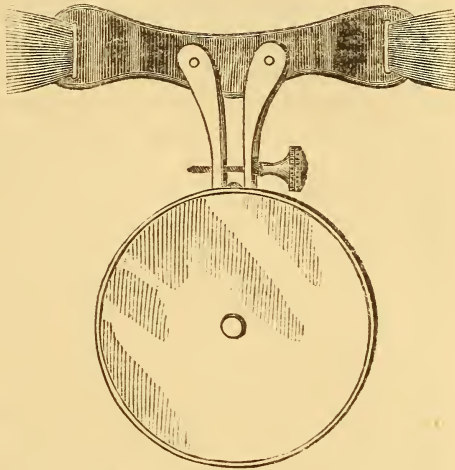


FIG. 8.—Forehead-mirror. (Half the natural size.)

head-band should be made partly of undyed leather and partly of elastic material. The leather portions should begin at either end of the forehead-plate and should extend to a distance of twelve or thirteen centimetres from these. Beyond these limits an elastic band of any material or color may be used. The adjustment of the band to the size of the head is effected by means of a buckle.

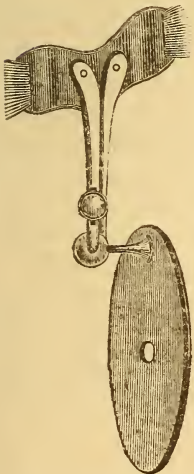


FIG. 9.—Forehead-mirror. Profile view.

As to the mirror itself, I have already described it sufficiently. Its mode of attachment to the forehead-plate is, however, a matter of great importance. All the contrivances used for this purpose are based upon the principle of the ball and socket joint. The majority of them, however, as I have already stated, allow so little freedom of motion that the physician often finds himself unable to use the source of light at his command. In the first place the ball should be attached, through the medium of a strong stem (of solid brass), to the metal back of the mirror (see Fig. 9). This stem should be fastened to the mirror at a distance not exceeding seven millimetres from its circumference. The point at which the stem broadens out into the ball should also be seven millimetres distant from the back of the mirror, and the ball itself should measure about one centimetre in diameter. The socket in which the ball revolves con-

nects with the forehead-plate. The ball itself should measure about one centimetre in diameter. The socket in which the ball revolves con-

sists of two segmental sockets hollowed out of the ends of two brass shanks, which are attached, each by a single rivet, to the convex side of the forehead-plate. The length of each shank is five centimetres. By means of an adjustable screw, which passes through a slot in one shank, the mobility of the joint may be increased or diminished at will.

If we examine such a mirror as I have endeavored to describe, we shall find in the first place that it may be rotated unusually far forward, thus enabling the observer to use a source of light situated comparatively high above the patient's head. In the second place, the mirror may be rotated so far toward one side or the other that the observer can use a source of light situated close to the extremes of either side. In the third place, we are not so strongly tempted to close one eye, when using the forehead-mirror, as we are when looking through the central aperture of the hand-mirror. Only one eye does the real work of examination in both cases, but in using the forehead-mirror we are not conscious, in the slightest degree, that we are not observing the object with both eyes in the ordinary manner. Finally, if it be found desirable to inspect the illuminated parts in the focal line,—or, in other words, to secure the maximum degree of illumination,—the mirror can readily be rotated in such a manner as to bring the central aperture in front of either eye. Unless a mirror can fulfil all these requirements it may safely be assumed that the instrument is not as perfect as it is possible to make it.

I have gone thus minutely into the details of construction and advantages of the forehead-mirror because I have observed that the use of the hand-mirror in aural examinations is almost universal, not only in this country but also on the continent of Europe. As no one who has ever once experienced the comfort of working with a good forehead-mirror would ever think of returning to the habitual use of the hand-mirror, I can only explain the widespread use of the latter instrument by assuming that no really good forehead-mirror has been brought to the notice of the profession. The one which I have described is essentially the same as that which was first shown to me in 1870 by Dr. Robert F. Weir of this city, and which he had been using, if I remember rightly, for several months previously.

If for any reason it is thought desirable to magnify the object under examination, a lens of suitable focal distance may be held between the eye of the observer and the speculum. A person with good eyesight, however, will gain but little, if any, additional information by the use of lenses in the examination of the ear.

*Introduction of the Speculum and Use of the Reflector.*

If the physician wishes to introduce a speculum into the ear in such a manner as to gain a satisfactory view of the deeper parts, and yet not cause

his patient either harm or unnecessary discomfort, he must first gain tolerably clear notions of the anatomy of the external auditory canal, both in the adult and in the young infant. For the minute anatomical details I must refer the reader either to his manual of anatomy, or to some systematic treatise on the ear. I can here simply allude, in a very brief manner, to those peculiarities in the anatomy of the external auditory canal which seem to me to have an important practical bearing upon the procedure which it is proposed to describe in the present chapter.

*Anatomical considerations.*—In infancy, the external auditory canal is almost entirely composed of soft tissues, and the drum-membrane lies but little below the surrounding surface of the skull. In older children and in adult life the inner half of the canal consists of a cylinder of bone, the inner end of which is spanned by the drum-membrane. There are still other anatomical differences between the infantile canal and that of adult life, which bear directly upon this question of examinations of the ear. In infants the drum-membrane faces chiefly downward, while in adults it faces chiefly outward. Again, in infants the soft walls of the meatus tend to collapse and lie in contact with each other, the general direction of the canal from the drum-membrane being outward and upward. It should also be kept clearly in mind that in the infant at birth the little ring of bone (annulus tympanicus) in which the drum-membrane is set, and to which the membranous meatus is firmly fastened, is itself still very feebly attached to the squamous portion of the temporal bone. Finally, in adults, the cartilaginous portion of the meatus tends to droop downward and forward. As the framework of this portion of the canal is not composed of a solid plate of cartilage, but is provided with several fissures spanned by elastic tissues, it will be found to possess a very considerable degree of mobility. In old age, however, these fibrous portions, which play, in a measure, the part of hinges, become stiff and hard from the abundant deposit of calcareous material, and the natural mobility of the canal is thereby seriously diminished. These, I believe, are the only important points that have a direct practical bearing upon the subject of the introduction of the aural speculum.

*Sources of light.*—In the examination of the ear with either the hand or the forehead-mirror, it is not necessary to procure any other source of light than those which can almost always be found in every house. Direct sunlight is so dazzling that we cannot use it with either comfort or advantage. Ordinary daylight, such as can be obtained by directing our mirror toward the sky above the horizon, or toward the white wall of a house near by, generally affords sufficient illumination for ordinary purposes. If the window of the room looks out upon a narrow street, it will be found better to trust to artificial light. In our larger cities the argand gas-burner probably furnishes the most brilliant and steady source of light that can readily be found. In office practice some kind of movable fixture should be used, in order that the light can readily be placed at different levels, according

to the height of the patient. The ordinary gas-flame, the light of a kerosene lamp, or even that of a candle, will afford all the illumination required in the great majority of cases. The interposition of lenses, for the purpose of increasing the brilliancy of the light, is superfluous.

*Position of the patient in relation to the light.*—The physician should try and acquire the power to use sources of light situated in all imaginable positions. As a matter of course the light must occupy such a position that when the observer's face is directed toward the ear that is to be examined, he can see the flame or other source of illumination by simply turning his *eyes* in the proper direction. If he is obliged to turn his *head*, however, in order to see the light, it is certain that he will not be able, by means of his mirror, to reflect any of it into the patient's ear. In the next place, the source of light (if an artificial one) should not be at too great a distance from the observer, as in that case the illumination of the auditory canal would be rather feeble. The best position for the light is at a point a short distance behind and on one or the other side of the patient, not more than three feet from him, and about a foot above the level of the ear to be examined. If the light occupies a position on the observer's right-hand side, and is at the usual height above the patient's ear, there is a strong probability that in his manipulations with the right hand he will intercept the rays of light, and so shut off his view of the object under examination. If it happens, however, to be more convenient for him to use a source of light which is situated on his right side, he can readily avoid the difficulty just mentioned by raising the light to a higher level, thus enabling the rays to reach the mirror over his right arm. Probably the best plan for the beginner is to draw his illumination from a source which is situated on his left side. After he has acquired practice in using the forehead-mirror, it will make very little difference to him what position the light occupies, provided it be not on a lower level than the object under examination, and provided, of course, that it can be readily seen by the observer when his face is turned toward the ear of the patient.

*The actual examination.*—After the physician has acquired a certain degree of skill in the management of both speculum and mirror, he will find very little difficulty in adapting himself to the different circumstances under which he may find it necessary to make an examination of the ear. To lay down rules for all these varying conditions would simply be a waste of time. It will be sufficient if I describe the proper mode of procedure to be followed when the patient can be placed in the position which best suits the comfort of the physician who makes the examination. Thus, for example, if the left ear be the one that we wish to examine, and if the patient be an adult, he should be made to sit in such a position that he will have the light in front of him, a little toward his right side, and a few inches above the level of his eyes. The physician, of course, sits directly facing the patient's left ear. The patient's ear should be as nearly as possible on

the same level with the observer's eyes. Where this is not the case, the patient's head must be bent toward one or the other side, until the long axis of his external auditory canal corresponds with the observer's axis of vision. The next step is to cause the reflected rays of light to fall directly upon the ear. In this connection there are one or two practical points to which attention should be called. In the first place, it is not necessary, with a mirror whose focal distance is about twenty centimetres, to observe whether the rays have been brought to a focus in the auditory canal, or several centimetres this side of it in the focal line. In other words, the illumination along the focal line, for a distance of several centimetres on either side of the focal point, is amply sufficient for all practical purposes. Hence, the observer, in examining an ear by the aid of a forehead-mirror, should hold his head in that position in which he can best see the parts to be examined. In the second place, in our efforts to cause the rays of light to fall upon the ear, we should not use the motions of the neck as a means of attaining this object. It is far better to fix the head in the proper position for observing the parts comfortably, and then rotate the mirror in its ball-and-socket joint until we find the position in which it reflects the light in the direction desired. This done, the observer is ready to introduce the speculum and proceed with the examination.

Until we have learned by actual experience how large a speculum the ear under examination will admit, it is best to begin arbitrarily with one of medium size. The ear to be examined, we will suppose, is the left one. Holding the instrument between the thumb and forefinger of the left hand, and lifting the auricle upward and backward with the right hand, we should introduce the speculum cautiously into the orifice of the canal. As we push the instrument farther and farther inward, by a sort of boring motion, we should keep the eye directed upon the parts illuminated at the bottom of the speculum. By thus watching the progress of the inner end of the instrument, we shall be able to introduce it as far as we desire without causing the patient pain or even discomfort. In lifting the auricle upward and backward, while introducing the speculum, it makes no difference which hand is employed for the purpose, though it is, of course, easier to employ the right hand for the patient's left ear, and the left for his right. After the speculum is in position, however, and we desire to use the right hand for operative or other purposes, the traction upon the auricle and the maintenance of the speculum in a steady position must be given over to the left hand. To accomplish this easily, the fore and middle fingers should be used for the purposes of traction, while the thumb is left free to steady the speculum.

With regard to the question of how far the speculum should be introduced into the meatus, it may be said that as soon as the instrument has reached a position in which a clear view of the membrana tympani and deeper portions of the canal can be obtained, nothing will be gained by

pushing it farther inward. With Toynbee's and Von Troeltsch's specula it is an easy matter for a rough or careless operator to injure the deeper parts of the canal. With Wilde's conical specula and the broad-mouthed instruments of Gruber, however, the danger is greatly lessened.

In infants, the mode of procedure described above must be slightly modified, on account of the anatomical differences already mentioned. Thus, for example, it is generally necessary to overcome the collapsed state of the membranous walls of the canal by pulling the entire canal symmetrically outward. One way of accomplishing this is to exert slight upward and backward traction of the upper part of the auricle with one hand, and an outward, or outward and downward traction of the lower part with the other. A better way is to accomplish this combined movement by means of the fore and middle fingers of only one hand, the speculum being held in position by the thumb. But the exact mode of arranging the fingers is a problem which each one must work out for himself, as the procedure is one that scarcely admits of satisfactory description.

*Accessory Instruments used in the Examination of the Ear.*

In a large proportion of the cases that come before us we find that the speculum and mirror are the only instruments required for obtaining a full and satisfactory view of the external auditory canal and drum-membrane. In a certain number of cases, however, we find the view obstructed by the presence of various substances such as cerumen, hairs, scales of epidermis, pus, etc. These must, of course, be removed, if we desire to see clearly the parts beyond, and for this purpose one or more of the following instruments may be employed: angular forceps, cotton-holders, probes and curettes, and the syringe. I mention the syringe last, because I believe it to be the clumsiest and in some cases the least efficient of the means enumerated. Farther on I shall have occasion to discuss the merits of this instrument more fully.

A well-constructed pair of *angular forceps* is an invaluable instrument to the aural surgeon. He should be provided with two patterns of the instrument—a rather stout pair, which he can use in removing large bodies that are near the outer orifice, and a slender pair that can be employed in the deeper parts of the canal.

The long arms or blades of the more slender instrument should measure about six and a half or seven centimetres in length. If they are less than six centimetres in length, some difficulty may be experienced in illuminating the object, which it is proposed to remove, during the actual operation. The shorter arms should measure about six centimetres in length, and the spring which they form by their union should be quite feeble. A stiff spring is very apt to make the operator's hand tremble when he is using the forceps.



At its extreme free end the blade should measure a trifle less than a millimetre in breadth and hardly three-fourths of a millimetre in thickness. From this point it should gradually increase in both dimensions, until near the angle it measures  $2\frac{1}{2}$  mm. in breadth, and  $1\frac{1}{2}$  mm. in thickness. The tips of the blades should be provided with short teeth, two on one side, and one on the other. When the blades are closed, and the instrument is looked at from one or the other side, no elevation should be visible at the angle. The presence of such a hump may seriously diminish either the degree of illumination or the extent of the field of vision. In the next place, it is important that, when the free extremities of the blades are brought close together, the stouter portions at the angle should not be too far apart. In a good instrument, if no greater force is exerted than is sufficient to make the toothed ends interlock, the distance between the blades at the angle should not exceed a millimetre and a quarter or a millimetre and a half (or the total diameter of both blades, with the intervening space, should not exceed five millimetres). Finally, in examining a number of these slender forceps, apparently all alike in other respects, I have observed that, when more force was used than was sufficient to bring the blades in contact with each other throughout their entire length, the interlocking toothed ends separated, in some instances quite widely. While this is an extremely annoying fault in a pair of forceps, it is also one that can be readily discovered at the time of purchasing the instrument.

Of the stouter forceps, I like best the pattern which is sold in the shops under the name of Politzer's forceps. As this instrument is not intended for delicate work, it is not necessary that I should devote any space to the consideration of the details of its construction. As usually found in the shops, it is a sufficiently good instrument for all the purposes to which the physician is likely to apply it. If he desire to purchase only one pair of forceps, it is certainly better for him to have in his possession the slender pattern.

*The cotton-holder* is an exceedingly useful instrument to the aural surgeon. It consists of a slender rod of malleable steel, about twelve centimetres in length, which is slightly roughened at one end, for the reception of the cotton, and at the other broadens out into a short and rather thick handle. For ordinary purposes, a cotton-holder with a shank of 1 mm. in diameter is the best size. For the more delicate manipulations which are sometimes required in the middle ear (with a perforated drum-membrane), an instrument with a shank of not more than half a millimetre in diameter will be found more appropriate. It is a common defect in the cotton-holders sold in this city that the ends are too much roughened, thus rendering the removal of the mass of cotton at times an exceedingly difficult matter. With the nail blade of a pocket-knife, however, it is easy to remedy this defect in a very few moments. It is a much more difficult matter to apply

the cotton to the holder quickly, neatly, and firmly. To describe the procedure intelligibly is a task which I can hardly hope to accomplish satisfactorily, and I therefore prefer to let my readers work out each one a method for himself. The most important point, as a matter of course, is to cover up the comparatively sharp end of the instrument so thoroughly with the cotton that no harm can be done with it. With regard to the uses to which the instrument, thus armed, can be put, I may say in general that it affords the quickest and best means, known to me, of removing from the ear fluid or semi-solid substances. The cotton-holder is also employed for other equally important purposes, but of these we shall make mention in subsequent chapters.

*Probes and cures* are important accessory instruments. In very many cases simple inspection of the parts leads us to wholly erroneous conclusions with regard to the true state of things. Thus, for example, simple inspection would perhaps justify us in making the diagnosis of a swollen and ulcerated condition of the posterior half of the membrana tympani; while inspection, combined with the proper use of the probe or curette, might reveal the existence of a polypoid mass that originated in the tympanic cavity, forced itself through a comparatively small perforation, and then spread itself out over the posterior half of the drum-membrane. I might enumerate many other pathological conditions which even the most skilful specialist would be very likely to interpret incorrectly if he did not use the probe as a means of correcting or confirming his first impressions. Of course, if obstacles intercept the view, these must first be removed; and here the probe or the curette may also serve an excellent purpose. Both of these instruments, however, must be delicately constructed, or the physician will find them of very little use, either as aids in making a correct diagnosis, or as substitutes for the forceps and syringe. The most essential details of construction of these instruments are the following: The probe should be made of a single rod of soft silver, and for a distance of 8 ctm. from one end it should be finished with four sides (each 1.5 mm. in diameter) in order to furnish a good hold for the fingers. This handle portion of the probe should merge gradually into a slender shank, less than half a millimetre in diameter, and terminating in a small knob, about three-fourths of a millimetre in diameter. A total length of 15 ctm. will be found amply sufficient. The handles of the cures should be of the same length as that of the probe, but they should be eight- instead of four-sided, and correspondingly heavier (diameter of nearly four millimetres). The shank, at the point where it broadens out abruptly into the handle, measures 1.5 mm. in diameter; at the point where it joins the ring, it measures but 0.5 mm. in diameter. The handles and shanks of the two different sizes of cures are precisely alike; the only difference is in the size of the rings. Both are oval in shape, the smaller one measuring  $3\frac{1}{2} \times 3$  mm., the larger one  $5\frac{1}{2} \times 4\frac{1}{2}$  mm. (by external measurement). Their thickness, from one flat side to the other, is

about 0.3 mm. ; measured transversely, from the inner to the outer side of the ring, it is a trifle more than 0.5 mm. in the larger ring, and a trifle less than 0.5 mm. in the smaller one. As these instruments are used for a variety of purposes, it is sometimes desirable to have the shank tempered, in order to give it the requisite degree of stiffness, while at other times a malleable state of the metal will be found preferable. If the larger of the two has a tempered shank, the smaller instrument may advantageously be allowed to have a malleable one, at least for a distance of a few millimetres from the ring.

With regard to the use of the *syringe*, it is not an easy matter to lay down any very well-defined rules. To the physician who possesses a steady hand and a delicate touch, my advice is, to emancipate himself as soon as possible from the syringe, and to trust chiefly to his probes, curettes, forceps, and cotton-holders, for the removal of foreign substances from the ear. Skill in the manipulation of these instruments may be cultivated to such a degree, that the occasions will be comparatively rare when the aid afforded by syringing will be required. At such times, however, the syringe serves an excellent purpose. Thus, for example, when there is soft cerumen in the canal, and especially when it is plastered over the membrana tympani, or fills the anterior cul-de-sac, its removal can generally be effected more rapidly by means of the syringe and warm water than by even the most skilful employment of the cotton-holder, the curette, or any of the other instruments mentioned above. Farther on I will go more fully into this subject of the use of the syringe as a means of removing cerumen. In this place I merely wish to say that my chief reason for not employing the syringe more often, lies in the fact that I can almost always accomplish the desired purpose more rapidly with the different instruments mentioned above. Furthermore, syringing has always appeared to me to be an exceedingly clumsy way of performing a comparatively simple operation. At the same time, I must confess that the requisite degree of manual




FIG. 10.—Ear-probe and curettes of two sizes.

skill and delicacy of touch is possessed by so few physicians, that probably for a long time to come the syringe will continue to be a very important aid in the diagnosis and treatment of ear diseases.

A good ear-syringe should have a piston that works easily. This is the first and most important requirement. In the next place, it should be provided with some contrivance which will enable the operator to alternately fill and discharge the instrument with one hand. This object is commonly attained by having the handle of the piston terminate in a ring large enough to admit the thumb, while two other rings large enough to admit the fore and middle fingers are fastened opposite to each other on the base of the cylinder. In the hard-rubber ear-syringes the neck of the cylinder is hollowed out in such a manner as to afford to the fore and middle fingers all the support that they receive from the rings in the metal instruments. With regard to the size of cylinder best adapted to the requirements of a good ear-syringe, I may say that, in general, it is better to employ an instrument of rather large capacity. The smaller syringes require to be filled so frequently that the patient's ear is apt to be subjected to a great deal of unnecessary handling. If carefully manipulated, the slender conical nozzle is probably the best that can be used. At its point it should not measure more than three and one-half or four millimetres in diameter.

The water employed in syringing the ear should have a temperature of from 95° to 100° F. If it be too cold, we may produce in the patient a sensation of faintness, nausea, or dizziness. The same effects may also be produced by injecting the water with too great force.

Finally, a word with regard to the different steps of the procedure. The patient's neck and shoulder should first be protected with a towel, and he should be given a bowl or mug to hold beneath his ear. The shallow hard-rubber or metal basins sold by the instrument-makers for this latter purpose are thoroughly unpractical. A sudden motion of the patient's body is apt to cause the contents of the basin to spill over upon his person, while if a mug, bowl, or other deep vessel be used, the same accident is much less likely to occur. In the majority of cases the bowl or mug may be used both as a reservoir from which to fill the syringe and as a receptacle for catching the water that runs out from the ear. If the proper conveniences, however, are at hand, it is better to fill the syringe from a separate vessel, as sometimes the matters which are washed out from the ear block the canal of the nozzle, and so cause trouble. After we have filled the syringe with the right hand, we must straighten the patient's external auditory canal with the fingers of the left hand, in the manner described on page 27. After this has been done, the nozzle is to be introduced a short distance,—roughly estimated, not more than half an inch,—into the meatus, and the water thrown in with little or great force, according to the nature of the conditions which led to the use of the instrument. If we are not pointing the syringe in the right direction,

or if we have pushed the nozzle too far into the ear, the patient will be very likely to reveal the fact by the expression of his countenance. No description, however, can serve as an adequate guide to the successful performance of this operation, which physicians are very apt to consider as a very simple task, but which in reality is often a very difficult one. In infants the hard rubber or metal syringe must be used with great caution. The douche or the bulb-syringe is a much safer instrument for this class of cases. The nozzles usually supplied with the douche are either so large that it is impossible to do effective work with them, or so slender and sharp that they may easily injure the canal or even the drum-membrane itself. In some of the shops it is now possible to purchase a form of nozzle which is free from both of these objections (Fig. 11). It is made of hard rubber, and is provided with four prongs which are symmetrically placed around the nozzle, each at a distance of eight millimetres from the free end. The diameter of the nozzle at the tip is three and one-half millimetres; at the bases of the prongs it is about four millimetres. The prongs themselves project about six millimetres from the sides of the nozzle, and they are inclined a little backward away from the tip. In adults it may be found advantageous to use a nozzle with a somewhat longer tip—one, for instance, that measures ten or eleven millimetres in length, instead of eight millimetres. Both sizes can be purchased, but the smaller size will almost always do equally good service in both adults and children. With such a nozzle the patient himself, or the mother, in the case of a child, can easily be taught to cleanse the deeper parts of the external auditory canal as safely and as efficiently as it can be done by the physician with a well-constructed syringe. In the case of the douche the desired degree of force can be given to the stream of water by lowering or raising the reservoir. Due allowance must be made for the cooling off of the water in its passage through the long rubber tube, and, just before introducing the nozzle into the ear, we must be careful to let the water escape from the nozzle for a moment or two, until its temperature, as it flows from the instrument, reaches the proper height. The cheapest and perhaps the best form of receptacle is that which is sold under the name of Clark's douche. It is made of tin and will hold at least a quart of fluid. Care must be taken not to pour too small a quantity of warm water into the receptacle, for it is only by drawing our supply from a comparatively large bulk of fluid (at least a quart) that we can prevent an inconveniently rapid lowering of its temperature.

However valuable the douche may be, it must be conceded that it is a rather awkward apparatus to use in cases where the canal requires to be cleansed frequently. The bulb-syringe, armed with the hard-rubber



FIG. 11.—Pronged hard-rubber ear-nozzle. (Larger size.)

pronged ear-nozzle described above, will be found a much easier instrument to manage, and one that is equally effective. The Davidson syringe, which may be found in almost every household, can be used as an ear-syringe in an emergency. A better pattern, however, especially for use in young children, is that represented in the accompanying cut (Fig. 12). The rubber bulb has an opening at one end for the reception of a tightly fitting hollow stem, five or six centimetres in length. One end of a piece of soft-rubber tubing, from ten to fifteen centimetres long, is pushed down over the free end of this stem, and the other is armed with the pronged nozzle already described. This form of bulb-syringe is so simple in its construction that it is hardly possible for it to get out of order, and if the piece of rubber tubing that connects the nozzle with the bulb is not too long, we may use the instrument quite readily with one hand. Before

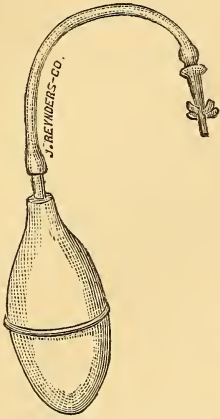
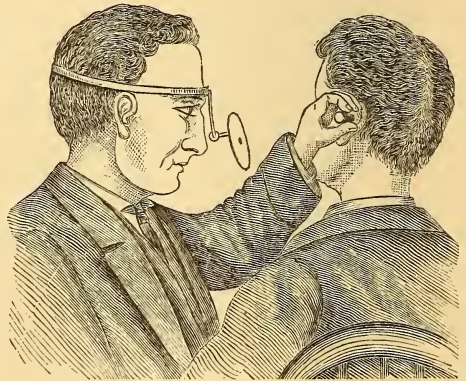

FIG. 12.—Simple pattern of ear-douche.

the water is injected into the ear, care should be taken to fill and empty the instrument two or three times in succession, for the purpose of warming it thoroughly.

In the foregoing description of instruments, I have mentioned only those which the physician may find it necessary or desirable to use in obtaining a satisfactory view of the membrana tympani and deeper parts of the external auditory canal. Those instruments which are used more particularly as means of ascertaining the condition of the Eustachian tube and middle ear, or for strictly therapeutic purposes, will be described farther on, in connection with the different forms of disease.

NOTE.—I find, on reading over the preceding chapter, that I have omitted to mention the very important fact that the forehead-mirror is to be worn in the manner represented in the accompanying cut, *i. e.*, with the ball-and-socket joint resting upon the bridge of the nose, and the mirror itself projecting at a still lower level. As our ordinary sources of light are almost invariably situated at a higher level than that of our eyes, the plan, often adopted, of resting the mirror against the forehead, will be found rather awkward in aural examinations. On the other hand, the plan represented in the cut is that which I have habitually used in practice since 1870, and I can therefore vouch for its usefulness.



Forehead-mirror in actual use.

## CHAPTER III.

### DISEASES OF THE AURICLE.

THIS part of the organ of hearing is subject not only to all the diseases which affect the skin in other parts of the body, but also to those which attack cartilaginous structures. It shares with the nose, the fingers, and the toes, a strong predisposition to become frost-bitten, and stands second only to the nose in its liability to receive injuries of various kinds. Owing to the practice of piercing the lobes for the introduction of ear-rings, the development of fibroid tumors is far more common in this locality than in any other part of the body. It is only in these respects, however, that the auricle differs from other parts of the surface of the body in its tendency to become diseased.

The commonest affection<sup>1</sup> to which the auricle is liable, is

#### ECZEMA.

Among the children of the poorer classes eczema of the auricle is an extremely frequent disease. If less frequent among the well-to-do classes, it is certainly by no means a rare affection even among them. Again, in old age and in the middle period of life, it is a quite common disease. In a certain proportion of the cases, it develops on other portions of the skin at the same time, *e.g.*, on the hairy scalp or in the mastoid region. In children it is often associated with a conjunctivitis, and the coexistence of the two diseases suggests the probability that the irritating secretions of the auricle have been transferred by the child's fingers to the eyes. In its mildest and simplest form, eczema of the auricle manifests itself as a reddening and infiltration of the skin at one or more points. The favorite places are those spots where the skin is folded upon itself, as the fossa helicis, and the angle behind the ear, where the skin is reflected from the auricle upon the mastoid process. The disease is observed at least equally often at the orifice of the external auditory canal, and extending from there forward over the tragus, and downward over the lobule,—in other words, at

---

<sup>1</sup> The Report of the N. Y. Eye and Ear Infirmary for 1878, shows that out of eighty-five cases of disease of the auricle, there were fifty-four of eczema.

points where there is apt to be a good deal of friction, or where an irritating discharge from the meatus may act as an exciting cause. At a later stage these reddened and infiltrated spots secrete a fluid which soon becomes inspissated, forming crusts or scabs. In many cases actual ulceration takes place beneath the scabs; and this is particularly apt to occur in the incisura intertragica, in the fossa helices, and in the angle behind the ear. In exceptional cases the entire auricle and immediate surroundings present an almost continuous mass of scabs. Again, it is not a rare occurrence for a diffuse and quite painful inflammation of the entire auricle to develop during the course of what appears to be a very trifling attack of eczema. The whole organ swells up to fully twice its natural size, and presents a vivid red color; the orifice of the external auditory canal becomes obliterated,—in a word, the picture presented is that of an acute attack of erysipelas.

We may also, in certain cases, see the eczema manifest itself in the form of an equally vivid reddening and equally marked infiltration of the entire auricle, but without pain and with but very little tenderness.

Finally, in another group of cases, a desquamative process, confined to certain portions of the auricle, seems to constitute the most characteristic, if not the only, manifestation of the disease. The intervening portions of the skin appear to be perfectly healthy, and even those parts which are desquamating or are covered with scab-like formations, present a pale and uninfamed appearance. The term chronic eczema is usually applied to this class of cases, but it may be applied with equal justice to other forms of the disease.

*Etiology.*—I have no intention of introducing here a disquisition on the etiology of eczema in general. I simply wish to call attention to the very intimate relation that exists between the development of an eczema of the auricle, and the character of the diet habitually used. This relation is so strongly marked in young children, that when a case of eczema auris is brought before us, we can safely accuse the parents of habitually feeding the child with tea, coffee, cakes, pies, salt meat, peanuts, or any other article of food which even an adult stomach often finds difficulty in digesting. In the middle and lower classes, children begin to feed upon this sort of diet at a remarkably early age. In adults I have occasionally been able to trace a similar connection between the development of eczema of the ear, and the condition of stomach digestion. I remember one case in particular. The patient, a man of about thirty-two, led a sedentary life. His ear, in spite of all treatment, presented a decidedly unpleasant appearance, and the tendency of the disease was to grow worse rather than better. His business compelled him to leave the city and spend several months in the far west, where he led a very active life, and subsisted on a very simple diet. When he returned to the city scarcely a trace of the eczema could be seen.



In a few instances I have observed the coexistence of a marked naso-pharyngeal catarrh and eczema of the auricle, and have suspected that the former affection was in some way connected with the causation of the eczema. We might then, in both classes of cases, speak of the eczema as a reflex affection dependent, on the one hand, upon irritation of the stomach, on the other, upon irritation of the naso-pharynx.

*Diagnosis.*—Where the disease localizes itself in distinct reddish and infiltrated spots, which are separated from each other by healthy skin, I know of no other affection with which it might possibly be confounded. I have seen one case of deep ulcerations of the auricle, which presented at first view every appearance of that variety or stage of eczema which is characterized by the formation of scabs or crusts without noticeable redness of the surroundings. In this case, however, the removal of the scabs displayed a group of deep ulcers, with excavated edges, and with bases resting directly upon the cartilage. The resemblance between the conditions was therefore merely an external one. A diffuse general inflammation of the auricle may readily be taken for a diffuse eczema of the organ. I am not sure that a positive distinction can be made between these two conditions in all cases,—certainly not by inspection alone. The previous history of the case may aid greatly in clearing up the nature of the affection. Erysipelas can be diagnosed with positiveness if the redness is found to spread rather rapidly to the adjacent cheek or forehead, and if it is accompanied by an elevation of the body temperature.

*Prognosis.*—In children a favorable prognosis may be given with very little hesitation. In adults, and especially in old people, a guarded prognosis must be given, as the tendency to relapses is very common.

*Treatment.*—Careful inquiry should be made, first into the character of the patient's diet, and then into that of his habits with regard to bathing and outdoor exercise. In children a complete and permanent cure may often be attained by simply restricting the diet to such simple articles as milk, oatmeal, hominy, fresh meat and vegetables, and light bread. Pastry, pies, cakes, salt meat and pork, tea and coffee must be rigidly excluded. In adults, it will generally be found easier to induce the patient to take an adequate amount of exercise in the open air, than to persuade him into excluding certain articles of food from his daily fare. If possible, he should be induced to do both.

In private practice I have rarely seen the aggravated forms of chronic eczema of the auricle, and have therefore had very little occasion to use arsenic as an internal remedy. In the few cases in which I prescribed it (5 drops of Fowler's solution of the arsenite of potassa, to be taken three times a day after meals, in a little water), I did not observe such a marked improvement in the condition of the auricle as would justify me in speaking favorably of its curative effects upon eczema of this part of the body. In dispensary practice the aggravated forms of eczema are comparatively

common, but in these cases I have thus far trusted almost wholly to local applications and dietetic rules; not caring to prescribe such a powerful remedy to patients who, as a rule, visit the institution at extremely irregular intervals.

Local applications form a very important part of the treatment of eczema of the auricle. In the acute stage, if there happen to be pain and tenderness, it may be desirable (though only in adults) to apply leeches, for the purpose of allaying the pain and diminishing the inflammation. It is rare, however, that local bloodletting seems indicated in these acute cases. If leeches are used, they should be applied in the immediate vicinity of the tragus or in the angle behind the ear. Cloths dipped in some cooling and astringent lotion, such as the lead and opium wash, or in simple water to which alcohol or *eau de cologne* may be added in varying proportions, will generally be found sufficient to allay all the acute symptoms. Afterward, if no crusts have formed in the meantime, we may apply some oleaginous preparation directly to the affected skin. If crusts have already formed, these must first be removed with a sponge dipped in hot water; and if the skin is actually ulcerated, I am in the habit of cauterizing such ulcers lightly with nitrate of silver in the form of a bead or solid stick. The chief value of the different oleaginous preparations lies, I imagine, in their power to exclude the air from the parts affected, rather than in the medicinal virtues of the drugs which enter into the composition. There can be very little doubt, however, that some of these drugs do exert a decided curative influence. This, I believe, is true more particularly of the oil of Cade and of certain preparations of lead. I formerly used the oil of Cade in the form of an alcoholic solution (one or two drachms of the oil to seven or six drachms of alcohol), and obtained fair results from its use. Of late I have substituted vaseline for the alcohol, and am well satisfied with the results which I now obtain with this combination. The patient is advised to apply it twice a day, at night just before retiring, and again the next morning. At night it may be applied very freely, as some kind of cap can be worn for the purpose of protecting the pillow. In the morning, if the patient is obliged to leave the house, the preparation should be applied so lightly that the ordinary observer will not be able to discover its presence. Each time, before the ointment is applied afresh, the auricle should be washed with tar-soap, or castile-soap, and warm water; and in drying the parts the patient should simply make pressure with the towel, and not rub the ear in the ordinary manner.

Of the lead preparations, I have used only one, viz., Hebra's diachylon ointment. The formula for this ointment, as prepared in Vienna, is (according to Gruber)<sup>1</sup> the following:

---

<sup>1</sup> Ueber Eczem am äusseren Ohrtheile. Monatsch. f. Ohrenheilk. Nov., 1867.

- ℞. Olei olivarum optimi. . . . . ℥ xv.  
 Lythargiri. . . . . ℥ iij. et ʒ vj.  
 Coq. l. a. in unguentum molle, dein adde ʒ ij.  
 olei lavand.  
 M. Ft. unguentum.

Unfortunately, it is not easy to procure this ointment even in a large city like New York, and for this reason I have not prescribed it as freely as I have the oil of Cade preparation. In one or two instances I have known it to prove successful when all the other well-known remedies had failed.

The benzoated oxide of zinc ointment is a favorite remedy with many physicians. I have used it a great deal in children, and have been in the main well satisfied with the results. Vaseline alone, in mild cases, seems to accomplish nearly as good results as are obtained by the employment of the other remedies mentioned.

Finally, in a certain proportion of the thoroughly chronic cases, in which all the ordinary preparations seem to have been powerless to affect even an amelioration of the unsightly condition of the ear, decided good may be accomplished by painting the diseased parts thoroughly (after all oily substances have been removed), from time to time, with acetum cantharidis.

It is a common mistake to stop using these local applications as soon as the ear appears to have regained its natural condition. It will be found safer to continue the treatment faithfully for at least a week or ten days after a cure has apparently been effected.

#### INFLAMMATION OF THE AURICLE.

(Furuncles. Diffuse inflammation.)

In my experience, furuncles, of sufficient size to lead the patient to consult a physician, develop very rarely on the auricle. In fact, I can find but one such entry in my records. As furuncles of the external auditory canal possess the same significance as these do, and as the treatment is essentially the same in both cases, the reader is referred to the chapter on Diseases of the External Auditory Canal, where this condition is discussed at greater length.

Diffuse inflammation of the entire auricle is observed in its purest type in cases in which hot poultices have been used to excess. After the auricle has been exposed for a certain length of time to the combined effects of the heat and the moisture, it becomes highly congested and slightly tender to the touch. The appearance of the organ is precisely the same as if it were affected with acute erysipelas. If the exposure is kept up for a still greater length of time, the auricle becomes quite painful and very much swollen. Abscesses, I am told, may even form at different points. As al-

readily stated in the preceding section, such a general inflammation of the auricle may develop in the course of an eczema, and I have occasionally seen it in connection with a circumscribed inflammation of the outer portion of the external auditory canal. In these cases, however, it was not quite clear whether the diffuse inflammation of the auricle was to be interpreted as an actual extension of the more localized process in the meatus, or as the result of the application of hot poultices.

At first sight one might hesitate to decide whether the disease under observation was a *bona fide* attack of erysipelas, a commencing perichondritis, or a simple diffuse inflammation of the auricle, limited chiefly to the structures of the skin. The limitation of the redness to the auricle and the probable absence of any noticeable elevation of temperature would favor the exclusion of erysipelas. The subsequent course of the case would soon enable one to exclude perichondritis, which runs a slow course and generally begins in a more circumscribed manner.

As the disease disappears quite rapidly as soon as the exciting cause has been removed, it is not necessary to make any additional remarks on the subjects of prognosis and treatment.

#### HÆMATOMA AURIS. PERICHONDritis.

(Othæmatoma, Chondromalacia, Chondromalacosis.)

These conditions are so closely allied to each other that it is better, I believe, to consider them together in one section. The term hæmatoma auris, or othæmatoma, is usually applied to a peculiar swelling of the auricle, which is most frequently observed in the insane, and which is chiefly due to the escape of a varying quantity of blood either between the cartilage and the perichondrium, or into the substance of the cartilage. The term perichondritis is restricted to those cases in which the symptoms of redness, pain (usually slight), and slowly increasing swelling, point very decidedly to processes that are chiefly inflammatory in their nature. With othæmatoma of the insane I have had no practical experience whatever, and must base my remarks wholly upon information gained through reading; with perichondritis I have also had very little experience, as the disease is comparatively rare. I am persuaded, however, that no sharp dividing line can be drawn between the two classes of cases, whether considered from an etiological, a pathological, or a therapeutical standpoint.

*Etiology and Pathology.*—Exposure to severe cold or extreme heat produces an inflammation to which the term perichondritis may fairly be applied. Violence may also produce the same pathological manifestations. Finally, in a few cases, no exciting cause can be discovered; the disease is then said to be idiopathic. In these cases the patients are generally found to be in a poor state of nutrition, and, in the absence of any other adequate

cause, we are almost compelled to assume that some local nutritive disturbances—probably of the same nature as those which are now generally admitted to be the chief factors in the production of the typical othæmatoma—have given rise to the perichondritis.

The pathology of othæmatoma proper has for many years past been a fruitful subject for discussion. Some advocate the doctrine that this lesion is peculiar to the insane, and depends upon a pathological condition of the brain. This is the view taken by Dr. Hun,<sup>1</sup> of Albany, who has written a very interesting paper on the subject of hæmatoma auris. Others maintain that the lesion is always produced by violence, and that it occurs more frequently among the insane, simply because they are peculiarly liable to violence. Finally, a third party maintains that the othæmatoma is not one of the pathological lesions of insanity, but that the surroundings of the insane, and the debilitated condition which so generally accompanies insanity, are the real reasons for its so frequent occurrence among that class of individuals. This is the view taken by Virchow in his treatise on tumors, and the exhaustive researches of Ludwig Meyer,<sup>2</sup> Pareidt,<sup>3</sup> Gudden,<sup>4</sup> Pollak,<sup>5</sup> and Haupt,<sup>6</sup> confirm it in the strongest possible manner. The essential facts developed by these investigations are the following :

First, degenerative changes are quite uniformly found in the cartilaginous framework of the auricle in cases of othæmatoma of the insane. These changes are of such a nature that Pareidt very properly termed the disease a *chondromalacia*,<sup>7</sup> or softening of the cartilage. The progress of the affection is described by Ludwig Meyer essentially as follows: Hæmatoma auris begins as a degeneration and softening of the cartilage at one or more spots. A gelatinous material takes the place of the hard cartilage. As the degenerative process goes on, newly formed blood-vessels shoot out from the perichondrium, or from the vessels that pierce the cartilage at different points, into these softened spots. The newly formed capillary vessels are quite large, and their walls are very thin and richly supplied with nuclei.

<sup>1</sup> American Journal of Insanity, July, 1870.

<sup>2</sup> Virchow's Archiv f. path. Anat., etc. Bd. XXXIII., Heft 4, 1865.

<sup>3</sup> De Chondromalacia, etc. Dissertatio inauguralis. Halle, 1864.

<sup>4</sup> Ueber den mikroskopischen Befund in traumatisch gesprengten Ohrknorpel. Virchow's Archiv f. path. Anat. Bd. LI., 4, p. 157; LII., 2, p. 303.

<sup>5</sup> Monatschrift für Ohrenheilkunde. Berlin, July, 1879. (Reviewed in Vol. I., No. 4, of the American Journal of Otology.)

<sup>6</sup> Gustav Haupt: Ueber das Othæmatom. Dissert. inaug. Würzburg, 1867. Reviewed in A. f. O. Vol. IV., p. 143. (Marked changes found in the cartilage of the apparently healthy ear of an insane person whose other ear had been the seat of a well-marked othæmatoma.)

<sup>7</sup> Loosely used in the sense of chondromalacosis, which means a *softening* of the cartilage. According to Kraus (Kritisch-etymologisches medicinisches Lexikon. Göttingen, 1844), the term chondromalacia means simply a *softness* of the cartilage.

Thus, we have two different processes going on side by side at the same time—a softening of the cartilage, and a granulation process on the part of the perichondrium.

In the second place, a careful macroscopical and microscopical examination of a large number of ears, taken from patients who had died from all sorts of diseases in the hospitals, but who had never manifested any symptoms of insanity, reveals the fact that precisely the same changes as those just described take place in the auricles of the mentally sane. According to the statement of Pollak, whose researches are probably the most recent, small nodules, varying in size from a mustard-seed to a lentil, are occasionally found in the cartilaginous portion of the external meatus, and especially in the anthelix. In these, when cut open, it is easy to detect, even with the naked eye, a departure from the normal condition of the reticular cartilage; in some cases, in fact, it will be found that a distinct cavity has already formed. Microscopic examination also reveals spots where the cartilage has broken down into a mass of granules, and others where evidences of new growth of tissue are distinctly recognizable.

In the third place, the number of instances of the occurrence of fully developed othæmatoma in persons who are perfectly free from any mental disorder whatever, is constantly increasing.

These facts justify the belief that insane persons are more liable to the disease under consideration, simply because malnutrition reaches a higher grade among them (taken as a class) than among the mentally sound. The new growth of unusually large and thin-walled capillary blood-vessels also furnishes an explanation of one of the most striking phenomena of othæmatoma, viz., the escape of a comparatively large amount of blood, either between the perichondrium and the cartilage, or into the substance of the cartilage. It can readily be understood how a very trifling exciting cause, such as a slight blow, the pressure of a hard pillow, or even the reflex congestion following some mental emotion, may lead to the rupture of one or more of these delicate vessels and produce the characteristic accumulation of blood.

*Course of the disease in the mentally sane.*—It rarely happens that the physician has an opportunity of seeing a case of idiopathic perichondritis, in its incipient stage. The patient generally waits until the discomfort or pain is sufficiently great to make him feel the need of medical aid, and usually by that time the disease has reached its highest stage of development. The following case is a good example of an idiopathic perichondritis of a comparatively mild type:

Female, thirty years of age, saleswoman in a retail shop, and in decidedly poor general condition. She presented herself at the N. Y. Eye and Ear Infirmary, on the 1st of November, 1878, and gave the following history: About ten days ago she first noticed some irritation at the upper part of the right auricle, not far from the helix. She had not received any

injury at this point, nor could she think of any other cause for the development of the soreness in that particular place. In the course of a few days, a circumscribed swelling developed at this spot, and she then consulted her family physician. He made two small incisions into the swelling, one at the upper, the other at the lower limit of the tumor, evacuated the fluid contents, and then passed a seton into one opening and out through the other. After this the auricle swelled up rapidly and became very painful. At the time of her visit to the Infirmary, the tumor was fully as large as a butter-nut. It presented a smooth, red, and inflamed appearance, and occupied the anterior aspect of the upper two-thirds of the auricle. There was also some œdema of the skin above and behind the ear. The seton was still in place, and on removing it a thin fluid spurted out from one of the openings. By aid of the probe it was ascertained that a large cavity existed, the posterior wall of which seemed to be formed by the denuded anterior surface of the cartilage. The two openings were converted into one by an incision, the cavity was carefully cleansed, and a tent was introduced to prevent the edges of the wound from uniting. When the contents of the cavity were evacuated, it was observed that the larger part consisted of thick, almost gelatinous pus, while the smaller part was apparently a thin serum. The patient was ordered to take twenty drops of the muriated tincture of iron three times a day, and to lay cloths wet with the lead and opium wash upon the inflamed auricle.

On the second day of November she visited my office, and reported that the pain had very markedly abated. I removed the tent and, in so doing, afforded escape to a moderate amount of thick pus and some thin, serous fluid. The parts surrounding the cavity were found to be still very much swollen. From the uniform smoothness of the posterior wall of the cavity it was inferred that no destruction of cartilage had taken place, and that the disease was, strictly speaking, a perichondritis, with effusion between the cartilage and the perichondrium. From this time forward the patient was visited regularly by my colleague, Dr. George B. Hickok. The cavity was daily cleansed, and then mopped out with tincture of iodine; afterward, moderate pressure was applied, for the purpose of keeping the walls of the cavity in close apposition.<sup>1</sup> In less than three weeks the cavity had completely healed, and the auricle had so nearly returned to its natural condition that there could no longer be any reasonable doubt about the speedy disappearance of all traces of the disease.

Chimani<sup>2</sup> reports an equally typical case of idiopathic perichondritis,

---

<sup>1</sup> Two short and flat bits of wood were employed for this purpose; one being placed behind, the other in front of the swelling, and rubber bands being used to exert the requisite pressure. The localization of the pressure was secured by interposing suitable pads of sheet lint between the skin and the bits of wood.

<sup>2</sup> Archiv für Ohrenheilkunde, Bd. II., S. 169.

which occurred in a young man, twenty-three years of age. The swelling was incised, and complete recovery took place in a little more than four weeks, without any deformity. Wendt<sup>1</sup> reports a similar instance of the development of a "spontaneous hæmatoma" in a strong and perfectly healthy young man, twenty years of age. Brunner<sup>2</sup> also reports a similar occurrence in a perfectly healthy individual, thirty-two years of age. In this case, however, it is quite probable that the cartilage was primarily diseased, as a certain degree of deformity remained after the parts had healed. Furthermore, the patient had already a few years previously experienced a similar inflammation of the other auricle, and an examination revealed the fact that some deformity still remained at the seat of this former attack.

In a second case which came under my observation, almost precisely the same conditions were presented as in the case which I first described. The same plan of treatment was followed, and very nearly all traces of the disease disappeared. The two cases, however, differed from each other in the following particulars: a frost-bite was clearly the exciting cause in the latter instance; and, furthermore, the contents of the sac were sufficiently bloody to communicate a bluish tint to the outside of the tumor. As no notes were kept of this case, I cannot say positively whether the fluid contents of the sac were simply stained with the coloring matter of the blood, or whether solid clots were also found to be present.

Dr. Charles J. Kipp, of Newark, N. J., has reported<sup>3</sup> a somewhat similar case of perichondritis—or spurious othæmatoma, as he terms it—of both auricles, the result of a burn. "The auricles were pushed out from the head, and the upper two-thirds of both were pear-shaped. The swelling was greatest at the top, and measured about an inch and a quarter from before backward. The auricles were hot and very sensitive to the touch. The surfaces of the swellings were convex and smooth, and the skin of normal color, but it looked as if it had been blistered. Fluctuation could be distinctly felt in both. An incision through the entire length of each swelling gave escape to a considerable quantity of a yellowish, glairy fluid. The swellings did not collapse after the evacuation of their contents. In both was found a cavity of about the size of a hickory-nut, lined by a smooth, shining membrane. The anterior wall of both was about a line thick, and was apparently composed of thickened perichondrium; the posterior wall was formed by the cartilage. Under the daily application of tincture of iodine to the interior and exterior of the swellings, the auricles gradually diminished in thickness, and at the end of two months they had regained their normal size and shape. The only deformity remaining when I last saw him was a wrinkled condition of the fossa helix."

---

<sup>1</sup> Ibidem, Bd. III., S. 29.

<sup>2</sup> Ibidem, Bd. V., S. 26.

<sup>3</sup> Transactions of the American Otological Society for the year 1873.



Finally, in a third case which came under my observation, the conditions found were essentially different from those observed in the two preceding cases. The patient, a man thirty years of age and in robust health, consulted me on the 11th of December, 1878. He stated that four years previously both of his ears had been frost-bitten, and that from that time to the present he had had four sores on the left ear and two on the right, as the results of the acute inflammation which immediately followed the freezing of the parts. All efforts to make these ulcers heal permanently had failed, although during the summer season some of them often presented all the appearances of having spontaneously healed. As soon as cold weather returned, however, these spots again became scabbed over. Upon examination, I found four spots on the left auricle and two on the right, occupied by scabs of moderate thickness. They were nearly circular in shape, and measured from five to eight millimetres in diameter. Five out of the six scabs were located on the outer aspect of the helix, above the level of the orifice of the external auditory canal; the sixth was located on the anthelix, on the same level with the external orifice. The edges of the scabs seemed to rest upon healthy skin. After they had been removed, it was ascertained that they each covered an ulcer with sharply defined and undermined edges. The bottom of each ulcer was smooth, hard, and of a pale color. The undermined edges had a markedly bluish hue, which faded gradually into that of the perfectly sound skin.

Nitrate of silver, tincture of iodine, and pure nitric acid were tried in succession, at brief intervals, but none of these reagents seemed to induce the slightest evidence of a healthy reparative process. I then tried the following plan: with a pair of curved and slender-pointed scissors I cut away the bluish undermined edges; then, as soon as the bleeding had ceased, I applied compound tincture of iodine freely to the base of the ulcer, and to the surrounding raw surface. A very thin layer of cotton-wool was next laid upon the exposed surface, and then liquid collodion was applied for the purpose of supplying an artificial scab. At the end of three or four days the collodion and cotton were removed, and the ulcer was found to be healing slowly both from the edges and from the bottom. The compound tincture was applied a second time and the wound was sealed up again with cotton and collodion. Nine such applications in all were made during the latter part of December, and, on the second day of January, I found the newly formed skin firm and dry over the spot which before had been the seat of the ulcer. The depression of the surface at this point was too slight to attract attention.

The remaining ulcers were treated in much the same manner as the first one, and with equally good results.

In the cases described above it is reasonably safe to assume that the cartilage itself was either not at all involved, or at most, only very superficially. The term perichondritis seems therefore more appropriate for this

class of cases than either of the other expressions—othæmatoma and hæmatoma auris. It would be better if we could abandon the use of these two terms altogether, and employ some term which indicated the essential nature of the disease, and not merely one of its comparatively unimportant manifestations—the escape of blood into the tissues. Pareidt's *chondromalacia* (or the correct expression, *chondromalacosis*) is certainly the best term that has thus far been proposed. I hesitate, though, to urge the abandonment of terms to which we have all been habituated for so long a time.

I have already said that this chondromalacosis is occasionally observed among the mentally sane. Through the courtesy of Dr. Oren D. Pomeroy, of this city, I once had the opportunity of seeing a very marked instance of this disease.<sup>1</sup> The patient, a cooper, forty-two years of age, and of perfectly sound mind, gave the following history: In the early part of May, 1874, he experienced a violent pain in the right ear, which continued for eleven days, with very little abatement. A discharge of thick creamy pus then made its appearance in the external auditory canal. Five days after the discharge began, he presented himself at the Brooklyn Eye and Ear Hospital. Owing to the swollen condition of the canal it was not found possible at that time to determine satisfactorily whether the disease had commenced in that region or in the middle ear. In the course of a few days the swelling extended outward from the canal, and involved the auricle, causing it to become very much thickened. An incision made in the swelling gave exit only to a thin, serous fluid. An opening in front of the meatus and just below the tragus afterward formed, from which the discharge was more purulent in character. On the 1st of September, when Dr. Pomeroy first saw the patient, a large abscess occupied the region of the fossa conchæ, and extended upward, downward, and backward, involving at least half the area of the auricle. In front of the meatus, near the tragus was a circumscribed swelling, with a fistulous opening in its apex. The large tumor was somewhat nodulated, but fluctuation was easily recognized throughout, both in front and behind. An incision was made posteriorly, where the wall of the abscess was very thin, and about five drachms of pus were evacuated. On exploration with the finger, it was found that the cavity of the abscess was bounded, both in front and behind, by integument and connective tissue only, the cartilage having entirely disappeared from the region involved. At subsequent times small abscesses made their appearance in other localities, viz.: in the region of the lobule, three; in the tragus, one; in the upper portion of the helix, two. The larger cavity closed in three weeks without special treatment, beyond a thorough daily cleansing with tepid water. The discharge from the abscess in the helix was somewhat glairy in character. Early in November the

---

<sup>1</sup> This case is reported in detail in the Transactions of the American Otological Society for the year 1875.

last abscess healed, but the auricle remained in a very greatly deformed state.

This case, when studied in the light of Meyer's and Pollak's investigations, adds strength, it seems to me, to the theory that othæmatomata owe their origin primarily to a softening of the cartilage in spots. An intercurrent acute inflammation of the skin, or of the perichondrium at some one spot, may be required to fan these smouldering fires into a rapidly destructive conflagration, such as that observed in the present instance; but, without the predisposition supplied by the existence of several centres of softening in different parts of the cartilage, it is difficult to understand how an inflammation, beginning in the middle ear or external auditory canal, and extending to the auricle, should result in such serious damage to the cartilaginous framework.

Wendt,<sup>1</sup> under the heading, "A Case of Subacute Inflammation of the Cellular Tissue of the Auricle," describes a case which corresponds in all essential particulars with the one just narrated. With this exception, I can find no other case on record in which the extent of the destruction of the cartilage and the degree of the deformity resulting therefrom were so great as in Dr. Pomeroy's case.

The case reported by Dr. Roosa, under the title of "Deformity of the Auricle, resulting from Inflammation of the External Auditory Canal," seems to me to belong properly to this category.<sup>2</sup> The subject is one of such importance that I make no apology for giving somewhat in detail the history of this case.

The patient, a female, forty years of age, consulted Dr. J. Orne Green, of Boston, on the 13th of November, 1871. She was then suffering from a diffuse inflammation of the meatus, of one week's standing. "The swelling was greatest about the middle of the meatus, closing the passage there. There was not much swelling externally. During that week she had a furuncle on one eyelid, and when seen was suffering from inflammation of one ala of the nose." As the application of poultices failed to reduce the swelling, Dr. Green made an incision nearly the whole length of the meatus. This evacuated a little pus and relieved the pain. Three or four days later the ear began to swell again, and all the old symptoms returned. Another thorough incision was made, evacuating a little pus and causing slight relief. On the 22d of December—that is, several days after the last incision had been made—she came under Dr. Roosa's care. The auricle, which had in the meantime been poulticed a great deal, presented a somewhat reddened appearance. The whole meatus was occluded by a fungous growth springing from the middle of the anterior wall of the auditory canal. Dr.

<sup>1</sup> Archiv für Ohrenheilkunde, Bd. III., S. 30.

<sup>2</sup> Transactions of the American Otological Society, 1873, p. 123 (with an excellent woodcut of the deformed auricle).

Roosa removed this by a snare, applied nitric acid to the base, and ordered the warm douche to be continued. The patient's general condition was not good. Tonics were continued. As the fungous growth still persisted in sprouting after its removal, Dr. R. found it necessary to remove portions of it from time to time. Toward the end of January the whole auricle became very red, swollen, and tender. Fluctuation could be felt in different parts, and especially in the concha. Incisions were made at different times into these fluctuating swellings. A bloody serum was evacuated, but no pus. "On February 12th the canal had thoroughly healed, but the auricle was still swelled, red, painful, and tender, and the natural features of the part, except the helix, were removed by this swelling, so that the ear was considerably deformed. The meatus was but a minute opening, but when the walls were drawn apart the hearing was found to be unimpaired. The membrana tympani was never affected during the whole course of the trouble." The patient returned to Boston at this time, and was under the care of Dr. Henry L. Shaw. The swelling of the auricle increased, and at different times incisions were made, and pus was evacuated. All active inflammatory symptoms did not cease until during the following April or May.

Dr. Lucien Howe, of Buffalo, has recently reported a case, which may possibly belong in this same category.<sup>1</sup> The degree of deformity observed in this case, and caused, as Dr. Howe believes, by a chronic purulent inflammation of the middle ear, is so slight that, when examined by itself, the auricle presents simply a somewhat peculiar appearance. When, however, it is compared with the auricle of the opposite side, where the middle ear shows no evidences of ever having been the seat of a chronic purulent inflammation, the deformity is seen to be quite marked. In the first place, the auricle, as a whole, is considerably smaller than its fellow; and, in the next place, the fossa conchæ is noticeably contracted and also more or less distorted in its outlines. It is a very common experience, in cases of chronic purulent inflammation of the middle ear, to find the external auditory canal greatly diminished in size from protracted inflammation of its walls, but I cannot recall a single case in which the auricle had become, through similar causes, so deformed as to attract my notice, and so lead me to compare it with its fellow. It is quite possible that in cases where pus is discharged for weeks and months at a time over the walls of the cartilaginous meatus, over the posterior aspect of the tragus, into the fossa conchæ, and through the incisura intertragica, a chronic subacute perichondritis may be kindled and kept up until a considerable amount of cicatricial tissue is produced. As the tendency of this newly formed tissue is to contract powerfully, it is easy to understand how, in course of time, the auricle may become noticeably diminished in size and otherwise twisted out of shape. But how are we to distinguish these cases with certainty from those in which the de-

---

<sup>1</sup> Buffalo Medical and Surgical Journal, Dec., 1879.

formity owes its origin to an attack of chondromalacosis? This latter disease may perfectly well run its course contemporaneously with a chronic otitis media purulenta; in fact it is not unlikely that the irritation produced in the canal and vicinity by the stream of more or less acrid pus which flows over it, may even fan into activity an otherwise latent chondromalacosis. A careful inquiry into the past history of cases like that which Dr. Howe has reported may in time solve some of these questions which now must await a solution until our store of facts has become larger.<sup>1</sup>

*Diagnosis.*—Perichondritis of the auricle presents, in its acute stage, such salient features that no physician would be likely to mistake it for any other form of disease. The conditions presented are practically those of an abscess, generally of large size; but the abscess has peculiar anatomical relations, and its contents are usually different from those of an ordinary abscess. Thus, we find, after an incision has been made, that the cartilage forms one wall of the abscess, and the perichondrium the other. We also find that the contents of this abscess are composed, not of thick, healthy pus, such as is usually found in acutely formed abscesses, but of a glairy yellowish fluid, or of a bloody serum, or partly of thick pus, and partly of thin, yellowish serum. From the external appearance alone it is impossible to decide whether the abscess owes its origin to a burn, to a frost-bite, to a blow upon the ear, or to nutritive changes in the cartilage or perichondrium.

If, in addition to the perichondritis, softening processes are going on in the subjacent cartilage, the combined destructive and proliferative changes may give to the auricle such a knobbed and distorted appearance as to suggest the presence of cancer. In Dr. Pomeroy's case I frankly confess that I leaned more decidedly toward the diagnosis of epithelioma of the auricle than toward that of a chronic inflammation of the perichondrium. I had recently had under my care a well-marked case of epithelioma of the auricle, and the outward resemblance between that case and the one I have just referred to was so strong that I could not help being struck with it. Besides, I had never before seen a case of chondromalacosis, and was not aware that it could produce such extensive destruction of the cartilage in one part of the ear, and such marked hypertrophy of the perichondrium in another. On closer examination, however, an appreciable difference between the two conditions can be made out even with the naked eye. In cancer, for instance, the skin will be found to have lost its suppleness, and to be rough and uneven on its surface; while in chondromalacosis the skin is either smooth or is capable of being made smooth by stretching, and it can readily be shown that the unevenness of surface is due to the unevenness of the subjacent

<sup>1</sup> From a very superficial examination of the literature I find that three cases of othæmatoma, in mentally sound persons, have been reported in addition to those already mentioned, viz., one by Schwartze (*Arch. f. Ohrenh.*, Bd. II., S. 213), in which a blow upon the ear was the exciting cause; and two by Brunner (*Op. cit.*, Bd. V., S. 26), in one of which a frost-bite was the exciting cause.

parts rather than to any changes in the skin itself. As a matter of course, a microscopic examination of the suspected tissues would set at rest all doubts about the correctness of the diagnosis.

*Prognosis.*—The prognosis in this class of cases has reference simply to the degree of deformity which is likely to result from the disease. In simple perichondritis the prognosis is good. If the abscess is opened early and freely, very little, if any, deformity will be left after the parts have healed. In chondromalacosis the degree of permanent deformity will depend chiefly upon the extent of cartilage destroyed, and only to a slight degree upon the inflammatory thickening of the perichondrium.

*Treatment.*—Cases of perichondritis or of chondromalacosis of the auricle rarely come into the physician's hands until a distinct cavity, with fluid contents, has formed. The most urgent indication in this stage of the disease is to relieve the tension and prevent further separation of the perichondrium from the cartilage. This can best be accomplished by making an incision into the swelling; not a small one, which will allow only the fluid portions of the contents to escape, but a liberal one, that will afford ample room for the thorough daily cleansing of the cavity. If the cartilage seems to be in a healthy condition, we may begin at once, on the day following the incision, to bring moderate pressure to bear upon the separated cartilage and perichondrium, in hope of thus hastening their union by adhesion. For this purpose Dr. Hickok's contrivance, described on p. 43, will be found very useful; or two pads may be adjusted, one in front of and the other behind the auricle, and a bandage may then be passed over the top of the head and under the chin, in such a manner as to keep the pads in position and exert moderate pressure upon the walls of the cavity. In addition to the daily cleansing of the cavity with tepid water, and the readjustment of the pads and bandage, it is doubtful whether we can do anything that will materially hasten the process of healing. My own preferences would lead me to mop out the cavity with tincture of iodine after each cleansing, but I cannot say positively that this procedure materially hastens recovery. Instead of the simple tincture, the compound tincture of iodine may perhaps be used with equal advantage. In cases of chondromalacosis it would probably be better to omit making pressure until we are confident that the processes of softening have come to an end. If new collections of fluid form in other parts of the auricle, these must each be treated separately, in exactly the same manner as the original collection.

Probably in a majority of these cases, it will be found desirable to prescribe quinine, iron, and a more liberal diet. It is unnecessary, however, for me to enter any more fully into this aspect of the subject.

## NEW-GROWTHS.

*Fibroid tumors* of the auricle are observed quite frequently among negroes, and occasionally among white women, as a result of the operation of piercing the lobule, or of the irritation caused by wearing an ear-ring. Through the kindness of my colleagues I have had the opportunity of examining two or three cases of this form of new-growth, but I have never had a case under my immediate care. The tendency to recur, after apparently complete extirpation with the knife, is perhaps the most interesting feature connected with these growths. In one of the cases referred to above, the extirpated tumor—the second or third return of the growth—was placed in my hands for microscopic examination. To my surprise, the most careful search failed to discover cellular elements in any part of the mass, which was as large as a hickory-nut and slightly lobulated in structure. The growth seemed to be made up entirely of fibrous tissue, which appeared under the microscope in the form of wavy bands.<sup>1</sup>

Next to the fibroma, *epithelioma* is probably the commonest form of new-growth observed in the auricle. The following is the only case of this nature that has come under my observation. The patient, a coachman, forty-three years of age, and otherwise in excellent health, presented himself at the Infirmary with an auricle which, at first sight, seemed to be affected with eczema. The larger part of the upper half of the auricle presented, on its anterior aspect, an almost continuous mass of scabs. On the posterior surface there was also one moderately large scab. Between these crusts, and surrounding them, the skin presented a bright red and infiltrated appearance, with quite sharply defined limits at the points where it merged into the surrounding healthy skin. After the scabs had been removed, it was found that they covered quite deep ulcers. At one spot, corresponding to the location of the crust on the posterior aspect of the auricle, the cartilage was completely destroyed, and a mop of cotton-wool, at least four millimetres in diameter, could readily be passed through the opening from one side to the other. The orifice of the external auditory canal was not involved. The patient gave the following history of the development of the disease: During the previous winter his right auricle had been frost-bitten, and the affected portion had subsequently remained quite sore. Different plans of treatment had been tried, but the area of soreness had steadily increased despite all treatment. As the neighboring glands

---

<sup>1</sup> Cases of fibroid tumor of the auricle have been reported by Bertolet (Trans. Amer. Otol. Soc., 1871), Clarence J. Blake (Arch. Ophth. and Otol., Vol. III., No. 1, p. 87), Burnett (Treatise on the Ear), and others. A very interesting case of myxofibroma of the auricle is reported by Dr. C. R. Agnew, in the Transactions of the American Otol. Soc. for 1878. In this case the tumor returned four times after the original operation.

were not enlarged, I thought the progress of the disease might be arrested, or at least be retarded, by excising the diseased portions of the auricle. The patient's consent having readily been obtained, he was etherized, and, while he was under the influence of the anæsthetic, a V-shaped piece, including the diseased tissues, was excised by means of a strong pair of scissors. The remaining upper and lower portions of the auricle were then fitted to each other as neatly as possible, and held in coaptation by means of several very fine interrupted sutures. The wound healed promptly, but very soon afterward fresh evidences of the disease manifested themselves along the line of the cicatrix, showing quite clearly that all the diseased tissues had not been excised. In 1877 I heard that the man was still alive, but could learn no particulars with regard to the condition of the affected auricle.

The case reported by Dr. J. Orne Green, of Boston,<sup>1</sup> resembles, in all essential particulars, the one which I have just described. In his case, however, the disease had made further progress, and complete amputation of the auricle and cartilaginous portion of the meatus was found necessary. Roosa,<sup>2</sup> and Burnett<sup>3</sup> each report a case, and the latter gives full reference to the literature of the subject.

In 1871, at the meeting of the American Otological Society, I reported a case of *cornu humanum*<sup>4</sup> of the auricle. The details of this case are as follows: The patient, a man fifty-five years of age, and in good general condition, stated that nearly two years previously he first noticed a small sharp point on the top of the ear. He picked it constantly with his nails, until it became sore. At the same time he noticed that what he supposed to be a simple scab covering the spot, grew to be quite thick, hard, and prominent. Whenever it reached such a size as to be an object of disfigurement, he was in the habit of paring it down with a razor. During the past two months it had grown, he thought, rather more rapidly than before, and he was therefore anxious to have it removed.

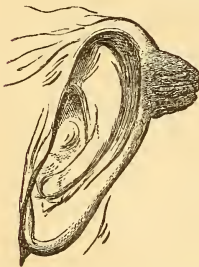

FIG. 13.—Cornu humanum of the auricle.

At the time when he visited me the growth presented the following appearances: a blunted, horn-like protuberance, three-fourths of an inch long and nearly as broad at its base, springs from the upper and posterior portion of the left helix. Of a whitish color at its base, it gradually grows quite smoky at its summit, which is more or less jagged in appearance. It is distinctly striated, the markings running in a slightly

<sup>1</sup>Transactions of the American Otological Society, 1870.

<sup>2</sup>Treatise on the Diseases of the Ear. New York, 1873.

<sup>3</sup>Treatise on the Ear. Philadelphia, 1877.

<sup>4</sup>See Rindfleisch: Pathologische Gewebelehre, Leipzig, 1866. § 293.



divergent direction from the summit to the base. At the extremity, and in the middle portion it is hard like horn, but near the base it can easily be compressed, though yet comparatively hard. The line of demarcation between the growth and the normal skin is very abrupt. There is no tenderness on pressure.

The patient having been brought under the influence of ether, I made two converging incisions on either side of the base of the tumor. The tissues included between these incisions comprised every trace of the new-growth, and the wedge-shaped wound which remained was obliterated by approximating the opposite edges of skin and keeping them in close apposition by means of fine interrupted sutures. Union took place by granulation, and at the end of the third week scarcely a trace of the operation could be detected. Six months later the patient was seen again. There were no signs of a return of the growth. A small, sharp point, however—similar, he says, to the one first noticed on the ear—could be distinctly felt and seen on the outer surface of the left eyelid.

#### MISCELLANEOUS DISEASES.

I have never seen a case of *herpes zoster* of the auricle, and must refer the reader, for information upon this topic, to a monograph by Gruber,<sup>1</sup> to a paper by J. Orne Green, on "Neuralgia in and about the Ear,"<sup>2</sup> and to Burnett's "Treatise on the Ear." I have also never seen a case of *lupus* of the auricle. Strawbridge,<sup>3</sup> of Philadelphia, reports one case of the disease, and Neumann<sup>4</sup> makes the statement that the auricle is the favorite seat of *lupus*.

*Syphilitic gummata* and *syphilitic ulcerations* are occasionally seen on the auricle. The following two cases are the only ones that have come under my personal observation:—

First case. Male, ætat. 26. May 27, 1874. Syphilis (primary) four years ago. Sore throat and eruption on face last December. Three weeks ago he began to have some pain in the left ear, without tinnitus or noticeable deafness. During the past week the pain has been more pronounced, and there has been a slight discharge from the outer canal. Tragus and outer portion of meatus red, swollen, and tender, especially superiorly. Deep ulceration of the auricle at the commencement of the helix just

<sup>1</sup> Die Bläschenflechte am Ohre. Monatsschrift für Ohrenheilkunde, IX., 5, May, 1875.

<sup>2</sup> Transactions of the American Otological Society, 1874.

<sup>3</sup> Ibid., 1878.

<sup>4</sup> Monatsschrift für Ohrenh. III., 5, May, 1869.

above the orifice of the external auditory canal. It measures fully half an inch in diameter, and extends down to the cartilage.

The ulcer was cauterized with the stick of nitrate of silver, and three leeches were applied in front of the tragus. (Patient did not return.)

Second case. Male, ætat. 32, in rather poor physical condition, June 16, 1875. He is now suffering from syphilitic disease of the nasal bones or cartilages, the contour of the nose being already disfigured. A large part of the fossa conchæ of the auricle is occupied by a dry scab, from beneath one edge of which a little pus escapes. The removal of this scab brought to view a roundish ulcer about the size of a three-cent piece. The ulcerated surface, which was not depressed below the surrounding surface of healthy skin, seemed to be composed of a soft, succulent tissue, in places apparently papilliform in structure. A single application of a saturated solution of nitrate of silver caused the ulcer to heal entirely in the course of a few days. It should be stated, however, that the patient had been taking iodide of potassium for some time previously.

Chimani reports an interesting case of *cirroid aneurism* of the auricle, involving the branches of the superior, anterior inferior, and posterior auricular arteries.<sup>1</sup> A somewhat similar case is reported by Weinlechner.<sup>2</sup> Repeated injections of a solution of the chloride of iron accomplished a complete cure in the former case, but in the latter it was found necessary to ligate the carotid artery.

In both of these cases a dilatation and perhaps lengthening of existing arterial vessels constituted the chief feature of the disease, while in the case of "*angioma cavernosum*" reported by Kipp,<sup>3</sup> an actual new-growth of blood-vessels appears to have taken place. The case of an "erectile tumor" of the auricle, reported by Martin,<sup>4</sup> and referred to by Schwartz,<sup>5</sup> was probably of the same nature as that observed by Kipp.

*Cleft lobule*, due to the wearing of ear-rings, is a comparatively common deformity of the auricle. I have several times seen a double cleft, but have never observed either the single or the double cleft in a patient who considered the deformity sufficiently great to impel her to have it remedied by an operation.

It would seem as if *wounds* and *contusions* of the auricle ought to come under the aural surgeon's observation quite frequently, especially in a large city like New York. As a matter of fact, I have seen but one case of this kind. Furthermore, on looking over the last annual report (1878) of the

<sup>1</sup> Archiv f. Ohrenheilkunde, Bd. VIII., S. 62.

<sup>2</sup> Monatsschrift f. Ohrenheilkunde, XI., 1877.

<sup>3</sup> Transactions of the American Otological Society, 1875.

<sup>4</sup> Gazette des hôpitaux, 102, 1857.

<sup>5</sup> Archiv f. Ohrenheilkunde, I., S. 237.

New York Eye and Ear Infirmary, I find that out of a total of nearly 2,800 cases of ear disease, there was but one case of lacerated wound of the auricle; from which I infer that traumatic disease of this part of the body is quite rare. In the single case which came under my observation, the patient, a strong, healthy woman, had fallen in such a manner as to strike heavily with the side of her head upon the sharp edge of a tin pail, which was standing upon the floor. She was probably intoxicated at the time. After she had risen to her feet, she discovered that the lower part of the ear (the entire lobule and the lower portion of the helix) had been almost severed from the head. When she appeared at the Infirmary, three days after the accident had happened, the lobule was found to be hanging loosely suspended by a small band of flesh. The raw surfaces had begun to suppurate, but there was very little redness or swelling of the adjacent parts. At the suggestion of my colleague, Dr. J. N. Beekman, the raw surfaces were kept in close apposition by means of a series of delicate supporting loops or bands of frayed lint held fast by a coating of collodion. By this device the edges of the wound were brought together in as perfect a manner as if a series of fine sutures had been used. The extreme posterior end of the wound was left open for drainage purposes. When the patient returned to the Infirmary, exactly one week later, the dressings were found to be still firmly in position, and the parts presented every appearance of having practically united by first intention; at all events, there was no evidence that further suppuration had taken place. To ensure thoroughly firm union, the patient was instructed to wait three or four days more before removing the dressings. As she did not return a third time, it is fair to infer that the cure proved successful.

#### CONGENITAL MALFORMATIONS.

Only three cases of congenital malformation of the auricle have come under my personal observation. In the first case (a young infant of the female sex), both ears were deformed, though in a very different degree. The right auricle was perfect in all its parts, but just in front of the tragus, and perhaps continuous with its cartilaginous framework, was a loosely attached, irregular mass, which might perhaps be considered as a supernumerary tragus. It consisted of three distinct lobes, of which the central one was considerably larger than the other two. The external auditory canal was normal. The left auricle was represented by a small, irregularly shaped, flattened mass, which bore no resemblance whatever to a normal auricle. Very nearly in the centre of this mass, externally, there was a small depression, which ended in a cul-de-sac at a depth of three or four millimetres. Beyond the depression, I could feel a short, solid cord, representing undoubtedly the obliterated or imperfectly developed external auditory canal. In all other respects, the child seemed to be perfectly formed and well nourished.

In the second case (female child, nearly three years old), the malformations of the auricles were exactly the same on both sides. The lobe was perfectly formed and of full size, but the upper parts of the auricle seemed to be shrivelled up into a small shapeless mass. As in the previous case, a small depression indicated the situation of the rudimentary external auditory canal. With the finger the tympanic ring could readily be outlined; it appeared to be of normal size. The parents were positive that the child heard quite well. I was not able myself to determine satisfactorily what degree of hearing she possessed. Apart from the deformities described above, the child appeared to be perfectly formed.

Finally, in the third case, the deformity consisted in an imperfectly developed cartilaginous framework of the auricle. The child, a twin, four years old, and otherwise well developed, possessed two large, but very thin, auricles. The fossa helices of each ear was obliterated, and the upper part of the auricle drooped, somewhat after the fashion of a dog's ear. The changes noted were more marked on the left than on the right side. The impression made upon my mind at the time was that undue pressure *in utero* had flattened both auricles, and had arrested the development of their cartilaginous frameworks.<sup>1</sup>

---

<sup>1</sup> Dr. C. J. Blake reports an interesting case of congenital malformation of the auricle, in the Archives of Ophthalmology and Otology, Vol. III., No. 1, p. 86. Strawberry reports a case in the Transactions of the American Otological Society, for 1875, and gives some references to the literature of the subject. Dr. Knapp also reports a case in the Transactions of the American Otological Society, for 1870. Further references to the literature of the subject will be found in the treatises of Roosa and Burnett.

## CHAPTER IV.

### DISEASES OF THE EXTERNAL AUDITORY CANAL.

THE diseases to which this portion of the ear is liable comprise those which affect the auricle, and others which are peculiar to the canal itself. By far the commonest of these is,

#### IMPACTED CERUMEN.

In the cartilaginous portion of the external auditory canal, and also, to a very limited extent, in the osseous portion, there are glands which secrete the peculiar substance known as cerumen, or ear-wax. These glands, when examined under the microscope, in thin sections of the meatus, are seen to be similar in all respects to the sweat-glands. The secretion from these glands is a transparent yellowish fluid. It is only after exposure to the air that it gradually becomes inspissated and of a darker color. Under certain conditions the ceruminous glands secrete this yellowish fluid in such abundance that it escapes from the orifice of the external auditory canal in the form of a watery discharge. I have several times been told by patients that they had a discharge from the ear, and, on making an examination, have been surprised to find that what both they and I supposed to be a *bona fide* discharge of pus or sero-pus, was in reality simply an excessive secretion of fluid cerumen. As a rule, however, the rate of secretion is so slow that the cerumen becomes inspissated very soon after it leaves the mouth of the gland. For the further propulsion of this material out of the canal, Nature seems to have made a very curious provision. It is now an established fact that at least the uppermost layer of the epithelium lining the external auditory canal moves constantly from within outward. Thus, for example, if on a certain day we find a scab resting wholly upon the drum-membrane, five or six days from that time we shall find it resting partly upon the drum-membrane, and partly upon the wall of the osseous canal. At the end of another week it will be found to have travelled outward entirely beyond the limits of the membrana tympani. This same surface movement undoubtedly takes place symmetrically throughout the entire length of the canal, and supplies the force required to extrude all ordinary accumulations

of cerumen. In the Eustachian tube and in the bronchial tubes we find the epithelial cells provided with cilia which constantly vibrate in such a manner as to propel any mucus or foreign substance that may happen to be in the tube, in the direction of the naso-pharyngeal space or of the larynx as the case may be. The conditions that exist in the external auditory canal do not require any such vigorous propelling power as that supplied by the movement of the cilia in the other channels mentioned, and, accordingly, Nature supplies a less active power, but, at the same time, one that is better adapted to stand the rough usage to which this part of the body is specially liable.

It is not an easy task to harmonize the existence of such an extruding power in the walls of the external auditory canal with the extremely frequent occurrence of the condition known as impacted cerumen. An abnormal activity on the part of the ceruminous glands is undoubtedly the most important factor in the production of this condition. At the same time hypersecretion alone can hardly be held responsible for the production of the impacted state; other factors must certainly aid in producing it. The sharp bend which the canal makes near the external orifice is often associated with such a marked shortening of one of its diameters that for all intents and purposes the canal is very much narrower at this point than it is a short distance deeper in, where the larger part of the cerumen is secreted. This narrowing of the canal varies greatly in different individuals, and in some no narrowing whatever is found. Where it exists, one can easily conceive how it may prevent a mass of cerumen, of comparatively small size, from being extruded from the canal. When the mass has once been arrested in its movement outward, there is no difficulty in understanding how it may grow, by accretions upon its surface, to the full size of the cavity which contains it. Furthermore, it is not unlikely that the individual's own efforts to keep the orifice of the external auditory canal clean, or to relieve the sensation of itching which is so often present in this condition, sometimes result in pushing the accumulation farther inward toward the drum-membrane.

Excessive secretion of cerumen is so often associated with naso-pharyngeal catarrh that it is hard to resist the belief that the former is a reflex phenomenon dependent upon the latter. On the other hand, in certain cases of well-marked deafness, it is a common experience to hear the patients say,—of their own motion, and not in response to a question,—that they never find wax in their ears, and have not for several months or years past. The few cases that I have examined, since my attention was attracted to the coincidence of deafness with absence of the secretion of cerumen, presented the following conditions:—The membrana tympani was unusually thin and translucent, though not appreciably sunken; through its posterior half could be seen the darkly shaded niche of the fenestra rotunda, and, above this, perhaps also the faint outlines of the long process of the

anvil. The whiteness of the promontory was also easily recognized through the membrane. On inspection of the pharynx the mucous membrane of this region was found to be pale and very thin; apparently the follicles had all disappeared through atrophy. As I shall have occasion to speak of these conditions again farther on, it is not necessary to enter more minutely into details in this place. If it be once admitted that increased functional activity of the pharyngeal glandular elements may in a reflex manner increase the functional activity of the ceruminous glands, the question at once suggests itself, Why may not the subsequent atrophy of the pharyngeal glands bring about, in the same reflex manner, a wasting of the glands in the external auditory canal? Is it not also by a reflex process that organic disease is set up in one eye by disease already existing in the fellow eye? It would of course be premature to express any positive opinion with regard to the relations here suggested. Further facts, both clinical and pathologico-anatomical, are needed, before we can be sure, first, that the relations described above are not exceptional, and, second, that the absence of cerumen in the auditory canal is really due to a wasting of the glands which produce it.<sup>1</sup>

*Symptomatology.*—During the formation of the mass, before it has reached such a size as to occlude the canal, the patient, as a rule, experiences no symptoms which would be likely to call his attention to the ear. In cases, however, where the canal is slit-shaped, a sense of fulness or discomfort may be experienced long before the canal is actually occluded,—that is, as soon as the accumulation is large enough to bridge the space between the opposite walls. Complete occlusion may take place so gradually that the patient's attention is attracted to only one symptom, viz., the gradual

---

<sup>1</sup> Some time after the above had been written, I discovered a paragraph in an article by Dr. O. D. Pomeroy, of this city (Trans. of the Amer. Otol. Society for 1872. Article on an Examination of 100 Cases of Impacted Cerumen, etc.), in which the writer expresses in part the same view as that which I have just stated. His words are: "In view of the fact that frequently an absence of a normal amount of cerumen is observed in old cases of aural catarrh, it may, together with the present observations, cause one to infer that the ceruminous function is greatly affected in catarrhal diseases.

"Perhaps a theory of this kind may sometimes be borne out by a sufficient number of facts; that the earlier stages of catarrh result in hyperæmia, and consequently augmented function of the ceruminous glands, which, continued, may result in atrophy, with abolition of function, precisely as results in inflammations of the mucous membrane lining the fauces, etc."

It is perhaps more in accordance with established facts to consider atrophy—as the natural termination of the prolonged increased functional activity of the ceruminous glands, than to consider it as the result of reflex influences. With regard, however, to the first step in this series of changes, I should rather favor the view which refers its origin to a reflex influence, than that which makes the irritation spread directly from the mucous membrane of the middle ear to the skin of the external auditory canal.

diminution of the hearing. In very many cases, however, the statement is made that the diminution in the hearing came on quite suddenly, as, for instance, after a bath, after washing the head, or after some mechanical interference with the ear (introduction of the end of a towel, etc.). This sudden diminution of the hearing may then pass away as suddenly as it came, to return again after the lapse of a few days or weeks. When the canal has become fairly occluded, other symptoms may develop. In a few cases there will be tinnitus, which may be ascribed to pressure exerted by the ceruminous mass upon the drum-membrane, or possibly to the obstruction of the venous circulation in the external auditory canal, thus causing a passive congestion of the veins of the middle ear, which pour their contents in part into those of the meatus. In any given case, however, it is nearly if not quite impossible to determine what share the ceruminous mass, and what the coexisting catarrhal inflammation of the middle ear, take in producing this symptom. Pain can hardly be mentioned among the symptoms of this condition, as it is due to an intercurrent inflammation of the walls of the canal. Cases are on record which seem to show that impacted cerumen may produce, in a reflex manner, epileptiform convulsions. I have also recently read of a case in which a chronic bronchial catarrh seemed either to owe its origin to, or to be kept up by, the presence of a mass of impacted cerumen in the patient's auditory canal.<sup>1</sup> At all events, the removal of the mass caused the cough and expectoration to cease in a very short time. Furthermore, cases have been reported in which a high degree of dilatation of the osseous canal is ascribed to the pressure of a mass of cerumen. I believe that cases have also been reported in which even a fatal issue has been referred back to the gradual increase in size of a mass of impacted cerumen. My impression is, that if all these cases could be carefully analyzed, the great majority of them would be found to be in reality cases of desquamative inflammation of the canal, or of otitis media purulenta, with hardening of the purulent secretion in the meatus. Inspissated cerumen forms on the outer side of, and becomes mingled with, these purulent and epidermal products, and so the cases come to be classified among those of impacted cerumen. While it may not be possible in all cases to draw a sharp line of distinction between the milder cases of desquamative inflammation of the canal, and those of inspissated cerumen, it is of decided practical importance to make the distinction whenever we can. So far as my own experience goes, I may say that I have never seen a case in which the pressure made by a mass of impacted cerumen has caused absorption of the bone and consequent increase in size of the canal. Nor have I ever seen one in which bronchial catarrh, epileptiform convulsions, or any other equally grave symptoms could fairly be attributed to impacted cerumen,

---

<sup>1</sup> The case is reported in either the *British Medical Journal* or the *London Lancet*, in one of the November numbers (1879).



in the strict sense of the term. Tinnitus and moderate dizziness, due probably to the pressure of the mass upon the drum-membrane, are certainly not rare symptoms, but I have never seen a case in which the impacted cerumen had produced actual fainting or loss of consciousness.

*Diagnosis.*—Inspection with the speculum and reflected light reveals the presence, in typical cases, of a black or dark brown mass, filling the canal, and obstructing the view of the deeper parts. Until the contents of the canal have been thoroughly removed, it is not safe to say positively that the case is simply one of impacted cerumen. All sorts of conditions may be found beyond the outer mass or shell of cerumen, and the physician must therefore withhold or modify his diagnosis until he can ascertain fully the true state of the ear.

*Prognosis.*—In cases of impacted cerumen, associated with difficulty of hearing, the physician will do well to express his opinion very guardedly with regard to the question of restoration of the hearing-power. It is such a common experience, as I have already stated, to find a chronic nasopharyngeal and middle ear catarrh associated with impacted cerumen, that he should always be prepared to find that the catarrhal affection and not the obstructing mass, has diminished the acuteness of the hearing. The marked tendency to relapses must also not be forgotten, when a prognosis is given.

*Treatment.*—The question of treatment resolves itself practically into the question, How can the obstructing mass be removed most thoroughly, quickly, and pleasantly—both for the patient and for the physician? In the earlier period of my practice I pursued the orthodox plan of employing the syringe and warm water for this purpose. Little by little, however, I became satisfied that in the great majority of cases the removal of the mass could be effected much more quickly and pleasantly by the use of the curettes, the cotton-holder, and the angular forceps, than by any other plan. Accordingly, during the past eight or nine years it has been my uniform practice to use the syringe only in certain exceptional cases, for instance, in those in which, after the removal of the greater part of the mass by instrumental means, a semifluid or very tenacious cerumen was found plastered over the drum-membrane; and also in those in which the extreme smallness of the canal rendered it unusually difficult to follow the movements of the curette with the eye. The objection raised by some authors against the instrumental plan of removing impacted cerumen, viz., that it requires great skill, and may prove highly dangerous in unskilful hands, does not seem to me to be a valid one. Therapeutic methods should be recommended in accordance with their absolute merits, and not because they will be likely to prove the least harmful in unskilled or clumsy hands. The merits of the instrumental plan have already been alluded to, but I will repeat them here. In the first place, when a case of impacted cerumen presents itself for the first time, we cannot say positively what is the condi-

tion of the membrana tympani and deeper portions of the canal. The conditions may be such as to contraindicate the introduction of a stream of water. This risk, which is entirely avoided by the instrumental plan, must be incurred by those who make a practice of employing the syringe. In the second place, in a large number of cases, the instrumental plan will accomplish in ten or fifteen minutes what the most skilful employment of the syringe cannot possibly accomplish in even an hour's time. In the third place, it is easily possible for a man with average manual skill to acquire such dexterity in the manipulation of the curette, and the other instruments mentioned, that he will be able to remove impacted cerumen from the auditory canal with less discomfort to the patient than is usually experienced when the syringe is used. I base this statement upon my experience as a clinical instructor; many of my pupils having, in a comparatively short time, acquired the power to accomplish this task successfully. Finally, I am confident that if those physicians who are now in the habit of employing the syringe for the removal of cerumen from the external auditory canal, would cast aside their prejudices and give the instrumental method a fair trial, they would not be willing to submit themselves again to the sloppy thralldom of the syringe. The cases of impacted cerumen and of acute and chronic otorrhœa, taken together, constitute nearly fifty per cent. of all the cases that come under the observation of the aural surgeon. The mere mention of this fact is sufficient to convey a tolerably accurate idea of the amount of syringing which the advocates of this therapeutic method must do in every-day practice.

As the cases of impacted cerumen differ from each other in important particulars, only very general directions can be given with regard to the proper mode of removing the impacted mass with instruments. In the first place, the physician must follow every step of the operation with the eye. He should use as large a speculum as the size of the canal will permit, and the illumination should be good. If the wax is quite soft, a small channel should be cleared, with the curette, for a short distance along the upper wall of the canal, in order to afford room for the introduction of the cotton-holder armed with a mop of cotton of suitable size. Two or three introductions of the cotton-holder, armed each time with a fresh mop, will usually suffice to remove all the cerumen lying between the external orifice and the farther end of the channel made by means of the curette. The remainder of the mass is to be treated in precisely the same manner, until the whole of it shall have been removed from the auditory canal. If the wax is moderately firm in consistency, the entire mass may be removed piece by piece with the curette. The occasional use of the forceps will also be found advantageous, especially if the surgeon has succeeded, by means of the curette, in separating the mass, or a large portion of it, from its attachments to the walls of the canal. There are certain conditions in which the slender silver probe will be found a more useful instrument than the curette; as, for

example, where a mass of cerumen is wedged in between the drum-membrane and the anterior and lower wall of the canal. By giving to the end of the probe a slight curve, one can readily dislodge the mass and bring it within reach of the forceps. In those cases in which, after removing almost all of the obstructing mass, I have found the membrana tympani plastered over with soft cerumen, I have usually resorted to the syringe as the quickest and (to the patient) pleasantest means of removing this remainder of the accumulation. So long as the curette is made to pass flatwise over the walls of the auditory canal, and so long as the force employed is applied in the direction from the periphery toward the centre of the canal, the patient will experience no pain and perhaps not even discomfort. If the canal is quite large and straight, the end of the curette may be bent in such a manner as to make the plane of the ring form an obtuse angle with the shank; and the same kind of dissecting manipulation as that to which I have just referred, can then also be applied to the surface of the drum-membrane. As a rule, however, a sort of scraping motion is the only effective one that can be communicated to the ordinary curette when brought in contact with the membrana tympani. Under these conditions, therefore, the syringe may be used with decided advantage.

If the physician, for any reason, decides not to use the instrumental method, he will find that in exceptional, though by no means rare cases, syringing alone will fail to dislodge the impacted mass. The only course left open to him, under these circumstances, is to employ some chemical reagent which possesses the power of softening masses of inspissated cerumen. Water alone, it is true, possesses this solvent power, but its action is extremely slow. Bicarbonate of soda, on the other hand, is quite rapid in its solvent action, and yet at the same time it may be used freely in concentrated solutions, without fear of injuring the walls of the canal. A good way of obtaining a concentrated solution is to drop a pinch of the powder into the orifice of the auditory canal (the patient's head being turned well over toward the opposite side) and then to pour in, with a teaspoon, a few drops of warm water. At the end of from twenty minutes to half an hour, the impacted mass will be found to have become softened to a depth of one or two millimetres, or even more. The softened débris are to be removed, and the concentrated solution is to be applied a second and a third time, until the entire mass has become so softened or so loosely attached to the walls of the canal, that its removal by syringing is easily effected.

Dr. Blake, of Boston, employs liquor potassæ, or a solution of caustic potassa, for the purpose of softening hardened masses of cerumen. He arms the end of a probe or cotton-holder with a small mop of cotton, dips it into the solution, and then applies it accurately to the centre of the outer end of the mass. Under the influence of such a strong alkali, the cerumen softens very rapidly, and so, little by little, he is able to bore a channel through the centre of the plug. The remaining shell can then be easily

broken into a mass of loose fragments, which syringing will quickly bring away from the canal.

Finally, one word more with regard to syringing in cases of impacted cerumen. One of the chief reasons why it so often fails to accomplish the desired result is this: the force of the current is spent upon the broad surface of the outer end of the plug, and tends therefore rather to drive it farther inward. The most effective plan is to direct the stream against one edge (preferably the upper edge) of the mass, in the hope of washing out a channel between the main body of the plug and the upper wall of the meatus. As soon as this has been accomplished, it will be found that the current begins to exert a *vis a tergo* upon a portion of the mass, and soon brings away fragments of considerable size.

*Complications.*—The only complication of which it is my intention to speak in this place, is that of an acute inflammation of the canal. Cases of this kind are not very common, and it is a fortunate thing that they are not, for the pain which characterizes the disease is usually of a very severe type. In all the cases which have come under my personal observation the patient had postponed seeking medical aid until the pain had become almost insupportable. By that time the orifice of the meatus had become closed by the swelling of the surrounding parts, and there was decided œdema of the skin covering the mastoid process. The tenderness involved both the temporal and the mastoid regions, though of course, it was most marked in the immediate vicinity of the canal. The pain was generally referred to the entire side of the head, as well as to the parts more directly affected. Only the smallest size of speculum could be used at first, but gradually the œdematous swelling yielded to the pressure made by the walls of the conical silver instrument, and eventually it was found practicable to employ one of the larger sizes.

Where severe pain is found associated with the conditions described above, the question is very apt to suggest itself, Shall we wait for the subsidence of this inflammation of the cartilaginous portion of the canal, before attempting to dislodge the impacted mass, or shall we proceed forthwith to remove it? I have always held the view that it was better to remove the plug as early as possible. Not even the most experienced surgeon can say positively, under such circumstances, whether the middle ear is involved or not, and to what extent the deeper portions of the meatus, those held fast between the bony walls and the hardened plug of cerumen, are participating in the inflammation. In the absence of accurate knowledge with regard to these important points, I believe the safest course to pursue is to remove the impacted cerumen as soon as practicable, and thus place the patient under the most favorable conditions, both for maintaining his hearing and for obtaining relief from his acute sufferings. This course, furthermore, is perfectly justified by the results. In every instance that has come under my observation, decided or complete relief speedily followed

the removal of the mass. In one or two cases, the removal of only the outer half of the plug brought such marked relief that I thought it perfectly proper to postpone the removal of the rest of the mass until the following day.

There is only one point to which I desire to call special attention in this connection. I refer to the employment of the conical specula as dilators. When well polished externally, they may be made to dilate a very narrow external orifice to one of really ample dimensions; and that, too, without causing the patient more pain than he or she can readily bear. I have sometimes accomplished the same thing with the cotton-holder, armed with a firm, olive-shaped mass of cotton, smeared on the outside with vaseline or simple cerate. By gradually increasing the size of the mass of cotton, and pushing it slowly inward by a sort of boring motion, the canal may be dilated to the desired size in a remarkably short time.

I have purposely avoided saying anything about desquamative inflammation of the auditory canal, as a complication of impacted cerumen, for the reason that I prefer to discuss the question under a separate heading, a few pages farther on.

#### ACUTE CIRCUMSCRIBED INFLAMMATION.

##### *Furuncles. Boils.*

The external auditory canal seems to possess a special predisposition to furuncular inflammation. Infants and young children apparently escape the disease altogether; or if boils do occur in such young subjects, they are so small and insignificant as not to attract attention. In children between the ages of five and fifteen, I have seen a few instances of the disease, and should hardly be justified in speaking of it as rare at this period of life. In adults, however, it is a comparatively common affection, constituting not less than two per cent. of all the forms of ear disease which come under the aurist's observation.

*Etiology and pathology.*—Our knowledge of the causes which give rise to the formation of furuncles in the external auditory canal is very scanty. In a fair proportion of the cases which I have seen, the patients have presented unmistakable evidences of not being up to the proper standard of health. In at least an equal number, however, the individuals have appeared to be perfectly healthy in all other respects than the one which led them to seek medical aid. In a few instances I have suspected a malarial origin for the local affection, but the grounds for this suspicion were in no case very strong. Among the exciting causes may be mentioned an irritating discharge from the middle ear or the deeper parts of the meatus. The entrance of salt water into the canal, seems, in a few cases, to supply

an adequate exciting cause. Instillations of a solution of alum are also said to favor the development of furuncles in the auditory canal. Finally, it is a very common occurrence for furuncles to develop in the course of an eczema of the auditory canal. In these cases, however, it is not quite clear to what extent we should lay the blame upon the eczema, and to what extent upon the scratching and rubbing which the itching of the eczema provokes.

In the development of furuncles in the external auditory canal, it is quite probable that in some instances a sebaceous follicle, in others a ceruminous gland, is the starting-point of the inflammation. When the latter seems to be displaying its chief activity far beneath the surface, it is fair to assume that the starting-point of this inflammatory action can hardly have been a sebaceous follicle, the deepest portion of which lies but a short distance from the surface. It seems more reasonable to suppose that, in these cases of deep-seated inflammation, the final coil of a ceruminous gland has furnished the starting-point for the inflammation. In a third class of cases the pathology is quite different. Externally the appearances are the same as those observed in cases of genuine furuncles. The subsequent course of the disease, however, shows unmistakably that a chondromalacosis, and not an inflamed sebaceous or ceruminous gland, is the real cause of the furuncular inflammation (*vide* Dr. Pomeroy's case, p. 46).

*Symptoms and course of the disease.*—The patient first notices a little pain in the region of the ear, and, on pressing with his finger upon the parts, finds that they are slightly tender. Sometimes the pain is preceded by a decided sensation of itching in the canal. Little by little the pain increases in severity, the tenderness becomes more marked, and the ear feels full and heavy. Throbbing is sometimes a marked symptom. Deafness is not observed until the swelling is sufficiently great to close the auditory canal entirely at the point involved. The pain, which at first is confined strictly to the ear, may afterward be referred to other parts of the head as well. It is often, for example, described as extending over the side of the head, or as shooting down into the lower jaw of the same side, or along the side of the neck. Not unfrequently the patients complain of their inability to eat solid food, on account of the pain which the motions of the jaw cause. If the furuncle is situated near the surface, it may rupture as early as on the second day; the inflammation and pain subside then very quickly. If the seat of the inflammation is farther removed from the surface, spontaneous rupture may not take place before the seventh or eighth day, or even, in rare cases, not until after the lapse of ten days or two weeks. The average duration, however, of the painful stage, is, roughly estimated, from five to seven days. In some cases—probably the majority—the pain disappears quite suddenly upon the occurrence of a rupture of the abscess; in others, little or no relief is experienced by the patient until some time afterward. In some instances, for a day or two

before the abscess ruptures, a scanty watery or slightly pinkish discharge is observed at the orifice of the canal. After the rupture, the discharge is usually purulent in character, and may even be quite copious. The duration of the discharge varies greatly in different cases. Usually it ceases in the course of two or three days; in a few cases, however, it may continue for several days or even weeks. In these cases it will generally be found that a mass of granulation-tissue has formed at the point of rupture of the former abscess, and that the latter is perhaps still represented by a small cavity or ulcerated depression in the skin. In rare cases the abscess burrows down in the direction of the parotid gland. This course of the disease I have observed only twice. In the first case, the patient—a female fifty-three years of age, and of apparently strong constitution—consulted me ten weeks after the disease had first manifested itself. The right auricle, and especially the fossa conchæ, was found to be red and swollen. The orifice of the auditory canal was closed by the swollen condition of the parts, and by the presence of a small mass of granulations springing from the base of the tragus. The deeper parts of the canal were not visible. There was considerable swelling in front of and below the auricle. On exploration with the probe it was ascertained that the mass of granulation-tissue at the orifice of the canal, concealed the entrance to quite a large cavity, situated chiefly below the tragus. Complete recovery followed in the course of about two weeks. In the second case,<sup>1</sup> the patient (a female, forty-three years of age) had been suffering from pain in the left ear for a period of nearly three weeks before I saw her. There had been no discharge from the ear. On examination, I found the orifice of the auditory canal closed by a circumscribed swelling, which presented all the appearances of a furuncle. A free incision through the mass failed, however, to reach pus. Three days later, I saw the patient a second time. The canal was even more swollen than before, and there was a noticeable swelling on the left side of the face, below and in front of the ear. Granulation-tissue had sprung up from the wound made by the incision. The pain had not abated. Four days later a copious discharge set in, and the patient experienced decided relief from pain. When I saw her, three days later still, I found the swelling below the ear more pronounced than when I had last seen her. The œdematous swelling extended to quite a distance from the abscess. Pressure made upon the most prominent portion of the tumor, below the ear, caused pus to flow from an opening in the lower wall of the meatus. The patient then became an inmate of St. Luke's Hospital, and I lost sight of the case.

In the first of these two cases it is quite possible that the disease originated in a softening of the cartilage of the meatus, and not in an ob-

---

<sup>1</sup> Both of these cases have already been reported in the American Journal of Otol-ogy, Vol. II., No. 1.

structed and inflamed ceruminous or sebaceous gland. Or a simple furuncular inflammation may have developed in a meatus whose cartilaginous framework was already the seat of a circumscribed area of softening; the resulting pathological changes being more extensive and permanent than if the process had been strictly furuncular in character. The possibility of such a concurrence of different pathological processes was suggested to my mind recently upon seeing a case of acute circumscribed inflammation of the external auditory canal in an individual whose auricle (of the same side) was the seat of quite a deep, circular ulcer of only a few weeks' standing. In the absence of any other satisfactory explanation of the origin of this ulcer, I was strongly disposed to look upon it, as well as upon the more recent circumscribed inflammation in the cartilaginous portion of the auditory canal, as having originated in a genuine though limited chondromalacosis. This case, unfortunately, passed from under my observation as soon as the pain had been relieved, and I am therefore unable to say whether any permanent deformity of the canal remained after the subsidence of the inflammation or not.

Some authors mention the occurrence of furuncles in the osseous portion of the auditory canal, and also speak of the extension of a furuncular inflammation from the cartilaginous to the osseous portion of the canal, and even to the membrana tympani and middle ear. I have occasionally seen abscesses develop in the cartilaginous portion of the auditory canal as a complication of a diffuse inflammation of the osseous portion of the same canal; but I have never seen a case in which I could say, with any degree of confidence, that a genuine primary furuncular inflammation of the cartilaginous portion of the canal had extended to the osseous portion—*i.e.*, had produced in this part any changes that were at all worthy the name of inflammation. I have also never seen a case of primary furuncular inflammation in the osseous portion of the auditory canal. I have seen abscesses in this part of the ear, but their pathology is so intimately bound up with that of acute and chronic purulent inflammation of the middle ear that I prefer to speak of them under those headings. Furthermore, the term furuncle is scarcely appropriate for abscesses like these.

*Diagnosis.*—In a simple uncomplicated case of acute circumscribed inflammation of the external auditory canal, no difficulty whatever should be experienced in making a diagnosis. In the first place, the development of pain in the ear, without deafness and tinnitus, would naturally lead us to locate the inflammation outside of the middle ear. In the second place, the existence of more or less tenderness on pressure externally would strengthen this belief, especially if the pain had developed recently in an ear that had always before been healthy. Finally, an examination with the speculum and reflected light could hardly fail to remove the last doubt that might remain in our minds with regard to the nature of the affection.

So much for the uncomplicated cases of primary acute circumscribed



inflammation of the external auditory canal. The questions, however, which we are sometimes called upon to solve in complicated cases of acute circumscribed inflammation of the auditory canal, may be far more difficult. Thus, for example, an inflammation of the middle ear may terminate in, or be associated with, a periostitis of the bony portion of the canal. A circumscribed collection of pus may eventually form at the junction of the cartilaginous and osseous portions of the canal, or perhaps even in the cartilaginous portion. If the physician has the opportunity of seeing such a case in its earlier stages, and can watch its progress from day to day, he will experience no difficulty in interpreting the circumscribed swelling correctly. If such a case, however, is seen for the first time only after the swelling has attained such a size as to obstruct the view of the deeper parts of the canal, he may find it a difficult matter to determine correctly what has been the chain of events, and therefore what is the true significance of the tumor. In such cases a careful weighing of the history of the attack will greatly aid in confirming or correcting the impressions made upon the mind by ocular inspection. Again, a mastoid periostitis may lead to the development of an abscess in the posterior cutaneous wall of the auditory canal, not far from the external orifice. In some instances the employment of a curved probe, introduced into the artificial opening, or into that established by natural processes, reveals a limited area of denuded bone surface. In others, although the probe may not encounter exposed bone, the previous history of the case and the persistency with which the wound remains open, justify the diagnosis of a mastoid periostitis rather than that of a furuncle of the auditory canal.

The *prognosis* of an acute circumscribed inflammation (furuncle) of the auditory meatus is in almost all respects good. We can unhesitatingly quiet the patient's fears with regard to the preservation of his hearing. So far also as my observation extends, life is never endangered by this form of aural disease. On the other hand, we cannot assure the patient that a second or even a third furuncle will not soon develop in the same ear.

*Treatment.*—If it be admitted that neither the patient's life nor his hearing power is threatened by the disease, the chief indication will clearly be to relieve his suffering. It is a disputed point how this may best be accomplished. Some of the best authorities unhesitatingly give the preference to incisions. Von Troeltsch says: "I am in the habit of incising furuncles at the earliest moment practicable, and do not even wait until it is reasonably certain that pus has formed. The earlier the knife is used the better."<sup>1</sup> Roosa says: "The proper treatment is to make an incision at as early a period as possible, and then to continuously apply warm water, giving the ear an uninterrupted warm bath, as it were. It makes no difference whether pus or blood be evacuated by the incision. The relief following is

<sup>1</sup> Lehrbuch der Ohrenheilkunde. Würzburg, 1868. S. 88.

generally immediate in either case.”<sup>1</sup> Burnett says: “The knife is the quickest and surest way of escape from the pain of these furuncles in the auditory canal.”<sup>2</sup> Hinton says: “In furuncles, as the rule, a free incision by a curved bistoury is always desirable.”<sup>3</sup> Dalby says: “The whole meatus is so swollen that it is not possible to see the position of the abscess with a speculum. This point having been distinctly localized, the sooner an incision is made into it the better, as by this the tension of the parts, to which the agonizing pain is due, is relieved.”<sup>4</sup> Keene says: “The greatest benefit will, however, be afforded in severe cases by an early incision, which should be made as soon as the situation of the furuncle can be discovered by circumscribed redness, swelling, or tenderness.”<sup>5</sup> With such a weight of authority in favor of the operation, the surgeon would certainly be justified in drawing the conclusion that in acute circumscribed inflammation of the external auditory canal, a free and deep incision through the tissues most intensely inflamed is almost certain to afford speedy relief from pain, and check the further progress of the inflammation. Furthermore, the certainty of relief which characterizes deep incisions in cases of whitlow is also very apt to occur to his mind in this connection, and confirm him in his decision to trust to the knife. Although for several years past I have not been able to satisfy myself fully with regard to the value of incisions in the class of cases we are now considering, I have been conscious of an increasing lack of confidence in their efficacy. As each new case presented itself, I have asked myself the question: Shall I incise the swollen meatus, or not? Influenced by the fear that the inflammation might extend and do some permanent damage, I have nearly always decided the question in the affirmative. Quite recently, however, I looked through my records of cases for the purpose of ascertaining how far I was justified in attaching any value to this possibility of damage, and found that in not a single instance had an acute circumscribed inflammation of the external auditory canal led to really serious results. The only question, then, that we should consider in this connection is, whether or not incisions afford such certain and decided relief that we can confidently urge the patient to submit to the pain of the operation. My own experience justifies me in saying that the knife very often disappoints us in cases of acute circumscribed inflammation of the auditory canal; the pain being relieved only for a short time, and the duration of the disease not being materially shortened. Some of the earlier writers on otology seem also to have held the same opinion with regard to the comparatively small value of incisions in this class of cases. Thus, for example, Erhardt

<sup>1</sup> A Practical Treatise on the Diseases of the Ear. New York, 1873. P. 130.

<sup>2</sup> The Ear: its Anatomy, Physiology, and Diseases. Philadelphia, 1877. P. 261.

<sup>3</sup> The Questions of Aural Surgery. London, 1874. P. 95.

<sup>4</sup> Lectures on Diseases and Injuries of the Ear. London, 1873. P. 26.

<sup>5</sup> The Causes and Treatment of Deafness. London, 1873.

says: "It is decidedly better to allow the abscess to open by natural processes than to accomplish this end by surgical interference."<sup>1</sup> Bonnafont says: "In private practice the use of the knife always frightens the patient; and unless the case is a very urgent one, and the patient himself is desirous to have the incision made, it is much better to allow the abscess to open of itself."<sup>2</sup> Finally, Wilde says: "As soon as we believe matter has formed and come some way to the surface, but not till then, we should make an incision."<sup>3</sup>

If we seek for the reasons why incisions are so uniformly successful in cases of whitlow, and so uncertain in their effects in acute circumscribed inflammation of the auditory canal, we shall find that the chief and perhaps the only reason lies in the fact that the anatomical relations of the two parts are wholly different. In the case of the finger, the incision is at once followed by a certain amount of gaping of the wound; there is complete relaxation of the parts. In the case of the auditory canal, a comparatively unyielding cylinder of cartilage surrounds the inflamed tissues and renders relaxation of the parts almost an impossibility.

This question with regard to the employment of incisions in cases of acute circumscribed inflammation of the auditory canal cannot, it seems to me, be settled by laying down any well-defined rules. In a general way, however, I might state the case thus: 1. If the patient has been in suffering for three or four days, and if local bloodletting or hot applications have failed to relieve the pain, we may with propriety urge upon him the advisability of having the swollen canal lanced; and particularly so if the appearance of the inflamed part indicates that a collection of pus has already formed. 2. If the patient has been in suffering only a short time (one or two days), and especially if the swelling is so general that we cannot locate accurately the spot where pus is probably forming, it is better not to make an incision. 3. If doubt exists with regard to what course we should pursue, and if the patient shows a disinclination to be cut, his wish should decide the question of an operation in the negative.

The best form of knife for incising furuncles in the meatus is a curved, sharp-pointed bistoury. If the swelling is well-defined, the incision should be made through the centre of it, the point of the knife being carried from within outward. The operation should be performed under illumination from the forehead-mirror, and the incision should be made of such a length and depth as will afford a free exit to the pus. If the swelling is not well defined, my plan is to introduce a cotton-holder, well protected with cotton, into the swollen canal, and then to exert pressure in different directions. The region of greatest tenderness is that into which I make the incision. It is

<sup>1</sup> Vorträge über die Krankheiten des Ohres. Leipzig, 1875. S. 160.

<sup>2</sup> Traité théorique et pratique des maladies de l'oreille. Paris, 1873. P. 188.

<sup>3</sup> Practical Observations on Aural Surgery. Philadelphia, 1873. P. 192.

well to have at hand a large sponge and a basin filled with hot water. Immediately after the incision has been made, the hot and moist sponge should be held against the ear, for the purpose of quieting the pain, which for a few minutes is generally very acute. When the pain subsides, dry warmth may be substituted for the hot and moist application. The only objection to the prolonged use of moist heat under these circumstances is, that it favors the development of granulation-tissue in the wound.

If it be thought best not to incise the inflamed meatus, we may trust to the employment of either moist or dry heat. Of the different methods of applying moist heat to the external auditory canal, I am disposed to give the preference to the hot douche, as by means of it we can bring the heat and moisture more directly in contact with the inflamed region than by any other method. Poultices are heavy and difficult to manage, but they certainly retain their heat a longer time than do any of the other substitutes. A pad, consisting of several thicknesses of soft flannel, and wrung out of hot water, makes a very light and agreeable substitute for a poultice. After it has been laid upon the ear, it should be covered over first with a piece of oiled silk, and then with a folded towel or another piece of dry flannel. A hop pillow, made of soft flannel and filled with dried hops, is preferred by some physicians to any other form of poultice, in painful affections of the ear. The pillow is to be steeped in hot water (or vinegar and water, as some prefer), and then wrung out with the hands until it is simply moist. Some patients dislike the odor of the hops, and, when this is found to be the case, the latter may be removed from the flannel bag and sponges substituted for them. All these different forms of poultices or moist applications require to be changed frequently, as they lose their heat rapidly.

Circumstances may be such that hot water cannot readily be obtained, or the patient may dislike moist applications. In such cases dry heat will often be found efficacious in relieving the pain. A flannel bag, filled loosely with rock-salt or bran, and heated to the proper temperature, answers the desired purpose very well. Two such bags are better than one; for while one is being used, the other may remain in the oven, ready for use as soon as the first one shall have lost its heat. In case of necessity, an ordinary kerosene lamp may be used to supply the requisite heat. With some rather stout wire a suitable frame can readily be extemporized, and upon this a tin pie-plate is to be placed, at a height of six or eight inches above the top of the lamp-chimney. After the bag of bran or salt has been placed upon the plate, a second plate may be laid upside down upon the first one, for the purpose of retaining as much of the heat as possible in this rude oven. Some patients who have tried both kinds of hot applications, the moist and the dry, express a decided preference for the latter.

I have had no experience whatever with the local use of anodynes in cases of acute circumscribed inflammation of the auditory canal. They may

possibly afford some relief, but I have never felt disposed to administer them in this manner. The introduction of glycerine, sweet-oil, or almond-oil commends itself still less to my judgment. Glycerine is by no means a bland and soothing fluid, and the oils may furnish a nidus for the subsequent development of the *penicilium glaucum*, or some other variety of fungous growth, which the surgeon may find it very difficult to get rid of.

Local bloodletting by means of leeches is very apt to disappoint us in cases of acute circumscribed inflammation of the auditory canal. In some instances it even aggravates the pain. I have never applied at one time more than seven leeches, and then only in full-blooded, vigorous individuals. If only three leeches are used, they may all be applied in front of the ear, viz., two in front of the tragus, and one in front of the incisura intertragica. If more than three are used, it is better to apply the additional ones behind the ear, close to the angle where the skin is reflected from the auricle upon the mastoid process, and at points below the level of the orifice of the external auditory canal. If the patient's condition does not contraindicate it, I usually allow the after-bleeding to continue for at least half an hour. I then endeavor to arrest the bleeding by means of cotton-wool and direct pressure upon the bleeding-point ; or, if this fails after a fair trial, I resort to the use of styptic cotton. If the application of the leeches is left to a nurse or to some member of the patient's family, the precaution should be taken to mark with pen and ink the spots where the leeches are to be applied, as otherwise we shall be likely to find, at our next visit to the patient, that they have been applied at points so remote from the canal that no benefit could reasonably be expected from the procedure. Glass leech-tubes will be found invaluable as a means of compelling the leeches to bite at certain fixed points.

In addition to the local treatment, some general measures will almost always be found advantageous in this form of ear disease. Thus, for example, it is very often observed that these furuncles develop in persons who are run down in health, or who have been indulging in all sorts of dissipation, or who have been subjected to prolonged mental anxiety. These errors should be corrected by the patient, and, in addition, it will be found advantageous to prescribe quinine or some preparation of bark. In some cases iron may also be prescribed to advantage.

In a few cases, a small ulcerated cavity or excavation remains for some time after the abscess has broken and after all the acute symptoms have passed away. The only symptom that it produces is a slight discharge. In one or two instances I should probably have overlooked the small orifice of the cavity entirely, had I not searched for it with a bent probe, and had I not also known, from previous examinations, that in a particular part of the canal an abscess had recently broken. It is more common, however, to find a mass of granulation-tissue, of variable size, at the mouth of the cavity. In the former case, a single light cauterization of the cavity with a bead of

nitrate of silver, fused on the end of a bent probe, usually causes it to heal up completely. In the latter case, it is better first to remove the granulation-tissue growth with Blake's snare. In two or three instances I have found the stimulus of the nitrate of silver insufficient to produce the desired effect, and have then succeeded perfectly in causing the cavity to heal by employing pure nitric acid instead of nitrate of silver. I use for this purpose a slender silver probe with a platinum tip, and wind a little cotton-wool around the end before dipping it into the acid. The pain resulting from such an application is of very short duration.

#### ACUTE AND CHRONIC DIFFUSE INFLAMMATION.

(Otitis externa diffusa. Periostitis. Eczema. Otomycosis.)

It may seem strange to some that I should group these apparently different conditions under one head. My reasons for doing so are simply these. While in certain cases I may be able to say, with some degree of positiveness: this is a case of acute periostitis of the osseous portion of the auditory canal; or that is a case of chronic eczema of the meatus,—in the great majority I find it impossible to make a positive diagnosis.<sup>1</sup> Simple ocular inspection does not furnish all the evidence required, and we are obliged to fall back upon the patient's own statements with regard to the causes which produced the disease, the time when it began, the course which it pursued, etc. Such statements, however, are exceedingly untrustworthy, and we are therefore often compelled to abstain from making an accurate diagnosis until sufficient time has elapsed to clear up some of the doubtful points. The most we can do under such circumstances is to rest satisfied with the diagnosis of an inflammation of the osseous portion of the auditory canal. So far as the patient's interests are concerned,—*i.e.*, so far as the treatment is concerned,—it really makes very little difference whether we succeed, or not, in making a more accurate diagnosis than this.

*Etiology and pathology.*—Primary diffuse inflammation of the osseous portion of the auditory canal is a disease peculiar to adult life. I do not remember to have observed it in an individual younger than eighteen. This diffuse form of inflammation, unlike the circumscribed form in the cartilaginous portion of the canal, can hardly be looked upon as an indication of overwork, of malarial poisoning, or of a poor general state of health.

---

<sup>1</sup> These remarks apply wholly to pathological processes involving chiefly the osseous portion of the external auditory canal. An eczema which does not extend inward beyond the limits of the cartilaginous portion may very properly be considered as an eczema of a part of the auricle. At all events this is the disposition which it has seemed best to me to make of the subject.

On the contrary, I have observed it so frequently in men and women of stout habit, all of whom were at the same time rather high livers, that I am disposed to hold the view that excessive eating and drinking stand in a causal relation to this particular disease. I think Hinton must have had this very class of cases in mind when he wrote the following: "I also think that there is no form in which a gouty affection of the ear is so clearly marked as in a peculiar obstinate irritability of the meatus, attended with slight serous or sticky discharge, with itching and pricking pain, the walls being somewhat swollen, with a tendency to purple in their redness. In these cases the membrane also is congested, but the structures of the tympanum may apparently scarcely be involved."<sup>1</sup> In the cases which have come under my observation I have not been able to establish the existence of a gouty diathesis. Bathing in salt water is often mentioned as an exciting cause. In rare instances the patient attributes the attack to exposure to cold while he was in a heated condition.

In very many cases this form of disease is found associated with an eczema of the auricle or of the cartilaginous portion of the meatus, or the physical conditions observed in the osseous portion of the canal are precisely the same as those observed in an eczema of the auricle. In these cases it certainly seems as if it would be proper to designate the disease as an eczema of the osseous portion of the external auditory canal. But these cases which are associated with an easily recognized eczema of some neighboring part of the skin, look precisely like those in which no such diagnostic clew exists. Owing to these difficulties in drawing a satisfactory distinction between the different cases, I decidedly prefer to apply to them all indifferently the term *diffuse inflammation of the auditory canal*.

*Symptomatology.*—I am quite confident that I should fail if I were to attempt a description of the symptoms which characterize a diffuse inflammation of the external auditory canal (osseous portion). This description might be quite truthful for some one particular case, but for all the others it would be inaccurate. The better plan, it seems to me, is to describe a few typical cases, and then to call attention to the salient points of these. I warn my readers, however, that these typical cases, although valuable because they furnish proof that the disease in question may have an independent existence, are in reality quite exceptional. In actual practice they must expect to find the great majority of cases so complicated that the statement of the correct anatomical diagnosis would require a comparatively long description. No short title, such as will be found at the beginning of this or other chapters of this treatise, would be likely to convey to the mind of any person who might read it, more than a very crude conception of the pathological picture presented. It is often a very difficult task for the physician to acquire a clear conception of the actual sequence of

---

<sup>1</sup> The Questions of Aural Surgery. London. 1874. P. 93.

events in any given case of ear-disease ; and this is particularly true of the form which I am now endeavoring to describe.

Now and then we have the opportunity of seeing a case of primary inflammation of the skin lining the osseous portion of the external auditory canal, which is so free from complications that we can no longer doubt the existence of such an independent form of aural disease. The following case is one in point : The patient, a lady, twenty-two years of age, and in a fair general condition of health, stated that four days previously she had experienced quite a sharp pain in both ears. From that time forward she had suffered more or less with pain, but there had been no discharge and only a little deafness and tinnitus. On examination, it was found that the inner half of the canal, on both sides, was red, swollen, and covered with a pasty material consisting chiefly of epithelium. The membrana tympani on both sides was also red and swollen, but chiefly so on the right side. There was tenderness on pressure over both mastoid processes. There was no appreciable impairment of the hearing for ordinary conversation, and the watch, which at first could be heard at a distance of only one inch, was heard at a distance of at least six inches after the pasty epithelium and pus had been removed from the canal. There were no evidences whatever of an acute nasal or naso-pharyngeal catarrh, or of an external eczema, and the patient did not give any history of exposure to cold. The posterior half of the right membrana tympani was incised, but the middle ear was found to be quite free from secretion. Two leeches applied behind each ear, and the frequent use of the hot douche, speedily removed all the pain, and in the course of a few days the parts returned to their natural condition.

So far as the appearances presented to the eye are concerned, this case might perfectly well have been interpreted as one of primary acute inflammation of the middle ear, with secondary inflammation of the contiguous lining membrane of the osseous portion of the auditory canal. The correctness of this diagnosis, however, is rendered improbable by the following considerations : An acute inflammation of the middle ear, of sufficient severity to seriously involve the osseous portion of the auditory canal in the short space of four days, would certainly have been associated with more decided impairment of the hearing, with a more highly swollen and vascular condition of the tympanic mucous membrane, or with a free exudation into the cavity of the middle ear. In the absence of these conditions it seems perfectly proper to classify the case as one of a primary acute inflammation of the skin and periosteum of the osseous portion of the external auditory canal. The inflammation of the cutaneous surface of the membrana tympani is an almost inseparable accompaniment of such an otitis externa diffusa. In a few cases, however, I have found the drum-membrane so little involved that, after I had wiped away the secretion which covered it, and which came from the inflamed lining of the neighboring



walls of the canal, it presented only very trifling evidences of inflammation. I have observed this non-participation of the membrana tympani more particularly in those cases which were apparently eczematous in their nature.

I may mention in this connection a second case of diffuse inflammation of the osseous portion of the meatus. The patient, a physician, thirty-two years of age, and in fair general health, stated that for a period of several months previous to the time at which I first saw him, he had been troubled with a serous or sero-purulent discharge from both ears, associated at times with pain. Occasionally the discharge ceased for several days or even weeks at a time. He had tried different plans of treatment, but they had all failed to give the desired relief. On examination, I found both auricles perfectly natural, and both external orifices free from any evidence of irritation. The hearing was not appreciably affected, either for the ticking of a watch or for conversation. The osseous portion of the auditory canal was found, on both sides, to be moderately swollen and congested, and covered with a pasty, whitish secretion. The peripheral and manubrial portions of both drum-membranes were moderately congested. The only treatment attempted consisted in the application of a strong solution of nitrate of silver (gr. 120— $\bar{3}$  i.) to the inflamed walls of the canal, two or three times a week. A few such applications were made, but without producing any material benefit. Four months later I saw the patient again, and learned that he had had in succession, at short intervals, at least a dozen abscesses in both canals. He expressed himself as feeling very much discouraged about the condition of his ears. Everything else having failed, I suggested to him the idea of smearing the inflamed canal with Hebra's diachylon ointment, at regular intervals of time. Five months later still, he reported the speedy and entire success of the therapeutic measure suggested.

In this case there was not the slightest evidence to show that the affection was eczematous in its nature, and yet the remedy which finally accomplished a rapid and permanent cure, was one that is almost considered a specific in eczema of other parts of the body. From this circumstance alone, however, we should certainly not be justified in drawing the inference that the disease was eczematous in its nature. The following case also furnishes a good example of an otitis externa diffusa, with only slight implication of the dermoid layer of the membrana tympani.

The patient, a lady, about twenty years of age, and in excellent general condition, consulted me in July, 1871, on account of a constant watery discharge from both ears. She said that during the previous month of March she had passed through an attack of scarlet fever, and that during convalescence she had experienced pain in both ears, followed by a watery discharge which had continued ever since. There had been no pain, no deafness, and no tinnitus. Once or twice the discharge had ceased entirely for a few days. On examination, I found the inner half of the meatus, on both sides, reduced in size by the swollen condition of its lining membrane.

The latter was also moderately red. The manubrial and peripheral portions of the membrana tympani were congested, and the intervening portions presented a soaked and opaque appearance. There was very little fluid in the canals—barely enough to moisten them. The ticking of a watch was heard at a distance of four feet, on both sides. The Eustachian tubes were freely pervious to air, and there was no noticeable catarrhal irritation of the naso-pharynx. Instillations of a solution of sulphate of zinc were prescribed. Four weeks later the patient returned to the city and reported that the discharge had rather increased than diminished under the treatment which I had advised. On examination, I found that no material change had taken place in the condition of the canals. I carefully wiped away all moisture from the inflamed surfaces and then filled the canal with a strong solution of nitrate of silver (120 grains to the ounce), the patient's head being turned well over toward the opposite side. As soon as she felt a distinct sensation of warmth in the ear, I removed the solution from the meatus by syringing it out with warm water. Both canals were treated in this manner. Two weeks later I saw the patient for the third time. No discharge whatever had been observed by her during the interval, and the ears then felt perfectly natural in every respect.

On the 11th of September, 1878,—that is, seven years later,—she again came to see me with regard to her ears. According to her statement, there had been a discharge from both canals since the early part of the preceding July. There had been no deafness, and the parts presented very nearly the same appearance as they did seven years previously. After drying the canals thoroughly, I applied powdered iodoform to the inflamed surfaces, and instructed the patient not to syringe the ears unless a discharge showed itself at the outer orifice. On the 14th I found the ears in precisely the same condition as on the 11th, and the patient had not observed any diminution in the activity of the discharge. I again dried the canals, and applied powdered burned alum instead of iodoform. On September 20th, very little, if any, improvement having taken place in the meantime, I mopped out the inner half of each canal with a saturated solution of nitrate of silver; the parts being kept thoroughly moistened with the solution until a distinct sensation of warmth was experienced by the patient. On the 25th of September, I found the walls of the canals and the drum-membranes perfectly dry and free from noticeable redness.

On the 25th of October she came again to see me, as her ears felt full and the discharge had returned. I again used the saturated solution of nitrate of silver, but allowed it to remain longer (about five minutes) in contact with the inflamed parts. Three days later she reported that she had experienced some pain after the last application of the silver solution, but that on the following day her ears had again felt quite natural, and the discharge had not returned since. From that time to the present (January, 1880) I have not seen the patient, and believe that I am justified in assuming

that she has remained free from active irritation in her ears during this comparatively long interval.

In a fourth case, which came under my observation quite recently, the eczematous nature of the affection was very plainly indicated. The patient, a girl, eighteen years of age, stated that for nearly a year she had had an intermittent discharge from both ears. On examination, I found both auricles noticeably red and covered with crusts. The canals were filled with pus and flakes of epidermis, in about equal proportion. The walls, however, showed very slight evidences of active irritation. The drum-membranes also showed merely a soaked and opaque appearance, but no marked swelling, such as we should have a right to expect if they had participated actively in the inflammation. The discharge seemed to come chiefly from the walls of the osseous portion of the meatus. The hearing, after the pus had been removed from the canals, was found to be quite good, both for the watch and for spoken words. The results of treatment may be briefly stated as follows: at the end of seven days, under the use of oil of Cade (3 i.) and vaseline (3 vij.), the auricles presented as natural an appearance as if they had never been covered with repulsive masses of crusts. At the end of four weeks, the discharge from the auditory canals was still as active as ever, and the patient's faith in an ultimate cure had so nearly vanished that she was unwilling to submit to further treatment. Insufflations of powdered burned alum and of iodoform failed to exert the slightest influence upon the activity of the discharge. Twice the affected parts, the drum-membrane included, were painted thoroughly with acetum cantharidis, but it also seemed to exert no restraining influence upon the activity of the discharge, and—what was stranger still—did not even produce the stinging sensation, or sensation of warmth, which it almost invariably produces when applied to the auricle. On two or three occasions I succeeded in arresting the discharge entirely for several days at a time, by employing a strong solution (120 grains to the ounce) of nitrate of silver. The last time, however, I employed a saturated solution, and allowed it to remain in the canal for several minutes. It failed, not only to arrest the discharge, but even to produce the customary sensation of warmth in the ear. As already stated, the patient at this stage became discouraged, and discontinued her visits.

These cases illustrate sufficiently the symptomatology and course of the more typical cases of acute and chronic diffuse inflammation of the external auditory canal. The primary acute cases are comparatively rare; on the other hand, acute exacerbations of the chronic form of the disease are often seen in aural practice, and are very apt to be associated with abscesses of the cartilaginous portion of the canal. This latter complication requires no further consideration in this place. There is another complication, however, which must be discussed at greater length. I refer to the growth of the different varieties of *aspergillus* in the inflamed canal. In this con-

nection I may say that I agree entirely with those authorities who consider the presence and growth of this vegetable parasite in the auditory canal or middle ear as simply an accidental complication, and not as an independent cause of disease in either of these localities. The diffuse inflammation of the canal or the chronic inflammation of the middle ear, especially if a large perforation in the membrana tympani leaves this cavity unnaturally exposed to the air, supplies a soil suitable for the growth of the sporules or germs with which the air is everywhere and at all times filled. An ear in a state of active secretion of pus, or other fluid, is not likely to furnish more than a momentary lodgment to these germs. The character of the fluid secreted also probably has much to do with their development; certain secretions being better suited for their growth than others. The cases in which the parasitic growth is most frequently observed are precisely these cases of diffuse inflammation of the osseous portion of the auditory canal. In the early stages of this disease the red and swollen skin lining the osseous portion of the meatus, and covering the outer surface of the membrana tympani, secretes just enough fluid to keep the parts moist, but not enough to give rise to a current. The conditions supplied here—moisture, absence of motion either in the fluid or in the surrounding air, and possibly darkness—are eminently favorable to the further development of the aspergillus germs. On two or three occasions I have had the good fortune to examine the ear just at the stage in which the fungus had reached its full aerial development. This happened in the following case: The patient, a female, thirty-five years of age, stated that about four weeks previously she noticed a sensation of fulness in the right ear, and, supposing that it was due to the presence of hardened wax, she dropped some sweet-oil into the meatus for the purpose of softening it. In the course of a few days she experienced a little pain in the affected ear, and again quite frequently during the following three weeks, but at no time was there any discharge. At the time I saw her, the hearing for the watch was reduced to  $\frac{4}{7\frac{1}{2}}$ . On examination with the speculum and reflected light, the outer half of the meatus was found to be perfectly normal. The lower half of the drum-membrane and the lower wall of the osseous portion of the canal were covered with a continuous, white, fuzzy material, which looked very much like cotton-wool. Here and there the whitish surface was dotted with small black specks. The upper portion of the membrana tympani and the rest of the osseous canal presented a red and moderately swollen appearance. Portions of the material removed from the auditory canal were examined with the microscope and found to be composed of the whitish or yellowish white variety of the fungus, intermingled with occasional specimens of the black variety.

Under the use of instillations of a weak solution of carbolic acid, the ear slowly improved, and when seen for the last time, about six weeks subsequently to her first visit, the parts had nearly returned to their normal condition.

So far as my experience goes, it is quite common to find the black and white varieties growing side by side in the same ear. The white variety usually preponderates. Beside these two commoner varieties of fungus, there are others with which I have had no personal experience. Those who are interested in the subject will find these rarer varieties fully described in a paper recently published by Dr. Charles Burnett.<sup>1</sup> In former years I made a careful search with the microscope for the fungus in every suspicious case. Perhaps once in five or six times I was successful in finding the parasite; but, as the discovery never materially altered my plan of treatment, and as the searches consumed a great deal of time, I soon abandoned the practice altogether.

*Diagnosis.*—There is no difficulty whatever in recognizing the red, swollen, and perhaps moist condition of the osseous portion of the auditory canal. We can then say positively that a diffuse otitis externa exists. If the drum-membrane presents at the same time a normal or at least a non-inflamed condition, we can, with considerable confidence, make the diagnosis of a *primary* inflammation of the osseous portion of the canal. The question of its *acute* or *chronic* nature can only be determined after we have heard the history of the case; and even then we may readily be misled, as patients are often not aware of the existence of a chronic subacute otitis externa diffusa until their attention is called to it by the pain or sense of fulness caused by an acute exacerbation of the inflammation. The point, however, around which the greatest interest centres, relates to the condition of the middle ear in many of these cases. The drum-membrane being red and swollen, we naturally ask ourselves the question: Is the diffuse inflammation of the auditory canal merely an extension of that which is apparently going on in the middle ear? or, Is the membrana tympani, by virtue of the intimate relations existing between its outer layer and the skin of the osseous portion of the canal, involved secondarily in an inflammation which really began in this latter region? This question, as I have already stated, cannot be determined by inspection alone. We must test the hearing, examine the condition of the naso-pharyngeal mucous membrane, and ascertain, by auscultation, during the act of inflation, the condition of the middle ear and Eustachian tube. If there is comparatively little disturbance of the hearing, if there is no evidence of an acute naso-pharyngeal catarrh, and if the air enters the tympanic cavity freely and without râles or crackling sounds, we are fairly justified in pronouncing the disease an acute primary diffuse inflammation of the external auditory canal.

The presence of aspergillus can only be determined positively by placing some of the suspected products under the microscope, and demonstrating the presence of the stalks, and perhaps also of the fruit, of the parasitic plant.

---

<sup>1</sup> American Journal of Otology, Vol. I., No. 2. New York, 1879.

*Prognosis.*—The different forms of diffuse inflammation of the auditory canal have very little tendency to damage the hearing, and apparently none whatever to spread toward the middle ear or mastoid cells. By direct extension it may excite a subacute mastoid periostitis. It is very apt also to occasion, or be associated with, furuncles of the cartilaginous portion of the canal. In the acute cases the prospects for an early and complete cure are good; in the chronic ones, our prognosis must be guarded, as the disease is at times exceedingly stubborn, and relapses are very common.

*Treatment.*—Our treatment of this disease must vary according to the stage or condition in which the disease happens to be. Thus, for example, if pain is a prominent symptom, the warm douche will be found very effective in allaying it. Other methods of applying dry or moist heat may answer the same purpose equally well. If the pain still continues, after these measures have been fairly tried, leeches may be employed with advantage. It is rare, however, that a primary diffuse inflammation of the canal gives rise to severe pain. If the parts have begun to secrete fluid, we should resort to the use of astringents. The rules which guide me in the choice of these local remedies are very simple. Now and then I yield to the temptation to try some new remedy in the hope of obtaining better results than those which I usually obtain. Whenever I do so, however, I almost invariably meet with ill-success, and am glad to return to the few remedies with which every physician is perfectly familiar, viz., sulphate of zinc, acetate of lead, and nitrate of silver. While the pain continues, I abstain entirely from the introduction of any other fluid but water into the canal. After the pain has subsided, and moisture begins to show itself in the meatus, I sometimes use sulphate of zinc, and sometimes acetate of lead. The latter remedy, on the whole, has proved more efficient in my hands than the former. With regard to the strength of the sulphate of zinc solution, it is my practice to employ only quite weak solutions, viz., from two to five grains of the salt in one fluid ounce of water. In the case of the acetate of lead, I use either a two- or a three-grain solution, as follows:

℞.	Plumbi acetatis.....	gr. ij.
	Acid. acetic. dil.....	ʒ x.
	Aquæ.....	ʒ i.

M.

I instruct the patient to syringe out the ear as well as he can, and then to turn his head over toward the affected ear, in order to remove from the meatus any free water that might otherwise remain in it. After he has done this, he should hold his head in such a position that he can readily fill the auditory canal, by means of a dropper, with the solution which he proposes to use. It is not necessary to warm the solution beforehand, unless the bottle containing it has been standing in a very cold room or closet. I

have arbitrarily chosen five minutes as the proper length of time for the solution to remain in the ear, and instruct my patients accordingly. It is not necessary to syringe out the solution after it has remained for a sufficient length of time in the canal; it is enough to allow it to run out of itself, the head being held in the proper position. The instillations should be repeated two or three times a day, as circumstances may permit.

In the more chronic cases, and especially in those which are characterized by a rather abundant secretion of fluid, it is almost useless to employ either sulphate of zinc or acetate of lead. I have repeatedly tried powdered burned alum and iodoform in cases of this kind, but rarely with any appreciable benefit. I might almost say that I have never obtained prompt and decided results in this class of cases except by the employment of the stronger solutions of nitrate of silver. This astringent seems to possess certain properties which apparently do not belong to any other astringent; or else the properties which are common to them all are much more strongly marked in nitrate of silver than in any of the others. However this may be, it appears to me to be a well-established fact that no other drug possesses, in so high a degree as does nitrate of silver, the power of restraining, in inflamed tissues, the production of lymphoid corpuscles. In the disease which I am now considering, the best method of applying the remedy is by instillation. The physician should always make the applications himself, as a person who is not in the habit of handling solutions of nitrate of silver will be quite sure to stain the patient's neck or clothing with the remedy.<sup>1</sup> Before we introduce the solution into the thoroughly cleansed meatus, the syringe and vessel of warm water should be placed within easy reach. After the solution (not previously warmed) has been dropped into the canal, my plan is, not to leave it there for any fixed period of time, but to allow it to remain until the patient experiences a distinct sense of warmth, or a throbbing sensation, in the ear. I always ask the patient beforehand to direct his attention to the ear, and to notify me as soon as he perceives either of the sensations referred to. With a solution of only sixty grains to the ounce, the sensation of warmth will generally not be felt by the patient until after the lapse of three or four minutes; with a solution of double or treble that strength, the sensation is usually experienced much sooner. As soon as decided warmth, throbbing, or perhaps even a little pain, is felt by the patient, I proceed to syringe out the solution with tepid water. Very often a single such application of the nitrate of silver will be found sufficient to arrest the discharge completely. In other cases several applications will be found necessary. While I am not aware that there is any serious objection to the daily employment of these strong solutions, I have followed the practice of making such applica-

---

<sup>1</sup> While the stains are fresh, it is easy to remove them with potassic cyanide, or even, in some cases, with potassic iodide.

tions only on alternate days, assuming that it is better not to interfere with the inflamed parts too frequently. If the discharge is quite active, the patient should be instructed to syringe out or douche the ear with tepid water once or twice a day.

If these measures fail, we may try the plan of smearing the canal with Hebra's diachylon ointment, or, better still, with the oil of Cade and vaseline mixture, or the patient may be put upon a course of internal treatment with Fowler's solution of arsenic. I have had too little experience, however, with the latter plan of treatment, in cases of diffuse inflammation of the osseous portion of the canal, to express a decided opinion with regard to its efficacy. In a single case I have known beneficial effects to follow a prolonged radical change in the patient's diet and mode of life. To prescribe such a radical change, however, to a person who has been accustomed to rather high living, and who experiences comparatively trifling annoyance from his chronic diffuse otitis externa, would probably appear to him like suggesting the substitution of a greater for a lesser evil.

Finally, it is necessary to consider the question how far we should modify our treatment when we discover that a diffuse otitis externa is complicated by aspergillus. During the early part of my practice I attached great importance to the local use of such remedies as carbolic acid, absolute alcohol, etc., in the belief that the employment of some form of parasiticide was almost absolutely essential to a speedy cure. So far as the carbolic acid was concerned, I soon found that, even in very weak solutions (two grains or even one grain to the ounce), it frequently rather added to, than diminished, the existing inflammation; and as for the alcohol, I could not satisfy myself that it possessed any special advantages as a local remedy in this disease. In one case I found that powdered iodoform seemed to act directly as a parasiticide. As this case presented other features of decided therapeutic interest, I may be permitted to narrate it briefly.

The patient, a lady, thirty-five years of age, in excellent general condition, though about six months advanced in pregnancy, stated that for a period of five or six weeks she had experienced uncomfortable sensations in the left ear, amounting at times to decided pain. During the previous twenty-four hours there had been a slight discharge from the auditory canal, and the pain had been more acute than usual. On inquiring more particularly into her mode of life, etc., I learned that she had had so many miscarriages that her physician, as soon as the fact of the present pregnancy had been established, advised her to remain quietly in her room throughout the remainder of her term. At the time I saw her, November 30, 1875, she had been confined to her room at least three months, and had not—so far as I could judge from her well-nourished condition and rather ruddy face—materially changed her previous habits of eating. On examination, I found that a furuncle occupied the upper wall of the left meatus, close to the outer orifice. The inner half of the canal and the drum-membrane



were covered with a whitish, pasty material, which I interpreted to be chiefly cast-off epidermis from the underlying inflamed skin. The membrana tympani was entire, and the ticking of the watch was heard readily at a distance of 2 feet. As the abscess had just broken, I advised no other treatment beyond the occasional use of the warm douche.

On the 14th of December she reported that the pain had not returned, but that the ear felt full and heavy. She had also noticed that the water which had been used in douching her ear was full of whitish flakes. On examination I found the deeper portion of the canal stuffed full with a whitish material, interspersed with black spots, which, on microscopic examination was found to consist partly of aspergillus (*A. flavescens* and *A. nigricans*) and partly of exfoliated epithelium. I prescribed instillations of a weak solution of carbolic acid ( $1\frac{1}{2}$  gr. to the ounce).

On the 15th of December, for reasons which are not stated in my notes, I discontinued the use of the carbolic acid solution, and mopped out the inner half of the canal with a saturated solution of nitrate of silver.

On the 17th she stated that considerable pain followed the application which I made on the 15th, but that her ear felt much better at that moment than it had for some time past. On examination I found the membrana tympani and adjacent walls of the canal covered with a dirty-looking dry crust. With the view of softening and ultimately removing this scab-like formation, I advised her to resume the use of the douche, which had been discontinued during the previous two days.

On the 19th I again found the canal almost filled with the parasitic growth. I removed it as thoroughly as possible, and then applied powdered iodoform very freely to the inflamed tissues. I also instructed the patient not to use the douche for several hours, in order that the remedy might be allowed sufficient time to exert its full curative effects.

On the 21st I found the canal more tightly packed with the fungus than on any previous occasion. I cleaned and dried it thoroughly, and again applied the powdered iodoform freely to the inflamed surfaces. This time I instructed the patient not to use the douche unless a discharge should show itself at the outer orifice, or unless the pain in the ear should become quite severe.

On the 23d the patient reported that she had experienced occasional twinges of pain in the affected ear, but had not discovered any evidences of a discharge. On examination I found the yellow powder still lying upon the drum-membrane and coating the inner end of the canal. The parts were still red and swollen, but they were perfectly dry, and not a trace of the fungus could be seen. As some of the hard, scab-like formations still remained in the canal, I ordered two or three instillations of a weak solution of bicarbonate of soda, for the purpose of softening them.

On the following morning she had quite a sharp attack of pain in the ear. Later in the day I made an examination, and found the meatus dry

and free from scabs, but decidedly more swollen. I accordingly recommended that two leeches should be applied in close proximity to the tragus. This was done, and on the following day I found her in a much better condition. The leeches had removed the last vestige of pain; there had been no discharge; she could hear the watch a distance of  $2\frac{1}{2}$  feet; and, on examination with the speculum, I found that the redness and swelling had diminished in a very marked degree. Perfect recovery followed in the course of a few days.

This case presents certain features which are of decided therapeutic interest. In the first place, the application of the saturated solution of nitrate of silver had arrested all secretion from the inflamed wall of the canal and dermoid surface of the membrana tympani. The meatus, therefore, no longer provided a suitable soil for the growth of the aspergillus. If I had paid no attention to the scab-like formations in the canal, whose presence there could certainly have done no harm, and had abstained from introducing water into it, the patient would probably have made a rapid recovery from that day forward. The douching, however, probably relaxed again the recently secreting skin of the deeper parts of the canal, and so invited a new growth of the fungus; in any event, it supplied again the moisture necessary to the development of its germs. The same mistake was also made after the first application of iodoform. Water was introduced into the canal only a few hours after the powder had been placed there, and the result was, the speedy development of the fungus a second time. The next time I used the iodoform, no water was introduced into the meatus for forty-eight hours, and inspection at that time showed a complete absence of the fungus. Water, however, was then introduced for the third time. A rather violent reaction followed, but, for some reason unknown to me, no visible growth of the fungus took place.

I have so frequently, in this form of disease, had good reasons for believing that the presence of free water, or even simply of moisture, in the auditory canal, has caused a return of the inflammation and discharge, that I now make a practice of carefully drying the meatus and the drum-membrane, and then of smearing them with vaseline and oil of Cade, before dismissing the patient from my office.

#### DESQUAMATIVE INFLAMMATION.

This form of disease differs from the other forms of diffuse inflammation of the osseous portion of the auditory canal in that its products consist almost entirely of continuous sheets of epithelium. I was formerly<sup>1</sup> disposed to consider the disease as quite distinct from that form of diffuse

---

<sup>1</sup> See an article on Desquamative Processes in the Ear, in the Medical Record of Dec. 15, 1877.

inflammation of the canal which we sometimes encounter in well-marked cases of eczema of the auricle. More recently, however, I have seen several instances of fully developed desquamative otitis externa in patients whose auricles or neighboring skin surfaces were affected with unmistakable eczema. I am therefore quite ready to admit that the disease may have some connection with eczema, or that all these different forms of diffuse inflammation of the auditory canal may be essentially one and the same disease. As a matter of convenience, however, it is advisable to keep these different varieties or types distinct in our minds, and to know them by separate names.

A certain amount of desquamation almost always takes place in every case of acute diffuse inflammation of the auditory canal. No special importance is attached to the phenomenon, and it passes for one of the regular manifestations of the disease. In those cases, however, to which the term "desquamative" should be restricted, the canal is often found tightly filled with layer upon layer of epithelium. We remove these products, and clean the canal thoroughly, but in a comparatively short time we find it again filled tightly with the same sort of laminated sheets of epithelium. Some of these cases have been under my observation now for nearly four years, but the desquamative tendency is apparently as strong to-day as it was four years ago. Furthermore, I have not observed the slightest disposition in any of these cases to change their peculiar desquamative type for one in which the secretion of pus is the predominant feature. It seems to me, therefore, that this form of diffuse inflammation of the auditory canal is better entitled to recognition as a separate disease than is any other form of diffuse inflammation of the canal.

*Etiology and symptomatology.*—This disease, in its early stages, does not seem to be accompanied by any symptoms that would be likely to call the patient's attention to the ears. At all events, I have never seen a case in which a perfectly healthy ear became the seat of changes, which I should be justified—in the light of the subsequent progress of the case—in considering as the early manifestations of this disease, and I am therefore unable to describe the conditions which characterize these earlier stages. When the canal has become filled with the exfoliated epithelium, the resulting deafness or discomfort leads the patient to consult a physician, and it is in this advanced stage, therefore, that we first see this form of disease. Occasionally we see cases of diffuse inflammation of the canal which run an acute course, and which are characterized by the exfoliation of very large quantities of epithelium in sheets of perfect whiteness. In these cases, however, the canal returns to a normal condition after the subsidence of the acute symptoms, and we can therefore hardly consider the pathological picture presented as that of a commencing (chronic) desquamative inflammation of this region. How the disease begins, and what are its exciting causes, are questions which I am unable to answer.

The simpler forms of the disease are undoubtedly of common occurrence, and will be found grouped, by many authors, among the cases of impacted cerumen. The appearances presented to the eye, before any efforts have been made to remove the obstructing mass, are very often those of impacted cerumen pure and simple. As we proceed to dissect out the mass, we find that beyond the outer layer (that nearest to the external orifice) of cerumen, lies a tough, leathery mass, composed of laminated epithelial sheets at the periphery, and of a conglomeration of dried pus, variously shaped masses of epithelium, crystals of cholesterin, cerumen, etc., in the centre. When we separate the outermost layer from the underlying skin, we find the latter in various stages of inflammation. In the milder cases, the skin will simply present a vivid red color; in the severe ones I have found even well-marked ulceration. In many of these cases the drum-membrane seems to take no part in the desquamative process, which may be confined to the outer half or two-thirds of the osseous portion of the canal, and the inner third of the cartilaginous portion. In one of the cases, of which I kept a careful record, the region of vivid redness ended quite abruptly, at a distance of about five or six millimetres from the posterior and inferior margin of the drum-membrane. In another case I found the desquamative process limited to a boat-shaped depression in the lower wall of the osseous portion of the canal. No satisfactory history could be obtained in this case, but it seemed reasonably clear that at some time in the past, probably in the man's boyhood, caries and exfoliation of quite a large portion of the lower bony wall of the canal had taken place. The chronic desquamative inflammation of the skin lining this excavation had caused the patient no pain or discomfort until the steadily increasing laminated mass of epithelium, no longer finding room for itself in the excavation, began to exert pressure. Then the patient experienced moderate pain in the ear and consulted a physician. The true condition of the parts was fully recognized, and prompt relief was afforded by dissecting the tough mass out from its bed in the bony canal. About once a year, during the past five years, this patient has experienced more or less discomfort in the ear, and has each time obtained entire relief by having the impacted mass removed. In a third case,<sup>1</sup> I saw the patient for the first time in 1875, and for the second in 1877. Both times I found the impacted masses to be composed of quite small flakes or fragments of epithelium intermingled with hardened pus. The face, neck, and hairy scalp bore unmistakable evidences of eczema. The walls of the canal, after the impacted mass had been removed, were found to be red and swollen, but comparatively smooth. The drum-membrane had apparently escaped altogether. As the impacted masses, on both the occasions mentioned, were found to consist of only small epithelial flakes, which did not show the slightest disposition to assume a

---

<sup>1</sup> Case III. in the article referred to at the beginning of this section.

laminated arrangement, and which furthermore were largely intermingled with dried pus, I was disposed to consider this case as distinctively eczematous in character, and quite different from those cases in which the desquamative process shows a disposition to produce chiefly laminæ of epithelium intermingled with very little pus. Since the publication of the article referred to, I have seen this patient twice, viz., in October, 1879, and again in January, 1880. Both times I found the laminated arrangement of the cast-off epithelium as well characterized as we ever see it. The last time I examined the ear I found that the inflammation of the canal had produced actual ulceration of the cutaneous surface, especially along the lower wall and near to the drum-membrane. I was therefore in error when I supposed that a distinction could properly be made between these two classes of cases—the eczematous and the desquamative.

I have already alluded to the fact that when the desquamative tendency becomes established, it seems to persist for a long time, and to retain its own peculiar type. The following case affords a good illustration of this fact, and also shows how the membrana tympani itself may participate in the desquamative process.<sup>1</sup> The patient, a strong, healthy sailor, consulted me at the New York Eye and Ear Infirmary, on the 23d of February, 1876. He complained of constant dizziness, and almost unbearable tinnitus in both ears "for some time past." No satisfactory information could be obtained from him with regard to the condition of his ears in previous years. The deafness was so marked that I was obliged to speak to him quite loudly in order to make myself heard. On examination both auditory canals were found to be filled with cerumen. After the removal of these masses, which were found to be composed entirely of cerumen, it was ascertained that a tough, leathery mass of laminated epithelium covered each membrana tympani to a depth of not less than one millimetre, and completely filled the recess at the lower and anterior portion of the inner end of the meatus. When touched with the probe the outer surface of the mass felt as hard and almost as smooth as parchment. The removal of these epithelial deposits was accomplished by means of the slender probe, the forceps, and the curettes; a solution of bicarbonate of soda having first been employed for the purpose of softening them and loosening their connections. The difficulty of the task was greatly increased by the circumstance that, whenever the instrument touched the wall of the osseous portion of the canal, the patient was seized with an irresistible desire to cough. This "ear cough," interfered so seriously with my manipulations that it was not until the fifth or sixth sitting that I finally succeeded in removing the last layer of epithelium. The pain caused by the manipulations also increased the difficulty which the patient experienced, of keeping his head perfectly quiet. After the removal of these masses from both ears, the drum-membrane, on

---

<sup>1</sup> Case V. in the article published in the Medical Record.

on each side, was found to be red, somewhat thickened, and adherent in its central portion to the opposite promontory. The neighboring walls of the canal also presented an inflamed appearance, but no recognizable ulceration or inequalities of the surface. The dizziness and distressing tinnitus were in a great measure relieved by the removal of the obstructions, and there was a little improvement in the hearing.

Since 1876 I have seen the patient twice, and both times I have found the same pathological appearances as those already described.

In a fifth case, finally, the desquamative process was allowed to go on unchecked for a long time—probably for a period of twenty years, until the bony canal which contained the laminated epithelial mass, became dilated to fully twice its normal size. After the impacted mass had been removed with considerable difficulty, the walls of the dilated portion were found to be in an ulcerated and granulating condition, with a limited area of exposed bone surface. The inner wall of this large cavity presented the appearance of a uniform granulating surface, in which not a trace of the membrana tympani, ossicles, or labyrinthine fenestræ could be distinguished. While a great deal of this damage might legitimately be looked upon as the effect of prolonged pressure exerted by a mass located in the auditory canal, it seemed to me more than probable that the original disease, out of which this desquamative affection subsequently grew, was a destructive inflammation of the middle ear. However, the patient, a woman of average intelligence and forty-one years old, was positive that she had never had a discharge from the affected ear, but admitted that, for a period of twenty years, she had experienced frequent earaches and more or less deafness in that ear.

*Diagnosis and prognosis.*—The products of this form of inflammation are so easily distinguished from pus and cerumen that an error in diagnosis can hardly occur. It is only in cases like that of the sailor (see preceding page) that some difficulty might be experienced in recognizing the true condition of things in the ear. The dry, hard, and comparatively smooth cul-de-sac at the inner end of the auditory canal would be very likely, at first sight, to be taken for a greatly thickened drum-membrane. In the case referred to, the correct interpretation of the condition observed suggested itself at once as soon as the curette had been used. At almost all points the hardened mass that occupied the inner end of the meatus passed, without any noticeable line of demarcation, into the neighboring skin of the canal. In one or two places, however, a free edge of thin cuticle indicated where the line of separation occurred. The curette was applied to these points, and, with a little cautious dissecting, the fact was ascertained that the thin, free edge of cuticle constantly grew thicker as the dissection was continued farther and farther inward. The desquamative nature of the affection was thus established beyond a reasonable doubt.

With regard to the *prognosis* of the disease, I should not be justified in

expressing any very positive opinion. The simple removal of the obstructing mass almost always affords the patient such marked relief that he does not care to submit to a course of treatment which has for its object, not the relief of a present trouble, but the prevention of a future one. My experience in the radical treatment of the disease is therefore very small, and I must limit myself to the statement that, if left to itself, the disease is quite certain to reproduce the impacted state in from two months to two or three years.

*Treatment.*—If the auditory canal is filled with laminated epithelium, dried pus, and other matters, the first step in the treatment should be to remove the impacted mass. The quickest way of accomplishing this is to dissect out the mass, or loosen its attachments with the curette, and then to extract it with the forceps, or with the curette used as a pry or shallow hook. If the mass does not form a connected whole, it must be broken down into fragments and removed piecemeal. The syringe alone, in this class of cases, will be found a very inefficient instrument. I have repeatedly seen cases where, after the syringe had been used several times in succession without success, the mass was easily removed in a few minutes by means of the curette and forceps. If the desquamated epithelium is found firmly adhering to the membrana tympani, in the form of a continuous leathery mass, it is advisable to soften it first before we make the attempt to detach it from the membrane. Strong solutions of bicarbonate of soda may be used for this purpose.

Once the impacted mass has been removed, the question confronts us, How can we prevent the canal from again becoming obstructed with a similar accumulation? or, in other words, How can we radically cure the desquamative inflammation of the auditory canal? So far as my own experience goes, I am unable to give any satisfactory answer to this question. I have obtained the best results from the daily use of the lukewarm douche, continued for a period of several weeks; but I cannot report a single instance in which, by this means, or by instillations of weak solutions of the acetate of lead, a well-marked chronic desquamative otitis externa, with intact drum-membrane, was really cured. It would be manifestly unfair, however, to pronounce the disease incurable upon the very limited experience which I have had, and yet it is hard to see how anything like an extended experience in the radical treatment of the disease is to be gained. In private practice persons whose ears feel perfectly natural, and whose hearing is fairly good, are usually not disposed to undergo a long course of treatment directed solely to the ear. In infirmary practice, it is useless to even suggest such a course of treatment.

## ULCERS, POLYPOID GROWTHS, AND CARIES.

The pathological conditions enumerated in the above title are sometimes encountered as independent affections. By this I mean, first, that ulcers and polypoid growths—and possibly also caries—may occur as genuine primary affections of the auditory canal; and second, that all three conditions, although at first simply accompaniments or sequelæ of a purulent inflammation of the middle ear, or of some other local disease, may be raised to the dignity of primary or independent diseases through the complete subsidence of the original affection. Thus, for example, no one will dispute the primary<sup>1</sup> or independent nature of syphilitic ulcers and condylomata of the auditory canal; and with regard to the occurrence of similar non-syphilitic lesions in this part of the ear, my impression is that they always represent the effects of some antecedent more general disease of either the meatus itself or of the middle ear; and as they form an essential part of those diseases, it will be more appropriate, I think, to describe them under those headings than in the present section. So far as the independent occurrence of the lesions under consideration is concerned, my entire experience is set forth in the following histories of cases.

The first case is that of a healthy boy, seventeen years of age. On the 7th of April, 1877, he consulted me for the first time, and gave the following history of his trouble. During the previous summer he had passed through an attack of typhoid fever, and while he was convalescing a large abscess developed in the right parotid region.<sup>2</sup> This abscess broke and discharged its contents through an opening in the right auditory canal. From that time to the present there had been more or less discharge from the ear, but on the whole it had been diminishing in quantity. He had experienced no deafness with it, except temporarily, when the discharge filled the canal. About three months previously he had discovered a small fragment of bone in the discharge. On examination, I found a flattened, succulent mass of granulation tissue lying on the lower and posterior wall of the canal, apparently at the junction of the osseous with the cartilaginous portion. This mass, as I ascertained by careful probing, grew from the edge of a not very deep ulcer, at the bottom of which denuded bone was readily felt. A short distance beyond, in the osseous or membranous part of the canal, a second superficial ulcer was found. At all other points the canal presented an uninfamed and natural appearance. The membrana tympani also appeared to be normal.

Treatment was commenced on the 19th of April, and on the 29th, ten days later, the larger ulcer was found to be completely healed. The poly-

---

<sup>1</sup> That is, not developed by extension from a neighboring region.

<sup>2</sup> Parotid abscesses are said to be among the very rare sequelæ of typhoid fever.



roid mass was first removed with the snare, and then the remaining raw surfaces were freely cauterized (daily) with nitrate of silver, fused upon the end of a cotton-holder. Five or six such cauterizations were made, and then the rapidly contracting ulcer was completely covered with pellets of powdered burned alum. After two or three such applications, complete cicatrization of the parts was found to have taken place. The more deeply situated, superficial ulcer, which seemed a very trifling affair in comparison with that which lay nearer to the external orifice, proved the more rebellious of the two. In fact, it had not yet entirely healed on the 29th, when the boy returned to his home in the country. A few weeks later, however, he visited me again, and I then found that this ulcer too had completely healed; no further treatment having been carried on in the meantime.

If this case could have been seen from the very beginning, it would probably have been an easy matter to trace the connection between the parotid abscess and the superficial ulcer which was situated near the drum-membrane. In all probability the abscess did not break until it had kindled an acute inflammation of the entire lower and posterior wall of the osseous meatus. The outer ulcer probably represented the spot where the rupture finally took place, and the inner one a spot where the inflammation was more severe than at other points. At the time I saw the case, however, the isolated position of this ulcer, and the absence of any evidence of inflammation of the parts lying between it and the outer ulcer, added a certain element of mystery to the case.

In the second case, which was first seen on the 20th of November, 1877, the conditions observed were even more difficult to explain. The patient, a very intelligent lady, thirty-eight years old, and in fairly good health, stated that during the previous five weeks she had experienced at times quite severe pain in the right ear. There had been no discharge, and very little disturbance of hearing, so far as general conversation was concerned. Her regular medical adviser had attributed the painful affection of the ear to impacted cerumen, and had syringed the canal very thoroughly with tepid water, but without beneficial effects. On examination, I found the orifice of the right auditory canal tender on pressure, and obstructed by the presence of a moderately large mass of granulation-tissue springing from the mouth of a recently ruptured furuncle. Beyond this fleshy mass, which I at once removed with the snare, the canal was found to be tightly plugged with a whitish mass which felt as hard as chalk. By means of the curette and forceps I was able to break down and remove piecemeal the entire mass. It presented throughout every appearance of being a chalky substance, and probably represented a calcareous transformation of pus that had first undergone cheesy degeneration. The inner end of the mass extended to within a few millimetres of the drum-membrane. After it had been entirely removed I found that the only lesion in the osseous part of the canal, beyond a moderate degree of redness and swelling, was a cir-

cumscribed ulcer, situated posteriorly and superiorly, not far from the junction of the osseous with the cartilaginous portion. On exploration with the probe, I ascertained that denuded bone surface constituted the base of the ulcer. The membrana tympani appeared to be perfectly normal.

An examination of the patient's left ear, which she had always supposed to be healthy in every respect, revealed the existence of a small, pale, succulent, polypoid mass, springing from the posterior wall of the osseous canal, close to the drum-membrane. The secretion from this mass was so scanty that no fluid could be seen in the canal except in the immediate neighborhood of the growth. Exploration with the probe showed that the polypus was simply a superficial outgrowth, not connected with any demonstrable disease of the bone. The membrana tympani appeared to be perfectly natural, and there was no appreciable redness or swelling of the walls of the canal in the vicinity of the growth.

I questioned the patient carefully with regard to the condition of her ears in the past, but could elicit no information that threw any light upon the peculiar lesions found. The pain of which she had complained during the previous five weeks was evidently due to the development of a furuncle near the outer orifice, and the mass of granulation tissue found in this location was simply the effect of continued irritation from some source or other. These lesions were clearly of comparatively recent date. The presence of the calcareous mass in the right meatus pointed clearly to a discharge of much earlier date; but it was not so easy a matter to define the location from which this discharge came. The middle ear, for instance, could safely be excluded as a source of the pus, as the patient was positive that she had never experienced any pain or discomfort in the right ear until recently, and also because the condition of the drum-membrane, as found after the chalky mass had been removed, showed no trace of any recent or former inflammation of the middle ear. The discharge, therefore, in all probability, came from the auditory canal. The patient, however, it will be remembered, stated distinctly that she had never observed a discharge from either ear. In explanation of this apparently contradictory state of things, the assumption seems almost unavoidable that in the outer portion of the canal there must have been some obstacle which prevented the escape of the pus secreted in the inner portion. Impacted cerumen would present such an obstacle, and, by greatly diminishing the rate of evaporation, which would take place in the pus, under ordinary circumstances (*i.e.*, in an unobstructed meatus), would favor its gradual accumulation and slow transformation first into a cheesy and then into a chalky mass. No cerumen, it is true, was found in the canal at the time I examined it; but it is more than probable that the thorough syringing, which the ear had received at the hands of the attending physician, had removed all that was there.

The question relating to the exact source of this assumed discharge, whether the latter came from the circumscribed ulcer described above, or

from some previous diffuse inflammation, of which this ulcer was the last remaining trace, is one which I am unable to answer. With regard to the treatment and subsequent progress of the case, there is very little of interest to communicate. Both ulcers healed slowly under the use of nitrate of silver (in the form of a bead) and (later) powdered iodoform. A dry eczema, affecting the orifices of the canals, continued for several weeks after the ulcers had healed, and then itself finally disappeared. As late as during the summer of 1879 I found both canals still quite natural in appearance.

In the foregoing cases the bony structure of the meatus was involved to only a very slight degree, and after the ulcer had healed, no irregularity of the surface remained to indicate the spot which it had recently occupied. In the following cases the disease of the bone constitutes a more prominent characteristic. In common with the case last described, however, they both were seen for the first time only after they had reached a more or less advanced stage of development. Neither the condition of the parts nor the patient's own statements furnished the slightest clew to the antecedent pathology of the disease.

The first of these cases was seen at the N. Y. Eye and Ear Infirmary on the 25th of October, 1871. The patient, a healthy man, twenty-two years of age, sought relief at the institution on account of an acute affection of the left ear. As a matter of routine, I also examined the right ear, of which the patient had made no complaint, and found the canal blocked by a large and hard plug of cerumen. After the mass had been extracted, I discovered that a ridge of bone, about two millimetres high, crossed the lower wall of the osseous canal, at right angles to its long axis, and only a short distance from the line of junction of the cartilaginous and osseous portions. Along its sides this ridge was covered with small, soft granulations. Quite firm pressure with the probe failed to break off any portion of the irregular, free edge of the ridge. The drum-membrane showed only insignificant changes, and there was simply moderate redness of the canal in the neighborhood of the carious region. The watch was heard at a distance of 6 feet. No evidences of syphilis could be found, and the patient was very positive that he had never had a discharge from the right ear, and had never experienced pain in it. (The patient was seen again only once, a few days later.)

The second case was seen on the 17th of March, 1873. The patient, a strong, healthy man, of fifty years of age, consulted me for a slight diminution in the acuteness of his hearing. On examination, I found both canals filled with cerumen. The impacted masses were removed, and the patient obtained the desired relief.

On the 23d of June he consulted me a second time, and on examination I was surprised to find that the canals were again obstructed with the same material, though in smaller quantity. The removal of the impacted masses again afforded the desired relief.

On the 26th of July the patient consulted me for the third time. The right ear, he said, had felt full, and at times he had experienced pain in it. On examination, very little cerumen was found in the outer portion of the canal, but in the immediate vicinity of the membrana tympani, there was a small mass of what appeared to be cerumen. As this mass was firmly impacted in the anterior cul-de-sac, between the drum-membrane and the wall of the canal, I instructed the patient to use instillations of a warm solution of bicarbonate of soda for two or three days, and then to let me examine the ear again. This he did, and when I afterward saw him, I found no difficulty in syringing out the accumulated material. An inspection of the canal then revealed the fact that an irregularly shaped body still occupied the extreme inner end of the meatus; part of it, in fact, seemed to be touching the membrana tympani. The free surface of this mass was made up of three or four jagged elevations, which felt like bone when they were touched with the probe. One of them was so prominent that I found no difficulty in seizing it firmly with the forceps. It was perfectly immovable, however, and there could therefore no longer be any reasonable doubt that this jagged ridge was in reality an exostosis or hyperostosis associated with a limited ulcerative process or caries; the material which I had last syringed out being in all probability hardened pus which had accumulated around the bony mass. The membrana tympani was moderately thickened and opaque, but free from all other evidences of old or recent inflammation. The ticking of the watch was heard at a distance of 2 feet on the right side, and 4 feet on the left. Careful inquiry into the patient's past history failed to throw any light upon the origin of this local caries of the meatus. The left ear was not examined.

On the 4th of September, 1874, the patient consulted me again. He said that he had experienced no unpleasant sensations in either ear until quite recently, when a slight discharge developed in both ears. On examination I found that the carious spot in the right meatus was covered with foul and cheesy pus, and that almost the same lesion existed in the left canal. In both ears the carious spot was situated on the lower wall of the meatus, close to the drum-membrane, and on both sides the spots were of about the same size.

On the 14th of November, 1876, the patient reported that during the previous summer he had experienced two or three attacks of moderately severe pain in the left ear, accompanied by a discharge of foul matter. At about the same time he had found two small fragments of bone in the discharge. The right ear had given him no trouble, though on one or two occasions he had noticed a slight discharge from it. On examination I found that the carious excavation in the left ear had increased decidedly in extent, and that a ridge of newly formed bone, about two millimetres in height, traversed the canal along the inner limit of the ulcer, and in close proximity to the membrana tympani. A very foul, dark pus covered the

region of the ulcer. On the right side no material change could be made out in the condition of the ear.

The subsequent treatment consisted simply in the regular use of the warm douche, for the purpose of removing the foul pus from the canal; the patient being unwilling to submit to any more systematic efforts to induce permanent healing of the carious spots, especially as I could not promise to him successful results.

The thought of syphilis suggested itself to my mind, as soon as I discovered that both osseous canals were symmetrically diseased; but the patient's ruddy countenance and splendid physique, his age, his high social standing, and the absence of any other evidence of constitutional syphilis, made me look upon this disease as a very improbable cause of the peculiar lesions described above. The only hypothesis which I can offer in place of the syphilitic one, is that which represents these lesions as being the sequelæ of a double otitis media that ran its course during the patient's infancy or childhood, but of which all traces had long before disappeared.

In the following case, which deserves the title of *primary caries of the osseous portion of the external auditory canal* more fully than does any case that I have ever seen, the exact pathology or mode of development of the disease is by no means clear. The patient, a healthy woman about thirty-five years of age, a member of one of the sisterhoods of the Episcopal Church in this city, consulted me on the 9th of June, 1880, for the purpose of having a "tumor" removed from the left ear. The only history that she could give was this: About three weeks previously she experienced a slight pain in the left ear, and a few hours later she noticed that there was a slight discharge from the ear. She paid very little attention to the discharge, as it was very slight and gave her no special annoyance. Two or three days before she came to see me, she noticed that her hearing had rather suddenly become impaired, and on examining the ear to ascertain what might be the cause of it, she discovered that the outer orifice was nearly closed by a red, fleshy mass. Thinking that she might have made light of the degree of pain experienced at the beginning of the disease, I questioned her very closely on this point. She was very positive, however, that she had experienced only a few twinges of pain at intervals during a part of one day, and these twinges, she said, were almost too trivial to deserve the name of pain. The hearing, so far as she knew, had always been perfect up to the time referred to above. On examination, I found the outer orifice blocked by a red, moist, firm, fleshy mass which sprang by a broad base from the lower and posterior wall of the meatus, a very short distance outside the line of junction of the cartilaginous with the osseous portion of the canal. From the firmness of the mass, from its uneven surface, from the painless manner in which it had developed, and from its rapidity of growth, I was at first disposed to consider it as a cancerous growth; but after I had cut it off flush with the level of the surrounding

healthy skin,—a procedure which caused her very little pain,—I observed that a canal ran through the centre of the tumor, from its base to its summit, and I at once abandoned the idea of a cancer. These hollow tumors, in my experience, grow only from the mouth of an abscess, be the latter simply furuncular in its nature, or of deeper origin (dependent on bone-caries). In the present case, the introduction of a curved probe revealed the existence of a limited area of exposed bone, which felt like the free outer edge of the osseous meatus. The drum-membrane and the inner half of the external auditory canal seemed to be normal, and the removal of the growth restored the hearing perfectly.

On the 20th of June, after fruitless efforts to arrest the growth by means of nitric acid, I again resorted to the use of the knife. I took this step because the fleshy mass had again nearly filled the orifice of the auditory canal, and therefore threatened to diminish the patient's hearing power during her vacation, which she was then about to take.

On the 16th of July she returned to the city, and reported that during the first two or three days of the month her ear became very much swollen, below and behind the meatus; and while it was in this condition she discovered, at the orifice of the canal, in wiping it out, a small fragment of bone. The swelling then rapidly subsided, the discharge ceased, and the ear seemed to her to return to a perfectly natural condition. The only trace of the former disease that I could find, when I examined the ear, was a small nodular cicatrix, at the spot where the granulation-tissue had previously existed.

It would be extremely interesting to know what were the precise changes that led to the limited death of the bone in this case, but unfortunately we can only speculate with regard to their nature. The almost entire absence of pain during the incipient stage of the disease, coupled with the fact that a separation was found to have taken place between the projecting end of the bone and the cartilaginous framework of the auditory canal, suggests the possibility of a change akin to chondromalacosis (see p. 46) as the starting-point of the entire series of morbid phenomena.

In all the five cases described in the present section, the lesions observed in the auditory canal presented every appearance of being primary in their nature, or, at all events, independent of any recognizable disease of the middle ear. In the following three cases, which I propose to classify as

#### *False Membranes in the Auditory Canal,*

the dependence of the lesions upon a primary disease of the middle ear, or upon the irritating presence of a foreign body, was so evident that it could scarcely escape the notice of even a superficial observer. It might there-

fore be expected that, in accordance with what I said at the beginning of this section, I should describe these conditions in the chapters relating to diseases of the middle ear. The conditions, however, to which I have reference, are seen so seldom, and possess such a decided individuality, that I prefer on the whole to describe them in the present section, in connection with the more strictly independent affections of the auditory canal.

The first case furnishes an instance of the development of a *cord-like bridge of flesh in the auditory canal*. The patient, a female, twenty-five years of age, and in good general health, presented herself for treatment at the New York Eye and Ear Infirmary, on the 30th of August, 1871. She stated that there had been a discharge from the left ear during the previous three years. On examination I found the outer orifice filled with a polypoid growth. With Blake's snare I then removed in succession four distinct polypoid masses, all of them growing from the walls of the auditory canal, and not connected, so far as I could discover, with carious bone.

On the 6th of September I saw the patient a second time, and found that the stumps of the polypi removed on the 25th of August had already markedly increased in size. I used the snare a second time, and cauterized the remaining raw surfaces with nitrate of silver.

On the 23d of September I examined the ear again and discovered that two of the stumps—situated opposite to each other, one on the upper, the other on the lower wall of the meatus—had coalesced so as to form a distinct cord-like bridge of flesh, stretching from the upper to the lower wall of the meatus. Moderate stretching of this band with the probe failed to produce a rupture, and, being anxious to see whether it would shrivel up and disappear of itself, or what would become of it, I abstained from any further interference, and simply advised the patient to syringe the ear daily with lukewarm water.

On the 4th of October I found that the fleshy band had perceptibly diminished in diameter. There was also very little discharge.

On the 6th of December I found that the discharge had ceased entirely, and that the walls of the meatus were perfectly dry. The fleshy band had diminished to the proportions of a slender cord scarcely one millimetre in diameter; and when touched with the probe it felt dry and stiff, as if it were made of parchment. The mass of granulation-tissue had undoubtedly become completely covered with epidermis, and then the process of contraction, which is common to all newly formed connective tissue as soon as suppuration ceases, had reduced its proportions to those of a slender cord.<sup>1</sup> (The patient did not subsequently return.)

In another case I had an opportunity of watching the same series of pathological changes take place on a much larger scale. The patient, a

---

<sup>1</sup> Dr. George T. Englemann, of St. Louis, has reported a very similar case in the *Archiv für Ohrenheilkunde*, Vol. VI., p. 203.

rather dull boy of twelve, was brought to the New York Eye and Ear Infirmary by his parents, on the 9th of July, 1873. Three years previously he had passed through an attack of scarlet fever, but no discharge from the ear had been noticed until a short time before his visit to the Infirmary. On examination, I found the entrance to the canal blocked by quite a large mass of granulation-tissue. The removal of this mass by means of Blake's snare brought to view a dark body, which felt hard when touched with the probe, and seemed to be tightly wedged in between the anterior and posterior walls of the canal. Steady traction, by means of a steel hook introduced flatwise between the foreign body and the upper wall of the meatus, and then turned point downward as soon as the inner end of the hard mass had been reached, brought it away entire. It proved to be a prunepit of moderate size. Neither the boy nor his parents could account for its presence in the ear. That portion of the meatus in which the greatest breadth of the pit lay seemed to be larger than the natural size, while just beyond and just this side of the dilated portion the soft parts of the canal appeared to be swollen.

Nine days later I saw the patient a second time. The inner limit of the dilated portion—corresponding to the junction of the inner and middle thirds of the osseous part of the canal—was then the seat of a ring-shaped mass of granulation-tissue, which encroached very decidedly upon the calibre of the meatus.

Sixteen days later still (August 4th), I found the calibre of the canal almost obliterated by this mass. Although the probe could still be passed through the centre of the obstructing granulations, the appearance presented was as if the calibre of the canal had been completely obliterated at this point.

During the following week three applications of chromic acid (in crystalline form) were made to the central portion of the mass. This caustic, however, set up so much inflammation that I was obliged to abandon its use. The boy was not seen again until the 2d of September. The canal was then found to be perfectly dry, and the patient said that the discharge had ceased several days previously. The ring-shaped mass of granulation-tissue had become transformed into a solid *cul-de-sac*, completely obliterating the calibre of the canal. The tissues were dry, smooth and firm, and no longer resembled granulation-tissue. In the centre of the mass, a small scab, about the size of the head of a pin, was visible. After this had been torn off, the probe could readily be pushed through to the broad part of the canal beyond.

Efforts at dilatation, by means of small laminaria bougies, were kept up during the following two or three days, but they caused considerable pain and proved of no avail. On the 28th of September fuming nitric acid was freely applied to the centre of the mass. The pain caused by this application was only moderate.



On the 4th of October I found that the acid had made quite a free opening in the mass. The application was not repeated, and yet the tissues forming the annular constriction continued to contract (centrifugally), and the calibre of the canal to enlarge, until, on the 22d of November, when I saw the boy for the last time, only a slight trace remained of the mass,—which, if it had been left to itself, would undoubtedly have formed a permanent obstruction in the canal, in the shape of a diaphragm or false membrane. The discharge, which made its appearance soon after the application of the acid, had entirely ceased. Beyond the narrowed portion of the canal, which was very near its inner limit, the membrana tympani was plainly visible. Its lower half was perforated near the centre.

The following case completes the picture which nitric acid spoiled in the preceding case :

The patient, a female, twenty-six years of age, consulted me at the New York Eye and Ear Infirmary, on December 1, 1873. She had been somewhat hard of hearing all her life. In childhood there had been a discharge from both ears, but during recent years there had not been any from the right one. In this ear the watch was heard only when pressed firmly against it. The left ear presented the ordinary appearance of an uncomplicated chronic purulent inflammation of the middle ear. An examination of the right ear revealed the following condition: the meatus was normal; at its inner end it terminated in a smooth, parchment-like membrane, of uniform but slight concavity outwardly, and looking very much like a membrana tympani from which the malleus had been removed. When tapped with the probe this membrane gave forth quite a loud sound, such as is heard when a stiff piece of parchment is bent. It appeared to be considerably thicker than the normal drum-membrane, and, at every point of the periphery, passed without the slightest break or irregularity into the skin of the auditory canal. A superficial observer might very readily, I think, have taken this strange diaphragm for the membrana tympani. Its greater proximity to the external orifice, however, and the absence of the handle of the hammer, showed almost conclusively that, notwithstanding its dry, membranous character, it was not the drum-membrane, but a new-formation of some kind.

So far as its influence upon the hearing was concerned, such a membranous diaphragm could only act as an obstacle. I therefore had no hesitation in making a free crucial incision through it. The angular flaps thus made showed very little disposition to retract. They were readily bent over toward the walls of the meatus, however, and thus a view of the deeper structures was obtained through the irregular opening. All that could be seen at that time was the red and moist mucous membrane of the promontory, situated about four or five millimetres beyond the plane of the false membrane. As an evidence of the vitality of the latter, I might mention the fact that, a very few minutes after the incisions had been made,

a glistening border of bloody serum was noticed along each of the cut edges of the angular flaps. The improvement then observed in the hearing, at least for conversation, was quite marked; for the watch, the hearing distance was increased to four inches.

At the next visit, a week later, the patient reported that there had been a constant discharge from the right ear since the day following the operation. The perforation was then circular in shape, from three to four millimetres in diameter, and through it the relations of the deeper parts could be distinctly made out. It was thus ascertained that the handle of the hammer was still entire, though adherent to and covered up at its tip by the tissues of the promontory. The short process of this ossicle could be distinctly recognized at the inner edge of the base of the false membrane.

When last seen the patient still complained of a slight muco-purulent discharge, and no marked change had taken place in the condition of the parts.

The two preceding cases each throw light upon the other. In that of the boy, for example, there can hardly be any reasonable doubt that if I had not interfered vigorously with nitric acid, a false membrane or diaphragm, similar in every respect to that which was observed in the case of the woman, would have developed at the seat of the constriction. On the other hand, had I not previously watched the peculiar behavior of the granulation-tissue in the boy's case, and also in that of the first case (p. 99), I might have experienced difficulty in explaining the presence of such a parchment-like diaphragm in the osseous portion of the auditory canal. In all three cases the different steps of the process were essentially the same. Under the stimulus of some irritating cause, granulation-tissue was produced. Two granulating surfaces met at a time when there was not a sufficient current of fluid secretion to prevent them from uniting; and they accordingly united into a single mass. The original irritating cause had by this time been withdrawn, and the absence of a free secretion of pus from the surface of the mass of granulations, opened the way for the growth of a protective covering of epithelium from the surrounding healthy skin. As soon as the mass had once become covered with skin, rapid contraction and atrophy of all the connective-tissue elements followed, until finally nothing remained but two horny epidermal layers separated from each other by a thin sheet or cord—as in the first case—of connective tissue, poorly supplied with blood-vessels, and apparently not at all furnished with sensory nerves.

The false membranes observed in the preceding cases were provided with blood-vessels and represented each an integral portion of the living body; that observed in the following case can only be looked upon in the light of something cast off and already dead, though still mechanically connected with the body.

The patient, a female, fifty years of age, consulted me in the summer of 1876, for deafness of slight degree, referable chiefly to the left ear, and of about one year's duration. Examination with the speculum and reflected light, revealed the following condition of things in the left ear: In the osseous portion of the external auditory canal, at a point about one-third of an inch from the drum-membrane, a membranous structure completely occluded the canal. To the eye, this membrane presented all the appearances of ordinary cast-off cuticle. At no point did it show any evidence of being provided with blood-vessels. When touched with the probe it yielded to the pressure in precisely the same elastic manner as would any thin membrane like the cuticle, when separated from its underlying connections. The peripheral portion of the membrane was carefully tested with the probe at all points of the circumference, for the purpose of ascertaining the nature of its attachment to the skin of the external auditory canal. At every point it was found to be continuous with the cuticle of the neighboring skin. The plane of the membrane was nearly at right angles to the axis of the canal.

In order to ascertain the exact condition of the deeper parts of the ear, and also, at the same time, for the purpose of removing from the canal what could only be considered as a hinderance to the perception of sound, I made a crucial incision through the membranous diaphragm, and then, with the forceps, tore away the greater part of the remaining segments. At the points where the attached membrane had been torn off, no evidence of any line of attachment remained, beyond at most a diffuse redness of the skin. The drum-membrane beyond presented a fairly normal appearance, and the hearing was somewhat improved by the removal of the obstacle.

This case, which is entirely different in its pathogenesis from the one last reported, derives its chief importance from the light which it throws upon the question of horizontal or surface motion in the epidermis of the membrana tympani and skin of the external auditory canal. That such a motion exists on the outer surface of the drum-membrane has been known for several years. Every aural surgeon who has had occasion to perform paracentesis of the membrana tympani has observed how from day to day the scab resulting from his incision moves from its original situation in the posterior half of the membrane, midway between the umbo and the periphery, toward the latter, and eventually, in its outward course, leaves the drum-membrane entirely. The same motion has been observed in the external auditory canal in the immediate vicinity of the membrana tympani. Dr. Burnett, in his "Treatise on the Ear" (p. 46), speaks of this outward movement of the skin of the external auditory canal as affording an explanation of the way in which the superabundant cerumen is extruded from the canal. This surface movement, then, of the epidermis of the drum-membrane and external auditory canal, furnishes, I believe, an explanation

of the presence—in the case narrated above—of a cuticle-like, membranous diaphragm in the outer canal of the ear. This membrane, according to this theory, would represent a desquamation—probably the result of an acute congestion of the parts—of the entire epidermal coat of the drum-membrane. That part of the cuticle of the membrana tympani which had separated from the underlying living epithelial cells must, in the present instance, have retained (at all points of the circumference) its connections with the neighboring healthy cuticle of the external auditory canal. The surface motion known to exist in the cuticle of the deeper portion of the canal extends without doubt throughout the entire canal. Hence, in the present case, after the cuticle had separated from the drum-membrane, the centrifugal motion of the remoter parts of the separated membrane—due to the traction exerted by the outwardly moving healthy cuticle of the external auditory canal—must have produced at first merely a state of tension (equilibrium) in the central portions of the cuticular membrane. At a later moment, however, this outward motion of the healthy cuticle must have exerted a symmetrical outward traction upon the cuticular membrane, eventually lifting it completely off the underlying membrana tympani. That in this particular case a rupture did not occur at some point must be ascribed simply to the fact that probably all things conspired to favor a separation of the desquamated cuticle in its entirety. After the act of separation had once taken place, there was no reason why the separated cuticle (then an independent diaphragm) should not remain unbroken, until acted upon by some force from without. If different parts of the healthy cuticle of the external auditory canal travelled outward at different rates of speed, we might look for a rupture, or at least for a distorted cuticular diaphragm. The flatness of the membrane, in the present case, and the inclination of the plane which it occupied, to the axis of the meatus, would rather favor the view that the rate of speed is the same for all parts of the canal.

Further observations and experimental researches will doubtless soon determine accurately all the facts connected with this peculiar horizontal cuticular motion, analogous to the growth of the nail, which may be looked upon as a cuticular structure.

#### SYPHILITIC ULCERS AND CONDYLOMATA.

To judge from the accounts of recent writers on otology, and also from my own experience, cases of syphilitic disease of the auditory canal are comparatively rare. I have seen but three instances in which the lesions observed in the meatus deserved to be classed as distinctively syphilitic. In the first one the picture presented was, I confess, not very striking; in the other two, however, the idea of syphilis was suggested at almost the first glance at the outer orifice.

The first case was seen on the 8th of April, 1874. The patient, a man, forty-four years of age, stated that he "caught cold" three weeks previously, but did not notice anything wrong about the ear until about two weeks later. The left ear then began to ache, and very soon afterward a discharge appeared at the orifice of the auditory canal. From that time to the day on which I first saw the patient, the discharge, he said, had been constant. On examination, I found the left membrana tympani red, very much swollen, and perforated anteriorly and inferiorly. The lower wall of the outer half of the meatus was ulcerated for a distance of about half an inch. The ulcer extended outward upon the auricle, and its limits were everywhere quite sharply defined. An examination of the throat revealed the existence of well-marked syphilitic lesions, and, on questioning the patient, he admitted that he had had a chancre one year previously. (This case was not seen again.)

As already mentioned, the lesions observed in this patient's ear were not of such a character as to suggest at once a syphilitic origin. It was only after the throat had been examined that the thought of a common origin for the two sets of lesions suggested itself to my mind. And yet, if we reflect for a moment, we shall be obliged to admit that the development of a well-defined ulcer in the auditory canal, after a discharge from the deeper parts of the ear had been going on for only one short week, was a very unusual phenomenon. In children the external auditory canal is very apt to become ulcerated by the constant flow of an irritating secretion over its surface; in adults, however, this rarely happens, and then almost always in connection with a chronic discharge from the ear. In the present case a comparatively large and well-defined granulating area or ulcer had developed in a canal which presented almost no other evidence of active inflammation, and which had been subjected to no other irritating influence than that which may have been exerted by the flow, for the period of a week, of a purulent fluid over its surface. Furthermore, the discharge was by no means copious, as we should rightly expect it to be if it had been the sole cause of the extensive ulceration observed. These are the points which seem to me to justify the view that this ulcer was a true syphilitic ulcer or gum-mous degeneration.

The second case was seen on the 7th of August, 1878. The patient, a man, twenty-eight years of age, of strong frame and apparently vigorous constitution, stated that during the month of February he first noticed a discharge from the right ear. It came on without pain, lasted for a few weeks, and then ceased of its own accord, without treatment. In the early part of the summer the discharge returned, and from that time forward it had been a constant symptom. He had experienced no difficulty in hearing, but for a short time before I saw him he had noticed some soreness of the affected ear. On examination I found the following conditions: the orifice of the right meatus was almost completely obliterated by the pres-

ence of an elevated patch of what seemed, at first sight, to be simple granulation-tissue; the dividing line between this patch, which completely encircled the orifice, and the healthy skin of the auricle, was sharply drawn, the edges of the elevated portion being quite abrupt. When the auricle was pulled upward, backward, and a little outward, the flattened patch opened in the centre and displayed a narrowed entrance to the auditory canal beyond. At the same time fissures became visible in the outer surface of the patch. When the auricle was allowed to resume its natural position, these fissures completely disappeared, and the central opening became converted again into a mere depression in the centre of the patch. When examined more closely, this circular patch, which seemed to be composed of granulation-tissue, proved to be made up, in reality, of very numerous minute vegetations or papillomata, the majority of which were of a pale pinkish hue, while a few presented a decidedly red color. A watery discharge oozed from the lower part of the elevated patch. The fissured appearance, observed when the parts were put upon the stretch, was found to be due to the fact that the minute papillomata sprang in groups from rather broad trunks, and the fissures corresponded with the spaces which separated these larger trunks. Just inside the orifice were found a few growths which were quite large in comparison with the greater number,—as large, *e.g.*, as a hemp-seed, or even larger. The external auditory canal itself, so far as the eye could see with the aid of a small speculum and reflected light, was filled with similar vegetations. Between the larger masses were numerous smaller and more pointed growths, like those observed at the orifice. When touched with the probe, the larger of these growths were found to be considerably harder than ordinary granulation-tissue. Some of them looked precisely like (on a smaller scale, of course) the warts seen on the fingers of young children, the skin covering them being pale and tough like natural skin. The smaller papillary growths, and one or two of the larger ones near the orifice of the canal, were less firm in structure, and bled readily when they were manipulated with the probe. The membrana tympani was not visible. The gland lying upon the mastoid process of the same side was enlarged to such an extent as to cause a visible swelling in this region. The occipital glands were also moderately enlarged. A diffuse discoloration of the skin, with desquamating surface, was observed on the hairy scalp, and also to a slight extent on the forehead of the left side. Two well-marked mucous patches occupied the left half of the velum palati. On questioning the patient it was ascertained that he had contracted the primary lesion about fifteen months previously.

Treatment was not begun until September 4th. It consisted in daily inunctions of mercury (about a drachm of Squibb's oleate of mercury [5 per cent.]), and also its internal use (one thirty-second of a grain of the bichloride three times a day). The larger vegetations which were within reach were snipped off with the scissors; the smaller ones were touched

with nitric acid. The patient was simply instructed to keep the ear clean by syringing it out from time to time with warm water.

The subsequent progress of the case may be briefly stated as follows:

September 26th.—The dose of the bichloride was increased to-day to one-sixteenth of a grain three times a day. The patient was also given some calomel with which to dust those vegetations which were within his reach.

October 2d.—Patient feels better in every way, and says that the otorrhœa is diminishing in quantity. The patch of vegetations around the orifice of the external auditory canal has perceptibly diminished in height and in vividness of color.

October 23d.—Patient has gained thirteen pounds in weight since the 4th of September. He has been very faithful in using the remedies prescribed. The squamous eruption on his forehead has almost disappeared. The orifice of the external auditory canal has been steadily increasing in size. Very little change, however, is perceptible in the condition of the deeper portions of the canal. By aid of the probe it was ascertained to-day that the innermost section of the meatus, close to the membrana tympani, was smooth and apparently free from vegetations. The "mucous patches" are still visible on the velum. Iodide of potassium is to be added to the bichloride mixture, in the proportion of ten grains to each dose.

November 6th.—The wart-like growths in the external auditory canal have become less prominent; they encroach less upon the calibre of the canal, and the intermediate bright red pointed condylomata have lost their bright color and well-defined outlines. Nitric acid (undiluted) applied firmly to one of the more prominent excrescences near the external orifice. The pain which followed lasted but a minute or two, and then entirely disappeared. Appetite good. No evidence of sponginess of the gums.

November 13th.—Application of nitric acid repeated to-day. The orifice is now increasing in size quite perceptibly, and the deeper condylomata—simply under the influence of the constitutional treatment—have now shrunk away to mere elevations of the skin. The discharge is also very much less than at first. The inunctions are still kept up. The improvement in the condition of the meatus has been more marked during the past week than during any previous week since treatment was begun. No appreciable change in the condition of the "mucous patches" on the soft palate. Dose of potass. iodid. increased to twenty grains three times a day.

November 20th.—Patient has now gained twenty-six pounds in weight. The discharge from the ear has ceased, and almost every trace of the condylomata has disappeared. Membrana tympani entire.

In the third case, the conditions observed in the auditory canal were in many respects different from those which I have just described. The

patient, a woman, twenty-five years of age, was under treatment at the time, for syphilitic disease of the vulva. The first symptoms referable to the ear were noticed about eight weeks previously. The ear became painful, and soon a discharge took place from the external auditory canal. Three weeks previously the ear again became painful, and relief was only obtained after a free incision had been made through the mastoid integuments; leeching and other simple measures having failed to quiet the pain. At the time I saw her the meatus was obstructed by the presence of several wart-like growths, situated on opposite sides of the canal, and bathed with a thin watery pus. These growths were very firm in texture, being covered apparently with true skin. The largest was equal to a pea in size, and sprang from the anterior wall of the canal, near the orifice, by a broad base. The drum-membrane and the deeper parts of the canal were concealed from view by these growths. By aid of the probe, however, I ascertained that the latter were not connected with any fistulous opening in the bone or with any superficial spot of caries. (The case was not seen again.)

At the beginning of the present section I stated that in two cases of syphilitic disease of the auditory canal—the two last described—the idea of syphilis suggested itself to my mind at almost the first view. In other words, the lesions presented to the eye were so characteristic, so different from those observed in non-syphilitic cases, that one could scarcely fail to be struck with their individuality. This opinion, I should state, is directly in conflict with that expressed by Schwartz. In a paper published by him in 1869,<sup>1</sup> he states that in the auditory canal polypoid granulations undoubtedly occur, which must be considered as a local manifestation of constitutional syphilis. “As granulations of this character, however, are exceedingly common in non-syphilitic individuals affected with a purulent inflammation of the ear, it becomes a very difficult matter to decide, in a given case, whether the growths are or are not of a specific nature. From the anatomical examination alone, no definite conclusion can be drawn. The characteristic papillary structure of the tumor, which sometimes presents the appearance of a perfectly developed condyloma, is also observed in cases where syphilis is not to be thought of for an instant.” As no material modification of this view is put forth in his recent treatise,<sup>2</sup> I assume that his opinion still remains substantially the same as it was in 1869. It is quite possible that the two cases of syphilitic “granulations” which came under my observation, were exceptionally well-marked types of the disease. This view, however, is rendered improbable by the fact that other authorities

---

<sup>1</sup> Archiv für Ohrenheilkunde. Vierter Band. Würzburg, 1869. Pages 253 et seq.

<sup>2</sup> H. Schwartz: The Pathological Anatomy of the Ear. Translated by J. Orne Green, M.D. Boston, 1878.



(Stoehr,<sup>1</sup> Gruber,<sup>2</sup> and Deprès<sup>3</sup> have reported quite a large number of cases in which well-characterized lesions of syphilis were observed in the auditory canal. I have also never seen, in non-syphilitic individuals, lesions which resembled in any but a very superficial degree those which I have described above. It seems to me, therefore, that Schwartze's statement is too sweeping in its character, and that it may be set down as a fact that well-defined lesions of constitutional syphilis may occur as well in the external auditory canal as in other parts of the body.

#### FOREIGN BODIES.

If we exclude such bodies as sequestra of bone, hardened masses of cerumen, calcareous bodies, and the so-called cholesteatomata,—which are essentially laminated masses of epithelium,—we may say that foreign bodies in the auditory canal are not of frequent occurrence. Thus, for example, out of 1,652 cases Dr. Blake found (in 1873) foreign bodies in the meatus sixteen times (about one per cent.). According to the statistical report of the New York Eye and Ear Infirmary for 1878, the proportion was about the same, viz., 30 cases out of 2,784. My own records show a still smaller proportion, viz., about half of one per cent. With regard to the ages of these individuals, I find that 18 out of the 29 cases seen were under twenty years of age. Between the ages of two and five, there were 4 cases; between five and ten, 10; between ten and fifteen, 2; between fifteen and twenty, 2. The foreign bodies found in the individuals who were under twenty years of age were quite different in character from those found in the adults. They comprised pebbles, glass beads, a cherry-pit, a prune-pit, ordinary beans, both black and white, a coffee-bean, a grain of corn, a piece of lead from a lead-pencil, a piece of slate pencil, and small rolls of paper. These articles, as will be noticed, are all such as a child would be likely to put into his own ear or into that of another child. Those articles found in the ears of adults were exclusively such as would be likely to find their way into the canal through accident or forgetfulness, or else wholly without human agency. In one case, for example, it was a fly; in a second, four flies were found; in a third, two living larvæ of the house-fly; in a fourth, a cockroach or Croton bug; in a fifth, a young bed-bug; in two others, a stiff hair was found, sprung like a bow between the wall of the canal and the drum-membrane; finally, in five cases, a forgotten mass of cotton-wool was in each instance found impacted between the drum-membrane and the anterior wall of the meatus.

<sup>1</sup> Archiv für Ohrenheilkunde, 1869. Fünfter Band, S. 130 et seq.

<sup>2</sup> Ueber Syphilis des Gehörorgans. Wiener Med. Presse, 1870. Nos. 1, 3, and 6.

<sup>3</sup> Annales des maladies de l'oreille, etc. December 31, 1878.

*Symptomatology.*—In many of the cases which come under observation, the patient complains of no symptoms whatever. Some mischievous playmate, or the boy himself, has introduced a bean, or a bead, or some other small object into the canal, and the parents are afraid that some harm may come to their child if the foreign body is allowed to remain in the ear. It is this fear on their part, and not any deafness or suffering on the part of the child, which usually leads them to consult a physician. Now and then the rough manipulations of medical men who attempt to remove a foreign body from the ear without seeing exactly what they are doing, convert a simple case of this kind into one of a very complicated and painful nature. During the years 1870 to 1874 I saw several cases of this kind, but during recent years I have not seen a single instance, and am disposed to consider this fact as an evidence that general practitioners, as a body, are more willing than formerly to entrust the management of these cases to the specialists.

In another class of foreign bodies, the patient experiences well-marked symptoms. Thus, for example, in both the cases where a hair was found sprung between the membrana tympani and the wall of the canal, the sensation of pressure or fulness in the affected ear was sufficiently marked to lead the patient to consult a physician. In another case, the patient complained of a crunching noise in one ear. It was not constant, but was noticed chiefly whenever he ate anything. On examination, a piece of dried cuticle was found lying against the drum-membrane, between it and the anterior and lower wall of the canal. Although from an anatomical standpoint it is difficult to comprehend how the motions of the jaw can exert traction upon either the membrana tympani or the skin lining the extreme inner end of the auditory canal, the fact remains that the opening and shutting of the mouth may produce sufficient motion in these parts to cause a slight friction between the foreign body and the drum-membrane. In the cases in which dead flies were found in the meatus, the patients had experienced no unusual symptoms, and were unable to say when or how these insects had found their way into the ear. As both patients were affected with a chronic purulent inflammation of the middle ear, it is quite possible that the flies were attracted to the ear by the odor of the discharge. The presence of living larvæ of the house-fly in the canal of another patient, also a sufferer from chronic purulent inflammation of the middle ear, is probably best explained by assuming that the eggs were actually deposited in the auditory canal by a fly, probably while the patient was asleep. The Croton bug and the bed-bug also undoubtedly effected an entrance when the patients were asleep, for in neither of the cases could the patient state at what exact time the insect entered the canal. At a certain time, however, both patients became aware that some living creature had got into the ear, as a sensation of something moving in the canal was felt by each of them. The Croton bug was dead when I extracted it; the bed-bug was alive, and, when first

seen, presented the appearance of a small mass of brownish ear-wax adherent to the upper part of the drum-membrane.

Finally, in those cases in which unskilful and unduly violent efforts had been made to remove the foreign body, before the patients finally came under my observation, the prominent symptoms were : marked pain and tenderness in the region of the ear, a bloody discharge from the canal, and a terrible dread of having the ear touched. In one of these cases I found the pebble lying partly in the meatus and partly in the middle ear, the drum-membrane having apparently been lacerated by the efforts previously made to remove it. In another instance the bony surface of the canal was found to have been laid bare. In a third case the external orifice was found to be in such a swollen condition that the diameter of the foreign body beyond must have been at least twice as great as that of the canal through which it would have to pass, while being extracted. Were it not for these, now fortunately rare, cases, the symptomatology of foreign bodies in the external auditory canal might almost be omitted altogether.

I should perhaps mention the fact that women sometimes consult a physician for the purpose of having an imaginary foreign body (generally a pin) removed from the ear. I have seen two or three such cases, and have observed in each instance that the patient seemed to be annoyed by my assurances that the auditory canal was perfectly natural and contained nothing that did not belong there. Judging from their actions, after the results of the examination had been communicated to them, I have no doubt that they ascribed my failure to find the foreign body to lack of sufficient skill in examining the ear.

*Treatment.*—Hard substances, like beads, pebbles, or buttons, if they do not cause pain, and if they are not actually impacted in the auditory canal, may be allowed to remain there undisturbed for a reasonable length of time. In one of my cases, for example, a glass bead of large size had remained twelve years in the canal without doing the slightest damage that I could discover. As the foreign body, however, may change its position and become wedged in between the drum-membrane and the anterior wall of the canal, and as an intercurrent inflammation of either the meatus or the middle ear might be seriously complicated by the presence of such a foreign body in the canal, it is better not to delay its removal any longer than is necessary to ensure a successful result. If the body is impacted in the canal and is causing pain, the sooner it is removed the better. If the operation is postponed, the outer portion of the canal may become swollen, and the task of extracting the foreign body may thereby be rendered materially more difficult. In the case of substances like dried peas and beans, which may swell up in water to fully twice their original size, it is important to abstain from using the syringe ; or else, if we fail by means of it to remove the foreign body, we should proceed, without further delay, to extract it by means of instruments.

Small bodies, which simply lie in the canal without being impacted between its walls, may be removed by means of such instruments as the slender forceps, the curette, or a bent probe, or by means of the syringe. Assuming that the physician has illuminated the canal by means of reflected light, and that he actually sees such a small foreign body lying in the auditory canal, I can think of only two valid reasons why he should rise from his seat, get ready a vessel of warm water, and proceed to syringe out the foreign body. These are, the lack of the proper instruments and the lack of a steady hand. If the foreign body is of sufficient size to fill the canal, or to press against its sides at two or more points, the use of the syringe seems to me to be thoroughly irrational and unpractical. What is required in such a case is a "force from behind," and not one that spends itself upon the outer surface of the foreign body, and thus tends to drive it deeper down into the canal. If the shape and position of the body are such that we may with some degree of confidence hope to extract it by seizing it directly with the slender forceps, this plan may be adopted. But it is far better not to make such an attempt, unless we are quite confident of success; for if we lose our grasp upon the body, we may be almost sure that we shall drive it a little beyond the position which it previously occupied, and thus render the problem of removal correspondingly more difficult. The better plan is to explore the circumference of the foreign body with the probe, and thus ascertain whether there is not some point where it is separated by a certain amount of space from the wall of the meatus. This is the point at which we should introduce the instrument by means of which we intend to bring the desired *vis a tergo* to bear upon the foreign body. In the case of a roundish body like a cherry-pit, a pea, or a bean, we shall undoubtedly fail to find such a point. Under these circumstances, if we desire to bring a similar force to bear upon the impacted body, we must employ an instrument that is both slender and strong: slender enough to force its way between the foreign body and the skin of the canal, without injuring the latter, and yet strong enough, after it has once been pushed inward the requisite distance, to exert a decided downward and outward pressure upon the inner end of the mass. The smaller curette and a delicate steel hook are almost the only instruments which I have used for the purposes we are now considering. The curette is made of steel and has been sufficiently described in an earlier section. The hook should also be made of steel, but the shank should be tempered and not left in a malleable state like that of the curette-shank. In introducing the curette, which must first be slightly bent flatwise, we must make its ring-shaped end describe an arc of a rather small circle, or we shall cause the patient unnecessary pain, and perhaps fail to carry the end of the instrument beyond the foreign body. In introducing the hook we must follow a somewhat different principle: as we push the instrument farther and farther inward, we must make the end of the hook proper hug the foreign body constantly.

By pursuing this plan we shall know instantly when the instrument has reached the inner end of the foreign body ; for the hook, no longer meeting with the resistance offered by the side of the obstructing mass, will at that very moment perform the rotatory movement which the pressure of our fingers has tended to give it. We must not allow it, however, to perform more than a quarter of a turn, for fear of bringing the free end in contact with the walls of the canal. When the hook has performed this quarter revolution, we should withdraw it cautiously but firmly, and thus dislodge the impacted foreign body. If that portion of the canal which is external to the foreign body is very much swollen, it will be found necessary to first dilate it gradually, by means of a series of well-polished, conical specula, or by means of cotton-wool wound tightly around the end of a cotton-holder, and moistened with vaseline or oil. In the case of older children it will probably not be found necessary to administer an anæsthetic ; and even in the younger ones I have only five times found it impossible to proceed without the administration of sulphuric ether. Again, let me emphasize the importance of carrying out all these manipulations only when the canal is perfectly illuminated.

The after-treatment in the graver cases is based upon the same principles as those which govern the treatment of other acute inflammations of the canal or of the middle ear. In the simpler cases no after-treatment whatever is required.

Those who are interested to learn something about the thousand and one ingenious methods which have been devised for removing foreign bodies from the external auditory canal, will find them fully described in Poulet's treatise on Foreign Bodies in Surgical Practice,<sup>1</sup> and in the general treatises of Roosa and Burnett. I have had no personal experience with these methods, and may therefore be excused from discussing their merits and demerits.

#### WOUNDS.

Injuries to the external auditory canal are, according to my experience, of comparatively rare occurrence. I have seen but three cases, and they were all of minor importance. In one of these the patient had introduced the rather pointed end of a pen-holder into the right ear, just as he rose from his seat to get something at the other end of the room. Passing too near an unusually high stove he suddenly felt a sharp pain in the right ear, as if a pointed object had been violently driven into it. Slight bleeding followed, and the patient almost at once experienced a decided sensation of faintness, which lasted, however, but a short time. For a period of five days the ear gave him scarcely any trouble, and then it began to be de-

<sup>1</sup> A translation of it forms a part of the present series of publications (Wood's Library of Standard Medical Authors).

cidedly painful. About a week later still I had an opportunity of examining the ear, and then found that an abscess had formed in the posterior wall of the canal, not far from the external orifice. From the appearances presented to the eye there could be no reasonable doubt that a distinct collection of pus existed at this spot. The patient, however, declined to have it lanced at that time, and I never saw him afterward.

In the second case it was not ascertained exactly how the injury was received, owing to the fact that the patient was intoxicated at the time. The blow or the fall, however, produced unconsciousness for a short time, and when the patient recovered his senses he observed that blood was escaping quite freely from the right ear. The accident occurred on the 9th of March, 1875, and from that time until the day on which I first saw him, viz., March 13th, an intermittent, but in the main abundant, hemorrhage had continued. On examination, I found a rather deep irregular wound in the cartilaginous wall of the canal, a short distance from its junction with the osseous portion. The bleeding had at that time ceased, and as the patient seemed to be free from pain, I advised him simply to leave the ear alone. Four days later I found the wound healing naturally by granulation.

In the third case the rib of a steel umbrella frame had been accidentally thrust into the external auditory canal, causing quite a small lacerated wound. Nevertheless the hemorrhage was quite free; and, even after the lapse of twenty-four hours, I found the blood still trickling from the ear in a steady stream. Upon the introduction, however, of a very small piece of styptic cotton, the hemorrhage instantly ceased.

The persistent bleeding which seems to characterize these lacerated wounds of the external auditory canal, is undoubtedly to be attributed to the fact that those blood-vessels which pierce the cartilaginous framework—as many of them do—are not capable of contracting and retracting beyond a very limited extent; their physical relations being essentially the same as those of the blood-vessels which traverse bony structures.

#### NEW-GROWTHS.

##### *Hyperostosis ; Exostoses ; Bony Closure.*

Both forms of hypertrophy of the osseous portion of the external auditory canal—the diffuse (hyperostosis) and the circumscribed (exostosis)—are by no means rare affections. As the child at birth has simply a rudimentary osseous canal, a mere ring of bone (the annulus tympanicus), we may safely assume that an exostosis or a diffuse hypertrophy of the bony canal is never a congenital but always an acquired condition. Out of thirteen individuals in whose auditory canals I found hypertrophy of the bone

(in the form of exostoses<sup>1</sup>) the youngest was twenty-two years of age. In two cases I was able to trace the development of well-marked exostoses to the local irritation accompanying a purulent inflammation of the middle ear. A symmetrical hyperostosis, however, is a much commoner result of this local irritation. The resulting stenosis, or narrowing of the calibre of the canal, is sometimes so great that it is impossible to see the drum-membrane and deeper parts of the canal. In a large proportion of the cases of exostoses, however, no exciting cause whatever can be found. The presence of the bony tumors is discovered by accident, and their development seems to take place independently of any appreciable local irritation. Syphilis, gout, and rheumatism are mentioned by some authors as predisposing causes, but I have not been able, in a single instance, to trace such a connection.

One of the most interesting questions connected with these bony tumors, relates to their rapidity of growth. So far as my own experience goes, I can throw but little light upon this important question. All but three of the patients were seen only once. In each of these three cases the ear was examined repeatedly during a period of several years, and it was clearly established that the bony tumor was slowly but steadily increasing in size. In the first case (that of a young girl, about eighteen years of age) the new-growth of bone took place in the form of a symmetrical encroachment upon the calibre of the inner end of the osseous canal. At first this stenosis was slight, and the deeper parts could still be seen under good illumination. The drum-membrane had been entirely destroyed; at one or two points in the middle ear, exposed bone was felt with the probe; near by were areas of granulation-tissue, and there was a constant flow of pus over the walls of the canal. In less than three years the hyperostosis had made such progress that it was utterly impossible to see anything of the deeper parts of the ear through the contracted canal. In this case the growth of bone seems to have been a gradual one, and if it had continued at the same rate, complete obliteration of the canal, at the region of the stenosis, in the course of two or three years more, might have been safely predicted. This case passed out of my hands, and I am unable to report its subsequent progress. In another case, however, three or four large, confluent (if I may be permitted to use the term) exostoses developed in the comparatively short period of three years, and then made no further progress during the following two years. When the exostoses ceased growing, the diminution in the size of the canal was so great that I could barely pass a slender silver probe through the narrowest part. That no further diminution in the size of the canal took place during the next two years, was shown by the fact that I was still able at the end of that time to

---

<sup>1</sup> I have not thought it worth while to ascertain in what proportion of the cases of chronic purulent inflammation of the middle ear stenosis of the auditory canal from diffuse hyperostosis of the bony portion occurs. It is by no means an uncommon condition, however, in this form of ear disease.

pass the same probe through the narrow part of the meatus. I watched this case with considerable interest, fully expecting that the previous rate of growth of the exostoses would be maintained, and that the resulting obstruction to the discharge of pus from the middle ear would necessitate an operation. As the patient (a drygoods clerk, thirty-five years of age) promised to come and see me as soon as he observed any material change in the condition of his ear, and as I have not seen him for about three years, I think it quite probable that no further growth of the bony masses has taken place during this period.

Finally, in a third case, the rate of growth of the exostoses was apparently more rapid. The patient, a physician, thirty-four years of age, had always heard well, and had never experienced any unnatural sensations in either ear, until toward the end of 1871. He then, for two or three successive days, experienced severe pain in the right ear, and Dr. Hackley, an experienced aurist, who examined the ear, after the severe pain had subsided, found in the meatus a circumscribed swelling which presented the appearance of a furuncle that either had not yet reached maturity, or had already begun to subside. In September, 1872, about a year after this condition of the right auditory canal had been observed, the patient consulted me for a troublesome tinnitus in the same ear. On examination I found the canal narrowed by the presence of two broad-based exostoses, situated exactly opposite each other, the one on the anterior, the other on the posterior wall, close to the junction of the cartilaginous with the osseous part of the meatus. Deeper in was a third exostosis, which overhung the drum-membrane, and apparently pressed against it. Smaller exostoses, occupying almost the same positions as those observed in the right ear, were found in the left meatus.

In March, 1873, I examined both ears a second time, and found that the exostoses in the right auditory canal, at least the two outer ones, had increased noticeably in size. Their summits approached within a millimetre of each other, and the outlines of the walls of the canal presented a perfect resemblance to the old-fashioned hour-glass. On the left side, apparently no change had taken place in the size of the bony tumors.

In October, 1876, I examined the patient for the third time, but could find no evidence of further growth on the part of the exostoses in either meatus.

It seems reasonably clear, therefore, that there is no fixed law governing the growth of these exostoses. At one time they increase in size at a relatively rapid rate, and then, for a period of years, without any perceptible change in the condition of the immediate surroundings, they show no further signs of growth. An irritating purulent discharge seems to be an exciting cause of their growth in many cases, and yet in others (*e.g.*, the last case mentioned) the growth of bone proceeds without any demonstrable exciting cause.



The prevailing shape of the exostoses that I have seen has been that of a hemisphere or low, broad-based cone. I have only twice seen a distinctly pedunculate exostosis, and in only one of these cases was the peduncle noticeably smaller than the body of the tumor. In the majority of cases I have found more than one exostosis in the auditory canal. If at first the growths are more or less separate and distinct, at a later stage they will be found to merge so completely the one into the other that a mere undulating surface is presented to the eye of the observer.

The bony character of the tumor is easily ascertained by means of the probe, or, better yet, by means of the paracentesis needle, or the curved, sharp-pointed bistoury. As a rule the surface of these exostoses is very slightly sensitive, and the sharp point of a knife is felt even less than the pressure of the comparatively broad end of a probe. The skin covering them is exceedingly thin.

There are only two conditions, it seems to me, which justify the surgeon in *recommending* operative interference with these bony tumors. For instance, if there is marked or total deafness in one ear, and the growth of an exostosis in the other auditory canal shuts it up and deprives the individual of the use of his only available ear, operative interference would, it seems to me, be perfectly justifiable and proper. It should first be clearly established, however, that a useful degree of hearing existed in the ear before the canal became entirely closed by the bony growth. Again, if a chronic purulent inflammation of the middle ear is associated with exostoses, or with a diffuse hyperostosis, of the osseous auditory canal, and if, through the gradual growth of these masses, the canal becomes so narrow that the pus can no longer escape with sufficient freedom, it is clear that the only remaining natural outlet for the pus is through the Eustachian tube. This channel, however, is very often so narrow that comparatively little pus can escape through it. Stagnation follows, and yet pus continues to form in this closed cavity. Under such circumstances the indications for operative interference are very clear and urgent. It is rare, however, that either of the conditions described above occurs. I have never seen a case in which operative interference seemed to be indicated; but Dr. J. Orne Green, of Boston, reports<sup>1</sup> the case of a young man in whose auditory canal two exostoses so nearly closed the meatus that the pus secreted in the middle ear could no longer escape freely enough, and death soon followed from the meningitis set up by the retention of the pus. Four days before the patient's death, Dr. Green was sent for. By means of a hand-drill he established a channel, 3 mm. in diameter, through the exostoses. With a larger drill he made an opening, behind the ear, into the mastoid antrum, and, by means of the syringe, passed a current of warm water from the meatus into the middle ear and antrum, and thence out through

---

<sup>1</sup> Boston Medical and Surgical Journal, April 18, 1878.

the external wound. The operation, however, had been performed too late, and the meningitis went on to a fatal termination. In the case reported by Dr. Mathewson,<sup>1</sup> a large exostosis almost entirely closed the auditory canal, and materially diminished the patient's hearing. Through this mass, which proved to be as hard as ivory, Dr. Mathewson established quite a broad channel by means of drills driven by the so-called dental engine. The operation was completed in less than thirty minutes. To judge from this single experience, this form of motive power presents decided advantages over that supplied by the hand. The drill can be guided with at least equal accuracy, and it can be equally well prevented from penetrating suddenly to a greater depth than is desired. In cases such as that described by Dr. Green, it may be found desirable to establish a counter-opening in the mastoid process, so that a stream of water, introduced into the meatus, may enter the antrum and then pass out through the artificial opening in the mastoid process. The necessity, or lack of necessity, for the establishment of this second opening will depend chiefly upon the degree of success attained in cleansing the deeper cavities of the ear, through the re-established meatus, and also upon the degree to which the mastoid process appears to be involved in the inflammation.

#### *Cancer.*

I can find but one case on record of a primary cancer of the external auditory canal, viz., that reported by Kessel.<sup>2</sup> It is quite possible that there are other cases in the literature of this subject, but my limited search has failed to discover them. The case reported by Delstanche, fils,<sup>3</sup> as one of primary cancer of the external auditory meatus, can hardly be accepted as a well-established instance of this disease. I have read the account carefully, and am by no means satisfied, nor does Delstanche himself seem to be, that the disease may not have developed first in the middle ear. Furthermore, Kessel's case can scarcely be considered as entirely satisfactory. Prof. von Biesiadecki gave him, for microscopic examination, twenty-two specimens of polypi that had been removed from the ears of different individuals. No histories accompanied these specimens, and no other data were known to Dr. Kessel beyond the scanty information which he could glean from the labels on the bottles that contained the polypi. One of these growths, which was labeled as coming from the external auditory canal, presented to the naked eye all the features of a medium-sized,

---

<sup>1</sup> Transactions of the First Congress of the International Otological Society. New York, 1877.

<sup>2</sup> Ueber Ohrpolypen. Arch. f. Ohrenh. Bd. IV., S. 184.

<sup>3</sup> Archiv für Ohrenheilkunde, Bd. XV., S. 21.

knobbed wart. A microscopic examination showed it to be provided with hairs, and with sebaceous and ceruminous glands. It therefore, in all probability, grew from some portion of the outer half of the meatus. Its outer surface was composed of a thick layer of epidermis cells which sent prolongations of epithelium deep into the substance of the wart. The presence of numerous balls of concentrically arranged epithelial cells and of nests of these elements, seemed to Dr. Kessel to establish the cancerous nature (epithelioma) of the growth beyond a shadow of a doubt. Such a conclusion, however, does not appear to me to be warranted by the facts. The minute anatomy of a perfectly benign wart is so like that of the malignant epithelioma, that without other data (the history of the case, the condition of the neighboring glands, etc.), one would hardly be justified in expressing so positive an opinion.

Even secondary cancers of the auditory canal are by no means common. Of the two cases which have come under my observation, one was preceded by a cancer of the middle ear, the other by one that originated in the glands of the neck behind and just below the ear. The former case will be narrated in detail in the chapter on diseases of the middle ear. The facts of interest in the latter case are as follows: The patient, a female, thirty years of age, and in rather poor general condition, was seen for the first time on the 3d of June, 1872. She stated that nine years previously a hard swelling showed itself on the left side of the neck, close behind the ear. It came without pain, and gradually increased in size until, at the end of five years, it had reached the dimensions of a large egg. It was then removed by Dr. Thomas M. Markoe, of this city, who found it to be a cystic tumor. The wound healed promptly, and for a period of about three years she remained free from any evidence of a return of the growth. Then, after the birth of her last child, the parts around the ear became swollen and painful. At the end of two weeks the swelling gradually subsided, without the formation of matter; the pain disappeared, and the patient remained free from all symptoms referable to the region of the ear for a period of several months. Early in January, 1872, she passed through a second attack of acute swelling of the parts around the ear, and again the attack passed off without giving rise to the formation of an abscess. Unfortunately, it is not stated in my notes whether complete subsidence of the swelling followed both of these attacks, or whether after each a certain degree of permanent swelling remained. It is stated, however, that throughout both of these attacks no appreciable deafness and no tinnitus or other subjective aural symptoms were present. During the following March she experienced a third attack, more severe than any previous one. This time there were both deafness and tinnitus, and at the end of a few days an abundant, and at times bloody, discharge made its appearance in the external meatus. From that time onward the discharge was constant, and the swelling behind and below the ear steadily increased. Early in May

Dr. James Little, through whose kindness I had an opportunity of examining the patient's ear, opened an abscess situated immediately over the left mastoid process. By aid of the probe he ascertained the existence of a sinus, leading from the cavity of the abscess into the external auditory canal. No denuded bone was found. At the time I saw the patient, about four weeks later, the opening behind the ear still existed, and pus could easily be forced out through it by pressure made upon the skin in the vicinity. Just in front of the tragus an irregularly shaped hard mass could be felt, which extended backward to the mastoid region. The skin was freely movable over the mass. The outer orifice of the auditory canal was filled with a reddish, mulberry-like fleshy mass, bathed with a thin pinkish pus. When manipulated with the probe it bled easily, but yet was quite firm in texture. By grasping the body of the tumor beneath the auricle, and moving it in different directions, I was able to satisfy myself that the fleshy growth in the meatus was simply an outgrowth from it. By means of the probe I ascertained that the cartilaginous wall of the meatus had been pierced (as already discovered by Dr. Little) at a point situated posteriorly and below, and not far from its junction with the osseous portion of the canal. One of the fibrous gaps in the cartilage (fissure of Santorini) had probably been the point through which first the pus of the abscess and then the offshoot of the tumor had forced their way.

No attempt at an operation was made. The tumor steadily increased in size, and eventually caused the patient's death. As no notes were kept at the time, Dr. Little is now unable to recall any further details of this interesting case.

#### *Sarcoma.*

The following case is the only one of its kind that has come under my observation. The history is as follows :

The patient, a strong, healthy girl, fourteen years of age, consulted me on the 25th of May, 1880, for an affection of the right ear, of recent date. About two weeks previously she noticed a sensation of fulness and perhaps very slight pain in the right ear. This was the first intimation that she received that her ear was not perfectly sound in all respects. She had never previously experienced either pain, discharge, deafness, or any other symptom referable to the ear. In the course of a few days a slight discharge was discovered at the outer orifice, and as the sensation of fulness still persisted, the family physician, Dr. A. A. Smith, was called in to see the child. On examination with the speculum and reflected light he discovered that the canal was blocked near the outer orifice, by a rather solid fleshy mass, which bled quite freely when he removed a part of it with the snare. Being convinced that the case was not one of ordinary polypus of the ear, Dr. S. referred the patient to me for further treatment. The tu-

mor at this time extended outward almost if not quite to the plane of the outer orifice of the auditory canal. It presented a smooth, but slightly uneven surface, felt very firm when pressed upon with the probe, was not at all sensitive, and seemed to spring by a very broad base from the upper and posterior wall of the osseous portion of the auditory canal. The cervical glands were not enlarged. The left ear was perfectly healthy. Twice in succession I surrounded the mass with a loop of No. 37 malleable steel wire, but both times the wire broke when I attempted to make it do the work of cutting through the tissues of the tumor. I then employed a blunt-pointed, curved (flatwise) bistoury, and endeavored to cut away the growth close to its base. The cutting edge of the knife, however, encountered bony resistance, and I was obliged, for the moment, to remain satisfied with the removal of two fragments, both together equal perhaps to one-third of the entire tumor. Moderately abundant bleeding followed this operative interference, but it ceased in the course of a few minutes. Exploration with the probe failed to discover any central channel or sinus, such as is found in those very similar tumors of the auditory canal which depend upon a limited area of carious bone. As soon as the bleeding had ceased, the patient noticed that her hearing was as perfect as it had ever been. The fragments removed were placed at once in alcohol (90%), and were then entrusted to Dr. William H. Welch for examination. His report reads as follows: "The larger specimen consists, for the most part, of closely compacted, small, round cells, between which is an ill-defined basement substance or stroma, constituting a reticulum when the cells are shaken out. There are also some larger, endothelial-like cells scattered irregularly among the round cells. The smaller fragment consists more of spindle-shaped cells, with a more distinctly fibrous stroma. The growth is rich in vessels, whose walls are embryonic, being composed simply of an endothelial lining and the surrounding tissue. In some parts of the fragment the epidermis is preserved. From the microscopical appearances the specimen is probably to be regarded as round-celled sarcoma, but the possibility of its being granulation-tissue cannot be wholly excluded."

On the 26th of May I succeeded, by means of as strong a wire as I could pass through Blake's double-mouthed canula, in removing another portion of the growth. This, too, was submitted to Dr. Welch for examination, with the following results: "The specimen presents in some places the same structure as that which characterized the first fragment; but, in addition, it presents certain points of interest. The central part of the specimen is hard, and, under the microscope, is found to consist of osseous tissue, with wide medullary spaces in which the tissue is rich in cells and fibrillated. The rest of the specimen is composed of a tissue containing numerous round and some irregular cells. Near to the bone the cells are less numerous, more irregular in shape, and have between them a homogeneous, glistening basement substance containing some elastic fibres.

Peripherally the cells are more numerous and the intercellular substance less glistening and more fibrillated. There are places where the tissue is of an osteoid character; that is, the cells, with fine processes, are inclosed in spaces in a homogeneous, bony-looking matrix. These seem to represent transition-stages between the sarcomatous tissue and the osteoid tissue on the one hand, and the osteoid and osseous tissue on the other. There are no cells which can be positively claimed as cartilage cells. The tumor seems to be an ossifying sarcoma (osteosarcoma), taking its origin, most probably, from the periosteum."

The patient was then examined by Drs. Robert F. Weir and D. B. St. John Roosa, separately—both of them experts in diseases of the ear. They both agreed that the tumor was not an ordinary connective-tissue growth, and favored an early operation for the purpose of extirpating it as thoroughly as possible. They thought it advisable, however, that a microscopic examination should first be made by another expert; and accordingly I removed (June 7th) another moderately large fragment and submitted it to Dr. Francis Delafield. His report, which was made on the 9th of June, fully confirms that previously made by Dr. Welch. It reads as follows: "The specimen is a small, rounded mass, about the size of half a pea. It was removed from the wound left by a previous operation. It is evident that the specimen consists of a portion of new-growth situated at the edge of the wound. Part of the specimen is covered by a layer of epithelium, and beneath the epithelium is connective tissue with an excess of cells and mucous tissue. The portions of the specimen not covered by epithelium are composed of connective tissue infiltrated with round cells—granulation-tissue. Part of the specimen, therefore, represents a new-growth—part granulation-tissue from a wound. If we compare this specimen with those already examined by Dr. Welch, it is evident that the tumor is one of those composite growths which sometimes grow from the periosteum. It is composed of connective tissue, mucous tissue, bone, and sarcomatous tissue. The prognosis of such a tumor is bad, but not very bad. If the growth can be completely removed, and if the bone is not involved, there may be no recurrence."

In this connection I should state that, during the short period of ten days that elapsed between the two partial operations, the tumor had again fully reached its former size, but not its former degree of hardness. The fragment submitted to Dr. Delafield represented largely this fresh growth.

On the 10th of June the patient was brought under the influence of an anæsthetic (sulphuric ether), and by means of suitable knives (blunt-pointed and curved flatwise) and a sharp-edged steel scoop I removed the entire tumor, together with a zone of seemingly healthy skin surrounding its base on all sides. The growth apparently sprang from the periosteum, as the underlying bone felt smooth and hard. A small nucleus of osteoid tissue was found in the centre of the growth. The bleeding was trivial in charac-

ter. The denuded bone was carefully scraped, and, in addition, a solution of chloride of zinc (forty grains to the ounce of water) was painted thoroughly over all the exposed surfaces. Dr. A. A. Smith and Dr. Robert F. Weir assisted me in the operation.

For about three hours after the operation the patient experienced a moderate degree of pain in the ear. After that she fell asleep and had a good night's rest. On the following morning she said that the ear felt perfectly natural. I examined the canal and found the parts covered with healthy pus and moderately swollen. The deeper part of the meatus and the membrana tympani appeared to be perfectly natural. The watch was heard at a distance of nearly four feet.

On the 19th of June the patient went with her mother to Newport, R. I., and placed herself under Dr. Rankin's care. The treatment consisted in daily cleansings followed each time by an application of powdered iodoform to the exposed surface of the wound. At the time of her departure from this city only a small depressed ulcer remained; and about the 28th of June Dr. Rankin reported that this had healed and that no further treatment was required. On the 7th of July I had an opportunity of examining the ear. A slight excavation alone remained to indicate the spot from which the growth had been removed. At the very centre of the depression a small dry scab was still visible, but everywhere else the skin was pale, smooth, and perfectly natural in appearance. Up to the present time (October 1st) no indications of a recurrence of the growth have been discovered.

A careful inquiry into the family history revealed no instances of cancer or any form of tumor among members of the immediate family. Both parents are strong and perfectly healthy. The maternal grandmother, however, died of some uterine disease which may have been cancerous in its nature. An aunt had a tumor removed from her neck. A grandaunt had cancer of the breast. Two second cousins also had cancers.

I have no comments to add to the foregoing history. The case is certainly one of great rarity, and perhaps even unique in the literature of aural tumors.

#### CYSTS.

I have seen but two instances of what might fairly be designated as a primary cyst-like formation in the auditory canal. In one case a small, yellow body, about the size of a No. 6 shot, and consisting apparently of cheesy or sebaceous material, surrounded by a thin envelope of epidermis, projected from the anterior and upper wall of the osseous portion of the meatus, just beyond the junction of the latter with the cartilaginous portion. In the second case a somewhat larger cyst, with cheesy or almost

chalky contents, and slightly constricted at its base, sprang from a point on the upper wall of the meatus not more than one or two millimetres distant from the upper limit of the drum-membrane. It was slightly sensitive to pressure made with the end of the probe, and seemed to be quite solid, though of course not so solid as an exostosis. As isolated glands (ceruminous) are sometimes found in the osseous portion of the auditory canal, and especially along the upper wall, I think these cysts with cheesy contents should be placed in the same category with the sebaceous cysts observed in other parts of the body. Their significance, in the ear, is simply that of pathological curiosities.

In the vicinity of the membrana tympani, cyst-like tumors are occasionally met with, but they are, I think I may safely say, invariably secondary to some affection of the middle ear. In some instances, however, the primary disease recedes so completely that the cyst-like formation in the meatus gains proportionately in individuality, and may even be taken for a tumor of primary development. As the description of these secondary cysts belongs more properly under the heading of diseases of the middle ear, I will say nothing further on the subject in the present section.



## CHAPTER V

### METHODS OF EXAMINING THE MIDDLE EAR.

As the *membrana tympani* constitutes the outer wall of the tympanic cavity, and receives its supply of blood from the same system of vessels, its appearance as regards vascularity and degree of swelling may be taken as an index of the degree of vascularity and swelling of the concealed parts of this cavity. Hence, if, on inspection with reflected light, the drum-membrane appears to be red and swollen, we may safely assume that the mucous membrane of the tympanic cavity is in very much the same condition. There is, I believe, but one exception to this rule, and that is where a diffuse inflammation of the osseous portion of the meatus involves the *membrana tympani*. The very slight disturbance of the hearing, which has been observed in these cases, justifies the belief that the processes of congestion and infiltration involve only the dermoid layer, and do not extend much beyond these limits.

In the second place, the physical peculiarities of the drum-membrane enable us to draw valuable conclusions with regard to two points: first, the degree of patency or permeability of the Eustachian tube; and second, the quantity and also at times the character of the fluid contained within the tympanic cavity, in cases of fluid exudation. A perfectly normal condition of the tympanic mucous membrane, and a perfect condition of the function of hearing are scarcely possible unless the *membrana tympani* is subjected to the same degree of atmospheric pressure on both sides. To maintain such a condition of equilibrium between the inner and the outer atmospheric pressures, Nature has constructed the Eustachian tube—the channel of communication between the middle ear and the throat—in such a way that the air can readily pass through it, to and from the cavity of the tympanum. If through disease this channel becomes closed, the condition of equilibrium ceases to exist, for the air in the middle ear rapidly becomes rarefied through absorption, and as a result the greater pressure upon the outer surface of the drum-membrane forces it inward beyond the position which it occupied when pressure and counter-pressure were exactly equal. The degree of patency of the Eustachian tube may therefore be estimated with more or less accuracy by a careful inspection of the drum-membrane. If, for example, the tube is simply obstructed to a slight degree, the mem-

brana tympani, provided it be of normal thickness and transparency, may reveal the fact in several ways. In the first place, the increased pressure upon the outer surface of the membrane will be likely to change its shape from that of a shallow cone to that of a saucer or segment of a hollow sphere. If the eye of the observer could see the drum-membrane in its normal position, and then immediately afterward see it in its slightly sunken condition, no difficulty would be experienced in appreciating the difference in appearance between the two states of the membrane. In actual practice, however, no such opportunities for comparing the normal and the sunken conditions occur, and we are compelled to depend upon other points as guides in determining the question whether the membrane is sunken or not. One of the most valuable of these is the degree of distinctness with which we can see the outlines of the long process of the anvil. If a drum-membrane is normal as regards its textures and its position, we should not be able to see the long process of the anvil at all. The mere fact that this little bone can be seen is good evidence that the membrane is either sunken or atrophied. A still better guide in determining the degree of arching inward of the drum-membrane is the apparent position occupied by the handle of the hammer with regard to the circumference of the membrane. If the membrane is not sunken, the handle of the hammer will appear to be of full length and to be situated about midway between the anterior and the posterior limits of the membrane; there will also be no noticeable prominence of the short process. On the other hand if the membrane is sunken, as a whole, to such an extent as to carry the handle of the hammer inward beyond the position which it should properly occupy, the latter will appear to be unnaturally short, and to occupy a position nearer to the posterior limit of the drum-membrane, and more nearly parallel with it, than it should. The short process and the adjacent posterior fold will also appear to be unusually prominent and well-defined, and the soft membrane immediately surrounding the short process (Shrapnell's membrane) may present a hollowed out or depressed appearance. This apparent foreshortening of the handle of the hammer is considered by Politzer to be the best guide to the degree of arching inward of the membrana tympani. Finally, the shape and situation of the "bright spot" furnish some indication of the degree of arching inward of the membrane. With complete absence of any abnormal depression, the bright spot should be triangular in shape, and should extend from the tip of the handle of the hammer to the circumference of the membrane. The moment the latter begins to curve abnormally inward, the bright spot at once begins to grow shorter and its outlines to be less sharply defined.

If the drum-membrane is decidedly sunken, the degree of curvature will be so great that no person who is in the least familiar with the appearance of a normal membrana tympani, could possibly fail to recognize the abnormal depression.

From these different conditions of the drum-membrane, therefore, it is often possible to ascertain quite accurately what is the degree of permeability of the Eustachian tube. We must always bear in mind the possibility, however, that muscular force acting through the tensor tympani muscle, or rather the retraction of the tendon belonging to this muscle, by whatever cause produced, is competent to give rise to precisely the same arching inward of the drum-membrane as that due to atmospheric pressure.

As already stated, we may sometimes learn, from a mere inspection of the drum-membrane, that the tympanic cavity contains fluid exudation, and that this exudation is thin like serum, or viscid in character, or tinged with blood. If the cavity is entirely filled with a thin, colorless exudation, the drum-membrane presents at times a dull, greenish hue, at other times a more pinkish or purple color, due to the reflection of light from the congested mucous membrane of the inner wall of the cavity. If the tympanum is filled with mucus, the membrane is more apt to present a dull, opaque appearance. The presence of blood in the exudation communicates to the membrane a more or less decided pinkish or red hue, the depth of the color being proportionate to the amount of blood present. If the tympanic cavity is only partially filled with fluid, and the drum-membrane still retains a fair degree of transparency, it is very often possible to see the upper limit of the fluid in the form of a delicate but well-defined curved line, that looks very much like a hair stretched across a portion of the membrane. If the patient moves his head cautiously backward and forward, it is generally possible, especially if the fluid is serous in character, to follow the changes which take place, under these circumstances, in the relations of the fluid-line to that of some fixed object, like the handle of the hammer. If our minds are still in doubt about the existence or non-existence of fluid in the middle ear, there are one or two simple devices which may be resorted to for the purpose of settling the question definitely. Thus, for example, air may be forced into the middle ear, by one of the methods soon to be described, and thus bubbles, which are very easily seen through a comparatively healthy drum-membrane, may be introduced into the fluid. Another plan is to watch the fluid-line while the drum-membrane is made to perform to-and-fro movements by means of Siegle's suction apparatus (see farther on). Finally, if the observer possesses the requisite skill, and the patient is not one of the particularly sensitive sort, an incision may be made in the posterior half of the membrane, and an outlet thus be afforded through which the fluid—if found to be present—may easily be evacuated. Farther on I will state my views with regard to paracentesis of the membrana tympani as a therapeutic procedure in cases of fluid exudation in the tympanum. I mention it here simply as one of the resources at our command—and, I believe, a perfectly safe one—for determining beyond all doubt whether the middle ear contains free fluid or not.

The suction apparatus of Siegle, or Siegle's pneumatic speculum, often

supplies us with a convenient means of ascertaining important information with regard to the mobility of the hammer, the atrophied or non-atrophied condition of the drum-membrane, etc. This instrument consists of a central cylindrical chamber, of either metal or hard rubber, to which is attached a flexible rubber tube about a foot in length. To one end of the chamber, which is a little over three centimetres in diameter, a conical speculum is fitted; the opposite end is closed by a glass window placed at such an inclination to the axis of the cylinder, that the rays of light used for illuminating the drum-membrane may readily pass through it without any portion of them being reflected back to the eye of the observer. The free end of the speculum is sheathed with rubber tubing, and may therefore be made to fit air-tight into the auditory canal. When the instrument is in actual use, the observer, by holding the free end of the rubber tube in his mouth, has it in his power to condense or rarefy the air in the auditory canal, and, while doing so, to watch the effects of these procedures upon the drum-membrane and handle of the hammer.

A simpler and in certain cases equally effective plan of ascertaining the degree of elasticity of the membrana tympani, and the degree of mobility of the hammer, is to touch these parts lightly with the end of the slender silver probe. Every step of this procedure must of course be made under adequate illumination and with the membrana tympani in full view all the time. If the physician is not sure of the steadiness of his hand, or if the patient is very sensitive, this method of observation, so valuable in skilled hands, should not be adopted.

All the methods of studying the condition of the middle ear which I have thus far described, are based upon the direct observation of the drum-membrane. The remaining methods derive their value chiefly from the facts which may be learned by auscultation combined with the forcible introduction of air into the middle ear, by way of the Eustachian tube. There are three ways of forcibly introducing air into the middle ear: Valsalva's method, Politzer's method, and that by means of the Eustachian catheter.

In inflating the middle ear by *Valsalva's method* the patient closes both nostrils by grasping the nose with the thumb and forefinger of one hand, shuts his mouth firmly, and then makes a strong expiratory effort. In this way he compresses the air in the pharyngeal and nasal cavities to such an extent that it seeks an outlet through the Eustachian tubes. If the effort is successful the physician, who has previously established a communication between his own ear and that of the patient, by means of a flexible auscultation tube, will hear a slight puff or thud, as the air enters the middle ear and distends the drum-membrane. Of the three methods at our command, this is altogether the most unsatisfactory, at least for the purposes of auscultation. Whether the fault lies with me or with the method I am unable to say positively; but it has disappointed me so often that I rarely use it now, when I desire to learn by auscultation what is the condition of the

Eustachian tube and tympanic cavity. When I wish to observe the changes that take place in the membrana tympani, while air is being forcibly introduced into the middle ear, I still give the preference to Valsalva's method. For this purpose it is undoubtedly more convenient than either of the other two methods. For therapeutic purposes, as will be explained farther on, Valsalva's method must be placed third on the list; or, better, yet, it should be omitted altogether from the category of therapeutic agents.

*Politzer's method* is very little better, for auscultation purposes, than that of Valsalva, unless the physician can avail himself of the services of an assistant. If he attempts to inflate and auscultate at the same time he will find the task an extremely difficult one, more so in adult patients than in children. In the latter, as a rule, so little force is required to inflate the middle ears, that one can often perform both acts (auscultation and inflation) with comparative ease. So far as the method itself is concerned, it is in principle essentially the same as that of Valsalva. In both methods, for example, the middle ears are inflated by compressing the air that is imprisoned in the nasal and naso-pharyngeal cavities to such a degree that it overcomes the resistance offered by the walls of the Eustachian tube, and forces its way into the tympanum.<sup>1</sup> There are two respects, however, in which these methods differ from each other very widely. In the first place, Valsalva's plan necessitates a degree of venous congestion of the head and neck that is directly proportionate to the force used in compressing the air contained in the naso-pharyngeal space. This fulness of the blood-vessels must necessarily diminish in a measure the permeability of the Eustachian tubes; it also promotes the very pathological condition which in nine cases out of ten leads the patient to consult a physician. In the second place, Politzer's method, while it is at least equally efficient with that of Valsalva in compressing the air contained in the naso-pharyngeal space, is entirely free from the two objections which I have just mentioned. It produces no fulness of the blood-vessels, nor does it diminish the permeability of the Eustachian tube; on the contrary, it makes the patient open that channel so far as it is possible for him to do so by means of the muscles attached to its walls.

The apparatus which is ordinarily used in carrying out Politzer's method of inflation consists of three parts, viz., a rubber bag, provided at one end with a hard-rubber nozzle, and of such a size and shape that it can readily be grasped with the hand; a short piece of rubber tubing, of such a small calibre that the nozzle of the bag will fit it tightly; and lastly, either a cylindrical or a bulbous nose-piece. So many modifications of this apparatus have been introduced during recent years that one can no longer send to an instrument-maker for a Politzer's apparatus, and be at all sure that he will receive an instrument bearing a reasonably close resemblance to

<sup>1</sup> Occasionally the air also forces its way through the lachrymal ducts.

that which Politzer introduced about fifteen years ago. In my judgment, Politzer's original instrument, or, at all events, that which he was in the habit of using in 1869, is more thoroughly practical and efficient than any of the later modifications. The bag, which is made of soft black rubber, is pear-shaped, and ribbed longitudinally at intervals of about one inch. The egg-shaped white-rubber bags, and the flask-shaped green-rubber ones are much more difficult to manipulate successfully, especially if the operator's hand is rather small. The bag which I have used habitually since the spring of 1870 was purchased of Leiter, in Vienna, and is to-day apparently as perfect as when it left the maker's shop. A second one, purchased at the same time, was injured by being left in an exposed closet during the coldest part of the winter. The rubber became hard and brittle, and the manipulations to which the bag was then subjected caused it to crack open.

Some of the rubber bags are provided with a small opening protected by a valve, which closes the aperture the instant the bag is compressed. The advantage claimed for these bags is, that the danger of suction is thereby prevented. The truth is, that the suction-power exerted, when our grasp upon the bag is relaxed, is simply diminished in degree, but not entirely counteracted or rendered null. Personally, I prefer the original form of rubber bag, which has no opening except that which is provided at the nozzle. To prevent suction, when this form of bag is used, it is simply necessary to acquire the habit of never relaxing our grasp upon the bag until we have finished wiping the nose-piece with the towel (in Politzer's method), or until we have withdrawn the nozzle of the bag from the mouth of the catheter (in catheterization of the Eustachian tube).

With regard to the rubber tubing which connects the nose-piece with the nozzle of the bag, I may say that it is not an indifferent matter what sort of tubing is used for this purpose. In the first place, it is a very common error to use too long a piece. The advantage of a long piece is, that the operator, in the act of compressing the bag, can swing his arm freely without risk of violently twisting the nose-piece in the patient's nose. This advantage, however, is more than offset by the loss of power, which is spent upon the elastic walls of the tubing. A piece of black-rubber tubing, four or five inches in length, with a calibre of about four millimetres, and walls at least a millimetre and one-half in thickness, will be found to answer the desired purpose very well. It must be remembered, however, that a bag provided with such a short piece of rubber tubing is more difficult to manage successfully than one with a piece ten or twelve inches long. The arm must be kept almost perfectly still, and the muscles of the forearm and hand must do the entire work.

Not the least important part of a good Politzer's apparatus is the nose-piece. In adults the slightly curved cylindrical, hard-rubber nose-piece will be found entirely satisfactory in the great majority of cases. In children under four or five years of age, in whom the nasal orifice is quite small

and tender, a nose-piece consisting of a spherical or cone-shaped glass bulb will usually be found preferable to the cylindrical one. I have always found it a difficult matter to purchase ready made a good hard-rubber cylindrical nose-piece. It makes very little difference whether the proper curvature has been given to the instrument or not, as by means of heat we can readily obtain any curve that we may desire. The chief difficulty lies in the smallness of the calibre given to the rubber cylinder of the desired size externally. Thus, for example, I selected, from a large number of nose-pieces kept for sale by one of our best instrument-makers, the one having the largest calibre. The measurements were as follows: internal diameter,  $1\frac{3}{4}$  mm.; external diameter,  $4\frac{1}{2}$  mm. The nose-piece of the Politzer's apparatus which I use habitually gives the following measurements: internal diameter,  $2\frac{1}{4}$  mm.; external diameter,  $3\frac{1}{2}$  mm. A simple comparison of these figures will show at once the superiority of the latter nose-piece. It occupies less room in the patient's nose and allows a much greater quantity of air to be forced into the naso-pharyngeal cavities in a given period of time and with a given expenditure of force used by the hand in compressing the rubber bag. The proportions of the longer and shorter arms of the nose-piece, and the degree of curvature which it should possess, are correctly given in the accompanying cut (Fig. 14). As already stated, if the instrument offered for sale does not possess the proper degree of curvature, the desired shape can easily be obtained by heating the instrument over the flame of a spirit lamp until it becomes perfectly pliable. In his recently published treatise on otology<sup>1</sup> Politzer states that he is now in the habit of using exclusively an elastic nose-piece (as suggested by Löwenberg) in the place of the curved hard-rubber one. He remarks, however, that a certain degree of practice is necessary in using such a nose-piece, as one is very apt, in closing the nostrils over the soft-rubber tube, to obliterate its calibre entirely. The advantages claimed for this form of nose-piece are, that it is pleasanter for the patient (that is, less painful than when the hard-rubber one is used) and less likely to produce nose-bleed. Furthermore, the argument is brought forward that in suspicious cases the patient can, at a trifling expense, be provided with his own special nose-piece. I have tried this flexible form of nose-piece, but cannot say that I like it. I have also tried the plan of slipping a short piece of soft-rubber tubing over the ordinary curved hard-rubber nose-piece, and find it useful in cases where the unprotected instrument causes nose-bleed. In the great majority of cases,

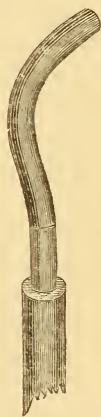

FIG. 14.—Nose-piece of Politzer's apparatus. (Natural size.)

<sup>1</sup> Lehrbuch der Ohrenheilkunde für praktische Aerzte und Studierende von Dr. Adam Politzer. Stuttgart, 1878.

however, I find the curved, cylindrical, hard-rubber nose-piece less troublesome to manage, and more effective, than any other instrument of which I have any knowledge.

Before entering into the details of Politzer's method of inflation, I ought to state that this operation of suddenly inflating the middle ears, although in the great majority of cases a perfectly safe procedure, should never be performed until after the condition of the drum-membrane and middle ear has been ascertained by direct inspection with the speculum and reflected light. I can recall the case of a gentleman, an army officer, in whose middle ear there were bands of adhesions which bound the membrana tympani down upon the promontory. I did not at that time appreciate the danger of forcibly inflating the middle ear under such circumstances, and consequently made no special effort to moderate the pressure exerted upon the bag. The effect of the inflation was to rupture some small blood-vessel in the middle ear and fill the cavity with blood, which speedily must have become clotted. The patient, who depended chiefly upon that ear for his power of hearing, at once noticed that the ear felt full, and that everything sounded less distinct than before. He never came to see me afterward, and I accidentally heard, about a year later, that the hearing in that ear had not returned to its previous degree of acuteness, and that my ill-advised interference was looked upon by the patient as the cause of this aggravation of his disability. On more than one occasion I have ruptured a highly atrophied drum-membrane or a so-called "cicatricial spot," by employing too great force in compressing the rubber bag. I have never known any harm to come from such ruptures of an atrophied or cicatricial drum-membrane. At the same time the effect of an accident like this upon the mind of the patient would be very likely to be of a character prejudicial to the physician who happened to be responsible for its occurrence.

With regard to the different steps of Politzer's method of inflation, very few words will suffice to explain the entire procedure. The patient is told to take a little water into his mouth, and to hold it there, with closed lips, until the physician says, Swallow! At this signal<sup>1</sup> he should forthwith swallow the water. The physician, on his part, is to hold the bag in his right hand, and then, as soon as the patient has taken the water into his mouth, he is to introduce the nose-piece into the patient's left nostril, using, if necessary, the left hand to aid him in accomplishing this. When the nose-piece of the instrument is in its proper position on the floor of the nasal passage, the physician should at once compress the nostrils over the rubber nose-piece, and give the patient the signal to swallow. The act of compressing the bag and forcing air into the nasal cavities should follow the signal almost instantly.

---

<sup>1</sup> If the patient is very deaf, the operator may use some other signal, such as a nod of his head, or a nudge with his knee.



This whole procedure, which seems to be a very simple affair, is found by many physicians to be at first quite difficult of execution. It may therefore prove useful to some if I mention in detail the difficulties which beset the operation. In the first place, it is a common mistake to allow the patient to take too large a quantity of water into his mouth. As the water is taken merely for the purpose of facilitating the act of swallowing, a mere sip is all that is necessary. If a mouthful is taken, the act of inflation is just as likely to force water out of the patient's mouth, over the physician's clothes, as it is to drive air through the Eustachian tube into the middle ear. Then again, the accident of "swallowing the wrong way" is much more likely to occur when a large than when a small quantity of water is taken.

In the second place, beginners are very apt to delay giving the signal to the patient too long a time after the nostrils have been compressed. The signal should be given and air should be forced into the naso-pharyngeal space as soon as possible after the operator has closed the nasal passages; for it must not be forgotten that, with both nose and mouth closed, the patient is unable to breathe, and consequently is rapidly approaching a condition of discomfort in which a prompt performance of the act of swallowing in response to the physician's signal, is no longer possible. Some patients find it very difficult not to open their mouths at the instant of performing the act of swallowing; others, and especially children, do it purposely, in order to escape the unpleasant sensation caused by the sudden compression of air in the nasal cavities. The whole purpose of the act of swallowing, in Politzer's procedure, is to render the naso-pharyngeal cavity a closed space by interposing the soft palate as an air-tight diaphragm between the oral and naso-pharyngeal cavities. There are other ways, however, in which the same result may be attained. For instance, the patient may be told to say "hic" or "hoc," or to distend his cheeks, by either of which means the desired shutting off of the naso-pharyngeal cavity will be effected just as perfectly as by the act of swallowing. At the same time I think it will be found that in every-day practice the swallowing plan gives greater satisfaction than either of the other two methods.

In the next place, if we wish to spare our patients unnecessary pain or the discomfort of a nosebleed, it is necessary that we should introduce the nose-piece of Politzer's apparatus with some degree of care. The large conical glass nose-piece can scarcely be used in such a clumsy or rough manner as to cause either pain or nosebleed; but the curved, cylindrical, hard-rubber instrument is very well adapted to cause both, unless introduced gently and in one particular way. Thus, for example, in each nasal orifice there is but one spot where the instrument can properly be allowed to remain while the nostrils are firmly compressed over it, viz., on the floor of the canal, as close as possible to the outer limit. In this position, the

instrument, if it has not been pushed in too far, will cause very little discomfort. If the nose-piece is properly curved, it is an easy matter to avoid the danger of pushing it in too far, by always allowing the straight portion of the instrument to rest against the patient's upper lip, in the direction of a line running from the outer angle of the nasal orifice to the outer angle of the mouth.

Finally, the question remains to be considered, how far we should modify the different steps of Politzer's procedure when the patient is a young child. I have already alluded to the fact that a spherical or cone-shaped glass nose-piece will be found better adapted to young children than the curved hard-rubber instrument. The pressure employed in compressing the bag must also, as a rule, be decidedly less than that usually employed in adults. The device of having the patient swallow a little water at a given signal can scarcely be resorted to in children under four years of age. In an infant it is simply necessary to adjust the glass bulb to one nostril, and then, while the other is kept closed by a finger of the same hand that holds the bulb in position, to compress the bag. It makes no difference whether the child's mouth is open or shut; the inflation seems to succeed equally well in both cases. In children of three, four, or five years of age, it is an easy matter to teach them to distend their cheeks at the moment the signal is given (blow!). If pain or a sense of fulness in the ear is complained of immediately after the inflation, it is a good plan to let the child swallow two or three mouthfuls of water, in order to facilitate the escape of air that may have become as it were imprisoned in the middle ear.

The employment of Politzer's method for therapeutic purposes might properly be discussed in this connection. For practical reasons, however, I think it will be better to take up this subject in connection with the individual diseases in the treatment of which this procedure plays an important part.

Of the three methods of inflating the middle ear mentioned at the beginning of this section, Valsalva's and Politzer's have been sufficiently described, and there remains still to be considered that by means of the Eustachian catheter. For purposes of auscultation this method is very justly preferred to both the other methods. When the catheter is used, the air passes through the Eustachian tube into the middle ear in a continuous current of one or two seconds' duration. This steadiness and long duration of the current afford the physician ample opportunity to listen deliberately to the character of the sounds which it produces. For purposes of diagnosis, therefore, this method possesses a decided superiority over the other two.

The Eustachian catheters offered for sale in the surgical-instrument shops are made of hard rubber, of German silver, or of coin metal. Those made of German silver have nothing to recommend them beside their cheapness. A well made hard-rubber catheter is an excellent instrument, and leaves

very little to be desired. It is very difficult, however, to find a well-made hard-rubber catheter; the calibre is rarely as large as it should be, or else, if the calibre is sufficiently large, the total diameter of the instrument is so great that we can use it only in exceptional cases. A good serviceable Eustachian catheter should have a calibre of about two and one-fourth or two and one-half millimetres, and a total diameter of not more than three and one-half millimetres. This proportion of calibre to total diameter is scarcely attainable in an instrument made of hard rubber. The largest rubber catheter that can ordinarily be bought in the shops, measures nearly four and one-half millimetres in its total diameter, while its calibre measures only two millimetres. For the majority of patients this instrument is too large, and yet its calibre is barely large enough to allow a current of air of the requisite force to reach the orifice of the Eustachian tube. On the whole, therefore, the silver catheter, if made of coin metal and properly proportioned, will be found to give the greatest satisfaction. I warn my readers, however, that very many of the silver catheters sold in the shops are even less serviceable than those made of hard rubber. The calibre is not one whit larger, in proportion to the total diameter, than that of the average rubber catheter; and when such is the case the latter instrument has decided advantages over the former. There is also another respect in which the silver instrument may be defective; the rim of the free end is often so sharp as to cause the patient pain, either during its passage through the nose, or while it lies in the mouth of the Eustachian tube. This defect, however, can easily be remedied.

With regard to the curve which a good Eustachian catheter should have, I may say that the one represented in the accompanying cut is that which I have found suited to the great majority of adult patients. Some of my colleagues use a straighter instrument, and others, one of even greater curvature; from which it is proper to draw the conclusion that the middle ear may be successfully inflated by variously curved catheters. To secure the most effective inflation, however, we should give the catheter such a curve that, when it is in position and air is forced through it, the direction of the escaping current will be the same as that of the Eustachian tube itself. The common error, so far as my observation goes, is to give the instrument a curve of too short a radius, which causes a large part of the force of the current of air to spend itself upon the upper wall of the Eustachian tube. In children from five to about twelve years of age, it will be found better to use a catheter that is even less curved than that represented in the cut; or one, at all events, in which the curve begins at a point considerably nearer the free end than is the case in this instrument.



FIG. 15.—Eustachian catheter. (About one-third the natural size.)

The rubber bag used for inflating the middle ear according to Politzer's method answers equally well for inflating this cavity through the Eustachian catheter. These bags are almost always provided with a rounded or somewhat olive-shaped end-piece, which may be screwed on or off at pleasure. When the catheter is to be used, it is a very common custom to substitute for this end-piece one that represents accurately a section of a cone, and that can therefore be made to fit air-tight into the cone-shaped orifice of the Eustachian catheter. I have tried both of these end-pieces, and give the preference unhesitatingly to the rounded or olive-shaped one. It fits the mouth of the catheter so accurately that the degree of leakage may practically be left out of the account. In this respect, therefore, it is essentially on a par with the cone-shaped end-piece. In all other respects, however, it is decidedly superior to the latter instrument. It can be removed instantly from the mouth of the catheter without disturbing the latter's position in the slightest degree, without causing the patient any of the discomfort which is very apt to accompany our efforts to disengage the tightly fitting conical end-piece, and, finally, without risk of exerting suction-power upon the mouth of the Eustachian tube.

While I believe that a written or *viva voce* description of the proper course to pursue in introducing the catheter into a patient's Eustachian tube may aid a beginner in his efforts to perform this operation successfully, I am quite positive that the greater part of the lesson must be learned by actual experience. It is of comparatively little use to say: at this point, turn to the left; at that, to the right, and so to direct the beginner's manipulations from the commencement to the end of the operation. For the beginning, it is true, we can lay down a sharply defined rule, which will hold good for all cases; for the end, also, we can give directions which will secure success in certainly the great majority of cases; for the intermediate portion, however, we can simply say: follow the instrument, even if it perform a complete revolution in its progress to the naso-pharyngeal space. These different steps of the procedure I may briefly describe as follows:

The physician should sit directly facing the patient, and on his right hand, within easy reach, should be his rubber bag, auscultation-tube, and a bowl or goblet, partially filled with water, and containing five or six catheters of different sizes and degrees of curvature. He should have his forehead-mirror in position, ready for use, as he may at the very beginning find it desirable to examine, under illumination by reflected light, the patient's anterior nares. Everything being in readiness, the operator should place the fingers of his left hand firmly upon the patient's forehead, and, with the end of his thumb, he should elevate as much as possible the end of the patient's nose,—the object of the latter procedure being to straighten the entrance to the nasal passage and in so far to facilitate the introduction of the catheter. This instrument should be held lightly by

the physician, between the thumb and forefinger of his right hand, and at no time should force be used in overcoming any obstacles that may be encountered. Just within the nasal orifice, the floor of the nasal passage rises up in the form of a ridge, the inner or deeper side of which is more abrupt than the outer one. When the catheter is first introduced into the nasal orifice, its outer end should be at a somewhat lower level, though in some cases we may begin at once with the instrument in a nearly horizontal position. To pass it beyond the ridge, and engage it in the lower nasal passage, the physician must elevate the ring end of the instrument until it occupies a nearly horizontal position. It is at this stage of the operation that the beginner is very apt to make a mistake. Instead of passing the catheter along the floor of the nasal canal, he slips it over the upper surface of the inferior turbinated bone, and, on reaching the naso-pharyngeal space, wonders why his efforts to turn the instrument into the mouth of the Eustachian tube cause the patient such great distress. A glance at the illustrations of this region, in some good treatise on anatomy, will show how easy it is to make this mistake. It is only necessary to push the beak of the instrument a short distance beyond the summit of the ridge, and we shall find it slipping only too easily along the wrong channel. When the catheter has been pushed beyond the ridge, and is actually resting upon the inferior turbinated bone, the elevation of the ring end of the instrument will not correct the error unless the catheter be withdrawn a certain distance. In the first stage of the operation, therefore, it is important to hug the floor of the nasal passage with the beak of the catheter, at least until the instrument has passed beneath the inferior turbinated bone, and is well engaged in the lower channel. As already stated, it is better, from this point onward, to let the instrument find its own way. By this I mean that if the catheter encounters some obstacle, we should abandon the attempt to push it onward in a certain fixed manner,—*i.e.*, with the beak always pointing downward and backward,—and should rotate the instrument slowly, while keeping up a gentle pressure from behind, until we find a position in which it no longer encounters opposition, but yields to the pressure which tends to drive it farther inward toward the naso-pharynx. As we wish the instrument, on first reaching the cavity, to lie with its beak turned directly downward, we should begin at once, after passing the obstacle referred to, to rotate the catheter back toward the desired position. If we fail in our efforts to overcome the obstacle encountered, we must either resort to an instrument of smaller diameter, or try to reach the Eustachian tube by way of the nasal passage of the opposite side. The latter course will usually be found the preferable one. When the catheter is in the naso-pharyngeal space, with its beak turned directly downward, we should first make sure of our bearings by pushing the instrument onward until we feel the resistance offered by the posterior pharyngeal wall. When the catheter is in this position, we know that if we rotate it far enough we shall carry the beak into what is known as

Rosenmüller's fossa, a slight depression located just behind the mouth of the Eustachian tube. Hence, if we wish to introduce the instrument into the latter cavity, we must draw it out a distance of two- or three-eighths of an inch, and then rotate it through an arc of about one hundred and thirty-five degrees (or until a line drawn through the plane of the ring attached to the catheter shall pass through the outer angle of the patient's eye). If we rotate the beak of the catheter first into Rosenmüller's fossa, and then draw it out a short distance, we can often feel the end of the instrument pass over the rounded eminence which constitutes the inner lip of the mouth of the Eustachian tube. As the distance of the tubal orifice from the posterior pharyngeal wall varies in different individuals, the method last described, of guiding our movements by aid of the sense of touch, rather than by rough estimates of distance, is the one to which most aurists, I think, give the preference. In some individuals the landmark which I have just described is so feebly developed, or the surrounding parts are so swollen, that the operator feels doubtful whether he has reached the mouth of the tube or not. In such cases the Giampetro-Löwenberg method will be found useful. According to this method, the catheter is to be rotated toward the Eustachian tube of the opposite side, and when its beak occupies a horizontal position, as indicated by the metal ring, the instrument is to be drawn out until the resistance of the posterior edge of the septum is encountered. The catheter is then to be rotated in the opposite direction, through an arc of at least one hundred and eighty degrees, into the mouth of the Eustachian tube which it is desired to reach. In all three methods, but especially in the one last described, the physician would do well to grasp the body of the catheter with the thumb and forefinger of the left hand before he performs the act of rotation with his right hand. In any event he will have to grasp it in this manner after the instrument finally reaches its proper position, as the right hand will be required for other purposes. The support thus afforded to the catheter is a very firm one, as the last three fingers of the left hand find a strong resting-place on the bridge of the patient's nose, or on the lower part of his forehead. So long as the operator's fingers press firmly against the patient's skull, he need have very little fear of the disturbing influence of a sudden motion of his head upon the position of the catheter.

When the physician believes that the beak of the instrument is lying in the mouth of the Eustachian tube, he should give the patient one end of the auscultation tube to place in the meatus of the corresponding ear, and should fix the other end tightly in his own auditory canal, preferably the left one.<sup>1</sup> With his right hand he should then grasp the rubber bag, and

---

<sup>1</sup> If the presence of the instrument in the naso-pharyngeal space causes the patient great discomfort, and especially if the act of swallowing is accompanied by pain, the physician may safely assume that the beak of the catheter is not lying in the mouth of the tube.

apply the hard-rubber nozzle of the instrument to the mouth of the Eustachian catheter. If the latter instrument is in the right position, and the Eustachian tube is not unnaturally contracted, he will hear the air streaming as it were into his own ear. If the catheter, however, occupies a wrong position, he will probably still hear the air streaming out of the end of the instrument, but it will no longer seem to be escaping into his own ear; the sound will appear to be more distant and less distinct.

In withdrawing the catheter from the nasal cavities, no special precautions are necessary. The instrument is first to be rotated back to its original position, with the beak pointing downward, and then it is to be drawn out gently from the nose.

So far as the operation of crossing over from one nasal passage to the Eustachian tube of the opposite side is concerned, very little need be said in addition to the preceding account. On the whole, I think the operation is somewhat easier to perform than the ordinary mode of reaching the tube. It is simply necessary to use a catheter with a curve of slightly greater length, in correspondence with the greater distance of the tubal orifice from the nasal passage through which the instrument is passed. In all other respects the precautions to be taken are precisely the same as those which have been recommended for the more direct operation.

In former years I experimented with catheters having a double curve, and thought at the time that in certain cases they enabled me to accomplish that which I had failed to do with the ordinary single-curved instruments. During the past three or four years, however, I have used only the latter variety of catheters, and do not remember to have felt the want of the others a single time. Those interested in the subject will find a full description of these double-curved catheters, by Dr. Henry D. Noyes, of this city, in the Transactions of the American Otological Society for 1870. In the volume for 1872 a description will also be found of the so-called "faucial catheter," an instrument devised by Dr. Oren D. Pomeroy, of this city. I have had no personal experience with the use of this instrument, and must confess that I am prejudiced, on *a priori* grounds, against its employment.

Besides the methods which I have already mentioned, there are other ways of ascertaining the condition of the pharyngeal end of the Eustachian tube. Thus, for example, in a few cases it is possible, by means of a Gruber's speculum introduced as far as possible into the nasal passage, and reflected light, to obtain a fair view of the mouth of the Eustachian tube. The mirror, however, must not be used in the manner which I have recommended (p. 34) for examinations of the ear; success can only be obtained when the eye of the observer is placed at the central aperture. This direct method of observation has been still further perfected by the invention of what are known as Zaufal's specula, which may be carried in even to the very entrance

itself of the tube. In many cases a good view of the tubal orifice and adjacent parts can be obtained by means of the laryngeal mirror and reflected light. Finally, a very good idea of the condition of the nasopharyngeal mucous membrane, and of the relations of the surrounding parts to the tubal orifice, may be formed from an exploration of this region with the forefinger (by way of the mouth).



## CHAPTER VI.

### DISEASES OF THE MIDDLE EAR.—NON-PURULENT FORMS.

#### *Preliminary Remarks.*

VERY great obstacles stand in the way of him who attempts to make a pathologico-anatomical classification of the diseases of the middle ear. In the first place, the dividing line between the different diseases are oftentimes more imaginary than real. Thus, for example, an acute inflammation of the middle ear may go so far as to cause a perforation to take place in the drum-membrane, and pus to flow for a certain length of time through this opening and out into the external auditory canal. We classify the disease, under these circumstances, as an acute purulent inflammation of the middle ear (*otitis media purulenta acuta*). Or, the attack may be equally painful, but owing to the greater toughness of the drum-membrane, or to the more open condition of the Eustachian tube, the inflammation begins to subside before the pressure exerted by its engaged products causes the drum-membrane to rupture. This pathological process in the middle ear would be classified by many authors as an acute catarrhal inflammation of the middle ear (*otitis media catarrhalis acuta*). The anatomical changes are precisely the same in both cases, and yet, through accidental influences, the one is associated with a perceptible discharge of pus, while the other is not accompanied by such a discharge. The presence or absence of the visible discharge is, therefore, the circumstance which shapes our decision in classifying these two apparently different processes. It is also for the same practical reasons that we speak of diseases of the Eustachian tube and of the mastoid cavities, both of which are essential portions of the middle ear. An inflammation in the Eustachian tube means almost invariably an inflammation, at the same time, of the tympanic cavity; and an entirely independent inflammation of the mastoid antrum or adjacent cells is certainly a very rare thing, if indeed it ever occurs. A classification upon a strictly anatomical basis is therefore scarcely attainable, and we are obliged to fall back upon that which is now almost universally employed by writers on diseases of the ear, viz., a classification based partly upon anatomy, and partly upon symptomatology. In this connection I should

like to give expression to the hope that the terms "catarrh" and "catarrhal" may at an early day be employed in a fixed and well-defined sense. At present, the term "catarrh" is used differently by different writers. In the United States it is applied almost invariably to those cases of inflammation of the middle ear in which the drum-membrane remains intact. In Germany the term is generally used in the same sense, though now and then we read of a "purulent catarrh." In Great Britain the term appears to be used indifferently for both classes of cases. Judged from an etymological standpoint the term catarrh may very justly be considered as including the idea of a discharge. For practical reasons, however, it seems better to restrict the use of the term "catarrh" and "catarrhal" to those cases of middle-ear disease which are not accompanied by a perforation of the drum-membrane nor by a visible discharge of pus or muco-pus from the middle ear.

#### EUSTACHIAN TUBE.

*Simple catarrh.*—I have already mentioned the fact that the mucous membrane lining the Eustachian tube and middle ear is in reality a continuation of that which lines the naso-pharyngeal space. A catarrhal inflammation<sup>1</sup> of the latter region does not necessarily imply an extension of the disease to the Eustachian tube, but an inflammation of the Eustachian tube is scarcely to be thought of except in connection with a naso-pharyngeal catarrh. The ordinary "cold in the head," which is the commonest type of an acute naso-pharyngeal catarrh, rarely runs its course without involving at least a portion of the Eustachian tube. The subjective symptoms in this subacute form of Eustachian catarrh are: a sense of tightness or pressure in the ear of the side affected; a slight ringing noise; a sense of fullness in the ear after blowing one's nose; crackling noises during this act, and also during eating, swallowing, or gaping; slight diminution in the acuteness of hearing; and, finally, in some cases slight darting pains. The appearances presented by the membrana tympani vary according to the degree of obstruction which the swelling of the tubal walls offers to the ventilation of the middle ear, and also according to the duration of the obstructed state. If the obstruction is slight, the drum-membrane may present a perfectly normal appearance; if the walls of the tube are decidedly swollen, the air in the cavities of the middle ear soon undergoes absorption, and the tendency toward the establishment of a vacuum then produces well-marked changes in the appearance of the membrana tympani. In the first

---

<sup>1</sup> The distinguishing characteristics of such a catarrhal inflammation are, increased vascularity, increased secretion, and a varying degree of infiltration of the mucous membrane.

place, the membrane appears sunken or drawn inward beyond its natural position (see p. 126). In addition to this the coloring of the membrane presents a deeper hue, which may border either on the purple or on the green, according to circumstances which I am unable to define with precision. In a general way, however, it may be said that the greenish hue is often an indication that fluid exudation has already taken place in the tympanic cavity, while the purplish or red color simply furnishes evidence of a distended condition of the blood-vessels of the mucous membrane. When the changes have gone as far as this, we are no longer able to draw a dividing line between a Eustachian catarrh and a subacute catarrhal inflammation of the middle ear. In fact, the same observer would be likely to use either term indifferently, in a series of cases, without being able to give satisfactory reasons why he used one term in preference to the other.

So far as the course of the disease, its treatment, etc., are concerned, I think all these questions may be considered to greater practical advantage under the section relating to catarrhal inflammation of the middle ear (see farther on).

*Other pathological conditions of the Eustachian tube.*—We sometimes see cases in which, although other parts of the organ of hearing may be involved, the condition of the Eustachian tube constitutes the most salient feature of the pathological picture presented. For example, the tube may be found impervious to air, or it may be so widely patent that the slightest condensation or rarefaction of the air in the naso-pharyngeal space causes a corresponding outward or inward movement of the drum-membrane. Again, paralysis or spasmodic contractions may take place in the muscles which separate the inner from the outer wall of the pharyngeal portion of the Eustachian tube. Destructive processes may terminate in the binding together of these walls at the pharyngeal orifice. Finally, foreign bodies may find their way from the nose into the Eustachian tube. To each of these processes or conditions I will now devote a little space.

I have already referred to the slighter degrees of *narrowing* which characterize a simple acute or subacute Eustachian catarrh. In this place I propose to consider only those cases in which the stenosis is more marked and permanent. The diagnosis of this condition is easily made by a simple inspection of the membrana tympani with speculum and reflected light. If the tube is completely impervious to air, and has been so for a sufficient length of time, the picture presented is a very striking one. The drum-membrane will be found lying like a thin, glistening film in close contact with the promontory, mouth of the Eustachian tube, anvil and stirrup. A deep depression posteriorly marks the vicinity of the entrance to the antrum. The lower end of the long process of the anvil and the head of the stirrup appear to project directly into the meatus. In fact, a superficial observer might easily be led to the conclusion that the membrana tympani had been destroyed, and that he was looking directly into the tympanic

cavity. After inflation by Politzer's method the picture presented at the fundus of the meatus changes completely. The highly atrophied drum-membrane appears to be blown out in the form of a tomato; the depression caused by the immovable handle of the hammer corresponding with the hilus for the stem of the fruit. Finally, the small whitish prominence of the long process of the anvil will be found to have entirely disappeared from view.

Treatment is of very little avail in these cases of extreme atrophy of the drum-membrane. The *substantia propria* having been entirely destroyed, the membrane no longer possesses the power of transmitting sonorous impulses to the handle of the hammer. In fact, the high degree of elasticity which such an atrophied membrane possesses renders it a positive obstacle to the transmission of such impulses to the labyrinth. Complete extirpation of the membrane, under these circumstances, would undoubtedly for the moment materially improve the patient's hearing: the sonorous impulses would produce a more decided effect, if they came in direct contact with the foot-plate of the stirrup than if the latter ossicle were enveloped in a soft, highly elastic membrane. However, if the drum-membrane, in these cases, has ceased to be of value for acoustic purposes, it still retains its protective power in almost undiminished degree. For this reason, and also for others which I will mention in another place, I am not in favor of interfering surgically in these cases. The question then presents itself, How much shall we gain—or rather, how much will the patient gain—if we succeed in restoring the Eustachian tube to a normal degree of patency? With a highly atrophied *membrana tympani*, the gain, I imagine, would at best be trifling. However this may be, I can only say that my efforts to restore the Eustachian tube to a normal degree of patency, in cases such as I have described above, have invariably proved unsuccessful.

I might state here that a highly atrophied *membrana tympani* possesses very little regenerative power. In one case (a fairly healthy young man, twenty-one years of age) I incised such an atrophied membrane on the twenty-seventh day of December. The edges of the wound, which was fully four millimetres in length, gaped widely apart. On the 30th I found the wound still gaping, and not a trace of inflammatory reaction could be discovered. On the 13th of January a free opening still existed in the drum-membrane. For how long a period it persisted afterward I am unable to say.

In all, or nearly all, of these cases of prolonged closure of the Eustachian tube, we can scarcely fail to notice the condition of the naso-pharyngeal cavity. Enormously enlarged tonsils, adenoid vegetations, or a more diffuse form of hypertrophy of the mucous membrane, will almost invariably be found to be present. If these conditions reach a high degree of development during the first years of life (from two to four, for example), they may produce not merely a sunken and atrophied condition of the *membrana*

tympani, as the direct result of the prolonged closure of the Eustachian tube, but even, in a few cases, secondary lesions in the labyrinth, which may destroy the hearing-power altogether.

Although in the great majority of cases the obstruction to the entrance of air is due to a diffuse swelling of the walls of the tube, in a few cases a more localized lesion will be found. Thus, for example, I once had the opportunity, through the kindness of Dr. Goodwillie, of this city, of seeing a well-marked instance of closure of the pharyngeal orifice of the Eustachian tube by a band of connective tissue, which stretched like a bridge from one side of the orifice to the other. As I very rarely employ posterior rhinoscopy as an aid to diagnosis in diseases of the ear, I am unable to state how frequently such lesions are encountered. Dr. Goodwillie, however, assures me that he has seen several instances similar to the one which I have just described. In looking through the back numbers of the *Archiv für Ohrenheilkunde*, I find that two similar cases have been reported, one by Schwartze<sup>1</sup> and one by Lindenbaum.<sup>2</sup> Other instances are also mentioned by Schwartze in his recent treatise on the pathological anatomy of the ear.<sup>3</sup> In the same work will be found descriptions of other varieties of tubal lesions, with which I have had no personal experience.

*Unnatural patency of the Eustachian tube* is rarely encountered in practice. In both of the cases which have come under my observation the patient did not seem to be conscious that the ear was in any respect peculiar. Both patients consulted me for the relief of a slowly-increasing deafness, associated, in one case, with a distressing tinnitus. In the first instance I found a large, sharply-defined, oval cicatrix occupying the posterior inferior quadrant, and encroaching a little upon the superior quadrant. As I watched the drum-membrane, through the speculum, and by means of reflected light, I noticed that this cicatricial portion performed well-marked to-and-fro movements, which corresponded accurately with the patient's expiration and inspiration. When she held her breath, the cicatricial membrane remained perfectly motionless. Inflation by means of Valsalva's method caused the cicatrix to protrude in the form of a well-defined hemispherical tumor; but as soon as the pressure was withdrawn, the cicatrix instantly returned to the plane of the surrounding membrane, and again performed its to-and-fro excursions, synchronously with the respiratory movements. In the second case, the entire membrana tympani presented a decidedly atrophied condition. The tip of the manubrium mallei was lacking. On questioning the patient I ascertained that in childhood she had been subject to a discharge from that ear. From these facts—viz., the absence of the end of the handle of the hammer, and the existence of otor-

---

<sup>1</sup> Bd. I., S. 214.

<sup>2</sup> Ibidem, S. 295.

<sup>3</sup> Translated by J. Orne Green, M.D.; Houghton, Osgood & Co., publishers. Boston, 1878.

rhoea during childhood—I drew the conclusion that the unusually thin membrane was not, as I first supposed, an atrophied membrana tympani, but represented a newly formed drum-membrane. Whenever the patient performed the act of swallowing, this cicatricial or newly formed membrane performed a distinct to-and-fro excursion. The respiratory movements, however, caused no visible excursion of the membrane. It is quite possible that, notwithstanding this absence of a respiratory excursion, the Eustachian tube was just as patent in this as in the first case. The much greater area of the cicatricial portion in the latter case would necessitate a correspondingly smaller excursion of any one portion of the membrane to which I might direct my attention,—an excursion probably too small for the naked eye to detect.

In seeking for a cause for the extraordinary patency of the Eustachian tubes in these two cases, we should bear in mind that both of them furnished unmistakable evidence of a pre-existing destructive inflammation of the middle ear. Instances are on record where such an inflammation caused the destruction of the lower wall of the osseous portion of the Eustachian tube, and eventually led to a fatal issue through ulceration of the walls of the carotid artery. If, however, the progress of such a destructive inflammation should be arrested before the carotid artery became involved, and if reparative action should then set in, I can see no good reason why an unnaturally patent Eustachian tube should not be the ultimate condition left when the ulcerated parts had fully healed. Again, I am not at all certain that an unnatural patency of the Eustachian tube may not result from a change in the relations of the soft parts which immediately surround this canal. Some years ago, while gaping, I suddenly discovered that I had unconsciously rendered one Eustachian tube unnaturally patent. I succeeded in keeping my jaws in this peculiar position long enough to satisfy myself that it was a possible thing to maintain the Eustachian tube in a perfectly patent condition for a shorter or longer time, according to the will of the experimenter. The rushing sound caused by the air as it passed to and from the middle ear with each act of respiration, the easily felt to-and-fro movement of the drum-membrane, and the cool sensation caused by the moving current of air, all furnished unmistakable evidence of the existence of an open channel of some size between the naso-pharynx and the middle ear. I have often tried since to reproduce this condition, but have only succeeded partially. It is not an uncommon thing, however, for patients who suffer from chronic Eustachian catarrh, to learn the knack of twisting their jaws in such a way as to open, for an instant, the obstructed Eustachian tube, and in this manner to obtain relief from the sensation of pressure which many of them find so annoying.<sup>1</sup>

---

<sup>1</sup> For additional information on this subject see Vol. I. of the *Archiv für Ohrenheilkunde*, pp. 96 and 139 (Reports of Cases by Lucae and Schwartze).

*In spasmodic contractions of the muscles of the Eustachian tube*, a positive diagnosis can scarcely be made without a rhinoscopic examination. At the same time, from the history of the case, and from the absence of any visible motion of the drum-membrane, we may infer that the peculiar snapping noises, which constitute the only appreciable symptom of the affection, are due to spasmodic contractions of those muscles which pull the inner from the outer wall of the mouth of the tube. I have seen but one well-marked instance of this affection. In this case, unfortunately, no contractions occurred during the short time spent at my office, and I was therefore unable to make a positive diagnosis. However, from the condition in which I found the drum-membrane, and from the account which the patient gave of his ailment, very little doubt can be entertained with regard to its nature. The patient, an intelligent man about fifty years of age, and in apparently good health, gave the following history: About seven years previously he consulted a physician for deafness and a sense of fulness in the right ear, and the removal of a large mass of impacted cerumen gave him decided relief. During the following year or eighteen months he remained free from all aural symptoms. Then he began to experience, from time to time, noises of a peculiar character, which followed each other in quick succession like a series of taps, but never lasted longer than a few seconds at a time. He compared the sounds to the pattering of rain upon a tin roof. For a period of at least five years he had continued to experience these spasmodic noises, but had never before consulted a physician for the purpose of obtaining relief from his troublesome ailment. On examination I found both drum-membranes very nearly normal in appearance. The hearing, for the tick of the watch, was reduced to about  $\frac{1}{2}$ . There was no evidence of anything like an active naso-pharyngeal catarrh, although the diminution in the hearing power was probably to be attributed to the effects produced by this disease during some earlier period of its activity. (The patient was not seen again.)

Cases have been reported in which the snapping noises were associated with synchronous, easily recognizable excursions of the drum-membrane. From this circumstance two inferences have been drawn: first, that the excursions observed were due to spasmodic contractions of the tensor tympani muscle; and second, that the noises heard were due to the sudden vibrations which these spasmodic contractions of the tensor tympani muscle produced in the drum-membrane. The latter inference is at variance with certain well-established facts. For example, in inflating the middle ear according to Politzer's method, we cause just such a sudden excursion of the drum-membrane to take place as that which would follow a spasmodic contraction of the tensor tympani muscle; and yet I do not remember ever to have heard, under these circumstances, any noise that could be attributed solely to the motions of the drum-membrane. A parchment-like transformation of this membrane might possibly render its more violent ex-

cursions distinctly audible ; but in the case reported above, and also in the few published cases to which I have had access, no such parchment-like condition of the membrana tympani existed. In the next place, in Schwartz's account of a case<sup>1</sup> of "spasmodic contractions of the tensor tympani muscle" it is distinctly stated that on inspection of the pharynx, during the occurrence of these spasmodic contractions, the soft palate was seen to rise and fall involuntarily, and synchronously with the noises. In this case, therefore, we cannot exclude the possibility that the noises were produced by the spasmodic separation of the pharyngeal lips of the Eustachian tube, and not by the visible excursions of the drum-membrane. In fact, it is not satisfactorily demonstrated in this or in any of the other published cases of which I have any knowledge, that the excursions observed in the drum-membrane were really due to contractions of the tensor tympani muscle. The question naturally suggests itself in this connection, Why might not these excursions of the membrana tympani have been produced by the alternate rarefaction and condensation of the air in the middle ear, which the spasmodic contractions of the tubal muscles caused? The answer might be made that in the published cases of spasmodic objective noises of clearly tubal origin, the membrana tympani invariably remained motionless. This evidence seems to me simply to justify the conclusion that in these cases the spasmodic contraction of the tubal muscles did not suffice—probably by reason of the swollen condition of the mucous lining of the tube—to cause any disturbance in the condition of atmospheric pressure within the middle ear. If we could readily and safely divide the tendon of the tensor tympani muscle, in those cases of this class which are accompanied by visible excursions of the drum-membrane, we should possess the means of settling this disputed question in every doubtful case. Without this operation, however, I do not see how we can, with any degree of positiveness, pronounce a case to be one of spasmodic contractions of the tensor tympani muscle.

A very full discussion of this whole subject will be found in Burnett's Treatise on the Ear.<sup>2</sup>

Quite recently Edward Woakes, of London, has published a paper<sup>3</sup> in which he expresses the opinion that a loss of power in the *palato-tubal muscles* (the levator and the tensor palati molliis) may play an important part in diminishing the acuteness of hearing. He describes two classes of cases, one with unilateral and the other with bilateral paresis. The lack of symmetry in the motions of the soft palate enables one easily to recognize the latter form of paresis, while the chief characteristic of the bilateral

---

<sup>1</sup> Archiv für Ohrenheilkunde, II. Bd., S. 4.

<sup>2</sup> Published by Henry C. Lea, Philadelphia, 1877.

<sup>3</sup> Throat-Deafness associated with Paresis of the Palato-Tubal Muscles, *American Journal of Otology*, Vol. I., No. 4, 1879.



form is a marked absence of sensitiveness on the part of the soft palate and uvula. Speaking of the nature of these forms of paralysis, Dr. Woakes says that it is certainly not to be referred to a central origin. "On the contrary, these cases belong essentially to loss of vaso-motor nerve-power affecting one or more ganglia of the sympathetic system." Farther on he says: "These vaso-motor pareses are very local in their manifestations, and depend entirely on the condition of the *nervi vasorum* of the nutrient arteries of the motor sensory nerves, and not at all on the condition of the sensori-motor centres. It is a question of nutrition of the muscular nerves themselves, and this depends on the blood-supply, which again is regulated by the vaso-motor nerves. These patients are often anæmic and have undergone mental worry, besides physical wear and tear. Under such circumstances, the nerve-force is readily exhausted, especially that of the sympathetic system. Some particular ganglion parts with its force more readily than the rest. It is like an exhausted galvanic cell; you must recharge it before it will act. But while thus waiting for recharge, the coats of the vessels it should control become the play of physical forces, and under the influence of the heart's impulse they stretch and are distended with blood. This interferes with the nice balance between arterial tension and tissue demand which is essential to nutrition, and hence malnutrition results as far as the nerve-tissue is concerned, and hence there is defective motor function. Mechanical pressure exerted upon the motor fibrillæ is an important factor in the production of this paresis, and is due to the great accession of blood within the nerve-sheath when the nutrient vessels, being deprived of their inhibitory control, experience an enormous dilatation of their calibre." This description of the pathology of paresis of the palato-tubal muscles is followed by an account of a case illustrating the bilateral form of the disease. From this account it appears that in all but two respects this case is identical with a not uncommon type of catarrhal inflammation of the middle ear and Eustachian tube. The points of difference are these: the previous history of the case certainly justified the assumption that an element of nerve-exhaustion entered into the etiology of the apparently local disease; and in the second place, inspection of the soft palate revealed the fact that a marked loss of power had taken place in its component muscles, a loss of power so great "that a strong faradic current applied to the palate excited no muscular action, and was scarcely felt by the patient."

Until I had read Dr. Woakes's interesting paper, I was not aware of the existence of any form of aural affection in which paresis of the palato-tubal muscles—and probably also of the tensor tympani and stapedius muscles, which are supplied by the same nerves—constituted the prominent feature of the disease. During the past few months I have taken pains to examine all my cases of subacute catarrhal inflammation of the middle ear, depending apparently on a similar state of the naso-pharyngeal mucous membrane, with

special reference to the pathological views which Dr. Woakes has put forward in the paper referred to above. Thus far, however, I have failed to discover a fairly well-marked instance of deafness of recent date, which appeared to me to depend upon paresis of the palato-tubal (and intratympanic) muscles. In several of the cases the previous history pointed very plainly to nervous exhaustion—by which expression I mean prolonged mental worry and lack of rest—as an important factor in the causation of the deafness, but in none of these was I able to demonstrate any muscular paresis of the soft palate. In two instances I found this organ and the naso-pharyngeal space so lacking in sensitiveness that I was able to paint the entire region bordering upon the tubal orifices with a twenty-grain solution of nitrate of silver in a perfectly deliberate manner. This procedure, which ordinarily causes the muscles of this region to contract strongly the instant the parts are touched, excited no muscular reaction whatever: the soft palate remained perfectly motionless and relaxed. On the other hand, when these patients said “ah” or “ee,” the soft palate rose promptly and symmetrically, showing clearly that no very decided degree of muscular paresis existed.

As these observations extend over a period of only four or five months, I should not be warranted in expressing any decided opinion for or against the view that paresis of the palato-tubal muscles constitutes an important factor in the causation of certain cases of deafness. I have often thought that the difficulty sometimes experienced in inflating the middle ears of elderly people by Politzer's method, must be largely due to a paretic condition of the muscles which open the tubes. The correctness of this view is rendered probable by the fact that often, in such a case, when air is forced into the Eustachian tube by means of the catheter, it is heard to enter the middle ear through a channel of normal size. The success of the inflation in Politzer's method is dependent in great measure upon the co-operation of the dilator muscles of the tube; on the other hand, in inflation by means of the catheter, this muscular co-operation is lacking, and the degree of success is directly proportionate to the force of the current of air driven through the catheter. The degree of force attainable by the latter method is much greater than that which can be attained by Politzer's method. It is therefore easy to understand how, in these cases of (assumed) paresis of the tubal muscles, inflation by Politzer's method fails to overcome the inertia of the more or less rigid walls of the tube, and to force air into the middle ear; while by catheterization no difficulty whatever is experienced in accomplishing this object. In further justification of this view I might mention the fact that post-mortem examinations of the tubal muscles have in certain instances revealed the existence of a high degree of fatty degeneration.<sup>1</sup>

---

<sup>1</sup> See, for example, a paper on this subject by Weber, in the *Monatsschrift für Ohrenheilkunde*, III. 4, April, 1869.

In the matter of treatment, Dr. Woakes lays great stress on the importance of administering such remedies as steel, phosphorus, hydrobromic acid, and cod-liver oil. "Phosphorus, steel, and hydrobromic acid possess a definite relationship to the vessel area innervated by the ganglia whose defective action produced the phenomena of paresis described in the former part of this paper. Their action is to increase the inhibitory power exercised by the ganglia over the vessels from which it had been withdrawn, and when this is restored, an involution process as regards the morbid effects of its absence at once commences, which speedily ends in the removal of the symptoms. This appears to be the rationale of the action of so-called 'nervine tonics.' The therapeutic effect of the salts of ammonia is essentially of this character, and was illustrated in the case of another patient in whom palatal paresis of the left side existed to a very marked extent, without deafness, but with loud tidal noises in the left ear, and to whom I gave five-grain doses of sesquicarbonate of ammonia three times daily with the result that all the symptoms disappeared in a fortnight." In addition to the internal treatment, Dr. Woakes recommends the employment of the induced current, in the following manner: "One pole should be applied to the veil of the palate posteriorly, for which purpose the laryngeal electrode is very suitable; the other, an ordinary sponge-holder, is placed outside the neck over the superior cervical ganglion, which is reached by making deep pressure behind the angle of the jaw."

#### ACUTE AND SUBACUTE INFLAMMATION OF THE MIDDLE EAR.

##### *General Consideration.*

An acute or subacute inflammation of the middle ear may run such a variety of courses and may produce such different lesions that, for the sake of convenience, at least, if for no other reason, it will be found easier to describe these different pathological pictures as so many distinct types of disease. Thus, for example, we can make two main subdivisions, the *catarrhal* and the *purulent* forms of *acute inflammation of the middle ear*. The catarrhal form, again, may be subdivided into the following subordinate yet well-marked types: *simple acute and subacute inflammation* (otitis media catarrhalis acuta et subacuta); *serous or mucous exudation into the middle ear* (hydrotyimpanum; otitis media serosa sive mucosa); and *hemorrhagic exudation into the middle ear* (hæmotyimpanum; otitis media hemorrhagica). The second main subdivision, the purulent variety of acute inflammation of the middle ear, may also be subdivided into a syphilitic, a tubercular, and a simple form; at the same time it should be stated that it is only in exceptional cases that we can recognize anything distinctly syphilitic or tuber-

cular in the pathological changes that take place in an acute or subacute otitis media purulenta.

The same causes may produce at one time a catarrhal, at another a purulent form of inflammation of the middle ear, according to the degree of vigor with which they act, and also partly according to the condition of the ear, and of the general nutrition of the individual at the time of the attack. Among the different causes of an acute inflammation of the middle ear the most frequent is undoubtedly a sudden chilling of the surface of the body. Next in order come the eruptive fevers, such as scarlet fever, measles, and small-pox. Typhoid fever, and perhaps also typhus fever, may give rise, occasionally, to an acute affection of the middle ear. A blow or a fall on the side of the head may lead to the same result by causing a diastasis or even a fracture of the bony walls of the tympanum. Direct violence to the parts may be followed by acute inflammation. The introduction of fluids through the Eustachian tube into the middle ear, either accidentally—during ocean-bathing, for example, or during the use of the nasal douche or one of its substitutes—or for therapeutic purposes, is very apt to be followed by a severe type of acute inflammation of the middle ear. Several years ago I published an account of several cases of acute otitis media, all of which were brought on by flooding the nasal cavities by means of the nasal douche, the posterior nasal syringe, or the snuffing method. I then gave the opinion, in corroboration of that previously expressed by Dr. Roosa, that all these procedures, however carefully carried out, were not free from the risk of setting up an acute inflammation of the ear. While I should like to discuss this question more fully, I must rest content at present with the mere statement that my later experience has only served to strengthen the opinion expressed at that time. Finally, in children the internal administration of quinine sometimes gives rise to an acute or subacute inflammation of the middle ear. I have seen several such cases, and in two of them (from three to five years of age) I was able to study the changes in the ear at such short intervals of time that I could no longer doubt the direct effect of the quinine upon the degree of fulness of the blood-vessels of the tympanum. As each additional dose of the drug was administered, the membrana tympani became more and more congested; and by the time 6 grains, in one instance, and 8 in the other, had been taken, the child was in evident suffering from pain in the ear. No further doses were given, warm applications were made to the ear, and the pain soon subsided. In all of these cases there already existed, before the quinine was administered, a slight tendency to naso-pharyngeal (and probably Eustachian) catarrh, as shown by the enlarged state of the tonsils and by the presence of an excessive amount of ropy mucus behind the soft palate. Hence I am not prepared to say that, in a perfectly normal state of the tympanic and tubal mucous membrane, quinine is competent to excite an acute inflammation, but simply that, in young children more particularly, this drug is

capable of fanning a slight and perfectly painless tubal and perhaps tympanic catarrh into a decidedly acute inflammation of this region.

*General Symptomatology.*

The two main types of acute inflammation of the middle ear, the catarrhal and the purulent, are characterized, up to a certain stage of the disease, by the same series of symptoms. It is only when the pressure of the fluid exudation within the tympanum causes the membrana tympani to rupture, that the distinguishing features of the purulent variety manifest themselves. On the other hand, in the catarrhal form, after the inflammation has reached its highest degree of activity, the subsequent course of the disease is characterized either by a gradual subsidence of all the symptoms, or by the development of certain conditions which justify the employment of the terms "hydrotyimpanum" and "hæmotyimpanum." So far as the syphilitic and tubercular varieties are concerned, the symptomatology of these will be considered in a separate section.

CATARRHAL INFLAMMATION OF THE MIDDLE EAR.

The symptoms which characterize a subacute catarrh of the middle ear are precisely the same as those which have already been enumerated under the head of Diseases of the Eustachian Tube, viz., diminution in the acuteness of hearing, a sense of fulness in the ear, subjective ringing or singing noises, unpleasant resonance of one's own voice in the affected ear, subjective crackling noises when the nose is blown, and perhaps occasional twinges of pain. Any or all of these symptoms may be present in one and the same case.

So far as the *pathology* of the disease is concerned, in the great majority of cases the inflammation commences in the naso-pharyngeal space and spreads thence to the middle ear through the Eustachian tube. A subacute Eustachian catarrh, with more or less swelling of the mucous membrane which lines the middle ear, would therefore represent the mildest type of inflammation of this region. The following case will serve as a good illustration of such a type of

*Subacute catarrhal inflammation of the middle ear.*—The patient, a young man twenty-two years of age, was seen, for the first time, at the New York Eye and Ear Infirmary, on the seventeenth day of May, 1871. He stated that about three weeks previously he began to experience difficulty in hearing, and that it steadily increased up to the time of visiting the Infirmary. It was accompanied by a slight ringing noise in the head, but there was no pain nor any other symptom sufficiently marked to attract

his attention. He also stated that during childhood he had been subject to frequent earaches. At the time when I saw him he was still able, under favorable circumstances, to understand ordinary conversation quite well. The hearing distance, as tested by the watch, was : R.  $\frac{9}{12}$  ; L.  $\frac{9-5}{12}$ . Both external auditory canals were perfectly normal. On the left side the membrana tympani was appreciably sunken, and through it the outlines of the long process of the anvil were distinctly visible. Essentially the same condition of the drum-membrane existed on the right side. The tonsils were moderately enlarged, and the entire pharyngeal mucous membrane presented an unnaturally red appearance. Inflation by Politzer's method caused air to enter the left middle ear, but not the right. A crackling sound characterized the entrance of the air into the left tympanum. The hearing distance for the watch, on the left side, rose from  $\frac{9-5}{12}$  to  $\frac{1-5}{12}$ , as a result of the inflation.

The treatment consisted in mopping out the naso-pharyngeal space with a solution of nitrate of silver, of the strength of twenty grains to the ounce of water, and in inflations by Politzer's method. At first the catheter was used two or three times, on the right side, as a means of inflating the middle ear ; but subsequently, as the swelling of the tube subsided, Politzer's method alone was found to be sufficient. The greater part of the time the patient visited the Infirmary only once a week, thus materially delaying his recovery. However, steady improvement took place in the condition of the parts and in the acuteness of the hearing. On the 1st of July, when treatment was discontinued, the hearing distance for the watch was : L.  $\frac{6}{12}$  ; R.  $\frac{7}{12}$ . On the 5th of August he reported that no relapse had occurred, and that he heard as well as ever before. As he had been subject to earaches during childhood, it is more than probable that his hearing, before the attack described above, was not normal, at least for sounds as delicate as the ticking of a watch.

The absence of pain, in the case just described, is the feature which characterizes it as a *subacute*, in contradistinction from an *acute* attack of inflammation of the middle ear. The comparatively long duration of the disease, and the incompleteness of the recovery, so far at least as the hearing is concerned, justify the assumption that the attack partook of the nature of an exacerbation of a pre-existing, but very slight naso-pharyngeal, Eustachian, and tympanic catarrh, and was not an entirely fresh attack, originating in an individual with perfectly normal ears. Had the affection been of the latter nature, the restoration of the hearing would have been perfect, and the total duration of the attack would have been much shorter. Such cases are quite common and I will therefore not stop to narrate an instance.

In a few cases of subacute catarrhal inflammation of the middle ear I have observed conditions which lead me to believe that the swelling of the mucous membrane may, in certain cases, be greatest at and near the tym-

panic orifice of the Eustachian tube. The most striking feature in these cases is the apparently contradictory relation which exists between the patency of the tube and the tensely bulging condition of the drum-membrane. This protrusion outward of the membrane, in the cases referred to, was clearly due to the presence of an excessively large volume of air in the cavities of the middle ear. In one of them I pricked the bulging membrane, whereupon it instantly resumed a perfectly natural position. As already intimated, no difficulty whatever was experienced in forcing air into the middle ear, and it appeared to enter it readily and without râles. A swollen condition of the tube at its pharyngeal orifice, or at any point along its course, would have interfered materially with the entrance of air into the tympanic cavity, and would have caused the drum-membrane to occupy a depressed or sunken position rather than a bulging one. The presence of a small mass of mucus at the tympanic orifice of the tube, where it might perfectly well play the part of a valve, suggested itself as a condition that would explain the peculiar phenomena observed. While I should not be justified in rejecting this hypothesis unconditionally, I am disposed to believe that a swollen condition of the mound-like tympanic orifice of the tube is the pathological condition which harmonizes best with all the symptoms and conditions observed in these cases. In the first place, in the case already referred to, the patient, for a period of nearly two weeks, experienced almost constantly a sensation of fulness or pressure in the affected ear. The prick made with the myringotome afforded instant relief, but it lasted only for a few hours. As this peculiar condition was associated with a marked naso-pharyngeal catarrh, I limited my treatment to tri-weekly paintings of this region with a solution of nitrate of silver, to counter-irritation over the mastoid process with tincture of iodine, and to inflations according to Politzer's method. During the third week the improvement was so rapid and so marked that treatment was discontinued. This experience, it seems to me, tallies with the hypothesis which I have put forward rather than with that of the accidental presence of a mass of mucus at the tympanic orifice of the tube. Had the latter been the true cause, the forcible inflations of air ought to have dislodged the mass at a much earlier period. Finally, it seems a little strange that if mucus were present I should have failed both by auscultation and by inspection to detect its presence in the tube or in the middle ear.

Closely connected with these uncomplicated cases of subacute catarrhal inflammation is another group of complicated cases in which the subjective symptoms and the pathological appearances of the *membrana tympani* are essentially the same as those which characterize the simpler cases. In the group referred to, a more or less permanent *obstruction of the nasal passages* constitutes a prominent and perhaps even the chief factor in the production of the deafness. So long as the nasal passages are perfectly unobstructed, the acts of breathing, gapping, swallowing, etc., all aid in properly ventilat-

ing the middle ear, that is, in restoring that equilibrium between the internal and external atmospheric pressures, which is so essential to perfect hearing. When the nasal passages, however, become obstructed, the acts just mentioned produce, at frequent intervals throughout the day, a condition of rarefaction in the air of the middle ears. The effect is very nearly the same as that produced by obstruction of the Eustachian tube. In all the cases that I have seen, these conditions have been associated together in such a manner that I have not been able to distinguish between the effects produced by the obstruction in the nasal passages, and those produced by the contemporaneous naso-pharyngeal, Eustachian, and middle-ear catarrh. I fully believe, however, that it is an important co-operating factor, and that permanent benefit can scarcely be attained in these cases so long as the nasal obstruction is allowed to remain.

In the class of cases just described the disease usually shows a tendency to pursue a chronic course. The *prognosis*—so far as the restoration of the hearing is concerned—will therefore depend on the degree of damage already done by the disease, on our ability to overcome the obstructions in the nasal passages, and on various other circumstances. In the main the prognosis is not good. In the simpler cases of subacute catarrhal inflammation, on the other hand, the prognosis is unqualifiedly good.

*Acute catarrhal inflammation of the middle ear.*—An acute catarrhal inflammation of the middle ear differs from the subacute form chiefly in the fact of its being characterized by pain. Furthermore, in the higher degrees the lesions will be found to be more pronounced than in the subacute variety. Very many of the “earaches” of young children, from four to ten years of age, are due to such an inflammation of the middle ear. The pain is very apt to come on during the night or late in the afternoon, while during the earlier part of the day the child may be quite free from pain. As neither a discharge, deafness, nor any other serious result characterizes these earaches, the parents or friends are very apt to draw the conclusion that *all* earaches are equally harmless, and that they may be allowed to run on for days or even weeks without any effort being made to ascertain the real cause of the pain. I have repeatedly been called to see children who had been suffering from pain in the ear for several days, and in whom the inflammation of the middle ear and adjacent parts had already assumed serious proportions; and yet the thought of sending for a physician had apparently not entered the minds of the parents until after the inflammation had approached very near to the limit beyond which surgical interference is not competent to control the disease. I have often, in these cases, asked the parents the question, Why have you waited for so long a time before sending for a physician? The majority have replied: “We thought it was simply an *earache*, and that it would pass off of itself.” Others have said that in the previous earaches of their children, the physician who had



been called simply prescribed the application of a hot poultice, or the instillation of warm sweet oil to which a few drops of laudanum were to be added; and that they naturally drew the inference that nothing further could be done in such cases.

These remarks, I concede, are of the nature of a digression, but I am anxious to call the general practitioner's attention to the harmful results that may follow such an erroneous belief, and the present opportunity seems to be a good one for the purpose. As I have already said, there is a certain foundation for the belief that earaches are harmless; but such a belief could scarcely have become so deeply rooted in the public mind, unless physicians themselves had in a measure confirmed it. It would seem natural to follow up this statement with the remark that in every case of earache, which does not yield readily to local applications of heat, a physician should be sent for in order that the underlying pathological condition may be ascertained and the proper remedy applied. Unfortunately for the public, very few physicians in the country districts are provided with the proper instruments, or possess sufficient technical knowledge, for the satisfactory accomplishment of this object. Aside from all these considerations, however, which in a few years, it is to be hoped, will cease to apply to practitioners in the United States, the rule, as stated, is a good one. Every earache should be considered as the beginning of what later may prove to be a fatal disease. It should receive early and constant attention at the hands of a physician who is able to examine the ear with speculum and reflected light. In other words, knowledge should take the place of guesswork in the management of these acute affections of the ear.

In the milder types of acute catarrhal inflammation of the middle ear, the peripheral and manubrial portions of the drum-membrane, and especially the more fleshy parts which form the upper boundary of the membrane, will be found red and moderately swollen. If the disease has made sufficient progress, a crackling sound will probably be heard when air is forced into the middle ear. In the course of twenty-four hours, with or without treatment, all these threatening manifestations may disappear. In the more pronounced types of acute catarrhal inflammation, however, the redness and swelling do not remain confined to the peripheral and manubrial portions of the membrana tympani, but involve also the intervening portions. An exudation into the middle ear soon follows, and may even be so copious as to cause a bulging outward of the drum-membrane, more particularly the posterior half. All these changes may develop in the course of a single day, or they may not reach the stage last described until after the lapse of several days. If the disease, after reaching this stage, ceases its activity and gradually subsides, leaving behind, perhaps, an accumulation of serum or mucus in the tympanum, the diagnosis of an acute otitis media catarrhalis may still be retained on our records. But if it goes one step farther, the exuded serum or mucus will become purulent in character,

and, with favoring conditions, a perforation will be established in the drum-membrane. From this time forward, until the perforation heals, the picture presented will be that of a purulent inflammation of the middle ear. Illustrative cases would scarcely add new light to the description already given of an acute otitis media catarrhalis, and I may therefore be permitted to omit them. There are certain cases, however, of which I should perhaps give a single illustration. I refer to a class of cases which, according to the definitions given of the two great classes of acute inflammation of the middle ear, belong properly to the catarrhal variety. They represent, in reality, aborted cases of acute purulent inflammation of the middle ear; that is to say, the lesions are often as grave as they are in the worst forms of this variety, and yet, for some unknown reason, pus is apparently not formed, and recovery takes place without a perceptible discharge from the ear. The following case may serve as an illustration:

A young girl, six years of age, and in excellent general health, though subject more or less to naso-pharyngeal catarrh, was aroused out of her sleep one morning in April by a sharp pain in the right ear. Her mother, who had acquired some experience in treating the earaches of her other children, at once applied the warm douche and soon relieved the pain. In the course of the afternoon of the same day the child began to complain of pain in the left ear. An hour or two later I was sent for by the mother. On examination I found the left drum-membrane markedly congested throughout its entire extent, but not perceptibly bulging. On the right side a purplish tumor occupied the position of the membrana tympani. By aid of the slender probe I ascertained that an exudation of dark fluid blood had taken place between the substantia propria of the drum-membrane and its outer dermoid covering. As the child seemed to hear ordinary conversation perfectly well, and as the right ear was free from pain, I simply advised the mother to use the warm douche in the left ear in the same manner as she had already used it in the right ear. The pain in the left ear was relieved by the douche in a very short time. No discharge was observed at any time in the right ear, and the membrana tympani soon returned to a normal condition. A few inflations according to Politzer's method constituted the only treatment.

In a second very similar case I found a much larger blood-sac, and evacuated its contents. According to the account given by the child's mother, an oozing of blood from the outer orifice of the auditory canal continued for some time after she left the Infirmary. In this case, also, the drum-membrane returned to its normal condition without the development of an otorrhœa. The thought suggests itself, Was not the progress of the inflammation arrested by this comparatively copious, spontaneous local bleeding? I think it not unlikely that these attacks, which began so vigorously, were in each instance materially subdued in acuteness by the spontaneous hemorrhage that followed.

With regard to the *prognosis*, it may be said that in the very great majority of instances it is good. Now and then a case proves rebellious under treatment, but as a rule perfect recovery follows in the course of two or three weeks.

So far as the *diagnosis* is concerned, an error is scarcely possible. The evidences of inflammation are too plainly marked for a careful observer to be easily misled in his interpretation of the conditions presented. The questions which suggest themselves to his mind are, first: Is this a simple catarrhal inflammation, or is it the beginning of a severe purulent inflammation? Mere inspection is not sufficient; the subjective symptoms, and especially that of pain, must be weighed in connection with the condition of the drum-membrane. In children, the thermometer may aid us materially in arriving at a correct conclusion; in adults, it is of comparatively little value. The second question is, Is the red and swollen condition of the membrana tympani the expression of an inflammation which began originally in the middle ear, or is it due to an extension of a diffuse inflammation of the canal on to the drum membrane? This is sometimes a difficult question to answer. If an inflammation of the middle ear has progressed so far as to involve the inner end of the external auditory canal, we may be quite sure of two things: there will be marked diminution of the hearing, and a history of rather severe pain. On the other hand, the insignificance of the pain and the slight impairment of the hearing are very striking features in those cases where the inflammation of the auditory canal is the primary affection, and that of the drum-membrane merely a secondary affair. In exceptional cases, marked pain and decided impairment of hearing may characterize the type of disease last mentioned. Under such circumstances it may not be possible to arrive at a correct diagnosis without further observation of the course which the disease pursues.

*Mucous or serous exudation into the middle ear (hydrotyimpanum; otitis media serosa sive mucosa).*—The accumulation of a serous or mucous fluid in the tympanic cavity may be brought about in two or three different ways. In the first place it may be a simple *hydrops e vacuo*, due to the closure of the Eustachian tube, and to the subsequent absorption of the air that may have remained in the middle ear. The pressure being, under these circumstances, withdrawn from the walls of the blood-vessels of the middle ear, they give up their watery contents to a variable extent, according as the tendency to a vacuum is greater or less. The fluid found in the middle ear in these cases is a thin, yellowish serum, with just enough admixture of mucus to render the fluid slightly sticky. An ordinary cold in the head, when it involves the Eustachian tube, and practically closes it for a short time, may produce this very condition of hydrotyimpanum, without even robbing the membrana tympani of its transparency. Again, the exuded fluid may represent a hypersecretion of the glands with which the tym-

panic mucous membrane is provided. Finally, in many cases probably both of the factors mentioned co-operate in producing the fluid exudation.

In the main the *symptomatology* of these cases is the same as that of the ordinary cases of subacute catarrhal inflammation. There are certain symptoms, however, which of themselves are almost sufficient to warrant a diagnosis of fluid exudation into the middle ear. One of these is, the sudden change from somewhat poor to good hearing, or the reverse. This change is not like that which so often occurs in cases of impacted cerumen, where the brief return of the hearing is accompanied by an explosive sound, due to the sudden restoration of a communication between the body of air lying between the drum-membrane and the ceruminous mass, and that which lies outside of the latter; the hearing either simply becomes clouded, or, in an equally quiet manner, the cloud seems to disappear. These changes in the hearing are clearly due to changes in the position occupied by the fluid. In a few cases the patient is able to state definitely in what positions of the head the hearing seems to be normal. These are most commonly the position with the head thrown far backward (fluid escapes into the antrum?), and that with the head bent far forward. In both of these positions the fluid, if not too viscid and if not too copious, will, in obedience to the law of gravity, flow away from the oval and round windows, thus leaving the ossicles and the membrana tympani secundaria free to perform their functions properly.

Another symptom which is peculiar to these cases, is the sensation of something moving in the ear. This is of course not felt when the head is quiet, but simply when the head is moved rather suddenly. Sometimes the patient gives a correct diagnosis of his condition in the very first words of his complaint: "I went in bathing, and got some water into my ear; and I am unable to get it out." He imagines, as a matter of course, that the water found its way into the ear by way of the external auditory canal; whereas the chilling of the surface of the body, or the accidental entrance of salt water into the middle ear by way of the Eustachian tube, has caused an exudation of fluid to take place in the tympanum in one of the ways already described. Finally, subjective crackling, squeaking, and bubbling sounds may be due to the presence of free fluid in the middle ear; they are just as likely, however, to owe their origin to an abnormally moist condition of the Eustachian tube. Of more decided value is the symptom of hearing gurgling sounds in the ear during the acts of coughing and sneezing.

The *course* of the disease is a very variable one, though in the majority of instances the fluid exudation is soon absorbed and the ear returns to a normal condition. Among the following cases will be found instances of probably all the types of serous exudation into the middle ear which the physician is likely to encounter in practice.

CASE I.—The patient, a man thirty-five years of age, had a few days previously caught a slight cold in the head, and had thenceforth experienced a sensation of fulness in the left ear. When he consulted me on the 13th of May, 1879, I found the left drum-membrane slightly congested at the periphery. Just below the umbo (the lower end of the handle of the hammer) a curved line was visible, which stretched from the anterior to the posterior periphery of the membrane. In whatever position the patient's head was placed, this curved line (with its concave side looking upward) maintained its horizontal position, thus showing clearly that it represented the upper boundary of a mass of free and rather thin fluid. Under treatment this pathological condition disappeared in about two weeks, and the hearing returned to its normal degree of acuteness.

CASE II.—The patient, a boy eight years of age, had been somewhat hard of hearing, as the mother believed, for about one year. At times, she said, he seemed to hear quite well, and then the deafness would return and last for a variable period. When I saw the boy at the Infirmary, on the 12th of October, 1870, his right membrana tympani presented no features worthy of special note in this connection. On the left side, the drum-membrane was noticeably sunken, but not congested nor lacking in a fair degree of transparency. In the posterior half of the membrane there was a sharply defined "fluid line," running from the umbo across the intervening space to the posterior periphery. Anteriorly, the limits of the fluid could not be defined. Moist râles were heard during inflation. "Fluid line" disappeared after inflation. Decided naso-pharyngeal catarrh. Hearing distance for the watch before inflation R. 2 in., L. 2 in.; after inflation, R. 24 in., L. 15 in. Whispered words were heard distinctly a much greater distance after inflation than before it.

The boy visited the Infirmary for treatment twice a week, for a period of four weeks. The fluid had by that time disappeared from the left middle ear, and the hearing, for the watch, remained steadily at twenty-four inches. On the right side, however, no perceptible improvement in the hearing had taken place.

These two cases are placed side by side because the former represents a purely fresh attack in a person whose ears had been previously healthy, while the latter furnishes a good instance of the development of hydrotympa-num in an individual whose ears had been for months affected with chronic catarrhal inflammation. Furthermore, they both represent the slighter degrees of fluid exudation into the middle ear.

CASE III.—A gentleman, sixty-nine years of age, but in vigorous health, consulted me on the 9th of December, 1876, for a decided loss of hearing in his right ear. He first discovered the defect about six weeks previously,

while suffering from a severe cold in the head. On examining the ear I found that the membrana tympani was decidedly sunken. Anteriorly a "fluid line" ran directly across from the umbo to the anterior periphery of the membrane. Posteriorly the uniform dark coloring of the membrane showed clearly that the fluid in this region rose to at least the height of the upper limit of the membrane. As the long process of the anvil lay almost in contact with the membrana tympani, its whitish body stood out in marked contrast with the deep slate color of the surroundings. Inflation by Politzer's method changed the entire picture. The fluid line, which before was visible only in the anterior half of the membrane, now stretched like a festoon from periphery to periphery. The long process of the anvil had also completely disappeared from view.

Under treatment this mass of fluid was dissipated—whether wholly by absorption, or partly by absorption and partly by dislodgement, I am unable to say—in less than two weeks, and the hearing returned apparently to its former standard of acuteness.

On first thought it may seem rather strange that in the posterior half of the cavity of the tympanum (in the case just narrated) the level of the fluid should rise at least to the height of the upper boundary of the drum-membrane, while in the anterior half the level should correspond with that of the umbo or central point of the membrane. This difference, however, is simply due to the effects of capillary attraction. The close proximity of the long process of the anvil to the posterior half of the membrana tympani supplies precisely the conditions which are necessary to develop the effects of capillary attraction, that is, to lift the apparent level of the fluid in this region to the highest limits of the drum-membrane.

CASE IV.—This patient, a young man twenty-eight years of age, contracted a bad cold in the head ten days previously, and shortly afterward began to experience a sense of fulness in the right ear, and diminished acuteness of hearing. When I examined his right ear at the Infirmary, on the 2d of November, 1870, I found the drum-membrane of a peculiar, dull hue, and almost directly in the centre of the posterior half the perfectly round outlines of a bubble of air, perhaps a millimetre and a half in diameter, were distinctly visible. This bubble seemed to be prevented from rising to a higher level by some unseen object—undoubtedly the end of the long process of the anvil and the head of the stirrup. The motions of the patient's head caused it to move slowly from one position to another, but only a very short distance. (No further notes of the case.)

It is perhaps more common to find several bubbles lying behind the drum-membrane. I remember, in one or two instances of hydrotyimpanum, to have seen (after inflation) the cavity of the tympanum apparently filled

from top to bottom with bubbles, which glided over each other like so many balls of glass. The first time I saw this phenomenon I was persuaded that I must have overlooked a minute perforation in the membrana tympani, and that the mass of bubbles lying before me was resting against the outer and not the inner surface of the membrane. By employing a small mop of cotton, however, I was able speedily to satisfy myself that the bubbles were confined within the tympanic cavity.

CASE V.—The patient, a marketman, thirty-one years of age, came to the Infirmary on the 4th of February, 1874. He complained of deafness and occasional tinnitus, of several months' standing. Recently, he said, he had sometimes observed gurgling sounds in the left ear, and had also noticed that when he threw his head far backward, he could hear decidedly better than when he held it in the natural upright position. I examined the left ear and found the membrana tympani appreciably sunken. Instead of a delicate, hair-like "fluid line," a rather broad yellow band crossed the lower half of the membrane. At the umbo this band was caught up like a festoon. Below it the color of the drum-membrane was like that of slate. Changes in the position of the head caused corresponding changes in the position of this band. A free vertical incision was made in the posterior half of the membrane, and inflation by Politzer's method was resorted to. In this way quite a large quantity of fluid was evacuated from the tympanic cavity,—fluid which, in no respect that I could discover, differed from that found in cases which are characterized by the presence of the delicate, hair-like, "fluid line." The evacuation of the fluid contents of the middle ear increased the acuteness of the hearing very noticeably, and three days later, when he returned to the Infirmary, I found that this gain had increased rather than diminished.

In all the five cases which have just been described, the fluid found in the tympanic cavity was almost purely serous in character. So far as my experience goes, it is only in comparatively few cases that the exuded fluid is found to consist largely or entirely of tough, tenacious mucus. I do not know why, in these few cases, mucus should predominate over serum in the exuded material, unless it be that in such cases the mucous glands of the middle ear are subjected to a higher degree of irritation than is usually the case. I have noticed, for example, that a purulent inflammation of the middle ear, with perforation of the membrana tympani, occasionally terminates in an accumulation of mucus in that cavity; the perforation apparently healing before the mucous membrane of the middle ear has had time to return to a fairly healthy state. At the same time a simple catarrhal inflammation of the middle ear, such as is commonly found to be the cause of the accumulation of serum in the tympanic cavity, is often also the cause of an accumulation of mucus. Furthermore, in its *symptomatology* this type of

middle ear disease is essentially the same as the one which we have just been considering. It is more apt, perhaps, to run a chronic course than is the serous variety of effusion. So far as the *diagnosis* is concerned, there are several features which justify the physician in suspecting that the effusion is mucous rather than serous in character. In the first place, rales are an almost necessary phenomenon in cases of serous accumulation, unless the fluid be too scanty in quantity to reach the level of the tubal orifice. In cases of an accumulation of mucus, it is perhaps the exception for rales to be heard; in fact the air, forced into the Eustachian tube by inflation, does not seem to reach the cavity of the tympanum at all. In the second place, the appearance of the drum-membrane in cases of otitis media mucosa is usually quite different from that observed in well-marked cases of otitis media serosa. It often has a peculiar dead, milky, opaque appearance, which, unfortunately, is sometimes also observed in cases of the serous variety. Hence, without paracentesis of the membrane, we can scarcely do more than entertain a strong suspicion that the case is one of an accumulation of mucus in the tympanic cavity. After paracentesis has been performed, and the exuded material has been forced through the perforation into the auditory canal, it becomes, of course, an easy matter to make an absolute diagnosis.

As I shall have occasion, in the section relating to treatment, to refer to the course which these cases pursue, I may be permitted to omit all farther reference to the subject in this place.

*Hemorrhagic exudation into the middle ear.*—There are two classes of cases to which the expression just employed may be applied with equal justice, viz., those cases of acute catarrhal inflammation in which, during the first onset of the disease, a hemorrhage occurs from some vessel in the middle ear, and those in which a serous fluid, deeply tinged with the coloring matter of the blood, finds its way into the tympanic cavity through other than inflammatory causes. Instances of the latter form of disease are very rarely met with, and then usually in connection with a depraved state of general nutrition (*morbis Brightii*). I once published<sup>1</sup> what I believed at the time to be a well-marked instance of this form of hemorrhagic exudation. It occurred in a person who was affected with œdema of the lower extremities and who presented the characteristic facies of Bright's disease. When the patient was seen a second time, a few years later, an intratympanic pulsating, vascular growth occupied the position of the former hemorrhagic exudation, and my previous error in diagnosis became at once apparent.

In the other form, that is, as an accompaniment of an acute congestion of the middle ear, hemorrhagic exudations are by no means common. I

---

<sup>1</sup> In the Medical Record for October, 1871.



refer, as a matter of course, to well-defined exudations, the red color of which is sufficiently pronounced for it to be readily distinguished through the membrana tympani. Serous exudations, slightly tinged with blood, are, on the other hand, often seen, and require no special consideration. The blood-vessels of the tympanic mucous membrane seem rarely to rupture under the strain to which they are subjected in acute congestion of these parts. It is far more common for the vessels which lie near the dermoid surface to break and afford escape to their contents. Occasionally, as a result of violence, both accidents may occur; some of the blood-vessels in the tympanic cavity as well as some of those on the outer surface of the membrana tympani affording escape to their contents. This happened, for instance, in the following case: The patient, a carpenter, in robust health, drank to excess one night, got into a fight, and was probably struck on the head. At all events, he remembered waking up the following morning with a loud ringing noise in the head, marked deafness, and blood oozing from both ears. Two or three days later I saw him at the Infirmary, and found both external auditory canals partially filled with clotted blood. I removed the clots and exposed the drum-membranes to view. The right one was pale and slightly cedematous on its outer surface, but no trace could be found of the spot from which the hemorrhage came. While the outer surface of the left drum-membrane presented the same appearance as that of the right, its deeper tone of color was bluish or bluish-black, indicating the presence of dark blood in the tympanic cavity. The man unfortunately refused to have an incision made in the drum-membrane, and my notes furnish no further details with regard to the progress of the case. He probably sought relief at some other charitable institution.

#### *Treatment.*

In discussing the means that may be employed to advantage in the treatment of the different forms of acute and subacute catarrhal inflammation of the middle ear, I propose to consider first the local and then the general measures.

*Local measures.*—If we once adopt the belief that all catarrhal or inflammatory affections of the Eustachian tube and middle ear owe their existence to, and are promoted by, a similar irritation or inflammation of the naso-pharyngeal mucous membrane, our chief efforts will naturally be directed toward restoring the latter to a healthy condition. It is not my purpose in the present treatise to mention all the different methods and remedies which are commonly employed for the accomplishment of this purpose. I will limit myself to a description of those which I have found to be successful in attaining the desired end, and to a statement of my reasons why I do not like to employ certain others which are recommended by good authorities.

For all the different degrees of naso-pharyngeal catarrh I know of no more efficient remedy than *nitrate of silver*. My mode of using it is the following: I wrap absorbent cotton around the end of a malleable steel cotton-holder, and then bend the armed end of the instrument in the manner shown in the accompanying cut. In adults this shorter arm of the instrument should not exceed one inch in length; in children, it should measure from a half to three-fourths of an inch, according to the age of the child. To a distance of about three-eighths of an inch from the end the sides of the instrument should be slightly roughened, in order that the cotton-wool may cling firmly to it. Before dipping the mop into the solution of the remedy, the physician should always pass his finger over it, for the purpose of ascertaining whether the sharp end of the instrument is thoroughly well covered by the cotton. It is scarcely possible to lay down any well-defined rule with regard to the proper size of the mop. As a rough estimate, I



FIG. 16.—Bent cotton-holder, armed with a mop of cotton.

may say that, at the point of its greatest breadth, it should measure about seven or eight millimetres in diameter for adults, and five or six millimetres for children.

The mop once ready, our next step is to saturate it to the proper degree with the remedial solution. Here again care must be exercised. If we dip the entire mop into the solution, and without further ado introduce it into the naso-pharyngeal space, we must not be surprised if the patient objects to a repetition of the procedure. The mop filled with the remedy is precisely like a sponge saturated with water. The moment the naso-pharyngeal muscles contract, they squeeze the mop just as a person would a sponge, and cause a stream of the silver solution to run down into the larynx, or at least very near to its entrance. The symptoms thus caused are always extremely unpleasant, and, in a few instances, they may be decidedly alarming. On more than one occasion, in former years, I have completely demoralized both the patient and the patient's friends by the spasm of the glottis which had been provoked by my careless mode of applying the remedy. To avoid these unpleasant symptoms we either should saturate the entire mop, and then, by pressure, carefully remove the excess of fluid, or we should saturate only one half of the mop, leaving the other half to serve the purpose of a receiver into which the excess of fluid, pressed out of the

moist half of the mop by the naso-pharyngeal muscles, may escape. This latter method is the one which I usually employ, and even then I endeavor to remove as much of the fluid as I can by pressing the saturated end of the mop against the neck of the bottle.

The steps of this operation of mopping out the naso-pharyngeal cavity are the following: The patient should sit directly facing the physician, with the source of light on one side of and a little behind him. Holding the instrument in his right hand, pressing the patient's tongue down firmly with the tongue-depressor, and keeping his pharyngeal cavity well illuminated by means of the forehead-mirror, the physician should pass the mop high up behind the soft palate, first toward one Eustachian orifice, and then across toward the other. If only one ear is affected, it will often be found sufficient to introduce the mop only on that side of the naso-pharyngeal cavity. Sometimes, when the attempt is made to carry the mop across from one tubal orifice to the other, quite a decided obstacle is encountered in the form of a hemispherical projection of the mucous membrane situated exactly in the median line of the posterior pharyngeal wall. If the instrument be pulled forward a little, no difficulty will be experienced in carrying the mop past the obstacle. In certain patients the mere act of depressing the tongue causes them to retch so persistently that all attempts to introduce the mop into the naso-pharyngeal cavity by way of the mouth have to be abandoned. It is often possible, however, in such cases, to accomplish the desired object by performing the operation with great speed. If this plan be adopted, the physician should be careful to protect his person, lest the contents of the patient's stomach be suddenly showered upon him. Finally, by wrapping a towel around the end of the patient's tongue, and instructing him how to pull that member well outside of his mouth, the physician may be able to reach the naso-pharyngeal cavity without producing the unpleasant results just mentioned.

In making remedial applications to the naso-pharynx the physician must notice particularly whether, and to what extent, the mucous membrane of that cavity is covered with mucus. On simple inspection he may very easily fail to discover the presence of any appreciable amount of mucus, and yet, on introducing his mop, be surprised to find that region well coated with a tough, tenacious, dirty-looking material which clings like a false membrane to the underlying tissues. It is easy to see how slight must be the degree of effectiveness of say a twenty or even a forty-grain solution of nitrate of silver when introduced into the naso-pharynx under such circumstances. Very little of it, as a matter of course, ever reaches the mucous membrane, and consequently little or no benefit results from the procedure. It is therefore important to first remove this coating of mucus from the naso-pharyngeal cavity, before we undertake to bring our remedies to bear upon it. For this purpose I am in the habit of employing simply

dry mops of cotton. A single introduction usually suffices to bring away any free mucus that may be present ; but sometimes I have experienced great difficulty in removing the tenacious material, and have even been obliged to employ forceps. I have no doubt that Weber's nasal douche, or the nasal syringe, might be used to great advantage in freeing the naso-pharyngeal cavity from such a tough coating of mucus ; but, as I have already stated in an earlier section, my experience justifies me in considering this therapeutic procedure by no means a safe one, and I am therefore unwilling to recommend it for the purpose named.

The next questions of importance are, What remedy or remedies are the most effective in subduing a naso-pharyngeal catarrh ? and How often should they be applied, and in how strong solutions ? My answer to the first question is this ; I rarely employ any other remedy than nitrate of silver. During the first years of my practice as an aurist I conscientiously and hopefully tried all the different solutions, powders, and sprays of which the numerous text-books and monographs speak in such favorable terms. As time went on, I found my stock of remedies gradually dwindling down until only four remained, viz., nitrate of silver, tincture of iodine, tannic acid, and alum. In all of these I place some confidence : in the first two I place a great deal of confidence, and more particularly in the first one. In young children, from four to eight years of age, I begin with a fifteen-grain solution of nitrate of silver and soon increase the strength to twenty or twenty-five grains to the ounce of distilled water. I first mop out the naso-pharyngeal cavity with the remedy, and then, after preparing a fresh mop, I paint the surfaces of the tonsils and the visible portion of the posterior pharyngeal wall. If some of the solution trickles down in the larynx, and causes violent coughing, or a spasm of the muscles of the glottis, I give the patient quickly cold water to drink. On the next day but one, I repeat the application of nitrate of silver, and continue to do so on every alternate day until the naso-pharyngeal mucous membrane has returned to a healthy state. In a few cases the mucous membrane returns to a *perfectly* healthy condition, so far at least as we can judge by simple ocular inspection ; in the majority of cases, however, the catarrhal process simply subsides, under treatment, to a minimum degree of activity,—that is, the mucous membrane returns to a *comparatively* normal condition. In healthy children the naso-pharyngeal mucous membrane can usually be restored to this comparatively normal condition in the course of from two to four or five weeks.

From a comparison of the results obtained in numerous cases I am disposed to consider a twenty-grain solution of nitrate of silver as that best adapted to the average case of acute or subacute naso-pharyngeal catarrh. In deciding, in any given case, whether to increase or to diminish the strength of the solution, I am guided by the following considerations : If the employment of the twenty-grain solution is followed by a sense of dis-

comfort, and perhaps even by pain, lasting for several hours afterward, I employ the next time a weaker solution, say one of fifteen grains to the ounce. On the other hand, if the sense of discomfort following the application passes away in the course of half an hour or an hour, we may safely assume that only a beneficial effect has been produced. Again, if the secretion of mucus continues with unabated activity, if the swelling of the parts does not diminish, and if their congested hue does not give place to a paler color, after four or five applications have been made, I then proceed without further delay to the employment of a thirty- or even a forty-grain solution. In those cases which are characterized by the presence of a tough mass of mucus in the naso-pharynx, I have repeatedly failed to obtain a satisfactory degree of improvement until I had employed a nearly saturated solution of nitrate of silver. By a nearly saturated solution I mean one obtained by rubbing the wet mop over the stick of nitrate of silver several times in succession. When a strong solution like this is used, it is of course doubly important to remove the excess of fluid from the mop.

I have placed the tincture of iodine second on my list of remedies, not that I have good solid reasons for believing it less efficacious than nitrate of silver, but simply because patients dislike it so much more than they do the latter remedy. For this very reason I have not often employed it, and when I have, it has usually been in cases which had not responded well to the applications of nitrate of silver. The experience gained from this limited use of the remedy justifies me in speaking favorably of it. I have used both the simple and the compound tincture, and have not diluted either of them. In young children I have never attempted to introduce the remedy into the naso-pharyngeal cavity, but have found it serviceable as an application for the swollen mucous membrane of the visible pharynx.

So far as the naso-pharyngeal cavity is concerned, I have used alum and tannic acid in various forms, but never with much satisfaction. Chlorate of potassa I have used with even less satisfaction. They all seem to possess—if I may use such an expression—very little penetrating power. I can recall one case, however, in which excellent results were obtained by the systematic employment (daily), for a period of three or four weeks, of finely powdered burned alum. The patient, a strong, healthy man about fifty years of age, and apparently of temperate habits, was suffering from a most distressing tinnitus. His entire pharynx was very markedly congested, and there was a moderate degree of swelling of the parts. He visited the Infirmary twice a week, for a period of several weeks, but received little or no benefit from the treatment adopted (applications of nitrate of silver solutions to the affected mucous membrane, and inflations according to Politzer's method). Then, by way of experiment, Dr. Charles Laight, my associate in that institution, proposed to the man to come every day to his office, and have finely pulverized burned alum blown upon the affected

pharyngeal mucous membrane (*not* upon that of the naso-pharyngeal cavity). The man eagerly consented, and visited the doctor faithfully for a period of about four weeks. At each visit, if I remember rightly, two or three inflations according to Politzer's method were made. It is possible, also, that the man was induced to abstain from smoking. No other measures, however, were adopted that might have exercised a beneficial influence upon the condition of the throat, and secondarily upon that of the ear. At the end of the period mentioned I examined the patient's throat, and found it practically normal in all respects. The congested appearance had entirely disappeared, and the tinnitus was so insignificant that the man paid no attention to it whatever, and considered himself as cured. In this case the beneficial influence exerted by the remedy upon the mucous membrane of the pharynx extended to that of the naso-pharynx and middle ear. The excellent results obtained in this case led me to hope for similar results in other cases; but I must confess that in this I have been disappointed. I cannot recall a single instance in which any such brilliant result has been attained either by this drug or by nitrate of silver. I have obtained *fairly good* results, however, with powdered burned alum in quite a number of cases.

I ought perhaps to explain in this place why if powdered burned alum is an effective remedy in allaying pharyngeal catarrh, I should not also employ it as a direct application to the naso-pharyngeal cavity. My reasons are these: In the first place, I have tried this plan of treatment and am not at all satisfied with the results obtained by it; and in the second place, the patients themselves dislike the remedy, when used in this manner. At first I employed the alum in its full strength, and each time the application was followed by a most distressing "cold in the head," as the patients described it, which lasted for hours. I then diluted the alum with powdered sugar of milk, but thereby simply diminished the severity of the unpleasant symptoms. When a finely divided powder is blown into the naso-pharyngeal cavity, portions of it undoubtedly find their way into the communicating nasal, frontal, and maxillary cavities. To the mucous membrane lining these parts such a drug as alum, for instance, is known to be highly irritating. Hence, in the form of a powder, neither alum nor tannin can be employed as a direct means of treating the naso-pharyngeal cavity, without causing the patient unnecessary discomfort. This same objection applies in a measure to a finely divided spray. The expensiveness, however, of the apparatus required for obtaining a good spray practically places this mode of treatment out of the reach of the majority of practitioners. If used in the form of a solution, both alum and tannin are apparently much less efficient than either nitrate of silver or the tincture of iodine.

In a certain proportion of the cases, the methods which I have already

described fail to accomplish the desired purpose, or, if they apparently succeed, a relapse soon occurs, and a resumption of treatment becomes necessary. In these cases the physician would do well to explore the naso-pharyngeal cavity with his finger, for the purpose of ascertaining whether the obstinate irritation is not kept up by what are termed "adenoid vegetations," or follicular swellings, of the naso-pharyngeal mucous membrane.<sup>1</sup>

---

<sup>1</sup> For the information of those who may not have read Meyer's classical treatise on Adenoid Vegetations in the Naso-pharyngeal Space (Archiv für Ohrenheilkunde, 1873 and 1874), I will give here a brief abstract of the more important portions of this admirable contribution to otology.

Out of 175 cases in which adenoid vegetations were discovered in the naso-pharyngeal space, Meyer found that 130, or 74 per cent., were hard of hearing. As the mucous membrane of this region passes by direct continuity into that of the Eustachian tube and middle ear, we can readily understand why, in so large a proportion of the cases, the organ of hearing should participate in the naso-pharyngeal inflammation. The pathological condition referred to, under the title of "adenoid vegetations," consists in the presence of numerous, variously shaped tumors in the naso-pharyngeal space. These vary in size from a mere follicular enlargement to a mass the size of a cherry-pit, or even a hazel-nut. Sometimes they are pedunculate, at other times they are grouped together in a row, like the teeth of a comb. These masses are very vascular, and consequently of a bright red color; they have about the same consistency as the parenchyma of the liver, and present either a smooth surface or one that is slightly granular. They rarely occur singly; as a general rule, there are as many as from four to eight. The presence of these tumors implies a degree of inflammatory irritation in the mucous membrane of this region, which can scarcely exist without an inflamed condition also of the Eustachian tubes. But these tumors may injure the organ of hearing in a purely mechanical manner. Thus Meyer mentions cases where one or two of these tumors, growing from favorable points, attained such proportions as to completely block the entrance to the Eustachian tube.

The *microscopic examination* of these tumors showed them to be composed chiefly of what Meyer terms "adenoid tissue," viz., a network of connective tissue supporting countless lymph corpuscles, or lymphoid cells, as they are sometimes called. Here and there, throughout the section, the outlet ducts of acinous glands were also encountered.

The chief *symptoms* characterizing this affection are the peculiar expression of the face, and the defective pronunciation of certain words; both of these phenomena being generally associated with more or less deafness. As regards the expression of the face, Meyer describes it in the following words: "In well-marked cases the mouth is constantly open, and the breathing takes place exclusively through it. There is also a lack of tone in the play of the features, and the expression is characterized by a certain shade of sadness. After the breathing has taken place for a certain period of time exclusively through the mouth, the nose assumes a peculiar sharpness of outline; it looks pinched, and the alæ appear to be sunken. If the patient happens to be suffering at the same time from a chronic nasal catarrh, this peculiar expression of the nose will, as a matter of course, not exist." The patient's pronunciation is defective in two respects: in the first place, the voice lacks the normal resonance; and in the next, the nasal tones—m, n, ng—are exchanged for others. Thus, for example, the patient does not say "Nase," but "Dase" or "Lase." Again, for the word "Zim-

If he finds this to be the case, he may safely assume that, by any or all of the therapeutic methods which I have described, he will probably fail to permanently relieve the patient of the more active manifestations of his naso-

mermann," he will say "Zibberbad," and for "Gesang," "Gesagk," and so on. These of course illustrate the modifications of pronunciation in a well-marked case. Such patients, Meyer says, have also great difficulty in singing high tones. Among other symptoms, he mentions the partial or total loss of the sense of smell, habitual headaches, the sensation of a foreign body in the back part of the nose, and the frequent escape of blood from the naso-pharyngeal region into the mouth. This last symptom he observed in a little over fifteen per cent. of all the cases that came under his observation.

While in this form of disease a positive *diagnosis* can only be made by physical means,—inspection of the naso-pharyngeal cavity by aid of the rhinoscope and reflected light, or an examination of these parts with the finger, introduced through the mouth,—we can nevertheless expect confidently to find adenoid vegetations in the naso-pharynx whenever we encounter the peculiar expression of countenance and the defective pronunciation described above. In support of this statement, Meyer mentions the fact that he examined 2,000 school children of both sexes in the public schools of Copenhagen, for the purpose of ascertaining, simply by looking at their faces and hearing them speak, how many of them were suffering from this affection. He found twenty children (1 per cent.) in whom these characteristics were well marked, and in each instance he verified the diagnosis by a digital examination. Meyer made a similar investigation in England, and found the proportion to be 13 out of 700, or nearly two per cent.

With regard to the question of *age*, Meyer found that, out of 175 cases, 134, or 76 per cent., were between the ages of five and twenty; the youngest patient was three years old, the oldest fifty-nine. In a few instances he found that there was a family tendency to this affection. Thus, in three instances, three sisters were affected with the disease, and in seven, two sisters.

As regards the *etiology* of this disease, Meyer simply states that the same causes which co-operate to produce a chronic catarrh of the naso-pharyngeal mucous membrane also play a chief part in the production of adenoid vegetations.

So far as his observations extend, Meyer believes that these vegetations usually commence to grow in childhood, but remain stationary during youth; and, if left to themselves, they will shrink away and disappear during maturity. Hence, so far as they themselves are concerned, these vegetations might be allowed to remain without any interference on the part of the surgeon. But when we take into account their important relations to the organ of hearing,—not to speak of the unnatural and disagreeable tone of voice which they produce,—it becomes necessary to get rid of those already formed, and to check the further production of new ones.

The *prognosis*, as regards the results of treatment, seems to be quite good. Meyer states that among a number of cases which remained under observation for a period of from two to five years, and in which the vegetations had been thoroughly removed, not a single relapse occurred. The prognosis, as regards the hearing, is also quite good. Out of 112 cases which had undergone proper treatment, the hearing was restored to the normal standard in 48 instances; in 29 it was improved; in 3 it remained unchanged; in 3 it was rendered worse; and in 29 cases no note was made with regard to the effect of treatment upon the hearing. This result appears in a still more favorable light when we examine the cases with regard to the length of time



pharyngeal catarrh. In these comparatively rare cases<sup>1</sup> it has been my practice to entrust the treatment of this condition to some of my colleagues who are more skilled than I in operative procedures in the naso-pharyngeal cavity. My first experience with a case of adenoid vegetations convinced

during which the deafness had existed. The following tables show this point very clearly :

TABLE I.

Duration of Deafness.	No. of Cases treated.	Cured.	Per cent.
Less than 3 months.....	10	5	50
From 3 to 12 months.....	12	5	41.7
From 1 to 2 years.....	17	9	52.9
From 2 to 5 years.....	23	11	47.8
From 5 to 10 years.....	21	7	33.3
More than 10 years.....	21	10	47.6
Indefinite.....	8	1	12.5
Total.....	112	48	42.9

TABLE II.

The Hearing.	Simple Catarrh. No. of Cases.	Purulent Inflammation. No. of Cases.	Total.
Was rendered normal in.....	34	14	48
Was improved in.....	18	11	29
Remained unchanged in.....	3	..	3
Became worse in.....	..	3	3
Was not tested in.....	23	6	29
Total.....	78	34	112

In the *treatment* of this form of disease, the essential thing, according to Meyer, is to remove the vegetations, either by mechanical or by chemical means. In children, and also in adults when the vegetations are not too large or too firm in texture, they can be destroyed by pressure made with the finger. If this mode of destroying them fails, we must resort to the use of some caustic, preferably the nitrate of silver, either in the pure form or mitigated by the addition of nitrate of potassa. The instruments to be used for this purpose are silver rods, armed with a flattened end-piece, and differently shaped, so as to enable the surgeon to cauterize readily growths springing from any part of the naso-pharyngeal space. Where the growths are large, and especially where they are firm in texture, it becomes necessary to use other surgical contrivances, such as the galvano-cautery, a double-bladed instrument like that used for crushing vesical calculi, a ring-shaped knife, etc.

<sup>1</sup>Speaking merely from recollection, I think I have not seen more than half a dozen cases in which I recognized the presence of adenoid vegetations in the naso-pharynx. In at least as many more cases I have probably overlooked the condition entirely.

me that chemical means alone cannot be trusted, if we wish to obtain permanently successful results. As this case is an instructive one, I will give a history of it in brief outlines :

A strong, healthy boy, fourteen years old, was brought to me for treatment on the 12th of June, 1874. The boy's mother stated that when he was three years old he had had scarlet fever, and from that time onward he had been subject to frequent earaches and had often shown a moderate degree of hardness of hearing. At times the hearing had been quite poor. On examination I found both drum-membranes markedly sunken and of a pinkish hue. Both Eustachian tubes were easily inflated, and the patient observed a marked improvement in the hearing immediately following the inflation. The pharyngeal mucous membrane was congested and swollen, and on the posterior wall of the pharynx there were five or six circumscribed elevations (enlarged follicles). On alternate days, during a period of three weeks, I mopped out the naso-pharyngeal cavity with a twenty-grain solution of nitrate of silver, and applied a solution of the same strength to the pharyngeal portion of the Eustachian tube, by means of a bougie. I also employed Politzer's method regularly. At the end of this time the pharyngeal mucous membrane appeared to be comparatively free from active irritation ; the drum-membranes occupied a more nearly natural position and had lost their former pinkish hue, and the boy appeared to hear conversation perfectly well. I accordingly discontinued treatment.

The following November he was again obliged to submit to a similar course of treatment. This time, however, the right middle ear was found nearly full of a thin, fluid exudation, which I evacuated through an artificial opening in the drum-membrane.

On the 25th of March, 1875, he returned for the third time, and again I found essentially the same conditions as existed on previous occasions. The presence of the well-marked follicular swellings on the posterior pharyngeal wall led me to ask myself whether the patient's decided tendency to catarrhal inflammation of the Eustachian tubes and middle ears was not due to the existence of similar swellings in the naso-pharyngeal cavity. There were also other conditions which favored such a belief ; conditions which up to that time had quite escaped my notice. I refer to the boy's peculiar expression of countenance, to his inability to breathe with the mouth closed, and to his muffled nasal tone of voice. As stated by Meyer, these symptoms point almost with certainty to naso-pharyngeal adenoid vegetations. In order to settle the question definitely, I explored this region with my finger, and to my surprise found it very much encroached upon by a number of nodular swellings of different sizes, the largest of which may have been as large as a filbert-nut. As soon as I had made this discovery, I decided to place the patient under the care of my friend, Dr. Horatio Bridge, who was then practising in this city, but who is now living in Colorado. I cannot now recall exactly how long a time the pa-

tient remained under the doctor's care, but my impression is that it was fully six or seven weeks. In that time he removed, little by little, a mass of fleshy fragments sufficient to nearly fill a two-drachm specimen bottle. If I remember rightly, he employed for this purpose a ring-shaped scraper, with a long, slender shank, and reached the vegetations with it by way of one or both lower nasal passages. I have also an indistinct recollection that while he manipulated this instrument with one hand, he guided its cutting end by means of the forefinger of the other hand, introduced into the naso-pharyngeal cavity through the mouth. I also remember that he was careful not to attempt too much at one sitting, and always waited for all inflammatory reaction or soreness to subside before he attempted to remove other masses or portions of masses. This series of operations proved highly successful. The hearing returned to a fairly normal degree of acuteness, and remained so for a period of at least three years (I have not seen the patient since 1878). His facial expression brightened up and became more intellectual in its stamp; a change which was undoubtedly due largely to the fact that he was no longer obliged to breathe through his mouth.

Operative procedures are also required in another and larger class of cases, viz.: those in which the tonsil becomes so enlarged as to encroach seriously upon the naso-pharyngeal space, and perhaps even upon the mouth of the Eustachian tube. The snail-like rate at which such a tonsil is likely to be reduced in size by superficial applications of either tincture of iodine or nitrate of silver, fully justifies the adoption, from the very beginning, of some more potent method of procedure. As I have no experience of my own to offer with regard to the best methods of excising small or large portions of the tonsil, I will refer the reader to some of the more recent text-books on the subject of throat diseases. In cases where the tonsils are so large as to interfere with the proper ventilation of the middle ears, or where they encroach upon the pharynx to such an extent as to interfere with respiration, and consequently with the development of the chest, it seems to me that there can be but one opinion with regard to the advisability of diminishing their size as rapidly as is consistent with the patient's safety. In cases where the swelling of the tonsils is not excessive, I am disposed to question the wisdom of either excising any considerable portion of the tumor or of injecting iodine into its substance: the surface applications described above will usually be found sufficient to control the activity of the catarrhal process.

In connection with the subject of treatment of the naso-pharyngeal mucous membrane, I might add that in a certain number of cases excessive smoking, and the frequent taking of the stronger alcoholic drinks (undiluted), contribute very appreciably toward keeping the pharyngeal mucous membrane in an irritated condition. If the patient is allowed to continue these habits, the physician will find it an up-hill task to cure the aural disease.

The question which naturally suggests itself next, in connection with the treatment of acute and subacute catarrh of the middle ear, is this: Shall we endeavor to bring our remedies, either in the form of a fluid or in that of a spray, into direct contact with the mucous membrane of the Eustachian tube and middle ear, or shall we trust solely to the indirect effects which follow the application of these remedies to the naso-pharyngeal space? I have no wish to place myself in opposition to the teachings of nearly every acknowledged authority in the department of practical otology, but I must say frankly that I have no faith in the practice of injecting fluids into the Eustachian tubes or middle ears. For a period of a year or eighteen months I used them in the manner in which I had been taught to use them in Vienna. I soon became satisfied, however, that in not a few cases the injections (weak solutions [gr. i. to iij. to the ounce] of sulphate of zinc, alum, or nitrate of silver) promoted the very irritation which I was endeavoring to allay; and, in the second place, that the completeness and promptness of the cure were in no instance more marked than in those cases which I had treated without injections. Furthermore, I was always conscious that I was employing a method over which I could exercise but little control; in fact, I never knew whether the small quantity of fluid which I had injected through the catheter, had entered the cavity of the tympanum, or had merely bathed the walls of the pharyngeal portion of the tube. With the view of removing this element of uncertainty from our efforts to apply remedies to the Eustachian tube, I suggested the employment of small mops which could readily be passed through the ordinary Eustachian catheters.<sup>1</sup> I gave this plan a fair trial, but I did not secure any better results than I did by means of the simpler method of leaving the Eustachian tubes alone. Furthermore, the procedure, as I am now convinced, is not a perfectly safe one, unless we abstain from using the stronger solutions of nitrate of silver. In the case of one of my patients, a gentleman, thirty-eight years of age, and in vigorous health, I found the tubes so obstructed that the drum-membrane on both sides, appeared to rest against the promontory. I carried out the simpler plan of treatment for a few days, and then, failing to accomplish the desired result, I resorted to the use of the bougie, armed with a mop of absorbent cotton, which had been dipped in a strong solution of nitrate of silver (exact strength not known). I passed the bougie, armed with this medicated mop, about a quarter of an inch into one tube, and then, after saturating the mop a second time, pushed it about the same distance into the other tubal orifice. While I was cleaning my instruments I noticed that the patient had grown very pale. I asked him if he felt ill, and he replied in the affirmative. I then took him by the arm for the purpose of assisting him to walk to the sofa, but by that time he had lost con-

---

<sup>1</sup> A Method of Using Medicated Eustachian Bougies. Transactions of the American Otological Society, 1875.

sciousness, and simply slid from his chair down upon the floor. His breathing rapidly became stertorous, and he passed into a violent convulsion which lasted fifteen or twenty seconds. The muscles then became relaxed, and perfect consciousness returned, the patient expressing great surprise that he should be lying stretched out upon the floor. His urine was examined, but it was found to be perfectly normal. The unconsciousness and convulsions were probably due in this case to a reflex spasm of the arteries of the brain, dependent upon the irritation supplied by my introduction of the bougie (saturated with a strongly irritating solution) into the Eustachian tube.

The employment of bougies is said to be attended by another danger, viz., that of lacerating the parts, and thus opening the way for the development of emphysema. This accident can only occur, I believe, when undue violence is employed in the manipulation of the bougie; for at one time (1874-5) I used this instrument very frequently in private practice, in young children as well as in adults, and yet I have never seen a case of emphysema following its employment. The free end of the whalebone bougie should be well wrapped in cotton, so that it shall present a perfectly blunt, soft mass; and if this precaution be taken, it is difficult to comprehend how laceration of the parts can result from the introduction of the bougie unless positively rough manipulations are employed.

The introduction of vapors into the middle ear is recommended by some authorities as an excellent therapeutic procedure in cases of subacute catarrhal inflammation of the middle ear. Some, for example, extol the beneficial effects of "steaming" the middle ear; others recommend highly the introduction of the vapor of iodine, or the fumes of sulphuric ether or chloroform. With regard to all these methods of treatment, I think we should put to ourselves the question, Do they accomplish better results than the simpler methods now generally employed? If they fail to accomplish a more speedy or a more perfect cure, I am at a loss to see why we should continue to use them. The evidence which I have gathered on this subject, partly from my own experience and partly from that of my colleagues, points very decidedly to the conclusion that these methods are not more efficient than the simpler plans now very widely adopted. I may therefore omit any further detailed account of these methods, and will pass on to the consideration of those other local therapeutic measures about whose beneficial effects there is very little dispute.

If we exclude those methods of treatment which aim to bring the different remedies in direct contact with the mucous membrane of the Eustachian tube and middle ear, we virtually establish the rule that, *in cases of simple uncomplicated acute or subacute catarrhal inflammation of the middle ear, all direct therapeutic interference with this region by means of drugs is to be dispensed with.* In certain complicated cases it will be found advantageous to introduce remedies into the cavity of the tympanum, but these cases are quite exceptional.

It is in the form of disease which we are now considering, that *inflations of the middle ear*, by means of compressed air, are especially efficacious. Whatever theory we may adopt with regard to the precise manner in which these inflations exert a beneficial effect, there can be very little doubt that a large part of this good effect is to be attributed to the restoration of the *membrana tympani* to its normal position;—and a return of the drum-membrane to its normal position almost necessarily implies a return of the entire chain of ossicles to a normal position. Inflations, however, probably do good in other ways. Thus, for example, it is not unlikely that the sudden rush of air through the Eustachian tube may dislodge portions of mucus which help to obstruct that channel. In the next place, the pressure exerted upon the oedematous mucous membrane of the middle ear and Eustachian tube must promote the absorption of the cellular and fluid elements to whose presence the swollen state of these parts is due. Whether these speculations with regard to the *modus operandi* of inflations be correct or not, the fact of their decidedly beneficial effects will scarcely be seriously disputed at the present time.

The first practical question that presents itself in connection with the therapeutic employment of inflations is this: Shall we use the catheter, or shall we trust to what is known as Politzer's method? As good results are obtained with both plans of procedure, it is not strange that the question should be answered differently by different men. The following considerations guide me in my choice between these two methods. As patients have a much greater repugnance to catheterization than to the employment of Politzer's method, and as the latter procedure is generally just as effective as the former, I always endeavor to dispense with the catheter, if circumstances will permit. Furthermore, it must be remembered that the presence of the catheter in the nasal passage and in the mouth of the Eustachian tube produces a certain degree of irritation. In a few cases I have observed that this irritation was sufficient to counterbalance the good effects of the inflations; at all events, appreciable improvement in the condition of the ear and in the acuteness of the hearing did not appear in these cases until after I had abandoned the catheter, and restricted myself to the employment of Politzer's method. There are cases, however, in which, for various reasons, Politzer's method fails to drive air with adequate force into the middle ear. Under these circumstances our course is clear: we must employ the catheter.

The next practical question is this, How often should we employ either of these two methods? To this question I can only give a more or less arbitrary answer. I really do not know whether it is better to inflate the ears several times daily, or only once a day, or even only on alternate days. I do know, however, that in the class of cases which we are now considering, I obtain reasonably good results by resorting to the inflations—four or five successful ones at a sitting—only every other day. Too frequent in-

fiations may undoubtedly do harm, especially if the practice be continued for a period of several weeks or months ; but it would be a difficult matter to define the limit beyond which inflations begin to be harmful.

It is equally difficult to lay down rules with regard to the proper duration of such a course of treatment. In subacute cases of recent origin two or three repetitions of the inflations on alternate days may be found sufficient to restore the drum-membrane permanently to its normal position, to remove every trace of congestion or swelling, and to bring back the hearing to its former degree of acuteness. In other cases—and these perhaps represent the average—a course of treatment covering a period of two or three weeks will be found necessary for the accomplishment of the same results. Finally, in the more stubborn cases, I very rarely keep up systematic treatment beyond the fourth or fifth week. I prefer to give the parts an absolute rest of two, three, or four weeks, and then, if necessary, resume the inflations and the applications to the naso-pharynx.

If, in these cases of catarrhal inflammation of the middle ear, the evidences of congestion are slow to leave the *membrana tympani*, the application of one or two leeches in front of the tragus, on alternate days, until five or six have been applied, will sometimes hasten recovery very materially. The employment of leeches, for the relief of pain, will be considered under the heading of Treatment, in the chapter relating to Purulent Inflammation of the Middle Ear.

*General measures.*—In the great majority of cases the local treatment alone will be found sufficient for the removal of the patient's symptoms. In a few cases, however, we may find it necessary to resort to other measures. Thus, for example, I have repeatedly met with patients who were affected with a naso-pharyngeal catarrh (either a recent attack or an exacerbation of a more chronic process) which resisted all my efforts to control it. At the end of the third week, having failed to materially improve the condition of the parts, I have urged the patient to get a change of air and scene for a week or ten days, or even longer, if necessary. One patient visited Savannah, another Aiken, S. C., a third Lake George, a fourth the Catskills, and so on ; and in nearly every instance with the effect of entirely throwing off all active manifestations of the catarrh. Again, in some of these cases, there is another feature which the physician must be careful not to overlook. I refer to the important part which disturbed gastric digestion plays in promoting a naso-pharyngeal catarrh. Thus far I have observed such a relation only in rather stout, full-blooded individuals, who took very little exercise and yet ate heartily. Local applications to the pharyngeal and naso-pharyngeal mucous membrane accomplish very little in such cases. An adequate daily amount of exercise, a diet of more easily digested articles of food, and the practice of daily sponging the entire surface of the body with cool water and then employing friction with a rough

towel, are the best means that I know of for eliminating whatever influence disturbed gastric digestion may exert upon a naso-pharyngeal and aural catarrh.

*Treatment of Special Stages or Conditions.*

To avoid repetition, I will say nothing at present about the treatment to be pursued in the painful stage of an acute otitis media catarrhalis. In this stage of the inflammation it is impossible to decide positively whether the attack will eventually be of the catarrhal or of the purulent variety. It seems better, therefore, in all cases to assume that the attack will be one of purulent inflammation of the middle ear; and for this reason I will refer the reader to the section relating to the treatment of that variety of ear disease.

The question which demands our attention more particularly in the present section is this: How far ought we to modify the plan of treatment just described, when we discover that a serous fluid or a mucoid material fills a large portion of the tympanic cavity? Here, again, it is scarcely possible to formulate a rule that will be found generally applicable in practice. Each case differs in some respects from the preceding one, and accordingly, our treatment must vary correspondingly. In former years I followed, for a time, the practice of always incising the drum-membrane, and evacuating the fluid, as soon as I discovered a sufficient amount of it in the tympanum to apparently half fill that cavity. I very soon found, however, that relapses were exceedingly frequent. I accordingly modified the rule to this extent. I postponed making the incision and evacuating the fluid until after I had materially diminished the naso-pharyngeal catarrh, and had re-established a free passage through the Eustachian tube. Under this régime I observed now and then a case in which the fluid contents of the tympanum gradually disappeared coincidently with the improvement in the condition of the naso-pharynx; thus rendering paracentesis unnecessary. This suggested to me the idea that the treatment employed in the ordinary cases of catarrh of the middle ear, without effusion, would probably be found equally successful in those with effusion. I accordingly dismissed from my mind the idea that paracentesis was either necessary or desirable, as a means of getting rid of the effusion in the tympanic cavity, and adopted the practice of treating these cases in precisely the same manner as I do the ordinary cases, in which there is no appreciable amount of effusion. I have followed this practice now for several years, and am well satisfied with it. It is only in rare cases now that I yield to the temptation to make an incision and evacuate the fluid; and even in some of these I have afterward arrived at the conclusion that the case would have got well just as quickly if I had not had recourse to the knife.

In some of the more stubborn cases I employ counter-irritation behind



and below the auricle. For this purpose I use either tincture of iodine or the cantharidal collodion. I instruct the patient to apply, every night before retiring, two or three coats of the iodine to the mastoid region of the side affected. As soon as the skin becomes uncomfortably sore,—*i.e.*, generally on the third, fourth, or fifth day,—the parts are to be left undisturbed for two or three days, and then the iodine is again to be applied every night in the same manner as at first. In several cases in which I used tincture of iodine in the manner just described, I was disposed to believe that the improvement which followed the employment of this remedy was fairly to be attributed to the property which it possesses of stimulating the absorbents to greater activity. The beneficial effects obtained with cantharidal collodion are undoubtedly to be attributed to this same property of stimulating the absorbents. I have used the latter preparation in the following manner: I apply two or three coats of cantharidal collodion to the skin of the mastoid region, cover it with Husband's plaster or the rubber plaster, or with simple collodion, and then keep up slight pressure over the spot by means of a soft linen pad held firmly in position by a bandage or handkerchief passed over the top of the head and under the chin. After a distinct sac containing fluid has formed, the patient should remove the bandage and pad, evacuate the fluid, and then cut away the dead cuticle. The remaining inflamed surface should then be dressed for a short time with vaseline or any other simple ointment. As soon as the skin has returned to a comparatively normal state, the same procedure may be repeated. As the tincture of iodine appears to be at least as efficacious as the cantharidal collodion, and as it can be managed much more easily than the latter, I now use it almost exclusively under the circumstances described above.

After the different measures which I have described have been tried for a reasonable length of time, say for three or four weeks, without materially diminishing the fluid exudation in the cavity of the tympanum, we may with advantage resort to paracentesis of the drum-membrane, for the purpose of providing an opening through which the fluid may be driven out into the external auditory canal, and also, in certain cases, for the purpose of confirming or modifying our diagnosis. This operation, if performed with a reasonable degree of care by a physician who knows something about the anatomy of the middle ear, may be considered as perfectly safe. There is but one real danger, and that is this: the operator may, with the point of his knife, injure the delicate attachments of the anvil, or drive the stirrup into the vestibule with such force as to rupture the annular ligament or injure some of the delicate labyrinthine structures. However, the attachments of the stirrup to the oval window are quite strong, and this ossicle can unquestionably be handled rather roughly without serious injury being caused to the organ of hearing. The attachments of the hammer are also very powerful. On the other hand, those of the anvil are very

feeble. This ossicle is as it were suspended between the hammer and the posterior wall of the tympanum. The bands which attach it to the hammer are extremely delicate. From these the anvil derives little or no stability; but from the peculiar interlocking of the articular surfaces it derives probably its chief strength. At best, however, this ossicle possesses very feeble supports, and may easily be disconnected from the hammer by the manipulations of an ignorant or careless operator. In incising the *membrana tympani*, therefore, we should so guide the end of the slender spear-pointed knife that it shall not strike the end of the long process of the anvil or the attached head of the stirrup. All these parts which are to be avoided occupy, fortunately, a comparatively small portion of the area within which the knife can be used. This dangerous region occupies about half (the upper half) of the posterior superior quadrant. Hence we may, without the slightest fear of injuring the ossicles, begin our incision a little above the dividing-line between the upper and lower posterior quadrants, and midway between the handle of the hammer and the periphery of the membrane, and carry it down nearly to the lower limit of the latter. The *membrana tympani secundaria* need give us no anxiety, as it lies safely concealed in its niche of bone, quite out of reach of any straight instrument that might be introduced through the outer meatus. Furthermore, if the point of the blade be carried too far inward, the only result will be an incision or a punctured wound of the mucous membrane covering the inner bony wall of the tympanum, a result that has no significance in the pathological conditions now under consideration. If the fluid exudation in the cavity of the tympanum be serous or only slightly mucoid in character, such a linear or slightly curved incision as I have described will afford an ample outlet for its escape. But if it be more decidedly mucoid in character, such a mere slit will not be found adequate. A second incision must then be made, at right angles to and opposite the middle point of the first one. In making this second incision we should cut in the direction from the periphery toward the centre of the membrane, and not from the existing incision backward.

It is by no means an indifferent matter what sort of a cutting instrument is used in making an opening in the *membrana tympani*. In a general way it may be said that a spear-pointed, two-edged blade is the best adapted to this purpose. In the construction of such a knife—or *myringotome*, as it is often called—regard must be had to the relations of the drum-membrane to the inner wall of the tympanum. Thus, for example, it is safe to assume that we shall never be called upon to incise a membrane whose posterior half occupies a position less than two millimetres distant from the inner wall of the tympanum. We may also take it for granted that we shall never find it necessary to incise a membrane so distended that it occupies a position more than five millimetres distant from the inner wall of the tympanum. It is therefore unnecessary to have the cutting

edges of the spear-pointed knife of greater length than five millimetres. The myringotomes which I use have cutting edges only three and a half millimetres in length, and I find them amply long. In the next place, it is desirable that the spear-headed blade should be quite broad at its base; the breadth in this case being measured from cutting edge to cutting edge. In children and sensitive people a single stab is often all that we can obtain, unless we resort to the use of an anæsthetic. Under such circumstances the broader the blade of our knife, the greater will be the length of our incision in the drum-membrane. In my instruments the greatest breadth is barely three millimetres. Possibly a breadth of three and a half millimetres would be found better adapted to all the purposes for which a myringotome is used; but we must not forget that we are often called upon to operate in a canal of very small calibre, and that even a slight increase in the size of the knife may be sufficient to greatly increase the difficulty of the task of operating successfully.

It is largely a matter of individual preference whether a straight or a slightly bent myringotome be employed. After using both kinds, I have gradually fallen into the habit of using only the straight instrument. It seems to me that I can control such a straight myringotome more perfectly than I can a bent one. Those which I use are made from a single piece of steel, 16 ctms. long; the slender shank together with the blade measuring 7 ctms., while the eight-sided, roughened handle measures 9 ctms. in length.

I do not remember ever to have found it necessary to resort to an anæsthetic in a case requiring paracentesis of the comparatively healthy membrana tympani. The pain caused by the incision must therefore be only moderately acute. It is also of very short duration. As soon as it has subsided, we should inflate the middle ears, according to Politzer's method, taking the precaution first to make the patient incline the head well over toward the shoulder of the side on which the drum-membrane has been incised, in order that the force of gravity may mass the fluid directly over the artificial opening. In a case of simple serous exudation, one or two inflations almost always suffice to drive out all the fluid into the meatus; but if the exudation consists of ropy mucus, the inflations alone will usually not be found equal to the task of expelling any considerable portion of the mass. Thus, for example, it is a common experience, after one or two vigorous inflations, to find lying just outside of the drum-membrane a small mass of mucus, which looks as if it might readily be removed with a mop of cotton; but when the attempt is made to do this, the fact is soon discovered that this mass is simply a rope-like extension of a greater mass that still remains behind in the middle ear. It is therefore better in these cases to combine inflation through the Eustachian tube with suction applied to the external auditory canal. With Siegle's apparatus we may perform effective suction, and at the same time observe exactly what is taking place

at the perforation. We may secure the requisite inflating power by instructing the patient to perform Valsalva's experiment at the moment when the sensation of tightness caused by the suction begins to be felt in the ear. In this way, by applying a pulling and a pushing force to the mass of mucus, we may often succeed in removing quite a large portion of it. There is but one way, however, in which we can be sure of removing every trace of mucus from the tympanum, and that is by washing out this cavity with tepid water. I have employed this procedure in such a small number of cases of well-marked otitis media mucosa that I do not feel justified in expressing an opinion either for or against it. In a somewhat different class of cases (see farther on) I have washed out the middle ear with the very best results, and I am disposed to believe that, in the class of cases now under consideration, equally good results may be obtained. I prefer, however, to wait until I have had further experience with the effects of this procedure before I recommend it to others.

After reasonable efforts have been made to drive out the mucus from the tympanum, my rule has been, at least during the past four or five years, to allow the perforation to heal, and then to treat the case in precisely the same manner as if it were an ordinary case of subacute otitis media catarrhalis. If we repeat our efforts to drive out the mucus, and reopen the wound in the drum-membrane too often, we shall be almost certain to set up a more or less active inflammation of the parts, and thus materially retard the patient's recovery. Individual cases, however, differ so much in their predisposition to inflammation, that it is scarcely possible to prescribe the limits beyond which it is not wise to go in our efforts to free the tympanum from mucus. In several instances I have had good grounds for believing that my therapeutic interference had, in the main, done more harm than good. I will give here, in brief outlines, the history of one of these cases.

The patient, a gentleman about forty years of age, and in a fair state of health, consulted me on the 5th of October, 1878, for an affection of the left ear. During the previous two weeks he had experienced moderate deafness and a feeling of fulness in the left ear, without pain. On examination I found the membrana tympani appreciably swollen, bulging posteriorly, and somewhat red. On auscultation during inflation, I heard crackling sounds in the left ear. I made a diagnosis of subacute catarrhal inflammation of the left middle ear, with considerable fluid exudation in the tympanum, and an unusual degree of swelling of the tympanic mucous membrane; and submitted the patient to the usual treatment (inflations and applications to the naso-pharyngeal space). In the hope of hastening his recovery, as he was desirous of leaving the city at an early date, I applied a blister to the mastoid region, and prescribed a preparation of Calisaya bark, to be taken internally.

On the 9th of October, I found the posterior half of the membrana tympani still markedly bulging. I therefore made a free vertical incision through the middle of the protruding portion, and was surprised to see the edges of the wound gape widely apart, as commonly happens when a cicatricial membrane is incised. This gaping of the wound displayed to view a mass of opaque mucus, which apparently filled the cavity of the tympanum. Simple inflation by Politzer's method detached from the main mass of mucus a piece about half the size of a pea, and hurled it against the upper wall, half way out of the canal. This mucus had apparently lost in a great measure its ropy character. In various ways I finally succeeded in removing several smaller pieces of mucus, all of them together forming a mass about the size of an ordinary pea. All these different manipulations, as well as the original paracentesis, caused the patient almost no pain. In fact, the anæsthesia was more marked than I had ever before observed it. The mucous membrane of the middle ear, so far as it could be seen through the gaping perforation, presented a dull, pinkish hue, quite in harmony with the anæsthetic condition alluded to above. After I had removed as much mucus as I could from the middle ear, I touched the edges of the wound lightly with a bead of nitrate of silver.

On the following day, October 10th, I found the ear perfectly quiet. No inflammatory reaction had followed. The parts were simply moist.

October 11th.—Very scanty watery discharge, without the slightest admixture of mucus. Continued freedom from pain. With a slender glass pipette (see p. 188) I introduced a small quantity of a ten-grain solution of nitrate of silver into the middle ear.

October 14th.—No return of the mucus. Wound shows little or no tendency to heal. Slight watery discharge continues. Patient is obliged to leave town for a few weeks.

November 30th.—During his absence from the city, patient has had a slight but constant watery discharge from the ear. Of late the discharge has been more abundant and thicker. On one or two occasions he experienced a moderate degree of pain in the ear, but he attributed it to the rough manner in which the syringe had been used. On examination I found the membrana tympani red, swollen, and bathed with a greenish pasty pus. By aid of the probe I discovered that the anterior cul-de-sac—the space between the drum-membrane and the anterior and lower wall of the meatus—was filled with a mass of granulation-tissue. I removed it with the snare in three or four seizures, and found that it consisted of two separate growths, one of them springing from the surface of the drum-membrane, close to the short process, the other from the edge of the perforation. The membrana tympani at all points seemed to be enormously hypertrophied, and noticeably so throughout the posterior half of the membrane, where, as seen through the large and gaping perforation, it appeared to fill the tympanic cavity solidly. The extraordinary course pursued by the dis-

ease in this case led me to suspect that perhaps it was complicated by syphilis. I accordingly investigated this point thoroughly, but failed to obtain the slightest evidence corroborative of such a view. Nevertheless I thought it best to prescribe for him the following :

R.

Hydrarg. bichlor.....	gr. j.
Potass. iodidi.....	ʒ v.
Tinc. gentian. compos.....	ʒ j.
Aquæ.....	ʒ iij.

M. S.—A teaspoonful three times a day after meals.

December 9th.—Since the last date the local treatment has consisted in applications, first, of nitrate of silver in the form of a bead, and afterward of powdered burned alum, to the spots from which the granulations grew. Under this treatment the discharge diminished very perceptibly, and the outer surface of the drum-membrane again became smooth and firm, but the gaping perforation and the enormous hypertrophy of the mucous membrane of the membrana tympani still persisted apparently unchanged. As the iodide of potassium produced quite a decided coryza, and brought out a reddish eruption on the face, I abandoned the idea of a syphilitic taint, and discontinued internal treatment.

A few days later the patient was again called out of town, and I have not seen him since.

I have always felt that this case, which is certainly an extraordinary one in many respects, would have got along better if I had treated it less vigorously. On the other hand, I can recall a very similar case, which I treated at the New York Eye and Ear Infirmary in an equally vigorous manner, but with very different results. The drum-membrane presented the same bulging appearance, and upon incising it the edges of the wound separated in precisely the same manner as in the preceding case. Instead of driving out the almost gelatinous mucus which apparently filled the tympanum, I boldly inserted a bead of nitrate of silver through the artificial opening and turned it upward and backward so as to bring it well in contact with the swollen mucous membrane of that region. Four days later, when the patient called a second time, I found the posterior half of the drum-membrane flat instead of bulging, and a dry scab occupied the site of the incision. In the course of another week or ten days, without any further treatment during the interval, the parts returned to a comparatively healthy state, all evidences of an accumulation of mucus disappearing completely.

In the following case, which presented very nearly the same physical conditions as those observed in the two preceding cases, I tried still another plan of treatment. The patient, a gentleman about fifty years of age and

in vigorous health, gave a history of slight deafness and a sensation of fulness in the right ear dating two months back. On examination, April 20, 1879, I found the right drum-membrane dull, opaque, and noticeably bulging posteriorly and superiorly. This condition was associated with a slight naso-pharyngeal catarrh. The watch was heard only when pressed against the ear. Without going into all the details of this case I may say that on the 23d I made a free linear incision in the bulging posterior half of the drum-membrane. As the edges of the wound gaped, I could see that the membrana tympani in this locality was very much hypertrophied through swelling of its lining mucous membrane. By means of Politzer's method of inflation I drove out a limited amount of mucus. I then used combined suction and inflation in the manner already described, but failed to evacuate any additional mucus. Finally, I introduced a curved slender glass tube into the tympanic cavity, and employed suction. These efforts, however, failed to remove any perceptible amount of mucus.

On the 27th of April, no inflammatory reaction having followed my interference on the 23d, I removed the scab which covered the wound, and injected, with a middle-ear pipette, a rather strong solution of bicarbonate of soda into the tympanum. I assumed that there must be more of the thick mucus, such as I had already removed, still remaining behind in the tympanum; and I thought that the solution of bicarbonate of soda would, in the course of a few minutes, soften it to such an extent that I should be able to remove a large part of it by means of Politzer's method. The experiment proved in a measure successful; at all events, it was found, after inflation, that a fair amount of ropy mucus had been driven out through the perforation in the membrana tympani, and that the patient's hearing had become somewhat more acute (H. D. W. = one inch).

May 1st.—Patient having experienced no pain in the ear as a result of the procedures just described, I ventured to re-open the wound a second time. I found the tissues still greatly swollen, but on inflation the air escaped freely through the perforation, with little or no admixture of fluid. I therefore decided to restrict my treatment to daily inflations of the middle ear (according to Politzer's method). The patient performed the inflations himself at his home, and presented himself for examination on the 18th of May. I then found that the bulging of the drum-membrane had entirely disappeared, and with it probably the greater part of the swelling which had constituted such a prominent feature in the case. The patient no longer experienced any difficulty in hearing what was said to him, and the sensation of fulness in the ear had entirely disappeared. Notwithstanding this subjective and objective improvement, the patient could distinguish the ticking of my watch only at a distance of two inches.

If the perusal of these histories of cases of otitis media mucosa leaves the reader in a state of doubt as to what course of treatment he should adopt under similar circumstances, I must confess frankly that I am not

yet in a position to urge confidently any of the plans which I have described. The excellent results which have followed my comparatively recent adoption of the plan of thoroughly washing out the middle ear in cases of otitis media purulenta, lead me to hope that I shall find the plan equally successful in these cases of otitis media mucosa. Unfortunately they are

of rather rare occurrence, and I am still waiting for an opportunity of testing the question for myself. Seven or eight years ago, after reading Hinton's monograph on the subject of washing out the middle ear, I made a single trial of the plan, but with such disastrous results that I have not, until recently, felt disposed to repeat the experiment. In the case just mentioned, however, I am now quite sure that the serious inflammation which followed ought not to be attributed to the cleansing procedure, but should rather be ascribed to the effects of the remedial solution (alum) introduced into the tympanum immediately afterward. Solutions of alum, no matter how dilute, are, I believe, dangerous to use in the middle ear. On the other hand, I have now used weak solutions (gr. ij. to the ounce of water) of nitrate of silver so often in this way that I never feel any anxiety about unpleasant after-effects. My idea with regard to the washing-out method is simply this: it frees the swollen and inflamed mucous membrane of the middle ear from its coating of mucus and other products, and thus enables the physician to bring his remedial solution in contact with it at every point.

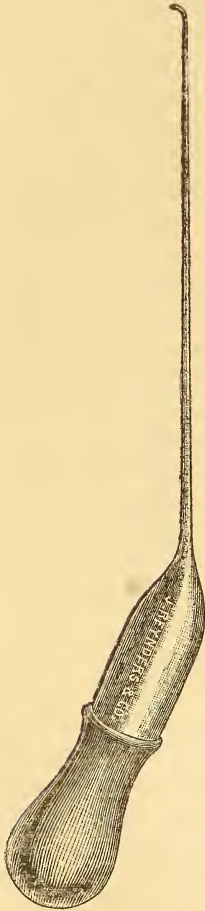


FIG. 17.—Middle-ear pipette.

This brings us now to the question, How shall we wash out the middle ear, and how shall the remedial solution be introduced? For both of these purposes I have a decided preference for slender glass tubes, to which, for the sake of convenience, I have given the name of "middle-ear pipettes" (see Fig. 17). These pipettes are made from glass tubing, about three-eighths of an inch in diameter, and with rather thick walls. As these pipettes are not so very difficult to make, I will describe briefly the steps of the procedure. Take a piece

of glass tubing, about eight inches in length, hold the ends lightly with the fingers of both hands, and rotate it slowly around its long axis over the blue flame of a Bunsen burner. As soon as the central portion of this bit of tubing has become sufficiently soft,—not at one small spot merely, but over a section of the tube say from half to three-fourths of an inch in length,—draw it out into a slender tube about ten inches long. As the pipette when completed should measure not less than seven centi-



metres in length in its slender portion, the next step should be to file a shallow circular notch around the tube, at a point eight or nine centimetres distant from the shoulder—if I may so designate the spot where the larger tube begins to grow narrower—and then break the tube at this spot. As it is desirable to have the tip of the pipette slightly bent, we should next heat it very cautiously until it bends over, from its own weight, in the direction that we desire it to follow. If the tip beyond the final bend is too long, or if the heat has caused the orifice of the narrow canal to become closed, a circular notch should be filed in the tip, at a distance of not more than two millimetres from the bend. To render this fractured end sufficiently smooth, it may either be brought sufficiently near to the Bunsen flame to fuse the sharp edges, or these may be ground smooth by a suitable file or stone. The broad portion of the tube, if too long, should be filed and broken off at a distance of from three to five centimetres from the point where it begins to grow narrower. Before doing this, however, the physician should heat the tube at this shoulder and bend it at an angle of about 120 degrees. The rubber caps attached to the glass droppers usually sold by the apothecaries may be fitted in a similar manner to these pipettes, and will be found to answer well the purposes for which they are intended.

In practice it will be found necessary to have right and left pipettes, as one adapted for the introduction of fluids into the right mastoid antrum cannot be used for this purpose in the left ear. A third pipette, with the tip bent directly downward (when the instrument is held with its rubber cap pointing downward), will also be found useful in those cases in which the perforation occupies the anterior inferior quadrant of the drum-membrane.<sup>1</sup>

It is scarcely necessary to discuss here at length the question whether the curved or the straight tips are the better adapted for general use. My own preference is for the former. With the straight tip one is apt either to push it in too far, or to unintentionally draw it out of the tympanic cavity altogether, in both of which cases no fluid from the pipette will reach the middle ear. On the other hand, with the curved tip, it is possible to push it firmly against the mucous membrane of the promontory without thereby closing the aperture; and if we draw the tip too far outward, the resistance offered by the membrana tympani gives us timely warning of what we are doing. Furthermore, the curved tip enables us to direct the current of the escaping fluid toward or into the mastoid antrum. For all these reasons I consider the curved tip decidedly preferable to the straight one.

As glass pipettes may easily be broken, it is urged by some that these instruments should be constructed of platinum. Those who are unable to

---

<sup>1</sup> To obviate the necessity of going into these details a second time, I can scarcely avoid alluding to forms of ear disease which do not belong in this section.

make their own pipettes, or who are not within easy reach of an instrument-maker, cannot probably do better than to follow this recommendation. In the course of three or four years I have broken perhaps the same number of pipettes, at a total cost of not more than twenty-five cents. A good set of platinum pipettes, similar in all respects to the glass ones which I have described, can scarcely be purchased for less than twenty dollars. To very many men this expensiveness of the platinum instruments would prove a serious objection to their use. I am therefore disposed to plead strongly in favor of the glass instruments. One writer has said that: "In order to be available, such an instrument [referring to the glass pipette] must be so very delicately constructed that even in skilled hands it would not be entirely free from danger; for, having been passed through the perforation in the membrana tympani, the patient, in an unguarded moment, might suddenly draw his head away from the operator, and the delicate hook-shaped extremity break off, fall into the middle ear, and its removal would certainly not be unattended with difficulty."<sup>1</sup> The objection raised by Dr. Andrews may be applied with almost equal force to any instrumental manipulations about the drum-membrane or adjacent parts. The fact is, only those who are provided with "skilled hands" have any right to operate upon a drum-membrane or middle ear that is not acutely inflamed.<sup>2</sup> In the hands of such persons I consider the glass pipette as a reasonably safe instrument. I have used it a great many times, in young children as well as in adults, and yet I have never met with the accident to which Dr. Andrews refers. Whenever I have broken a pipette it has been through carelessness in transporting it from one place to another, but never during any manipulations about the ear.

As I have already stated, the middle-ear pipettes may be used either for the purpose of washing out the middle ear, or for that of introducing remedial solutions into that cavity. If our object is to only partially wash out the middle ear, the simplest plan is to draw the pipette full of water at a temperature of from 100° to 105° F., and then, after introducing the curved tip through the perforation, to throw the entire contents steadily but not too slowly into the tympanum, and preferably in the direction of the antrum. I usually repeat the operation a second or perhaps even a third time, always taking the precaution each time to mop up the fluid that has been driven out into the meatus. If a more thorough cleansing of the middle ear is thought desirable,—as in cases of otitis media mucosa, in which the mucus is very tough,—the best plan is to attach the pipette to the rubber tubing of a Clark's or fountain douche, filled with water at a

<sup>1</sup> J. A. Andrews, M.D., Archives of Medicine, April, 1880, New York.

<sup>2</sup> In cases of acute inflammation of the middle ear, the circumstances may be such that operative interference on the part of a person whose hands are not skilled may be perfectly proper.

temperature of from 105° to 110° F. As the water cools rapidly in its passage from the reservoir to the pipette, it is important not to introduce the instrument into the middle ear until the water has been allowed to run for a few moments from the curved tip. Then, compressing the rubber tube with the thumb and forefinger, close to the point where it is attached to the pipette, we should introduce the tip into the middle ear, and then, when everything is ready, allow the water to flow through the pipette by relaxing our pressure upon the rubber tube. A sponge held beneath the ear will catch all the fluid that escapes from the meatus. As soon as the water begins to flow out through the perforation, the exact position of the pipette can no longer be judged by actual inspection. It is therefore a matter of great importance that we should hold the instrument very steadily during the flow of water into the middle ear; for if we fail to take this precaution, we shall run a great risk of injuring the structures of the middle ear, or shall fail utterly to wash out that cavity. Just before the water is allowed to flow through the pipette we may gain some assistance in holding the instrument steadily in its proper position by grasping the slender portion with the thumb and forefinger of the left hand, the remaining fingers of which find a firm resting-place against the patient's cheek or mastoid process. With regard to the quantity of water that should be allowed to flow through the middle ear, I can only assign an arbitrary limit, say from half an ounce to an ounce. At the same time I should not hesitate to use three or four times that quantity if I had any reason for believing that the smaller amount had failed to dislodge the mucus.

When it seems desirable to wash out the middle ear in a more thorough manner than can be done with the pipette when simply armed with the rubber cap, I believe that Blake's middle-ear syringe (see Fig. 18) will be found to answer this purpose fairly well. The great objection to the employment of a syringe for delicate work of this kind is the difficulty which one experiences in holding the nozzle steadily at one small spot while simultaneously pushing in the piston with the thumb of the same hand. On the other hand, this syringe possesses, at least for cleansing purposes, the fol-

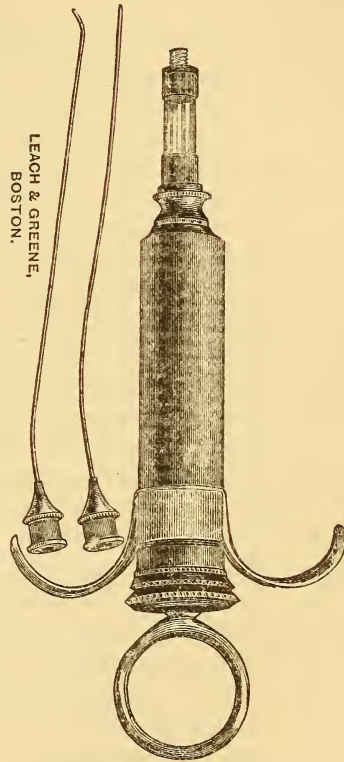


FIG. 18.—Blake's middle-ear syringe.

lowing decided advantages over the douche and pipette: it is decidedly less cumbersome, and it can deliver a stream of much greater strength.

After the middle ear has been washed out sufficiently, it is desirable to get rid of as much of the water that remains behind as we can. If we allow the water to remain, it will dilute to an unknown degree the remedial solution employed, and thus perhaps prevent the effect desired. The better way is to resort to inflations immediately after the cleansing process, and thus remove at least the greater part of whatever fluid may be in the tympanum.

As already stated, the foregoing remarks with regard to cleansing the middle ear are based upon an experience with a class of cases somewhat different from those which belong properly in this section. The differences, however, are often so slight that for all practical, and especially therapeutical purposes, I should be perfectly justified in considering them as identical with those to which the term *otitis media mucosa* would be strictly applicable. From this standpoint, therefore, I should recommend the employment of only weak solutions of nitrate of silver, say of two and five grains each to the ounce of water, and preferably the weaker one of these two. I have never been in the habit of warming the solution before introducing it into the middle ear. If the perforation is of ample size, I fill the pipette as full as I can and discharge its entire contents; if the perforation is quite small, I suck up into the instrument only enough to fill the slender portion of the tube, say one or two minims. If we use only the smaller quantity of fluid, it will not be necessary to pay attention to the position in which we hold the pipette; but if we have drawn up into it all the fluid that its limited suction-power can raise, we must keep the slender arm of the pipette pointing somewhat downward during the act of introducing it, or the fluid will soon run back into the rubber cap, and we shall simply drive out air into the middle ear, and thus fail in the accomplishment of our purpose. After the remedial solution has once been introduced into the middle ear, I usually allow it to remain there undisturbed and pay no further attention to it. Applications of this character can be made to the middle ear as often as three times a week. (For further details with regard to the employment of the middle-ear pipette, the reader is referred to the chapter on *Purulent Inflammation of the Middle Ear*.)

It is not an uncommon occurrence for the patient to ask the physician whether he or she cannot carry out the requisite treatment at home. Self-inflation—if I may so designate the act of inflating one's own middle ears according to Politzer's method—is not a very difficult procedure to learn; but the effective application of a remedial solution to one's own nasopharyngeal space is a far more difficult task, and one that very few patients succeed in learning. In my experience, the results obtained by self-treatment, even when the patient is a physician and thoroughly conversant with

the procedures to be employed, are rarely satisfactory in the class of cases which we are now considering.

#### CHRONIC SUBACUTE CATARRH.

In this category are generally included all those cases in which the characteristic symptoms are : progressive deafness, noises in the ears, and an intact drum-membrane. If we could examine the interior of the middle ear and labyrinth, we should probably find that the very large number of cases,<sup>1</sup> which we now, in our ignorance of the underlying pathological conditions, register under the single title of "chronic catarrh of the middle ear," would have to be divided into several distinct classes. Even at the present time we are able to recognize decided differences between these cases. Thus, for example, we may distinguish quite readily three fairly distinct groups.

In the first of these groups may be placed those cases which are characterized by evidences of congestion, and perhaps also infiltration of the mucous membrane of the middle ear, and by a similar condition of the naso-pharyngeal mucous membrane. The term *chronic hypertrophic catarrhal inflammation of the middle ear* might perhaps be adopted as a suitable name for this group of cases. It is in this class particularly that we should be on the lookout for adenoid vegetations in the naso-pharyngeal cavity.

In a second group the characteristic features are a very transparent drum-membrane (not necessarily much sunken), an apparently unobstructed Eustachian tube, and a smooth, thin, pale pharyngeal mucous membrane. The inner wall of the tympanum, as reflected through the transparent membrana tympani, appears to be unnaturally white, in marked contrast with the deeper coloring observed in the cases of the first group. This unnatural whiteness is due to the fact that the extreme thinness of the mucous membrane covering the bone allows its natural white color to be reflected back to the eye of the observer. On questioning such patients, we usually learn that at a certain period of their lives they suffered considerably from naso-pharyngeal catarrh. And in the light of this fact we are justified in assuming that the morbid process, in the ear as well as in the throat, began as a proliferative inflammation, with great increase in the connective-tissue elements, and ended in the contraction and condensation (hardening) of the newly formed connective tissue. In this process of contraction—usually, I believe, called sclerosis—the glandular elements disappear, and we have, as the final result, an unnaturally thin, non-vascular, atrophied mucous membrane. The term *sclerosis of the tympanic mucous membrane* would

---

<sup>1</sup> As a rough estimate I should say that the cases belonging to this class represent at least 30 per cent. of all of the cases that apply to the aurist for relief.

seem, therefore, to be a fairly appropriate one to apply to the cases of this second group.

Finally in a third group may be placed all the remaining cases, the prominent feature of which is the absence of all discoverable lesions of sufficient gravity to account for the marked impairment of the hearing. We can simply guess at the real nature of the pathological changes in such cases. In some of them it is possible that the auditory nerve may be the part affected; in others an ankylosis of the stapedio-vestibular joint may explain the deafness; finally, in others still, the secondary tympanic membrane may have undergone thickening or calcareous degeneration, or an exostosis<sup>1</sup> may have encroached upon it. All these lesions have been observed after death, but it is easy to understand how difficult, not to say impossible, it would be to recognize any such pathological conditions during the patient's life-time.

We may encounter cases belonging to the first group at almost any period between the tenth and the fortieth or forty-fifth year of life. Those belonging to the second group are rarely encountered before the thirtieth year; while the type of aural disease which characterizes cases of the third group may be seen in individuals of almost any age after childhood. In all the cases of these three groups the histories given are almost always the same. In those belonging to the first group we are apt to hear of ups and downs, but in those belonging to the other groups the histories all point to either a stationary course, as regards the hearing, or to one in the direction of more marked deafness. The *loss of hearing* may take place quite rapidly; as a rule however, the progress toward absolute deafness is a very slow one, and that extreme limit is rarely reached. The loss of the hearing may be a steadily progressive one for a certain period of years or months, and then, for many years, or for the remainder of life, it may make no further progress. Taken as a class, these cases are practically incurable. If our diagnosis has been correctly made, we may say, without hesitation, that no material improvement in the acuteness of the hearing can reasonably be expected from treatment, except possibly in the first class of cases. In these we must assume that a certain amount of fresh disease (or an exacerbation) has been grafted upon the original chronic malady, and to this more recent disease we may direct our therapeutic efforts with some hope of moderate success. Then, again, there is an element of hope in another direction. The physician sometimes (alas! not very often) mistakes a comparatively recent and curable affection for one of a chronic and incurable nature. A suitable course of treatment soon reveals the erroneousness of the diagnosis, by rapidly restoring the patient's hearing.

---

<sup>1</sup> At the post-mortem examination of a patient who died in the Heidelberg Hospital, in 1869, I found the head of one hammer enlarged to nearly double its natural size by an exostosis which sprang by a broad base from the very top of this little bone.

The prognosis with regard to the disappearance or continuance of the distressing *tinnitus*, is just as bad as that which I have given with regard to the hearing. *Tinnitus* of long standing is, so far as my experience goes, rarely cured.

In deciding the question, in any given case, whether to undertake *treatment* or not, I would suggest the following course:—If the case belongs to the second or third group, and the patient states that the loss of hearing began several years previously, I should advise against treatment; and in those not very rare cases, where a patient states that he can hear quite well in the midst of noise (as in a railroad car or an omnibus, or on a noisy street in one of our large cities), I should give such an unfavorable prognosis without any hesitation. If the case, however, belongs to the first group, we may give a guarded prognosis; that is, we may say to the patient that we find evidences, in the ear and in the throat (nasopharynx), that the disease is still in more or less active operation, and that treatment alone can determine how much of the existing deafness is due to comparatively recent and curable organic changes, and how much to those of a permanent character. We may then proceed to carry out the plan of treatment recommended on p. 165 and following pages, and if, by the end of say the third week, we shall not have succeeded in accomplishing at least the beginnings of a favorable result, we may without hesitation abandon our efforts.

In some cases the patients seek medical advice for the *tinnitus* alone. They often say that they will cheerfully bear with the deafness if we can only relieve them of the distressing noises in the ears. I must confess frankly that I have very rarely succeeded in affording even temporary or partial relief for this symptom. Bromide of ammonium or bromide of sodium, in ten-grain doses, to be taken either after meals, or at short intervals (*e.g.*, three or four doses during the evening), has, in my hands accomplished more, for the relief of *tinnitus*, than any other drug which I have tried. However, plenty of out-door exercise, a short sea-trip, or one among the mountains, will generally accomplish more than can be obtained by the administration of internal remedies.

## CHAPTER VII.

### DISEASES OF THE MIDDLE EAR.—PURULENT FORMS.

#### ACUTE PURULENT INFLAMMATION.

##### *Etiology.*

As I have already stated in another place, both forms of acute inflammation of the middle ear, the catarrhal and the purulent, rarely originate in any other way than by an extension of the irritation or inflammation from the naso-pharyngeal space along the Eustachian tube. In scarlet fever and small-pox, it is quite possible that the inflammation peculiar to these diseases may develop primarily in the middle ear, as well as by extension from the naso-pharyngeal space. However this may be, the fact remains that the nasal or naso-pharyngeal symptoms usually precede the aural. Scarlet fever stands at the head of the list of diseases which are apt to be followed or complicated by a purulent inflammation of one or both middle ears. Measles should perhaps be placed next on the list; and then follow, in about the order in which I name them, small-pox, typhoid fever, cerebro-spinal meningitis. Another very common cause is an acute "cold in the head," or naso-pharyngeal catarrh. I have known heat-prostration to be followed by acute purulent inflammation of the middle ear. A blow, a fall, or a sudden concussion of the air may induce a similar inflammation. During the summer season, ocean-bathing, or, rather, bathing in salt water, figures prominently as a cause of purulent inflammation of the middle ear. The different methods of flooding the nasal passages with remedial solutions or with simple water are all liable to produce an acute inflammation of the middle ear. Dr. Cornwell, of Youngstown, Ohio, in *The Transactions* for November, 1879, refers to a case that occurred in the Brooklyn Eye and Ear Hospital, in which an acute purulent inflammation of the middle ear followed the introduction of the vapor of chloroform and ether through the catheter into the middle ear. Finally, in addition to these, I should mention the establishment of an artificial opening in the drum-membrane as a not uncommon exciting cause of the change from an otitis media catarrhalis, with a serous or mucoid exudation, to an otitis media purulenta.

It is held by some authorities that a diffuse inflammation of the exter-



nal auditory canal may extend to the middle ear, and set up there a purulent inflammation, with perforation of the membrana tympani. I do not remember ever to have seen a case in which this sequence of events, the reverse of that which we usually encounter, took place. I should feel much more disposed to believe in the development of an otitis media purulenta from an extension of an inflammation of the brain or its meninges, as is claimed to be a fact by some German authorities.

*Pathology.*

In my description of the acute catarrhal form of inflammation of the middle ear, I spoke of the changes observed in the drum-membrane when the disease had reached its highest point. These appearances are precisely the same as those observed in the purulent form of inflammation at a certain stage in the progress of the disease. While in the catarrhal form these appearances from that time forward steadily become less and less marked, until finally the drum-membrane returns to its natural state, in the purulent variety a series of other changes first take place before the stage of retrogression and healing sets in. These changes, which I will now endeavor to describe, are probably never all observed in a single case. On the other hand, an attack of acute purulent inflammation of the middle ear can scarcely run its course without developing one or more of them.

In well-marked cases, one of the most characteristic changes often observed is the formation of a sac or blebs, containing a colorless or blood-stained serum, at the upper boundary of the drum-membrane, close to the short process of the hammer. Such a blebs may form at any point of the periphery of the drum-membrane, though it is more apt to form at the point mentioned than at any other. The main trunks of the blood-vessels of the membrana tympani congregate at this spot, and the strain upon them, when inflammatory stasis takes place, is probably very great. If a rupture of one of these vessels does not take place, the blebs formed will be perfectly colorless; generally, however, a rupture does take place, and we then find a dark purplish tumor occupying the region of Shrapnell's membrane, and concealing a part of the membrana tympani. With regard to the size of these cystic tumors, I may state that I have sometimes seen them of sufficient size to fill the inner end of the meatus and completely conceal the drum-membrane. In the majority of cases, however, they are much smaller, viz., from the size of a pin's head to that of a No. 2 shot. These tumors are occasionally seen in cases of acute otitis media catarrhalis, but they are far more common in the purulent form of inflammation.

The development of a bulging condition of the posterior half of the drum-membrane is another change, which may be said to be almost always present in the really acute cases when they reach the proper stage. This

bulging is of course due to the pressure of the fluid exudation that is contained within the tympanum, and that is constantly increasing in quantity. In some cases it develops at a comparatively early stage of the attack ; in others it may not occur until after the tissues of the drum-membrane and surrounding skin of the canal have become so much infiltrated that a distinct convexity (outward) of the posterior half of the membrane can scarcely be recognized.

Simultaneously with the development of the bulging condition, and sometimes before that event, or independently of it, an exudation of fluid takes place upon the outer or free surface of the drum-membrane. At first this exudation causes the dermoid layer of the membrane to become white and opaque. Then follows a period of several hours, or two or three days, during which sufficient fluid is thrown off from the inflamed drum-membrane to render the external auditory canal perceptibly moist. In this scanty secretion whitish flakes or masses of epidermis are usually found. The drum-membrane, during this period, is apt to present a whitish appearance. Ordinary syringing or mopping with the cotton-holder, armed with cotton, will often fail to remove this outer whitish layer, and thus a novice may easily be misled into believing that he is looking at a pale and uninflamed drum-membrane. With the aid of the slender middle-ear probe or the smaller curette, one can readily satisfy himself that beneath this whitish, soaked epidermis the drum-membrane presents all the appearances of being intensely inflamed. At a somewhat later stage this clinging of the soaked epidermis to the subjacent tissues ceases to be a noticeable feature.

The participation of the soft parts of the adjacent external auditory canal in the inflammation of the middle ear is an event that would be naturally expected, in view of the intimate vascular and nervous relations that exist between these two regions. In the less severe cases this participation is very slight ; in the more severe ones it may lead even to the complete obliteration of the osseous portion of the canal.

Again, the drum-membrane, partly under the effects of the pressure from within, and partly through the melting away or death of a limited portion of its substance, gives way at some point, and thus affords relief from the tension of the fluid in the tympanum by furnishing it with an outlet. Such a perforation may develop at any part of the drum-membrane. One would expect that the part most likely to become the seat of such a rupture would be the central portion of the posterior half, where the tension usually seems to be greatest. While the tension may seem to be greater at this part of the *membrana tympani* than at any other, it is probably a fact that the tension is equally great at all points of the membrane. If this be a fact, the *apparent* difference in tension must be due to an optical delusion, which in turn is probably favored by the circumstance that the posterior half of the drum-membrane is much nearer the observer's eye than the anterior half. From the fact that the perforation may occur at almost any part of the

membrane it is fair to assume that the rupture occurs at that spot which is weakest, either through a congenital or through an acquired defect in the nutrition or structure of the part. In scarlet fever, and perhaps also in small-pox, it is probable that an actual death of a limited area of the drum-membrane—or sometimes even of the entire membrane—has more to do with the development of the perforation than has the direct force of pressure. How else can we explain the enormous losses of drum-membrane tissue observed after scarlet fever in young children? I once had the opportunity of observing this gradual melting away of a considerable portion of the membrana tympani in a boy four years old. I was called to see him soon after desquamation had ceased, and perhaps three or four days after he had begun to complain of his ear. The canal was slightly moist, and the drum-membrane was covered with a whitish pasty material. There was only a moderate degree of bulging, and the boy complained very little of pain. In the course of one or two days I recognized the existence of a small perforation in the central portion of the membrane. Little by little this perforation increased in size until, after the lapse of about two weeks, it measured perhaps a full millimetre in diameter. I then lost sight of the child for a period of nearly one year. During this interval the mother had occasionally observed a slight discharge from the ear, but she attached very little importance to it. On examining the ear, I was surprised to find that the entire central portion of the drum-membrane had been destroyed, the opening which remained measuring easily four millimetres in diameter.

Cases of acute purulent inflammation of the middle ear differ very materially one from another in respect of the degree of swelling of the mucous membrane. In some the inflammation seems to spend itself in throwing out an abundant secretion from the free surface of the mucous membrane, which in that event undergoes comparatively little swelling; while in other cases—and these are usually the more severe ones—the mucous membrane becomes enormously swollen through infiltration of its tissues. It is probably under conditions like these that the adhesions and false bands occasionally observed in the middle ear are formed.

Finally, in every case of acute purulent inflammation of the middle ear, it is important to bear in mind that the communicating system of cavities, the mastoid antrum and surrounding cells, can scarcely escape being involved to a greater or less degree in the inflammation. At one or more points vessels pierce the bony roof of the tympanum, and along these the inflammation spreads to the dura mater and membranes of the brain. *A localized meningitis may be assumed to exist in every severe case of acute purulent inflammation of the middle ear;* though, as a matter of course, it is only in a very small minority of the cases that it spreads to the ventricles, involves the brain-substance proper, or becomes a more general meningitis.

*Symptomatology and Course of the Disease.*

The development of pain in the ear is the most striking, if not the first symptom noticed by the patient. In infants, and even sometimes in children two or three years of age, the physician is often puzzled to know what ails the child, and the first hint that he receives with regard to the real cause of the patient's fretfulness and feverish condition is that afforded by the appearance of a slight discharge at the outer orifice of the ear. Teething is very apt to be assumed as the cause of the fever, and thus many a case of severe inflammation of the middle ear is allowed to run its destructive course unrecognized and consequently unchecked. It is greatly to be regretted that physicians in general practice should not more frequently suspect an inflamed ear of being the source of these obscure attacks of illness in children. Upon the development of a perforation, the patient often experiences marked and speedy relief. "I felt something give way in the ear, a watery discharge appeared, and the pain soon subsided," is a statement which one often hears patients make. In many cases, however, the rupture of the membrane affords little or no relief. This is probably due, in the great majority of instances, to the insufficient size of the outlet. As the pus can only escape under considerable pressure, when the perforation is small, the tension, which is the chief cause of the pain, continues and the patient of course experiences little or no relief from his suffering. In a few cases the Eustachian tube affords an outlet for some of the exudation, and the patient can distinctly feel the fluid trickling down the side of his nasopharyngeal space. These cases, however, are comparatively rare, for as a rule the parts surrounding the tympanic orifice of the tube are so much swollen that even compressed air fails to effect a passage through it. Among the symptoms of minor importance may be mentioned: a sensation of fulness and sometimes of throbbing or pulsation in the affected ear; subjective sounds of various kinds, such as roaring, singing, whistling, etc.; more or less marked impairment of hearing in the affected ear; increased pain when the jaws are opened and shut; tenderness on pressure over the orifice of the external auditory canal, etc. The two last-named symptoms indicate that the inflammation has spread from the middle ear to the outer meatus. All these symptoms may then gradually subside, and in the course of ten days or two weeks from the onset of the disease the patient may be quite well again and free from all symptoms referable to the ear. Such an attack, in the course of which no alarming symptoms manifest themselves, may be designated as one of moderate or average severity.

The following case affords a good illustration of the course pursued by a simple, uncomplicated attack of acute otitis media purulenta: The patient, a boy four years of age, began to complain of pain in the right ear early in

the afternoon of May 30, 1877. He seemed unnaturally languid, and manifested no desire to take part in the other children's play. In the course of two or three hours the pain disappeared. During the night he awoke several times, and each time complained of his ear.

May 31st.—Frequent paroxysms of pain, of short duration. Membrana tympani red and swollen; near its posterior border, low down, the dermoid layer is raised into a well-marked blebs by an effusion of serum between it and the deeper layers of the membrane.

June 1st.—The child slept well last night, after taking two drops of Magendie's solution of morphine. A few paroxysms of pain during the day.

June 2d.—Patient slept well last night without morphine. No pain in the ear. No appreciable heat of skin and no acceleration of the pulse; yet the child refuses food, and looks pale and languid. Early in the afternoon the ear became quite painful, but in the course of two or three hours the pain disappeared again.

June 3d.—Patient awoke this morning with a sharp earache. Pressure both in front of and behind the ear causes pain. The posterior half of the membrana tympani is now (10 A.M.) markedly bulging and of a diffusely red color. I incised it freely, and gave exit to a blood-stained serum. In less than ten minutes the child fell asleep and slept soundly until 4 P.M. While he was asleep the discharge from the ear—a pinkish serum—was constant and very abundant. At five o'clock he took food, for the first time in several days, with apparent appetite. The ear, he says (6 P.M.), is entirely free from pain.

June 4th.—The discharge is growing thicker and more like ordinary pus. No return of pain. Appetite good. Expression of countenance has entirely changed.

June 8th.—Discharge has ceased. Drum-membrane has almost resumed its natural appearance. The boy seems to be perfectly well again.

In this case the disease developed in a perfectly healthy ear. The subject of the disease, furthermore, was a healthy child. These two facts explain in a measure why the recovery was so prompt and complete. In adults, and especially in those who have passed through previous attacks of inflammation of the middle ear, recovery takes place as a rule more slowly. The following case furnishes a very marked instance of the slight healing powers possessed by some individuals:

The patient, a gentleman, forty-two years of age and in fair general health, consulted me on the 1st of February, 1880. He said that during the previous two or three weeks he had been so much annoyed by a bad cold in the head that he had repeatedly snuffed warm salt water. He had never experienced any but good effects from this procedure. A few hours before calling to see me, however, he began to be conscious of a sensation of fulness in the right ear, and, as he had passed through several attacks of acute inflamma-

tion of the ear, he felt anxious lest this might prove to be the beginning of a fresh attack. I examined the right ear and found the membrana tympani slightly congested at the periphery, especially superiorly and along the handle of the hammer. Watch heard at a distance of eight or ten inches. I advised him to send for leeches and a Clarke's douche, if actual pain should come on later.

On February 2d I visited the patient at his house. He reported that soon after he returned home from my office the pain in the ear became quite severe, and continued throughout nearly the entire night. Toward morning he heard moist sounds in the ear, and at 6 A.M. he experienced simultaneously a sensation of relief from pain and a profuse outpouring of bloody serum from the ear. At 11 A.M., when I visited him, I found the pillow, the night-gown, one handkerchief, and numerous pieces of cotton-wool fairly soaked with the discharge. The pain had disappeared completely. The inner end of the canal was so swollen that I could only make out the existence of a central perforation. The swollen parts were gorged with blood and looked purple. The remainder of that day the discharge continued to be very profuse, and still appeared like bloody serum.

The following day (February 3d) the discharge steadily diminished and began to grow more yellowish. On examination with the speculum I found the perforation to be a little larger than the head of a pin of average size. The swollen walls of the canal had lost their purplish hue and were simply pink, and less swollen.

From this time forward, for a period of about two weeks, little or no change took place in the condition of the ear. The discharge, which was only moderate in quantity, never became thick like pus, nor did it assume any of the characteristics of mucus: it remained thin and very yellow, or at times yellowish green. Powdered iodoform, powdered burned alum, and solutions of nitrate of silver of different strengths, all failed to exert any very marked effect upon the discharge. As the patient had been treated for syphilis eighteen or twenty years previously, I thought that this poison might possibly have something to do with the remarkable sluggishness of the parts, and I accordingly prescribed the bichloride of mercury ( $\frac{1}{32}$  gr.) and iodide of potassium (gr. x.), to be taken three times a day. Finally, as a last resort, I advised the patient to visit Florida and remain there for one, two, or three weeks, according to the effects produced upon the ear. This advice was followed, and the change of climate, scene, and diet accomplished what local treatment had failed to do. When the patient returned, after an absence of a little over three weeks, I found the drum-membrane healed, and the adjacent canal only a very little swollen. The discharge had ceased already several days previously.

In the case just narrated I should have mentioned the fact that the patient had been for years affected with an aggravated naso-pharyngeal ca-

tarrh. At the time when I examined his throat, a mass of very tough, dirty yellowish mucus occupied the naso-pharyngeal cavity. Beneath and around it the mucous membrane was very red, dry, and swollen. I made several applications of nitrate of silver to these parts, but the beneficial results produced were very slight. It was quite probable that this persistently inflamed condition of the naso-pharyngeal mucous membrane contributed materially to keep up the inflamed condition of the adjacent tympanic mucous membrane.

Some persons possess a decided predisposition to acute inflammation of the middle ear. This is particularly true of children with enlarged tonsils and marked chronic naso-pharyngeal catarrh. Every fresh "cold in the head" in such individuals usually means a fresh attack of acute inflammation of the middle ear. If we examine their ears during the interval between the attacks, we rarely fail to find the drum-membrane more or less congested and generally drawn in beyond its proper plane. This predisposition is observed much less often in adults. The most striking case of the kind that I can recall is that of a woman, a seamstress, about thirty-five years of age and in apparently vigorous health, who during a period of about six years had at least as many well-marked attacks of acute inflammation of the right middle ear,—some of them ending in a perforation and a discharge of pus, others subsiding without going as far as this. I treated her during three or four of these attacks, and each time relieved her of her intense pain by freely incising the posterior half of the membrana tympani. The employment of leeches and the hot douche simply afforded temporary relief. After each incision the discharge of pinkish serum was very abundant, and the subsequent purulent discharge generally lasted but three or four days, the membrana tympani then healing promptly.

The following case affords a good illustration of a somewhat higher grade of inflammation. The patient, a lady about forty years of age and of decidedly nervous temperament, contracted a bad "cold in the head" during the first week of September, 1878. In the course of two or three days she began to experience pain in the left ear. Various measures were employed to relieve it, and among other things leeches were applied in close proximity to the outer orifice of the ear. The pain, however, steadily increased, and at the time when I first saw her (September 18, 1878) it involved the entire left side of the head. She could hear the ticking of my watch at a distance of only half an inch ( $\frac{0.5}{1.5}$ ). On inspection I found the membrana tympani slightly bulging posteriorly. The canal was perfectly dry, but the dermoid surface of the membrane presented a soaked appearance. The parts immediately bordering upon the membrane were intensely red and moderately swollen. Ether having been administered, I made a free incision through the posterior half of the membrane, and carried it upward

through a portion of the red and swollen tissues of the posterior fold. A sero-purulent fluid oozed through the artificial opening.

September 19th.—The hot douche was used freely after the drum-membrane had been incised, and the patient remained free from pain for several hours. This morning she is again in suffering. As the douche is used very frequently, it is impossible to state how free the discharge is. On examining the right ear, of which she now complains very decidedly for the first time, I find the membrana tympani and surrounding parts in essentially the same condition as that observed on the left side yesterday. Free incision of the posterior half, to be followed by the use of the hot douche.

September 20th.—Pain in the right ear relieved; slight watery discharge this morning. Pain in the left ear was severe during the greater part of the night; toward morning it diminished, and she was able to sleep for three or four hours. On examination I find the left drum-membrane concealed by a soft, pale fleshy mass which occupies the inner end of the meatus and appears to be attached to the central portion of the membrana tympani. By pulling upon it with the forceps I ascertained that its peduncle was engaged between the lips of the artificial opening in the drum-membrane. Further traction caused the mass to break off at the perforation. The discharge from the left ear, so far as I can learn, has been slight.

September 21st.—Last evening, while I was out of town, the pain in the left ear became quite severe. Dr. Sexton, who was sent for, found the posterior half of the left drum-membrane markedly bulging, and re-incised it. The incision afforded relief, but at the present time (8 P.M.) the pain is again quite severe. On inspection I found a fleshy mass occupying the inner end of the left meatus. It was of a pale pinkish hue, but at one part it presented a decidedly red color. By pulling upon it I ascertained that its peduncle was held fast between the lips of the perforation. In all outward respects, therefore, it was like the mass previously removed. By means of the forceps and Blake's snare I removed all of it that was within reach. Under the microscope a teased specimen presented the appearance of a homogeneous mass of dark granules, interspersed here and there with red blood-corpuscles whose circular outlines were barely recognizable. In some places there were indistinct evidences of fibrillation.

September 22d.—Patient passed a poor night. To-day (9 A.M.) there is tenderness over the squamous portion of the left temporal bone, over the mastoid process, and down along the left side of the neck. She complains of a dull, heavy pain in the left temple and eyeball. The left eye is blood-shot. At 8 P.M. I found the patient in so much suffering that I decided to convert the linear incision in the left drum-membrane into a T-shaped one, in the hope of affording an unobstructed escape for the exudation in the tympanic cavity. The patient having first been rendered unconscious by means of ether, I carried out this step, and also made a long and deep incision over the mastoid process.



September 23d.—By aid of opium and poultices patient passed a fair night. This morning (9 A.M.) I find her almost entirely free from pain in the left ear. The pain in the right ear continues, but is not severe. The discharge from both ears is still quite watery in character and not abundant. At 6 P.M. the pain in the right ear became severe. When I saw the patient at 7.30 P.M. I found decided tenderness over the mastoid process, but no œdema nor redness of the integument. Ether having been administered, I made a free incision through the posterior half of the right drum-membrane and also through the mastoid integuments.

September 24th.—Patient slept the greater part of the night, and this morning she seems to be every way better. The discharge from both ears is now distinctly purulent in character, though not abundant.

October 1st.—Steady improvement since last note. Left drum-membrane has nearly healed, and the discharge has ceased. On the right side the discharge still continues, but it is steadily diminishing in quantity. Moderate pain at times in both ears.

October 8th.—Right drum-membrane has healed. Patient is now entirely free from pain.

About ten days later I found both drum-membranes apparently normal. So far as the patient could judge, the hearing had been entirely restored. On testing it with the watch, however, I found a slight degree of impairment.

There are two or three points of interest in the case which I have just narrated. In the first place, linear paracentesis of the left drum-membrane afforded only a temporary relief from pain, and that, too, notwithstanding the fact that the opening, although slit-shaped, was of ample length. In the second place, the development of a mass of fibrinous material in the middle ear, and its expulsion from that cavity through the perforation in the drum-membrane, are events of very rare occurrence. Shall we, with Dr. J. Orne Green, of Boston, consider the attack as one of a high grade of inflammation associated with an exudation of a fibrinous material, or shall we consider it as one of a simple acute inflammation associated, accidentally, with the formation of an ordinary clot of blood? So far as the microscopic examination throws any light upon the question, either hypothesis may be the true one. But if we compare the peculiar conditions observed in this left ear on two different days, with those observed in hundreds of other similar cases, in many of which blood-vessels must have been divided just as freely as in the present case, I think we are justified in drawing the conclusion that Dr. Green's view is the more plausible of the two, and that the fibrinous masses observed were in reality exudation-masses and not blood-clots.

To revert to our first point, viz., the failure of linear paracentesis to afford relief from pain, I have very little doubt that it should be ascribed to

the obstruction interposed by this fibrinous material. Steady and marked improvement followed the establishment of an angular opening in the drum-membrane. Such an opening permitted the freest possible escape of all the products of inflammation, while the slit-shaped opening was probably soon rendered useless by the accumulation of the fibrinous material which effectually closed it.

The following case presents still another type of acute purulent inflammation of the middle ear, viz., one in which the mastoid cavities participate to a certain extent in the inflammation almost from the very beginning of the attack. The patient, a boy seven years of age and in excellent physical condition, was attacked with a severe pain in his right ear on the 22d of March, 1879. Various measures were tried, but they all failed to give more than temporary relief. On the 24th of March (9 P.M.), when I first saw the patient, I found the following conditions: body temperature, taken in the mouth, 102° F.; external auditory canal normal, except in the immediate vicinity of the drum-membrane, where it was red and somewhat swollen; the drum-membrane itself was covered with a white, pasty coating of epithelium, beneath which the parts were of a bright red color. Although there was no noticeable bulging of the posterior half of the membrane, I thought it better not to wait for this, but to perform paracentesis at once. No visible escape of fluid followed the incision.

March 25th.—Clarke's hot douche was used freely during the night, but yet the boy passed a poor night, obtaining very little relief from his suffering. There is now a scanty watery discharge from the ear. Pressure over the mastoid region causes him to wince. One leech to be applied to this region, and the hot douche to be used freely.

March 26th.—Another bad night. Toward morning, however, the discharge became profuse, and the pain disappeared entirely in the course of a few hours.

April 2d.—Yesterday the ear again became painful. The boy had felt so well for several days that his parents allowed him to run about as usual. To-day I find him crying with pain. Inspection shows the inner end of the meatus to be almost closed by the swelling of the soft parts, especially along the upper and posterior wall. Decided tenderness over the mastoid process. Cervical glands enlarged. Moderate fever. Free incision of swollen posterior wall of the meatus. Poultices or dry heat to be applied externally.

April 3d.—Pain has moderated.

April 4th.—Continued improvement.

(Complete recovery followed in the course of about two weeks.)

The tenderness on pressure over the mastoid process furnished, in this case, good evidence of a certain degree of periostitis of that region. The question of its mode of origin—whether by extension from the auditory

canal, or by extension through the mastoid cells—is one that can be discussed perhaps to better advantage under the head of *Diagnosis*. In this particular case I am disposed to look upon the subacute mastoid periostitis and upon the more acute periostitis of the posterior wall of the meatus, in the immediate neighborhood of the membrana tympani, as both alike dependent upon an inflammation whose centre of greatest activity was probably located in the mastoid antrum. The more serious forms of mastoid inflammation (both corporeal and periosteal) will be considered in a separate section.

Among the most troublesome cases to manage are those in which the products of inflammation seek an outlet through the membrana flaccida, and not through the drum-membrane proper. This membrana flaccida, or Shrapnell's membrane, in certain individuals is so thin and flaccid that the least change in atmospheric pressure in the cavity of the tympanum shows itself at this point sooner than in the drum-membrane. It is a common experience to examine the ear and find a distinct hollow situated above and behind the short process, and then after inflation to find this same region converted into a rounded prominence; while at the same time the drum-membrane proper shows at most only a slight change in its position as a whole. In such cases it is easy to understand how, under the pressure incident to the accumulation of an inflammatory exudation in the tympanum, this particular region should, by reason of its being the place of least resistance, be the spot where a perforation takes place. Before an actual outlet is established,—that is, probably, before the last layer of the tissues, the dermoid, gives way beneath the pressure,—the soft parts immediately surrounding this spot display very marked evidences of a special irritation. They become red and swollen, and if our examination of the ear is made for the first time at this particular stage of the disease, we are not at all likely to diagnose accurately what is the true state of the case. I have incised such swellings in the full belief that I was dividing the posterior half of the drum-membrane, and have only discovered my error after the inflammatory swelling had subsided sufficiently to reveal to me the true relations of the parts. The following case affords a good illustration of the peculiar lesions described above:

The patient, a physician, about thirty-five years of age, contracted a bad cold during the first week of March, 1874. Soon afterward he began to experience pain in the left ear, with a moderate degree of deafness. In the course of two or three days a discharge made its appearance, and the pain at the same time became less severe. On the 17th of March, when I first examined the patient's ear, I found it in the following condition: the external auditory canal, in its outer half, was perfectly normal; in the neighborhood of the drum-membrane it was red and somewhat swollen. After all the pus had been carefully removed, the picture presented at the bottom of the canal was that of a red and swollen drum-membrane (pos-

terior half). Posteriorly and superiorly the swelling merged imperceptibly into the wall of the canal; anteriorly and inferiorly quite a deep recess separated it from the wall of the canal. At the most prominent part of the swelling a slight depression, from which fluid escaped, marked the location of the perforation. As there was comparatively little pain in the ear, so long as the patient remained quiet, I decided to watch the further progress of the case before adopting any more active treatment than simple cleansing of the canal, together with occasional inflations (Politzer's method).

On the 20th of March, finding that the swollen condition of the parts persisted, and assuming that the small perforation could scarcely afford an adequate outlet for the discharge, I made a free incision through the swollen tissues.

March 23d.—Persistent pain. Discharge at times bloody. No diminution in the swelling of the membrana tympani. Mastoid integuments, including the periosteum, freely incised.

March 27th.—Decided improvement in all respects. The swelling has now so far diminished that I am able to distinguish quite accurately the relations of the parts. The drum-membrane proper is intact. Just above it, and overhanging its posterior half, is a teat-like swelling which represents the pouting orifice of the perforation or (more correctly) sinus. In the hope of diminishing the degree of resistance which the discharge must encounter in escaping through such a long sinus, I removed a large portion of this teat-like projection with Blake's snare.

On the following day patient took passage on one of the Savannah steamers, in the hope of hastening his recovery by a change of air and scene. About three weeks later (April 17th) he returned to New York. The discharge from the ear, he reported, had ceased entirely on the 13th, and his general condition had greatly improved. On examination, I found that all evidences of active inflammation had disappeared. There was still, however, a small conical projection of the tissues just above the posterior half of the membrana tympani, and at its tip (and forming part of it) was a collection of whitish material—probably cheesy pus. There was no recognizable impairment of the hearing for voice-sounds and conversation, but the ticking of a watch was heard at a distance of only two inches.

In March, 1875, every trace of the attack had disappeared, and the ticking of the watch was readily distinguished at a distance of nearly three feet.

The pouting character of the external orifice of the sinus or perforation is not peculiar to perforations in Shrapnell's membrane. I have occasionally observed precisely the same condition, though on a somewhat smaller scale, at or near the centre of the drum-membrane. The prolonged resistance of the dermoid layer to the pressure exerted by the pus is probably as much the cause of the pouting condition here as it is in the region of Shrapnell's membrane.

A few words more with regard to perforations in general. In my own practice I have never known more than one perforation to form in the membrana tympani as a result of an acute inflammation of the middle ear. That two perforations may occur, however, in the same membrane, is clearly shown by the fact that occasionally, and particularly in dispensary practice, we find drum-membranes perforated in two places, or presenting two well-defined cicatrices—evidences of the former existence of perforations. Finally, I have seen one case in which the fluid exudation found an outlet for itself, not through the drum-membrane proper, nor through the soft parts above the membrane, but at some point below it. It is hard to conceive how this could have taken place, and yet the evidence in this case pointed very clearly to the existence of a channel of communication between the tympanic cavity and a collection of pus in the external auditory canal.

#### *Sequelæ and Complications.*

The more important sequelæ of an acute purulent inflammation of the middle ear are: inflammation of the mastoid process (corporeal and periosteal), meningitis, and chronic purulent inflammation of the middle ear with its very numerous lesions. These sequelæ possess the importance of independent diseases, and I will therefore consider them in separate sections. The only affection of any importance that can be considered as a complication of an acute otitis media purulenta is abscess of the meatus. I have before me the incomplete notes of five such cases. In three of these the abscess was located near the outer orifice, and was circumscribed or furuncular in its nature. In the other two a collection of pus formed between the skin (*i.e.*, periosteum) and the bone at the inner and upper portion of the meatus, close to the drum-membrane. In these two cases it seems to me more than likely that a partial perforation took place in Shrapnell's membrane, and that the pus, instead of forcing its way directly through the tissues which form the outer limit of this region, burrowed a way for itself between the soft parts and the bony wall of the meatus. As I did not see these cases, however, until after the collection of pus had formed (toward the end of the second week of the disease), I cannot speak very positively with regard to this point. In the three cases of circumscribed abscess of the canal, the first symptoms of this complication did not show themselves until after all the acute manifestations of the middle-ear inflammation had subsided. In all three cases I felt confident that the abscess was not a legitimate outgrowth or complication of the original disease. In the first case, for example, the abscess was induced, as I believe, by the use of the solution of the acetate of lead, and in the second by the employment of burned alum; while in the third case it owed its origin to a local eczema confined to the outer half of the meatus, and which needed only

the irritation supplied by the discharge from the middle ear to fan it into an acute circumscribed inflammation.

The participation of the cervical and post-auricular glands in the inflammatory process is a noticeable feature in quite a large proportion of the cases of acute purulent inflammation of the middle ear. I have never known this sympathetic inflammation, however, to go beyond the point of producing a moderate degree of swelling and tenderness of the affected glands.

### *Diagnosis.*

If called to see a person who is suffering with an acute inflammation of the middle ear of recent origin, we shall probably at first be obliged to limit our diagnosis to the simple establishment of the fact that the disease is inflammatory in its nature and to the determination of the locality in which the inflammation is taking place. The disease, we can say, is an acute inflammation of the middle ear, but whether it will go on to the formation of pus, or whether it will recede after reaching some point short of this stage, are questions which cannot surely be answered at such an early stage. As our treatment is not based upon the character of the exudation which is thrown out into the middle ear, we may safely wait for circumstances to reveal the facts with regard to the point in question. If the disease has not progressed so far as to involve the external auditory canal to a marked extent, it is scarcely possible to err in our diagnosis. Even without actual inspection, the patient's account of the attack—in the case of an adult—generally gives us some idea of what peculiar part of the ear is the seat of the inflammation. Actual inspection of the parts, however, can scarcely fail to remove the last element of doubt. I can think of but two possibilities of error: first, an inflammation of the soft parts lining the osseous portion of the external auditory canal and the outer aspect of the drum-membrane may easily be mistaken for an acute inflammation of the middle ear that has involved (secondarily) the inner half of the meatus; and secondly, the whitish appearance of the dermoid surface of the drum-membrane, concealing perfectly—as it often does—the underlying inflamed tissues, may mislead an inexperienced observer into the belief that he is looking at an opaque, thickened, and uninflamed membrana tympani. The first error can only be avoided by a careful sifting of all the evidence. An acute inflammation of the middle ear causes more decided deafness and far more pain than does an inflammation of the osseous portion of the canal. Again, the order in which the different symptoms have followed each other furnishes us with valuable aid in deciding which of the two diseases is the one that is under observation in any given case. To avoid the second error, it is simply necessary to demonstrate, by actual manipulation of the parts,—that is, by the use of the slender probe, the curette, or the cotton-holder, armed

with a small mop of cotton,—that the surface under observation is a part of the living tissues, and not a pasty, dead exfoliation.

In infants and young children we must rely almost entirely upon what we can ascertain by actual inspection. The mother's account of the symptoms observed is usually very vague, at best. On the other hand, primary acute affections of the meatus are very rare at this early age.

If we limit our diagnosis, in the class of cases under consideration, to the mere determination of the locality in which the inflammation is going on, our task—judged from the standpoint of practical utility—is but half completed. In order to treat the case intelligently and successfully, we should push our researches much farther. We should have before our minds, for example, a reasonably clear picture of the limits of the inflamed area and of the amount of damage already done by the disease. The color of the drum-membrane, the extent to which it is disfigured, the flatness or rotundity of its movable portions, especially its posterior half, and the degree of inflammatory disturbance in the adjacent cutaneous walls of the canal, all furnish valuable means of estimating the degree of vigor displayed by the inflammation, and the degree of tension or pressure to which the soft parts lining the middle ear are being subjected. Having ascertained these facts with more or less accuracy by direct inspection, our next step should be to try and learn to what extent the inflammation has spread from the tympanic cavity to adjacent parts. Has it spread in the direction of the cranial cavity? The severity of the pain in the head, on the same side as that of the affected ear, affords a rough means of measuring the degree to which the congestion of the adjacent meningeal vessels has progressed. Without insisting too much on the value to be attached to the following statement, I may say that I have been disposed to consider the change from a simple unilateral headache to one more distinctly localized in the occipital or frontal region as an evidence that the meningeal congestion has materially increased in degree and extent. I have observed this phenomenon so often in the more serious cases of inflammation of the middle ear that I think some diagnostic value should be attached to it. Has the inflammation spread to the mastoid region? Pain referred to this region, redness, and perhaps swelling of the skin covering the mastoid process, and tenderness on pressure with the finger, these are the symptoms which indicate that the mastoid process is participating in the inflammatory process. In this same group of symptoms may be placed another, viz., redness and swelling of the posterior and upper wall of the meatus, in the immediate vicinity of the drum-membrane. Finally, the determination of the patient's body temperature may serve to confirm the opinion that we have formed from the other methods of examination employed. In children we may confidently expect to find an appreciable elevation of the body temperature in all cases of acute inflammation of the middle ear; in adults we also usually find some elevation of the body temperature, but, as I know from personal observa-

tion, this elevation may be markedly disproportionate to the serious character of the damage that is being wrought in and around the ear, and particularly in the cranial cavity. It is therefore unsafe in adults to infer, from the insignificance of the rise in temperature, that the case is progressing well and that no harm need be feared.

The existence of a perforation may be learned by direct observation or by auscultation while air is being forced into the middle ear. If the perforation is small, or if the membrane has not been thoroughly dried with the mop of cotton-wool, it may be impossible to distinguish the situation of the perforation by simple inspection. As a rule, we can readily discover the point of rupture in such cases by asking the patient to perform Valsalva's experiment while we watch the behavior of the drum-membrane. Even then the perforation may be so small that we can simply distinguish the oozing of a little fluid from a certain portion of the drum-membrane. With the slender probe, however, we can always demonstrate the precise spot occupied by the opening. The presence of fluid exudation in the external auditory canal is not to be taken as satisfactory evidence of the existence of a perforation. It may be, and very often is, simply an exudation from the outer surface of the drum-membrane and adjacent inflamed walls of the canal.

#### *Prognosis.*

An acute purulent inflammation of the middle ear, if allowed to run its course unchecked, will undoubtedly, in the majority of cases, do so without serious detriment to the patient. In the minority of cases, however—and it is by no means a small minority—the disease produces more or less serious damage. An impairment of hearing of variable degree, a chronic and generally offensive discharge from the ear, and even fatal disease of the adjacent organs, are the prominent items in the catalogue of damages that may result from an unchecked acute inflammation of the middle ear. These facts are now so well known to the profession that I certainly may be excused from the necessity of furnishing satisfactory evidence of the truth of what I say. There was a time, however, and that too within the memory of some of the younger men in the profession, when an acute inflammation of the middle ear was looked upon in a very different light; it was generally considered as one of the diseases of minor importance, and it was accordingly allowed to run its course practically unchecked. As a result of that regime of professional ignorance and indifference with regard to diseases of the ear, there were, and are still in this city alone, thousands of individuals affected with chronic discharge from the ear. In those days, therefore, the prognosis of an acute purulent inflammation of the middle ear—if based upon the facts of actual observation—must necessarily have been unfavorable, or at least very guarded in its nature, especially where the disease origi-



nated in one of the exanthemata. During the past few years, however, a very noticeable change has taken place in two particulars. In the first place, the majority of the better class of practitioners now recognize the danger of allowing an acute inflammation of the middle ear to run its course unchecked. If they do not feel competent to manage this class of diseases themselves, they call to their assistance some professional brother who is familiar with their treatment. In the next place, the number of physicians who are competent to treat a case of acute otitis media has very greatly increased. While these remarks apply more particularly to the city of New York, it is, I have reason to believe, true also of other cities and towns. There is therefore no lack of men who know how to prevent the disastrous results which sometimes flow from an acute inflammation of the middle ear. These important changes, both in the state of professional opinion and in that of professional skill, have already led to a marked change in the prevalence of the bad types of chronic purulent inflammation of the middle ear. I speak now entirely from my own personal observation; and in accordance with that I may say that, if we compare the material observed between 1870 and 1875 with that observed between 1875 and 1880, a very noticeable diminution will be found to have taken place, in the latter period, in the proportion of cases affected with really serious chronic disease of the middle ear. There is but one plausible interpretation that we can put upon this fact, viz., that the treatment of this disease in its acute stage has been better conducted during the latter than during the former period. In fact, it is not an exaggeration to say that under proper treatment, *if begun soon, i. e., within a few days after the onset of the attack, an acute inflammation of the middle ear rarely results in the patient's death, or seriously impairs the hearing of the affected ear, or passes into a really chronic purulent inflammation.* At the present time, therefore, the aurist, or the general practitioner who has acquired the special knowledge and skill which the treatment of these cases demands, may give a very good prognosis in cases of acute inflammation of the middle ear, provided he be not sent for after serious damage has actually been inflicted by the disease. There is scarcely another department of practical surgery in which the physician can boast of greater triumphs than those attained at the present day in the treatment of acute diseases of the middle ear.

The physician is often asked to state the probable duration of an attack of acute inflammation of the middle ear. The answer must of course depend upon the severity of the attack, upon the age and condition of health of the patient, upon the degree of inflammation and hypertrophy of the naso-pharyngeal mucous membrane, upon the exciting cause of the disease, upon the surroundings and mode of life of the patient, and upon various other circumstances too numerous to mention. Assuming that all these circumstances are favorable, we may estimate the probable duration at from ten days to three weeks in the cases of average severity, and at from four to

six weeks in those of a more virulent type. In young and healthy children recovery takes place more quickly than in adults. In persons who have passed the middle period of life, the return to a healthy condition of the parts is apt to be slow. In individuals of a consumptive type our prognosis, especially with regard to the duration of the subsequent discharge from the ear, must be very guarded. In these individuals the mucous membrane of the middle ear seems to possess little or no recuperative power, and the discharge may continue for weeks or months, in spite of our best efforts to arrest it. In cases of acute inflammation of the middle ear following scarlet fever or measles we must expect a less prompt recovery, as a rule, than is generally observed in cases which owe their origin to a "cold."

#### *Treatment.*

The different therapeutic measures employed in the management of an acute inflammation of the middle ear may be discussed under three heads, viz., those measures which tend to arrest or diminish the direct force of the inflammation, those which tend to prevent its indirect effects, and those which possess the power of arresting the purulent discharge which follows the acute stage of the disease.

1. *Therapeutic measures which tend to arrest or diminish the direct force of an acute inflammation of the middle ear.*—It does not often happen that we are called to see a case of acute inflammation of the middle ear at such an early stage of its development that we can prevent it from going through all the different stages of an ordinary attack of otitis media purulenta acuta. If a young child, four or five years of age, complains of pain in the ear, the mother is apt to send for a physician without very much delay; and this explains why a majority of the individuals in whom we have the satisfaction of seeing the inflammation subside, under the employment of suitable remedial measures, without going on beyond the first stage, are children of about this age. The practical question which naturally suggests itself in this connection is this: by what evidences or symptoms are we to know whether we should employ the milder abortive methods of treatment, or whether we should, without further loss of time, proceed to more heroic measures? Or, to put the question somewhat differently, up to what time, judging from the evidences obtained by direct inspection and from the patient's own sensations, can we safely and properly postpone the operation of establishing a vent in the membrana tympani? As paracentesis is performed almost solely for the purpose of relieving the great pressure exerted upon the membrana tympani and the mucous membrane of the middle ear by the fluid exudation that is being poured into that cavity, we may answer the question by stating that so long as the drum-membrane, and particularly its posterior half, does not display what is termed a "bulging"

condition, we may safely persist in our efforts to arrest the inflammation by means of the various antiphlogistic measures which I am about to describe. The only limitation that I would place upon this rule is this: if, by reason of the swelling of the adjacent parts, we are unable to decide positively whether bulging of the membrane exists or not, we should establish the opening and thus give the patient the benefit of the doubt.

In the early stage of the inflammation, while there is simply redness and swelling (infiltration) of the tissues, I know of nothing more potent to quiet the pain and check the further progress of the inflammation than *hot water*, if kept in contact with the drum-membrane for a certain length of time. In children over four years of age Clark's douche armed with the pronged nozzle, described on p. 33, can be used very readily. By keeping the reservoir only slightly raised above the level of the patient's ear, and by renewing its contents from time to time, we can keep a steady but gentle current of hot water flowing over the outer surface of the drum-membrane. As a rule this continuous poulticing of the deeper parts of the ear affords the patient marked and prompt relief. In a few cases, however, some form of dry heat—*e.g.*, flannel pillows or bags containing hot bran, hot salt, or hot sand—seems to afford greater relief than does the douche. In this connection I should state that much of the ill-success experienced by physicians in the employment of the hot douche is due to the imperfect manner in which the operation is performed. It is almost useless to give the patient's mother or friend an order on some apothecary or instrument-maker for the requisite apparatus, and then to accompany this order with a verbal explanation of the way in which the instrument should be used. Under such circumstances there are very few chances that the apparatus will be managed in such a way that the current of water will ever go beyond the cartilaginous portion of the meatus. The physician should personally superintend the carrying out of this procedure, when it is done for the first time, and he should satisfy himself that the person to whom it is entrusted is competent to perform the task efficiently. In favorable cases relief from pain may be obtained in the course of fifteen or twenty minutes, or even sooner. As soon as relief has been obtained, the douche should be withdrawn, and warm applications (dry or moist, according to the patient's preferences) should be made to the outside of the ear. If the pain returns, the use of the douche should be resumed. If, after a fair trial—say for a period of fifteen or twenty minutes—no appreciable relief is obtained by the employment of the douche, it is better to abandon it altogether.

Another, fully as effective, but far simpler plan of poulticing the drum-membrane, is to pour water of a temperature of about 100° F. into the external auditory canal. For this purpose an ordinary teaspoon, or better yet, a glass dropper may be employed. The water must be poured into the ear, as a matter of course, while the patient is lying upon the opposite side, with the affected ear turned upward. A large vessel containing hot water

should be near at hand, so that hot wet cloths may be quickly laid over the ear before the water in the meatus has had time to cool. As an additional means of retaining the heat as long as possible, dry flannel cloths (heated, if possible) may be laid upon the moist ones. In the course of a few minutes, the cloths are to be removed, the water is to be allowed to escape from the ear, and a fresh supply is to be introduced in the same manner as at first. As already stated, I have found this very simple procedure fully as effective as the more complicated plan of keeping the drum-membrane constantly bathed by a running stream of hot water.

*Local bloodletting*, by means of leeches applied near the orifice of the external auditory canal, or in the angle just behind the auricle, stands perhaps next in order as a means of alleviating the pain and checking the inflammation. In children it is better to abstain wholly from the use of leeches in combating an acute attack of inflammation of the middle ear. Even in adults I am much less disposed than formerly to place faith in their power to prevent such an inflammation that is still in its first stage, from going on through all its stages. In a later stage of the disease, after a purulent discharge has set in, leeches will often produce effects which every other therapeutic measure has failed to accomplish. Farther on we will refer to this matter again. So far as the number of leeches to be employed is concerned, I may say that in a fairly strong and healthy adult it is of very little use to apply less than four. If there are no conditions which contraindicate such a course, it is a good plan to allow the after-bleeding to continue for at least half an hour. In applying leeches under these circumstances the same instructions hold good as those which were given in Chapter IV. (see p. 73).

It is not at all unlikely that *dry cups* might be used to advantage in checking an acute inflammation of the middle ear. In persons with hairy necks it would of course be difficult or even impossible to apply them until the hair had first been shaved. I have never used dry cups in the treatment of ear diseases, and merely mention them now as means which might under circumstances be used to advantage.

Some authorities recommend the employment of ice, in the form of an ice-bag, which is to be applied to the outside of the ear. As I have had no personal experience with this method of controlling an inflammation of the middle ear, I may be permitted to pass on at once to the consideration of other matters.

An acute inflammation of the middle ear is almost invariably aggravated by physical exercise on the part of the patient. *Rest*, or the avoidance of physical exercise, is therefore a very important agent in diminishing the virulence of this disease. A man in active business does not like to remain quietly at home simply because his ear is somewhat painful, and the physician often finds difficulty in convincing him that by pursuing such a course he will in the end economize time. Again, at a later period, after the acute symptoms of the disease have apparently subsided, patients are

apt to resume business too soon, and in this way they may bring on a relapse which may prove even more serious than the original attack. Young children, during the onset of the disease, show very little disposition to play or to take any form of exercise. At a later stage, however, the precautions referred to above are very necessary. The moment the child is relieved from pain and has had the requisite amount of sleep, the desire to resume play manifests itself in an unmistakable manner. Restraint should be exercised under these circumstances, and the child should be allowed to regain its full measure of freedom in this respect only gradually. I am disposed to attach a great deal of importance to this matter of rest in the treatment of acute affections of the middle ear. I do not mean by this that I consider it necessary for the patient to go to bed and remain there until every trace of the inflammation has subsided, although in certain cases this will be found to be the better course to pursue; but simply that he should not walk about to any extent, that he should not go up and down stairs, that he should not ride in a carriage or omnibus over our rough city pavements, that he should not transact any business that is calculated to engross his attention very seriously, and so on. All these things excite the heart's action or cause a jarring of the inflamed and sensitive mucous membrane of the middle ear, and, if they are persisted in, renewed inflammation is likely to be the result. Some of the worst cases of inflammation of the ear that I have seen clearly owed their protracted and violent course to the patient's disregard of this well-established principle in the treatment of inflammatory affections.

Stress has been laid by some authorities on the value of *position* as a means of diminishing the severity of an acute inflammation of the ear. I have never made a serious effort to ascertain whether or not some one position of the body favored the subsidence of the inflammation sufficiently for us to utilize this knowledge in our treatment of this class of cases. Patients very soon discover for themselves what is the position of body in which they experience the least pain, and they naturally select that position by preference.

The diet during the acute stage should of course be of a non-stimulating character. This is a matter, however, which generally regulates itself, as the patient is not apt to have sufficient appetite for any but the lightest kind of food.

2. *Therapeutic measures which tend to prevent the indirect effects of an acute inflammation of the middle ear.*—In the preceding section I have enumerated the various measures that may be employed to arrest or diminish the direct force of an acute inflammation of the middle ear. These are the measures which we shall probably find it advisable to use when we are first called to see the patient, unless we find that the disease has already gone beyond what might properly be called the first stage. If we bear in mind

what is the direct purpose of these different measures,—I refer more particularly to the employment of the hot douche and leeches, and to the abstinence from physical exercise,—we shall appreciate at once the fact that they may come into requisition, not simply during the first stage of the disease, but at other times during its course. During the first stage, however, our entire reliance is placed upon these measures, and if they fail to arrest the progress of the inflammation, there will come a time when other measures will be found necessary,—measures which have for their chief object the relief of the pressure and tension caused by the fluid exudation that is being poured out into the cavities of the middle ear, and also to a less extent into adjacent soft parts. We will suppose, then, that in a given case we have tried one or more of the methods of treatment recommended in the preceding section, and have failed to relieve the pain or to arrest the disease. What is to be done next? The proper course to pursue is generally indicated in a very clear manner. The inflammation in its further progress has by this time either caused the drum-membrane (the only part of the middle ear that we can see) to swell greatly, through infiltration of its tissues, or to bulge outward through the pressure of the free inflammatory exudation contained in the tympanic cavity. In either case an incision through the drum-membrane is what is most urgently needed. The longer the pressure is allowed to continue, the greater the danger of those various sequelæ which may be described roughly under the titles of mastoid disease, inflammation of the brain, and chronic discharge from the ear. The incision should be made in the posterior half of the membrane, and its character should depend upon the condition of the parts. For instance, if the membrane is simply bulging and there is not much infiltration of the tissues, a linear incision will suffice. In unruly young children, we are often compelled, unless an anæsthetic has first been administered, to be satisfied with a mere stab of the membrane. Such a stab, however, if made with a properly constructed paracentesis-needle (see p. 182), usually suffices. In adults, a longer incision (say four millimetres in length) is desirable. It should be made deliberately, with or without the aid of an anæsthetic, according to the patient's ability to bear the pain without flinching. If both the drum-membrane and the adjacent soft parts in the meatus are, so to speak, fused into an unrecognizable swollen mass, or if good evidence exists that the inflammation has already spread to the adjacent parts, a single linear incision can scarcely be trusted to afford adequate relief. It is better then to convert the linear into a crucial or T-shaped (a T turned over on its side) incision. My plan is to introduce the point of the needle as high up as I dare in the swollen tissues of what I deem to be the posterior half of the drum-membrane, to cut downward a distance (roughly estimated) of about four millimetres, then to turn the blade of the needle and carry the incision directly backward until I meet with bony resistance.

In speaking of paracentesis of the drum-membrane, under the head of mucous or serous accumulations in the tympanic cavity, I said that I rarely found it necessary to employ an anæsthetic, the pain of the operation being quite bearable. In the case of an acute inflammation of the middle ear the parts are much more sensitive, and paracentesis under these circumstances is decidedly painful. I am therefore often obliged to employ an anæsthetic; certainly not in the majority of cases, but yet in a very respectable minority of them. When the severity of the inflammation seems to demand a crucial rather than a linear incision, I urge the patient to take an anæsthetic. As it is important to use the knife deliberately and cautiously, when we are compelled to operate without the aid of the usual landmarks (short process and handle of hammer, and outlines of the periphery of the membrane), it is far better to wait until the patient is perfectly unconscious, so that we may have simply the unavoidable difficulties of the operation to contend with. The dangers that beset the operation have already been stated on p. 181, and it is not necessary to allude to them again in this place.

Immediately after the operation I am in the habit of filling the auditory canal with as hot water as the patient can readily bear, and then of applying externally a large sponge or several thicknesses of flannel cloth wrung out of hot water. The heat and moisture relieve the pain caused by the incision and favor the establishment of a discharge from the inflamed tissues. At intervals of five or ten minutes these hot applications should be renewed, as they retain their heat for only a short time. As soon as the pain has been relieved, all active therapeutic interference should cease until a free discharge has set in. Then the ear should be douched or syringed gently two or three times a day, for the purpose of removing the pus from the auditory canal before it has time to become foul. In cases that run a favorable course, if the discharge is steadily diminishing in quantity, the ear need not be douched or syringed so frequently. It is particularly during this stage of recovery from an acute attack of otitis media purulenta that intelligent and faithfully carried out douching or syringing contributes so largely toward a speedy healing of the perforated drum-membrane. In young children this simple operation of keeping the ear clean will, in the great majority of cases, be found sufficient, treatment with drugs being required in only a few instances.

3. *Therapeutic measures which possess the power of arresting the discharge which follows the acute stage of a purulent inflammation of the middle ear.*—In a large proportion of the cases the discharge from the ear, which sets in after the acute stage of the inflammation has subsided, disappears so rapidly that the methods referred to under this third heading are not called into requisition. In a certain proportion of the cases the discharge continues for a longer period than is perhaps generally observed under similar circum-

stances. If I were asked to state what should be considered as the normal duration of the discharge in these cases of acute otitis media purulenta, I would say one week for the milder cases, and two or three weeks for the more severe ones. By this I mean that the physician is perfectly justified in not adopting direct measures for the arrest of the discharge until it has run on unchecked for a week in the milder cases, and for two or three weeks in the more severe ones. While the selection of the time when it is proper to interfere actively in the treatment of this stage of the disease is a more or less arbitrary affair, there are nevertheless a few points which serve as aids to us in reaching a decision. In the first place, the patient, or the patient's parents, may express the desire to have the discharge arrested as soon as possible. Our course, under these circumstances, is very clear. We should proceed at once to adopt such measures as will accomplish the result desired. There is one rule, however, that comes into play in this connection, and it is a rule that cannot safely be disregarded: *never make any attempt to arrest or diminish the discharge so long as pain persists.* I usually employ nothing but the warm douche or syringing with warm water until a full week has elapsed from the time when the patient last experienced pain in the ear. If at that time the discharge is steadily diminishing in quantity, I prefer—unless urged by the patient to adopt more active measures—to trust a little longer to the simple plan of cleansing the ear. If nature is working out a cure in a reasonably rapid manner, why should the physician interfere? After a second week has elapsed, however, and the discharge is still more or less active, I feel no hesitation in advising the adoption of measures calculated to arrest the discharge.

If we wish to treat successfully a case of otorrhoea or discharge from the ear, we must picture to ourselves clearly the precise locality from which the discharge comes. In the disease which we are now considering the discharge is supplied chiefly by the mucous membrane lining the tympanic cavity, and to a less extent by that lining the mastoid antrum and adjacent air-containing cells. This mucous membrane is diseased, and to restore it to a healthy condition we must bring our remedies in direct contact with it. This is the problem which we, as physicians, are called upon to solve. If a large perforation has formed in the drum-membrane, the problem is comparatively easy of solution. As a rule, however, the perforation is quite small, sometimes even invisible. How, then, are we, under these circumstances, to bring our remedies in contact with the tympanic mucous membrane? As there are but two routes by which the tympanic cavity can be reached, we must select one or the other of these. That by way of the Eustachian tube is encompassed with various difficulties, that is, if we attempt to use it for the purpose of bringing fluids in contact with the tympanic mucous membrane. That by way of the perforation in the drum-membrane is therefore practically the only route that we can follow.



Having chosen our route, let us next consider the practical details of the operation of bringing our remedial solutions in contact with the diseased tympanic mucous membrane. In the first place, we may assume that the cavity of the tympanum is filled with fluid exudation. Our first step should therefore be to remove this secretion as thoroughly as we can. If the perforation is sufficiently large we can wipe out some of the fluid by means of the cotton-holder<sup>1</sup> armed with absorbent cotton. Inflations by means of Politzer's method will also aid materially in freeing the tympanic cavity from any secretion that it may contain. In the natural order of things, however, the inflations should precede the use of the cotton-holder. In the majority of cases the cleansing that is effected by one or both of these methods will be found sufficiently thorough for our purposes. A more perfect method will be described farther on. If the perforation be very small, we may find it desirable or even necessary to enlarge it with the paracentesis-needle. This enlarging of the perforation is specially indicated in cases in which the discharge is mucoid in character; for in these cases the secretion cannot be forced through a small perforation, unless a greater degree of force be used than is proper. After we have removed as much fluid as we can from the middle ear, our next step should be to introduce our remedial solution as thoroughly as possible into this same cavity. A simple and fairly effective way of accomplishing this is the following: the patient should hold his head in such a position that the affected ear will be turned upward. The remedial solution should then be dropped into the auditory canal until it covers the drum-membrane to a depth of at least five or six millimetres. In order to force a part of this solution through the perforation, pressure must be exerted from without upon the mass of fluid as a whole. This can be done in two ways. With one hand the physician should pull the auricle outward (*i.e.*, away from the head), with the forefinger of the other he should press the tragus backward in the same manner as he would shut the lid of a box, and then, relaxing his hold on the auricle, he should press the tragus firmly inward toward the drum-membrane. In this way quite a strong pressure can be brought to bear upon the fluid that lies upon the outer side of the drum-membrane. It is well, however, not to trust to this pressure alone, but to take advantage of the aid which the patient (if an adult) is able to afford by performing the act of swallowing (with or without simultaneous closure of the nasal orifices). When I resort to this method of forcing fluid into the middle ear, I make it a rule to lessen the pressure the moment the patient experiences either pain or dizziness. I also cease to make pressure as soon as the patient notices that some of the solution has reached the naso-pharyngeal space. A Politzer's rubber bag, armed with a nozzle that will fit the orifice of the external auditory canal in an air-tight manner, affords another means

---

<sup>1</sup> The smallest size of instrument should be used for this purpose.

of condensing the air in the meatus, and of forcing the remedial solution into the middle ear. After I have succeeded, by one of these two methods, in introducing the remedy into the tympanum, I usually allow it to remain there undisturbed for two or three minutes, and then I have recourse to Politzer's method of inflating the middle ear for the purpose of dislodging the solution from that cavity. I am now disposed to believe that when quite weak solutions are used, it would be better not to attempt to dislodge the remedy, but to leave it undisturbed in the tympanum.

The methods which I have just described are fairly effective in diminishing and eventually arresting a discharge from the middle ear. In not a few cases, however, they seem to exert but very slight curative effects; and if we seek for the reasons why they fail to produce these effects, we find either that the middle ear has not been adequately cleansed, thus preventing the remedial solution from coming in contact with the mucous membrane, or that the solution has really never passed through the perforation into the cavity of the tympanum.

A much more satisfactory plan of treating these cases is that by means of the middle-ear pipettes described on p. 188. This method, which in skilled hands is simply invaluable, often arresting the discharge as it were by a single stroke, is unfortunately beyond the reach of the average practitioner. It is only after a man has acquired delicacy and steadiness in his manipulations, skill in the management of the forehead-mirror, and thorough familiarity with the region of the middle ear, that he may safely undertake to treat a case by aid of the middle-ear pipette (no matter of what material, platinum or glass, the instrument be constructed). With regard to the mode of using this instrument in the class of cases now under consideration, there is very little to say in addition to what has already been said in the section relating to otitis media mucosa (see p. 190 et seq.). If the discharge is not mucoid in character, the preliminary cleansing described above will usually be found sufficient. The curved end of the pipette is then to be introduced into the perforation, and the remedial solution is to be injected into the tympanic cavity. These injections should be repeated on alternate days, or three times a week; and if, after the third or fourth injection, little or no improvement is perceptible, we may safely assume that our treatment is defective in respect to the preliminary cleansing. The proper course is then to wash out the middle ear in one of the two ways described on pp. 190 and 191, and immediately afterward to introduce the remedial solution.

Of the different local remedies that may be used in the treatment of a non-chronic purulent discharge from the middle ear, I employ only nitrate of silver, in the form of solutions of different strengths. In the great majority of cases it is not necessary to employ a stronger solution than one containing two grains to the ounce of water. If the perforation is comparatively large, say about two millimetres in diameter, we may—if the weaker

solutions fail to produce the desired effect—employ a solution of almost any strength, *e.g.*, one of even 480 grains to the ounce (saturated solution). In this connection I may say that during the past two or three years I have rarely felt the necessity, even in the chronic forms of purulent discharge from the middle ear, of employing a stronger solution than one of five grains to the ounce. I almost never introduce the remedial solution into the tympanum in any other way than by means of the slender glass pipette, and it is to this more perfect method of bringing the remedy in contact with the diseased tympanic mucous membrane that I attribute the successful results which I have obtained with such a weak solution as one of two grains to the ounce. It may seem strange to some who read this section that I should recommend solutions of only one drug, *viz.*, nitrate of silver. I do it, however, advisedly, for I have wasted a great deal of time in trying various remedies,—all of them highly recommended; but I have found them one and all so far inferior to nitrate of silver that I feel no hesitation in passing them all over in silence.

Unless the perforation is quite large, it is practically useless to recommend the patient to employ some remedial solution at home. If for any reason, however, it seems desirable to do so, a three-grain solution of sulphate of zinc or a two-grain solution of acetate of lead, may be prescribed. The solutions of nitrate of silver can scarcely be employed by the patient himself,—or by the mother in the case of a child,—for without a certain degree of familiarity with the handling of these solutions, almost anybody would be quite certain to stain either his person or his garments.

The more rebellious cases of otitis media purulenta acuta merit the title of otitis media purulenta chronica, and it is to that chapter that I would refer the reader who desires to learn further details with regard to the management of this class of cases.

If the perforation is large enough to admit of such a procedure, powdered remedies (alum, iodoform, boracic acid) may sometimes be used to advantage in checking the discharge from the middle ear. My mode of using them is the following: the tympanic cavity having been freed as far as possible from the secretions which it may contain, I moisten the tip of the slender middle-ear probe, dip it into the powder, and then cautiously introduce it, with the mass of powder clinging to it, into the opening in the drum-membrane. In the case of a small opening I generally find it necessary afterward to push in, one after another, the portions of powder that remain sticking to the edges of the perforation. Sometimes a single such charge of powder suffices to arrest the discharge permanently; at other times, repeated applications will be found necessary. So far as the quantity is concerned, I am not aware that it is important to employ any particular amount of either of the three remedies mentioned above. In the case of powdered burned alum, a mass equal in size to a No. 8 shot (or a sphere about two millimetres in diameter) will often suffice for a single charge. I

frequently, however, use three or four times this amount, especially if the perforation be one of good size. I have never experienced any unpleasant effects from using powdered burned alum in this manner. In former years I was in the habit (in chronic cases, with extensive destruction of the drum-membrane) of blowing comparatively large quantities of powdered alum indiscriminately into the exposed cavity of the middle ear, and I occasionally experienced unpleasant effects. This mode of procedure, however, is very different from the one recommended above. In the scale of efficiency I should place powdered iodoform very nearly if not quite on a par with powdered burned alum; in the scale of safety I should place both it and boracic acid ahead of the alum. The penetrating odor of the iodoform is sometimes so disagreeable to the patient, or to the patient's friends, that the physician is obliged to abstain from its further use. Apart from this it is a most valuable remedy. Boracic acid, in the form of a very fine sand,—I have not yet succeeded in obtaining a finely divided powder,—seems to produce its beneficial effects by robbing the secretions of all their irritating properties, and not by exerting anything like an astringent effect. I have not used it very much in the manner described above, and am therefore scarcely competent to express a decided opinion with regard to its efficiency. In its direct curative powers, I am confident that it will be found inferior to both alum and iodoform. I frequently prescribe it, however, as a deodorizer, instructing the patient to add it to the water used for syringing the ear, in the proportion of a scant teaspoonful to the pint of water. I am not positive that I can yet say very much in its favor even as a simple deodorizer, though in the main I have been pleased with the results obtained.

*Acute Inflammation of the Posterior Fold of the Drum-Membrane.*

I have seen only two cases of this rare form of disease, and as both the subjective symptoms and the changes observed in the ear are almost the same as those which characterize certain forms of acute inflammation of the middle ear, I have thought it best to say what little I have to say on this subject in the present chapter. The history of the first of these cases is as follows:

The patient, a policeman, consulted me on the 10th of March, 1874, for a very distressing tinnitus in both ears. He had experienced no pain in them, and his hearing, so far as he was aware, was perfect. The tinnitus had made its appearance about two months previously. I tested his hearing with my watch and found it to be: R.  $\frac{6}{1\frac{1}{2}}$ ; L.  $\frac{6}{1\frac{1}{2}}$ . Both drum-membranes presented a dull and opaque appearance, and were slightly sunken. On the left side there was moderate congestion of the posterior fold (the parts above and behind the short process of the hammer). My diagnosis was catarrhal inflammation of both middle ears, and I began treating the patient in accordance with that diagnosis.

On the 14th of March, finding that the redness of the posterior fold still persisted, I painted the parts with a strong solution of nitrate of silver (gr. 120 to the ounce). I interpreted this redness as an evidence of a still more active congestion of the neighboring mucous membrane, and employed the solution of silver simply for the purpose of producing a derivative effect.

On the 16th the patient reported that the tinnitus in the left ear had materially increased: there was, as he described it, a constant ringing of bells in his ear. His face presented the aspect of one who was in suffering, but yet he described the pain in his ear as being only trifling. H.D.W. = L.  $\frac{3}{12}$ . On inspection I found that the skin immediately above the posterior half of the drum-membrane was red, tense, and glistening. Through the upper and posterior portion of the membrana tympani, which was still translucent, a yellowish area was visible. It conveyed to my eye the appearance as if a yellowish body projected downward from the inner side of the axis-band of the hammer. Suspecting the existence of an accumulation of pus, I incised the inflamed and swollen posterior fold, and afforded escape to a drop of thick, creamy pus. A second incision into the anterior fold, which was also quite red, gave escape only to blood. (The patient bore both of these cuts without flinching.) Inflation by Politzer's method failed to exert the slightest appreciable influence upon the contents of the abscess. After the immediate pain of the incisions had subsided, the patient expressed himself as feeling greatly relieved in the condition of his head.

On the 18th of March the patient reported that he was feeling better, and that no discharge had yet made its appearance; and on inspection I found that no evidence existed of there having been any discharge since the day of the operation.

On the 23d of March only a slight singing noise remained in the left ear. (The subsequent history of the case is of no further interest in its bearings upon the subject of the present section.)

The second case was seen about two years later, and from that time to the present I have not seen a third case. The history, in brief, is as follows: The patient, a lady, about thirty years of age and in good health, began to suffer from pain in her right ear on April 18, 1876. Her physician examined the ear, and finding it filled with a plug of cerumen, he removed it by syringing. During the following three days she continued to suffer from pain in the ear, the pain not being constant, but coming on in paroxysms, with intervals—which sometimes lasted for several hours—of complete freedom from pain. The pain, however, when it came, was of very great severity, especially on the 21st of April, the day on which I saw her. At this time I found the external meatus in a normal condition; the drum-membrane was beginning to be slightly œdematous (like polished steel

when breathed upon), but not appreciably reddened ; the posterior fold was red and somewhat swollen, especially posteriorly, but without any appreciable pouting, as if pus were working its way toward the surface. Hearing distance for watch  $\frac{1}{2}$ . A free incision (about four millimetres in length) made in the posterior fold caused quite a large drop of pure, thick pus to almost gush out through the opening. (The patient was under the influence of an anæsthetic.)

I did not see the case again, but the physician reported that the operation gave complete relief, and that very little, if any, discharge made its appearance afterward.

In the report which I published of these two cases, in the Transactions of the American Otological Society for 1877, I made the following remarks : "Every aurist sees a number of cases of otorrhœa in which the only demonstrable lesion of any importance is an ulcerated opening in the posterior half of Shrapnell's membrane, from which a fistulous track leads inward a variable distance, and at the bottom of which the probe usually encounters denuded bone. Sometimes this opening is so extensive that the neck and head of the hammer lie exposed to view. The peculiarity of these cases, however, lies in the fact that the membrana tympani is still entire, and, in many cases, not adherent to the inner wall of the tympanum. Inflation, too, either by Politzer's method or by means of the catheter, reveals the fact that the cavity of the tympanum contains no fluid, and has no communication with the fistulous cavity. In other words, the trouble is a chronic caries of a limited region of bone in the immediate vicinity of the middle ear ; but it differs from all the most common forms of caries encountered in this region in the fact that the pus and detritus thrown off from the diseased part do not escape by way of the tympanum, but through a sinus which, though appearing to lead directly into the middle ear, has no communication whatever with this cavity. If I am not mistaken, it has been customary to explain these cases on the supposition that originally there was an inflammation of the entire middle ear, with a perforation in Shrapnell's membrane, but that gradually the inflammatory process became restricted to the tissues occupying the upper and posterior portion of the cavity, the wall of separation formed by the healing process being so perfect as to entirely prevent any of the inflammatory products from entering the middle ear. In a word, these cases have been looked upon as cases of an imperfectly healed purulent inflammation of the middle ear. The two cases which I have just reported suggest the idea that the pathology of this class of cases may be a different one ; that is, that at the outset the inflammation may have been restricted to the soft parts constituting, and lying near to, the posterior half of Shrapnell's membrane [posterior fold is meant]. As the descriptions of these two cases show, such a circumscribed inflammation of Shrapnell's membrane does sometimes occur, and, such being the

fact, is it not more natural to explain these cases of fistulous opening in Shrapnell's membrane as *ab initio* cases of circumscribed inflammation? Further observations of such cases will undoubtedly furnish us, in due time, with a satisfactory explanation of their pathology." Further observations have not been forthcoming, and from this circumstance alone I am convinced that the view which these two cases strongly tempted me to adopt is not the correct one, at least so far as the majority of cases of ulceration of Shrapnell's membrane is concerned. Furthermore, it is difficult for me to get rid of the idea that an irritation from without—supplied, in the one case, by the application of a strong solution of nitrate of silver, and in the other by the pressure very probably exerted by the mass of impacted cerumen—may have determined the localization of the inflammation in this particular region.

So far as the *diagnosis* of an abscess in the posterior fold is concerned, the following may be mentioned as the points which will enable us to suspect strongly that pus is developing in this particular locality :

1. The well-marked redness of the parts which lie immediately above the posterior half of the drum-membrane.
2. The absence of any evidence of active inflammation of the middle ear proper.
3. The unusual severity of the pain in the ear.
4. The slight degree of impairment of the hearing.
5. The absence of pain, tenderness, or swelling in the mastoid region, one or all of which symptoms would be present if the redness of the posterior fold were simply an evidence of the more acute inflammation going on in the mastoid antrum.
6. The previous history of the case can alone enable us to differentiate the condition under consideration from that produced by a fracture of the squamous portion of the temporal bone.

The *treatment* has already been sufficiently indicated above.

#### SYPHILITIC DISEASE.

Writers on diseases of the ear are, I believe, nearly unanimous in the statement that lesions characteristic of syphilis are never observed in the middle ear or membrana tympani. While I do not feel justified as yet in disputing this statement with any great degree of positiveness, owing to the scantiness of the material which has come under my observation, I cannot help feeling that, we shall in time learn to recognize in these parts textural lesions as distinctively characteristic of syphilis as are most of its external manifestations. Take for example the following cases :

CASE I.—The patient, a gardener, thirty-seven years of age, was in good physical condition when he first came to the Infirmary, on the 25th of Sep-

tember, 1872. He stated that seven years previously he first noticed that his hearing was diminishing in acuteness. The deafness increased very slowly, and there was constant tinnitus aurium. When I first saw the patient I was obliged to raise my tone of voice a little in order to make myself heard by him. The ticking of my watch was heard at a distance of three inches on the right side, while on the left side he could only hear it when the watch was pressed against the ear. Pharyngeal mucous membrane pale and "sclerosed." Both drum-membranes opaque and somewhat whitish in color, but perfectly normal in position.

*Treatment* (twice a week): inflations, according to Politzer's method; mopping out the naso-pharyngeal space with a twenty-grain solution of nitrate of silver.

October 9th.—Pharyngeal mucous membrane is now red and somewhat swollen.

November 20th.—Ten days ago, according to his account, he began to suffer from pain in the left ear. Three days ago a serous discharge made its appearance, and has continued since. On examination, the left drum-membrane is found to be red and swollen, with a small perforation in the anterior inferior quadrant. The handle and short process of the hammer are no longer distinguishable. No bulging of any part of the membrane.

November 26th.—Perforation has apparently healed. Otorrhœa has ceased. During inflation the air is heard through the auscultation-tube to enter the middle ear in a continuous current, without râles. The drum-membrane is still red, swollen, and parchment-like on its outer surface.

December 4th.—To-day the right drum-membrane is found to be red and swollen. No history of pain in the ear.

December 7th.—Redness of right drum-membrane less marked.

December 14th.—Condition of the left drum-membrane has again changed. It is now of a bright red color, moist, more decidedly swollen than at the last visit, and covered in front with a thick white mass, suggestive of a growth of vegetable fungus. Examined under the microscope, however, this mass is found to be composed entirely of large, flattened epithelial cells. Perforation again visible in the anterior inferior quadrant.

December 18th.—Swelling of left drum-membrane has again diminished. Perforation is barely recognizable as a black point.

January 15, 1873.—Pharyngeal mucous membrane is still red and swollen. Patient complains of constant pain in the ears. He can no longer distinguish the ticking of a watch in either ear. A perforation has also formed in the right drum-membrane. A well-defined circular white spot has developed, since the last visit, in the posterior superior quadrant of the left drum-membrane.

January 29th.—Pain continues. A second perforation now exists in the left drum-membrane; it is located at the site of the circular white spot noticed at the last visit.



March 5th.—Patient has not visited the Infirmary since the last date. His general condition has very much changed during the interval. He is emaciated. His face wears constantly an expression of pain. Pulse rapid and feeble. He states that he has suffered a great deal since his last visit with pain throughout the left side of the head. Discharge from the left ear copious and fetid. Total loss of hearing in the left ear. The tones of a vibrating tuning-fork are referred to the right ear, even when it is placed upon the left temporal bone. At the innermost portion of the left meatus the upper cutaneous wall of the canal appears to be in a collapsed condition. By means of a probe this collapsed portion can be lifted back nearly to its natural position, though not sufficiently at all points to bring the membrana tympani into view. When passed farther in the probe encounters quite an extensive region of denuded bone. No special change has taken place in the right ear, except that the hearing is so poor that we are obliged to communicate with him by writing.

June 25th.—Patient is barely able to walk about without assistance, owing to his feeble condition. Left side of face paralyzed. Tongue swollen and ulcerated. He admits to-day, for the first time, that ten years ago he had a chancre, followed soon by sore throat and other characteristic symptoms. He has been an inmate of one of the large general hospitals of the city for several weeks past, and declines to enter the Infirmary. (This was his last visit to the institution.)

CASE II.—Male, twenty-four years of age, well nourished. He was seen for the first time on the 9th of October, 1878. Double otorrhœa of several weeks' standing. No history of anything like an acute beginning, nor does he remember to have ever had otorrhœa before the present attack. Syphilitic ulceration of velum; diffuse redness and swelling of entire fauces. Right external auditory canal filled with pus. The membrana tympani, after the removal of the pus, was found to be of a bright red color, very much swollen, and perforated in two places—below and in front, and posteriorly near the umbo. A whitish material filled the posterior perforation. In a word, the drum-membrane presented precisely the same appearance, as regards color, condition of ulceration, diffuse swelling, etc., as did the soft palate. (No note was made of the condition of the left ear, and the patient was seen for the last time a few days later.)

The development of a second perforation in the left drum-membrane of Case I., through a melting process similar to that observed so frequently in the velum palati, is totally different from anything that I have ever observed in any case of non-syphilitic inflammation of the middle ear. In Case II. probably this same melting away of a limited area of the drum-membrane took place, though in that case I only had an opportunity of observing the process at its stage of completion. There were no evidences of pressure

from within in either of these cases ; in both, the loss of substance could only be described as a melting away or death of the tissues. In Case I., furthermore, the subsequent course of the disease—the development of caries and facial paralysis, with no evidences of interference with the free escape of the pus formed—was certainly not in harmony with the ordinary course of a non-syphilitic otitis media purulenta acuta.

In all the other cases that I have seen of inflammation of the middle ear, of syphilitic origin, the picture presented by the membrana tympani was invariably the same as that which we frequently see in the non-syphilitic cases.

With regard to the question of prognosis and treatment, a word or two will suffice. The prognosis is the same as that of a corresponding syphilitic lesion in any other part of the body. Aside from the administration of constitutional remedies, the treatment is the same as that employed in an ordinary case of acute purulent inflammation of the middle ear.<sup>1</sup>

#### CHRONIC PURULENT INFLAMMATION.

(Otitis media purulenta chronica.)

##### *Etiology.*

A chronic purulent inflammation of the middle ear begins almost invariably as an acute inflammation. In tuberculous and syphilitic individuals we may observe an insidious and painless development of the disease in the middle ear, but these cases are comparatively rare. The etiology of chronic purulent inflammation of the middle ear, so far at least as it can be said to have an etiology separate from that of the acute variety, may be summarized in a single sentence : the lack of proper treatment during the acute stage of the inflammation is the cause of the chronic form of the disease in ninety-nine out of a hundred cases. This may seem somewhat exaggerated. Nevertheless, I believe it to be true. There are many cases, I admit, which yield very slowly to even the most skilful treatment, and which perhaps would be described as having merited the title of “ chronic ; ” but the total duration of the affection is even then not likely to exceed a few weeks, whereas a genuine case of chronic otitis media purulenta is one in which the morbid process in the middle ear has been going on for months, if not for years. It is to cases of this kind that I refer when I say that they owe their origin, as a rule, to the lack of proper treatment during the earlier stages of the attack.

---

<sup>1</sup> See a recent paper on this same subject by Dr. F. R. Sturgis, in the Boston Medical and Surgical Journal, June 3, 1880.

*The Course of the Disease.*

A chronic purulent inflammation of the middle ear may run a variety of courses. For years the mucous membrane of the middle ear may secrete a scanty purulent or muco-purulent fluid, and if the patient is careful to cleanse the ear at stated intervals, this persistent but slight otorrhœa may represent the only symptom of which he has any complaint to make. Furthermore, the most careful examination may fail to detect any evidence of the existence of any other pathological condition than that of a slightly swollen and relaxed<sup>1</sup> tympanic mucous membrane; I except, as a matter of course, the loss of drum-membrane substance that took place undoubtedly in the earlier stages of the disease. If this perforation in the membrana tympani is of ample dimensions, it is not likely that the pathological picture which I have described will undergo any material change for the worse.

In another group of cases this placid course of the disease is disturbed by a complication which may lead to a whole train of more or less serious disorders. I refer to the development of granulation-tissue. Two elements co-operate in certain cases to bring into activity this proliferative tendency: first, the acrid and irritating nature of the secretions; and second, the uncleanly habits of the patient, who permits these acrid secretions to lie undisturbed, in a decomposing condition, in contact with the mucous membrane of the middle ear. Sometimes the irritating properties of these secretions are so great that even the skin lining the external auditory canal undergoes ulceration from contact with them. In this second group the discharge is almost always abundant.

Finally, if the conditions just described are not properly treated, or, as is more likely to be the case, if they are allowed to remain wholly untreated, the inflammation of the middle ear begins to encroach upon the neighboring organs, and we then encounter, as results of this extension of the disease, the following catalogue of lesions, which are often fatal: caries or necrosis of the bony walls of the middle ear or of the mastoid cells—the result, very commonly, of retained pus; ulceration of the carotid artery, with fatal hemorrhage; ulceration of the lateral sinus or of the communicating mastoid vein, with phlebitis, pyæmia, and perhaps metastatic abscesses; meningitis, or abscess of the brain; consumption, due to an infection of the system produced by a collection of cheesy pus and débris retained in the middle ear or mastoid antrum; and perhaps still other lesions which do not now occur to my mind.

For purposes of convenience, then, I will treat the subject of the present chapter under three headings, corresponding to the three groups into

---

<sup>1</sup> Not possessing the firm and healthy appearance of the normal mucous membrane.

which I have divided all cases of chronic purulent inflammation of the middle ear. Before considering these groups in detail, however, I will make a few

*General Remarks on Diagnosis and Prognosis.*

The term "chronic purulent inflammation of the middle ear," as already intimated, covers such a multitude of different conditions and combinations of conditions that, as diagnosticians, we must consider our task as only begun when we ascertain the fact that the case is one of otitis media purulenta chronica. It is not sufficient even to determine in a general way that it belongs to one of the three larger classes mentioned above. If we wish to treat the case successfully we must make a diagnosis of the exact condition of every square millimetre of the surface of the auditory canal, drum-membrane, tympanic mucous membrane, etc.—so far, at least, as it is possible to reach some of these remoter portions of the ear. As a matter of course there are parts which we cannot see, nor even reach with an instrument. When once, however, the art of exploring the nooks and crannies of the middle ear has been learned, it is surprising how often we are rewarded by discoveries which enable us to arrest the troublesome discharge, and perhaps also to relieve the patient of other distressing symptoms. The art of properly cleaning the ear is the art which I would urge the beginner in otology to cultivate. I am strongly tempted to add that when he has mastered this very difficult art, he will find himself a master both in the diagnosis and in the treatment of diseases of the ear. This is not far from the truth. As an instructor I have repeatedly made the observation that, after the ear had been properly cleansed, even a beginner would often be able to make a correct diagnosis of rather complicated conditions. But very rarely indeed have I known a pupil to be able to clean an ear even fairly well, until he had served a somewhat long apprenticeship. This cleansing process must be done by means of the cotton-holder, the curette, the slender middle-ear probe, and the delicate angular forceps. *The syringe, as a rule, is not to be used.* If the external auditory canal is filled with a very foul pus, it may be pleasanter for the physician to remove as much of it as he can by syringing. If the discharge, however, is not particularly offensive, time will be saved by employing, from the very beginning, the cotton-holder armed with absorbent cotton. By varying the amount of cotton used, the physician can make a mop suitable either for the removal of large quantities of pus in the broad external auditory canal, or for the thorough cleansing of a small sinus leading through Shrapnell's membrane into the recesses of the middle ear. If syringing alone is employed, the picture afterward presented to the eye of the observer will almost invariably be a deceptive one. All the depressions and interstices will continue to hold a certain amount of water, and under these circumstances the most experienced observer can scarcely fail to interpret

incorrectly what he sees. But oftentimes even the cotton-holder fails to accomplish all that is desired. Masses of cheesy pus or of epithelium remain embedded in the recesses or cling firmly to the tissues, and we are obliged to use the curette, the slender probe, or the forceps. In all these recommendations I assume that I am dealing with physicians who possess a fair degree of steadiness of hand and delicacy of touch. I assume, furthermore, that they have mastered the art of illuminating the deeper parts of the ear with a forehead mirror. To men who are not accustomed to the delicate manipulation of instruments, this whole chapter must necessarily, in a large measure, prove unprofitable. If cases belonging to the first group come into their hands for treatment, they may, by employing the syringe and by instilling suitable remedial solutions into the ear, occasionally effect a cure; but a large number of perfectly curable cases will experience comparatively little benefit from this—if I may be allowed the expression—indiscriminate firing at the enemy. It is far better, however, for such men to recognize early their lack of manual dexterity, and to abstain religiously from using instruments of any kind in the ear. They will then be almost sure of doing their patients no harm, and they will, as already stated, occasionally effect a cure by those methods of treatment which necessitate the employment of no other instrument but the syringe.

It is unnecessary to enter here into a minute description of the conditions which call for the use of this or that particular instrument, or to attempt a description of the proper modes of using them. I will simply formulate two general rules, which will be found, I believe, useful. In the first place, when granulation-tissue presents itself to view, it is never safe to assume that the relations are what they seem to be. Thus, for example, I have more than once thought, after thoroughly cleansing an ear, that the picture presented to my eye was one of a granulating and very much hypertrophied mucous membrane of the inner wall of the tympanum, with total destruction of the membrana tympani. By the aid of simple inspection this was as far as I was able to go in my interpretation of the appearances observed. By gently manipulating the parts with the probe or the curette, however, the incorrectness of my interpretation became at once apparent. The "granulating and hypertrophied mucous membrane of the inner wall of the tympanum" was in reality a flattened polypoid growth, lying upon the outer surface of the drum-membrane. Its peduncle, which passed through a large perforation in the posterior superior quadrant of the drum-membrane, sprang from the upper and posterior portion of the tympanic cavity. Long experience and the most careful scrutiny will never enable the physician to dispense with these instrumental manipulations. And it must be remembered that an error in diagnosis, under circumstances such as I have just described, means also an erroneous plan of treatment.

The second rule to which I referred above, is this: it is a good plan to assume that, in the great majority of cases of long-standing otorrhœa, the

discharge is kept up either by a carious process in some portion of the temporal bone, or by a mass of granulation-tissue, situated in one of the following three places: the external auditory canal, the middle ear proper, or the mastoid antrum. If the physician, therefore, expects to relieve his patient of his otorrhœa, he must ascertain, as accurately as possible, where the caries or the granulation-tissue is situated. It is not sufficient for him to ascertain, in a general way, that it is situated in the external auditory canal or in some part of the middle ear; he must ascertain the precise limits of the disease, just as the general surgeon does in a case of caries of the tibia or in one of uterine polypoid growths. He must introduce his slender probe into every recess; he must touch with it every spot of suspicious redness; in a word, he must render to himself a strict account of every portion of the ear within his reach. If the external canal is free from granulation-tissue or from caries, and the pus clearly escapes from the middle ear through a perforation in the membrana tympani, he must pass his cotton-holder (armed with absorbent cotton) through the perforation and soak up the pus or mucus that fills the middle ear and prevents him from seeing the opposite promontory. In this way one can often bring to light a polypoid growth which otherwise would escape observation. But in many cases such a cleansing of the middle ear is not sufficient. The polypus may be so situated that no portion of it can be seen through the perforation. For instance, it may spring from the upper or outer wall, and may hang down on one side or the other of the opening. In addition, therefore, to the cleansing, it is advisable to bend the end of the probe slightly, and then, passing it in through the perforation, to rotate it in such a manner that it will be likely to bring into the field of vision any polypoid growth that may be located in the immediate vicinity. If these manipulations are executed with delicacy—the surgeon's eye being directed all the time upon the perforation, and account being taken of the exact situation of the (concealed) end of the probe—the patient will probably not complain of even a sense of discomfort, much less of pain. If, after making a critical search, the physician fails to find either a caries or a region of granulation-tissue, he is still not warranted in drawing the inference that these lesions are absent, that is, that the case belongs to the first of the three groups into which I have divided all cases of otitis media purulenta chronica. He should proceed, however, to treat it as if it really did belong to this group, and upon the success or lack of success of his treatment he should finally base his diagnosis. I do not mean by this that his conclusion will always be in harmony with the facts; but simply that there is a strong probability that such will be the case. In the absence of these lesions, a suitable medication of the middle ear will soon arrest the discharge; if these lesions, however, are present, the same medication will almost certainly fail to accomplish this result.

So far as the question of *prognosis* is concerned, only a few rules of

general applicability can be laid down. In the first place, when a case of chronic purulent inflammation of the middle ear is brought to us for an opinion as to what is likely to be the future course of the disease, we must, in a large proportion of the cases, be guarded in our statements. This is true, in a special degree, with regard to the effects of treatment. Let us consider, first, the question of the *arrest of the discharge*, which is generally the one that most interests the patient. Taking a large number of cases together, we may promise very good results from treatment, but in individual cases we cannot safely predict what will be the results. Oftentimes the cases which seem as if they would be the easiest to manage, and with regard to which we feel disposed to give a very favorable prognosis, prove in the end to be the most stubborn. On the other hand, if the discharge is profuse and offensive, and if there is an abundant development of granulation-tissue, we may safely make the prediction that treatment will effect a very marked improvement in the condition of the ear,—that the discharge will be greatly diminished in quantity, and at the same time be rendered inoffensive. In fact, in quite a large number of cases the discharge will be arrested permanently, but it is not safe to predict such a result. The prognosis is perhaps better in cases in which the perforation in the drum-membrane is large than in those in which it is small. In the next place, the prognosis is far better in cases in which the perforation involves the membrana tympani proper than in those in which the discharge escapes through an opening in Shrapnell's membrane or in the soft parts in that immediate vicinity.

The next question in prognosis to which we must frequently give an answer, relates to the *recovery of the hearing-power* in the ear affected. If masses of granulation-tissue surround, and perhaps even press upon, the stirrup, and if we find that we can remove these masses, we may safely say that a certain degree of improvement in the hearing will be likely to result from treatment. The effects produced by the presence of a purulent or muco-purulent fluid in the middle ear upon the acuteness of the hearing is very nearly the same as those due to a mass of granulation-tissue, when the latter occupies the position just mentioned. It would appear, therefore, as if, in those cases in which there are no obstructive granulations, our prognosis should be the same with regard to the improvement of the hearing as with regard to the arrest of the discharge. This is true in perhaps the majority of cases. In a certain proportion of the cases, however, the hearing seems to be affected by other changes, directly dependent upon the arrest of the discharge. Thus, for example, after we have succeeded in arresting the discharge, the patient will be conscious for a short time that his hearing is better than it was during the continuance of the discharge. Then gradually the hearing will become less acute and the patient will complain that he does not hear as well as when the discharge existed. If some slight exposure causes the otorrhœa to return, we may observe the

apparently perplexing phenomenon of an increased acuteness in the hearing power, due to the re-establishment of a purulent otitis media. The explanation of these conflicting phenomena, which are encountered by no means rarely, is undoubtedly the following: So long as the soft parts surrounding the stirrup, and especially its foot-plate, are moist, this ossicle possesses its highest degree of mobility. For a short time after the discharge has been arrested these soft parts remain simply moist, and, in the absence of any considerable quantity of free fluid, which would of course act as a damper, the stirrup can vibrate with the maximum degree of freedom—that is, the patient's hearing will be at its maximum degree of acuteness. With the increasing dryness of these parts, however, they lose their flexibility, and the stirrup, or rather the stapedio-vestibular articulation, then becomes partially ankylosed, and the patient's hearing will then be at its minimum degree of acuteness—a lower degree even than that which existed when the middle ear was filled with fluid.

Finally, we are sometimes called upon to state how far a chronic purulent inflammation of the middle ear is likely to endanger the patient's life. If we are asked the question in a general way, as for instance by the officers of a life insurance company, we can only say that a small proportion of all the individuals who are affected with a chronic discharge from the ear die from some form of disease directly induced by the ear affection.<sup>1</sup> If we are asked, on the other hand, to state the probabilities in individual cases, we must base our predictions upon a variety of data, viz., the past history of

---

<sup>1</sup> The practical question which presents itself to the life insurance authorities is this: Should a sweeping rule be laid down to the effect that all applicants who may be affected with a chronic discharge from the ear, must be rejected? Or should these cases be investigated, and the decision made to depend upon the result of the investigation? The sweeping rule affords undoubtedly the safest and simplest way out of the difficulty. At the same time such a course would lead to the rejection of many good risks, which rival companies would be quick to accept. On the other hand, if the attempt were made to discriminate carefully between the comparatively safe and the more dangerous cases of otorrhoea, the services of an expert would have to be secured, and to this additional expense the great majority of life insurance offices would object very seriously. In the next place, such expert examinations could only be obtained in the cities. This alone, therefore, would render the adoption of such a rule impracticable. I think, however, that if favorable answers can be obtained to questions bearing upon a few of the more important points, these cases of otorrhoea may be accepted as fair average risks. The points to which I have reference are these: duration of the discharge—whether constant or intermittent; its characteristics—whether thick or watery in its nature, whether odorless or offensive, and whether tinged with blood at times or simply purulent; the frequent occurrence of pain in the ear or in any part of the head; and, finally, the existence of tenderness on pressure behind, above, or in front of the ear. On the other hand, if the applicant states that the discharge is abundant, that it is offensive, that it is occasionally bloody, and that he is subject to pain in the region of the affected ear or throughout that side of the head, the risk should certainly be considered as extra-hazardous.



the case, the nature of the existing lesions, the care which is likely to be bestowed upon the diseased ear, etc. Frequent intercurrent acute attacks of inflammation in the past afford some indication of what may be expected in the future. If a large perforation exists in the drum-membrane, and the external auditory canal is of normal size, we may estimate lightly the danger of either mastoid or cerebral disease. A small perforation in the drum-membrane proper involves far less risk of serious intercurrent disease than does one in the region of Shrapnell's membrane. When the existence of a carious process can be demonstrated in or near the tympanic cavity, the patient should be warned of the serious nature of his disease, and he should be urged to keep the ear scrupulously clean, and to obtain skilled assistance with the least possible delay when pain develops in or near the ear. Farther on I may recur to this subject of prognosis again.

*Different Types of Chronic Purulent Inflammation of the Middle Ear.*

I. SIMPLE UNCOMPLICATED CASES.

Strange as it may seem, the number of cases that belong strictly to this first group is by no means so large as one might suppose. It is quite possible that the absolute number of such cases is large; but, as the symptoms are not of a troublesome nature, many patients probably think it unnecessary to consult a physician, and so it happens that the aurist sees only a few of them. The only difference that exists between these cases and those of subacute catarrhal inflammation of the middle ear is, I suspect, the following: in the former group the absence of the whole or a part of the membrana tympani leads to the establishment of a more active secretion from the mucous membrane of the middle ear than is apt to be the case when the drum-membrane is entire. The exciting cause is probably the same in both sets of cases; it is only in the outward manifestations of these diseases, but not in their intrinsic nature, that a difference exists between the two. The term employed by many English and German writers to designate the purulent form of the disease,—viz., “purulent catarrh of the middle ear;”—is one which seems to be peculiarly appropriate to this class of cases. At the same time there are decided objections to the employment of the term “catarrhal” in this connection (see p. 142). The chief distinguishing feature of these simple uncomplicated cases of chronic purulent inflammation of the middle ear is the total absence—so far, at least, as can be ascertained from the character of the discharge and from the visible and tangible lesions—of any evidences of active inflammation, or of the development of granulation-tissue.

The following case may be taken as a type of the form of disease now under consideration: The patient, a lady, forty years of age, stated that

she had passed through a rather severe attack of purulent inflammation of both ears when she was quite a young girl. She believed that the attack had begun while she was convalescing from scarlet fever. From that time forward she had been subject to an intermittent discharge from both ears, never copious nor offensive, and, so far as she had observed, never materially affecting her hearing. On examination (April 6, 1871), I found both drum-membranes perforated, the opening in each being of large size. A very slight quantity of thin secretion moistened the lower wall of the external auditory canal. The mucous membrane of the promontory was pale, moist, and moderately thickened. At no point was there any evidence of active irritation. No treatment was advised beyond the occasional cleansing of both ears with a little lukewarm water. Four years later (June 8, 1875) I again saw the patient. She reported that no change had taken place in the course of the disease; and, on examination, I found almost precisely the same picture as that which I had observed in 1871. On the left side it seemed to me that the perforation had materially increased in size; of this change, however, I could not feel positive.

In cases like the one which I have just narrated it would undoubtedly be easy to control the slight discharge for a limited period by instilling into the middle ear a feebly astringent solution, say one of nitrate of silver (gr. ij. ad  $\bar{5}$  j.); but in these typically chronic cases we cannot look for permanently beneficial results, and it is therefore better not to urge the patient to submit to treatment. In cases of more recent origin, and especially in those which are characterized by a small perforation in the drum-membrane, treatment is more likely to produce results which will be permanent and which the patient cannot fail to appreciate. The following case may serve as an illustration: The patient, a merchant, forty years of age and in good health, first noticed a discharge from the left ear during the second week of August, 1878. It came on without pain, and continued unchecked up to the 13th of September. On examination made at that time, the external auditory canal was found to be filled with a moderately thick, purulent fluid. A perforation about the size of a pin's head, and with sharply defined limits, occupied the central portion of the drum-membrane, which otherwise appeared to be natural, or at least free from any evidences of inflammation. After the middle ear had been inflated (Politzer's method), for the purpose of driving out as much of the secretion as possible, a few drops of a ten-grain solution of nitrate of silver were dropped into the left ear, firm pressure was then made upon the tragus, and at the same time the patient was told to perform the act of swallowing three or four times in succession. In this way the remedial solution was brought in contact with probably a large part of the tympanic mucous membrane. No appreciable pain followed this procedure.

On the 16th of September the patient reported that the discharge

ceased on the fourteenth, and that the ear since then had felt quite natural. On examination, both the external auditory canal and the tympanic cavity were found to be perfectly dry; the perforation still persisted.

There can be very little doubt that the perforation in this case was the result of some former attack of inflammation of the middle ear, and not of the painless attack which I have just described. In the next place, the prompt manner in which the tympanic mucous membrane returned to a healthy condition and remained so for many months afterward (I have met the patient frequently since 1878), shows conclusively that the case belongs strictly in this first class of uncomplicated cases. Finally, there is still another point of practical importance which is suggested by this case. The method which I employed of introducing the remedial solution into the middle ear is a rather crude but useful method of accomplishing the desired purpose, provided the perforation in the drum-membrane is sufficiently large (*i.e.*, not much smaller than the head of an ordinary pin). If the perforation, however, is quite small, the middle-ear pipette will be found to afford the only sure means of introducing fluids into the tympanic cavity. As this subject of medication of the middle ear is one of great practical importance, I make no apology for giving below, in brief outlines, the histories of three cases in which the successful results obtained were largely due, I believe, to the employment of this more direct method of introducing remedies into the tympanic cavity.

CASE I.—The patient, a clerk, about thirty-five years of age and in good general health, was brought to me by his physician on the twentieth day of October, 1879. The story which he gave of his ear trouble was this: About the first of October he was struck on the left side of the head, and for nearly a week afterward he experienced severe pain in the left ear. On or about the fourth day he discovered that matter was escaping from the left auditory canal, and from that time forward the discharge had been constant. On examination, I found the left external meatus filled with a thick, purulent fluid. A perfectly circular perforation occupied the posterior inferior quadrant. It presented no resemblance whatever to a perforation of traumatic origin, *i.e.*, due to the violent concussion of the air in the meatus. In all other parts the membrana tympani presented a very whitish and tough appearance. The impression made upon my mind was that at some earlier period of his life the patient had been subject for a long time to a purulent inflammation of the left middle ear, and that both the perforation and the marked hypertrophy were the results of that earlier inflammation; while the blow which he had recently received had merely brought on a somewhat severe otitis media purulenta acuta. From the patient, however, I was unable to obtain any evidence corroborative of this view.

He was positive that the ear had always been perfectly healthy before he had received the blow.

I advised the attending physician to instil (three times a week) a five-grain solution of nitrate of silver into the external meatus, after he had thoroughly removed all the pus, and then to force it through the perforation into the middle ear in the manner described above. I then performed the operation once in his presence, in order that he might see exactly how the treatment was to be carried out.

On the 9th of November the physician brought his patient to see me a second time. He reported that the discharge had increased rather than diminished. On questioning the patient I ascertained that he had not once tasted the silver solution since the day on which I first saw him; in other words, it is fair to assume that the remedial solution had only on that occasion been successfully brought in contact with the tympanic mucous membrane. This plan of treatment having failed, I resorted to the use of the pipette, and introduced two or three drops of a ten-grain solution of nitrate of silver into the tympanic cavity. The patient felt it in his nasopharyngeal space almost instantly. He also experienced quite a sharp ear-ache, which was relieved in about one minute by pouring rather hot water into the upturned meatus.

On the 11th and 13th of November the remedy was again introduced into the middle ear in the same manner, and on the 15th the patient reported that there had been no discharge during the previous forty-eight hours. Inspection of the parts also showed that the discharge had entirely ceased, and that even the tympanic cavity was free from unnatural secretion.

On the 9th of January, 1880, the patient consulted me again. He stated that about five days after I last saw him the discharge had reappeared, and had been constant since that time. He had been too much occupied with his business affairs, however, to place himself again under medical care. The same plan of treatment (with the pipette) was resumed.

January 11th.—Discharge still active. Silver solution introduced a second time.

January 14th.—No improvement perceptible. The thought then occurred to me that my lack of success was probably due to the fact that the remedial solution did not come in contact with more than a comparatively small portion of the tympanic mucous membrane, owing partly to the imperfect manner in which I cleansed the cavity of the middle ear, and partly to the small quantity of the remedial solution injected. I accordingly syringed out the tympanum with Blake's middle-ear syringe, using the entire contents of a full syringe (a little over one drachm) for that purpose. So far as I could discover, this procedure brought away only a littleropy mucus. I then injected into the middle ear two or three drops of a ten-grain solution of nitrate of silver, and, after the lapse of a few minutes, no pain having developed in the meantime, I repeated the operation, each

time causing the solution to pass through the Eustachian tube into the naso-pharynx.

The patient returned on the 17th of January and reported that the discharge had entirely ceased. Inspection also confirmed this statement. Before dismissing the patient, however, I introduced into the left tympanic cavity, by means of the slender middle-ear probe, two or three pellets of powdered iodoform and burned alum, in about equal parts. About six weeks later he reported that up to that time no relapse had occurred.

CASE II.—The patient, a man forty years of age and in good general health, stated that in boyhood he passed through an attack of scarlet fever, which left him with both ears damaged. At long intervals he had had a discharge from the right ear, and recently he had also noticed a sense of fullness in the left ear, and at times a slight watery discharge from it. On examination (December 27, 1879), I found the left meatus moistened with a thin, watery discharge, and the membrana tympani somewhat bulging and decidedly soaked in appearance. No perforation was visible, but probably a small, valve-like opening existed in the posterior half of the membrane. When Valsalva's experiment was performed by the patient, the membrana tympani yielded as a whole to the pressure from within, but there was no escape of fluid to indicate the location of the perforation. I might state here that sometimes, in acute cases, the transudation of fluid through the unbroken membrana tympani is so active as to produce not merely a moist condition of the auditory canal, but even a discharge from the external orifice. It is quite possible that such a state of things existed in the present case. At the same time it is not safe to infer that no perforation exists simply because we are unable to discover one. A small mass of mucus may effectually plug the opening for a short time, or its edges may become glued together temporarily. The existence or non-existence of a perforation, however, was not in this instance a matter of any importance, as it was very evident that the perforation—if it really existed—was too small to be of much service as an outlet. I therefore made a free incision through the bulging posterior half of the membrane, and afforded escape to some pinkish serum. Although the pressure had been withdrawn, the posterior half of the membrane retained its convex condition, showing clearly that the pressure from within must have been of comparatively long standing. Without any preliminary washing-out procedures, I introduced, with the pipette, two or three drops of a two-grain solution of nitrate of silver into the middle ear. No unpleasant symptoms followed.

On the 28th of December, the discharge still continuing, and the opening in the membrane still being of ample size, I introduced a five-grain solution into the tympanic cavity. None of it appeared to reach the naso-pharynx in the ordinary manner; but yet, almost instantly after the injection had been made, tears began to flow freely from the patient's left eye,

and, for perhaps two or three minutes, he experienced quite a sharp pain in the ear.

On the 30th of December, patient reported that the discharge had diminished in quantity and that the ear felt lighter (*i.e.*, less full). On examination I found that the lower wall of the meatus was barely moist, and that the posterior half of the drum-membrane had almost entirely lost its unnatural convexity. The perforation had nearly healed. After clearing out the middle ear by means of Politzer's method of inflation, I injected into the tympanum, by means of the pipette, a much larger quantity of the silver solution (five grains to the ounce) than I had ever injected before. It amounted to at least ten drops, and as the perforation was then quite small, no regurgitation took place, as on the previous occasion. Tears at once came into the left eye, and for some minutes the patient was unable to utter a word, so much of the solution had escaped into his throat. A watery fluid ran for a short time in an almost continuous stream from the left nasal orifice. The pain in the ear was quite sharp, but it yielded very quickly to instillations of hot water.

On the 2d of January, I found that the discharge from the ear had almost ceased. As there seemed to be no free fluid in the middle ear, I forced through the perforation, into the tympanic cavity, a few small pellets of powdered iodoform and burned alum.

January 4th.—Same condition. Iodoform and alum introduced a second time.

On the 8th of January the patient reported that the discharge had not reappeared since the 4th inst. On inspection I found the membrana tympani pale, dry, and of perfectly natural curvature. A small scab covered the site of the perforation. The hearing distance, for the watch, had increased from two inches up to nine inches. So far as conversation was concerned, the patient experienced no difficulty whatever in hearing all that was said to him. (On the right side, I should have stated before, the drum-membrane was amalgamated with the tissues of the promontory.)

CASE III.—The patient, a college student, seventeen years of age and of good physique, consulted me on the 16th of September, 1878, on account of a discharge from both ears, associated at times with pain. So far as he could remember, the discharge began during his childhood, and had continued without intermission up to that time. On one or two occasions he had found the secretion slightly stained with blood. Furthermore, the discharge varied in activity, at times being barely perceptible. During the period immediately preceding his visit, however, it had been more profuse than usual. On examination I found both auditory canals filled with thick muco-pus. Both drum-membranes presented the same lesions, *viz.*, a small, round perforation in the posterior inferior quadrant, marked bulging of the posterior half, a generally tough and soaked appearance of the

whole membrane, and, finally, entire absence of any evidence of active irritation. The most urgent indication on both sides, therefore, was to establish a free outlet, and thus to relieve the constant condition of pressure upon the mucous membrane of the middle ear and the constant partial stagnation of the purulent secretion. I therefore made a long, crescent-shaped incision in the posterior half of each drum-membrane, and, after removing as much of the fluid contents of the middle ear as I could, I injected several drops of a ten-grain solution of nitrate of silver.

On the following day, the 17th, the patient reported that the discharge had diminished noticeably in quantity, especially on the left side. He had also experienced no pain since the operation. (And here I might state that, if the precaution be taken to establish an opening of ample size in the membrana tympani, before we inject our remedial solution into the middle ear, we need feel no fear that a prolonged painful reaction will follow this procedure. If the perforation, however, is quite small, my rule is, not to inject a solution of nitrate of silver of greater strength than two grains to the ounce of water.) On inspection I found that the edges of the wound, in both drum-membranes, were somewhat red and swollen. No injections made.

On the 18th I repeated the injections, using on both sides a forty-five grain solution of nitrate of silver. Very little pain followed.

On the 19th I found that the discharge was very trifling. I therefore pushed a few pellets of powdered iodoform ( $\frac{1}{3}$ ) and burned alum ( $\frac{2}{3}$ ) through the perforation into the tympanic cavity.

On the 20th I repeated this procedure.

On the 23d the patient reported that he had been entirely free from discharge since the 20th, and on examination I found the parts almost perfectly dry. As the patient was anxious to return that day to his home in Michigan, I was unable to keep the case any longer under observation. I have very little doubt, however, that what was then an apparent cure proved to be a permanent one.

To these three histories I might add a fourth, which illustrates a somewhat different method of treatment. The patient, a child, six years of age, had been subject since infancy to a slight watery discharge from the left ear, the result of an attack of measles. On examination (Oct. 11, 1876) I found a moderate amount of thin, purulent secretion in the left meatus. The membrana tympani showed no evidences of active inflammation, but a small circular perforation occupied the anterior inferior quadrant. After drying the parts as thoroughly as I could, I introduced the end of the middle-ear probe, on which a bead of nitrate of silver had been fused, into the middle ear through the perforation. I pressed it for an instant against the mucous membrane near the orifice of the Eustachian tube, and then quickly withdrew it. The child made no complaint of pain afterward.

On the 14th of October the mother reported that no discharge had been seen since the 11th, and that the child's hearing had appreciably improved. Inspection showed the parts to be perfectly dry.

The objection to this latter plan of treatment, in the simple uncomplicated cases of otitis media purulenta chronica, is this : if we allow the bead to remain in contact with the tympanic mucous membrane for too long a time, we may subject the patient to unnecessary pain. Taking all things into consideration, I have no hesitation in asserting that nitrate of silver in the form of a weak solution (from two to five grains to the ounce of water), if brought thoroughly in contact with the mucous membrane of the middle ear, constitutes the most efficient and most easily managed remedy that we possess for the treatment of these uncomplicated cases of chronic purulent inflammation of the middle ear.

*Cheesy inflammation of the middle ear.*—In certain cases the establishment of a purulent inflammation of the middle ear takes place in such a painless, insidious manner that one cannot avoid the suspicion that the process is related in some manner to that which often takes place in the lungs, in the cervical lymphatic glands, and in other parts of the body. The suspicion ripens into belief when we find other evidences that the individual is affected with tuberculosis. In these cases, furthermore, treatment seems to be of very little effect : the parts display no tendency whatever toward reparative action, and in some cases a curious process develops without any adequate provoking cause. In one or two cases I have noticed what I might term an unduly rapid melting away of the edges of the perforation, such as is sometimes observed in a purulent otitis media following scarlet fever. Beyond these ill-defined symptoms I have never observed anything, in these apparently tubercular cases, which might fairly be called diagnostic of the disease. The form of inflammation, however, which is called cheesy inflammation<sup>1</sup> of the middle ear, presents a very striking picture ; one so totally different from that observed in any of the other forms of middle-ear disease encountered in healthy (non-tubercular or non-consumptive) individuals, that one is strongly tempted to consider it as characteristic of a tubercular form of middle-ear disease. The following cases are the only examples of cheesy inflammation of the middle ear that I have ever seen :

CASE I.—The patient, a man thirty-two years of age and in a poor general condition (habitual cough, night-sweats, incurvated nails, emaciated countenance), gave the following account of his ear affection : About one year

---

<sup>1</sup> See Schwartze's Pathological Anatomy of the Ear, translated by J. Orne Green. Houghton, Osgood & Co., Boston.



previously he had experienced slight pain in one ear, which was followed shortly afterward by a discharge. In the course of six months he went through the same experience with the other ear. In both ears the discharge lasted only for a short time, but the deafness, which was well-marked, had continued unchanged ever since. On examination, October 4, 1876, I found the right drum-membrane of a peculiar pale, flesh-tint color, with two or three dilated blood-vessels crossing its outer surface. The impression conveyed to the eye was as if the drum-membrane had been stretched so tightly over some whitish body that its superficial blood-vessels (veins) had been compelled to perform not only their own legitimate task, but also that of the more deeply situated, but then obliterated vessels.

I saw this case only once. I made a note of the conditions observed, but was not able at that time to offer any satisfactory explanation of their origin or significance. I also omitted to test the membrane with the probe; though the appearances were such that I could scarcely have been mistaken with regard to the presence of some semi-solid material in the tympanum, which pressed sufficiently against the drum-membrane to interfere with the circulation on its mucous surface. In the light of the following case, however, I believe that the two cases were essentially identical.

CASE II.—The patient, a clerk, about thirty years of age and in rather poor general health, and with all the external appearances of a person affected with phthisis, consulted me on the 30th of January, 1878, for marked deafness affecting both ears. He gave the following account of his trouble: During the previous autumn, as a result of sea-bathing, both ears had begun to discharge. He was very positive that the affection had developed without pain, and that previous to that time his hearing had been perfect. In corroboration of this statement he called my attention to the fact that he was the head of one of the departments in a large publishing house, and that it would scarcely have been possible for him to have risen to that position, and to have performed its duties properly, unless his hearing had been fairly good. At the time when I saw him his deafness was so marked that I was obliged to speak in quite a loud tone of voice in order to make myself understood. On examination, I found the right auditory canal perfectly dry. The drum-membrane presented a peculiar whitish, polished appearance. A circular perforation, with sharply cut, somewhat thickened edges, occupied the anterior superior quadrant. The entire posterior half of the membrane was in a perceptibly bulging condition and over its surface ran two or three dilated and sharply defined blood-vessels. When I tested this bulging portion with the probe I found that the drum-membrane was resting upon some solid substance. It felt more like a semi-solid substance (cheesy material, for example) than like bone. Anteriorly the drum-membrane yielded readily to the pressure of the probe. On the left side, I found a little thin, purulent secretion in the auditory canal. The

drum-membrane was in all essential respects like the right one. The only difference that I could discover was this: the perforation was slit-shaped and occupied the anterior inferior quadrant, close to the periphery of the membrane; whereas in the other ear it was circular and occupied the anterior superior quadrant, midway between the periphery and the handle of the hammer.

I expressed to the patient's physician the belief that cheesy material had accumulated in both middle ears, and said that I would like to make an incision through the bulging posterior half of one drum-membrane and endeavor to wash out the cheesy material; and if the operation proved successful, I should want to repeat it on the other ear. My proposition was explained to the patient, but he declined to submit to any such operative interference.

## II. PROLIFERATIVE CASES.

As the cases belonging to this second group are almost invariably characterized by either an abundant or an offensive discharge,—two symptoms which are annoying to the patient and which therefore lead him to seek relief,—they will be found to constitute, I think, the larger part of all the cases of otitis media purulenta chronica which come under the aurist's observation. The feature which distinguishes them from the cases that belong to the preceding class, consists in the proliferative tendency displayed by the inflamed mucous membrane. This proliferative process affords unmistakable evidence that the mucous membrane is being subjected to some unusual irritating influence. There are two ways, in which we can account for the existence of such an irritating influence. In the first place, decomposition may take place in the secretion and impart to it properties which are in the highest degree irritating. Under the influence of this irritation the mucous membrane begins to proliferate at one or more points, and so granulation-tissue, or a distinct polypoid growth representing an enormous hypertrophy of all the normal structures of the tympanic mucous membrane, may be developed. In other cases, however, the irritating influence may emanate from an entirely different source. Thus, for example, prolonged pressure, during the original acute attack, may have deprived the superficial portion of the bony wall of the tympanum, over a limited area, of its nourishing supply of blood, and thus have produced death both of the bone and of the mucous membrane immediately covering it. Such a caries of the bony wall of the tympanum supplies a secretion of a very irritating character, and, under the constant stimulus of this irritant, masses of granulation-tissue are formed in precisely the same manner as they are formed at the orifice of a sinus leading from the surface of the body to a spot of carious bone. When, therefore, we find granulation-tissue or polypoid growths in the middle ear or external auditory canal, we may feel perfectly sure that

a discharge of an irritating nature bathes these parts. Here, then, is furnished the first and most important indication of what is required in the way of treatment, viz., that in all cases belonging to this second class we should adopt every means at our command to keep each nook and corner of the middle ear and external auditory canal clean. If the irritating secretion owes its peculiar properties simply to the decomposition which always takes place in a stagnating animal secretion, systematic and thorough cleansing will often of itself, without other measures, produce the desired cure. If the irritating secretion, however, comes from a superficial bone-caries we can scarcely expect simple cleansing measures to produce as prompt and satisfactory results as in the proliferative cases which are not dependent on bone-caries.

Granulation-tissue may develop at any point in the cavities of the middle ear. Growths of this kind are found more rarely in the vicinity of the orifice of the Eustachian tube than in any other part of the tympanic cavity. Speaking again simply from memory, I should say that they develop more often at the posterior and upper portion of the tympanic cavity than at any other point. So far as their texture and size are concerned, they differ widely. Some are extremely vascular, while others are but poorly supplied with blood-vessels; some have almost the soft consistency of a myxoma, while others are as hard as the hardest fibroid growths; some are as small as the head of a pin, while aural polypi very commonly reach the size of a bean. I have one in my collection which measures an inch and three-fourths in length, and fully half an inch in diameter at its broadest point. It is not an uncommon experience to find the larger growths lobulated or branching.

So far as my experience goes, the great majority of polypoid growths encountered in the external auditory canal are of middle-ear origin. Furthermore, even the largest of these large polypoid growths will be found, as a rule, to possess remarkably small peduncles.

It would almost require a separate treatise to describe thoroughly the different pathological pictures that are presented by these proliferative cases of chronic purulent inflammation of the middle ear. Furthermore, the value of such an exhaustive description would be small in comparison with the labor that it would entail. I will describe, therefore, only a few instances of this proliferative variety.

CASE I.—The patient, a strong, healthy boy, seven years of age, was brought to me by his mother on the 3d of October, 1872. She stated that he had had a constant discharge from the right ear since early infancy. On examination, I found the meatus partially filled with pus. The membrana tympani had been totally destroyed. All that remained of the handle of the hammer was a mere stump, which projected into the cavity of the tympanum. The mucous membrane covering the promontory was much hy-

pertrophied, and at two or three points it presented small knobs of granulation-tissue. From the posterior and upper portion of the tympanic cavity a polypoid growth sprang. It was of moderate size, and its peduncle was comparatively small. By means of Blake's snare I removed this growth without any difficulty. To the stump and to the remaining smaller knobs on the promontory I applied powdered burned alum. My instructions to the mother were that she was not to syringe the ear with lukewarm water until the discharge reappeared,—my object being to keep the alum in contact with the granulating surfaces as long as possible.

Failing to arrest the discharge entirely by means of these applications of powdered burned alum, on the 15th of October I applied the liquor ferri subsulphatis, on a small pledget of cotton, to the base of the polypoid growth, and touched the granulating spots on the promontory in the same manner with a forty-five-grain solution of nitrate of silver.

On the 21st of October I applied powdered burned alum again, the discharge having in the meantime almost ceased.

On the 24th of October I found the parts perfectly dry and quite natural in appearance.

On the 19th of January, 1880, more than seven years later, I had an opportunity of examining the ear again. To my great surprise the drum-membrane had been almost entirely reproduced. Posteriorly and superiorly a small gap still remained, but everywhere else a very thin and very much depressed membrane separated the cavity of the tympanum from that of the external meatus. (See remarks on p. 273, with reference to the reproduction of the membrana tympani.)

CASE II.—The patient, a girl eight years of age, had been affected with a discharge from the left ear since early infancy, the discharge at times being stained with blood. On examination, October 29, 1873, I found the canal ulcerated, very much narrowed, especially in its deeper portion near the drum-membrane, and bathed with a rusty-colored secretion. The condition of the membrana tympani and middle ear could, at that time at least, only be inferred from the history of the case, and from the fact that during inflation air escaped freely from the external auditory canal. The slightest touch with the mop of cotton caused the ulcerated walls of the meatus to bleed. The treatment adopted was the following: at the Infirmary I cleansed and dried the canal as thoroughly as possible, and then applied nitrate of silver to the entire surface—the first time, a forty-five grain solution; on the 5th of November, the pure salt, in the form of a bead fused on the end of the cotton-holder; at her home the patient's ear was syringed regularly three or four times a day with lukewarm water. Under this plan of treatment the discharge—which undoubtedly came in large measure from the ulcerated walls of the meatus—diminished greatly in quantity and assumed the character of a moderately thick purulent secretion, free from

any admixture of blood. The swelling of the canal so far subsided that on the 8th of November I was able to make out the exact condition of the middle ear. The drum-membrane had been entirely destroyed. Two polypoid growths, having rather large peduncles, sprang from the posterior end of the tympanic cavity. Both of these were removed with the snare.

On the 19th and 26th of November I applied nitrate of silver to the bases of the growths recently removed, as they showed a strong disposition to grow again.

On the 29th I used the snare for the purpose of cutting down the knobs of granulation-tissue—the bases of the former polypoid growths—as nearly as possible to the level of the surrounding mucous membrane. I then touched the remaining raw surfaces lightly with chromic acid.

On the 3d of December I found the region which I had recently burned with chromic acid almost on a level with the surrounding mucous membrane. The discharge, too, had almost ceased. I accordingly applied powdered iodoform to the parts, and gave instructions that the syringing was to be discontinued.

On the 6th of December, the discharge having ceased and the parts appearing to be perfectly free from active irritation, I dismissed the case as no longer requiring treatment.

In the preceding case I would call especial attention to the swollen and ulcerated condition of the cutaneous walls of the external auditory canal. In infirmity practice this is not an uncommon lesion in cases of chronic purulent inflammation of the middle ear. It shows clearly that no attempts whatever have been made to keep the ear clean, or else that these efforts have not been skilfully conducted. In such cases our first attention should be directed to the restoration of the meatus to a healthy condition. Frequent and thorough douching or syringing of the ear at home, and the occasional application of nitrate of silver (pure, in the form of a bead) to the greater part of the swollen and ulcerated surface, by the physician, are the two things that will most rapidly restore the parts to a healthy state. When this has been accomplished, the treatment of the diseased middle ear can be undertaken intelligently and with good prospect of a successful issue.

I might mention here that in cases of chronic otorrhœa, living maggots, the larvæ of the ordinary house-fly, are occasionally found in the meatus or even in the tympanic cavity. I have only once or twice encountered them in the ear, but they have been seen more frequently by Gruber,<sup>1</sup> Blake,<sup>2</sup> and others. The explanation usually given is this: the fly, attracted by the offensive odor of the discharge, deposits her eggs in the meatus near

---

<sup>1</sup> *Monatsschrift für Ohrenheilkunde*, III. 3, March, 1869; III. 4, April, 1869.

<sup>2</sup> *Archives of Ophthalmology and Otology*, II. 2, p. 37.

the orifice ; and in this decomposing fluid the eggs find a soil suitable for their development into living larvæ.

In certain cases the proliferative process in the tympanic mucous membrane takes place in an ear which still possesses an almost entire membrana tympani. These cases are comparatively rare, and they are usually very difficult to manage. I should like very much to discuss here in detail this rare but very attractive combination of lesions, but I can only give the history of a single case, as the scope of the present treatise will not admit of the detailed discussion of a topic of such narrow limits.

The patient, a girl six years of age, was brought to me by her mother on the 17th of July, 1879. About five months previously, as I was told, she had passed through quite a severe attack of scarlet fever, which left her with a double otorrhœa. On examination I found the left drum-membrane destroyed, and the mucous membrane of the middle ear in a granulating condition. The hearing-power of this ear was still quite good. On the right side I found the inner end of the meatus filled with a soft polypoid growth, which concealed the deeper parts of the ear. By aid of the snare I removed the greater part of this polypus. I found that it sprang from some portion of the mucous membrane of the middle ear, and that its peduncle emerged through a circular perforation (about two millimetres in diameter) in the membrana tympani, just below the tip of the handle of the hammer, and then branched out into two distinct lobes, which together formed a mass about as large as a large pea. Assuming that the growth sprang from the upper portion of the tympanic cavity posteriorly, I gave the wire loop such an inclination to the silver canula that I was able to remove all visible portions of the polypoid growth. In other words, so far as I could see through the perforation into the cavity of the tympanum, every trace of the polypoid growth had been excised.

On the 4th of August, the patient having returned from the country, I examined the ear again, and found that a dry, cicatricial membrane had grown over the former opening in the drum-membrane. On touching this cicatricial portion, however, with the probe, I was surprised to find that it offered the same degree of resistance that one would expect to find in a moderately tough polypoid growth. No appreciable improvement had taken place in the hearing.

On the 6th of August, that is, about forty-eight hours later, I was astonished to find in the place of the cicatricial membrane a moist, succulent, but not granulating surface. My interpretation of this apparently sudden change was this : the slow growth of the intratympanic polypoid mass, and the unusually slight quantity of pus formed during the growing process, had allowed the perforation an opportunity to heal by the formation of a cicatricial membrane. Then the increasing pressure from within, exerted by the growing tumor upon the thin cicatricial membrane, had caused the two to unite into one continuous mass of tissue, and as a result of this

union the outer cicatricial portion had assumed some of the characteristics of granulation-tissue. Already on the 4th, when I examined the ear, the polypoid growth had reached the plane of the cicatricial membrane, and communicated to it that semi-solid condition which puzzled me not a little at the time; but it was not until the 6th that the union had become sufficiently intimate for the latter membrane to assume some of the characteristics of the deeper growth.

The child returned with her parents on the 6th to their home in Nebraska, and I did not see her again until the 5th of December, 1879. The discharge had reappeared in the right ear during this interval, and had become quite abundant. On examination I found that the appearances presented by the right membrana tympani had changed very materially. In the first place, the membrane as a whole had been drawn inward beyond the position which it had previously occupied. Quite low down anteriorly there was a very small perforation. Touching different parts of the membrane gently with the probe, I found that it offered solid resistance throughout the central portion; in other words, it had become amalgamated with the mucous membrane of the inner wall of the cavity. While at all other points the drum-membrane presented a pale and tough appearance, that portion which corresponded to the former cicatrix was of a pale purplish hue, and perhaps a trifle more concave than the surrounding portions. So far as I could ascertain, the Eustachian tube was impervious to air. For the purpose of arresting the discharge, I injected into the middle ear daily, for four or five days, a five-grain solution of nitrate of silver, by means of the middle-ear pipette. Under this plan of treatment the discharge ceased on the fourth or fifth day.

On the 15th of January, 1880, I found the right drum-membrane perfectly dry and free from any evidence of active irritation. A very minute perforation still remained in the anterior inferior quadrant. In front of the perforation, and also posteriorly near the periphery, the membrane seemed, when I pressed upon it with the end of the probe, to be free. All the intervening central portion, however, appeared to be solidly amalgamated with the mucous membrane of the opposite wall. As no discharge had made its appearance for several weeks, I allowed the patient to return home.

Sometimes the proliferative tendency restricts itself to the membrana tympani. In one case, for example, I made the diagnosis of a simple uncomplicated otitis media purulenta chronica, and treated the patient for weeks without success. Finally, one day noticed something of a pinkish hue just beyond (*i.e.*, on the inner side of) the edge of the small perforation, and, on closer investigation, found it to be a small polypoid growth which sprang from the inner aspect of the edge of the perforation. With some trouble I managed to get a fine wire loop around the growth and succeeded

in cutting it off close to the drum-membrane. The discharge, which had previously resisted every effort to arrest it, then stopped as if by magic. In this particular case I did—in a moment of desperation—what I would not advise others to do : I instilled a very strong solution of nitrate of silver (120 grains to the ounce) into the external auditory canal, and then forced it through the perforation and through the Eustachian tube. The operation was followed by severe pain in the ear and by nose-bleed. Both symptoms, however, lasted but a short time, and the discharge was reduced to a minimum for several days.

In a second case, in which the discharge was very slight, I found a sharply defined, pedunculate polypus growing from the edge of the rather small perforation and resting against the outer surface of the membrana tympani. The removal of the growth with the snare, which was of course effected very easily, caused the discharge to cease and a scab to form over the perforation. Fifteen days later I had an opportunity of examining the ear again, and found the scab still occupying the same position.

I might mention briefly in this connection certain peculiar lesions which I have encountered thus far only twice. I refer to the development of a granulating condition in an old cicatrix of the drum-membrane, without the re-establishment of a perforation. In the first case the patient, a laborer, twenty-six years of age, had been subject for a short time, about a year previously, to a discharge from the right ear. The discharge gradually diminished and finally ceased ; but at the time when I saw him (November 22, 1873) it had reappeared. On examination I found the right membrana tympani red, swollen, and smooth everywhere except over the greater portion of the posterior superior quadrant. Here the membrane presented a bright red and granulating surface, which bled upon the slightest touch. To this region I applied a forty-five-grain solution of nitrate of silver, by means of a cotton mop.

On the 29th of November I found that the granulating portion of the membrane had apparently become scabbed over. When I inflated the middle ear, the posterior superior quadrant of the membrane remained for a few moments in a markedly bulging condition, showing almost conclusively that no perforation existed at this point, and also that the membrane in this region had lost its *substantia propria*.

In the second case the ulcerated or granulating spot was circular in shape and occupied the central portion of the lower half of the membrane. In this case I resorted to inflation before the part had become scabbed over. The result was that the ulcerated portion alone responded visibly to the increased aërial pressure within the tympanum. It would seem, therefore, as if cicatrices of the drum-membrane were in a measure predisposed to ulcerative action.

We come now, finally, to the consideration of the measures that may be employed to advantage in removing polypi or masses of granulation-tissue



from the middle ear. Very few surgeons at the present day advocate the removal of aural polypi (*i.e.*, growths of an appreciable size) by any other than mechanical means. The slow, unsatisfactory, and sometimes painful plan of destroying them by caustics or astringents has been very generally abandoned. If a large polypus fills the external auditory canal and presents itself within easy reach at the outer orifice, an ordinary dressing-forceps, or better yet, Hinton's polypus-forceps, will serve the desired purpose as well as any other instrument with which I am acquainted. The mass is firmly grasped between the blades of the forceps, and is then separated from its deeper attachments by a combined rotary and pulling motion, or simply by direct traction. Farther on I will state under what circumstances traction is not to be employed. If the polypus, however, is situated more deeply in the canal, and reflected light is required to render the mass visible, such an instrument as Hinton's forceps—unless the canal happens to be unusually large—will be found awkward to manage and productive of pain to the patient. Blake's snare<sup>1</sup> is the proper instrument to use under these circumstances. By aid of the slender silver probe the

---

<sup>1</sup> This instrument, which was introduced by Dr. Clarence Blake, of Boston, in 1869 or 1870, is sometimes spoken of as "Blake's modification of Wilde's snare." Those, however, who have compared the two instruments, and know from practical experience how different they are from each other, will agree with me that the more recent instrument is justly entitled to the name of "Blake's snare." In 1872 or 1873 the instrument was still further improved by the substitution of a simple canula of soft (pure) silver for the double-mouthed steel or German-silver tube usually sold with the instrument. The pure silver canula measures three inches (8 ctm.) in length and but one millimetre in diameter (externally) throughout its entire length (except where it fits into the handle), while the steel or German-silver one measures two millimetres in diameter, and at the flaring end over two and a half millimetres. In cases where the external auditory canal is narrow, or where it is found necessary to remove a polypus which is situated within the tympanic cavity and which can only be reached through a comparatively small perforation in the membrana tympani, the great advantage of the slender silver canula is very apparent. But this is not the only advantage. In the double-mouthed canula the wire does not cut entirely through the polypus; a slender connecting cord of tissue always remains uncut between the wire and the septum which separates the two mouths of the canula. With this canula, therefore, the last step of the operation always consists in the tearing asunder of this connecting bridge of tissue,—a procedure necessarily more or less painful to the patient. In the simple silver canula the wire, on being withdrawn into the tube, cuts the polypus off entirely at the point of seizure, all necessity for traction being thus done away with. As a result of this, the operation of removing a polypus from the ear is in very many cases an almost painless procedure. Finally, the employment of very fine malleable steel wire (size=No. 37), may be designated as the latest improvement which has been introduced in connection with Blake's snare. Wire of this size possesses all the strength required for the removal of the great majority of polypi, and at the same time causes far less pain to the patient, whenever it comes in contact with the healthy and very sensitive walls of the auditory canal or of the middle ear, than does the heavier wire hitherto commonly employed.

physician can ascertain whether the mass grows from the cutaneous walls of the canal or from the middle ear or mastoid cells. Where the growth is of such size as to fill the canal, it is not necessary that he should satisfy himself of the exact situation of the base of the polypus before applying the loop of wire. It is sufficient for him to ascertain by actual probing that he can pass his snare over the mass to a given depth (distance from the orifice of the meatus) without encountering any obstacle. The loop is then pushed in over the mass to this depth and tightened sufficiently to hold the polypus firmly in its grasp. If the growth is succulent and not very firm, and especially if it can easily be rotated about its long axis, steady traction should be made, in the hope of pulling out the polypus, peduncle and all. In not a few cases this object will be attained; but even if the effort fail to remove the entire growth, at least as much of the mass will be torn off as would have been if the wire had been made to cut through the polypus instead of simply grasping it firmly. If the growth is firm in texture and not easily rotated, it is better to use the loop simply as a means

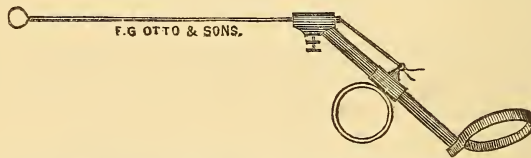


FIG. 19.—Blake's Polypus Snare. (About half the natural size.)

of cutting off portions of the growth. The same remark applies to the use of Hinton's polypus-forceps. Where the growth is firm in texture and firm in its deeper attachments, traction must not be employed. As soon as the bleeding has ceased, and the portion cut off by the wire loop has been removed with the bent forceps, the remainder of the growth is to be treated in precisely the same way as the first portion. The wire loop is to be applied again and again until the base of the growth has been cut away to the level of the surrounding mucous membrane or skin. If the polypoid mass springs from some portion of the external auditory canal, it will be found as a rule decidedly firmer in texture and more sensitive than one of middle-ear origin. It will also not possess the same degree of mobility as the latter. In polypi of middle-ear origin we shall find that they spring more frequently from the upper and posterior portion of the tympanum (entrance to the antrum) than from any other locality.

*It is a good rule in practice not to resort to the use of caustics until the base or peduncle of the polypus has been cut away with the snare to the level of the surrounding parts (skin or mucous membrane). Furthermore, in deciding whether the peduncle has been cut away to the proper level, we are not to trust to the sense of sight alone; the behavior of the peduncle, when circumscribed by the end of the probe, furnishes the only trustworthy guide to a knowl-*

*edge of the exact relations which this peduncle bears to the surrounding parts.* When the mass has been so far extirpated that we cannot encircle it with a wire, we may, with benefit to the patient, resort to the use of caustics and astringents.

Before speaking, however, of the after-treatment, it would perhaps be well to consider for a moment the dangers, real or apparent, which surround the operative procedure just described.

As regards *hemorrhage* from the torn or cut surface of the mass, we need entertain very little anxiety. In malignant growths alone have I ever seen or heard of any loss of blood that could fairly be termed serious; and only once have I encountered anything like an arterial hemorrhage, requiring the use of a tampon or plug.

As regards the question of inflicting damage upon the apparatus of hearing in the middle ear, I have no doubt that clumsy and unskilful operative interference may result in serious impairment of the hearing. The hammer, however, and the firm ridge in front of and behind Shrapnell's membrane, afford an excellent protection to the more deeply situated stirrup, which is by far the most important piece in the mechanism of the middle ear. Polypi are occasionally encountered whose peduncles include in their substance the handle of the hammer (the rest of the membrana tympani being destroyed). In such cases the wire should be applied with caution, and no traction whatever should be employed. The few polypi of this kind which have come under my observation were quite small, and were attached to the ossicle by rather slender peduncles. In one of them, however, I made the very mistake which I am now cautioning against (*i.e.*, I applied the wire to that portion of the peduncle which included the handle of the hammer), and only discovered my error by finding that the wire loop could not be drawn back into the canula. By cutting the wire loose from the instrument and pulling upon one end of it, no difficulty was experienced in disengaging it from the ossicle.

Besides hemorrhage from divided vessels and injuries to the ossicles, I know of no other danger which may arise in the course of the operation for removing an aural polypus.

As regards the *after-treatment*, this must be modified according to the location from which the growth springs. If the polypus grows from the cartilaginous portion of the outer canal (as a result, for instance, of an abscess in this locality), and is firm in consistency, the application of nitrate of silver in solid form to the base which remains after the removal of the fleshy mass, will act rather as a stimulant to further growth. Fuming nitric acid, applied cautiously but thoroughly to the base, is the only remedy upon which we can depend to arrest promptly a further reproduction of the growth. As the fumes of the acid are apt to prevent the operator from seeing clearly what he is doing, an instrument called a "porte-acid" has been devised, which enables the physician not only to apply the

acid accurately to the desired spot, but also to confine its action in great measure to the region immediately cauterized. This instrument consists of a slender glass tube (about ten centimetres in length, not quite two millimetres broad, and somewhat flaring at both ends), through which a platinum wire of moderately small size passes. One end of the wire is bent upon itself, so as to prevent the mop of cotton-wool, which is wound round it, from falling off. When the instrument is to be used, the wire should be first pushed into the tube far enough to carry the mop end of the wire well outside of the flaring end of the tube. The mop having been dipped into the acid, the other end of the wire is then to be pulled out far enough to draw the mop well back into the flaring mouth of the tube. The base of the growth having first been thoroughly dried, the flaring end of the tube should be placed firmly upon the raw surface, and, while it is in this position, the mop should be pushed down firmly for an instant against the part to be cauterized. The reaction which follows is very slight, and the pain is of but short duration. The best way to remove the mop from the platinum wire is to burn it off in the gas flame.

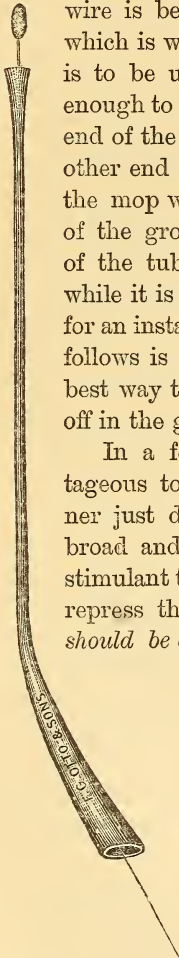


FIG. 20.—Glass "porte-acid" with platinum cotton-holder passing through its interior. (Natural size.)

In a few cases of middle-ear polypi, it will be found advantageous to apply nitric acid to the base of the growth in the manner just described. Where the base, for example, is unusually broad and firm in texture, nitrate of silver is apt to act rather as a stimulant to further growth, while nitric acid will much more surely repress the tendency to grow. In these cases, however, *the acid should be applied with great caution.* The firm pressure which it is perfectly proper to use in the case of growths in the external auditory canal, would here be likely to produce a very unpleasant reaction. As regards the employment of such reagents as chromic acid, acid nitrate of mercury, acetic acid, sulphate of copper, etc., for the purpose of checking the growth of granulation-tissue or polypi, my own experience has led me to abandon them all. Acid nitrate of mercury is a very treacherous remedy; it seems to penetrate to a much greater depth than nitrate of silver, or even nitric acid, and is apt to be followed by considerable pain. Chromic acid, in my experience, is also rather treacherous. As I have used it only in a crystalline state, however, it is not unlikely that my prejudice against this much-praised caustic is ill-founded. It should be used only in a fluid state. Absolute alcohol cannot be used properly unless it be made at the same time to bathe all the surrounding healthy tissues. Its effects seem to be superficial and evanescent. In the great majority of cases, pure nitrate of silver, fused upon the

end of a cotton-holder or probe in the form of a rounded bead, will be found the most convenient, most efficient, and least painful of all the caustics. Each application should be followed by the mopping process with the cotton-holder, in order that the caustic may not spread beyond the limits of the diseased locality.

Oftentimes a single cauterization will suffice to complete the levelling process begun by the wire snare. In a few cases the snare will be found to have done its work so effectually that the intermediate stage of the treatment—that of cauterization—may be omitted altogether. It should be clearly kept in mind that the caustic is to be used for the express purpose of destroying the superficial portions of the stump of the growth, in order to bring it down to such a level that the surrounding healthy mucous membrane may grow out from all sides over the mass, and so furnish it with a natural covering of mucous membrane.

That nitrate of silver also exerts a beneficial astringent action,—that it sometimes seems to restrain in a most remarkable manner the tendency to the production of lymphoid elements (pus- or tissue-forming cells), cannot be denied by any one who is in the habit of using it much. In a large number of cases, however, it produces the very opposite effects. Hence the desirability of resorting as soon as possible to the use of pure astringents.

The third and last stage of the treatment consists in the application of astringents to the remaining stump of the growth. The parts are to be thoroughly dried with the mop of absorbent cotton, and then powdered burned alum or iodoform (or a mixture of the two) is to be laid upon the dried surface freely but not too thickly. By moistening the end of the slender silver probe and then dipping it into the powder, one can readily take up quite a large mass, which will cling to the end of the probe with sufficient tenacity to enable the physician to transfer it to the desired spot in the middle ear or outer canal. These pellets of powder are to be applied again and again, until the granulating surface is well coated with the remedy. In a few cases I have observed that iodoform (finely powdered) has been able to completely arrest all further growth and all secretion of pus, when the alum had failed to accomplish the desired result. In my hands the iron and tannin preparations have not proved so efficient as the two remedies just mentioned.

If all these efforts fail to arrest the otorrhœa, we may safely draw the conclusion that a carious condition of some portion of the temporal bone (the posterior end of the tympanic cavity, in the majority of the cases), or an undiscovered granulation-growth is the source of the continued discharge. In regard to hidden growths, our best course is to abandon all active treatment and to simply examine the ear at longer intervals (say once in three or four months). After a varying length of time the growth may attain such a size as to encroach upon some visible part of the ear, when it will readily be discovered if the physician examines carefully.

Finally, in a limited number of cases, the external auditory canal is so narrow, or the anterior or lower wall so prominent, that we cannot obtain a view of the spot from which the polypus springs, although the greater part of the growth can readily be distinguished and easily removed. In these cases we are quite likely to experience defeat, so far as the attainment of a perfect cure is concerned ; but the removal of the greater part of the mass will, as a rule, greatly diminish the otorrhœa, and oftentimes also improve the hearing, for a period of several weeks or even months.

If I have said nothing about the removal of polypoid growths by means of the galvano-cautery wire, it is simply because I cannot see what advantage is to be gained by the use of this instrument. Blake's snare fully meets all the requirements of the case, and in the matter of simplicity and cheapness it is far superior to the complicated galvano-cautery.

*Foreign bodies in the middle ear.*—As my only experience with this rare condition relates to a case of chronic purulent inflammation of the middle ear, of the proliferative variety, I may with propriety give a detailed account of it in this place. The patient, a lady about sixty years of age, consulted me on the 24th of March, 1879, for a painful affection of the right ear. According to her statement, she had had a slight discharge from the right ear all her life. About the first of March of that year she noticed that her hearing was more dull than usual, and, at the suggestion of a friend, she consulted a physician. He gave her very little encouragement, but said that she might experience some relief by wearing an artificial drum-membrane, and, with her permission, he introduced one into her ear. As this artificial membrane, however, did not improve her hearing, but, instead, caused her considerable discomfort, he undertook to remove it. Although he failed, as will be seen, to accomplish his object, he in a measure satisfied the patient that the membrane had been removed. From that time forward the ear had grown more and more painful, and she had latterly experienced considerable pain throughout the entire right side of the head. At the time when I saw her she presented the appearance of a person who had passed through a prolonged period of suffering. On examination I found the inner half of the canal filled with a soft polypoid mass, bathed with moderately thick pus. I removed the growth with the snare and found that it sprang from the edge of a moderately large perforation in the drum-membrane. In the centre of the opening I noticed something of a peculiar grayish white color, and on touching it with the probe I discovered that it consisted of some hard material which was firmly lodged in the cavity of the tympanum. By aid of the slender angular forceps I succeeded in extracting this foreign body, which proved to be a rather thick disk of whitish rubber, in the central portion of which was a small hole for the reception of a thread. This circular piece of rubber was of almost precisely the same size and shape as the normal drum-membrane.

After this foreign body had been removed from the middle ear the pain soon disappeared entirely, the discharge became again insignificant, and when I examined the ear, after the lapse of about ten days, I found a perfectly smooth and unirritated drum-membrane, in the centre of which was a circular perforation not more than three millimetres in diameter. No further treatment was advised.

It is difficult to understand how any physician, possessed of his senses, could have deliberately done such a foolish thing as to force a comparatively large disk of rather stiff rubber through an opening in the drum-membrane scarcely three millimetres in diameter. And yet the condition in which I found the ear showed very clearly that the rubber disk had been placed deliberately in the situation where I found it.<sup>1</sup>

### III. CASES IN WHICH THE BONE IS INVOLVED.

The pathology of these cases is often difficult to determine. Imprisonment of the pus during the original acute attack is probably, in very many cases, the cause of the carious process in the bone. The imprisoned pus subjects the mucous membrane of the middle ear to great and prolonged pressure, and, as a consequence of the resulting interruption in the circulation, death may take place at one or more points in the membrane. As the mucous membrane, however, is also at the same time a periosteum or nourishing membrane of the bone, the superficial portions of the latter at the points mentioned are also apt to die. This explanation will perhaps often suffice for those limited spots of caries which are so frequently found in the middle ear, but it will scarcely account for the extensive areas of necrosis which are sometimes encountered. In such cases we must assume that other processes, perhaps embolic in their nature,<sup>2</sup> have contributed chiefly to the production of the result in question. Schwartze, in his "Treatise on the Pathological Anatomy of the Ear," mentions the extension of a simple ulcerative process from the mucous membrane to the subjacent bone as one of the common ways in which caries of the middle ear is produced. In the more serious cases, however, of caries or necrosis of some portion of the temporal bone, it will almost invariably be found that retention of pus, and especially of cheesy and decomposing pus, in the tympanum proper or in the mastoid antrum, is in some way connected with the disease of the bone. This danger lurks in every case of chronic purulent inflammation of the

---

<sup>1</sup> For other instances of the presence of a foreign body in the middle ear see: Noyes, Transactions of the Amer. Otol. Society, 1870; Israel, Berlin. klin. Wochenschrift, 1876, No. 15; Voltolini, Monatschrift für Ohrenheilkunde, May and June, 1876; Schalle, Berlin. klin. Woch. No. 31, 1877; Voltolini, Monats. f. Ohrenh., Aug. 1878.

<sup>2</sup> See Trautmann: Archiv für Ohrenheilkunde, XIV. p. 73.

middle ear, and is particularly to be dreaded in those cases that are characterized by a small perforation in the drum-membrane, or by one located in Shrapnell's membrane.

The cases that belong in this third subdivision may readily be divided into several smaller groups, in accordance with the differences in the parts involved, in the symptoms manifested, in the issue of the disease, etc.

1. *Superficial caries, with unobstructed outlet for the discharge.*—In cases of the proliferative variety it is a very common experience to find, in the immediate neighborhood of the mass of granulations, or at the base of the polypoid growth, a spot of exposed and roughened bone. The favorite situations for such spots of bone-caries are the posterior wall of the tympanum, just below the entrance to the antrum, the bony floor of the tympanum, near the posterior end of the cavity, and the ridge of bone separating the middle ear from the external auditory canal. In two cases I found the mucous membrane of the promontory very much thickened (the drum-membrane had been totally destroyed), and on manipulating it with the probe I discovered that, below, it was not continuous with the mucous membrane covering the floor of the tympanum, but ended in a thickened and rounded edge, which could be lifted up like a hanging curtain. The end of the probe, passed beneath the edge of this fleshy curtain, encountered quite an extensive surface of denuded but smooth bone.

In cases that belong to the present group I am not in the habit of modifying my mode of treatment materially. The plan suggested by some authorities, of subjecting the bone at these spots to a thorough scraping with some sharp instrument, does not commend itself at present to my judgment. The principle is undoubtedly sound, but the application of it to a carious spot of unknown depth and extent does not appear to me to be safely practicable. The removal of the granulation-tissue or polypus, as the case may be, the careful daily cleansing of the ear with lukewarm water (with or without the addition of boracic acid), and the judicious application of caustics or astringents to the proliferating mucous membrane, will be found to produce fairly satisfactory results. So long as the outlet is sufficiently free—as it is in cases where the perforation in the drum-membrane is large, or where the membrane is entirely destroyed—this group may be considered as identical, in all essential particulars, with that of the proliferative cases.

2. *Caries with more or less obstructed outlet for the discharge.*—Cases belonging to this group are not very numerous, but they furnish a large proportion of the deaths from ear disease. In the present section, however, I propose to consider only the more favorable cases belonging to the group. It is in these alone that we can study quietly the ordinary course of this serious form of disease of the ear. The early stages of the malady can only be inferred from the lesions observed at some latter stage of its course. The whole picture, however, points clearly to the lack of proper treatment



during the early stages of the acute attack. I will give the details of one or two well-marked cases :

CASE I.—The patient, a strongly built man, thirty-eight years of age, consulted me on the 15th of May, 1874, on account of a very offensive odor which came from his left ear. He stated that he had had scarlet fever during childhood, and that from that time forward, with occasional short intermissions, he had been troubled with a scanty but offensive discharge from the left ear. Inspection revealed the existence of two perforations : one situated in the posterior fold, involving a little of the drum-membrane proper ; the other involving only the anterior fold and part of the bony ridge above it. Both perforations partook rather of the nature of fistulous tracks communicating with some more deeply situated centre of disease, than of that of simple perforations. In other respects the membrana tympani was a fairly healthy, though much thickened membrane. A little dark-colored and very offensive secretion was found in the neighborhood of the fistulous openings, but elsewhere the parts were quite clean and dry. The edges of the posterior opening were in a slightly granulating state. As there was no evidence of active local irritation, I advised the patient to douche the affected ear very gently about three times a week, simply for the purpose of removing the foul discharge from the meatus.

On the 30th of March, 1875, the patient came to see me again. He had experienced considerable pain in the left ear during the previous three days. I examined the ear and found the soft parts surrounding the anterior opening red and swollen, and the orifice of the sinus obliterated. Treatment : two leeches to be applied to the tragus, and the ear to be frequently douched with warm water.

These measures relieved the pain, and the patient was then not seen again until September 9, 1876. He had for a short time previously suffered considerably from dizziness, and the discharge from the ear had increased in quantity. On examination I found the inner end of the meatus occupied by quite a large, two-lobed polypoid growth. I removed it with the wire loop, and found that its peduncle occupied the posterior fistulous opening.

On the 13th I removed a portion of the peduncle with the snare, carrying my wire loop a short distance into the fistulous opening.

On the 16th I succeeded in passing the wire-loop deep down into the fistula, and in cutting off the peduncle at a point probably very close to its actual base. With the porte-acid I then made an instantaneous application of nitric acid to the remaining stump at the bottom of the fistula.

On the 18th I noticed for the first time that a small knob of granulation-tissue, about the size of a No. 3 shot, protruded from the orifice of the anterior opening. By passing the wire loop over the mass and as far into the sinus as possible, I succeeded in removing probably the greater part of the

growth. I also applied nitric acid to the base of this second growth. The pain following these applications of undiluted nitric acid was insignificant and of only short duration.

On the 20th, and again on the 22d, I succeeded, with Blake's snare, in removing masses of granulation-tissue from the bottom of the posterior sinus. I also discovered that exposed and roughened bone could be reached with the probe in the vicinity of the entrance to the antrum.

On the 25th the patient reported that the discharge from the ear had nearly ceased, and that he was completely relieved of his distressing dizziness.

On the 2d of October I was again obliged to employ the snare in both openings. On the 4th I could discover no trace of granulation-tissue in either fistula. I therefore introduced into them pellets of powdered burned alum. On the 7th and 10th I repeated the applications of burned alum, and then dismissed the patient, as the discharge had practically ceased. I advised him, however, to use the douche faithfully at least three times a week.

On the 4th of January, 1877, he reported that a very slight discharge had persisted since his last visit. On examination I found a small mass of granulation-tissue at each of the two orifices. I used the snare in the same manner as on previous occasions, and then introduced powdered iodoform into the openings.

From this time forward, patient remained almost free from discharge until shortly before the 14th of July, 1879, when I was obliged again to use the wire snare. (From that time to the present [September, 1880] I have not seen the patient.)

CASE II.—The patient, a merchant, thirty years of age and in good general health, consulted me on the 21st of October, 1878, for an offensive discharge from the left ear. He stated that about four months previously he had experienced severe pain in that ear, and that after the lapse of a few days a discharge had made its appearance and had continued steadily since. At times the discharge had been tinged with blood. On examination I found the left auditory canal noticeably smaller than the right. It contained a moderate amount of brownish, offensive secretion. The membrana tympani was very opaque, but smooth, uninfamed, and possessing, apparently, the normal degree of curvature. Just above and in front of the short process of the hammer there was a small excavation, filled with a dark-colored cheesy material. The tissues immediately surrounding it were red and somewhat swollen. By means of a curved probe I ascertained that this excavation was in reality the outer orifice of a sinus which led inward and a little upward, probably to the upper part of the tympanic cavity. From the appearance of the membrana tympani at that time, and from the subsequent course of the disease, I suspect that the cavity which supplied the pus was

shut off from the general cavity of the middle ear by a partition of adventitious tissue or by the prolapsed and thickened mucous membrane belonging to the upper wall of the tympanum. For a short time I made the attempt (by thoroughly cleansing the sinus and by the application of caustics and astringents) to diminish the quantity and the offensiveness of the discharge, but I failed to accomplish this object.

On the 27th of October, 1879, I was sent for by the patient, as he was too ill to leave his bed. He was in considerable suffering, and stated that the pain in the left ear had developed three days previously, and had steadily increased in severity up to that time. Leeches had been applied by his regular medical attendant, but they had afforded only temporary relief. I examined the ear and found that a red, conical swelling occupied the situation of the former excavation, and that from a small opening in the apex of this swelling pus was escaping. Believing that the patient's suffering was largely due to the inadequateness of the outlet for the pus, I made a free incision through the centre of the conical swelling.

I was not sent for again until the 5th of November. The patient then stated that the operation had relieved the severe pain, and had rendered the discharge quite active, but that every day, and especially toward night, he had experienced a dull pain throughout the entire left side of the head. He had also been very much annoyed by dizziness. On examination I found the inner end of the meatus filled with a large, succulent polypoid mass. I removed it with the snare, and found that it grew from the region of the former excavation. I also found, on probing the sinus, that it contained a small fragment of exfoliated bone. On withdrawing the probe I brought to the orifice of the sinus some white cheesy material.

The removal of the polypoid growth afforded considerable relief for a short time, but on the 29th of November he came to see me again, as the pain was steadily increasing. To my surprise, I found the external auditory canal almost filled with a polypoid growth. I removed it thoroughly with the snare.

On the 20th of December I found the condition of the ear materially changed. The polypoid growth had not reappeared, but equivalent changes had taken place in the cavity of the tympanum. The drum-membrane appeared to have become amalgamated with an intratympanic growth, which had already attained such dimensions that the visible background, at the bottom of the meatus, appeared like a solid, rounded mass of flesh. There was nothing in the appearance of the mass to remind one that its outer portion, at least, consisted of the membrana tympani. At one spot, near the floor of the canal, this otherwise tough-looking mass appeared to be granulating, and on pressing my probe against the spot it passed readily inward to a distance of about one-third of an inch. The dizziness and pain still persisted, and the patient was unable to attend to business.

On the 10th of January, 1880, I removed with the snare a rather large

polypoid mass which sprang by a slender peduncle from the lower part of the drum-membrane. Since the 20th of December a very noticeable change had taken place in the condition of these deeper parts. The membrana tympani still occupied an unnatural position, but it was evident that the intratympanic growth had diminished very decidedly in size, as the membrane then protruded only to a moderate degree.

On the 10th of February the patient reported that he was almost entirely free from dizziness and pain in the head, and that the discharge had greatly diminished in quantity. On examination, I found everything restored to the state in which I had found the ear in October, 1878. The drum-membrane was entire and occupied a very nearly natural position; no granulating surface was anywhere to be seen; in a word, the only difference that I could discover was a slight enlargement of the orifice of the sinus—and of this, even, I could not be positively certain.

The preceding cases suggest two points with regard to which I should perhaps say a word or two. In the first place, in both of these cases marked dizziness was a prominent symptom, and in both it seemed to depend upon increased intratympanic pressure. In these cases, therefore, of caries with obstructed outlet for the pus, we should make use of this symptom as a measure of the degree of obstruction that exists, and as an indication that we should interfere for the purpose of re-establishing a free outlet. In the second place, the obstacles that stand in the way of a successful treatment of this pathological condition are very great. As a rule, we are obliged to rest satisfied with only partial success.<sup>1</sup>

3. *Extensive caries or necrosis of the temporal bone.*—The few cases of this nature that I have seen, came under my observation for the first time only after the damage had been done. I am therefore unable to throw any light upon their pathology, but can simply record the nature and extent of the damage found at the time of my examination. Thus, for example, in the case of a boy, seventeen years of age, I found all that part of the squamous portion of the temporal bone, which separates the upper part of the tympanic cavity from the external auditory canal, destroyed. The anterior and posterior folds were still intact, and so was the drum-membrane proper. The head of the hammer, however, with the exception of only its extreme upper portion, stood out prominently in the centre of the irregularly shaped excavation. In a second case the anterior and posterior folds formed the dividing ridge between two *culs de sacs*,—the upper one being formed by a carious excavation in the bone situated in front of the head and neck of

---

<sup>1</sup> For further information with regard to these perforations in the region of Shrapnell's membrane, consult the articles by Blake and Burnett, in the Transactions of the American Otological Society for 1874; and one by Miller, in the volume for 1878.

the hammer, the lower one consisting of the exposed cavity of the tympanum. In a third case the membrana tympani, the hammer and anvil, the anterior and posterior folds, and a large part of the bone situated above the drum-membrane, had all been destroyed. The appearance presented to the eye of the observer was as if the external meatus terminated in quite a cavern. Notwithstanding this extensive destruction of the parts, the hearing-power of that ear remained fairly good. In a fourth case I extracted quite a large mass of bone from the external auditory canal, and, on examining it, I found it to consist of the larger part of the cell-structure of the mastoid process. I have never seen a case of necrosis and casting-off of the labyrinthine portions of the petrous bone, but many such have been reported.<sup>1</sup> There is even a case on record<sup>2</sup> where almost the entire temporal bone was cast off, as the result of necrosis.

4. *Desquamative processes.*—Under ordinary circumstances the inflamed mucous membrane of the middle ear casts off pus, muco-pus, or a simple serous fluid. Under certain conditions, however, it casts off, in addition to these elements, layer upon layer of flattened or pavement epithelium. These layers, as a rule, are not floated out of the ear with the fluid portions of the products of inflammation, but show a disposition to adhere to each other and to the subjacent living tissues, thus forming laminated masses of epithelium which sometimes attain very large proportions. The laws governing the development of this desquamative process are not known. It is very commonly found associated with carious processes in the tympanum, mastoid antrum, or mastoid cells, but it is not always clear whether the irritating effects of the caries have called forth the desquamative process, or whether the pressure of the constantly growing mass of cast-off epithelium has produced the caries. In exceptional cases we may encounter such laminated masses of epithelium in a middle ear which presents no evidence of being the seat of a carious process. Thus, for example, in February, 1878, I was consulted by a gentleman, who stated that since boyhood he had been affected with occasional, but very slight discharge from both ears. On examination I found in the left ear a fistulous opening in the anterior fold, and a small perforation in the posterior inferior quadrant. In the right ear I found a little watery secretion in the meatus, and an opaque and tough-looking membrana tympani, which at first sight appeared to be entire. On more careful inspection, however, I discovered a linear, slit-shaped perforation, perhaps two millimetres in length, running parallel

<sup>1</sup> For instance, by Toynbee, by Schwartze (A. f. O. IX., p. 238), by Dennert (op. cit., X., p. 231 and XIII., p. 19), by Lucæ (ibidem, p. 236), by Agnew (American Med. Times, Vol. VI., No 16), by Pomeroy (Transactions of the American Otological Society, 1872), and by Spencer (Transactions Missouri Medical Association, 1875).

<sup>2</sup> Dr. J. Gottstein: Archiv für Ohrenheilkunde, XVI. Bd., Erstes and Zweites Heft.

with and close to the posterior periphery of the membrane. When the patient performed Valsalva's experiment, the entire drum-membrane yielded to the pressure from within, just as an unbroken membrane would. From this behavior of the membrane I inferred that either a mass of mucus or a polypoid growth, acting like a valve, prevented the air from escaping through the perforation. I accordingly enlarged the opening in the membrana tympani by making two incisions, one at each end of the perforation and at right angles to it. By these incisions I converted one lip of the opening into a rectangular flap, and so secured a broad outlet. Inflation by Politzer's method was then resorted to, and as a result a whitish mass, three-eighths of an inch long, two-eighths of an inch broad, and about one millimetre in thickness, was driven out into the external auditory canal. Under the microscope small fragments of this mass were found to consist solely of flattened epithelium (non-nucleated). The removal of this large mass from the cavity of the tympanum gave the patient marked relief from an annoying sense of fulness in the ear, and also materially improved his hearing, but did not arrest the discharge. The patient remained under observation for about four days, and was then obliged to return to his home in Ohio.

It is a more common experience to find the laminated mass of epithelium filling the cavity of the tympanum, or at least its upper portion, as in the following case :

CASE I.—The patient, a lady about thirty years of age, consulted me on the 23d of November, 1878, for a painful affection of the left ear. According to her story she had had a discharge from this ear since girlhood, though not constantly. Recently, however, the discharge had become quite active, and she had suffered from a steady, dull pain, which seemed to be most acute in the neighborhood of the mastoid process. Her head had also felt heavy and full. After removing two polypoid growths, which obscured the view of the deeper parts, I discovered that quite a large mass of tough, laminated epithelium filled the entire cavity of the tympanum. By dissecting the edges carefully I was able to loosen it and remove it as a single tough, leathery mass. A considerable portion of the bony ridge situated just above the drum-membrane had been destroyed, and the larger part of the epithelial plug was located in the excavation which remained. The polypoid growths sprang from the outer margin of this same excavation. The relief which the removal of this tightly fitting mass afforded the patient was apparently very great.

On the 27th of December, the patient returned to the city and reported that she had carried out my instructions (simply to douche the ear daily with lukewarm water) faithfully, and that as a result the discharge had ceased entirely since the middle of the month. The pain and sense of discomfort in the head had also entirely disappeared. I examined the ear and

found the parts perfectly clean and pale, with no signs at any point of a tendency to develop granulation-tissue.

The preceding case may be taken as a fair type of these not very rare cases. If one can judge correctly from the published reports of many of the best authorities, the mastoid antrum is the most frequent starting-point of such desquamative processes.<sup>1</sup> Marked variations from the type described above, however, are occasionally encountered. As an instance of such an exceptional course of the disease, I will narrate the following case :

CASE II.—The patient, a strong, healthy man, twenty-five years of age, had been subject to frequent earaches and to an occasional discharge from both ears since childhood. During the last three weeks of September, 1875, he had experienced constant pain in the left ear. When I examined his ear on the 1st of October, 1875, I found the external auditory canal blocked with a red, fleshy mass, which sprang from the upper wall of the canal. The most prominent portion, which looked like ordinary granulation-tissue, was removed with the snare, and then it was ascertained that the fleshy mass which blocked the entrance of the external auditory canal was really the prolapsed upper cutaneous wall, in which an opening had established itself. A probe introduced into this opening could readily be passed in a distance of fully three-fifths of an inch, without encountering at any point denuded bone. Considerable cheesy and very foul pus was removed from the contracted meatus, but no view could be obtained of the deeper parts, owing to the fact that the prolapse of the upper cutaneous wall of the canal extended inward as far, apparently, as to the immediate vicinity of the membrana tympani. As this prolapsed portion could not be lifted back to its natural position, it was evident that some substance (cheesy pus, as I supposed) had accumulated between it and the bony wall. For its removal I adapted a slender nozzle (diam.  $1\frac{1}{2}$  mm.) to an ordinary hard-rubber ear-syringe, interposing between it and the nozzle of the syringe a short bit of rubber tubing. This slender nozzle was introduced without any difficulty into the mouth of the sinus, and upon forcing in the warm water it was found that the greater part of it returned by the side of the nozzle, while the rest made its way through the sinus into the deeper parts of the ear, whence it escaped through the meatus proper. This procedure caused the patient not a little pain, and consequently could be repeated only a few times at a sitting. The first time (October 2d) almost nothing was brought away by the syringing, but on subsequent days the

---

<sup>1</sup> Consult Von Troeltsch (*Arch. f. Ohr.*, IV., p. 105), Toynbee (*Medico-chirurg. Trans.*, Vol. XLV.), Lucae (*A. f. O.*, VII., p. 255), Duncanson (*Edinb. Med. Jour.*, Nov., 1877), Matthewson (*Trans. Amer. Otol. Soc.*, 1878), Moos (*Archives of Ophthal. and Otol.*, III., No. 2), and Kipp (*Archives of Ophthal. and Otol.*).

stream of water regularly brought away fragments of epithelial laminae of the most perfect whiteness. The bent forceps was also frequently used in dislodging the larger masses, which were too large to pass through the orifice of the sinus except with the aid of some tractile force. On October 10th (the syringe having been used daily in the meantime) the last fragment was dislodged. The total amount of epithelium removed was sufficient to fill a two-drachm bottle (no force being used to pack the substance into small compass). A microscopic examination revealed the presence of a few crystals of cholesterine in addition to the lamellae of large, polygonal, perfectly transparent, sharply outlined epithelial cells. From day to day, as the accumulation of epithelium became reduced in quantity, the calibre of the external auditory canal grew steadily larger, until, on the 11th of October, I was able to ascertain quite accurately by inspection the condition of the middle ear and deeper portion of the meatus. There was at the same time a very perceptible improvement in the hearing. After the last mass of epithelium had been removed, the probe introduced into the sinus encountered roughened bone surface at the point where the posterior wall of the meatus becomes the outer surface of the mastoid process. Farther inward, however, the end of the probe passed over a series of small, smooth hummocks, which conveyed to my mind the impression of being the exposed septa of the mastoid cells (the solid bone composing the posterior and upper wall of the meatus having been destroyed by caries,—or possibly by pressure). At the farther end of the sinus, and encroaching slightly upon the posterior fold, was a second opening (in the cutaneous wall), which communicated with the inner end of the meatus, and was fringed like the outer one with granulation-tissue. Upon the removal of the granulations with the snare, the membrana tympani could be seen. It was still entire, but amalgamated at almost every point with the tissues of the inner wall of the tympanum. In the posterior upper portion, and in one or two places below, the membrane was still free. There was no swelling or tenderness over the left mastoid process.

As the patient died soon afterward (November 1st) at his home in Canada, from the results of long-standing disease in the right ear (an account of which would here be out of place), I am unable to add further details regarding the complicated condition observed in the left ear.

It is not easy to build up any theory that will satisfactorily explain all the aspects of this unusual case. Originally there was probably a severe inflammation of the middle ear, which, not finding a free escape for its products through the membrana tympani,—that membrane probably being more resistant than usual,—extended to the antrum and adjacent cells. From this resulted in course of time a caries of that portion of the mastoid process which forms the posterior and upper wall of the external auditory canal. A fistulous opening then established itself in the cutaneous wall of the canal, and, as it was of small size and probably from time to time became



closed for a short time, the accumulating pus from the carious region must have dissected a way for itself in the direction of least resistance, that is, inward toward the posterior fold. At this point, too, the cutaneous wall is thinnest, and here it was that a second opening established itself. As the mastoid cells were found to be exposed over quite an extent, without at the same time being carious, a condition which I will not venture to explain, it is fair to assume that the immense mass of epithelium found in this situation must have been cast off from the mucous membrane lining these cells, cheesy and foul pus having originally supplied the necessary irritating stimulus.

5. *Extension of the ulcerative process to neighboring organs.*—If we leave out of consideration for the present those cases in which the brain and its membranes and the lateral sinus are invaded by the disease, there still remain those cases in which the chorda tympani nerve, the facial nerve, and the carotid artery become affected. With the exception of a few cases of facial paralysis, the various conditions which I have just enumerated have never come under my immediate observation, and I am therefore unable to give any information based upon personal experience. Cases of fatal hemorrhage from the carotid artery, dependent upon caries of the temporal bone, will be found in Marcé's monograph on this subject.<sup>1</sup> The only instance that I can recall of an affection of the chorda tympani nerve, occurring in the course of a chronic purulent inflammation of the middle ear, is that reported by Noyes.<sup>2</sup>

6. *Cyst-like tumors of the drum-membrane.*—I can find in my records but six cases of well-defined cysts of the membrana tympani. In four of them there had previously existed a purulent inflammation of the middle ear. In one of these four cases, which I reported in detail in 1872,<sup>3</sup> the cyst seemed to have formed between the layers of the drum-membrane. In the other three cases, however, the cyst-like tumor consisted of the posterior half of the drum-membrane, which, having lost its substantia propria through the prolonged pressure of the exudation in the tympanic cavity, had no longer been able to resist that pressure, and so gradually became converted into an elastic diverticulum. In acute cases I have frequently observed, during convalescence, a very marked pouting of the membrane in the immediate vicinity of the perforation; and in one case, which is now under my care, I found on returning to the city, after an absence of a week, that the simple pouting of the membrane had developed into a well-defined, almost pedun-

<sup>1</sup> Marcé: De l'ulcération de la carotide interne dans la carie du rocher. Paris, 1874. See also a case reported by Hermann (A. f. O., IV., p. 294).

<sup>2</sup> Transactions of the American Otological Society, 1874.

<sup>3</sup> In the Medical Record of November or December of that year.

culate cyst, fully three millimetres in diameter. A minute perforation still existed, but it was so inadequate, as an outlet for the purulent secretion, that the neighboring parts were kept in a constant state of tension.

In the remaining two cases the cysts were of quite a different nature. One of them occupied the very centre of the drum-membrane and measured nearly three millimetres in diameter. It was also somewhat flattened, as if a portion of the fluid contents had been absorbed. The other cyst occupied the lower two-thirds of the posterior half of the membrane. It had evidently originated at the upper part of the membrane, and had, as it increased in size, dissected its way down to the lower part. Both of these cysts contained apparently pure serum, unmixed with blood. Both occupied spaces which they had made for themselves between the *substantia propria* and the outer dermoid layer. Both seemed to have originated in a subacute congestion of the middle ear, which had run its course, however, without causing any appreciable exudation in the tympanic cavity. After the contents had been evacuated, both cysts soon disappeared completely.

So far as the size of these tympanic cysts is concerned, the largest that I have seen was so large as to completely conceal all the remaining half of the drum-membrane; that is, it was as large as a medium-sized pea. In every case but one the posterior half of the drum-membrane alone was involved. Finally, in one of the four cases first described I was surprised to find that there was quite a large perforation in the anterior half of the *membrana tympani*, and that pus escaped freely through it. To explain this condition of things satisfactorily, one must assume that inflammatory adhesions had at some previous time shut off the posterior from the anterior half of the tympanic cavity, perhaps not entirely, but at least to such an extent as to keep the fluid contents of the posterior half under great pressure.

So far as the treatment is concerned, the most urgent indication, in the case of cysts that communicate with the middle ear, is to establish a very free opening in the *diverticulum*, and then to treat the case in the same way as we should a simple case of purulent inflammation of the middle ear.

7. *Deformities caused by both the acute and the chronic forms of purulent inflammation of the middle ear.*—Even the very worst cases of purulent inflammation of the middle ear will often heal, and cease thereafter to give the patient any annoyance beyond that caused by the impairment of his hearing. This symptom, however, often brings such patients to the physician's office, and in this way we have opportunities of seeing a great variety of deformities. It would require considerable space to give anything like a full list of the numerous pathological pictures presented by the cases that belong in this category. I will therefore simply allude briefly to some of the more important ones.

*Calcareous deposits* in the drum-membrane furnish good evidence that the middle ear has at some previous time been the seat of a purulent in-

flammation. During the course of this inflammation aggregations of pus-cells are deposited between the layers of the membrana tympani, and in this position undergo, first, cheesy and then calcareous degeneration. According to the original distribution of the pus-cells, there will ultimately be developed either a plate of calcareous material or a series of small calcareous spots. I have seen almost the entire area of the drum-membrane occupied by one or more calcareous plates. Of themselves these chalky deposits in the drum-membrane exert very little influence upon the acuteness of the hearing. I have seen extensive chalky patches in the drum-membranes of individuals whose hearing was very acute. Their chief value lies in the evidence which they afford of a previous purulent inflammation of the middle ear, and also in the light which they throw upon the nature of the lesions underlying certain cases of marked deafness. Such calcareous deposits have been found, post-mortem, in the neighborhood of the stapedio-vestibular joint, a location where they may produce a high degree of disturbance in the mechanism of hearing. During a patient's lifetime we cannot inspect this particular region; but if we find calcareous plates in the membrana tympani of a very deaf individual, would it not be natural to infer—in the absence of other satisfactory causes—that a similar chalky material has been deposited in the tissues surrounding the foot-plate of the stirrup?

*A tough and thickened drum-membrane* is sometimes left as a permanent sequela of an otitis media purulenta of long standing. Taken by itself, such a thickening of the drum-membrane cannot very greatly impair the power of hearing. As an evidence, however, of a general thickening of the mucous membrane lining the middle ear, it must be considered as an important lesion.<sup>1</sup>

*Cicatrices*, or incomplete reproductions of the drum-membrane substance (as represented by its three essential layers), are very common. They are usually round, oval, or kidney-shaped, but they may also have other shapes. They are, as a rule, smooth, extremely thin, and transparent, and yield to pressure as if they were made of rubber. In a few cases we find the cicatrix in a crumpled condition, as if it had been unduly stretched. Anatomically such cicatrices consist of the dermoid layer, on the side toward the meatus, and of a continuation of the epithelial layer which constitutes the free surface of the tympanic mucous membrane. Between these will be found some elastic fibres and a few capillary blood-vessels, but probably no nerves. The significance of the existence of such cicatricial spots in the drum-membrane is simply this: they afford strong, if not absolutely positive, proof that at some previous time the middle ear has been inflamed, and that, as a result of such inflammation, a perforation of

---

<sup>1</sup> Urbantschitsch (Archiv für Ohrenheilkunde, X., p. 7) describes peculiar pearl-like thickenings of the epithelium of the drum-membrane.

the same size as the cicatricial spot was established in the membrana tympani. After inflation, these cicatrices, unless the Eustachian tube happen to be unusually pervious to air, will be found to present a totally different appearance. In the place of a flat, or, more commonly, a concave, smooth, transparent surface, we shall see a tense, slightly opaque, hemispherical or tomato-shaped blebs, which in the course of a few minutes usually returns to its former flat or concave state. More than once I have ruptured such cicatricial reproductions of the membrana tympani, and have in the majority of instances seen no harmful results from such a rupture. In one case, however, the inflation produced pain and some impairment of the hearing. I must therefore dissent from the views expressed by Politzer in 1868.<sup>1</sup> I believe it is better to avoid rupturing these cicatricial portions, and especially such as are found lying against the mucous membrane of the promontory. In these particular cases there is some likelihood that adhesions may have formed between the cicatrix and the mucous membrane, and forcible inflation under such circumstances is quite sure not merely to rupture the adhesions (which may in certain cases be a desirable thing), but also to tear the mucous membrane and cause hemorrhage (which in the middle ear is never a desirable thing).

So far as the size of these cicatricial reproductions of the membrana tympani is concerned, I may say that in this respect there is practically no limit to the reproductive powers of the membrane. The substantia propria, it is true, seems to possess extremely little regenerative power. On the other hand, the dermoid and mucous surfaces possess this power to an amazing extent. In one of my cases exactly one-half of the drum was cicatricial, viz., the posterior half. The dividing line between the original membrane and that which had been reproduced was very sharply drawn. The elastic nature of this cicatricial half manifested itself in a striking manner when I made an incision in it,—the lips of the wound instantly gaping widely apart as the tissues were divided. In four other cases there was very clear evidence that the drum-membrane had been entirely reproduced. I will describe each of these cases in brief outlines.

CASE I.—The patient, a boy about twelve years of age, consulted me at the New York Eye and Ear Infirmary, on the 3d of May, 1871, for a slight general impairment of his hearing. On questioning him, I ascertained that from early childhood up to a recent date he had been subject to a discharge from both ears. On examination I found the left auditory canal normal. At the inner end of the canal the picture presented to the eye was as if the membrana tympani had been destroyed. On closer inspection, however, I discovered that a very thin membranous structure dipped directly inward from the annulus tympanicus, and applied itself closely to

---

<sup>1</sup>Wiener med. Presse, 1868.

all the irregularities of surface of the inner wall of the tympanum. The tip of the handle of the hammer was firmly bound down to the tissues of the promontory. Behind it the long process of the anvil and the posterior arch of the stirrup were seen standing out in relief, but from their peculiar glistening aspect it was evident that they too were covered with the cicatricial membrane.

CASE II.—The patient, a girl ten years of age, was brought by her mother to the Infirmary on the 23d of August, 1871. The history given was this: Five years previously the child had contracted a double otorrhœa, which lasted without interruption for about two years and then gradually ceased, leaving her with a moderate degree of deafness. On examination I found that the posterior half of the right drum-membrane consisted entirely of cicatricial tissue, while on the left side the appearances presented were almost precisely the same as those observed in the preceding case.

In regard to both of the preceding cases the objection may be raised that the thin membranous structures, which I have described as reproduced drum-membranes, may have been in reality atrophied drum-membranes, which, through some intercurrent inflammatory action, had contracted adhesions with the inner wall of the tympanum. I admit the possibility of such a series of pathological changes, and I also admit the fact that an atrophied drum-membrane may present to the naked eye precisely the same appearances as a newly-produced membrane. I think, however, that of the two hypotheses mine is the more probable; especially if we take into consideration the previous history of each of these cases, and if we remember that the reproduction of a substitute for a drum-membrane that has been entirely destroyed is now a well-established fact.<sup>1</sup> In the following two cases the evidence is certainly conclusive.

CASE III.—The patient, a strong healthy boy eight years of age, was brought to see me on the 3d of October, 1872. The history which his mother gave was this: Three or four years previously he had passed through an attack of scarlet fever, which left him with a discharge from the left ear, which had continued ever since. I examined the ear and found that the drum-membrane had been entirely destroyed, and that from the posterior and upper part of the tympanum a pedunculate growth sprang which partially filled the inner end of the meatus. I removed this growth with the snare, and treated the thickened spot of mucous membrane from which it grew, first with pure nitrate of silver (in the form of a bead), and

---

<sup>1</sup> See the report of such a case by Dr. H. N. Spencer, of St. Louis, in the Transactions of the American Otological Society for the year 1871.

afterward with powdered burned alum. The right ear was perfectly normal.

On the 24th of October, the discharge having ceased and there being no evidence of a return of the growth, I dismissed the boy from active treatment.

On the 19th of January, 1880, I had an opportunity of examining the patient's left ear again. He said that he had remained perfectly free from a discharge since 1872, and that the ear had given him no trouble beyond that due to the slight impairment of the hearing. To my surprise I found that a thin, dermoid membrane had grown from the rim that remained of the original membrane, and followed the inequalities of the inner wall of the tympanum in much the same manner as was observed in the preceding cases.

CASE IV.—The patient, a boy fifteen years of age, came to the New York Eye and Ear Infirmary on the 27th of May, 1874. He stated that two years previously he had had scarlet fever, and that it was followed by a discharge from both ears, which had continued without intermission up to that time. On examination I found the right external auditory canal filled with pus. I cleaned the parts thoroughly, and then ascertained that the drum-membrane had been destroyed, and that the mucous membrane of the tympanic cavity was almost everywhere in a granulating condition. No effort had been made to keep the deeper parts of the ear clean, and as a result the purulent secretion had become highly offensive, and was undoubtedly extremely irritating to the mucous membrane of the middle ear. I saw the patient at irregular intervals and treated the case in the usual way. It was not, however, until during the latter part of October of that year that I finally succeeded in arresting the tendency, on the part of one or two spots in the tympanic mucous membrane, to develop granulation-tissue.

On the 17th of April, 1875, I found that the gap which had previously existed between the plane of the annulus tympanicus and the inner wall of the tympanum had been filled in by a newly produced cicatricial membrane of a peculiar glistening appearance. My notes read as follows: "The handle of the hammer loses itself in the tissues of the promontory. The drum-membrane—or, rather, a dry cicatricial tissue—follows accurately the entire background, spanning the cavity at two or three points, viz., high up posteriorly and opposite the mouth of the Eustachian tube, as a tense, creased membrane."

*False membranes or bands of adhesion* are often encountered in the middle ear. They must be considered as sequelæ of an acute or chronic inflammation (generally purulent in character) of the middle ear. I will select a few examples of this pathological condition from my case-books. In one

case the description reads thus: "The drum-membrane is entirely destroyed, with the exception of a narrow rim at the periphery. The hammer is drawn out of position, so that the neck and a part of the head are visible. Its handle is bound down to the long process of the anvil by adhesions." In a second case I found "a strong, isolated fibrous band running from the lower part of the tympanic ring (the posterior half of the membrane having been destroyed) to (possibly) the head of the stirrup." In a third case a band ran from the centre of the handle of the hammer forward and a little downward to some point in the vicinity of the mouth of the Eustachian tube. In a fourth case the drum-membrane was found either to have undergone a high degree of atrophy or to have been replaced by a cicatricial membrane, through which was distinctly seen a whitish band running almost directly upward from the tip of the handle of the hammer to the region of the stapedio-incudal joint. In a fifth case the rigidity of the handle of the hammer, as ascertained by pressing upon it with the end of the probe, justified the assumption that the high degree of deafness which existed in this case was probably due to a similar ankylosis of the other joints, and particularly of the stapedio-vestibular joint. In a sixth case I found the hammer drawn completely out of its natural position and bound down by firm adhesions to the anterior wall of the auditory canal, or, at all events, to the anterior edge of the annulus tympanicus. Finally, in a seventh case I found one of the larger ossicles similarly bound down to the upper and posterior wall of the canal. It was so enveloped in firm cicatricial tissue that I was unable to distinguish accurately which of the two ossicles it was.

The deformities which I have just enumerated are comparatively rare. Much more common are those adhesions which bind the handle of the hammer, or the drum-membrane, or both, to the opposite promontory.

*Double perforations* in the drum-membrane proper are by no means common. In one of my cases the two perforations occupied the lower half of the membrane. In two other cases two small perforations were found, one in the anterior inferior quadrant, the other in the posterior inferior quadrant. In the fourth case my notes read as follows: "All that remains of the drum-membrane is a narrow bridge of tissues stretching from the tip of the handle of the hammer to the opposite portion of the sulcus tympanicus."

Finally, in the category of deformities, I might mention the *destruction or expulsion of the ossicles*.—It is a very common experience to find the handle of the hammer reduced to a mere knob in the vicinity of the short process. If the hammer has disappeared, we may be very confident that the anvil has gone with it; for when the anvil loses the support of the hammer, it becomes a mere dangling body, having only two remaining supports and those comparatively feeble (the stapedio-incudal and the tympano-incudal articular ligaments). Unless extensive caries or necrosis of the petrous portion of the temporal bone exists, the stirrup seems to be able to main-

tain its position firmly in the fenestra ovalis. When it goes, or rather, when its foot-plate goes, the hearing-power also vanishes. This at least must be the rule, but that exceptions may occur will appear from the fact developed in the following case :

The patient, a well-known physician in this city, about forty-five years of age and very deaf, consulted me on the 17th of October, 1879, on account of a very distressing tinnitus. He said that during boyhood he had been subject to a discharge from both ears, and that on one occasion his mother had discovered in the discharge from the right ear the stirrup, in a perfect state of preservation. She put it into a box and kept it as a curiosity. The doctor had himself seen this ossicle as recently as during 1877, and was positive that it was the stirrup and not one of the other ossicles. During recent years he had been entirely free from discharge, and at times heard fairly well. I tested his hearing and found that words loudly spoken were heard about equally well in both ears. He could distinguish words correctly, however, only at a distance of three or four feet. The sound of the tuning-fork, when placed upon the forehead, was referred by the patient to that region, and not to either ear ; when held near the ear, it was heard by him at a distance of about four inches, in both ears. Every trace of the drum-membrane, hammer, and anvil had vanished from both ears, and a thick and pale (fibrous) cicatricial tissue covered the entire background, the only decided depression being a niche at the tympanic orifice of the Eustachian tube.

This is the only instance that I have met with in which the evidence was fairly conclusive that the expulsion of this most important ossicle had not wholly deprived the patient of the hearing-power in the ear thus maimed. Nature, we may assume, had in this instance probably provided a fibrous substitute for the foot-plate of the stirrup before the actual separation and expulsion of the ossicle took place.

The question of *treatment* of these deformities of the middle ear may be dismissed in a very few words. Excision of the hammer, and attempts to render it mobile by the employment of a certain degree of force in cases where this ossicle has acquired a rigid, immovable position, do not commend themselves to my judgment. Operative interference in cases of adhesions between the membrana tympani and the mucous membrane of the promontory, or between the ossicles and some portion of the tympanum, may possibly in certain cases accomplish some good ; but I have not yet had the good fortune to encounter a case in which I felt in the slightest degree encouraged to undertake such operative interference. In cases of simple perforation of the drum-membrane, where the discharge has ceased, I never make any attempt to cause the healing over of the opening by a cicatricial membrane, the gain which might result therefrom being altogether too insignificant. There is one point, however, which should be borne in



mind with regard to these cases of simple perforation. I refer to the harm which sometimes comes from the introduction of water into the external auditory canal. It is almost sure to find its way into the tympanic cavity, and—the tympanic mucous membrane being in a comparatively healthy state—its presence there is apt to give rise to considerable irritation, and perhaps even to re-establish a subacute purulent inflammation of these parts. The removal of impacted cerumen from the external auditory canal by means of the syringe may, in cases such as we are considering, result in the production of an evil which in its turn may require considerable treatment. In cases, therefore, in which there are good grounds for suspecting the existence of a perforation in the drum-membrane (without otorrhœa), the syringe should not be used, if we can possibly dispense with it. The patient should also be cautioned about bathing in either salt or fresh water, without first protecting the affected ear against the entrance of water.

So far as the symptom of deafness is concerned, a certain degree of relief may be obtained in a few cases by the wearing of Toynbee's *artificial drum-membrane*. I have not seen more than four or five cases in which this contrivance, or some substitute for it, materially increased the acuteness of the patient's hearing. At the same time I must confess that my lack of faith in its efficacy has led me to test its virtues in comparatively few cases. Furthermore, the presence of such a foreign body in the meatus, and in close contact with the drum-membrane, or with the stump of the manubrium mallei, is very annoying to the great majority of patients.

## CHAPTER VIII.

### FRACTURES OF THE TEMPORAL BONE.

THE subject of fractures of the temporal bone is generally considered to belong to the domain of general surgery, and it may therefore seem somewhat strange to some of my readers that I should treat of it in a work devoted to diseases of the ear. A fracture of the temporal bone, however, implies, almost necessarily, damage to some part of the middle ear or labyrinth, and, in consequence of this, many of these cases of fracture, after leaving the surgical wards of our hospitals, come into the aurist's hands for the relief of a partial or total loss of the sense of hearing. My experience with cases of this class is therefore necessarily one-sided. It does not extend to the fatal cases, nor does it cover the first stage of the illness, except in so far as the facts relating thereto can be learned from the patient or from his friends. The picture which I may be able to draw of this traumatic affection must therefore depend for its value chiefly upon the degree to which it supplements those already drawn by surgical authors.

By reason of certain peculiarities in the construction of the temporal bone, fractures that take place in it are apt to occur at certain spots, or along certain fixed lines, where the bone is weaker than at other points. These lines correspond with the lines of union of the three bony portions which together form the temporal bone, and which originally (in the foetus) were separate centres of development, viz., the squamous portion (together with the zygoma), the tympanic portion (annulus tympanicus), and the petrous portion (together with the mastoid process). Fractures at these points are perhaps, strictly speaking, simply diastases. There is a fourth region, however, where the bone is particularly weak, and where a genuine fracture is very apt to occur. I refer to the central portion of the pars petrosa, where the bone is hollowed out by a series of cavities (the meatus auditorius internus, the cochlea, the vestibule, and the semicircular canals), separated from each other by comparatively thin partitions of bone. Finally, the squamous and the mastoid portions of the temporal bone, situated as they are upon the outer surface of the skull, are liable to be fractured or cracked at any point, viz., wherever the direct force of the blow or fall may be applied. Of the other fractures—viz., those occurring in the deeper parts of the temporal bone—a large proportion are undoubtedly

produced by *contrecoup*; that is, in falling the patient strikes upon the back or top of his head, while the fracture occurs at the base of the skull. In the technical sense, however, I believe that the term "fracture by *contrecoup*" is applied only to those cases in which the direct force of the blow or fall is received upon the side opposite to that on which the fracture occurs. Aside from the treatment, the most practical question connected with fractures in this region is, how far can they be diagnosed at the bedside?

From a study of the fourteen cases which have come under my observation, I find that I can make two grand subdivisions of fractures of the temporal bone, viz.:

1. Fracture or diastasis of the tympanic or squamous portion in the region of the middle ear, without implication of the petrous portion.
2. Fracture of both the tympanic and the petrous portions.

In one or two of these fourteen cases the symptoms observed seemed to justify the establishment of a third subdivision, viz.: fracture of the petrous portion of the temporal bone without implication of the middle ear. The chain of evidence, however, though pointing strongly to such a conclusion, is not sufficiently complete to warrant the introduction of this third class.

Class I., which includes cases of fracture of the temporal bone in the region of the middle ear, without implication of the petrous portion, may be broken up into smaller subdivisions. Thus, for example, we may have:

1. *Cases in which no visible hemorrhage or other discharge takes place from the ear.*
2. *Cases in which a hemorrhage or bloody discharge from the ear follows the accident.*
3. *Cases in which the accident is followed by spitting of blood, due to its escape from the middle ear, by way of the Eustachian tube, into the nasopharyngeal cavity or nasal passages.*

Of the first subdivision I can give no examples. Of the second I can give two, as follows:

CASE I.—The patient, a carpenter, thirty-four years of age, was struck on the head by a falling plank, on the 1st of July, 1878. The blow rendered him unconscious only for a few minutes. He was then shortly afterward able to resume his work, though not feeling right in his head. On the 8th of July he came to the Infirmary to obtain relief. He said that there had been a constant blood-stained, watery discharge from the left ear, and that the pain in his head had been steady and quite severe. He had noticed some impairment of the hearing on the left side, and a sensation of numbness on the forehead and on both sides of the face. He had also observed that when he exposed himself to the sun, and when he lifted heavy objects, the headache was much aggravated. His gait was perfectly steady.

On examination I found that there was still an oozing of bloody serum from the left ear, and that the hearing was so far impaired that the patient could hear the ticking of the watch only when it was pressed against the ear. The soft parts lying immediately above the drum-membrane were red and so much swollen that only the lower part of the membrane itself was visible. No perforation could be seen.

(My notes contain no memoranda of the treatment adopted.)

On the 31st of July the patient was seen a second time. He still complained a little of his head, but the discharge from the ear had ceased, and the hearing had been restored to almost its normal degree of acuteness.

During the following October the patient was seen a third time, and was found to be perfectly well in every respect.

CASE II.—Machinist (Bridgeport, Conn.), fifty-two years of age, and well nourished. November 28, 1873. Sixteen days ago he received a blow on the right side of the head. It was followed immediately by profuse bleeding from the right ear, and partial unconsciousness. The bleeding continued for eight days, during a part of which time he had daily chills, with fever, followed by sweating during the night. Tinnitus, total deafness, pain and dizziness were the other prominent symptoms. He does not remember having noticed any discharge from the ear after the bleeding ceased. On the second day the pain in the ear became quite severe, and continued with increasing severity up to the eighth day. Coughing and blowing the nose aggravated the pain. At first it was confined to the ear alone, but it soon extended to the parts behind and above the ear, and eventually to the entire right side of the head. A cough, which has now become very troublesome, developed on the fifth day. It is associated with a profuse mucopurulent expectoration. The patient has had no distinct chills since three days ago. Chilly sensations and sweating, however, still continue. He complains of feebleness. He was positive that the hearing in both ears was perfect before he received the blow on the side of the head. During the past few days he has experienced an almost constant desire to sleep. (This symptom is very marked. The moment the man has finished answering my questions, and while I am writing my notes, he drops off into an apparently sound sleep, from which I am obliged to rouse him before putting a new question to him.) Face and neck noticeably congested. Veins on the forehead and temples stand out prominently. Pulse at wrist, 72 and feeble. Respirations (counted while he was asleep in the chair), 28 to the minute. Watch heard when firmly pressed against the ear. Vibrations of the tuning-fork are uniformly referred to the right ear. With the good ear closed the patient can distinguish correctly only now and then a word spoken loudly in close proximity to the right ear. No appreciable redness or swelling of the mastoid integuments. This region, however, and also the

temporal region, are both quite tender on pressure. Eustachian tube easily inflated. External auditory canal normal. Membrana tympani congested and œdematous; no bulging.

Under date of July 1, 1874, Dr. George F. Lewis, his physician, wrote that the patient gradually recovered his health, and was at that time perfectly well.

Finally, in the third subdivision of Class I, I would place the following case:

CASE III.—The patient, a female, twenty-five years of age and in good health, was seen by me at the New York Eye and Ear Infirmary, on the 15th of June, 1870. She gave the following history: Four days previously she fell, striking upon the left side of the head. Since then she had experienced moderately acute pain in the right ear, and constant noises, like the rushing of waters, but no appreciable deafness. On the day following the accident she occasionally spat a little blood. On examination I found the right drum-membrane partially concealed by a bloody bleb, which projected forward from the posterior and upper portion of the canal, at its line of junction with the membrana tympani. The drum-membrane itself—so much of it, at least, as was not concealed by the bloody tumor—presented a purplish red appearance. There was tenderness on pressure both behind and in front of the ear. The watch was heard at a distance of six inches. Treatment: puncture of the blebs; warm douche every half-hour until pain had been relieved.

On the 18th of June she reported that a slight discharge from the right ear had made its appearance on the 16th. Pain steadily diminishing. Watch heard at a distance of only three inches. No perforation in the drum-membrane visible.

On the 9th of July she reported that the discharge had ceased. On examination I found that the membrana tympani had lost its red color, and presented simply an opaque appearance. External auditory canal normal. No pain. Patient simply complained of an unpleasant resonance of her own voice in the affected ear. Watch heard at a distance of twenty inches.

August 3d.—Watch heard at a distance of six feet before inflation, and nine feet after it.

In reference to these three cases, let me call attention to the fact that in all of them there were unmistakable evidences that some serious injury had been done to the parts immediately surrounding the drum-membrane, and yet in all of them the hearing was not seriously affected. For the present I will simply mention these two circumstances as constituting the prominent characteristics of cases belonging to Class I, or cases of fracture of some portion of the temporal bone in the immediate neighborhood of the drum-membrane.

Class II. comprises cases of fracture involving both the tympanic and the petrous portions of the temporal bone. These cases are, as a rule, of a more serious character than those belonging to Class I. The severity and duration of the illness which immediately follows the accident are usually so great that the aurist never sees such cases until after the characteristic lesions in the region of the drum-membrane have disappeared. The line or lines of fracture may run in a variety of directions, and may involve other organs besides that of the ear proper. From the symptoms produced by the accident, we may also, in many cases, locate more or less accurately the course pursued by the fracture. In illustration of this second class I will give here briefly the histories of ten cases :

CASE IV.—Robert K., a liquor dealer, twenty-nine years of age, consulted me at the New York Eye and Ear Infirmary on the 23d of October, 1872. He gave the following history : Four weeks previously he fell from a wagon and struck upon his head. Blood flowed out of his right ear, as he was told, and he remained in an unconscious state for about twenty hours. When consciousness returned, he noticed that he was entirely deaf in the right ear. The objects in the room seemed to him to be going round in a circle. He vomited twice. For a period of nearly two weeks he was unable to go about without assistance, on account of the difficulty which he experienced in maintaining his balance. Then, as improvement took place in this respect, he was able to walk about with the aid of only a cane. During the few days immediately preceding his visit to the Infirmary, he had been able to dispense with all assistance. At first the subjective sounds were of a musical character, but they gradually gave place to a simple ringing or roaring. On examination I found no lesions of any importance in the right ear ; the parts were practically in a normal condition. When the watch was pressed against the centre of his forehead he heard its ticking faintly in the left ear. (Treatment with iodide of potassium was advised, but the patient was not seen again.)

CASE V.—Louis Anderson, a seaman, twenty-five years of age, was struck on the head by a falling heavy cable, on or about March 15, 1874. He did not lose consciousness. As soon as he had recovered from the acute pain of the blow, he noticed that blood was running out of the right auditory canal, and that he could hear only with the left ear. He also discovered that he was unable to close the right eye ; and later, when he attempted to eat, he found that pieces of food lodged in the right side of the mouth, and that, in drinking water, some of it escaped from this same side. He was questioned with regard to his powers of tasting, but, so far as could be learned by mere questioning, his sense of taste had not been affected.<sup>1</sup>

---

<sup>1</sup> Such a case of impairment of the sense of taste has been reported by Brunner : *Archiv für Ohrenheilkunde*, Bd. V., p. 32.

Gradually all the symptoms disappeared, with the exception of the deafness and a slight trace of the facial paralysis. Finding that the deafness persisted, the patient came to the Infirmary on the 29th of April, 1874.

As the drum-membrane presented a perfectly normal appearance, and the facial paralysis was discoverable only upon careful search, I discouraged him from expecting any beneficial results from treatment.

CASE VI.—David Brant, a boatman, twenty-two years of age, fell, during the last week of January, 1874, a distance of about fifteen feet, striking upon his head. He remained in an unconscious state for about half an hour. During the following week there was a constant watery discharge from the right ear. Then the patient became very ill, the prominent symptoms being pain in the head, fever, and delirium, with a continuation of the thin, watery discharge from the right ear. This acute illness lasted nearly two weeks, and from that time to the date of his visiting the Infirmary (March 28, 1874) he slowly but steadily regained his general health and strength. The discharge, which became decidedly purulent in character during convalescence, was still quite active at the time when he visited the Infirmary. On examination I found the right auditory canal filled with pus. The drum-membrane was perforated posteriorly, and its lower half, especially anteriorly, was converted into an irregular mass of granulation-tissue. So far as I could ascertain, the hearing-power had been totally destroyed in this right ear. When the watch was placed between his teeth in the median line, the patient said that he heard its ticking in his left ear.

Treatment was commenced for the purpose of arresting the discharge, but the patient never returned. He was told that he would probably never recover the power of hearing in his right ear, and this undoubtedly drove him away from the institution.

CASE VII.—About the 1st of September, 1877, Michael Kennedy, a laborer, forty years of age, fell from a scaffolding thirty feet high, and struck upon his head. He was found in an unconscious state, and remained so for two hours. For a period of two weeks and a half after the accident he was unable to leave his bed. During this time he was obliged to maintain a half-sitting posture, as whenever he attempted to lie down at full length the pain and distress in his head became unbearable. I was unable to learn exactly what his symptoms were during this period, or whether he had been delirious or not. He was quite sure, however, that no blood nor any watery discharge had come from either ear. He remembered having been very much annoyed by a constant tinnitus, particularly in the left ear. Going upstairs or shaking his head, he said, aggravated the tinnitus very much. When he had so far recovered that he was able to leave his bed, he experienced great difficulty in maintaining his equilibrium. His head, he said, seemed to him as if it weighed a ton, and he felt all the time as if

he were on the point of falling. This difficulty in walking did not materially improve until about the middle of the following December. From that time to the 27th of December, when he made his first visit to the Infirmary, quite rapid improvement had taken place in this respect. At the time when I saw him he was able to walk fairly well; there was no paralysis, but simply a lack of co-ordinating power. There was total loss of the sense of hearing in the left ear. Drum-membrane normal in texture and position. Hearing-power of the right ear nearly normal. (No treatment advised.)

CASE VIII.—The patient, a boy seven years of age, was brought by his mother to the Infirmary on the 8th of January, 1873. She stated that about six months previously he had passed through, first, scarlet fever, and then cerebro-spinal meningitis, which left him with a staggering gait. While in this condition he fell backward out of a wagon, and struck upon the back of his head. Inflammation of the brain set in, and, as a result of this, the boy became totally deaf. The mother, who was an intelligent woman, was positive that the deafness only developed after this accident, and not after either of the other illnesses. She was also confident that there had never been a discharge from either ear. On inspection I found both drum-membranes practically normal.

CASE IX.—John O'Brien, a boy twelve years of age, was knocked off the steps of an omnibus and fell, striking his head heavily against the pavement. He was taken up in an unconscious state, and was afterward "very ill" for several weeks. When he recovered, it was discovered that he had entirely lost the power of hearing in both ears. The parents state that there had never been any hemorrhage or discharge from the ears, and that the boy had not even complained of pain in them. On examination, December 6, 1873, a year after the occurrence of the accident, I found both drum-membranes perfectly healthy.

CASE X.—John Miller, a framer, fifty-eight years of age, came to the New York Eye and Ear Infirmary on the 29th of April, 1874. He said that in the spring of 1873 he fell a distance of eleven feet, striking upon his head. Blood flowed from both nostrils and ears. He was then "very ill for a long time," and in answer to my questions said that he had been out of his head part of the time. During recovery he found that he was almost totally deaf; at the same time he suffered from ringing noises in the head and from dizziness, and experienced considerable difficulty in swallowing. The deafness is still very marked (almost total), and he is not yet free from the other symptoms mentioned. Both drum-membranes are intact, though opaque and thickened. (No treatment advised.)

CASE XI.—Elenora Smith, a healthy girl, six years of age, was brought by her mother to the Infirmary on the 24th of July, 1872. The following



history was given : Three months previously the child fell down-stairs, and was ill for about a month with fever, delirium, and spasms. During recovery the mother discovered that the child was perfectly deaf. She thinks that she made this discovery about ten days or two weeks after the occurrence of the accident, and at about the same time she noticed that there was a discharge from the left ear. The child's hearing previous to the accident had been perfect. When she was brought to the Infirmary her gait was still noticeably unsteady. The mother, whose attention was called to this peculiarity, said that it was then very much less than it had been during the early part of convalescence. On inspection, a simple otitis media purulenta, with perforation of the membrana tympani, was found on the left side, while on the right the middle ear appeared to be normal.

Finally, to the foregoing cases, in which the injury was produced by a blow or a fall, may be added the following two, in which the impact of a bullet produced the injury :

CASE XII.—The patient, a powerful but idiotic-looking negro, thirty-five years of age, while animated by a desire to end his life, fired one chamber of a loaded revolver into his right ear, and then, finding that he was still alive, he discharged the contents of a second chamber into his left ear. This was done on the 6th of March, 1874, and on the 18th he was brought to the New York Eye and Ear Infirmary. I was not able to learn what had been the man's condition during the interval between these dates. The patient himself was perfectly deaf, and the person who accompanied him simply knew the facts relative to the shooting. On examination I found the right external auditory canal filled with polypoid granulations. These sprang from the anterior and lower wall of the meatus, about midway between the outer orifice and the drum-membrane. At this point the bent probe entered an excavation in which loose pieces of bone were encountered. On the left side the auditory canal was also found to be filled with pus. I removed several small polypoid growths from the narrow canal, but failed to discover any region of exposed bone ; I also was unable to obtain a satisfactory view of the deeper parts of the canal. There could be very little doubt, however, of the absence of the drum-membrane, and probably of the ossicles. The right ear being very painful, I prescribed leeches.

On the 22d of April I saw the patient a second time. The leeches had relieved him from pain. With the slender angular forceps I removed two fragments of bone from the right auditory canal.

On the 2d, and again on the 6th of May, I removed fragments of bone, one of which presented a blackened appearance.

On the 9th of May I encountered some hard substance in the region of the middle ear, and succeeded in extracting it. It proved to be a mass of

lead, about the size of a half-pea, probably a portion only of the ball fired from the revolver. The opening in the canal from which the fragments of bone had been removed presented every appearance of being on the point of healing.

On the 16th of May I removed another piece of lead and some fragments of bone from the region of the right middle ear.

On the 3d of June I found that the wound in the meatus had healed, and that the mucous membrane of the middle ear was free from all evidences of active irritation. The discharge had apparently ceased entirely.

After the removal of the polypoid granulations from the left auditory canal all active discharge from that ear ceased.

If the damage observed in this left ear is to be ascribed to the effects of the shooting, the bullet must have been extracted by some physician during the period of twelve days that elapsed between the infliction of the injury and the time of the patient's entrance into the Infirmary.

In the preceding case it is quite possible that the squamous and petrous portions of the temporal bone (on both sides) were also fractured. The ball, however, may simply have driven the stirrup violently into the vestibule, and not have produced an actual fracture of the petrous bone. In the following case the petrous bone could scarcely have been involved to a serious extent, though probably the squamous portion did not wholly escape.

**CASE XIII.**—The patient, an apparently strong man, thirty-four years of age, and a soldier, was admitted to the New York Eye and Ear Infirmary, June 12, 1872. He gave the following history: In the course of an engagement with the enemy, in Valverde, New Mexico, on the 22d of February, 1862, the company of which he was a member (Co. G., First U. S. Cavalry) was ordered to retake a battery. While they were advancing he was shot in the right side of the head, the ball entering the skin just in front of the ear. The shot had come from a detachment of the enemy in the rear. Three days later the ball was extracted from beneath the skin, just above the right eyebrow. He then noticed a sensation of throbbing and fulness in the right ear, and not long afterward a discharge made its appearance in the outer canal. He remembers also that one of his comrades, at about that time, removed a bunch of hair, clotted with blood, from the right ear. During the first ten or twelve months following the injury he frequently found small fragments of bone in the discharge from the ear. Six months previous to his visit to the Infirmary he had experienced a severe attack of pain in the right ear, but before that time he had always been comparatively free from pain. From the very first he had been annoyed by a tinnitus, like the roaring of a shell. All sounds, moreover, seemed to reach

him by way of the left ear. At night he had always been obliged to sleep on the right side, for whenever he attempted to lie on the left side the sense of weight in the right ear became unbearable. About a week previous to his visit to the Infirmary the parts about the right meatus became very painful and swollen. The swelling subsided in the course of a day or two, and then for the first time he discovered the presence of some hard substance filling the outer canal. He came to the Infirmary for relief, and in this way became my patient. On examination of the ear I found a black mass, partly covered by pus, blocking up the entrance to the right auditory canal. I experienced no difficulty in extracting it with the forceps, and on examination found it to be a very much corroded, oblong leaden bullet, a little over half an inch in length, and three-eighths of an inch in diameter. The deeper portion of the meatus was found to be filled with a mass of granulations. No sinus could be found, nor any exposed surface of bone. The Eustachian tube was pervious. In front of the tragus there was a depressed scar, indicating the point where the other ball had entered. The patient was unable to hear the ticking of my watch in the right ear. The sound of a vibrating tuning-fork, placed on the central part of his forehead, was referred by him to that point, and not to either ear. With the left ear tightly closed, and the right ear turned toward the speaker, he could understand ordinary conversation at a distance of four or five feet.

On the 15th of June the patient reported that he had been quite free from pain since the removal of the ball, and that the discharge had also ceased.

On the 24th of July he again visited the Infirmary. The discharge had not returned. The tinnitus continued unchanged, but the sense of weight had disappeared, and he was able to lie indifferently on either side. Cicatrization had taken place in the ulcerated portion of the meatus, and there was then a clear but funnel-shaped passage down to the cavity of the tympanum. No trace was found of either the drum-membrane or the ossicles.

At the time when he was wounded, and even up to the time when he visited the Infirmary, the patient supposed that his ear trouble had been caused by the glancing backward of a fragment of the ball which struck him in front of the ear. Even the removal of a tuft of hair from the external auditory canal had not suggested to him the idea of a second ball, until after I had shown to him that the leaden mass removed from the meatus could scarcely be considered as a fragment of the ball that had been extracted from above the eyebrow of the same side. He then stated that many of the men in the enemy's ranks were armed with double-barrelled fowling-pieces, and suggested the possibility of his having been shot by the simultaneous discharge of both barrels of such a weapon. A more natural supposition is that he was shot by two balls contained in a single cartridge—one of them entering the meatus directly, without leaving any external

wound, the other striking the bone in front of the ear and glancing forward.<sup>1</sup>

The complete loss of the hearing-power in all these eight cases (I exclude the last two) constitutes the distinguishing feature of this second class. When, in a case of injury to the head, this symptom is discovered shortly after the occurrence of the accident, it is safe to assume, with the knowledge which we at present possess, either that a fracture has taken place through the labyrinth, or that an extravasation of blood has taken place in the cochlea, without a fracture. The results of numerous post-mortem examinations show that fractures through the petrous portion of the temporal bone, involving the labyrinth, are quite common. We have, therefore, good grounds for assuming, in cases such as I have just described, that the total loss of hearing means a fracture of the petrous portion of the temporal bone. At the same time we do not possess a sufficient number of facts to justify us in excluding the possibility of a mere extravasation of blood without fracture. And yet, on the other hand, we possess no facts which show that the blood-vessels of the labyrinth are specially predisposed to rupture under the influence of a mere concussion.

In this connection I should state that in one of my cases the hearing was not noticeably affected by the accident, but later, after meningitis had developed, the child became totally deaf. In this case, which I will narrate in brief outlines, the loss of hearing was undoubtedly due to an extension of the inflammation from the meninges to the labyrinth.

CASE XIV.—The patient, a boy eleven years of age and in fair general health, was brought to the Infirmary on August 6, 1872. According to the mother's statement, he had had a fall from a high stoop, on a Friday toward the end of April. After the fall he came home and said that he wanted to go to bed. Condition of hearing and equilibrium not then noticed. That night the mother observed that the boy moaned constantly through the night. The next morning, Saturday, he came down-stairs of his own accord, and then the mother noticed that his gait was staggering. That day the hearing was undoubtedly unaffected, inasmuch as the child answered all questions. That night he slept well. On Sunday morning he came down-stairs without assistance. Gait still staggering, though not so bad as on Saturday. On Sunday the mother noticed a change in his appearance; his face was very pale, he vomited frequently, and complained of severe pain in the head. The vomiting ceased the same day, but the patient continued to complain of his head and gradually passed into a state of delirium and high fever. Acute symptoms with delirium and involun-

---

<sup>1</sup> For similar cases of gunshot wounds of the temporal bone, see Moos: *Archives of Ophthalmology and Otology*, Vol. II., p. 342; Vol. III., pp. 111 and 216; Terrillon: *Annales des maladies de l'oreille*, 1878, p. 249.

tary evacuations, continued for a little more than a week. Convalescence lasted four or five weeks. Staggering gait had continued up to the time when I saw him, but it was gradually growing better, as the mother thought. There had been no discharge from either ear at any time during his life. So far as I could discover, the deafness was absolute. On examination I found both drum-membranes normal in appearance. I advised the parents to send the boy to some institution for deaf-mutes.

In considering the significance to be attached to the different symptoms which are observed in cases of fracture of the temporal bone, we would naturally begin with that of *bleeding from the ear*. This symptom has always been considered of great diagnostic value. It was a prominent symptom in five of my cases. Prescott Hewett, in his article on Fractures of the Base of the Skull,<sup>1</sup> speaks of this symptom of bleeding from the ears in the following terms: "Bleeding from the ears, in severe injuries of the head, has, for many years past, been held, and deservedly too, as one of the most valuable diagnostic signs of fractured base. But this bleeding, to be of any value as a means of diagnosis, must be of a serious nature, and, above all, it must continue for some time. With such a bleeding it may be safely diagnosed that there is a fracture of the base running through the petrous bone,<sup>2</sup> and opening up a communication between the cavity of the tympanum and some of the numerous and large vascular channels which surround this bone, or with an extravasation of blood within the cranium itself." In the statement which I have just quoted, stress is laid, as will be observed, upon both the copiousness and the duration of the bleeding, and we are permitted to draw the inference that if the bleeding is not "of a serious nature," a fracture of the base may not have taken place. Again, in the next sentence, we are told that a copious and prolonged bleeding indicates the "opening up of a communication between the cavity of the tympanum and some of the numerous and large vascular channels which surround this bone, or with an extravasation of blood within the cranium itself." At this point let me state that neither Prescott Hewett's nor my own observations warrant any very positive statements on these points. This whole subject of fractures of the temporal bone needs to be studied afresh. We possess numerous good clinical observations made by surgeons; we possess also the records of carefully made post-mortem examinations; but we possess, so far as I know, no records of cases in which, in addition to the facts obtained by the foregoing methods of studying the

---

<sup>1</sup> Holmes' System of Surgery, Vol. II., p. 284.

<sup>2</sup> The term "petrous bone" is used here, I suspect, not in the strict anatomical sense of the term, but rather with the idea of designating all that more solid portion of the temporal bone which lies below the line of the zygoma (viz., all of the petrous portion proper, a considerable part of the squamous portion, and the osseous auditory canal).

phenomena of the disease, those obtainable by an examination of the auditory canal, membrana tympani, and middle ear, shortly after the occurrence of the accident, are available for purposes of study. I maintain that in every case of suspected fracture of the temporal bone, such an aural examination should be made, and the conditions observed should form a part of the record of the case. Until this shall have been done in a sufficiently large number of cases, it will not be possible either to confirm or to refute authoritatively the statements which I have just quoted. So far as my own incomplete material furnishes any light upon the significance of bleeding from the ears, I may say that this symptom is susceptible of a somewhat broader interpretation than that given to it by Prescott Hewett. I would add to his proposition the following: *When a fall or blow upon the head is followed by bleeding from the ear, no matter how trivial, we may diagnose a fracture of the temporal bone in the neighborhood of Shrapnell's membrane, and probably in the line of the Glaserian fissure.* By this proposition I mean to convey the idea that, so far as the mere symptom of bleeding from the ears is concerned, we are scarcely justified in assuming that the line of fracture extends beyond the region of the tympanum. The petrous bone may also be fractured at the same time, and a laceration of the lateral sinus, or of one of the smaller sinuses, may have taken place; but the mere fact of a copious hemorrhage from the ear does not, in my opinion, justify us in assuming the existence of any such serious lesions. In the first place, if we concede the possibility of a persistent and copious venous bleeding from the ear, we must assume that an almost gaping communication exists, first, between the middle ear and the venous sinus, and, second, between the middle ear and the external auditory canal. Otherwise, how could venous blood flow freely and copiously from one of the sinuses in the cranial cavity out into the external meatus? I am far from denying the possibility of such an occurrence, and am even disposed to believe that the case of the machinist, Case I., may afford an example of this very combination of lesions. In the majority of cases, however, a fairly copious and protracted bleeding may occur from a simple laceration of the tympanic artery, such as would be very likely to follow a fracture involving the temporal bone in the line of the Glaserian fissure. As there are no other sources<sup>1</sup> besides the two mentioned, from which a copious hemorrhage in the meatus might come, we must choose between these in any given case. I have very little doubt that a careful examination of the drum-membrane alone, if made before these parts have become inflamed, would aid us very materially in determining the source of the bleeding.

The necessity of such examinations is shown very clearly in those cases of fracture in which no outwardly visible hemorrhage or other discharge takes place from the ear. As all my cases are cases of recovery, I am un-

---

<sup>1</sup> The carotid artery is, I believe, only very rarely lacerated in injuries of this kind.

able to furnish an indisputable instance of fracture of the temporal bone without hemorrhage from the ear ; but Dr. George L. Peabody, the pathologist of the New York Hospital, has very kindly supplied me with such an instance from the records of that institution. The report reads as follows :

James Battersby, æt. 40 ; Ireland, widower, iron-worker ; admitted June 2, 1879. About an hour before admission he fell from a scaffold while at work on the Ninth Avenue Elevated Railroad, a distance of twenty feet, striking his head on the pavement.

He was suffering from shock, from which he rallied after administration of stimulants. On admission he was found in a condition of stupor, and was observed to be absolutely deaf. He could easily be roused, talked intelligibly, and was not paralyzed at all. There was a slight contused wound of scalp, which did not reach the bone, and the history states that "examination of surrounding parts gave no evidence of fracture."

He took but little nourishment, became gradually completely comatose, and died on June 4th, two days after admission. There was a thin watery discharge from the nose, but there were no aural signs except deafness. Before he died the scalp was incised, and a fracture detected.

*Autopsy 24 hours after death.*—The viscera of thorax and abdomen were substantially normal. The following is the account of the examination of the head as taken from the autopsy book (Case 109) :

Beneath dura mater is a thin coagulum, extending over convexity of cerebrum pretty generally. At anterior extremity of left frontal lobe there is a rather thick clot, which extends into brain-substance. Latter is completely broken down, hemorrhage having probably taken place from vessels of brain-substance. Sphenoid lobe on same side is in similar condition, as is also posterior extremity of right hemisphere of cerebellum. Ventricles are normal, and in other respects brain is healthy.

There are several fractures of skull, viz. : one beginning in occipital bone in fossa for cerebrum of left side, and extending downward to the right through interior occipital protuberance, and onward through the fossa for the cerebellum on right side, obliquely to foramen magnum, which it enters on the extreme right of its circumference.

One on the right side, beginning in the foramen lacerum posterius and extending forward through the middle of the petrous portion of the temporal bone, and terminating in the roof of the tympanum. By removing this, the ossicles are found enveloped in a small clot of blood. There is no appearance of hemorrhage in the mastoid cells.

One on right side, starting at anterior condyloid foramen, and extending upward and forward to foramen lacerum posterius.

One on the left side, extending from the inferior maxillary foramen forward through the greater wing of the sphenoid to the foramen lacerum anterius.

One on the left side, through the petrous portion of the temporal bone, extending from the foramen lacerum posterius forward and inward through the roof of the tympanum, and onward to the inferior maxillary foramen, at which point it becomes continuous with the preceding fracture. On removing roof of tympanum ossicles are found as on other side, surrounded by a clot of blood. On this side there are clots in the mastoid cells.

The membranæ tympanorum are not affected, except that they show a slight bulging outward, caused by blood in tympani, as described above.

On careful examination, it was found that the fractures in both temporal bones extended into the semi-circular canals, and that on the right side the cochlea contained a clot. The right Eustachian tube is filled with clotted blood.

The symptom of visible bleeding from the ears is not, therefore, a necessary accompaniment of a fracture of the temporal bone. On the other hand, evidence of inflammation of the parts surrounding the drum-membrane affords excellent evidence of such a fracture.

Of the remaining symptoms, which may be ascertained without an examination of the drum-membrane, the most important, after hemorrhage from the ear, is that of a *watery discharge from the external auditory canal*. The significance of this symptom has, I think, been very fairly stated by Prescott Hewett in the article to which I have already made reference.<sup>1</sup> He sums up the matter in these words: "There are, then, as far as is known at present, three classes of cases of this watery discharge. In the first class, where the fluid from the ear is plentiful and of a decidedly watery character immediately after the accident, there need be no doubt as to the nature of the injury—the watery discharge is due to the escape of the cerebro-spinal fluid, which, as already stated, can only take place through a fracture of the petrous bone implicating the internal auditory canal and its membranes.

"In the second class of cases, characterized by a copious and prolonged bleeding from the ear, followed by a watery discharge, a fracture of the petrous bone may also be safely diagnosed; but it cannot be said that the fracture follows any particular course. In these cases it must, however, be clearly understood that it is not to the watery discharge that we can trust for our diagnosis, but to the copious and prolonged bleeding.

"Thus far there is no difficulty. Not so, however, in the third class of cases, in which there is at first a discharge of blood only, neither copious nor prolonged, which is followed by a watery discharge, varying as to the time of its appearance—varying as to its quantity. It may be present within a very few hours after the accident—it may be profuse within a few hours after its appearance. These are the cases in which experience has of late proved that the diagnosis ought to be doubtful. The discharge of blood

---

<sup>1</sup> Op. cit., Vol. II., pp. 291 and 292.



is certainly not of a character to warrant a diagnosis of fracture of the petrous bone ; and as to the watery discharge, it is now well known that such a discharge may occur within a few hours after the accident, that its quantity may even be profuse, and yet there may be no fracture."

Among my own cases there are but two in which the symptom of a watery discharge from the ear was well marked. In one of these a blood-stained watery discharge made its appearance soon after the accident, and continued for at least a week afterward. As the hearing was almost entirely restored in this case, it is safe to assume that the fracture did not involve the petrous portion of the temporal bone, but merely the tympanic or the squamous portion. The watery discharge was therefore probably purely inflammatory in its nature. In the other case a watery discharge was observed shortly after the occurrence of the accident, and continued for at least a week. Inflammation of the meninges then set in, and the discharge soon became purulent. As the hearing-power was totally destroyed in the affected ear, it is probable that the fracture involved the petrous as well as the tympanic portion of the temporal bone, and that the watery discharge was due largely, at first, to the escape of the cerebro-spinal fluid. In this connection, however, I should mention a fact with which every aural surgeon is familiar, and which should make us hesitate a long time before we pronounce a watery discharge, no matter how profuse, to be due to the escape of the cerebro-spinal fluid. The fact to which I refer is this : in exceptional cases of acute inflammation of the middle ear the flow of a thin serous fluid from that cavity, after a perforation has become established in the drum-membrane—whether by natural or by artificial means, it matters not—is so copious as to excite very great astonishment. I have known it to soak through several cloths in the course of a night, and to give place to a distinctly purulent discharge only after two or three days had elapsed. Furthermore, the breaking of the bony wall of the tympanum and the consequent laceration of the superjacent soft parts would supply an amply adequate exciting cause for such a high degree of irritation of the tympanic mucous membrane as this profuse watery discharge would imply.

Once more I desire to call attention to the question of examining the ears of patients supposed to be suffering with fracture of the temporal bone. *The lesions demonstrable by the aid of the speculum and reflected light, in the soft parts immediately surrounding Shrapnell's membrane, furnish us with a valuable means of locating at least a part of the injury done to the temporal bone.* If a fracture or diastasis has occurred in the line of the Glaserian fissure, we should find either an actual solution of continuity in the soft parts, or a spot from which blood is escaping ; or, if one or two days have elapsed since the occurrence of the accident, we should not fail to find well-marked evidences of inflammation in the vicinity of Shrapnell's membrane, or along the anterior portion of the upper wall of the bony canal. The rent in the soft parts may even involve the drum-membrane proper.

On the other hand, all evidences of this local inflammation may disappear as early as during the fourth week following the accident.

In this connection the question naturally suggests itself, why may not the inflammation of Shrapnell's region, or the escape of blood from some point in this vicinity, or even an actual rent in the soft parts, owe its origin to something else besides a fracture or diastasis of the neighboring bone? In the light of this question let us examine some of these cases of assumed fracture in the neighborhood of the middle ear. For example, in the second case narrated above, the patient received a blow on the right side of the head, and the hemorrhage took place from the auditory canal of the same side. In this case, therefore, the hemorrhage might possibly have come from some superficial blood-vessel which had been ruptured by the violent concussion of the air in the auditory canal. In the first case, however, this explanation would be considered, to say the least, far-fetched. The man was struck on the top of his head by a falling plank, and blood escaped from one ear. In the third case the patient fell and struck upon the left side of the head, but her symptoms thenceforth all pointed to some serious damage done to the opposite ear, and inspection, four days later, showed it to be the seat of two significant lesions—inflammation of the parts near Shrapnell's membrane, and an extravasation of blood in the middle ear. In both of these cases there can certainly be no question of a violent concussion of the air in the auditory canal, and we are obliged to seek for some other cause. A fracture of the bone near Shrapnell's membrane, affords, as it appears to me, the only satisfactory explanation of all the phenomena observed. A fracture of the bone in this particular locality, where the soft parts are tense and inelastic, means, at the same time, a rupture of these soft parts. If the fracture follows the line of the Glaserian fissure,—and in many of the cases this is probably the course which the fracture takes,—we have a right to expect that in a certain proportion of them the tympanic artery, which lies in that fissure, will be torn. The copious bleeding from the ears, which is so often observed in these cases of fracture of the base, owes its origin, I believe, quite as frequently to the tearing of this artery as to the laceration of one of the more remotely situated venous sinuses. An artery that is surrounded by bony walls is more likely, when ruptured, to bleed for an unusually long time, than one whose muscular coats have an opportunity to contract and retract.

Thus far I have considered only those symptoms and visible lesions which point to fractures in two parts of the temporal bone, viz., the petrous portion and the tympanic portion. There are other symptoms, however, which enable us to still further define the course which the fracture may have taken. Thus, for example, in one of my cases there was *facial paralysis* on the same side as that on which the hearing-power had been destroyed. It was discovered shortly after the occurrence of the accident, before inflammation could have set in, and was undoubtedly due to the direct effects

of the violence. The simplest explanation would be that the line of fracture involved the facial canal, which lies just above the oval window (see cut on p. 361).<sup>1</sup> In another case the patient experienced considerable difficulty in swallowing. Without more accurate data than those which my notes of the case furnish, I can scarcely express an opinion upon the significance of this symptom. In a case of fracture of the base, recently seen by Dr. L. Putzel, of this city, the patient made precisely this same complaint; and, on closer scrutiny, the doctor discovered that the difficulty experienced was not in swallowing, but in masticating the food taken into the mouth. The masseter and temporal muscles of one side were paralyzed, and the patient was unable to protrude the lower jaw straight forward. The inference which he drew from this condition was, that the fracture had not merely involved the central portion of the pars petrosa (the patient had entirely lost the hearing in one ear), but had probably extended down to the very apex of the bone, causing injury to motor filaments of the fifth nerve. Finally, in the second case mentioned above, the combination of symptoms points, I believe, to a fracture not merely involving the tympanic or the squamous portion of the temporal bone, but extending probably through the posterior wall of the tympanum down to the lateral sinus, and perhaps even causing a rent in its walls. The daily chills, fever, and sweating; the development of a cough on the fifth day, and the profuse muco-purulent expectoration which soon became associated with it; the flushed face, prominent veins of the head and neck, and marked stupor; perhaps, also, the tenderness on pressure in the mastoid region—all these symptoms, it appears to me, are to be explained upon the assumption that a fracture, involving the fossa sigmoidea, caused a phlebitis of the lateral sinus, and this in turn gave rise to the pyæmic manifestations, and then to those of interference with the venous circulation (drowsiness and fulness of the veins).

It is a great mistake, it seems to me, to think that nothing is to be gained by an examination of the ears, in such cases, beyond the establishment of the diagnosis upon a somewhat firmer basis. The first examination will, as a matter of course, accomplish this result, but subsequent examinations, if made at proper intervals, should in many cases enable the surgeon to materially modify the severity of the inflammation which is almost certain to follow the violence done to the parts lying along the base of the brain. The timely establishment of a free opening in the membrana tympani, incisions in the inflamed and tense tissues in the neighborhood of Shrapnell's membrane, the free use of leeches and the warm douche—are not all these measures just as likely to be efficacious in a traumatic inflammation of the middle ear as in one of different origin? and may not the abatement of the inflammation in this limited area be sufficient to turn the scale in favor of recovery?

---

<sup>1</sup> Consult Eysell: *Archiv für Ohrenheilkunde*, Bd. VII., p. 208.

## CHAPTER IX.

### DISEASES OF THE MASTOID PROCESS.

#### ANATOMY.

At birth the mastoid process consists of a small, flattened tuberosity, containing but one cell of considerable size—the antrum (see Fig. 21). At puberty there is a distinct prominence, conical in shape, whose apex points downward, and whose length, in some instances, may measure as much as an inch and a quarter (Figs. 23 and 24). The substance of this bony prominence is formed of a number of small cavities, or cells, varying very greatly in size and shape. Some of these cells communicate with one another, and are lined with an extension of the mucous membrane of the tympanum. Others are simply filled with a fatty tissue resembling that which is found in the diploë of fresh bones. Zuckerkandl,<sup>1</sup> who examined one hundred mastoid processes in the fresh state, and one hundred and fifty macerated specimens, found that air-cavities were wholly lacking in twenty per cent. of the specimens, and that perfectly pneumatic mastoid processes, without any diploëtic spaces, represented only 38.6 per cent. of the entire number. Furthermore, he ascertained the fact that in some individuals only the lower half of the process is diploëtic, while the upper half is pneumatic. These comparatively recent researches<sup>2</sup> throw a great deal of light upon the pathology of acute and chronic purulent affections of the middle ear, and it is not so very improbable that the facts which they have established may even lead to the discovery of better methods of diagnosis.

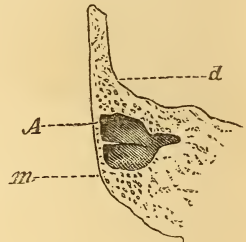


FIG. 21.—A vertical transverse section through mastoid portion of an infantile temporal bone: *d* = dura mater; *A* = antrum; *m* = rudimentary mastoid process. (Natural size.)

<sup>1</sup> Monatsschrift für Ohrenheilkunde, Bd. XIII., No. 4.

<sup>2</sup> Schwartze (Arch. f. Ohr., June, 1873, p. 169) makes the statement that, according to Zoja, diploëtic spaces are often found in the mastoid process, near its apex and on the median (inner) side. This is the earliest reference to the subject that I can find.

Such marked differences have been found in the size of the air-cells, in their limits of distribution, in the thickness of the bony partitions which separate them one from another, and in the thickness of the layer of bone which forms the outer side of the mastoid process, that no general statement can be made with regard to these points. If, in an individual who has not been subject to a chronic purulent inflammation of the middle ear, the process stands out very prominently from the side of the head, we may assume that the pneumatic spaces are well-developed, and that the outermost ones lie very near the surface. This was the case in the specimen represented in Fig. 24. The apex itself of the bone consisted of a single large cavity, in the upper and inner portion of which I counted three broad openings leading into adjacent cells. Above this cavity lay a series of

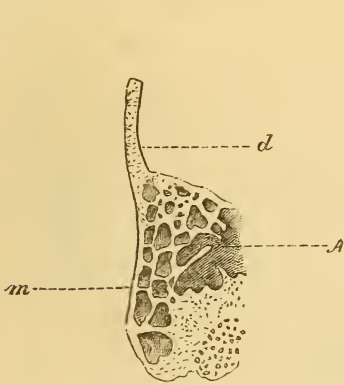


FIG. 22.—Mastoid process of a child (aet. circa 5), with well-developed air-cells or pneumatic spaces. Same section and lettering as in Fig. 21. (Natural size.)

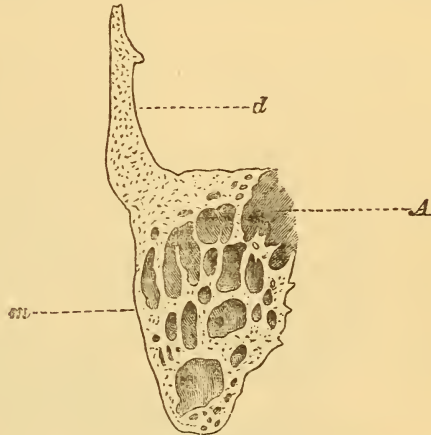


FIG. 23.—Mastoid process at puberty. Same section and lettering as in Fig. 21. (Natural size.)

smaller cells, in each one of which I found at least one opening that communicated with an adjacent cavity. Anteriorly, as will be seen in the cut, the pneumatic cells extend into that part of the temporal bone which constitutes the upper wall of the external meatus. Superiorly, they extend to within half an inch of the temporo-parietal suture. Posteriorly, they cease abruptly, and without any appreciable diminution in size, in the immediate vicinity of the temporo-occipital suture. In Schwartze's article (*loc cit.*), the statement is made that Hyrtl, out of six hundred skulls examined by him for this purpose, found three in which the pneumatic cells extended even into the occipital bone. Farther on (p. 351) will be found the history of a case of large abscess of the mastoid process, in which pus was also found between the outer and inner tables of the occipital bone, a short distance back of the temporo-occipital suture. At the time of the operation, I supposed that the pus occupied the diploëtic spaces natural to this region.

In the light of Hyrtl's discovery, however, it appears probable that the pus really occupied pneumatic spaces.

In the specimen which I have just described (Fig. 24), the external table of the bone measured scarcely a millimetre in diameter. Usually, however, in drilling into the bone from the outside, we do not reach the cell-structure at such a slight depth. The thickness of the outer layer of solid bone varies, I should say, from one to three millimetres.

In the distribution of its pneumatic cells, the temporal bone from which Fig. 24 was taken, must not be considered as an average type, but rather as an exception. The relations depicted in Fig. 23 more nearly represent the average cell distribution in the human adult mastoid process.

At the posterior and upper portion of the tympanic cavity is the entrance to the mastoid antrum, or "horizontal portion of the mastoid cells," as it is termed by Toynbee. In macerated specimens this entrance is com-

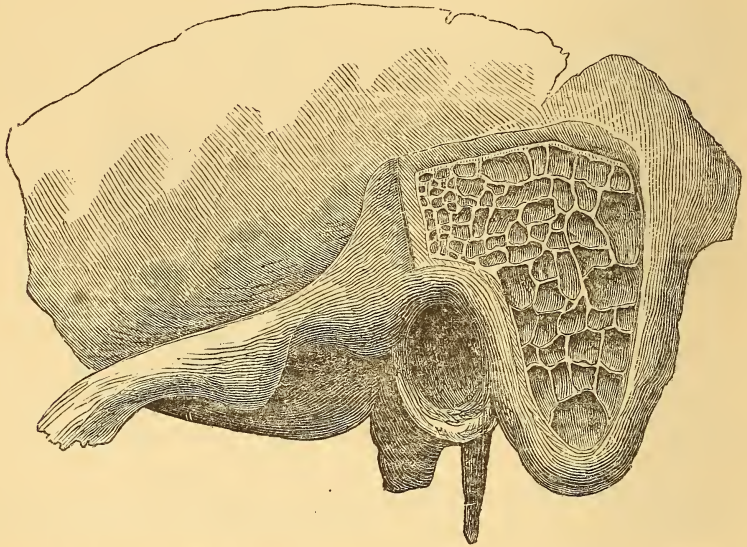


FIG. 24.—Mastoid process. External portion chiselled away to show how far the cells extend.

paratively broad, but in the natural condition of the parts, and especially when the mucous membrane is swollen from inflammation, it is a rather small opening. In the adult the antrum occupies a position from 12 to 20 mm. ( $\frac{1}{2}$ – $\frac{3}{4}$  in.) distant from the outer surface of the bone. In cases of hyperostosis, it is sometimes situated at a greater distance from the outer surface of the bone. It is separated from the dura mater by a plate of bone which rarely exceeds one millimetre in thickness, and as a rule is probably thinner than this. The posterior extremity of the antrum is separated from the lateral sinus by an interval of cell-structure which varies from three to five or six millimetres in thickness.

Finally, there are several points where the bone surrounding the antrum is pierced by small channels which give passage to blood and lymph vessels. The two most important of these are: 1, the sutura petro-squamosa, and 2, the channels for the mastoid emissary veins. One of the latter often opens on the outer surface of the mastoid process, near its centre, and about on a level with the upper wall of the external auditory canal. It is along the first of these channels that inflammation spreads from the antrum to the intracranial organs, and along the second that it reaches the subcutaneous cellular tissue on the side of the neck. The mastoid inflammation may also set up a phlebitis of one of these emissary veins and so lead to phlebitis and perhaps thrombosis of the lateral sinus, with which it directly communicates.

#### PATHOLOGY.

It is not my intention to undertake in this place a thorough exposition of the pathology of mastoid diseases, but simply to mention briefly certain points which seem to me to have an important bearing upon the diagnosis and treatment of these affections. Thus, for example, I think it is desirable to keep clearly before our minds the idea that *in both the acute and the chronic forms of mastoid disease, obstruction to the escape of the products of inflammation from the antrum is almost invariably the cause of those changes or processes which endanger the patient's life.* It is therefore a very rare thing to meet with a case of serious disease of the mastoid process in an ear whose membrana tympani has been destroyed; and when we do encounter such cases, we may look confidently for the presence of obstructive granulations at the tympanic orifice of the antrum.

In the second place, it must be remembered that in individuals who have been subject to a chronic purulent inflammation of the middle ear, the pneumatic spaces in the mastoid process may become completely obliterated through a process of sclerosis or hyperostosis. We are familiar with such a process of hyperostosis in the middle ear proper, and I can see no good reason why we should not accept the doctrine that the ivory-like hardness of the mastoid process, which we often encounter in operations upon that bone, is due, at least in a certain proportion of the cases, to an actual hyperostosis, and that this, in turn, owes its existence to a chronic subacute inflammation of the mucous membrane lining the pneumatic cells. I may also add that in chronic purulent inflammation of the middle ear, such a subacute inflammation of the mucous membrane lining the pneumatic cells is probably the rule. To test the correctness of this view, I have carefully examined the histories of Schwartze's fifty cases of perforation of the mastoid process (with drills or with gouges). In twenty-three out of the fifty a chronic purulent inflammation of the middle ear, of not less than five years' duration, preceded the acute symptoms which induced Dr. Schwartze

to perform the operation of perforating the mastoid process; and in thirteen of this number, —56½ per cent.,—complete or nearly complete sclerosis of the middle and upper portions of the process was found. Of the remaining ten cases there are four in which no mention whatever is made of the condition of the bone, and six in which it is distinctly stated that there was no sclerosis. In these six cases, however, it is quite possible that sclerosis of the mastoid process, or at least of that portion of it which is ordinarily exposed to view by the operation, could not have taken place, simply because these parts had already, during the earlier stages of the disease (perhaps even years before the operation was performed), been destroyed by carious processes. Out of five cases of my own, which were similar to Schwartze's twenty-three cases, there were four, —or 80 per cent.,—in which more or less pronounced sclerosis of the mastoid process was found at the time of the operation or on post-mortem examination. In the light of the evidence afforded by Schwartze's and my cases, therefore, we may establish the following rule: *The existence of a sclerosed condition of the mastoid process may be assumed in the great majority of cases of chronic purulent inflammation of the middle ear.*

The facts established by Zuckerkandl's researches, make it easy for us to understand how a large abscess may develop in the mastoid process in a comparatively short period of time. We have only to assume that this bony prominence is perfectly pneumatic, and there is then no difficulty in understanding how, if the inflammation of the middle ear be allowed to go on unchecked for a certain period of time, these large and freely intercommunicating pneumatic cells may become filled with pus, and how, later, under the influence of ulcerative processes, the bony septa between the cells may undergo disintegration, thus converting the entire bony prominence into an abscess imprisoned in a shell of bone.

#### GENERAL CLINICAL HISTORY.

Inflammation of the mastoid process is characterized by a great variety of symptoms, according to the duration and degree of severity of the inflammation, the part or parts of the organ implicated, and the extent to which it has involved neighboring organs. In accordance with the anatomical limits of the inflammation, we may distinguish three classes of mastoid affections, viz.: 1, those in which the antrum is the part chiefly involved; 2, those in which the surrounding body of the bone participates in the inflammation to an equal or decided degree; and 3, those in which the prominent feature of the disease is a periostitis of the outer aspect of the bone. There are no sharply drawn boundary lines between these three classes, nor are they in any sense separate and distinct affections. There are practical reasons, however, why we should endeavor, in each case of



supposed mastoid disease, to assign it to its appropriate place in one of the three classes mentioned.

I. *Affections in which the Antrum is the Part chiefly Involved.*

In all the inflammatory affections of the middle ear the antrum, which may be considered as a mere diverticulum of the tympanic cavity, must almost necessarily participate. In the great majority of cases, there are no symptoms which call our attention in the slightest degree to this particular portion of the middle ear. In a few, however, the antrum becomes the seat of pathological changes which call for special therapeutic measures, and which may even assume such prominence as to render the original disease of the tympanic cavity of decidedly subordinate importance.

Probably the simplest form of clinically recognizable antrum disease is that to which may be given the name of

*Chronic subacute purulent inflammation.*—In the treatment of the great majority of simple, uncomplicated cases of chronic purulent inflammation of the middle ear, little or no thought, I suspect, is given by physicians to the antrum, as a locality which may need separate attention. So far as my own practice is concerned, I have, up to a recent date, entirely ignored this portion of the middle ear, at least in the class of cases to which I have just referred. At the same time I have often been puzzled to know why, in so many cases, in which apparently all the conditions were favorable to success, my efforts to arrest the discharge should have proved fruitless. I had searched carefully for some concealed spot of caries of the bony walls of the tympanum or for some granulating point in its lining mucous membrane, but had failed (in these particular cases) to find any such cause for the persistent otorrhœa. It then occurred to my mind that possibly the discharge might come in large part from the antrum, and that treatment directed more especially to this cavity would result in the complete arrest of the discharge. I soon had an opportunity of subjecting this view to a practical test. Three cases of chronic purulent inflammation of the middle ear were placed under my care for treatment at nearly the same time. In all three of them the pathological conditions were almost precisely the same. In the first case the patient was an adult, forty-five years of age; in the other two, the patients were respectively twelve and fourteen years of age. All of them were in good health, so far as I could judge. In the case of the adult there had been no discharge from the ear for a period of several years. Recently, however, without any known reason, the discharge had reappeared, and at the time when he consulted me it had been going on for a period of several weeks. In the second case the discharge had existed for about one year, the child having contracted the disease during an attack of scarlet fever. In the third case the discharge had existed (though not continuously) for a period of several years. In all three cases

the membrana tympani was practically destroyed, and in all three the mucous membrane of the inner wall of the tympanum was very much swollen. In addition to this diffuse swelling of the mucous membrane, there was in each case a circumscribed growth of granulation-tissue, located just behind the promontory in two cases, and just above the centre of it in the third case. The entrance to the antrum in the latter case was so contracted that I could barely introduce the tip of the middle-ear pipette into it. In the other cases the entrance appeared to be of natural size. In all three cases I assumed that the irritation which had caused the swelling of the mucous membrane of the inner tympanic wall, was supplied by the secretions from the antrum. The treatment adopted was in brief the following: first, the removal of the masses of granulation-tissue in the tympanum with the snare; second, cauterization of the remaining raw surface with a bead of nitrate of silver; third, the washing out of the mastoid antrum with lukewarm water; fourth, the injection into that cavity of a two-grain solution of nitrate of silver; fifth, the application of powdered burned alum and iodoform in small masses to all that portion of the tympanic mucous membrane which was visible. The first two steps were found necessary only at the first visit. The remaining steps were carried out at each succeeding visit. In two out of the three cases the discharge was entirely arrested after the fifth or sixth visit. In the third case it was arrested still earlier, but it returned very slightly after the lapse of a few days, and the case is still under treatment. This last case is the one in which the entrance to the antrum is very much contracted. In this case I also observed that the water which escaped from the antrum after washing it out, was quite milky in appearance.

The evidence afforded by these cases is, I fully appreciate, susceptible of a different interpretation from that which I am disposed to adopt. Thus, for example, the objection may be raised, that the arrest of the discharge was due to the restoration of the tympanic mucous membrane proper to a fairly healthy condition, by means of those remedial measures which were directed particularly to that portion of the middle ear, and not to any improvement in the condition of the mucous membrane of the antrum that may have been brought about by the measures directed especially to that locality. To this objection I would reply that, in one of the cases, I at first paid no attention whatever to the condition of the antrum, and failed to secure as the result of my strictly tympanic treatment, more than a diminution in the activity of the discharge; while in the same case, a few months later, I experienced no difficulty, by treating the antrum in the manner already mentioned, in very soon arresting the discharge permanently. I cannot help feeling that in the other two cases also the antrum treatment had a great deal to do with the promptly favorable results obtained.

When I have had more experience in this (to me) new plan of manag-

ing a certain class of cases of chronic purulent inflammation of the middle ear, I may be able to speak more positively with regard to the propriety of conceding a certain degree of individuality to such a chronic subacute purulent inflammation of the mastoid antrum. In the meantime, however, I would urge those of my colleagues who are in the habit of treating cases of chronic purulent inflammation of the middle ear, to adopt special antrum measures in those instances in which the disease seems to resist all the ordinary methods of treatment, and in which there are no demonstrable lesions of a sufficiently pronounced character to explain the obstinacy of the discharge.

Before dismissing this subject I will give a brief account of a case which I saw in 1872, and which I even at that time was disposed to consider as belonging to the form of disease which I am now considering.

CASE I.—The patient, a rather pale medical student, but yet in fairly good health, consulted me in March, 1872, for an otorrhœa of fifteen years' standing. It had established itself as a sequela of scarlet fever, and was accompanied by constant tinnitus and by frequent attacks of a dull, steady pain, referred to the deeper parts of the ear. Various methods of treatment had been pursued, but the discharge had never materially diminished. An inspection of the ear showed the membrana tympani to have been entirely destroyed, the handle of the hammer resting against the promontory, the mucous membrane being pale and very fibrous in appearance, and the posterior upper portion of the tympanic cavity being filled with a small mass of granulations which seemed to grow from the entrance to the antrum. There was no tenderness over the mastoid process. The watch could be heard at a distance of 7 inches. A few applications of chromic acid were made, and the granulations shrank entirely out of sight behind the projecting angle of bone.

The subsequent treatment consisted in introducing a probe, armed with cotton, thoroughly cleansing and drying all the parts within reach, and then applying nitrate of silver in solution (the strength being gradually increased from twenty grains to a drachm to the ounce of water). At the expiration of two weeks the discharge was just as abundant as at the first. On the 29th of March, I substituted powdered alum for the silver solution, blowing it in with a suitable tube. The quantity used was just sufficient to form a thin layer over the exposed mucous membrane. On the 30th the patient reported that there had been almost no discharge since the last application. The alum was accordingly applied a second time, after all the remains of the first charge had been removed. This second application was followed in the course of an hour by dizziness, nausea and vomiting, and a throbbing sensation in the ear, without tinnitus. Objects appeared blurred before his eyes. Two hours afterward he had a second similar attack, which compelled him to take to his bed. The dizzi-

ness and nausea continued then for nearly forty-eight hours, when the discharge reappeared, and he was again able to walk about.

In view of the long continuance of the discharge, of the frequent, dull, deep-seated pain, of the presence of granulations which sprang from the entrance to the antrum, and from the throbbing sensation which ensued, when that entrance became closed,—as it doubtless did when the alum was applied,—it appeared to me probable that the case was one of chronic subacute purulent inflammation of that cavity.

*Acute inflammation, probably without caries.*—In all cases of acute inflammation of the middle ear the antrum undoubtedly participates in the inflammatory process to as great a degree as does the tympanic cavity proper. In this sense, therefore, acute inflammation of the antrum may be said to be a very common affection. The clinical picture presented under these circumstances, however, is the familiar one of an acute inflammation of the middle ear, and the distinctive participation of the antrum is only recognizable in exceptional cases. Thus, for example, in the following cases, the evidence showed conclusively that the mastoid region was participating to more than the usual degree in the general inflammation of the middle ear. The only element of doubt relates to the question whether, among the component parts of the mastoid process, the antrum alone was involved, or whether the surrounding pneumatic spaces were not also, and to an equal extent, inflamed. Pain in the mastoid region and over the corresponding side of the head, redness and swelling of the upper and posterior wall of the meatus in the immediate neighborhood of the membrana tympani, only slight tenderness on pressure over the mastoid process, and particularly over its upper portion, and no noticeable redness or swelling of the mastoid integuments, these are the symptoms which, as it appears to me, would justify us in drawing the conclusion that the inflammation was still restricted chiefly to the mastoid antrum.

CASE II.—The patient, a man seventy years of age, in good general health, came to the Infirmary on the 3d of November, 1873. He said that about six weeks previously he began to suffer from pain and deafness in the right ear. Two weeks later a discharge made its appearance, but the pain continued with but little if any abatement. On examination I found the meatus filled with pus. The upper portion of the drum-membrane was red and swollen, and presented an appearance of pouting; elsewhere it exhibited a very tough appearance. I made a free incision through the posterior half of the membrane, and also through the posterior fold, and prescribed the use of the warm douche at home.

November 5th.—Pain still continues, but it is decidedly less severe.

November 8th.—Discharge has ceased. Pain is now referred only to the mastoid region, where there is tenderness on pressure, but no redness or swelling of the skin. Four leeches to be applied over the spot of great-

est tenderness, which corresponds to the point of entrance of the principal mastoid emissary vein.

November 12th.—Dull pain still continues in the mastoid region. Tincture of iodine to be applied daily to the painful locality. The membrana tympani still retains a red and swollen appearance, but there has been no discharge for nearly a week past.

November 15th.—Persistent dull pain in mastoid region. No perceptible benefit from the iodine. Mastoid integuments freely incised, and the sides of the wound thoroughly cauterized with nitrate of silver, after the bleeding had entirely ceased.

November 19th.—External wound suppurating freely. Pain almost entirely relieved.

November 22d.—Wound healing rapidly. Patient complains now only of a roaring sound in his ear. (He was not seen again.)

CASE III.—Female, thirty-two years of age and in robust health, she was attacked with an influenza on the 9th of November, 1872, and had more or less fever, with a constant catarrh of the eyes and nose. On the 12th, the right ear became involved, the symptoms being moderate deafness, roaring and some pain. Watch heard at a distance of six inches. External auditory canal healthy. Membrana tympani dull, opaque, and rather flatter than normal. The air during inflation entered the middle ear with a dry sound. Four leeches applied in front of the ear.

November 14th.—The leeches afforded only partial relief. Membrana tympani cedematous in appearance and somewhat convex outwardly.

November 15th.—Patient passed a bad night. The pain is again severe, and is referred by her to the entire side of the head. Tenderness on pressure over the mastoid process, but no redness or swelling of the integuments. The posterior wall of the external auditory canal has also become tender upon pressure. A free vertical incision through the posterior half of the membrane was followed by an oozing of bloody serum from the wound. By inflation of the middle ear through the Eustachian catheter the serum was made to escape in such quantity that it ran down over her cheek.

November 16th.—Comparatively free from pain last night. The watery discharge continued through the night, as shown by the stains on the pillow. The tenderness has disappeared, and patient feels quite well again. No subsequent return of the pain.

CASE IV.—Female, about thirty-five years of age, and of a rather delicate constitution. January 20, 1877. Two days ago, while suffering from a bad "cold in the head," and not very long after snuffing salt water for the relief of her trouble, she was seized with a rather sharp pain in the right ear. Yesterday, the pain in the meantime having grown worse, five

leeches were applied behind the ear. These afforded only temporary relief, and, as a consequence, she was able to get but little sleep during the night. To-day the pain has been severe. On examination with the speculum and reflected light, the membrana tympani, and especially the upper and posterior portion, is found to be red and swollen. Two small blebs, springing from the lower wall of the canal, conceal the lower part of the drum-membrane from view. Incision of posterior half of the membrane afforded escape to a drop of bloody serum. Warm douche to be used freely. Patient to remain in bed.

January 21st.—She has passed another night of suffering. There is now a free sero-purulent discharge, but the pain has not abated. On examination the posterior wall of the meatus is found to be greatly swollen in the vicinity of the drum-membrane. Tenderness over the mastoid process, but no redness or swelling of the integuments. Patient being under the influence of ether, two free incisions were made through the inflamed tissues of the external auditory canal and posterior fold of the drum-membrane, and a third through the mastoid integuments. Tent introduced into the external wound. Poultices to be applied, and patient to be given 10 minims of Magendie's solution of the sulphate of morphia.

January 22d.—She passed a fairly comfortable night, and to-day feels comparatively free from pain. Tent removed.

January 23d.—Pain again moderately severe. The discharge from the ear is now decidedly purulent. Pulse, 104; temperature, 99.2° F.

January 24th.—Pain still persists throughout the entire right side of the head, and is especially noticeable whenever she coughs.

January 25th.—Last evening pain again became quite severe. Temperature rose to a little over 100° F. Four leeches were applied in front of the tragus. This morning patient feels better. The discharge is now profuse. Temperature normal. Patient is conscious of a constant escape of pus through the Eustachian tube into the back part of the nose. From the character of the matter expectorated (absence of mucus) and from the sensations experienced by the patient, I have very little doubt that the discharge referred to comes from the middle ear by way of the Eustachian tube. Swelling of inner end of meatus diminishing.

January 26th.—Continued improvement. Temperature, normal; pulse, 88. Tubal discharge diminishing; discharge from the meatus still active.

February 3d.—Patient is now entirely free from pain, and there is very little discharge from the ear.

February 14th.—The perforation in the drum-membrane has healed, and very little swelling of the parts remains. An insignificant scar indicates the location of the incision behind the ear. Watch heard at a distance of 4 inches.

In children an acute inflammation of the antrum may lead, in a compara-

tively short time, to inflammation of the coverings of the brain. The following case may serve as an illustration.

CASE V.—The patient, a girl, six years of age, and of apparently delicate constitution, was seen by me for the first time on January 4, 1876. About four weeks previously she had passed through a rather severe attack of pharyngeal diphtheria, from which she had scarcely recovered, when she began, about one week previously, to complain of pain in both ears. The pain, which soon became severe, had continued with unabated severity up to the time when I saw her, robbing her of sleep and of all desire to take nourishment. On the day when I was asked to see her she had been a little delirious at times. Temperature, 105° F.; pulse, 140. The deafness seemed to be almost total. Examination with the speculum and reflected light showed the right drum-membrane to be red and swollen in its upper portions, and somewhat bulging superiorly and posteriorly; the parts were perfectly dry. On the left side the external meatus was partly filled with masses of whitish moist epithelium. The drum-membrane was red and swollen. There was no redness, swelling, or tenderness of the mastoid integuments on either side. I made a free incision through the posterior half of each membrana tympani. Only blood was evacuated by the incision. Warm douche to be used freely, also poultices.

January 5th.—No improvement. Temperature, 105° F.; pulse, 140, and feeble; sordes on teeth; tongue dry; no discharge from either ear. Child lies as if in a state of partial coma. At the suggestion of Drs. Markoe and James R. Wood, who were called in to see the child, mercury was administered: internally, in the form of calomel, in small doses; externally, in the form of unguents of the oleate of mercury (10 per cent.), frequently repeated. Bromide of potassium was also given, in conjunction with the calomel.

January 6th.—Yesterday the child was decidedly delirious, especially toward night, and cried out, at intervals, with pain (referred to the left ear chiefly). This morning, however, the child is very much better, an active discharge having established itself in both ears during the night.

From this time onward,—as I learned from her physician, Dr. A. A. Davis,—she made a rapid recovery, and regained her hearing almost perfectly.

In the four preceding cases I am disposed to believe that the inflammation at no time involved the pneumatic cells to any considerable extent. In the case last narrated (Case V.) the inflammation extended to the coverings of the brain—probably by way of the blood-vessels and other soft parts that pass from the antrum to the cranial cavity through the fissura petro-squamosa, and this complication for a short time completely overshadowed the original disease. The mastoid pneumatic spaces may have been imperfectly

developed, in this case, and so have offered an obstacle to the extension of the inflammation in an outward direction ; or the vascular connections between the dura mater and the mucous membrane of the antrum may have been more numerous than they usually are, and so have favored the spread of the inflammation from the latter cavity to the meninges. In adults, the inflammation is apt to travel from the antrum proper, or from the series of pneumatic spaces immediately surrounding it, along the central emissary vein to the outer integuments. Pus may also find an outlet through this channel, and in this way sometimes a spontaneous cure may be effected. In the following four cases I think it is reasonably clear that the antrum was the part chiefly affected, and that the pus eventually found a way for itself, not through the intervening pneumatic or diploëtic spaces, which probably participated in the inflammation in only a subordinate degree, but along the bony channel normally occupied by the mastoid emissary vein.

CASE VI.—(New York Eye and Ear Infirmary.) Wm. B. Hillison, æt. forty-five, janitor, previously in good health. (Patient seen in consultation with Dr. Charles Laight.) In August, 1872, he overheated himself, and then sat in a draught of cool air. A few hours later, he experienced severe shooting pains in the right ear, and a throbbing sensation in the mastoid region. The pain continued, with varying severity, for ten days. At the end of this time a discharge appeared, and was soon followed by relief from pain. Early in November the discharge ceased, and the pain again became severe. This time it was referred chiefly to the region behind the ear, and was accompanied by some tenderness and swelling of the parts. The swelling gradually increased, and on December 14th he reluctantly decided to seek medical advice. His physician, Dr. Charles Laight, found the meatus swollen, and the mastoid region these at of quite a large swelling. A free incision through the mastoid integuments liberated about an ounce of healthy pus. No denuded bone detected.

December 15th.—Pain relieved. A profuse sweat to-day.

December 16th.—Mastoid region again moderately painful. Wound healing by adhesion. Occasional pain in the right chest.

December 18th.—To-day I saw the patient for the first time, in consultation with Dr. Laight. The pain again severe. The countenance pale. Pulse 108, and feeble. Holds his head as if suffering from a stiff neck. The skin and subjacent tissues over lower portion of mastoid process, and extending at least two inches below it, are soldered by inflammation into a single, flattened, hard mass, red on the surface. Tenderness on pressure, extending up toward squamous portion of temporal bone. Meatus very much swollen, and filled with fetid pus. A small mass of granulations on posterior superior wall of meatus, just beyond the junction of the cartilaginous with the osseous portion. From this point a sinus leads to exposed but apparently not carious bone. Deeper parts of the meatus not recog-



nizable. Perforation of the mastoid process advised, and patient recommended to enter the New York Eye and Ear Infirmary. The operation was performed the same afternoon by Dr. Laight. The perforation was made with a drill, which was applied at a point half an inch behind the meatus, a little below the level of the upper wall, and was directed inward, decidedly forward, and a little upward. The instrument first encountered cell-structure at a depth of three-fifths of an inch. No pus. Ordered decubitus, poultices, generous diet, iron and quinine, and sherry wine,  $\frac{3}{4}$  vi. daily.

December 19th.—Almost entire relief from pain. Pulse 90, and stronger than yesterday. Meatus still swollen. Takes food well.

December 20th.—Free discharge from the wound and from the meatus. Steady improvement. The wound and the meatus both to be syringed frequently with a weak solution of carbolic acid.

January 18, 1873.—The wound has entirely healed except at one point, where a small sinus leads to the perforation in the bone. The sinus in the meatus has also closed. Since the 8th of January there has been no discharge from the meatus. A small perforation still present in the membrana tympani. General condition greatly improved. No return of pain since the operation.

January 29th.—Patient is to-day discharged cured.

CASE VII.—Male, twenty-one years of age, in good general health (New York Eye and Ear Infirmary), November 3, 1875. About three months ago he contracted a severe earache in the left ear from bathing in salt water. The pain continued to be severe for a period of two weeks, and then became bearable. About six weeks ago the pain again returned and has continued with, on the whole, increasing severity up to the present time. Besides the pain and deafness he has noticed a roaring sound in the affected ear, but never any discharge. The pain now involves the entire side of the head. On examination, I find the inner half of the meatus filled with a dark-colored material looking like a mixture of cerumen and pus. There is no appreciable redness or swelling of any part of the canal. The drum-membrane is covered with a tough, whitish material—undoubtedly a soaked and thickened layer of epithelium—which completely conceals the outlines of the hammer. A V-shaped incision was then made in the membrane, but it was not followed by any escape of fluid. By lifting up the flap, it was observed that the middle ear was filled with a semi-gelatinous substance (see page 205), which very soon, however, became infiltrated with blood. Nothing abnormal observed in the region of the mastoid process.

November 6th.—Since last note there has been a constant discharge from the left ear. To-day, for the first time, the pain has been appreciably less severe than usual.

November 17th.—During the past few days there has been no discharge from the ear. The parts behind the ear, however, have become tender and

swollen. On examination I find the external auditory canal dry, and the perforation in the drum-membrane healed. The membrane has a tough, leathery appearance, and there are no evidences of inflammatory action in the immediate vicinity. The swelling behind the ear is found, on examination, to be due to the presence of a collection of fluid beneath the skin. Fluctuation can be felt not only behind the ear, but also above it. A free incision affords escape to quite a large quantity of pus, and the probe reveals the fact that it lay, at least in part, between the periosteum and the bone. While exploring the denuded bone surface, I discovered an opening, just large enough to admit the probe, at a point about an inch and three-quarters immediately above the tip of the mastoid process. The direction of the opening was upward, inward, and a little backward, and the probe passed into this bony canal a distance of half an inch without encountering any resistance. A fresh tent to be introduced into the wound daily.

November 20th.—Entire relief from pain since abscess was opened. Wound healing rapidly. Almost no tenderness in the vicinity. (No further data.)

CASE VIII.—Male, forty-two years of age and in good general health. May 17, 1879. (Case seen in consultation with Dr. E. T. Ely and afterward with Dr. Roosa.) Six days previously patient first began to suffer from a sensation of fulness and pain in the right ear. Dr. Roosa examined the ear and found the membrana tympani moderately inflamed. Two leeches were applied, but only temporary relief was afforded. As the pain continued to increase, Dr. Roosa incised the membrane. The relief lasted but a short time, and leeches were again applied. All these measures having failed, the warm douche was tried faithfully. The pain, however, has gone on steadily increasing during the past three days, until now it is very severe. On examination to-day (in consultation with Dr. Ely, who has taken charge of the case during Dr. Roosa's absence), the drum-membrane is found to be red and greatly swollen. The neighboring cutaneous walls of the meatus are also very much inflamed, and almost entirely conceal the membrana tympani from view. The parts are slightly moist. There is no tenderness over the mastoid process. The patient being under the influence of ether, the membrana tympani was punctured at its centre, and the incision was carried directly backward until the knife encountered the bone; the incision was then extended outward, a distance of fully one-third of an inch, through the swollen tissues of the canal, the point of the knife being kept in contact with the bone throughout. A free escape of blood followed the incision, but no pus was observed. Five leeches ordered; four to be applied in front of the ear, and one behind. Warm douche to be used freely.

May 18th.—During the night, after the free use of the warm douche,

an active purulent discharge set in, and the patient began at once to experience relief from pain. This morning he feels decidedly better.

May 19th.—Patient passed a comfortable day yesterday, but toward night he again experienced pain in the ear and right side of the head, though in a much milder form. To-day he feels quite free from pain. The discharge continues to be abundant.

May 20th.—Yesterday afternoon the pain returned with all its previous severity. Temperature (beneath the tongue) was 101° F.; pulse, 92. Three leeches were applied behind the ear, close to the auricle, and the after-bleeding was allowed to continue for some time after the leeches had fallen off. After a hot foot-bath had been given to the patient, he fell asleep and slept through the entire night. This morning his temperature is 98.8° F. He is very low-spirited about his condition, but expresses himself as being free from pain. Ordered two compound cathartic pills, his bowels being sluggish.

May 21st, evening.—At 8 P.M. last evening, patient's temperature was 100° F. He had taken his food well, and had been free from pain. As the compound cathartic pills had failed to accomplish their purpose, he was ordered to take four grains of blue pill that same evening and a full dose of Hunyadi Janos water the following (this) morning. To-day, with the exception of a short attack during the afternoon, he has been quite free from pain. Two copious movements of the bowels have taken place. The swelling of the inner end of the canal is as marked as it was on the 17th. and the discharge is still profuse. Temperature, 99.5° F.

May 22d, evening.—This morning, the pain having again become severe, two leeches were applied behind, and one in front of, the ear. These afforded only temporary relief. This evening the pain is again severe. It shoots, as he describes it, from between the occiput and the mastoid process, up over the side of the head. Temperature, 99.5° F. Tenderness on pressure over the region situated just behind the mastoid process. Blister to be applied to this spot. Patient now takes, for the relief of his pain, a twelfth of a grain of sulphate of morphia every three or four hours.

May 23d.—Patient passed a fair night, but to-day the pain is again severe. Discharge from the ear continues to be active, and the swollen condition of the drum-membrane and meatus does not abate. There is decided œdema, to-day, of the skin covering the mastoid process. Temperature, 99.5° F. Pulse, 86. Magendie's solution of morphine, ten minims, to be given hypodermically, to relieve the pain.

May 24th.—Patient passed a comfortable night; morphine being now administered as often as is necessary for the purpose of relieving pain. Tenderness on pressure over the mastoid process is more decided to-day. Temperature normal.

In view of the persistence and increasing severity of the pain, notwithstanding the vigorous antiphlogistic measures employed; of the profuse-

ness of the otorrhœa, indicating the activity and extent of the inflammation ; of the persistent swollen condition of the inner end of the meatus ; of the recent development of tenderness and œdema of the mastoid integuments ; and, finally, of the danger in which the patient would be placed, if the inflammation should continue to extend unchecked ;—in view of all these facts, and of the safety of the operation, I suggested to Dr. Ely the desirability of obtaining the patient's consent to having the mastoid process perforated at an early day. The doctor explained the matter fully to the patient,—himself a physician,—and, at the latter's request, Dr. C. R. Agnew was asked to see him and pass judgment upon the propriety of performing the operation. Dr. Agnew examined the case carefully, and expressed the opinion that the proper time had not yet come for the operation. Dr. Roosa, who had by this time returned from a brief sojourn in the country, also concurred in this opinion, but favored a free incision of the skin and periosteum of the mastoid process. Such an incision was accordingly made on the following day, May 25th. The bone at the bottom of the wound was found to be perfectly sound, so far as we could discover. Dr. Roosa now resumed charge of the case.

On the 16th of June I again visited the patient, and learned that the incision of the mastoid integuments had afforded only temporary relief. On the 27th and 28th of May, quinine was given in large doses (70 grains in the course of the two days), in the belief that the pain might be of a neuralgic (malarial) character. The patient, it appears, had quite recently experienced a very severe attack of facial neuralgia, and this fact gave some color of probability to the view that a neuralgic element complicated the present illness. The quinine treatment, however, afforded no relief, and it was abandoned. On the 7th of June, as I was informed, the pain which had previously been referred to the entire right side of the head, as well as to the ear and its immediate neighborhood, localized itself chiefly just below the mastoid process. Coincidentally with this change, right facial paralysis manifested itself (upper eyelid and the side of the mouth involved), and a well-defined swelling appeared just below the mastoid process. The power of the right side of the tongue to distinguish between bitter, sweet, acid, and salty, had not—as I was told—been affected. On examination, I find, just beneath the mastoid process, a flat, hard swelling, consisting evidently of diffusely inflamed connective tissue and cervical lymphatic glands matted together into an irregularly shaped mass. The skin covering these parts and the lower portion of the mastoid process is moderately congested. The discharge from the ear continues to be abundant. The improvement, which had begun already two or three days before, simultaneously with the development of the characteristic swelling on the side of the neck, continued steadily from that time onward. The discharge from the ear very soon ceased, the patient's strength gradually returned, and he was soon able to leave the city for his summer vacation in the country.

At the present time (August 15, 1879) paresis of the facial still continues, but it is much less noticeable than before he went into the country. (Shortly afterward every trace of the disease disappeared.)

In each of the preceding seven cases the acute inflammation developed in a middle ear whose membrana tympani was probably at the time intact. In each of the following cases the inflammation seems to have developed in an ear whose drum-membrane was undoubtedly at the time defective. It is difficult to explain satisfactorily the progress of the disease in these cases, unless we assume that at an early stage of the inflammation the tympanic orifice of the antrum became closed.

CASE IX.—Dr. A. P. W., of Chester, S. C., æt. 56, of a strong constitution, consulted me, October 12, 1872, for a painful affection of the mastoid process. He gave the following history: In 1835 he contracted an acute inflammation of the left middle ear from the bursting of a gun-barrel. The severe symptoms soon passed off, but the purulent discharge continued for some time afterward. Since that time, however, the ear has not troubled him in any way, except that there has been a moderate degree of deafness and some tinnitus. The perforation in the membrane has always persisted. About the middle of last July he noticed a slight serous discharge from the left ear, and felt a little pain in it. The pain became gradually more severe and was associated with headache and fever. The doctor bled himself to the extent of about sixteen ounces; six hours later he took from the arm an additional quantity of about eight ounces. A profuse suppuration from the ear soon took place and the pain then became tolerable. For a month no marked change occurred in the condition of the ear. The discharge continued, but at times it would almost stop. On the 23d of August he had a rigor, which was followed by a return of all the acute symptoms. The pain was referred to the base of the brain, the mastoid process and the articulation of the jaw. That night the pain, according to his own words, was very severe. Bleeding, to the amount of twelve or fifteen ounces, afforded some relief, and the discharge again became abundant. For a week the pain remained unbearable. On the 31st of August he had another rigor, followed by intense pain, referred to the mastoid process, and thence backward toward the occiput and occipito-vertebral articulation; in fact, the whole side of the head was painful. There was tenderness over the mastoid process and the auricle was pushed somewhat out from the head. On the 2d of September, Dr. Darby, at that time Professor of Surgery in the University of Columbia, S. C., and Dr. Robinson, of Winsboro', were telegraphed for, but by the time they arrived the discharge had reappeared, and the pain had moderated. The mastoid region, however, was still swollen and quite tender on pressure. On the 18th of September, no improvement having taken place in his condition, the doctor started for New York in the

hope of obtaining relief there. The sea voyage from Charleston benefited him very decidedly. The severe symptoms abated, and for some time after reaching this city he enjoyed, at least during the day, comparative comfort; toward night, however, the old trouble returned with greater or less severity. During the few days preceding his visit to me he suffered acutely from pain in the ear.

On examination the meatus was found to be normal; the membrana tympani was perforated anteriorly, the opening measuring about two millimetres in diameter and having sharply cut edges; the Eustachian tube was freely pervious, and there was only a trace of pus in the middle ear. Mastoid region œdematous and tender on pressure. The tenderness also extends back toward the occiput. General condition fair. Pulse a little over ninety. No heat of skin. At a consultation with Professor James R. Wood and Dr. Herman Knapp, it was deemed best to perforate the mastoid process. At the patient's own request the operation was performed without ether. The appearance of the bone, after the periosteum had been lifted aside, was entirely normal. The drill was applied on a level with the upper wall of the meatus, and made to penetrate to a depth of three-fifths of an inch without encountering mastoid cells. At this depth, however, a tolerably firm pad of connective tissue was felt. The supposition at the time was that this mass filled the antrum, but on subsequent inspection I became persuaded that, owing to the thickness of the swollen integuments, and the recumbent position of the patient, I had erred somewhat in the direction which I gave to the drill, pointing it too far backward. The pad of connective tissue was undoubtedly the outer wall of the lateral sinus.

October 13th.—Patient passed a fairly comfortable night. Pain much easier than before the operation. Ordered quinine (gr. ij., t.i.d.).

October 14th.—Pain again severe. Consultation with Drs. Robert F. Weir (Professor Wood out of town) and Herman Knapp. A second perforation was made, this time nearer to the meatus and on a lower level than the first. Mastoid cells small in size and congested; intervening septa thick and hard; no pus found. Tent inserted; poultices.

October 15th.—Slight improvement. Appetite rather poor. Ordered tinct. ferri chlor. gtt., x., with each dose of quinine.

October 16th.—Appetite better. Temperature 97°. Pain diminishing. Ordered carbolic acid dressings to wound, from which there is a free discharge.

October 17th.—Marked improvement in every respect. Poultices to be stopped.

October 23d. Tenderness over mastoid process almost gone.

November 14th.—Feels quite well again. There is no discharge from the meatus, and the wound behind the ear has healed except at two points, corresponding to the two sinuses which lead to the perforations in the bone. Patient proposes to return to South Carolina.

A few weeks later I heard from the doctor that there had been no return of the pain, and that his general health was quite good again.

CASE X.—Boy, seventeen years of age, in fair general health (New York Eye and Ear Infirmary), November 7, 1874. He has had a discharge from the left ear during the past ten years. About two weeks ago the discharge ceased, and he then began to suffer from pain in the left ear. The parts behind the ear soon became tender and swollen, and the pain extended throughout the entire left side of the head. On examination to-day, I find the external auditory canal filled with inspissated pus. The drum-membrane is perforated anteriorly. The skin covering the mastoid process is red, swollen, and tender on pressure. A deep incision, made in the usual situation, is followed by such active arterial hemorrhage, that no further exploration of the parts can be made at present. Wound stuffed with lint and pressure applied.

November 9th.—Patient has been entirely free from pain during the past two days, and there is now a free discharge from the auditory canal and also from the wound. The probe introduced into the wound engages itself readily between the periosteum and the bone, and then passes forward and inward quite a distance without encountering any resistance. Below the wound there is still some swelling and inflammation of the skin and subjacent tissues on the side of the neck.

November 11th.—To-day, on exploring the bottom of the wound, I discovered an opening in the bone at a point a little below the level of the upper wall of the meatus. The probe penetrated quite a distance into the mastoid process, but no crumbling bone or spiculæ were encountered. Patient's general condition good.

November 21st.—No return of pain since last note. External wound scabbed over. No redness, swelling, or tenderness of adjacent parts. Free discharge from external auditory canal.

*Acute inflammation with caries.*—If the products of inflammation remain confined in the antrum, the resulting pressure upon the lining mucous membrane of this cavity may be expected sooner or later to induce a caries of some portion of the underlying bone. If a free outlet is established for these products before the carious process has involved too large an area of bone, the parts may, in course of time, return to a healthy condition; but if the pus is allowed to remain pent up in the antrum, we may confidently expect one of the following results: an inflammation of the membranes of the brain, the formation of an abscess in the brain itself, or the development of a purulent phlebitis of the lateral sinus with basilar meningitis.

CASE XI.—Male, thirty-five years of age, and of vigorous constitution. October 29, 1877. (Case seen in consultation with Dr. J. Simrock.) About

nine weeks ago he contracted an acute inflammation of the right middle ear, from bathing in the ocean. The severe pain lasted for a few days and then passed away upon the appearance of a discharge from the ear. Of late he has again suffered from pain in the affected ear, and throughout the entire right side of the head. The pain at times shoots forward into the right eye, or backward toward the occiput. The discharge still continues. On examination I find the meatus filled with pus. At its inner end a large teat-like fleshy mass projects from above downward into the canal and entirely conceals the drum-membrane from view. When the patient performs Valsalva's experiment, pus can be seen to escape from the tip of this projecting mass. There is tenderness on pressure over the posterior aspect of the right mastoid process, and the conjunctiva of the right eye is noticeably congested. During the past few nights patient has obtained such sleep as he could get, in an easy chair, in a semi-recumbent posture, the full recumbent posture aggravating his discomfort. By means of Blake's snare quite a large portion of the projecting fleshy mass was removed. Four leeches were also applied behind the ear.

November 1st.—No improvement. Pain continues without abatement. Free incision of the mastoid integuments; wound afterward stuffed with lint. Poultices.

November 4th.—Decided relief from pain, discharge not quite so abundant as before. The external wound is kept open by means of fresh tents introduced daily.

November 5th.—Patient passed a comfortable night. No diminution in the amount of the discharge. Temperature, at 4 P.M., 99.2° F.

November 9th.—Four very comfortable days and nights. Patient has had only spasmodic attacks of pain, which came on generally toward night and never lasted longer than three or four hours.

November 12th.—External wound has almost healed. The granulation-growth in the meatus is now nearly as large as when I first saw it. Blake's snare employed a second time in removing a large part of the mass. The "neuralgic" attacks continue. Ordered pot. bromid., gr. xv., t.i.d.

November 17th.—No material change. Granulation-tissue is again growing actively.

November 24th.—The pain is again on the increase. The discharge from the ear continues to be abundant. Enlarged the sinus in the projecting mass by means of the knife.

November 26th.—During the night from the 24th to the 25th, the pain in the right side of the head was quite severe. It extended to the right eye, and was accompanied by congestion of the scleral conjunctiva.

November 27th.—Patient passed a fairly comfortable night. The tenderness over the mastoid process is very slight. The growth of granulation-tissue in the canal takes place very rapidly. To-day several large pieces were removed, and yet the more solid base which remains still conceals the



drum-membrane from view. From its position it undoubtedly involves a part of the posterior and upper portion of the membrane. A curved probe introduced into the sinus encounters exposed but not roughened bone. Discharge thick and abundant, but odorless. Appetite good.

November 28th.—The pain has become more severe. To-day there is tenderness on pressure at several points above and behind the ear. No swelling or redness of the skin over the mastoid process; no tenderness on pressure immediately over the process proper.

November 29th.—No improvement. Consultation with Dr. Robert F. Weir and Dr. Daniel A. Dodge (of Brooklyn), both of whom agreed with Dr. Simrock and myself with regard to the advisability of perforating the mastoid process. The patient having been brought under the influence of ether, the mastoid integuments were incised, and the opening in the bone was made at the usual spot. The drill was carried to a depth of nearly three-fourths of an inch. The cells were found to be of moderate size and healthy, so far as we could judge. The septa were quite thick. At the upper portion of the bottom of the excavation thus made in the mastoid process, the probe encountered soft tissue. The sinus in the projecting fleshy mass at the bottom of the meatus was explored more thoroughly than had been found practicable when the patient was not under the influence of an anæsthetic, and it was ascertained that the bone constituting the lateral and lower edges of the entrance to the antrum was denuded and in a roughened condition. No communication could be demonstrated (by means of two probes) between the middle ear and the bottom of the excavation in the mastoid process. External wound dressed with salicylic jute.

November 30th.—Patient says that he passed a comfortable night, and experienced less pain than usual. When the probe is pressed against the soft tissues at the bottom of the artificial opening in the bone, he says that he feels the pressure in the ear. From the direction taken by the drill, from the depth to which it was made to penetrate, and from the patient's sensations as just described, there can be very little doubt that the soft tissues at the bottom of the artificial opening represent the swollen mucous membrane of the antrum.

December 1st.—Last evening the patient's temperature rose to 100.4° F. and he experienced considerable pain throughout the right side of the head.

December 3d.—No appreciable improvement since last date. Vaseline dressings substituted for the salicylic jute, which seems to irritate the external wound.

December 4th.—Evening temperature normal last evening.

December 10th.—Pain still continues, but is severe only at times, especially toward night. Since the 29th of November, when the mastoid process was perforated, there has been no further growth of granulation-tissue in the external auditory canal.

December 13th.—Discharge from ear increasing. External wound reduced to very small dimensions. Lateral headache quite severe yesterday. This morning the right conjunctiva is again congested.

December 29th.—Since last date patient has experienced fully as much pain as during any previous two weeks. The pain seems to be directly proportionate to the degree of obstruction offered by the mass of granulation-tissue at the inner end of the external auditory canal; for when this is cut away sufficiently to permit the pus to escape freely from the middle ear, the pain abates in a very marked degree. Three or four such attempts at excision have been made during the past two weeks, but all of them have been very imperfect, owing to the severity of the pain caused by the operation. To-day, however, the patient was etherized, and Dr. Simrock and I excised the greater part of the obstructing mass. It was found to involve a considerable part of the posterior half of the drum-membrane, and was composed of very firm tissue. The task of excising this mass was found to be exceedingly difficult. The moment the knife began to cut, the flow of blood completely obscured the field of vision, and owing to the proximity of important organs (anvil and stirrup) it was thought desirable not to proceed without a clear view of the parts which it was proposed to cut. Notwithstanding this, it was discovered, at the close of the operation, that the anvil had become loosened in its attachments.

December 30th.—Patient passed a very comfortable night. There is now quite a large opening in the drum-membrane, and the surrounding parts are very little swollen.

December 31st.—No return of pain.

January 9th.—Since last date, and without any therapeutic interference beyond keeping the ear clean with the warm douche, the middle ear and drum-membrane have been rapidly returning to a healthy condition. There is very little discharge. A small perforation still exists in the posterior half of the membrane. Otherwise the membrana tympani presents a nearly natural appearance, the outlines of the short process and handle of the hammer being distinctly recognizable. The external wound has nearly healed. Patient is now able to sleep through the entire night, and says that his head feels perfectly natural. The ticking of the watch is heard only when it is pressed against the auricle.

A few days later Dr. Simrock reported that the perforation in the membrana tympani and the external wound had both healed.

CASE XII.—On the 21st of September, 1872, I was asked by Dr. Herman Knapp to see with him, in consultation, a Mr. F., aged fifty-seven, and of a strong constitution. The history of the case was briefly this: During the previous ten or twelve years Mr. F. had had five distinct attacks of acute purulent inflammation of the left middle ear, from all of which he made a good recovery. The present attack began about seven weeks pre-

viously, and was characterized by headache and dulness of hearing, unaccompanied by discharge. On examination of the ear Dr. Knapp found the external auditory canal swollen, especially on the posterior side; the membrana tympani injected, and the mastoid process tender on pressure. In the progress of the disease, the membrana tympani becoming more congested and convex outwardly, the doctor incised it. No pus escaped, but the patient experienced relief from his suffering for about a week. The pain then returned, and the integuments covering the mastoid process became swollen. The patient also noticed a gurgling sensation in the ear, whenever he shook his head. An incision down to and through the mastoid periosteum afforded only temporary relief. The pain again became severe. At the consultation (September 21st) it was decided that perforation of the mastoid process was the only course that offered any hope of recovery. The patient, however, refused to have the operation performed.

September 22d.—Up to this time there had been no brain symptoms, but to-day, being called in haste to see the patient during the absence of Dr. Knapp from the city, I found him unconscious, pupils non-responsive, face flushed, and head very hot; pulse about 120, and full; breathing stertorous. The friends were then willing enough to have the operation performed, but it was clearly too late. The patient died the same night.

At the post-mortem examination, purulent basilar meningitis was found, together with a free communication between the mastoid antrum and the cavity of the lateral sinus. The two formed together an irregularly shaped cavity filled with pus. The pus did not extend down into the jugular vein, nor back toward the torcular Herophili. Both these portions of the vein contained venous blood. Sclerosis of the mastoid cells. Membrana tympani entire.

CASE XIII.—Male, about forty-five years of age and of strong constitution. April 3, 1877 (consultation with Dr. S. Sexton). About six weeks ago patient began to suffer from pain in the right ear. The physician whom he consulted a few days later, restricted his treatment to the frequent use of the syringe and to the administration of internal remedies. The pain, nevertheless, grew steadily worse, and involved the entire right side of the head. On the 31st of March, Dr. Sexton was asked to treat the case. No discharge from the ear had yet been observed by the patient, but on examination Dr. Sexton found the meatus inflamed, moderately swollen, and covered with a small amount of pus. Two incisions were made through the swollen walls of the canal. The patient continued to grow worse, and to-day he has been at times delirious and has vomited his food. It is only with difficulty that he can be made to answer our questions. He holds his head with both hands, as if in suffering. Pupils normal. Pulse 58; three days ago it was 100. He refers the chief pain to the occipital region. There is but little pus in the canal, and so far as it can be seen the membrana

tympani has a tough, soaked appearance. No evidence of the existence of a perforation. Iodide of potassium to be given in ten-grain doses every four hours.

April 5th.—Patient is to-day profoundly comatose.

April 7th.—Death occurred this morning. (Post-mortem examination refused.)

CASE XIV.—Male, nineteen years of age, in good general condition. September 24, 1876. Consultation with Dr. F. Simrock. Patient has been subject to chronic purulent inflammation of the right middle ear. Four years ago Dr. Simrock ascertained the existence of caries of the bony walls of the tympanum, and warned the boy's parents of the danger connected with that condition. A week ago the patient began to complain of pain in the right ear, and it soon became quite severe. Temporary relief was afforded by a free incision carried through the posterior fold of the drum-membrane. The boy had two chills yesterday, followed by vomiting, and last night the pain again returned with great severity. To-day the boy is so drowsy that he can only be roused with great difficulty. At times he is also delirious. On examination, the external auditory canal is found to be perfectly natural, except in the immediate vicinity of the membrana tympani, where it is red and moderately swollen. The membrane itself is of a pinkish hue, and much disfigured by inflammatory changes (old). A perforation can be distinguished only when air is forced out through it by suddenly condensing the air in the naso-pharyngeal space, by means of a Politzer's bag. No redness, swelling, or tenderness behind or above the ear.

From the history of the case, from the condition of the middle ear, and from the absence of any redness or tenderness behind the ear, it seemed unlikely that, at such an advanced stage of the cerebral disease, any relief would be afforded by the operation of perforating the mastoid process. An effort was made, however, to bring the patient under the influence of mercury (inunctions, and calomel by the mouth), but he grew steadily worse, and died two or three days later.

CASE XV.—Saloon-keeper, thirty-nine years of age, and of vigorous physique. October 22, 1873. While on a fishing excursion last July, patient got a thorough wetting and soon afterward began to suffer from pain in the left ear. Deafness in the affected ear and tinnitus were also noticed from the beginning. The pain extended from the ear to the entire left side of the head, and was particularly severe in the occipital region. At the end of four weeks an abscess of large dimensions developed behind the ear, and broke of itself. At no time was there any discharge from the external auditory canal. Since the spontaneous opening of the abscess the patient has suffered chiefly from pain referred to the left temple. He has also had frequent attacks of dizziness, though this may possibly have had

some connection with a sunstroke which he experienced about three years ago.

From Dr. Buechler, who saw the patient on about the seventh or eighth day of the attack, I learn that he found him in convulsions and with a high fever. Several leeches were applied near the ear, and the inflammation appeared to have been arrested by this depletory measure. At all events Dr. Buechler was not sent for again until to-day.

At the present time the ticking of the watch is not heard at all in the left ear, even when it is pressed against the auricle. The sound of the tuning-fork, however, is referred very promptly to the affected ear. On examination with the speculum and reflected light, the meatus and membrana tympani were found to be almost free from evidences of inflammation. The drum-membrane was dull, milky, and apparently thickened; peripheral and manubrial plexuses moderately injected; no cicatricial spot or other evidence that a perforation had ever existed. Behind the ear a fistulous opening is visible. The probe introduced into this, engages itself in a small opening in the upper part of the mastoid process, about at the same level with the upper wall of the meatus.

October 23, 3 P.M.—With the assistance of Drs. Buechler and Charles Laight, patient was etherized, and a vertical incision was made through the mastoid integuments, exposing to view the orifice of the bony fistula. A silver probe of ordinary size could be passed directly inward to a depth of only about a third of an inch. No loose fragments were felt. The drill (diameter  $\frac{1}{4}$  inch) was then engaged in the opening and made to penetrate inward a little upward and forward, to a depth of three-fifths of an inch. At first the bone was found to be in a softened condition, but deeper in it was almost as hard as ivory. A tent anointed with simple cerate was then inserted into the wound.

8 P.M.—Patient complains of feeling very weak and cold. No special pain in the region of the wound or in the head. His wife says that he has been more or less delirious since the operation. Ordered beef-tea (ca.  $\frac{3}{4}$  iij.) every three hours, and

- R. Quinæ sulphatis . . . . . gr. xxxij.  
 Acid. sulph. dil. . . . . q. s.  
 Aquæ . . . . . ad  $\frac{3}{4}$  iv.  
 M. S.—Two teaspoonfuls every three hours.

October 24th.—Patient feels much better to-day. Quinine solution to be taken three times a day instead of every three hours. No pain in head. Wound to be dressed with carbolated oil.

October 25th.—Wound granulating healthily. Very little swelling of the neighboring parts. The tinnitus, which troubled him before the opera-

tion, has now entirely disappeared. Appetite good. Quinine to be stopped, and patient to take in its stead:

R. Ferri citratis..... gr. xvi.  
 Tinch. cinch. comp.....  $\frac{3}{4}$  j.  
 Aquæ .....  $\frac{3}{4}$  iij.  
 M. S.—A tablespoonful three times a day.

October 27th.—During the past two or three nights patient has had quite severe headache—not so severe, however, as before the operation. During the day-time he has been free from pain. Urine examined and found to be normal. No history or existing evidence of syphilis. Iodide of potassium in five-grain doses to be taken three times daily.

November 1st.—Wound healing rapidly. Pain still continues to be quite severe at night. Doses of iodide of potassium increased to ten grains each. Small hard-rubber drainage-tube introduced into the orifice of the fistula in the bone, as granulation-tissue is rapidly filling up the external wound.

November 5th.—The hard-rubber canula, though kept in position simply by the pressure of a bandage passed lightly over the top of the head and under the chin, causes him so much discomfort that he is unwilling to wear it any longer. The pain at night is much less severe.

November 10th.—Patient is now entirely free from pain at night. Ordered iodide of potassium to be discontinued.

November 17th.—Continued freedom from pain. External wound still remains open. From time to time it has been found necessary to resort to the use of nitrate of silver (in stick) for the repression of an exuberant growth of granulation-tissue.

December 6th.—Two days ago patient again began to experience pain at night throughout the left temporal region. Ordered strychniæ sulphat., gr.  $\frac{1}{40}$ , t.i.d.

January 15, 1874.—Pain of late has again been insignificant or entirely absent. Patient, however, complains a good deal of dizziness. On introducing my probe into the bony sinus I found that it could be passed upward and backward a distance of an inch from the opening on the outer surface of the bone. The probe felt as if it was surrounded by bone on all sides, and, from its position, it must have occupied the diploë lying immediately behind the sulcus for the lateral sinus. The fear of doing some damage prevented me from passing the probe any higher up in the direction in which it was going, although up to the point reached no obstacle was encountered. At all previous explorations it had not been found possible to pass the probe into the bone to any but a very short distance.

The suggestion of further operative interference brought the patient to

the decision that he would wait and see how he should get along without medical aid.

CASE XVI.—Female, twenty-nine years of age, in fair general health (New York Eye and Ear Infirmary), February 10, 1875. She states that she has been subject to a discharge from the left ear since childhood. About six months ago a "tumor" was discovered in the affected ear. Several attempts were made at different times to remove this "tumor," but it constantly reappeared. Of late she has experienced a great deal of pain throughout the entire left side of the head. The pain has been especially severe at night, and at times has been accompanied by what she describes as "brain fever." Occasionally she has experienced a sensation as if the left eyeball were being pushed out from its socket.

On examination the meatus was found to be blocked by the presence of a mass of granulation-tissue. After removing the greater part of this growth with the snare, I discovered, by aid of the probe, that it sprung from the posterior wall of the meatus, near the junction of the cartilaginous with the osseous portion, and that its point of origin was close to the orifice of a sinus that led quite a distance inward and a little upward and backward. In its course the probe, which did not seem actually to enter the substance of the mastoid process, encountered denuded and crumbling bone. No redness or swelling of the skin behind the ear. Moderate tenderness on pressure over the lower part of the process and also over that portion of the skull which is situated immediately in front of the occipital protuberance.

She was advised to become an in-patient of the Infirmary, in order that she might receive better care than it would be possible for her to receive at her tenement-house home. She readily consented and was assigned to a bed in a separate room.

February 13th.—Pain still continues. Patient having been etherized, the mastoid integuments were divided, and the bone perforated with the larger drill to a depth of three-fifths of an inch. No pus or softened bone encountered. Anteriorly, however, the periosteum was found to have become separated from the underlying bone, thus allowing the probe to pass easily along the surface of the bone into the meatus.

February 14th.—Marked relief from pain.

February 16th.—Decided swelling and tenderness in front of and above the auricle. Motions of the jaw cause pain in the region of the ear. Temperature nearly normal.

February 20th.—Since last note patient has had an attack of syncope, lasting about one hour, and requiring the use of stimulants. To-day she is in about her usual condition. Her temperature varies from 98.5° to 99.5° F. The pain in her head is nearly constant. The parts around the ear still remain swollen. The polypoid mass in the meatus having grown

to such a size as to obstruct the free escape of pus from the deeper regions, I removed the larger part of it to-day with the snare.

February 24th.—This morning patient had two epileptiform seizures of short duration. The swelling in the vicinity of the ear has diminished quite noticeably. The pain, however, continues. When asked in what part of the head she felt the most pain, she replied at once, in the left eye. Her answers to other questions were at times almost unintelligible. She would begin her answer and then stop as if trying to think what else she should say. Temperature remains at about 99° F. Profuse sweats. Occasional vomiting.

February 26th.—She is now very restless, and force has to be used to keep her in bed. Her mind wanders constantly, and she no longer pays any attention to questions addressed to her. The right eye is drawn outward and the right upper lid droops. Temperature 101° F.

She died the same night. The discharge from the ear continued to be abundant up to the very last. No post-mortem examination was allowed. By means of the probe, however, I ascertained that the inner and posterior bony walls of the tympanum were denuded and roughened. The bent probe passed upward and backward through what felt like a small opening in the tegmen tympani, into the cranial cavity (abscess of the brain?).

CASE XVII.—Female, twelve years of age, of rather delicate appearance. May 29, 1874. When the family physician was called to see the patient, ten days previously, he found her suffering with a moderately severe headache, fever, occasional chills, and general malaise. No complaint was made of pain in, or discharge from, the ear. After the lapse of a few days, no improvement having taken place in the patient's condition, the physician made special inquiry with regard to the condition of the ears, and then for the first time learned that there had been a free discharge from the left ear since the time when the girl was first taken ill, *i.e.*, about a week before he was called to see her. The pain in the head continued to increase in severity, the fever became more pronounced, the chills occurred more frequently (as many as six in the course of the day), and there was occasional delirium. At the time I saw the patient, her condition was as follows: Temperature, 107° F.; pulse, 140. She made no response to questions that were addressed to her. Low muttering delirium. Eyelids half-closed, and eyes rolling about constantly. Pupils dilated (equally), and fully responsive to light. No strabismus. Tongue thickly coated. Examination of the left ear revealed the following condition: No redness or swelling of the mastoid integuments; external auditory canal normal in its outer portion; only a moderate amount of pus. At the inner end of the meatus a mass of polypoid granulations conceals the deeper parts from view. After removing this mass with the snare, I found that it grew from the neighborhood of the mouth of the antrum, through a perforation in the posterior and upper por-



tion of the drum-membrane. A curved probe introduced into the antrum encountered denuded bone. Treatment: four leeches to be applied to the mastoid region, and three in front of the ear; the warm douche to be used frequently.

May 30th.—Temperature, 102. 5° F. Delirium and unconsciousness still continue.

May 31st.—Delirium of a more pronounced character. Constant jactitation. Pupils dilated and no longer responsive to light. Pulse 168 and irregular.

Death occurred on the following day.

CASE XVIII.—Male, twenty-five years of age, in excellent physical condition. October 1, 1875. Frequent earaches and discharge from both ears since childhood. For a period of about two years he has had no discharge from the ears until within the past three weeks. He is now so deaf that I am obliged to speak to him in a very loud tone. (For the history of the left ear, see Case II. on p. 267.) On examination of the right ear, an unusually hard fleshy mass is found occupying the inner end of the narrowed meatus. It fits the meatus so closely that I am unable, by means of the probe, to locate its exact origin. Its base, however, is clearly very broad. By means of Blake's snare, I succeeded in removing only a small portion of the mass.

October 2d.—Another portion of the mass removed with the snare.

October 3d.—Two or three more small pieces removed.

October 4th.—Snare used for the fourth time, and with nearly the same results as on previous occasions. The mass proves to be larger than I first estimated it to be.

October 5th.—Two portions removed.

October 7th.—Snare again used, and with the same results. I then split the fleshy mass with a suitable knife, and introduced nitrate of silver, in the form of a bead fused upon the end of a cotton-holder, into the centre of the growth.

October 8th.—No unpleasant reaction followed the use of the caustic. On the other hand, it does not appear to have exerted the slightest influence in causing any considerable portion of the mass to slough away. One seizure effected with the snare.

October 9th.—Mass incised as before, and liquor ferri subsulphatis (on a small pledget of cotton wound round the end of the cotton-holder) introduced into the very centre of it.

October 10th.—No material change in the condition of the fleshy mass. Application of subsulphate of iron repeated.

October 11th.—To-day, for the first time, there are evidences of inflammatory reaction in the right ear; the meatus being decidedly swollen. No further interference until the inflammation shall have entirely subsided.

October 13th.—Patient complains of considerable pain throughout the right side of the head. The discharge, which heretofore has been rather scanty, is now profuse, and is tinged with blood. Slight tenderness of the mastoid integuments.

October 14th.—Patient is again free from pain, and there is no tenderness on pressure over the mastoid process. Two successful seizures made with the snare.

October 15th.—Snare used again with moderate success. Owing to the small size of the meatus, and to the unusual toughness of the fleshy mass, causing the wire loop to bend upon itself the moment it is pushed a short distance beyond the visible end of the growth, the numerous seizures thus far made have accomplished comparatively little in diminishing the size of the obstructing mass. Enough, however, has now been removed to afford a fairly free outlet for the profuse discharge, the greater part of which seems to come from the mastoid antrum,<sup>1</sup> through an irregular opening in the upper and posterior part of the drum-membrane—the exact condition of which cannot be ascertained, owing to the presence of the fleshy mass.

On the 17th of October the patient returned to his home for the purpose of taking a rest for a few weeks, as it did not seem wise to make any further efforts at that time to remove the remainder of the obstructing fleshy growth. The following extracts from a letter written by the patient's father, on the 8th of November, furnish a clear history of the subsequent course of the disease.

“We left New York on Sunday evening, the 17th of October, arriving at home on Monday afternoon, the 18th. My son bore the journey well, and remained free from pain for about two days, with the exception of experiencing a confused sensation in the head. On Thursday, the 21st of October, he was seized with a violent pain in the right ear and side of the head. Dr. R. prescribed leeches, but that not relieving him, a liquid blister was applied at the back of the ear with a brush, followed the next day with a fly blister; but nothing seemed to afford him relief, and he obtained but little sleep at night. During this time he was not confined to his bed, and on Sunday morning, the 24th of October, he took a long walk, hoping to shake off the pain. That afternoon he was taken a great deal worse, and had to go to his bed; Dr. R. gave him a dose of morphine to induce sleep. Vomiting and violent retching ensued during the night, and continued for three days, during which time nothing would stay on his stomach. Heated cloths and linseed poultices were constantly applied to his ear during his illness. The doctor was afraid to apply ice to the head for fear of increasing the

---

<sup>1</sup> From the history of the case, and from the conditions observed in the ear, there can be very little doubt about the existence of a limited carious process in the antrum or in the upper and posterior portion of the tympanic cavity proper. The sensitiveness of the parts prevented me from actually demonstrating its existence by means of the probe.

trouble in the ear. After the one dose of morphine, no more was given, but bromide was substituted, two teaspoonfuls being administered every three hours.

“On Wednesday, the 27th of October, the face became partially paralyzed on the right side.

“On Friday, the 29th of October, his ear began to discharge freely, which seemed to give him some relief, and this discharge continued more or less to the end.

“The retching ceased about three days before his death, and we managed to give him a little beef-tea and jelly from time to time. He was unconscious from Saturday afternoon, the 30th of October, but although delirious, he was not at all violent. He wandered a good deal, fancying he was sailing in a yacht or rowing in a boat, an amusement of which he was very fond. He remained unconscious to the time of his death, which took place on Monday evening, the 1st of November, at 8.30, having been ill twelve days. He passed away peacefully and gently, his breathing ceasing as suddenly and as noiselessly as the cessation of the ticking of a clock when run down.”

CASE XIX.—(New York Eye and Ear Infirmary.) Michael Casey, twenty-three years of age, a sufferer from pulmonary phthisis, applied to me, March 20, 1872, for relief from a painful affection of his left ear. He stated that two months previously he first noticed a discharge from his left ear; that at first there was no pain connected with it, but that when the discharge became copious, as it did about two weeks before, he began to suffer from earache. On examination the left meatus was found to be completely closed by a collapse of the upper cutaneous wall. After the speculum had been forced in for a certain distance, it encountered a mass of granulations, which obstructed a view of the deeper parts. Three leeches applied near the orifice of the meatus.

March 23d.—Better. The motion of the lower jaw produces pain in the left ear. Granulations removed with Blake's snare. Probe encountered denuded and roughened bone surface in the meatus.

March 30th.—Paralysis of the left side of face noticed to-day for the first time.

April 6th.—Edema of the skin above and behind the ear. Incision over mastoid process gave escape to a large quantity of pus, a part of which was confined between the periosteum and the bone, the surface of which was somewhat roughened. Occasional nausea to-day.

April 8th.—Is steadily losing strength. Pulse, 112, and feeble. Suffers great pain throughout the left side of head, but does not refer it to the mastoid region. On my advice the patient entered St. Luke's Hospital, where he could obtain proper food and nursing.

On the 9th of April, Dr. George A. Peters made a free incision through

the upper wall of the meatus, exposing to view the denuded and roughened bone, and giving a free outlet to the pus that had accumulated above the auricle, and to that which was constantly forming in the deeper parts of the ear, but had hitherto found an escape chiefly through the Eustachian tube.

The operation afforded the patient great relief; but in the course of a few days, the temperature rose to 106°, the cerebral symptoms became alarming, and the patient died comatose.

At the post-mortem examination the dura mater covering the convexity of the left hemisphere was found to be intensely red; on the right side it was nearly normal. Pus at the base of the brain on the left side. Dura mater covering the left tegmen tympani thickened and of a maroon color. The thickened portion, whose limits were very abrupt, resembled closely an elevated and swollen Peyer's patch. Between the swollen dura mater and the greenish, softened tegmen tympani lay quite a collection of cheesy disorganized pus. The lateral sinus was not involved. The antrum mastoideum was nearly filled with a cheesy mass enveloped in a coating of foul greenish pus. The mastoid cells were sclerosed. A small sinus led from the outer surface of the upper portion of the process directly inward to the antrum. (It was not detected during life.) The tympanum was filled with the same greenish, foul pus, which had also accumulated in the vestibule and scala tympani, owing to the destruction of the stirrup and membrane of the round window. The lining mucous membrane of the tympanum was not recognizable; the pus seemed to be lying in direct contact with the bone. Membrana tympani totally destroyed. The cavity of the temporo-maxillary articulation filled with pus. Eustachian tube ulcerated and very much enlarged. The pus had also burrowed down in the direction of the basilar process of the occipital bone.

## II. *Acute Inflammation of both the Antrum and the Pneumatic Spaces.*

In a second series of cases the inflammation extends beyond the limits of the antrum and involves the pneumatic spaces. The inflammation of these spaces may stop short at the congestive stage, or it may go on until the cells become filled with pus, and sometimes even until a necrosis of the bony septa takes place. The diffuse redness, swelling, and tenderness of the mastoid integuments furnish good evidence that such an extension of the inflammation to the pneumatic spaces has actually taken place. Farther on I will call attention to the exceptions which must be made to this rule.

The following cases, which are divided into two groups, may be taken as fair illustrations of an acute inflammation of the antrum and pneumatic spaces.

*Cases in which the pneumatic spaces are simply congested.*—CASE XX.—The patient, a female, about forty-five years of age, of rather delicate organization, consulted me on the 28th of May, 1874. About three weeks previously she had had a severe earache in the right ear. It lasted for two or three days, and then passed away simultaneously with the development of a discharge from the ear. A few days before she came to see me, however, the pain had returned, and had become quite severe. She was unable to sleep. The mastoid integuments were very tender under pressure, and somewhat reddened. The external canal was filled with pus. The membrana tympani was red, swollen, and disfigured. I made a free incision through the posterior half of the drum-membrane, and prescribed the frequent use of the warm douche.

May 29th.—Pain still continues. Five leeches applied to the mastoid region.

May 30th.—The leeches afforded almost immediate relief, and the patient experienced a good night's rest. Appetite has returned, and pulse is again normal.

May 31st, 10 A.M.—Patient reports that during the night the mastoid region again became painful. She also experienced a sensation of dizziness, associated with nausea, and saw dark objects floating before her eyes. She vomited two or three times. Toward morning she experienced a peculiar sensation of something dropping into the throat from the back part of the nasal cavity. On spitting it out she discovered that it was blood. Just before the bleeding began, she became suddenly aware that the sense of fullness and pain had left the ear. The bleeding continued for several hours, though growing steadily less until it finally ceased. The quantity thus expectorated amounted to about a fluid ounce, and was bright-colored when I saw it. Pulse, 100, easily compressible. At 4 P.M. I saw her in consultation with Dr. Robert F. Weir. Shortly after my visit the hemorrhage returned, and continued until she had again expectorated about an ounce of blood. An examination with the laryngeal mirror and reflected light reveals the existence of a varicose condition of the veins in the naso-pharyngeal space, but no blood at the orifice of the Eustachian tube. Valsalva's experiment forces out through the perforation in the drum-membrane only clear pus. Treatment: powdered tannin to be blown upon the naso-pharyngeal mucous membrane.

June 1st.—Since yesterday patient has had a hemorrhage from the lungs; the quantity of blood raised being about five ounces. No evidences of lung disease discovered by physical examination. Ear free from pain.

June 2d.—Three or four smaller hemorrhages, apparently from some part of the lungs. No fever. Only occasional paroxysms of coughing.

June 3d.—Hemorrhages continue, but they partake rather of the character of bloody sputa. Patient has now a constant short, hacking cough.

Consultation with Dr. James R. Leaming, who finds apices of both lungs congested. Friction with turpentine and alcohol advised.

June 4th.—Much less cough. No expectoration.

June 8th.—No cough. She complains only of dizziness and great weakness. She is to be taken to her home in Troy. (No subsequent data.)

CASE XXI.—Male, forty-two years of age, and very stout. May 21, 1876. Patient states that ten days ago he contracted a severe "cold in the head," which culminated, three days ago, in a sharp earache in the right ear, accompanied by subjective roaring sounds and deafness. The pain now involves the entire right side of the head, and to-day, for the first time, he has noticed the existence of a slight watery discharge from the ear. On examination, the cutaneous lining of the inner half of the external auditory canal is found to be red, swollen, and bathed with a colorless secretion. The swelling is greatest in the immediate vicinity of the drum-membrane—which is almost completely concealed from view—and shades off gradually from that point outward. Four leeches to be applied in front of the ear; ear to be syringed frequently with warm water.

May 22d.—Pain abating slowly.

May 23d.—Almost entirely free from pain to-day. Air enters the middle ear readily, when inflation is performed according to Politzer's method, but no perforation sound can be heard. The watery discharge, therefore, probably comes entirely from the swollen and inflamed walls of the outer canal. Nitrate of silver (in the form of a bead) applied lightly to the red and cedematous tissues.

May 26th.—Patient felt so well yesterday morning that he took a carriage and drove to the lower part of the city—a distance of fully three miles—on a business errand. Before reaching home again, the jarring caused by riding over the rough pavements had brought back the earache in all its former severity. Patient passed a bad night, and is still in suffering to-day. Poultices to be tried for the relief of the pain.

May 27th.—Another bad night. To-day the skin covering the mastoid process is red and tender. Free incision through these parts.

May 28th.—Decided relief from pain. Patient again very comfortable.

June 6th.—Since last note patient has passed through a moderately severe attack of facial erysipelas, the disease beginning at the mastoid wound and extending to the forehead, nose, upper portion of the cheek, and hairy parts of the scalp just around the ear. The membrana tympani and external auditory canal have, in the meantime, returned to nearly a healthy condition.

CASE XXII.—Male, twenty-six years of age, in fair general health. (New York Eye and Ear Infirmary.) August 25, 1875. History of an acute inflammation of the middle ear (L.) of only a few days' duration.

Pain severe. Purulent discharge from external auditory canal. On examination the membrana tympani was found to be red, swollen, and perforated. Leeches and warm douche were ordered.

September 4th.—Patient states that the leeches afforded only temporary relief. The pain returned with increased severity, and the parts behind the ear soon became red and swollen. During the past few days he has experienced great distress throughout the entire left side of the head. Free incision through the tender and swollen mastoid integuments. Poul-tices.

September 18th.—The incision afforded great relief, and patient is now comparatively free from pain. The redness, swelling, and tenderness of the mastoid integuments still persist, and there is a constant and profuse discharge of thick pus from the auditory canal. The external wound has healed.

October 19th.—Patient states that, although at no time entirely free from pain, he has experienced no acute suffering during the past month until about three days ago. Since then the swelling behind the ear has increased quite rapidly, and the pain has become severe again. The auricle is now pushed forward by a tense red swelling, involving the mastoid integuments and extending above the ear and as far forward as the temple. A free incision made in the line of the cicatrix of the former cut gave rise to such a copious hemorrhage that I was obliged to stuff the wound with lint and apply pressure by means of a bandage.

October 20th.—I removed the stuffing from the wound to-day and pushed an exploring needle from the upper end of the wound forward, upward, and inward, in the direction in which—from the degree of swelling above the auricle—I thought it would be likely to reach pus. In this I was successful, and after enlarging the channel of communication I was able, by pressure in front of and above the ear, to drive out about a drachm of thick, healthy pus. On probing the cavity from which the pus had been forced out, I discovered that the bone in that region was denuded of its periosteal covering. There was marked tenderness throughout all this region, and decided redness of the infiltrated skin. Poul-tices ordered.

October 23d.—External wound has again healed, and the swelling is at least as great as on the 20th. Incision repeated, pus evacuated, and a tent introduced. The patient promises to insert a fresh one every day.

October 27th.—No return of pain. Discharge from meatus diminishing. Probe still encounters denuded bone surface. Daily introduction of a tent to be continued for a few days longer.

November 14th.—Patient is doing well. Tent to be omitted.

November 24th.—Discharge of pus from external wound has rapidly diminished since the introduction of the tent has been omitted. A small scab now covers the wound. The discharge from the meatus has ceased.

December 12th.—External wound has completely healed. No tender-

ness exists at any point in the vicinity of the ear. The drum-membrane is intact, and nearly normal in appearance.

CASE XXIII.—Girl, six years of age, and apparently in robust health. October 17, 1874 (New York Eye and Ear Infirmary). During the previous March she had passed through an attack of scarlet fever, which had left her with a discharge from the right ear. Pain had been a prominent symptom of the ear complication during its first stages. About three weeks previously the discharge had become profuse, the child had complained of pain, and the soft parts just behind the ear had become very much swollen, red and tender. A few days later a well-defined swelling had made its appearance a short distance behind the mastoid process. At the time when I saw the patient, there was still redness, tenderness, and swelling of the mastoid integuments. The external auditory canal was swollen and filled with pus. About midway between the mastoid process and the occipital protuberance, and a little above the line connecting these two regions, there was a well-defined, fluctuating swelling. A free incision through this tumor was instantly followed by such a gush of blood that I was unable to determine whether the fluctuation was due to the presence of pus, or to that simply of serum or fluid blood. The hemorrhage was arrested by stuffing the cavity laid open by the incision, with lint, and then applying a compress and bandage.

October 20th.—She has been comparatively free from pain since last note. No further hemorrhage occurred from the wound. To-day, there being evidences of suppuration in the wound, I removed the lint stuffing.

November 6th.—The child's mother reports that the wound healed soon after the last visit, and that the discharge from the ear had diminished very perceptibly. She says, however, that during the past few days, the child has had cough and night-sweats, and has lost flesh appreciably. On examination I find that all manifestations of mastoid inflammation have disappeared, there being now only a subacute purulent inflammation of the middle ear, with partial destruction of the membrana tympani. The girl's general appearance, however, has greatly changed. She is pale and emaciated, and presents every appearance of a child suffering from pulmonary phthisis. (No subsequent data.)

CASE XXIV.—Male, twenty-five years of age, in poor general health (through constitutional syphilis). New York Eye and Ear Infirmary. November 26, 1873. About a week ago patient began to suffer from pain in the left ear, followed soon by a watery discharge (tinged with blood) from the ear. Both have continued since, and the pain now involves the mastoid region. On examination, the auditory canal is found to be filled with pus. The membrana tympani is red, swollen, and perforated anteriorly. Mastoid region tender under pressure. Watch heard only when



pressed against the ear. Syphilitic inflammation of the pharynx, with destruction of a portion of the soft palate. Patient is now under active constitutional treatment (in the throat department of the Institution). The perforation in the drum-membrane being very small, a free incision was made to-day through the posterior half. Three leeches to be applied to-night to the mastoid region.

November 29th.—No improvement. Instead of three leeches, the patient allowed only one to be applied behind the ear. During the past forty-eight hours he has had quite an active diarrhoea (sixteen stools).

December 1st.—Patient has remained in bed since the last note, and the diarrhoea has ceased. The pain in the head, however, is rather increasing, and the skin covering the mastoid process is to-day red and moderately swollen. Three leeches to be applied to this region.

December 3d.—The leeches drew well, and the patient experienced decided relief from pain. This morning, however, the pain returned with increased severity. A free incision through the mastoid integuments was followed by arterial hemorrhage, necessitating the use of the ligature. The incision had been carried a little nearer the angle of insertion of the auricle than is usual in such cases. Poultices to be applied behind the ear.

December 6th.—Slow but steady diminution in the acuteness of the pain. Patient is to take daily four grains of quinine and cod-liver oil, his general condition being decidedly poor.

December 10th.—Two days ago the discharge from the ear ceased. The pain comes only in paroxysms now. General condition improving. External wound is healing slowly; at the bottom of it the probe still encounters exposed bone. The membrana tympani is red and swollen, but dry. No perforation visible. The iodide of potassium, which at first disagreed with him, is now taken without the slightest discomfort, in combination with the sesquicarbonate of ammonia.

December 13th.—Continued and very marked improvement.

December 17th.—As patient is entirely free from pain, he is allowed, at his own request, to return home. The external wound has not quite healed.

CASE XXV.—Male, twenty-three years of age, in good physical condition. May 13, 1876. Four weeks ago, while suffering from a bad "cold in the head," he contracted a severe earache in the right ear. Although a discharge soon made its appearance, the pain continued for a period of nearly two weeks. A period of comparative freedom from pain then followed, but three days ago the pain returned, and the soreness behind the ear, which had developed some days previously, became decidedly more marked. The pain had not been confined to the ear and its immediate vicinity, but involved the entire right side of the head. On examination, the external meatus was found to be nearly normal; the drum-membrane,

however, was red, swollen, and perforated posteriorly. The skin covering the mastoid process was decidedly red and swollen, and very tender when pressed upon with the finger. A free incision was made through these swollen tissues, the point of the knife being carried along the surface of the bone. Subsequent warm, moist applications to the parts.

May 14th, 8 p. m.—Patient has been entirely free from pain to-day. His appetite is returning.

May 19th.—No return of the pain. The discharge from the meatus has ceased, and the perforation in the drum-membrane has healed. There is no longer any redness or swelling of the skin covering the mastoid process, and the external wound has very nearly healed. Subsequent recovery perfect.

CASE XXVI.—Richard Murphy, *æt.* 11, phthisical in appearance, contracted, about the 4th of September, 1872, a pain in the left ear, in consequence of exposure to cold. Two days later a discharge appeared, and from that time to this (September 11th) he has suffered from severe pain in the affected ear. To-day the discharge ceased. Patient appears to be in great suffering. Pulse 108 and feeble. Tenderness and *œdema* over the left mastoid process. The external meatus closed by the swelling of its walls. Valsalva's experiment caused dizziness and retching. The patient being under the influence of ether, an incision was made through the integuments of the mastoid process. The surface of the bone was found to be normal in appearance and consistency. The outer shell of bone was then perforated with a conical drill, which exposed to view the mastoid cells at a depth of less than two lines. These were found to be highly congested, and the thin bony septa readily broke down under the pressure of the steel director. No pus was found. A small tent was introduced into the wound, and a poultice was applied to the parts. Milk and beef-tea diet. Patient to remain in bed.

September 12th.—Pain has gone, but patient is unable to keep anything on his stomach (the effect, probably, of the ether). The discharge from the meatus has returned. Some erysipelatous swelling about the wound. Ordered lime-water p. r. n.

September 13th.—Food retained. General condition decidedly better. Free discharge from the meatus. Wound granulating. No return of pain. Ordered simple dressing to wound, tent to be left out and poultices to be omitted; patient also to take quin. sulph., gr. j., t.i.d., and solid food.

September 14th.—Erysipelatous blush is fading away.

September 16th.—Continued improvement. Patient is now able to leave the house.

September 18th.—A free discharge both from the meatus and from the wound. Ordered iron and cinchona to be substituted for the quinine.

September 21st.—Entire freedom from pain since the operation. His

general condition, however, is not so good as when he last visited me three days since. Night-sweats have set in, and his breathing is hurried.

Since the last note I have not heard from the boy, and have very little doubt that he soon afterward died of phthisis. The operation certainly gave great relief, but the subsequent copious discharge of purulent matter was too great a strain for a system burdened with phthisis, and he probably succumbed under both.

CASE XXVII.—(New York Eye and Ear Infirmary). Mrs. Kate Ryan, æt. 36, with syphilitic destruction of the bones of the nose, but otherwise in good health, consulted me January 15, 1873, for a painful affection of the right ear. She stated that a week previously she was attacked during the night with a severe pain and roaring in the ear. She had always been hard of hearing in that ear, but could not recollect ever to have had a discharge from it. In the course of twenty-four hours she obtained some relief by the sudden giving way of something in the ear and the appearance of a discharge at the outer orifice. Soon, however, the pain returned and gradually became almost intolerable. It extended over the entire side of the head and was accompanied by soreness in front of and behind the ear. On examination I found the external auditory canal closed by an œdematous swelling of its walls. Membrana tympani perforated, but invisible. Tenderness on pressure over mastoid region; moderate œdema. Tongue coated. Appetite poor. Pulse 90 and of fair strength. No appreciable heat of skin. Incision of the mastoid integuments.

January 16th.—No relief from the incision. Pulse 104 and feeble. She is evidently in much suffering. Consultation with Dr. Robert F. Weir. Perforation of the mastoid process advised. As the patient preferred to bear the pain, the operation was performed without anæsthesia. The bone was perforated with the larger of the two drills to a depth of half an inch, without encountering pus. The cells were few in number, and separated by strong septa. The outer surface of the bone appeared to be perfectly normal. Treatment: introduction of a tent into the opening in the bone, poultices every four hours, iron and quinine, and moderate stimulation.

January 17th.—Decidedly better in every respect. Pain moderate. Pulse 88. Takes nourishment well. The meatus and the wound to be syringed every four hours with a warm, weak solution of carbolic acid.

January 22d.—Continued improvement. Wound granulating. Occasional shooting pains.

January 29th.—Entire freedom from pain in the right ear. Wound rapidly filling up with healthy granulations. Almost no discharge from the meatus. Three days ago, without any apparent cause, the left ear became acutely inflamed. Incision of membrana tympani afforded an outlet to the pus and relieved the pain.

February 8th.—Steady improvement. Left ear free from pain.

February 13th.—No discharge from the right ear since the 10th. A thin cicatricial depression indicates the location of the former perforation in the membrana tympani. Outer wound entirely healed except at one small spot which is still covered by a scab.

CASE XXVIII.—This case commenced as an ordinary acute inflammation of the middle ear, resulting in a discharge of pus through a small perforation in the left membrana tympani. The patient was twenty-three years of age, in fair health at the time, though a frequent sufferer from articular rheumatism. His first visit to the Infirmary was on the 19th of March, 1873. The acute symptoms had then passed off, and he was simply troubled with moderate deafness in the affected ear and a very slight discharge.

Ten days later, it was found that the opening in the membrane had healed over, and that the latter had resumed a comparatively healthy appearance. The only thing that attracted any special attention was the existence of a faint circular outline in the posterior half of the membrane. Siegle's tympanoscope failed to dislodge this supposed bubble from its position, and the auscultatory sounds were so thoroughly dry, that I very nearly abandoned the idea that there was fluid in the tympanum. To satisfy myself, however, on this point, I made a linear incision through the posterior half of the membrane, and performed suction through Siegle's apparatus. No fluid escaped. The linear incision was then converted into a crucial one, and suction was again employed. This time a mass of tough mucus was brought through the perforation into the cavity of the meatus. This mass remained connected with the mucus within the cavity of the tympanum by a round cord of the same substance. By exerting traction upon this cord, it could be drawn out to a distance of several inches from the ear. The act of suction was repeated two or three times, and each time successfully. By having the patient perform Valsalva's experiment while I was exhausting the air in the meatus by aid of Siegle's apparatus, I found that the mucus could be drawn into the outer canal in larger quantity and more readily than without the patient's co-operation. The quantity of mucus thus withdrawn from the tympanum was so great that I could not avoid the belief that much of it must have come from the Eustachian tube. The hearing, which before the operation was about  $\frac{9}{12}$ , rose to  $\frac{1}{2}$  for the watch. No inflammatory reaction followed, nor did the patient complain of any special feeling of soreness about the ear.

On the 2d of April, four days later,—the hearing in the meantime not having increased beyond  $\frac{1}{2}$  for the watch, and the perforation having healed,—I repeated the operation. The quantity of mucus obtained was nearly the same as before, but the hearing remained unchanged. Thinking that very probably the ossicles were enveloped with mucus, I resorted to the use of a saturated solution of the bi-carbonate of soda for the pur-

pose of liquefying the mass. The outer canal was filled with the solution, and then, while the patient performed the act of swallowing, firm pressure was made from without upon the tragus, thus forcing the fluid into the tympanum and through the Eustachian tube into the nostrils. At the end of a few minutes suction was again performed, and a certain amount of fluid was withdrawn from the tympanum, but without any appreciable improvement in the hearing.

On the 3d of April, the operation was repeated. The soda solution was not forced in as before by means of pressure, but was injected through the perforation in the membrane by means of a hypodermic syringe, armed with a suitable bent nozzle of gold. This time, after the tympanum had been emptied as far as possible of its contents, a warm, weak solution of alum was injected into the cavity. The solution was of such a strength that the sour taste could barely be recognized by the tongue. It was allowed to remain about five minutes in the tympanum, and was then withdrawn in the manner already described. On this occasion, as on the two previous ones, the operation was not accompanied by pain. The fluids withdrawn from the tympanum were not tinged with blood, except on the first occasion, and then it evidently came from the incision in the membrana tympani.

On the 4th of April, I found the patient in very great suffering from his ear. The pain, he said, came on early that morning—that is, about twelve hours after the injection of the alum—and soon became severe. He referred it to the region immediately behind and above the ear. On examination, I found that there was moderate tenderness over the mastoid process; that the membrana tympani was red and abnormally convex, the perforation in it having entirely healed. A vertical incision in the posterior half of the membrane gave vent to a large drop of healthy pus, and was followed by some relief from pain. Five leeches were applied behind and in front of the ear, and afterward poultices were used.

From this time till the 13th of April—a little over a week—the patient enjoyed comparative freedom from pain. There was a free discharge of pus, through the perforation in the membrane, and little or no fever. The mastoid region, however, continued to remain tender on pressure.

From the 13th to the 16th, the pain steadily increased and was referred chiefly to the region behind the ear. The motion of the jaws in eating or speaking also became more and more painful. A vertical incision an inch long was made behind the ear, down to and through the periosteum, in the hope of checking the advance of the trouble in this direction. Poultices were also applied.

On the 17th and 18th, increasing suffering.

On the 19th of April, his condition was the following: Temperature 101.5°; pulse 92, and rather feeble; motion of jaws very painful; meatus

slit-shaped vertically, owing to the swelling of its walls ; the wound behind the ear imperfectly healed.

After consultation with Dr. Robert F. Weir, the patient was etherized and an opening was made in the mastoid process, with a one-fourth inch drill, to the depth of three-fifths of an inch. The outer surface of the bone was normal in appearance ; the mastoid cells were congested, small in size, and separated by strong, bony septa ; no pus was found. The opening was made on a level with the upper wall of the meatus, and about half an inch behind it. The only point of interest connected with the operation was the great prostration which followed it. It was only by active stimulation (accomplished with great difficulty) that a fatal syncope was prevented.

From the 19th to the 22d, the soft parts behind and below the wound became more and more swollen and painful. The temperature, which on the 20th had fallen to 98.5°, rose slowly to 101°. Warm poultices were frequently applied, and iron and quinine were given internally. From this date to the 27th, the patient appeared to be making rapid progress toward recovery. During the night of the 27th of April, the pain again returned with great severity, the temperature rose to 100°, the pulse to 120, and the skin near the wound again became very much swollen and tender on pressure. From the 29th of April the recovery was steady and rapid.

On the first of June, I found the meatus normal, the membrana tympani entire, all tenderness gone, and the hearing reduced to about  $\frac{1}{2}$  of the watch.

CASE XXIX.—Female, æt. circa thirty, and in excellent health. After exposure during house-cleaning on the 1st of May, 1872, she began to suffer from sore throat, slight deafness, and pain in the right ear. The pain soon extended to the parts behind the ear, and gradually increased in severity, robbing her of her sleep. On the 6th of May I saw her for the first time, and found the ear in the following condition : The external auditory canal normal ; the membrana tympani red and swollen, though entire ; the Eustachian tube closed to Politzer ; very marked tenderness on pressure, and some redness of the skin over the mastoid process. Upper portion of pharynx moderately congested. Watch heard when pressed against the ear. Four leeches applied over the mastoid process gave great relief.

May 9th.—Pain and tenderness entirely gone. A solution of nitrate of silver ( ʒ j.—ʒ j. aquæ ) applied to the still swollen membrana tympani.

May 13th.—No return of the pain. Swelling of the membrana tympani diminishing. Watch heard at a distance of half an inch. She subsequently had no return of the pain in that ear, and the improvement in hearing was steady and marked.

On the 8th of the following November I was consulted again for a very similar attack in the left ear. The history given was, that about the 1st of November she was attacked with a severe pain behind the ear, accompanied

by tenderness on pressure, and a little swelling. The application of six leeches to the affected part relieved these symptoms entirely, but on the previous night the pain returned with considerable severity. On examination I found the left membrana tympani sunken, but not congested. Watch heard at a distance of three feet. There was tenderness over the mastoid process, and some œdematous swelling of the integuments. Six leeches applied behind the left ear afforded entire relief.

CASE XXX.—Infant, seven months old, and apparently healthy. (New York Eye and Ear Infirmary.) October 21, 1874. For some time past the mother had noticed that there was a discharge from the left ear. Three days ago the child began to be very restless, and the mother then discovered that there was a swelling behind the left ear. This increased quite rapidly in size, and to-day it causes a marked dislocation of the auricle forward. The skin covering this tense swelling is red, and fluctuation can easily be distinguished on palpation. An incision affords escape to about a drachm of thick, healthy pus. By means of the probe introduced into the wound it is ascertained that a carious sinus exists in the central portion of the rudimentary mastoid process. As the probe passes inward along this sinus a crumbling condition of its bony walls can be distinguished. Tent introduced into the wound.

October 24th.—The mother reports that since the operation the child has been, so far as she could judge, perfectly well. The external wound has not yet healed, but there is very little discharge from it, and the surrounding skin appears to be quite healthy. The discharge from the meatus has also diminished in a marked degree. (Child not seen again.)

*Cases in which the pneumatic spaces are filled with pus or the intervening septa are in a carious condition.*—CASE XXXI.—Male, forty-two years of age, in good general condition of health. (New York Eye and Ear Infirmary.) February 11, 1874. Severe earache (R.) two months ago, followed, in the course of about two weeks, by a discharge from the auditory canal. Upon the appearance of the discharge, the pain diminished in severity. During the past few days he has noticed blood in the discharge. On examination, the canal is found to be blocked by the presence of a rather firm mass of granulation-tissue. There is an appreciable swelling behind the ear. Firm pressure upon it causes about a drachm of sero-pus to escape from the orifice of the external auditory canal. The swelling, which is of a doughy character, extends some distance below the mastoid process, on the side of the neck. By aid of the probe it is ascertained that the mass of granulation-tissue springs from the posterior wall of the canal, a little beyond the junction of the cartilaginous with the osseous portion of the canal. At the base of the mass the probe enters a sinus which leads upward and backward into the bone. At the bottom of it a roughened surface is felt. The removal of

the polypoid mass revealed the existence of an intact drum-membrane. Watch heard at a distance of eight inches.

February 18th.—Granulation-tissue is being slowly reproduced.

February 21st.—Free incision through the mastoid integuments. At the bottom of the wound the probe encounters quite an extensive surface of exposed bone.

February 25th.—Wound healing naturally.

February 28th.—Polypoid granulations in canal removed a second time. Two probes passed, the one through the external wound, the other through the opening in the meatus, meet. Almost entire freedom from pain.

March 7th.—External wound reduced to very small dimensions. The probe no longer encounters exposed bone at the bottom of it. Third removal of granulations in the meatus; the remaining raw surface and the walls of the sinus freely cauterized with a bead of nitrate of silver fused upon the end of a probe.

March 14th.—Discharge from meatus has ceased. Sinus has apparently healed (scabbed over).

March 18th.—Considerable pain in the region of the ear during the past two or three days. Discharge has returned, and to-day he is again free from pain. On exploration I find that the sinus is now open, and exposed bone can be felt at the bottom of it.

March 25th.—Granulations in the meatus removed for the fourth time. Nitrate of silver applied freely.

April 4th.—No discharge during the past three or four days. Granulation-tissue, however, still develops at the mouth of the sinus.

April 8th.—Fifth removal of granulation-tissue.

May 9th.—Since last note a few small fragments of bone have come away with the slight discharge from the meatus and from the external wound. No return of granulation-tissue.

Soon afterward I learned that the external wound had healed and that the discharge from the meatus had not reappeared.

CASE XXXII.—April 8, 1871, I was called to see Mrs. Peter Green (colored), aged forty-seven, and of strong constitution. The story was, that on the preceding Christmas she had been attacked with severe pain in the right ear, followed soon after by a purulent discharge. Eight days previously, the discharge having almost ceased, she had again suffered from a severe earache, sleeplessness, occasional vomiting, and at times incoherence of speech. At the time of my visit she appeared to be in great suffering. Pulse 104 and rather feeble. No heat of skin. Pus escapes through the Eustachian tube into the pharynx. Marked tenderness over the mastoid process. The external auditory canal closed by the swelling of its walls. A free incision over the mastoid process and warm fomentations.



April 9th.—Last night, soon after the operation, the discharge reappeared.

April 18th.—Comparative freedom from pain since the last note. To-day I discovered a mass of granulations springing from the upper and posterior wall of the meatus, a little beyond the junction of the cartilaginous with the osseous portion.

May 25th.—Occasional attacks of pain.

June 5th.—Another severe attack of pain last night. Motion of the jaws painful. Mastoid process tender on pressure. Ordered two leeches to the part.

June 6th.—Some relief from the leeches.

June 15th.—Since the last note the pain has been steadily growing worse. Leeches have been applied from time to time, but with only temporary relief. To-day there has been some nausea after meals.

June 16th.—A sinus discovered leading from the mass of granulations mentioned above to the mastoid cells. Consultation with Dr. Robert F. Weir. Perforation of the mastoid process advised. The patient being under the influence of ether, an incision was made exposing to view the surface of the right mastoid process. The lower part of the process appeared to be softer than natural. The bone was perforated with a small drill, and the opening was afterward enlarged by means of a small gouge. No pus found. Mastoid cells congested. Two probes introduced into the mastoid process, the one through the sinus, the other through the newly made opening, were found to meet.

From this time there was a rapid improvement in all the symptoms. Her general health, which had suffered materially by the prolonged sickness, soon regained its usual standard. On the 27th of July I was unable to find any trace of the fistulous opening in the meatus, and the discharge had entirely ceased. No return of the pain at any time.

CASE XXXIII.—William McClusky, a resident of Orange, N. J., twenty-one years of age, of a healthy constitution, consulted me September 4, 1872, for a painful affection of the mastoid process. He stated that in June he was seized with a severe pain in the ear after bathing. The pain continued for three or four days, and then stopped, leaving him quite deaf in the affected ear. At the expiration of two weeks a discharge appeared, and this had continued since until the fourth or fifth day previous to his visit to me. Shortly before the discharge stopped, he noticed some tenderness behind the affected ear. The pain, which for four days had been growing steadily worse, was referred to the mastoid region, whence it extended upward and backward to the parietal and occipital regions. Tinnitus. Appetite poor. Countenance pale. Watch heard at a distance of four inches on the affected side. The skin covering the mastoid process red and swollen. External auditory canal diminished in calibre by the falling forward

of the posterior cutaneous wall. Membrana tympani invisible. Incision of the integuments covering mastoid process. Free escape of pus and blood. The periosteum was dissected up a short distance on either side and the underlying bone appeared to be healthy. The following day, September 5th, while pressing pretty firmly against the bone with a steel director, it seemed to me that the point of the instrument met with less than the usual resistance. I then attempted to perforate the outer shell with a small steel drill, and in doing so suddenly exposed a large abscess which nearly filled the entire mastoid process. The opening was further enlarged with a conical drill until the little finger could be admitted, and the contents were then entirely evacuated. Tent inserted and patient allowed to return to his home where he said that he could get further medical treatment. The incision of the integuments on the previous day had already greatly alleviated his sufferings.

On the 14th of November following he wrote: "The pain never returned since you performed the operation, and the wound healed inside of ten days. I went to a doctor to have it dressed, but he refused to have anything to do with it, and said that it was a very dangerous operation, and might have killed me; so I went to a friend of mine and had it dressed. In ten days the outside was all healed, and I could hear a great deal better. Now I can hear my watch tick about twenty-four inches from my ear."

CASE XXXIV.—Male, twenty-eight years of age, and of robust constitution. (New York Eye and Ear Infirmary.) August 25, 1875. About ten days ago he began to suffer from pain in the right ear, after bathing in the ocean. A discharge soon made its appearance, but the pain has continued unabated up to the present time. On examination I find the drum-membrane red, swollen, and perforated. The skin covering the mastoid process is red, swollen, and tender when pressed with the finger. Free incision of the mastoid integuments; warm douche at home.

September 15th.—The incision afforded almost entire relief from pain. The wound, however, has not yet fully healed, and more or less tenderness still remains in the vicinity. The discharge from the meatus is abundant.

October 7th.—During the past few days the discharge has been slight, but the pain has returned and is now quite severe. It involves the entire right side of the head. There is still tenderness on pressure behind the ear, and the skin in this region is red and swollen. Patient having been brought under the influence of ether, the mastoid integuments were divided in the line of the former incision, and the drill was applied at the usual point on the surface of the process, where the periosteum was found to have become separated from the underlying bone throughout a limited area. After two or three turns the instrument suddenly entered an oblong cavity, estimated to be about three-fifths of an inch long (vertically) and about a quarter of an inch wide. The bone through which the drill passed felt ap-

preciably softer than natural. As the bleeding from the external wound was quite active, it was impossible to ascertain whether the cavity referred to contained pus, or not. No fragments of bone were discovered. Tent introduced into the wound.

October 8th.—Patient passed a comfortable night. Temperature 99.5° F. Carbolized oil dressings.

October 9th.—Quite sharp pain last night for a few hours. To-day he feels again quite free from pain. Introduction of tent to be discontinued.

October 12th.—Decided increase of pain since yesterday. It is referred to the mastoid region. Pulse is to-day quite weak (104), and patient has a decidedly drowsy appearance. Temperature 99° F. Three leeches to be applied behind the ear; afterward hot poultices.

October 18th.—A few days ago a swelling began to develop on the right side of the head, midway between the mastoid process and the occipital protuberance, but on a little higher level than the line drawn from the latter point to the external meatus. This swelling has steadily increased in size until now it forms a well-defined lump on the side of the head. On palpation distinct fluctuation is felt. The drowsiness noticed on the 12th still continues. At the same time the patient's countenance wears an expression of suffering. An incision through the centre of the circumscribed swelling afforded escape to about half a drachm of thick pus. By means of the probe it was ascertained that the pus lay between the periosteum and the bone. Pulse ranges from 76 to 84, and is fairly strong.

October 20th.—Decided improvement in patient's condition. He has lost his appearance of drowsiness, and says that the pain is very much less than on the 18th. Both external wounds still remain open. The discharge from the auditory canal has nearly ceased.

October 27th.—Patient again complains of pain in the right side of the head, more particularly toward the occipital region and in the temple. The wound made by the last incision has apparently healed, and no visible swelling remains, but tenderness on pressure still persists in this region. A probe directed backward and upward from the bottom of the mastoid wound passes easily onward a distance of an inch and a half without encountering any resistance. Firm pressure over the point reached by the end of the probe causes a few drops of pus to escape from the mastoid wound. During the past four days, the patient has been able to leave his bed and walk about the ward.

November 20th.—Since last note patient's condition has changed very little. His general condition is good. The pain has moderated to such an extent that he no longer complains of it. The second wound is again open in the form of a very small sinus. Denuded bone can still be felt through both openings.

November 24th.—The two fistulous openings not showing any tendency to heal, I to-day connected them by a deep incision, thus converting the

pus-secreting region into an open wound. The bone was found to be denuded over quite a large area, but at no point could anything like a carious process be made out. At one spot an opening in the bone was found. It led in an upward direction, and its upper edge was sharp and shelving. Whether this opening, which in a normal state probably afforded a passage for one of the emissary veins, in the present pathological condition of the parts furnished an outlet for the pus that had accumulated between the periosteum and the bone, I was unable to determine. Wound to be stuffed daily with charpie, for the purpose of favoring its healing from the bottom.

December 15th.—For several days past the patient has been entirely free from pain in the head. The wound is apparently healing permanently.

January 15th.—External wound has healed perfectly, and patient feels as well as he ever did.

*Temperature Record (Fahrenheit).*

	Morning.	Evening.
October 7 .....	—	99°
8 .....	98.5°	99.5°
9 .....	98.7°	99.5°
10 .....	98.7°	99.5°
11 .....	98.7°	99.5°
12 .....	99°	99°
13 .....	99°	99°
14 .....	98.7°	99°
15 .....	98.7°	99°
16 .....	98.7°	99°
17 .....	98.5°	98.5°
18 .....	98.5°	98.5°
19 .....	98.5°	98.5°
20 .....	98.5°	98.5°

CASE XXXV.—Male, fifty-three years of age, in a poor general condition of health. (New York Eye and Ear Infirmary.) March 29, 1876. Four days ago he got thoroughly chilled and wet in a rain-storm. The following day he experienced quite severe pain in the right ear, and a slightly bloody discharge made its appearance at the orifice of the external auditory canal. From that day to the present time the pain has steadily increased, and it is no longer confined to the ear, but involves the entire right side of the head. Five leeches to be applied behind the ear, where there is tenderness on pressure. Poultices.

April 7th.—Pain continues with unabated severity. The skin covering the mastoid process is red, swollen, and tender. A free incision through

these parts, including the periosteum, was followed by a slight discharge of a watery nature.

April 19th.—Free discharge of pus both from the meatus and from the wound. At the bottom of the latter the bone is found to be denuded of its periosteum throughout an area equal in size to a nickel five cent piece. Feeling confident that the mastoid cells must be in a condition of active inflammation, I applied the drill to the surface of the bone, at the usual spot, and, after a few turns of the instruments, reached a distinct cavity of moderate size, containing thick pus and fragments of the bony septa natural to these parts. No anæsthetic was used.

April 22d.—Decided relief from pain since the operation.

May 10th.—No return of pain. Two small fragments of bone removed from external wound, which has nearly healed. Discharge from meatus has ceased. Although free from pain, and not affected with a discharge of sufficient amount to act as a drain upon his strength, the patient has the appearance of a person far advanced in consumption. The change that has taken place in this respect since the latter part of March is very marked. The wretchedness of his hygienic surroundings is probably as much the cause of this malnutrition as the disease of the mastoid process.

Patient remained under observation until May, 1877. At that time a fistulous opening still existed in the mastoid region. For days he would have no active discharge, and then the scab would yield and give exit to a few drops of pus. The probe could then still be passed deeply into the body of the mastoid process. At times it encountered a sort of bone sand, but at the last visits merely denuded bone was encountered. His general health had improved, and he had not developed any symptoms of pulmonary phthisis. The middle ear proper remained free from evidences of active disease.

CASE XXXVI.—Female about fifty years of age, and of apparently robust health, New York City, January 5, 1874.

About three weeks ago she began to suffer from pain in the left ear. It steadily increased in severity, and a few days ago a discharge showed itself in the external auditory canal. Dr. George R. Cutter, who was then called to see the case, applied several leeches in close proximity to the ear. As the relief obtained was only partial, he yesterday incised the mastoid integuments freely. At the present time the pain is referred to the entire left side of the head, but it is much less severe than before the incision was made. The mastoid integuments are still red, swollen, and tender. The external auditory canal is filled with pus. With the view of increasing the counter-irritant effect of the wound in the mastoid integuments, I advised free cauterization of its raw surfaces with nitrate of silver.

January 15th.—For a few days the patient remained comparatively free from pain, but it soon returned and is now again quite severe and con-

stant. While I was exploring the bottom of the external wound with the probe, the end of the instrument engaged itself in an opening in the bone, and I then pushed it on to a depth of a quarter of an inch. The withdrawal of the probe was followed by the appearance of a drop or two of pus at the surface of the wound. By means of the larger of the two drills, I established an opening in the mastoid process, fully half an inch in length and a quarter of an inch in diameter. No appreciable softening of the bone was recognized. Upon withdrawing the drill an unusually copious flow of blood followed. The hemorrhage was allowed to continue for a short time, but as it showed no tendency to grow less active, styptic cotton and pressure were resorted to for the purpose of arresting the flow.

From this time forward the patient improved quite rapidly, and was soon considered well enough to resume her daily duties and dispense with medical aid.

March 4th.—For a period of nearly five weeks following the operation, patient remained free from pain. During the past ten days, however, she has again been in suffering. The pain has been steadily increasing and is now quite severe; it is referred to the region above and behind the ear, and even as far back as the occipital protuberance. On examination of the meatus it is found that a mass, consisting partly of prolapsed upper cutaneous wall and partly of granulation-tissue, blocks up the inner end of the canal. A probe introduced into the sinus behind the ear encounters at the bottom of it denuded bone surface over a limited extent. I removed the granulation-tissue in the meatus by means of Blake's snare, and ordered five leeches to be applied around the ear. Patient to remain in bed.

March 5th.—Decided relief. The prolapsed wall of the meatus has returned nearly to its normal position. The discharge is abundant.

March 9th.—Since yesterday the discharge has markedly diminished in quantity, and the pain has again returned. It is now referred by the patient almost entirely to the left temple, which is very tender on pressure over an area of about the size of a silver dollar. The pain is often of a shooting character. The muscles about the left eye are to-day in a constant state of contraction. Three leeches to be applied to the region of greatest tenderness.

March 10th.—Very little, if any, relief from the leeches. Discharge from the ear still very scanty. She says that the pains occasionally shoot through from the side to the back of the head. Temperature, 100° F., pulse, 82. Blister to be applied to the left temple. She is also to begin taking iodide of potassium, five grains three times a day, and two pills of aloes and iron every night (for her habitual constipation).

March 11th.—The discharge from the ear is again quite abundant, and patient suffers less from pain. To-day there is marked oedema of the left zygoma and eyelids. Temperature, 102° F., pulse, 80.

March 12th.—Last night patient suffered intensely from pain in the

left frontal region. A hypodermic injection of Magendie's solution of the sulphate of morphia (℥.vii.) afforded relief for several hours. At the time of my visit (3 P.M.), however, she was again in great suffering. Discharge continues to be abundant. Temperature, 102° F. In the belief that the continuation of the pain and inflammation might be due to the blocking-up of the matter at its only point of exit, *viz.*, the small and slit-shaped opening in the membrana tympani, I made a free incision through the posterior half of the drum-membrane and extended it upward through the posterior fold. The hemorrhage was very slight, and no noticeable escape of pus followed the incision. Nevertheless, in the course of a few minutes, the patient expressed herself as having very decidedly less pain. Her expression of countenance also indicated this relief in a marked manner. I ordered Politzer's inflation to be carried out two or three times in the course of the day, for the purpose of preventing the edges of the incision from healing too soon.

March 13th.—Patient feels very comfortable to-day. Temperature, 100.6° F. in the morning, 99.5° F. in the evening.

March 14th.—She continues to remain free from pain. Appetite very poor. Oedema of eyelids and vicinity disappearing. Temperature, 99° F. in the morning, 100.2° F. in the evening. Iodide of potassium to be discontinued.

March 16th.—Temperature, 99.5° F.

March 17th.—Temperature, 98.5° F.

March 25th.—During the past week she has been entirely free from pain and there has been no discharge from the ear. The sinus behind the ear has also healed perfectly.

CASE XXXVII.—Female, thirty-five years of age, in fair general health, March 17, 1876. A little over three weeks ago a severe earache developed in the left ear. In the course of a few days a purulent discharge from the external auditory canal made its appearance, and the pain then became more tolerable. For a period of a few days she remained entirely free from pain, but four days ago it returned with increased violence, and has continued, with very little if any abatement, up to the present time. The discharge is now profuse, and the pain involves the entire left side of the head. There is decided tenderness over the mastoid process, but there is no appreciable redness or swelling. Examination with the speculum and reflected light reveals a prolapsed condition of the upper cutaneous wall of the meatus. Pressure with the cotton-holder causes pain. The drum-membrane is invisible. Mastoid integuments freely incised. Ordered liq. opii. comp., gtt. xv. every hour (beginning at 8 P.M.), until sleep is procured.

March 18th.—Incision afforded decided relief from pain. She feels comparatively comfortable this morning.

March 20th.—No return of pain. Appetite is fair. More or less œdema of the skin in the vicinity of the external wound.

March 24th.—Patient remains in a very weak condition. Pulse 125 and feeble. Temperature normal. She has had no chills or chilly sensations, no sweats, no nausea. At times she complains of pain in the head, but says that it is not severe. The external wound still remains unhealed at one point, and the probe introduced into it encounters, at the bottom of the sinus, denuded bone. In the vicinity there is still decided tenderness. After consultation with my father, Dr. Gurdon Buck, the patient was etherized, the wound was enlarged, and the larger drill was applied to the denuded bone surface. The bone was found to be quite soft, and a cavity (one of the larger cells?) was reached after two or three revolutions of the drill. Owing to the amount of blood present in the wound, it was impossible to determine whether this cavity contained pus or not. No loose fragments of bone were felt with the probe.

March 25th.—She passed a rather uncomfortable night, on account of pain. This morning, however, she is free from pain, and in good spirits.

March 26th.—A little fever toward night.

March 27th.—Ordered quin. sulph., gr. iv., to be taken at 3 P.M., also a milk punch at night.

March 28th.—No return of fever last night. General condition improved. Quinine and milk punches to be continued.

April 12th.—Improvement has been going on steadily but very slowly. The wound behind the ear has nearly healed, and there is scarcely any discharge from the ear. Yesterday she began to complain of pain in the left shoulder and clavicular region, and in the muscles of the left side of the neck. Slight tenderness, but no redness or swelling of these parts. Temperature a little above the normal.

May 11th.—Since last note, patient has passed through a severe siege of acute polyarthritis, which has left her in a condition of extreme weakness. The discharge from the wound, which had nearly ceased, has again become active, and undoubtedly contributes largely to her feeble state. She has had no return of acute pain in the ear and head, but at times has a dull headache which is confined to the left side. She leaves to-day for the country, on a visit to her relatives. (About a year later I learned that she had recovered her health perfectly.)

CASE XXXVIII.—Strong, healthy woman, twenty-six years of age. While nursing a young infant, she was suddenly attacked with a pain in the left ear, which lasted about twenty-four hours and then passed off. A week later, the pain returned with still greater severity, and lasted three days before it began to diminish somewhat in intensity. With the abatement of the pain she noticed the appearance of a slight yellow discharge at the outer orifice. Five days later (February 12, 1873), she visited the In-



firmly. The inner half of the meatus and the membrana tympani were found to be very much swollen, and accordingly they were incised.

For ten days subsequently she enjoyed almost entire relief from pain. On the 23d, however, she again began to suffer from her ear, the pain this time being referred chiefly to the region of the mastoid process. In the course of two days the pain became severe and extended over the entire left side of the head. Despite this she continued to nurse her infant, and did not visit the Infirmary till March the first. By that time there were evident symptoms of commencing mastoid trouble ; namely, redness of the skin, œdema, and tenderness on pressure. No appreciable change had taken place in the condition of the meatus or membrana tympani. She was advised to have the bone perforated behind the ear, but she refused to submit to the operation. A free incision, however, was made over the mastoid process, and the patient was ordered to apply poultices to the part so long as any pain remained.

The patient's next visit to the Infirmary was on the twelfth day of March. Her story was, that the incision had afforded her relief from the pain for a day or two, but that the ear soon became as painful as before. Her countenance also indicated prolonged suffering. The wound had entirely healed, but the mastoid integuments were red, swollen, and very tender to the touch.

Her consent having been obtained, the patient was etherized and the mastoid process was perforated, as in the preceding case. The outer surface of the bone appeared to be perfectly healthy. Instead of applying the drill at the spot usually selected, it was made to enter the mastoid process not far from its projecting tip. The cell-structure was thus reached at a very slight depth and the drill was easily made to penetrate a distance of about a third of an inch. It was hoped that this more distant opening would suffice to relieve the trouble.

The day following I found her condition improved. The relief from pain was very decided.

March 14th.—Erysipelas on left side of face.

March 15th.—Entire face involved. Temperature, 105°. Pulse, 108. Wound healthy in appearance. Little or no pain about the ear.

On the 17th of March I found her again suffering acutely from pain in the mastoid region. A careful exploration of the wound with the probe led to the discovery of a small sinus in the upper portion of the process, at or close to the spot where the perforation is usually made. The probe could be passed into the bone to a depth of three-fourths of an inch without meeting any obstacle ; it could also be rotated in a vertical plane as if in a cavity of considerable size. The drill was placed over the outer orifice of the sinus, and with one or two turns made to penetrate into a distinct cavity. On withdrawing the instrument, a moderate amount of venous blood escaped, together with a little pus. The bony walls of the

cavity were in a softened condition. The venous hemorrhage soon ceased of itself.

The next day, March 18th, I again found the patient comparatively free from pain. The erysipelas was evidently subsiding (temperature  $101^{\circ}$ ), and she appeared every way better. The soft parts near the wound, especially behind it, were still very much swollen. From this time forward the improvement was steady and rapid.

On the 29th of March she left the Infirmary. There had been no discharge from the meatus since the operation, and for more than a week she had been entirely free from pain. The wound still remained open, but it was very much reduced in size and in a perfectly healthy condition. I have not since had an opportunity of seeing the case, as the patient did not subsequently return to the Infirmary.

CASE XXXIX.—Male, silkweaver by occupation, thirty years of age, and of rather poor physique. February 7, 1874. Fifteen months ago patient was attacked with a severe pain in the right ear. The inflammation soon spread to the mastoid cells, an abscess formed behind the ear, and at the end of the eighth week it broke spontaneously, affording him relief from his prolonged suffering. The fistulous opening which remained after the abscess broke, did not heal until six months later. A purulent discharge from the ear has been present from almost the beginning of the attack, and is now occasionally tinged with blood. Two days ago the pain returned. It is confined chiefly to the mastoid region. On examination, the external auditory canal is found to be narrowed (slit-shaped almost vertically) to such an extent that the deeper parts cannot be seen. The discharge consists of pus tinged with blood. No tenderness on pressure over the mastoid process or in front of the tragus. Three leeches to be applied to the mastoid region.

May 23d.—The pain was relieved by the leeches, and patient went to the country for a few weeks. Two days ago the pain returned, and the discharge from the ear became more abundant. The pain is referred to the right temple. Warm douche to be used freely.

May 27th.—Pain continues. Blister to be applied in front of the ear.

June 3d.—Entirely free from pain.

July 9th.—During the past three weeks he has again suffered a great deal from pain involving the entire right side of the head. Diarrhœa has set in, and a fistulous opening has again established itself behind the ear. The discharge of pus from this opening is quite abundant, and there is no swelling or tenderness in the vicinity. A large polypoid growth fills the external auditory canal. After removing this mass with the snare, I discovered, by aid of the probe, that the inner and posterior portion of the meatus (vicinity of antrum) was in a carious condition. The probe, introduced into the sinus behind the ear, encountered denuded bone, and engaged it-

self in a small opening in the mastoid process which led into a cavity containing loose fragments. The patient having been etherized, I made a free incision through the skin covering the mastoid process, enlarged the opening in the bone by means of the larger drill, made a new opening a short distance above the old one, and then broke down the intervening bridge of bone. A large and sharply defined cavity, filled with fluid and cheesy pus and several fragments of bone, was found in the unusually large mastoid process. The highest point of the cavity was fully three-fourths of an inch above the level of the upper wall of the meatus. It was estimated that the cavity contained at least a drachm of pus. The largest fragment of loose bone removed measured two-thirds of an inch in length, and consisted evidently of the peculiar honey-combed structure of the mastoid cells.

July 10th.—Complete freedom from pain. Appetite good.

July 11th.—Moderate swelling of the parts surrounding the wound. Patient doing well in every respect.

July 22d.—Since the last note patient has complained very much of pain in the lower jaw on the right side. There is no redness or swelling in this region, but the jaw on this side is everywhere tender to the touch. On exploring the meatus I discovered that it was nearly closed by a collection of pus lying between the upper and posterior bony wall and the skin of the canal. Near the stump of the polypus (removed July 9th) I discovered a small opening in the skin which was apparently the only outlet for this collection of pus. Upon enlarging this opening I was able to press out nearly half a drachm of pus, and one small fragment of exfoliated bone; other small fragments could be felt with the probe, but no attempt was made to remove them.

July 25th.—Great improvement since last note. Patient eats and sleeps well and is entirely free from pain. On wiping out the orifice of the ear he occasionally finds a small fragment of bone.

September 20th.—I have not seen the patient since the last note, but find him to-day in a very low state. He has no pain in or about the ear, but complains of a "headache" which comes on every afternoon. His general appearance is that of a man in the last stage of consumption. The probe can now be passed, through the opening in the posterior and upper wall of the external auditory canal, upward and backward a distance of fully two inches from the outer orifice, without encountering any resistance. The presence of smaller and larger fragments of bone can be readily distinguished as the probe is pushed along the fistulous track. Sinus in the mastoid region (behind the auricle) still open.

I did not see the patient subsequently, but am safe in saying that he must have died very soon after I saw him.

CASE XL.—(New York Eye and Ear Infirmary.) Mrs. Sarah Curry, æt. 62, of a rather feeble constitution, consulted me July 10, 1872, for a painful affection of the left ear. Her story was that for many years she had been

somewhat hard of hearing, especially in the left ear, but had never had any discharge from either ear. Two years previously she had an attack of facial paralysis, affecting the left side. After a certain length of time this passed off entirely. About nine weeks previously she began to suffer from pain in and behind the left ear and extending over the entire left side of the head. There was also tenderness behind the ear. For two days and nights the pain was severe. After that there remained a steady, dull aching, together with a moderate degree of tenderness behind the ear. Two weeks previously the acute pain again returned, and since then she had suffered almost constantly up to the time of her visit to the Infirmary.

On examination the meatus was found nearly closed by a falling forward of the posterior cutaneous wall. Membrana tympani invisible. No appreciable tenderness in the meatus. No discharge. Tenderness over the mastoid process, and also over the lower part of the parietal bone. Watch heard when pressed against the ear. The patient's countenance was indicative of great suffering. Incision of the integuments and periosteum covering the mastoid process. No pus found.

July 13th.—Little or no relief afforded by the incision. To-day the auricle is pushed forward by a swelling behind the ear. Incision entirely healed. A second incision gave exit to about half an ounce of pus. No roughened bone or sinus discovered.

July 18th.—Comparative relief from pain until last night, when the pain again became severe. She refers it to the mastoid process, the top and back of the head. The meatus is less swollen and the membrana tympani can now be seen. It is entire, but of a very tough, opaque, tendinous appearance. Eustachian tube open. The entrance of air is accompanied by râles. No brain symptoms. Consultation with Dr. Robert F. Weir. Mastoid process perforated with a conical drill. The outer surface of the bone found to be in every respect perfectly sound. At a depth of about one-fifth of an inch pus was found filling a cavity about the size of a filbert. Pus removed with pledgets of cotton, and outer orifice of the cavity enlarged sufficiently to admit the end of my little finger.

July 19th.—Patient much relieved by the operation, but she still complains of soreness over the back and side of the head. Pressure over the left occipital and parietal regions produces pain.

July 20th.—Severe pain in the head, behind the mastoid process. Appetite only moderately good. Is losing strength. Stimulus ordered. Wound discharging freely.

July 22d.—Still severe pain behind the mastoid process. Consultation with my father, Dr. Gurdon Buck. Skull trephined about three-fourths of an inch behind the mastoid process, at the point of greatest tenderness. The outer surface of the bone appeared to be perfectly healthy; but on withdrawing the trephine, after sawing through the outer table, the circular track was found to be filled with healthy pus, which had welled up from

the intervening cancellous diploë. No appreciable softening of the bone. The removal of the inner button of bone exposed to view a tense, deep-red dura mater, but no pus. The subsequent oozing of venous blood from the ruptured branchlets was readily checked by laying a pledget of cotton-batting in the circular opening.

July 23d, 11 A.M.—Patient slept a part of the night. This morning she has considerable heat of skin. Pulse 100 and feeble. Less pain in the head. Eight P.M., pulse 106 and feeble. Intellect perfectly clear. The discharge from the mastoid process appears to have nearly ceased. Vomited once this evening.

July 24th, noon.—Patient is evidently sinking. Pulse 110 and very feeble. Respirations 44. No râles over anterior and lateral portions of the chest. Intellect still clear, but she has not sufficient strength to speak in an audible tone when answering my questions. She died on the 26th, apparently from exhaustion.

Post-mortem examination refused by the friends.

CASE XLI.—Boy, eight years of age, and in apparently vigorous health. (New York Eye and Ear Infirmary.) October 11, 1876. Since childhood he has had an open sore behind the right ear, associated with a purulent discharge from the external auditory canal. From time to time he has had attacks of pain involving the region of the ear and also the entire right side of the head. These attacks have been due, the parents think, to “gatherings” behind the ear; for as soon as a discharge took place from the open sore, which was generally scabbed over, the boy experienced relief from his pain. On examination I find the mastoid region occupied by a thick scab, covering the entrance to an excavation in the bone. A probe introduced into this cavity, after the scab had been removed, passes directly inward, without encountering the slightest resistance, to a depth of an inch and a half; when directed more backward, it encounters resistance at a depth of about an inch; and when directed downward, it passes unobstructed down to the very tip of the process. At no point does the probe encounter denuded bone surface. The entire cavity, however, is filled with thick and exceedingly foul pus, showing that in all probability an active carious process is still going on at some points. No examination was made of the meatus and middle ear, and patient never returned for treatment, which was to have consisted in a very careful daily cleansing of the cavity with warm carbolated (very weak) water.

CASE XLII.—Male, thirty-seven years of age, in poor general condition (pulmonary phthisis). (New York Eye and Ear Infirmary.) January 5, 1876. He can give no satisfactory account of the commencement of his ear disease. He is positive, however, that the discharge from the left ear dates only eight months back. About ten days ago he began to suffer from

pain in the affected ear. It rapidly increased in severity, and involved the entire left side of the head. On examination I find the meatus filled with pus. The membrana tympani is destroyed, and the anvil lies free on the bottom of the tympanum. The upper cutaneous wall of the meatus droops. No denuded bone surface can be found with the probe. There is tenderness on pressure over the upper portion of the mastoid process. There is also slight paresis of the muscles of the left side of the face. Three leeches to be applied behind the ear; patient to remain in bed.

January 12th.—Well-marked facial paralysis of the left side. Comparatively free from pain during the past four days. (No further data.)

CASE XLIII.—Female, twenty-five years of age, and apparently far advanced in phthisis. August 20, 1873. About one year ago she had an attack of acute inflammation of the left middle ear. The pain was severe for about a day. A discharge then made its appearance, and the pain rapidly diminished in severity. Simultaneously with this attack the patient began to cough, to lose flesh, and occasionally to raise small quantities of blood. The discharge from the ear had continued uninterruptedly, and she had experienced frequent attacks of pain, which involved the left side of the head, and especially the left temple. On examination a mass of granulation-tissue was found occupying the outer portion of the meatus. It was removed with the snare, and was found to spring from the upper and posterior portion of the canal, close to the junction of the cartilaginous with the osseous portion. Its point of origin corresponded with the entrance to a sinus that led upward and backward into the mastoid cells. The probe encountered loose fragments of bone in its course. Deeper parts of ear concealed from view. There was tenderness on pressure over the mastoid process, and the skin at this point had a purplish appearance.

The unlikelihood of obtaining any material benefit from an operation, if made under such conditions, seemed to me to justify a course of non-interference. (The patient was not seen again.)

CASE XLIV.—Mr. I. H. N., *æt.* 40, a sufferer from pulmonary tuberculosis, was sent to me in consultation by Dr. William Hyde, of Stonington, Conn. July 12, 1872. He stated that he became somewhat deaf in the left ear eight years previously. In the autumn of 1871 he was attacked with pain, roaring and throbbing in the left ear, followed in the course of a week by a discharge. Since then the discharge had never ceased, and there had always been more or less pain. On one occasion he found a small fragment of bone in the discharge. Pain quite severe recently, but not referred specially to the mastoid process.

The condition of the patient at the time I saw him was that of a person advanced in phthisis. An examination of the ear revealed a marked degree

of deafness, tenderness over the mastoid process, and pus escaping from the meatus, which was quite blocked up by the presence of a mass of granulations, springing from the upper and posterior cutaneous wall. During the exploration I extracted four loose fragments of bone, which were evidently bony septa from the mastoid cells. By aid of a curved probe I ascertained that a sinus led from the meatus (quite near the outer end of the osseous portion) backward into the very centre of the mastoid process. In its course the probe encountered two or three sharp projecting spiculae of bone. The patient was so feeble that I was obliged to desist from further exploration.

On the 28th of September the patient died, with no other symptoms than those of exhaustion. Two days before death, there was a considerable hemorrhage from the ear.

No post-mortem examination was made.

### III. *Inflammation of the External Periosteum of the Mastoid Process.*

Some writers describe a primary periostitis of the mastoid process. While I do not wish to deny the existence of such an affection, I must confess that I have never yet seen a case to which I should feel justified in giving the title of a primary idiopathic mastoid periostitis. Even the traumatic form, I think, must be quite rare, as I can find but one instance of the kind in my records. The history of this case is as follows :

CASE XLV.—The patient, a strong laboring man, twenty-six years of age, sought relief at the Infirmary, on the 15th of October, 1873, for a large, tense, fluctuating swelling which occupied the region just above and behind the right ear. He stated that four months previously he had received a blow on the right side of the head. The injured spot had never ceased to be tender and painful since, and recently a swelling had made its appearance in this region. He had not observed any loss of hearing in the right ear, and on testing it with the watch I found that he could hear the ticking at a distance of six inches. A free incision at the most dependent portion of the tumor afforded escape to about two ounces of thick creamy pus. After the pus had been evacuated, a tent was introduced into the wound, and the patient was told to introduce fresh tents from time to time. (My notes, unfortunately, do not state whether exposed bone was found or not.)

November 1st.—Patient has allowed the external wound to heal, and there is now a second collection of pus, almost as large as that first evacuated. Incision repeated.

The patient was very faithful after this in introducing a fresh tent daily, and in the course of about two weeks the wound healed permanently.

On two or three occasions I have seen infants or very young children with large, tense swellings behind their ears, which seemed to have developed independently of any discoverable disease of the external auditory canal or middle ear. In these cases, which I had an opportunity of examining only after the swelling had attained a considerable size, I assumed that the primary disease was an acute purulent inflammation of the middle ear; and that the pus had found an easier way of escape through the opening for the central mastoid emissary vein than through the drum-membrane (which, probably in these particular cases, was unusually resistant). The antrum lies so near the surface in young children, and the intervening bone is so soft in comparison with that of the adult mastoid process, that it is quite easy to understand how this unusual route might, in certain cases, be the easier one of the two for the pus to follow. I give, below, the history of one of these cases.

CASE XLVI.—Child, twelve months old, well-nourished, but pale. April 14, 1879. About four weeks ago the child became very fretful and feverish, and seemed to be in suffering. It was not, however, until several days later that the parents discovered that there was a small swelling behind the ear. This has gone on slowly increasing up to the present time; all sorts of remedies having been tried, in the interval, to dissipate the swelling. On examination the auricle is found to be pushed markedly forward by a tense, hemispherical swelling situated immediately upon the mastoid process and extending beyond its limits. The external auditory canal was so narrow that I was unable to obtain a view of the drum-membrane. The child, however, had never had a discharge from either ear. A free vertical incision gave exit to at least a drachm of thick healthy pus. By means of the probe it was ascertained that the mastoid process was extensively denuded of its periosteum. A tent was introduced into the wound, and left there until the following morning.

Ten days later I learned from the attending physician that the external wound had healed, that the auricle had returned to its natural position, and that the child was as well as it had ever been.

In the following case the pathology of the disease is by no means clear. While the periostitis of the mastoid process (including the posterior wall of the external auditory canal) constitutes the most striking feature of the disease, it is difficult to resist the impression that an acute congestion of the antrum and pneumatic spaces constituted in reality the primary affection. At the same time the acuteness of the hearing in the ear of that side would indicate that, while the inflammation must have started in the tympanic cavity, it could scarcely have attained much vigor until it reached the remote mastoid region.<sup>1</sup>

---

<sup>1</sup> Compare with Case XXIX. (on p. 338), which resembles this one in many respects.



CASE XLVII.—Male, twenty-three years of age, student, healthy. December 5, 1873. About one week ago he began to suffer from pain in the left ear. The pain has been steadily increasing and is now so severe as to deprive him of sleep. It involves the entire left side of the head. Marked tinnitus. No noticeable deafness (watch heard a distance of seven inches). Motion of the lower jaw somewhat painful. External auditory canal (L.) red, dry, and swollen, especially along the posterior wall and in close proximity to the drum-membrane, which is almost concealed from view by the swollen tissues of the canal. Skin covering the mastoid process red, swollen, and very tender upon pressure. Angle behind the ear obliterated by the swelling of the subjacent parts. Ordered five leeches to mastoid region, and rest in bed; also poultices, if pain persists.

December 12th.—Leeches gave entire relief, and appetite soon returned. Ordered elixir of iron and quinine, to be taken for a week or ten days. No otorrhœa, but meatus filled with desquamated moist epithelium.

A secondary mastoid periostitis, dependent upon a primary acute inflammation of the external auditory canal, is seen quite often in practice. The following case, in which the too free employment of chromic acid in the meatus supplied the necessary exciting cause, may serve as an illustration of such a secondary periostitis.

CASE XLVIII.—Boy, thirteen years of age, well nourished. March 4, 1873. Discharge from the left ear since infancy; at times admixed with blood. Occasional tinnitus. Membrana tympani destroyed. A small but rather firm mass of granulation-tissue springs from the upper and posterior portion of the tympanic cavity, in the vicinity of the entrance to the antrum. A very small crystal of chromic acid, attached to the moistened end of a slender middle-ear probe, was applied to the most prominent portion of the mass, and the patient was ordered to syringe out the ear two or three times daily with a lukewarm weak solution of carbolic acid (℞. Acid. carbol., ʒ iij., aquæ, ʒ ij. M. S.—Half a teaspoonful to a pint of lukewarm water).

March 8th.—Discharge decidedly less. Chromic acid application repeated.

March 12th.—Forty-eight hours after the last application of chromic acid, the patient began to suffer from quite severe pain in the ear. The pain continued without remission up to this morning, when it diminished appreciably in severity. The mastoid integuments are red and swollen, and there is tenderness on pressure. The walls of the meatus are also swollen and tender on pressure. Four leeches to be applied to the left mastoid process, and, after the bleeding has ceased, hot poultices.

These measures relieved the patient entirely of his pain, and arrested the further progress of the inflammation.

## ANALYSIS OF SYMPTOMS.

In the preceding pages I have endeavored to show that the acute affections of the mastoid process are susceptible of being arranged in groups or classes, in accordance with the degree to which particular regions of the bone are affected, and also in accordance with the nature of the lesions produced. At the autopsy table it is a perfectly easy matter to distinguish between these different types of mastoid disease, but at the bedside, unfortunately, it is very difficult, and often impossible, to recognize any such distinctions. However, so far as the treatment of this class of diseases is concerned, it is of the greatest importance that we should be able to judge, in any given case, what parts of the mastoid process are involved in the inflammation, to what stage it has progressed in each of these parts, and finally to what extent neighboring organs are involved in the disease. As our task in diagnosis relates chiefly to the determination of these different points, I have thought that an analysis of the symptoms presented by the several forms of mastoid disease, would afford the best means of showing how far they may safely be trusted as indicators of certain lesions in certain localities.

*Pain.*—In all the acute forms of mastoid disease pain is the most prominent, and, at the same time, the most constant symptom. In its general character it is at first precisely like that which is observed in an ordinary attack of acute inflammation of the middle ear. Afterward, the character of the pain changes, and the features which distinguish it from the pain of the more strictly tympanic inflammation become apparent. Thus, for example, in the latter form of disease the pain is of shorter duration, and is confined more particularly to the ear and its immediate surroundings, while in mastoid diseases it is apt to be referred to the entire side of the head as well as to the immediate surroundings of the ear. In some cases the pain is referred chiefly to the upper part of the side of the head. In others the patients describe it as shooting into the eye of the side affected. In others still, it is referred to the back of the head. During the night it is usually more severe than during the day. If it persists despite the various antiphlogistic measures that usually relieve the pain which accompanies the more strictly tympanic type of inflammation,—such measures, for example, as paracentesis of the membrana tympani, the liberal use of leeches, and hot applications,—we may assume that either in the antrum itself, or in the adjacent pneumatic spaces, an inflammation is going on, which threatens serious damage to important organs, unless speedily checked. The severity of the pain in comparatively distant parts of the head (frontal, parietal, and occipital regions) has always appeared to me to indicate in a measure the degree of local meningeal irritation, which the subjacent mastoid inflammation has set up.

*Tenderness, redness, and swelling of the skin covering the mastoid process.*

—The changes which take place in the mastoid integuments furnish us with a valuable means of learning what is going on in the underlying bone. Their value, however, depends upon the relation which they bear to the progress of the disease in other respects. In an acute inflammation of the middle ear, slight tenderness, and perhaps even redness, of the mastoid integuments may develop as early as on the second or third day of the attack, and we may interpret these symptoms as an indication that not only the antrum but even the pneumatic spaces are congested, provided the condition of the external auditory canal renders it improbable that the inflammation has travelled directly from this region along the anterior surface of the mastoid process. This rapid development of congestive phenomena in the mastoid integuments also affords good evidence, in any given case, that sclerosis of the bone does not exist. In cases where we are in doubt as to the origin of the congestion,—whether from an extension of an inflammation of the cells, or from an extension of the periostitis or cellulitis of the external auditory canal,—we must depend upon the history of the case, and also, in some measure, upon the topographical limits and severity of the pain experienced by the patient, for additional light in arriving at a correct conclusion. In examining the skin that covers the mastoid process, we must remember that, in a few individuals, a small lymphatic gland lies directly upon the body of the bone, and that this gland is apt to swell and become tender some time before the pneumatic spaces participate in the inflammation of the middle ear and antrum. The recognition of the presence of a small, movable nodule beneath the skin should prevent us from mistaking this condition for a tenderness of the mastoid integuments, in the ordinary sense of the term. On the other hand, there are perhaps two spots where such tenderness is apt to show itself early. These are, first, a point near the centre of the base of the process, about on a level with the external orifice; and, second, a point on the posterior aspect of the bone, perhaps half an inch above its tip. Both of these points correspond with openings of canals for mastoid emissary veins. Tenderness on pressure at these points affords good evidence that the inflammation is spreading in an outward direction from the antrum. Finally, when the mastoid integuments begin to pit on pressure, we may draw the conclusion that the congestion of the deeper structures has reached a stage from which it is not likely to recede without the development of a certain amount of free pus. Beyond this point, however, we are not yet able to go in formulating our conclusions.

Sometimes the redness, tenderness, and swelling extend beyond the limits of the mastoid process. Thus, for example, the soft parts lying above and even in front of the auricle, may become swollen and more or less tender; and the same condition often develops in the direction of the occiput. These lesions, however, are not so significant as those which show themselves below the mastoid process. The order in which this series of

changes takes place, is usually the following : first, tenderness on pressure over the central portion of the base of the mastoid process ; second, diffuse redness and swelling of the mastoid integuments ; third, very marked tenderness of the cervical glands and other tissues lying below the mastoid process, on the side of the neck ; fourth, pain in this region when the head is moved,—the patient carrying his head as if he had a stiff neck ; fifth, the matting together of all the inflamed tissues below the mastoid process into a solid, flattened cake, over which the skin presents an almost erysipelatous appearance. When, for a period of several days, or perhaps even for two or three weeks, the symptoms of the disease have been pointing more and more decidedly toward the existence of acute inflammatory changes in either the antrum or the pneumatic spaces, the rather rapid development of the phenomena just enumerated may be confidently interpreted in one of two ways, viz., either as the expression of a phlebitis of the mastoid emissary vein (J. Orne Green), or as an indication that pus is actually working its way outward toward the surface (either along the bony canal which belongs to this vein, or along that which contains the facial nerve).

In cases in which we can exclude a periostitis by extension from the auditory canal, tenderness on pressure, redness, and swelling of the mastoid integuments afford the best of evidence that inflammatory changes are going on in the subjacent pneumatic spaces. The absence of these conditions, however, does not warrant us in drawing the conclusion that the more remotely situated antrum is not seriously involved.<sup>1</sup> In individuals who have been subject to chronic purulent inflammation of the middle ear, we may, as a rule, assume that the mastoid process is in a sclerosed condition, and that consequently there are no pneumatic spaces to which the inflammation may extend. The absence of redness, swelling, and tenderness of the outer integuments in such cases is therefore what we should expect ; and we may even interpret it as corroborative evidence of the existence of such a sclerosis. The practical deduction to be made from these facts is this : In cases of protracted, deep-seated pain, we must not wait for the development of these external manifestations of disease before we resort to the operation of perforating the bone ; the decision to operate should be based upon a variety of circumstances connected with the progress of the case, and not upon any one group of symptoms like that which we have just been considering.

Finally, the symptoms referred to possess no value as means of determining whether the pneumatic spaces are simply congested or whether

---

<sup>1</sup> Moos reports a case (Archives of Ophthalmology and Otology, Vol. III., p. 188), in which, during life, there were no evidences of mastoid disease beyond the existence of severe and persistent deep-seated pain in the region of the ear. At the post-mortem examination the cell-structures were found in a carious condition. Death occurred from exhaustion.

pus has already formed in them. If the tenderness, redness, and swelling are very marked, we may lean toward the belief that pus has already formed, rather than toward that which implies a simple congestion.

*Tenderness on pressure and swelling in other parts of the head.*—I have observed this symptom several times. In one case, for instance, the patient called my attention to a spot of marked tenderness on the very top of the head. In the course of a few days a circumscribed swelling appeared at this spot, and then very slowly the swelling and tenderness both disappeared, though not until after the mastoid affection proper had almost got well. In several cases I have observed phenomena of the same nature midway between the occipital protuberance and the mastoid process. In two of my cases this metastatic inflammation went beyond the stage of tenderness and infiltration of the tissues, and terminated in the formation of an

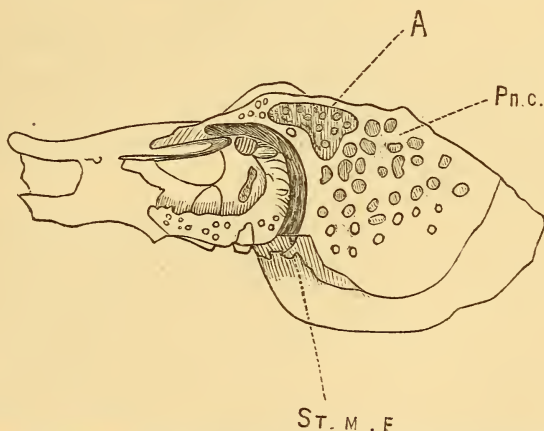


FIG. 25.—Section of the temporal bone showing the relations of the antrum to the facial canal. A = antrum; Pn.c. = pneumatic cells; ST. M. F. = stylo-mastoid foramen, or orifice of facial canal.

abscess on the side of the head, at some distance from the area of mastoid inflammation. In two of Dr. Simrock's cases of mastoid disease, which I had the privilege of examining, such a metastatic abscess had developed in the temporal region. In all cases of this nature, we must assume that some irritating products of the mastoid inflammation are carried either along the venous or along the lymphatic network of vessels, to some remote spot on the head, where they soon give rise to an acute inflammation which may at times eventuate in the formation of an abscess.

*Facial paresis or paralysis.*—When we consider how near the antrum is to the canal containing the facial nerve (see Fig. 25), we can no longer wonder that it should often become affected in the course of an inflammation of this cavity. The development of such a paresis or paralysis of the

facial nerve simply furnishes a valuable means of estimating how far what was primarily an inflammation of the mucous membrane of the tympanic cavity and antrum has extended into the substance of the surrounding bone. Considered with regard to its prognostic value this symptom is not necessarily a grave one. In some cases permanent paralysis remains after the mastoid disease has entirely subsided; while in others every trace of the paralysis disappears in the course of a few weeks.

*Body-temperature.*—The height of the body-temperature may, as a rule, be taken as a measure of the degree of inflammatory disturbance in and around the ear. In a few cases, however, we may be led astray by the temperature record. Thus, for example, in Case XXXIV., the temperature was taken twice daily, during a period of thirteen days before the patient's death (probably from abscess of the brain), and yet it did not once rise as high as 100° F. In Case XVI., in which the cell-structures of the mastoid process were actively inflamed, the temperature rose to only 101° F. In adults, therefore, we must not allow ourselves to be lulled into a sense of security by the fact that the body-temperature does not rise above the point which we might expect it to reach in even an ordinary attack of acute purulent inflammation of the middle ear. In children, the thermometer will be found more serviceable.

*Psychical phenomena.* In four of my cases there was well-marked delirium. Three of the patients died, while the fourth (a young child) recovered. Drowsiness and coma, without delirium, were observed in other cases; all of them terminating fatally. In all cases of delirium we may assume that a certain degree of meningitis of the convex portions of the brain has developed; in those of coma, an effusion into the lateral ventricles, or an accumulation of inflammatory products at the base of the brain, may be assumed to exist. Both symptoms, therefore, are of grave import.<sup>1</sup>

*Septicæmic or pyæmic symptoms.*—Symptoms pointing to the entrance of pus or other poisonous matters into the circulation, are by no means common in cases of mastoid disease. At the same time quite a large percentage of these cases die with symptoms of rather rapid consumption, and it is not unlikely that in some of these auto-inoculation may have taken place from some cheesy material imprisoned in the tympanum, antrum, or pneumatic spaces. In one of Schwartz's cases<sup>2</sup> the symptoms of pyæmia were very pronounced, and yet eventually the patient recovered.

<sup>1</sup> Consult J. Orne Green: Brain Disease in its Relations to Aural Affections. Report of Boston City Hospital for 1877.

<sup>2</sup> Archiv für Ohrenheilkunde, Bd. X., p. 186. See also the report of a fatal case of pyæmia, by Burnett, in the Philadelphia Medical Times, September 1, 1877.

*Ocular symptoms.*—Aside from strabismus in one case, and a difference in the size of the pupils in another,—both of which conditions did not manifest themselves until toward the end of the disease,—I have not observed any ocular symptoms in either the acute or the chronic varieties of mastoid disease. In the more severe cases, the patients are very apt to complain of pains that shoot into the eye of the side affected, and in one or two of these cases I have observed a slight conjunctival congestion.<sup>1</sup>

*Redness, swelling and prolapse of the upper and posterior cutaneous wall of the osseous portion of the auditory canal.*—In acute inflammation of the antrum the severity of the attack may be measured quite accurately by the character and extent of the changes which take place in the posterior and

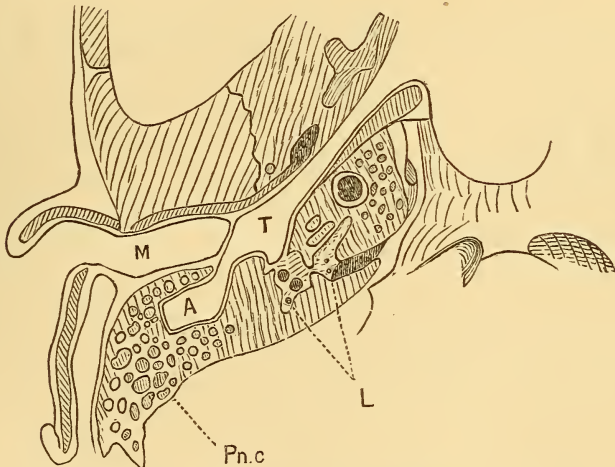


FIG. 26.—Horizontal section of the temporal bone, showing the relations of the antrum to the external auditory canal: A = antrum; M = meatus auditorius externus; T = tympanic cavity; Pn.c = pneumatic cells; L = labyrinth.

upper wall of the meatus, near the drum-membrane. If a horizontal or slightly inclined section be made in such a manner as to pass through this portion of the auditory canal and also through the antrum—as has been done in the accompanying cut taken from “Henle’s Anatomy”—the proximity of this cavity to the upper and posterior limits of the osseous auditory canal will be appreciated at a glance. In cases of chronic purulent inflammation of the middle ear the mass of bone lying between these two cavities may assume such an ivory-like hardness that no inflammatory influences can traverse it. This possibility must be borne in mind, and in cases of suspected sclerosis of the mastoid process, associated with deep-seated pain, we must not expect to find the lesions which I have just described.

<sup>1</sup> Consult Moos: Archiv für Ohrenheilkunde, Bd. XIV., p. 280.

In the majority of cases, however, we may attach very great value to the condition of this posterior and upper portion of the inner half of the canal.

#### TREATMENT.

In discussing the question of treatment I will consider separately the different measures which are known to exercise a controlling influence upon inflammatory affections of the mastoid process.

In the first place, *the application of heat and moisture*, in the form of poultices, will often be found useful; not because such hot applications possess any decided power to arrest the inflammation, but because they mitigate the pain in an appreciable degree. When the cervical glands and surrounding cellular tissue on the side of the neck become inflamed and matted together into a hard, flattened mass, poultices will be found very effective in removing the hardness and in promoting the absorption of the exuded material.

*Local depletion* by means of leeches exerts a direct restraining influence upon the inflammation. In young persons they must be used with great caution, if used at all. In a strong, healthy adult they may be used very freely. In fact, it is not of much use to employ them in any other manner. It is comparatively rare that the application of three or four leeches does more than produce a temporary remission of the pain. Recently I have obtained more positive results by applying as many as seven or eight leeches, and then, twenty-four hours later, applying three or four more. In these cases, however, the deep-seated pain and the tenderness behind the ear had existed for only a few days, and consequently the inflammation had probably not progressed much beyond the stage of congestion. Under such circumstances the free use of leeches may accomplish much. In the later stages of the disease, it is better, I think, not to use them except as an adjunct to other more radical measures. The angle behind the ear is probably the spot where the leeches may be applied to the best advantage. A few hours after the bleeding has ceased, we must expect to find the skin in the vicinity of the leech-bites red, swollen, and tender on pressure. As increased redness, tenderness, and swelling are, as I have already stated, valuable indications of an increase in the deep-seated mastoid inflammation, we may sometimes find it a difficult matter, after the employment of leeches, to decide what precise value should be attached to these symptoms. If in other respects the patient is worse, it is probably better to assume that the increased swelling, redness, and tenderness of the mastoid integuments signify a corresponding progress of the fundamental disease. On the other hand, if the patient seems to be better in other respects, we may attribute the increase in the outward manifestations of disease entirely to the leech-bites.

A still more effective method of obtaining local depletion is that by



means of the operation known as *Wilde's incision*. In this operation the skin and subjacent tissues, inclusive of the periosteum, are divided by an incision extending from the base very nearly to the apex of the mastoid process (the external wound measuring from three-fourths of an inch to one inch in length). If the patient's head is in the erect position, the point of the knife should be made to pierce the skin about on a level with the upper wall of the external orifice of the auditory canal. If we begin the incision higher up, we are apt to divide a branch of the posterior auricular artery, which usually crosses the bone at about this level. On the other hand, if we make the incision a little too far forward, we may nick this artery or incise it longitudinally, and so prepare the way for the development of a false aneurism.<sup>1</sup> I believe that many a case of serious mastoid

---

<sup>1</sup> This accident happened in the following case :—

CASE XLIX.—Plumber, twenty-one years of age, and in the habitual enjoyment of good health. Two weeks before visiting the New York Eye and Ear Infirmary, he was attacked with the symptoms of an acute inflammation of the right middle ear, namely: deep-seated pain, throbbing, tinnitus, and deafness. When the pain became so severe that he could not tolerate it any longer, he visited the Infirmary. An examination then revealed the fact that the outer canal was nearly obliterated by the swelling of its cutaneous walls, and that the skin over the mastoid process was red, swollen, and tender upon pressure. By gradual dilatation, the swelling of the canal was diminished sufficiently for me to obtain a view of the deeper parts. In this way it was ascertained that the inner half of the canal was occupied by a mass of granulation-tissue, the removal of which was easily effected by the snare. To relieve the congested condition of the mastoid structures, a free incision was made in a vertical direction behind the ear, and of such a depth as to divide the periosteum. The incision having been carried rather nearer to the angle of the ear than is usual under such circumstances, the withdrawal of the knife was followed by a small jet of arterial blood. The bleeding was arrested by a compress placed over the wound and held tightly in position by a suitable bandage. All efforts to place a ligature around the wounded vessel, or to control the bleeding by torsion, proved unavailing.

This occurred on the 9th of April, 1873. Three days later I saw the patient a second time. I found that the edges of the wound had united by adhesion, and that the pain had been entirely relieved by the incision. At the same time an abundant purulent otorrhœa had established itself.

On the 14th of April the resident surgeon noticed distinct pulsation over the mastoid region.

On the 15th there was a circumscribed pulsating tumor, about the size of a hickory-nut.

On the 16th the pulsation ceased altogether, and the tumor diminished perceptibly in size. An incision was made in the line of the former wound, and a rather firm, nearly spherical clot of blood was removed from a distinct cavity. The outer portion of the clot was found to be laminated in structure.

As the hemorrhage recurred upon the removal of the clot, the cavity was stuffed with lint.

On the 18th, the removal of the lint was again followed by an arterial jet, which rendered it necessary to stuff the wound a second time and apply firm pressure by means of a compress and bandage.

disease might have been prevented from going beyond the congestive stage if this simple and perfectly safe operation had been performed more frequently at the beginning of the attack than has generally been the case. As Wilde was the first to call attention to the great practical value of deep incisions in acute mastoid affections, it is both proper and pleasant to retain the name of *Wilde's incision* for this operation.

*The establishment of an opening in the mastoid process* constitutes undoubtedly the most effective procedure thus far discovered for checking an inflammation in this region, or for preventing it from spreading to important organs in the neighborhood. In some cases the beneficial effects of the operation are clearly to be attributed to the fact that a free outlet is thereby afforded to encaged products of inflammation. In other cases the benefit derived from this procedure can only be explained on the assumption that the establishment of a new centre of inflammation, in close proximity to that which called forth the operation, produces a strongly derivative effect, and so checks the original disease.

The first point of importance in connection with this operation is this: we should have in our minds a reasonably clear conception of the circumstances which render its performance desirable. Thus, for example, in a case of acute origin, we may be guided by the following rule:

In the early stage of the disease, when there is persistent and rather severe deep-seated pain, perhaps involving the entire side of the head as well as the parts immediately surrounding the ear, and when there is tenderness on pressure over the mastoid process and possibly also a little redness of the skin, we should apply to this region from four to eight leeches, according to the age and vigor of the patient. If the loss of blood has not pro-

The compress and bandage were removed the following day, but the lint stuffing was left to ulcerate its way out.

The patient subsequently made a rapid and good recovery.

In regard to this case of traumatic aneurism, I would say, that the rarity of its occurrence in this particular locality is simply owing to the fact, that, when it becomes necessary to incise these parts, the incision is almost invariably made more posteriorly than in the present case. In this instance I purposely departed from the prevailing rule in order to ascertain a fact of some practical importance. In fully half of the cases of this kind, I have noticed that the loss of blood which ensued was exceedingly small,—much smaller than, in my opinion, was desirable,—and I believed that, to obtain uniformly a greater loss of blood, the incision should be carried close up to the angle where the skin is reflected from the mastoid process upon the auricle, and where the posterior auricular artery and vein lie. The experience gained in the present case shows, however, that the danger of simply nicking the artery, instead of dividing it, and the difficulty of placing a ligature around the divided vessel, deeply situated as it is among very firm and unyielding tissues, are good and sufficient reasons why the established rule should not be departed from.

(Dr. Charles J. Kipp, of Newark, N. J., reported a very similar case to the New York Ophthalmological Society at one of its meetings in 1873. The hemorrhage, in his case, was so serious as to threaten the life of the patient.)

duced any decided depressing effect upon his strength, the after-bleeding may be allowed to continue for half an hour or one hour. Warm fomentations should then be kept applied to the mastoid region for several consecutive hours. If these measures fail to afford the desired relief, or if after the lapse of say twenty-four hours, the pain is found to be as active as it was before the leeching, a Wilde's incision should then be made without further delay. Finally, if this procedure also fails to relieve the pain, or if it relieves this symptom only temporarily, an opening should as soon as possible be established in the mastoid process. The nature, location, and depth of this opening will be considered farther on.

The question might be raised by some physicians whether they should interpret this rule as meaning that, in the event of their failing to alleviate the pain by the other measures enumerated, they ought to perforate the mastoid process as early as on the fifth or sixth day after it has shown signs of being inflamed. As a matter of course, the rule is not to be followed blindly, nor without due consideration of all the facts connected with the case. Circumstances undoubtedly may exist which would render it desirable to modify the rule. For instance, the condition of the external auditory canal or drum-membrane on the fifth or sixth day may be such as to render it advisable that we should then devote special attention to this region before we adopt the conclusion that the mastoid process should be perforated. But if no such valid contraindicating reasons exist, I believe that the sooner the operation is performed, the better it will be for the patient. In actual practice, it will rarely happen that, in following the rule which I have laid down, and which is essentially the same as that which I published in 1873,<sup>1</sup> we shall find ourselves called upon to perforate the bone as early as on the fifth or sixth day. The vigorous employment of leeches is usually followed by a remission of the pain for from one to two or three days; and a still more protracted lull is apt to follow Wilde's incision. In this way the question of an operation upon the bone does not usually present itself for serious consideration before, say, the tenth day.

A question far more difficult to solve than the one which I have just been discussing is that which relates to the class of cases in which there is no tenderness on pressure over the mastoid process, no redness of the skin covering this bone, and no perceptible swelling. The persistent deep-seated pain, the previous history of the case, and the appearances presented by the drum-membrane or neighboring parts, are the only data upon which we can base an opinion with regard to the advisability or non-advisability of perforating the bone. As these data vary greatly in the different cases of this class, no such general rule can be formulated for them as for those cases in which the outward manifestations of mastoid disease are plainly visible. We shall not often go astray, however, if we assume that the mastoid

---

<sup>1</sup>Archives of Ophthalmology and Otology, Vol. III., 1873.

process is sclerosed, and that consequently the outward manifestations of disease observed in the acute cases (without sclerosis) are not to be expected. In some of these cases we may succeed in restoring an adequate outlet through the obstructed natural channel tympanic orifice of antrum. As a rule, however, the establishment of an artificial opening in the bone affords the patient the best chance for his life.

Thus far I have spoken only of the circumstances under which it is desirable to perforate the mastoid process. I will now mention briefly those under which it is better not to interfere. Thus, for example, the physician

may not be called to see the patient until after coma has set in, or until pyæmia has developed; or he may find the patient far advanced in consumption. Under such circumstances the chances of doing the patient any good by an operation are so slight, that he may with perfect propriety advise against it.

So far as the operation itself is concerned, it may be described as follows:

A free vertical incision should be first made through the skin and periosteum covering the mastoid bone. The condition of the latter should then be noted. If it be soft or roughened, an attempt should be made to break through the outer lamella by firmly pressing upon it with the end of a steel director. If pus be found between the periosteum and the bone, search should be made with a bent probe for a sinus

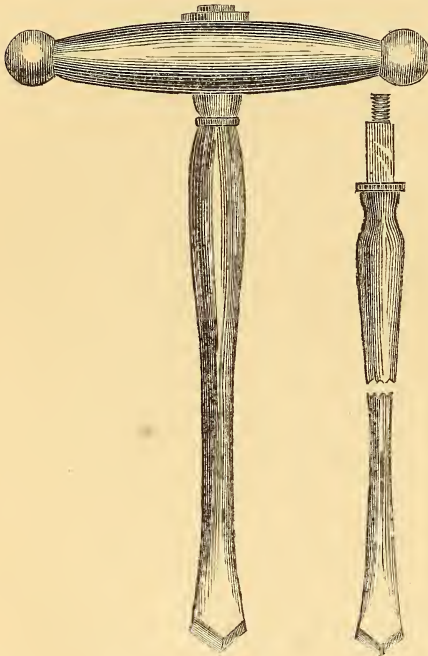


FIG. 27.—Bone drills. (Natural size.)

through which the pus may have found an escape from the mastoid cells. If such an one can be found, the drill should be applied at this point, and the existing channel or fistulous opening should simply be enlarged. If no opening be found, the periosteum should be dissected from that portion of the mastoid process which is situated immediately behind the external auditory canal, and the drill<sup>1</sup> should be applied at a point a quarter of an inch distant

<sup>1</sup> Of the two drills represented in the cut, I almost always employ the larger one. Schwartze gives the preference to small bone gouges and chisels, which he uses in connection with a mallet. I fail to appreciate, however, in what respect these instruments are superior to the drills represented above.

from the canal and a little below the level of its upper wall. The instrument should then be rotated in a direction inward, forward, and a little upward—that is, nearly parallel with the canal. The depth to which it should be carried will vary in different cases. In the acute cases the aim should be to reach the peculiar cell-structure of the mastoid process. Ordinarily, it will be reached at a slight depth. The drill should then be withdrawn and the steel director may be used to break down the bony septa. In infants the antrum is situated so near the outer surface of the bone that very little effort will be required to establish the desired opening. If sclerosis of the bone be found, we should endeavor to bore a channel down to the antrum. In performing this operation, however, we must observe certain precautions. In the first place, the lateral sinus may occupy an unnatural position; that is, its bony groove may encroach to so great an extent upon the body of the mastoid process as to lie directly in the path of the drill. It is therefore important to manipulate the instrument in such a manner that it shall not injure, even though it may encounter, this vein. The simplest way of accomplishing this is to keep the forefinger of the right hand (if that be used in operating the drill) constantly pressing against the neighboring surface of the bone. In this way (by counter-pressure) the danger of injuring the lateral sinus will be almost entirely removed.<sup>1</sup> The next question of practical importance relates to the depth to which we may safely carry the drill in our efforts to reach the antrum. Schwartze says: "Never go deeper than twenty-five millimetres." Unless the case is of such a grave character that we may safely run some risk, it is better, I believe, to place the extreme limit of depth at twenty millimetres, or about three-quarters of an inch. The risk to which I have reference is that of plunging the point of the drill into some portion of the labyrinth.

Some writers lay stress on the importance of sending a stream of tepid water from the artificial opening, first into the middle ear and then out through the external auditory canal. This practice has never commended itself to my judgment. The washing out of either the antrum (if filled with cheesy or foul pus) or the cavity of an abscess located in the body of the mastoid process, by means of a nozzle or tube that is considerably smaller than the artificial channel in the bone, seems to me to be a very proper procedure; but to use force, in order to make the water escape by way of the external auditory canal, does not appear to me to be good practice. In other respects the after-treatment is to be precisely like that of any other open wound. Drainage-tubes, I am confident, can perfectly well be dispensed with.

---

<sup>1</sup> See history of case in which I encountered this vessel in boring through a sclerosed mastoid process. Out of fifteen operations this is the only one in which I have encountered the lateral sinus.

## CHAPTER X.

### MISCELLANEOUS CONDITIONS OF THE DRUM-MEMBRANE, OSSICLES, AND TYMPANIC CAVITY.

*Atrophy of the membrana tympani.*—In the condition known as atrophy of the membrana tympani, we find this membrane usually thin and transparent, and at the same time more concave than natural. In its slighter degrees one may very easily fail to recognize this condition. In such doubtful cases of atrophy the behavior of the membrane under inflations of the middle ear will often aid us very materially in arriving at a correct diagnosis. Thus, for example, if atrophy exists, an undue convexity of the membrane (after the inflation) and a certain peculiar opacity (like polished steel just breathed upon), due to the undue stretching of the outer dermoid surface of the membrane, will at once attract the attention of the observer. Furthermore, I think one is less likely to err in estimating the degree of unnatural convexity than in determining that of undue concavity. After inflation of the middle ear, a non-atrophied drum-membrane should present but a very slight degree of convexity, even when the Eustachian tube is so obstructed as to keep the air engaged in the cavities of the middle ear. The lesser degrees of atrophy are very common. A high degree of this condition is observed in cases of chronic naso-pharyngeal catarrh, with hypertrophied tonsils and follicular enlargements. Prolonged undue atmospheric pressure upon the outer surface of the membrane is the cause of the atrophy in these cases. In cases of sclerosis of the mucous membrane of the middle ear, we find an atrophy of the membrane which seems to differ from that which I have just described. The membrane is apparently just as thin and transparent as in the other form of atrophy, but it seems to retain its substantia propria unchanged; for the membrane is at most very little sunken, and inflation does not cause it to bulge to an unnatural extent. This condition, as it appears to me, may be explained in the following manner: The atrophy is probably limited to the mucous lining of the membrana tympani; though perhaps the process of contraction may at the same time interfere with the circulation of blood in this membrane to such an extent as to diminish materially its entire blood-supply.

So far as the *diagnosis* is concerned, the only other condition that might be mistaken for atrophy is a newly produced drum-membrane. The pres-

ence of other evidences of an otitis media purulenta, either in the affected ear, or in its fellow, or the history of a previous otorrhœa, would favor the diagnosis of a cicatricial membrane; while the absence of these, especially if the condition of the throat and Eustachian tube pointed to the previous existence of active disease in these localities, would favor the diagnosis of simple atrophy.

No *treatment* of which I have any knowledge is likely to restore an atrophied drum-membrane to its normal state; nor do I know of any procedure that will render it less elastic, that is, more capable of responding to the vibrations of the air. I have not the slightest faith in frequently repeated incisions.

*Horny growth of the membrana tympani.*—I have seen but one case of this peculiar pathological condition. The patient, a man thirty-six years of age, was admitted to the New York Eye and Ear Infirmary on the 21st of June, 1871. He stated that fourteen years previously, during exposure to severe weather, he first began to be troubled with noises and slight deafness in both ears. These symptoms had continued since, though at times they were less marked than at others. In both cases the watch could only be heard at a distance of two inches; in conversation with him, however, I was not obliged to raise my voice appreciably. On inspection I found the external auditory canal filled with hard inspissated cerumen. To facilitate the removal of these hard plugs of wax, the patient was instructed to fill the ears night and morning with a warm solution of bicarbonate of soda (gr. x. —  $\frac{3}{4}$  j.). Three days later the cerumen was easily removed by syringing. On examination, the drum-membranes then presented the following appearances: On the left side there was nothing specially noteworthy; on the right, the upper three-fourths of the membrane was occupied by a flattened, sharply outlined mass of a pale yellow or yellowish white color. It stood out from the level of the membrane to a distance of a little more than a millimetre, and terminated, throughout its entire lower border, with abrupt edges. Along its upper and anterior boundary, the mass became gradually merged in the skin of the auditory canal. Its surface was smooth and slippery, and, when touched with the probe, conveyed the impression of being quite hard. The portion of the membrane that was not covered by the mass, was of a uniform milky appearance, similar to that which is frequently observed in cases of chronic catarrh. With a view to obtaining more light on the nature of this mass, I instructed the patient to continue the use of the soda solution for another week. At the end of this period I found the mass practically unchanged. Its surface had been rendered slightly soft by the prolonged soaking, but I could discover no other change.

My interpretation of this case was, that the mass represented a horny growth from the dermoid layer of a limited portion of the membrana tym-

pani. It has also seemed to me probable, or at least possible, that the long-continued pressure of a ceruminous plug might have been the exciting cause.

*Vascular growth of the membrana tympani.*—In a young lady, twenty-two years of age, who consulted me for a slight general impairment of her hearing, I found in the posterior superior quadrant, just behind the short process of the hammer, and encroaching a little upon this bone, a small, rounded, bright-red fleshy mass, about as large as a No. 12 shot (*i.e.*, about a millimetre or a millimetre and a half in diameter). It appeared to be quite soft, and was freely movable when manipulated with the probe; at the same time it was not pedunculate. In the present instance this vascular *nævus* possessed no significance beyond that of a mere pathological curiosity; and yet there is no good reason why, in this case, at some future day, a more extensive tumor of this kind may not be found growing from the membrana tympani.

*Deformed drum-membrane.*—The following case illustrates one of the many transformations in the relations of the parts which a prolonged purulent inflammation is capable of producing:

The patient—a girl about twenty years of age—stated that she had had a discharge from the left ear for a period of several years, but that two years ago it ceased entirely. Since then she had simply been conscious of a certain degree of deafness in the affected ear. An examination revealed the following state of things:

The meatus was quite natural in its outer two-thirds; beyond this point it rapidly diminished in size and terminated in a very small (diameter = 2 mm.), circular, translucent membranous plate, which occupied, so far as I could judge, exactly the same position as that which the drum-membrane should occupy. Its edges merged imperceptibly into the surrounding tissues. There were no landmarks of any kind by means of which I might decide whether this membranous structure was a remnant of the membrana tympani, or a membranous transformation of newly formed inflammatory tissue. Its situation certainly favored the former view. The hearing-power in the L. ear was fair.

*Absence of the hammer.*—In examining the ear of a patient at the New York Eye and Ear Infirmary, I was very much surprised to find that the drum-membrane, which seemed to be perfectly constructed in all other respects, totally lacked its manubrium mallei. On questioning the man, I ascertained that about four years previously an operation had been performed (under chloroform) on that ear, but that it had failed to relieve him of his deafness. From this statement, and from the condition observed, I drew the inference that excision of the entire hammer had probably been



performed. In this case I searched very carefully for a cicatricial region in the location which the manubrium should occupy, but I failed to find the slightest difference between this portion of the membrane and the surrounding portions.

*Hook-shaped manubrium mallei.*—The peculiar deformity observed in the following case was probably of congenital origin. The patient, a boy thirteen years of age, was admitted to the New York Eye and Ear Infirmary on the 15th of May, 1872. When three years old he had passed through an attack of scarlet fever, which left him with a double otorrhœa. On the right side the discharge had continued up to that time without interruption; on the left it had entirely ceased about one year previously. On examination I found the end of the handle of the hammer, on the left side, curved from behind forward, in the manner shown in the accompanying cut. The membrane itself was opaque and somewhat mottled, but it presented no traces of ever having been perforated. There was also nothing to indicate that a fracture had ever occurred. On the opposite side the drum-membrane and handle of the hammer had been entirely destroyed, so that it was no longer possible to institute a comparison between the two sides. The boy was in robust health, and presented no signs of ever having had rickets.<sup>1</sup>

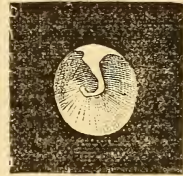

FIG. 28.—Hook-shaped manubrium mallei.

*Ruptures of the drum-membrane.*—In my experience, ruptures of the membrana tympani, from concussion of the air in the external auditory canal, are comparatively rare. I can find only five instances of this lesion in my records. In two of these the rupture was produced by a "box" on the ear, in two others the patients seemed to be unwilling to divulge the cause (one of them, however, stated that she fell down stairs, but I was satisfied that she was trying to deceive me), and in the fifth case the patient was struck on the ear by a snowball. In two cases the rupture ran directly downward and a little backward, in a line directly continuous with the handle of the hammer. In other words it consisted in a mere separation of the radial fibres of the substantia propria. In the third case it ran from a point near the periphery of the posterior superior quadrant directly downward in a straight line to a point near the periphery of the posterior inferior quadrant. In the fourth case the perforation ran in a slightly curved line from the lower limit of the posterior superior quadrant (midway between the umbo and the periphery) to the central portion of the anterior inferior quadrant. Finally, in the fifth case, the rupture occupied the posterior inferior quadrant and consisted of an irregularly shaped open-

<sup>1</sup> A case of abnormally bent manubrium mallei has been reported by Buhl and Hubrich in the *Monatsschrift für Ohrenheilkunde*, II., 1, January, 1868.

ing with jagged edges. In three cases the appearance presented by the rupture was simply that of a reddened line, without any visible solution of continuity, while the parts were at rest. In the fourth case there was slight gaping of the edges. In the case of the rupture produced by the impact of a snowball the opening showed no tendency whatever to close. I saw it as late as six months after the occurrence of the injury, and it was still in a gaping though perfectly dry state. In one case, a discharge of short duration followed the injury. Finally, in two cases, hemorrhagic infarctions were found in the vicinity of the rupture.

Other injuries have been observed by different authorities, but those which I have mentioned are the only ones with which I have had any personal experience.<sup>1</sup>

*New-growths in the middle ear.*—In this category I propose to consider only those new-growths which depart so markedly from the ordinary type of aural polypoid tumors that it would be scarcely proper to consider them in the section devoted to the proliferative form of otitis media purulenta. Of the benign growths, the bony and the vascular are the only ones that have come under my observation.

*Marked hyperostosis* of the bony wall of the tympanum is, in my experience, a very rare condition. I have seen but two instances of it, both of them in middle ears that had previously been affected with a chronic purulent inflammation. In the first case the bone in the neighborhood of the fenestræ had increased so greatly in size that the posterior half of the drum-membrane presented a tense, polished, convex outer surface, due to the pressure of the subjacent bony growth. The handle of the hammer marked the anterior limit of the tumor, and rested firmly against it. The anterior half of the drum-membrane seemed to be cicatricial in character, and abnormally sunken. The patient was sixty-two years of age, and said that he had been quite deaf for at least thirty years. In the second case a hemispherical bony mass, apparently about five millimetres in diameter at its base, overhung the tympanic orifice of the Eustachian tube (right ear). Posteriorly it touched the stump of the handle of the hammer (the drum-membrane had been completely destroyed). The mucous membrane covering the tumor was still recognizable as a distinct, more or less succulent membrane. The patient was sixteen years old, and there had been a discharge from the right ear for a period of fully seven years.<sup>2</sup>

---

<sup>1</sup> Consult, on this subject, Weir: Ununited Fracture of the Manubrium Mallei, Transactions American Otological Society, 1870; Schalle, in Archiv für Ohrenheilkunde, XII., p. 10; Burnett, in Transactions American Otological Society, 1872; Politzer, in Wiener Medical Presse, 1872; Bürkner: Archiv für Ohrenheilkunde, XIV., p. 230; Shaw: Boston Medical and Surgical Journal, November, 1868; Turnbull, in Medical and Surgical Reporter, Philadelphia, February 22, 1879.

<sup>2</sup> Consult also Zaufal, in Archiv für Ohrenheilkunde, II., p. 48; Moos, in Archives of Ophthalmology and Otology, II., pp. 127 and 190.

*Intratympanic vascular growths* are probably encountered even more rarely than are those of a bony nature. So far as I can learn, there are but four instances on record in which a vascular tumor developed in a middle ear whose drum-membrane was still intact, viz., one reported by Schwartze,<sup>1</sup> two by Weir,<sup>2</sup> and one by myself.<sup>3</sup> In Schwartze's case very few details are given. The left drum-membrane, which was otherwise white and lustreless, presented a pulsating point near the umbo. The pulsations were synchronous with the radial artery, and ceased during the performance of Valsalva's experiment. From the meagreness of the details given, it is not even quite clear that the case belongs in the present category. In both of Dr. Weir's cases, however, one of which I had the privilege of examining at my office, and also in my own case, the evidence of the existence of an intratympanic vascular growth is reasonably clear. In view of the rarity of tumors of this nature, I will give in full the histories of these three cases.

*Dr. Weir's first case.*—"Mrs. J. A., ætat. 35, was sent to me in November, 1870, by Dr. J. T. Metcalfe, for deafness of the right ear, which had begun about a year previously, had rapidly increased during the past few months, and was associated with a disagreeable though regularly pulsating noise. There had been no pain or discharge. At times slight attacks of vertigo had been experienced.

"On examination, H. D. right side= $\frac{3}{16}$ ; left, normal. After I had removed a slight layer of cerumen, a remarkable appearance presented itself. The whole drum-membrane was evenly and intensely reddened and strongly pushed forward in a bulging manner, except along the line of the malleus, which was situated apparently in a depression, and was marked at its free end by a white spot, in strong contrast to the other parts of the membrane. The whole membrane pulsated visibly and strongly, especially so superiorly, where there was a broad light spot. The pulsation was synchronous with that of the carotids, and was arrested by pressure on the artery of the corresponding side. No distinct vessels were to be seen on the membrane, only a general redness. By Siegle's tympanoscope the drum-membrane could be forced in but little, and the pressure only rendered the pulsation more broadly and decidedly marked, and particularly so near the inner side of the malleus. By the otoscopic tube the heart-sounds were distinctly heard, but not so on the sound side. No air could be felt to enter the tympanic cavity by Valsalva's or Politzer's method, nor by the catheter. No redness or abnormal change was noticed in the external auditory canal.

"Thinking at first that I had to do with an exaggerated case of bloody serum in the middle ear, paracentesis was resorted to at the middle of the

<sup>1</sup> Arch. f. Ohrenh., I., p. 140.

<sup>2</sup> American Journal of Otolology, Vol. I., p. 120.

<sup>3</sup> Ibid., p. 126.

posterior segment, giving exit to blood which rapidly filled up the canal and flowed to the amount of  $\frac{3}{4}$  j. in a few seconds, but was easily arrested by plugging the canal for a few moments with cotton. Attempts were made to inflate the tympanic cavity by the catheter, after bougieing the Eustachian tube up to its isthmus, but no air emerged from the puncture. On inspection no change in the appearance of the drum-membrane had resulted from the puncture, but three days later, when paracentesis was again resorted to, and after the cessation of a moderate hemorrhage, the drum was found collapsed and somewhat wrinkled; the hearing also was found to have increased to  $\frac{2}{3}$  v. This improvement in hearing and condition of the drum-membrane only continued until the next day, and the pulsation was then felt as decidedly as ever by the patient, though to the eye it was much more feeble. I had by this time come to the conclusion that I had to deal with a vascular tumor in the middle ear, or that I had, according to Schwartze, a hypertrophied condition of the mucous membrane associated with an accumulation of bloody serum in the cavity. Leaning, however, to the first view, a consultation with Dr. Simrock, an acknowledged aural authority, was suggested and carried out. Dr. Simrock thought that the difficulty was due either to fluid in the middle ear, or, as he thought that he succeeded in forcing air through the Eustachian tube, that it was a collection of fluid in the tissue of the drum-membrane itself. A third puncture was made posteriorly, carrying the needle in until it reached the promontory—no air could be forced out. Convinced of the correctness of my diagnosis, on December 5th a fourth puncture was made with a large needle, and a probe dipped in pure nitric acid was inserted through the opening into the middle ear. But little pain was occasioned by this treatment. As a result of the several punctures, it was noticed not only that after each the hearing-distance increased, but that the pulsation became less distinct. This subsidence became more and more permanent, but the cicatrices of the punctures, yielding under the pressure from within, protruded almost teat-like from the drum-membrane, and after this application of acid a mass projected through the opening there made, and, spreading out and pulsating faintly, obscured nearly the whole membrane, and assumed a polypoid appearance in the course of a week. This mass was punctured and a probe dipped in liq. ferri persulph. introduced into its depths, blanching it at once.

“The subsequent history is in brief this: the mass sprouting from the opening in the drum-membrane was with difficulty destroyed by the use of nitric acid applied, first, every second or third day for a number of times; afterward, at intervals of one or two weeks (as the patient lived out of the city); and subsequently, as the tissue became tougher, by the use of the acid nitrate of mercury, which was carried, by means of a thin film of cotton around the end of a fine wire, through the tympanic opening into the cavity itself. At times considerable pain was caused by the applications,

but as a rule they were less distressing than would have been anticipated. Several attempts were made to extract pieces of the mass for microscopical examination, and the one or two small portions so obtained were reported, by Dr. A. H. Buck, to show nothing but scales of epidermis and debris so changed by caustics as to be unrecognizable.

"By this treatment, the tumor, in the course of four to five months, was apparently destroyed, and it was observed that in the later cauterizations little or no hemorrhage occurred, and that when the punctures and applications—for they were sometimes conjoined—were carried into the tympanic cavity, the sensation was given that that space was more or less filled with a solid tissue. No air at any time was felt in the middle ear.

"On July 1, 1871, three weeks after the cessation of treatment, it is noted that H. D. =  $\frac{2}{20}$ ; bottom of canal closed by a smoothly depressed, fleshy-looking membrane, still considerably though irregularly injected. No pulsation whatever to be seen or heard by the physician, and only very slightly perceived by the patient.

"August 4th.—Mrs. A. presented herself, on her way from Newport, stating that she had had only occasional pulsation in the ear in the erect position, but always when in bed. On examination it was found that the membrane had changed from its former fleshy appearance to one more normal. Now the malleus could be defined; the membrane itself was still irregularly patchy, of a pink hue in spots, but with some translucency. By the use of Politzer's inflation, for the first time air is heard to enter the middle ear by the otoscope. Ordered Valsalva's experiment to be practised at home.

"November 14th.—Drum-membrane is quite normal in the posterior part. Malleus clearly seen. Anteriorly, two months ago, was seen a red, bulging spot, as if the tumor was returning there, but this to-day is not seen; the drum-membrane at this point being now mottled with white bands running from the malleus to the periphery. Tube slightly open by Valsalva's method; air readily enters. H. D. =  $\frac{3}{20}$  to  $\frac{4}{20}$ . To use Politzer's bag daily.

"February 7, 1872.—H. D. =  $\frac{8}{20}$ . Hears pulsation only when in bed. Drum-membrane still mottled and sparsely injected. No evidence of return of tumor.

"December, 1878.—No recurrence of the tumor. Reports herself as hearing well. Ear giving her no trouble whatever. As patient was met in the street, exact information could not be obtained."

*Dr. Weir's second case.*—"A negro woman, thirty-five years of age, was seen by me December 8, 1870, with the history that for four years past she had had "beating noises" in the left side of her head, which were much increased by stooping, which position would also cause severe dizziness. Vertigo came on at times in the erect position. The hearing on the same

side had also failed, and on her visit to me was  $\frac{1}{2} \frac{2}{0}$ , while on the left side it was normal. She believed that her heart was affected, as she so distinctly and so persistently heard the sounds in her ear. There was, however, no cardiac lesion. She was much depressed and anxious by reason of her ear trouble. On inspection it was perceived that the posterior surface of the drum-membrane, and more especially its inferior portion, was of a reddish hue, with some vessels running over it, and that it was not only bulged outward, but that it visibly pulsated synchronously with the heart. Considerable injection of the malleus was also present. The Eustachian tube was pervious. By Siegle's otoscope it was seen that a faint line half-way up the posterior segment was movable. Paracentesis was, therefore, resorted to, and blood rapidly filled the canal, but was readily checked by a mop of cotton left a few moments against the drum. Politzer's inflation being then used, air freely escaped through the opening in the drum-membrane, after which H. D. =  $\frac{3}{2} \frac{0}{0}$ . She was not seen again until June 1, 1871, when she returned with the statement that since the puncture she had been very much better, and her hearing had improved and kept in fair condition until a week previously, when the latter rapidly diminished. Now H. D. =  $\frac{2}{2} \frac{4}{0}$ . Left drum-membrane translucent everywhere, except at postero-inferior portion, where a roundish red spot, the size of a small pea, was seen projecting forward, but not pulsating. By Siegle's apparatus fluid line was again detected; it was rendered more clear after Politzer's inflation had been successfully used. Projection outward apparently the same.

"June 15th.—Paracentesis used for a second time, causing not only H. D. to rise to  $\frac{1}{2} \frac{2}{0}$ , but also disappearance of the pulsating noise and redness. This absence of pulsation was noticed only a few days.

"August 1st.—Returned with symptoms of dizziness, deafness, and pulsation. Fluid seen in tympanic cavity. Redness and pulsation in drum-membrane observed as at first. Paracentesis, with needle carried in until it was arrested by bony resistance.

"November 7th.—Repeated paracentesis. Says that after every puncture the sound is lessened in intensity.

"December 11th.—Paracentesis twice in past week, and a probe wet with liquor ferri persulphat. also introduced.

"She was not seen subsequently until February 18, 1873, when the tumor was seen projecting still on the posterior and inferior segment of the drum, pulsating, and of a red color. Dizziness complained of more than ever. H. D. = 0.

"Up to March 24th, paracentesis was performed three times, with the subsequent introduction of cotton wound around a cotton probe and dipped in acid nitrate of mercury. This kept the opening patent, and several applications through it of a solution of chromic acid (100 gr. to  $\frac{3}{4}$  j.) were made. Pulsation scarcely seen, and heard much less distinctly by the patient. Dizziness has also ameliorated.

“April 25th.—For the past three weeks she has been free from vertigo and pulsating noises. After a rest of two weeks after last state, a new and long slit was made in the drum-membrane, and the chromic acid freely applied in the drum-cavity by the cotton probe. Considerable swelling and discharge followed. This has nearly all subsided and she feels better in her head than she has felt in five or six years. She can now stoop down and do her work without any unpleasant pulsation.

“June 25th.—Has had the paracentesis and chromic acid used but twice since last note. She has steadily improved, having had no pulsation and no dizziness until about ten days ago, when both were noticed after violent exertion. By the speculum the lower part of the drum was found to be quite normal, save a few cicatricial traces. At the upper part posteriorly and advancing a little forward on the roof of the external auditory canal, is seen a reddish mass about two lines wide and about three long, not pulsating, but evidently an extension of the angioma. She was then going into the country, and promised to return to me in the autumn if any further symptoms arose. She, however, did not do so. I have recently heard of her death in 1875, from phthisis.

“From her friends I learn that the noises in her ear slowly increased, and for several months prior to her death they caused her much annoyance and distress.”

*My own case.*—Female, ætat. 33, anæmic in appearance, and with œdema of the lower extremities. March, 1871. Patient states that two months previously she began to be troubled with a peculiar noise in the right ear, resembling in character—as she described it—the croaking of a bull-frog. This noise came at regular intervals, synchronous, as she had noticed, with the heart-beat. She had never experienced pain in the ear, and could not remember ever to have had an otorrhœa. She had also never noticed any difficulty in hearing. On examination with the speculum and reflected light, the following condition of the parts was found: the meatus was normal. The membrana tympani was moderately sunken. The handle of the hammer was whitish and sharply outlined. In the anterior superior quadrant the membrana tympani appeared to be perfectly normal; in the posterior superior quadrant it was so transparent that the long process of the anvil and head of the stirrup could be plainly seen through it. The entire lower half of the membrane presented a uniform and rather vivid red color, as if an exudation of blood or bloody serum lay upon its inner side. Such, at all events, was the diagnosis made at the time. Paracentesis was suggested, but the patient felt too weak and miserable to have anything done.

On the 17th of September, 1873, patient presented herself at the New York Eye and Ear Infirmary for the second time. Her story then was that two years previously she experienced some pain in the right ear, and after-

ward observed that her hearing in that ear was very imperfect. From that time to this there had been a constant, pulsating, roaring noise in the affected ear. On examination it was found that she could no longer distinguish the ticking of the watch in the right ear. The membrana tympani was found to have undergone the following changes: the lower half of the membrane was still as brightly red as in 1871, but at the umbo, passing from before backward, the upper boundary line of the red region ran upward and backward, instead of straight across. The posterior half of the membrane—chiefly the lower two-thirds—was now markedly convex and pulsated synchronously with the pulse at the wrist. Suction with Siegle's apparatus gave marked relief for the moment, but the throbbing instantly returned when the instrument was withdrawn. I advised against active interference at that time. Patient never returned.

Drs. Henry D. Noyes and Charles Laight verified the condition as described above.

The points of interest and importance in this case may be briefly enumerated as follows:

1. The development of a new-growth in the middle ear, without any apparent cause for such growth (such as inflammatory irritation), either in the past history or in the present condition of the ear.
2. The highly vascular character of the growth.
3. The slowness of its development.

The growths described in the preceding section were strictly intratympanic, and furthermore they developed as it were spontaneously, without the provocation which an irritating purulent secretion is capable of affording. In the case which I am about to describe there was ample provocation for the development of some form of new-growth, but it is not clear why a strictly vascular growth—to which I have given the name of angioma cavernosum—should have been developed. Virchow, in his admirable treatise on tumors, devotes nearly two hundred pages to the consideration of vascular new-growths. He subdivides the angioma into a number of varieties, and applies the term cavernosum to that variety which is characterized by the existence of a network of blood-spaces, occupying the place and fulfilling the function of capillaries. According to his view, the arteries, in a growth of this kind, pour their blood into these spaces, from which it then passes into the veins, and so back into the general circulation. Such a growth as this, on a small scale, came to my notice in the practice of the New York Eye and Ear Infirmary. The patient, a mechanic, nineteen years old, was admitted as an out-patient on the 2d of April, 1870. He stated that from the time when he was seven years old to that time he had been affected with a discharge from both ears, and with frequent earaches. He had also been very much troubled by all sorts of noises in his ears. Recently, he said, the noise in the left ear had been what might be termed



a pulsating, humming noise. It had been constant, but at regular intervals, corresponding apparently to the pulse-beat, it would become louder. Running upstairs, or any other violent exercise, would aggravate the noise very much. When he awoke, on the morning of the day on which he visited the Infirmary, he found his pillow covered with blood, which was still escaping from his left ear. The hemorrhage, which was not associated with even a trace of pain in the ear, continued throughout the entire forenoon. Up to the time of which we are now speaking, the patient had never seen any blood in the discharge from either ear. On examination I found the left meatus filled with blood, partly fluid and partly clotted. I removed it by syringing out the ear, and then, on examination, I found that an oblong, dark-colored body, about the size of a small pea, was lying, apparently free, on the lower wall of the meatus. On closer inspection, however, I discovered that it was attached by a long and slender peduncle to the stump of the hammer. Dr. Robert F. Weir, in whose department the patient belonged, then divided the peduncle with slender scissors. No hemorrhage of any account followed. Almost immediately after its removal, the small growth was placed in a weak solution of chromic acid, the only preservative fluid that happened to be at hand at the time. Later it was transferred to a bottle containing alcohol.

On the 25th of June the patient reported that, about the middle of May, the noises and the discharge had both returned, and had continued ever since. On examination of the left ear, I found a pinkish, vascular teat dependent from the stump of the hammer, and standing out in marked contrast with the pale mucous membrane which formed the background.

When the specimen had been sufficiently hardened in alcohol, it was imbedded in a mixture of wax and oil in equal parts. No special precautions were taken to place the tumor in such a position that the sections through it should include either the point of rupture or the stump of the peduncle; but, fortunately, the middle sections included both of these points.<sup>1</sup> I will not attempt in this place to give a minute description of the anatomy of this tumor, but will simply state that it was found to consist almost entirely of blood-vessels, which radiated from an irregularly shaped central cavity, and which were separated from each other by a network of of fibrillated connective tissue holding blood-corpuscles in its meshes. In some of the sections a large blood-vessel could be followed from the central cavity into the peduncle. In one of these, and also in other sections, the point of rupture could be distinctly traced from the central cavity to the periphery of the tumor.

As the patient was asleep at the time when the hemorrhage took place, it must be assumed that it occurred through natural causes, operating

---

<sup>1</sup> Lithographic drawings of the microscopic appearances of this rare aural growth will be found in the Archives of Ophthalmology and Otology, Vol. II., Part I.

within the tumor itself. The constant pressure, which first produced the marked dilatation of the blood-vessels, and then an obliteration of their walls at different points, and eventually led to the formation of the large central cavity, must have been the chief agency in producing the final rupture of the peripheral portion of the tumor. Virchow's view, that an angioma is an independent new-growth of vessels, just as much as an exostosis is an independent new-growth of bone, finds strong confirmatory evidence in the fact that, six weeks after the original vascular tumor had been removed, a second one, of precisely the same vascular character, was found growing at the same spot.

*Malignant tumor of the middle ear.*—Cancer or sarcoma of the middle ear is fortunately an extremely rare affection. Thus, for example, so far as I can learn, only one case of malignant disease of the middle ear had been reported<sup>1</sup> in this country, prior to the publication of a case by Dr. H. Knapp, in December, 1879. As the latter case was under my care for several weeks during Dr. Knapp's absence from the city, and as it is the only instance of malignant disease of the tympanum that I have seen, I will give here a brief sketch of it.

The patient, a man thirty-seven years of age, and in poor physical condition, consulted Dr. Knapp on the 7th of May, 1877. The conditions which were found at that time are thus described by Dr. Knapp:<sup>2</sup> "Below and in front of his right ear there was a tumor the size of a hen's egg, which he had first noticed six or seven years previously. It had increased very slowly at first, but quite perceptibly during the last six months. His left ear was affected with chronic otorrhœa, without pain or any symptoms of irritation. His right ear never discharged, and he could always hear well with it until three days before he came to me. At that time he went to bed feeling and hearing as well as ever, but on awaking the next morning, he found that he was deaf.

"*Condition at first visit.*—When the left ear was closed, he could understand ordinary speech at the distance of five feet, and hear the watch tick when in contact with the right ear, the right mastoid process, or the forehead. There was no diminution of sensibility or mobility in the face or any part of the body, and his mental faculties were undisturbed.

"The right membrana tympani was uniformly bluish red, slightly convex, and greatly dislocated forward. The cone of light was absent, but there was a dull, roundish reflex on the posterior lower part. The malleus was seen in its ordinary direction from above forward to below downward, but its tip lay less deep in the canal than the short process. Neither the

<sup>1</sup> By Dr. Robertson, of Albany, in the Transactions of the American Otological Society for 1870.

<sup>2</sup> In the Archives of Otology, Vol. VIII., No. 4, December, 1879.

drum-head nor the adjacent parts of the ear-canal showed increased sensibility to the touch, and the drum-head yielded to the probe as if a soft substance, harder than liquid, were behind it.

"When, the next day, I found the condition of the patient unchanged, I made an incision with a paracentesis-needle into the drum-membrane, in front of and below the handle. The edges of the wound at once retracted, and through the gaping opening I saw a reddish, fleshy growth, filling the whole space behind the displaced membrana tympani. The cut surface showed that the membrana tympani was not thickened. The incision caused no particular pain, liberated no pus, serum, or blood, but gave rise to considerable hemorrhage, and did not improve the hearing. When touched with a probe the tumor gave the sensation as of a somewhat soft, fleshy mass.

". . . . . The incision which I had made in the drum-head was followed for a few days by a scanty sero-purulent discharge. On May 23d he came to me again, having had great pain in the ear the previous day and night. I found the inner half of the auditory meatus occupied by the tumor, and the walls of the outer half red, swollen, and tender to the touch. I ordered warm instillations of a weak solution of carbonate of soda. During the next few days the inflammatory swelling in the outer part of the ear-canal and its surroundings was more pronounced. On May 29th the pain was relieved. An abscess had formed, and pus escaped upon pressure on the tragus. Both Dr. Sands [to whom the patient had been referred by Dr. Knapp for the removal of the parotidean tumor] and myself thought it advisable to delay the operation until the inflammatory symptoms had subsided. When in a few weeks this had occurred, on examination (June 20th) I found that the aural tumor filled the entire meatus, whereas there was no noticeable change in the parotidean tumor. My departure for Europe being at hand (June 23d), I advised him to let another aural surgeon in my stead take charge of the case, and proposed Dr. A. H. Buck, whom he also consulted at once."

The following note furnished by Dr. Sands to Dr. Knapp gives all the facts of importance relating to the parotid tumor :

"June 26, 1877.—I excised the parotid tumor at the New York Hospital. A vertical incision, extending from the level of the meatus down to the lower end of the growth, measuring from three and a half to four inches in length, was made over the middle of the most prominent part of the tumor. It included only the superficial tissue. The remaining tissues were cut on a grooved director, and carefully dissected out with the fingers. The large mass was first removed, and beneath it was found a sort of pedicle, which was also removed by careful and delicate dissection. The growth proved to be an enchondroma, covered by parotid glandular tissue externally, and firmly adherent to the digastric and other deep-seated muscles. The operation was difficult and tedious, but no large vessel or

nerves were divided. After the operation no paralysis of the facial nerve could be detected, although the tumor was apparently situated beneath the parotid gland, the tissue of which was freely divided. No connection existed between the parotid and aural tumors; and with Dr. Buck's assistance I removed as much as I could of the latter by means of a dressing-forceps, having previously snapped two pieces of wire in attempting to effect removal with the "snare."

"July 24th.—Patient remained in the hospital until a fortnight since, when he went to Ithaca. To-day he returned nearly well."

At this point my own records take up the history of the case, and from them I have compiled the following brief account:

The external tumor, removed by Dr. Sands, proved to be a mixed growth (fibrous chiefly, but in parts cartilaginous, and in still others cellular). The parotid gland was found spread out over the mass in the form of a capsule, but was not involved in its growth. Very careful search was made, but at no point could any offshoot be discovered which might be looked upon as the connecting link between the outer tumor and that within the ear. One portion of the growth seemed to terminate at the tip of the stylo-mastoid process. This suggested the idea that the extension of the growth to the middle ear had perhaps taken place by way of the stylo-mastoid foramen. This could scarcely have been the case, however, as there was complete absence of facial paralysis.

July 25, 1877.—The external wound in the neck has almost entirely healed, and the patient is now exceedingly anxious to have an effort made to remove the aural growth. The pain in the region of the ear continues, and the tumor has increased quite perceptibly in size. By means of a curved blunt-pointed knife, made expressly for this case, I was able to cut off quite a large portion of the growth. The bleeding was active, but not profuse. The patient experienced pain during the cutting operation. As soon as the bleeding had ceased, I attempted to further diminish the size of the mass by gnawing away small portions with a miniature "rongeur." After one or two seizures I was obliged to desist, as the blood poured from the ear in a continuous stream, and the bleeding showed no tendency to stop of itself. The hemorrhage was readily arrested by stuffing the ear with cotton, and applying pressure by means of a bandage passed over the head and under the jaw.

The slippery character of the masses removed (like boiled sago) was a very noticeable feature; and when broken down, the fragments did not show the slightest evidence of possessing any fibrous tissue in their composition.

The *microscopic condition* of one of these masses, from thin sections made by Dr. W. H. Porter, of New York, stained with carmine, and mounted in Dammar varnish, was as follows: with low powers it appears that the tumor is composed in part of round, oblong, and branching alveoli filled with

medium-sized cells which have imbibed the staining material quite uniformly and abundantly. Only here and there among these cells can the outlines of a still more deeply stained nucleus be distinguished. The interalveolar tissue occupies fully one-half of the entire specimen. It has apparently not imbibed any of the staining material, though the round and oat-shaped nucleus-like bodies, scattered quite uniformly throughout its substance, are as deeply stained as the epithelioid elements in the alveoli. At many spots the stained nuclei seem to be surrounded by a perfectly colorless hyaline substance, sharply limited against the contiguous interalveolar tissue: in other words, cartilage cells seem to enter largely into the composition of the matrix of the tumor. All the blood-vessels encountered are of comparatively large size, and filled with blood-corpuscles. At no point can I find distinctly fibrillated connective tissue.

Later, on the day of the operation, a second and very unsatisfactory effort was made to diminish the size of the growth. The copiousness of the bleeding, however, again obliged me to desist.

July 26th.—I introduced four red-hot needles in succession into the mass, with a view of diminishing the bleeding. As soon as the rongeur was used, however, the bleeding became as active as on previous occasions. Before I had reached the middle ear in my mining operations, I thought it advisable to abstain from further interference.

Soon afterward a large abscess developed on the side of the neck, just below the mastoid process, and the patient was again transferred to Dr. Sands' care.

Early in August the patient returned to his home in the central part of this state. Already at that time the growth in the middle ear and meatus had begun to extend into the neighboring parts. On the 24th of October, however, when he came to New York for a few days, I was surprised to see how formidable the growth had become in that short interval of ten weeks. The auricle had been dislocated outward a distance of at least an inch beyond its normal position. This dislocation seemed to be due to the development of a broad, hemispherical mass of tissue beneath (*i.e.*, on the inner side of) the outer ear and on all sides of it. The external meatus was still filled with the growth, and there were two fistulous openings,—one in front of, the other behind, the auricle,—from which pus and blood could readily be forced by pressure made in the neighborhood. The mass could be grasped and moved a little as a whole, but in the main its attachments were very firm. Dr. Sands, Dr. Knapp, and I, each agreed that an operation for the removal of this growth was out of the question. The patient returned home.

On the 29th of May, 1878, Dr. S. H. Peck, his medical adviser, wrote to me as follows: "The tumor has attained an enormous growth, is larger than a child's head, and of nearly the same shape; it measures thirteen inches in circumference at the base, and is partly covered by integument.

His general health is very much impaired and he is greatly emaciated. He has slight attacks of hemorrhage. I use carbolic acid as a disinfectant. He takes morphine ; does not suffer much pain."

After the patient's death from exhaustion, on the 15th of September, 1878, Dr. Peck sent to Dr. Knapp the following memorandum with regard to the condition of the tumor at that time :

"At the time of death the tumor measured in circumference at the base twenty-two inches, in the antero-posterior diameter eight inches, in the vertical seven inches. Its elevation over the surface of the skull was five inches. It extended anteriorly to within half an inch from the orbit, posteriorly nearly to the occipital protuberance, superiorly to the parietal eminence, inferiorly to the angle of the lower jaw. The ear, normal in size and appearance, rested upon the external surface of the tumor, being carried outward by the tumor. In general appearance the tumor presented a lobulated form, viz. : a superior, middle and inferior lobe, the superior being above the ear, the middle behind, and the inferior below the ear. Mastication was slightly interfered with, simply by the weight of the tumor. No protrusion of the growth into the bucco-pharyngeal cavity was noticeable. No mental disturbance."

*Subjective and objective systolic murmurs.*—Subjective systolic murmurs are by no means rare, but those which can be heard by a second person, as well by the patient, are, I believe, very rare. I know that I have repeatedly, in cases of subjective pulsating noises, applied the auscultation-tube to the affected ear, but only once have I been rewarded by hearing what the patient had previously described. In the case to which I refer, the patient, an intelligent woman, about forty years of age, consulted me at the Infirmary for a very distressing puffing noise in the right ear. She said that she had discovered that, by making pressure behind the right ear, she could stop the noise. Her hearing had not been affected, nor had she experienced any pain in the right ear. On examination, I found the drum-membrane normal both in texture and in position. No visible pulsation could be detected, nor was there any congestion of the parts. By means of the auscultation-tube, however, a distinct systolic bruit was heard, both by Dr. Wm. McFarland, who was at that time my assistant, and by myself. The pressure of the conical end of the auscultation-tube against the walls of the orifice of the auditory canal rendered the bruit inaudible. The heart-sounds were normal, and the carotids of the two sides seemed to beat with equal force. Unfortunately, I neglected to ascertain whether firm pressure upon the carotid of the right side caused the noise to cease, or not. From the fact, however, that the woman herself was able to stop the noise by pressing upon some spot situated behind the ear, and from the fact that the conical hard-rubber end-piece of the auscultation-tube accomplished the same result, there can be very little doubt but that

the bruit originated either in some twig of the stylo-mastoid artery, which supplies the drum-membrane and posterior portion of the tympanum, or in that branch of the posterior auricular artery which supplies the external auditory canal. It does not seem to me to be necessary to assume that the noise in question owed its origin to an aneurismal dilatation: it might equally well have been caused by some pathological process that took place outside of the artery, as, for example, by the contraction of cicatricial tissue, in its neighborhood, causing diminution in its calibre.<sup>1</sup>

*Otalgia.*—In the great majority of instances pain in the ear implies inflammatory action either in the middle ear or in the external auditory canal. In the absence, however, of any evidence of inflammation in these parts, we are compelled to seek for the cause in some adjacent or more remote organ. It is to this class of cases that the term “reflex or sympathetic otalgia” is usually applied. According to my experience, such cases are by no means so common as some authorities would have us believe. When a patient complains of pain in the ear, and, on examination, I fail to find any adequate cause for its existence in the condition of either the external or the middle ear, I at once suspect his teeth of being at the root of the trouble; and in the majority of these cases of otalgia I find sufficient dental disease to justify the belief that this condition is the fundamental one, and the otalgia simply a reflex phenomenon. If the teeth are found to be in a healthy condition, we may think next of a malarial, rheumatic, or syphilitic origin for this neuralgia of the ear. I have seen cases in which I have been disposed to ascribe the otalgia to malarial, rheumatic, or syphilitic influences, but I have never yet encountered a case in which I was justified in entertaining more than a mere suspicion. In one of these cases the pain was clearly due to a chronic arthritis of the temporo-maxillary joint; the motions of the jaw causing a plainly audible creaking sound. In another case the otalgia finally terminated in a facial paralysis on the same side of the face. The suspicion that the affection was syphilitic in its nature was strong, but as the patient did not remain long under observation, I was unable to arrive at a satisfactory diagnosis.<sup>2</sup>

I have had absolutely no experience with affections of the *chorda tympani* nerve, and will therefore omit all mention of it here.

<sup>1</sup> Consult, on this subject, a paper by Dr. J. Orne Green, of Boston, in the Trans. of the American Otol. Society for 1878. Dr. Spencer, of St. Louis, has also, I believe, written on this subject in a recent number of one of the St. Louis journals.

<sup>2</sup> Consult, on this subject, a paper by J. Orne Green, on Neuralgia in and about the Ear, Transactions American Otological Society, 1874; another by Voltolini, on Otalgia Intermittens, in the Monats. f. Ohr., May, 1878, and July, 1878; a third by Gruber, on Otalgia, in the M. f. O., September, 1869; and, finally, a fourth by Weber-Liel, on Neuralgia of the Ear, in the M. f. O., May, 1878.

## CHAPTER XI.

### DIFFERENT FORMS OF AURAL DISEASE IN WHICH THE LABYRINTH IS BELIEVED TO BE INVOLVED.

THIS chapter comprises a series of aural disturbances, all more or less grave in character, and many of them very obscure in their pathology. It is customary to group them together under the heading, "Diseases of the Labyrinth," but, unfortunately, there are good reasons for believing that this convenient designation cannot rightfully be applied to more than a fair proportion of the entire number. In the cases of total deafness following the disease known as epidemic cerebro-spinal meningitis, there can be very little doubt that the chief lesions are located in the labyrinth.<sup>1</sup> I will give in brief outlines, the histories of two such cases. In the first one of these the patient, a boy seven years of age, was brought to the Infirmary on the 26th of June, 1872. His father stated that ten weeks previously his son had been taken ill with severe headache, fever, pain in the back, and bending backward of the head and shoulders. About the fourth day of the attack, it was noticed that the boy was decidedly deaf, and twenty-four hours

---

<sup>1</sup> And yet, even in these cases, the lesions found after death are sometimes confined almost entirely to the middle ear. Thus, for example, Moos (*Archives of Ophthalmology and Otology*, Vol. III., No. 2, p. 177) reports a case of cerebro-spinal meningitis, in which decided, if not total deafness was observed two days before death. At the autopsy, it was found that the tympanic mucous membrane, on both sides, was decidedly hyperæmic and swollen. There were also very decided evidences of a general meningitis. But the auditory nerve, in the porus acusticus internus, was quite free from evidences of inflammation, on both sides. Both labyrinths were also examined and found normal in every respect.

Klebs also (*Virchow's Archiv*, Vol. 34, p. 356 et seq.) narrates the history of a somewhat similar case of meningitis. The patient, a subordinate officer in the army, was taken ill on the 10th of April, and died on the 7th of May. No deafness was noticed when he was first taken ill. Soon afterward, however, he gradually became totally deaf. At the post-mortem examination the auditory nerves (examined microscopically) were found to be perfectly normal. The terminal apparatus of the cochlea was also found to be normal. The middle ear, however, was found (on both sides) to be the seat of extensive inflammatory changes. Strong bands of connective tissue, well supplied with blood-vessels, traversed the cavity in all directions, and must of necessity have greatly impeded the movements of the ossicles, to which they were adherent at numerous points.



later he appeared to have lost the sense of hearing entirely. There had been no discharge from either ear, and the only complaint which the boy had made with reference to his ears was, that he constantly heard noises in them of the most varied character. This symptom still persisted at the time when I saw him. During convalescence, whenever the patient attempted to walk without assistance, he experienced great difficulty in maintaining his equilibrium. Although this difficulty had afterward greatly diminished, it was still sufficiently marked, when the boy came to the Infirmary, to attract my attention. On examination, I found both external and middle ears in a comparatively healthy state. The deafness was absolute.

In the second case, the patient, a boy four years of age, and in apparently good health, was brought by his mother to the Infirmary on the 24th of September, 1872. She gave the following history :

Five months previously the boy had been taken with symptoms of cerebro-spinal meningitis, viz., vomiting, pain in the head, delirium, high fever, and opisthotonos. In the course of a week the delirium passed off, and then the parents noticed that the child was entirely deaf. Since recovery the child had shown an "ugliness" of disposition to his family which they had never noticed before, and a desire to destroy clothing and other articles which came within his reach. His gait had been staggering and was still, at the time when I saw him, somewhat unsteady. Deafness complete. Right membrana tympani opaque and sunken ; left, in nearly the same condition. In other respects the middle ears appeared to be normal.

In both of these cases it is reasonably clear that the original disease partook of the nature of a meningitis, and that the inflammation at a certain stage spread to both labyrinths. If the inflammation had not involved the labyrinths, but had simply damaged the main trunks of the auditory nerves, it is difficult to understand why the trunks of the facials, which are so intimately related to these nerves, should have escaped. Equally great are the difficulties that stand in the way of the assumption that the auditory centres in the medulla oblongata are the parts involved. Weber-Liel has shown,<sup>1</sup> by direct experimentation, that a free communication exists between the endolymphatic and perilymphatic spaces of the labyrinth and the extralabyrinthine intracranial spaces, and it is probably by this route that the inflammation spreads from the meninges to the labyrinth.

Epidemic cerebro-spinal meningitis is not the only epidemic affection which is apt to be followed by labyrinthine disease. Scarlet fever, typhoid fever, and measles, also furnish a large proportion of the cases of this form of aural disease. In one instance that came under my observation the sud-

---

<sup>1</sup> Virchow's Archiv, Bd. 77, 1879.

den and complete loss of the hearing-power took place shortly after an attack of mumps. In another case the mother attributed the loss of hearing to a series of epileptic seizures. As the child, however, had been subject to otorrhœa, it is quite probable that the relations were reversed, viz., that the epileptic attacks were due to the aural affection. In many of these cases the deafness develops at a time when there is no reason to believe that even a trace of meningitis exists, and we must, therefore, in such cases, seek for some other mode of origin. The high degree of inflammation of the middle ear which characterizes a certain proportion of these cases suggests the likelihood of an extension of the inflammation from the tympanum to the labyrinth.<sup>1</sup> Blood-vessels pass freely from the tympanum to the vestibule through the stapedio-vestibular ligament, and, if I am not mistaken, also through the membrana tympani secundaria. There are, therefore, no anatomical reasons why such an extension of the inflammation should not take place. As a matter of fact, however, an acute inflammation of the middle ear, no matter how severe, rarely leads (during the acute stage) to serious and permanent impairment of the hearing, or, in other words, to serious disease of the labyrinth. This is the only objection that I know of, to the view that in some of these cases of total loss of hearing the damage may be due to an extension of the inflammation from the middle ear to the labyrinth. I might frame still other hypotheses for the purpose of explaining these obscure cases of rapid loss of hearing, but the actual facts in our possession are so few that I prefer to abstain from any further theorizing on the subject.

In a few cases the loss of the power of hearing takes place in a gradual manner, and without any attendant symptoms that might throw light on the cause of such loss. As an example of this, I might mention the following case: A healthy young girl, thirteen years old, was brought by her mother to the Infirmary on the 3d of November, 1873. Six months previously the mother had noticed that her daughter was a little deaf, and in the course of about two weeks the child completely lost the sense of hear-

---

<sup>1</sup> In this connection I might mention a case of intermittent complete deafness, in a boy about four years old. The child, as I learned from the mother, had twice before remained in a condition of total deafness for a period, each time, of several weeks. During the intervals he had heard sufficiently well for those around him to be able to make themselves understood. At the time when I saw the boy, he had been absolutely deaf for a period of six weeks, and the parents were beginning to fear that he had permanently lost the sense of hearing. On examination I found the drum-membranes so highly atrophied that each of them lay like a thin film in contact with the purplish and swollen mucous membrane of the inner wall of the tympanum. The tonsils were enormously swollen, and the naso-pharyngeal space seemed to be almost obliterated by the highly swollen condition of the surrounding walls. As a consequence the boy was obliged to breathe wholly through the mouth. So far as I could ascertain by actual experiment, the boy was totally deaf. (The subsequent history of this case is unknown to me.)

ing. No illness of any kind preceded or accompanied this loss, and even the dizziness and staggering gait, which are so often associated with the sudden development of deafness, were absent in this case. An examination showed that the middle and external ears were in every respect normal.

In this category may be placed those cases of total loss of the power of hearing which are observed in women shortly after confinement.

Voltolini<sup>1</sup> maintains that there is such a thing as a primary acute inflammation of the labyrinth, and gives the histories of a few such cases. He admits that this form of disease is often mistaken for "inflammation of the brain," and I suspect that the error—if error it be—is one that can scarcely be avoided. In some instances, however, the history of the progress of the disease shows quite clearly that the meningitis does not precede the disease of the labyrinth. Thus, for example, Schwartz<sup>2</sup> has published the details of a case in which the symptoms during life pointed to an acute primary inflammation of the labyrinth. Subsequently meningitis developed and the patient died. At the autopsy no other cause for the general meningitis was found beyond a purulent inflammation of the labyrinth.

The term "Ménière's disease" is loosely applied to all those cases of sudden loss of hearing (on one or on both sides, complete or incomplete) which are associated with vertigo, tinnitus, nausea, inability to maintain one's balance, etc. In some of these cases, especially in young individuals, it is more than likely that the disease should be considered as a mild attack of epidemic meningitis, with an extension of the inflammation to the labyrinths. In 1872 this disease was fairly epidemic in this city and vicinity, and in parts of Connecticut, and many of the patients were brought to the Infirmary in the hope that their deafness could be relieved. In a few of these cases the cerebral disturbances seemed to have been very trivial, and had it not been for the fact that the disease was epidemic and that I was interested in learning something about it, I think I might very easily have overlooked the primary disease and have considered some of these cases, at least, as instances of a primary affection of the labyrinth. Take as an example the following case :

The patient, a girl, about fourteen years of age, was brought to the Infirmary on the 8th of May, 1872. From her mother I learned that three months previously she had been taken ill one day with dizziness, noises in the ears, slight disturbance in vision, photophobia, and finally vomiting. On the afternoon of the second day the mother noticed that she was very deaf, and by bed-time it had increased to such an extent that they were

<sup>1</sup> *Monatsschrift für Ohrenheilkunde*, October, 1867 ; June, 1868. See also a case reported by Schwartz, in the *Archiv für Ohrenheilkunde*, XIII., p. 107.

<sup>2</sup> *Archiv für Ohrenheilkunde*, Bd. XIII., p. 107.

obliged to communicate with her by writing. So far as I could learn there had been no delirium, no opisthotonos, nor any other decided symptom of meningitis. Although the other symptoms soon disappeared, the deafness and the inability to easily maintain her equilibrium persisted. The latter symptom had not entirely disappeared at the time when I saw the patient, but the deafness was apparently as profound as on the second day of the attack. I found the middle ears practically normal.

In other cases it is extremely difficult to picture to ourselves the precise nature of the pathological processes and the exact locality in which they are taking place. When we take into consideration the apoplectiform character of the attack or attacks,—for there are often several of them,—the nearness of the auditory centre to other important centres (that governing the pneumogastric, for instance), and the fact that, when the inflammation spreads from the tympanum to the labyrinth, all those concomitant symptoms which are considered as essential features of the typical Ménière's disease,—viz., the dizziness, the staggering gait (or movements in a circle), and the nausea or vomiting,—are lacking; when we consider all these things, I say, it is hard to resist the belief that the medulla oblongata is more likely to be the seat of the disease than the labyrinth.<sup>1</sup>

---

<sup>1</sup> In this connection I might mention the results of experiments made by Arthur Böettcher, in 1872, on pigeons, and published in the *Archiv für Ohrenheilkunde* for 1874. Those made by Flourens, many years earlier, seemed to determine beyond a doubt that in that part of the labyrinth which is represented by the semicircular canals resides the power of controlling the equilibrium of the body. In 1870 Goltz repeated these experiments, and was led to the conclusion that the semicircular canals "were organs of sense for the maintenance of the equilibrium of the head, and so also, indirectly, of the entire body." Böettcher, by operating in a somewhat different manner from that pursued by his predecessors, was able to divide the posterior vertical semicircular canal of the frog *without* producing in that animal any of the peculiar movements described by Flourens. This induced him to carry out a series of similar experiments upon pigeons, the results of which may be stated as follows:

In those cases in which the operation was carried out without any special precautions, and in which, as a consequence, there was considerable hemorrhage from the vessels in the neighborhood of the semicircular canals, the results obtained were essentially the same as those described by Flourens, Goltz, and others, viz., twisting of the head to one side, rolling movements, travelling in a circle toward the affected side ("*mouvements de manège*"), unsteady and uncertain gait, pendulum-like motions of the head, etc. In one case the twisting of the head and the rolling movements did not appear until the fifth day after the second operation (division of the canal on the opposite side). At the post-mortem examination in this case the evidences were found of an acute inflammation of the dura mater in the vicinity of the region where the second operation had been performed, and extending thence to the portion which covers the cerebellar hemispheres.

In a second series of cases, although great care was used in performing the operation, the results varied very greatly. Thus, in one case, after division of the inner vertical canal of one side, the bird showed a tendency to fall forward, but this continued

I will give here a few examples of that form of Ménière's disease in which the apoplectiform character of the attack would lead a careful observer to doubt seriously the correctness of the prevailing view that the labyrinth in such cases is the region chiefly or exclusively affected.

---

for only two days. After division of the horizontal canal of the opposite side, pendulum-like movements of the head began, and the bird showed a tendency to fall toward that side. The pendulum-like movements, however, soon ceased, and the bird slowly recovered the use of its legs. The power of flight was totally lost after the second operation.

In another case, after division of the semicircular canals, the tendency to move in a circle showed itself, but soon passed off. Although a semicircular canal on each side had been divided, no pendulum-like movements occurred. A short time after the operation, and notwithstanding the fact that the continuity of the semicircular canals was broken on both sides, no disturbance of the equilibrium could be noticed. Furthermore, the tendency to move in a circle scarcely showed itself at all when the bird walked, while during its flight it was very marked. The peculiar manner of holding the head sideways, and the attacks of bringing the head down in such a way that the top would touch the floor, did not appear as the immediate result of the operation, but for the first time as late as four weeks after the operation, that is, after the full disappearance of all the immediate effects of the operation. These peculiar symptoms were therefore due to some disturbances which must have developed at a later date, and were only indirectly connected with the division of the semicircular canals. The rolling movements appeared in connection with the twisting of the head whenever the bird was very greatly disturbed. There was no appreciable connection between the rolling movements and the tendency to move in a circle. The latter symptom was noticeable for a long time before the rolling movements appeared, and when these came, the tendency to move in a circle disappeared altogether.

In still another case, after the division of both outer vertical semicircular canals, the twisting of the head and the rolling movements did not appear until after a lapse of about three weeks. There was total loss of the power of flight, and the left leg appeared to be permanently affected. At the autopsy, an extravasation of blood was found in the pia mater, on the left side, just over the origin of the acoustic nerve. The supposition is therefore justifiable that the symptoms which developed later,—the twisting of the head and the rolling movements,—were due to this extravasation.

Finally, in a fourth case, after the division of the lower arms of both vertical semicircular canals, the bird was still able to hold its head in a perfectly normal position. The ability to walk and the power of flight were very materially diminished; yet they improved very decidedly in the course of a short time. About ten days after the operation, well-marked pendulum-like movements in a vertical direction set in, and the power of flight appeared to be quite destroyed. At last these symptoms, too, almost entirely disappeared. No lesions found in the brain or its membranes at the autopsy.

In a third series of cases the operation was performed more successfully, as regards the avoidance of injury to neighboring important parts; and in these cases, after the division of one or more semicircular canals on both sides, but very slight and transient motor disturbances followed; the birds in a very short time entirely recovered their powers of locomotion, of maintaining perfectly their equilibrium, and of picking up particles of food.

By these very important experiments Böettcher proves that the semicircular canals may be divided *without* causing any of the symptoms described by Flourens and Goltz as specially due to a lesion of this apparatus. If, as he says, the destruction of the

CASE I.—The patient, a decidedly stout, full-blooded lady, about forty years of age, consulted me on the 1st of August, 1871. She stated that on the previous Christmas morning, while in the enjoyment of her usual good health, she had been suddenly seized with a severe pain in her head,

semicircular canals were the cause of these characteristic motor disturbances, the latter should have persisted as a permanent thing; instead of this, however, they soon disappeared entirely, notwithstanding the fact that the apparatus of the semicircular canals had been practically destroyed. Another point to which he calls attention, and which certainly has a suspicious character about it, is this: *the motor disturbances, when only one side is operated upon, always appear in the extremities of the side upon which the operation has been performed.* Thus, the movements in a circle are always executed toward the injured side. A slight paresis of the foot or wing of one side would be sufficient to cause these peculiar movements in a circle, which have hitherto been considered as something almost specific of a lesion of the semicircular canals.

In conclusion, Böttcher thus states his views regarding this question: "These disturbances of equilibrium manifest themselves either immediately after the operation,—and are then due to an injury of the brain,—or after the lapse of a few days, in which case they are due to pathological processes which have involved the central portions of the nervous system."

As regards an injury to the brain, Böttcher calls attention to the fact that the auditory nerve is not bound down at any point between its origin in the brain, on the one hand, and the fundus of the meatus auditorius internus, on the other; and that consequently any operative interference with the semicircular canals, which may result in pulling upon or tearing the ampullæ or sacculi,—that is, in pulling upon the vestibular fibres of the auditory nerve,—must necessarily produce a certain amount of injury in that portion of the brain from which these fibres come. The variable results obtained from interference of this kind are due to the circumstance that at one time one set of fibres is pulled upon, while at another, another set. In this connection he quotes Brown-Séquard as saying: "I have ascertained that the phenomena observed in these experiments do not depend on the section of these canals, as this operation may not cause these phenomena, but that they are the results of an irritation of the auditory nerve, from the drawing upon it by the membranous semicircular canals at the time we divide them." (Course of Lectures on the Physiology and Pathology of the Central Nervous System, Philadelphia, 1864, p. 195.)

In answer to the objection of some, that the motor disturbances here under consideration are of too long duration for so slight a lesion, and always take place on the side of the body corresponding to the lesion,—which does not agree with the generally accepted notion that an injury to one side of the brain should be followed by disturbances upon the opposite side of the body,—Böttcher again cites the following remarks of Brown-Séquard (loc. cit.): "It is a fact worthy of attention, that a puncture with a needle through the anterior pyramids, which contain very nearly all, if not all, the nerve-fibres employed in voluntary movements, will hardly produce a momentary contraction in some muscles; while certain punctures through the olivary column of the medulla oblongata at once produce a spasm of many muscles, although this column does not contain more than very few (if any at all) voluntary motor fibres! And now, to add to the strangeness of the fact, in this last case the muscles remain contracted sometimes for hours, sometimes for days and weeks."

" . . . There is, therefore, in some parts of the nervous centres, a property of acting in a persistent manner to produce muscular spasms during and after a mechanical excitation."

accompanied by dizziness, nausea, and loud noises in both ears. She was walking about the room at the time of the attack, and was obliged to take hold of some article of furniture, in order to escape from falling. The objects in the room seemed to her to be turned upside down; she also saw double. She lay down upon the bed, and soon afterward vomited. When her friends came into the room and spoke to her, she discovered that she had completely lost the sense of hearing. The nausea and vomiting ceased in the course of a few hours, and, with the disappearance of these symptoms, she experienced decided relief from the pain in the head. Her hearing soon began to return, and at the end of about six days she was able to hear fairly well. The double vision lasted somewhat longer, and did not finally disappear until after the lapse of several weeks. The subjective noises, however, and a moderate degree of deafness had continued to annoy her up to the time when I saw her. I tested the hearing and found it to be: R.,  $\frac{2.5}{1.2}$ ; L.,  $\frac{0.03}{1.2}$ . The sound of the vibrating tuning-fork, no matter at what point it was placed on the cranium, was heard best in the right ear. Aside from a slightly opaque condition of the drum-membranes, the external and middle ears appeared to be normal. Both pupils responded to the light, but the left was fully twice as large as the right. From Dr. Carl Reincke I ascertained that the ophthalmoscopic examination had yielded only negative results. Auscultation revealed the existence of a loud systolic bellows-murmur, heard most distinctly at the base of the heart. (The patient was not seen again.)

CASE II.—The patient, a well-to-do farmer, about sixty years of age, consulted me on the 15th of April, 1873. He gave the following history: About two months previously he was taken suddenly ill with severe pain in the head, dizziness, and nausea. The objects in the room seemed to be revolving in a circle. He lay down, and in about five minutes all the more marked symptoms, with the exception of the headache, disappeared. The attack, however, left him in such a prostrated condition that he was compelled to keep his bed for about three weeks. During this period he occasionally vomited his food, and whenever he attempted to walk about the room he experienced great difficulty in maintaining his equilibrium. About

---

“ . . . The parts of the base of the encephalon which are capable of producing persistent spasms seem to be quite different from those employed in the transmission of sensitive impressions, or of the orders of the will to muscles, at least in the medulla oblongata and the pons Varolii. They constitute a very large portion of these two organs, and perhaps the three-fourths of the first one; they are placed chiefly in the lateral and posterior columns of these organs; many of their fibres do not decussate, and produce, therefore, spasms on the corresponding side of the body.”

This is important evidence in favor of Böettcher's view: showing, as it does, that a slight injury of the medulla oblongata,—the very part of the brain from which the auditory nerve springs,—may result in motor disturbances on the corresponding side of the body, and, furthermore, that these disturbances may last for quite a long time.

five weeks after this attack he experienced two more of a similar character, the interval between the two not exceeding twenty-four hours. At the time when he consulted me there was complete deafness in the right ear, the sound of the tuning-fork being referred very promptly by the patient to the right ear. I was unable, however, to ascertain satisfactorily at what precise time during the previous eight weeks this loss of the hearing-power had taken place. The patient complained chiefly of a throbbing pain throughout the left side of the head. The noises in the left ear also distressed him. On examination I found both ears in a comparatively healthy state. Suction with Siegle's tympanoscope diminished the throbbing appreciably. An examination of the urine showed simply a rather low specific gravity (1004).

Dr. Brown-Séguard, to whom I referred the patient, wrote as follows: "Your patient is evidently attacked with what has been miscalled Ménière's disease (an affection which I had described in lectures and books three or four years before Ménière spoke of it). He has no organic affection of the brain so far as it is possible to say so from the fact that there are no brain-symptoms actually. I would, however, recommend the use of the two medicines for which I have given him a prescription, and I will suggest that counter-irritation of some kind be used behind each of the ears. The patient must live well, taking chiefly nourishing food, but avoiding excess as regards quantity of any kind of food. He has no need of stimulants." The prescription referred to is the following:

℞. Sodii iodidi . . . . .	3 ijss.
Sodæ bicarb. . . . .	3 j.
Infus. calumbæ fl. . . . .	℥ ij.
Tinc. rhei. . . . .	3 ij.

M. S.—A teaspoonful and a half three times day before meals, with a little water. (B.-S.)

Also:

℞. Strychniæ sulphatis . . . . .	gr. j.
Acid. sulph. dil. . . . .	℥ xv.
Aquæ destillatæ . . . . .	fl. ℥ v.

M. S.—Two teaspoonfuls three times a day after meals. (B.-S.)

The plan of treatment suggested above was carried out faithfully up to the 23d of May. As the effects of the strychnine were then beginning to show themselves (muscular pains and stiffness), the patient was advised to discontinue internal treatment. His general condition had certainly improved during the interval, but the aural symptoms had remained unchanged.

CASE III.—The patient, a healthy but rather full-blooded lady, about thirty years of age, consulted me on the 17th of September, 1872. She



stated that during the previous spring she had experienced a sudden attack of severe pain in the head, with loud noises in the right ear. Afterward she discovered that she could not walk without staggering, and that the hearing of the right ear was very much impaired. The former symptom had gradually disappeared, but the deafness and the noises still persisted. On examination, I found both drum-membranes—so far as they could be seen—normal in appearance. In each external auditory canal, however, there was a hemispherical exostosis, sufficiently large to conceal the lower two-thirds of the membrana tympani. These symmetrically placed bony tumors were in close proximity to the drum-membranes. The tuning-fork was heard best in the left ear; the ticking of the watch was not heard at all in the right ear; when the left ear was closed, words spoken in an ordinary tone of voice were not heard correctly in the right ear beyond a distance of about one foot.

In the course of about two months, under the employment of the iodide of potassium in ten-grain doses, repeated three times a day, the patient so far regained her hearing that she could distinguish the ticking of my watch at a distance of half an inch, and words spoken in an ordinary tone of voice at a distance of about five feet. The tinnitus continued unchanged. Two or three times, during this period of eight weeks, the remedy had disagreed with her, and she had been obliged to discontinue it for about one week each time.

As recently as during the summer of 1879, I learned that the patient had not experienced a relapse.

CASE IV.—The patient, a clerk, about forty years of age, and a decided sufferer from stomach indigestion (nausea, heartburn, gaseous eructations, etc.), was taken suddenly ill, about the 15th of August, 1880, with marked dizziness and noises in the left ear. When he attempted to walk, he found that he could do so only with great difficulty, as he was unable to keep his balance. On the second or third day he discovered that his sense of hearing in the left ear was not as acute as before the attack.

On the 30th of August he consulted his regular medical adviser, and was by him sent to me for a report on the condition of his ear. Although his gait had, he thought, steadily improved, it was still at that time noticeably unsteady. He not only used a cane, but in walking out of doors he seemed to avail himself of the assistance of his wife. He was barely able to distinguish the ticking of my watch, when I pressed it firmly against the left mastoid process. With the right ear closed, he distinguished words spoken in an ordinary tone of voice at a distance of several feet from the left ear. The tuning-fork was heard best (by bony conduction) in the right ear. The drum-membrane showed slight evidences of a subacute catarrhal inflammation, and there was also a moderate degree of naso-pharyngeal catarrh.

With regard to the cases in which the auditory nerve, either before or after its entrance into the labyrinth, is the part believed to be principally affected by constitutional syphilis, I find that my material is far too scanty and too imperfect to justify any special conclusions. In these cases it is generally assumed that the labyrinth is the seat of the syphilitic lesion. It is quite possible, however, that the lesion may be in the middle ear, or in the auditory nerve before it enters the labyrinth. It is a peculiarity of poisoning by syphilis that almost any spot in the body may become the seat of well-marked textural changes, such as increased vascularity, infiltration, proliferation, or death. The parts in the immediate neighborhood may exhibit no evidences whatever of participation in the process. Thus, for example, the mucous membrane lining the niche for the round window, or the membrana tympani secundaria itself, may become congested and very much swollen, without narrowing of the Eustachian tube, without exudation of fluid into the middle ear, and without the slightest change in the condition of the drum-membrane—or, in other words, without any discoverable evidence of disease in the middle ear. The swelling of these parts, and especially of the secondary tympanic membrane, cannot take place without producing pressure upon the fluid of the labyrinth. This lesion, therefore, would be competent to produce the hardness of hearing, the staggering gait, and the dizziness observed in some of these cases.<sup>1</sup> If not arrested by treatment, the swelling might increase to such a degree that the displacement outward of the foot-plate of the stirrup would no longer compensate for the pressure exerted at the round window upon the contents of the labyrinth. In that event we should have not only a mechanical interference with the working of the cochlear apparatus, but also an intralabyrinthine anæmia (due to pressure), which would very soon cause disturbances in the nutrition of the delicate structures of the cochlea. All degrees of hardness of hearing might in this way be produced.

Lesions at the oval window, by obstructing the action of the stirrup, would likewise be competent to diminish very materially the power of hearing. Thus, even complete ankylosis of the stapedio-vestibular articulation might result from syphilitic disease.

Finally, still another possibility must be taken into consideration. The auditory nerve, after its separation from the facial in the meatus auditorius

---

<sup>1</sup> The fact that pressure upon the fluid contents of the labyrinth may cause dizziness, nausea, and perhaps even a staggering gait, does not appear to me to add strength to the view that in some part of the labyrinthine cavities—*e.g.*, in the semicircular canals—resides the organ which co-ordinates the movements of the body, or the organ of equilibrium sense. It seems to me to show simply this, that pressure has been made upon filaments of the sympathetic nerve. Pressure upon the mucous membrane of the mastoid antrum (see Case I. on p. 303) may produce precisely the same train of symptoms, and yet nobody has ever ventured to suggest that the organ for controlling the movements of the body is situated in that cavity.

internus, passes through the minute openings in the cul-de-sac of the meatus and enters into numerous bony channels in the modiolus. The most insignificant pathological changes in these minute channels—changes which it might be difficult to detect even with the microscope—would suffice to inhibit the functional capacity of the bundles of auditory nerve filaments contained within them.

In the present state of our knowledge of aural pathology, therefore, we can only use the expression “syphilitic disease of the labyrinth” in a somewhat loose sense, and as a term of provisional usefulness.

I will give here, in brief outlines, the histories of some of my cases which belong clearly in the category which we are now considering :

CASE I.—The patient, a man twenty-nine years of age and in good general health, consulted me on the 24th of March, 1877, at the request of Dr. Roosa. During January of that year he had suddenly and almost completely lost the hearing-power in both ears; chancre eighteen months previously. No other evidence of syphilis, with the exception of an ill-defined ulcer on the right side of the tongue, near its tip. Nothing worthy of note in the condition of the middle ears. Antisyphilitic treatment (by Dr. Roosa), consisting of inunctions with the oleate of mercury and the internal administration of iodide of potassium in large doses (reaching 6 drachms in a single day on one occasion), brought about, in the course of a few weeks, a very marked improvement of the hearing.<sup>1</sup> (Full details with regard to this case will be found on p. 528 of the fourth edition of Dr. Roosa’s “Treatise on the Ear.”)

CASE II.—Female, *ætat.* 40, a teacher, somewhat anæmic, October 6, 1877. Totally deaf in the right ear since childhood. Two weeks ago she began to notice slight deafness in the left ear, together with occasional pains and a sense of tightness in the ear. Left drum-membrane apparently normal. The ticking of a watch heard at a distance of four feet. Right drum-membrane very much disfigured by inflammation that occurred during childhood. Pharynx healthy. As there are no indications for treatment, she is advised to wait.

On the 23d of October she returned. The hearing-power had been steadily and even quite rapidly diminishing. Tinnitus constant. On the 12th she began to experience a sensation of dizziness, which soon became so marked that she could only walk with the assistance of a friend. No

---

<sup>1</sup> It should be stated here that this patient had already been subjected to what might be termed an ordinary course of antisyphilitic treatment. Little or no benefit, however, resulted. It was not until the more vigorous antisyphilitic plan of treatment had been instituted—the plan which Dr. Roosa was the first, I believe, to employ in these cases of sudden and complete deafness—that decided benefit was obtained.

change in the condition of the drum-membrane. Treatment: iodide of potassium in fifteen-grain doses three times a day.

October 30th.—Slight improvement in the hearing; dizziness the same. Dose of iodide of potassium increased to twenty grains three times a day.

November 28th.—Hearing is now, so far as she herself can perceive, as acute as when I first saw her on the 6th of October. The ticking of the watch is heard at a distance of four feet. The dizziness has also disappeared entirely, though a little tinnitus still remains. All treatment is to be stopped.

From her physician, Dr. Charles Packard, I learn that he has had occasion to treat her for a suspicious periostitis on both tibiæ. The deafness was therefore probably due to a syphilitic affection of the auditory nerve, or of the labyrinth, or of some structure in its immediate neighborhood.

CASE III.—Male, ætat. 45, in fair general health, March 22, 1876. Eighteen months ago he became paralyzed on the left side of the body, and also discovered that his hearing in the left ear was not as acute as usual. Already six months prior to this he had noticed that he sometimes saw double. Five months ago he quite suddenly—in the course of a few minutes, he says—lost the hearing in his right ear. This was associated with more or less dizziness, which has steadily increased from that time to this. He admits having had syphilis at the age of thirty-five. On examination, both drum-membranes are found to be in a nearly normal condition.

He was given iodide of potassium in slowly increasing doses, but he ceased to visit the Infirmary before any appreciable improvement had yet taken place, or could reasonably have been looked for.

Under the title of *anomalies of hearing* may be grouped a series of comparatively rare phenomena which are usually considered as being dependent on lesions confined to the cochlear structures. In this category are included the conditions known as diplacusis monauricularis and binauricularis,<sup>1</sup> and that known under the designation of limited range of audition. No instances of the latter anomaly have as yet come under my observation; of the former, however, I have seen three cases. In the first of these, the patient, an intimate personal friend, contracted a severe "cold in the head," and soon afterward a subacute catarrh developed in the right middle ear. When notes of a rather low pitch were sounded, he heard them as well-defined simple musical tones. When, however, the highest tones and even those of a moderately high pitch were sounded, the patient heard, besides the fundamental tone, a second and less distinct one. His ear not being sufficiently cultivated, he was unable to state what was the interval between

---

<sup>1</sup> Dr. Knapp, of this city, was, I believe, the first to describe and give a name to this peculiar anomaly (Arch. of Oph. and Otol., Vol. II.).

these two tones. Furthermore, while suffering in this way he attended a public concert, but, instead of deriving pleasure from the music, he experienced positive discomfort by reason of the great confusion of sounds which it produced in his ear. He discovered, however, that when he kept the right ear closed, the confusion entirely disappeared, and the musical tones which reached his ear appeared to be distinct and harmonious. In the course of a few weeks these unpleasant symptoms entirely disappeared.

In this case, the term *diplocusis monauricularis* (or double hearing in one and the same ear) would be the appropriate expression to use in designating the pathological condition. In a second case, the patient, who was also suffering at the time from a naso-pharyngeal (and, in all probability, tympanic) catarrh, experienced still a different form of annoyance. "When I whistled," I quote very nearly his own words as written down at the time in my note-book—"I heard in one ear the corresponding (or correct) note, but in the other ear I heard a tone which harmonized with the first note; the exact relation of which, however, to the note whistled I am not musical enough to state. If I closed the ear that was out of tune I heard only one note, and not a chord." As the patient was giving me an account of something that had happened before I saw him, I was unable to gather more accurate information with regard to several points which suggest themselves when we read the above statement. In classifying this case, we might very properly designate it by the term *diplocusis binauricularis*, the phenomenon of double hearing requiring, in this case, both ears for its production.

In a third case, the patient, a maiden lady about fifty years of age, consulted me on the 25th of June, 1873, for a slowly increasing deafness, which on examination I found to be due to a chronic catarrhal inflammation of both middle ears. When I placed the vibrating tuning-fork (C) upon the central portion of the forehead, she said that she heard it differently in the two ears, that is, lower in the left than in the right. As she knew very little about music, she could not tell what the interval was between the two notes. She was positive, however, that it was less than an octave. She also said that the two notes harmonized. I then held the vibrating fork first in front of one ear and then in front of the other, and she still insisted that the pitch of the tone heard on one side was lower than that heard on the other.

I greatly regret that I allowed these cases (or at least the first and the last ones) to pass out of my hands without first subjecting them to a more thorough examination with regard to the behavior of the ears when tested with tones of different pitch. Since 1873 I have not had a single opportunity of making good these deficiencies. But even these three imperfectly observed cases offer data that possess a certain degree of value. Thus (in the first place), it will be noticed that in all of them there was disease of the mucous membrane of the middle ear. In the second place, in the first two cases (and, possibly, for aught I know also in the third) the phe-

nomenon of double hearing disappeared entirely when the catarrh subsided. In the third place, there was nothing sudden in the character of the attack, nor was there any nausea or giddiness. Finally, in the second case I would call attention to the patient's statement that when he closed the ear that was out of tune, the symptom of double hearing ceased. Cases of diplacusis are considered as *par excellence* cases of disease of the cochlea. It is assumed that those particular fibres or sets of fibres in the organ of Corti, which normally should vibrate in sympathy with a different tone from that sounded, become so altered in their tension or in their loading that they too respond to the tone in question, and so send a wrong communication to the brain. If such be the true state of things in these cases of diplacusis, why should the closing of the affected ear—which implies the nearly total exclusion of those sound impulses that would naturally reach the labyrinth by way of the membrana tympani and chain of ossicles, put a stop to the phenomenon of double hearing? The vibrations of the air in the patient's mouth, as he continued to whistle, must, under these circumstances, have been transmitted to the cochlea of the affected (or mis-tuned) ear through the intervening bony structures, without the aid of the mechanism of the middle ear, and, finding there a healthy organ of Corti, these vibrations then produced effects which caused correct impressions to be transmitted to the brain. If this phenomenon can be verified in other similar cases, it will go far toward demonstrating the possibility that the mechanism of the middle ear may be so mis-tuned as to allow certain harmonics of the note sounded to exert a preponderating influence upon its mode of vibration, and thus to excite unduly the corresponding portions of Corti's organ.<sup>1</sup>

I bring forward these points, not because I wish my readers to adopt these views, but simply because I wish to impress upon them the necessity of waiting for further proofs before they unhesitatingly adopt any view. I am myself utterly in the dark with regard to all this category of assumed labyrinthine diseases, and I think we should endeavor to collect, with minds unprejudiced in favor of any particular view, further *facts*. In this way,

---

<sup>1</sup> Patients suffering from catarrhal inflammation of the middle ear sometimes complain of a symptom which might perhaps be described as a diplacusis monauricularis. While singing, or when standing near to an individual who is singing, such patients experience at times an unpleasant jarring sound in one ear. During a part of one winter, several years ago, I suffered from this symptom to such a degree that it was very unpleasant for me to take part in chorus-singing. It was only when the higher notes were sounded that this symptom manifested itself. The sensation then produced was as if sympathetic vibration had been excited either in the chain of ossicles or in some other part of the middle or external ear. The high tone thus generated could be felt as well as heard, and the sensation produced was partly that of a musical tone and partly that of a jarring. I was not able to define the relationship of this unpleasant tone to that which called it into existence. My recollection is, however, that it was much higher than the latter.

and in this way only, shall we be able to reach conclusions that will bear the test of time.

In a few cases I have observed the condition usually designated as *hyperæsthesia acustica*. The individuals so affected were invariably of a nervous temperament, and I have always looked upon the symptom rather as an evidence of an overstrained nervous system, than as a manifestation of any disturbance of a peculiarly aural type.

The condition known as *boiler-makers' deafness* is usually classed among the labyrinthine affections. It is not known what are the precise lesions upon which the deafness depends, but it is supposed that the violent concussions, to which the cochlear structures are almost incessantly subjected, cause such a relaxation of these parts that they lose the power of responding to the more delicate vibrations of the sounds produced in ordinary conversation. In the course of time, it is probable that a certain degree of thickening and rigidity takes place in consequence of the frequently repeated mechanical violence done to the parts. In the few cases which I have had an opportunity of examining, the drum-membrane invariably appeared to be much thicker and tougher than is natural, and from this circumstance I have sometimes thought that boiler-makers, perhaps, owed their deafness in part to the great changes in temperature to which they are exposed. It is more likely, however, that the thickening referred to is dependent upon the prolonged irritation caused by the concussions of the air.

I should perhaps refer in brief terms to the diagnosis, prognosis, and treatment of the class of cases referred to in the present chapter.

If, in the course of scarlet fever, measles, typhoid fever, or cerebro-spinal meningitis, a sudden loss of the hearing-power takes place, we may at once suspect that the lesions are either intracranial or labyrinthine. If, on examination, we fail to find any adequate cause for the deafness in the condition of the external or middle ear, we may feel as positive, with regard to the correctness of our diagnosis, as it is possible to be in the present state of otological knowledge. If the deafness is confined to one ear, the tuning-fork will be found of great value in corroborating our suspicions. It is not an indifferent matter what sort of a tuning-fork we use for this purpose. If the instrument be too small and of too high a pitch, we shall find it utterly unfit for use. No matter how quick our movements may be, we shall barely have time to plant the vibrating fork on the patient's forehead before its vibrations will have become so feeble that to the patient they will be inaudible. In all the instrument-makers' shops it is now an easy matter to purchase forks of low pitch and so constructed that they maintain sufficiently vigorous vibrations for a period of several seconds—that is, long enough for the surgeon to deliberately place the vibrating fork on the pa-

tient's head, and for the patient then to quietly observe in which ear he hears the sound best. In the class of cases which we are now considering, the sound of the vibrating fork, placed on the bridge of the nose or in the median line of the forehead, will be heard best or exclusively in the unaffected ear ; while if the affection be due to some disturbance in the middle ear (the drum-membrane still being entire), the sound will probably be heard best in the affected ear. In children the test is of doubtful value at best.

The mode of development of the deafness (as, for example, in the cases of Ménière's disease) will also aid us greatly in arriving at a correct diagnosis. In every doubtful case it behooves us to remember the possibility of a syphilitic origin. No harm can come from the assumption, in any given case, that the disease is of syphilitic origin ; but the failure to recognize such a cause may under certain circumstances deprive the patient of a cure which is perhaps within reach.

The *prognosis*, in all the different cases of this class, is bad ; and yet now and then recoveries are observed. I can recall a single case of total deafness in one ear, following an attack of scarlet fever, in which the hearing, after the lapse of about two weeks, gradually returned to a fair degree of acuteness. The case of syphilitic deafness treated by Dr. Roosa (p. 399) affords a good illustration of what may sometimes be accomplished in this form of the disease. In "Ménière's disease" the prognosis is decidedly bad. In those cases in which the hearing is only partially lost, a certain degree of improvement may afterward take place ; in the great majority of cases, however, the damage is permanent. The deafness produced by cerebro-spinal meningitis may be considered as the most hopeless of all the known forms of sudden or rapid loss of hearing.

So far as the *treatment* is concerned, I have very little experience of my own to offer. The iodide of potassium afforded some relief in one or two cases ; in another, the course of treatment recommended by Dr. Brown-Séguard (see p. 396) ameliorated the patient's condition in other respects, but failed to improve the hearing ; finally, in a third, a vigorous antisymphilitic treatment so far restored the patient's hearing that he was able to hear ordinary conversation fairly well. I have not sufficient faith in the efficacy of electricity or galvanism, in cases of this kind, to justify me in urging a patient to make a trial of them.



# INDEX.

- ABSOLUTE alcohol, in the treatment of granulation-growths, 256
- Acetum cantharidis, in the treatment of eczema, 39
- Acid nitrate of mercury, employment of as a caustic, 256
- Acoumeter, Politzer's, 19
- Adenoid vegetations, naso-pharyngeal, 171
- Adhesions in the middle ear, 274
- Aërial distention of the middle ear, 155
- Air-cells of the mastoid process, variations in the size of, 297
- Alcohol, absolute, in the treatment of granulation-growths, 256
- Alum, burned, employment of, in the treatment of granulation-growths, 257  
powdered, in the treatment of naso-pharyngeal catarrh, 169  
solutions, introduction of into the middle ear dangerous, 337
- Ampullæ of membranous semicircular canals, 8
- Aneurism of posterior auricular artery, 365  
of the middle ear, 380
- Angioma cavernosum of auricle, 54
- Angular forceps, 28
- Annulus tympanicus, 25
- Anomalies of hearing, 400
- Antrum (mastoid), acute inflammation of, 304  
caries of, 315  
chronic subacute purulent inflammation of, 301  
relations of, to external auditory canal, 363  
relations of, to facial canal, 361
- Anvil, anatomical relations of, 3
- Arsenite of potassa, in the treatment of eczema, 37
- Artificial drum-membrane of Toynbee, 277
- Aspergillus, growth of, in auditory canal, 79
- Astringents, employment of in the treatment of granulation-growths, 257
- Atrophied drum-membrane, slight regenerative power of, 144
- Audition, limited range of, 400
- Auditory canal, cysts of, 123  
desquamative inflammation of, 86  
diffuse inflammation of, 74  
diseases of, 57  
eczema of, 74  
false membranes in, 93  
foreign bodies in, 109  
furuncles of, 65  
horizontal surface motion in, 57  
in the infant, 25  
new-growths in, 114  
relations of to neighboring organs, 1  
syphilitic ulcers and condylomata of, 104  
ulcers of, 92, 249  
wounds of, 113
- Auditory nerve, syphilitic disease of, 398
- Auricle, angioma cavernosum of, 54  
cirroid aneurism of, 54  
cleft lobule of, 54  
congenital malformations of, 55  
contusions of, 54  
cornu humanum of, 52  
diseases of, 35  
eczema of, 35  
epithelioma of, 51  
fibroid tumors of, 51

- Auricle, herpes zoster of, 53  
inflammation of, 39  
perichondritis of, 40  
syphilitic disease of, 53  
ulcers of, 45
- BENZOATED oxide of zinc ointment, in the treatment of eczema, 39
- Blake's middle-ear syringe, 191  
snare, 253
- Bleeding from the ear, significance of, in cases of supposed fracture of the temporal bone, 289
- Bloodletting by leeches, value of, in acute inflammation of the middle ear, 216
- Body-temperature, in mastoid affections, 362
- Boettcher, Arthur, on the function of the semicircular canals, 392  
experiments with regard to the function of the semicircular canals, 15
- Boiler-maker's deafness, 403
- Bone-drills for establishing an opening in the mastoid process, 368
- Bone-caries in the external auditory canal, 95
- Boracic acid, employment of, in cases of otitis media purulenta, 224
- Bright spot of the membrana tympani, 126
- Bulb-syringe, 33
- Bullet, removal of, from ear, 285
- Burnett, onaspergillus in external auditory canal, 81  
on horizontal motion in the external auditory canal, 103
- CADE, oil of, in the treatment of eczema, 38
- Caerumen, impacted, 57
- Calcareous deposits in the drum-membrane, 270
- Calcareous mass in the auditory canal, 93
- Canalis reuniens, 8, 13
- Cancer of external auditory canal, 118
- Caries, primary, of the external auditory canal, 97
- Carious processes in the middle ear, 259
- Carotid artery, ulceration of, and fatal hemorrhage, 269
- Catarrh, definition of the term, 142
- Catarrhal inflammation of the middle ear, 153
- Caustics, employment of, in cases of poly-poid growths, 254
- Cerebro-spinal meningitis, a frequent cause of labyrinthine disease, 389
- Cheesy inflammation of the middle ear, 244
- Chondromalacosis of the auricle, 40
- Chorda tympani nerve, affections of, 269, 387
- Chromic acid, employment of as a caustic, 256
- Chronic subacute catarrh, 193
- Cicatrices of the drum-membranes, 271
- Cicatricial drum-membranes, rupture of, 132
- Cirsoid aneurism of auricle, 54
- Clark's douche, 215
- Cleft lobule of auricle, 54
- Cochlear whorl, transverse section of, 10
- Columella, in the ear of the sea-turtle, 3
- Condylomata of external auditory canal, 104
- Contrecoup, fractures by, 279
- Contusions of auricle, 54
- Copper, sulphate of, as a caustic, 256
- Cord-like bridge of flesh in the auditory canal, 99
- Cornu humanum of auricle, 52
- Corti's membrane, 10
- Corti's organ, definition of the term, 14  
mechanism of, 12
- Cotton-holders, 29, 166  
value of, in cleaning the auditory canal, 232
- Curettes, 30
- Cupola of cochlea, 12
- Cuticular membrane in the external auditory canal, 104
- Cyst-like tumors of the drum-membrane, 269
- Cysts of the auditory canal, 123
- DEFORMITY of drum-membrane, 372
- Deformities caused by purulent inflammation of the middle ear, 270
- Desquamative inflammation of the external auditory canal, 86
- Desquamative processes in the middle ear, 265


- Diachylon ointment, Hebra's, in the treatment of eczema, 38
- Diet in eczema, 36
- Diplacsis, monauricularis and binauricularis, 400
- Diploëtic spaces of the mastoid process, 296
- Drills, for perforating the mastoid process, 368
- Double-curved Eustachian catheters, 139
- Double hearing, 400
- Double perforations in the drum-membrane, 228, 275
- Douche, aural, 33
- Douche, nasal, its use a cause of acute inflammation of the middle ear, 152
- Drum-membrane, atrophy of, 370  
 cicatrices of, 271  
 cyst-like tumors of, 269  
 deformity of, 372  
 double perforations in, 228, 275  
 paracentesis of, 181  
 reproduction of, 273  
 rupture of, 373
- Dry cups, in the treatment of acute inflammation of the middle ear, 216
- Ductus cochlearis, 8
- EAR** disease and life insurance, 236
- Ear-douche, simple pattern of, 34
- Ear-nozzle, pronged variety, 33
- Ear-specula, 20
- Eczema of the auditory canal, 74  
 of the auricle, 35
- Electricity, in the treatment of diseases of the labyrinth, 404
- Epithelial masses, laminated, in the middle ear, 265
- Epithelioma of auricle, 51
- Erysipelas, facial, following Wilde's incision, 330
- Eustachian bougies, medicated, 176
- Eustachian catheters, 134  
 mode of introducing them, 136
- Eustachian tube, closure of, 144  
 function of, 1  
 narrowing of, 143  
 simple catarrh of, 142  
 spasmodic contractions of muscles of, 147  
 unnatural patency of, 145
- Examination of the ear, rules for, 26
- Exostoses of the external auditory canal, 115
- External auditory canal, relations of, to neighboring organs, 1
- FACIAL** canal, relations of, to antrum, 361
- Facial paresis or paralysis, in mastoid affections, 361
- False membranes in the auditory canal, 98  
 in the middle ear, 274
- Faucial catheter, 139
- Fenestra rotunda, 6
- Fibrinous exudation in acute inflammation of the middle ear, 205
- Fibroid tumors of auricle, 51
- Forceps, angular, 28  
 Hinton's, 253  
 Politzer's, 29
- Forehead-mirror, for aural examinations, 22, 34  
 mode of employing it, 34
- Foreign bodies in the external auditory canal, 109  
 in the middle ear, 258
- Fowler's solution in the treatment of eczema, 37
- Fractures of the temporal bone, 278
- Furuncles of the auditory canal, 65  
 of the auricle, 39
- GALVANISM**, in the treatment of diseases of the labyrinth, 404
- Galvano-cautery, employment of, for removal of polypoid growths, 258
- Giampetro-Löwenberg method of introducing the Eustachian catheter, 138
- Granulation-tissue, formation of, in middle ear, 246
- Green, J. Orne, on exudations of fibrin into the middle ear, 205
- Gruber's specula, 21
- Gummata of auricle, 53
- Gunshot wounds of the ear, 285
- HÆMATOMA** auris, 40
- Hammer, absence of, 372  
 anatomical relations of, 3
- Hand-mirror, for aural examinations, 22
- Handle of hammer, hook-shaped, 373

- Hearing, anomalies of, 400  
 physiology of, 1
- Hearing-cells, inner and outer, 10
- Heat, moist or dry, in the treatment of furuncles of the auditory canal, 72
- Hebra's diachylon ointment in the treatment of eczema, 38
- Helicotrema, 12
- Helmholtz theory of hearing, 12
- Hemorrhage, in removal of polypi, 255
- Hemorrhagic exudation into the middle ear, 164
- Herpes zoster of auricle, 53
- Hewett, Prescott, on fractures of the base of the skull, 289
- Horizontal motion in the external auditory canal, 103
- Hinton's polypus-forceps, 253
- Hook-shaped handle of hammer, 373
- Horny growth of the membrana tympani, 371
- Hot douche, value of, in acute inflammation of the middle ear, 215
- Howe, on deformed auricle, 48
- Hun, on othæmatoma of the insane, 41
- Hyperæsthesia acustica, 403
- Hyperostosis of the bony wall of the tympanum, 374  
 of the external auditory canal, 114
- ICE, employment of, in the treatment of acute inflammation of the middle ear, 216
- Incisions, in furuncles of the external auditory canal, 69
- Inflations of the middle ear, therapeutic action of, 178
- Intermittent deafness, 390
- Intratympanic medication, 188, 220  
 vascular growths, 375
- Iodine, tincture of, application to the mastoid integuments, 181  
 in the treatment of naso-pharyngeal catarrh, 169
- Iodoform, employment of, in the treatment of granulation-growths, 257
- KIPP, on angioma cavernosum of auricle, 54  
 on spurious othæmatoma, 44
- Knapp, Herman, on malignant tumors of the middle ear, 382
- LABYRINTH, anatomical relations of, 7
- Labyrinth, diseases of, 388
- Lamina reticularis, 10
- Lamina spiralis ossea, 10
- Laminated epithelial masses in the middle ear, 265
- Larvæ of the house-fly in the auditory canal, 110, 249
- Lateral sinus, phlebitis of, 295
- Leeches, employment of, in furuncles of the auditory canal, 73  
 in mastoid affections, 364
- Life insurance and ear disease, 236
- Ligamentum spirale, 10
- Light, sources of, for aural examinations, 25
- MALFORMATIONS, congenital. of auricle, 55
- Malignant tumor of the middle ear, 382
- Malleo-incudal joint, 3
- Mastoid cells, caries of, 339  
 inflammation of, 328
- Mastoid process, anatomy of, 296  
 establishment of an opening in, 366  
 integuments of, tenderness, redness, and swelling of, 359  
 periostitis, 355
- Mathewson on exostoses of the external auditory canal, 118
- Mayer, experiments of, with relation to the transmission of composite sounds, 6
- Membrana basilaris, 8
- Membrana flaccida, 207
- Membrana tectoria, 10
- Membrana tympani, almost entire reproduction of, 248  
 atrophy of, 370  
 changes in position of, 126  
 relations of to hammer, 3
- Membrana tympani secundaria, 6
- Ménière's disease, 391, 404
- Meningitis, from acute inflammation of the mastoid antrum, 306
- Mercury, acid nitrate of, as a caustic, 256
- Metastatic abscesses, in mastoid affections, 361
- Meyer, on naso-pharyngeal adenoid vegetations, 171


- Middle ear, catarrhal inflammation of, 153  
 fluid exudation in, 127  
 methods of examining it, 125  
 new-growths in, 374  
 purulent inflammation of, 196  
 syphilitic disease of, 227
- Middle-ear pipettes, 188
- Mucus, accumulation of, in the tympanic cavity, 159, 336  
 removal of, from tympanum, 180
- Murmurs, systolic, subjective and objective, 386
- Myringotome, 182
- NARROWING** of the Eustachian tube, 143
- Nasal douche, employment of, may cause acute inflammation of the middle ear, 152
- Nasal passages, obstruction of, a cause of deafness, 155
- Naso-pharyngeal adenoid vegetations, 171  
 catarrh, treatment of, 166
- Necrosis of the temporal bone, 264
- New-growths in the external auditory canal, 114  
 in the middle ear, 374
- Nitrate of silver, in eczema of the auditory canal, 38, 83  
 pure, in the treatment of granulation-growths, 256  
 solutions, in otitis media purulenta, 222  
 solutions of, in treatment of naso-pharyngeal catarrh, 166
- Nitric acid, employment of, in cases of polypoid growths, 256
- Nose-piece of Politzer's apparatus, 131, 134
- Noyes, on double-curved Eustachian catheters, 139
- OCULAR** symptoms, in mastoid affections, 363
- Oil of Cade, in the treatment of eczema, 38
- Ossicles, destruction of, 275
- Otalgia, 387
- Otomycosis, 74
- Othæmatoma, 40
- PAIN**, significance of, in mastoid diseases, 358
- Palato-tubal muscles, paresis of, 148
- Papillomata, syphilitic, of external auditory canal, 106
- Paracentesis of the drum-membrane, 181, 218
- Paresis or paralysis of the facial, in mastoid affections, 361
- Parotid abscess following typhoid fever, 93
- Patency, unnatural, of the Eustachian tube, 145
- Pearl-like thickenings of the drum-membrane, 271
- Perichondritis of the auricle, 40
- Periostitis, mastoid, 355
- Pillars of Corti, inner and outer, 10
- Pipettes for introducing fluids into the middle ear, 188, 222
- Pneumatic spaces of the mastoid process, 296
- Politzer's acoumeter, 19  
 forceps, 29  
 method of inflating the middle ear, 129
- Polypoid growths in auditory canal, 94  
 removal of, 252
- Polypus snare, Blake's, 253
- Pomeroy, on othæmatoma, 46  
 on impacted cerumen, 59  
 faucial catheter, 139
- Porte-acid, 255
- Posterior fold, acute inflammation of, 224
- Potassa solution, solvent action of, upon cerumen, 63
- Poultices, in treatment of mastoid affections, 364
- Putting character of perforations, 208
- Powdered remedies, in the treatment of otitis media purulenta, 223
- Probes, 30
- Prolapse of upper cutaneous wall of auditory canal, in mastoid affections, 363
- Proliferative form of otitis media purulenta chronica, 246
- Pronged hard-rubber ear-nozzle, 33
- Prout's method of recording the hearing-power, 19
- Psychical phenomena, in mastoid affections, 362
- Putzel, Dr. L., on injury to the fifth nerve, 295
- Pyæmic symptoms in mastoid affections, 362


- QUININE**, acute inflammation of middle ear caused by, 152
- REFLECTORS**, 22  
 use of, in aural examinations, 24
- Reissner's membrane, 10
- Reproduction of the drum-membrane, 248
- Roosa, on othæmatoma, 47  
 on the treatment of syphilitic affections of the ear, 399
- Rosenmüller's fossa, 138
- Ruptures of the drum-membrane, 373
- SACCULE**, 8
- Safety-tube of Eustachian canal, 1
- Sarcoma, primary, of the external auditory canal, 120
- Scala tympani, 8
- Scala vestibuli, 8
- Sclerosis of the mastoid process, 299  
 of the tympanic mucous membrane, 193
- Sea-turtle, auditory apparatus of, 2
- Semicircular canals, function of, 15, 392  
 transverse section of, 15
- Septicæmic symptoms in mastoid affections, 362
- Serous exudation into the middle ear, 159
- Shrapnell's membrane, 126, 207  
 perforations in, 226  
 inflammation of, in cases of supposed fracture of the temporal bone, 293
- Siegle's pneumatic speculum, 127
- Silver nitrate, in the treatment of eczema, 38  
 pure, in the treatment of granulation-growths, 256
- Snapping noises in the ear, 147
- Soda solution, solvent action of, upon cerumen, 63
- Spasmodic contractions of the muscles of the Eustachian tube, 147
- Specula, aural, 20  
 employment of, as dilators, 65  
 how they should be introduced, 24, 27
- Stapedio-vestibular articulation, 4
- Stirrup, anatomical relations of, 3  
 expulsion of, 376
- Sulphate of copper, as a caustic, 256
- Syphilitic disease of the middle ear, 227  
 of the labyrinth, 398
- Syringes, 31
- Syringing, for the removal of impacted cerumen, 64
- Systolic murmurs, subjective and objective, 386
- TEMPERATURE** of the body in mastoid affections, 362
- Temporal bone, fractures of, 278
- Temporo-maxillary joint, arthritis of, 387
- Tenderness on pressure over the mastoid region, 359
- Tests of the hearing-power, 17
- Tonsils, enlarged, treatment of, 175
- Toynee's artificial drum-membrane, 277  
 specula, 21
- Tubercular cases of otitis media purulenta, 244
- Tympanic cysts, 269
- ULCERATION** of the cutaneous walls of the external auditory canal, 249
- Ulcers of auditory canal, 92  
 of the auricle, 45  
 syphilitic, of external auditory canal, 104
- Utricle, 8
- VALSALVA'S** method of inflating the middle ear, 128
- Vascular growths of the membrana tympani, 372  
 in the middle ear, 375
- Vaseline, in the treatment of eczema, 39
- Vegetations, syphilitic, of the external auditory canal, 106
- Vestibule, or central cavity of the labyrinth, 7
- Voltolini, on primary acute inflammation of the labyrinth, 391
- Von Troeltsch's specula, 21
- WARTS**, syphilitic, of external auditory canal, 107

- Washing out the middle ear, 190  
Watch, ticking of, as a test, 17  
Watery discharge from the ear, significance of, in cases of supposed fracture of the temporal bone, 293  
Weir, Robert F., on intratympanic vascular growths, 375  
Wilde's incision, 365  
    specula, 21  
Words, whispered or spoken, as tests of the hearing, 117  
Wounds of the auditory canal, 113  
ZAUFAL'S nasal specula, 139  
Zinc ointment, in the treatment of eczema, 39  
Zuckerkanrl, on anatomy of the mastoid process, 296











LIBRARY OF CONGRESS



0 029 827 915 0

WOOD'S LIBRARY



of STANDARD MEDICAL AUTHORS