


---

**U.S. ARMY MEDICAL DEPARTMENT CENTER AND SCHOOL  
FORT SAM HOUSTON, TEXAS 78234-6100**

---



# **THE SENSORY SYSTEM**

**SUBCOURSE MD0582    EDITION 100**

## **DEVELOPMENT**

This subcourse is approved for resident and correspondence course instruction. It reflects the current thought of the Academy of Health Sciences and conforms to printed Department of the Army doctrine as closely as currently possible. Development and progress render such doctrine continuously subject to change.

## **ADMINISTRATION**

Students who desire credit hours for this correspondence subcourse must enroll in the subcourse. Application for enrollment should be made at the Internet website: <http://www.atrrs.army.mil>. You can access the course catalog in the upper right corner. Enter School Code 555 for medical correspondence courses. Copy down the course number and title. To apply for enrollment, return to the main ATRRS screen and scroll down the right side for ATRRS Channels. Click on SELF DEVELOPMENT to open the application; then follow the on-screen instructions.

For comments or questions regarding enrollment, student records, or examination shipments, contact the Nonresident Instruction Branch at DSN 471-5877, commercial (210) 221-5877, toll-free 1-800-344-2380; fax: 210-221-4012 or DSN 471-4012, e-mail [accp@amedd.army.mil](mailto:accp@amedd.army.mil), or write to:

NONRESIDENT INSTRUCTION BRANCH  
AMEDDC&S  
ATTN: MCCS-HSN  
2105 11TH STREET SUITE 4191  
FORT SAM HOUSTON TX 78234-5064

Be sure your social security number is on all correspondence sent to the Academy of Health Sciences.

## **CLARIFICATION OF TERMINOLOGY**

When used in this publication, words such as "he," "him," "his," and "men" are intended to include both the masculine and feminine genders, unless specifically stated otherwise or when obvious in context.

## **USE OF PROPRIETARY NAMES**

The initial letters of the names of some products may be capitalized in this subcourse. Such names are proprietary names, that is, brand names or trademarks. Proprietary names have been used in this subcourse only to make it a more effective learning aid. The use of any name, proprietary or otherwise, should not be interpreted as endorsement, deprecation, or criticism of a product; nor should such use be considered to interpret the validity of proprietary rights in a name, whether it is registered or not.

## TABLE OF CONTENTS

<u>Lesson</u>	<u>Paragraphs</u>
INTRODUCTION	
1	ANATOMY AND PHYSIOLOGY OF THE SENSORY SYSTEM
	Section I. General .....1-1--1-2
	Section II. The Special Sense of Vision (Sight).....1-3--1-5
	Section III. The Special Sense of Hearing (Auditory) .....1-6--1-8
	Section IV. The Special Sense of Smell (Olfaction).....1-9--1-11
	Section V. The Special Sense of Taste (Gustation) .....1-12--1-15
	Exercises
2	PHYSICAL ASSESSMENT OF THE SENSORY SYSTEM (HEENT) .....2-1--2-10
	Exercises
3	EENT DISEASES AND DISORDERS
	Section I. Ocular Diseases and Disorders.....3-1--3-14
	Section II. Conditions of the Ear.....3-15--3-22
	Section III. Nasal Conditions/Throat Conditions.....3-23--3-30
	Exercises
4	HEENT TRAUMA
	Section I. Head Injuries .....4-1--4-2
	Section II. Eye Injuries .....4-3--4-7
	Section III. Ear Injuries/Disorders.....4-8--4-13
	Section IV. Nose Injuries .....4-14--4-16
	Section V. Throat Injuries .....4-17--4-19
	Exercises

**CORRESPONDENCE COURSE OF  
THE U.S. ARMY MEDICAL DEPARTMENT CENTER AND SCHOOL**

**SUBCOURSE MD0582**

**THE SENSORY SYSTEM**

**INTRODUCTION**

The sensory system by which we see, smell, taste, and hear is often taken for granted until we lose one or more of these senses. From the time we are born, our senses shape our view of the world and transmit those impulses to the brain which trigger an adaptive response. The importance of becoming familiar with the sensory structures is fundamental to the Medical NCO due to the structures' innate sensitivity and key role in daily life.

**Subcourse Components:**

The subcourse instructional material consists of four lessons as follows:

Lesson 1, Anatomy and Physiology of the Sensory System.

Lesson 2, Physical Assessment of the Sensory System.

Lesson 3, EENT Diseases and Disorders.

Lesson 4, HEENT Trauma.

Here are some suggestions that may be helpful to you in completing this subcourse:

--Read and study each lesson carefully.

--Complete the subcourse lesson by lesson. After completing each lesson, work the exercises at the end of the lesson, marking your answers in this booklet.

--After completing each set of lesson exercises, compare your answers with those on the solution sheet that follows the exercises. If you have answered an exercise incorrectly, check the reference cited after the answer on the solution sheet to determine why your response was not the correct one.

**Credit Awarded:**

Upon successful completion of the examination for this subcourse, you will be awarded 10 credit hours.

To receive credit hours, you must be officially enrolled and complete an examination furnished by the Nonresident Instruction Branch at Fort Sam Houston, Texas.

You can enroll by going to the web site <http://atrrs.army.mil> and enrolling under "Self Development" (School Code 555).

A listing of correspondence courses and subcourses available through the Nonresident Instruction Section is found in Chapter 4 of DA Pamphlet 350-59, Army Correspondence Course Program Catalog. The DA PAM is available at the following website: <http://www.usapa.army.mil/pdffiles/p350-59.pdf>.

## **LESSON ASSIGNMENT**

### **LESSON 1**

Anatomy and Physiology of the Sensory System.

### **LESSON ASSIGNMENT**

Paragraphs 1-1 through 1-15.

### **LESSON OBJECTIVES**

After completing this lesson, you should be able to:

- 1-1. Identify the sensory receptors in terms of their location.
- 1-2. Identify the major structures of the eye and their corresponding functions.
- 1-3. Identify the major structures of the ear and their corresponding functions.
- 1-4. Identify the structures related to the sense of smell.
- 1-5. Identify the structures related to the sense of taste and their functions.

### **SUGGESTION**

After completing the assignment, complete the exercises of this lesson. These exercises will help you to achieve the lesson objectives.

## LESSON 1

### ANATOMY AND PHYSIOLOGY OF THE SENSORY SYSTEM

#### Section I. GENERAL

##### 1-1. INTRODUCTION

The ability to sense stimuli is vital to man's survival. If pain could not be sensed, burns would be common. Internal problems such as an inflamed appendix or a stomach ulcer could be unnoticed without pain. Without sight there is a greater risk of injury from obstacles. Harmful gas could be inhaled if there were no sense of smell. Loss of a sense of hearing would keep us from recognizing hazards such as automobile horns. And if there were no taste, toxic substances could be ingested. If we could not "sense" our environment and make the necessary adjustments, we probably could not survive on our own.

**NOTE:** In this subcourse, you will see the letters EENT and HEENT. EENT stands for eyes, ears, nose, and throat. HEENT stands for head, eyes, ears, nose, and throat.

##### 1-2. THE SENSORY PATHWAYS

a. **Sensations.** The body is continuously bombarded by types of information called stimuli (stimulus, singular). Those few stimuli which are consciously perceived (in the cerebral hemispheres) are called sensations. Structures that detect changes in man's external and internal environment produce sensations on the senses.

b. **Senses and Receptions.** The senses and the location of their receptors are as follows:

- (1) Vision--receptors in the eyes.
- (2) Smell--receptors in the nose.
- (3) Hearing--receptors in the ears.
- (4) Taste--receptors in the tongue.
- (5) Touch, heat, cold, pain --receptors in the skin.
- (6) Position--receptors in the muscles, joints, inner ear.
- (7) Hunger, thirst--receptors in the tongue, pharynx, mouth.

c. **Two Types of Senses.** They are differentiated by the type of sensation they cause. Special senses are produced by receptors limited to small areas such as the tongue, nose, balance, hearing, vision, smell, and taste. General senses are produced by receptors scattered throughout the body such as pressure, temperature, pain, position, and touch.

d. **Sensation and Perception.** In its broadest meaning, sensation refers to man's state of being aware of external or internal conditions of the body. The state of being aware of something through the senses is perception. Four conditions must take place for a sensation to occur.

(1) A stimulus--a change in the environment which causes a response by the nervous system.

(2) A receptor or sense organ-- picks up a stimulus and converts it to a nerve impulse.

(3) Conduction--the impulse must be conducted from the receptor or sense organ along a pathway to the brain.

(4) Translation--the impulse must be translated into a sensation when the impulse is in a region of the brain.

## Section II. THE SPECIAL SENSE OF VISION (SIGHT)

### 1-3. ANATOMY OF THE EYE

a. **Structure/Location.** The size of the adult eyeball is about 2.5 cm (1 inch) in diameter. The eyes are recessed in the bony cavities (the orbital cavities) of the skull with only the front one-sixth of the eyeball's total surface area exposed. Bones protect each eyeball: the frontal, maxillary, zygomatic, lacrimal, sphenoid, and palatine bones.

b. **Tunics (Layers) of the Eyeball.** The eyeball is composed of three layers called tunics: the fibrous tunic, the vascular tunic, and the retina or nervous tunic.

(1) Fibrous tunic. The fibrous tunic is the outer layer of the eye. This layer is formed by the sclera (the white of the eye) and the cornea (the window of the eye). The sclera is a white coat of fibrous tissue that covers the entire eyeball except the front colored portion. The sclera gives the eyeball shape and protects the inner parts of the eyeball. The cornea covers the iris, the colored part of the eye. The cornea is a transparent fibrous layer which has no blood vessels. An epithelial layer covers the outer surface of the cornea. At the point where the sclera and the cornea meet is a venous sinus called the Canal of Schlemm.



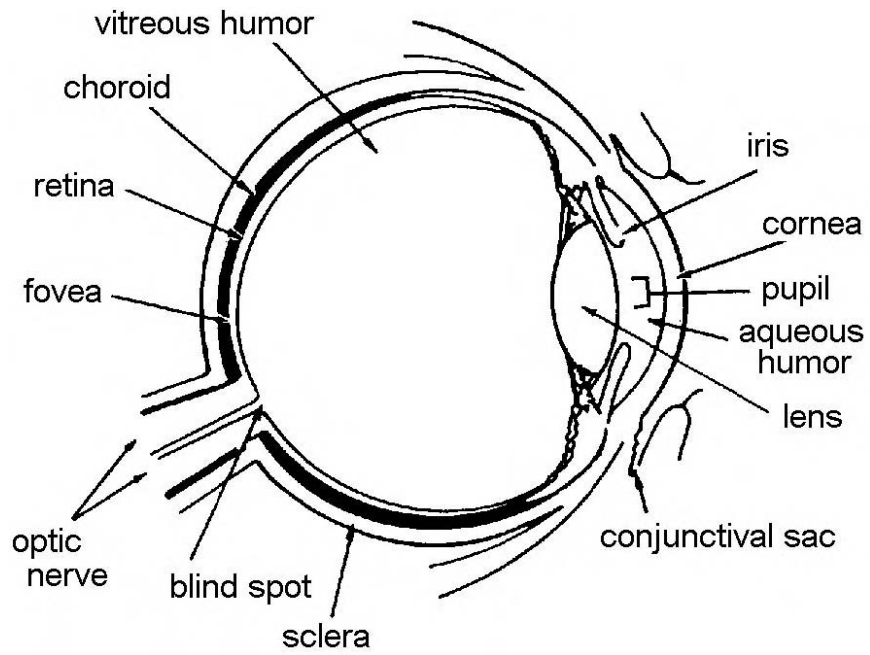


Figure 1-1. Anatomy of the eye.

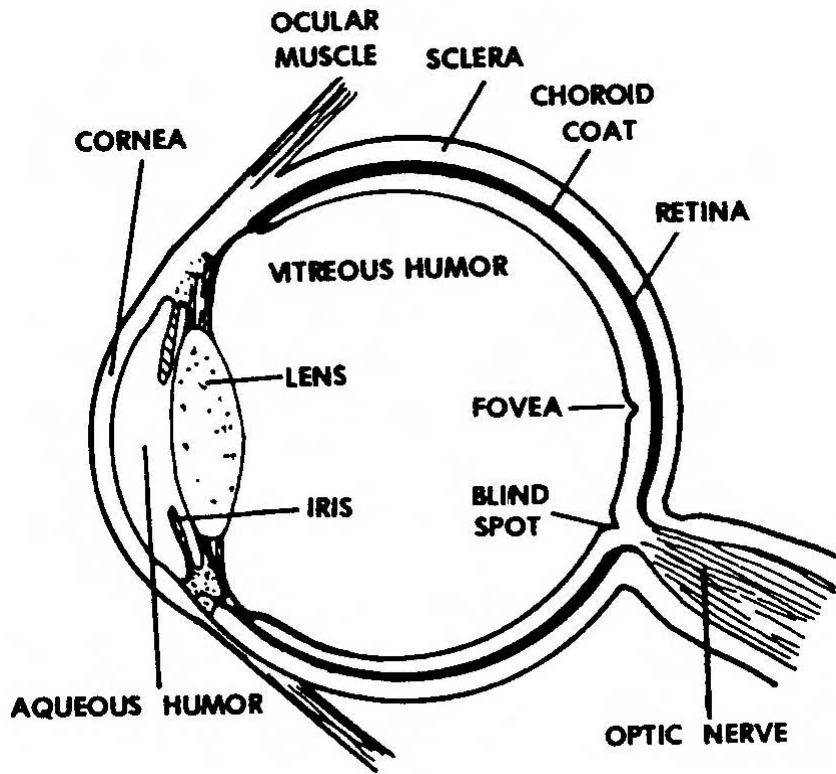


Figure 1-2. Cross section of the eye.

(2) Vascular tunic. This is the middle layer of the eye and is made up of the choroid, the ciliary body, and the iris. Altogether, these structures are called the uvea.

(a) Choroid. The choroid is the back part of the vascular tunic. It is a thin, dark brown membrane which lines most of the internal surface of the sclera. This membrane has many blood vessels and a large amount of pigment. The layer absorbs light rays so they are not reflected back out of the eyeball. The blood supply in this layer nourishes the retina. The choroid is pierced by the optic nerve at the back of the eyeball.

(b) Ciliary body. The front part of the vascular tunic, the ciliary body, is the thickest part of the vascular tunic. Ciliary processes and ciliary muscle make up this part of the layer. The ciliary processes are made up of folds of the internal surface of the ciliary body; these folds secrete aqueous humor (a clear, watery fluid in the front and back chambers of the eye). The ciliary muscle is a smooth muscle that changes the shape of the lens in order to see objects that are close or far away.

(c) Iris. The third part of the vascular tunic is the iris, a structure composed of circular and radial smooth muscle fibers arranged in a doughnut shape. The pupil is the black hole; light enters the eyeball through this hole.

(3) Retina (nervous tunic). The retina is the third and inner layer of the eye. It covers the choroid and consists of an inner nervous tissue layer and an outer pigmented layer. The pigmented part of the layer extends over the back of the ciliary body and the iris and is the nonvisual part of the retina. This layer also contains three zones of neurons which conduct impulses. These zones of neurons are called the photoreceptor neurons, the bipolar neurons, and the ganglion neurons. Photoreceptor neurons contain rods and cones, so named because of their shape. Rods, specialists in dim-light vision, allow us to distinguish between different shades of dark and light and let us see shapes and movement. Cones permit us to see color and are specialists in daylight vision. The optic disc is located in this area and is a blind spot with neither rods nor cones. It is here that the optic nerve leaves the eyeball.

c. **Blood Vessels**. The structures of the eye include blood vessels, layer vessels in the sclera, and capillaries in the retina.

d. **Cavities and Humor**. The anterior cavity of the eye is anterior to the lens. The anterior chamber is anterior to the iris and posterior to the cornea. The posterior chamber is posterior to the iris and anterior to the lens. The anterior cavity contains the aqueous humor secreted by the ciliary body. Too much aqueous humor results in glaucoma. The posterior cavity of the eye is posterior to the lens and suspensory ligaments and anterior to the retina. This cavity contains gelatinous substances called vitreous humor which maintain the globular shape of the eyeball.

e. **Muscles of the Eye.** The structure of the eye includes the muscles of the eye--intrinsic muscles and extrinsic muscles. Intrinsic muscles include the two involuntary muscles within the eye--the iris and the ciliary muscles. The iris regulates the amount of light which can enter the eye. The iris does this by dilating (opening more) and by constricting (opening less). The extrinsic muscles are composed of four rectus muscles (superior muscles, inferior muscles, medial muscles, and lateral muscles) and two oblique muscles (superior muscles, and inferior muscles). The extrinsic muscles move the eye within the orbit. The eye is the only organ with both voluntary and involuntary muscles.

#### 1-4. ACCESSORY STRUCTURES OF THE EYE

The site of accessory structures of the eye are as follows: eyebrows, eyelashes, eyelids, conjunctiva, and lacrimal apparatus.

a. **Eyebrows.** The eyebrows are made up of several rows of hair above the upper eyelids. The eyebrows form an arch at the junction of the upper eyelid and the forehead and structurally resemble the hairy scalp. The hairs are generally coarse and grow toward the side of the face.

b. **Eyelashes.** Eyelashes are a row of hairs which project from the border of each eyelid. Eyelashes coming from the upper eyelid are usually long and turn upward; eyelashes from the lower eyelid are generally short and turn downward. Sebaceous glands at the base of eyelash hair follicles pour a lubricating fluid into the follicles. When these glands become infected, a sty forms.

c. **Eyelids.** Each eyelid consists of epidermis, dermis, subcutaneous connective tissue, fibers of oculi muscle, a tarsal plate, tarsal glands, and a conjunctiva. The epidermis, dermis, and subcutaneous connective tissue make up the skin of the eyelid. The tarsal plate is a thick fold of connective tissue that forms part of the inner wall of each eyelid. The tarsal plate gives form and support to the eyelids. The conjunctiva is a mucous membrane which lines the inner aspect of the eyelids as well as the visible portion of the cornea (the glossy, transparent part of the cornea).

d. **Lacrimal Apparatus.** This is the term used for a group of structures that manufacture and drain away tears. Included are the lacrimal glands, the excretory lacrimal ducts, the lacrimal canals, the lacrimal sacs, and the nasolacrimal ducts.

(1) Lacrimal gland. A lacrimal gland is located in the upper outer corner of each orbit. The lacrimal glands secrete lacrimal fluid through small ducts into the space between the external surface of the eyeball and the upper eyelid.

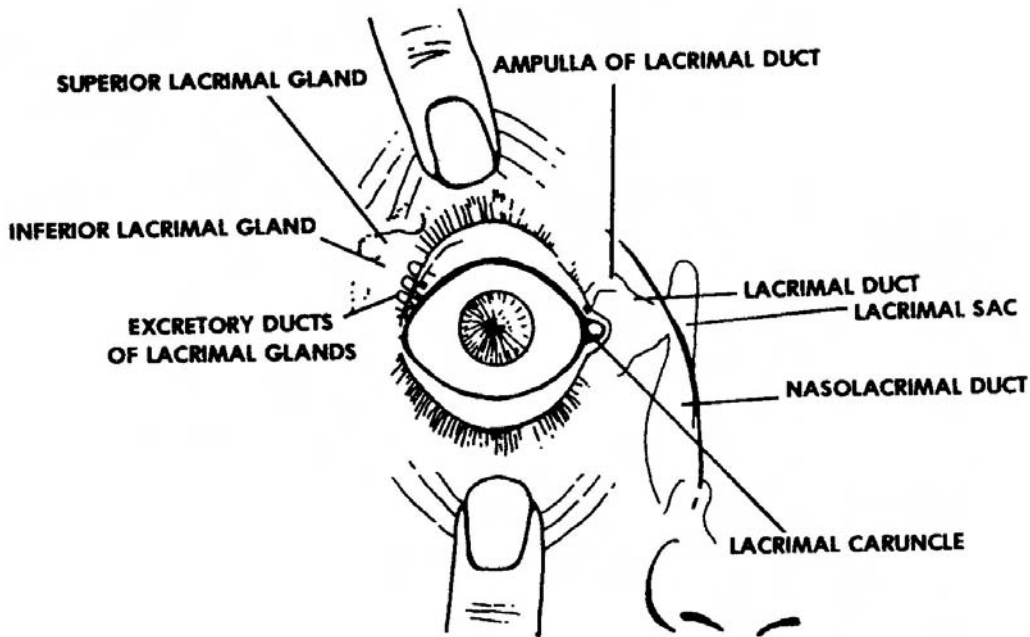


Figure 1-3. The lacrimal apparatus.

(2) Conjunctiva. The conjunctiva covers the inner surface of the eyelids and the outer surface of the eyeball. Lacrimal fluid keeps the conjunctiva transparent. With the blink reflex, the lacrimal fluid washes away any foreign particles that may be on the surface of the conjunctiva.

(3) Eyelid oil glands. The free margins of the upper and lower eyelids have special oil glands. The oily secretion of these glands helps prevent the lacrimal fluid from escaping.

(4) Lacrimal fluid. With the movement of the eyeball and the eyelids, the lacrimal fluid is gradually moved across the exterior surface of the eyeball to the medial inferior corner. Here, the lacrimal fluid is collected into a lacrimal sac, which drains into the nasal chamber by way of the nasolacrimal duct. Thus, the continuous production of lacrimal fluid is conserved by being recycled within the body.

## 1-5. PHYSIOLOGY OF VISION

For vision to occur, light must pass through the cornea, aqueous humor, pupil, lens, and vitreous humor before it (light) can reach the rods and cones. Light reaches the rods and cones of the retina and forms an image on the retina. Next, nerve impulses are conducted to the visual areas of the cerebral cortex (a part of the brain).

a. **Retinal Image Formation.** Four basic processes are involved in the formation of an image on the retina: refraction of light rays, accommodation of the lens, constriction of the pupil, and convergence of the eyes. Accommodation and pupil size are caused by intrinsic eye muscles (muscles inside the eyeball). Extrinsic eye muscles control convergence.

(1) Refraction of light rays. When light rays traveling through a transparent medium (such as air) and pass into a second transparent medium with a different density (such as water), they bend at the surface of the two media. This is refraction. The eye has four such media of refraction: cornea, aqueous humor, lens, and vitreous humor. Light rays entering the eye from the air are refracted at the following points:

(a) The anterior surface of the cornea as they pass from the lighter air into the denser cornea.

(b) The posterior surface of the cornea as they pass into the less dense aqueous humor.

(c) The anterior surface of the lens as they pass from the aqueous humor into the denser lens.

(d) The posterior surface of the lens as they pass from the lens into the less dense vitreous humor.

(2) Degree of refraction. The degree of refraction that takes place at each surface in the eye is very precise. Light rays from an object 20 feet away must bend to fall on the central field, where vision is the sharpest. Light rays from objects that are near are divergent rather than parallel. As a result, these light rays must be refracted toward each other to a greater extent. The lens of the eye makes this change.

(3) Accommodation of the lens. The lens of the eye is biconvex; that is, it curves outward on both sides. If the surface of a lens curves outward, as in a convex lens, the lens will refract incoming rays toward each other so they eventually intersect. The greater the curve, the more acutely it bends the rays toward each other. Conversely, when the surface of a lens curves inward, as in a concave lens, the rays bend away from each other. The lens of the eye has the unique ability to change the focusing power of the eye by becoming moderately curved at one moment and greatly curved the next. When the eye is focusing on a close object, the lens curves greatly in order to bend the rays toward the central fovea. This increase in the curvature of the lens is called accommodation. In near vision, muscles cause the lens to become shortened, thickened, and bulged. In far vision, muscles cause the lens to flatten.

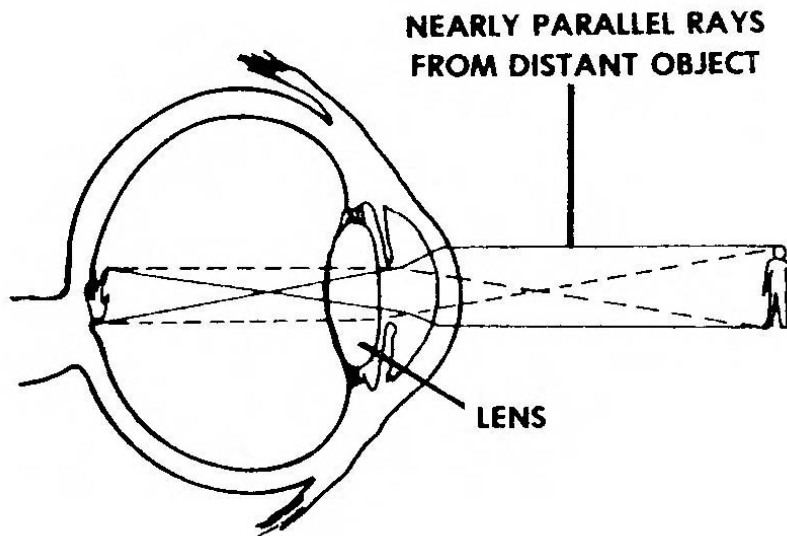


Figure 1-4. Accommodation for objects 20 feet or more away.

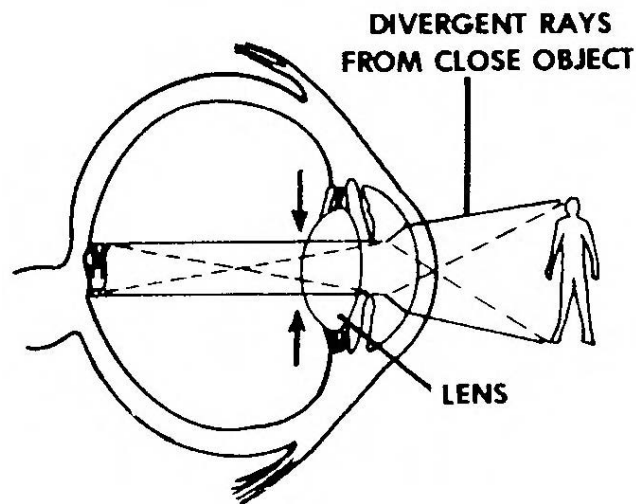


Figure 1-5. Accommodation for objects nearer than 20 feet.

(4) Constriction of the pupil. The circular muscle fibers of the iris also assume a function in the formation of clear retinal images. Part of the accommodation mechanism consists of the contraction of the dilator and sphincter muscles of the iris to constrict the pupil. Constriction of the pupil means narrowing the diameter of the hole through which light enters the eye. This action occurs simultaneously with accommodation of the lens and prevents light rays from entering the eye through the periphery of the lens. Light rays entering at the periphery would not be brought to focus on the retina and would result in blurred vision. The pupil, as noted earlier, also constricts in bright light to protect the retina from sudden or intense stimulation.

(5) Convergence. Some animals see a set of objects off to the left through one eye and an entirely different set off to the right through the other. This characteristic doubles their field of vision and allows them to detect predators behind them. In humans, both eyes focus on only one set of objects--a characteristic called single binocular vision. Single binocular vision occurs when light rays from an object are directed toward corresponding points on the two retinas. When we stare straight ahead at a distant object, the incoming light rays are aimed directly at both pupils and are refracted to identical spots on the retina of both eyes. But as we move closer to the object, our eyes must rotate medially for the light rays from the object to hit the same points on both retinas. The term convergence refers to this medial movement of the two eyeballs so they are both directed toward the object being viewed. The nearer the object, the greater the degree of convergence necessary to maintain single binocular vision. Convergence is brought about by the coordinated action of the extrinsic eye muscles.

### **Section III. THE SPECIAL SENSE OF HEARING (AUDITORY)**

#### **1-6. GENERAL**

The human ear serves two major special sensory functions-- hearing (auditory) and equilibrium (balance). Receptors for sound waves and receptors for equilibrium are located in the ear. The stimulus for hearing is sound waves, and the stimulus for equilibrium is gravitational force.

#### **1-7. ANATOMY**

The ear is divided into three principal regions: the external (outer) ear, the middle ear, and the internal (inner ear). See figure 1-6 which shows the anatomy of the ear.

a. **The External Ear.** The external ear begins on the outside of the head in the form of a funnel-shaped auricle (pinna). Actually serving as a funnel, the auricle directs airborne sound waves into the external auditory meatus. The external auditory meatus is a tubular canal extending into the temporal portion of the skull.

b. **The Middle Ear.** The middle ear is also called the tympanic cavity. It is a small epithelial-lined, air-filled cavity hollowed out of the temporal bone. The eardrum separates this cavity from the external ear. The cavity is separated from the internal ear by a thin bony partition that contains two small openings: the oval window and the round window.

(1) Tympanic membrane. At the inner end of the external auditory meatus is the tympanic membrane. The tympanic membrane (eardrum) is a circular membrane which separates the external auditory meatus from the middle ear cavity. The tympanic membrane vibrates (mechanically oscillates) in response to airborne sound waves.

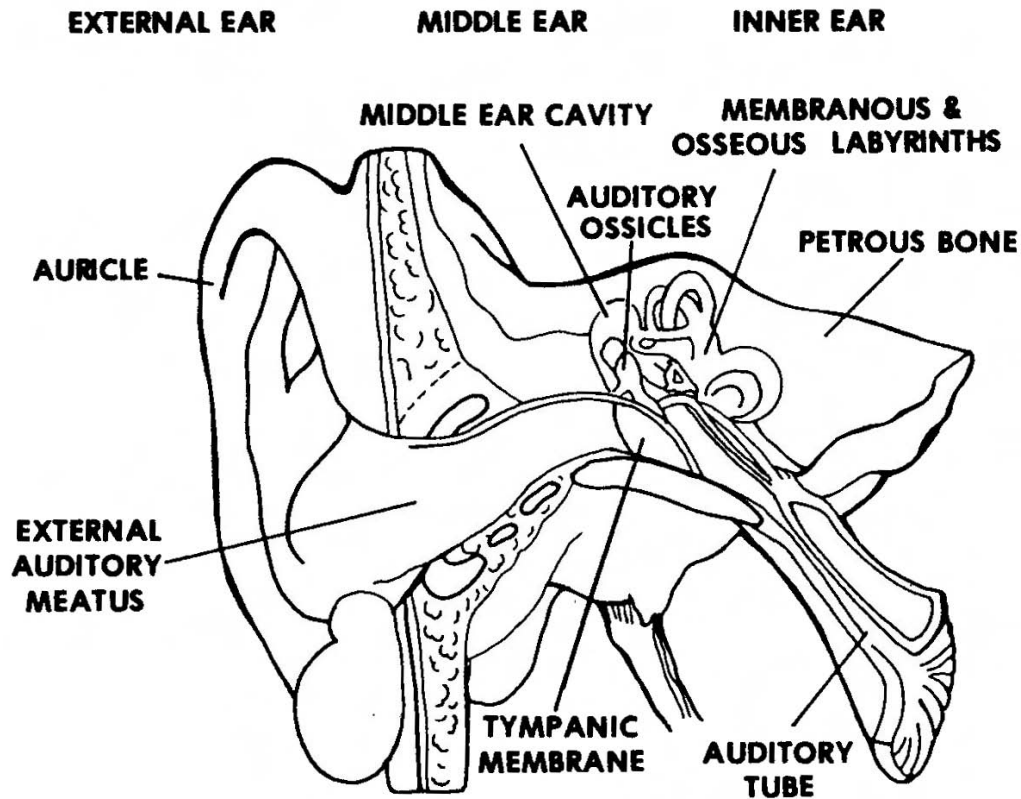


Figure 1-6. A frontal section of the human ear.

(2) Middle ear cavity. On the medial side of the tympanic membrane is the middle ear cavity. The middle ear cavity is a space within the temporal bone.

(3) Auditory ossicles. The auditory ossicles (OSSICLE = small bone) are three, very small bones which form a chain across the middle ear cavity. They join the tympanic membrane with the medial wall of the middle ear cavity. In order, the ossicles are named as follows: malleus, incus, and stapes. The malleus is attached to the tympanic membrane. A sound stimulus is transmitted from the tympanic membrane to the medial wall of the middle ear cavity by way of the ossicles. The ossicles vibrate (mechanically oscillate) in response to the sound stimulus.

(4) Auditory (eustachian) tube. The auditory tube is a passage connecting the middle ear cavity with the nasopharynx. The auditory tube maintains equal air pressure on the two sides of the tympanic membrane.

(5) Association with other spaces. The middle ear cavity is associated with other spaces in the skull. The thin roof of the middle ear cavity is the floor of part of the cranial cavity. The middle ear cavity is continuous posteriorly with the mastoid air cells via the antrum (an upper posterior recess of the middle ear cavity).



c. **The Internal Ear.** Because of its complicated series of canals, the internal ear is also called the labyrinth. There are two main divisions: a body labyrinth and a membranous labyrinth that fits in the body labyrinth.

(1) Labyrinths.

(a) Bony labyrinth. The bony labyrinth (LABYRINTH = a maze) is a complex cavity within the temporal bone. It has three semicircular canals, a vestibule (hallway), and a snail-shaped portion.

(b) Membranous labyrinth. The membranous labyrinth is a hollow tubular structure suspended within the bony labyrinth.

(2) Fluids of the internal ear. The endolymph is a fluid filling the space within the membranous labyrinth. The perilymph is a fluid filling the space between the membranous labyrinth and the bony labyrinth.

(3) The cochlea. The cochlea is a spiral structure associated with hearing. It has 2-1/2 turns. Its outer boundaries are formed by the snail-shaped portion of the body labyrinth.

(a) The central column, or axis, of the cochlea is called the modiolus. Extending from this central column is a spiral shelf of bone called the spiral lamina. A fibrous membrane called the basilar membrane (or basilar lamina) connects the spiral lamina with the outer bony wall of the cochlea. The basilar membrane forms the floor of the cochlear duct, the spiral portion of the membranous labyrinth. Within the cochlear duct, there is a structure on the basilar membrane called the organ of Corti. The organ of Corti has hairs which are the sensory receptors for the special sense of hearing.

(b) Within the bony cochlea, the space above the cochlear duct is known as the scala vestibuli, and the space below is known as the scala tympani. Since the scalae are joined at their apex, they form a continuous channel, and the connection between them is called the helicotrema.

(c) Between the scalae and the middle ear cavity are two windows: the oval window and the round window. The oval window, also called the fenestra vestibuli, is between the middle ear cavity and the scala vestibuli. It is filled with the foot plate of the stapes. The round window which is also known as the fenestra cochlea is located between the inner ear cavity and the scala tympani. This window is covered or closed by a membrane.

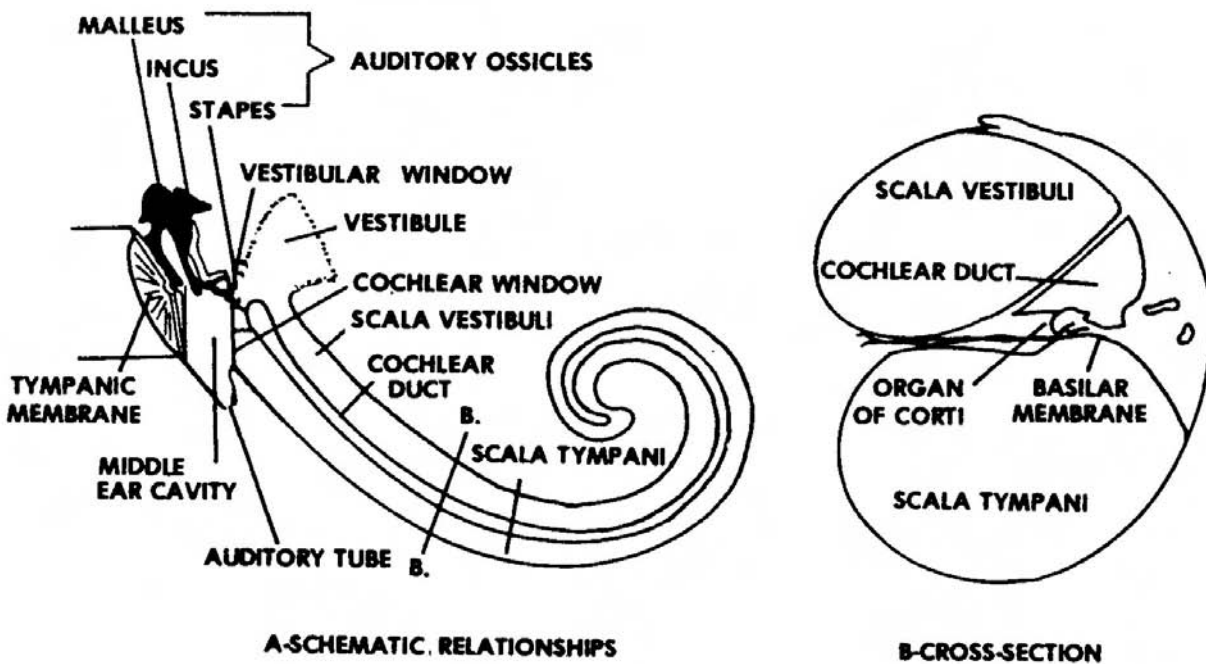


Figure 1-7. Diagram of the scalae.

## 1-8. PHYSIOLOGY

a. **Sensation of Sound.** If a medium is set into vibration within certain frequency limits (average between 25 cycles per second and 18,000 cycles per second), we have a sound stimulus. The sensation of sound occurs only when these vibrations are interpreted by the cerebral cortex of the brain at the conscious level. The human ear is the special sensory receptor for the sound stimulus. As the stimulus passes from the external medium (air, water, or a solid conductor of sound) to the actual receptor cells in the head, the vibrations are in the form of (1) airborne waves, (2) mechanical oscillations, and (3) fluid-borne pulses.

b. **Events in the Physiology of Hearing Sound Waves.** The function of hearing involves many structures and is a complicated process. Here is a brief listing of the events in the process:

(1) The external ear (the auricle) funnels sound waves into the more internal structures concerned with hearing. The external auditory meatus directs sound waves inward, forward, and down to the tympanic membrane.

(2) In the tympanic membrane area, there are ceruminous glands that secrete ear wax (cerumen). Too much ear wax can partially obstruct the auditory canal and interfere with hearing.

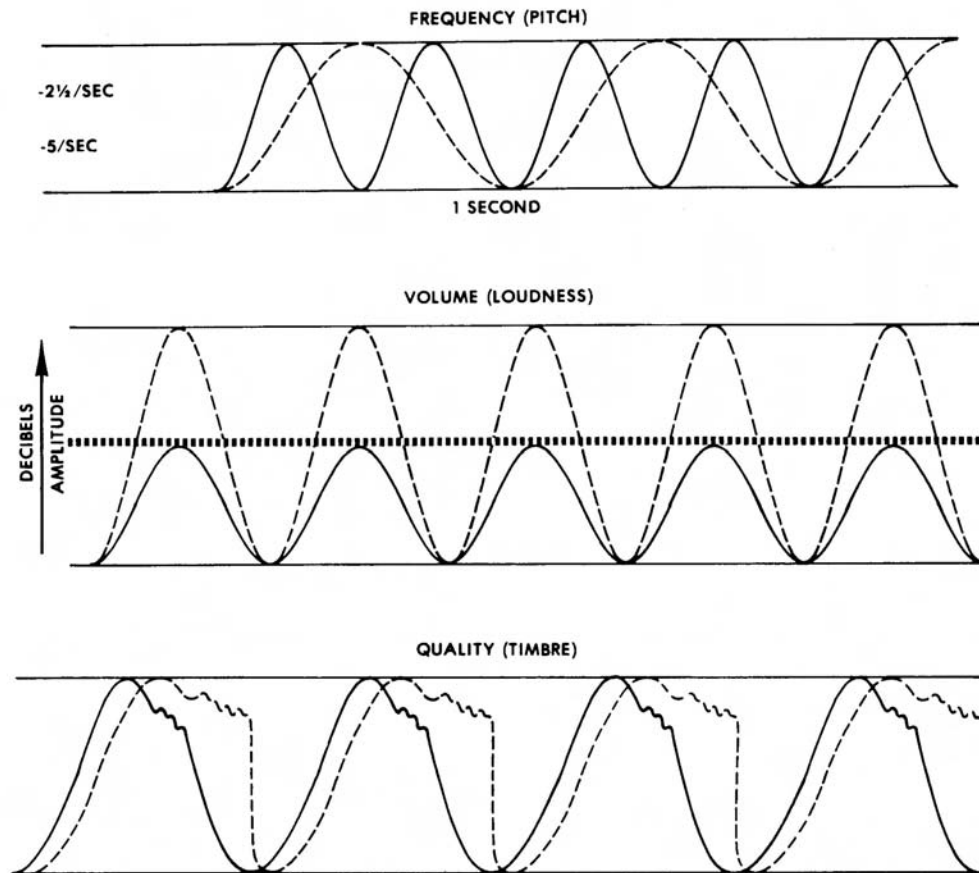


Figure 1-8. Characteristics of sound.

(3) Sound waves reach the tympenic membrane and cause it to vibrate; these membranes transmit vibrations into the middle ear.

(4) In the middle ear, those small bones called the auditory ossicles move in response to the vibrations of the tympanic membrane. The movement of these small bones causes the oval window into the inner ear to move.

(5) The oval window presses against the fluid in the cochlear channel causing ripple-like waves.

(6) The waves of this fluid stimulate the hair cells of the organs of Corti, which are located on the basilar membrane in the cochlea.

(7) Stimulation of the hair cells of the organs of Corti travels to the temporal side of the brain.

(8) The brain sends us the message that we hear sound.

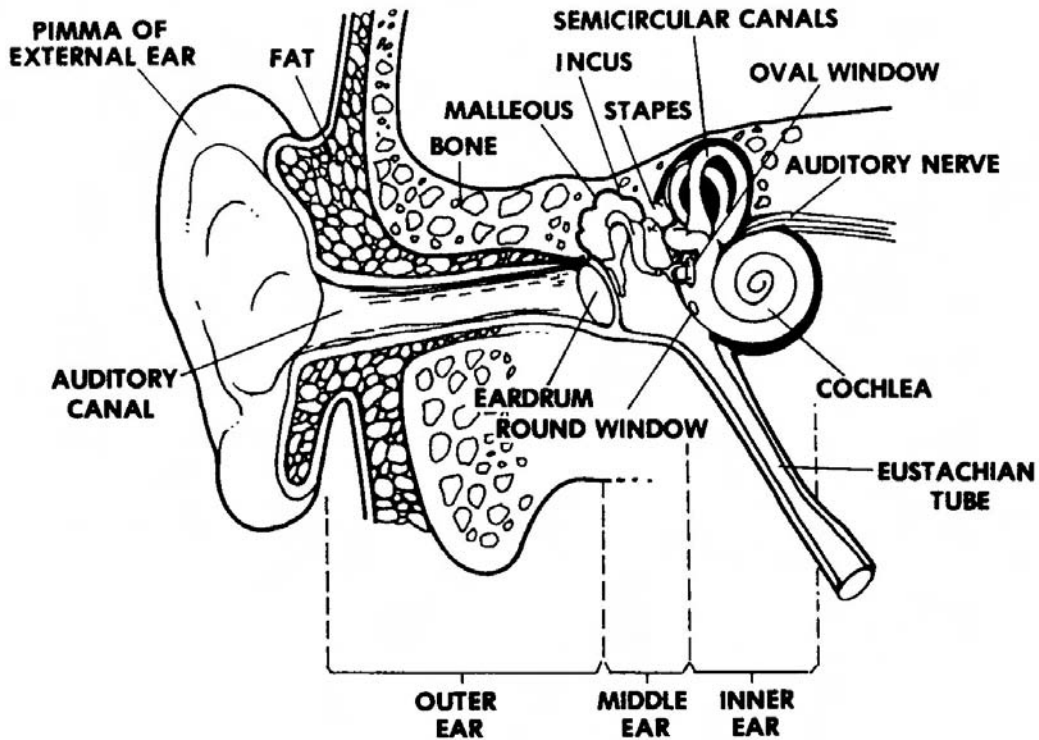


Figure 1-9. The outer, inner, and middle ear.

#### Section IV. THE SPECIAL SENSE OF SMELL (OLFACTION)

##### 1-9. GENERAL

The taste sensation is closely related to the sensation of smell. We often select food and enjoy particular dishes because of a pleasant odor or aroma. A person with a cold or allergies usually claims the food is tasteless. Actually, his sense of smell has been affected and disturbed his sense of taste. There have been many attempts to distinguish and classify the primary sensations of smells. One classification distinguishes seven classes of primary sensations: camphoraceous, musky, floral, pepperminty, ethereal, pungent, and putrid. Later research suggests that there may be as many as fifty or more primary sensations of smell. Although animals have a more highly developed sense of smell than humans, humans can identify at least 4000 different odors. Olfactory receptors become tired easily with the result that humans cannot smell the same odor for very long, but they can pick up a new odor. Additionally, a particular odor in an area of many odors can be identified, and an odor smelled only once can often be remembered.

## 1-10. ANATOMY OF OLFACTION

Olfactory sense receptors are located in the nasal epithelium in the superior part of the nasal cavity on either side of the nasal septum. There are two kinds of cells in the nasal epithelium: supporting cells and olfactory cells. Supporting cells are shaped like columns and are located in the mucous membrane lining of the nose. This membrane is kept moist by the olfactory glands. The olfactory cells lie between the supporting cells. The free end of each olfactory cell contains six to eight dendrites called olfactory hairs.

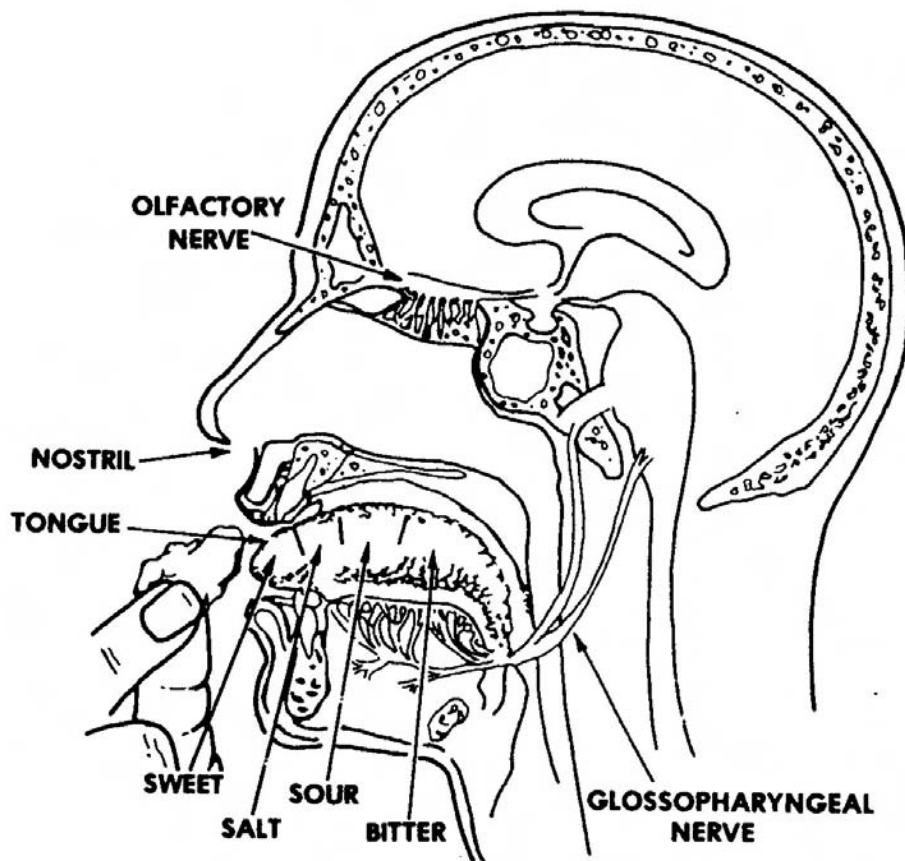


Figure 1-10. Organs of smell.

## 1-11. PHYSIOLOGY OF OLFACTION

The sensation of smell functions in this manner. We breathe in a gaseous substance that dissolves in the fluid of the nasal chamber. The fluid stimulates the olfactory cells in the upper part of the nasal mucosa. Sniffing increases the amount of gaseous substance, and the odor becomes stronger. The sensory pathway for the sense of smell is the olfactory nerve. Olfactory cells transmit impulses from the receptors over the olfactory nerve to the brain.

## Section V. THE SPECIAL SENSE OF TASTE (GUSTATION)

### 1-12. GENERAL

When a substance is put in the mouth, the substance is exposed to tiny receptors in the taste buds. Each person has about 10,000 taste buds. Most of the taste buds are on the surface of the tongue, but some are on the roof of the mouth and some are in the throat. We seem to taste many substances, but actually there are only four primary taste sensations: sour, salt, bitter, and sweet. Other tastes such as chocolate, pepper, and coffee are combinations of these four tastes changed by olfactory sensations. If you have a cold or an allergy, you may feel that you cannot taste your food. What is happening is that your taste sensations are operating correctly, but your olfactory (smell) sensations are not. Much of what we think of as taste is actually smell. The odor from food passes upward into the nasopharynx and stimulates the olfactory system. If the sense of smell is greatly impaired, the quality of taste can change completely; fresh onions can taste sweet and limburger cheese taste very bland. Receptors for the four primary tastes are located in different parts of the tongue. The anterior tip of the tongue reacts to all four primary taste sensations, but it is more responsive to sweet substances. Taste buds on the anterior edges of the tongue are responsive to salty substances. Sour substance receptors are located on the lateral margins of the tongue, and receptors for bitter substances are on the posterior midportion of the tongue.

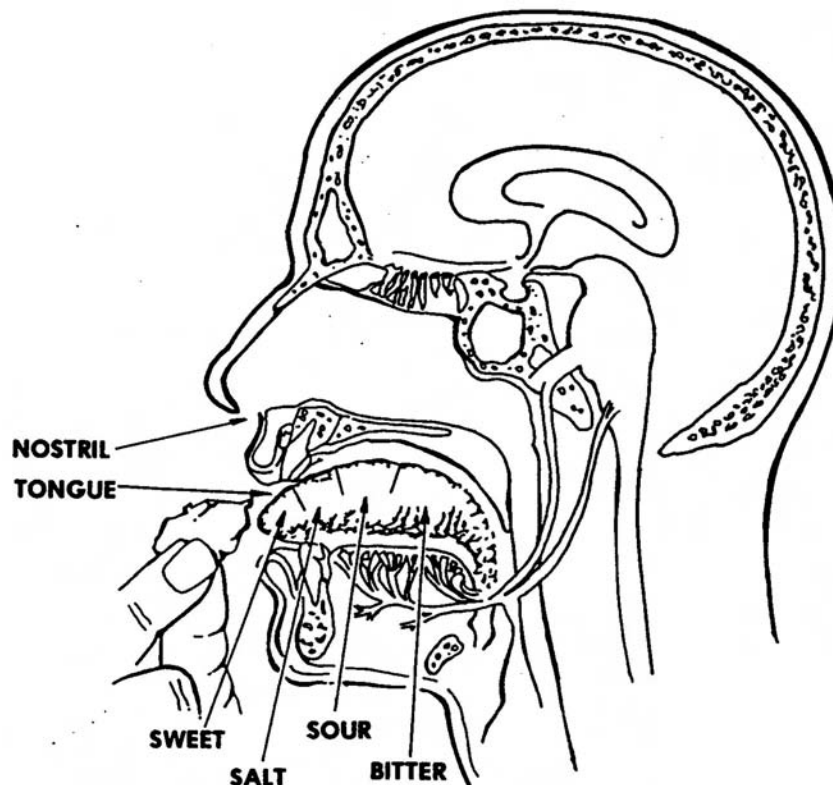


Figure 1-11. Organs of taste.

## 1-13. ANATOMY OF GUSTATION

a. **Receptors and Taste Buds.** The receptors for the sensation of taste are the taste buds which are located primarily on the tongue but also on the soft palate, the epiglottis, and the pharynx. The taste buds are oval-shaped and are made up of two kinds of cells: supporting cells and gustatory cells. The supporting cells are composed of a special kind of tissue that forms a capsule. Inside the capsule are four to twenty gustatory cells. Gustatory hair projects out of each gustatory cell. This hair extends to the external surface through an opening in the taste bud called the taste pore. This is the opening for taste stimuli to make contact with gustatory cells.

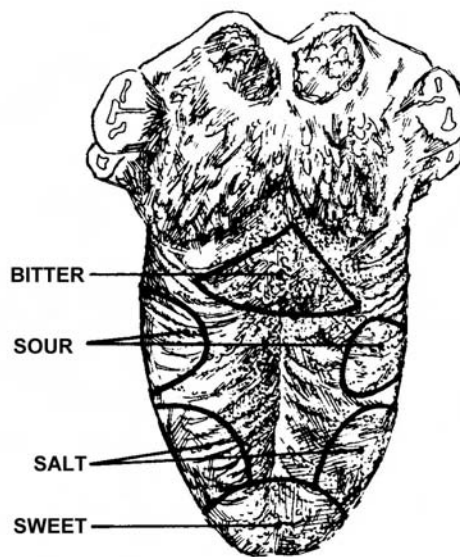


Figure 1-12. Location of taste buds.

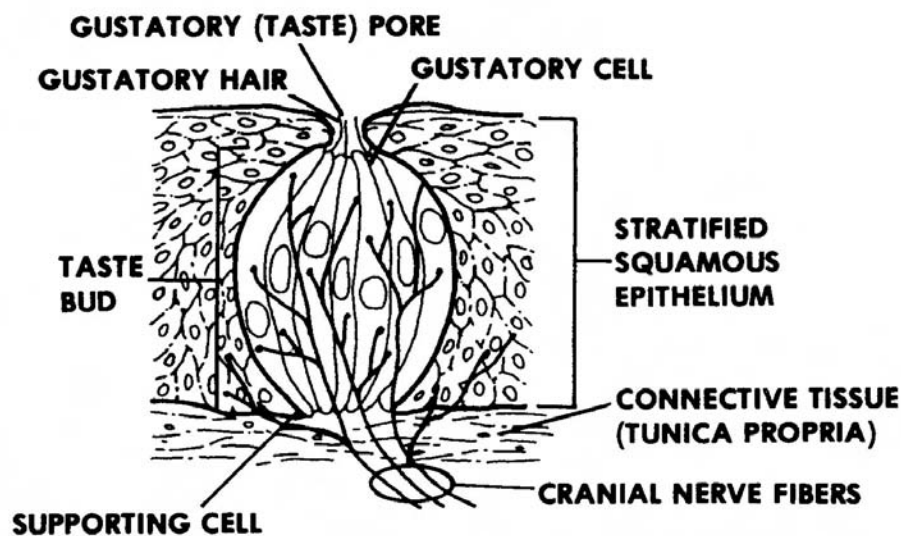


Figure 1-13. The structure of a taste bud.

b. **Papillae.** Some taste buds are located in elevated connective tissue on the tongue. This tissue is called papillae. Papillae cause the upper surface of the tongue to look rough. Circumvallate papillae are the largest papillae; they form an inverted V-shaped row at the back of the tongue. Fungiform (mushroom-shaped) papillae are located primarily on the tip and sides of the tongue. There are taste buds in all circumvallate and most fungiform papillae. The front two thirds of the tongue are covered with pointed, thread-like structures called filiform papillae.

#### **1-14. PHYSIOLOGY OF GUSTATION**

To create the sensation of taste, a substance must be in a solution of saliva so that the substance can enter the taste pores. The taste substance makes contact in the pores with plasma membranes of the gustatory hairs; this causes the taste receptors to be stimulated. There are two sensory pathways for taste. Pathway one contains the facial nerve which carries taste sensations from the front two-thirds of the tongue. Pathway two, the glosso-pharyngeal nerve, carries taste sensations from the back one third of the tongue. These sensations are transmitted to the brain where the information is interpreted as the sensation of taste.

#### **1-15. CLOSING**

A thorough understanding of the sensory system is essential in your ability to provide basic emergency and primary medical care for today's soldier. For example, laser injuries affect eyesight; artillery blasts affect hearing. Your knowledge of the anatomy and physiology of the senses is necessary for you to recognize the effects of modern weaponry and treat the soldier accordingly.

**[Continue with Exercises](#)**



## EXERCISES, LESSON 1

**INSTRUCTIONS.** The following exercises are to be answered by writing the answer in the space provided. After you have completed all the exercises, turn to the solutions following the exercises and check your answers.

1. Define sensation, in its broadest meaning. \_\_\_\_\_  
\_\_\_\_\_

2. List the four conditions which must be present for a sensation to occur.

a. \_\_\_\_\_.

b. \_\_\_\_\_.

c. \_\_\_\_\_.

d. \_\_\_\_\_.

3. List the three tunics (layers) of the eyeball.

a. \_\_\_\_\_.

b. \_\_\_\_\_.

c. \_\_\_\_\_.

4. The \_\_\_\_\_ layer of the eyeball contains three zones of impulse-conducting neurons.

5. Light enters the eyeball through a hole in the \_\_\_\_\_, one of the parts of the vascular tunic.

6. The iris dilates and constricts thus, regulating \_\_\_\_\_  
\_\_\_\_\_.

7. \_\_\_\_\_ consist of epidermis, dermis, subcutaneous connective tissue, and conjunctiva as well as other parts.
8. The structures which make and drain away tears are termed \_\_\_\_\_.
9. List the four basic processes involved in forming an image on the retina.
- a. \_\_\_\_\_.
  - b. \_\_\_\_\_.
  - c. \_\_\_\_\_.
  - d. \_\_\_\_\_.
10. List the two major special sensory functions of the ear.
- a. \_\_\_\_\_.
  - b. \_\_\_\_\_.
11. List the three principal regions of the ear.
- a. \_\_\_\_\_.
  - b. \_\_\_\_\_.
  - c. \_\_\_\_\_.
12. The oval window and the round window are part of the \_\_\_\_\_ ear.
13. List the three characteristics of sound.
- a. \_\_\_\_\_.
  - b. \_\_\_\_\_.
  - c. \_\_\_\_\_.

**Check Your Answers on Next Page**

## SOLUTIONS TO EXERCISES, LESSON 1

1. Sensation refers to man's state of being aware of external or internal conditions of the body. (para 1-2d)
2. Stimulus.  
Receptor or sense organ.  
Conduction.  
Translation. (paras 1-2a through d)
3. The fibrous tunic.  
The vascular tunic.  
The nervous tunic (retina). (paras 1-3b(1) through (3))
4. Nervous or retina. (para 1-3b(3))
5. Iris. (para 1-3b(2)(c))
6. The amount of light which enters the eye. (para 1-3e)
7. Eyelids. (para 1-4c)
8. Lacrimal apparatus. (para 1-4d)
9. Refraction of light rays.  
Accommodation of the lens.  
Constriction of the pupil.  
Convergency of the eyes. (para 1-5a)
10. Hearing.  
Equilibrium. (para 1-6)
11. External or outer ear.  
Middle ear.  
Internal or inner ear. (para 1-7)
12. Middle. (para 1-7b)
13. Frequency or pitch.  
Volume or loudness.  
Quality or timbre. (figure 1-8)

**End of Lesson 1**

## LESSON ASSIGNMENT

### LESSON 2

Physical Assessment of the Sensory System (HEENT).

### LESSON ASSIGNMENT

Paragraphs 2-1 through 2-10.

### LESSON OBJECTIVES

After completing this lesson, you should be able to:

- 2-1. Identify terminology related to the sensory system.
- 2-2. Identify the areas of patient history to be considered in a physical assessment of the sensory system.
- 2-3. Identify the procedures for physical assessment of the eyes.
- 2-4. Identify the procedures for physical assessment of the ears.
- 2-5. Identify the procedures for physical examination of the nose and sinuses.
- 2-6. Identify the procedures for physical examination of the mouth and pharynx.

### SUGGESTION

After completing the assignment, complete the exercises of this lesson. These exercises will help you to achieve the lesson objectives.

## LESSON 2

### PHYSICAL ASSESSMENT OF THE SENSORY SYSTEM (HEENT)

#### 2-1. INTRODUCTION

The sensory system is the part of the nervous system which allows humans to be conscious of and react to their environment. Processes in the brain respond to nerve impulses from sense receptors causing humans to have sensations. It is extremely important that the sense organs function properly to keep humans aware of conditions in their environment as well as activities taking place in their bodies. The sense organs interpret data from the body's sense organs, and the body makes the appropriate adjustments. Proper physical assessment of the sensory system is essential to ensure that the sensory organs are functioning correctly.

#### 2-2. OBTAIN PATIENT HISTORY

Gathering medical information about the patient is very important in making a diagnosis of the patient's present health condition. Information on these areas should be obtained: past medical history, family history, psychosocial history, and a review of the patient's body systems. The following information should be obtained about the patient's present health problem:

- a. **Trauma.** Is the health problem the result of trauma? If so, describe the trauma.
- b. **Disease.** Is the health problem the result of a disease? What diseases has the patient had in the recent past?
- c. **Pain.** Ask the patient to describe the pain in terms of its location, quality, severity, time (when the pain occurs, how long the pain lasts, and how often the pain occurs), region (the region of the body in which the pain occurs), conditions which make the pain worse, and any other facts which are relevant to the pain.

#### 2-3. EXAMINATION OF THE FACE

The human face is not only the center for vital functions of the human body-- speech, eating, smell, taste, vision, and hearing--but the face is a very noticeable part of the human anatomy. Any injury to the face can impair body functions and create severe stress in a person's life. It is, therefore, important to locate and correct any facial problem as soon as possible. Examine the face using two techniques: inspection and palpation.

a. **Inspection.** Look at the patient's face. Notice the symmetry of the face. Are there any involuntary movements? Is there any edema? Are there any masses?

b. **Palpation.** Using the pads of your fingers with the fingers together, gently feel in all parts of the face. Do not use short, quick jabs. Move your fingers smoothly being sensitive to any areas of tenderness.

## 2-4. EYE ASSESSMENT PROCEDURES

a. **Check for Accommodation.** Accommodation is the adjustment of the eye for seeing at different distances. Accommodation is another word for focusing. It is a change in the curvature of the lens of the eye to adjust to see objects both near and far. The eye lens curves greatly to focus on objects that are close. When a person is focusing on an object far away, the lens becomes flatter. In both instances, the eye lens adjusts or accommodates to the object being looked at. The eye muscle which controls whether the eye lens is very curved or flattened is the ciliary muscle.

b. **Check Visual Acuity.** Visual acuity is clearness or sharpness of vision. A visual acuity test should be a routine examination of all patients. There are several special charts of test letters used, but the most commonly used chart is the Snellen chart. The patient is seated twenty feet from the chart. He places a clean card in front of one eye without putting pressure on the eye globe. The chart has several rows of progressively smaller letters. The patient is asked to read the letters down the chart as far as possible. A patient who can read the letters on the "20/20" line from a distance of twenty feet is said to have 20/20 vision in that eye. The same process is repeated for the other eye. If the patient normally wears glasses for distance, the test should be repeated with his glasses on. Results should then be recorded as "uncorrected" and "corrected."

### c. **Check for Color Vision.**

(1) Color vision test. A color vision test determines a person's ability to distinguish primary colors and shades of those colors, usually a total of ten primary colors and shades. The most commonly used test is the one developed by Ishihara, Stilling, and Hardy- Rand-Ritter. The person being tested looks at a series of plates made up of dots of the primary colors printed on a background of similar dots in a variety of colors. The dots are set up in patterns which a person with normal color perception can identify (numbers or symbols). A person who is color deficient will be unable to identify any patterns.

(2) Color blind or color deficient. The term "color blind" is really less accurate than "color deficient." A person who cannot distinguish between certain colors is not completely lacking in color perception. Instead, he sees those colors differently than the individual with normal color perception. About eight percent of the men in the United States cannot distinguish between red and green. Four percent of the women in the United States have the same difficulty. It is very rare to find someone who cannot distinguish between blue and yellow or who has trouble identifying the color violet.

d. **Check Visual Field.** The visual field refers to the entire area which the person can see without changing his gaze. A visual field test determines whether the retina, optic nerve, and the optic pathways are functioning properly. Conduct this test to determine the perimeters of the patient's field of vision:

(1) Seat yourself in front of the patient with your face directly in front of and on the same level as the patient's face. (The distance between you and the patient should be about two feet.)

(2) Have the patient cover one eye without pressing on it.

(3) Ask the patient to focus on your nose.

(4) Move a pencil or other small object in from the side at 15 degree intervals and ask the patient to signal when he sees the object. (A person with normal vision can see a moving object about ninety degrees to the side.) This method will pick up only large visual field defects.

(5) Repeat the test with the other eye.

e. **Check Position and Alignment of the Eyes.** Look at the eyes to see if they are positioned and aligned normally.

f. **Check the Eyebrows.** Look at the eyebrows. Examine for:

(1) Quantity of hairs in the eyebrows.

(2) Distribution of hairs in the eyebrows.

(3) Scaliness of the skin under the eyebrows.

g. **Examine the Eyelids.** Look for:

(1) Swellings or edema.

(2) Lesions on the eyelids.

(3) Crusting on the eyelids.

(4) Adequacy of eye cover. Check for entropion (eyelid margin turning inward and causing eyelashes to rub on the cornea) or ectropion (eyelid edge turns outward).

**h. Check Lacrimal Apparatus.**

(1) Lacrimal gland region inspection. Lift up the bottom part of the upper lid; direct the patient to look down and to the opposite side. Look to see if the lacrimal gland is swollen and sticks out between the upper lid and the eyeball.

(2) Lacrimal sac area inspection. Examine this area to see if there is swelling. If the eye tears too much, press on the inside portion of the lower eyelid just inside the orbital rim. Look to see if fluid comes out of the lacrimal duct openings. Examine the area for tenderness by palpation. If the lacrimal sac is acutely inflamed, take care to press very gently.

**i. Conjunctiva.**

(1) Examine both the palpebral and bulbar portions of the conjunctiva.

(2) Examine the inferior sac. Pull down the skin beneath the eye. Have the patient look upward.

j. **Cornea.** To look for corneal abrasions, shine a light from a penlight so that the side of the cornea is illuminated. Use a fluorescein strip to stain any corneal abrasion you may find. Fluorescein is a solution which may cause infection. Follow this procedure:

(1) First, moisten the strip with a sterile solution of water or saline. Then touch the strip to the lower cul-de-sac.

(2) Take care not to stain anyone's clothes, yours or the patients'.

(3) The dye will drain into the nasal cavity.

k. **Corneal Sensitivity.** Check corneal sensitivity by touching a cotton wisp to the cornea and observing whether the patient blinks. Touching the eyelashes invalidates this test. Touching the eyelashes stimulates a different reflex.

**l. Pupils.** Inspect pupils for the following:

(1) Inspect the pupils for equality and roundness.

(2) Pupils equal and reactive to light (PEARL).



(3) Pupils equal, round, reactive to light, and accommodation (PERRLA).

(4) Both eyes should constrict when light is directed into one eye. This is the consensual reflex.

(5) The eye should also constrict when focusing several inches from the nose.

**CAUTION:** When you are checking the pupillary reaction, be sure the patient does not look directly at the light. Looking directly at the light may cause constriction just by accommodation.

(6) If the patient has lesions on the optic nerve or has tract lesions, the pupillary response may be defective.

m. **Extraocular Muscles.** Extraocular muscles are muscles located outside the eye but having to do with the eye. To assess these muscles, do the following:

(1) Check to see if the patient's gaze is straight.

(2) Check the six cardinal positions of gaze. Ask the patient to look right, look left, look to the upper right, look to the upper left, look to the lower right, and look to the lower left.

(3) Conduct the cover-uncover test for strabismus. This test checks eye muscle deviation. Have the patient fix his gaze on a small, stationary object first at a distance of twenty inches and then at a distance of twelve inches. Cover one of the patient's eyes while he looks at the object with the other eye. Look for any movement of the uncovered eye. If the eye moves, it means it was not fixed on the object originally. Any movement in the uncovered eye is abnormal. Also, note the direction the uncovered eye moves, if it moves.

n. **Intraocular Tension.** Intraocular refers to conditions within the eye. Intraocular pressure can be measured by Schiottz tonometry and applanation tonometry. Instill a local anesthetic in the patient's eye. Put the Schiottz tonometer lightly on the corneal surface and measure the indentation of the cornea made by a given weight. The force necessary to flatten a small area of the central cornea is measured by applanation tonometry.

## 2-5. EXAMINATION OF EARS

a. **Auricle.** Look at the external ear. Inspect each auricle for and the surrounding tissues for deformities, masses, and lesions.

b. **Ear Canal and Eardrum (Tympanic Membrane (TM)).** The eardrum may need to be cleaned before you can examine it properly.

(1) Cleaning the eardrum. If the eardrum needs to be cleaned, clean under direct observation. The eardrum can be cleaned with a cerumen spoon #8. Only a skilled professional should do such cleaning. Irrigation with a softening agent such as Debrox<sup>®</sup>, Cerumenex<sup>®</sup>, or water is another method of cleaning the ear drum. DO NOT jab blindly with a cotton-tipped applicator; this may result in puncture of the tympanic membrane or packed cerumen.

(2) Examining the ear canal and eardrum. Follow this procedure:

(a) Attach a speculum to the otoscope. (An otoscope is the instrument commonly used to examine the ear.) Use the largest diameter instrument earpiece that will fit the ear canal without causing the patient discomfort.

(b) Hold the otoscope in either of these two ways. Hold the instrument right side up with your fingers between the otoscope handle and the patient's head. Or, hold the instrument upside down with your finger and the ulnar surface of your hand against the patient's head.

(c) Tip the patient's head away from you and straighten the ear canal by pulling the auricle up and back slightly.

(d) Gently insert the tip of the otoscope into the ear canal.

(e) Inspect the ear canal for cerumen, redness, swelling, foreign bodies, and scaling.

(f) Locate the eardrum. (It is the pearly, translucent membrane.) Inspect it for color (pearly) and shape (non-bulging).

c. **Hearing.** Test for auditory acuity.

(1) Whisper numbers at a distance of one foot. Have the patient repeat the numbers after you. If the patient cannot hear a whisper at a distance of one foot, he probably has about a 30 decibel hearing loss.

(2) Hold a ticking watch next to one ear. Note the closest distance at which the patient can hear the watch tick.

(3) Conduct the Weber test. This test is used to determine hearing loss in one ear. The procedure consists of striking a tuning fork and holding one end against the middle of the patient's forehead. Ask the patient if he can hear the sound the same or better in one ear than the other. If the patient says the same, his hearing is the same in both ears. If the patient hears the sound best in the ear with poorer hearing, he has conductive hearing loss. If he hears the sound best in the good ear, he has perceptive (nerve) hearing loss.

(4) Conduct the Rinne test. The Rinne test also determines conductive or nerve hearing loss.

(a) Procedure. The test is conducted in this manner. Strike the tuning fork and place one end against the mastoid process of one ear. Note the length of time the patient can hear the sound. Without striking the fork again hold the fork end near the ear, about one inch away. Again, note the length of time the patient can hear sound from the tuning fork.

(b) Results. If the patient can hear the sound twice as long when the tuning fork is held against the mastoid process, he has normal hearing. If hearing in both instances (tuning fork against the mastoid process and tuning fork held away from the ear) is diminished with greater hearing when the fork is held away from the ear, the patient probably has perceptive (nerve) hearing loss.

## 2-6. EXAMINATION OF NOSE/SINUSES

a. **External Examination.** Inspect the external nose and look for redness, edema, lumps, tumors, or poor alignment. A patient with red nostrils may blow the nose frequently because of allergies or infectious rhinitis. Dilated, engorged blood vessels of the nose may indicate either that the patient is outside in all kinds of weather much of the time or that he is an alcoholic. A person with a bulbous, discolored nose may have rosacea (a chronic inflammatory disorder similar to acne).

b. **Internal Examination.** Follow these steps.

(1) Obtain patient history. Ask the patient about any previous olfactory disturbances.

(2) Spread the nares. Do this by pushing on the tip of the patient's nose. This gives a fair view of the inside of the nostrils.

(3) Examine with speculum with otoscope. Using a plastic funnel-type speculum with otoscope, examine the septum and the turbinates. Check for polyps, bleeding, and purulent drainage on the inside of the nasal passages.

(4) Check nasal discharge. If there is nasal discharge, assess its color, consistency, and odor. Also, check for blood in the discharge. The patient may have an allergy or a cold if the discharge is profuse and thin.

(5) Examine the sinuses. Palpate the sinuses. Apply pressure gently to the nostrils, orbital rims, and cheeks. If the patient experiences pain after pressure is applied above the upper orbital rims, the patient has frontal sinus irritation. If he feels pain after pressure is applied to the cheeks, he has maxillary sinus irritation.

## **2-7. EXAMINATION OF MOUTH/PHARYNX**

a. **Mouth**. Ask the patient to open his mouth wide. Depress his tongue with the tongue blade in the middle of the tongue. The posterior tongue is involved in the gag reflex. Check the following structures:

(1) The tongue. Inspect the top, bottom, and sides. Test for movement, taste, and sensation. The normal variants of the tongue include a deeply furrowed surface.

(2) The teeth. Check for caries (cavities). Also, check for broken teeth.

(3) Gums. Inspect for redness which could indicate inflammation (infection). Also, check for bleeding. Bleeding could be an indication of poor brushing habits or gum disease.

(4) Mucous membranes. Check for pallor or redness. Either could be a sign of an unhealthy mouth.

b. **Pharynx**. Shine a bright light in the mouth and on the throat. Inspect for inflammation or white patches. If necessary, take a throat culture to identify infection-causing organisms.

## **2-8. SPECIFIC ITEMS TO LOOK FOR IN AN HEENT INSPECTION**

Look for these conditions when you are conducting a head, eyes, ears, nose, and throat inspection.

### **a. The Bony Skull: Trauma.**

(1) Mandibular joint dislocation --obvious with malpositioned mandible (jawbone) and decreased range of motion.

(2) Skull fracture--watery discharge, bloody discharge from cranial orifices.

(3) Battle's sign--discoloration behind the ear, an indication of a fracture of the base of the skull.

**b. The Bony Skull: Nontrauma.**

(1) Hydrocephalus--excessive accumulation of cerebrospinal fluid in the ventricular spaces of the brain or in the subarachnoid spaces. This condition occurs primarily in newborns causing an enlarged head.

(2) Osteitis deformans (Paget's disease of bone)--a bone disease with areas of bone destruction followed by a period of excessive, abnormal bone formation. The new bone growth is fragile and weak, and the excessive growth results in internal and external deformities.

**c. The Hair.**

(1) Brittleness and thinning as seen in pituitary problems and thyroid deficiency.

(2) Hair loss. Syphilitic alopecia (patchy baldness, usually temporary) occurs in the second stage of syphilis. The head of such a patient can be described as having a "moth eaten" appearance.

**d. The Lips.**

(1) Dryness--fever, dehydration.

(2) Blister--fever blisters, herpes labialis (type I).

(3) Chancre--the first lesion of syphilis. This lesion occurs at the site of the entrance of the syphilitic infection as a hard, reddish ulcer with an eroded center covered by a yellowish secretion.

(4) Perleche--monilia (a genus of molds or fungi) infection marked by an inflammation at the angles of the mouth. Perleche occurs in those who have a habit of licking the corners of the mouth or in the undernourished.

**e. The Tongue.**

(1) Strawberry tongue characteristic of scarlet fever.

(2) Excessive smoking--mild glossitis (inflammation of the tongue) with brown/gray coating (smoker's breath).

(3) Carcinoma--a malignant, cellular tumor appearing as a depressed lesion which bleeds easily and won't go away.

(4) Aphthous ulcers--small, white patches commonly called "canker sores." Viral in origin, most resolve spontaneously in 7-10 days.

## 2-9. MEDICAL TERMS RELATED TO THE EYES

a. Astigmatism--refractive error which prevents the light rays from coming to a single focus on the retina because of different degrees of refraction in the various meridians of the cornea.

b. Cataract--a lens opacity; a loss of transparency of the lens of the eye, resulting in partial or total blindness. Surgery results in improvement of vision in 95 percent of those affected.

c. Chalazion--granulomatous inflammation of the meibomian gland; lump or swelling on eyelid.

d. Color blindness--diminished ability to perceive differences in color.

e. Concave lens--lens that diverges rays of light (myopic)--also known as reducing, negative minus lens(-).

f. Convergence--the process of directing the visual axis of the eyes to a near point.

g. Convex lens--lens that converges rays of light bringing them to focus; also known as magnifying, hyperopic, plus lens (+).

h. Diplopia--seeing one object as two.

i. Ectropion--turning out of the eyelid.

j. Entropion--turning inward of the eyelid.

k. Glaucoma--a group of eye diseases characterized by abnormally high intraocular pressure (pressure in the eyeball). This pressure can damage the optic nerve and, if untreated, lead to a gradual loss of vision -- and eventually blindness.

l. Hyperopia (farsightedness)--a refractive error in which the focal point of light rays from a distant object is behind the retina.

m. Miotic--a drug causing pupillary constriction.

n. Mydriatic--a drug causing pupillary dilatation without affecting accommodation.

o. Myopia--a refractive error which the focal point for light rays from a distant object is anterior to the retina.

- p. Nystagmus--an involuntary, rapid movement of the eyeball; normally horizontal movement.
- q. Photophobia--abnormal sensitivity to and discomfort from light.
- r. Presbyopia--"old sight," physiologically blurred vision, often occurs soon after 40 if at all.
- s. Ptosis--drooping of the eyelids.
- t. Refraction--deviation in the course of rays of light in passing from one transparent medium into another of different density.
- u. Ametropia--a defect in the eye that prevents light rays from being brought to a single focus on the retina.
- v. Strabismus (tropia)--a manifest deviation of the eyes--focusing is not on one point.

## **2-10. CLOSING**

You are now aware of the many areas of the sensory system and the clues to the body's health problems found in the sensory system. Use this tool for the complete assessment of your patients.

**Continue with Exercises**

## EXERCISES, LESSON 2

**INSTRUCTIONS.** The following exercises are to be answered by writing the answer in the space provided. After you have completed all the exercises, turn to the solutions at the end of the exercises and check your answers.

1. Define the sensory system. \_\_\_\_\_  
\_\_\_\_\_
  
2. List three questions to ask the patient about the pain he is experiencing.
  - a. \_\_\_\_\_.
  - b. \_\_\_\_\_.
  - c. \_\_\_\_\_.
  
3. Name two examination methods used in the physical assessment of the face.
  - a. \_\_\_\_\_.
  - b. \_\_\_\_\_.
  
4. The shape of the eye lens changes from very curved to relatively flat to allow humans to see objects either close or far away. The term for this ability of the lens to change shape is \_\_\_\_\_.
  
5. Visual acuity is \_\_\_\_\_ and may be tested by using the Snellen eye chart.
  
6. The Ishihara, Stilling, and Hardy-Rand- Rittler plates--plates made up of dots--test determines whether a person has \_\_\_\_\_.



7. The patient sits directly in front of the examiner, covers one eye, and focuses on the examiner's nose. The examiner moves a small object from the side front of the patient toward the inside of the patient's face. The patient signals when he first sees the object. The examiner is conducting a test for \_\_\_\_\_.

8. List four conditions to look for when performing an inspection of the eyelids.

a. \_\_\_\_\_.

b. \_\_\_\_\_.

c. \_\_\_\_\_.

d. \_\_\_\_\_.

9. How can corneal sensitivity be tested? \_\_\_\_\_

\_\_\_\_\_

10. PEARL and PEARRLA are acronyms used to describe characteristics of the pupils of the eye. Write the meaning of each acronym.

a. PEARL = \_\_\_\_\_

\_\_\_\_\_

b. PEARRLA = \_\_\_\_\_

\_\_\_\_\_

11. List the six cardinal positions of gaze.
- a. \_\_\_\_\_
  - b. \_\_\_\_\_
  - c. \_\_\_\_\_
  - d. \_\_\_\_\_
  - e. \_\_\_\_\_
  - f. \_\_\_\_\_
12. The Schiotz tonometer and the puff-of-air technique are both used to test for \_\_\_\_\_
13. Do not jab the ear with a cotton-tipped applicator because you could \_\_\_\_\_ the tympanic membrane.
14. A patient who cannot hear you whisper at a distance of one foot probably has a hearing loss of about \_\_\_\_\_ decibels.
15. The Rinne test can reveal two types of hearing loss: \_\_\_\_\_ and \_\_\_\_\_
16. When you are conducting a physical assessment of the nose, look at the inside of the nasal passages for:
- a. \_\_\_\_\_.
  - b. \_\_\_\_\_.
  - c. \_\_\_\_\_.

17. List four parts of the mouth to be assessed.

a. \_\_\_\_\_.

b. \_\_\_\_\_.

c. \_\_\_\_\_.

d. \_\_\_\_\_.

18. Gum pigmentation should be inspected for inflammation or \_\_\_\_\_.

19. List three tongue functions which should be checked.

a. \_\_\_\_\_.

b. \_\_\_\_\_.

c. \_\_\_\_\_.

**Check Your Answers on Next Page**

## SOLUTIONS TO EXERCISES, LESSON 2

1. The sensory system is the part of the nervous system which allows humans to react to their environment. (para 2-1)
2. You are correct if you listed any three of the following:
  - Quality of pain.
  - Region of pain.
  - Characteristics of the pain.
  - Severity of the pain.
  - Time the pain occurs. (para 2-2c)
3. Inspection.
  - Palpation. (paras 2-3a, 3b)
4. Accommodation. (para 2-4a)
5. Sharpness of vision. (para 2-4b)
6. A color deficiency. (para 2-4c(2))
7. Perimeter of visual fields. (para 2-4d)
8. Swelling (edema).
  - Lesions.
  - Crusting. (para 2-4g(1) through (3))
9. Touch a cotton wisp to the cornea and observe whether or not the patient blinks. (para 2-4k)
10. PEARL = Pupils equal and reactive to light.  
PEARRLA = Pupils equal, round, reactive to light and accommodation.  
(para 2-4l(2), l(3))
11. The patient looks to:
  - The right.
  - The left.
  - The upper right.
  - The upper left.
  - The lower right.
  - The lower left. (para 2-4m(2))
12. Intraocular tension. (para 2-4n)

13. Puncture. (para 2-5b)
14. 30 (para 2-5c(1))
15. Conductive loss.  
Perceptive (nerve) loss. (para 2-5c(4))
16. Polyps.  
Bleeding.  
Purulent drainage. (para 2-6b(3))
17. Tongue.  
Teeth.  
Gums. (para 2-7a(1) through (3))
18. Infection. (para 2-7a(3))
19. Movement.  
Taste.  
Sensation. (para 2-7a(1))

**End of Lesson 2**

## LESSON ASSIGNMENT

### LESSON 3

EENT Diseases and Disorders.

### LESSON ASSIGNMENT

Paragraphs 3-1 through 3-30.

### LESSON OBJECTIVES

After completing this lesson, you should be able to:

- 3-1. Identify the signs, symptoms, and treatment of the following ocular diseases/disorders: exudation; gonococcal conjunctivitis; herpes simplex keratitis; uveitis; cataracts; eye strain; floaters; blepharospasm; hordeolum; chalazion; blepharitis; and Phthirus pubis infection.
- 3-2. Identify the signs, symptoms, and treatment for the following ear diseases: external otitis; cerumen impaction; eustachian tube dysfunction; serous otitis media; purulent otitis media; perforation of the tympanic membrane; labyrinthitis; and tinnitus.
- 3-3. Identify the signs, symptoms, and treatment for the following nasal conditions: septal deviation; septal ulceration; septal perforation; septal hematoma or abscess; rhinitis medicamentosa; and nasal polyps.
- 3-4. Identify the signs, symptoms, and treatment for the throat condition peritonsillar abscess.

### SUGGESTION

After completing the assignment, complete the exercises of this lesson. These exercises will help you to achieve the lesson objectives.

## LESSON 3

### EENT DISEASES AND DISORDERS

#### Section I. OCULAR DISEASES AND DISORDERS

##### 3-1. INTRODUCTION

Disorders which affect our ability to see, hear, smell, or speak cause considerable anxiety because such conditions affect those functional areas which influence the way we interact with our environment. Most of the EENT problems seen in the field setting can be treated adequately without extensive medical intervention. Learning to differentiate, however, between those EENT disorders which must be evacuated and those which will soon be resolved will be critical in the management of casualties. Common ocular diseases and disorders include the following: exudation (conjunctival discharge); gonococcal conjunctivitis; inclusion conjunctivitis (swimming pool disease); herpes simplex keratitis (dendritic); uveitis; cataracts; corneal ulcer; eye strain; floaters (spots before the eyes); blepharospasm (tics); hordeolum (stye); lid disorders; and other related diseases and disorders.

##### 3-2. EXUDATION (CONJUNCTIVAL DISCHARGE)

a. **Description.** Exudation is a visible indication of an active conjunctival (mucous membrane that lines the inner portion of the eyelids) infection. If the infection is bacterial, the discharge will be purulent. If the infection is caused by a virus, the eyes will be watery and sensitive to light; there will also be a burning sensation.

b. **Signs/Symptoms.** Signs and symptoms include:

- (1) A purulent discharge (in a bacterial infection).
- (2) Watery, burning eyes with a sensitivity to light (viral infection).
- (3) Tearing along with a "ropy or stringy" discharge and itching (as in allergic conjunctivitis).
- (4) Copious discharge with eyelids stuck firmly together on waking (bacterial or chlamydial infection).

c. **Treatment.** Bacterial conjunctivitis is a self-limited disease which lasts from 10 to 14 days even if untreated. The disease usually lasts from two to three days if treated with a sulfonamide or antibiotic ointment applied locally three times daily.

**CAUTION:** Do not use antibiotic corticosteroid combination.

### 3-3. GONOCOCCAL CONJUNCTIVITIS

a. **Description.** This disease is evidenced by a large purulent discharge. A stained smear and culture of the discharge can confirm the diagnosis. The disease occurs as a self-inoculation from gonorrheal genital infection, or the disease can be acquired from contact with someone with gonorrhea. Twenty-four to 48 hours after exposure, the disease develops.

b. **Signs/Symptoms.** This disease has two basic signs and symptoms. The eyelids and conjunctiva may become swollen with the eye having a beefy-red appearance. A second sign is a serosanguineous discharge (serum and blood) that quickly becomes purulent.

c. **Treatment.** Basic treatment includes parenteral antimicrobial therapy (penicillin) and ten percent to thirty percent sodium sulfacetamide (sodium Sulamyd<sup>®</sup> ophthalmic), one to two drops every two hours. This is done after gram staining of conjunctival scraping and discharge to confirm assessment. If untreated, this disease remains acute for about five days and subsides in four to six weeks. Complications which may occur if treatment is delayed include corneal ulceration and perforation, abscess, and blindness.

**CAUTION:** Parenteral antimicrobial therapy is contraindicated when sensitivity to sulfa drugs is known or suspected.

### 3-4. INCLUSION CONJUNCTIVITIS

a. **Description.** Inclusion conjunctivitis is associated with swimming pools. The disease source is exposure to infected genital secretions and/or chlamydiae in poorly chlorinated swimming pools. The disease can also be transmitted by intercourse. Adenovirus can also produce conjunctivitis.

b. **Signs/Symptoms.** Initially, acute redness, discharge, and irritation of the eye occur. Eye findings consist of conjunctivitis with mild corneal inflammation. A nontender preauricular lymph node can often be palpated, and the front of the ear must be palpated to assess a preauricular lymph node.

c. **Treatment.** To prevent bilateral infection, the drug of choice is tetracycline one percent.

### 3-5. HERPES SIMPLEX KERATITIS

a. **Description.** Herpes simplex keratitis is a common corneal ulceration caused by the herpes simplex virus (HSV).



b. **Signs/Symptoms.** A sign likely to be displayed by the patient is a "dendrite," a figure stain pattern on the cornea. The dendrite may appear in a number of other configurations. The keratitis stage has particular signs and symptoms. The patient at this stage may display mild irritation and infection (redness) of the conjunctiva. He may also have mild tearing, photophobia (eyes unusually sensitive and uncomfortable in light), and some degree of haziness in sharpness of vision. The symptoms may increase in severity as keratitis advances to the ulcer stage.

c. **Treatment.** Treatment of herpes simplex includes topical application of idoxuridine 1 percent (Stoxil<sup>®</sup>) drops or ointment as prescribed by a doctor. It is necessary to be cautious when administering this drug to pregnant women or women of childbearing potential. If no signs of healing are apparent within three to five days, debridement is done with a cotton-tipped applicator. If healing is not apparent within a week, refer the patient to ophthalmology.

### 3-6. UVEITIS

a. **Description.** The uveal tract includes the iris, the ciliary body, and the choroid. Any inflammation of the uveal tract (the iris, the ciliary body, and the choroid) is termed uveitis. Anterior uveitis is inflammation primarily of the iris. Posterior uveitis or retinochoroiditis is inflammation of the choroid (usually also inflammation of the retina).

b. **Signs/Symptoms.** A patient suffering from uveitis may have several signs and symptoms. The iris may be swollen and cloudy causing brown eyes to appear muddy and blue or gray eyes to seem dull or greenish. The pupil is often distorted by adhesions (synechias) to the lens. Extreme pain and photophobia (abnormal intolerance of or fear of light) along with occasional blurring of vision and transient myopia (nearsightedness) may be present. The pain may radiate to the forehead and temple. The patient's eye may seem to be severely infected and red with no discharge and a decrease in pupil size (less than 2 mm (normal being 4 mm)).

c. **Treatment.** It is important to diagnose and treat uveitis early to prevent the formation of posterior synechiae (adhesions of the iris to the cornea or to the lens of the eye). For treatment of this condition, refer the patient to the ophthalmology clinic. It takes from one to three weeks for uveitis to clear up. Recurrences of the condition are common.

### 3-7. CATARACTS

a. **Description.** A cataract is any opacity of the lens or its capsule. That is, the lens or its capsule loses its transparency; light cannot pass through the lens. The result is increasing loss of vision finally resulting in blindness unless treated. A person who has cataracts will usually be affected in both eyes.

b. **Signs/Symptoms.** A cataract may appear as a white or yellow discoloration in the lens. Any cataract that develops over a period of time (from months to years) is usually yellowish or light brown in color. A traumatic cataract usually appears white if it develops over a short period of time. This type of cataract is usually due to a metallic foreign body striking the lens such as a BB shot, darts, or rocks. A traumatic cataract may also be caused by overexposure to heat (glassblowers' cataract) or steel fragments. Opacities may develop anywhere in the lens; the location of the cataracts plus the pattern or shape may give an indication as to the cause. For example, a typical cataract due to long-term corticosteroid therapy will usually start in the posterior subcapsular area.

c. **Treatment.** For treatment of the cataract, refer the patient to the ophthalmology clinic.

### 3-8. CORNEAL ULCER

a. **Description.** As the name suggests, a corneal ulcer is an ulcer on the cornea of the eye. Corneal ulcers are a medical emergency. There are many causes of corneal ulcers: bacterial, viral, and fungal infections as well as allergic disorders.

b. **Signs/Symptoms.** Signs and symptoms include the following:

- (1) Mild eye irritation.
- (2) Photophobia.
- (3) Blurred vision.
- (4) Visible corneal ulcers.

c. **Treatment.** Management of this condition depends on the cause of the ulcer. In any case, refer the patient to the ophthalmology clinic. Prompt treatment is essential to prevent complications such as visual impairment due to corneal scarring or infection.

### 3-9. EYE STRAIN

Eye strain is a common eye complaint. Usually this condition indicates eye discomfort associated with prolonged reading, close work, or the use of binoculars. In order to assess the condition, it is necessary to screen the eye for a refractive error. Also, determine whether the patient works/reads in inadequate light or overuses dark glasses. Both may contribute to eye strain.

### 3-10. FLOATERS

Floater are also called "spots before the eyes." They are due to vitreous debris from the membranous attachment of the vitreous body to the optic nerve and retina. This condition is more prevalent in highly myopic (nearsighted) and older persons. The condition tends to become less noticeable with time. Bright lights may make the condition worse. These spots are relatively normal and insignificant unless the spots appear after trauma. Then, the spots may indicate that the retina has become detached.

### 3-11. BLEPHAROSPASM (TIC)

A blepharospasm (tic) is a persistent or repetitive involuntary contraction of the orbicularis oculi muscle. No one knows what causes this condition. The cause may be irritative lesions of the cornea. Tics can be aggravated by emotional stress and fatigue. A tic usually stops on its own. If it is persistent, the patient must be referred to the ophthalmologist.

### 3-12. HORDEOLUM (STYE)

a. **Description.** A hordeolum, usually called a sty, is a common staphylococcal abscess. It is an infection of the eyelid sebaceous glands. There are two types of hordeolum: internal hordeolum and external hordeolum. An abscess that points to the skin or to the conjunctival side of the eyelid is an internal hordeolum. An infection of the glands of Moll or Zeis results in an external hordeolum, a sty which appears on the margin of the eyelid.

b. **Signs/Symptoms.** The signs and symptoms of this disease are red, swollen eyelids with pus. The eyelids are also tender and painful.

c. **Treatment.** The disease can be treated with warm compresses held on the eyelids for ten to fifteen minutes three times a day. If this process does not clear up the condition within forty-eight hours, the patient must be referred to a doctor for incision and drainage. Treatment may also include instilling of ophthalmic antibacterials such as sodium sulfacetamide into the conjunctival sac every three hours or as ordered by the doctor.

### 3-13. EYELID DISORDERS

a. **Chalazion.** Chalazion is one of the three most common eyelid infections. (The other two are blepharitis and Phthirus pubis.) This infection is a common inflammation of a meibomian gland. It is characterized by localized swelling of the eyelids or a small or hard tumor. The infection may be preceded by a sty. There may be no inflammatory signs. The treatment for this condition is a surgical excision performed by a doctor. There may be some complications of chalazion such as cellulitis (spread of infection) over the entire eyelid. Another possible complication is astigmatism (faulty vision caused by imperfections in the curvature of the cornea). Astigmatism is caused by the pressure of the constantly swollen eyelid on the eyeball. Astigmatism results in uneven focusing in different planes, and the patient experiences visual distortion.

b. **Blepharitis.** This condition, an inflammation involving hair follicles and surface glands of the eyelids, is a common problem which affects the lid margins of both eyelids. The condition may be ulcerative or nonulcerative. Other conditions almost always associated with blepharitis are seborrhea of the scalp, the brows, and frequently the ears. Symptoms include sore eyelids and itching of the eyelid margins due to sticky exudate. Treatment of blepharitis consists of soap and water. Shampoo the scalp, eyebrows, and lid margins. Antibiotics applied topically may also be used.

c. **Phthirus pubis.** A third eyelid disorder, Phthirus pubis, is an infection caused by a crab louse which infects the eyebrow and the eyelid margins. The louse releases feces which irritate the affected areas and cause conjunctivitis. The symptom of the condition is an intense itching of the eye region. Treat the condition with mechanical removal of the louse and Kwell<sup>®</sup> shampoo.

### 3-14. ANTIBACTERIAL MEDICATIONS FOR EYE DISEASES

a. **Introduction.** Antibacterial medications are indicated for the treatment of superficial bacterial infections of the eye such as conjunctivitis, styes, and blepharitis. Secondary infection due to injury or viral infection should be prevented. The topical use of antibiotics, commonly used systemically, should be avoided because of possible sensitization in future use. Some preparations that can be used as antibacterial medications include sodium sulfacetamide (Sulamyd<sup>®</sup>), bacitracin ophthalmic, and gentamicin (Garamycin<sup>®</sup>).

b. **Sodium Sulfacetamide (Sulamyd<sup>®</sup>).** This medication may be used as a solution 10 to 30 percent or ointment 19 percent. The procedure consists of instilling one or two drops frequently, depending on the severity of the infection. Its bacteriostatic action is a broad spectrum against gram-positive and gram-negative organisms which inhibit the growth of microorganisms. The medication is contra-indicated in sulfa hypersensitive patients. Usually sodium sulfa-cetamide is ineffective in the presence of large or heavy purulent discharge.

c. **Bacitracin Ophthalmic**<sup>®</sup>. This is a standard ointment with bacteriostatic (gram-positive organisms) action against strains of staph and strep. A bacteriostatic agent is a medication that kills bacteria that is present and inhibits the growth of new bacteria. Gentamicin (Garamycin<sup>®</sup>) is also available in solution and ointment. It is gaining wide acceptance for use especially against infections caused by gram-negative organisms.

## **Section II. CONDITIONS OF THE EAR**

### **3-15. INTRODUCTION**

Conditions of the ear are classified and treated according to their location. Ear problems may be considered as diseases of the external ear, the middle ear, or the inner ear.

### **3-16. DISEASE OF THE EXTERNAL EAR--EXTERNAL OTITIS**

a. **Description.** External otitis varies in severity from a mild dermatitis to cellulitis or even furunculosis of the ear canal. This ear problem is often referred to as a fungal infection of the ear. In many cases, the problem is not an infection but dermatitis caused by contact with earphones or earrings.

b. **Signs/Symptoms.** Pain, itching, dry scaling ear canal, and watery or purulent discharge are the chief signs/symptoms of external otitis. Fever may be present if the infection is severe. Other signs and symptoms are erythema, edema, and pustule formation.

c. **Treatment.** Systemic treatment includes systemic antibiotics used when the spread of the infection is noted beyond the skin of the ear canal. Systemic analgesics are needed for pain. Local treatment is administered by thoroughly cleaning the ear canal, gently wiping, and then applying wax softener. Irrigation may be necessary. It is important to keep the ear canal dry. If necessary, use a wick saturated with antibiotic ointment or ear drops such as neomycin, polymyxin, and bacitracin. Compresses of Burrow's solution and 0.5 percent acetic acid can be applied.

### **3-17. DISEASE OF THE EXTERNAL EAR--CERUMEN IMPACTION**

a. **Description.** The cause of this disease is excessive secretion of cerumen, narrowing or twisting of the ear canal, or dryness or scaling of the skin in the ear canal.

b. **Signs/Symptoms.** Included are the following:

- (1) Decreased hearing.
- (2) Feeling of fullness of the ear.
- (3) Cough due to reflex stimulation of the vagus nerve.

(4) An otoscopy (tympanic membrane examination with an otoscope) reveals a mass of yellow, brown, or black wax buildup obscuring the view of the tympanic membrane.

c. **Treatment.** This condition is treated by irrigating the ear with a fifty/fifty solution of hydrogen peroxide and water from an ear syringe. Irrigation is done by pointing the stream to the superior wall of the ear canal. The solution should be at body temperature in order to prevent nausea.

### **3-18. DISEASE OF THE MIDDLE EAR--AUDITORY TUBE DYSFUNCTION**

Auditory tube dysfunction is a blockage due to upper respiratory infections (URI), pharyngitis, and other diseases. The blockage causes poor drainage. Fluid buildup eventually leads to serious otitis media if not treated. Auditory tube dysfunction can be treated with the Valsalva's maneuver. The Valsalva's maneuver consists of holding one's nose closed so that no air may escape then making an exhalation effort.

### **3-19. DISEASE OF THE MIDDLE EAR--OTITIS MEDIA**

a. **Description.** Otitis media is another middle ear condition. It is most common in infants and children, but it may also occur in adults. Usually, it happens after or along with an upper respiratory infection. The condition is bacterial in origin. The two types of otitis media are serous otitis media and purulent otitis media.

b. **Serous Otitis Media (SOM).** This condition is not caused by an infection. The infection is in the pharynx at the eustachian tube. Clear amber fluid with air bubbles has built up behind the tympanic membrane (TM).

c. **Purulent Otitis Media (POM).** POM occurs after an upper respiratory infection or bacterial (strep) pharyngitis. A yellowish-brown purulent fluid builds up behind the tympanic membrane.

d. **Signs/Symptoms of Otitis Media.** Included are the following:

- (1) Pain. The mastoid tap will be positive (causing pain.)
- (2) Deafness.
- (3) Fever.
- (4) Chills.
- (5) Feeling of fullness and pressure. Pressure may cause the tympanic membrane to rupture.

e. **Treatment.** Bedrest and analgesics such as aspirin are parts of the treatment for otitis media. Penicillin or broad-spectrum antibiotics continued for 7 to 10 days will help to prevent the recurrence of infection. In case of penicillin-allergic patients, give alternate drugs. A nasal decongestant will serve as an aid in the restoration of auditory tube function.

### **3-20. CONDITION OF THE MIDDLE EAR--TYMPANIC MEMBRANE PERFORATION**

a. **Description.** The cause of this condition is usually trauma but occasionally the problem is caused by acute otitis media.

b. **Signs/Symptoms.** Included are:

- (1) Occasional pain.
- (2) Hearing loss.
- (3) Blowing sensation in the ear caused by air passing through the tympanic membrane.
- (4) Occasional clear or purulent discharge may be present.

c. **Treatment.** Treatment should not include medications in the ear or any packing of the ear. Keep the ear dry and clean. An external dressing is recommended. Oral analgesia is not usually needed. The patient should be restricted from flying, swimming, or heavy contact with loud noises. Keep water out of the ear. Systemic antibiotics should be given only if infections occur. Evacuation is not urgent unless a flap is present. If there is only a small perforation, called a "pinhole," no treatment is necessary. Some complications of this condition are the failure to heal spontaneously, ear infection, and scarring.

### 3-21. DISEASE OF THE INNER EAR--LABYRINTHITIS

a. **Description.** Labyrinthitis is a suppurative (pus-forming) causing disease process arising from chronic otitis media. The cause of this disease includes trauma associated with concussion producing bleeding such as a crack in the cochlea and nasal skull fracture. The condition may be caused by cardiovascular diseases such as arteriosclerosis and certain allergies.

b. **Signs/Symptoms.** Included are:

- (1) Deafness and hearing loss.
- (2) Tinnitus.
- (3) Vertigo.
- (4) Nausea and vomiting.
- (5) Blurring of vision and nystagmus (involuntary jerking of eyes, sometimes fast and sometimes slow).
- (6) Staggered gait.

c. **Treatment.** Treatment for labyrinthitis should be confined to symptomatic treatment of the underlying cause, if that cause is known. Promethazine (Phenergan<sup>®</sup>) is used for motion sickness and thiethylperazine (Torecan<sup>®</sup>) is given for nausea and vomiting. The medical evacuation procedures should be done carefully. It may be dangerous aboard ship or aircraft.

### 3-22. DISEASE OF THE INNER EAR--TINNITUS

a. **Description.** Tinnitus is the perception of sound in the absence of acoustic stimuli. Tinnitus may be caused by irritation of nerve endings in the cochlea, by degenerative vascular diseases, or vasomotor diseases. Hearing sounds when there are none becomes worse when the patient drinks coffee, takes aspirin, or smokes a cigarette.

b. **Signs/Symptoms.** Common signs and symptoms include the following:

- (1) Buzzing.
- (2) Ringing.
- (3) Roaring.



(4) Whistling or hissing quality sounds. (This noise is bearable during the day but more disturbing during the quiet of night.)

(5) Warning signs related to tinnitus are degenerative nerve process, labyrinthine diseases, and tumors such as acoustic neuroma.

c. **Treatment.** Treatment for tinnitus is directed to the underlying causes, if the causes are known. If the cause is unknown, reassure the patient. The patient may find it helpful to play music softly at night. Those with difficult cases of tinnitus may be referred to an ENT (ears, nose, and throat) neurologist or a psychiatrist.

### **Section III. NASAL CONDITIONS/THROAT CONDITIONS**

#### **3-23. INTRODUCTION**

Nasal conditions are varied. They include septal deviation, septal ulceration and perforation, septal hematoma or abscess, rhinitis medicamentosa, and nasal polyps.

#### **3-24. SEPTAL DEVIATION**

a. **Description.** A septum consisting of bone and cartilage divides the nasal cavity into two passages. Some people have an absolutely straight septum, and some people have a very crooked septum. Often caused by trauma, a crooked septum can be present at birth. One nostril can be larger than the other when the septum is crooked. A very crooked septum can cause complete obstruction of one nostril and interference with sinus drainage.

b. **Signs/Symptoms.** Included are the following:

- (1) Nasal obstruction affecting one or both nostrils.
- (2) Increased nasal or postnasal mucus discharge.
- (3) Development of sinusitis due to inadequate sinus discharge.
- (4) Epistaxis (nosebleed) as a result of drying air currents.

c. **Treatment.** As treatment for this condition, refer the patient for septoplasty (surgical resection of the septum) as urgency requires. In this operation, an incision is made through the mucous membrane, and portions of the septum causing the obstruction are removed.

### 3-25. SEPTAL ULCERATION/SEPTAL PERFORATION

a. **Description.** Septal ulceration is an erosion of the mucous membrane of the nasal septum. The condition may occur in one nostril or in both nostrils. Perforation is the destruction of the septal cartilage or bone and mucous membrane on both sides of the septum. Septal ulceration or perforation may result from chronic trauma often caused by an attempt to remove dry mucus and crusting. Factors conducive to either septal ulceration or septal perforation include inadequate air humidification; breathing caustic chemical fumes; and septal deviation causing excessive drying of nasal membranes.

b. **Signs and Symptoms.** Other signs and symptoms include:

- (1) Nasal irritation.
- (2) Foreign body sensation.
- (3) Crust formation.

(4) Epistaxis (nosebleed). Epistaxis is usually the first sign. Small perforations may produce a whistling sound.

c. **Treatment.** The treatment for this condition is based on bacitracin ointment. Cases are referred to the Ear, Nose, and Throat clinic on a routine basis.

### 3-26. SEPTAL HEMATOMA (SEPTAL ABSCESS)

a. **Description.** Septal hematoma, a collection of pus held in a pocket beneath the mucous membrane, can occur after trauma to the nose or following septal surgery. The septum swells and causes nasal obstruction. An infected septal hematoma usually causes septal abscess.

b. **Signs and Symptoms.** The most common signs and symptoms of these conditions are:

- (1) Nasal obstruction.
- (2) Sensation of pressure.
- (3) Slightly elevated temperature and dull frontal headache which is present frequently.
- (4) Hematoma in one nostril may simulate a deviation.

c. **Treatment.** Refer the patient for incision and drainage (I and D). A small hematoma, watched closely to be sure it does not become infected, should resolve itself in four to six weeks. Another way of treating a small hematoma is to make an incision and drain it. If the hematoma is large, it must be drained. Treatment for a septal abscess consists of making a wide incision on one side of the septum, suctioning pus, and carefully removing necrotic tissue. Systemic antibiotic therapy to control infection may be required.

### 3-27. RHINITIS MEDICAMENTOSA

a. **Description.** Rhinitis medicamentosa is a chronic congestive condition associated with prolonged "overdosage" of local nasal medications. The condition is caused by nasal obstruction which is relieved initially by medications. The relief is short lived causing the patient to reuse nasal medications. Eventually, the nasal medications cause nasal membranes to swell rather than constrict (rebound effect).

b. **Signs and Symptoms.** Included are the following:

- (1) A diminished sense of smell (the most common symptom).
- (2) A small amount of thin mucoid.
- (3) Nasal discharge present in the nasal passages and in the nasopharynx.
- (4) Mucous membranes appear pale and atrophic in the nasal passages.

c. **Treatment.** Treatment consists of discontinuing use of nasal medications.

### 3-28. NASAL POLYPS

a. **Description.** Nasal polyps are growths of mucous membrane. These growths hang down from the posterior wall of the nasal septum. Called polyps, these growths look like bluish-white tumors. As they get bigger, they may fill the nasopharynx. The cause of nasal polyps is thought to be chronic irritation such as nasal rhinitis.

b. **Signs and Symptoms.** Included are the following:

- (1) Nasal obstruction.
- (2) Sneezing.
- (3) Watery nasal and postnasal discharge.
- (4) Impaired sense of smell. (Occurs when polyp is located superiorly impeding the direct contact of air and olfactory nerve endings.)

c. **Treatment.** Corticosteroids can relieve small polyps. If the polyps obstruct the airway or promote sinusitis, refer the patient for surgical removal. Nasal polyps are easily removed by a doctor using a nasal snare and cautery.

### **3-29. PERITONSILLAR ABSCESS**

a. **Description.** Peritonsillar abscess is a common condition of the throat. Also called quinsy, this throat problem occurs as a complication of acute tonsillitis. The infection spreads to the potential peritonsillar space between the tonsillar capsule and the constrictor pharyngis muscle. Mixed pyogenic organisms such as staph, strep, or pneumococci may be the cause of infection.

b. **Signs and Symptoms.** Included are the following:

- (1) Sore throat or tonsillitis becoming more severe on one side.
- (2) Increase of dysphagia (difficulty in swallowing).
- (3) Swelling of the soft palate and displaced uvula (away from the affected side).

c. **Treatment.** Refer the patient to a physician.

### **3-30. CLOSING**

The diseases dealt with here may not be life-threatening, but they can be painful thus preventing a soldier from doing his best. Much of your patient work load will be simple sick call. The management of these soldiers has a great impact on the Army's ability to complete the mission.

**Continue with Exercises**

### EXERCISES, LESSON 3

**INSTRUCTIONS.** The following exercises are to be answered by writing the answer in the space provided. After you have completed all the exercises, turn to solutions to exercises located at the end of the exercises and check your answers.

1. \_\_\_\_\_ also called conjunctival discharge is a visible indication of an active conjunctival infection.
  
2. \_\_\_\_\_ is an eye disease which can be acquired by contact with someone who has gonorrhea.
  
3. Exposure to infected genital secretions and/or chlamydiae in poorly chlorinated swimming pools is a source of the eye disease \_\_\_\_\_ conjunctivitis.
  
4. Herpes \_\_\_\_\_ is a common corneal ulceration which is caused by the herpes simplex virus (HSV).
  
5. The name of the tract which includes the iris, the ciliary body, and the choroid is the \_\_\_\_\_ tract. Any inflammation of this tract is called \_\_\_\_\_.
  
6. A traumatic cataract usually appears white if \_\_\_\_\_.
  
7. List three causes of corneal ulcers.
  - a. \_\_\_\_\_.
  - b. \_\_\_\_\_.
  - c. \_\_\_\_\_.

8. List three causes of eye strain.
- a. \_\_\_\_\_.
  - b. \_\_\_\_\_.
  - c. \_\_\_\_\_.
9. Another name for "spots before the eye" is \_\_\_\_\_.
10. A persistent or repetitive involuntary contraction of the orbicularis oculi muscle is called a tic or a \_\_\_\_\_.
11. A sty, a common staphylococcal abscess, is also called a \_\_\_\_\_.
12. List three eyelid disorders.
- a. \_\_\_\_\_
  - b. \_\_\_\_\_.
  - c. \_\_\_\_\_.
13. Dermatitis caused by contact with earphones or earrings can result in the external ear disease \_\_\_\_\_.
14. List two symptoms of the ear disease cerumen impaction.
- a. \_\_\_\_\_.
  - b. \_\_\_\_\_.
15. Valsalva's maneuver is one method of treating auditory tube dysfunction. What is Valsalva's maneuver? \_\_\_\_\_  
\_\_\_\_\_

16. List two signs/symptoms of otitis media.
- a. \_\_\_\_\_.
  - b. \_\_\_\_\_.
17. Labyrinthitis is \_\_\_\_\_
18. List three signs/symptoms of labyrinthitis.
- a. \_\_\_\_\_.
  - b. \_\_\_\_\_.
  - c. \_\_\_\_\_.
19. The patient hears buzzing, ringing, and whistling sounds, but none of these sounds are really happening. He may be suffering from the inner ear problem \_\_\_\_\_
20. List two signs/symptoms of the nasal condition septal deviation.
- a. \_\_\_\_\_.
  - b. \_\_\_\_\_.
21. Erosion of the mucous membrane of the nasal septum can cause \_\_\_\_\_.
22. Septal hematoma is \_\_\_\_\_
23. \_\_\_\_\_ is a chronic congestive condition associated with prolonged "overdosage" of local nasal medications.

24. Nasal polyps, growths resembling bluish -white tumors, hang down from \_\_\_\_\_  
\_\_\_\_\_.

25. A throat problem in which an acute tonsillitis infection spreads to the space  
between the tonsillar capsule and the constrictor pharyngis muscle is called  
\_\_\_\_\_.

**Check Your Answers on Next Page**



### SOLUTIONS TO EXERCISES, LESSON 3

1. Exudation. (para 3-2a)
2. Gonococcal conjunctivitis. (para 3-3a)
3. Inclusion. (para 3-4a)
4. Simplex keratitis. (para 3-5a)
5. Uveal.  
Uveitis. (para 3-6a)
6. It develops over a short period of time. (para 3-7b)
7. Bacterial infection.  
Viral infection.  
Fungal infection. (para 3-8a)
8. You are correct if you listed any three of the following:  
  
Prolonged reading.  
Close work.  
Use of binoculars.  
Inadequate light.  
Overuse of dark glasses. (para 3-9)
9. Floaters. (para 3-10)
10. Blepharospasm. (para 3-11)
11. Hordeolum. (para 3-12)
12. Chalazion.  
Blepharitis.  
Phthirius pubis. (paras 3-13a, b, c.)
13. External otitis. (para 3-16a)
14. You are correct if you listed any two of the following:  
  
Decreased hearing.  
Feeling of fullness of the ear.  
Cough due to reflex stimulation of the vagus nerve.  
Mass of yellow, brown, or black wax buildup blocking view of the tympanic membrane. (para 3-17b)

15. Valsalva's maneuver is holding one's nose closed and then making an exhalation effort. (para 3-18)

16. You are correct if you listed any two of the following:

Pain

Deafness

Fever.

Chills.

Feeling of fullness and pressure in the ear. (para 3-19d)

17. A suppurative inner ear disease. (para 3-21)

18. You are correct if you listed any three of the following:

Deafness/hearing loss.

Tinnitus.

Vertigo.

Nausea/vomiting.

Blurred vision and nystagmus.

Staggered gait. (para 3-21b)

19. Tinnitus. (para 3-22)

20. You are correct if you listed any two of the following:

Nasal obstruction affecting one or both nostrils.

Increased nasal or postnasal mucus discharge.

Development of sinusitis.

Epistaxis. (para 3-24b)

21. Septal ulceration. (para 3-25a)

22. A condition of pus held in a pocket beneath the mucous membrane. (para 3-26a)

23. Rhinitis medicamentosa. (para 3-27)

24. The posterior wall of the nasal septum. (para 3-28a)

25. Peritonsillar abscess. (para 3-29)

### **End of Lesson 3**

## LESSON ASSIGNMENT

### LESSON 4

HEENT Trauma.

### LESSON ASSIGNMENT

Paragraphs 4-1 through 4-19.

### LESSON OBJECTIVES

After completing this lesson, you should be able to:

- 4-1. Identify the signs, symptoms, and treatment for these facial injuries: blowout fracture; tripod fracture; mandibular fracture; maxillary fracture; and zygomatic fracture.
- 4-2. Identify the general considerations for eye injuries.
- 4-3. Identify the signs, symptoms, and treatment for the following ocular injuries: periorbital hematoma; conjunctival hemorrhage; anterior chamber hemorrhage; superficial foreign body in the eye; corneal abrasion; burns to the eye; penetrating eye injuries; eyeball knocked out of the socket; and eyelid injury.
- 4-4. Identify the signs, symptoms, and treatment for the following ear injuries/disorders: hematoma of the external ear; laceration of the external ear; perforation of the tympanic membrane; conductive deafness; and foreign bodies in the ear.
- 4-5. Identify the signs, symptoms, and treatment for the following nose injuries: epistaxis; fracture of the nose; and foreign bodies in the nose.
- 4-6. Identify the signs, symptoms, and treatment for the following throat injuries: foreign bodies in the oropharynx and foreign bodies in the esophagus.

### SUGGESTION

After completing the assignment, complete the exercises of this lesson. These exercises will help you to achieve the lesson objectives.

## LESSON 4

### HEENT TRAUMA

#### Section I. HEAD INJURIES

##### 4-1. INTRODUCTION

Trauma can cause injuries to the bones of the face. Such trauma is usually the result of industrial accidents, falls, sporting accidents, and fist fights. Automobile accidents, however, are the most common cause of injuries to facial bones. Most major injuries of this type are dealt with by a specialist, but initial treatment is of vital importance to the patient. Suspect the possibility of a facial fracture if you note the following:

- a. Blood in the airway.
- b. Facial deformity.
- c. Black eye(s) discoloration below the eye(s).
- d. Lower jaw which is swollen/poor jaw function.
- e. Loose or broken teeth/knocked out teeth/broken dentures.
- f. Other indications of a severe blow to the face.

##### 4-2. FACIAL FRACTURES

###### a. **Blowout Fracture.**

(1) Description. A blowout fracture is a fracture in the orbital floor, the bottom of the eye socket. The orbit is the cavity in the skull which contains the eyeball. Commonly, the orbit is called the eye socket. The bottom or floor of the orbit is thin bone, and a blow by a blunt object such as a fist or a baseball bat can fracture or break the bone on the bottom of the eye socket. A blowout fracture is usually not associated with other facial fractures such as fractures of the orbital rim or other facial bones. When the bone at the bottom of the eye socket is broken, the eye drops down out of position causing eye function problems.

(2) Signs/symptoms. Included are the following:

- (a) Pain.
- (b) Swelling.

- (c) Ecchymosis (bruise).
- (d) Diplopia (double vision)
- (e) Enophthalmos (displaced eyeball receding in orbit).
- (f) Limited eyeball motion upward inward, upward outward, and downward gaze on the injured side.

(3) Diagnosis. Diagnosis is made by taking a patient history. Did the patient experience a direct blow to the soft tissues of the orbit? Conduct a physical examination of the movement of the eyes. The coordinated action of six muscles controls the movement of each eye. Asking the patient to move his eyes in a specific direction can not only test the function of the six muscles but also help determine the presence of a blowout fracture. In order to test the eye movement of the patient, ask him to follow your finger or a pencil as you move through the six cardinal fields (directions) of gaze. Moving your finger or a pencil at a comfortable distance from the patient, ask him to look to the right; upward to the right of the midline; straight down; to the left; upward to the left of the midline; straight down.

(4) Treatment. Protect the area from further injury. Evacuate the patient for further evaluation.

#### **b. Tripod Fracture.**

(1) Description. A tripod fracture is caused by a blow to the cheekbone. The fracture occurs at the juncture of three bones in the cheek.

(2) Diagnosis. Diagnosis is made by taking a patient's history. Did the patient suffer a blow to the cheekbone? A physical examination should reveal a lessened sensitivity to touch in the affected area.

(3) Treatment. Protect the area from further injury. Evacuate the patient for further evaluation.

#### **c. Mandibular Fracture.**

(1) Description. The mandible is the lower jaw. Mandibular fractures are very common and usually not life-threatening. The mandible bone is very strong, but there are areas of relative weakness where fractures can occur. Mandibular fractures occur more often in areas without teeth than areas with teeth. The patient may only complain of one area of tenderness. Since the force of any blow to the mandible is very strong, look for fractures in other facial areas.

(2) Signs/symptoms. Included are the following:

- (a) Pain without motion.
- (b) Tenderness over the site of the fracture.
- (c) Swelling.
- (d) Bruise.
- (e) Malocclusion (teeth do not close properly to chew).
- (f) Cannot open mouth.
- (g) Excessive salivation.
- (h) Facial appearance is abnormal.
- (i) No feeling in the lower lip.

(3) Treatment. Protect the area from further injury. Evacuate the patient for further evaluation. Wiring and or surgery of the jaw may be required.

**d. Maxillary Fracture.**

(1) Description. The maxilla, the upper jaw bone, is located in the middle third of the face and is a stable, sturdy structure. A great amount of force is required to fracture this bone. The most common cause of maxillary fracture is an automobile accident. There may be massive hemorrhaging due to laceration of major vessels in the nasopharyngeal area from the force of the blow which caused the fractures. These fractures have the potential to be life-threatening since airway obstruction and exsanguination (bloodlessness) may occur. Airway obstruction may be caused by displacement of the maxilla.

(2) Signs/symptoms. Included are the following:

- (a) Pain.
- (b) Swelling.
- (c) Ecchymosis (bruise).
- (d) Malocclusion (teeth do not close properly for chewing most common sign).
- (e) Palpable fracture separations.

(3) Treatment. Protect the area from further injury. Evacuate the patient for further evaluation. Usually, a specialist will need to wire the jaw and perhaps perform surgery.

**e. Maxillary and Zygomatic Fractures.**

(1) Description of zygoma or malar bone (cheek bone) problem. The cheek bone occupies a prominent position in the structure of the face. The zygomatic bone meets other facial bones at three points. If there is trauma to the zygoma, a problem usually occurs at one of these three points. Sutures are another name for the three points: the zygomaticofrontal suture, the zygomaticomaxillary suture, and the zygomaticotemporal suture. The zygoma is in a prominent position and liable for all kinds of trauma, but the most common trauma is from blows of fists. Blows to the zygoma may cause the bone to move in almost any direction, but it usually is displaced downward and inward.

(2) Signs/symptoms. Included are the following:

- (a) Pain.
- (b) Swelling.
- (c) Ecchymosis (bruise).
- (d) Epistaxis (nosebleed) on one side if injury at zygomaticomaxillary suture or if maxillary sinus lining is torn.
- (e) Pain on opening the mouth.
- (f) Injured side of face flattened or depressed.
- (g) Teeth don't make proper contact for chewing.

(3) Treatment of oral fractures (mandible, maxilla, zygoma).

- (a) Protect the patient from further injury.
- (b) Evacuate for further evaluation.
- (c) Usually requires wiring of jaw and/or surgery.

## Section II. EYE INJURIES

### 4-3. GENERAL CONSIDERATIONS

a. **Key Considerations in Initial Care.** Be careful about moving the patient's head. Try to immobilize head movement. Avoid pressure when examining the patient. Have the patient avoid coughing or straining, if possible. Do not use Betadine<sup>®</sup> on the patient's eyes. Continually reassure the patient.

b. **Evacuation.** Transport the patient in the supine position with his upper torso elevated 15 to 30 degrees. When the patient is being evacuated by air, give oxygen as indicated. Advise the air crew to climb slowly and avoid abrupt maneuvering. The aircraft cabin should be at sea level pressure, and the aircraft should be flying at low level. Request that you be informed of any change in flight altitude.

### 4-4. NONPENETRATING EYE INJURIES

#### a. Periorbital Hematoma (Black Eye).

(1) Description. A hematoma may be described as an abnormal mass of blood located outside the blood vessels. The cause of a periorbital hematoma, a black eye, is usually blunt trauma to the orbital region; for example, as a result of a fist fight.

(2) Signs/symptoms. Included are the following:

(a) Swelling of soft tissue.

(b) Discoloration (black and blue spot on the skin caused by escaped blood from injured blood vessels).

(3) Treatment. Recommended treatment is application of cold packs for 24 to 36 hours. Analgesics may be taken for pain. A blow heavy enough to cause periorbital hematoma may also cause underlying injuries. It is, therefore, very important to assess the patient for underlying fractures.

#### b. Subconjunctival Hemorrhage.

(1) Description. This type of hemorrhage is often spontaneous and usually occurs in only one eye. This condition may occur after a bout of sneezing, coughing, or vomiting.

(2) Signs/symptoms. The hemorrhage will appear bright red with sharp delineations. The hemorrhage stops at the corneoscleral limbus. The condition is asymptomatic with the accumulated blood being absorbed in two or three weeks.



(3) Treatment. Included are the following:

- (a) Apply cold packs.
- (b) Reassure the patient.

**c. Anterior Chamber Hemorrhage (Hyphema).**

(1) Description. Hyphema is hemorrhage into the anterior chamber of the eye. The most common cause is bleeding from the iris blood vessel. Other causes include irritation, infection, inflammation, trauma, tumors, or increased intraocular pressure.

(2) Signs/symptoms. Included are:

- (a) Fluid level visible with the patient seated.
- (b) Blurred vision.

(3) Treatment. Treatment consists of absolute bed rest with the body elevated at a 45 degree angle for four to five days. Place a binocular patch over the patient's eyes so that he will not move his eyes. Give analgesics for pain, and evacuate the patient. DO NOT put any medication in the eye.

**d. Superficial Foreign Body.**

(1) Description. Foreign bodies in the cornea make up about 25 percent of all eye injuries. These injuries are usually not extensive.

(2) Symptoms. Included are the following:

- (a) Discomfort.
- (b) Blurred vision.
- (c) Sensitivity to light.

(3) Signs.

- (a) Increased tearing.
- (b) Redness.

(c) **Visible foreign body.** Sometimes you can look at the cornea of the patient's eye and see that there is something on the cornea. If the patient complains of feeling something on the eye, but you see nothing try looking at his eye through a magnifying glass.

(4) **Treatment.** Topical anesthetic (tetracaine 0.5%, 2 drops) is given only for foreign body object removals. NEVER give the patient anesthetic drops to use. One method of removing the foreign object is to irrigate the eye with normal saline in an attempt to wash out the foreign body. Removal may be attempted with a wet swab. NEVER dab with a dry cotton tip because the cotton tip leaves fuzz in the eye. To control infection after the removal of the foreign object, Polysporin<sup>®</sup> (polymyxin B--bacitracin) or gentamicin drops or ointment may be used. Patch the injured eye for comfort, and examine the eye daily for evidence of infection.

**CAUTION:** Any object or medication placed in the eye must be sterile and made for ophthalmic use only. Healing should occur within 24 or 25 hours.

e. **Abrasions (Corneal).** A corneal abrasion is a scratch on the surface of the cornea. This type of scratch can be caused by a foreign body--cinder, piece of dust, dirt, grit--that becomes embedded under the eyelid. The cornea may still be scratched even if tears wash out the foreign body. Other causes of corneal abrasion include scratch by a fingernail or piece of paper. Symptoms of corneal abrasion are the same as for superficial foreign body: increased tearing, redness, etc. Treatment includes topical application of antibiotics such as polymyxin B or gentamicin. Patch the injured eye for a period of 12 to 24 hours. Check the eye each day to see how the abrasion is healing.

f. **Burns.** Heat, light, or chemicals can cause burns to the eyes. Burns caused by ultraviolet radiation such as sunlamps or sunlight or burns caused by electrical flash are usually self-limiting. A chemical burn, however, is a medical emergency.

(1) **Eyelids.** Sometimes only the eyelids are burned. Don't try to inspect the eyes to see if they are damaged. Instead, have the patient close his eyelids and cover his eyes with sterile, moist fluff dressings.

(2) **Eyes--extremes of light burns.** It is possible to suffer burns to the eyes from extended periods of exposure to the brightness of sun reflected from sand or snow or from the flash of an arc welder. Gradually, the patient experiences eye pain and has the sensation that sand has blown in his eyes. Treatment includes placing moist patches over the patient's eyes and keeping at rest in the supine position with his upper torso elevated fifteen to thirty degrees. Meperidine (Demerol<sup>®</sup>), a narcotic analgesic, can be given as required for pain.

(3) Eyes--chemical burns. Chemical burns constitute a medical emergency and require immediate care. If sterile water is available, use it to flush the chemical substance out of the eyes. Use tap water if no sterile water is available. Wash the eyes for at least five minutes. Keep a steady stream of water flowing from the medial to the lateral part of the eye. If the chemical was an alkali, continue to flush the eyes for at least fifteen minutes. Alkali substances continue to burn tissues even when the substance has been diluted. After you have thoroughly flushed the eyes, close the patient's eyelids and apply a loose sterile dressing. Administer narcotic analgesics as needed for pain and evacuate the patient.

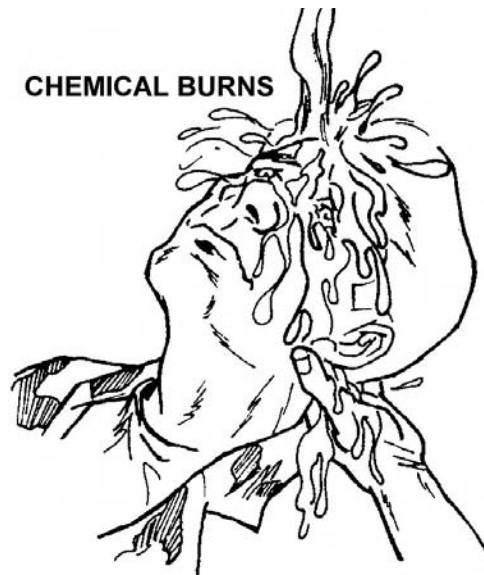


Figure 4-1. Treatment for burns to the eyes.

#### 4-5. PENETRATING EYE INJURIES

a. **Description.** Penetrating eye injuries may occur with or without the foreign body remaining in the eye. Objects which can penetrate the eye include metallic chips from metal-on-metal blows or from grinding wheel injuries and glass fragments. There is a strong possibility that a foreign body in the eye can cause mechanical damage (problems is moving and focusing the eye) or infection in the eye.

b. **Symptoms.** Determine whether the patient was in an area where metal was being pounded on metal just before the injury and whether he felt a sharp eye pain while in that area. Pain is variable, sometimes strong and sometimes minor. Strangely enough, a tiny object can penetrate the eye with the patient experiencing almost no pain. He may, however, have double vision.

c. **Signs.** Included are the following:

(1) Visible foreign body within the eyeball. (Small objects which have penetrated the eyeball are sometimes not visible except with special equipment.)

(2) Visible tear in the globe.

(3) Contents of the eyeball coming out of the eyeball.

(4) The pupil of the eye looks irregular rather than round.

d. **Protection.** The goal is to provide protection so that the eye is not damaged further. A doctor will need to remove an object that is impaled or imbedded in the eye. Follow this procedure:

(1) DO NOT manipulate the foreign body; leave it in place.

(2) DO NOT put medicines in the eye.

(3) Give the patient narcotic analgesics as required for pain.

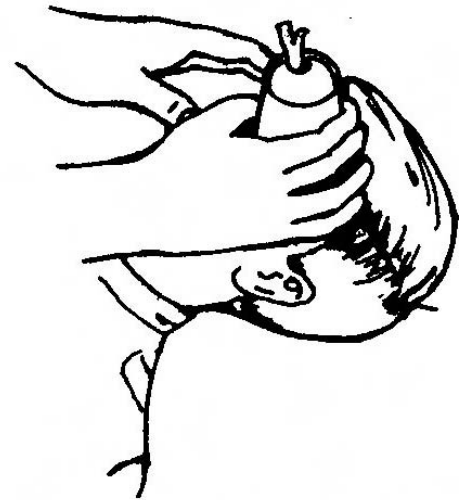(4) Tell the patient that you must bandage both eyes to protect the injured eye.

(5) Wrap a gauze dressing or other suitable material around the affected eye.

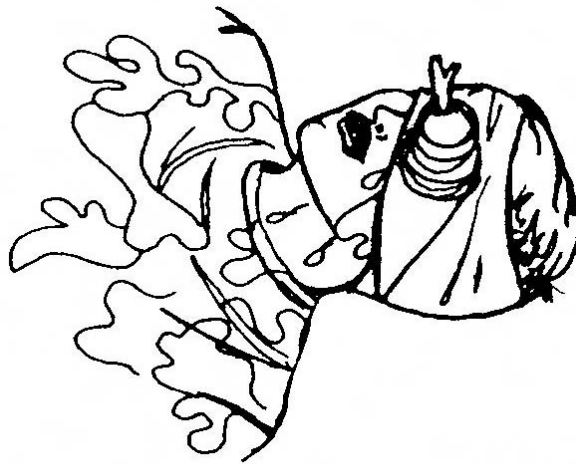
(6) Place a crushed cup or cone over the embedded/impaled object. Be sure the object does not touch the top or sides of the cup. (Cut out the top of the cup for an impaled object such as an arrow.)



**IMPALED OBJECT IN EYE**



**DRESS AND STABILIZE  
IMPALED OBJECT**



**BANDAGE THE CUP IN PLACE**

Figure 4-2. Impaled object in the eye.

(7) Use a compress or roller bandage that covers both eyes to hold the cup and dressing in place. (The bandage must cover both eyes to prevent movement of the injured eye.)

(8) DO NOT leave the patient alone. He may become frightened with both eyes bandaged and accidentally move his hand into the impaled object causing more eye damage. Keep in hand contact with the patient so that he will know someone is there.

(9) Put sand bags or large pads around the patient's head so that his head will not move. Transport the patient on his back.

(10) If the patient is unconscious, close his eyes as much as possible before bandaging to keep eye tissues from drying. (Blindness can be caused by drying tissues.) Closed eyes allows moisture from normal tears to keep tissues moist.

(11) Keep the patient at rest in the supine position with his upper torso elevated fifteen to thirty degrees.

(12) Evacuate the patient.

#### **4-6. ENUCLEATION/EYEBALL KNOCKED OUT OF SOCKET**

Enucleation is the complete surgical removal of the eyeball. Enucleation could also be the eyeball being knocked completely out of the socket so that the eyeball does not rupture. The eyeball will rarely be knocked completely out of the socket. Follow this procedure for an eyeball being knocked partially out of the socket:

- a. DO NOT try to put the eye back in the socket.
- b. Cover the eye with a moist covering and a protective cup. DO NOT apply pressure to the eye.
- c. Apply a bandage compress or roller bandage to cover both eyes.
- d. Position the patient with his face up.
- e. Evacuate the patient to a medical treatment facility.

#### **4-7. EYELID**

a. **Lacerated or Partially Torn Eyelid(s).** Return the eyelids to their normal anatomic position. Cover the injured lid(s) completely with a moist dressing. Make the dressing snug enough to hold any pieces of skin in place. Patch both eyes, reassure the patient, and evacuate him to a medical treatment facility.

b. **Completed Separation of Eyelid(s).**

(1) Eyelid separated--half eyelid. Recover eyelid(s) fragment(s) and put the pieces in the normal anatomic position as much as possible. Lower the lid(s) which was separated. Pull the upper lid down to cover the eye and tape the lid in place. Cover the injured area with moist gauze and evacuate the patient to a medical treatment facility.

(2) Eyelid separated--eyelid lost. If the upper eyelid is lost, cover the eyeball with ophthalmic ointment. Examine the eyeball to be sure there is no penetrating injury. Then, patch both eyes. Reassure the patient and evacuate him to a medical treatment facility. If evacuation cannot be accomplished in twenty-four hours for either eyelid injury, consider giving the patient antibiotics.

## Section III. EAR INJURIES/DISORDERS

### 4-8. GENERAL CONSIDERATIONS

Most ear injuries and disorders are not fatal. Instead, they may cause serious communication problems. Untreated hearing loss or deafness can impair a person's ability to interact with others. Additionally, ear disorders can disturb an individual's equilibrium (balance)

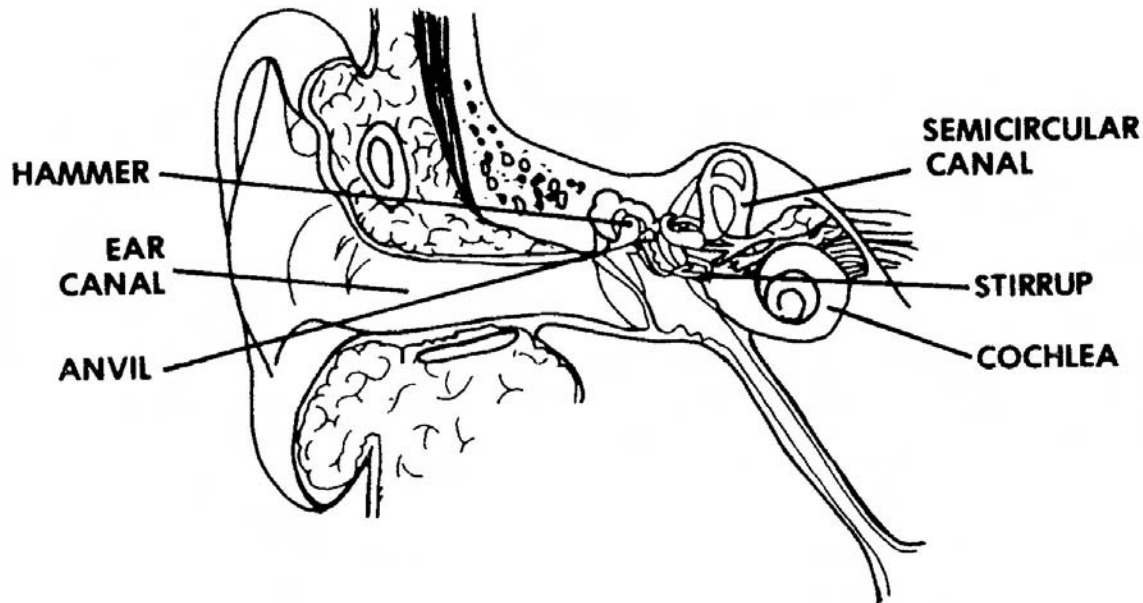


Figure 4-3. Structure of the ear.

### 4-9. HEMATOMA OF THE EXTERNAL EAR

a. **Description.** The external ear is in an exposed position; therefore, external ear injuries are very common. Hematoma of the external ear, as accumulation of blood outside the blood vessels, is caused by a blow to the ear by something blunt. The accumulation of blood interrupts the nutrition to underlying cartilage. Treatment is essential not only to restore blood supply to the cartilage but also to avoid deforming and thickening of the ear.

b. **Treatment.** For an accumulation of blood without swelling, apply cold compresses to limit the spread of edema and discoloration. Give analgesics for pain. If the accumulation of blood is large, aspirate (remove the fluid with a 16-gauge or 18-gauge needle) the hematoma. Apply a pressure dressing and observe the area for recurrence of the hematoma.

**CAUTION:** Failure to provide proper treatment can result in the patient having a "cauliflower" ear.

#### 4-10. LACERATION OF THE EXTERNAL EAR

a. **Description.** There are two types of ear lacerations: simple and complex. Simple ear lacerations involve a tear in the skin. Complex ear lacerations involve a tear in the ear cartilage also.

b. **Treatment.** Reconstructing an external ear laceration must be done very carefully in order not to cause a physical deformity. For both simple and complex ear lacerations, apply a pressure dressing to stop the bleeding. Bandage the dressing in place, and evacuate the patient to a medical treatment facility. See figure 4-4, 4-5, and 4-6, for types of ear lacerations and methods of repair at medical treatment facilities.

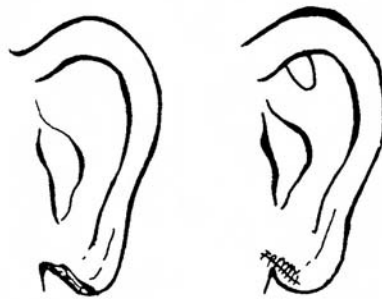


Figure 4-4. Laceration/repair of the earlobe.

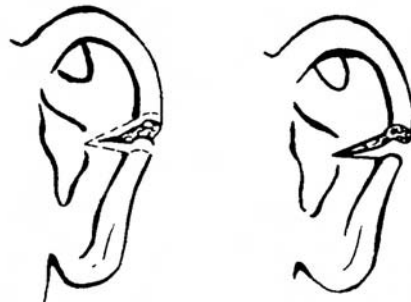


Figure 4-5. Laceration/natural healing of the ear.

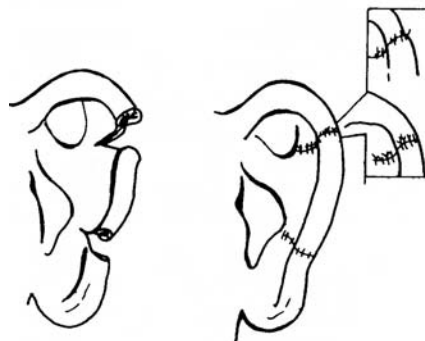


Figure 4-6. Laceration/accurate alignment repair of external ear.



#### 4-11. PERFORATION OF TYMPANIC MEMBRANE

a. **Description.** The tympanic membrane, the part of the middle ear which is also called the eardrum, is very delicate. This membrane can be injured by violent vibrations of air such as the explosion of a bomb or the firing of a heavy gun. Diving and blows to the head with cupped hands can also cause a perforation (hole or series of holes) in the tympanic membrane.

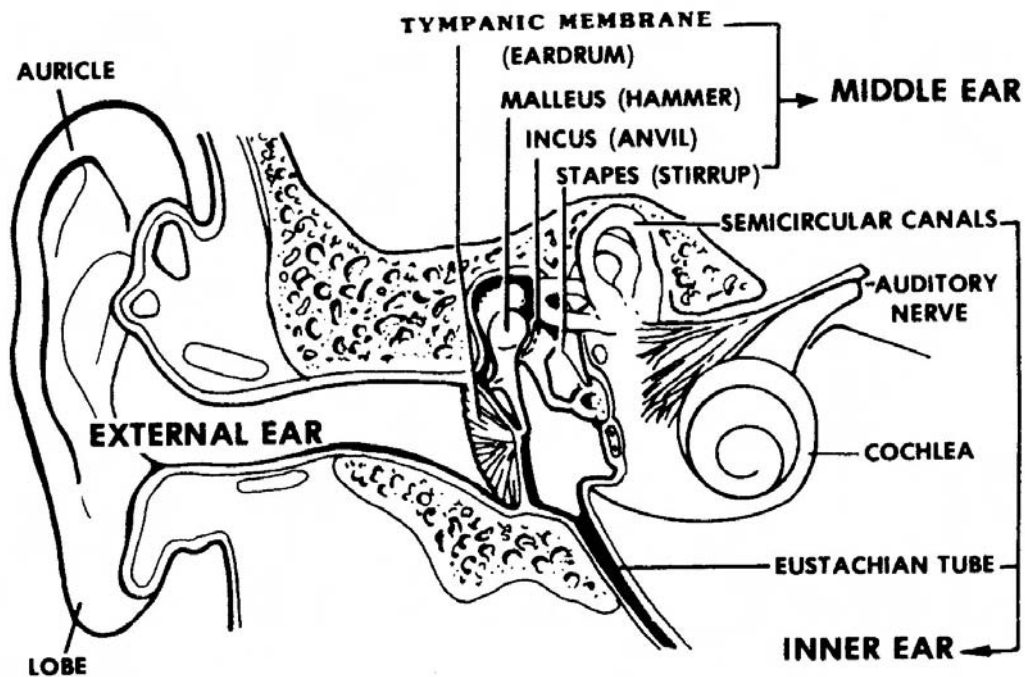


Figure 4-7. Structures of the ear showing the tympanic membrane.

b. **Signs and Symptoms.** Included are the following:

- (1) Severe pain initially.
- (2) Tinnitus (ringing, buzzing, or roaring noises in the ear).
- (3) Hearing loss, sometimes.

c. **Treatment.** DO NOT put medications in the ear. DO NOT put packing in the ear. Put a dressing on the external ear to keep the ear dry and clean. Then, follow this procedure:

- (1) Restrict the patient from flying, swimming, and contact with loud noises.
- (2) Advise the patient to keep water out of his ear.

- (3) Give systemic antibiotics only if infection occurs.
- (4) Analgesics may be given orally but are usually not necessary.
- (5) Evacuate the patient. Evacuation is not urgent unless the tympanic membrane is flapping.

d. **Complications.** Included are:

- (1) Failure to heal spontaneously.
- (2) Ear infection.
- (3) Impairment of hearing.

#### 4-12. CONDUCTIVE DEAFNESS

a. **Description.** Hearing loss is caused by a problem in the transmission of sound waves--a mechanical or nervous problem in transmission. One of the major forms of loss of hearing is conductive hearing loss which is the interrupted passage of sound from the external ear to the site where the stapes and the oval window meet. Conductive deafness is due to a defect of the sound conducting apparatus.

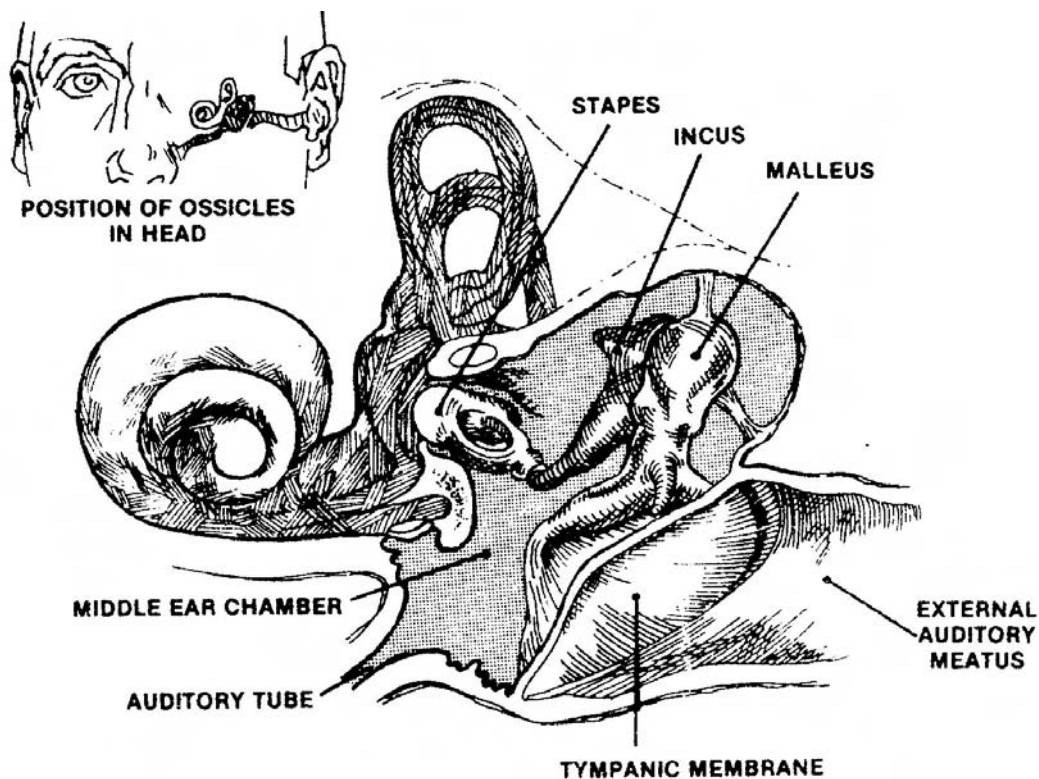


Figure 4-8. Ear structure.

b. **Causes.** Included are the following:

(1) Malformation of the external or middle ear present from birth.

(2) Trauma to the tympanic membrane or the ossicular chain (the three small bones of the ear (malleus, incus, and stapes) which form a bony chain across the middle ear chamber and conduct sound waves from the tympanic membrane (eardrum) to the oval window).

(3) Inflammatory ear diseases.

(4) Otosclerosis (spongy bone forming and growing in the capsule of the middle ear interfering with conduction of sound waves and resulting in gradual hearing loss).

(5) Use gentle pressure when flushing the liquid into the ear canal. Strong pressure of liquid may only force the object deeper into the ear.

c. **Treatment.** Resolve the ear infection if there is one. Surgery can sometimes repair defects the patient is born with or acquired abnormalities of the external ear canal or middle ear structure which interfere with hearing.

#### **4-13. FOREIGN BODIES IN THE EAR**

a. **Description.** Foreign objects are sometimes blown into the ear by explosions, etc. Such objects must be removed or damage to the ear parts or loss of hearing can occur.

b. **Signs/Symptoms.** Included are:

(1) Pain.

(2) Itching.

(3) Conductive hearing loss.

(4) Fullness sensation.

(5) Foreign object in the ear can be seen.

c. **Treatment.** If you are sure the object has not perforated the eardrum, follow this procedure:

- (1) Fill a bulb syringe with alcohol.
- (2) Have the patient lie down with the ear with the foreign object over a basin.
- (3) Put the syringe tip near the top part of the entrance to the external ear.
- (4) Flush liquid rapidly into the ear canal.
- (6) Evacuate the patient if the object cannot be flushed out of the ear.

## **Section IV. NOSE INJURIES**

### **4-14. EPISTAXIS (NOSE BLEED)**

a. **Description.** Epistaxis, bleeding from the nose, may be either a primary disorder or a problem caused by another health condition. Nose bleeds in adults usually originate in the posterior septum and can be severe. Usually, a nose bleed occurs as a result of external or internal trauma; for example, a blow to the nose, nose picking, or insertion of foreign objects. Nose bleeds can also be caused by polyps (growths in the nasal cavity), acute or chronic infections such as sinusitis or rhinitis, or inhalation of chemicals that irritate the nasal mucosa. Factors which increase the possibility of nose bleeds include:

- (1) Anticoagulant therapy (patient is taking medication which prevents blood from clotting rapidly).
- (2) Chronic use of aspirin.
- (3) High altitudes and dry climates.
- (4) Scurvy.
- (5) Vitamin K deficiency.
- (6) Arterial hypertension (HTN) and hemorrhage diseases.
- (7) Leukemia.

b. **Signs and Symptoms.** Blood oozes from the nostrils. The blood may be bright red if it comes from the anterior nose. Blood from the back of the throat may be dark or bright red. The amount of blood may be great or small; there may or may not be pain. Ninety percent of all nose bleeds occur at the anterior of the septum. Ten percent occur in the posterior portion of the nose. A person having a moderate nose bleed may feel light-headed, dizzy, and have slight respiratory difficulty. A person having a severe hemorrhage may experience a sudden drop in blood pressure, rapid and bounding pulse, dyspnea pallor, and other indications of progressive shock.

c. **Evaluation.** Begin by questioning the patient. Ask how long the bleeding has been taking place and if he has a history of vascular disease. Then, estimate how much blood the patient has lost. Check the patient's vital signs: temperature, pulse, respiration, and blood pressure. Determine the location of the bleeding in this manner: for anterior bleeding, inspect the nasal cavity closely. Clean the nasal cavity with clean cotton tipped applicators dipped in sterile water. Use an otoscope or nasal speculum to inspect the nasal cavity gently. For posterior bleeding, have the patient in a sitting position. Be sure your light source is adequate. Have the patient hold his tongue or you use a tongue depressor to hold his tongue down. Visually inspect. If the patient has vomited, he may have swallowed large amounts of blood.

d. **Treatment.** Follow this procedure:

(1) Position the patient. A patient with no other signs or symptoms of injuries should be in a seated position, leaning slightly forward. Then, blood and mucus can drain well. If the patient cannot sit because of other injuries, have him lay back with his head elevated slightly or have him turn his head to one side. For an unconscious or possible spinal damage patient, immobilize the neck and spine before you position him. If possible, all patients should have the head and upper torso elevated.

(2) Apply local pressure. Apply pressure to the affected nostril. For anterior bleeding, pack the affected area with petrolatum strips sprayed with epinephrine. For posterior bleeding, use nasogastric tubes to control the bleeding.

(3) Medication. Vasoconstrictor drugs may be administered (drugs which narrow the blood vessels).

(4) Bleeding. Cauterize if the bleeding does not stop.

#### **4-15. FRACTURE OF THE NOSE**

a. **Description.** Fracture of the nose is a common injury, usually the result of a blunt blow. The direction, type, and force of the blow to the nose determine the severity of the fracture. Adequate and immediate treatment is necessary to prevent permanent problems such as nasal displacement, septal deviation, or nasal obstruction.

b. **Signs/Symptoms.** Included are the following:

- (1) Position of the nose (appears abnormal; possible deformity of septal deviation).
- (2) Pain and edema (swelling).
- (3) Epistaxis (nose bleed).

c. **Treatment.**

(1) Control hemorrhage. Apply cold compresses for mild bleeding and edema. For anterior bleeding, have the patient press the affected nostril closed with his fingers and hold the nostril closed for five minutes at a time. Be sure the entire nostril is pressed closed. Cauterize with electrocautery (cauterizing instrument with platinum wire, heated by electrical current). If this instrument is not available, cauterize with silver nitrate. Pack the affected nasal passage with one-half Vaseline<sup>®</sup> impregnated gauze or antibiotic ointment on gauze. Use antibiotics on gauze if the pack is to remain in place for forty hours or more. Gauze with antibiotics may be left in place for as long as five to six days if necessary. For posterior bleeding, anesthetize the area with a solution of four percent cocaine. Perform posterior packing: a Red Robinson catheter and nasogastric tube as well as tonsil packing. The patient must be hospitalized and on complete bed rest. Antibiotics should be given as needed. A patient experiencing uncontrolled bleeding should be medically evacuated for further electrocautery or artificial ligation (surgical tying of a blood vessel).

(2) Bone displacement. Determine whether a bone has been moved out of its proper place by x-ray.

(3) Bone realignment. A bone which is out of its proper position may be realigned if the patient is given local anesthetic. At a later time, rhinoplasty (plastic surgery/surgical reconstruction of the nose) can be used to correct an out of place bone.

(4) Bilateral nasal packing.

- (a) Insert a catheter in the nostrils.
- (b) Draw the catheters through the mouth.
- (c) Tie a suture from the pack to each catheter securing the pack in place. See figure 4-9(A).
- (d) Draw the catheters back through the nostrils as shown in figure 4-9(B).
- (e) Hold the sutures tightly and insert packing into the anterior nose.

(f) Secure the sutures around a dental roll. The middle suture, extending through the mouth, should be secured on the cheek. See figure 4-9(C).

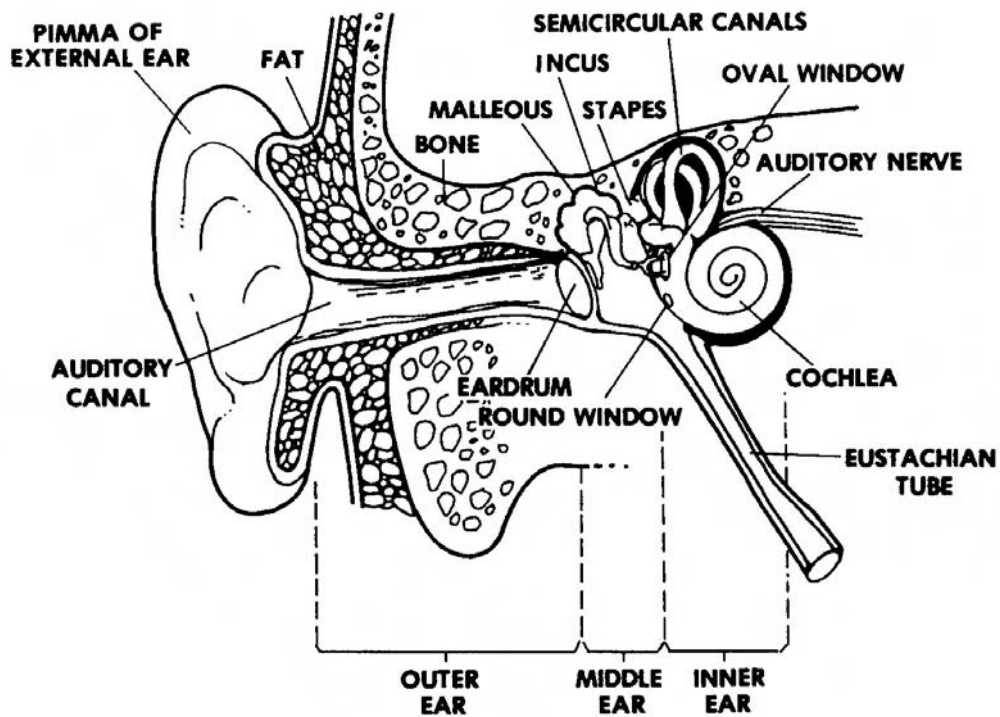


Figure 4-9. Insertion of anterior-posterior nasal pack (continued).

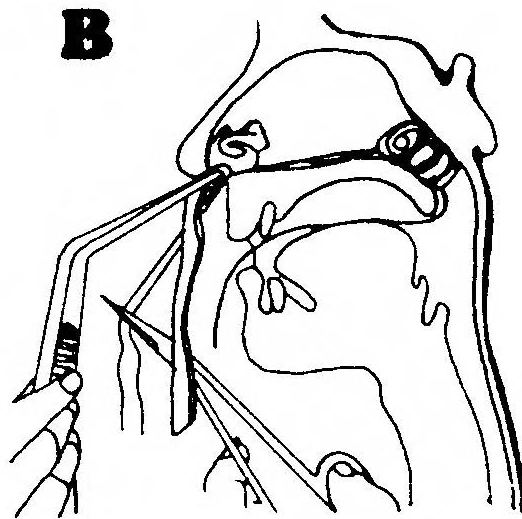


Figure 4-9. Insertion of anterior-posterior nasal pack (continued).

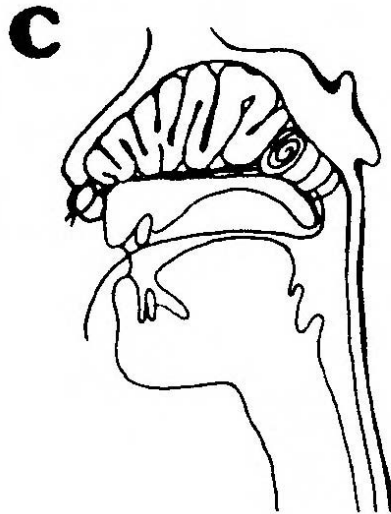


Figure 4-9. Insertion of anterior-posterior nasal pack (concluded).

(5) External splint. Follow this procedure to splint a nose:

- (a) Place one or two thicknesses of soft cotton roll over the nose.
- (b) Cut four thicknesses of fast-setting ordinary plaster of Paris. (The plaster of Paris will relieve the pressure over the inner canthus of each eye.)
- (c) Gently mold the wet plaster to the shape of the glabella (smooth area of frontal bone between the eyebrows) and the nasal bones.
- (d) Turn the edges of the cotton upward to protect the skin from the edges of the plaster.
- (e) Two small plaster strips may be placed along each side of the nose for extra strength.
- (f) Using your fingers, hold the plaster in position against the bridge of the nose until the plaster becomes firm.
- (g) Secure the plaster splint to the cheeks and the forehead with adhesive tape.
- (h) Place removable gauze lightly taped across the end of the nose to control secretions from nasal packing.
- (i) Leave the splint in place for about five days.



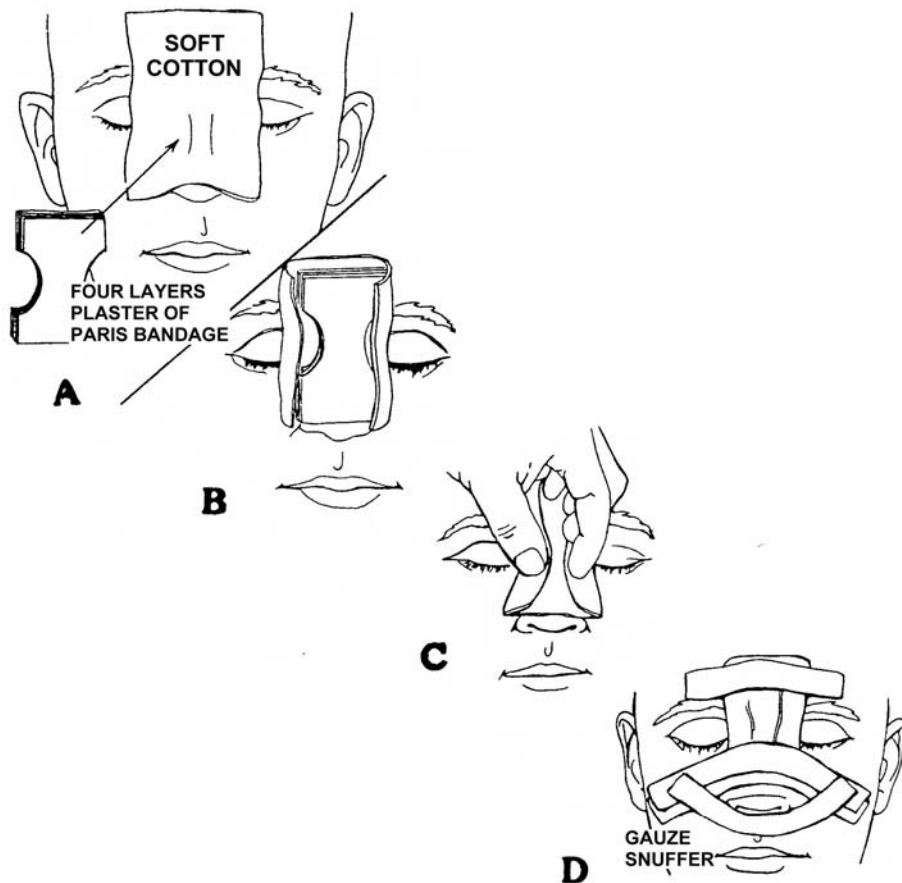


Figure 4-10. External splint to the nose.

#### 4-16. FOREIGN BODIES OF THE NOSE

a. **Description.** Through a variety of circumstances, foreign objects sometimes get in the nose. These objects can cause difficulties.

b. **Signs and Symptoms.** Signs and symptoms depend on the size, shape, location, and length of time the object has been in the nose. Included are the following:

- (1) Watery nasal discharge.
- (2) Ulcer formation.
- (3) Foul smelling discharge coming from one nostril.
- (4) Nose bleed.
- (5) Nasal obstruction.

- (6) Sneezing.
- (7) Fever.
- (8) Headache.

c. **Treatment.** Vasoconstrictors (drug to narrow blood vessels) can be given. The foreign object may be removed with nasal or bayonet forceps. If an ulceration has formed, treat with Furacin<sup>®</sup> or bacitracin.

## Section V. THROAT INJURIES

### 4-17. OROPHARYNX FOREIGN BODIES

a. **Description.** The oropharynx is the central part of the pharynx and is located directly behind the oral cavity. The oropharynx extends from the inferior border of the soft palate to the lingual surface of the epiglottis, the palatine tonsils, and the posterior faucial pillars.

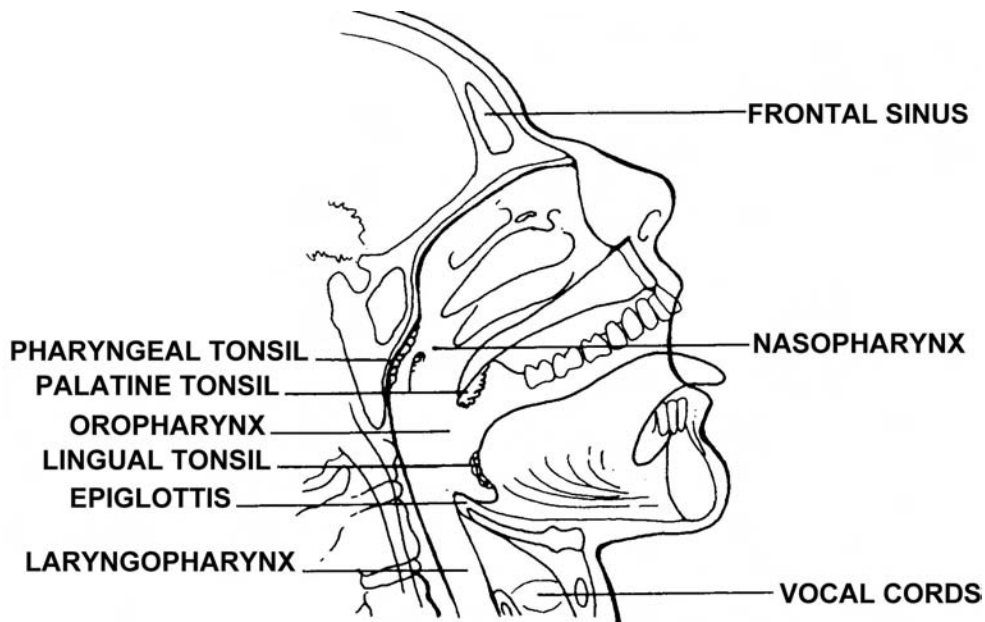


Figure 4-11. Foreign bodies in the oropharynx.

b. **Signs and Symptoms.** The patient has a feeling of "something present" in the oropharynx area. Sometimes there is a feeling of constant irritation in the area. Usually, the irritation is felt when the patient swallows.

c. **Treatment.** The foreign object can be removed using tonsil hemostats. Antibiotics may or may not be indicated.

#### 4-18. ESOPHAGEAL FOREIGN BODIES

a. **Description.** Foreign objects--fish bones, peanuts, etc.--sometimes become lodged in the esophagus.

b. **Signs and Symptoms.** Included are the following:

- (1) Immediate coughing and gagging.
- (2) Pain in the neck at the level of the thyroid cartilage. Most esophageal foreign bodies lodge in the esophageal inlet.
- (3) Patient complaint of, "Something stuck in my throat," but his voice is normal.
- (4) Difficulty in swallowing or inability to swallow.
- (5) Saliva pools in the pyriform sinuses.

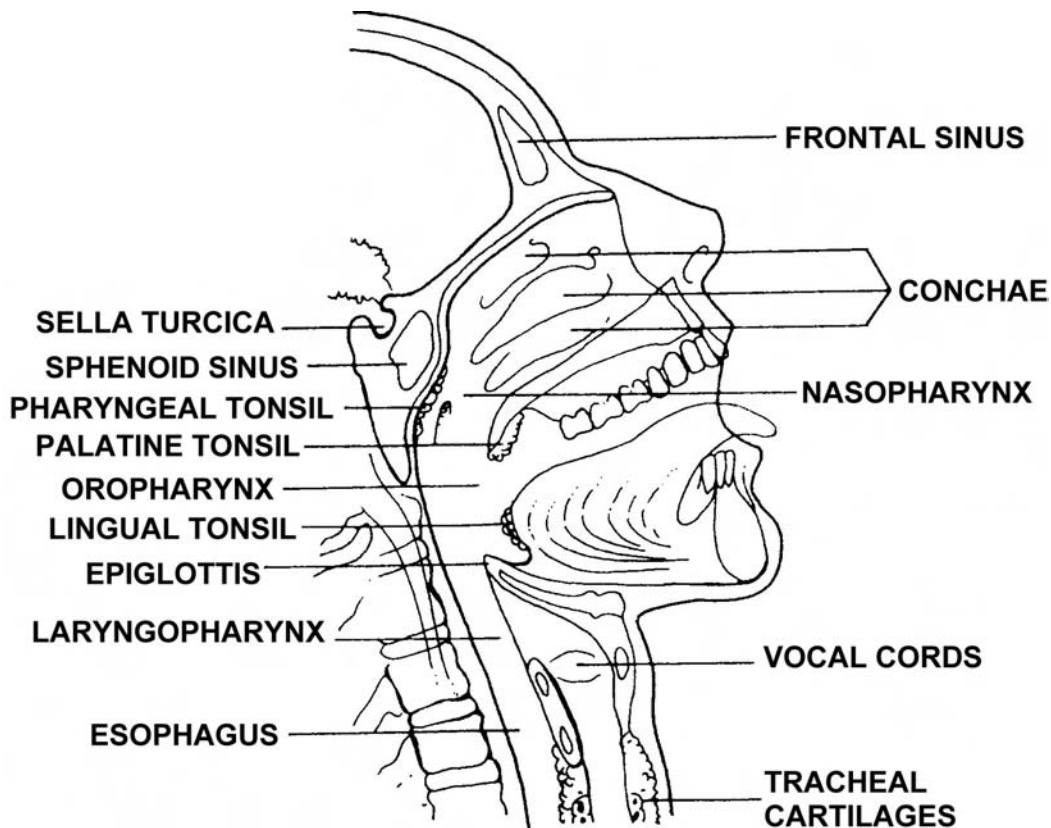


Figure 4-12. Foreign bodies in the esophagus.

c. **Treatment.** An endoscopist should remove the foreign object with the aid of an esophagoscope (instrument used to examine the esophagus). Blind probing, in an effort to dislodge a foreign body, is extremely hazardous. Usually, a foreign body in the esophagus is NOT an emergency, and a delay for proper medical treatment is not hazardous to the patient. Evacuate the patient to a medical treatment facility where soft tissue x-rays of the neck, chest, and ear-nose-throat areas can be obtained.

#### **4-19. CLOSING**

The structures of the eyes, ears, nose, and throat are delicate. Loss of such structures can be detrimental to one's appearance. When treating a trauma patient, always revert back to your ABCs first. After you are sure you have taken needed initial lifesaving measures, you can be concerned with more detailed work.

**Continue with Exercises**

## EXERCISES, LESSON 4

**INSTRUCTIONS.** The following exercises are to be answered by writing the answer in the space provided. After you have completed all the exercises, turn to the solutions located at the end of the exercises and check your answers.

1. A blowout-fracture occurs at \_\_\_\_\_ of the eye.
  
2. List two steps included in treating a patient with a blowout fracture.
  - a. \_\_\_\_\_.
  - b. \_\_\_\_\_.
  
3. A tripod fracture is \_\_\_\_\_.
  
4. List three signs/symptoms of a mandibular fracture.
  - a. \_\_\_\_\_.
  - b. \_\_\_\_\_.
  - c. \_\_\_\_\_.
  
5. Malocclusion may be a sign of either a mandibular fracture or a maxillary fracture. Malocclusion is \_\_\_\_\_.
  
6. List four general considerations for all eye injuries.
  - a. \_\_\_\_\_.
  - b. \_\_\_\_\_.
  - c. \_\_\_\_\_.
  - d. \_\_\_\_\_.

7. \_\_\_\_\_ is another term for a black eye.
8. Signs of a black eye include \_\_\_\_\_ and discoloration of \_\_\_\_\_.
9. Subconjunctival hemorrhage may occur spontaneously or after a bout of sneezing, vomiting, or \_\_\_\_\_.
10. A \_\_\_\_\_ is a hemorrhage in the anterior chamber of the eye.
11. List three steps in treating a hemorrhage of the anterior chamber of the eye.
  - a. \_\_\_\_\_.
  - b. \_\_\_\_\_.
  - c. \_\_\_\_\_.
12. A superficial foreign body on the cornea of the eye can be detected by using \_\_\_\_\_.
13. NEVER try to remove a foreign object on the surface of the cornea of the eye with a dry cotton swab because \_\_\_\_\_.
14. List two treatments for a corneal abrasion.
  - a. \_\_\_\_\_.
  - b. \_\_\_\_\_.

15. Include the following when treating a patient with chemical burns to the eyes.
- a. \_\_\_\_\_.
  - b. \_\_\_\_\_.
  - c. \_\_\_\_\_.
  - d. \_\_\_\_\_.
16. Extremes of light, such as reflection of light from snow or from \_\_\_\_\_, can cause burns to the eyes.
17. Blurred vision and some pain may both be symptoms of \_\_\_\_\_ eye injuries.
18. If there is a foreign object in the eye, leave it in place, put on a \_\_\_\_\_ dressing, and patch both eyes.
19. Enucleation is \_\_\_\_\_
20. List three steps to take if the eyelid is lacerated or partially torn.
- a. \_\_\_\_\_.
  - b. \_\_\_\_\_.
  - c. \_\_\_\_\_.
21. Write three steps to take if the eyelid has come off completely.
- a. \_\_\_\_\_.
  - b. \_\_\_\_\_.
  - c. \_\_\_\_\_.

22. List two treatments for a hematoma of the ear.
- a. \_\_\_\_\_.
  - b. \_\_\_\_\_.
23. Write three signs/symptoms of perforation of the tympanic membrane.
- a. \_\_\_\_\_.
  - b. \_\_\_\_\_.
  - c. \_\_\_\_\_.
24. Conductive deafness is \_\_\_\_\_.
25. Two signs/symptoms of foreign bodies in the ear are:
- a. \_\_\_\_\_.
  - b. \_\_\_\_\_.
26. Ninety percent of all epistaxis take place in the anterior tip of the
27. Symptoms of fracture of the nose include pain, swelling, deformity in the nasal septal deviation, and \_\_\_\_\_.
28. List three signs/symptoms of foreign bodies of the nose.
- a. \_\_\_\_\_.
  - b. \_\_\_\_\_.
  - c. \_\_\_\_\_.



29. Foreign bodies in the oropharynx may be removed by using tonsil

\_\_\_\_\_

30. A foreign body in the esophagus should be removed through an \_\_\_\_\_  
by an \_\_\_\_\_.

**Check Your Answers on Next Page**

## SOLUTIONS TO EXERCISES, LESSON 4

1. The base of the bony orbit. (para 4-2a(1))
2. Protect the patient from further injury.  
Evacuate the patient for further evaluation. (para 4-2a(4))
3. A fracture at the junction of the three bones in the cheek. (para 4-2b(1))
4. You are correct if you listed any three of the following:  
  
Excessive movement of the maxillary segment.  
Point tenderness.  
No feeling over the upper lip.  
Bruise and swelling (if there is a black eye).  
Teeth not making proper contact for chewing. (para 4-2c(2))
5. Improper closure of the teeth for chewing. (para 4-2d(2))
6. You are correct if you listed any four of the following:  
  
Pain without motion.  
Tenderness over the site of the fracture.  
Swelling.  
Bruise.  
Malocclusion (teeth do not close properly to chew).  
Cannot open mouth.  
Excessive salivation.  
Facial appearance is abnormal.  
No feeling in the lower lip. (para 4-2c(2))
7. Periorbital hematoma. (para 4-4a)
8. Swelling of the soft tissue around the eye.  
Discoloration. (para 4-4a(2))
9. Coughing. (para 4-4b(1))
10. Hyphema. (para 4-4c(1))

11. You are correct if you listed any three of the following:
  - Put patient on absolute bed rest, upper torso elevated at 45° angle, bed rest for four to five days.
  - Binocular patch the eyes.
  - DO NOT put medication in the eye.
  - Give analgesics as needed.
  - Evacuate to a medical treatment facility. (para 4-4c(3))
12. Fluorescein dye 2% strip. (para 4-4d(4))
13. The dry cotton swab will leave fuzz in the eye. (para 4-4d(4))
14. Apply antibiotics topically (Polysporin or Gentamicin).  
Patch the injured eye for twelve to twenty-four hours. (para 4-4e)
15. Flush the eye immediately with any clean fluid.  
Record the name of the chemical which caused the burn.  
Evacuate the patient to a medical treatment facility immediately.  
Give narcotic analgesics as required. (para 4-4f(3))
16. Arc welding. (para 4-4f(2))
17. Penetrating. (para 4-5(c))
18. Donut. (para 4-5d)
19. Surgical removal of the eyeball. (paras 4-6a through e)
20. You are correct if you listed any three of the following:
  - Return the eyelid to its correct anatomical position.
  - Cover the eyelid completely with a moist dressing.
  - Cover the eyelid snugly enough to hold all fragments in place.
  - Patch both eyes.
  - Reassure the patient. (para 4-7a)
21. You are correct if you wrote any three of the following:
  - . Put all eyelid pieces in the correct anatomical place on the eye.
  - . Cover the injured eyelid/eye with moist gauze.
  - . Patch both eyes.
  - . Reassure the patient. (para 4-7b)

22. You are correct if you listed any two of the following:
- Apply cold compresses.
  - Aspirate if the hematoma is large.
  - Apply a pressure dressing. (para 4-9b)
23. Severe pain initially.
- Tinnitus.
  - Hearing loss, sometimes. (para 4-11b)
24. A defect in the sound conducting apparatus. (para 4-12a)
25. You are correct if you included any two of the following:
- Pain.
  - Itching.
  - Conductive hearing loss.
  - Fullness sensation.
  - A foreign object which can be seen in the ear. (para 4-13b)
26. Septum. (para 4-14a)
27. Epistaxis. (para 4-15b)
28. You are correct if you listed any three of the following:
- Watery nasal discharge.
  - Ulcer formation.
  - Foul smelling unilateral discharge.
  - Development of epistaxis.
  - Nasal obstruction. (para 4-16b)
29. Hemostats. (para 4-17c)
30. Esophagoscope.
- Endoscopist. (para 4-18c)

**End of Lesson 4**