

# ORAL ANESTHESIA

---

THOMA

YALE  
MEDICAL LIBRARY



HISTORICAL  
LIBRARY

THE GIFT OF  
YALE UNIVERSITY LIBRARY





## ORAL ANESTHESIA

**Oral Abscesses**—A Pathological Study of  
Infectious Foci in the Mouth and Their  
Relation to Somatic Diseases.

**Oral Roentgenology**—A Roentgen Study  
of the Anatomy and Pathology of the  
Oral Cavity.

# ORAL ANESTHESIA

## LOCAL ANESTHESIA IN THE ORAL CAVITY

---

TECHNIQUE AND PRACTICAL APPLICATION IN THE  
DIFFERENT BRANCHES OF DENTISTRY

BY

KURT H. THOMA, D.M.D.

ASSISTANT PROFESSOR OF ORAL PATHOLOGY AND MEMBER OF RESEARCH DEPARTMENT  
HARVARD UNIVERSITY DENTAL SCHOOL. INSTRUCTOR IN DENTAL ANATOMY,  
HARVARD UNIVERSITY MEDICAL SCHOOL. ORAL SURGEON ROBERT BRECK  
BRIGHAM HOSPITAL. VISITING ORAL SURGEON, LONG ISLAND HOSPITAL.  
MEMBER NATIONAL, STATE, AND LOCAL DENTAL SOCIETIES AND IN-  
TERSTATE ASSOCIATION OF ANESTHETISTS. FELLOW IN THE  
AMERICAN ACADEMY OF DENTAL SCIENCE. ASSOCIATE  
FELLOW OF THE AMERICAN MEDICAL ASSOCIATION.

---

*Second Edition, Revised with 79 Illustrations*



BOSTON  
M. C. CHERRY  
22 SEYMOUR STREET  
1920

*(The right of reproduction of the original illustrations is strictly reserved)*

*Copyrighted at the Registry of Copyrights, Washington, D. C., 1914*

*Revised, reprinted and recopyrighted, Washington, D. C., 1920*

---

*All rights reserved*



TO  
HERMANN F. THOMA  
MY FATHER  
THIS VOLUME IS FONDLY DEDICATED



## PREFACE TO THE SECOND EDITION

**W**ITH the introduction of local anesthesia into this country, a great demand was created for instruction among members of the dental profession. The writer had the pleasure of introducing this method into the operative clinic of the Harvard Dental School, and though it was at first viewed with suspicion it soon became recognized as one of the greatest boons in the relief of suffering in the dental chair. Invitations for papers and clinics at various dental conventions which were largely attended and demands for postgraduate instruction became more and more numerous; and to-day local anesthesia is part of the dental curriculum in every school and in use in every modern dental office. It has certain unquestionable advantages over nitrous oxide and oxygen anesthesia for oral operations.

Correspondence with brother practitioners grew daily, and the great amount of information sought by them, together with the desire to be of assistance to his colleagues, stimulated the writer to present to the profession a concise but comprehensive publication, a primer, so to speak, for the busy practitioner, going, however, sufficiently into fundamentals to make it a textbook for the dental student.

The first edition of 5000 volumes having been exhausted in a comparatively short time, and the continuous demand for this book, made it necessary to issue a new edition. The author has been making use of this welcome opportunity to entirely rewrite the work. The volume is opened with a

description of the nature of pain and fear, the two emotions which are so closely related. It is not sufficient to control pain alone. The successful anesthetist and surgeon should also promote a helpful and coöperative attitude in the patient. Some of the new substitutes for cocain have received consideration in the chapter dealing with drugs and the name "Procaine" has been substituted for "novocain" in the entire volume, as the latter is now manufactured in the United States and licensed by the Federal Trade Commission under this new trade name. The Procaine-Metz manufactured in New York by the H. A. Metz Laboratories has been found as efficient, in every respect, as the imported novocain and is referred to in the work entirely when the name "Procaine" is used. The T tablets, the manufacturing of which was promised in the first edition, came into the market after a short delay and have been giving great satisfaction. An H tablet is now being made containing three times as much as a single T tablet which facilitates the preparation for the solution for those who use local anesthesia extensively. The technique of the injections described in the first volume has stood the test of time, but new methods have since then been developed and have been incorporated in this edition. The extraoral methods which are of great value in war surgery and extensive oral operations in general, have been described carefully and many new illustrations have been added to make the text more comprehensive or to replace some crude figures of the earlier edition. The chapter on Ill Effects, Failures, Accidents, and Postoperative Sequelæ has been entirely changed, more careful consideration, experience, and research work having done a great deal towards better understanding of these conditions. In the last chapter, on Practical Application, the subject has been greatly condensed, leaving out material not strictly pertaining to local anesthesia.

A list of literature on local anesthesia and subjects co-

related has been added to give due credit to other writers and operators who have aided in the development of local anesthesia, as research workers or teachers. While there are still some disputed points of minor importance and slight deviation of individual technique, no one has introduced any radical changes since the first publication of this book.

The writer has received valuable assistance from Dr. Leonard D. Nathan in the preparation of the manuscript and proofreading for this edition, and five excellent anatomical drawings by Miss Herford should also receive grateful acknowledgment.

KURT H. THOMA

43 BAY STATE ROAD  
BOSTON, MASSACHUSETTS  
July 5, 1919



# CONTENTS

	PAGE
I. THE NATURE OF PAIN AND FEAR AND METHODS OF CONTROLLING THEM . . . . .	15
II. SPECIAL ANATOMY OF THE ORAL CAVITY . . . . .	19
1. THE UPPER JAW . . . . .	19
The Anterior Surface . . . . .	20
The Infratemporal Surface . . . . .	23
The Alveolar Process . . . . .	23
The Palatal Process . . . . .	26
The Maxillary Sinus . . . . .	29
The Nasal Cavity . . . . .	29
2. THE LOWER JAW . . . . .	29
The External Surface . . . . .	29
The Internal Surface . . . . .	34
Mandibular Foramen . . . . .	34
3. SENSORY INNERVATION OF THE ORAL TISSUES AND THE FACE . . . . .	37
The Trigeminal Nerve . . . . .	38
Ophthalmic Division . . . . .	39
Maxillary Division . . . . .	42
Sphenopalatine Ganglion . . . . .	44
Mandibular Division . . . . .	48
Otic Ganglion . . . . .	51
Submaxillary Ganglion . . . . .	52
Table of Sensory Nerve Supply of Face and Oral Tissues . . . . .	52
III. INSTRUMENTARIUM . . . . .	54
Syringe No. 1 for Intraoral Injection . . . . .	54
Needles . . . . .	55
Boiling Cups . . . . .	57
Glass Jar . . . . .	59
Bottle for Ringer Solution . . . . .	59
Glass Tray with Cover . . . . .	59
Alcohol Lamp . . . . .	60
Syringe No. 2 for Extraoral Injections . . . . .	60
Needles . . . . .	61
IV. PHARMACOLOGY OF DRUGS USED FOR LOCAL ANESTHESIA . . . . .	62
Cocain . . . . .	62
Requirements of a Substitute for Cocain . . . . .	63
Apothesine . . . . .	64
Novocain . . . . .	64
Procaine . . . . .	65
Table of Comparative Toxicity of Cocain and Novocain . . . . .	67
Adrenalin . . . . .	70
Suprarenin Syntheticum . . . . .	71
Solvent Medium . . . . .	75
Distilled Water . . . . .	77

	PAGE
Procain-Suprarenin Combined	80
Ampules	80
Prepared Solutions	81
Seidel's Method	81
Tablets. Author's Method	81
List of Tablets of Metz Laboratories	82
Procaine Pluglets	83
Method of Preparing the Solution	83
Requirements of a Solution Prepared from Tablets	84
V. PREPARATION OF THE PATIENT	85
Preanesthetic Medication	86
Local Preparation	87
Preparing the Mucous Membrane	87
Preparing the Skin	87
VI. SPECIAL TECHNIQUE OF LOCAL ANESTHESIA	89
Absorption Anesthesia	89
Application to the Oral Mucous Membrane	90
Nasal Application	91
Application to Exposed Pulp	91
Infiltration Anesthesia	93
Infiltration of the Skin and Mucous Membrane	96
Infiltration Method for Anesthetizing Individual Teeth	98
Injection on Labial or Buccal Side of Upper Jaw	102
Injection on the Lingual Side of Upper Jaw	103
Injection on the Labial Side of the Mandible	103
Injection on the Lingual Side of the Mandible	104
For upper Central Incisors	104
" " Lateral	105
" " Cuspids	105
" " First Bicuspid	106
" " Second Bicuspid	106
" " First Molars	106
" " Second Molars	106
" " Third Molars	107
" " Lower Incisors	109
Infiltration Method for Anesthetizing a Number of Adjoining Teeth	109
Conduction Anesthesia	110
<i>Intraoral Methods</i>	113
Pterygomandibular Injection	113
Mental Injection	123
Buccinator Injection	126
Sphenomaxillary Injection	126
Zygomatic Injection	132
Infraorbital Injection	134
Incisive Injection	138
Palatine Injection	139
Table for Infiltration Anesthesia for the Teeth only	140
Table for Infiltration Anesthesia for Teeth and Soft Tissues	141
Table for Conduction Anesthesia for the Teeth only	142
Table for Conduction Anesthesia for Teeth and Soft Tissues	143
<i>Extraoral Methods</i>	144
Mandibular Injection	144
Pterygomandibular Injection	148
Maxillary Injection	152
Infraorbital Injection	157



	PAGE
VII. ILL EFFECTS, FAILURES, ACCIDENTS, AND POSTOPERATIVE SEQUELAE . . . . .	159
Ill Effects . . . . .	159
Pain . . . . .	159
Toxic Effects . . . . .	159
Failures . . . . .	159
Anatomical Conditions . . . . .	159
Faulty Instruments and Technique . . . . .	160
Deteriorated Drugs . . . . .	160
Accidents . . . . .	161
Breaking of Needle . . . . .	161
Entering Blood Vessel . . . . .	161
Local Vasoconstriction . . . . .	161
Centering Nerve Trunks . . . . .	161
Anesthesia of Motor Fibers . . . . .	162
Psychic Shock . . . . .	162
Syncope . . . . .	164
Postanesthetic and Postoperative Effects . . . . .	165
Tissue Lesions . . . . .	165
Edema . . . . .	166
After Pain . . . . .	167
Prolonged Anesthesia . . . . .	170
VIII. PRACTICAL APPLICATION OF LOCAL ANESTHESIA IN DENTISTRY AND ORAL SURGERY . . . . .	171
Cavity Preparation . . . . .	171
Crown and Bridge Work . . . . .	172
Pulp Extirpation . . . . .	173
Treatment of Pyorrhea Alveolaris . . . . .	174
Diagnosis of Trifacial Neuralgia . . . . .	174
Alcohol Injections for Major Neuralgia . . . . .	174
Oral Surgery . . . . .	174
Extraction of Teeth . . . . .	174
Operations on the Jaws . . . . .	174
Operations on the Maxillary Sinus . . . . .	174
Resections of Jaws . . . . .	175



## PART I

### THE NATURE OF PAIN AND FEAR AND METHODS OF CONTROLLING THEM

THE sensation of pain is brought about by the stimulation of receptors, which are highly specialized organs, capable of receiving and transmitting stimuli through sensory neurons to the cerebral cortex. These receptors are widely distributed over the body, being present in the skin and in the lining membranes, such as the periosteum and perichondrium. All the oral tissues and particularly the teeth are especially well supplied. Pain is a protective device which gives information regarding conditions which affect the normal state of the body. It registers injury and disease, and while being an ally under these circumstances, it becomes a hindrance when operative measures are necessary to eliminate abnormal conditions. The intensity of pain varies. Some parts of the body are much more susceptible than others, as evidenced by the need of a stronger stimulus to produce a reaction from the palm of the hand than from the back. Race, age, sex, general health, and the susceptibility of certain individuals are factors which explain differences in the intensity of pain. Education, with its promotion of self-control, is an important influence in controlling the closely associated emotion of pain — fear, which, in turn, may cause an enormous exaggeration of the actual condition. It must always be remembered that the person concerned, consciously or unconsciously, recalls instances similar to the present, in which he was actually the sufferer, or of which he has knowl-

edge only from hearsay; and furthermore, there is a probability that phylogenetic experience, that of progenitors acquired during the past centuries, may automatically give a reaction.

Pain, an internal body sensation, as well as fear, an outside influence, of which dread is a diminutive and fright an intensified condition, causes certain changes in the body. Crile, in his excellent work on "Anoci-association" explains these emotions by a theory resulting from phylogenetic habits, and so he finds that our ancestors had two principal methods of defending themselves, namely fight and flight. The means in both cases was muscular activity, which, if carried to an extreme, resulted in physical exhaustion. To-day, when placed in a similar position, fight and flight are not countenanced. The discharge of energy therefore results in no actual work, and if the stimulation is strong enough and the expenditure of energy rapid, the condition is designated "shock."

Shock may be produced by physical causes, such as pain, injury, infection, and muscular exertion, or by psychic conditions, such as fear, dread, and worry. Crile presented evidence from histological and clinical observation proving that all these conditions cause physical alterations in the cells of the brain, the suprarenal glands, and the liver. In dental and oral surgical operations, most of these factors are present in a larger or smaller measure and should be eliminated as far as possible.

The physical stimuli are transmitted to the brain whether the patient is conscious or unconscious. Crile states that a general anesthetic alone does not prevent stimulation of the cells of the brain, nor physical shock; but this can be well accomplished by a local anesthetic which blocks the transmission of impulses along the nerve. Psychic stimulation, however, is not taken care of by this method and presents a problem of a much more complex character. The thought of the pending operation and of the general anes-

thetic may often cause the prospective patient days and nights of anxiety and dread. The sight of the operating room, thoughtless conversation by the nurses, the unintentional expression of danger by the operator, confusion in preparing for the operation, and finally the sight of the operation and the flow of blood, are factors which may arouse fear and fright. How can these emotions be controlled? A general anesthetic will eliminate the psychic effects connected with the operative procedures; Crile therefore advocates a combination of local and general anesthesia to attain a state as free as possible from harmful stimuli, "noci-associations," so as to reach a state of "anoci-association."

In dental and minor oral surgical operations, the operative procedure is not so severe but that the average patient can bear to have it performed while fully conscious, while the psychic effects can be controlled in a large percentage of cases by careful management of the patient, harmonious environment, tactful reception by the office staff, considerate treatment by the nurse, as well as noiseless and unostentatious preparations for the operation. The personality of the operator is perhaps the most important factor. He should secure from the first the confidence of the patient by a sympathetic and convincing attitude, by which the patient cannot fail to be reassured. The operator should be in full control of any situation that may arise, and should act unpretentiously without arousing the patient's fears and doubts. Since the patient's nerves are keyed to the highest pitch, sometimes the mere mention of the words "knife," "hemorrhage," or "infection," may cause disastrous results. The patient should never be permitted to become conscious of any uncertainty or indecision. The operator should work quietly, following step by step the technique decided upon and from time to time reassure the patient. If the operation is long and tedious, as in the case of unerupted

third molars, the patient, as well as the operator and his assistant, should rest occasionally; and the patient should be made to realize that the anesthetic will last longer than is necessary for the painless completion of the operation.

With the modern methods of conduction anesthesia, pain can be entirely controlled. A local anesthetic is preferable when the operation is to be performed in the office, where it is difficult to prepare the patient properly. It does away with a general anesthetist and eliminates the dangers attending general anesthesia. The absence of vomiting after the operation, the coöperation of the patient under the local anesthetic, and the fact that the field is almost bloodless are factors which facilitate the work of the operator.

Notwithstanding these great advantages, the cases for local anesthesia must be selected carefully. Children are usually poor subjects, although very intelligent older children are sometimes exceptions. For some patients, a general anesthetic is contra-indicated and in such cases, danger can be avoided by the use of local anesthesia. Many adults will consent to nothing but a general anesthetic. The excitable, nervous, and timid patients who dread consciousness of the operation can sometimes be satisfactorily prepared by preanesthetic medication, such as the administration of bromural, veronal, or morphia.

## PART II

### SPECIAL ANATOMY OF THE ORAL CAVITY

**T**HE use and development of local anesthesia necessitates a thorough study of the bony structures of the maxillae as well as the nerves and vessels supplying the various tissues and organs of the mouth. Numerous openings which can be found on the surface of the jaws—transmitting arteries, veins, nerves and lymph vessels—furnish a possibility of infiltrating the inner part of the bones with an anesthetic solution, injected under the mucous membrane. Smaller nerve branches and larger nerve trunks can be conveniently reached in various places; but an accurate knowledge of the important landmarks is imperative in determining their exact location.

#### 1. The Upper Jaw

The upper and lower jaws are dissimilar in their make-up. They vary in structure as well as in shape and appearance. Both are covered with periosteum through which small nutrient vessels enter the bone by way of the Haversian canals.

The body of the maxillary bone incloses a large cavity, the maxillary sinus (O. T. Antrum of Highmore), the walls of which are very thin. Of the spaces and processes which it presents for examination, those of special interest to us are the anterior and infratemporal surfaces, the zygomatic and palatal processes, and particularly the alveolar process, which contains the teeth.

**The anterior surface** (O. T. external or facial surface) presents an elevation over the root of the cuspid tooth, called the canine eminence, which separates the incisive

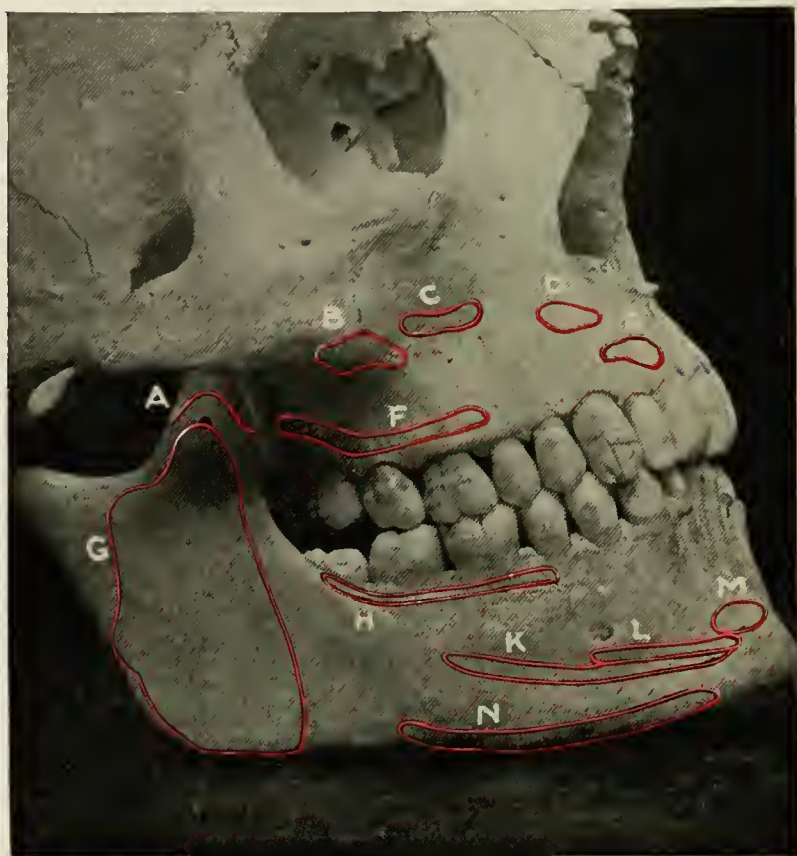


FIGURE 1

Side view of upper and lower jaw, showing attachment of muscles. A. Temporalis m. B. Masseter m. C. Levator anguli oris m. D. Compressor nasi m. E. Depressor septi m. F. and H. Buccinator m. G. Masseter m. K. Depressor anguli oris m. L. Depressor labii inferior m. M. Depressor menti m. N. Platysma myoides m.

from the canine fossa. Above, the incisive fossa gives origin to the compressor nasi; below and more to the median line, to the depressor septi muscle (O. T. depressor alae nasi). The canine fossa gives attachment to the levator anguli oris muscle. The infraorbital foramen opens above the



origin of this muscle. It is situated immediately below the centre of the infraorbital ridge and above the root apex of the first bicuspid tooth. Its distance from the infraorbital

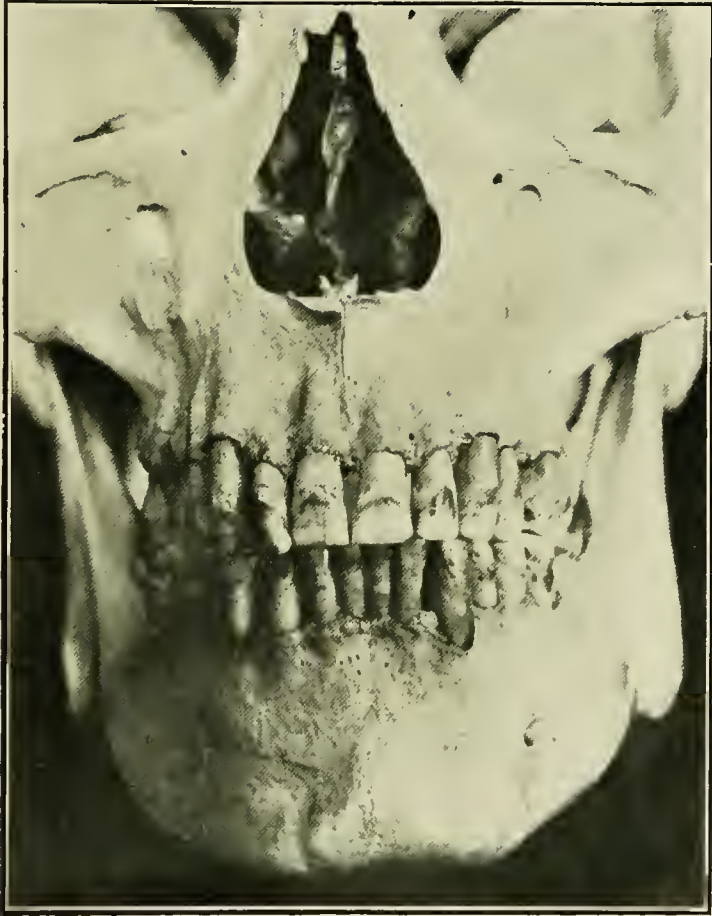

FIGURE 2

Front view of upper and lower jaw, showing small foramina in the alveolar process made use of in infiltration anesthesia.

margin is normally 7 mm. in the adult. The infraorbital foramen is the outlet of the infraorbital canal, and its course shows a decided downward direction. The canine fossa

which continues from this point towards the alveolar process varies greatly as to size and shape. Its formation depends on the prominence of the infraorbital margin, the develop-

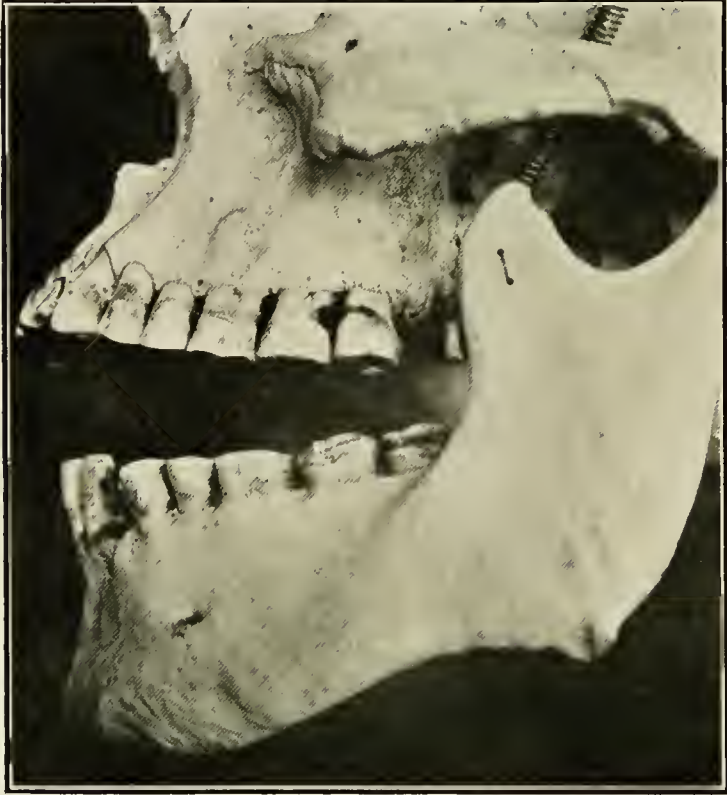

FIGURE 3

Side view of upper and lower jaw, showing small foramina in the alveolar process of the maxillary bone and dense cortical surface of mandible.

ment of the zygomatic and the position and direction of the alveolar processes.

The **Infratemporal Surface** (O. T. posterior or zygomatic surface) is convex, directed backward and inward. It forms part of the zygomatic fossa. From the anterior

surface it is separated by the zygomatic process. At its posterior and inferior part is a rounded eminence, the tuber maxillare. Besides giving attachment to a few fibers of the external pterygoid muscle, it presents a greater or lesser number of openings which are usually more marked in youth than in old age. These are in the neighborhood of the root of the third molar and probably transmit vessels which furnish nutrition to the inner part of the bone and give opportunity for local anesthesia.

The posterior alveolar foramina are located higher up. There are one or two, seldom three foramina of larger size. These are openings to very fine canals which run along the outer wall of the maxillary sinus and transmit the posterior alveolar vessels and nerves which innervate the molar teeth.

**The alveolar process** which furnishes the bony support to the roots of the teeth is continuous from the tuberosity on one side to the tuberosity on the other. It is made up of an outer and inner plate of hard, solid bone called cortex between which plates extend many small trabeculae of bone. These form a reticular structure which incloses the medullary spaces, the continuity of which is interrupted only by the alveolar sockets. A stratum durum, dense bone, forms the wall of the dental alveoli, the outer and inner aspects of which are at the cervical part, fused into the cortical plate, especially on the labial and buccal sides. On the outside of the bone vertical ridges corresponding with the roots of the teeth are distinctly visible and indicate the thinness of the bone. This is especially the case over the roots of the central incisors, the cuspids, and bicuspid, and these teeth therefore can be easily and quickly anesthetized by infiltration. There are numerous small canals, the openings of which are clearly visible, which communicate with the marrow spaces and allow the anesthetic solution to pass inside the bone. There it affects the dental

plexus and small dental rami before they enter the alveolar socket to supply the peridental membrane and the pulps of the teeth. Posteriorly in the region of the molars the outer plate of the alveolar process becomes thicker and much more dense in character on account of the zygomatic process (O. T. malar process) which takes its origin directly over the first or second molar tooth. When the zygomatic process extends far towards the cervical margin of the teeth,

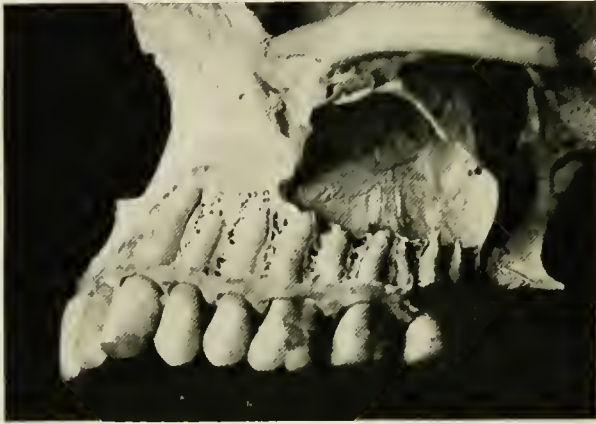

FIGURE 4

Side view of maxillary bone with outer cortical plate removed, showing inner structure of bone and relation of the teeth to the maxillary sinus.

anesthetization of the teeth becomes impossible. There are, however, occasional cases when the alveolar process is well formed and long enough even in the molar region to bring the apex of the buccal roots of the molars within reach of the anesthetic solution. The posterior extremity of the alveolar process takes part in the formation of the tuber maxillare. In this region the bone is thin, and presents many small foramina, as previously described. The inner plate of the alveolar process is heavier and stronger; small pores are evenly distributed over its entire surface. However, the roots, especially the apices, are generally a con-

siderable distance from the surface, especially in the case of single-rooted teeth, and infiltration from this side cannot be depended upon. On the other hand, if there are palatal roots present as in first bicuspid, and first and second molars, complete anesthesia of the tooth by infiltration

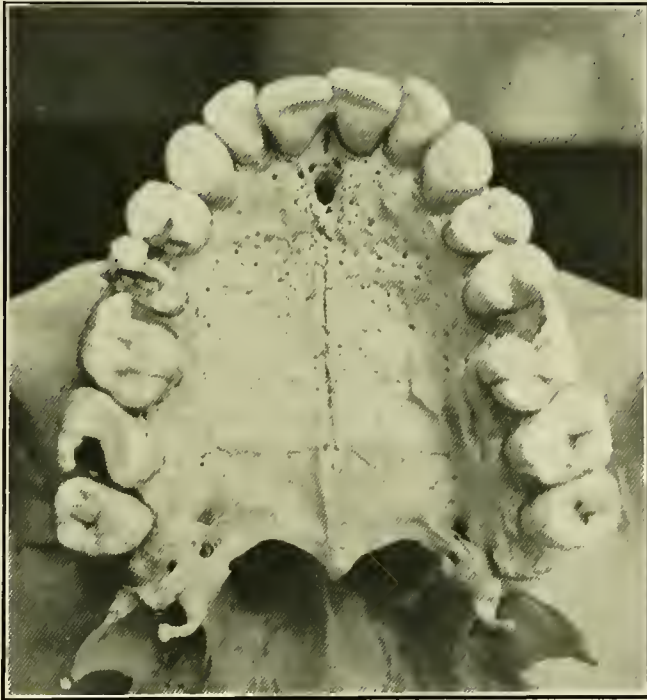


FIGURE 5

Skull, showing location of incisive and palatal foramina in the adult.

can only be secured when the solution is injected both at the buccal and palatal sides.

**The Palatal Process** joins the maxillary bone at the upper extremity of the alveolar process. It projects horizontally towards the median line, where it meets its fellow of the opposite side and so forms the roof of the mouth. It

usually forms a distinct angle where it joins the alveolar process, and the well-rounded appearance of the vault is due to the filling in of this region by an abundance of connective tissue containing the palatal glands.

The incisive foramen lies in the median line immediately behind the incisor teeth. The distance from the alveolar margin is usually 8 mm. in the adult. It is formed by

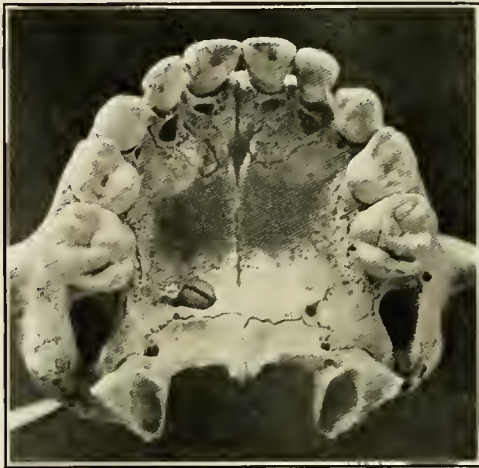

FIGURE 6

Skull, showing incisive and palatal foramina in a child between five and six years of age.

four canals, two laterally for the descending palatine arteries, one anteriorly and one posteriorly directly in the median line for the nasopalatine nerves. The direction of the incisive canal is not vertical, but is inclined slightly forward and downward, and therefore a needle inserted enters easily along its course. The incisive foramen is covered by a protuberance of the soft tissue known as the papilla palatina, the centre of which lies exactly in the axis of the canal. It transmits the nasopalatine nerves and descending palatine arteries, which supply the anterior part of the palate.

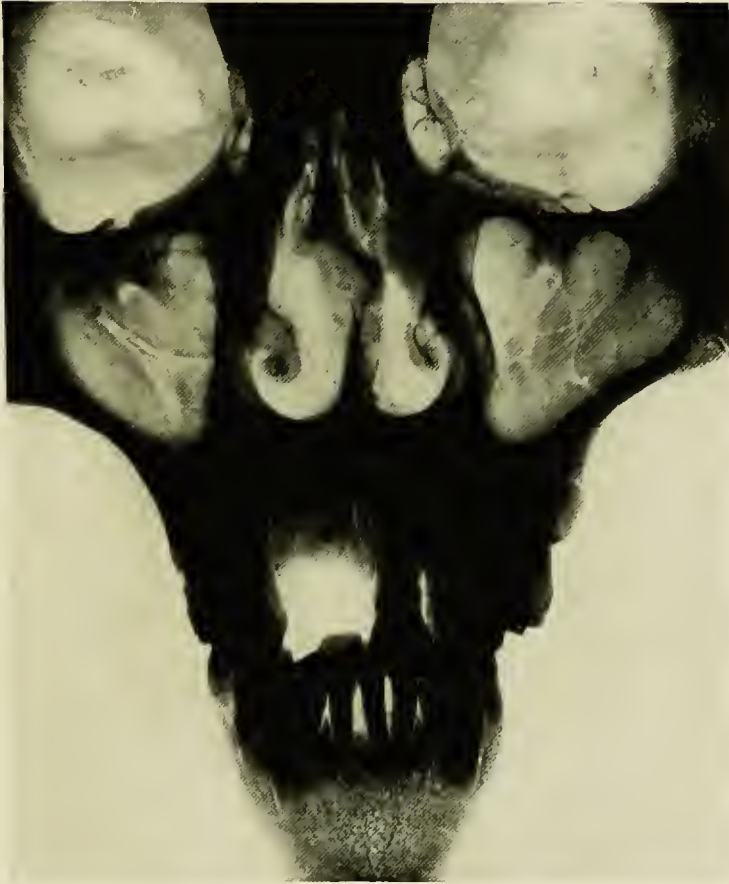

FIGURE 7

Roentgen picture, showing outline of the superior alveolar canals in the bony walls of the maxillary bone.

The palatine foramina are four in number, a larger and a smaller on each side of the jaw. They are the outlets of the palatine canals, which are formed partly by the maxillary and partly by the palatal bone. The larger foramen is anterior and transmits the anterior palatine nerve and vessels, which are in no way connected with the teeth but

supply the soft tissues of the posterior part of the hard palate. Its location varies according to the age of the patient and always lies medial to the last erupted molar. In a child under six years, it is found medial to the second temporary molar; later, up to the age of ten or eleven, medial to the first permanent molar, and, up to the erup-

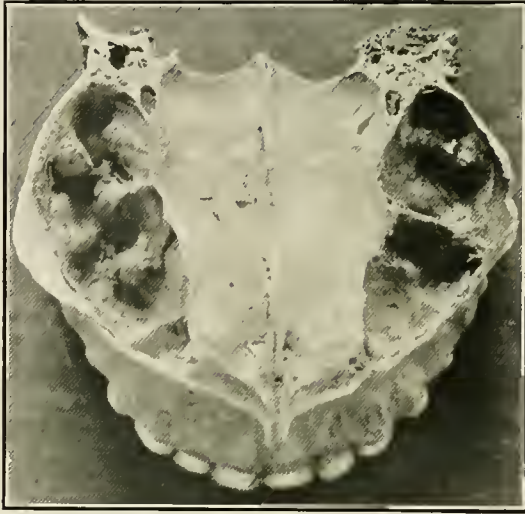


FIGURE 8

Section through the two maxillary bones, showing nasal cavity and on each side floor of maxillary sinus. Note relation of the teeth.

tion of the wisdom tooth, palatally to the second molar. The smaller palatine foramen transmits the middle palatine nerves and vessels which supply the soft palate. Its location is slightly posterior to the larger foramen, and as it is undesirable to produce anesthesia of the soft palate, care must be exercised to confine the injection to the region of the larger palatine foramen.

The **maxillary sinus** (O. T. Antrum of Highmore) is only of interest to anesthetists on account of its walls con-



taining the posterior and anterior alveolar canals through which pass the posterior middle and anterior alveolar nerves and vessels. Occasionally the molars and bicuspids project into the sinus and form protuberances of considerable size, a condition which may account for some failures of the infiltration method.

**The nasal cavity** is partly formed by the palatal processes of the maxilla. The apices of the incisor teeth are in close relation to the floor of the nose. Anesthetization of the nerves which supply the pulps of these teeth is comparatively simple, by means of applications to the anterior part of the floor of the nose, just inside the nares.

## 2. The Lower Jaw

The body of the mandible as well as the rami are surrounded by a layer of thick cortical bone, especially thick in the molar region where the bone is reinforced by the massive internal and external oblique lines. The construction of the cancellous part of the mandible is similar to the upper jaw, but the alveolar process is much less distinctive than in the maxillary bone. The body of the mandible and the alveolar process will be described together.

**The external surface** is in general composed of dense bone. Probably, on account of the abundant blood supply from the inferior alveolar artery, there are none of the small foramina which are so numerous in the maxilla to be found in the posterior part of the body of the adult mandible. The thickness of the bone, the density of the cortex, and the absence of the canals are conditions which account for an unsatisfactory anesthesia in the posterior part of the lower dental arch by means of the infiltration method (see Figure 3). Small pores, however, are frequently found along the margin of the alveolar process. These are the outlets of tiny canals which connect with the marrow spaces of the intraalveolar

septa and transmit small nutrient vessels. They are not constant, often only being found in the incisor region but sometimes on the alveolar margin of the bicuspids. They are rarely seen in the region of the molar teeth. The use of these foramina by injecting into the gingival margin of the gum around the posterior teeth of the mandible has been advocated, but the distance from the alveolar margin to the apex of the tooth and the uncertain presence of these

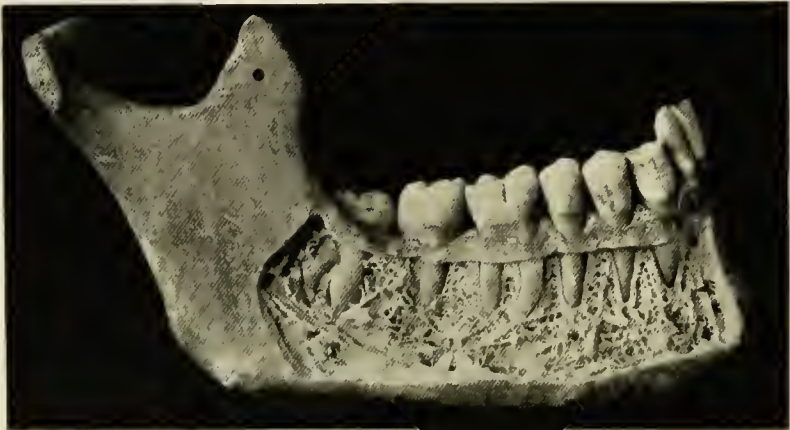

FIGURE 9

Side view of mandible with outercortical plate removed, showing inner structure of bone and relation of the teeth to the mandibular canal.

openings makes success too hazardous to advise the method for routine procedure.

A different condition exists in the mental region. The mental fossa which lies directly under the incisor teeth presents on each side a number of small foramina which sometimes extend as high up as the alveolar margin. At times one or two larger openings can be found. On the other side of the canine eminence below the apex of the cuspid there is also a depression which corresponds to the canine fossa of the upper jaw. Here canals are frequently found entering the cortex of the bone (see Figure 2).

The mental foramen is the largest opening on the external side. Its location is important for conduction anesthesia. In the child it is generally below the first temporary molar and in the adult its location is generally between the two bicuspid halfways between the alveolar margin and the inferior border of the mandible. In a great many cases,

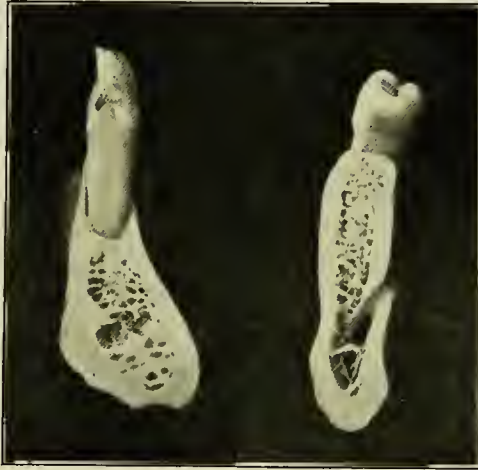

FIGURE 10

Cross sections through mandible, showing thick cortical layer. The right section is through bicuspid region, showing mental foramen. The left section is taken in front of the jaw.

however, the mental foramen may be found further back opposite the apex of the second bicuspid or even distal to it. The shape of the foramen is normally oval; the horizontal diameter is the longer and measures usually three to four millimeters. Abnormalities are not uncommon. The author has seen a foramen four times the normal size. Occasionally a double opening is found. The foramen opens distally and a distinct groove can often be seen, a depression made by the mental vessels and nerve.

The internal surface of the body of the mandible presents only in the anterior part conditions which may be

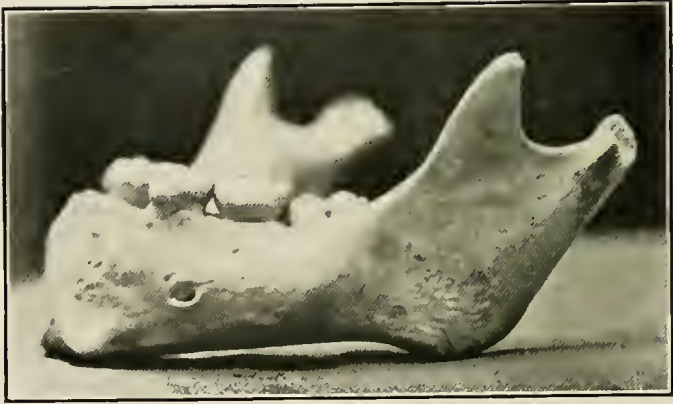

FIGURE 11  
Location of the mental foramen in a child.

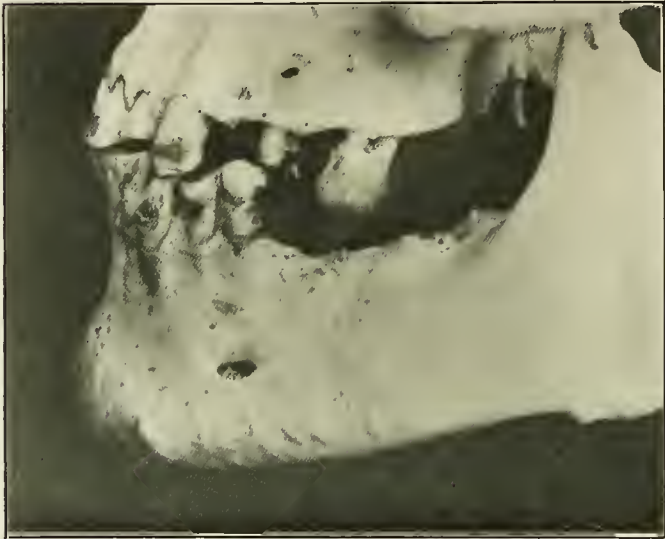


FIGURE 12  
Location of the mental foramen in an adult.

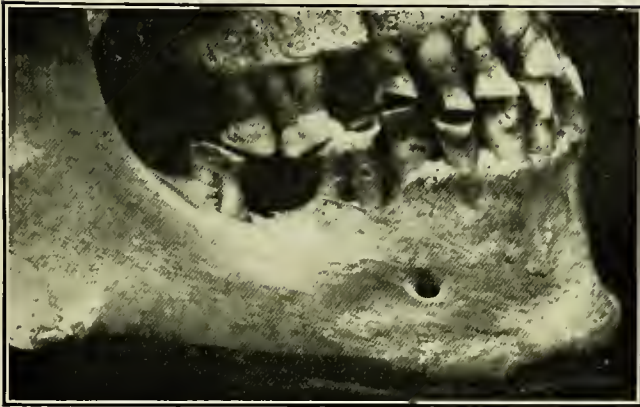

FIGURE 13  
Location and shape of the mental foramen in another adult.

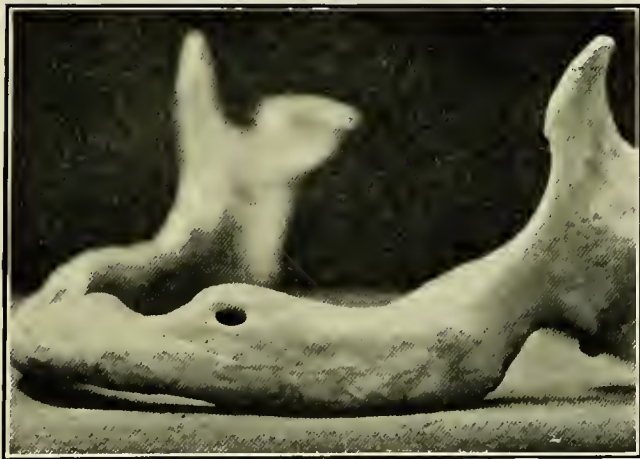


FIGURE 14  
Location of the mental foramen in the senile.

utilized for the purpose of producing anesthesia of the teeth. Along the lingual border, there are numerous openings which are almost constant and through which nutrient vessels enter the alveolar septa. In the cortical part around the

mental spine there are usually a number of larger canaliculi. These transmit end branches of the sublingual arteries which anastomose with the inferior alveolar artery.

The **mandibular foramen** (O. T. inferior dental foramen) is an opening on the internal side of the ramus through which the inferior alveolar nerve and vessels pass. The

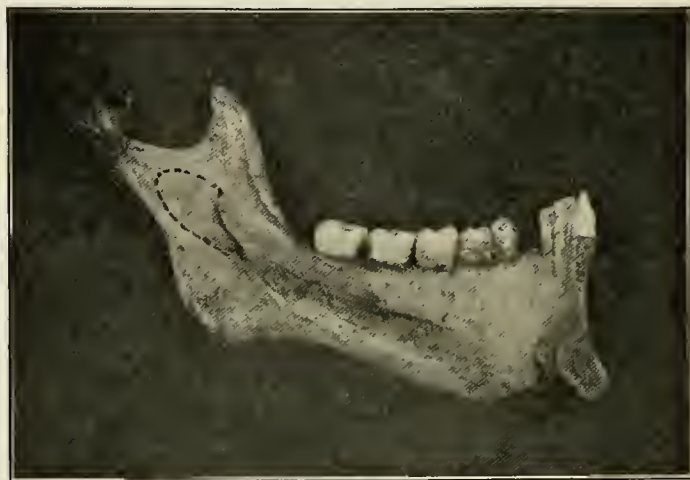

FIGURE 15

Inner surface of mandible, showing outline of sulcus mandibularis. (Dotted line.)

exact location of this foramen is of greatest importance to the oral anesthetist, and the effect that age has upon its position must be carefully considered. If a line is drawn over the alveolar border of both a child's jaw and that of an adult, it will be observed that the foramen is at a very much higher level in the adult. If, however, the line is drawn over the cutting edge of the incisors and the occlusal surface of the last molar, it will be found that there is little difference in the measurements, due to the change in the curvature formed by the occlusal surfaces in the teeth. The foramen is located about two or three millimeters

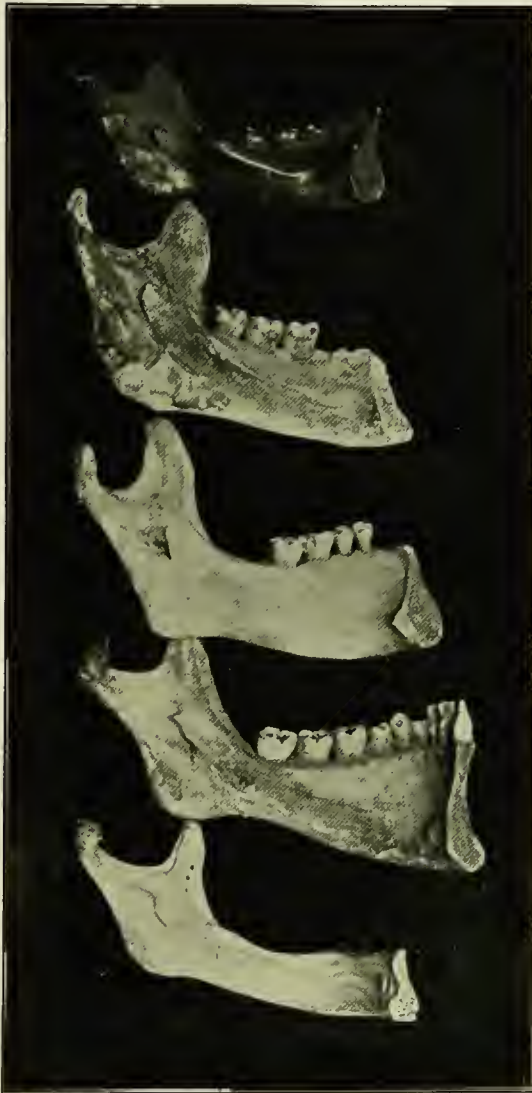

FIGURE 16

A collection of mandibles, showing variations of the lingula, mandibular foramen, and sulcus mandibularis. On top, a child's mandible; below, a senile jaw.

below such a line and halfway between the anterior and posterior border. If the mandible is viewed from the front, the foramina are not visible. They are covered by the projection of the internal oblique lines, the ramus being not parallel with the median line but at an angle which varies in different individuals and races. The shape of the foramen may be compared with a funnel, and its width varies according to Stein between two and eleven millimeters. The entrance of the alveolar nerve and vessels is protected anteriorly by the lingula or mandibular tongue, which gives attachment to the speno-mandibular ligament. The dis-

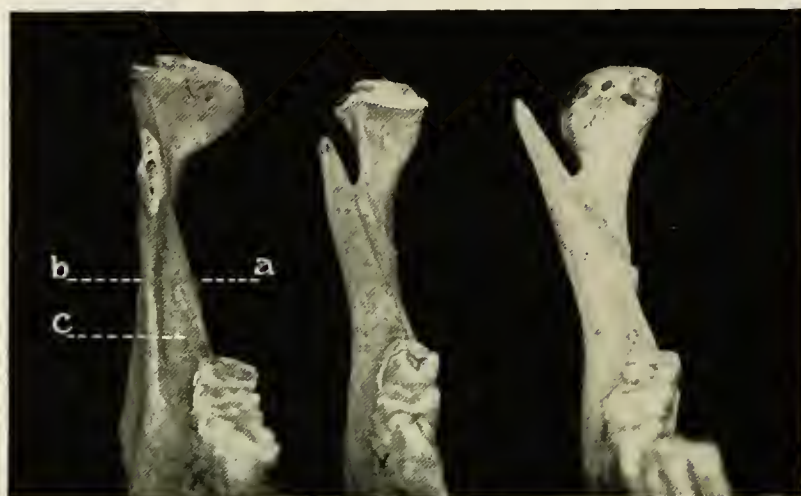


FIGURE 17

Anterior view of the rami in three mandibles, showing differences in the postmolar triangle. a. Internal oblique line. b. External oblique line. c. Post-molar triangle.

tance by which the point of the lingula extends over our normal line shows a marked difference. In the child it is only about one to two millimeters, while in the adult it is five to six millimeters. The shape of the lingula varies considerably. It may be only an indistinct ridge or a promi-



nent projection with a rounded edge or a sharp outstanding margin. From the foramen a decided groove runs obliquely downward. This is caused by the mylohyoid nerve and artery which are pressed against the bone by the internal pterygoid muscle. The muscle is attached to rough oblique ridges which often form a well-marked protuberance at the angle of the ramus. The internal pterygoid muscle covers the entire lower two-thirds of the internal surface of the ramus with the exception of a circular area forming a shallow depression called *sulcus mandibularis*.

The anterior surface of the ramus forms the postmolar triangle and furnishes a landmark for the pterygomandibular injection as will be seen later. Its external boundary is the external oblique line, which starts from the anterior margin of the coronoid process and passes downward and outward to the external surface of the body of the mandible, where it is continued as a well-marked ridge. This is always pronounced and can be easily palpated in the mouth. The internal boundary is the internal oblique line. This varies greatly in different people. Sometimes it is well marked, while at other times it is indistinct and there is a well-rounded margin between the anterior and internal surfaces of the ramus. The base of the triangle is formed by the distal alveolar margin of the third molar.

### **3. Sensory Innervation of the Oral Tissues and the Face**

The success of local anesthesia depends a great deal on the exact knowledge of the sensory innervation and nerve anastomosis of the parts. A thorough knowledge of the nerve supply and a clear picture of the course and distribution of the various branches as well as their surrounding anatomical structures should be constantly before the operator's mind.

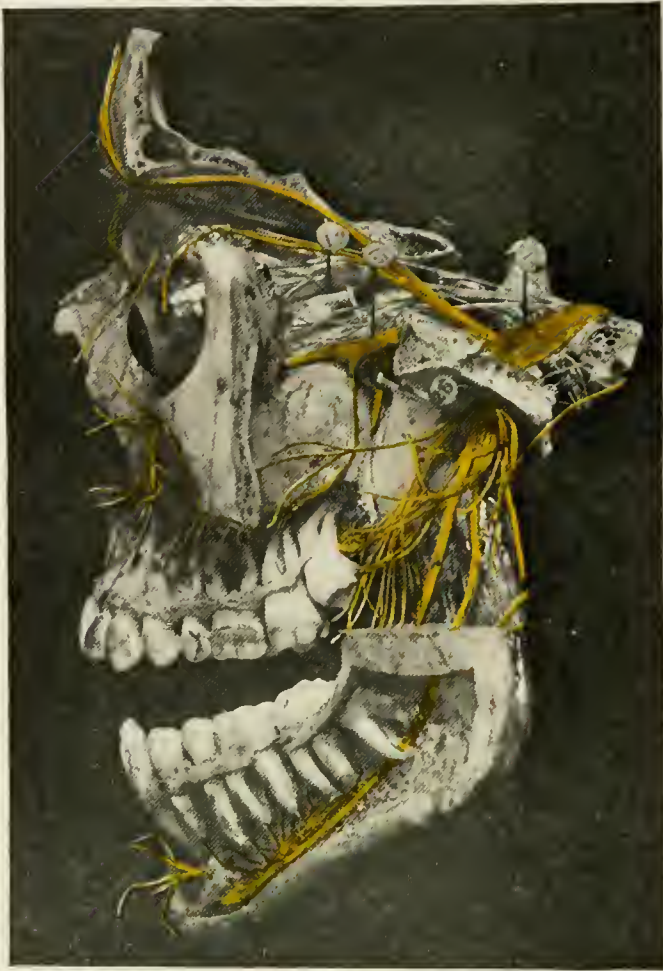

FIGURE 18

Dissected specimen, showing the trigeminal nerve.  
13. Maxillary division. 26. Mandibular division.

### The Trigeminal or Fifth Cranial Nerve

This supplies most of the tissues in the mouth. Its distribution is extensive and it is closely related to other nerves through the various ganglia and plexuses of the sympathetic system. Like a spinal nerve, it arises by two roots,

an anterior which supplies the motor branches and a posterior which forms the semilunar ganglion (O. T. Gasserian ganglion) from which all the sensory branches arise. The ganglion is situated in a shallow depression on the anterior surface of the pyramidal portion of the petrous bone and is covered by the dura mater. The branches emerge from the skull through three different openings.

### Ophthalmic Division

The **ophthalmic nerve** runs along the cavernous sinus, emerges through the superior orbital fissure, and at once divides into three branches, the lacrimal, the frontal, and the nasociliary nerves.

The **lacrimal nerve** enters the orbit and runs along the upper border of the external rectus muscle. It communicates with the zygomatic nerve of the maxillary division. It gives off filaments to the lacrimal gland, the conjunctiva, and finally terminates in the skin of the outer canthus of the upper eyelid.

The **frontal nerve** is the largest of the first division. It enters the orbit through the sphenoidal fissure and divides into two branches, the supratrochlear and the supraorbital.

The **supratrochlear branch** passes above the pulley of the superior oblique muscle and leaving the orbit by curving around the supraorbital arch, it divides into two branches. These pierce the orbicularis and frontalis muscles, supplying the skin of the forehead on either side of the middle line and send branches to the conjunctiva and skin of the upper lid. There is also a branch given off which joins the infratrochlear branch of the nasociliary nerve.

The **supraorbital branch** emerges through the supra-orbital foramen. It gives off filaments to the upper eyelid and the mucous membrane of the frontal sinus, terminating in the cutaneous and pericranial branches. The cutaneous branches extend posteriorly as far as the vertex,

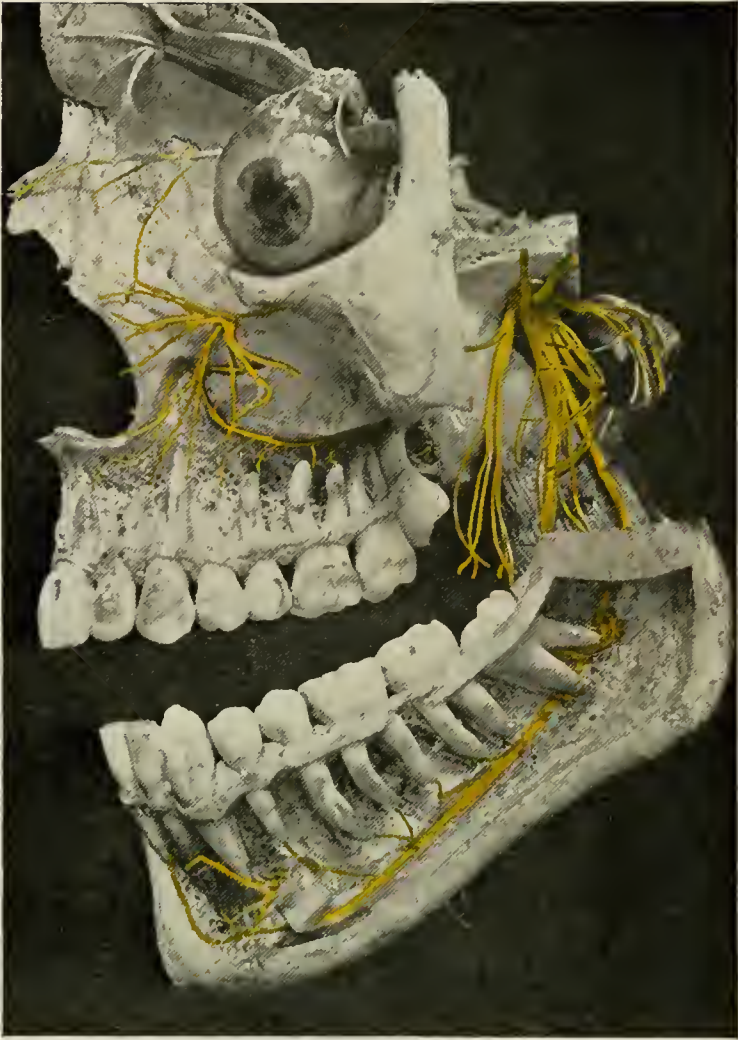

FIGURE 19  
Dissected specimen showing the trigeminal nerve.

while the pericranial ones are distributed in the pericranium of the frontal and parietal bone.

The **nasociliary nerve** enters the orbit through the sphenoidal fissure and passes to the inner wall of the orbit

until it enters the cranium through the anterior ethmoidal foramen and, transversing a shallow groove on the front of the cribriform plate, it passes through the nasal fissure

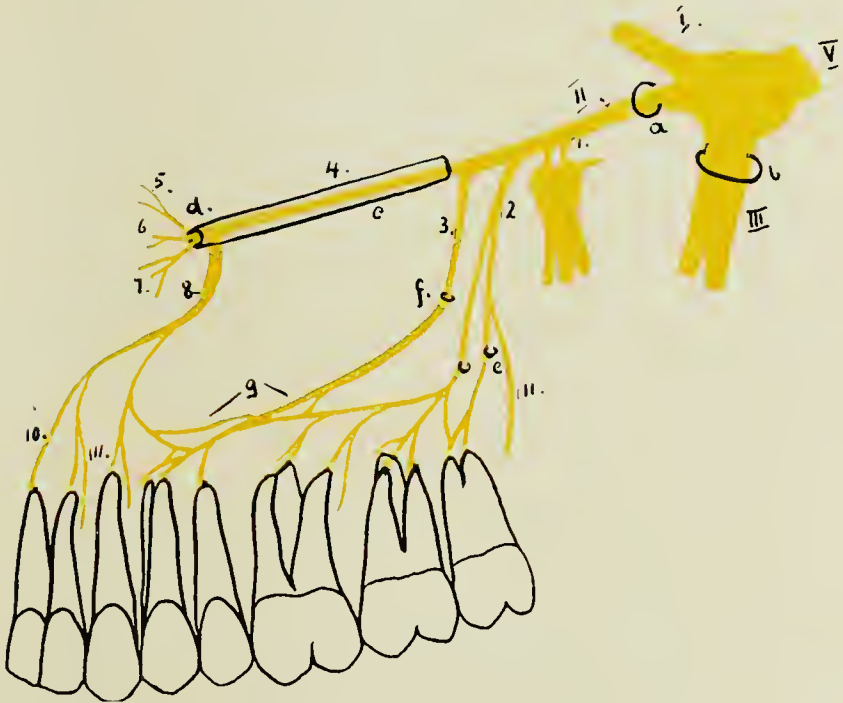


FIGURE 20

Diagram of the maxillary division of the trigeminal nerve. V. Ganglion semilunare; I. N. ophthalmicus; II. N. maxillaris; III. N. mandibularis; 1. N. sphenopalatine; 2. Rami alviolares superiores posteriores; 3. Ramus alviolaris superior medius; 4. N. infraorbitalis; 5. Rami palpebrales; 6. Rami nasales; 7. Rami labiales; 8. Rami alviolares superiores anteriores; 9. Plexus dentalis superior; 10. Ramus dentalis superior; 11. Ramus gingivalis superior; a. F. rotundum; b. F. ovale; c. Canalis infraorbitalis; d. Foramen infraorbitalis; e. Foramina alviolaria posteriores.

by the side of the crista galli into the nose. Here it gives off a branch, the internal nasal, to the mucous membrane of the nasal septum.

**The external nasal branch** is given off with the internal. It supplies the tip of the nose.

**The infratrochlear branch** is given off just before the nasociliary nerve passes through the anterior ethmoidal foramen and joined by the filament of the supratrochlear nerve, it passes to the inner canthus of the eye, the conjunctiva, the cornea, and the skin of the bridge of the nose.

### Maxillary Division

**The maxillary nerve** emerges from the foramen rotundum. It is entirely sensory. It crosses the pterygopalatine fossa (O. T. sphenomaxillary fossa) and enters the infraorbital groove which leads into the canal of the same name. Here it is called the infraorbital nerve. In the pterygopalatine fossa, the zygomatic and sphenopalatine branches are given off.

**The zygomatic nerve** enters the orbit and immediately divides into two branches: the zygomatico-temporal and zygomatico-facial. The first supplies the skin of the anterior part of the temple as well as the conjunctiva and lateral part of the lower lid, the latter the zygomatic region of the face.

**The sphenopalatine nerves** descend from the first part of the maxillary nerve to form the sensory or short roots of the sphenopalatine ganglion.

**The posterior superior alveolar branches** (O. T. dental rami) are given off just before the nerve enters the infraorbital groove. They are two or three in number, but often have a common trunk. They divide and pass downward on the tuberosity of the maxilla. Filaments ramify to the buccal part of the gum and mucous membrane of the cheek; these are called the superior gingival branches. The posterior alveolar branches enter from the infratemporal surface of the maxilla into the posterior alveolar canals. They supply the mucous membrane of the maxillary sinus, and then take part in the formation of the superior dental plexus,

supplying the molar teeth, the alveolo-dental membrane and the gum.

**The middle superior alveolar nerve** sometimes branches from the maxillary nerve just before it enters the infra-orbital groove. More frequently, however, it originates in the posterior part of the canal. It runs downward and

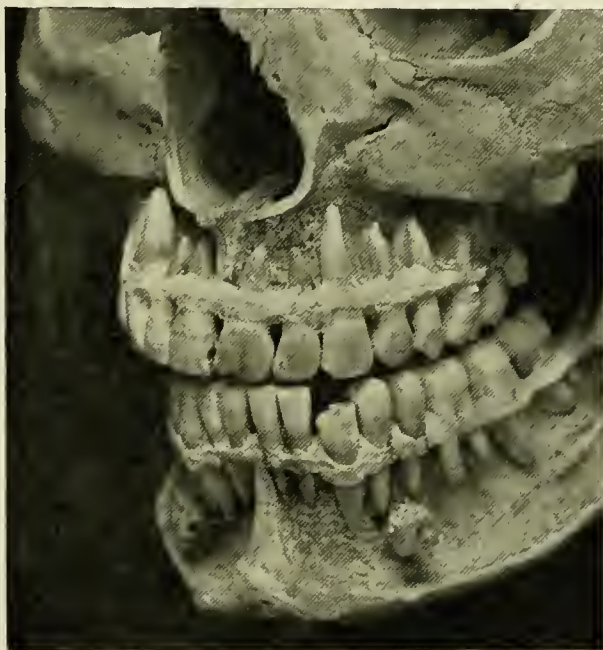


FIGURE 21

Dissected skull, showing the anterior superior alveolar canal.

forward on the outer wall of the maxillary sinus, in a special canal, to supply the bicuspid teeth and join in the formation of the superior dental plexus.

**The anterior superior alveolar branch** is the largest. As a common trunk, it runs through a canal in the anterior wall of the antrum; then divides into a series of branches, supplying the incisor teeth and the cuspid and anastomosing with the middle superior alveolar branch. It also supplies the

fore part of the mucous membrane of the inferior meatus of the nose. It is a common observation that by anesthetizing the mucous membrane of the nose, the patient experiences numbness of the front teeth.

**The superior dental plexus** is formed by the free branching of the three superior alveolar nerves. Its subdivisions supply the teeth and the alveolar process.

**The superior dental rami** are the small nerve fibers which enter the roots of the teeth by the apical foramina, to take part in the formation of the pulps, supplying also the alveolo-dental membrane.

**The superior gingival branches** are also given off from the superior dental plexus. They pass into the alveolar process and supply the gum.

**The infraorbital nerve** forms three terminal branches after it emerges from the foramen.

**The inferior palpebral branches** pass upward beneath the orbicularis palpebrarum muscle and supply sensory fibers to the skin and conjunctiva of the lower eyelid.

**The internal nasal branches** supply the skin of the side of the nose and join with the nasal branches of the ophthalmic nerve.

**The superior labial branches** are the most numerous. They pass beneath the levator labii superioris muscle and are distributed to the mucous membrane of the oral cavity overlying the anterior surface of the maxilla and the integument of the upper lip.

**The sphenopalatine ganglion** (O. T. Meckel's ganglion) is deeply placed in the pterygomaxillary fossa. It is heart-shaped and lies just below the maxillary nerve, in which it has two sensory roots. The motor root arises from the facial nerve and is called the large superficial petrosal nerve; the sympathetic root comes from the carotid plexus, and is called the deep petrosal nerve. They join and form the Vidian nerve. The following branches of the sphenopalatine ganglion are of interest:



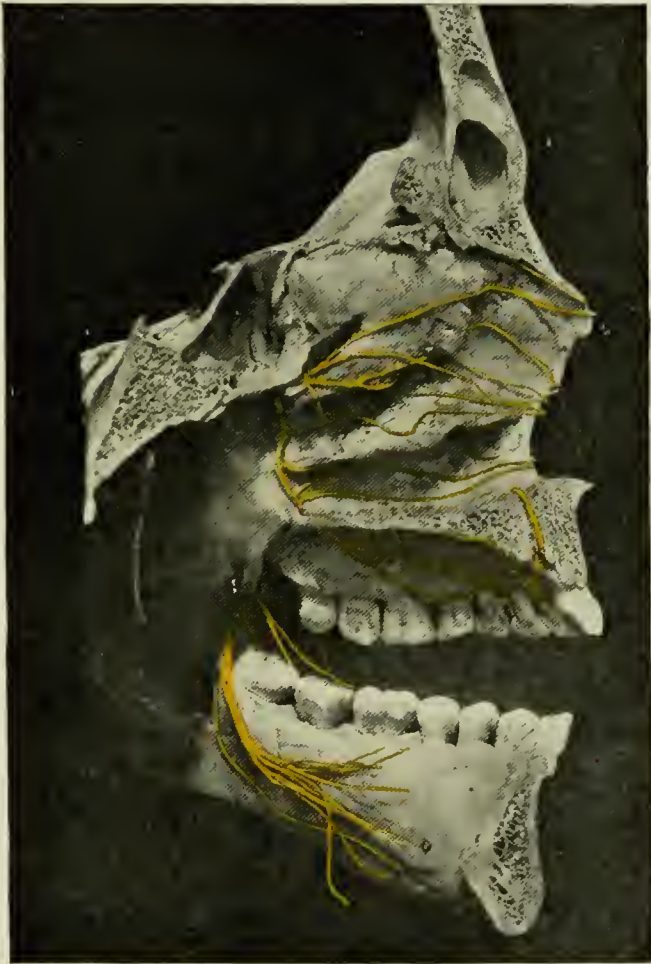

FIGURE 22

Sagittal section of skull through median line, to show nasal and palatal branches of sphenopalatine ganglion; also lingual and buccinator nerve.

The anterior palatine nerve passes through the palatine canal emerging from the palatine foramen and is accompanied by the artery which supplies the hard palate, as far forward as the cuspid teeth.

The middle palatine nerve issues through the accessory palatine foramen, supplying the soft palate, uvula, and tonsils.

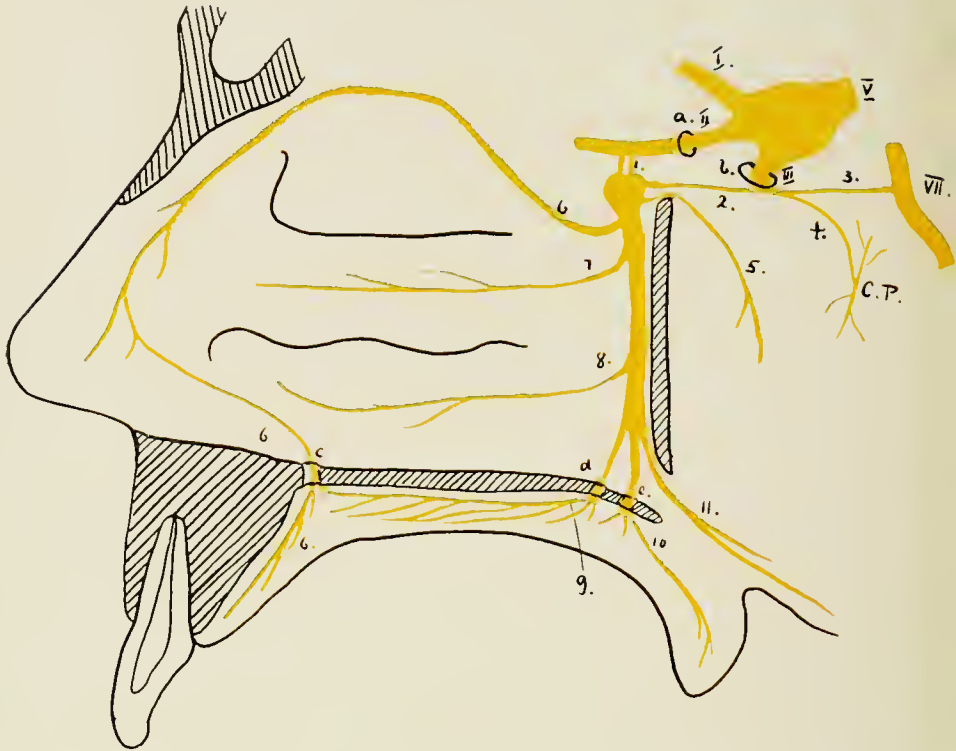


FIGURE 23

Diagram of the sphenopalatine ganglion and its branches. V. Ganglion semilunare; I. N. ophthalmicus; II. N. maxillaris; III. N. mandibularis; IV. N. spheno-palatini; 2. N. vidii; 3. N. petrosus superficialis major (from N. facialis); 4. N. petrosus profundus (from carotid plexus); 5. N. pharyngis; 6. N. naso-palatinus; 7, 8. Rami nasales; 9. N. palatinus anterior; 10. N. palatinus medius; 11. N. palatinus posterior; a. F. rotundum; b. F. ovale; c. F. incisivum; d. F. palatinum majus; e. F. palatinum minus.

The **naso-palatine nerve** runs from the sphenopalatine foramen across the inside of the roof of the nose until it reaches the septum. From here it passes downward and

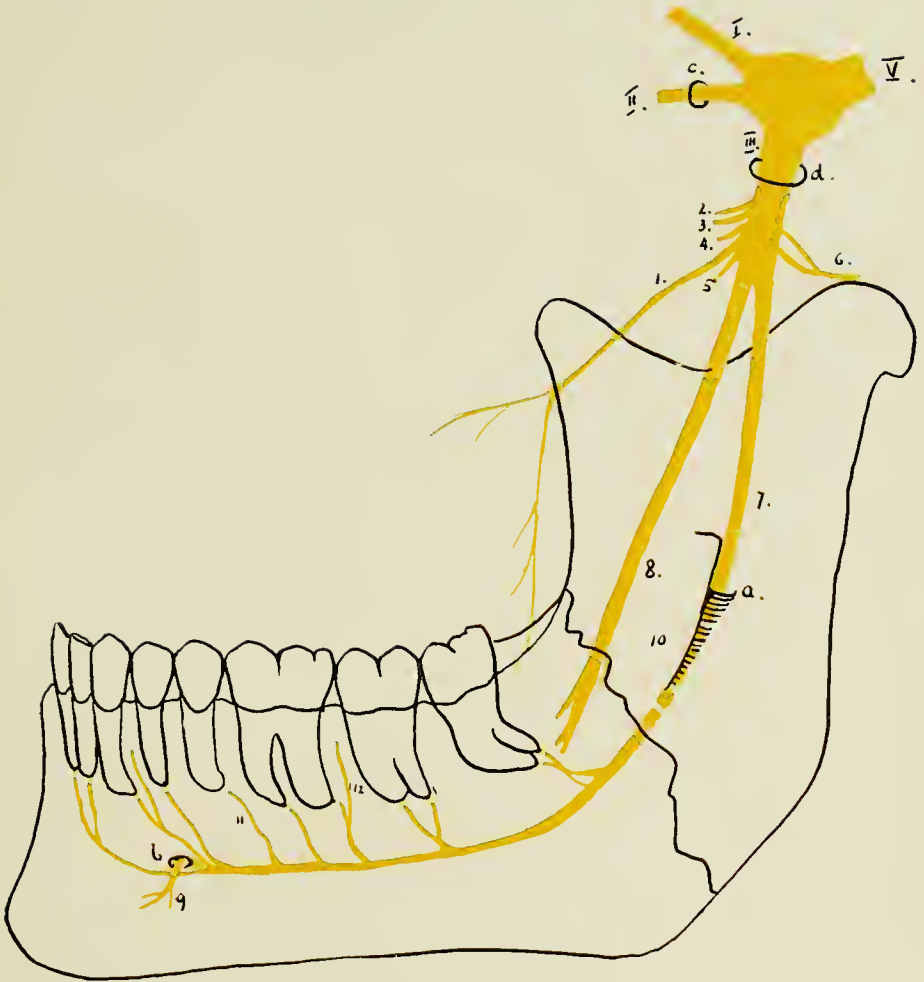


FIGURE 24

Diagram of the mandibular division of the trigeminal nerve. V. Ganglion semilunare; I. N. ophthalmicus; II. N. maxillaris; III. N. mandibularis; 1. N. buccinatorius; 2. N. massetericus; 3. Nn. temporalis profundus; 4. N. pterygoideus externus; 5. N. pterygoideus internus; 6. N. auriculo temporalis; 7. N. alviolaris inferior; 8. N. lingualis; 9. N. mentalis; 10. N. mylohyoideus; 11. Ramus dentalis inferior; 12. Ramus gingivalis inferior; a. F. mandibularis; b. F. mentalis; c. F. rotundum; d. F. ovale.

forward between the periosteum and the mucous membrane to the incisive canal. It emerges from the incisive foramen, is distributed over the anterior part of the hard palate, and anastomoses with the anterior palatine nerve.

### Mandibular Division

**The mandibular nerve.** This is the largest of the three divisions of the trigeminal nerve and is made up of a sensory and a motor part. Its egress from the skull is through the foramen ovale and it immediately branches into anterior and posterior divisions.

The anterior part is made up almost entirely of motor fibers. It supplies the muscles of mastication and therefore is called the masticatory nerve. A description of its branches follows.

**The masseteric branch** passes in front of the mandibular articulation behind the tendon of the temporal muscle. It crosses the sigmoid notch with the artery of the same name and passes to the deep surface of the masseter muscle. It also gives off a small filament to the mandibular joint.

**The internal pterygoid branch** is in close contact with the otic ganglion. It passes downward and inward to the deep surface of the internal pterygoid muscle.

**The deep temporal branch** passes outward and upward above the external pterygoid muscle and, being in close contact with the temporal bone, enters the deep part of the muscle.

**The external pterygoid branch** is most frequently given off from the buccinator branch, but may arise as a separate branch of the anterior part of the mandibular nerve. It supplies the external pterygoid muscle.

**The buccinator branch** is almost entirely sensory. It descends at the inner surface of the coronoid process and continues along the anterior margin of the ramus until it passes into the cheek at the level of the parotid duct. At

the surface of the buccinator muscle it divides into a superior and inferior branch. The superior supplies the upper part of the buccinator muscle and the skin overlying it, while the inferior passes forward to the angle of the mouth. It supplies the skin and lower part of the muscle, the mucous membrane lining the inner surface of the cheek and the buccal part of the gum in the lower jaw from the first or second bicuspid back to the ascending ramus.

The posterior part of the mandibular nerve is the larger and contains for the most part sensory fibers. It divides into three branches.

**The auriculotemporal nerve** arises as a rule by two roots which pass on each side of the middle meningeal artery and then reunite. It then passes back between the internal pterygoid muscle to the inner side of the neck of the mandible. From here it accompanies the temporal artery ascending over the zygoma, where it divides. The branches of the auriculotemporal nerve supply principally the skin of the anterior part of the auricle, and of the temporal region of the cheek, the external auditory meatus and part of the outer surface of the tympanic membrane.

**The lingual nerve** passes behind the external pterygoid muscle, together with the inferior alveolar nerve at its inner side. It soon turns forward and descends between the ramus of the mandible and the internal pterygoid muscle, descending at its anterior margin. Finally it crosses the submaxillary duct and supplies the anterior two-thirds of the tongue. It gives off branches to the tonsil and the inner surface of the mandible, being distributed to the periosteum, the lingual gum of the lower jaw, and the mucous membrane of the floor of the mouth.

**The inferior alveolar nerve** (O. T. inferior dental) is the largest branch of the mandibular nerve. It passes downward with the lingual nerve, at first beneath the external pterygoid muscle, then is joined by the inferior al-

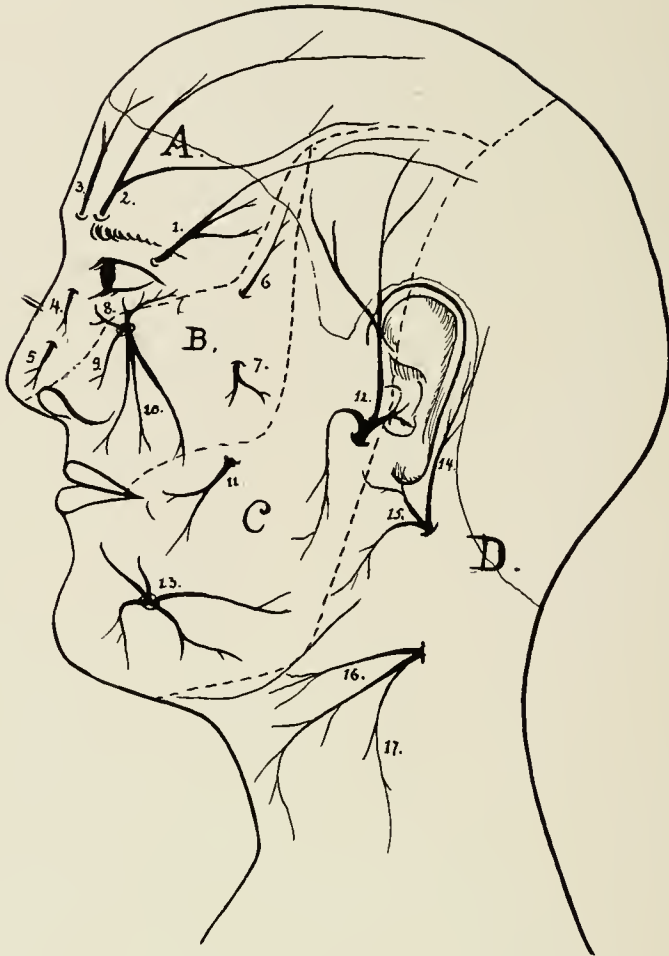


FIGURE 25

Lateral view of face, showing nerve supply of 'skin. 1. Lachrymal N. 2. Supraorbital N. 3. Supratrochlear N. 4. Infra-trochlear N. 5. Ext. nasal N. 6. Zygomatic-temp. N. 7. Zygomatic facial N. 8, 9, 10. Palpebral, nasal and labial branch of infraorbital N. 11. Buccinator N. 12. Auriculotemporal N. 13. Mental N. 14, 15. Post. and ant. great auricular N. 16, 17. Sup. and inf. cutaneous Coli. N.

A. Supplied by 1st division of V. B. Supplied by 2d division of V. C. Supplied by 3d division of V. D. Supplied by cervical nerves.

veolar artery and enters the pterygo-mandibular space between the inner side of the ramus and the internal pterygoid muscle. Both vessels and nerve enter the mandibular foramen, behind the lingula the nerve lying anteriorly. Here the mylohyoid nerve, which runs with the artery of the same name along the mylohyoid groove, is given off. It is chiefly motor in character and supplies principally the mylohyoid, digastric tensor palati and tensor tympani muscles. The inferior alveolar nerve follows the mandibular canal, forming the inferior dental plexus and giving off the mental branch in the bicuspid region. The remainder forms the incisor branch, which continues inside the mandible, supplying the incisor teeth. The end branches are said to anastomose with the branches of the opposite side, and some investigators (Bünthe and Moral) believe that they communicate with the lingual nerve forming a loop such as is found in the upper jaw, where the alveolar branches, coming from the tuber maxillare, anastomose with the anterior alveolar branches or the anterior palatine nerve, which in turn communicates with the nasopalatine nerve. The value of these anastomoses lies in the fact that nerve impulses intercepted in one direction may be transmitted by the other end of the loop.

**The inferior dental rami** enter the roots of the teeth to take part in the formation of the pulp and also to supply the alveolodental membrane.

**The inferior gingival rami** supply the alveolar process and gums.

**The mental nerve** is a branch of the inferior alveolar nerve. It emerges through the mental foramen, and supplies the skin of the chin, the corner of the mouth, and the mucous membrane of the lower lip and the anterior part of the gum, as far back as the first bicuspid tooth.

**The otic ganglion** is situated just below the foramen ovale and is in close contact with the inner surface of the

mandibular nerve. The long or sensory root is the lesser superficial petrosal nerve, a continuation of the tympanic branch of the glossopharyngeal and a branch from the auriculotemporal nerve. The motor root comes from the internal pterygoid branch of the mandibular nerve and the sympathetic root is derived from the plexus around the middle meningeal artery.

Its branches are filaments to the tensor tympani, chorda tympani, mucous membrane of the middle ear, and tensor palati.

The **submaxillary ganglion** is found over the deep part of the submaxillary salivary gland. Its sensory root arises from the lingual nerve, its motor root from filaments received by the lingual nerve from the chorda tympani, a branch of the facial nerve and the sympathetic root from the plexus around the facial artery. The branches are distributed to the submaxillary gland and duct and the mucous membrane of the mouth.

The following tables may be found practical for ready reference in regard to the sensory, secondary branches and main nerves supplying the organs and tissues of the mouth:

Region	Part Supplied	Sensory Branch	Secondary Branch	Main Nerve
<b>1. TEETH, ALVEOLAR PROCESS AND GUMS OF UPPER JAW</b>				
Incisor region	Teeth and labial part	Ant. Sup. Alveolar	Infraorbital	} Second Division of V.
	Palatal part	Naso-palatine	Sphenopalat. G.	
Bicuspid and molar region	Teeth and buccal part	Middle and post. sup. alveolar	Infraorbital	
	Palatal part	Ant. palatine	Sphenopalat. G.	
<b>2. TEETH, ALVEOLAR PROCESS AND GUMS OF LOWER JAW</b>				
Ant. region to 1st bicuspid	Teeth	Inf. alveolar	Inf. alveolar	} Third Division of V.
	Labial part	Mental	.....	
	Lingual part	Lingual	.....	
Post. region from 2d bicuspid to 3d molar	Teeth	Inf. alveolar	.....	
	Buccal part	Buccinator	.....	
	Lingual part	Lingual	.....	



Region	Part Supplied	Sensory Branch	Secondary Branch	Main Nerve
<b>3. INNERVATION OF UPPER JAW, MAXILLARY SINUS, AND LOWER JAW</b>				
Upper jaw	.....	Entire	.....	Second Division of V.
Max. sinus	External part Internal part	Sup. Alveolar Branches Nasal branches	Infraorbital Spheno-palat. G.	} Second Division of V.
Lower jaw	.....	Entire sensory branches	.....	
<b>4. INNERVATION OF PALATE, CHEEKS, TONGUE, FLOOR OF MOUTH, LIPS</b>				
Hard palate	{ Ant. part Post. part	Naso. palatine Ant. palatine	} Spheno-palat. G.	} Second Division of V.
Soft palate	{ Soft palate Uvula	Mid. & post. palat. Mid. & post. palat.		
Cheeks	Mucous membrane	Buccinator	.....	Third Division of V.
Tongue	{ Ant. part Post. part	Lingual Lingual branch	.....	} Third Division of V. Glosso-pharyngeal
Floor of mouth	.....	Lingual	.....	
Lips	{ Upper lip Lower lip	Labialis superior Mental	Infraorbital Inf. Alveolar	Second Division Third Division of V.
<b>5. INNERVATION OF THE SKIN OF FACE AND NECK</b>				
Skin of outer cantus		Lacrimal	} Frontal	} First Division of V.
Upper lid, forehead and Crown		Supraorbital Supratrochlear		
Skin of inner cantus		{ Infraorbital Ext. nasal		
Tip of nose		Zygomaticotemp.	} Zygomatic	} Second Division of V.
Ant. part of temple		Zygomatofacial		
Malar region		Palpebral	} Infraorbital	
Lower eyelid and ant. part of cheek		Nasal		
Ala of nose		Labial	} Buccinator	
Upper lip		Auriculotemporal		
Angle of mouth		Mental	Inf. alveolar	} Third Division of V.
Ant. part of auricle, temple and cheek		Aot. branch of great Auricular	} Post. branch of great Auricular	
Lower jaw and chin				} Cervical Plexus
Angle of jaw				
Post. Auricular region		Sup. cutaneous Coli	} Inf. cutaneous Coli	
Inf. border of jaw				
Ant. part of neck				

## PART III

### INSTRUMENTARIUM

A LARGE number of syringes and accessory appliances for local anesthesia have been devised during the last few years, and the extensive armamentarium which is sometimes illustrated in publications or exhibited by a clinician creates a great deal of confusion in the mind of the beginner. The armamentarium should be simple and adapted for quick use, facilitating sterilization and aseptic measures. It is best to keep the entire outfit for local anesthesia separately on a small aseptic glass table.

For intraoral anesthesia the author uses the following:

**Syringe No. 1 for Intraoral Injections.** The R. and R. Fischer syringe made of metal and glass is satisfactory for all conditions. It is advisable to keep two or three mounted with the various needles and connections in order to save time. The author uses the long 42 mm. needles for both methods and has two syringes mounted with these, so that the nurse or assistant can refill one while the other is in use. This has the advantage of saving time, if more than one injection is required, and does away with moments of apprehension and dread, experienced by the very sensitive patient. The third syringe should have a barrel long enough to hold 3 cc. and should be fitted with the special bayonet attachment designed by the writer and a 50 mm. needle for the sphenomaxillary injection. (Some R. and R. Fischer syringes are graduated to 2 cc., but have barrels sufficiently long to hold 3 cc.)

**Needles.** Schimmel needles with short, concave, razor-edged points are employed. These are not soldered to the hub, but are passed through it, and when screwed into

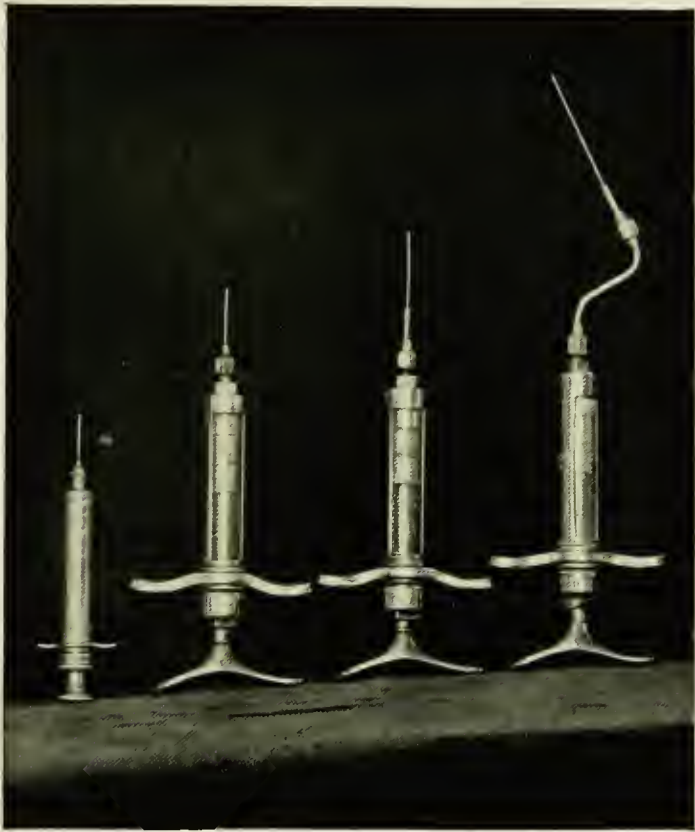

FIGURE 26

Syringes for intraoral methods. The small syringe with 27-gauge platinum needle for mucous anesthesia previous to injecting with the large syringe. The next syringe is Fischer's syringe, mounted with the short needle. The third is mounted with the 45 mm. long needle, and the last one is mounted with Fischer's bayonet piece and a 50 mm. long needle.

the syringe, the soft metal cone at the end of the needle is expanded and forms a non-leakable joint. The needles

are manufactured in steel, pure nickel, gold, and iridio-platinum.

Steel needles, when used, should either be discarded after each case or subjected to a careful sterilization. When sterilizing, the needle must be washed, boiled, alcohol forced through the lumen, and dried by hot air, after which



FIGURE 27

New bayonet attachment with 50 mm. needle.

a wire should be drawn through and the needle laid in a carefully stopped glass vial. This is important, because steel needles, when not perfectly dry, are apt to rust and to break during an injection. Iridio-platinum needles are used by the writer, as they may be bent several times with less danger of breaking, and if desirable they can be slightly curved, which is of help in some cases. They can be left mounted and are therefore always ready for use. Frequent

sharpening is of importance, in order to minimize the pain caused by inserting the needle. A special round, fine, engine stone may be used for this purpose. Use the following needles and hubs:

Method of Anesthesia	Length in mm.	Inches	Metal	Gauge	Hub
Infiltration anesthesia	26	1	I. P.	25	short
Conduction anesthesia except	42	1 $\frac{5}{8}$	I. P.	25	long
For sphenomaxillary injection	50	2	I. P.	25	long

A 42 mm. needle can also be had with extra heavy walls and the same outside diameter. This needle is considerably stronger and is to be highly recommended.

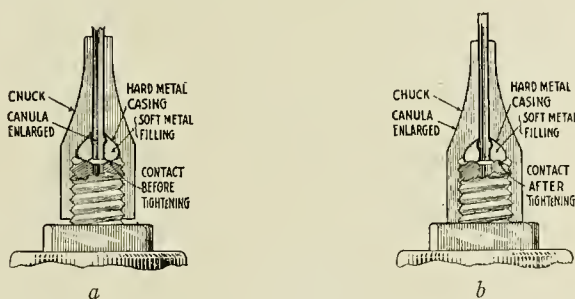


FIGURE 28

Schimmel needle in hub. Shows how a tight joint is produced by tightening the hub. a. Before tightening up. b. After tightening up.

**Boiling cups** are made in three sizes, containing 3 cc., 6 cc., and 10 cc. of solution. The best are made of a porcelain which is free from alkalis. They are graduated and come with a wire handle which serves at the same time as a holder. Unfortunately the holder corrodes in alcohol. Any dentist, however, can easily make a handle of similar shape of pure nickel wire or precious metal. The cups should be cleaned occasionally with dilute hydrochloric acid.



FIGURE 29  
Large and small dissolving cups.



FIGURE 30  
Glass jar with ground cover and glass tray to hold syringes and cups.

A glass jar with ground-glass cover to prevent evaporation is used to sterilize and keep the syringes and boiling cups in. A new one has been perfected recently, which contains a glass tray instead of a metal stand.<sup>1</sup> It has four holes for either two syringes and two cups or three syringes and one cup. The cups can also be placed on the top of the tray without the wire holder. Pure alcohol can only be purchased if one is the holder of a special permit, which is given on bond,




FIGURE 31

Bottle for Ringer solution and tray for tablets and needles.

but it can be substituted by the following formula:

Alcohol 95 p. c.	. . . . .	99 parts
Phenolis	. . . . .	1 part

**Bottle for Ringer Solution.** This bottle has a ground-glass stopper and protecting cover. The bottle should be marked 100 cc., so as to facilitate the making of the solution, which is described in the next chapter.

A glass tray with cover is useful for novocain tubes, reserve needles, and engine stones for sharpening needles. A similar tray can be used for applicators. These are the

<sup>1</sup> John Hood Co., Boston, Mass.

regular applicating sticks cut in half and wound with cotton on one end. A certain number should be prepared, sterilized, and put in the container for applying the iodine solution to the mucous membrane.

An **alcohol lamp** fitted with protecting shield for flame and ring to hold dissolving cups.



FIGURE 32

Alcohol lamp with holder for dissolving cups.

For extraoral anesthesia additional instruments are required:

**Syringe No. 2 for Extraoral Injections.** A Record, or Luer syringe of 5 cc. capacity is used. These have slip connection ends and can be readily attached after the needle has been inserted. They can be taken apart and sterilized by boiling; but no soap or soda solution should be used, *as alkaloidal reagents decompose the anesthetic solution*. The Record syringe is made of glass and metal, but can be easily taken apart and reassembled without having to tighten any parts by means of wrenches or pliers. The Luer syringe is still simpler, being made entirely of glass, but the nozzle breaks easily.



**Needles.** An assortment of steel or nickel needles fitting the nozzle of the syringe should be kept on hand. It is of advantage to have a number of various gauges and lengths.

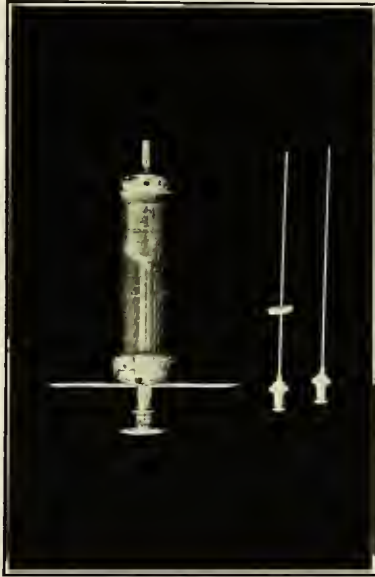

FIGURE 33

Record syringe and needles for extraoral methods.

A needle of 22 or 23 gauge and 6 to 8 cm. long answers nearly all requirements. All that has been said about the steel needles for the intraoral methods applies to these. (Iridio-platinum recommended.)

## PART IV

### PHARMACOLOGY OF DRUGS USED FOR LOCAL ANESTHESIA

#### Cocain

A CERTAIN plant, later named *Erythroxylum coca*, the leaves of which were used by the natives of Peru and Bolivia for overcoming hunger and fatigue, was discovered by Pizarro in 1532. He observed that runners, after chewing the leaves, were capable of enduring the fatigue of long distances without being conscious of hunger. He deduced that the absence of the sensation of hunger was the result of the local anesthetic action on the endings of the sensory nerves of the stomach, and that the prevention of exhaustion was probably due to stimulation of the central nervous system. It was not until the nineteenth century that the plant was exported to Europe. From the leaves an alkaloid of the formula  $C_{17}H_{24}NO_4$  called cocain was extracted, from which several salts were prepared, the principal one being cocain hydrochloride,  $C_{17}H_{24}HCl$ . In 1855 Garmecke noted that the leaves when chewed caused numbness of the tongue. Von Aure in 1879 was the first to inject cocain into his arm. Soon afterward many investigators tried a solution for operations on the eye, throat, and nose. Its use was more and more developed and a great advance was made when Carning and Goldscheider demonstrated that nerve impulses were inhibited when cocain was injected into a nerve. Cocain gradually came into general use and was employed in from one half to twenty per cent solutions in all fields of medicine. Its toxic effects, however, became more and more evident and many fatal cases were

reported from even very small doses, while comparatively large amounts could be administered to others without deleterious results. It was found that in certain diseases cocain was contraindicated on account of its toxic action on the nerves, kidneys, and heart, especially in anemia, chlorosis, neurasthenia, nephritis, heart disease, arteriosclerosis, and in patients with lowered resistance. These untoward effects became a serious objection to the use of this drug, which was the means of promoting the development of a new method for the elimination of pain in surgical operations. Moreover, its habit-forming property, with its sinister sequelae of pathological and moral degeneration, revealed such a serious aspect that even legislative measures had to be invoked to protect society against its use. Scientists, therefore, endeavored to discover a drug to replace the dangerous cocain and a number of comparatively non-toxic local anesthetics were prepared. Prominent among these are Alpha- and Beta-Eucaine, Stovaine, Alypin, Tropacocain, Anesthesin, Holocain, Quinine Urea Hydrochlorid, and Apthesine. Most of these, however, have their shortcomings. Some are very irritant; others almost as toxic as cocain; still others cannot be sterilized by boiling, or the anesthesia produced is not satisfactory.

**Requirements of a Substitute for Cocain.** Braun, who has contributed largely to the development of local anesthesia, formulated the following requirements of a substitute for cocain:

1. The substitute must not be inferior to cocain in its anesthesia-producing power.
2. It must be relatively non-toxic.
3. It must not have any irritating action even on the most delicate tissue, but must be absorbed from the place of application, without causing hyperemia, inflammation, painful infiltrates or necrosis.
4. It must be possible to combine the substance with

suprarenin without losing any of its potency, and it should not affect the suprarenin.

5. It must be soluble in water and the solution sufficiently stable to permit sterilization at boiling temperature.

### Apothesine

The hydrochloride of dimethyl-amino-propyl cinnamate, called apotesine, is the most recent local anesthetic. It is recommended by some prominent surgeons and is said to conform with Braun's requirements. The author has used it experimentally in a few cases, with fair results. However, it presents no advantage over procaine, and its combination with adrenalin instead of the synthetic suprarenin is an objection. The sugar of milk which is used as a base does not preserve the tablet sufficiently.

### Novocain

The rapid and general introduction, as well as the great advance in the technique and application of local anesthesia, is due in great measure to the discovery of novocain, and its application in combination with suprarenin. Novocain most nearly approaches the ideal anesthetic, as it practically satisfies all the requirements laid down by Braun.

**History of Production.** After the discovery of the anesthetic property of cocain, research was at once begun to determine its chemical structure and physiological action, and when the disadvantages of cocain became apparent, pharmacologists and chemists set out to produce synthetically a preparation possessing the same anesthetic qualities, but conforming with Braun's requirements, enumerated above. It was soon found that all esters of aromatic acids, to which class cocain belongs, had the property of inducing local anesthesia, and many hundreds of such esters have been prepared and physiologically tested. Einhorn examined a number of alkamine esters of benzoic acid but found that

they produced considerable irritation of the tissue. He replaced benzoic acid with its para-amino derivative and selected from a very large number of alkamine esters of aromatic amino and polyamino acids prepared in his laboratory, the diethyl-amino-ethanol ester of p-amido benzoic acid. This drug conformed so completely to the pharmacological and clinical requirements that its hydrochloride was introduced in 1905 under the name of novocain, after having been thoroughly tested by Braun, Bieberfeld, Bier, and others. Since then, its value as a local anesthetic has been demonstrated by an enormous number of investigators and clinicians in all branches of medicine and surgery.

### Procaine

Einhorn's diethyl-amino-ethanol ester of p-amido benzoic acid is now manufactured in the United States under license from the Federal Trade Commission and the name "Procaine," suggested by the American Medical Association, was adopted as a general designation for the product. Several manufacturers have been licensed to manufacture "Procaine" and are permitted to designate their brands by their respective trade-mark names in connection with the name "Procaine." The special preparation used by the writer and to which all statements made in this book pertain is the one manufactured by the H. A. Metz Laboratories and put on the market as "Novocain" or "Procaine-Metz."

It occurs as small, colorless and tasteless crystals, soluble in water (one part) and less soluble in alcohol (thirty parts). It is also soluble in glycerine (5 parts) at a temperature of 20° centigrade. Its melting point is 156° centigrade. Its aqueous solution is neutral and does not decompose on boiling.

**Chemical Reactions.** It shows the general alkaloid reactions. Tincture of iodine produces a brown and picric

acid a yellow precipitate. Alkalies produce a white precipitate, which is soluble in alcohol and ether. If a solution of 0.1 gram novocain is mixed with 5 cc. of water, three drops of dilute sulphuric acid and five drops of potassium permanganate, the violet color immediately disappears. This distinguishes novocain from cocain.

**Incompatibles.** Contact with alkalies, their carbonates, and all alkaloidal reagents should be avoided, as they decompose the drug.

**Physiological Properties.** It possesses the same action upon peripheral sensory nerves as cocain. The 0.25 per cent solution is sufficient to completely anesthetize even thick nerve trunks in about ten minutes. Locally applied there is no irritation, even if brought in strongly concentrated solutions upon the most sensitive tissue, such as the cornea. General effects upon the system after its absorption are scarcely perceptible; neither the circulation nor the respiration suffers, and the blood pressure is not increased.

**Dosage.** The maximum dose is 0.5 gram (Fischer) for subcutaneous injections, but as much as 2 grams has been used without producing symptoms. For dental and oral operations, requiring the use of conduction anesthesia, the maximum dose, which allows 24 cc., or 12 syringes full of a two per cent solution, is seldom reached. Caution should be used with patients with low blood pressure or heart depression. The writer, however, has used procaine with success in very serious cases of almost every description, where general anesthetics were contraindicated. Even cases with a history of cocain poisoning have been successfully handled with novocain.

**Toxic Properties.** Its use has become so general all over the world, with so very few reports of accidents, that it may well be considered a comparatively safe local anesthetic. It is difficult to determine its exact toxicity in man

owing to the fact that the production of general symptoms depends a good deal upon the manner and method of application and the so-called individual susceptibility to the drug. In this connection it should be borne in mind that psychological factors as well as physical conditions often play an important part in such cases, and that it is extremely difficult to distinguish between true toxic reactions and mental conditions. (See Chapter VI.) The toxic effects are generally compared with those caused by cocain and various investigators differ considerably as to the exact proportion. Biberfeld (1905) concluded that novocain was one fifth to one sixth as toxic as cocain. Le Broig (1909) found novocain about one half as toxic as cocain, while Piquand and Dreyfus (1910) concluded that novocain was one fourth to one sixth as toxic as cocain. All these figures were obtained by animal experiments and were again repeated by Roth in 1917. The following table is from his published article:

COMPARATIVE TOXICITY OF COCAIN & NOVOCAIN IN FROGS,  
MICE, RATS, GUINEA PIGS, AND RABBITS

Animal used	Method of administration	Cocain M.L.D. <sup>1</sup> in gms. per Kilo of body weight	Novocain M.L.D. in gms. per Kilo of body weight	Ratio of Toxicity Cocain to Novocain
Frogs	subcutaneously	1.000	0.700	1.0 to 1.4
Mice	"	0.100	0.550	5.5 to 1.0
Rats	"	0.200	2.000	10.0 to 1.0
Guinea pigs	"	0.060	0.600	10.0 to 1.0
Rabbits	"	0.075	0.400	5.3 to 1.0
"	intravenously <sup>2</sup>	0.0077	0.030	3.9 to 1.0

<sup>1</sup> The M.L.D. is the amount per kilogram of body weight required to kill within 24 hours.

<sup>2</sup> Administered under general anesthesia.

Roth concludes from these experiments, "that the relative toxicity of cocain and novocain varies and depends upon the amount used in making the determination, as well as upon the method of the administration of the drugs. For warm-blooded animals the toxicity of cocain is from four to ten times greater than novocain; while for a cold-blooded animal, the frog, the toxicity of novocain is slightly greater than cocain. A further experiment proved that if novocain or cocain is given intravenously in dilute solution to anesthetize rabbits, at about five-minute intervals, larger amounts of the drugs (186 mgs. per kilo of body weight) can be tolerated, than when given in a larger dose to the unanesthetized animals (27 mgs. per kilo of body weight)." This brings out an important factor, namely that the rate of the injection, together with the concentration employed, must be taken into account. The concentration of the drug in the blood at any given time is therefore of greatest importance; and in surface infiltration and conduction anesthesia, this depends greatly upon the amount and rapidity of absorption from the tissues into the general circulation. It is therefore evident that if the solution is accidentally injected into a vessel, disastrous consequences may immediately occur. Experiments made by Levy and Hatcher show that the suprarenin which generally is added to the solution to prolong the anesthetic action by retarding absorption, tends to lessen the toxicity of the drug to a notable degree, for the same reason.

The cause of death from novocain poisoning was also investigated. Roth found that after intravenous injection, the respiration stopped about one half to one minute before the heart, if the injection was made slowly (2-3 minutes). When making the injection rapidly, the animal receiving the entire amount in one fourth to one half of a minute, death would be cardiac, the heart stopping under these conditions 10-15 seconds before the respiration had ceased. The



symptoms preceding death are rapid and weak pulse, irregular respiration, often vomiting, chronic convulsions which may become violent, and collapse.

**Methods of Combating Toxic Effects.** On account of the rapid action of novocain poisoning, it is necessary to size up the situation quickly. In cases of simple fainting, in which the cause is of an entirely different nature, we rarely have more serious symptoms than pallor, limpness and loss of consciousness. In severe conditions it is safer to assume that we have to deal with real toxic effects. Fortunately such accidents are extremely rare, but call for immediate action.

Before all, place the patient in a recumbent position. This is easily accomplished with the modern dental chair. It relieves the heart considerably. Loosen all tight clothing; direct the patient to breathe deeply, or if respiratory failure is evident, resort to artificial respiration at once. Sylvester's method is best employed, and every anesthetist should be familiar with this method. In mild cases, aromatic spirits of ammonia (15 to 20 drops) may be administered with a small amount of water only to cause irritation of the mucous membrane. Better still is camphorated Validol. Kells suggested that it be administered by dropping the proper dose (7 to 8 drops) on sugar. In serious cases, however, hypodermic medication is to be resorted to at once. For a cardiac stimulant strychnin sulphate ( $\frac{1}{30}$  gr.) may be administered and repeated after fifteen minutes and once again, later, if necessary. If there is danger of respiratory failure, atropine sulphate ( $\frac{1}{120}$  to  $\frac{1}{60}$  gr.) should be given. These drugs should be kept on hand in the so-called "Greeley Units," so that no time is lost in preparing the solution. Greeley units are ideal for emergency. They consist of a collapsible tube, containing a definite dose of the drug in solution, sterile and ready for injection. The hypodermic needle is attached and closed with

a wire covered by a glass tube for asepsis. Camphor in oil,<sup>1</sup> 1-2 cc. hypodermically injected, has lately been introduced on account of its stimulant effect on both the respiratory center and the heart; it is also a sedative and is anti-spasmodic. It is given subcutaneously and repeated every half hour. The most rapid action, however, is gained by administering by inhalation. Smelling salts and aromatic spirits of ammonia act by irritating the mucous membrane, causing a reflex action. Engstadt of Minneapolis, who has been working for fifteen years on the problem of cocain poisoning, recommends ether, which he believes has a direct antidotal effect, as it is a directly acting, diffusible cardiac stimulant, stimulating the vasomotor as well as the respiratory centers. It increases blood pressure and apparently has a special affinity for the toxic elements of the diffusible alkaloids. Dr. Corbit of the University of Minnesota reports that also in animal experiments ether would prevent a fatal outcome from the toxic action of cocain or synthetic substitutes. Engstadt recommends for best results administration of ether to a degree of mild surgical analgesia only or even less than that. It is important to give the ether on a mask by the drop method so as not to exclude the air. Just a few shakes of the ether bottle on the mask is usually enough to revive the patient. Coffee should be given to all patients who have experienced toxic effects, no matter whether the condition was mild or very serious. Its effect is almost that of an antidote and its advantage as a respiratory and cardiac stimulant lies in its safety and lasting quality.

### Adrenalin

The discovery that deeper and more prolonged anesthesia can be produced by injecting cocain into an anemic field and that the toxic effects are greatly lessened was rendered practical when the physiological action of the extract of the suprarenal gland was discovered.

<sup>1</sup> Park Davis Co.

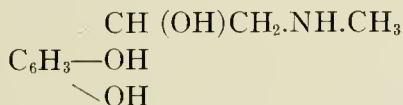
**Production.** The extract is gained from the suprarenal glands of the sheep or ox after the glands have been freed from fat, cleaned, dried, and powdered. The active principle occurs as a white crystalline substance, which dissolves readily in salt solutions. It is marketed under the name of adrenalin, suprarenalin, adnephtrin, epinephrin, and in England under the name of paranephtrin.

### Suprarenin Syntheticum

The unstable nature and admixture of organic impurities of the animal product and the fact that it decomposes and deteriorates very easily gave rise to the desire to produce this drug synthetically in a pure form. Such a product is now on the market and is called L-Suprarenin syntheticum.<sup>1</sup> It has been thoroughly tested by Biberfeld, Abderhalden, and Cushing, and found to equal if not surpass in its chemical and physiological properties, qualitative as well as quantitative, the best substances obtained from the suprarenal glands. On account of its purity, stability of action, and greater durability, it is far superior to the organic drug.

**Production.** Chloracetopyrocatechol is transformed by methylamin into methylaminacetopyrocatechol. By reducing this keton, the secondary alcohol, L.-Suprarenin syntheticum, is formed.

**Chemical Properties.** The chemical name is o-dioxyphenylethanolmethylamin. Its formula is:



Suprarenin synthetic is preferably used in the form of the bitartrate of suprarenin, and in its solution is the most stable of all salts. It is a white powder, insoluble in alcohol and ether. It does not dissolve easily in cold or hot water, but if titrated with diluted acids a clear solution is easily

<sup>1</sup> H. A. Metz Laboratories Inc.

obtained. Its melting point is 207–208° centigrade. Even synthetic suprarenin is very sensitive. Free alkali, air, light, and especially heat cause it to decompose. It must be kept in bottles made of special alkali-free glass, and should not be exposed unnecessarily. In solution it is stable only for a comparatively short time; in tablet form it keeps practically indefinitely either alone or in combination with procaine. The compressed tablets are preferable. Another advantage over the organic adrenalin is that it may be boiled for a short time for sterilization without decomposition. Pink or red coloring of the solution is a sign that the drug is decomposed. It should then be discarded so as to prevent toxic and irritating effects.

**Incompatibles.** Contact with alkalies should be avoided, as they decompose the drug.

**Physiological Properties.** Its local action, when applied to the surface of a mucous membrane or injected subcutaneously, is that of a powerful hemostatic. It contracts the walls of capillaries and smaller blood vessels by its action on the smooth muscle fibers. This is made use of in local anesthesia to retard the circulation in the injected part, thus hindering the dilution of the anesthetic and preventing too rapid absorption. It therefore intensifies and prolongs the anesthetic effect and at the same time decreases the danger of its own toxic properties, as well as that of the anesthetic used. It also may be used to produce a local anemia, which permits a bloodless field of operation.

Its general action on the system when absorbed in very small quantities, as in local anesthesia, is believed by the writer to be a beneficial and valuable one. Cannon, who has undertaken extensive investigations, published in his extremely interesting and important work "Bodily Changes in Pain, Hunger, and Fear" proved that adrenal secretions are released into the circulation in all strong emotions and pain, and that this in turn has a "purposive" nature in pre-

serving the welfare of the organism. The viscera are emptied of their blood while a vasodilator action is exerted on the heart, the brain, and the lungs, supplying these essential organs, the "tripod of life," as well as the skeletal muscles, abundantly with blood. This drug has a remarkable influence on fatigued skeletal muscles, quickly restoring them. It causes relaxation of the smooth muscles of the lungs, another means of rendering the organism more efficient, by supplying fresh air and a speedy discharge of the carbonaceous waste. Its action on the heart is of a stimulating nature, causing an increase both in rate and amplitude of cardiac contraction. It aids also in taking sugar from the liver's store of glycogen and adding it to the circulation, where it is utilized as a source of energy, and in supplying increased nutrition to the heart. The heart may consume, as Patterson and Starling have shown, as much as four times the ordinary amount of glycogen in extreme cases. On account of these physiological properties, suprarenin may be looked at as an "antidote" for toxic effects of cocain or novocain. It is made use of by Crile for the treatment of shock. He advocates its administration in combination with a saline infusion by inserting the needle of a hypodermic syringe filled with adrenalin chloride 1:1000 into the rubber tube near the canula, injecting one to two cc. drop by drop at short intervals. Its therapeutic value for this purpose is sometimes nothing short of marvelous, as the writer had occasion to observe in a desperate case of surgical shock.

**Toxic Properties.** If suprarenin is used subcutaneously in too highly concentrated solutions or if it is accidentally injected into a vessel, toxic symptoms may appear at once. Some individuals also are more susceptible to the effects of this drug. One of my patients gets toxic effects every time an injection of procaine and suprarenin is administered, as well as from the application of suprarenin (1:1000) alone to the mucous membrane of the nose. Systemic symptoms

attend, as increased pulse in rate and volume, blanching of the skin, due to constriction of the blood vessels, dilated pupils, stimulation of the secreting glands, causing excessive flow of saliva, mucous in the throat, and marked perspiration. There may be slight nausea and tremor of the extremities. The toxic effects of suprarenin are increased with the rapidity of injecting, as has been proven by animal experiments. The most serious results, however, are no doubt caused by accidental injection into a small vessel. Stale and discolored solutions are also more toxic. A fresh solution should be prepared from compressed tablets as manufactured by the Metz Laboratories in New York. These have been found the best by the writer. They keep for months in the original packing, and if properly taken care of, for a long time even after the tube has once been opened.

**Dosage.** In the first edition of this book, the author advocated a reduction of the percentage of suprarenin in the anesthetic solution for normal cases. This solution, containing only 0.00002 gram of suprarenin to 1 cc., has since then been used exclusively with very few exceptions. Many thousands of cases so treated have proven that the anesthesia is just as efficient and lasts approximately the same length of time, and that the number of cases with toxic symptoms has been reduced to a minimum. The experiments and observations of Nyman and Prinz confirm these findings.

On account of the temporary increase of the blood pressure caused by suprarenin in large doses, which is due to its stimulating action on the heart and the contraction of arterioles and capillaries, it is advisable to use a weaker solution and a smaller amount in patients with severe heart disease, anemia, arteriosclerosis, and in old people with hardened vessels and abnormally high blood pressure. In these cases use only 0.00001 gram of suprarenin to 1 cc.

If strong local anemia is desired, the percentage of supra-

renin should be increased to 0.00005 gram of suprarenin to 1 cc.

### Solvent Medium

The principal requirement of the solution is that it should be isotonic, sterile, and non-irritant, that is, free from any unnecessary chemicals such as are often added to patent preparations. No antiseptics or preservatives are necessary. Physiological salt solution is generally recommended for dissolving the anesthetic tablets. Some firms also prepare anesthetic tablets containing the salt required to make an isotonic solution. These are dissolved in distilled water only. There is, however, the disadvantage to this method that the concentration of the anesthetic solution cannot be varied by changing the amount of the solvent. The solution may be either hypertonic or hypotonic, depending on whether less or more distilled water is used. To counteract derogatory action of the glass alkali and to prevent oxidation of the suprarenin, Braun recommends adding a very small amount of dilute hydrochloric acid to the solution. His formula is:

Sodii chloridi puriss . . . . .	2.0
Acidi hydrochlorid. Diluti . . . . .	gtt. 1
Aquae dest . . . . .	300.0

Guerber found that the addition of calcium salts greatly improves the process of absorption in the tissue; it has a stimulating action on the leucocytes, which in turn increase the resistance to infection. At his instigation, Fischer recommended the use of the Ringer solution. This is made up as follows:

Sodium chloride . . . . .	0.50
Calcium chloride . . . . .	0.04
Potassium chloride . . . . .	0.02
Aquae dest . . . . .	100.00

Ringer tablets can be bought conveniently put up. Dissolve ten tablets in 100 cc. of distilled water, as described below.

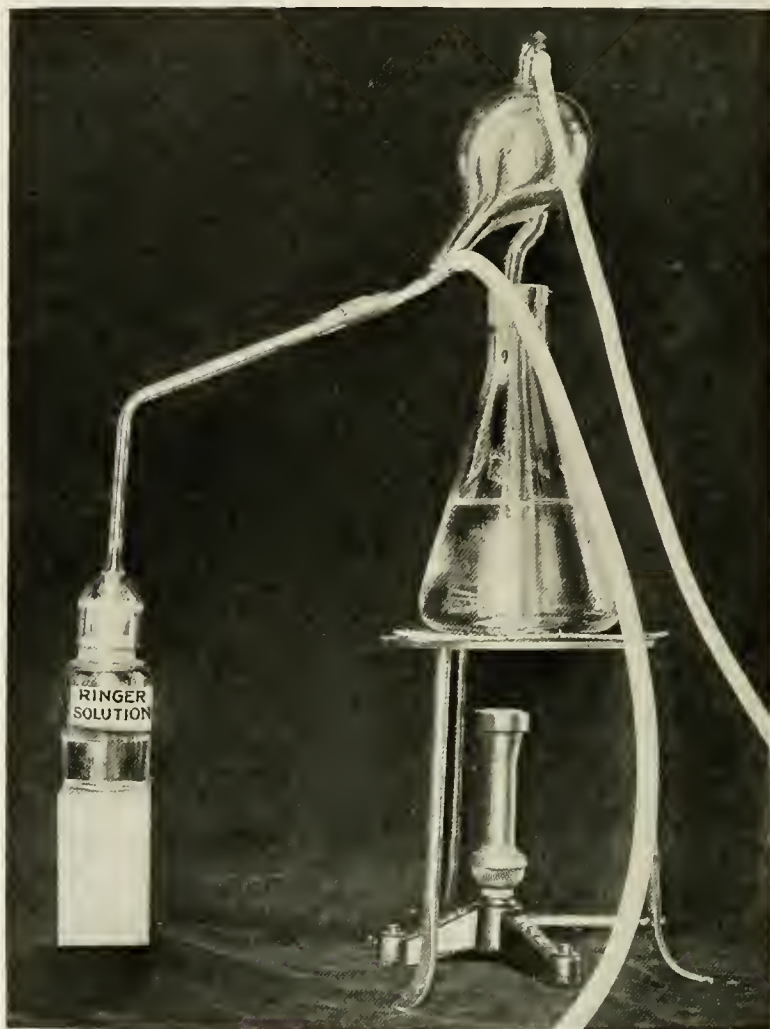

FIGURE 34

Femel apparatus to produce distilled water.



**Distilled Water.** Unfortunately, it is almost impossible to secure freshly prepared, pure, and sterile distilled water. If it is left to stand a few days, growths of all kinds of fungi and their products may be found. Vegetations of these can be seen by the naked eye swimming around the container, and although the organisms are killed when the solution is

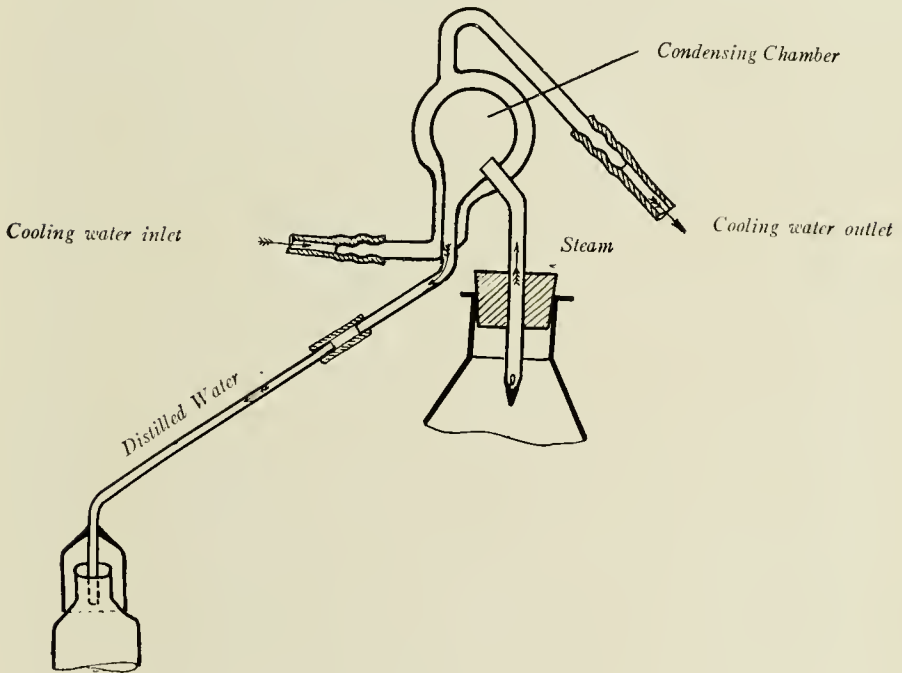


FIGURE 35

Diagram showing how Femel Still works.

boiled, the dead cells and their toxins are not eliminated by this process. Clinically, this was demonstrated by Ehrlich, who found that infusions of salvarsan made with commercial distilled water, caused toxic effects which did not occur if sterile, freshly distilled water was used. Any one can easily produce sterile, toxin-free and chemically pure distilled water, by means of a glass still, parts of which can be bought at any supply house dealing in chemical apparatus. Various

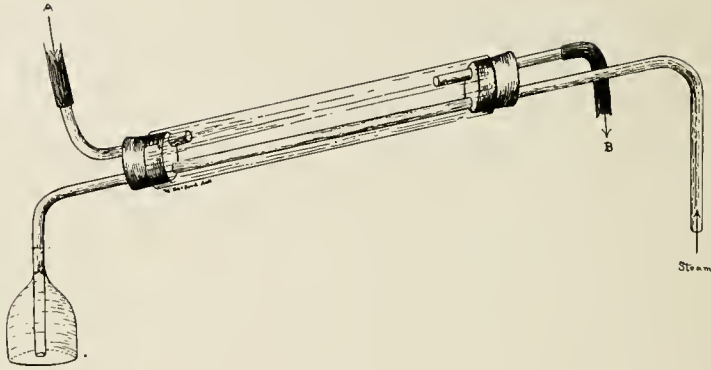


FIGURE 36a

A simple home-made still. A. Inlet for cooling water. B. Outlet.

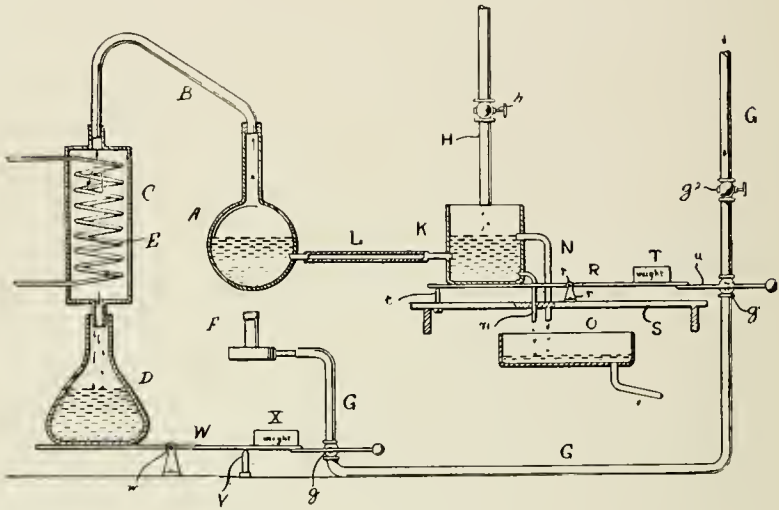


FIGURE 36b

Kells still. A. Container for tap water. B. Tube connecting with condenser. C. Condenser. E. Cooling coil. D. Final container. F. Bunsen burner. G. Gas pipe. H. Water pipe. h. Water faucet. K. Water reservoir. L. Tube connecting K with A. N. Overflow. n. Water outlet.

types are made. It is, however, important that it be made entirely of glass. The distilled water should not come in contact with metal. The "Femel still" which is used by the author is illustrated to explain the principle and the *modus operandi*. A vessel filled with tap water or, better still, commercial distilled water is fitted with a rubber stopper containing a glass tube. This leads to the condenser, which may have any form and is surrounded by a cooling chamber, through which cold water can be forced in an opposite direction to the steam. The outlet of the condenser is connected by a glass tube with a bottle which receives the distilled water. It should have a hood to protect the opening of the bottle while the still is in operation. Figure 35 shows a schematic drawing of the Femel apparatus. The simplest form of a still for small quantities is illustrated in Figure 36*a*. This can easily be made with glass tubes and rubber stoppers by any one.

The still is operated in the following manner: Set up the apparatus and connect the various parts. Heat the water and let the steam pass through the condenser into the receiving bottle. This bottle should be the final container. It should be cleaned previously as should all other parts and dealkalied by the use of dilute hydrochloric acid. Let steam pass through the apparatus for five to ten minutes for sterilizing purposes and then turn on the cooling water. This will condense the steam entering the condensing chamber and the distilled water will run into the bottle into which 10 Ringer tablets are placed. The bottle is graduated and when it is filled to the 100cc. mark, the apparatus is disconnected and the bottle closed.

Figure 36*b* shows the Kells still. It is operated on the same principles, but has some ingenious accessories. *A* indicates the bottle, filled with tap water. This is continuously fed from a reservoir, *K*, into which the water flows from the faucet. It is kept at a certain level by means of the overflow,

*N.* The steam from the vessel, *A*, is conducted into the condenser, which contains a cooling coil, and from here it drops into the final container. There are two automatic shut-offs, which are not absolutely necessary, but one or the other can be used according to the conditions under which the still is operated. The first one is connected with the final container and automatically shuts off the gas underneath the container, *A*, when the bottle is full of distilled water. This is accomplished in the following manner:

When the bottle, *D*, is full, its weight is counterbalanced by the weight, *X*, which releases the gas shut-off, *g*. A similar contrivance may be used in connection with the reservoir, *K*. This, however, is only necessary in localities where the tap water is liable to be cut off without notice. The arrangement causes the gas to be shut off at *g'* if the water in the reservoir, *K*, is emptied and not replenished.

The whole unit makes possible the production of distilled water without supervision.

### Procaine-Suprarenin Combined

Procaine-suprarenin solution may be prepared in various ways. The simplest methods are, however, not always the best and nothing is of greater importance than to be sure that the anesthetic provided is fresh, non-toxic and safe.

**Ampules** containing prepared solutions of procaine and suprarenin are in the market. It is only necessary to break the end, insert the needle, and draw the contents into the syringe. However, there are objections; it is difficult to know the age of these solutions, and procaine and suprarenin do not keep as well in solution as in tablet form. The solutions from ampules are often badly discolored and the question as to the sterility of the solution may be raised. Most solutions which come in ampules contain antiseptics, such as thymol, carbolic acid, and others which are equally

harmful, because they are irritants and often are the cause of pain, edema, and necrosis.

**Prepared Solutions.** Solutions put up in bottles are still more undesirable than those in ampules. After the bottle is once opened, the remainder of the solution deteriorates quickly. To overcome this, manufacturers again add anti-septics. These, besides being harmful, will only protect the drug from bacterial deterioration while most of the toxic properties come from chemical decomposition due to the effects of light, air, and heat.

**Seidel's Method.** Seidel makes up a sterile 2 per cent novocain solution in large quantity which he keeps on hand. From this, he measures out as much as he requires and adds to it by means of a special normal pipette as many normal drops of suprarenin solution as required. While this method no doubt is almost ideal, allowing changes in the dose of suprarenin for every case, it, nevertheless, has its disadvantages. The sensitiveness of the suprarenin solution to external influences, especially if not used frequently, is perhaps the greatest objection. It causes considerable waste, as the remainder of the solution cannot be used very long after the bottle has once been opened. The danger of toxic effects is increased, and if the solution has to be prepared by the office assistant, there is the additional possibility of errors which may have serious results.

**Tablets, Author's Method.** Procaine and suprarenin keep best if combined in tablet form. In the tablets the two ingredients are mixed in a dry state, in which they are better preserved. They do not deteriorate as long as no moisture penetrates into the tube, which is prevented by the use of a rubber stopper. The best tablets are the compressed kind, as they are not as hygroscopic as the ones with sugar of milk as a base. The latter are of soft consistency and are easily spoiled.

The following tablets are used by the author:

*T Tablets*<sup>1</sup>

Procaine-Metz	0.02	gram
L-Suprarenin synthetic	0.00002	"

These tablets are used in all normal cases, for purely dental as well as oral surgical operations; infiltration as well as conduction anesthesia. Dissolve one tablet to each cc. of Ringer solution, which gives a 2 per cent solution of procaine with 0.00002 gram of suprarenin to each cc.

*H Tablets*<sup>1</sup>

Procaine-Metz	0.06	gram
L-Suprarenin synthetic	0.00006	"

The H tablets contain the same proportions of the drugs, but three times the quantity in a single T tablet. Dissolve 1 tablet in 3 cc. of Ringer solution, which gives the same proportions as in the above.

*E Tablets*<sup>1</sup>

Procaine-Metz	0.02	gram
L-Suprarenin synthetic	0.00005	"

These are used to produce local anemia, which is sometimes desirable to get a bloodless field of operation. One tablet to each cc. of the solvent medium is used, giving a solution which contains 2 per cent novocain and 0.00005 gram suprarenin to each cc.

*Mixing Tablets*<sup>1</sup>

In abnormal cases, where it is desirable to further decrease the amount of suprarenin, as in serious cardiac disorders, arteriosclerosis and anemia, 1 F and 2 T tablets may be dissolved in  $4\frac{1}{2}$  cc. of Ringer solution. F tablets contain 0.05 gram of procaine and no suprarenin. The percentage of the latter is therefore decreased by using this combination, which results in a solution containing 2 per cent of novocain and about 0.00001 gram of suprarenin to 1 cc.

<sup>1</sup> H. A. Metz Laboratories, Inc., 122 Hudson St., New York, N. Y.

One E and one F tablet dissolved in  $3\frac{1}{2}$  cc. Ringer solution may be used if T tablets are not at hand and give approximately the same solution.

### *Procaine Pluglets*

These are used for pressure anesthesia for the removal of the dental pulp as well as for application to the mucous membrane, previous to inserting the needle. They come twenty in one original tube, each containing the following:

Procaine-Metz . . . . .	. 0.01 gram
L-Suprarenin synthetic . . . . .	. 0.0002 "

### **Method of Preparing the Solution**

Take syringe and dissolving cup from jar and remove all traces of alcohol by washing the cup with sterile distilled water and drawing it into the syringe a few times. Rid the cup of water and expel water from the syringe as well as possible. Measure the amount of Ringer solution into the graduated cup and add a little more to make up for evaporation. Place cup into the holder over the alcohol flame, and when it comes to boiling point add the tablets as required to get the proper solution. Do not touch the tablets with your hand nor with instruments, but hold the tube over the cup and allow them to roll into the solution by turning the tube gently and guiding them with the rubber stopper. The latter should be replaced as soon as the tablets are removed. Heat carefully until the tablets are dissolved, letting the solution boil up once or twice for the purpose of additional sterilization. Do not boil the solution for more than a few seconds after the tablets have been added, or else the drugs will decompose. Sterilize the needle in the flame and insert it into the cup; draw the piston way back and if the point of the needle is continuously submerged, the syringe will fill itself completely without drawing in air bubbles.

<sup>1</sup> H. A. Metz Laboratories, Inc., 122 Hudson St., New York, N. Y.

The syringe is now ready for use. Place it so that the asepsis of the needle will not be spoiled and cover the solution remaining in the cup with a glass cover. After injecting, expel what is left in the syringe, sterilize needle in flame, wash cup with sterile distilled water, and draw same into syringe to remove all traces of salt, which, if left in the syringe, will spoil the accurate fit of the piston in the barrel. Draw a small amount of alcohol into the syringe and place it back in the jar. The alcohol in the jar should cover the syringes entirely.

### Requirements of a Solution Prepared from Tablets

1. It should be used immediately after it has been prepared. The fresher a procaine-suprarenin solution, the less is its toxicity and the greater its anesthesia-producing power.
2. The tablets should not be touched with hands but with instruments, and immediately after use the tube should be closed with the rubber stopper. The tablets are chemically changed by air, light, and especially by moisture. The tablets should be white. Sometimes the uppermost one in the tube is discolored, caused by improper handling of the tube. Discard discolored tablets.
3. The solution should not come in contact with anything except the porcelain cup and the syringe. It should not be left longer than absolutely necessary in either, as it is very sensitive, being affected and chemically changed by air, heat, light, and especially by alkalies. In ten minutes a procaine-suprarenin solution will show discoloration. Its power then is diminished and its toxicity increased. Yellow discoloration is due to oxidation of the novocain and red discoloration to the suprarenin.



## PART V

### PREPARATION OF THE PATIENT

**T**HE attitude of the operator towards the patient is of utmost importance, as has already been pointed out in the opening chapter of the book; and the same applies to any other person with whom the patient comes in contact, either before or during the operation. Even the arrangement of the operating room or the outlook from the window may be a great help in distracting the patients' thoughts, occupying their minds with something else during a period when they are most apprehensive. The same result may be gained by engaging the patient in conversation which is of special interest to him. If new patients are treated, one should inquire without disturbing their confidence whether they have had local anesthetics before, and as a rule they will at once voluntarily mention any disagreeable experiences which they have had or serious disorders or diseases from which they may be suffering. The operator can then be guided accordingly. Change the percentage of the suprarenin if it seems indicated, and most of all assure the patient of the safety and success of the operation.

Emotional factors are of importance and the natural fear which almost every individual has should be counteracted by the kind and sympathetic, but firm and assuring, attitude of the operator. Calm and decided action and confidence on the part of the operator make decidedly for success.

No special preparation is required as far as dietary measures are concerned. The patient should be as little

disturbed in his living habits as possible. A good night's rest and a cup of coffee with a light breakfast are especially recommended, if the operation to be performed is of a more serious character.

### Preanesthetic Medication

X  
Apprehensive, excitable, nervous and timid patients, as well as children, can sometimes be better taken care of by the use of preanesthetic medication. Bromural-Knoll (a-monobrom-isovaleryl-urea), which is bought in the original tubes containing ten tablets of 5 grams each, is an excellent nerve sedative and a safe hypnotic. It exerts a selective action on the cerebrum and is devoid of secondary and injurious effects, even if given in overdose. It has no cumulative action, no habit-forming quality, produces no gastric irritation and has no harmful effect when given to patients with heart disease. It removes such sensations as restlessness, anxiety, giddiness, and palpitation. Bromural also decreases the activity of the secretory organs, inhibiting bronchial mucous secretions and lessening excessive perspiration. The writer has had excellent results from the use of this drug in excitable and unmanageable children, as well as neurotic adults. The dose is  $1\frac{1}{2}$  grains for infants, 5 grains for children under ten years, 5 to 10 grains for children over ten years, according to the seriousness of the operation, and for adults 10 to 15 grains. The tablets must not be masticated but allowed to disintegrate in water. Administer twenty minutes before making the injection.

)  
Veronal, a more powerful hypnotic, is useful when given the night before the operation, to assure a good night's rest. The dose is 5 to 10 grains. It may cause depression of respiration and circulation.

)  
**Morphia.** If the operation is of a very serious nature, in which case extraoral injections are generally used, morphia may be resorted to. This must be given at least thirty

minutes before the injection is made, or else it should be omitted entirely, because in the beginning its action is often of an exciting rather than a quieting nature. The dose is  $\frac{1}{6}$  to  $\frac{1}{4}$  gr. subcutaneously administered. In alcoholics and very strong muscular men give morphia  $\frac{1}{4}$  and scopolamin  $\frac{1}{150}$ .

### Local Preparation

The patient should be made comfortable in the chair. A partly reclining position is the best suited. Tight clothing should be loosened to allow free and easy circulation. All instruments should be prepared and covered with a sterile towel before admitting the patient. The patient should not be disturbed by the sight of instruments or unnecessary sounds.

**Preparing the Mucous Membrane.** Spray the mouth with a mild antiseptic solution of pleasant taste, after which the lip or cheek, as the case may be, should be retracted from the gum and tincture of iodine or a mixture of tincture of aconite and iodine, equal parts, applied to the place where the needle is to be inserted. Tincture of iodine is used for its well-known antiseptic properties, and the tincture of aconite is added on account of its analgesic properties. In very sensitive patients, the region may be superficially anesthetized by the use of campho-phenique, application of procaine crystals or pluglets, or by a submucous injection of a few drops of procaine solution made with a small hypodermic syringe, and a very sharp, fine (28-gauge) iridio-platinum needle.

**Preparing the Skin.** Extraoral injections must be made under strictly aseptic conditions, and must not be undertaken by those who are not familiar with aseptic surgical procedure. The skin should be prepared by painting with tincture of iodine, covering a large area. It is important that the skin be dry to secure the best action of the iodine. Washing and shaving should be done the day before and in

emergency cases it is better to shave dry and refrain from washing. Dehydrants, such as ether or alcohol, are not necessary and only tend to decrease the efficiency of the iodine. After the operation the iodine may be washed off with ether or alcohol. The ethyl chlorid spray may be applied after the skin has been thoroughly prepared to decrease the pain from inserting the needle. However, this is as a rule not necessary with preanesthetic medication.

## PART VI

### SPECIAL TECHNIQUE OF LOCAL ANESTHESIA

**F**ROM the various methods of local anesthesia, the following only may be used for operations in and about the oral cavity:

- Absorption or surface anesthesia,
- Infiltration, terminal or peripheral anesthesia,
- Conduction anesthesia or nerve blocking.

The method should be chosen with consideration for anatomical possibilities, pathological changes, the size of the field of operation, and the time required. To the solution used for conduction anesthesia, it is advisable to add a certain percentage of suprarenin in order to secure a bloodless field of operation. In general, it is advisable to select a method which covers the operative field, with as few injections as possible. Injection into a pathological field should be avoided, especially if suppuration be present, as infection might be carried into healthy tissue. It is a principle in modern methods to separate the induction of local anesthesia from the operation proper. The interval which is necessary for the anesthesia to deepen can be utilized in making necessary preparations for the operation.

#### ABSORPTION ANESTHESIA

This method is accomplished by the application of local analgesics, or anesthetics, to the surface. Its efficiency depends entirely upon the absorptive qualities of the tissues to be desensitized. As the areas affected are generally superficial, the usefulness of surface anesthesia is limited,

and a greater concentration of the solution is necessary with the method. When absorption anesthesia is indicated it is necessary to guard against dilution of the anesthetic by the action of the saliva. The mucous membrane should first be thoroughly dried. This method gives better results when it is possible to use pressure, as shown by the ease with which an exposed dental pulp can be completely anesthetized.

*Applications to the Oral Mucous Membrane.* Sufficient anesthesia can be secured for the painless fitting of bands, the finishing of fillings at the cervical margin, the application of a rubber dam clamp high up on the root of a tooth, the lancing of a subgingival abscess, and the insertion of the needle for hypodermic injections.

*Preparing the Site of Application.* The utmost care should be taken to exclude saliva by isolating the part to which the application is to be made. For this purpose cotton rolls and napkins may be used and the part swabbed with a pellet of cotton.

*Drugs.* Various drugs having more or less anesthetic action may be used, allowing 3 to 5 minutes to take effect.

*Tincture of aconite.* This is generally used with equal parts of tincture of iodine, and applied to the mucous membrane before inserting the needle. Aconite has a marked local anesthetic action.

*Procaine Solution 10-20%.* This can be applied on small cotton pellets to the previously dried surface of the mucous membrane.

*Procaine Crystals or Powder.* Procaine crystals or pluglets may be applied to a small area of the mucous membrane and allowed to dissolve in the moisture of the tissues. While waiting for them to take effect proper care is necessary to prevent the procaine from being washed away by the fluids of the mouth.

*Method of Application.* An applicator made by winding cotton around the end of a toothpick may be used. Some-

times, however, it is more practical to saturate a pellet of cotton and apply it to the mucous membrane for a few minutes. The absorptive qualities of the mucous membrane can be increased by drying with compressed air.

**Nasal Application.** This method of anesthetizing the upper incisor is often of value, especially in the treatment of children, who object to the pain caused by the insertion of the needle. The method is in general use for nasal operations.

*Drugs.* A five or ten per cent solution of cocain is often used; but a 20 per cent solution of procaine, made by dissolving 4 F tablets to each cc. of Ringer solution is safer and just as effective.

*Method of Application.* A piece of cotton saturated with the anesthetic solution is placed into the inferior meatus of the nose, directly behind the nares. In a short time the solution will penetrate the mucous membrane and infiltrate the bone directly above the apices of the incisor teeth. The nerves leading to them are consequently anesthetized, making it possible to operate on these teeth without causing pain.

**Application to Exposed Pulp.** In 1890 Edward C. Briggs of Boston described a new method of devitalizing a tooth with cocain, which has proven so satisfactory that it is still in use. It is generally known as "pressure anesthesia" and if used properly it anesthetizes the dental pulp in a very short time. The patient, however, experiences a considerable amount of pain during the application, on account of which anesthesia produced by injecting is usually more satisfactory. If, however, complete anesthesia of the pulp cannot be gained by the infiltration or conduction method, pressure anesthesia may be used in addition with splendid results, and with but little discomfort, on account of the partial numbness already existing.

*Drugs used.* Originally cocain pellets were used. They are small compressed cylinders, containing  $1/12$  grain of pure cocain hydrochlorid in soluble form. Similar pellets are now used containing 0.01 gram of procaine with 0.0002 gram suprarenin and are just as efficacious. Ordinary hypodermic tablets such as recommended for use in solution cannot be used for this purpose because they do not dissolve readily, being purposely made to dissolve only when heated.

*Method of Application.* The following method has been found satisfactory by the writer and with the exception of slight changes in technique is the one in general use. Apply the rubber dam, adjusting it carefully so that there is no leakage around the tooth. It is necessary to have a cavity with four walls so as to confine the solution under pressure. Where four walls are not standing they can be built temporarily, with cement. Before applying the anesthetic the adjoining teeth and especially the cavity should be thoroughly sterilized by some germicidal agent, such as a solution of 1:500 of bichloride of mercury. (This solution attacks instruments and pliers, which therefore should be coated with wax or immediately dried.) Dry the cavity as well as possible, and apply one half pellet of procaine. It is of great advantage to have a concentrated solution; therefore the pellet should be permitted to dissolve in the exudation of the exposed pulp. Sometimes, however, it is necessary to use a small amount of sterile water; but one should apply only enough to reduce the pellet to a paste. A piece of unvulcanized rubber, slightly warm, is placed into the cavity. It should be just large enough to fill three-quarters of the cavity. A flat-ended instrument the size of the cavity is used to press the rubber in the direction of the pulp canal; this will prevent the solution escaping at the sides. Pressure should be applied slowly, with an evenly increasing force, so as to minimize the



pain. When all pain has disappeared remove the rubber, and with a sterile bur open the pulp chamber and remove the pulp.

### INFILTRATION ANESTHESIA

In this method the anesthetic solution is injected beneath the mucous membrane or the skin, as the case may be. Anesthesia is induced by the action of the anesthetic on the terminal nerve fibers. The method, therefore, is also called terminal or peripheral anesthesia. Its action is limited to a small area, and a considerable amount must be injected when a large field is to be anesthetized. In certain parts of the jaws, the solution will penetrate the bone, traveling through the Haversian canals. In localities where these canals are numerous and where the apices of the teeth are near the surface, we are able to make use of infiltration to anesthetize the teeth, the solution affecting the dental nerves before they enter the apical foramen.

The infiltration method gives quick results; but it cannot be employed for deep action, especially with regard to its effect on the teeth. The injection is more painful than for the conductive method, particularly if the mucous membrane is in an inflamed condition; furthermore it must be repeated a number of times to cover a large field. If suppuration is present, the method is entirely contraindicated on account of the danger of spreading infection.

**Anatomical Considerations.** The face is covered by the common integument, which is similar in structure to the skin covering other parts of the body. It consists of the epidermis and the corium. The latter is a layer of densely interwoven bundles of connective tissue, forming papillae immediately under the epidermis. These, however, in the face are not well developed. In each papilla there is a terminal knot of capillary blood vessels and nerve endings. Through the corium extend the hair shafts and ducts which are the out-

lets of the sweat glands found in the stratum subcutaneum. Here also we find fat glands and numerous vessels.

At the transitional part of the lips the mucous membrane of the mouth begins. The oral cavity is lined by stratified, squamous epithelium, papillae of which extend into the tunica propria. Underneath this is the submucosa which connects the mucous membrane with the underlying

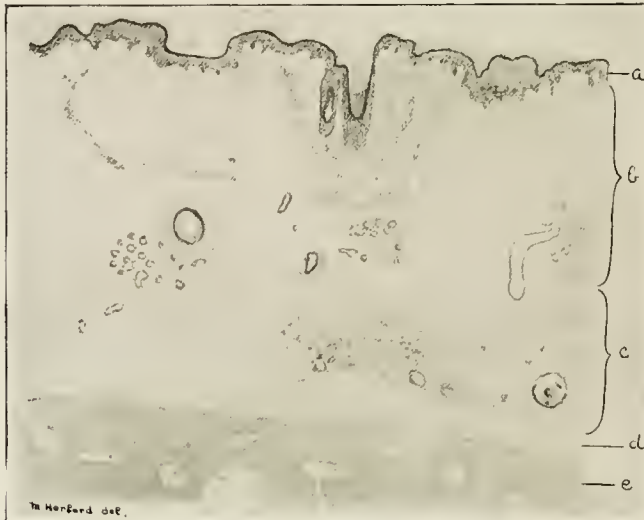


FIGURE 37

Microscopic drawing of a section through skin overlying bone. a. Epidermis; b. corium; c. subcutaneous tissue; d. periosteum; e. bone. Endermic injection is made into b directly beneath epidermis. Subcutaneous injection is made into c. Subperiosteal injection between d and e.

structures. In certain locations, it contains numerous mucous glands varying in size, the ducts of which wind through the tunica propria until they find an outlet at the surface of the epithelium. The gums have a very dense submucosa, consisting of thick connective tissue bundles, containing numerous elastic fibers which extend into the periosteum, binding the mucous membrane closely down

to the bone. At the reflection of the mucous membrane, where it turns over cheek, lips, or the floor of the mouth, the submucosa becomes loose and is represented by a thick layer of connective tissue. A similar condition is found on the palatal side, where the angle formed by the alveolar and palatal processes is padded with a large amount of connective tissue. This connective tissue contains a great deal of fat and most of the mucous glands of the hard palate. Towards the center of the roof of the mouth the mucous membrane is very thin, extremely fibrous, and closely attached to the bone. The blood supply of the mucous membrane is very free. Larger branches are found in the submucosa giving off capillaries, which extend into the papillae of the tunica propria. Here they ramify widely and anastomose.

The nerve endings seem to be more numerous in the anterior part of the mouth, where the mucous membrane is much more sensitive than in the back. Primitive nerve fibers extend from the submucosa into the papillae of the tunica propria, where they terminate.

**Technique of Injection. General Remarks.** When the syringe has been filled it should be held in readiness either by the nurse or assistant, or placed within reach of the operator, but in such a manner as to prevent it from coming into contact with anything but sterile conditions. This especially applies to the needle. Some operators place a piece of sterile cotton or gauze saturated with absolute or 70 per cent alcohol over the needle. If the needle is to be adjusted after sterilization, use sterile instruments for the purpose. The needle should not be touched with the fingers under any circumstances. In case of doubt, it should be resterilized. At this time make sure that no air is in the syringe, because air injected into the tissue causes pain. Retract the lip or cheek and prepare the mucous membrane as previously described. When inserting the needle, carry it down at once into the submucous tissue, but not into the

bone, or the point of the needle will be bent. It should be borne in mind that a sharp needle causes less pain than a blunt one and a blunt point tears the delicate tissue fibers. When injecting into the mucous membrane, the dense part near the alveolar margin should be avoided. The old method of anesthetizing the gum required enormous force and, therefore, caused a great deal of pain. The loose part of the submucosa should be reached as soon as possible, for here the solution is taken up easily and with little pressure. Continuous and slow advancement of the needle will obviate the danger of injecting into an artery or vein. The force of the solution flowing from the point of the needle has a tendency to push aside small vessels.

#### **Infiltration of the Skin and Mucous Membrane**

The nerve supply of the skin and mucous membranes is extremely complicated. Nerve branches originating from various sources anastomose and form an intricate meshwork. It is therefore necessary, if operations include the soft parts of the face, to supplement conduction anesthesia with regional infiltration. This also affords an opportunity to produce local anemia for a bloodless field of operation if desired.

Infiltration of both the skin and mucous membrane may be accomplished either by endermic or subcutaneous injections. In the endermic method, the end organs of the nerves are anesthetized directly in the skin. The solution should be injected as near the surface as possible, that is, directly under the epidermis or the epithelium, to bring it in direct contact with the nerve ending in the papillae of the corium or tunica propria. In subcutaneous injections, the solution is injected into the subcutaneous tissue or the submucosa. Here the solution affects the nerve filaments, and as it has to penetrate the nerve sheaths, it requires more time for the anesthesia to take effect and a greater amount of solution is required.

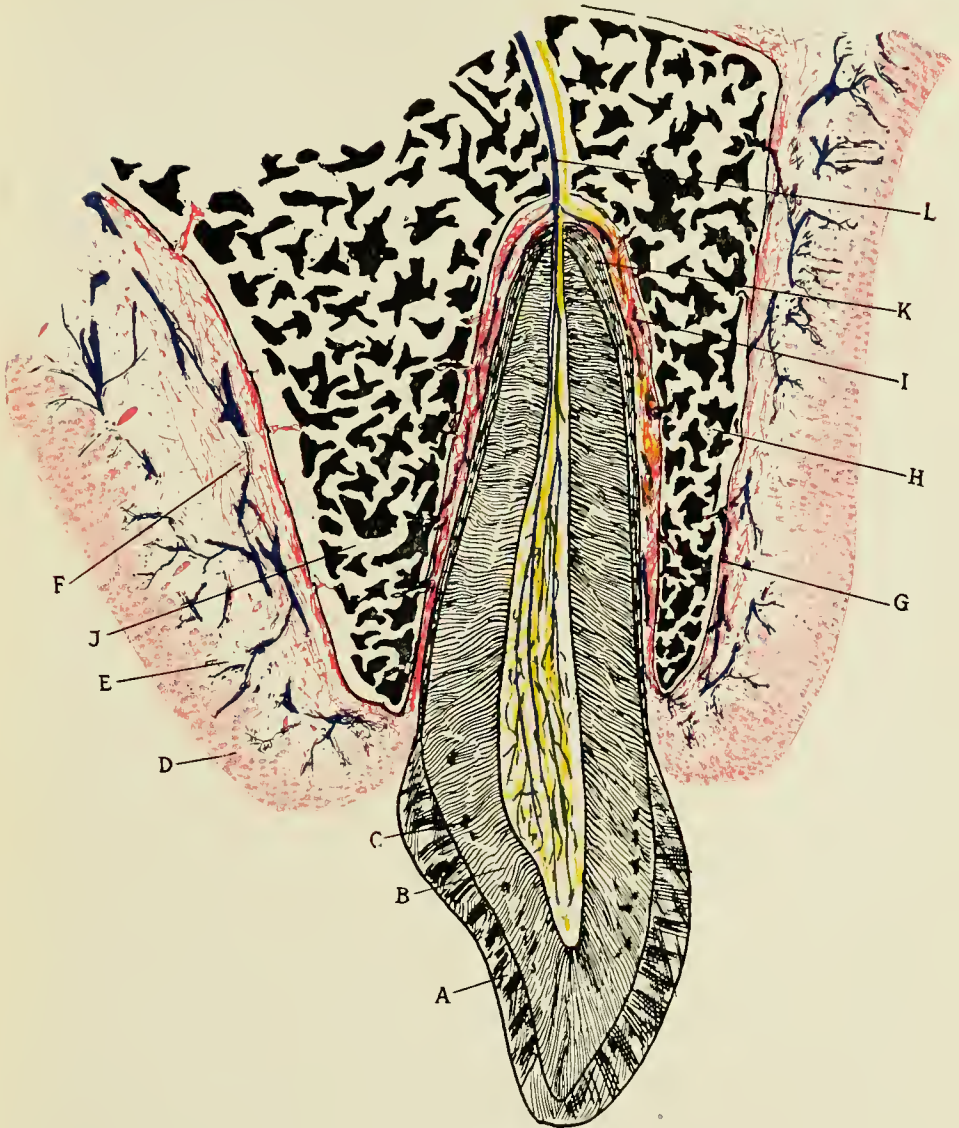


FIGURE 38

Section through the upper jaw in the incisor region. A. Enamel; B. Dentin; C. Interglobular spaces; D. Epithelium; E. Tunica propra; F. Submucosa; G. Periosteum; H. Outer Plate of alveolar process; I. Inner Plate of alveolar process; K. Cement; L. Dental nerves and vessels.

**Instruments.** Use a syringe with a short fine needle for endermic injections. For subcutaneous injections, use a long needle. The larger the needle, the better it allows progress in advancement, and a larger field can be covered with one puncture. (Use long needle shown in Figure 26.)

**Technique of Injection. Endermic Method.** The skin is picked up with thumb and forefinger, and while applying considerable pressure to render it less sensitive, the needle is inserted. Inject at once. The blood is pressed out of the capillaries, causing blanching of the skin or membrane. Inject slowly with even pressure, so as not to cause any pain by rapidly expanding the tissue. The needle should remain close to the surface. It is inserted again at the distal periphery of the blanched area and this is repeated until the entire area is anesthetized. The more solution is injected at each puncture, the wider becomes the anesthetized area. Anesthesia takes effect almost immediately, but as the blanched appearance disappears rapidly, it is best to first mark the place to be incised.

**Subcutaneous Method.** The skin is picked up as previously described, but the needle passes at once into the subcutaneous or submucous tissue. This tissue is generally very loose; therefore little pressure is required, and the solution is taken up freely. The needle is slowly advanced while injecting until it is inserted to its full extent. It can then be partly withdrawn and advanced in another direction or else withdrawn entirely and reinserted at a different place. A larger area, however, can be covered by one puncture if the needle is long enough. Anesthesia occurs in about five minutes.

#### **Infiltration Method for Anesthetizing Individual Teeth**

For any purely dental operation, such as is necessary for restoration or the removal of the pulp, anesthesia of the dentinal nerve fibers supplying the tooth and peridental membrane can be accomplished in certain parts of the

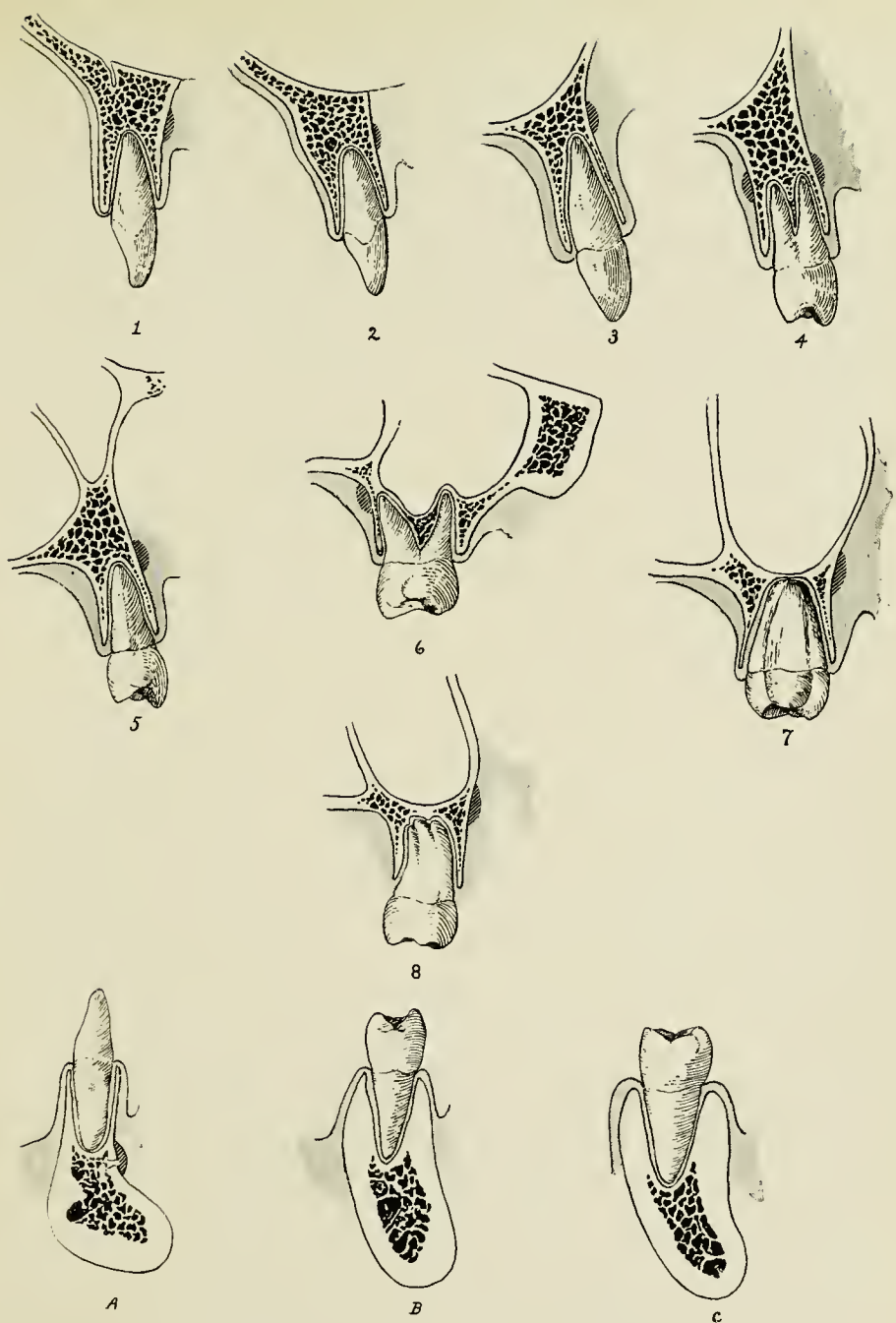


FIGURE 39

M. Herford, dec.

Sections through teeth in situ, to show the relation of the tooth root to the surface of the bone. 1. Central incisor; 2. lateral incisor; 3. cuspid; 4. first bicuspid; 5. second bicuspid; 6. first molar; 7. second molar; 8. third molar of upper jaw. A. incisor; B. bicuspid; C. molar of lower jaw.

Shaded area shows where injection should be made. The sections which show no area cannot be anesthetized by this method.

mouth by the infiltration method. The solution is injected as close to the bone as possible, from where it penetrates through the Haversian canals. It is not necessary to make a special effort to insert the needle beneath the periosteum. In the writer's opinion, subperiosteal injections are liable to cause swelling and pain, because they tend to detach the periosteum from the bone. In children and adults with thin bone, infiltration is usually more successful than in old persons and patients with heavy bone, because in the former there is as a rule an abundance of pores, through which the solution can pass. In the upper jaw, the incisors and bicuspid are the most easily anesthetized. Next come the cuspids and third molars, while difficulties are sometimes encountered with the first and second molars, on account of the zygomatic process, which in a number of cases is very near the alveolar margin, increasing the thickness of the bone at the buccal side.

The lower jaw affords opportunity for infiltration only in the anterior part and is usually unsatisfactory for the cuspids, bicuspid, and molars.

**Technique of Injection.** As a general rule, use the following injections, if only the tooth is to be anesthetized:

Labial or buccal injection alone on single-rooted teeth.

Buccal and lingual injection both on multi-rooted teeth.

If both the tooth and surrounding tissue are to be anesthetized, as for extraction or other surgical procedure, use:

Labial or buccal and lingual injections on all teeth.

**Instruments.** The syringe with the short iridio-platinum needle (26 mm.) and mounted with the short hub is generally used for infiltration anesthesia. If the operator has become proficient in handling the syringe, and especially if he uses conduction anesthesia in most cases, the long needle mounted with the long hub can be used for both methods. This simplifies the equipment. The long needle, however, bends easily and special care is required so as not to spoil it.



**Technique.** The needle is inserted into the sterilized place with the opening of the needle facing the bone. In the beginning, it is advisable to hold the syringe like a writing pen. This method gives the operator a chance




FIGURE 40 Wrong position of needle. FIGURE 41 Right position of needle.

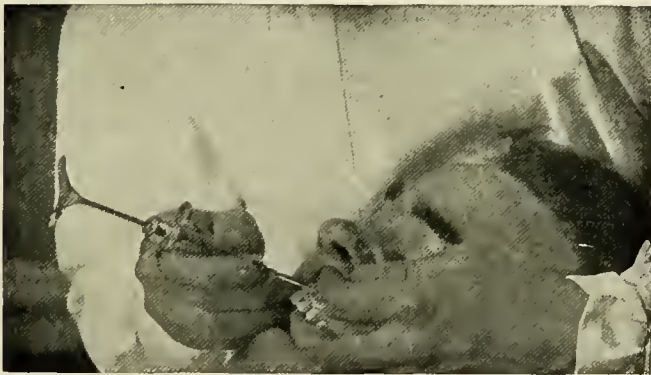

FIGURE 42 Position of operator when injecting for an upper tooth by the infiltration method.

to steady his hand against the patient's jaw. Later, however, it may be taken hold of in a manner which allows the injection of a few drops, immediately after the puncture is made. If this method is adopted, it is often possible to make

use of the left hand, which is used for retracting the lip or cheek, as a support for the syringe hand. The needle then is carefully and slowly advanced, injecting continuously a small amount until a place opposite or a little higher than the apex of the tooth is reached. Here the remainder of the solution is deposited. The injection should be made evenly. At no time should it require an unusual amount of force. No velum should be produced, as in the old way of injecting into the gum. The formation of a velum is a sign that the needle has not been inserted in the deepest part of the tissue. Sometimes a great deal of resistance is experienced, which may be followed by sudden release. This causes the operator to inject a large amount all at once, and produces injury which is usually followed by after pain and soreness. When the injection is made carefully, slowly, and with an even flow of the solution, less pain is experienced by the patient. After removing the syringe, which should be done swiftly, it is necessary to wait for the solution to infiltrate the bone. It takes from five to eight minutes for the tooth to become anesthetized. When the solution is seen to come out through the opening made by the needle, a strong astringent such as tannic acid in glycerin should be applied at once on sterile cotton or gauze. Pressure applied to the part sometimes also prevents the flowing out of the solution. Some operators advise the massaging of the part injected so as to force the solution into the bone, but according to the writer's experience this is only necessary in isolated cases.

**Injection on the Labial or Buccal Side in the Upper Jaw.** The place where the needle should be inserted on the labial or the buccal surface of the jaw is directly over the eminence of the root, halfway between the gum margin and the apex. In the molar region, it is often necessary to deviate from this rule, pushing the needle obliquely to the intended place, where the main part of the solution is deposited.

**Injection on the Lingual Side of the Upper Jaw.** The lingual gum of the maxilla is supplied by the anterior palatine and naso-palatine nerves; therefore for surgical operations an additional injection to produce anesthesia of the soft parts is required. For the molars, and often for the first bicuspid, the lingual injection is needed for complete anesthesia of the tooth, as it anesthetizes the palatal root.

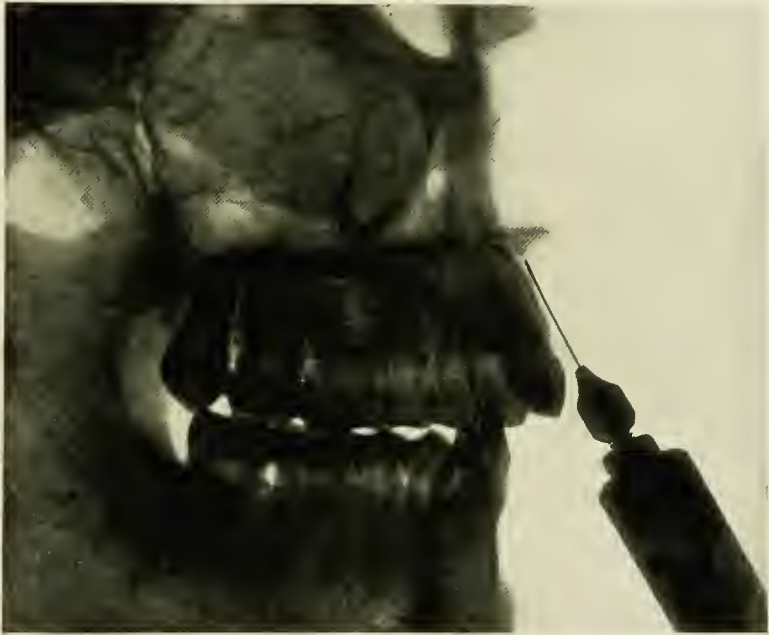

FIGURE 43

Roentgen picture, showing the position of needle to anesthetize an upper incisor by the infiltration method.

On the lingual side we start at the gingival margin, push the needle at once down parallel with the process into the submucous tissue, which takes up the solution easily, requiring little force.

**Injection on the Labial Side of the Mandible.** Here the procedure is similar to that used for the maxilla. Often, however, it is easier to insert the needle over the tooth next

to the one that is to be anesthetized, pushing it obliquely toward the apex of the tooth in question.

**Injection at the Lingual Side of the Mandible.** The mouth should be open as wide as possible. The procedure is the same as described for the maxilla. The lingual gum is supplied by the lingual nerve. This injection is only necessary in case of extraction of the lower incisors.

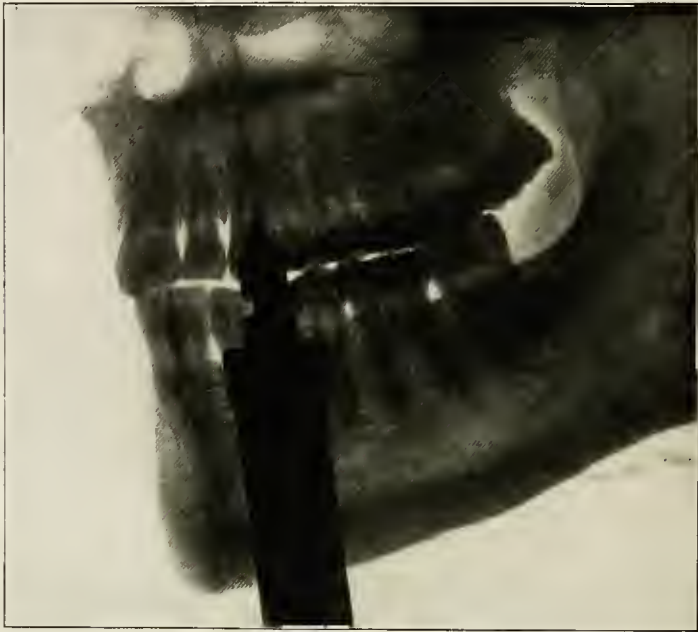

FIGURE 44

Roentgen picture, showing position of needle to anesthetize an upper cuspid.

**For Upper Central Incisors.** The apex of this tooth lies close to the outer surface and its root is about the same length as the crown or a little longer. When the needle is inserted on the labial side to the full extent, it often meets with resistance, due to a prominence, the nasal spine. (See Figure 43.) Do not, therefore, force the needle further,

or it will bend. For extraction, an additional injection on the palatal side is necessary.

**For Upper Lateral Incisors.** The root of the lateral is usually longer than the central root and often is bent distally. It is placed in the center of the bone and its apex is therefore generally further from the surface than the apex of the

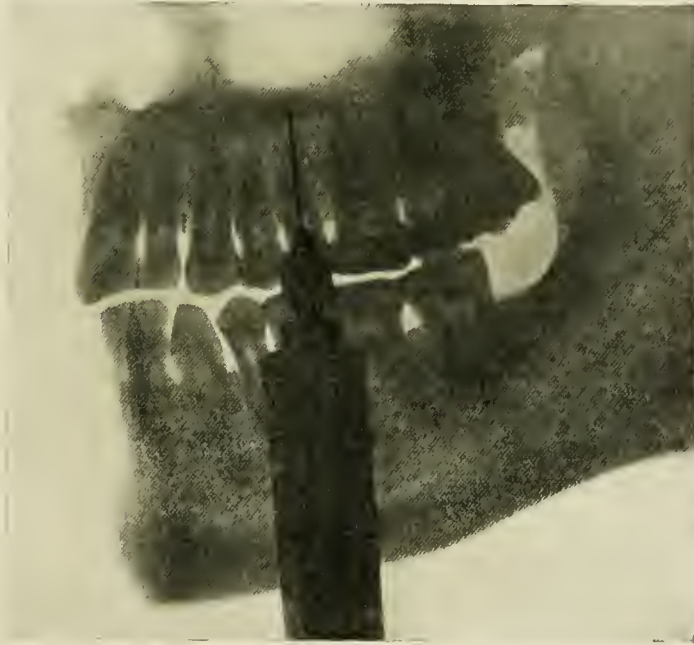


FIGURE 45

Roentgen picture, showing position of needle to anesthetize an upper bicuspid.

central. The injections are made in the same manner as for the previously described tooth.

**For Upper Cuspids.** This tooth has a very long root; in extreme cases, almost twice as long as the crown. The needle therefore should be inserted higher up, unless a 42 mm. needle is used, which is long enough to reach the proper region. Generally, the root is covered only by a thin layer

of bone, and it can be easily anesthetized, if the injection is made by following the canine eminence to a point a little higher than the apex of the tooth. An injection should be made also on the lingual side if surgical work is intended.

**For Upper First Bicuspids.** This tooth nearly always has two roots, which are about one and one half times as long as the crown. Both their apices are near the surface. Injections should be made on the buccal and lingual sides in order to reach both the dental nerves, one entering the buccal and one entering the palatal root. It is best to use this procedure every time, disregarding the possibility of an occasional single root.

**For Upper Second Bicuspids.** For this tooth, one injection on the buccal side is nearly always sufficient for purely dental operations. The lingual gum has to be taken care of with an additional injection, if the soft tissues are to be included in the operation.

**For Upper First Molars.** The nerves leading to the pulp of this tooth in most cases cannot be reached by the infiltration method. In children, conditions are more favorable. Sometimes, however, we find anatomical conditions which make infiltration possible, such as when the zygomatic process emerges higher than usual or when the alveolar process is especially long. It is necessary to insert the needle obliquely, backward and upward, because the opening of the mouth does not allow a vertical direction. A place between and a little higher than the apices of the buccal roots should be reached, and a separate injection is necessary on the lingual side for the nerve entering the palatal root.

**For Upper Second Molars.** The conditions of the bone around this tooth are mostly unfavorable, depending more or less on the formation of the zygomatic process of the maxilla. All that has been said about infiltration anesthesia for the upper first molar may be applied to this tooth.

**For Upper Third Molars.** The third molar is easy to anesthetize, the bone being very porous. As its roots are generally not divergent and mostly fused, a buccal injection

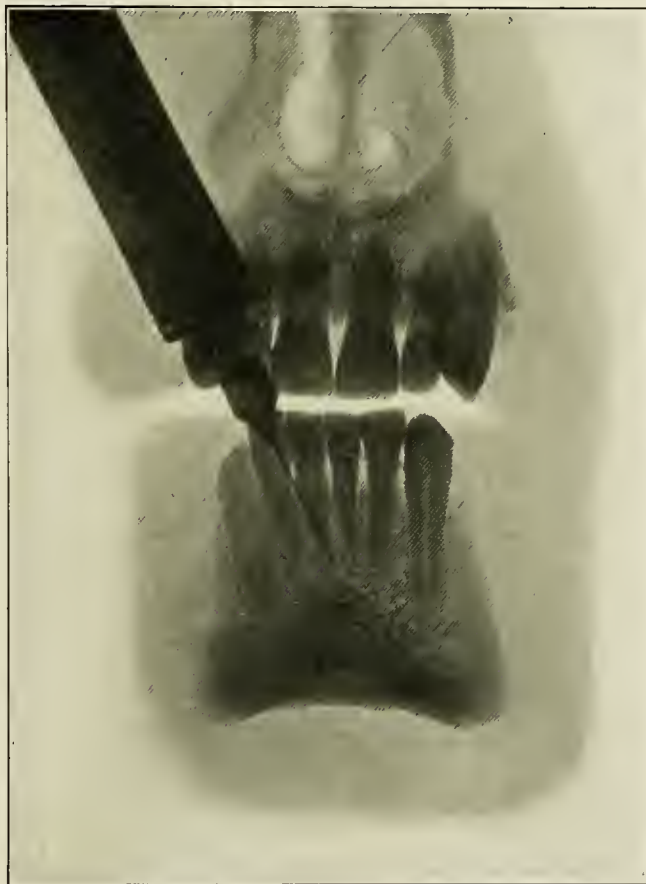

FIGURE 46

Roentgen picture, showing position of needle to anesthetize a lower incisor.

is usually sufficient. The patient should be directed to open the mouth but slightly and completely relax the muscle of the cheek. This makes it possible to sufficiently retract the corner of the mouth, and gives access for insertion of the




FIGURE 47

Roentgen picture, showing position of the needle for a horizontal injection.

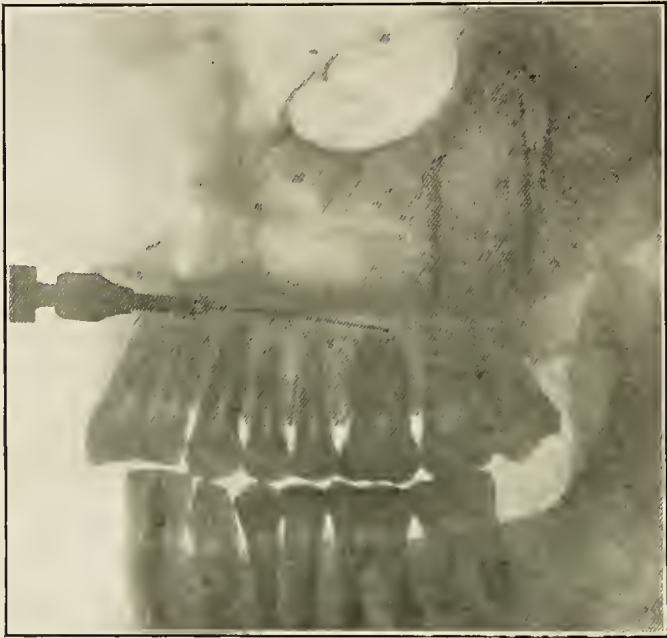


FIGURE 48

Roentgen picture, showing position of needle for a horizontal injection, the cuspid, both bicuspids, and first molar having been anesthetized.



needle. A long needle is desirable and should be directed over the middle of the root of the second molar. It is then pushed inward and slightly upward, until the point reaches a slightly higher level than the apex of the wisdom tooth. For surgical operations, use also a palatal injection.

**For the Lower Incisors.** The lower incisors are easily anesthetized by means of the infiltration method, as the bone is very porous, especially on the anterior surface opposite their roots. To make the injection more conveniently, the needle is inserted obliquely, starting over the tooth nearer the operator, but care should be taken that the point of the needle reaches a spot opposite the apex of the tooth to be anesthetized. An injection on the lingual side is necessary for surgical anesthesia, but is not always easily accomplished, especially if the incisors have a lingual inclination. The patient should be instructed to open the mouth as wide as possible. For extracting, it is only necessary to inject into the gum margin. Often it is found of great help to use the long needle, which has been bent before being sterilized.

#### **Infiltration Method for Anesthetizing a Number of Adjoining Teeth**

To avoid repeated puncture of the mucous membrane, when several adjoining teeth are to be anesthetized by the infiltration method, the long needle should be inserted over the apex of the root of the tooth farthest forward or nearest the operator. Having injected for the first tooth, the needle should be forced along the bone in a horizontal direction, until the place opposite the apex of the second tooth has been reached; here again deposit some of the solution and proceed in the same manner for the next tooth. This method can be used for a series of teeth in the incisor region, in the upper as well as in the lower jaw, and for anesthetizing adjoining maxillary bicuspid and molars. The use of

the horizontal injection is only advisable in healthy tissue, on account of the danger of spreading infection. For surgical anesthesia, the lingual side must also be anesthetized. The tables on pages 140 and 141 give the amounts to be injected for each tooth.

### CONDUCTION ANESTHESIA

Conduction anesthesia is the ideal method of producing local anesthesia. Its action is to intercept or block the conductivity of a nerve at a convenient point, in order to

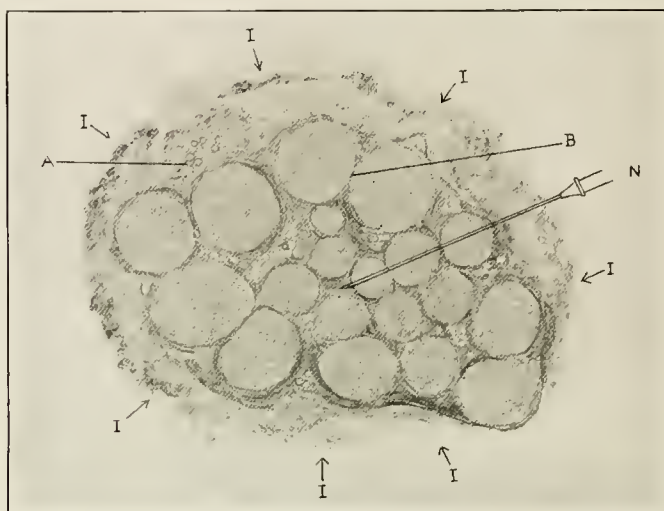


FIGURE 40

Cross section through a nerve trunk. The whole trunk is surrounded by a dense layer of tissue called the epineurium, (A) Each nerve bundle is surrounded by a similar layer called perineurium, (B) The needle (N) illustrates an intraneural injection. The arrows (I) indicate infiltration of the nerve in extraneural injections.

prevent afferent impulses from reaching the brain. The injection is made into loose connective tissue or a bony canal, at some distance from the field of operation, which lessens the possibility of infection and the tendency to post-operative pain.

Infiltration anesthesia may be combined with conduction anesthesia, especially if it is desirable to have a bloodless field of operation. The main advantages over the infiltration method are the following:

1. A comparatively large area can be covered by the injection, anesthetizing equally well the superficial tissue, the deeper parts, soft tissue as well as bone, and in the jaws all the teeth supplied by the injected nerve.

2. The needle is inserted at a place generally quite distant from the field of operation. The injection may be made into the nerve trunk itself (endoneural injection) or in the tissue surrounding the nerve (perineural injection). In the first method, it is necessary to expose the nerve, which is usually done with infiltration anesthesia. It is more frequently practiced in connection with general anesthesia. The perineural injections are almost entirely used in dentistry and oral surgery. The solution is injected into the neighborhood of the nerve into which it diffuses. The time necessary for the solution to affect the nerve is dependent upon the thickness of the nerve trunk and the density of the perineurium. The part supplied by the nerve fibers located in the periphery is anesthetized first, the part supplied by the centrally located fibers last and sometimes not as efficiently.

3. The point of injection is generally remote from parts which are diseased and hypersensitive. This not only decreases the pain made by the puncture but is a safeguard against spreading of the disease into deeper or neighboring tissue. It also minimizes postoperative pain.

4. The anesthesia is as a rule of longer duration and the time can be controlled by the amount injected. If necessary, the injection can be repeated at any stage of the operation.

Accurate knowledge of anatomy and skill in technique is required for the successful use of conduction anesthesia.

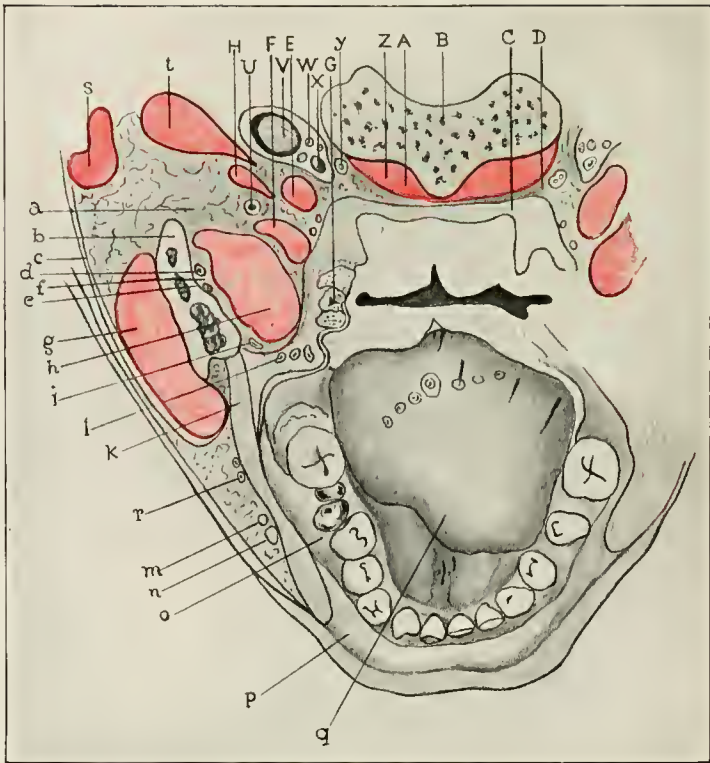


FIGURE 50

Horizontal section through the human head in the plane in which mandibular conduction anesthesia is best accomplished. a. Glandula parotis; b. Ramus mandibulae; c. Fascia parotideomasseterica; d. A. and V. alveolaris inf.; e. Nervus alveolaris inf.; f. Spatium pterygomandibulare; g. M. masseter; h. M. pterygoid int.; i. Nervus lingualis; k. M. buccinator; l. Glandulae palatinae; m. Art. maxillaris externa; n. Glandulae buccalis; o. Gingiva; p. Labium inferius; q. Lingua; r. Glandulae buccalis; s. M. masseter; t. M. Diaphragmaticus; u. Art. carotis externa; v. Vena jugularis interna; w. N. vagus, glossopharyngeus and hypoglossus; x. Art. carotis interna; y. Ganglion cervicale superior; z. M. longus capitis.

A. M. rectus capitis anterior; B. Epistropheus; C. M. constrictor pharyngis superior; D. Fascia praevertebralis; E. M. stylopharyngeus; F. M. styloglossus; G. Tonsilla palatine; H. M. Stylohyoideus.

## INTRAORAL METHODS OF CONDUCTION ANESTHESIA

In the intraoral methods, the nerve to be anesthetized is approached from within the oral cavity. Intraoral injections will probably always be more popular than the extraoral ones, although the latter have distinct advantages which will be discussed later:

### The Pterygomandibular Injection

#### *For the Lingual and Inferior Alveolar Nerve*

With this method the inferior alveolar nerve is reached before it enters the mandibular foramen, resulting in anesthesia of half of the mandible, half of the lower lip, and the

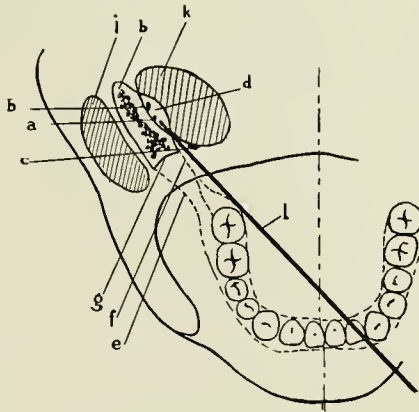


FIGURE 51

Diagram showing injection into the pterygomandibular space.  
 a. N. Alveolaris inf.; b. A. Alveolaris inf.; c. N. Lingualis;  
 d. Spatium pterygomandibulare; e. Linea obl. externa; f. Linea  
 obl. interna; g. Trigonium retromolare; h. Ramus mandibulae;  
 i. M. Masseter; f. M. Pterygoid int.; l. Position of needle.

teeth. The lingual nerve, which not only supplies the tip of the tongue but also the lingual part of the gum, is situated very near the place where the needle is inserted and can also easily be included.

**Anatomical Considerations.** It is important to have a mental picture of the associated anatomical structures.

Frozen sections cut in coronal and frontal plane about one half inch apart furnish an excellent means of instruction. Figure 50 shows a drawing made from a coronal section cut exactly through the plane in which the needle is inserted. Note the internal oblique line of the ramus, from which a fascia extends around the internal pterygoid muscle, at the anterior margin of which lies the lingual nerve. Between the muscle and the inner surface of the ramus is a space, the circumference of which marks the sulcus mandibularis, seen

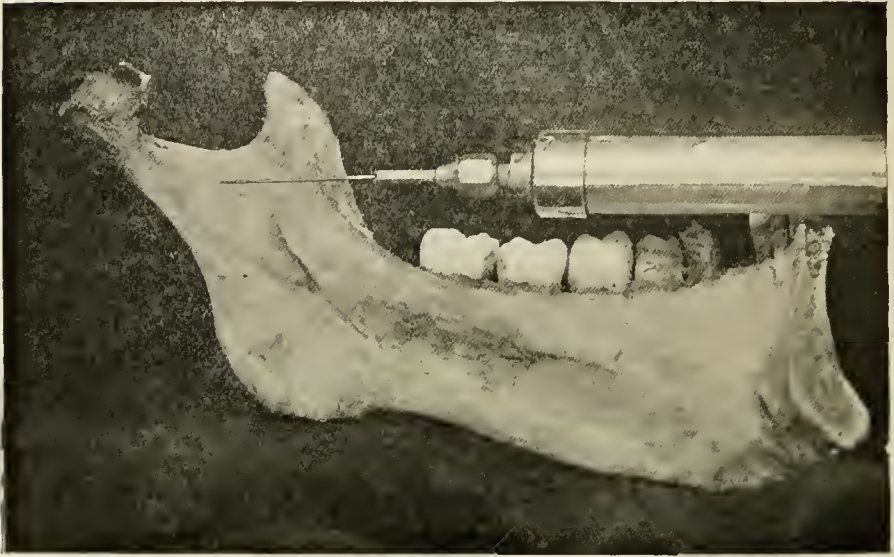


FIGURE 52

The needle should be inserted into the sulcus mandibularis over the lingula.

in Fig. 15. This space is called the pterygomandibular space. It is filled with connective tissue and contains the inferior alveolar nerve and artery. Here they enter the bone. The nerve in this location generally lies anterior to the artery, which is of moderate size. The artery is a branch of the internal maxillary artery and passes down between the speno-mandibular ligament and the mandible.

The inferior alveolar vein forms a plexus around the artery. The lingula more or less projects over and partly surrounds

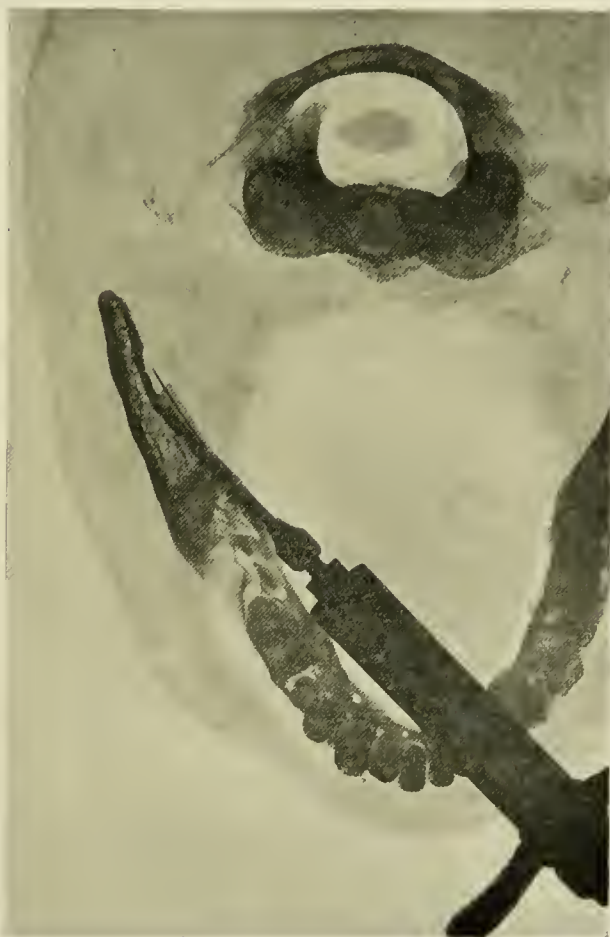


FIGURE 53

Roentgen picture showing needle inserted over the lingula into the pterygomandibular space.

these structures. If the needle is inserted too low, it may be easily guided into the muscle. Therefore care should be taken to inject at a higher level.

**Instruments.** Use syringe No. 1, mounted with the long 45 mm. iridio-platinum needle, and the long straight hub.

**Landmarks.** The post-molar triangle is located by palpating first the external oblique line of the ramus, which is very prominent, then the internal oblique line which varies greatly in prominence and form. The tip of the finger rests easily in the depression between the two. This manipulation should be done gently and later can be omitted entirely.

**Technique.** Various methods have been described for this injection. They differ, however, only in minor points. Seidel employs the thumb of the left hand for palpation on either side. Fischer and Smith recommend the use of the index finger of the left hand while Blum teaches the use of the index finger of the left hand for the left side. For the right side he uses the right index finger for palpation and the left hand to hold the syringe and make the injection. The method described hereafter has been found easiest to learn and most convenient by the writer.

For the right side of the mandible stand on the right side of the chair facing the patient. Find the post-molar triangle with the tip of the thumb of the left hand, applying the other fingers to the outside of the jaw. This position enables the operator to steady the head. The finger nail marks the location of the internal oblique line and the needle is inserted close to the nail; but the operator should prevent any contact which would destroy the asepsis (Fig. 54, 1).

For the left side stand further back facing in the same direction as the patient. The left arm should extend around the patient's head, the regular position for the use of the mouth mirror on that side. Palpate the post molar triangle with the tip of the left index finger, the finger nail facing the median line. The other fingers again take hold of the outside of the jaws as seen in Fig. 54, 4.



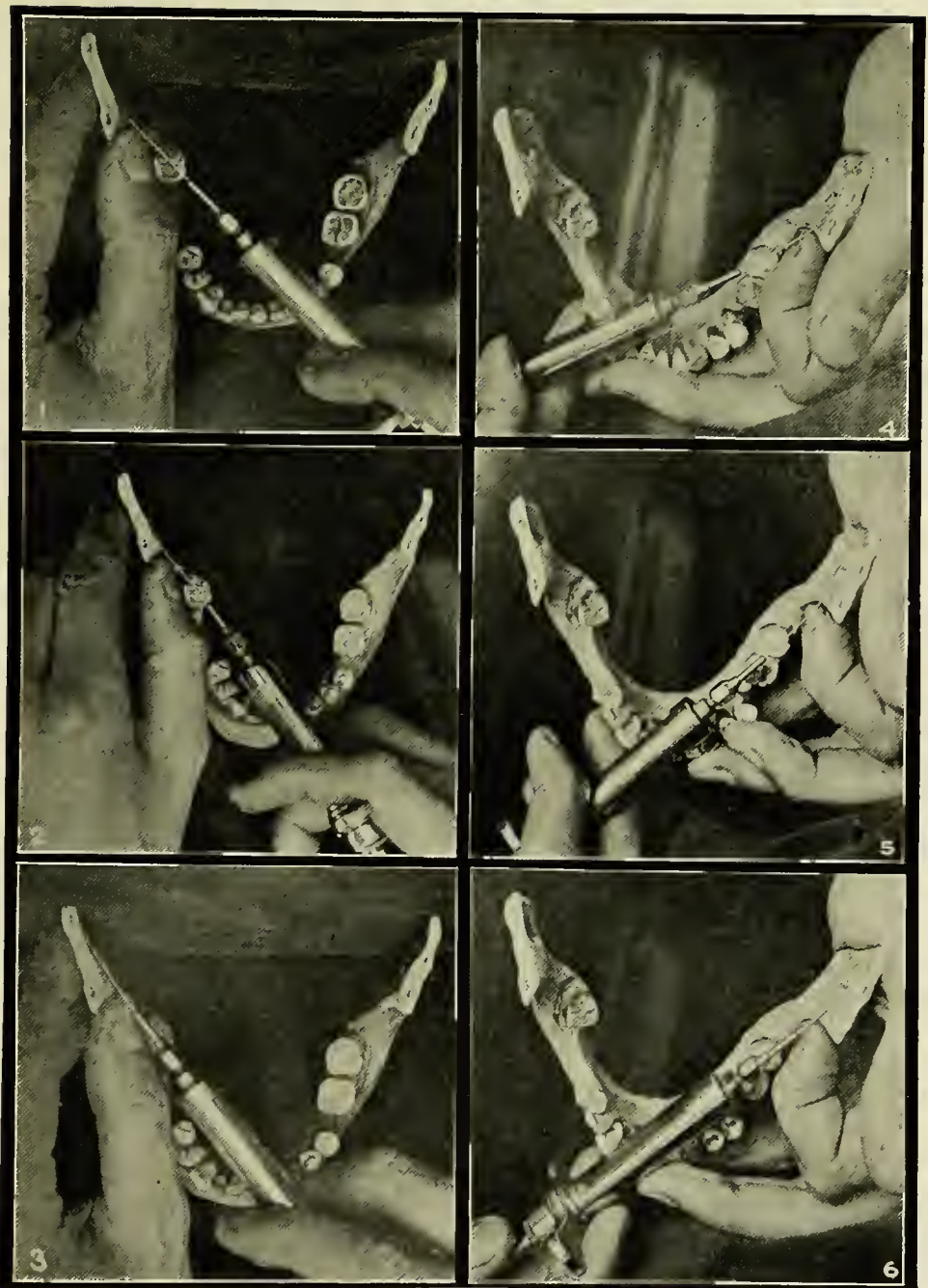


FIGURE 54

Technique of inserting the needle for the pterygomandibular injection. 1, 2, and 3, on the right side; 4, 5, and 6, on the left side. 1 and 4, feeling of the internal oblique line. 2 and 5, adjusting position of the syringe parallel with the ramus. 3 and 6, reaching the pterygomandibular space.

After finding the proper position, prepare the mucous membrane for the puncture in the usual manner. The position of the left hand is not changed until the injection is made.

**Insertion of the Needle.** The place for inserting the needle is on the inner side of the palpating finger, 1 cm.

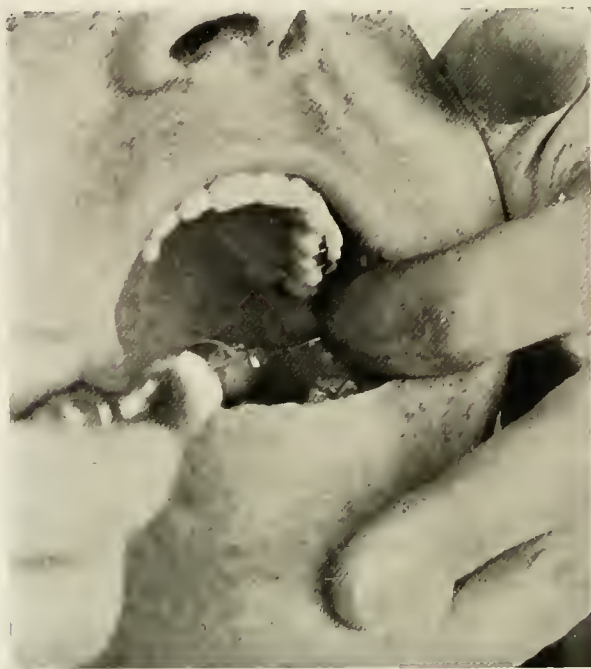

FIGURE 55  
Pterygomandibular injection of left side.

over the last molar, Fig. 56. The student will at first be surprised to find this place a good deal further to the outside than he expected. If the last molars have been lost, it is sometimes difficult to determine the exact position for the puncture. Sometimes there is a good deal of atrophy of the jaw, and the tendency therefore is to make the injection too low. It is better to err in the other direction.

If the upper teeth are present, an imaginary line may be drawn over their occlusal surfaces. The place where this meets the internal oblique line, with the mouth opened as wide as possible, is generally the right location. If there are no back teeth in either jaw, have the patient open the mouth wide and estimate the location by dividing the dis-




FIGURE 56

Roentgen picture, showing needle inserted for the pterygo-mandibular injection.

tance between the inferior and superior alveolar ridge in two. The needle is inserted one cm. above this point.

The syringe, which is held in readiness, is taken up with the right hand and at the same time the palpating finger should draw the mucous membrane to the outside. This not only makes the puncture easier, but also makes it possible to change the position of the needle after it has been

inserted by moving it with the mucous membrane towards the median line, if necessary. Introduce the syringe at an acute angle to the inner surface of the ramus by placing the barrel between the cuspid and bicuspid of the other side. Puncture the mucous membrane, the opening of the needle pointing toward the outer side, and inject a few drops to anesthetize the superficial structures.

Advance the needle, following the same direction. A fascia, which often presents considerable resistance, is met next. A sharp needle penetrates this with a little additional pressure, and then comes in contact with solid bone, the internal oblique line. This is an important landmark and should be reached after inserting the needle about 5 mm. If it cannot be felt, it is due to one of two things, either the needle has been inserted too far medially, or else the direction is not correct, in which case the barrel of the syringe should be moved still further back. After feeling the internal oblique line, the direction of the syringe should be changed, bringing it more towards the median line, until it is almost parallel with the ramus (Fig. 54, 2 and 5). If it is desired to anesthetize the lingual nerve, the needle should be inserted 1 cm., when about  $\frac{1}{2}$  cc. of the solution should be injected.

If the inferior alveolar nerve is also to be anesthetized, the needle should be advanced further. It is well to make sure of the proper direction by occasionally feeling the bone. Even the experienced operator should not neglect to do this, to avoid failures in case of anatomical variations. It is, however, important not to push the needle underneath the periosteum. If the anterior part of the inner surface of the ramus presents a well-marked convex condition, as is often found in heavy people with thick, solid bones, it is often necessary to draw the needle back. By releasing the mucous membrane and moving it with the needle towards the median line, the pterygomandibular space is approached at a less acute angle, the needle being aimed from the

first towards the center of the ramus. After it has been fully inserted (Fig. 54, 3 and 6) (in children correspondingly less) make sure that the right place has been reached by again feeling the bone. The point of the needle should now be in the pterygomandibular space, just above the lingula (Fig. 53) where the main part of the solution is injected ( $1\frac{1}{2}$  cc.) in a slow and even manner, gently moving the syringe back and forth. It is important not to inject while

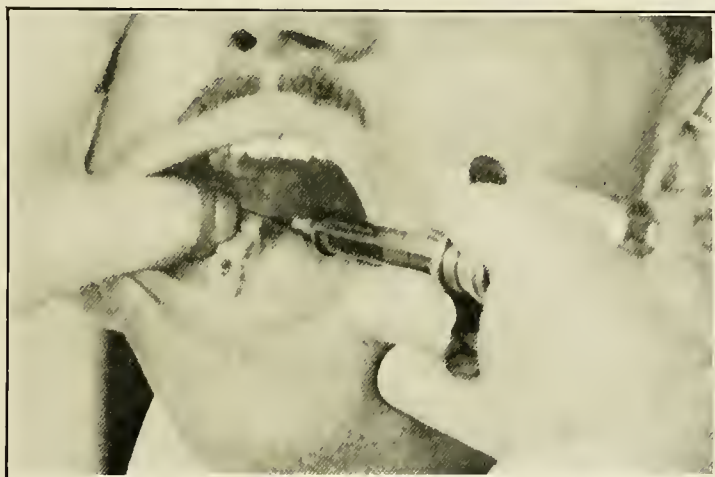


FIGURE 57

Pterygomandibular injection on the right side.

inserting the needle so as to avoid infiltration of the muscle, and also reserve a larger amount for the final injection, which is readily taken up by the connective tissue of the pterygomandibular space.

In children the mandibular foramen lies somewhat lower, and in the aged, higher. The injection should be made accordingly.

**Waiting Period.** The anesthesia takes effect in from 10 to 20 minutes, and is at its best after half an hour.

**Symptoms of Anesthesia.** After about five minutes or earlier, the patient feels a condition in the tip and side of tongue and the corresponding half of the lower lip, which is described as tingling, hot, cold, hard, stiff, swollen, or numb sensation. If these symptoms do not appear within a reasonable time, another injection should be made.

**Area Anesthetized.** By blocking the inferior alveolar nerve the following parts are anesthetized: externally the lower lip and the region of the corners of the mouth as far back as the mental foramen; internally all the teeth and the bone on that side, also the gum on the labial side from the anterior teeth as far back as the first bicuspid. Blocking the lingual nerve in addition gives anesthesia of the tip and side of the tongue and lingual part of the gum.

**Communicating and Interlacing Nerves.** When operating in front of the mouth, the nerve of the other side has to be considered, and also the branches of the cervical plexus. The buccinator nerve supplies the gum on the buccal side of the second bicuspids and molars, and is generally not anesthetized with the pterygomandibular method.

**Duration of Anesthesia.** If about 2 cc. of a 2 per cent solution is injected, the anesthesia usually lasts from one to one and a half hours. If more time is required for the operation, the injection should either be repeated after one hour or else 4 cc. should be injected at once, when it will last for about two to three hours.

**Return to Normal.** The anesthesia wears off gradually through absorption of the anesthetic solution.

**Failures** occur if the needle loses contact with the inner surface of the ramus and the solution is injected into the muscle; if the needle is not inserted deep enough; or if the injection is made too low. If the solution does not thoroughly infiltrate the nerve, the parts supplied by the central fibers may not become entirely anesthetized.

## Mental Injection

### *For the Mental Nerve and Anterior Part of Inferior Alveolar Nerve*

This injection is not often used, as it has no special advantages and the same parts can be more easily and efficiently anesthetized by means of the pterygomandibular injection. The location of the mental foramen is variable, as has already been seen, and its size and formation varies greatly. The injection is used to anesthetize the mental nerve where it leaves the bone, as well as to produce anesthesia of the anterior part of the inferior alveolar nerve, supplying the incisor teeth, cuspid, and first bicuspid.

**Instruments.** Use syringe No. 1 with long hub and 42-mm. needle.

**Landmarks.** The mental foramen cannot always be readily found. It lies halfway between the inferior border of the mandible and the gingival margin. The teeth serve usually as landmarks. Its location is either anterior, inferior or posterior to the apex of the second bicuspid. The foramen may be found with the tip of the palpating finger.

**Technique.** If it is intended to inject the solution outside the foramen, the needle can be inserted about 1 cm. anteriorly. If the injection is to be made into the mental foramen itself, the needle should be inserted posteriorly and from above to follow the direction of the canal. After the foramen has been located and the mucous membrane prepared in the usual manner, place the tip of the palpating finger over it and insert the needle a short distance anterior to the finger. After injecting a small amount, it is advanced along the bone until the point is felt, when 1 cc. of the solution is injected while applying pressure with the finger tip. If we depend on this method for anesthesia of the anterior branch of the inferior alveolar nerve, it is necessary to promote its infiltration into the canal by apply-

ing pressure during the injection and several minutes afterwards. Better results can be attained by inserting the needle from above and behind, guiding it into the foramen for about 5 mm. One cc. is then injected directly into the canal.

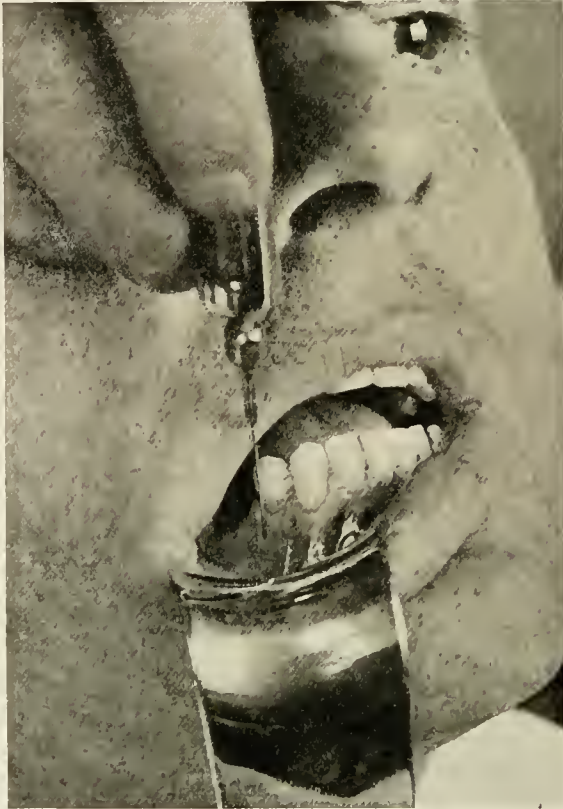

FIGURE 58  
Mental injection on right side.

**Waiting Period.** Anesthesia usually occurs in ten minutes.

**Symptoms of Anesthesia.** Numbness of the lip occurs as in the previous method, this being due to the blocking



of the mental nerve, but it is not a sign that the teeth in the anterior part of the mandible have been anesthetized.

**Area Anesthetized.** The lip, anterior part of the gum, and, if the canal is successfully infiltrated, the teeth anterior to the foramen are anesthetized. The lingual part of the



FIGURE 59  
Roentgen picture, showing needle inserted for mental injection.

gum retains its sensation. The injection is generally used on both sides simultaneously, to get anesthesia of the anterior part of the lower jaw. It may also be used in conjunction with the pterygomandibular injection on the op-

posite side and serves to block the communicating nerves coming from the other side.

**Duration of the Anesthesia.** The duration depends upon the amount of solution which penetrates into the mandibular canal. It may last one hour.

### **The Buccinator Injection**

The mucous membrane of the cheek and buccal part of the gum at the lower jaw, usually as far forward as the second bicuspid, is supplied by the buccinator nerve. If an operation involves these parts, either infiltration anesthesia has to be resorted to or else the buccinator nerve has to be blocked. Some writers claim that this area is anesthetized while injecting for the inferior alveolar nerve.

**Anatomical Considerations.** The buccinator nerve lies for a considerable distance at the anterior aspect of the ramus until it passes into the cheek at the level of the parotid duct. The cheek is taken between the thumb and index finger and extended laterally with the jaws opened. Insert the needle towards the ramus and inject about 1 cc.

**Area Anesthetized.** Mucous membrane of cheek, post-molar triangle, and buccal part of gum in lower jaw.

### **Sphenomaxillary Injection**

#### *For the Second Division of the Fifth Nerve*

The entire upper jaw is not as easily anesthetized as the mandible because its nerve supply is not as conveniently situated and no method has been developed so far which is simple and gives evenly satisfactory results. There is not only the difficulty of reaching the maxillary nerve and inducing anesthesia of all its branches, but even if it could be easily accomplished from the oral cavity, it would not be practical for minor dental operations on account of producing numbness of parts which are not only remote from the field

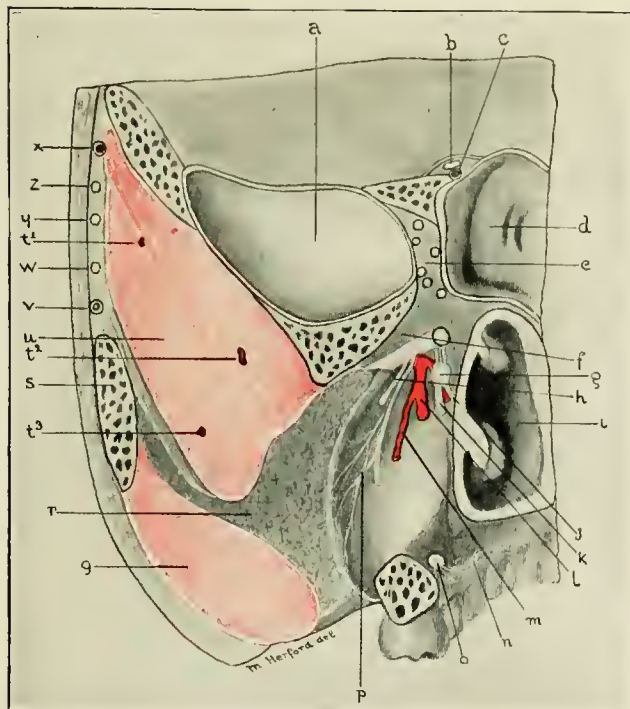


FIGURE 60

Oblique frontal section through sphenomaxillary fissure, showing posterior surface of maxillary bone. a. Sphenoid bone. b. Optic nerve. c. Ophthalmic artery. d. Sphenoidal sinus. e. Frontal, lacrimal, trochlear, nasociliary, abducens, oculomotor nerves. f. Sphenomaxillary fissure. g. Sphenopalatine ganglion. h. Post. sup. alv. nerves. i. Nasal cavity. j. Posterior palatine. k. anterior palatine nerve and artery. l. Internal maxillary artery. m. post. sup. alveolar artery. n. Anterior palatine nerve on palate. o. Large palatine foramen. p. Buccal branch. q. Masseter m. r. Parotid gland. s. Zygomatic arch.  $t^1, t^2, t^3$ , Temporal artery. u. Temporal m. v. Branches of superficial temporal artery. w, y, z. Branches of facial nerve.

of operation, but which would cause disagreeable sensations, such as numbness of the soft palate and uvula. On account of this, it is desirable not to block the entire maxillary nerve where it emerges from the foramen rotundum, but at a

place as far peripheral as possible, so as to avoid the sphenopalatine ganglion but include the posterior superior alveolar nerve. The mucous membrane of the hard palate and gum can easily be taken care of separately by blocking the nerves at the incisive and larger palatine foramina.

**Anatomical Considerations.** The maxillary division, after leaving the cranium through the foramen rotundum, crosses the sphenomaxillary fossa. Its length to the place where it enters the infraorbital fissure is about 1 cm. The sphenomaxillary fossa is filled with connective tissue, and externally is bordered by the parotid gland. It contains a number of vessels, the largest being the infraorbital artery. Smaller branches are the posterior superior alveolar branches, the sphenopalatine branches, and several veins emptying into the pterygoid plexus. The sphenopalatine ganglion lies directly over the pterygopalatine canal, and its sensory branches leave the maxillary nerve as soon as the latter enters the sphenomaxillary fissure. The maxillary nerve, after leaving the fossa, is called the infraorbital nerve and for its first course runs in an open channel, the sulcus infraorbitalis on the floor of the orbit, the continuation of which is the canal of the same name (Fig. 18). The parts supplied by all the superior alveolar branches can therefore be anesthetized by blocking the nerve where it enters the sulcus, avoiding the nasal and palatal branches. Here the posterior superior alveolar and gingival branches are given off. The middle superior alveolar branch usually begins in the sulcus infraorbitalis, where it enters a canal in the outer wall of the antrum. Sometimes, however, it runs for a short distance over the zygomatic surface of the maxilla before entering a special foramen anterior to and above the one for the posterior branch. It is, therefore, desirable to reach the nerve just where it enters the sulcus infraorbitalis.

**Instruments.** A special needle is required for this injection. It should be larger (22 gauge) and its free

length, from hub to point, should be 4 cm. Smith has designed a special needle (Fig. 61) for this purpose, bent at a right angle. It is mounted on syringe No. 2. After giving it a fair trial, I found that I could do better with the bayonet-shaped attachment of new construction and 5 cm. needle mounted on syringe No. 1 (Fig. 27).

**Landmarks.** With the jaws but slightly opened and the buccinator muscle relaxed, the cheek can be sufficiently retracted laterally so as to bring into plain view the beginning of the zygomatic process on the maxillary bone.

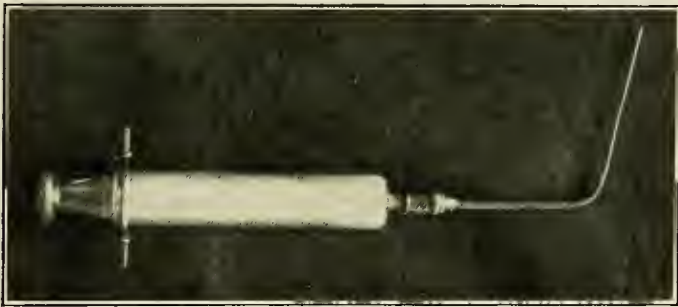

FIGURE 61

Luer syringe with needle for intraoral sphenomaxillary injections

**Technique.** The needle is inserted high up in the reflection of the mucous membrane at the concave posterior surface of the zygomatic process of the maxilla over the apices of the second molar, the opening of the needle directed towards the bone. After inserting the needle, it is advanced obliquely upward and slightly backward, keeping in close contact with the bone covered by the periosteum. A few drops are injected after the puncture is made and more while the needle advances. After it is inserted about 3 cm. the point should be in the neighborhood of the infra-orbital fissure, where the remaining part of the solution in the syringe containing 3 cc. is deposited.

The solution is taken up freely and easily by the connective tissue, and occasionally may be so extensively distributed that it affects other nerves, especially the sphenopalatine ganglion and its branches, also the oculomotor or abducens nerve. Smith, making this injection with his specially devised needle, anesthetizes the entire second division. He inserts his needle more posteriorly as far back

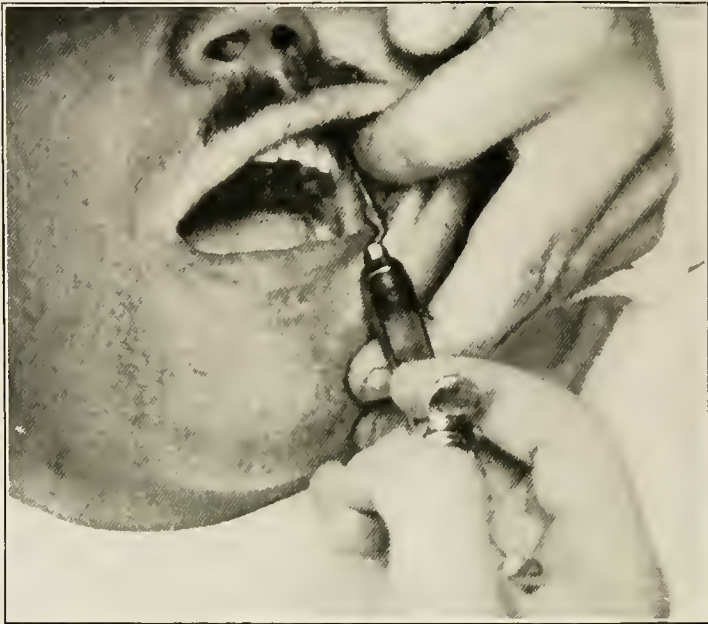


FIGURE 62

Sphenomaxillary injection with new bayonet attachment.

as the roots of the third molar and then follows a more vertical direction, keeping in close contact with the periosteum of the maxilla. He inserts the needle 3 cm. and injects 3 cc. Stern advocates a shifting of the needle for the last part of the injection, about 5 mm. in a posterior direction to include the ganglion. The author, however, prefers the extraoral method, if the entire maxillary division

is to be anesthetized. One should remember to keep close to the zygomatic surface of the maxilla to avoid injury of a vessel, as this may cause the formation of a hematoma.

**Waiting Period.** Generally about fifteen minutes, but the time is dependent upon how close to the nerves the solution is deposited.

**Symptoms of Anesthesia.** The symptoms are important, as they give an idea of the success of the injection and the extent of the anesthesia. If the infraorbital region of the skin and half of the upper lip feels somewhat numb, it is a sign that the infraorbital nerve and its dental branches have been successfully blocked. If the corresponding half of the nose and the palate feel numb, it is a sign of anesthesia of the sphenopalatine ganglion and its branches.

**Area Anesthetized.** If successful, all the upper teeth on one side and the buccal and labial part of the gum should be anesthetized. Occasionally, however, only the superior alveolar branches may be reached, and at times the solution may infiltrate the sphenopalatine ganglion and its nasal and palatal branches. The symptoms of anesthesia and testing of the various parts will give the desired information.

**Communicating Nerves.** The branches which have not become anesthetized by the primary injection have to be taken care of separately.

**Duration of Anesthesia.** The time on which we can depend for painless operating is from one to one and one half hours.

**Failures and Undesirable Symptoms.** On account of the variability of the anatomical relations, success is not as certain as with the other methods. The technique is also more difficult because of the inconvenient location of the nerve. If the ganglion or the oculomotor and abducens nerve is anesthetized, difficulty in swallowing, or ocular disturbances may be produced (see also under extraoral maxillary injection).

### The Zygomatic Injection

#### *For the Posterior Superior Alveolar Nerves*

This injection, which is also called tuberosity injection, is very useful. Its aim is to block the posterior superior alveolar branches and in a large number of cases the middle superior alveolar branch. It is a modification of the sphenomaxillary injection.

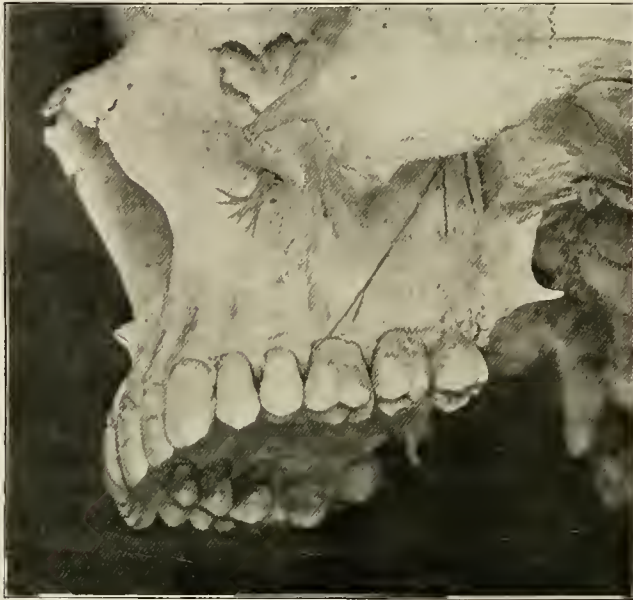

FIGURE 63

Infratemporal surface of the maxilla. The posterior superior alveolar branches are shown entering the foramina. One branch is a gingival branch.

**Anatomical Considerations.** The posterior superior alveolar branch descends on the zygomatic surface of the maxilla in an almost vertical direction. It may be accompanied for a short distance by the middle superior alveolar nerve. The former enters its foramen at about the middle of the surface; the latter much higher up.



**Instruments.** Syringe No. 1 with a 42-mm. platinum needle is used. The needle may be slightly curved previous to sterilizing it. Some operators find it more convenient to mount it with the bayonet attachment.

**Landmarks.** Palpate the zygomatic process of the maxilla with jaws opened halfway and cheek relaxed.

**Technique.** The needle is inserted opposite the roots of the second molar, as high up in the reflection of the mucous membrane as possible, the opening directed towards the bone. Follow an upward, backward, and inward direction, keeping in close contact with the periosteum and depositing the solution while advancing. The path of the needle crosses the posterior, superior alveolar and gingival branches and often reaches the middle superior alveolar branch.

**Waiting Period.** Anesthesia occurs in ten minutes.

**Symptoms of Anesthesia.** Symptoms are usually absent from this injection.

**Area Anesthetized.** The posterior teeth and corresponding alveolar part of the bone and buccal gum of the upper jaw are anesthetized. The extent depends somewhat on whether both the posterior and middle alveolar nerves have been blocked or whether the posterior one alone has been affected, in which case it results generally in anesthesia of the three molar and two bicuspid teeth. The gingival branch, however, reaches usually only as far forward as the second bicuspid.

**Anastomosing and Communicating Nerves.** It is important to keep in mind that the posterior middle and anterior alveolar branches form an extensive plexus, the superior dental plexus, and that impulses and sensations may be conveyed in two directions. With the posterior alveolar branch blocked, the second and third molars are as a rule completely anesthetized, but pain from the first molar may still be conveyed by way of anastomoses with the middle alveolar branch. The palatal part of the gum has to be

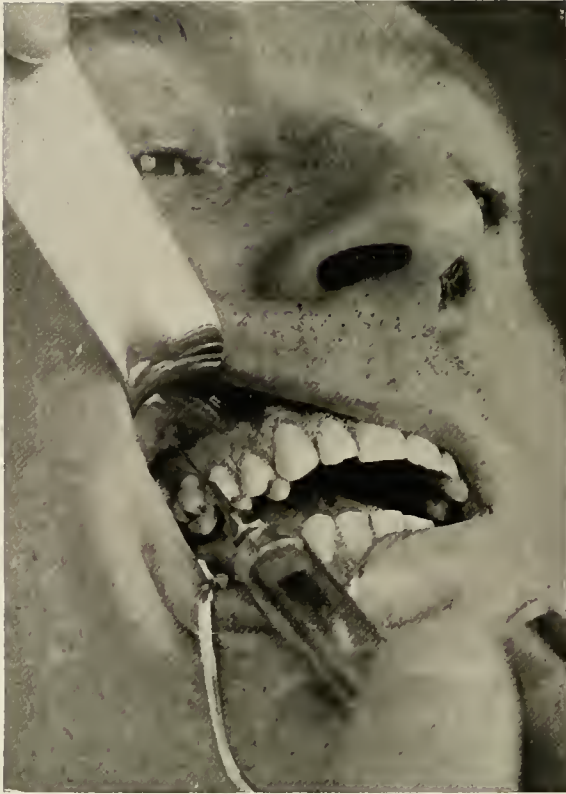

FIGURE 64  
Zygomatic injection on right side.

taken care of separately by either the infiltration or conduction method for the palatal branches.

**Duration of Anesthesia.** Anesthesia usually lasts about three quarters of an hour.

**Failures** are due either to improper technique or to anatomical variations.

### **Infraorbital Injection**

*In the Anterior Superior Alveolar and Terminal  
Branches of the Infraorbital Nerve*

With this method anesthesia of the terminal branches of the infraorbital nerve, the palpebral, the nasal and labial

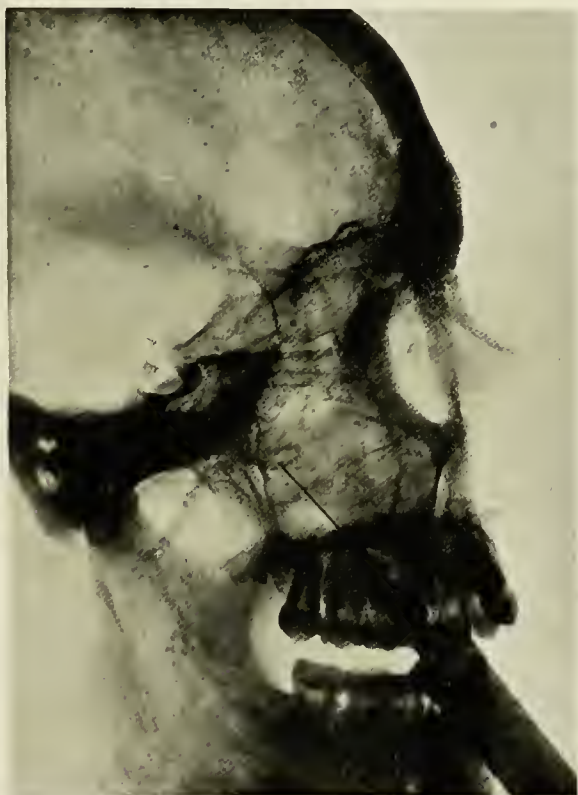

FIGURE 65

Roentgen picture, showing needle inserted for zygomatic injection.

nerves is induced. It is, however, more frequently employed to anesthetize the anterior superior alveolar nerve. As it is impossible to insert the needle into the canal except by the extraoral method, it is necessary to depend on infiltration of the solution through the foramen into the canal, as far back as is necessary to reach the anterior alveolar branch. This injection has not become very popular, as many patients object to the slight swelling caused by the infiltration.

**Instruments.** Use the 42-mm. needle mounted with the long hub on syringe No. 1.

**Landmarks.** Palpate the inferior border of the orbit. The infraorbital foramen lies a few millimeters below on the anterior surface of the maxilla and can be easily located with the finger\* tip.

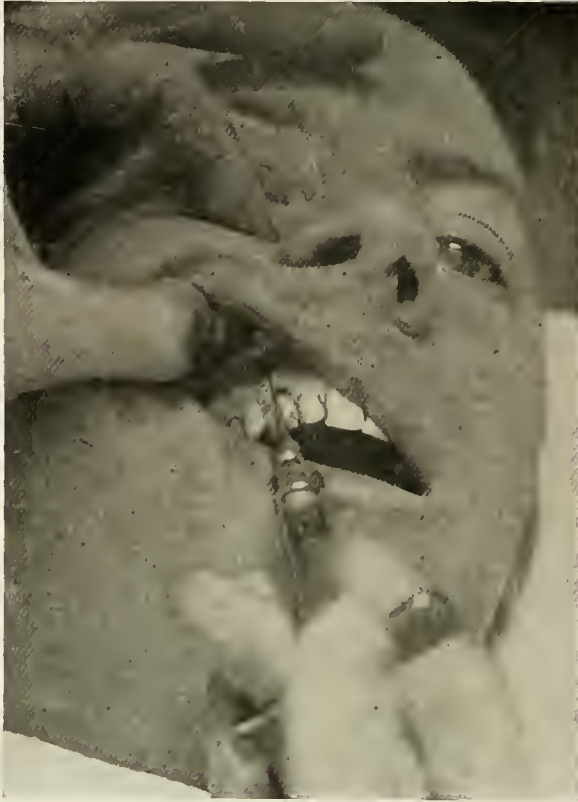

FIGURE 66  
Infraorbital injection on right side.

**Technique.** The index finger should be placed over the infraorbital foramen when the operator's position is in front of the patient. When the position is at the side of the chair, the thumb is more convenient. With another finger

retract the upper lip so as to expose the entire canine fossa, where the needle should be injected as high up as possible. Advance until it is felt under the palpating finger. Sometimes it is necessary to inject a small amount to detect the

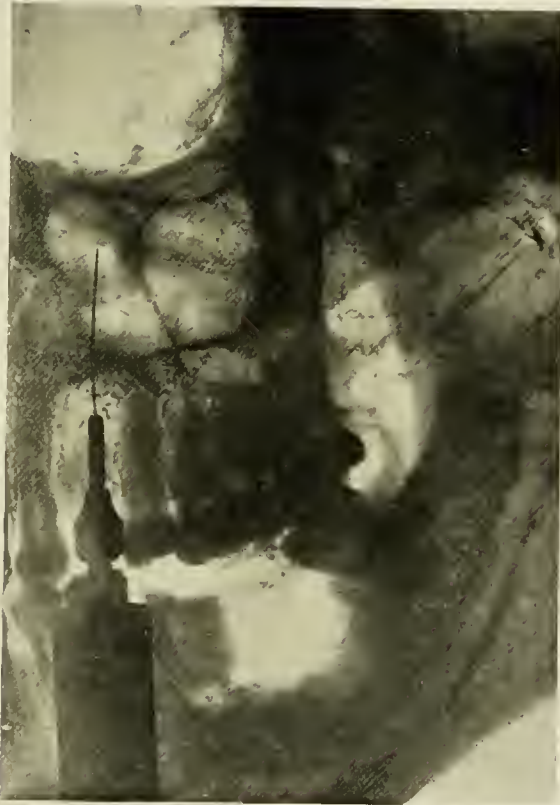

FIGURE 67

Roentgen picture, showing needle inserted for infraorbital injection.

location of the point of the needle. Insert the needle down to the bone and compress the soft tissue over the foramen, while making the injection, so as to force the solution into

the infraorbital canal, where the anterior superior alveolar nerve will be anesthetized. Use 1 to  $1\frac{1}{2}$  cc. of the solution.

**Waiting Period.** About ten minutes.

**Symptoms of Anesthesia.** Numbness in upper lip, lower eyelid, and side of nose. This, however, is only a sign that the terminal branches have been anesthetized and is not an indication of anesthesia of the teeth.

**Area Anesthetized.** Besides the external tissues just mentioned, anesthesia is produced in the central and lateral incisors, and sometimes the cuspid.

**Communicating and Anastomosing Nerves.** Anastomoses from the opposite side as well as from the posterior branches of the infraorbital nerve should be kept in mind. The palatal part of the gum is supplied by the nasopalatine nerve and therefore needs an additional injection.

**Duration of Anesthesia.** About three quarters of an hour.

### Incisive Injection

#### *For the Nasopalatine Nerve*

This method is used to anesthetize the anterior part of the palate and palatal gum. The injection is made into the foramen, which usually is of large size.

**Instruments.** Syringe No. 1 with long or short needle.

**Technique.** Insert the needle in the median line, directly behind the central incisors. If the bone is followed, the needle will be conducted into the foramen, where a few drops (about  $\frac{1}{4}$  cc.) only are necessary to produce anesthesia.

**Area Anesthetized.** The palatal gum and anterior part of the hard palate as far back as the cuspids.

**Waiting Period.** Anesthesia occurs almost at once.

**Duration of Anesthesia.** This varies according to amount injected. One quarter cc. lasts about one hour.

## Palatine Injection

### *For the Anterior Palatine Nerve*

This injection, as the preceding one, gives anesthesia of only the soft tissues, namely the mucous membrane covering the posterior part of the palate, and the palatal part of the alveolar process.

**Anatomical Considerations.** The location of the larger palatine foramen varies according to the age of the patient, as has been described in the chapter dealing with the anatomical structure of the jaws.

**Instruments.** Syringe No. 1 can be used with either the long or the short needle.

**Technique.** Insert the needle about 1 cm. above the gingival margin on the palatal side of the last erupted molar or, if extracted, the position it occupied. The place should be selected so that the needle can be advanced toward the palatine foramen in a straight line. After the foramen has been reached, about  $\frac{1}{4}$  cc. or less of the anesthetic solution should be injected.

**Area Anesthetized.** This injection anesthetizes the lateral half of the posterior two thirds of the palate approximately from the cuspid back.

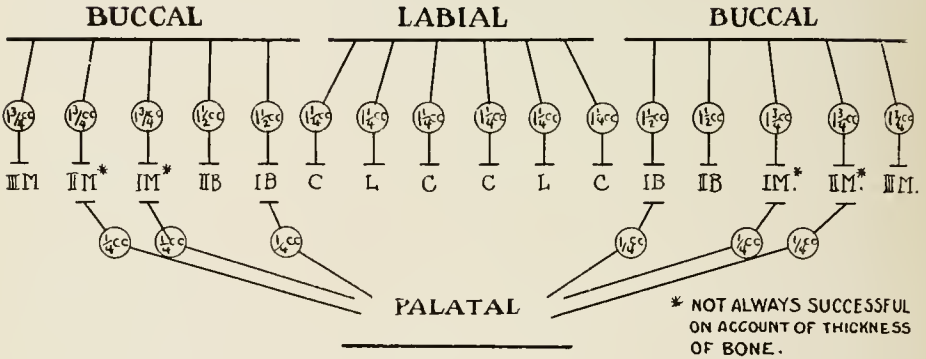
**Duration of Anesthesia.** About one hour.

**Undesirable Symptoms.** If too much of the solution is injected, anesthesia of the palatine nerve supplying the soft palate results, which is uncomfortable and often distressing to the patient.

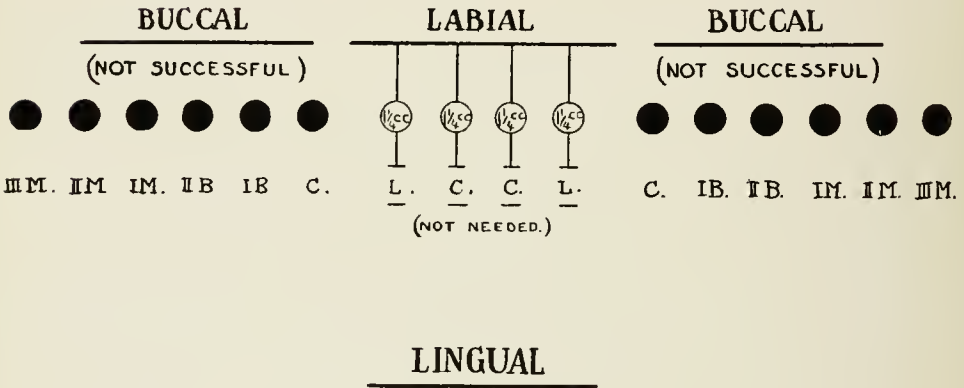
The following tables give general information assisting in the proper selection of the infiltration or conduction methods, as well as the amounts to be injected.

INFILTRATION ANESTHESIA FOR THE TEETH ONLY

I. MAXILLA



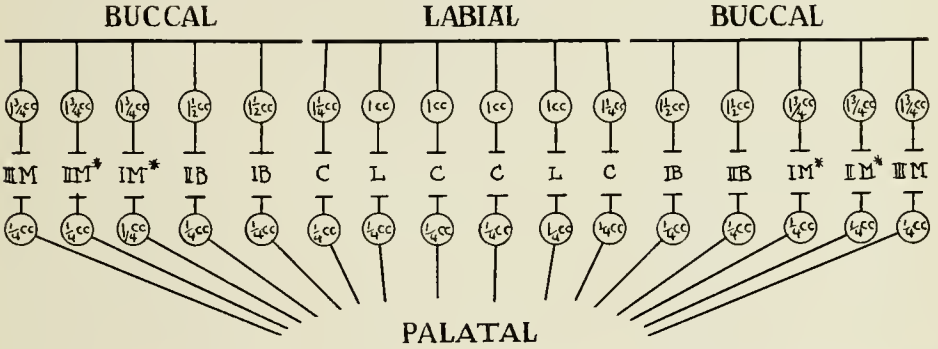
II. MANDIBULA





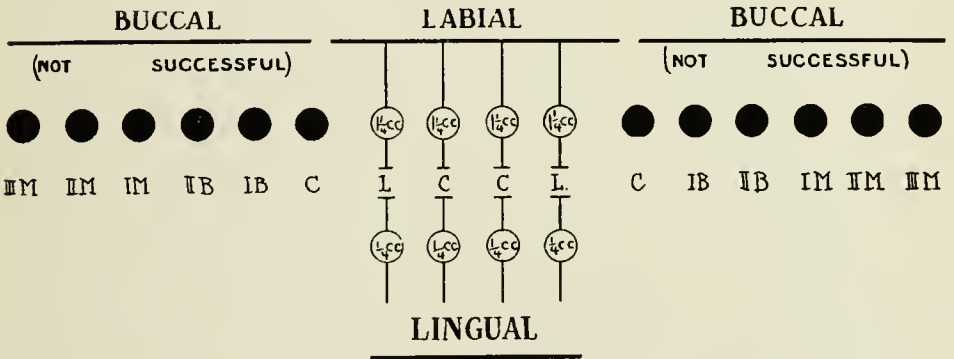
INFILTRATION ANESTHESIA FOR THE TEETH AND SOFT TISSUES

I. MAXILLA



\* NOT ALWAYS SUCCESSFUL ON ACCOUNT OF THICKNESS OF BONE.

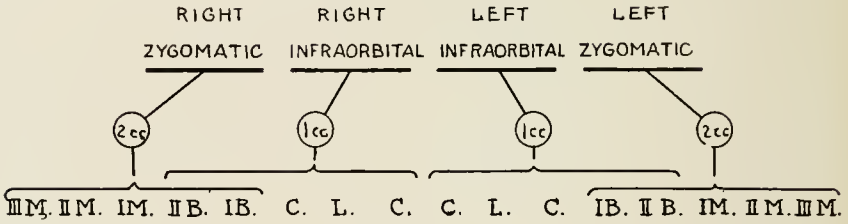
II. MANDIBULA



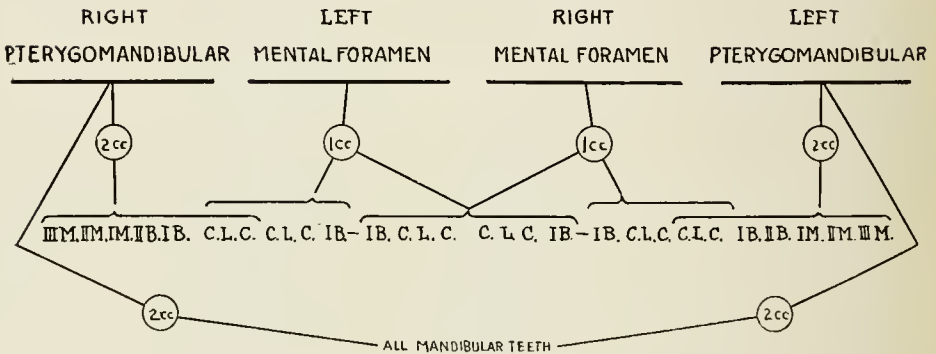
LINGUAL

CONDUCTION ANESTHESIA FOR THE TEETH ONLY

I. MAXILLA

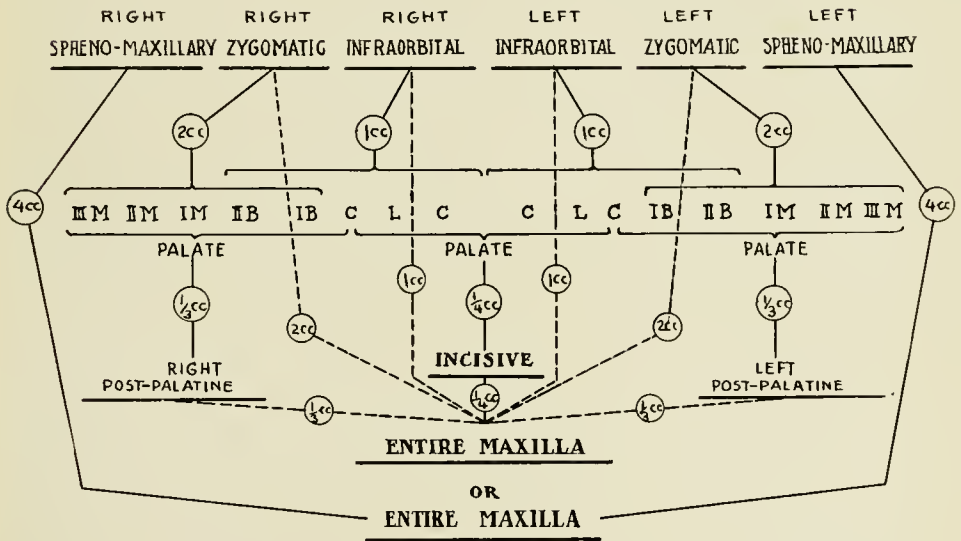


II. MANDIBULA

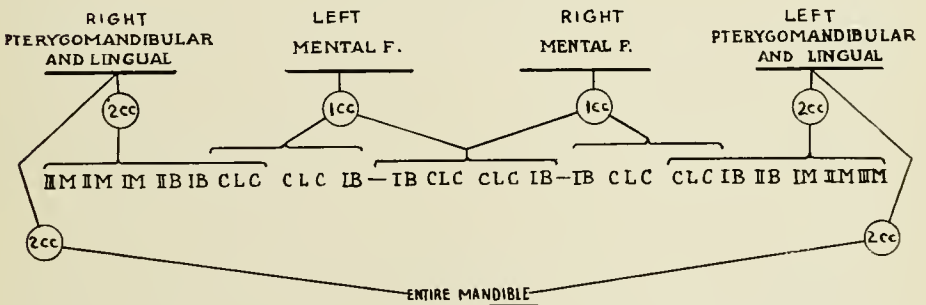


CONDUCTION ANESTHESIA FOR THE TEETH AND SOFT TISSUES

I. MAXILLA



II. MANDIBULA



### Extraoral Methods of Conduction Anesthesia

Extraoral injections are indicated in all cases in which the intraoral methods are inadvisable on account of pathological changes in the regions where injections should be made. In cases of fractures, bullet wounds, and injuries which prevent the opening of the mouth, or render manipulation of the lips and cheeks painful, the extraoral injections are especially indicated. Also in cases of extensive operations, such as excisions of the upper or lower jaw. Extraoral are not more difficult than intraoral injections, and it is principally a psychic cause which prevents their more extensive use, as the dentist and even the oral surgeon hesitates to involve parts which are outside the oral cavity and seemingly have nothing to do with his field of work. These methods, however, are more than justified in extensive operations because with them a much larger area can be anesthetized and the operative procedure may be conducted aseptically. The danger of infection of deeper areas is reduced, as aseptic measures are more readily controlled externally than within the mouth. However, it is important to warn all operators that extraoral injections must be strictly aseptic, as infections from them are more dangerous than those from intraoral injections on account of their greater depth and closer proximity to the brain.

### Extraoral Mandibular Injections

*For the Entire Third Division of the Trigeminal Nerve*

Anesthesia of the mandible can be accomplished successfully by injecting into the pterygomandibular space by the intra- and extraoral methods. The mandibular injection is indicated for operations on the ramus, especially the superior part; also if the pterygomandibular injection is contraindicated on account of pathological conditions.

**Instruments.** Use syringe No. 2 with a steel needle 6 to 8 cm. long and a rubber disc placed so as to indicate 5 cm. from point of needle.

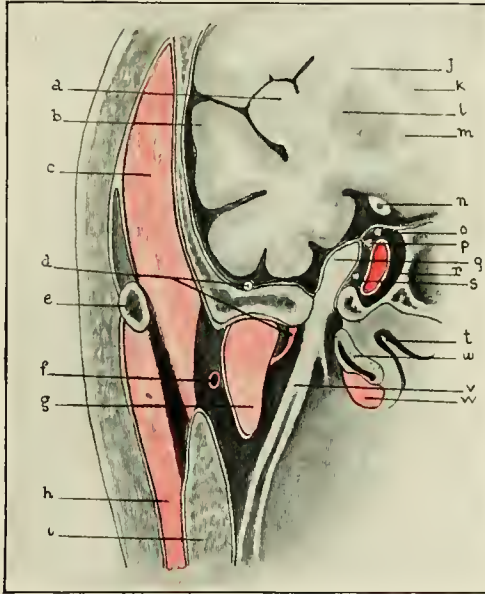


FIGURE 68

Frontal section through foramen ovale showing structures to be pierced by needle to reach the mandibular nerve. a. Insula. b. Dura mater. c. Temporal m. d. Meningeal a. e. Zygomatic process. f. Internal maxillary a. g. External pterygoid m. h. Masseter m. i. Coronoid process of mandible. j. Claustrum. k. Corpus nuclei caudati. l. Putamen. m. Globus pallidus. n. Tractus opticus. o. Oculomotor nerve. p. Trochlear nerve. q. Trigeminal ganglion. r. Cavernous sinus. s. Abducens nerve. t. Pharyngeal recess. u. Auditory tube. v. Mandibular nerve. w. Levator palatine m.

**Landmarks.** A line drawn from the zygomatic angle to the tragus of the ear is divided into halves and at the dividing point, just below the inferior border of the zygomatic arch, is the place for the insertion of the needle.

**Preparing the Site of Injection.** Disinfect the skin

where the injection is to be made, as described in a previous chapter. Use a small syringe with fine needle to infiltrate the skin with the previous use of the ethyl chlorid spray if necessary.

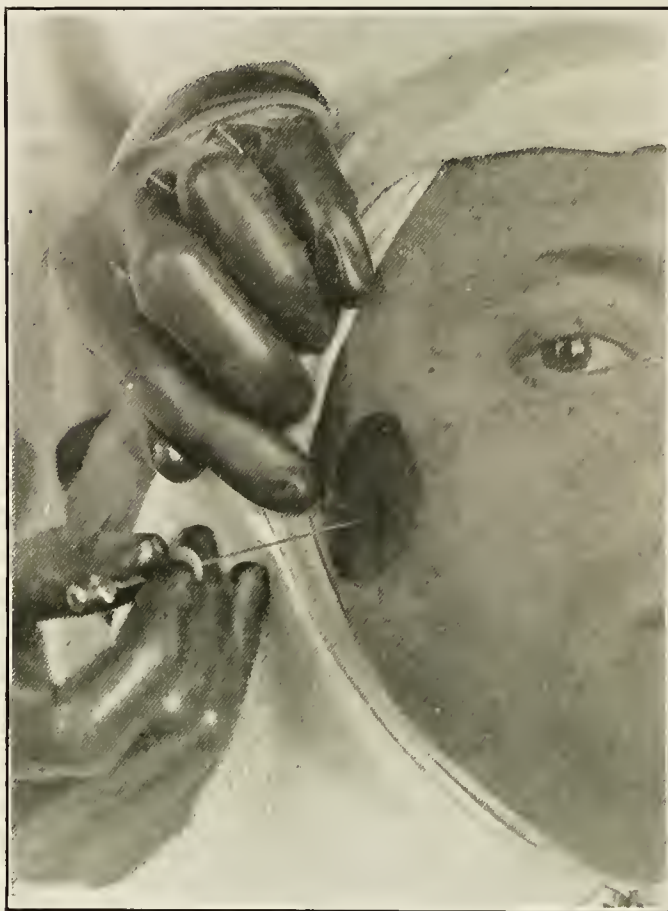

FIGURE 69

Landmarks to find place for inserting the needle for the extra-oral mandibular injection.

**Technique.** Insert the needle and advance in a slightly upward direction. The needle passes anterior to the neck

of the condyle and below the zygomatic arch. A few drops may be injected at once, but no more should be injected until the nerve is reached, as the needle transverses several muscles (see Fig. 68). After advancing to a depth of 3 to

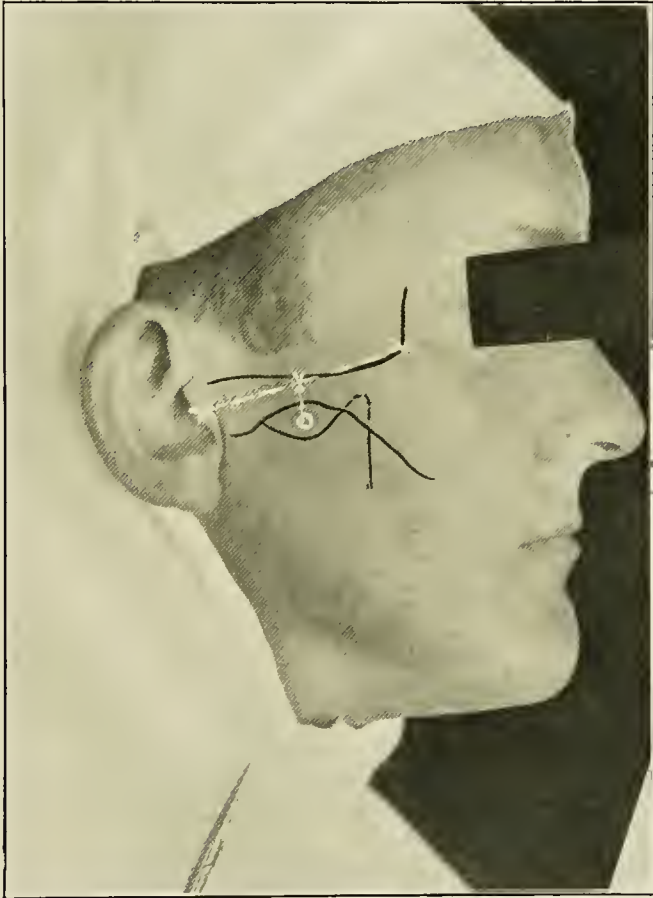


FIGURE 70  
Needle inserted for the extraoral mandibular injection.

4 cm. the point of the needle should strike the smooth infra-temporal surface and be carried along for one more cm. until the mandibular nerve is reached, when the patient notices

suddenly a radiating pain in the region supplied by it. Inject from 2 to 5 cc.

**Waiting Period.** Five to twenty minutes may elapse before anesthesia is complete, depending on the proximity of the injection to the nerve.

**Symptoms of Anesthesia.** The same as in the pterygo-mandibular injection.

**Area Anesthetized.** Teeth and bone of the mandible, lower lip, chin, corner of the mouth, lower part of the cheek and temporal region.

**Communicating Nerves.** Branches of the cervical plexus and the mandibular nerve from the other side are to be considered when preparing for an extensive operation.

**Duration of Anesthesia.** The anesthesia lasts from two to three hours, depending on the amount injected.

### **Extraoral Pterygomandibular Injection**

#### *For the Inferior Alveolar Nerve*

This is made into the same region as the intraoral injection; namely, the pterygomandibular space. It is indicated whenever the intraoral method cannot be used, as is often the case in fractures of the mandible and trismus of the muscles of mastication.

**Instruments.** Use syringe No. 2 with a steel needle 6 to 8 cm. long and a rubber disc placed 5 cm. from point of needle.

**Landmarks.** A line is drawn from the tragus of the ear to a point marked by the anterior margin of the masseter muscle and the lower border of the mandible. The point where the line is divided in halves marks the projection of the mandibular foramen upon the skin.

**Technique.** Position of left hand for the injection on the right side: Place index finger behind and parallel with the posterior border of the ramus, the thumb in the same direction, its tip touching the lower border of the ramus.



Position of the left hand for injection on the left side: The left arm is passed around the patient's head, the thumb is placed behind the posterior border of the ramus pointing downwards and the index finger bent around the angle of

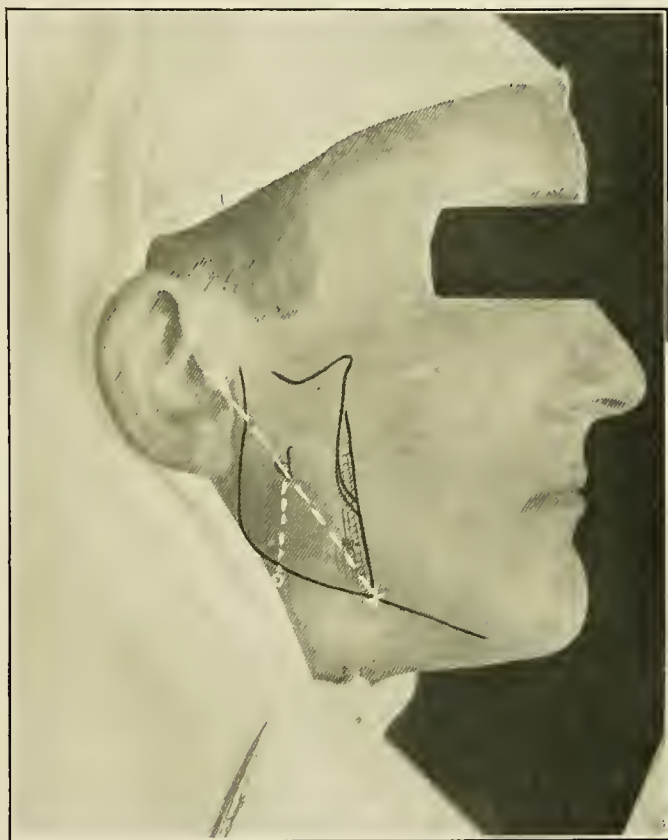


FIGURE 71

Landmarks to determine the location of the mandibular foramen.

the ramus. The head is bent towards the opposite side. The dismantled needle is now inserted at the inner side of the lower border of the mandible, 2 cm. anterior to the angle of the ramus. Advance in a parallel direction to the posterior border of the ramus, marked on the left side by

the thumb and on the right side by the index finger. The pterygomandibular space is about 4 cm. from the point of insertion of the needle, and as the direction of the needle is parallel to the nerve, it is of no consequence if the needle is inserted a little too far. Inject 2 cc.

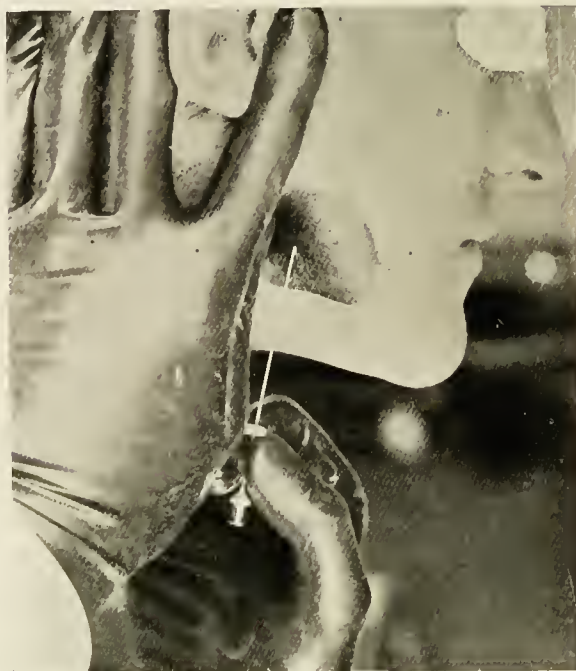

FIGURE 72

Inserting needle on right side for extraoral pterygomandibular injection.

**Waiting Period.** Anesthesia takes effect in fifteen minutes.

**Symptoms of Anesthesia.** Numbness of the lip is felt about five minutes after the injection.

**Area Anesthetized.** The lower teeth and jaw on the side injected, the lower lip and anterior part of gum.

**Communicating Nerves.** The inferior alveolar nerve and the mental and lingual nerves of both sides communicate

freely in the anterior part of the lower jaw. If anesthesia of the lingual nerve is required, it must be done separately. This can be accomplished in two ways, first by withdrawing the needle about 1 cm. and reinserting it in a vertical direction to the inferior border of the mandible. This brings it further forward. Second, by inserting the needle 5 cm.,

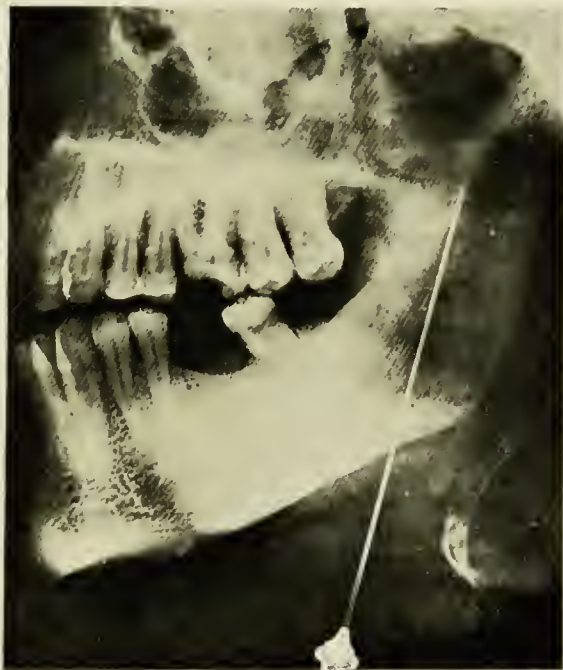

FIGURE 73

Roentgen picture, showing needle inserted for extra-oral pterygomandibular injection.

which carries it higher and near the place where the inferior alveolar and lingual nerves divide.

**Duration of Anesthesia.** Same as for the intraoral method; that is, about one hour if 2 cc. are injected.

**Failures.** The advance of the needle may find bony resistance at a depth of 3 cm. This comes from wrong direction of the needle point, striking a well-marked internal

oblique line. The needle may strike bone at once, which may indicate a well-marked protuberance for the attachment of the pterygoid muscle.

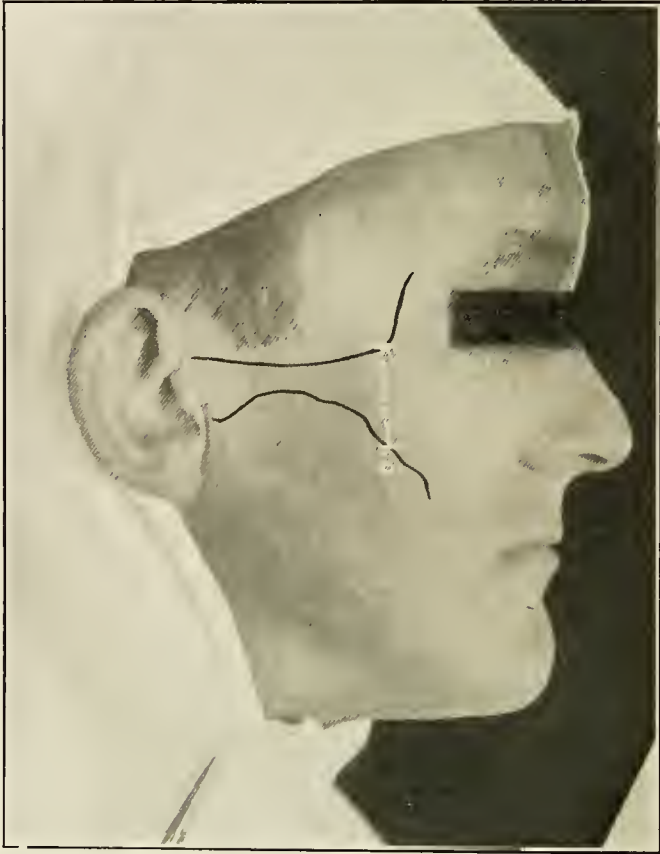


FIGURE 74

Landmarks to find point where to insert needle for extraoral maxillary injection.

### **Extraoral Maxillary Injection**

*For the Entire Second Division of the Trigeminal Nerve*

Considerable progress has been made in the development of intraoral conduction methods for the upper jaw,

with the aim of anesthetizing a larger area with a small number of injections. However, the extraoral method is more satisfactory for extensive surgical operations than intraoral injections if the entire second division is to be anes-

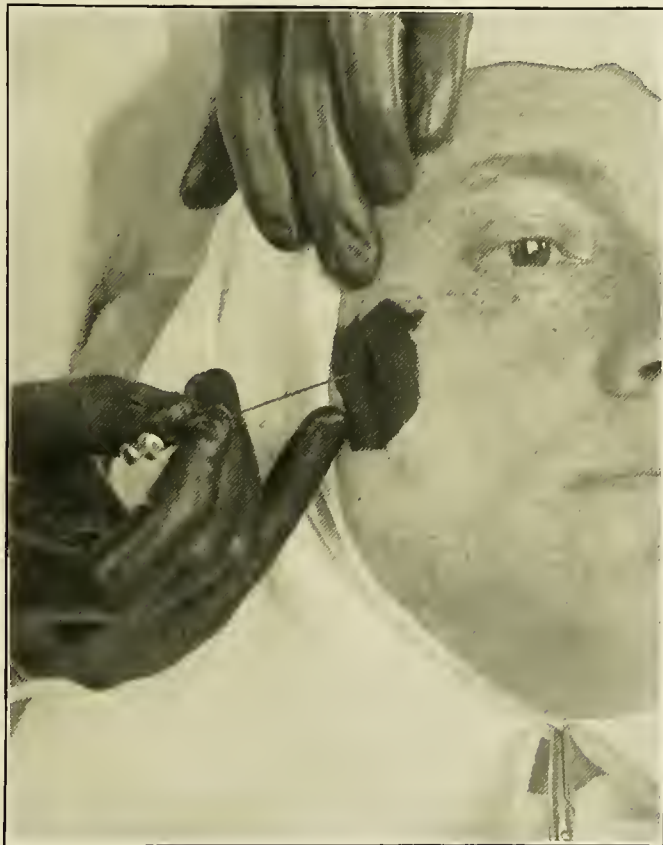

FIGURE 75  
Inserting needle for the maxillary injection.

thetized. By the extraoral path the sphenomaxillary fossa can be reached directly, but the greatest advantage lies in the possibility of inserting the needle in a place remote from the field of operation, and, in extensive lesions, outside the diseased zone.

**Anatomical Considerations.** The sphenomaxillary fossa has already been described under the heading of the intraoral sphenomaxillary injection. The only structures which are penetrated by the needle are the skin and buccinator muscle. (See also Fig. 6o.)

**Instruments.** Use syringe No. 2 with a steel needle 6 to 8 cm. long and a rubber disc placed 5 cm. from point of needle.

**Landmarks.** Palpate the superior border of the zygomatic arch and find the place where it forms a right angle with the superior margin of the orbit. This is called the "zygomatic angle." From this point, draw a vertical line downwards and the point for insertion of the needle is about  $\frac{1}{2}$  cm. below the place where this meets the inferior border of the zygomatic arch.

**Technique.** With the teeth in occlusion insert the needle with syringe mounted. A few drops are injected under the skin. After advancing in a vertical direction to the cheek for 2 to 3 cm., the maxillary tuberosity is struck. If only the posterior molars are to be anesthetized, the injection can be made here. If the whole upper jaw is to be anesthetized, the needle is advanced in the same direction to the sphenomaxillary fossa. Sometimes it is necessary to direct the needle a little further backward to pass by the tuberosity which is felt for orientation. After a further advance of 2 cm., bony resistance is again felt when the point of the needle strikes the inferior part of the anterior surface of the larger wing of the sphenoid bone, just below the foramen rotundum. The depth at this place is about 5 cm. One to two cc. are injected. The injection is made purposely below the foramen to keep away from the nerves supplying the eye (see Fig. 6o).

**Waiting Period.** Complete anesthesia usually occurs in from ten to fifteen minutes.

**Symptoms of Anesthesia.** After about five minutes the patient feels numbness in the nose, and sometimes in the upper lip, but the symptoms are much less marked than in the lower jaw.

**Area Anesthetized.** Practically all the parts supplied by the maxillary division are anesthetized, the maxillary

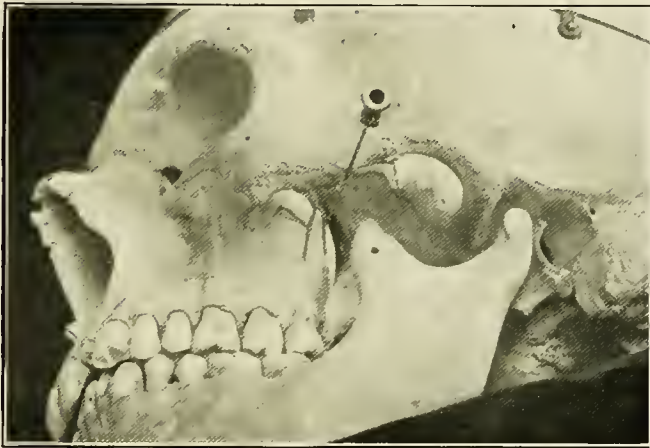

FIGURE 76

Skull, showing direction of needle. Note the sup. alv. nerve branches.

bone, the teeth, the gum, half of the palate and upper lip, the anterior part of the cheek, the skin of the nose, the antrum and part of the nasal cavity.

**Anastomosing and Communicating Nerves.** Branches from the other side have to be considered and the facial branches of other divisions of the trigeminal nerve.

**Duration of the Anesthesia.** The anesthesia lasts from two to three hours.

**Undesirable Symptoms.** Anemia in the region of the infraorbital artery sometimes causes circumscribed blanching of part of the cheek supplied by it. This is of no consequence. Diffusion of the solution into the orbit is liable

to occur, causing ocular disturbances of short duration. The oculomotor or abducens nerve may be infiltrated, causing double sight, weakness in the upper eyelid, dilation of the pupil, and if some of the accompanying vessels are affected, anemia of the eyelids will be observed. Sometimes

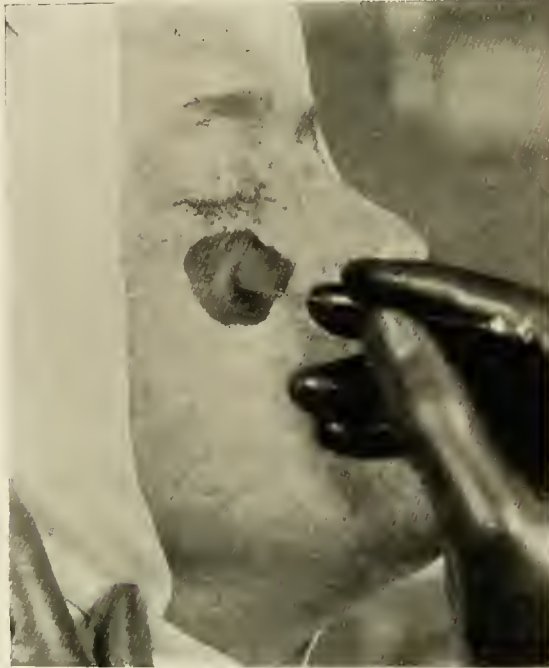

FIGURE 77

Inserting needle for the extraoral infraorbital injection.

anesthesia of the soft palate gives difficulty in swallowing. All these complications, which occasionally accompany the anesthesia, last from fifteen minutes to two hours and are not serious, merely inconveniencing the patient for a short time. The patient should be told that these conditions occur at times and that they are to be disregarded. As this method is only used for operations of a serious and extensive nature, the occasional occurrence of complications



can be considered a small factor compared with the advantage of positive asepsis and the disadvantages of general anesthesia for such operations in the mouth.

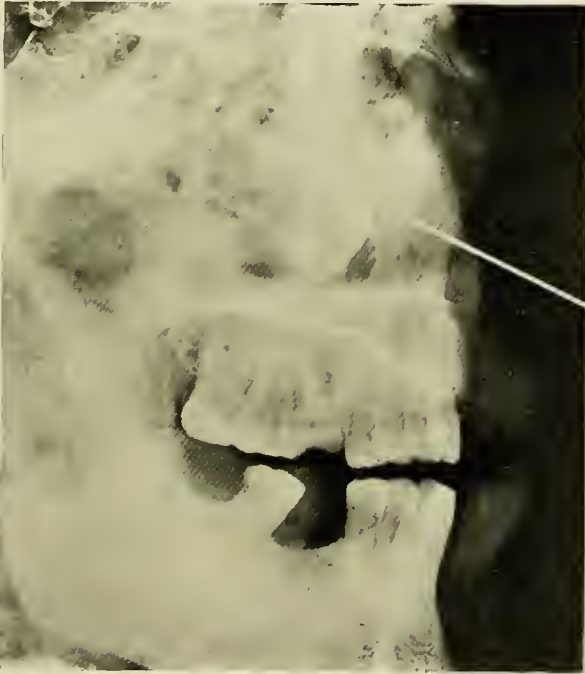

FIGURE 78

Roentgen picture, showing needle inserted into the infraorbital canal.

### **Extraoral Infraorbital Injection**

*For the Anterior Superior Alveolar and Infraorbital Nerve*

The disadvantage of the intraoral method for the infraorbital injection is that the needle cannot be introduced directly, and that the success depends on infiltration of the canal. Entrance to the foramen is especially important if alcohol injections are to be used for the relief of neuralgic pain.

**Anatomical Considerations.** The direction of the infraorbital canal varies considerably. Its course is quite frequently curved, so that a needle cannot be inserted to any great extent. Its direction is generally slightly upward and outward. Sometimes there are accessory foramina.

**Instruments.** Syringe No. 1 may be used with the 42-mm. iridio-platinum needle. The syringe, however, should not be entirely filled, so that after inserting the needle to the desired point, the piston may be drawn back, to make sure that the needle has not been inserted into a vessel. If syringe No. 2 with a detachable needle is used, it should be of small calibre (25 gauge) and made of iridio-platinum, which is flexible.

**Landmarks.** The infraorbital foramen can be easily palpated below the inferior border of the orbit.

**Technique.** The needle is inserted directly into the infraorbital foramen from the surface of the previously prepared skin for about  $1\frac{1}{2}$  cm. It is important to avoid pushing the needle into a vessel. (See Page 161.) One and a half cc. are injected with even pressure.

**Waiting Period.** The anesthesia usually occurs in a very short time.

**Area Anesthetized.** Same as in the intraoral method; namely, the upper incisor teeth, labial part of gum, anterior part of maxillary sinus, and the area supplied by the palpebral, nasal and labial branches of the infraorbital nerve.

**Duration of Anesthesia.** In this method the results are quicker and more lasting, as the infiltration of the anesthetic solution through the infraorbital foramen is not depended upon as in the intraoral method.

## PART VII

### ILL EFFECTS, FAILURES, ACCIDENTS, AND POSTOPERATIVE SEQUELAE

#### Ill Effects

**P**AIN may be caused by injecting solutions which are not isotonic, from too rapid injecting or from the injection of solutions which are either too hot or cold. Drugs such as thymol, carbolic acid, etc., cause pain, as demonstrated by Seidel, who found by using the velum test on the skin of his arm that antiseptics added to the solution cause severe pain in some cases. Pain during injection is also caused when the tissue is hypersensitive, owing to pathological conditions, such as in gingivitis, especially if the solution is forced into an acute abscess where there is already pain due to pressure exerted by the accumulated pus.

**Toxic effects** due to the procaine or suprarenin have already been discussed at length (see Pages 66 and 73). For therapeutic measures see Page 69.

#### Failures

**Anatomical conditions** may prevent success in local anesthesia. In the chapter dealing with the anatomy of the maxillae possible anatomical variations have already been pointed out. Recognition of the landmarks is of paramount importance and anatomical difficulties have to be considered when selecting the technique for the individual case. The anatomical relations and structures involved should always be clearly in the mind of the operator.

**Faulty Instruments and Technique.** Proper selection of needles and careful technique is of importance. In the infiltration method, the most frequent causes for non-anesthesia are failure to reach the part opposite the apex of the root, which may be due to too short a needle, from not inserting it deep enough or from loss of contact with the bone. In conduction anesthesia, it is still more essential to follow the technique exactly so as to inject the solution into the connective tissue surrounding the nerve to be anesthetized, and as close to the nerve as possible. If the injection is not made close enough to a nerve trunk so that the latter is freely infiltrated, partial anesthesia results. The parts supplied by the peripheral nerve fibers may be numb, but the centrally located fibers may not have been affected by the drug. For example, in conduction anesthesia of the inferior alveolar nerve, the lip may be numb, but one of the molar teeth may react partially to painful stimuli. Another injection will usually remedy the trouble. At times the non-anesthesia is due to not waiting sufficiently long. It takes from ten to twenty minutes for the entire nerve to become affected. Again it may occur that the needle is inserted in a wrong direction; especially in the pterygo-mandibular injection one is liable to enter the internal pterygoid muscle. The result is failure to get anesthesia, and stiffness in the jaw for several days, the patient often being hardly able to open the teeth. This is due to a muscular trismus which will last until the solution is absorbed, sometimes several days, because absorption from muscles is slow.

**Deteriorated Drugs.** Procaine or suprarenin which has been decomposed is much less active and may lose its therapeutic effect entirely. Deteriorated procaine can be recognized by a yellow brownish color. Suprarenin turns pink to brownish red. A fresh active solution is as clear as water.

### Accidents

**Breaking of Needle.** The breaking of a needle is an accident which may be caused from sudden unexpected movements by the patient. This, however, can be prevented almost entirely by using iridio-platinum needles, which can be bent several times at the same place before breaking. (See also chapter dealing with instruments.)

**Entering Blood Vessels.** Arteries are thick-walled and elastic and are inclined to give way. They are therefore not easily punctured. Smaller blood vessels and capillaries can be avoided by injecting a small amount while pushing the needle into the tissue. However, if the vessels run along the path of the needle and especially if enclosed in a narrow bony canal, such as the infraorbital canal, it is very much more difficult to avoid them and it is necessary to use special precaution. In such cases, after the needle is inserted, the piston of the syringe should be slowly withdrawn. If the point of the needle is in a vessel, blood will be sucked into the syringe.

**Local Vasoconstriction.** The author has had a number of cases where marked anemia has resulted in the skin of the face immediately after the injection was made. At one time, a blanched area as large as a silver dollar appeared underneath the eye, and at another time one side of the nose was included. This condition is due to the constricting action of the suprarenin on the smooth muscle tissue in the walls of an artery, which may be so complete as to prevent circulation entirely. The patient is not conscious of this condition and it is better not to call his attention to it, or at least not until the operation is completed.

**Entering Nerve Trunks.** If a nerve trunk is injected, no harm follows, though a sudden radiating pain is felt in the parts supplied. Anesthesia is complete almost immediately.

Should nerve fibers be torn accidentally during injection,

temporary anesthesia of the parts supplied persists until the fibers regenerate.

**Anesthesia of Motor Fibers.** Motor fibers, especially of the facial nerve, are occasionally infiltrated, which results in temporary muscular disturbances indicated by the closing of the eyelid or drooping of a part of the upper lip. These conditions, while disfiguring, disappear as soon as the effect of the anesthetic wears off. Reassure the patient by explaining that the parts will return to normal in a very short time.

**Psychic Shock.** Psychological effects on the human organism have only recently received proper consideration. Research on this subject by Cannon and Crile furnishes food for deep thought and offers explanations for certain clinical observations, which heretofore have been laid to the toxicity of a drug or the idiosyncrasy of a patient.

Of the various emotions, fear is perhaps the strongest and deepest rooted. It is closely associated, however, with pain and anger, all of which arouse in the body peculiar instinctive reactions. Crile has given expression to the view that on a principle of "phylogenetic association" these emotions, born of innumerable injuries in the course of evolution, have developed into portentous foreshadowings of possible injury, and have become, therefore, capable of putting into action all offensive and defensive activities that favor the survival of the organism. These responses are automatic and not willed movements, and the ability to suppress them, more or less, is gained by racial and individual training. This virtue of heroically submitting to physical punishment and suffering is, however, not a mark of high civilization, as is illustrated by the stoic American Indian of the days gone by and the spoiled child of our own race.

Flight and fight express the most characteristic inherited impulses which may be produced either singly or combined

in man. The first is manifested by the attempt or intention to withdraw from painful and dangerous contact, while the other causes modifications of the action seen in animals at bay or in attack. Muscular tension, defensive movements with the arms, the set jaw, clenched fists, and dilated nostrils are often observable in certain patients. The effect of these energies, generated but not actually transformed into activity, on the body mechanism, Crile compares with the detrimental action of a motor running at full speed in an automobile which is kept stationary. It expresses itself in trembling, sweating, blanching, rapid respiration and palpitation. The result often is exhaustion and causes, according to Crile, a low brain threshold. Therefore, in patients obsessed by fear, all stimuli — both physical and psychological — are augmented.

On this basis must be explained the extreme prostrating effects produced in many people by the sound of instruments, traumatic injury, the sight of blood, and often even merely the thought of an operation. It should also be remembered that some patients associate local anesthesia with cocaine and fear its toxic effects; and unfortunately prospective patients have frequently been well informed by their friends of all the accidents, toxic effects, and post-operative sequelae that have come to their knowledge.

Fear, therefore, is an important factor and cannot be neglected, as it is frequently the cause of untoward effects, developed by some patients before or after the anesthetic solution is injected. The pain caused by the initial puncture should also be considered in this connection. Several years ago the writer made clinical demonstrations, selecting hospital patients of various temperaments. It was observed that in nervous, sensitive patients the pulse rate markedly increased when the needle was inserted and before any solution was injected. In the phlegmatic type, the patient did not complain of pain when the needle was inserted, and the

pulse rate remained almost the same. Psychic shock is also more likely to occur in individuals who have been suffering from pain and insomnia and whose general resistance is lowered by various diseases, such as anemia, hysteria, toxemia, and infection. The following will serve as an illustration in which debilitating factors combined with fear were the cause of an accident which would have been laid to the toxic effects of the anesthetic, had it occurred after the injection. The incident happened on the occasion of a demonstration given by the author before the State Society of Massachusetts in May, 1913. The patient, a mail carrier, about thirty to thirty-five years of age, was seated in the chair in front of the audience. He had been suffering pain for several days and was weakened from loss of sleep. While explaining the technique of the injection suitable for the case, the patient suddenly collapsed. No injection had been made.

It is evident, therefore, that to operate successfully under local anesthesia confidence must be inspired by a convincing attitude and a certainty of success which will dispel lack of faith, obviate fear, and prevent those conditions caused by the emotions.

**Syncope.** The loss of consciousness due to reflex inhibition of the cardiac and respiratory centers starts with paleness, nausea, cold sweat, and dizziness. It comes on with dilation of the pupils and muscular relaxation and is accompanied by rapid, small and regular pulse, slow and shallow respiration. It is caused by emotions, such as fear, especially if the air is hot and close. Anemic persons are very susceptible, and a slight amount of pain or the sight of blood may cause syncope. The condition is as a rule not serious and disappears soon under the proper therapeutic measures. Place the patient with the head at a lower level than the rest of the body. Children may literally be placed on their heads. For adults, the recumbent position is com-



mendable, or the head may be lowered between the knees, if the patient is sitting. The last two methods will prevent the entire loss of consciousness, when resorted to as soon as the first symptoms appear, and in anemic patients a recumbent position should be selected from the first. Aromatic spirits of ammonia by inhalation is one of the quickest acting stimulants. If the patient has not lost consciousness, it may also be administered by the mouth. The dose should be given in a very small amount of water. Its action, due to irritation of the mucous membrane, is better and quicker in concentrated form. Camphorated Validol, already recommended, is an excellent preparation and is best administered on a piece of sugar. Use 5 to 10 drops. In severe cases, strychnia,  $1/60$  or  $1/30$  of a grain hypodermically, is one of the most reliable remedies and should always be kept on hand in Greeley Units (see page 69). Black coffee should be given the patient before leaving the office. It is a splendid stimulant, on account of its lasting action.

Syncope should be distinguished from collapse due to toxic action of the anesthetic solution, and treated as described under separate head (see page 69).

### Postanesthetic and Postoperative Effects

**Tissue Lesions.** If the anesthetic is properly prepared from fresh drugs and isotonic sterile Ringer solution without harmful and unnecessary admixtures, there is no danger of harmful effects on the tissues. If pathological conditions occur following local anesthesia, they may either be traced to infection from non-sterile solutions, or instruments, to infection of the wound made by the puncture of the needle during or after the operation, or to too high a percentage of suprarenin. Complete anemia is not desirable except in very rare instances. Arrest of circulation increases the possibility of infection. Bleeding is both a cleansing and

protective reaction. Its prolonged inhibition or entire absence retards normal repair and gives bacterial invasion a chance for unrestricted development. Injecting into suppurative lesions should also be avoided on account of the danger of spreading the infection or carrying organisms into deeper, healthy structures. Conduction anesthesia eliminates dangers from this source and also enables the operator to distinguish between conditions caused by operative procedures from those that might be blamed on the injection. The author has inquired into the history of many cases of alleged tissue lesions or after-pain, and found that frequently opponents of local anesthesia encourage the patient, without investigating, in the belief that such conditions, which may clearly be due to operative procedures, are caused by the procaine. Worse still, I have found that there are dentists who blame the drug if their own cases happen to be followed by complications, from fear that the patient may find fault with their operative ability or surgical skill.

The question whether the dental pulp may be permanently injured if a tooth is anesthetized has been raised. It is the writer's opinion that no harm can be done if conduction anesthesia is used, and with the infiltration method the only danger is through infection. More likely causes of inflammation of the pulp after local anesthesia may be found in the operative procedure, especially on account of the tendency to generate too much heat.

**Edema** is due to an accumulation of serum in and between the cells of the tissue. The swelling may be due to infection or the condition may be caused by toxic or irritating effects upon the protoplasm from deteriorated drugs, antiseptics or other unnecessary additions to the anesthetic solutions; by solutions which are not isotonic; by traumatism, caused by inserting the needle several times in the same part, correcting the direction; by injecting into

muscles, from which absorption is sluggish, sometimes causing for several days stiffness and interference with normal action. If the internal pterygoid muscle is infiltrated, it may result in trismus, which interferes considerably with the motions of the jaw, and frequently causes swelling of the throat.

Edema, not due to infection, will disappear without treatment. Cold applications will give comfort to the patient and massage and exercise will promote absorption from muscles.

**After-pain.** The question of pain following an operation after the effects of a general or local anesthetic have worn off is one of greatest importance. The custom of dismissing the patient, after having performed a perfectly painless operation, leaving him in ignorance as to the possibility of postoperative pain is to be deplored. By a little forethought, it is not only possible to almost entirely eliminate physical suffering from postoperative sequelae, but also to preserve the mental equilibrium of the patient, and more than that, to prevent important general physiological disturbances. Cannon has shown that pain causes digestive disturbances by arresting the flow of the gastric juices and inhibiting the normal contractions of the stomach and intestines.

The degree of suffering varies. Hertzler, in his article on "After-pain in its Relation to General and Local Anesthesia," writes: "The interpretation of pain by the individual patient is the deciding factor, and consequently the testimony is subject to endless variation. The patient's own testimony varies. He may complain of pain a few hours after the operation, while after a week he may no longer recall his experience as painful, but willingly attributes his discomfort to the apprehension of possibilities of wound complication." The susceptibility of the individual is an important factor. It is influenced by the race, temperament, mental attitude, and state of health.

After these general remarks on pain occurring after operations, it is necessary for our special purpose to distinguish between after-pain due to local anesthesia and postoperative sequelae due to the operative procedure itself. The latter are usually due to the trauma of the operation. Simple trauma does not cause a great deal of pain, however, unless complicated by tissue destruction due to thermal influences, such as heat generated by a bur, causing pulpitis, or by lasting mechanical irritation, such as is often produced by tight dressings and more frequently by sharp pieces of bone sticking into the membrane covering it, or foreign bodies, parts of fillings, or fractured particles of enamel, and detached pieces of bone which may remain in the wound. Infection also plays an important part. Bacterial influences and food cannot be entirely excluded from wounds in the oral cavity, but fortunately, a blood clot generally closes the wound and furnishes sufficient protection. If, on the other hand, the deeper structures remain uncovered or if the clot fails to organize or breaks down, postoperative complaints are sure to ensue. In the writer's opinion, after-pain is in most cases due to the operation proper, and not to the anesthetic, which can be demonstrated in conduction anesthesia, where the injection is made in a place remote from the field of operation, or in anesthesia for operations on hard tooth substances, performed with proper care so that the pulp has not been injured.

Comparison of the amount of postoperative pain after general or local anesthesia is difficult, owing to the different susceptibility of various individuals, as well as the same patient at different times, and in no less a degree to the variations in the clinical, pathological and surgical aspects of one type of an operation. Moreover, the general custom of using morphia previous to administering ether will sometimes give the patient many hours' comfort during the time when after-pain would be most severe. Of course, prean-

esthetic medication can be employed with local anesthesia. Then again, the condition of the patient after ether is quite different from the condition after local anesthesia, due to disturbed sensibility and nausea, which at times is so bad that after-pain is hardly noticed at the time.

Postanesthetic pain after local anesthesia may actually occur, however. It is usually avoidable and generally the fault of the anesthetist. In the following, some causes which may produce postanesthetic pain are enumerated: deteriorated drugs through their toxic action on the tissue cells, as well as antiseptics, if strong enough to destroy bacteria; the use of too hot or too cold a solution; injecting too fast, causing laceration of the tissue; the use of a blunt needle or unnecessary injury when inserting it; changing the direction of the needle several times; injecting air into the tissue; infection from non-sterile needles and solutions; infection spread by injecting into parts where pus has accumulated, and one more important condition which has been brought to the attention of the profession by Dr. Lewis of Lake Forest, Illinois, in an excellent article published in the May *Cosmos*, 1919. He claims that after-pain may frequently be due to the chilling of the anesthetized part. Local circulation is retarded, due to the constricting action of the suprarenin, preventing the area from receiving the normal proportion of warmth from the blood. On account of the anesthesia, the patient is unable to feel the cold. This, he believes, brings about in some persons considerable discomfort as the effect of the anesthetic departs, and it is his firm conviction that pain is almost invariably suffered by nearly all persons in proportion as the temperature is lowered during the period of anesthesia. Patients therefore should be advised to keep the face protected, and comfortably warm, until the effect of the anesthetic has worn off, not only in winter, but also on cold and windy summer days, or if the patient drives home in an open automobile.

It is evident that postanesthetic pain can be avoided with proper care and technique, and pain occurring from the operation or condition of the wound should, if anticipated by the operator, receive proper consideration. The intelligent patient may be told what is to be expected and instructed in palliative measures. A prescription should be given according to the amount of pain expected. The following have been found excellent by the writer: Phenacetin and Aspirin gr. v of each, taken when pain comes on and repeated after one hour if necessary. In more severe cases:

Phenacetin	Gr. xxiv
Sodii bicarb.	Gr. xl
Codein. sulph.	Gr. ii
Caffein. cit.	Gr. viii
Fiat capsulae No. viii	

Sig. Take for severe pain and repeat after three hours if not relieved.

For prompt relief give  $\frac{1}{8}$  or  $\frac{1}{4}$  grain of morphia hypodermically.

To avoid infection of the wound made by the puncture of the needle apply tannic acid and glycerin equal parts immediately after the injection. This acts as an astringent, contracting the wound margins, as well as a protective agent. The same may be used on wounds.

**Prolonged Anesthesia.** Cases of prolonged anesthesia have been reported to last for several days or weeks. These may be traced to injury of a nerve during the operation, as in the case of the lower jaw when the tooth sockets come in contact with the mandibular canal. In impacted wisdom teeth, there is special danger of injuring the inferior alveolar nerve. A fractured piece of bone, when misplaced, may cause pressure on the nerve. Accidental injection of alcohol may also be mentioned here. The syringe, after being taken from the jar, should be carefully rinsed, as described on page 83.

## PART VIII

### PRACTICAL APPLICATION OF LOCAL ANESTHESIA IN DENTISTRY AND ORAL SURGERY

**A**FTER the student has become familiar with the various methods of local anesthesia, he needs as a rule a little help in order to put into practice his newly acquired knowledge. Not only is it of importance that he know what method is best suited for a practical case, but he must become accustomed to operating under the new conditions. Pain, which in many operations the dentist is accustomed to rely upon as a signal before serious damage is done to healthy tissue, and which he has become used to having as a guide for the extent of his operation, is entirely abolished. Therefore, it is necessary to make a more extensive and careful investigation of the pathological condition and use more judgment and precaution when rapid cutting instruments are applied.

Two good rules for selecting the method of anesthesia are:

1. Use always the simplest and surest method.
2. Avoid injecting into pathological tissue.

**Cavity Preparation.** For all purely dental operations involving only the hard structures of the tooth and the dental pulp, we need only to anesthetize the dentinal nerve supplying the tooth in question. The accessory injections for the investing structure are not needed, except if the gum has to be retracted with a high cervical clamp or in other cases involving the soft tissue. The conductive method

will be found of special advantage if cavities are to be prepared in several adjoining teeth. It is advisable to prepare all cavities in the teeth to be anesthetized at one time regardless of whether they can be filled the same day. When preparing a cavity for a filling under anesthesia, care must be taken to avoid heating the tooth. Thermal shocks, though not felt by the patient, may burn the delicate pulp tissue, cause inflammation and subsequently death of the pulp. It should be remembered that the pulp chamber varies in size not only with the age of the patient, but also in persons of the same age. If, therefore, the cavity is extensive, it is of great value to ascertain the outline of the pulp chamber by means of a Roentgen film, and after the operation is finished, the dentinal tubules should be sealed by applying carbolic ether rosin to the cavity, both to prevent irritation and pain when the anesthetic has worn off, as well as on account of the danger of bacterial invasion which later might cause infection of the pulp.

**Crown and Bridge Work.** In crown and bridge work the most radical dental operations are performed. Not only is it necessary to remove more tooth substance than in any other dental operation, but the grinding seems almost unbearable to many patients and this in turn frequently prevents the dentist from performing his work with exactness. It is therefore evident that local anesthesia will not only prevent suffering, but gives an opportunity for better work, and therefore is of double benefit to the patient. It will also do away with one of the reasons why teeth have been devitalized in the past, some operators finding it necessary to eliminate pain by removing the dental pulp in order to be able to get satisfactory results. The abutments, as well as the soft tissue, generally need to be anesthetized, the latter to eliminate pain caused by the preparation of the neck of the tooth and the fitting of crowns and bands. Here again the exposed dentine should be protected after the



operation is completed. It is the writer's firm belief that the principal cause of pulp disease after crowning a vital tooth is from infection, through bacteria which have found entrance into the dentinal canals sectioned in close proximity to the pulp during the time which elapsed between tooth preparation and cementing the crown into place. The painless fitting of crowns and bands can be accomplished by surface anesthesia, as described on page 89.

**Pulp Extirpation.** The importance of saving the dental pulp is becoming more evident every day. Preventive dentistry does a great deal toward preserving this important organ, and the serious conditions resulting from devitalized teeth, case reports of which are to be found in every edition of any dental journal, clearly point out that the removal of healthy pulps is a poor practice except in occasional instances. The treatment of pathological pulps should only be undertaken after careful Roentgen examination. It is important to know the condition of the periapical tissues, the size and shape of the root canal, and whether there are obstructions to proper treatment, such as pulp stones or other calcifications. Infiltration or conduction anesthesia may be used. If a slight amount of sensation remains, and this occasionally happens if the pterygomandibular injection is employed to anesthetize the lower molars, complete anesthesia is easily obtained by the use of pressure anesthesia, which is a supplementary method. Local anesthesia is especially helpful in all cases where other methods cannot be applied or have proven a failure, especially if due to deposits, pulp stones in the root canals, and in teeth with hypertrophied pulps and where sensitive nerve tissue has been left in the apical part of the root canal. When extirpating a pulp under local anesthesia, it is important to realize that the periapical tissues are also anesthetized and proper care must be exercised so as not to injure or infect the peridental membrane. The length of the root canal can

be estimated by means of a Roentgenogram and another Roentgen film should be taken with a broach inserted to make sure that the pulp tissue has been removed to the very apex of the tooth. It is generally better to fill the canal at a subsequent sitting, as the patient is not able to cooperate and we have no way of telling when the filling has penetrated the apex.

If the infection has gone beyond the apical foramen, causing acute periodontitis or acute abscess, the conduction method is indicated, so as not to inject into tissue more or less infiltrated with pus.

**Treatment of Pyorrhea Alveolaris.** The conduction methods are of great help in the treatment of pyorrhea, especially if cauterizing of hypertrophied tissue is necessary. Some operators object to the painless method, claiming that it increases the chance of lacerating healthy tissue. However, it is greatly appreciated by the sensitive patient, especially in cases where a great deal of instrumentation is required.

**Diagnosis of Trifacial Neuralgia.** It is often difficult to locate the cause of minor neuralgia or to determine which division of the trigeminal nerve is affected. Many times there are several conditions found by means of Roentgen diagnosis, any of which might be the cause of the trouble. It is possible by means of local anesthesia to confirm or disprove a diagnosis by anesthetizing the suspected nerve branch or tooth.

**Alcohol Injections for Major Neuralgia.** The various methods of conduction anesthesia, especially the extraoral ones, are used for injecting alcohol in the treatment of neuralgia majores or tic douloureux. These injections cause prolonged anesthesia, lasting generally about six months or longer and then they have to be repeated. Alcohol is used in various strengths, or the following formula, recommended by Patrick:

Novocain	2 per cent
Chloroform	5 per cent
Alcohol	70 per cent
Ringer solution	23 per cent

If the injection is made into the deep orbit, he recommends reducing the quantity of chloroform to 2 per cent. The normal healthy patient should receive  $\frac{1}{2}$  grain of codein or  $\frac{1}{150}$  grain of scopolamin, and  $\frac{1}{6}$  grain of morphia about thirty minutes before the injection.

**Oral Surgery.** The advantages of local anesthesia for extraction of teeth and other surgical operations in and about the mouth have already been spoken of elsewhere at length. The operator who has had experience with both gas and oxygen anesthesia and the local methods will have no difficulty in choosing, and most patients who have had experience with the two ways will be found ardent advocates of local anesthesia.

*Extraction of Teeth.* In exodontia local anesthesia is entirely successful. With the old method of injecting into the gum producing a gingival velum, the operation was often painful. The methods described in this book make it possible to fully control pain by anesthetizing not only the superficial structures, but also the periosteum, bone, periodental membrane, and the tooth itself; and it lasts sufficiently long, no matter how difficult and tedious the case may be, giving the operator opportunity to resect irregular, sharp, bony protuberances, which hastens healing and allows early restoration by artificial appliances.

*Operations on the Jaws.* Any standard operation may be performed on the jaws. Local anesthesia is used by the writer continuously for apicoectomy, the removal of impacted teeth, cysts, tumors of the jaws, and the setting of difficult fractures.

*Operations on the Maxillary Sinuses.* Conduction anesthesia may be used, especially the sphenomaxillary or

extraoral maxillary method. It is often sufficient, however, to inject the anterior wall with the submucous method for making an opening through the canine fossa, such as would be necessary to remove a root or tooth which may have been forced into this cavity.

*Resections of the Jaws.* Both the upper and lower jaws may be resected with local anesthesia. The extraoral methods are used for such extensive operations. In the upper jaw, the entire second division, including the sphenopalatine ganglion and, in the lower, the entire third division, should be anesthetized. If incisions are made in the skin, these should be taken care of separately on account of the many interlacing branches and the multiplicity of their origin. The elimination of the anesthetist and his appliances, better control of hemorrhage, and the absence of contamination of the wound by vomiting are advantages.

In all operations of more extensive character, preanesthetic medication is absolutely essential to dull the patient's keenness and apprehension sufficiently to eliminate any complications from emotional and psychic activities.

## INDEX

- A
- Accidents, 161  
Adrenalin, 70  
After-pain, 166, 167  
Alcohol, injected accidentally, 170  
Alcohol, injected in trifacial neuralgia, 174  
Alypin, 63  
Ampules with Procaine-suprarenin solution, 80  
Anatomy, consideration for infiltration anesthesia, 93  
Anatomy, consideration in  
    buccinator injection, 126  
    causing failures, 159  
    extraoral infraorbital injection, 157  
    maxillary injection, 152  
    palatine injection, 139  
    pterygomandibular injection, 113  
    sphenomaxillary injection, 126  
    zygomatic injection, 132  
Anemia,  
    general, 164  
    local, 74, 165  
Anesthesia,  
    absorption, 89  
    conduction,  
        extraoral, 144  
        intraoral, 110, 113  
    general, 18  
    infiltration, 93  
    local, technique, 89  
    local *vs.* general, 18, 168, 175, 176  
    nasal, 90  
    of adjoining teeth, 109  
    of a number of teeth, 109  
    of individual teeth, 98, 104  
    of motor nerves, 162  
    of pulp, 90  
    prolonged, 170  
    selection of, 18  
    surface, 89  
Anesthesin, 63
- Anger, 162  
Anoci-association, 17  
Application,  
    nasal, 91  
    practical of local anesthesia, 171  
    to exposed pulps, 91  
Apothesine, 63, 64  
Associations, phylogenetic, 16, 162  
Author's method of preparing the solution, 81
- B
- Bleeding, cleansing, 165  
Blood pressure and suprarenin, 74  
Blood vessel, entering, 161  
Bottle for Ringer solution, 59  
Bromurol, Knoll, 86  
Buccinator injection, 126
- C
- Camphor, in oil, 70  
Canal, palatine, 27  
Cavity, nasal, 29  
    preparations, 171  
Cocain, discovery, 62  
    contraindications, 63  
    habit-forming, 63  
Coffee, as stimulant, 71  
Cold, exposure to after local anesthesia, 169  
Conduction anesthesia, 110  
Conduction anesthesia, advantages, 111, 166  
    extraoral, 144  
    intraoral, 113  
Confidence of operator, 85  
    of patient, 17  
Contents, 11, 12, 13  
Crown and bridge work, 172  
Cups to prepare solution, 57  
Cysts, 175

- D
- Diagnosis of trifacial neuralgia, 174
- Distilled water, 77
- Distilled water, Femel apparatus, 76
- Kells still, 78
- Dizziness, 164
- Drugs, deteriorated, 160
- for absorption anesthesia, 90
- E
- Edema, 166
- Effects, postanesthetic, 165
- postoperative, 165
- prostrating, 163
- toxic, 159
- combatting of, 69
- Einhorn, 64
- Eminence, canine, lower jaw, 30
- canine, upper jaw, 19
- Endermic injection, 98
- Engstadt's method in cocain poisoning, 70
- Ether in cocain poisoning, 70
- Eucaine, 63
- Extraction of teeth, 175
- F
- Failures and ill effects, 159
- anatomical conditions, 159
- deteriorated drugs, 160
- faulty instruments, 160
- faulty technique, 160
- in extraoral pterygomandibular injection, 151
- in pterygomandibular injection, 122
- in sphenomaxillary injection, 131
- in zygomatic injection, 134
- respiratory, 69
- Fainting, 69
- Fear, 15, 162, 164
- Femel apparatus, 79
- Foramen, incisive, 26
- infraorbital, 21
- mandibular, 34
- mental, 31
- palatine, 27
- posterior superior alveolar, 23
- Foreign body, in maxillary sinus, 176
- Fossa, canine, 20, 21
- incisive, 20
- mental, 30
- semilunar, 39
- zygomatic, 22
- Fractured jaws, 175
- G
- Ganglion, otic, 51
- sphenopalatine, 44
- submaxillary, 52
- General anesthesia vs. local, 18, 168, 175, 176
- Greeley's units, 69
- H
- Habits, phylogenetic, 16, 162
- Halocain, 63
- Hubs, for syringes, 57
- I
- Ill effects in local anesthesia, 159
- Impacted teeth, 175
- Incisive injection, 138
- Infiltration anesthesia, 93
- Infraorbital injection, extraoral, 157
- intraoral, 134
- Injection, alcohol for neuralgia, 174
- buccinator, 126
- endermic, 98
- extraoral, 144
- for a number of teeth, 109
- horizontal, 110
- incisive, 138
- individual teeth, 104
- infraorbital, 134
- intraoral, 113
- mandibular, 144
- maxillary, 152
- mental, 123
- on labial and buccal side of upper jaw, 102
- on labial side of mandible, 103
- on lingual side of mandible, 104
- on lingual side of upper jaw, 103
- palatine, 139
- pterygomandibular, 113
- extraoral, 148
- sphenomaxillary, 126

Injection, subcutaneous, 98  
 tables, 140, 141, 142, 143  
 zygomatic, 132

Innervation of oral tissues, 37

Insertion of needle, preparing place for,  
 87

Instrumentarium, 54

Instruments, faulty, 160

## J

Jar for syringes, 59

Jaws, fractured, 175  
 lower, anatomy of, 29  
 resection of, 176  
 upper, anatomy of, 19  
 operations on, 175

## K

Kells, still, 78

## L

Lamp, alcohol, 60

Lesions, tissue, 165

Lewis, 169

Local anesthesia *vs.* general, 18, 168, 175,  
 176

## M

Mandible, anatomy, 29

Mandibular injection, 144

Margin, infraorbital, 21

Maxilla, anatomy, 19

anterior surface, 19

Maxillary injection, 152

nerve, 25

Medication, postanesthetic, 170

preanesthetic, 86, 176

postoperative, 170

Method of pulp anesthesia, 92

Morphia, 86

Mucous membrane, infiltration of, 96  
 preparation of, 87

## N

Nasal anesthesia, 91

Nausea, 164

Needle, breaking of, 161  
 for injection, 55  
 extraoral, 61

Needle, iridio-platinum, 56  
 steel, 56

Nerve, fibers torn, 161

motor, anesthesia of, 162

trunks entered by needle, 161

Nerves, anterior palatine, 45

anterior superior alveolar ramus, 43

auriculotemporal, 49

buccinator, 48

frontal, 39

inferior alveolar, 49

dental rami, 51

gingival rami, 51

palpebral rami, 44

infraorbital, 44

infratrochlear, 42

labial, superior, 44

lacrimal, 39

lingual, 49

mandibular, 48

maxillary, 42

mental, 51

middle palatine, 46

middle superior alveolar ramus, 43

nasal, external, 42

internal, 44

nasociliary, 40

naso-palatine, 46

ophthalmic, 39

palpebral, inferior, 44

posterior superior alveolar rami, 42

sphenopalatine, 42

superior dental plexus, 44

superior dental ramus, 44

superior gingival ramus, 44

supraorbital, 39

supratrochlear, 39

trigeminal, 38

vidian, 44

zygomatic, 42

Neuralgia, major, alcohol injection for,  
 174

trifacial, diagnosis of, 174

Novocain, history of production of, 64

## O

Operations, on jaws, 175

Operator, personality of, 17

Ophthalmic nerve, 39

- Oral cavity, anatomy of, 19  
surgery, 175
- P
- Pain, 162  
caused by original puncture, 163  
control of, 18  
nature of, 15  
postoperative, 167
- Palatine injection, 139
- Paleness, 164
- Palpitation, 163
- Papilla, palatina, 26
- Patient, apprehensive, 86  
preparation of, 85
- Patrick's formula for alcohol injection,  
174
- Pharmacology of drugs used, 62
- Phylogenetic habits, 16, 162
- Plexus, superior dental, 44
- Pluglets, procaine, 83
- Poisoning, procaine, 69
- Postanesthetic effects, 165  
medication, 170
- Postoperative medication, 170
- Practical application of local anesthesia,  
171
- Preface, 7
- Preparation of the solution, author's  
method, 81, 83; Seidel's method,  
81  
local of patient, 87  
of mucous membrane, 87  
of patient, 85  
of skin, 87
- Procaine, 65  
chemical reaction of, 65  
dosage, 66  
incompatibles, 66  
Metz, 65  
name substituted, 8  
physiological properties, 66  
pluglets, 83  
toxic properties, 66
- Procaine-suprarenin, combined, 80  
in ampules, 80  
prepared solution, 81  
Seidel's method, 81  
Tablets, author's method, 81
- Process, alveolar, of maxilla, 23  
palatal, 25  
zygomatic, 23, 24
- Psychic effects, 17
- Pterygomandibular injection, extraoral,  
148  
intraoral, 113
- Pulps, after local anesthesia, 168  
anesthesia of, 91  
inflamed, 172  
removal of, 173
- Pyorrhea alveolaris, treatment of, 174
- Q
- Quinine urea hydrochlorid, 63
- R
- Ramus of mandible, anterior surface, 37
- Removal of pulps, 173
- Requirements of a solution prepared  
from tablets, 84  
of a substitute for cocain, 63
- Resection of jaws, 176
- Respiration, artificial, 69
- Ridge, infraorbital, 21
- Ringer solution, 75  
tablets, 76
- Roth, 67
- Rules for selecting methods of local anes-  
thesia, 171
- S
- Salt solution, physiological, 75
- Seidel's method of preparing Novocain-  
suprarenin solution, 81
- Sharpening of needle, 57
- Shock, 16  
psychic, 162, 17, 164
- Sinus, maxillary, 28, 19  
operations on, 175
- Skin, infiltration anesthesia of, 96  
preparation of, 87
- Smith, syringe, 129
- Solution, for syringes, 59  
preparation of, 81, 83; author's  
method, 81  
requirements if prepared from tablets,  
84
- Solvent medium, 75



- Sphenomaxillary injection, 126  
 Still, Kells, 78  
 Subcutaneous injection, 98  
 Sulcus mandibularis, 29  
 Suprarenin-syntheticum, 71  
   chemical properties, 71  
   dosage, 74  
   incompatibles, 72  
   physiological properties, 72  
   production, 71  
   toxic properties, 73  
 Surface, anesthesia, 89  
   anterior of maxilla, 19  
     of ramus, 37  
   external of mandible, 29  
   infratemporal, 22  
   internal of mandible, 31  
 Surgery, oral, 175  
 Sweating, 163, 164  
 Syncope, 164  
   treatment of, 165  
 Syringes, for extraoral method, 60  
   for intraoral method, 54
- T
- Table for conduction anesthesia of the  
 teeth only, 142  
 for conduction anesthesia of the  
 teeth and soft tissue, 143  
 for infiltration anesthesia of the  
 teeth only, 140  
 for infiltration anesthesia of the  
 teeth and soft tissue, 141
- Table for the selection of needles, 57  
   of comparative toxicity, 67  
   of nerve supply, 52, 53  
 Tablets of Procaine-suprarenin, 81  
   E, 82  
   E F, 82  
   H, 82  
   Mixing, 82  
   Ringer, 76  
   T, 82  
 Technique, faulty, 160  
   of local anesthesia, 89  
 Teeth, extraction of, 175  
   impacted, 175  
 Tray, glass, for novocain tubes, 59  
 Treatment of syncope, 69, 164  
 Trembling, 163  
 Tropacocain, 63  
 Tuber maxillare, 23  
 Tumors, 175
- V
- Validol, 69, 165  
 Vasoconstriction, 161  
 Veronal, 86
- W
- Water, distilled, 77  
 Wisdom teeth, impacted, 175
- Z
- Zygomatic injection, 132



## BIBLIOGRAPHY

- BERGER, A., 1915. An Accident with Conductive Anesthesia. Dental Items of Interest, p. 659.
- BLUM, THEODOR, 1914. Local Anesthesia. Dental Items of Interest, p. 185.
- BLUM, THEODOR, 1917. Notes on Conductive Anesthesia. Jour. of the National Dental Association, October, p. 1097.
- BLUM, THEODOR, 1918. The Teaching of Conductive Anesthesia. Jour. of the National Dental Association, July, p. 693.
- CANNON, W. B., 1915. Bodily Changes in Pain, Hunger, Fear and Rage. Appleton & Co., New York, p. 311.
- CRILE, GEO. W., 1915. Anesthesia, Anemia and Resuscitation. Year Book of Anesthesia and Analgesia. Surgery Publishing Co., New York, p. 77.
- CRILE, GEO. W., 1915. Anoci-Association. W. B. Saunders Co., Philadelphia, Penn., p. 259.
- DUFFIELD, L. B., 1917. Novocain Anesthesia (Conductive) in Exodontia. Dental Cosmos, July, p. 709.
- EAST, B. R., 1916. Nerve Blocking. Dental Items of Interest, p. 619.
- ENGSTADT, J. E., 1916. American Journal of Surgery, January.
- ENGSTADT, J. E., 1910. Jour. of the American Medical Association, March 19.
- FERGUSON, ROBERT H., 1915. The Psychic Factors of Surgical Anesthesia. Year Book of Anesthesia and Analgesia. Surgery Publishing Co., New York, p. 152.
- FISCHER, GUIDO, 1914. Local Anesthesia in Dentistry. Dental Items of Interest, p. 547.
- HERTZLER, ARTHUR E., 1915. Local Anesthesia and After Pain. Year Book of Anesthesia and Analgesia. Surgery Publishing Co., New York, p. 338.
- HIRSCHEL, G., 1913. Local Anesthesia. Wood & Company.
- HOGAN, W. J., 1914. Local or Inhibitive Anesthesia. Dental Items of Interest, p. 452.
- HUYLER, 1918. Jour. of American Medical Association, p. 374.

- JACKMAN, W. T., 1914. High Pressure Anesthesia. *Jour. of the National Dental Association*, p. 208.
- KELLS, C. EDMUND, 1917. Novocain-Suprarenin. *Dental Items of Interest*, May, p. 321.
- LEDERER, W. J., 1915. Tooth Extraction and Local Anesthesia. *Rebman Company*, New York, p. 262.
- LEVY, J. M. and HATCHER, R. A., 1915. Observations on the Relative Toxicity of Novocain and Cocain. *Dental Items of Interest*, p. 721.
- MCMEECHAN, F. H., 1915. *American Year Book of Anesthesia and Analgesia*. Surgery Publishing Company, New York.
- MILLER, F. L., 1918. Conductive Anesthesia. *Dental Review*, June, p. 521.
- NYMAN, JOHN E., 1916. The Elimination of Pain in Dental Operations. *Jour. of the Allied Dental Societies*, p. 13.
- OTTESSEN, T., 1912. Local Anesthesia in Dental Surgery. *Jour. of the Allied Dental Societies*, p. 311.
- PATTERSON and STARLING, 1913. *Journal of Physiology*, Vol. XLVII, p. 143.
- PLATT, FRANK L., 1916. Peridental Anesthesia; Intra-Osseous Method. *Dental Items of Interest*, p. 296.
- PUTERBAUGH, P. G., 1918. Indications and Practical Application of Local Anesthesia in Dentistry. *Dental Review*, February, p. 95.
- RIETHMULLER, R. H., 1914. Further Studies of Novocain-Suprarenin Anesthesia. *Dental Cosmos*, p. 1320.
- ROTH, G. B., 1918. The Relative Toxicity of Cocain and Novocain. *Jour. of the National Dental Association*, June, p. 574.
- SHIELDS, J. S., 1918. Apothesine — The New Local Anesthetic. *Dental Cosmos*, April, p. 298.
- SILVERMAN, S. L., 1917. A Study of the Disputed Points in Local Anesthesia. *Jour. of the National Dental Association*, July, p. 718.
- SMITH, ARTHUR E., 1918. Anesthesia in Dentistry. *Dental Review*, June.
- SMITH, ARTHUR E., 1917. Local Anesthesia. *Dental Items of Interest*, June, p. 429.
- SMITH, ARTHUR E., 1918. Nerve Blocking. *Dental Review*, October, p. 803.
- SPECHT, EMIL, 1917. Novocain-Suprarenin. *Dental Items of Interest*, June, p. 401.
- STERN, LEO, 1916. A Consideration of Technique in Conductive Anesthesia. *Dental Items of Interest*, p. 721.

- STERN, LEO, 1915. Local Anesthesia in Operative Dentistry. *Dental Items of Interest*, p. 641.
- STERN, LEO, 1916. The Application of Local Anesthesia to Dentistry. *Dental Cosmos*, January, p. 13.
- THOMA, K. H., 1917. Extraoral Conductive Anesthesia for Oral Surgical Operations. *Jour. of the National Dental Association*, p. 18.
- THOMA, K. H., 1915. Intraoral and Extraoral Methods of Local Anesthesia in Dentistry. *Year Book of Anesthesia and Analgesia*. Surgery Publishing Co., New York, p. 39.
- THOMA, K. H., 1914. Local Anesthesia (Infiltration and Conductive Methods). *Jour. of the National Dental Association*, p. 202.
- THOMA, K. H., 1915. Local Anesthesia (Infiltration and Conductive Methods). *Jour. of the Allied Dental Societies*, p. 235.
- THOMA, K. H., 1913. Local Anesthesia of the Oral Cavity. *Dental Items of Interest*, p. 241.
- WATSON, L. F., 1918. Some Observations on Local Anesthesia for Certain Operative Procedures and Its Effects on Blood Pressure. *American Journal of Surgery, Anesthesia Supplement*, July, p. 88.













Accession no.

9201

Author

Thoma, K.H.

Oral anesthesia.

Call no.

ANL5 HESI

