NEUROANATOMY

through

Clinical Cases

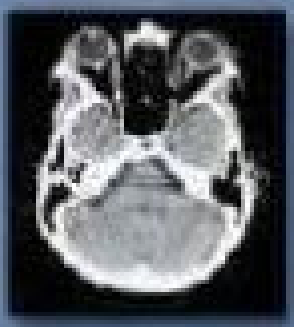

HAL BLUMENFELD, M.D., PH.D.

Note

The author and the publisher have made every effort to provide clinical information in this book that is up-to-date and accurate at the time of publication. However, diagnostic and therapeutic methods evolve continuously based on new research and clinical experience. Because medical standards are constantly changing, and because of the possibility of human error, neither the author, nor the publisher, nor any other party who has been involved in the preparation or publication of this work warrants that the information contained herein is in every respect accurate or complete, and they disclaim all responsibility for any errors or omissions, or for clinical results obtained from use of the information contained in this work. Readers are strongly encouraged to consult other sources to confirm all clinical information when caring for patients, particularly in regard to medications, doses, and contraindications, which are subject to frequent changes and improvements, or when using new or infrequently used drugs.

Neuroanatomy through Clinical Cases

Copyright © 2002 by Sinauer Associates, Inc.
All rights reserved. This book may not be reproduced in whole or in part without permission from the publisher.

For information, address Sinauer Associates, 23 Plumtree Road,
Sunderland, MA 01375 U.S.A.
FAX: 413-549-1118
E-mail: publish@sinauer.com
Internet: www.sinauer.com

Library of Congress Cataloging-in-Publication Data
Blumenfeld, Hal.
Neuroanatomy through clinical cases / Hal Blumenfeld.
p. ; cm.
Includes bibliographical references and index.
ISBN-10: 0-87893-060-4
ISBN-13: 978-0-87893-060-9
1. Neuroanatomy. 2. Neurologic examination—Case studies. I. Title.
[DNLM: 1. Nervous System Diseases—diagnosis—Case Report. 2. Nervous System—pathology—Case Report. 3. Neurologic Examination—methods—Case Report.
WL 141 B658n 2000]
QM451 .B68 2000
616.8'0475—dc21 00-058806

10 9 8 7 6

To Michelle
For your patience, encouragement, and love

Brief Contents

1 Introduction to Clinical Case Presentations 3

2 Neuroanatomy Overview and Basic Definitions 13

3 The Neurologic Exam as a Lesson in Neuroanatomy 49

4 Introduction to Clinical Neuroradiology 83

5 Brain and Environs: Cranium, Ventricles, and Meninges 121

6 Corticospinal Tract and Other Motor Pathways 213

7 Somatosensory Pathways 263

8 Spinal Nerve Roots 303

9 Major Plexuses and Peripheral Nerves 339

10 Cerebral Hemispheres and Vascular Supply 367

11 Visual System 427

12 Brainstem I: Surface Anatomy and Cranial Nerves 459

13 Brainstem II: Eye Movements and Pupillary Control 529

14 Brainstem III: Nuclei, Pathways, and Vascular Supply 575

15 Cerebellum 653

16 Basal Ganglia 689

17 Pituitary and Hypothalamus 737

18 Limbic System: Homeostasis, Olfaction, Memory, and Emotion 761

19 Higher-Order Cerebral Function 817

Epilogue: A Simple Working Model of the Mind 911

Contents

Preface xvi

How to Use This Book xix

Chapter 1 Introduction to Clinical Case Presentations 3

Introduction 4

The General History and Physical Exam 4

Chief Complaint (CC) 5

History of the Present Illness (HPI) 5

Past Medical History (PMH) 6

Review of Systems (ROS) 6

Family History (FHx) 6

Social and Environmental History (SocHx/EnvHx) 6

Medications and Allergies 6

Physical Exam 7

Laboratory Data 7

Assessment and Plan 7

Neurologic Differential Diagnosis 8

Relationship between the General Physical Exam and the Neurologic Exam 9

References 11

Chapter 2 Neuroanatomy Overview and Basic Definitions 13

Basic Macroscopic Organization of the Nervous System 14

Main Parts of the Nervous System 14

Orientation and Planes of Section 16

Basic Cellular and Neurochemical Organization of the Nervous System 17

CNS Gray Matter and White Matter; PNS Ganglia and Nerves 21

Spinal Cord and Peripheral Nervous System 22

Cerebral Cortex: Basic Organization and Primary Sensory and Motor Areas 24

Lobes of the Cerebral Hemispheres 24

Surface Anatomy of the Cerebral Hemispheres in Detail 25

Primary Sensory and Motor Areas 28

Cell Layers and Regional Classification of the Cerebral Cortex 29

Motor Systems 32

Main Motor Pathways 32

Cerebellum and Basal Ganglia 34

Somatosensory Systems 34

Main Somatosensory Pathways 34

Thalamus 35

Stretch Reflex 37

Brainstem and Cranial Nerves 38

Limbic System 41

Association Cortex 41

Blood Supply to the Brain and Spinal Cord 44

Conclusions 46

References 46

Chapter 3 The Neurologic Exam as a Lesson in Neuroanatomy 49

Overview of the Neurologic Exam 50

neuroexam.com 52

The Neurologic Exam: Examination Technique and What Is Being Tested 52

1. Mental Status 52
2. Cranial Nerves 58
3. Motor Exam 63
4. Reflexes 64
5. Coordination and Gait 68
6. Sensory Exam 70

The Neurologic Exam as a Flexible Tool 72

Coma Exam 73

General Physical Exam 73
1. Mental Status 73
2. Cranial Nerves 75
3. Sensory Exam and 4. Motor Exam 76
5. Reflexes 77
6. Coordination and Gait 78

Brain Death 78
Conversion Disorder, Malingering, and Related Disorders 78
The Screening Neurologic Exam 80
Conclusions 81
References 81

Chapter 4 Introduction to Clinical Neuroradiology 83

Introduction 84
Imaging Planes 84
Computerized Tomography 84
CT versus MRI 87
Magnetic Resonance Imaging 87
Neuroangiography 93
Functional Neuroimaging 95
Conclusions 97
NEURORADIOLOGICAL ATLAS 98
References 119

Chapter 5 Brain and Environs: Cranium, Ventricles, and Meninges 121

ANATOMICAL AND CLINICAL REVIEW 122
Cranial Vault and Meninges 122
Ventricles and Cerebrospinal Fluid 128
Blood–Brain Barrier 133
KCC 5.1 Headache 135
KCC 5.2 Intracranial Mass Lesions 137
KCC 5.3 Elevated Intracranial Pressure 137
KCC 5.4 Brain Herniation Syndromes 140
KCC 5.5 Head Trauma 142
KCC 5.6 Intracranial Hemorrhage 143
KCC 5.7 Hydrocephalus 151
KCC 5.8 Brain Tumors 152
KCC 5.9 Infectious Disorders of the Nervous System 154
KCC 5.10 Lumbar Puncture 161
KCC 5.11 Craniotomy 163
CLINICAL CASES 164
5.1 An Elderly Man with Headaches and Unsteady Gait 164
5.2 Altered Mental Status Following Head Injury 166
5.3 Delayed Unresponsiveness after Head Injury 174
5.4 Headache and Progressive Left-Sided Weakness 176
5.5 Sudden Coma and Bilateral Posturing during Intravenous Anticoagulation 180
5.6 Severe Head Injury 188
5.7 A Child with Headaches, Nausea, and Diplopia 189
5.8 Headaches and Progressive Visual Loss 196
5.9 An Elderly Man with Progressive Gait Difficulty, Cognitive Impairment, and Incontinence 199
5.10 A Young Man with Headache, Fever, Confusion, and Stiff Neck 203
Additional Cases 204
BRIEF ANATOMICAL STUDY GUIDE 205
A Scuba Expedition through the Brain 206
References 208

Chapter 6 Corticospinal Tract and Other Motor Pathways 213

ANATOMICAL AND CLINICAL REVIEW 214
Motor Cortex, Sensory Cortex, and Somatotopic Organization 214
Basic Anatomy of the Spinal Cord 216
Spinal Cord Blood Supply 219
General Organization of the Motor Systems 220
Lateral Corticospinal Tract 222
Autonomic Nervous System 228
KCC 6.1 Upper Motor Neuron versus Lower Motor Neuron Lesions 231
KCC 6.2 Terms Used to Describe Weakness 232
KCC 6.3 Weakness Patterns and Localization 232
KCC 6.4 Detecting Subtle Hemiparesis at the Bedside 239
KCC 6.5 Unsteady Gait 241

KCC 6.6 Multiple Sclerosis 241
KCC 6.7 Motor Neuron Disease 243
CLINICAL CASES 244
6.1 Sudden Onset of Right Hand Weakness 244
6.2 Sudden Onset of Left Foot Weakness 245
6.3 Sudden Onset of Right Face Weakness 249
6.4 Pure Motor Hemiparesis I 251
6.5 Pure Motor Hemiparesis II 253
6.6 Progressive Weakness, Muscle Twitching, and Cramps 256
Additional Cases 258
BRIEF ANATOMICAL STUDY GUIDE 258
References 259

Chapter 7 Somatosensory Pathways 263

ANATOMICAL AND CLINICAL REVIEW 264
Main Somatosensory Pathways 264
Posterior Column–Medial Lemniscal Pathway 267
Spinothalamic Tract and Other Anterolateral Pathways 268
Somatosensory Cortex 270
Central Modulation of Pain 270
The Thalamus 271
Relay Nuclei 273
Intralaminar Nuclei 274
Reticular Nucleus 275
KCC 7.1 Paresthesias 276
KCC 7.2 Spinal Cord Lesions 276
KCC 7.3 Sensory Loss: Patterns and Localization 277
KCC 7.4 Spinal Cord Syndromes 279
KCC 7.5 Anatomy of Bowel, Bladder, and Sexual Function 282
CLINICAL CASES 285
7.1 Sudden Onset of Right Arm Numbness 285
7.2 Sudden Onset of Right Face, Arm, and Leg Numbness 286
7.3 A Fall Causing Paraplegia and a Sensory Level 288
7.4 Left Leg Weakness and Right Leg Numbness 291
7.5 Sensory Loss over Both Shoulders 293
7.6 Body Tingling and Unsteady Gait 295
7.7 Hand Weakness, Pinprick Sensory Level, and Urinary Retention 296
Additional Cases 297
BRIEF ANATOMICAL STUDY GUIDE 297
References 300

Chapter 8 Spinal Nerve Roots 303

ANATOMICAL AND CLINICAL REVIEW 304
Segmental Organization of the Nervous System 304
Nerve Roots in Relation to Vertebral Bones, Discs, and Ligaments 305
Dermatomes and Myotomes 307
KCC 8.1 Disorders of Nerve, Muscle, and Neuromuscular Junction 311
KCC 8.2 Back Pain 314
KCC 8.3 Radiculopathy 315
Simplification: Three Nerve Roots to Remember in the Arm 317
Simplification: Three Nerve Roots to Remember in the Leg 317
KCC 8.4 Cauda Equina Syndrome 318
KCC 8.5 Common Surgical Approaches to the Spine 318
CLINICAL CASES 319
8.1 Unilateral Neck Pain and Tingling Numbness in the Thumb and Index Finger 319
8.2 Unilateral Occipital and Neck Pain 320
8.3 Unilateral Shoulder Pain and Weakness 321
8.4 Blisters, Pain, and Weakness in the Left Arm 323
8.5 Unilateral Shoulder Pain and Numbness in the Index and Middle Fingers 324
8.6 Unilateral Neck Pain, Hand Weakness, and Numbness in the Ring and Little Fingers 325
8.7 Pain and Numbness in the Medial Arm 326
8.8 Low Back Pain Radiating to the Sole of the Foot and the Small Toe 327
8.9 Unilateral Thigh Weakness with Pain Radiating to the Anterior Shin 328
8.10 Low Back Pain Radiating to the Big Toe 329
8.11 Saddle Anesthesia with Loss of Sphincteric and Erectile Function 332
Additional Cases 335
BRIEF ANATOMICAL STUDY GUIDE 335
References 336

Chapter 9 Major Plexuses and Peripheral Nerves 339

ANATOMICAL AND CLINICAL REVIEW 340
Brachial Plexus and Lumbosacral Plexus 340
Simplification: Five Nerves to Remember in the Arm 342
Simplification: Three Nerves Acting on the Thumb 344
Intrinsic and Extrinsic Hand Muscles 344
Simplification: Five Nerves to Remember in the Leg 345
KCC 9.1 Common Plexus and Nerve Syndromes 346
KCC 9.2 Electromyography (EMG) and Nerve Conduction Studies 349
CLINICAL CASES 351
9.1 Complete Paralysis and Loss of Sensation in One Arm 351
9.2 A Newborn with Weakness in One Arm 353
9.3 A Blow to the Medial Arm Causing Hand Weakness and Numbness 353
9.4 Nocturnal Pain and Tingling in the Thumb, Pointer, and Middle Finger 355
9.5 Hand and Wrist Weakness after a Fall 355
9.6 Numbness and Tingling in the Pinky and Ring Finger 356
9.7 Unilateral Thigh Pain, Weakness, and Numbness in a Diabetic 357
9.8 Tingling and Paralysis of the Foot after a Fall 358
9.9 A Leg Injury Resulting in Foot Drop 359
9.10 Lateral Thigh Pain and Numbness after Pregnancy 361
9.11 Dysarthria, Ptosis, and Decreased Exercise Tolerance 362
Additional Cases 363
BRIEF ANATOMICAL STUDY GUIDE 363
References 363

Chapter 10 Cerebral Hemispheres and Vascular Supply 367

ANATOMICAL AND CLINICAL REVIEW 368
Review of Main Functional Areas of Cerebral Cortex 368
Circle of Willis: Anterior and Posterior Circulations 369
Anatomy and Vascular Territories of the Three Main Cerebral Arteries 371
Vascular Territories of the Superficial Cerebral Structures 371
Vascular Territories of the Deep Cerebral Structures 373
KCC 10.1 Clinical Syndromes of the Three Main Cerebral Arteries 376
KCC 10.2 Watershed Infarcts 378
KCC 10.3 Transient Ischemic Attack and Other Transient Neurologic Episodes 379
KCC 10.4 Ischemic Stroke: Mechanisms and Treatment 380
KCC 10.5 Carotid Stenosis 384
KCC 10.6 Dissection of the Carotid or Vertebral Arteries 385
Venous Drainage of the Cerebral Hemispheres 386
KCC 10.7 Sagittal Sinus Thrombosis 387
CLINICAL CASES 388
10.1 Sudden-Onset Worst Headache of Life 388
10.2 Left Leg Weakness and Left Alien Hand Syndrome 389
10.3 Decreased Vision on One Side 390
10.4 Transient Episodes of Left Eye Blurriness or Right Hand Weakness 398
10.5 Nonfluent Aphasia with Right Face and Arm Weakness 399
10.6 Talking Ragtime 403
10.7 Dysarthria and Hemiparesis 404
10.8 Global Aphasia, Right Hemiplegia, and Hemianopia 405
10.9 Left Face and Arm Weakness 408
10.10 Left Hemineglect 411
10.11 Left Hemineglect, Hemiplegia, and Hemianopia 413
10.12 Unilateral Proximal Arm and Leg Weakness 415
10.13 Right Frontal Headache and Left Arm Numbness in a Woman with Gastric Carcinoma 419
Additional Cases 421
BRIEF ANATOMICAL STUDY GUIDE 421
References 424

Chapter 11 Visual System 427

ANATOMICAL AND CLINICAL REVIEW 428
Eyes and Retina 428
Optic Nerves, Optic Chiasm, and Optic Tracts 431
Lateral Geniculate Nucleus and Extrageniculate Pathways 432
Optic Radiations to Primary Visual Cortex 433
Visual Processing in the Neocortex 435
Parallel Channels for Analyzing Motion, Form, and Color 435
Ocular Dominance Columns and Orientation Columns 437
KCC 11.1 Assessment of Visual Disturbances 438
KCC 11.2 Localization of Visual Field Defects 440
KCC 11.3 Blood Supply and Ischemia in the Visual Pathways 443
KCC 11.4 Optic Neuritis 445
CLINICAL CASES 446
11.1 A Dark Spot Seen with One Eye 446
11.2 Vision Loss in One Eye 447
11.3 Menstrual Irregularity and Bitemporal Hemianopia 448
11.4 Hemianopia after Treatment for a Temporal Lobe Tumor 449
11.5 Visual Changes Caused by Migraine Headaches? 451
Additional Cases 453
BRIEF ANATOMICAL STUDY GUIDE 453
References 456

Chapter 12 Brainstem I: Surface Anatomy and Cranial Nerves 459

ANATOMICAL AND CLINICAL REVIEW 460
Surface Features of the Brainstem 461
Skull Foramina and Cranial Nerve Exit Points 464
Sensory and Motor Organization of the Cranial Nerves 466
Functions and Course of the Cranial Nerves 469
CN I: Olfactory Nerve 471
KCC 12.1 Anosmia (CN I) 472
CN II: Optic Nerve 472
CN III, IV, and VI: Oculomotor, Trochlear, and Abducens Nerves 472
CN V: Trigeminal Nerve 474
KCC 12.2 Trigeminal Nerve Disorders (CN V) 478
CN VII: Facial Nerve 479
KCC 12.3 Facial Nerve Lesions (CN VII) 482
KCC 12.4 Corneal Reflex and Jaw Jerk Reflex (CN V, VII) 484
CN VIII: Vestibulocochlear Nerve 484
Auditory Pathways 485
Vestibular Pathways 489
KCC 12.5 Hearing Loss (CN VIII) 491
KCC 12.6 Dizziness and Vertigo (CN VIII) 492
CN IX: Glossopharyngeal Nerve 495
CN X: Vagus Nerve 496
CN XI: Spinal Accessory Nerve 499
CN XII: Hypoglossal Nerve 499
KCC 12.7 Disorders of CN IX, X, XI, and XII 500
KCC 12.8 Hoarseness, Dysarthria, Dysphagia, and Pseudobulbar Affect 500
Review: Cranial Nerve Combinations 502
CLINICAL CASES 504
12.1 Anosmia and Visual Impairment 504
12.2 Cheek Numbness and a Bulging Eye 505
12.3 Jaw Numbness and Episodes of Loss of Consciousness 508
12.4 Isolated Facial Weakness 509
12.5 Hearing Loss and Dizziness 512
12.6 Hoarse Voice Following Cervical Disc Surgery 516
12.7 Hoarseness, with Unilateral Wasting of the Neck and Tongue Muscles 517
12.8 Uncontrollable Laughter, Dysarthria, Dysphagia, and Left-Sided Weakness 521
Additional Cases 522
BRIEF ANATOMICAL STUDY GUIDE 523
References 526

Chapter 13 Brainstem II: Eye Movements and Pupillary Control 529

ANATOMICAL AND CLINICAL REVIEW 530
Extraocular Muscles, Nerves, and Nuclei 530
Extraocular Muscles 530
Extraocular Nerves and Nuclei 532
KCC 13.1 Diplopia 535
KCC 13.2 Oculomotor Palsy (CN III) 536
KCC 13.3 Trochlear Palsy (CN IV) 538
KCC 13.4 Abducens Palsy (CN VI) 539
The Pupils and Other Ocular Autonomic Pathways 540
KCC 13.5 Pupillary Abnormalities 543
KCC 13.6 Ptosis 546
Cavernous Sinus and Orbital Apex 546
KCC 13.7 Cavernous Sinus Syndrome (CN III, IV, VI, V_1) and Orbital Apex Syndrome (CN II, III, IV, VI, V_1) 547
Supranuclear Control of Eye Movements 548
Brainstem Circuits for Horizontal Eye Movements 548
KCC 13.8 Brainstem Lesions Affecting Horizontal Gaze 549
KCC 13.9 Parinaud's Syndrome 551
KCC 13.10 Right-Way Eyes and Wrong-Way Eyes 552
CLINICAL CASES 554
13.1 Double Vision and Unilateral Eye Pain 554
13.2 A Diabetic with Horizontal Diplopia 555
13.3 Vertical Diplopia 557
13.4 Left Eye Pain and Horizontal Diplopia 558
13.5 Unilateral Headache, Ophthalmoplegia, and Forehead Numbness 559
13.6 Ptosis, Miosis, and Anhidrosis 560
13.7 Wrong-Way Eyes 562
13.8 Horizontal Diplopia in a Patient with Multiple Sclerosis 563
13.9 Headaches and Impaired Upgaze 567
Additional Cases 568
BRIEF ANATOMICAL STUDY GUIDE 568
References 572

Chapter 14 Brainstem III: Internal Structures and Vascular Supply 575

ANATOMICAL AND CLINICAL REVIEW 576
Main Components of the Brainstem 576
Brainstem Sections 577
Cranial Nerve Nuclei and Related Structures 584
Long Tracts 586
KCC 14.1 Locked-in Syndrome 587
Cerebellar Circuitry 587
Reticular Formation and Related Structures 588
Widespread Projection Systems of Brainstem and Forebrain: Consciousness, Attention, and Other Functions 589
Brainstem Reticular Formation and Thalamus 590
Identified Neurotransmitter Systems 592
Anatomy of the Sleep–Wake Cycle 598
KCC 14.2 Coma and Related Disorders 601
Reticular Formation Motor, Reflex, and Autonomic Systems 605
Brainstem Vascular Supply 607
KCC 14.3 Vertebrobasilar Vascular Disease 612
CLINICAL CASES 620
14.1 Face and Contralateral Body Numbness, Hoarseness, Horner's Syndrome, and Ataxia 620
14.2 Hemiparesis Sparing the Face 622
14.3 Dysarthria and Hemiparesis 626
14.4 Unilateral Face Numbness, Hearing Loss, and Ataxia 626
14.5 Locked In 629
14.6 Wrong-Way Eyes, Limited Upgaze, Decreased Responsiveness, and Hemiparesis with an Amazing Recovery 632
14.7 Diplopia and Unilateral Ataxia 639
14.8 Intermittent Memory Loss, Diplopia, Sparkling Lights, and Somnolence 641
14.9 Intractable Hiccups 644
Additional Cases 645
BRIEF ANATOMICAL STUDY GUIDE 649
References 650

Chapter 15 Cerebellum 653

ANATOMICAL AND CLINICAL REVIEW 654
Cerebellar Lobes, Peduncles, and Deep Nuclei 654
Microscopic Circuitry of the Cerebellum 658
Cerebellar Output Pathways 660
Cerebellar Input Pathways 664
Vascular Supply to the Cerebellum 668
KCC 15.1 Cerebellar Artery Infarcts and Cerebellar Hemorrhage 669
KCC 15.2 Clinical Findings and Localization of Cerebellar Lesions 670
KCC 15.3 Differential Diagnosis of Ataxia 675
CLINICAL CASES 676
15.1 Sudden Onset of Unilateral Ataxia 676
15.2 Walking Like a Drunkard 677
15.3 A Boy with Headaches, Nausea, Slurred Speech, and Ataxia 680
15.4 Nausea, Progressive Unilateral Ataxia, and Right Face Numbness 682
Additional Cases 686
BRIEF ANATOMICAL STUDY GUIDE 686
References 687

Chapter 16 Basal Ganglia 689

ANATOMICAL AND CLINICAL REVIEW 690
Basic Three-Dimensional Anatomy of the Basal Ganglia 690
Input, Output, and Intrinsic Connections of the Basal Ganglia 698
Inputs to the Basal Ganglia 698
Outputs from the Basal Ganglia 699
Intrinsic Basal Ganglia Connections 699
Hyperkinetic and Hypokinetic Movement Disorders 701
Parallel Basal Ganglia Pathways for Movement, Eye Movement, Cognition, and Emotion 702
Ansa Lenticularis, Lenticular Fasciculus, and the Fields of Forel 704
KCC 16.1 Movement Disorders 705
KCC 16.2 Parkinson's Disease and Related Disorders 712
KCC 16.3 Huntington's Disease 716
KCC 16.4 Stereotactic Surgery for Movement Disorders and Other Conditions 717
CLINICAL CASES 719
16.1 Unilateral Flapping and Flinging 719
16.2 Irregular Jerking Movements and Marital Problems 720
16.3 Asymmetrical Resting Tremor, Rigidity, Bradykinesia, and Gait Difficulties 723
16.4 Bilateral Bradykinesia, Rigidity, and Gait Instability with No Tremor 726
BRIEF ANATOMICAL STUDY GUIDE 732
Additional Cases 733
References 733

Chapter 17 Pituitary and Hypothalamus 737

ANATOMICAL AND CLINICAL REVIEW 738
Overall Anatomy of the Pituitary and Hypothalamus 738
Important Hypothalamic Nuclei and Pathways 740
Major Hypothalamic Nuclei 740
Hypothalamic Control of the Autonomic Nervous System 741
Hypothalamic–Limbic Pathways 742
Other Regionalized Functions of the Hypothalamus 742
Endocrine Functions of the Pituitary and Hypothalamus 743
KCC 17.1 Pituitary Adenoma and Related Disorders 746
KCC 17.2 Diabetes Insipidus and SIADH 749
KCC 17.3 Panhypopituitarism 750
CLINICAL CASES 751
17.1 Moon Facies, Acne, Amenorrhea, and Hypertension 751
17.2 Impotence, Anorexia, Polyuria, Blurred Vision, Headaches, and Hearing Loss 754
Additional Cases 756
BRIEF ANATOMICAL STUDY GUIDE 757
References 759

Chapter 18 Limbic System: Homeostasis, Olfaction, Memory, and Emotion 761

ANATOMICAL AND CLINICAL REVIEW 762
Overview of Limbic Structures 763
Olfactory System 770
Hippocampal Formation and Other Memory-Related Structures 771
Hippocampal Formation and Parahippocampal Gyrus 772
Intrinsic Circuitry of the Hippocampal Formation 776
Input and Output Connections of the Medial Temporal Lobe Memory System 777
The Fornix and Medial Diencephalic Memory Pathways 778
KCC 18.1 Memory Disorders 780
The Amygdala: Emotions, Drives, and Other Functions 787
Other Limbic Pathways 789
KCC 18.2 Seizures and Epilepsy 790
KCC 18.3 Anatomical and Neuropharmacological Basis of Psychiatric Disorders 798
CLINICAL CASES 800
Case 18.1 Sudden Memory Loss after a Mild Head Injury 800
Case 18.2 Progressive Severe Memory Loss, with Mild Confabulation 802
Case 18.3 Transient Diplopia, Lethargy, and Hemiparesis, Followed by a Sustained Memory Deficit 804
Case 18.4 Episodes of Panic, Olfactory Hallucinations, and Loss of Awareness 806
Case 18.5 Episodes of Staring, Lip Smacking, and Unilateral Semipurposeful Movements 809
BRIEF ANATOMICAL STUDY GUIDE 816
Additional Cases 817
References 817

Chapter 19 Higher-Order Cerebral Function 821

ANATOMICAL AND CLINICAL REVIEW 822
KCC 19.1 The Mental Status Exam 822
Unimodal and Heteromodal Association Cortex 823
Principles of Cerebral Localization and Lateralization 825
The Dominant Hemisphere: Language Processing and Related Functions 827
KCC 19.2 Differential Diagnosis of Language Disorders 829
KCC 19.3 Bedside Language Exam 830
KCC 19.4 Broca's Aphasia 831
KCC 19.5 Wernicke's Aphasia 832
KCC 19.6 Simplified Aphasia Classification Scheme 833
KCC 19.7 Other Syndromes Related to Aphasia 835
KCC 19.8 Disconnection Syndromes 838
The Nondominant Hemisphere: Mechanisms of Attention and Spatial Processing 839
Lateralized Aspects of Attention 839
Spatial Analysis and Integration 840
KCC 19.9 Hemineglect Syndrome 841
KCC 19.10 Other Clinical Features of Nondominant Hemisphere Lesions 846
The Frontal Lobes: Anatomy and Functions of an Enigmatic Brain Region 847
Regional Anatomy of the Frontal Lobes 847
Connections of the Prefrontal Cortex 848
Functions of the Frontal Lobes 849
KCC 19.11 Frontal Lobe Disorders 850
Visual Association Cortex: Higher-Order Visual Processing 854
KCC 19.12 Disorders of Higher-Order Visual Processing 855
KCC 19.13 Auditory Hallucinations 858
Attention, Awareness, and Other General Network Functions of The Brain 859
General Mechanisms of Attention 859
Awareness of Self and Environment 862
KCC 19.14 Attentional Disorders 864
KCC 19.15 Delirium and Other Acute Mental Status Disorders 865
KCC 19.16 Dementia and Other Chronic Mental Status Disorders 868
CLINICAL CASES 876
19.1 Acute Severe Aphasia, with Improvement 876
19.2 Nonsensical Speech 879

19.3 Aphasia with Preserved Repetition 881
19.4 Impaired Repetition 882
19.5 Inability to Read, with Preserved Writing Skills 883
19.6 Left Hemineglect 888
19.7 Abulia 891
19.8 Blindness without Awareness of Deficit 894
19.9 Sudden Inability to Recognize Faces 898
19.10 Musical Hallucinations 899
19.11 Progressive Dementia, Beginning with Memory Problems 901
Additional Cases 902
BRIEF ANATOMICAL STUDY GUIDE 904
References 906

Epilogue: A Simple Working Model of the Mind 911

CASE INDEX 915
SUBJECT INDEX 924

Preface

Neuroanatomy is a living, dynamic field that can bring both intellectual delight and aesthetic pleasure to students at all levels. However, by nature, it is also an exceedingly detailed subject, and herein lies the tragic pitfall of all too many neuroanatomy courses. Crushing amounts of memorization are often required of students of neuroanatomy, leaving them little time to step back and gain an appreciation of the structural and functional beauty of the nervous system and its relevance to clinical practice.

This book has a different point of view: instead of making the mastery of anatomical details the main goal and then searching for applications of this knowledge, actual clinical cases are used as both a teaching instrument and motivating force to encourage students to delve into further study of normal anatomy and function. Through this approach, structural details take on immediate relevance as they are being learned. In addition, each clinical case is an ideal way to integrate knowledge of disparate functional systems, since a single lesion may affect several different neural structures and pathways.

Over 100 clinical cases, accompanied by neuroradiological images, are presented in this text, and I am grateful to many neurologists, neurosurgeons, and neuroradiologists at the Harvard, Yale, and Columbia medical schools for helping me to amass enough material to present clinically relevant discussions of the entire nervous system. I have used this book's diagnostic method to teach neuroanatomy at these medical schools, and both students and faculty greeted the innovation enthusiastically. I now hope that students and faculty at many more institutions will benefit from *Neuroanatomy through Clinical Cases*, and will find it to be an enjoyable and effective way to learn neuroanatomy and its real-life applications.

Acknowledgments

First and foremost, I must thank my wife Michelle, and our children Eva and Jesse, for their enthusiasm and support throughout the writing and publication of this book.

This project has spanned a number of years, and stints at several academic centers, so there is a formidable list of people who I must thank for their important contributions. This book was conceived while I was teaching neuroanatomy as an M.D., Ph.D. student at Columbia Medical School, where I was inspired by my teachers Eric Kandel, Jack Martin, and Steven Siegelbaum. They have remained invaluable sources of inspiration and advice ever since. I would also like to thank the following individuals who served as mentors, benefactors, or role models during my training as a neurologist and neuroscientist: Raymond D. Adams, Bernard Cohen, C. Miller Fisher, Jack Haimovic, Walter Koroshetz, Terry Krulwich, Elan Louis, Stephan Mayer, David McCormick, Thomas McMahon, Timothy Pedley, Pasko Rakic, Susan Spencer, Dennis Spencer, Stephen Waxman, Anne Young, and George Zubal. I would also like to offer special thanks to those who were my closest colleagues and friends during my neurology residency: Jang-Ho Cha, Mitchell Elkind, Martha Herbert, David Jacoby, Michael Lin, Guy Rordorff, Diana Rosas, and Gerald So.

The focus and main strength of this book is its clinical cases. Therefore, I am very grateful to the many colleagues who suggested the clinical cases used in this book: Robert Ackerman, Claudia Baldassano, Tracy Batchelor, Flint Beal, Carsten Bonneman, Lawrence Borges, Robert Brown, Jeffrey Bruce, Brad Buchbinder, Ferdinando Buonanno, William Butler, Steve Cannon, David Caplan, Robert Carter, Verne Caviness, Jang-Ho Cha, Paul Chapman, Chinfei Chen, Keith Chiappa, In Sup Choi, Andrew Cole, Douglas Cole, G. Rees Cosgrove, Steven Cramer, Didier Cros, Merit Cudkowicz, Kenneth Davis, Rajiv Desai, Elizabeth Dooling, Brad Duckrow, Mitchell Elkind, Emad Eskandar, Stephen Fink, Seth Finkelstein, Alice Flaherty, Robert Friedlander, David Frim, Zoher Ghogawala, Michael Goldrich, Jonathan Goldstein, R. Gilberto Gonzalez, Kimberly Goslin, Steven Greenberg, John Growdon, Andrea Halliday, E. Tessa Hedley-Whyte, Martha Herbert, Daniel Hoch, Fred Hochberg, J. Maurice Hourihane, Brad Hyman, Michael Irizarry, David Jacoby, William Johnson, Raymond Kelleher, Philip Kistler, Walter Koroshetz, Sandra Kostyk, Kalpathy Krishnamoorthy, James Lehrich, Simmons Lessell, Michael Lev, Susan Levy, Michael Lin, Elan Louis, David Louis, Jean Lud-Cadet, David Margolin, Richard Mattson, Stephan Mayer, James Miller, Shawn Murphy, Brad Navia, Steven Novella, Edward Novotny, Christopher Ogilvy, Robert Ojemann, Michael Panzara, Dante Pappano, Stephen Parker, Marie Pasinski, John Penney, Bruce Price, Peter Riskind, Guy Rordorff, Diana Rosas, Tally Sagie, Pamela Schaefer, Jeremy Schmahmann, Lee Schwamm, Michael Schwarzschild, Saad Shafqat, Barbara Shapiro, Aneesh Singhal, Michael Sisti, Gerald So, Robert Solomon, Marcio Sotero, Dennis Spencer, Susan Spencer, John Stakes, Marion Stein, Divya Subramanian-Khurana, Brooke Swearingen, Max Takeoka, Thomas Tatemichi, Fran Testa, James Thompson, Mark Tramo, Jean Paul Vonsattel, Shirley Wray, Anne Young, and Nicholas Zervas.

I am deeply indebted to the many individuals who provided critical reviews of one or more chapters, greatly enhancing the accuracy and clarity of the material in this book: Raymond D. Adams, Joshua Auerbach, William W. Blessing, Laura Blumenfeld, William Boonn, Lawrence Borges, Michelle Brody, Richard Bronen, Joshua Brumberg, Thomas N. Byrne, Mark Cabelin, Jang-Ho Cha, Jaehyuk Choi, Charles Conrad, Rees Cosgrove, Merit Cudkowicz, Mitchell Elkind, C. M. Fisher, David Frim, Darren R. Gitelman, Jonathan Goldstein, Gil Gonzalez, Charles Greer, Stephan Heckers, Tamas Horvath, Gregory Huth, Michael Irizarry, Joshua P. Klein, Igor Koralnick, John Krakauer, Matthew Kroh, Robert H. LaMotte, John Langfitt, Steven B. Leder, Elliot Lerner, Grant Liu, Andres Martin, John H. Martin, Ian McDonald, Lyle Mitzner, Hrachya Nersesyan, Andrew Norden, Robert Ojemann, Stephen Parker, Huned Patwa, Howard Pomeranz, Bruce Price, Anna Roe, David Ross, Jeremy Schmahmann, Mark Schwartz, Ted Schwartz, Michael Schwarzschild, Barbara Shapiro, Scott Small, Arien Smith, Adam Sorscher, Susan Spencer, Stephen M. Strittmatter, Larry Squire, Mircea Steriade, Ethan Taub, Timothy Vollmer, and Steven U. Walkley. I express my gratitude for their helpful suggestions, but accept full responsibility for any errors in this text.

Marty Wonsiewicz, John Dolan, Greg Huth, John Butler, and Amanda Suver were helpful in the early stages of editorial development of this book. Michael Schlosser and Tasha Tanhehco helped gather the references, and Jason Freeman and Susan Vanderhill helped obtain copyright permissions.

Wendy Beck and BlackSheep Marketing designed and implemented the neuroexam.com website. The video segments for neuroexam.com and *The NeuroExam Video* were filmed by Douglas Forbush and Patrick Leone at Yale, and edited by Evan Jones of RBY Video. Milena Pavlova provided helpful suggestions, and played the role of the patient.

Finally, I thank the entire staff at Sinauer Associates for their tremendously helpful collaboration in all stages of producing this book. I have enjoyed working with, and am especially grateful to, Andrew D. Sinauer, Peter Farley, Kerry Falvey, Christopher Small, and Jefferson Johnson, but I extend my deep appreciation to all other members of the Sinauer staff as well. It is a pleasure to work with people who truly care about creating a fine book.

How to Use This Book

The goal of this book is to provide a treatment of neuroanatomy that is comprehensive, yet enables students to focus on the most important "take-home messages" for each topic. This goal is motivated by the recognition that, while access to detailed information is often useful in mastering neuroanatomy, certain selected pieces of information carry the most clinical relevance, or are most important for exam review.

General Outline

The first four chapters of the book contain introductory material that will be especially useful to students who have little previous clinical background. Chapter 1 is an introduction to the standard format commonly used for presenting clinical cases, including an outline of the medical history, physical examination, neuroanatomical localization, and differential diagnosis. Chapter 2 is a brief overview of neuroanatomy which includes definitions and descriptions of basic structures that will be studied in greater detail in later chapters. Chapter 3 builds on this knowledge by describing the neurologic examination. It includes a summary of the structures and pathways tested in each part of the exam, which is essential for localizing the lesions presented in the clinical cases throughout the remainder of the book. Much of the material in this chapter is also covered on the neuroexam.com website described below, which provides video demonstrations for each part of the exam. For readers who are unfamiliar with neuroimaging techniques, Chapter 4 contains a concise introduction to CT, MRI, and other imaging methods. This chapter also includes a Neuroradiological Atlas showing normal CT, MRI, and angiographic images of the brain. Chapters 5–19 cover the major neuroanatomical systems and present relevant clinical cases.

Chapters 5–19

Chapters 5–19 have a common structure. An "Anatomical and Clinical Review" at the beginning of the chapters presents relevant neuroanatomical structures and pathways, and generously sized, carefully labeled color illustrations are used to vividly depict spatial relationships. The first part of each chapter also includes numbered sections called "Key Clinical Concept," or "KCC," which cover common disorders of the system being discussed.

Clinical Cases. The second part of each chapter is a "Clinical Cases" section that describes patients seen by the author and colleagues, each presented in a numbered color box. Full-length cases include complete findings from the neurologic examination, while "Minicases" have a briefer format. Each case begins with a narrative of how the patient's symptoms developed and what deficits were found on neurologic examination. For example, one patient in Chapter 10 suddenly developed weakness in the right hand and lost the ability to speak. Another, in Chapter 14, experienced double vision and lapsed into a coma. Important symptoms and signs are indicated in boldface type. The reader is then challenged through a series of questions to deduce the neuroanatomical location of the patient's lesion and the eventual diagnosis.

A discussion follows each case, beginning with a summary of the key symptoms and signs. Answers to the questions are provided which refer to anatomical and clinical material presented in the first half of the chapter that is demonstrated by the case. Continual improvements in imaging technology have allowed us to make clear and detailed radiographs of the nervous system *in vivo*, and one of the most exciting features of the book is the inclusion of large-format, labeled CT, MRI, or other scans that show the lesion for each patient, and serve as a central tool for teaching neuroanatomy. These images reveal, with striking clarity, both the lesion's location and the anatomy of the system being studied. In addition, these radiographs help the reader develop skill in interpreting the kinds of diagnostic images employed on the wards. The neuroimaging studies for each case are provided in special boxes at least one page turn away from the case questions, so the answers to the questions are not "given away" by the imaging (see below).

The clinical course is also provided for each patient, and includes a discussion of how the patient was managed, and what outcome followed. Thus, by the end of each case, students learn the relevant material by application and diagnostic sleuthing rather than by rote memorization.

Special Features for Focused Study and Review

Since one of the goals of this book is to enable students to either read the material in depth, or to distill it down to the most clinically relevant points or to material most commonly covered on the national boards or other examinations, several special features have been included to expedite focused study and review:

- **Boldface type** is used rather differently than in most texts. In addition to identifying the text for all important topics and definitions, boldface is also used to facilitate rapid or focused reading.

REVIEW EXERCISE

- **Review Exercises** appear in the margins throughout the text, highlighting the most important anatomical concepts in each chapter, and providing practice exam questions.

MNEMONIC

- Helpful **mnemonics** are provided throughout the text, and these are flagged in the margins by a special icon (shown at left) showing a section of the hippocampus (a structure important in memory formation).
- A **Brief Anatomical Study Guide** appears at the end of each chapter, which summarizes the most important neuroanatomical material, and refers to the appropriate figures and tables needed for focused exam review.

- The **Neuroradiological Atlas** in Chapter 4 also provides a useful review of neuroanatomical structures in three-dimensional space, and can be used for reference and comparison to lesions seen in clinical cases.
- The **neuroexam.com** website includes much of the text from Chapter 3 describing the neurologic exam and its anatomical interpretation, and also features video demonstrations of each part of the exam that are cited in the text (e.g., "see neuroexam.com Video 37"). Selected video frames are also shown in the book margins, as shown at right, to illustrate relevant portions of the neurologic exam. Students or instructors who prefer to view a full-length VHS tape of the neurologic exam can obtain *The NeuroExam Video* from Sinauer Associates (www.sinauer.com).

Rapid hand movements

KEY CLINICAL CONCEPT

- The **Key Clinical Concept** (KCC) sections provide a comprehensive introduction to clinical topics in neurology and neurosurgery, and enable an efficient review of these topics.
- Finally, the **Clinical Cases** can be used by themselves for study and review, since they consist of anatomical puzzles that reinforce the subject matter for each chapter in the most clinically relevant context. As noted above, the neuroimaging studies for each case are deliberately placed at least one page turn away from the case questions; the location of the images for each case are indicated by page numbers located within black arrows, as shown at right.

2-56

- The **Additional Cases** section at the end of each chapter, and the **Case Index** at the end of the book provide further cases relevant to the topics in each chapter.

Suggested Course Use

Neuroanatomy through Clinical Cases is intended primarily for first- or second-year medical students enrolled in a course in neuroanatomy or neuroscience, but it is a versatile text that could be used in many settings.

The topics covered in the book include all neuroanatomical material required for the medical school board examinations. Although fundamental concepts are emphasized, some advanced subject matter is also provided. Because the book includes chapters on peripheral nerves, students will also find this book useful in their general gross anatomy course in which peripheral nerves are usually covered. The Key Clinical Concept sections in this book also cover the major neurologic and neurosurgical disorders at a level appropriate for medical school pathophysiology courses, clinical rotations, and residents early in their training.

Students of other health professions, especially physical therapy, occupational therapy, nursing, dentistry, speech therapy, and neuropsychology will find this textbook useful as well, and it may also be of interest to graduate students of neuroscience. In addition to those learning neuroanatomy, it is hoped that the cases in this book will serve as a resource for advanced medical students in their clinical rotations, and residents in neurology, neurosurgery, and neuroradiology seeking examples of "typical" cases of neurologic disorders. Because each case is a real patient, the clinical cases in this book are, in effect, a collection of case reports that can serve as a useful resource, especially for teaching purposes and board review. It should be noted, however, that the cases presented here are highly selected for their teaching value and do not constitute an unbiased sampling of the kinds of cases found in clinical practice.

Here are some suggestions for using *Neuroanatomy through Clinical Cases* in various courses and curricula:

- For a comprehensive course in **medical school neuroanatomy,** students should read Chapters 2 and 5–18, with selected topics from Chapters 1, 3, 4 and 19. Reading assignments and large class lectures could focus on the Anatomical and Clinical Review sections at the beginning of each chapter. The clinical cases are most effectively discussed in small groups of students, where instructors can help students puzzle through the anatomical localization and diagnosis, and then discuss the neuroradiology and clinical outcome.
- For medical school courses covering both neuroanatomy and other topics in **neuroscience,** additional readings from neuroscience texts such as *Neuroscience* by Purves et al. (2001, Sinauer Associates) or *Principles of Neural Science* by Kandel et al. (2000, McGraw-Hill) should be provided.
- For a comprehensive course in **clinical disorders of the nervous system,** students should read Chapters 3 and 4, and the Key Clinical Concept sections in Chapters 5–19. *The NeuroExam Video* should be viewed in class, and students referred to neuroexam.com for review. Clinical cases could then be presented in small groups, as described above.
- For a course focusing on **neuropsychological disorders** and anatomical correlations, students should read Chapters 2, 10, 18 and 19 and selected parts of Chapters 14 and 16.
- Finally, for a more **basic course in clinical neuroanatomy,** readings could be confined to selected topics in Chapters 2, 5–7, 10–16, and 18.

CHAPTER 1

Introduction to Clinical Case Presentations

Introduction
The General History and Physical Exam
- Chief Complaint
- History of the Present Illness
- Past Medical History
- Review of Systems
- Family History
- Social and Environmental History
- Medications and Allergies
- Physical Exam
- Laboratory Data
- Assessment and Plan

Neurologic Differential Diagnosis
Relationship between the General Physical Exam and the Neurologic Exam

Case presentations provide the framework for all communications about patient care. They lay down the basic information needed to formulate hypotheses about the location and nature of patients' problems. This information is then used to decide on further diagnostic tests or treatment measures. To diagnose and treat patients such as those described in this book, we must first learn how clinicians generally present a patient's medical history and findings from their physical examination. In addition, we must learn how to formulate ideas about neurologic diagnosis, and how the neurologic evaluation fits into the general context of patient assessment.

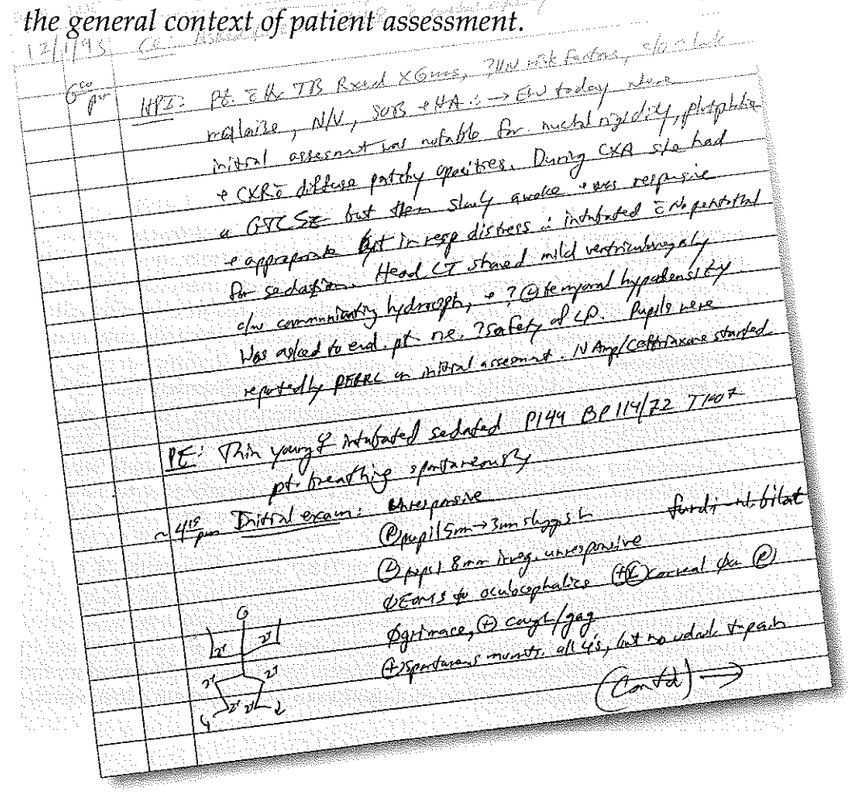

Introduction

Neuroanatomy is one of the more clinically relevant courses taught in the first years of medical school. Principles learned in neuroanatomy are directly applicable to patient care, not just for the neurologist or neurosurgeon, but also for health care professionals in virtually every other field. However, medical students in their first years and other students of neuroanatomy are often unfamiliar with the basic principles of clinical case presentations used on the wards. Therefore, the first section of this chapter has been provided for the *nonclinician* or the *not-yet-clinician* as a brief orientation. Others may prefer to skip this section. The second section of this chapter discusses the neurologic differential diagnosis, a process through which several possible diagnoses are considered based on the available information. We will use this method when attempting to arrive at diagnoses in the cases throughout the remainder of the book.

Abbreviations will be avoided in the case presentations in this book whenever possible, although in reality they are used quite often on the wards. Therefore, some commonly used abbreviations will be introduced in this chapter.

The neurologic exam is only one part of the general physical exam. Nevertheless, the patient should always be treated as a whole and, in addition, much can be learned about neurologic illness from other parts of the physical exam. Therefore, in the final section of this chapter we will discuss the dynamic relationship between the general physical exam and the neurologic exam.

The General History and Physical Exam

While there are variations in personal style, clinicians adhere to a fairly standard format when presenting cases so that all of the essential information can be succinctly communicated. Since this may be your first exposure to this format, we will first discuss the general structure of the history and physical examination that is used in all fields of medicine. Although the basic structure is always the same, the emphasis varies depending on the specialty. Therefore, in Chapter 3 we discuss the neurologic part of the physical exam in more detail. Note that case presentations in this book focus on the neurologic history and physical exam, although it is crucial to treat the patient as a whole and to never neglect symptoms and signs arising from other body systems. In addition, as described in the discussion that follows, certain features of the general physical exam often provide important information about neurologic illness.

One of the most daunting tasks confronting medical students as they first enter the wards is to master the art of case presentations. When a new patient is admitted to the hospital, it is the responsibility of the medical student and resident on call to obtain a good history and physical exam (H&P) and then to communicate this knowledge to the other members of the medical team. These skills are continually refined throughout a clinician's career as they see more patients.

The level of detail used in obtaining an H&P depends on both the setting and the patient. For example, the appropriate H&P when caring for an unfamiliar patient with multiple active medical problems is much more detailed than the H&P for a familiar patient who is generally healthy and comes to the outpatient office with an injured finger. As clinical skills develop, the H&P becomes a highly focused tool used both to investigate clinical problems of immediate concern, and to screen for other potential problems that may be suspected on the basis of the overall clinical picture.

Remember that the whole point of the H&P is to *communicate*. The goal is to present the important points of the case to one's colleagues in the form of an interesting "story." They can then contribute to the patient's care through discussion of the case, and by taking care of the patient in the middle of the night when the people who originally admitted the patient may be sound asleep at home. As one learns more clinical medicine, one gradually comes to know the difference between critical details not to be overlooked and irrelevant side issues that put listeners to sleep. This distinction is often surprisingly subtle, but it makes all the difference in effective case presentations.

The general format most commonly used for an H&P contains the following elements, which we will discuss in more detail in the sections that follow:

- Chief complaint
- History of the present illness
- Past medical history
- Review of systems
- Family history
- Social and environmental history
- Medications and allergies
- Physical exam
- Laboratory data
- Assessment and plan

Chief Complaint (CC)

This is a succinct statement that includes the patient's age, sex, and presenting problem. It may also include one or two very brief pieces of pertinent historical data.

Example: "The patient is a 53-year-old man with a history of hypertension now presenting with crushing substernal chest pain of 1 hour's duration."

History of the Present Illness (HPI)

This is the complete history of the *current* medical problem that brought the patient to medical attention. It should include possible risk factors or other causes of the current illness, as well as a detailed chronological description of all symptoms and prior care obtained for this problem. Related medical problems can be mentioned as well; however, those that are not of direct relevance to the present illness are usually covered instead in the section on past medical history (to be discussed next).

Example: "The patient has cardiac risk factors consisting of hypertension for 15 years, and a family history of coronary artery disease. He does not smoke, nor does he have diabetes or elevated cholesterol. He has not had previous myocardial infarction. For the past 5 years he has had a stable pattern of chest pain on exertion, brought on by walking up two or more flights of stairs, lasting less than 5 minutes, not accompanied by other symptoms. The pain is relieved by rest and sublingual nitroglycerin. He has refused to undergo further cardiac workup, such as exercise stress testing, in the past. His hypertension is being treated with a beta-blocker. He denies symptoms of congestive heart failure and has no history of peripheral vascular or cerebrovascular disease. Today while sitting at his desk at work, he developed sudden 'crushing' substernal chest pain and pressure radiating to his neck, accompanied by tingling of the left arm, shortness of breath,

sweating, and nausea without vomiting. The pain was not relieved by three sublingual nitroglycerin tablets, and his coworkers called an ambulance to bring him to the emergency room, where he was afebrile with pulse 100, BP 140/90, and respiratory rate 20, and had an EKG with ST elevations, suggesting anterolateral myocardial ischemia. His pain was initially relieved by IV nitroglycerin and 2 mg of morphine, but then returned again, lasting about 20 minutes with continued ST elevations, so he was started on the tissue plasminogen activator protocol for thrombolysis. He is now being admitted to the cardiac intensive care unit for further care, currently pain free."

Past Medical History (PMH)

Prior medical and surgical problems not directly related to the HPI are described here.

Example: "The patient has a history of a mildly enlarged prostate gland. He had a right inguinal hernia repair in 1978."

Review of Systems (ROS)

A brief head-to-toe review of all medical systems—including head, eyes, ears, nose and throat, pulmonary, cardiac, gastrointestinal, genitourinary, OB/GYN, dermatologic, neurologic, psychiatric, musculoskeletal, hematological, oncologic, rheumatological, endocrine, infectious diseases, and so on—should be pursued with each patient to pick up problems or complaints missed in earlier parts of the history. If something comes up that is relevant to the HPI, it should be inserted in that section, not buried in the ROS.

Example: "The patient has had mild upper respiratory symptoms for the past 4 days, with nasal congestion, but no cough, temperature, or sore throat."

Family History (FHx)

This section should list all immediate relatives and note familial illnesses such as diabetes, hypertension, asthma, heart disease, cancer, depression, and so on, especially those relating to the HPI. Family tree format is often a succinct and clear way to present this data.

Example: "Patient's mother died at 66 of myocardial infarction, had hypertension. Father had myocardial infarction at 55, had diabetes, died at 73 of stroke. Brother, 47 years old, healthy. Two children, healthy."

Social and Environmental History (SocHx/EnvHx)

This section should include the patient's occupation, family situation, travel history, and habits.

Example: "Electrical engineer. Married with two children. No recent travel. Denies ever smoking cigarettes or using drugs. Drinks 1–2 beers on Sundays."

Medications and Allergies

This section should list all medications currently being taken by the patient, as well as any known general or drug allergies.

Example: "Atenolol 50 mg PO daily. Sublingual nitroglycerin as needed. No allergies. NKDA (no known drug allergies)."

Physical Exam

The examination generally proceeds from head to toe and includes the following sections:

- General appearance—for example, "A slightly obese man in no acute distress."
- Vital signs—temperature (T), pulse (P), blood pressure (BP), respiratory rate (R)
- HEENT (head, eyes, ears, nose, and throat)
- Neck
- Back and spine
- Lymph nodes
- Breasts
- Lungs
- Heart
- Abdomen
- Extremities
- Pulses
- Neurologic (see Chapter 3)
- Rectal
- Pelvic and genitalia
- Dermatologic

Laboratory Data

This comprises all diagnostic tests, including blood work, urine tests, electrocardiogram, and radiological tests (chest X-rays, CT scans, etc.).

Assessment and Plan

The **assessment** section usually begins with a one- or two-sentence **summary,** or **formulation,** that encapsulates the patient's main clinical features and most likely diagnosis. In more diagnostically uncertain cases, a brief discussion is added to the assessment, including a **differential diagnosis**—that is, a list of alternative possible diagnoses. With neurologic disorders, this discussion is often broken down into two sections: (1) localization and (2) differential diagnosis.

The **plan** section immediately follows the assessment and is usually broken down into a list of problems and proposed interventions and diagnostic procedures.

Example: "This is a 53-year-old man with cardiac risk factors of hypertension and family history of coronary disease who presents with substernal chest pain and EKG changes suggestive of anterolateral wall myocardial infarction.

1. Coronary artery disease/hypertension: Will continue IV nitroglycerin and IV heparin after completion of tissue plasminogen activator protocol. Will resume beta-blocker, as patient has no evidence of congestive heart failure. Will check serial EKGs and cardiac enzymes to determine whether or not the patient has had a myocardial infarction.
2. Further cardiac workup: To include echocardiogram and an exercise stress test if cardiac enzymes are negative. If the patient develops further chest pain, he may require emergency cardiac catheterization."

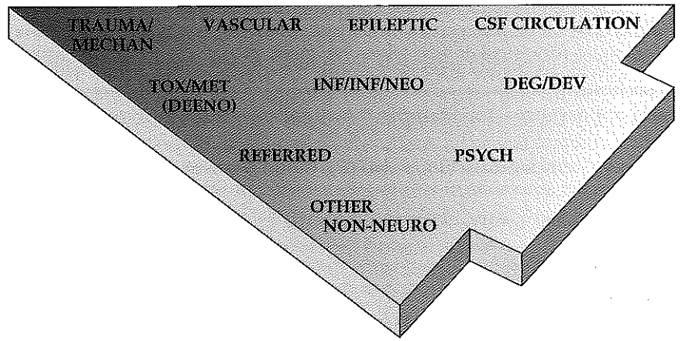

Figure 1.1 Arrowhead of Neurologic Differential Diagnosis More acute diagnoses are often (but not always) at the top left point, and along the outer edges of the arrow. Examples and explanations of abbreviations are listed.

Category	Examples
TRAUMA/ MECHAN	Traumatic disorders such as subdural hematoma; nontraumatic mechanical disorders such as herniated intervertebral disc
VASCULAR	Infarct, hemorrhage, migraine, vascular malformations
EPILEPTIC	Partial or generalized seizures
CSF CIRCULATION	Hydrocephalus, pseudotumor cerebri, intracranial hypotension
TOX/MET (DEENO)	Toxic disorders such as opiate overdose; metabolic disorders such as hepatic encephalopathy (DEENO = mnemonic for Drugs, Electrolytes, Endocrine, Nutrition, Organ failure)
INF/INF/NEO	Infectious diseases (e.g., bacterial meningitis); inflammatory diseases (e.g., multiple sclerosis); neoplastic diseases (e.g., glioblastoma multiforme)
DEG/DEV	Degenerative disorders (e.g., Alzheimer's disease); developmental disorders (e.g., tuberous sclerosis)
REFERRED	Left arm parasthesias due to cardiac ischemia
PSYCH	Major depression, conversion disorder
OTHER NON-NEURO	Loss of consciousness due to cardiac arrhythmia, impaired gait due to joint deformity

Neurologic Differential Diagnosis

Reaching the correct diagnosis in patients with neurologic disorders sometimes presents a considerable challenge. As noted in the previous discussion, the assessment section of the H&P is, therefore, often broken down into several logical steps to facilitate this thought process. The first step is **localization** based on neuroanatomical clues gleaned from the H&P. This integration of anatomical and clinical knowledge will be the focus of this book. However, we will also briefly discuss the next step, the **neurologic differential diagnosis**.

When the diagnosis is uncertain and multiple possibilities must be considered, it is often helpful to have a mnemonic device handy, especially while being questioned on rounds by a more senior clinician. Such a mnemonic, the Arrowhead of Neurologic Differential Diagnosis, is shown in Figure 1.1. Disorders that tend to be more acute and require more immediate attention appear along the top and left-hand leading edges of the arrowhead; disorders that are usually more chronic in nature appear on the inside. In visualizing and prioritizing one's clinical interventions, it can therefore be useful to move from the point on the left along the top row, and then along each subsequent row from left to right.

MNEMONIC

Relationship between the General Physical Exam and the Neurologic Exam

The neurologic exam is *part of the general physical exam.* Thus, although the neurologic exam is covered separately in Chapter 3, in reality the neurologic exam and the general physical exam should always be done and described as a single unit. The patient must be treated as a whole, with problems in different systems given priority depending on the situation. In addition, essential information about neurologic disease can be gleaned from all portions of the general physical exam. Some examples are given here (for explanations of unfamiliar terms see the Key Clinical Concepts throughout the rest of the book, or consult the Index):

- **General appearance.** How a person appears and behaves throughout the exam provides a wealth of information about his or her mental status and motor system.
- **Vital signs.** Hypertension, bradycardia, and other changes can be seen in elevated intracranial pressure. Exaggerated orthostatic changes (between reclining and upright positions) in heart rate and blood pressure can be seen in autonomic dysfunction and spinal cord injuries. Respiratory pattern provides important information about brainstem functioning. Elevated temperature suggests infection or inflammation, which may involve the nervous system.
- **HEENT.** Head shape can be a clue to congenital abnormalities, hydrocephalus, or tumors. Careful examination of the head, ears, and nose is essential in cranial trauma. Tongue abnormalities can suggest nutritional deficiencies, which may have neurologic manifestations. Oral thrush suggests immune dysfunction, which can predispose patients to a host of neurologic disorders. Palpation of the temporal and supraorbital arteries can give clues about vasculitis and collateral blood flow in cerebrovascular disease. A whooshing sound called a *bruit* can sometimes be heard with the stethoscope when intracranial vascular disease or arteriovenous malformations are present. Scalp tenderness may be present in migraine. The funduscopic exam is so relevant to neurologic disease that it is often included as part of the neurologic exam itself.
- **Neck.** Neck stiffness can be a sign of meningeal irritation. Cervical bruits can be heard with carotid artery disease. Thyroid abnormalities can cause mental status changes, eye movement disorders, and muscle weakness.
- **Back and spine.** Tenderness, misalignment, and curvature can give important information about possible fractures, metastases, osteomyelitis, and so on. Muscle stiffness and tenderness are diagnostically helpful in cases of back pain.
- **Lymph nodes.** Enlarged lymph nodes can be seen in neoplastic, infectious, and granulomatous disorders, which may involve the nervous system.
- **Breasts.** Breast cancer can metastasize to the nervous system or produce paraneoplastic disorders.
- **Lungs.** Unilateral decreased breath sounds with decreased movement of the diaphragm detected by percussion can be a sign of phrenic nerve dysfunction. An abnormal lung exam can also be associated with hypoxia and with infectious or neoplastic diseases, which may involve the nervous system.
- **Heart.** Clues to embolic sources can be provided by an irregular heartbeat with atrial fibrillation or by murmurs with valvular disease or endocarditis. Aortic stenosis can produce syncope, and severe heart failure results in cerebral hypoperfusion.

- **Abdomen.** Hepatomegaly may be palpated in Wilson's disease and other metabolic disorders that involve the nervous system. Abdominal aortic aneurysm, pancreatitis, and other abdominal pathology can produce back pain, which can occasionally be mistaken for disease of the spine.
- **Extremities.** Pain on straight-leg raising is a sign of nerve root compression. *Kernig's sign* (when examiner straightens the patient's knees with the hips flexed, patient has pain in the hamstrings) and *Brudzinski's sign* (when examiner flexes the patient's neck, patient flexes legs at the hips) are signs of meningeal irritation. Arthritis can be seen in autoimmune disorders, which often involve the nervous system. Clubbing or cyanosis suggests systemic illness, which may involve the nervous system. Leg edema can be seen in deep venous thrombosis, which is a common complication of neurologic disease, occurring with increased incidence in patients who rarely rise from bed.
- **Pulses.** Peripheral vascular disease suggests atherosclerosis, which may also involve intracranial vessels. Peripheral vascular disease produces symptoms such as pain, tingling, numbness, and even weakness, which can masquerade as neurologic disease.
- **Neurologic exam.** See Chapter 3.
- **Rectal.** Decreased rectal sphincter tone can signify pathology of the spinal cord or sacral nerve roots.
- **Pelvic and genitalia.** Gynecologic malignancies can be associated with paraneoplastic disorders involving the nervous system and, sometimes, with metastases. Testicular abnormalities can be seen in some neurodevelopmental disorders.
- **Dermatologic.** Several so-called neurocutaneous disorders have important dermatologic manifestations that can signal neurologic disease. These include neurofibromatosis, tuberous sclerosis, Sturge-Weber syndrome, and other disorders. A characteristic skin eruption is also seen in dermatomyositis. Local changes in skin texture, temperature, and color can be signs of chronic neurologic injury to the affected area. Other dermatologic abnormalities can, once again, signify systemic illnesses that may involve the nervous system.

Many more examples could be mentioned, but this list should at least illustrate that the neurologic exam and the general physical exam are inextricably linked.

Conclusions

In this chapter we have introduced the general format of the history and physical exam used in most medical settings. In the case presentations throughout the rest of the book, the same format will be used, with a focus on aspects of the H&P that reveal neurologic abnormalities. We have seen that much can be learned about neurologic disease from the *non-neurologic* portions of the general physical exam. Nevertheless, the *neurologic* portion of the general physical exam ultimately provides much of the information that enables us to localize lesions within the nervous system. Before we explore the neurologic exam in more detail, we must first lay down some foundations of basic neuroanatomy. This we will do in the next chapter, and we will then return to the neurologic exam in Chapter 3.

References

Bickley LS, Hoekelman RA. (eds.). 1999. *Bates' Guide to Physical Examination and History Taking*, 7th Ed. Lippincott-Raven, Philadelphia.

Coulehan JL, Block MR. 1997. *The Medical Interview: Mastering Skills for Clinical Practice*, 3rd Ed. FA Davis, Philadelphia.

DeGowin RL. 1994. *DeGowin & DeGowin's Diagnostic Examination*, 6th Ed. McGraw-Hill, New York.

Gilman S. 2000. *Clinical Examination of the Nervous System*. McGraw-Hill, New York.

CHAPTER 2

Neuroanatomy Overview and Basic Definitions

Basic Macroscopic Organization of the Nervous System
- Main Parts of the Nervous System
- Orientation and Planes of Section

Basic Cellular and Neurochemical Organization of the Nervous System

CNS Gray Matter and White Matter; PNS Ganglia and Nerves

Spinal Cord and Peripheral Nervous System

Cerebral Cortex: Basic Organization and Primary Sensory and Motor Areas
- Lobes of the Cerebral Hemispheres
- Surface Anatomy of the Cerebral Hemispheres in Detail
- Primary Sensory and Motor Areas
- Cell Layers and Regional Classification of the Cerebral Cortex

Motor Systems
- Main Motor Pathways
- Cerebellum and Basal Ganglia

Somatosensory Systems
- Main Somatosensory Pathways
- Thalamus

Stretch Reflex

Brainstem and Cranial Nerves

Limbic System

Association Cortex

Blood Supply to the Brain and Spinal Cord

The nervous system is perhaps the most beautiful, elegant, and complex system in the body. Its interconnected networks perform processing that is simultaneously local and distributed, serial and parallel, hierarchical and global. Accordingly, structures of the nervous system can be described on multiple levels: in terms of macroscopic brain divisions; connecting pathways and cell groupings; individual brain cells; and, ultimately, receptors, neurotransmitters, and other signaling molecules. In this chapter, we will learn about the nervous system's overall organization, and we will learn some basic terminology that will help us become oriented when we embark on a detailed study of the individual parts of the nervous system in subsequent chapters.

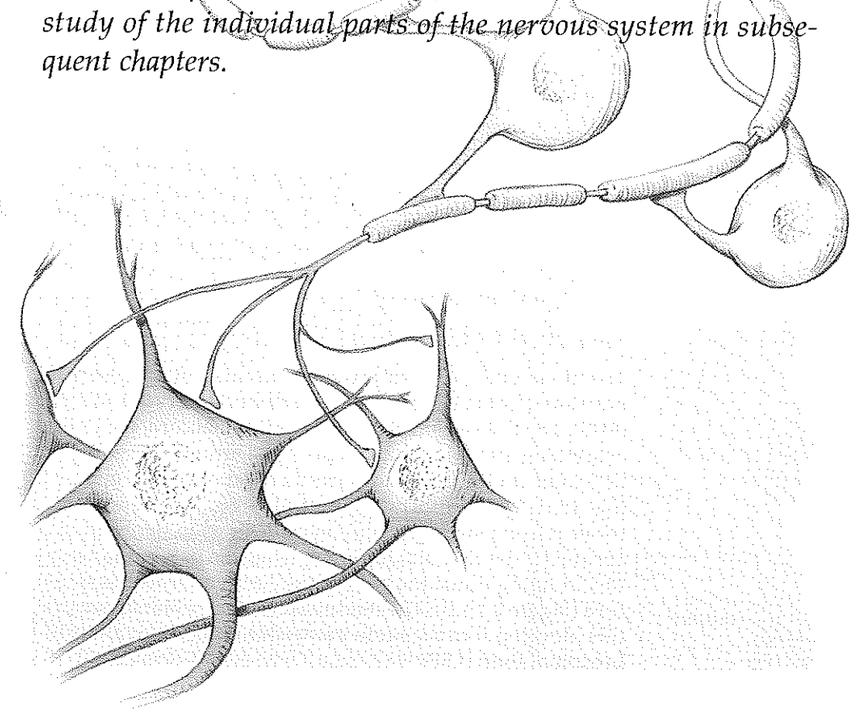

Basic Macroscopic Organization of the Nervous System

Deciding to study neuroanatomy is somewhat like agreeing to paint a large mural that you will spend the rest of your life carefully improving and refining. To begin painting this mural we must first agree on the orientation of our subject matter—choose an up and down, forward and backward. Then we will boldly sketch out the major features of the composition, paying particular attention to the relationships between different components and to how the composition works as a whole. The rough sketch provides a framework so that as we embark on painting various segments of the mural in ever finer detail we never lose sight of the big picture, and we are therefore able to pass seamlessly from one area of the mural to another.

This chapter is devoted to the rough sketch. It would be a vain undertaking to attempt to learn the neuroanatomy of one system or region without some concept of how it relates both spatially and functionally to the whole nervous system. This is especially true when one uses clinical cases to learn neuroanatomy. Thus, although each of the clinical cases in this book focuses on a particular neuroanatomical system, lesions almost invariably affect neighboring regions as well. These **neighborhood effects** are often critical in localizing neuroanatomical lesions. Therefore, in this chapter we will sketch out the main components of the nervous system and begin to describe some of the most important functions of each part.

After reading this chapter you should have some understanding of the nervous system as a whole. In addition, when you begin reading the clinical cases (Chapters 5–19), you should be able to localize lesions in certain general locations in the nervous system even though you have not yet studied those regions in detail. Finally, this chapter will provide the necessary background for understanding Chapter 3, in which we introduce the neurologic exam.

A caveat is in order before reading this chapter: This material is presented in the traditional style, without clinical cases. Therefore, do not become discouraged if you have trouble remembering all of the details. As you read the clinical cases in later chapters and refer back to this information to reach clinical diagnoses, the material will gradually be reinforced and solidified.

Figure 2.1 Parts of the Human Nervous System

Main Parts of the Nervous System

The human nervous system can be divided into the **central nervous system** (**CNS**) and the **peripheral nervous system** (**PNS**). The CNS includes the brain and spinal cord; the PNS is everything else (Figure 2.1; Table 2.1). During embryological development the CNS arises from a sheet of ectodermal cells that folds over to form the **neural tube.** The neural tube forms several swellings and outpouchings in the head that eventually develop into the brain, while the part of the neural tube running down the back of the embryo forms the spinal cord (Figure 2.2A,B). The fluid-filled cavities within the neural tube develop into the brain **ventricles,** which contain **cerebrospinal fluid** (**CSF**).

The developing brain has three main divisions: the forebrain, or **prosencephalon;** the midbrain, or **mesencephalon;** and the hindbrain, or **rhombencephalon** (Figure 2.2). The **forebrain** is the largest part of the nervous system in humans, and it is further subdivided into the telencephalon and diencephalon. The **telencephalon** (meaning "end brain" in Greek) is made up of the cerebral hemispheres, and includes structures discussed later in this chapter such as the cerebral cortex, white matter, and basal ganglia. The **diencephalon** is composed of the **thalamus, hypothalamus,** and associated structures. The **midbrain** is a relatively short and narrow region connecting the forebrain and hindbrain. The **hindbrain** is composed of the **pons** and **cerebellum** (**metencephalon**) together with the **medulla** (**myelencephalon**) (Figure 2.2).

The midbrain, pons, and medulla together form a connection between the forebrain and the spinal cord. Since the forebrain sits on top of the **midbrain, pons,** and **medulla,** almost like a cauliflower on its stalk (see Figure 2.2C), these structures are often referred to as the **brainstem.*** The brainstem is the most evolutionarily ancient part of the human brain and is the part that

*Some authors formerly defined the brainstem to include the cerebellum and diencephalon. In common clinical usage today, however, the term "brainstem" refers to the midbrain, pons, and medulla.

TABLE 2.1 Main Parts of the Human Nervous System

Central nervous system (CNS)
Brain
Spinal cord
Peripheral nervous system (PNS)
Cranial nerves and ganglia
Spinal nerves and dorsal root ganglia
Sympathetic and parasympathetic nerves and ganglia
Enteric nervous system

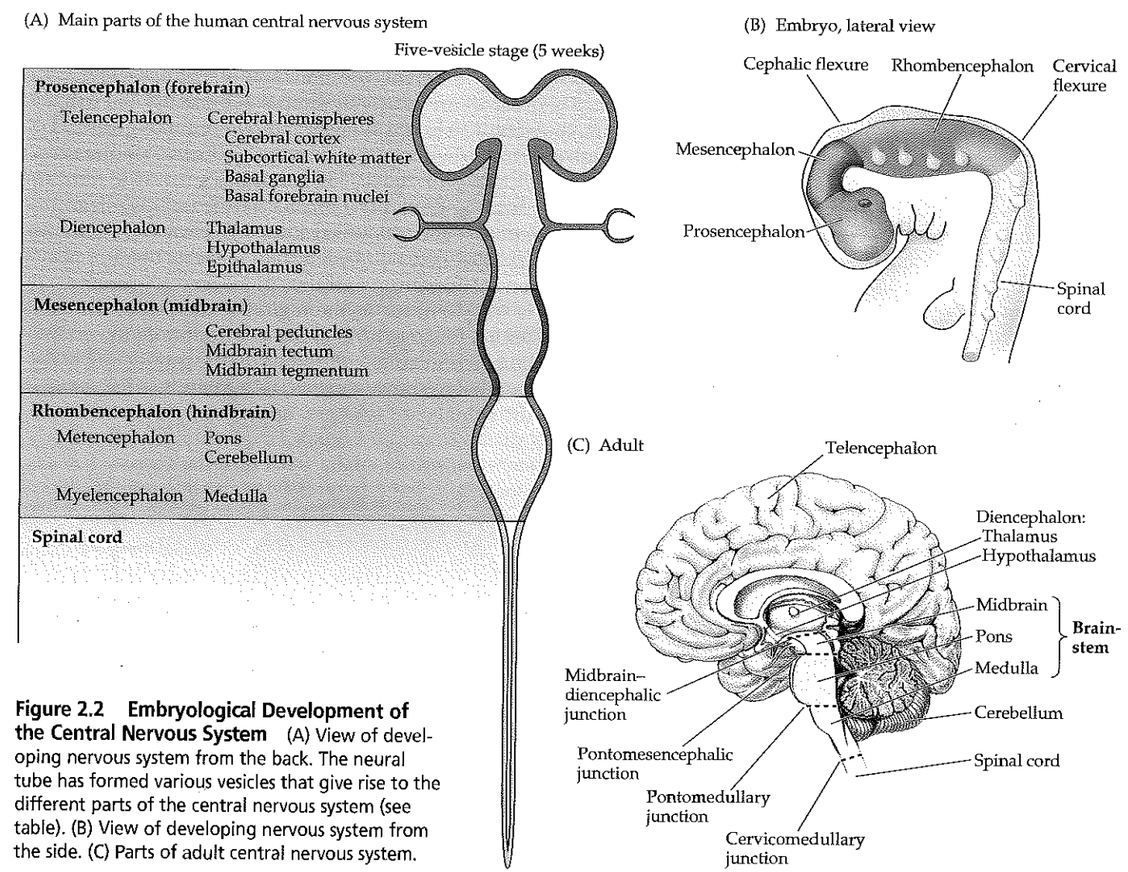

Figure 2.2 Embryological Development of the Central Nervous System (A) View of developing nervous system from the back. The neural tube has formed various vesicles that give rise to the different parts of the central nervous system (see table). (B) View of developing nervous system from the side. (C) Parts of adult central nervous system.



Figure 2.3 Orientation of the Central Nervous System in Reptiles The same terms apply above and below the midbrain.

most closely resembles the brains of fish and reptiles. It controls many of the most basic bodily functions necessary for survival, such as respiration, blood pressure, and heart rate.

Cerebrospinal fluid is formed mainly by vascular tufts lying within the ventricles called **choroid plexus** (see Figure 5.10). CSF circulates from the **lateral ventricles** to the **third ventricle,** and then leaves the ventricular system via foramina in the **fourth ventricle,** to percolate around the outside surface of the brain and spinal cord. The central nervous system is covered by three membranous protective layers called **meninges** (see Figure 5.1). Listed from inside to outside, the meninges are the **pia, arachnoid,** and **dura** (mnemonic = PAD). Once it leaves the ventricular system, CSF travels in the space between the arachnoid and pia and is ultimately reabsorbed into the venous system.

MNEMONIC

Orientation and Planes of Section

A variety of terms is used for different directions and planes of section in the nervous system. These terms are relatively simple in animals, like fish and reptiles, in which the nervous system is linear in orientation (Figure 2.3). In these animals, **ventral** (from the Latin *venter,* meaning "belly") is always toward the earth, **dorsal** (Latin for "back," as in a shark's fin) is toward the sky, **rostral** (Latin for "beak"—think of a "rooster's rostrum") is toward the snout, and **caudal** (Latin for "tail") is toward the tail. However, since humans have an upright posture, the nervous system makes a bend of nearly 90° somewhere between the forebrain and the spinal cord (Figure 2.4). By definition, this bend is said to occur in the region of the midbrain–diencephalic junction. Therefore, for structures above the midbrain, the orientation of the nervous system is the same with respect to the ground (as in reptiles). At the midbrain and below, however, there is a rotation of 90°, since in the standing position the spinal cord is approximately perpendicular to the ground in humans.

MNEMONIC

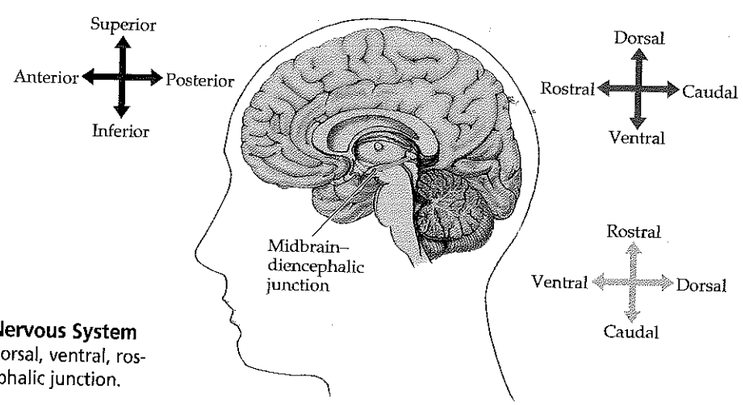

Figure 2.4 Orientation of the Central Nervous System in Humans The meaning of some terms (dorsal, ventral, rostral, caudal) changes at the midbrain–diencephalic junction.

Another set of terms that is often used for orientation in the nervous system remains constant with respect to the environment both above and below the midbrain. These are **anterior, posterior, superior,** and **inferior.** By looking at Figure 2.4 you should be able to confirm the definitions of the following terms as they apply to humans:

- Above the midbrain:
  Anterior = rostral
  Posterior = caudal
  Superior = dorsal
  Inferior = ventral
- Below the midbrain:
  Anterior = ventral
  Posterior = dorsal
  Superior = rostral
  Inferior = caudal

Thus, for example, above the midbrain the *anterior* commissure is *rostral,* the *posterior* commissure is *caudal,* the *superior* sagittal sinus is *dorsal,* and the *inferior* sagittal sinus is *ventral.* Meanwhile, below the midbrain the *anterior horn* of the spinal cord is *ventral,* the *posterior* horn is *dorsal,* the *superior* cerebellar peduncle is *rostral,* and the *inferior* cerebellar peduncle is *caudal.* In the midbrain itself, the same conventions as below the midbrain are generally used.

When the nervous system is studied pathologically or imaged radiologically, it is usually cut in one of three different orthogonal planes of section (Figure 2.5). **Horizontal** sections are parallel to the floor. Equivalent terms for horizontal sections in humans include **axial** or **transverse** sections, meaning sections perpendicular to the long axis of the person's body. The name **coronal** comes from the sectioning plane approximating that of a tiara-like crown. **Sagittal** sections are in the direction of an arrow shot, and this plane of section is best visualized by imagining the plane defined by a bow and arrow held by an archer (as in the constellation Sagittarius). Sagittal sections passing through the midline are referred to as **midsagittal,** and when they are just off the midline they are referred to as **parasagittal** sections.

Note that the sagittal plane is orthogonal to the left–right axis, the coronal plane is orthogonal to the anterior–posterior axis, and the horizontal plane is orthogonal to the superior–inferior axis. When a plane of section lies somewhere between the three principal planes, it is referred to as oblique. The planes of section used for CT and MRI scans are approximately horizontal, coronal, or sagittal, with some slight adjustments (especially in the horizontal plane) often being necessary for technical reasons (see Chapter 4).

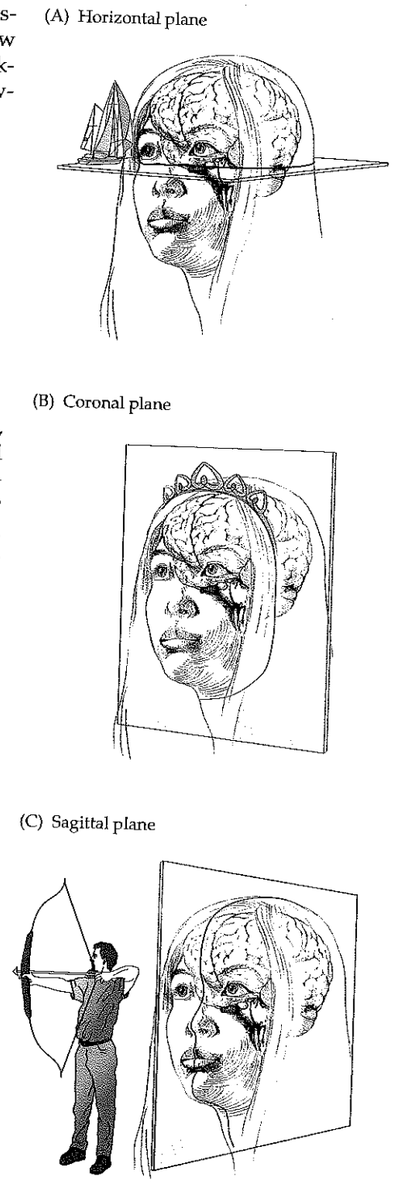

Figure 2.5 Anatomical Planes of Section (A) Horizontal (axial, transverse) plane. (B) Coronal plane. (C) Sagittal plane.

Basic Cellular and Neurochemical Organization of the Nervous System

Microscopically, the nervous system is composed of nerve cells, or **neurons,** and support cells called **glial cells** (or simply **glia**). Neurons are mainly responsible for signaling in the nervous system, although glial cells may contribute as well. Neuronal signaling is a complex phenomenon, presented here in a very simplified manner geared toward the clinical–anatomical discussions in this book (see the references at the end of this chapter for a more detailed treatment). A typical neuron has a **cell body** containing the nucleus, relatively short processes called **dendrites,** which receive most inputs to the cell, and long processes called **axons,** which carry most outputs (Figure 2.6). Most

mammalian neurons are **multipolar,** meaning that they have several dendrites, as well as several axons (Figure 2.6A). Often, a single axon arising from the cell body will travel for a distance, and then one or several **axon collaterals** branch off the main axon to reach different targets. Some neurons are **bipolar,** with a single dendrite and a single axon arising from the cell body. Bipolar cells are often sensory neurons, such as those involved in vision (see Figure 11.4) or olfaction (see Figure 18.5). Some bipolar neurons are called pseudounipolar, since their processes are initially fused, and then split to produce

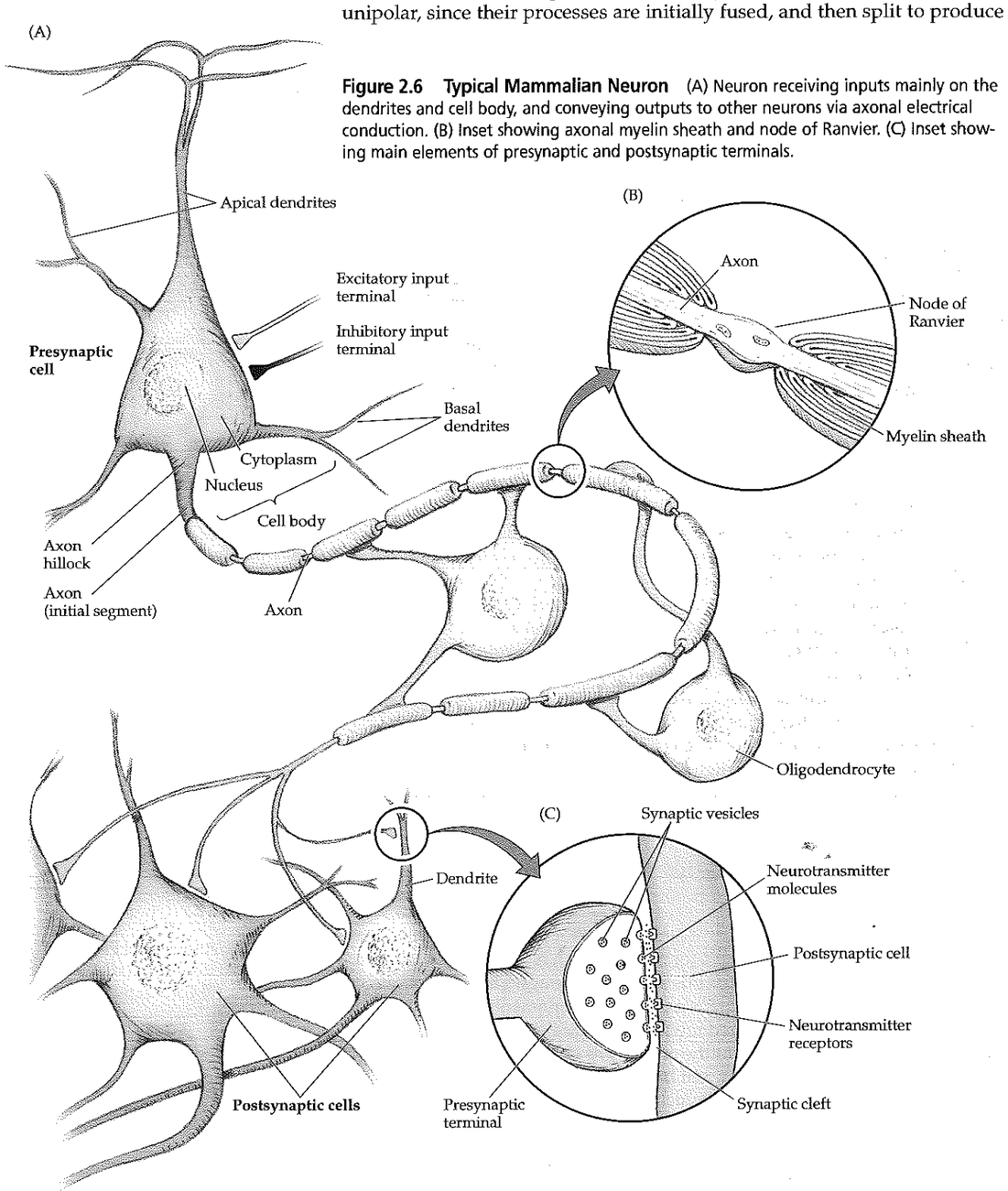

Figure 2.6 Typical Mammalian Neuron (A) Neuron receiving inputs mainly on the dendrites and cell body, and conveying outputs to other neurons via axonal electrical conduction. (B) Inset showing axonal myelin sheath and node of Ranvier. (C) Inset showing main elements of presynaptic and postsynaptic terminals.

two long axons. An example is dorsal root ganglion sensory neurons (see Figure 2.21). **Unipolar** neurons, in which both axons and dendrites arise from a single process coming off the cell body, occur mainly in invertebrates.

Communication between neurons takes place mainly at specialized regions called **synapses.** Classically, synapses carry information from the axon terminals of one neuron to the dendrites of the next neuron. However, there are also axo-axonic and dendro-dendritic synapses, and some forms of communication can even occur in reverse, traveling from dendrites back to axons. At **chemical synapses,** chemical **neurotransmitter** molecules, stored mainly in **synaptic vesicles,** are released from **presynaptic terminals** of the neuron (see Figure 2.6C). They then bind to **neurotransmitter receptors** on the **postsynaptic** neuron, giving rise to either excitation or inhibition of the postsynaptic neuron. In some cases, communication also takes place at **electrical synapses** where direct electrical coupling of neurons occurs through specialized junctions.

Neurons are electrically and chemically active. When excitatory synaptic inputs combine with endogenous transmembrane currents to sufficiently excite a neuron, a transient voltage change called an **action potential** occurs, lasting about 1 millisecond. Action potentials can travel rapidly throughout the length of a neuron, propagating at rates of up to about 60 meters per second along the cell membrane. Classically, action potentials travel from the dendritic end of the neuron along its axon to reach presynaptic terminals, where communication can occur with the next neuron (see Figure 2.6). Action potentials trigger release of neurotransmitter molecules from synaptic vesicles, allowing chemical communication with the postsynaptic cell (see Figure 2.6C).

Axons are often insulated by specialized glial cells that form a lipid **myelin sheath,** thereby speeding the rate of action potential conduction (see Figure 2.6B). The myelin-forming glial cells in the CNS are **oligodendrocytes;** in the PNS they are **Schwann cells.** Voltage-gated ion channels are concentrated in short exposed segments of the axon called **nodes of Ranvier** (see Figure 2.6B). Conduction from node to node occurs rapidly by a process called saltatory conduction.

Chemical neurotransmitters have two general types of functions. One is to mediate rapid communication between neurons through fast excitatory or inhibitory electrical events known as **excitatory postsynaptic potentials** (**EPSPs**) and **inhibitory postsynaptic potentials** (**IPSPs**). Fast EPSPs and IPSPs occur on the time scale of tens of milliseconds, and rapidly move the membrane voltage of the postsynaptic neuron between states more or less likely to fire an action potential. The postsynaptic neuron summates EPSPs and IPSPs arising from many presynaptic inputs. The second function of chemical neurotransmitters is **neuromodulation,** generally occurring over slower time scales. Neuromodulation includes a broad range of cellular mechanisms involving signaling cascades that regulate synaptic transmission, neuronal growth, and other functions. Neuromodulation can either facilitate or inhibit the subsequent signaling properties of the neuron.

Some of the more important and common neurotransmitters are summarized in Table 2.2. Note that neurotransmitters can be small molecules such as acetylcholine, amino acids like glutamate, or larger molecules such as peptides. Depending on the specific receptors present, neurotransmitters can mediate fast neurotransmission through EPSPs or IPSPs, or may have facilitatory or inhibitory neuromodulatory effects on neuronal signaling. Some neurotransmitters have different actions at different synapses or even at the same synapse when a mixture of receptor types is present. In addition, more than one type of neurotransmitter molecule is often released, even at a single synapse.

TABLE 2.2 Some Important Neurotransmitters

NAME	LOCATION OF CELL BODIES	MAIN PROJECTIONS	RECEPTOR SUBTYPES	MAIN ACTIONS
Glutamate	Entire CNS	Entire CNS	AMPA/kainate	Excitatory neurotransmission
			NMDA	Modulation of synaptic plasticity
			Metabotropic	Activation of second messenger systems
GABA	Entire CNS	Entire CNS	$GABA_A$, $GABA_B$	Inhibitory neurotransmission
		Retina	$GABA_C$	Inhibitory neurotransmission
Acetylcholine	Spinal cord anterior horns	Skeletal muscles	Nicotinic	Muscle contraction
	Autonomic preganglionic nuclei	Autonomic ganglia	Nicotinic	Autonomic functions
	Parasympathetic ganglia	Glands, smooth muscle, cardiac muscle	Muscarinic	Parasympathetic functions
	Basal forebrain: nucleus basalis, medial septal nucleus, and nucleus of diagonal band	Cerebral cortex	Muscarinic and nicotinic subtypes	Neuromodulation
	Pontomesencephalic region: pedunculopontine nucleus and laterodorsal tegmental nucleus	Thalamus, cerebellum, pons, and medulla	Muscarinic and nicotinic subtypes	Neuromodulation
Norepinephrine	Sympathetic ganglia	Smooth muscle, cardiac muscle	α and β subtypes	Sympathetic functions
	Pons: locus ceruleus and lateral tegmental area	Entire CNS	α_{1A-D}, α_{2A-D}, β_{1-3}	Neuromodulation
Dopamine	Midbrain: substantia nigra, pars compacta, and ventral tegmental area	Striatum, prefrontal cortex, limbic cortex, nucleus accumbens, amygdala	D_{1-5}	Neuromodulation
Serotonin	Midbrain and pons: raphe nuclei	Entire CNS	$5\text{-}HT_{1A-F}$, $5\text{-}HT_{2A-C}$, $5\text{-}HT_{3-7}$	Neuromodulation
Histamine	Hypothalamus: tuberomammillary nucleus; midbrain: reticular formation	Entire brain	H_{1-3}	Mainly excitatory neuromodulation
Glycine	Spinal cord; possibly also brainstem and retina	Spinal cord, brainstem, and retina	Glycine	Inhibitory neurotransmission[a]
Peptides	Entire CNS	Entire CNS	Numerous	Neuromodulation

[a]Glycine also has a modulatory role by binding to the MNDA receptor and increasing its response to glutamate.

In the CNS, the most common *excitatory* neurotransmitter is **glutamate;** the most common *inhibitory* neurotransmitter is **GABA** (gamma-aminobutyric acid). In the PNS, **acetylcholine** is the main transmitter at neuromuscular junctions, and both acetylcholine and **norepinephrine** are important in the autonomic nervous system (which we will discuss a little later). Aside from those listed in Table 2.2, numerous other neurotransmitters and neuro-

transmitter receptors have been described, and many more are yet to be discovered. Additional details of the functions of particular neurotransmitters will be provided in Chapters 6, 14, and 16.

CNS Gray Matter and White Matter; PNS Ganglia and Nerves

Areas of the CNS made up mainly of myelinated axons are called **white matter.** Areas made up mainly of cell bodies are called **gray matter.** Most of the local synaptic communication between neurons in the CNS occurs in the gray matter, while axons in the white matter transmit signals over greater distances. The surface of the cerebral hemispheres is covered by a unique mantle of gray matter called the **cerebral cortex,** which is far more developed in higher mammals than in other species. Beneath this lies the white matter, which conveys signals to and from the cortex (Figure 2.7A). Gray matter is also found in large clusters of cells called **nuclei** located deep within the cerebral hemispheres and brainstem. Examples include the **basal ganglia, thalamus,** and **cranial nerve nuclei** (Figure 2.7A,B).

In the cerebral hemispheres the gray matter cortex is outside, while the white matter is inside. In the spinal cord the opposite is true: White matter pathways lie on the outside, while the gray matter is in the center (Figure 2.7C). In the brainstem, gray matter and white matter regions are found both on the inside and on the outside, although most of the outside surface is white matter.

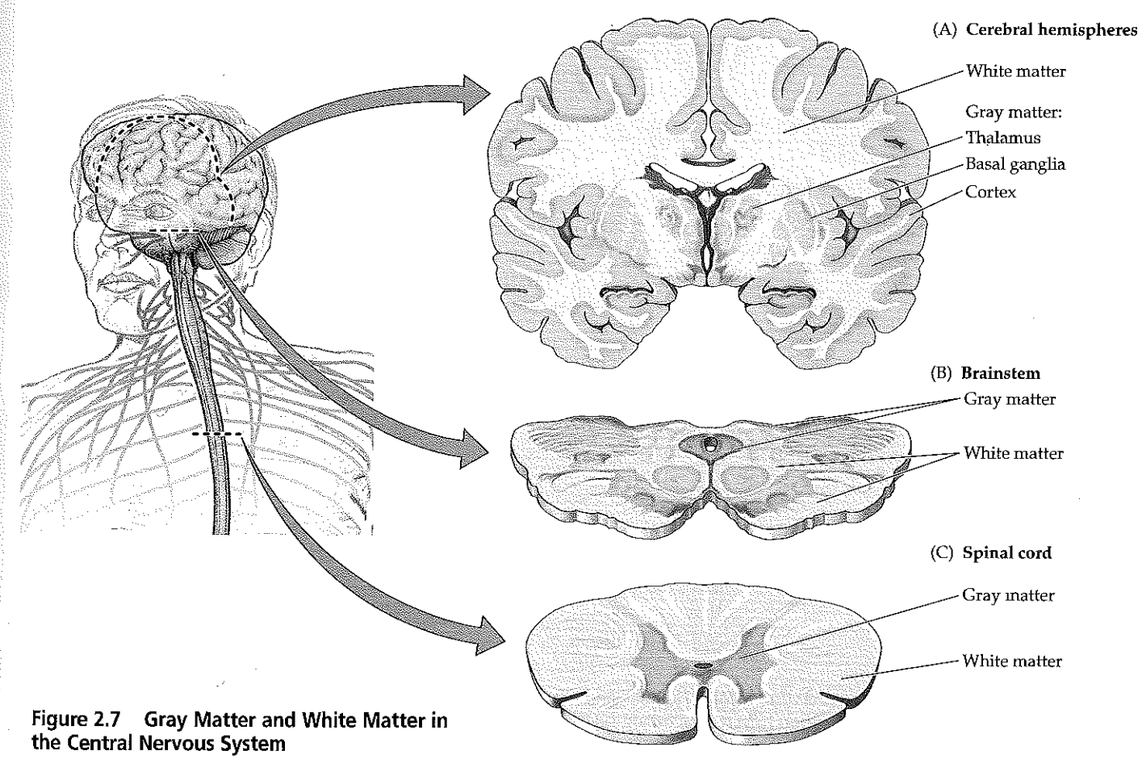

Figure 2.7 Gray Matter and White Matter in the Central Nervous System

(A)

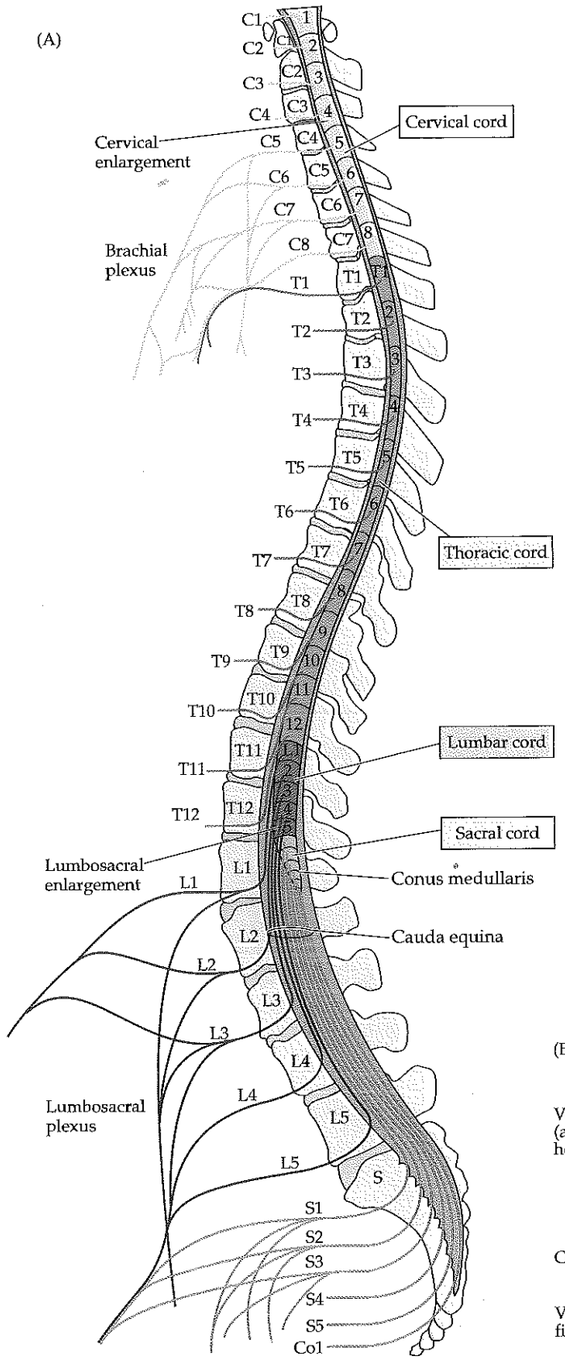

Several different names with similar meaning are used for white matter pathways in the CNS, including **tract, fascicle, lemniscus,** and **bundle.** A white matter pathway that connects identical structures on the right and left sides of the CNS is called a **commissure.** Axons in the PNS form bundles called **peripheral nerves,** or simply nerves. Clusters of cell bodies in the PNS are referred to as **ganglia.**

In general, pathways carrying signals *toward* a structure are called **afferent,** while those carrying signals *away from* a structure are called **efferent** (*a*fferents *a*rrive, *e*fferents *e*xit). Thus, peripheral nerves convey afferent sensory information about the environment to the CNS and carry efferent signals for motor activity from the CNS to the periphery.

Spinal Cord and Peripheral Nervous System

The human nervous system develops in segments similar to those of simpler animals, such as segmented worms. As already described, the segments in the head expand and fuse together, forming the cerebral hemispheres and brainstem. Twelve pairs of **cranial nerves** (see Figure 2.1) exit these segments (these will be discussed further later in the chapter). The **spinal nerves** arise from the segments of the spinal cord. Each segment gives rise to both sensory and motor nerve roots on each side of the body (Figure 2.8B).

Throughout the nervous system, motor systems tend to be more ventral, or anterior, and sensory systems more dorsal, or posterior. The same holds true for the spinal cord. Thus, **dorsal nerve roots** convey mainly afferent sensory information into the dorsal spinal cord, while **ventral nerve roots** carry mainly efferent motor signals from the ventral spinal cord to the periphery. The segments and nerve roots of the spinal cord are named according to the level at which they exit the bony vertebral canal. Thus, there are **cervical, thoracic, lumbar,** and **sacral** nerve roots (see Figure 2.8A).

(B)

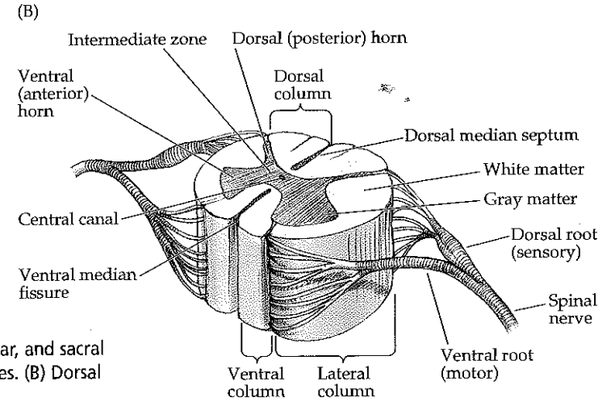

Figure 2.8 The Spinal Cord (A) Cervical, thoracic, lumbar, and sacral spinal cord segments and nerves in relation to vertebral bones. (B) Dorsal sensory roots and ventral motor roots arise at each segment.

During development, the bony vertebral canal increases in length faster than the spinal cord. Therefore, the spinal cord ends at the level of the first or second lumbar vertebral bones (L1 or L2). Below this the spinal canal contains a collection of nerve roots known as the **cauda equina** ("horse's tail"), which continue down to their exit points. The sensory and motor nerve roots join together a short distance outside the spinal cord and form a mixed sensory and motor spinal nerve (see Figure 2.8B). Control of the arms and legs requires much more signal flow than does control of the chest and abdomen. Thus, the nerves controlling the extremities give rise to elaborate meshworks referred to as the **brachial plexus** for the arm and the **lumbosacral plexus** for the leg (Figure 2.8A). In addition, the spinal cord contains a relatively increased amount of gray matter in these segments, causing the overall thickness of the cord to be greater. These regions of the cord are called the **cervical enlargement** and the **lumbosacral enlargement,** respectively.

In addition to the sensory and motor pathways already described, the PNS includes some specialized neurons that are involved in controlling such automatic functions as heart rate, peristalsis, sweating, and smooth muscle contraction in the walls of blood vessels, bronchi, sex organs, the pupils, and so on. These neurons are part of the **autonomic nervous system.** The autonomic nervous system has two major divisions (Figure 2.9): The **sympa-**

Figure 2.9 Autonomic Nervous System The sympathetic division is shown on the left, and the parasympathetic division is shown on the right.

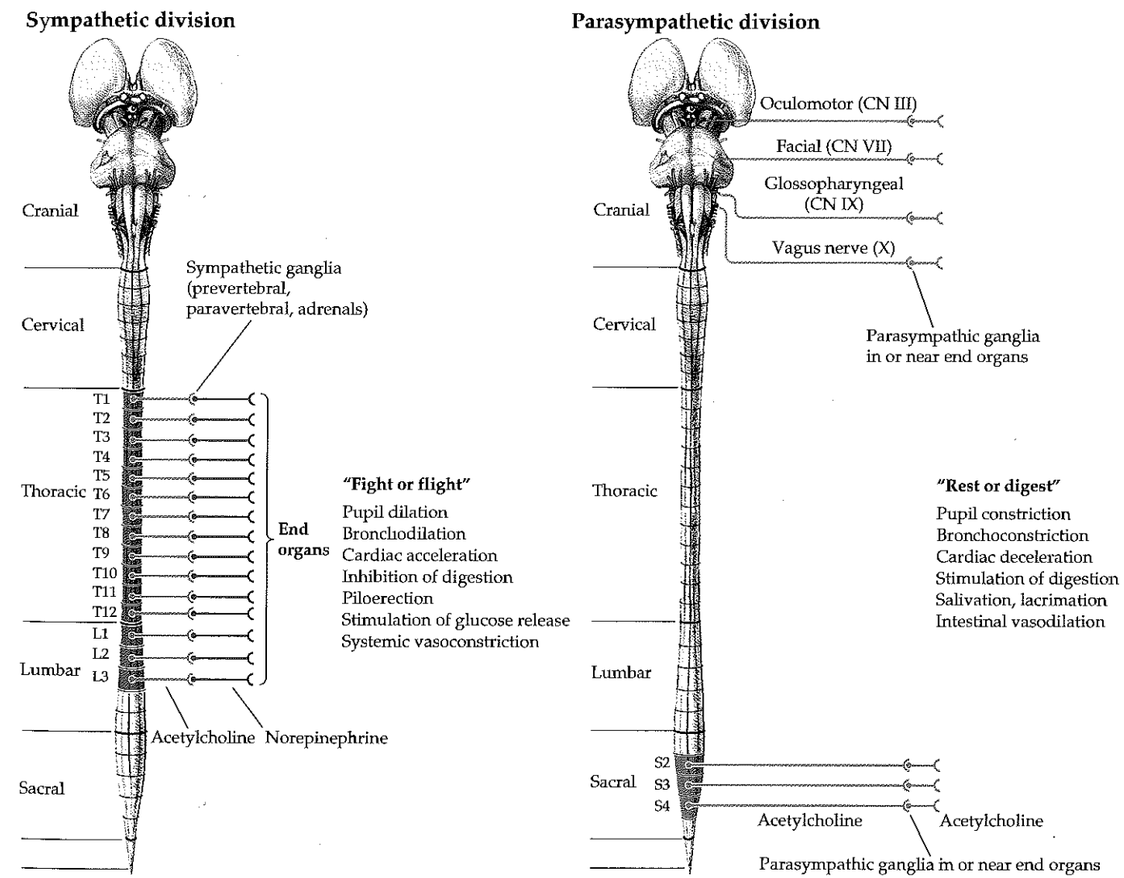

thetic division arises from thoracic and lumbar spinal levels T1 to L2 (the **thoracolumbar** division). It releases the neurotransmitter **norepinephrine** onto end organs, and is involved in such "fight or flight" functions as increased heart rate and blood pressure, bronchodilation, and increased pupil size. The **parasympathetic** division, in contrast, arises from the cranial nerves and from sacral spinal levels S2 to S4 (the **craniosacral** division). It releases **acetylcholine** onto end organs, and is involved in more sedentary functions, such as increasing gastric secretions and peristalsis, slowing the heart rate, and decreasing pupil size. The sympathetic and parasympathetic pathways are controlled by higher centers in the hypothalamus and limbic system, as well as by afferent sensory information from the periphery.

The enteric nervous system is considered a third autonomic division, and consists of a neural plexus lying within the walls of the gut that is involved in controlling peristalsis and gastrointestinal secretions.

Cerebral Cortex: Basic Organization and Primary Sensory and Motor Areas

The cerebral cortex is not a smooth sheet, but rather has numerous infoldings or crevices called **sulci.** The bumps or ridges of cortex that rise up between the sulci are called **gyri.** Some sulci and gyri have particular names and functions, as we will learn shortly. The cerebral hemispheres have four major lobes: the frontal, temporal, parietal, and occipital (Figure 2.10).

Lobes of the Cerebral Hemispheres

The **frontal lobes** are, appropriately, in the front of the brain and extend back to the **central sulcus of Rolando.** The frontal lobes are separated inferiorly and laterally from the **temporal lobes** by an especially deep sulcus called the **Sylvian fissure,** or lateral fissure. (The term **fissure** is sometimes used to refer to deep sulci.) The **parietal lobes** are bounded anteriorly by the central sulcus but have no sharp demarcation from the temporal lobes or the **occipital lobes** when viewed from the lateral side of the brain (see Figure 2.10A). When viewed from the medial aspect, the **parieto-occipital sulcus** can be seen more easily, separating the parietal from the occipital lobes (see Figure 2.10B).

Figure 2.10 Cerebral Cortex: Frontal, Parietal, Temporal, and Occipital Lobes
(A) Lateral view of left hemisphere.
(B) Medial view of right hemisphere.

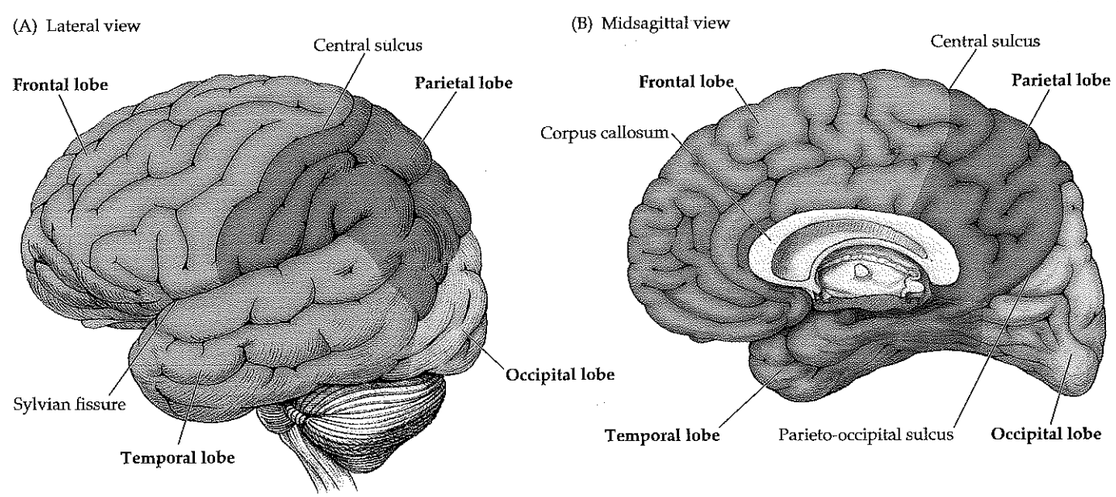

In addition to these four major lobes, an additional region of cerebral cortex lies buried within the depths of the Sylvian fissure, called the **insular cortex** (see Figure 2.24B). The insula is covered by a lip of frontal cortex anteriorly and parietal cortex posteriorly, called the **frontal operculum** and **parietal operculum,** respectively (*operculum* means "covering" or "lid" in Latin) (see Figure 2.24B). The limbic cortex (see Figure 2.25) was formerly referred to as the "limbic lobe," but this terminology is no longer generally used.

The two cerebral hemispheres are separated in the midline by the **interhemispheric fissure,** also known as the **longitudinal fissure** (see Figure 2.11D). A large C-shaped band of white matter called the **corpus callosum** (meaning "hard body") connects homologous areas in the two hemispheres (see Figure 2.10).

Surface Anatomy of the Cerebral Hemispheres in Detail

Although there is some variability, the sulci and gyri of the cerebral hemispheres form certain fairly consistent patterns. We will now briefly review the names of the major sulci, gyri, and other structures of the cerebral hemispheres (Figure 2.11). Functions of these structures will be discussed in the next section and throughout the remainder of the book.

On the lateral surface (see Figure 2.11A), the frontal lobe is bounded posteriorly by the central sulcus, as already noted. The gyrus running in front of the central sulcus is called the **precentral gyrus**. The remainder of the lateral frontal surface is divided into the **superior, middle, and inferior frontal gyri** by the **superior and inferior frontal sulci**. Similarly, the lateral temporal lobe is divided into **superior, middle, and inferior temporal gyri** by the **superior and middle temporal sulci**. The most anterior portion of the parietal lobe is the **postcentral gyrus**, lying just behind the central sulcus. The **intraparietal sulcus** divides the **superior parietal lobule** from the **inferior parietal lobule**. The inferior parietal lobule consists of the **supramarginal gyrus** (surrounding the end of the Sylvian fissure) and the **angular gyrus** (surrounding the end of the superior temporal gyrus).

On the medial surface (see Figure 2.11B), the **corpus callosum** is clearly visible, consisting of the **rostrum, genu, body,** and **splenium**. The **cingulate gyrus** (cingulum means "girdle" or "belt") surrounds the corpus callosum, running from the paraterminal gyrus anteriorly to the isthmus posteriorly. It has a **marginal branch**, running up to the superior surface that forms an important landmark, since the sulcus immediately in front of it on the superior surface is the central sulcus. The central sulcus does not usually extend onto the medial surface, but the region surrounding it is called the **paracentral lobule**. The portion of the medial occipital lobe below the **calcarine fissure** is called the **lingula** (meaning "little tongue"), while the portion above the calcarine fissure is called the **cuneus** (meaning "wedge"). Just in front of the cuneus, the medial parietal lobe is called the **precuneus**.

On the inferior surface (see Figure 2.11C), the **orbital frontal gyri** can be seen, which lay on top of the orbital ridges of the eye. More medially, the **olfactory sulcus** (containing the olfactory bulb) separates the orbital frontal gyri from the **gyrus rectus** (meaning "straight gyrus"). On the inferior surface of the temporal lobe, the **inferior temporal sulcus** separates the inferior temporal gyrus from the **occipitotemporal,** or **fusiform, gyri**. More medially, the **collateral sulcus**, continuing anteriorly as the **rhinal sulcus**, separates the fusiform gyri from the **parahippocampal gyrus**.

Finally, on the superior surface (see Figure 2.11D), many of the same landmarks seen on the lateral surface are again visible.

REVIEW EXERCISE

At this point you should become acquainted with the different lobes and with the major sulci and gyri of the cerebral hemispheres: Cover the labels in Figure 2.11A–D and attempt to name as many structures as possible. By the time you have completed this text, the functions of most of these sulci and gyri should be familiar.

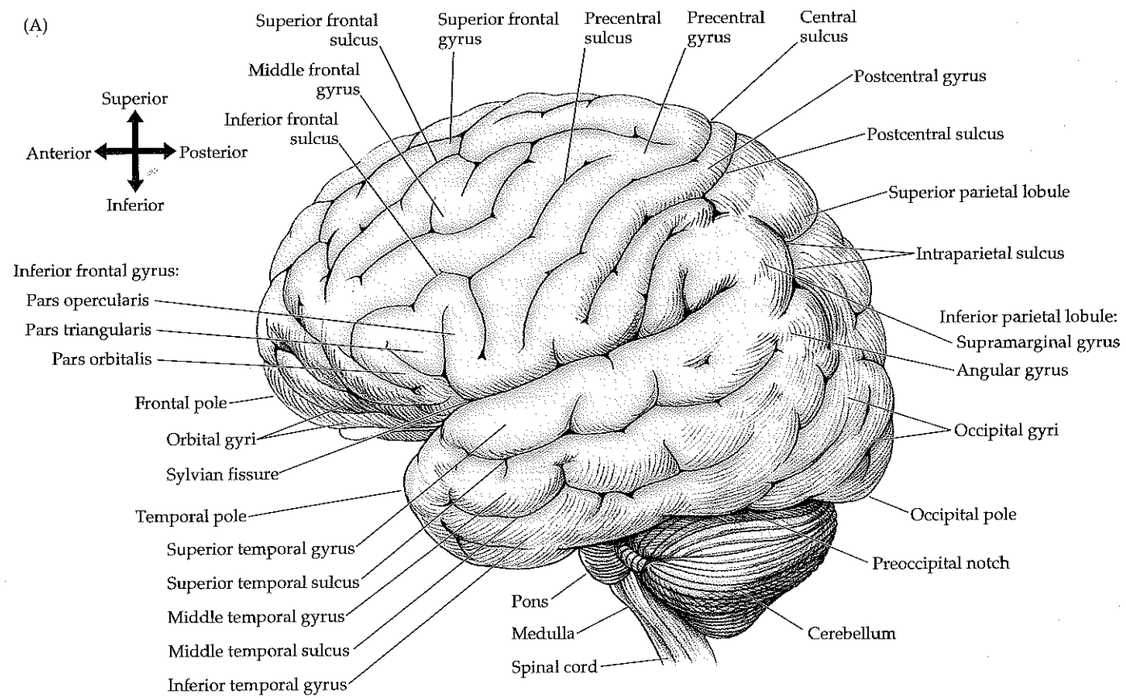

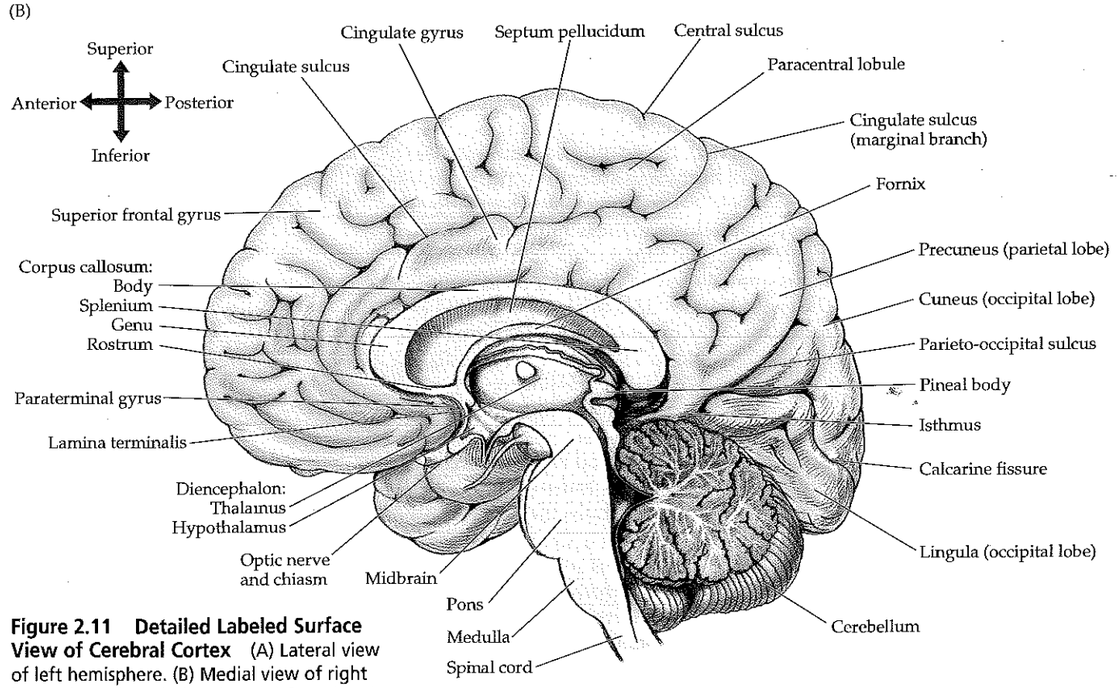

Figure 2.11 Detailed Labeled Surface View of Cerebral Cortex (A) Lateral view of left hemisphere. (B) Medial view of right hemisphere. (C) Inferior view. (D) Superior view.

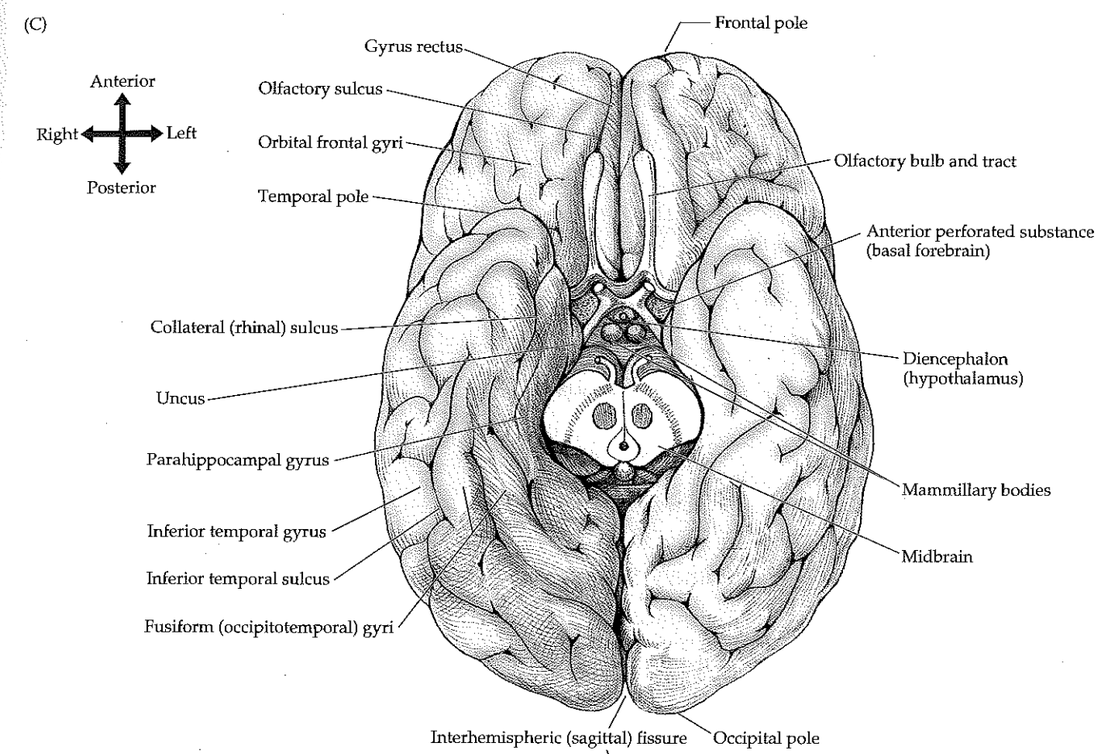

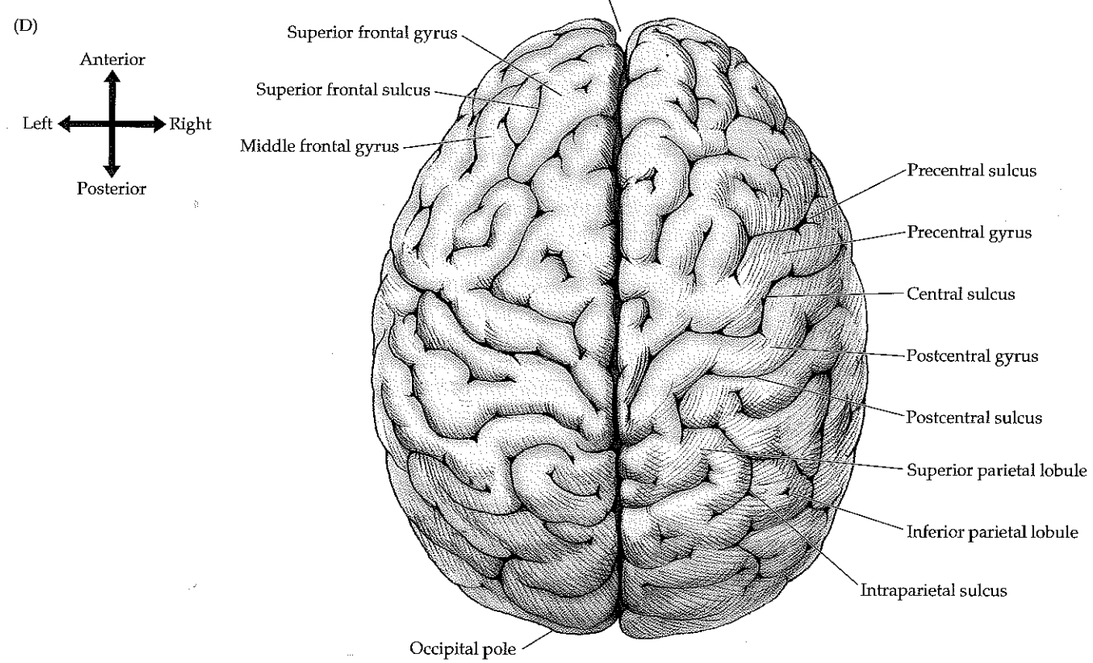

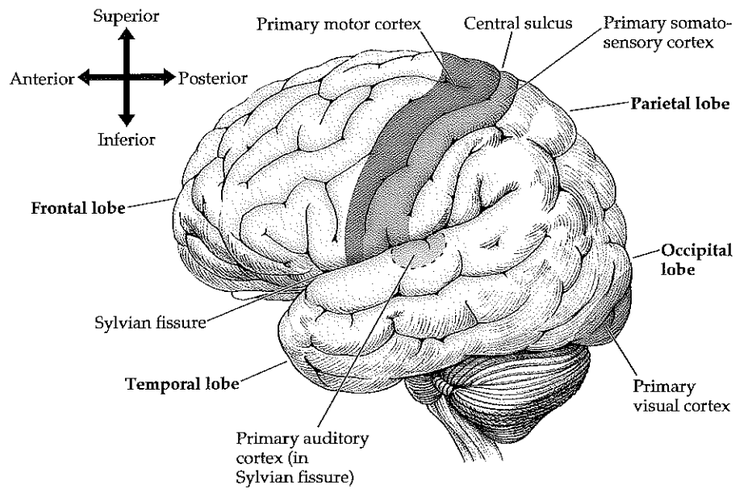

Figure 2.12 Primary Sensory and Motor Cortical Areas

Primary Sensory and Motor Areas

The primary sensory and motor areas of the cortex are shown in Figure 2.12. The **primary motor cortex** lies in the **precentral gyrus** in the frontal lobe (see Figure 2.11A). This area controls movement of the opposite side of the body. The **primary somatosensory cortex** is in the **postcentral gyrus** in the parietal lobe and is involved in sensation for the opposite side of the body. Note that the precentral and postcentral gyri are separated by the **central sulcus,** and that (as in the spinal cord) motor areas lie anterior to somatosensory areas. The **primary visual cortex** is in the occipital lobes along the banks of a deep sulcus called the **calcarine fissure** (see Figures 2.11B, 2.12). The **primary auditory cortex** is composed of the **transverse gyri of Heschl,** which are two fingerlike gyri that lie inside the Sylvian fissure on the superior surface of each temporal lobe (see Figures 2.12, 2.24B). Higher-order sensory and motor information processing takes place in the association cortex, as will be discussed later in this chapter.

Sensory and motor pathways are usually **topographically organized.** This means that adjacent areas on the receptive (or motor) surface are mapped to adjacent fibers in white matter pathways and to adjacent regions of cortex. For example, in primary motor and primary somatosensory cortex, regions representing the hand are adjacent to regions representing the arm and so on (Figure 2.13). These **somatotopic** maps on the cortex are sometimes called the motor or sensory **homunculus** ("little man"). Similarly, adjacent retinal areas are mapped in a **retinotopic** fashion onto the primary visual cortex, and adjacent regions of the cochlea sensing different frequencies have a **tonotopic** representation on the primary auditory cortex.

Interestingly, the primary somatosensory cortex and primary motor cortex represent sensation and movement, respectively, for the opposite side of the body. This relationship was first noted by physicians in ancient Greece, including Hippocrates, who observed that patients with head injuries had deficits affecting the side of the body opposite to the side of the injury. Knowledge of the levels at which the somatosensory and motor pathways cross over in the nervous system can be helpful for clinical neuroanatomical localization, and will be discussed later in this chapter. The primary visual cortex represents visual inputs from the opposite *visual field.* Thus the left half of the visual field *for each eye* is mapped to the right primary visual cortex (see Figure 11.15). Information reaching the primary auditory cortex is less lateralized, and represents more of a mixture of inputs from both ears (the input from the opposite ear is slightly stronger, but this is usually not clinically detectable).

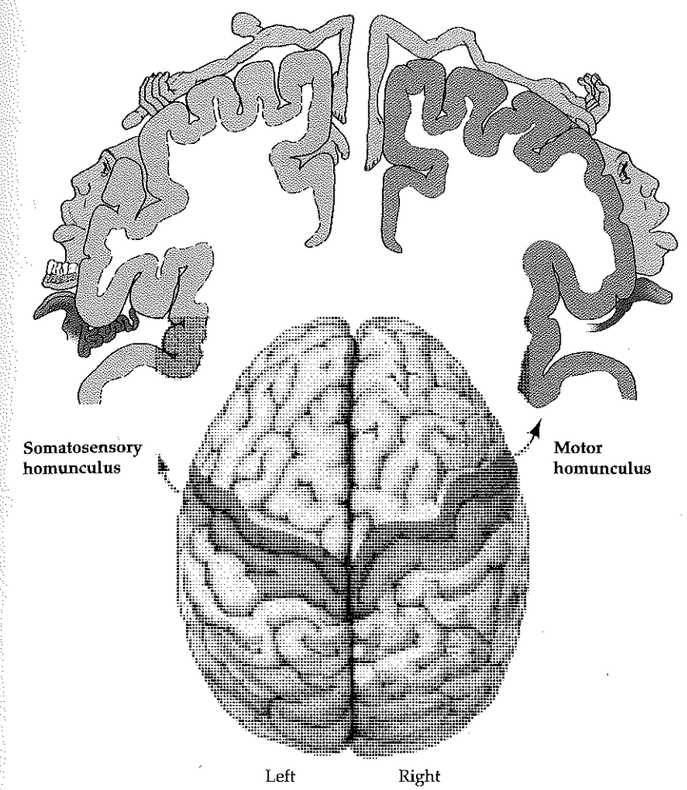

Figure 2.13 Somatotopic Maps in the Cortex Somatosensory homunculus in postcentral gyrus of left hemisphere, and motor homunculus in precentral gyrus of right hemisphere.

Cell Layers and Regional Classification of the Cerebral Cortex

The majority of the cerebral cortex is composed of **neocortex,** which has **six cell layers,** labeled I through VI counting from the surface inward (Figure 2.14; Table 2.3). In a few regions associated with the limbic system, less than six layers are present. Neocortical circuitry is quite complex, and we will describe only a few of the major connections of each layer here. **Layer I** contains mainly dendrites of neurons from deeper layers and axons. **Layers II** and **III** contain neurons that project mainly to other areas of cortex. **Layer IV** receives the majority of inputs from the thalamus. **Layer V** projects mostly to subcortical structures other than the thalamus, such as the brainstem, spinal cord, and basal ganglia. **Layer VI** projects primarily to the thalamus. In addition to these connections, numerous other circuits exist between and within the cortical layers that are beyond the scope of this discussion. The cortical layers I to VI also have names that will not be used here but are included in Table 2.3 for reference.

The relative thickness of the cell layers varies according to the main function of that area of cortex. For example, the primary motor cortex has large

Figure 2.14 Layers of the Neocortex
(A–C from Parent, A. 1996. *Carpenter's Human Neuroanatomy*, 9th Ed. Williams & Wilkins, Baltimore).

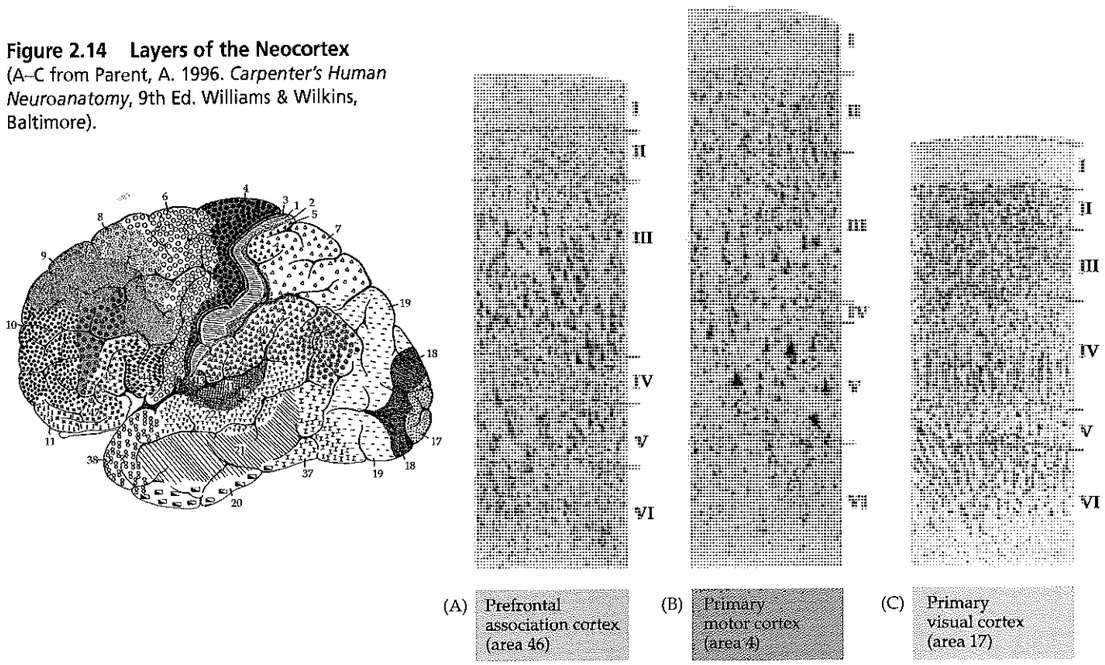

efferent projections to the brainstem and spinal cord, which control movement. It receives relatively little direct sensory information from thalamic relay centers. Therefore, in the primary motor cortex, layer V is thicker and has many more cell bodies than layer IV (see Figure 2.14B). The opposite holds for primary visual cortex, where layer IV contains many cell bodies and layer V is relatively cell poor (Figure 2.14C). Association cortex has a cellular structure that is intermediate between these types (Figure 2.14A).

A variety of classification schemes exist for different regions of the cerebral cortex based on microscopic appearance and function. The most widely known of these was published by Korbinian **Brodmann** in 1909. On the basis of microscopic studies, Brodmann parceled the cortex into 52 **cytoarchitectonic areas,** each assigned a number corresponding to the order in which he prepared the slides (Figure 2.15; Table 2.4). It turns out that many of the areas identified by Brodmann correlate fairly well with various functional areas of the cortex, and therefore his nomenclature is still often used today.

TABLE 2.3 Cell Layers of the Neocortex

LAYER	NAME	ALTERNATIVE NAME	MAIN CONNECTIONS
I	Molecular layer		Dendrites and axons from other layers
II	Small pyramidal layer	External granular layer	Cortical–cortical connections
III	Medium pyramidal layer	External pyramidal layer	Cortical–cortical connections
IV	Granular layer	Internal granular layer	Receives inputs from thalamus
V	Large pyramidal layer	Internal pyramidal layer	Sends outputs to subcortical structures (other than thalamus)
VI	Polymorphic layer	Multiform layer	Sends outputs to thalamus

TABLE 2.4 Brodmann's Cytoarchitectonic Areas

BRODMANN'S AREA	FUNCTIONAL AREA	LOCATION	FUNCTION
1, 2, 3	Primary somatosensory cortex	Postcentral gyrus	Touch
4	Primary motor cortex	Precentral gyrus	Voluntary movement control
5	Tertiary somatosensory cortex; posterior parietal association area	Superior parietal lobule	Stereognosis
6	Supplementary motor cortex; supplementary eye field; premotor cortex; frontal eye fields	Precentral gyrus and rostral adjacent cortex	Limb and eye movement planning
7	Posterior parietal association area	Superior parietal lobule	Visuomotor; perception
8	Frontal eye fields	Superior, middle frontal gyri, medial frontal lobe	Saccadic eye movements
9, 10, 11, 12	Prefrontal association cortex; frontal eye fields	Superior, middle frontal gyri, medial frontal lobe	Thought, cognition, movement planning
17[a]	Primary visual cortex	Banks of calcarine fissure	Vision
18	Secondary visual cortex	Medial and lateral occipital gyri	Vision; depth
19	Tertiary visual cortex, middle temporal visual area	Medial and lateral occipital gyri	Vision, color, motion, depth
20	Visual inferotemporal area	Inferior temporal gyrus	Form vision
21	Visual inferotemporal area	Middle temporal gyrus	Form vision
22	Higher-order auditory cortex	Superior temporal gyrus	Hearing, speech
23, 24, 25, 26, 27	Limbic association cortex	Cingulate gyrus, subcallosal area, retrosplenial area, and parahippocampal gyrus	Emotions
28	Primary olfactory cortex; limbic association cortex	Parahippocampal gyrus	Smell, emotions
29, 30, 31, 32, 33	Limbic association cortex	Cingulate gyrus and retrosplenial area	Emotions
34, 35, 36	Primary olfactory cortex; limbic association cortex	Parahippocampal gyrus	Smell, emotions
37	Parietal–temporal–occipital association cortex; middle temporal visual area	Middle and inferior temporal gyri at junction of temporal and occipital lobes	Perception, vision, reading, speech
38	Primary olfactory cortex; limbic association cortex	Temporal pole	Smell, emotions
39	Parietal–temporal–occipital association cortex	Inferior parietal lobule (angular gyrus)	Perception, vision, reading, speech
40	Parietal–temporal–occipital association cortex	Inferior parietal lobule (supramarginal gyrus)	Perception, vision, reading, speech
41	Primary auditory cortex	Heschl's gyri and superior temporal gyrus	Hearing
42	Secondary auditory cortex	Heschl's gyri and superior temporal gyrus	Hearing
43	Gustatory cortex (?)	Insular cortex, frontoparietal operculum	Taste
44	Broca's area; lateral premotor cortex	Inferior frontal gyrus (frontal operculum)	Speech, movement planning
45	Prefrontal association cortex	Inferior frontal gyrus (frontal operculum)	Thought, cognition, planning behavior
46	Prefrontal association cortex (dorsolateral prefrontal cortex)	Middle frontal gyrus	Thought, cognition, planning behavior, aspects of eye movement control
47	Prefrontal association cortex	Inferior frontal gyrus (frontal operculum)	Thought, cognition, planning, behavior

Source: Martin, JH. 1996. *Neuroanatomy Text and Atlas.* McGraw-Hill, New York.

[a]Areas 13, 14, 15, and 16 are part of the insular cortex.

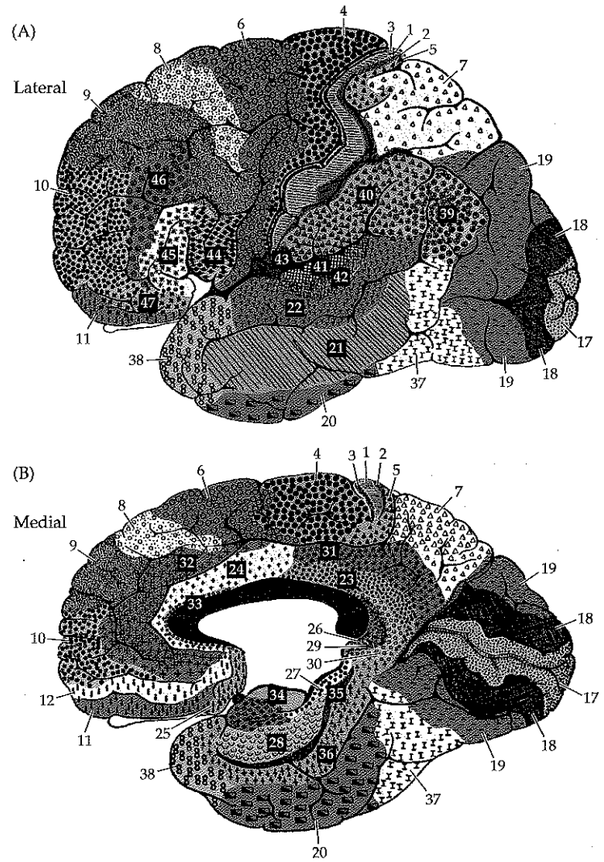

Figure 2.15 Brodmann's Cytoarchitectonic Areas (A) Lateral view of left hemisphere. (B) Medial view of right hemisphere.

Motor Systems

Motor control involves a delicate balance between multiple parallel pathways and recurrent feedback loops. We will now provide an overview of the most important motor pathways, and of the cerebellum and basal ganglia, which are major feedback systems.

Main Motor Pathways

The most important motor pathway in humans is the **corticospinal tract.** The corticospinal tract begins mainly in the primary motor cortex, where neuron cell bodies project via axons down through the cerebral white matter and brainstem to reach the spinal cord (Figure 2.16). The majority of fibers in the corticospinal tract (about 85%) cross over to control movement of the opposite side of the body. This crossing over, known as the **pyramidal decussation,** occurs at the junction between the medulla and the spinal cord. Thus, lesions occurring above the pyramidal decussation produce **contralateral** (opposite-sided) weakness with respect to the lesion, while lesions below the pyramidal decussation will produce **ipsilateral** (same-sided) weakness. Several other descending motor pathways that exist in addition to the corticospinal tract will be discussed in Chapter 6.

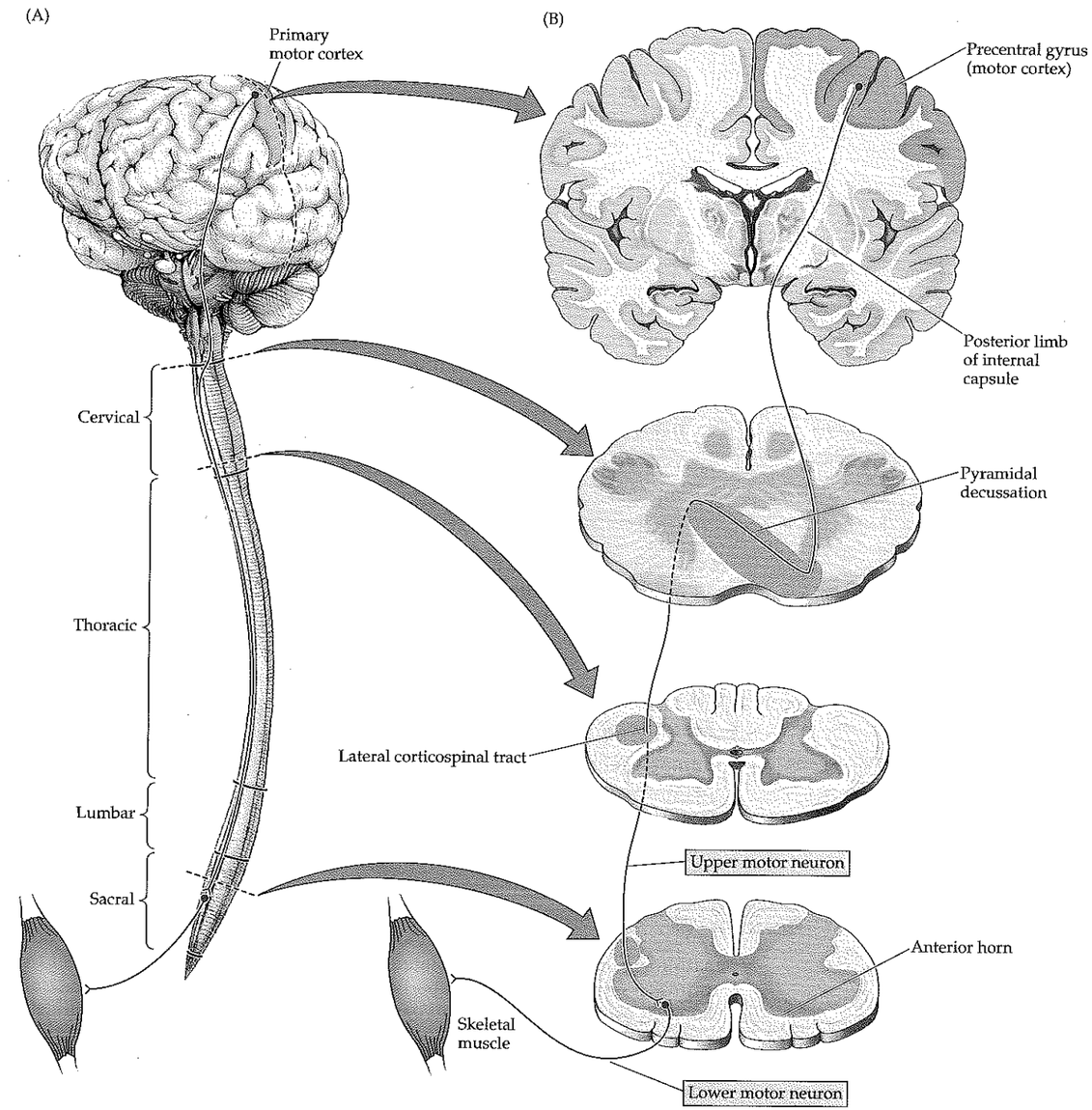

Figure 2.16 Overview of Corticospinal Tract (A) Pathway of upper motor neuron from motor cortex to lower motor neuron in contralateral spinal cord. (B) Representative sections through the cerebral cortex, pyramidal decussation, and spinal cord showing corticospinal tract.

Motor neurons that project from the cortex down to the spinal cord or brainstem are referred to as **upper motor neurons (UMNs)**. UMNs form synapses onto the **lower motor neurons (LMNs)**, which are located in the **anterior horns** of the **central gray matter** of the spinal cord (see Figure 2.16B) or in **brainstem motor nuclei.** The axons of LMNs project out of the CNS via the anterior spinal roots or via the cranial nerves to finally reach muscle cells in the periphery. Lesions affecting UMNs and LMNs have certain distinct clinical features, which we will learn about in Chapter 3.

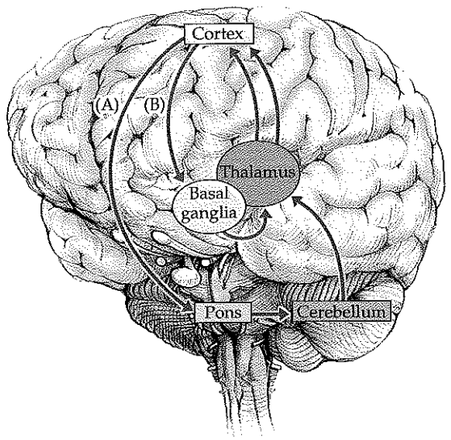

Figure 2.17 Overview of Basal Ganglia and Cerebellar Circuits (A) Feedback loop (red arrows) between motor cortex, pons, cerebellum, thalamus, and back to cortex. (B) Feedback loop (blue arrows) between motor cortex, basal ganglia, thalamus, and back to cortex.

Cerebellum and Basal Ganglia

The motor system is called upon to perform many delicate and complicated tasks. Therefore, in order to refine the output of the motor system, multiple feedback systems are employed, including the **cerebellum** and **basal ganglia** (Figure 2.17). These two systems do not themselves project directly to the LMNs. Instead, the cerebellum and basal ganglia act by modulating the output of the corticospinal and other descending motor systems. The cerebellum and basal ganglia both receive major inputs from the motor cortex. The cerebellum also receives significant inputs from the brainstem and spinal cord, as discussed in Chapter 15. The cerebellum and basal ganglia, in turn, project back to the motor cortex via the thalamus.

Lesions in the cerebellum lead to disorders in coordination and balance, often referred to as **ataxia.** Lesions in the basal ganglia cause **hypokinetic movement disorders,** such as **Parkinsonism,** in which movements are infrequent, slow, and rigid, and **hyperkinetic movement disorders,** such as **Huntington's disease,** which is characterized by dancelike involuntary movements.

Somatosensory Systems

Sensation from the body is conveyed by parallel pathways mediating different sensory modalities that travel to the central nervous system. We will now review the most important sensory pathways and introduce the thalamus, a major relay center for signals of all kinds (sensory and other) that travel to the cerebral cortex.

Main Somatosensory Pathways

Somatic sensation refers to the conscious perceptions of touch, pain, temperature, vibration, and **proprioception** (limb or joint position sense). There are two main pathways in the spinal cord for somatic sensation:

1. The **posterior column pathways** (Figure 2.18) convey proprioception, vibration sense, and fine, discriminative touch.
2. The **anterolateral pathways** (Figure 2.19) convey pain, temperature sense, and crude touch.

Some aspects of touch sensation are carried by both pathways, so touch sensation is not eliminated in isolated lesions of either pathway. Note that the **primary sensory neuron** cell bodies are located outside the CNS in the **dorsal root ganglia** and that they have bifurcating axons, with one long process extending to the periphery and one into the spinal cord (see Figures 2.18 and 2.19). Equally as important as the knowledge that the corticospinal tract crosses over at the pyramidal decussation, which allows us to localize lesions, is the knowledge of where in the CNS the two main sensory pathways cross over. These two main sensory pathways are, therefore, briefly outlined here.

POSTERIOR COLUMN PATHWAY. Primary sensory neuron axons carrying information about proprioception, vibration sense, and fine touch enter first the spinal cord via the dorsal roots and then the ipsilateral white matter dorsal (posterior) columns to ascend all the way to the dorsal column nuclei in the medulla (see Figure 2.18). It is here that they make synapses onto the secondary sensory neurons, which send out axons that cross over to the other side of the medulla. These axons continue to ascend, now on the contralateral side, and synapse in the thalamus, and from there neurons project to the primary somatosensory cortex in the postcentral gyrus.

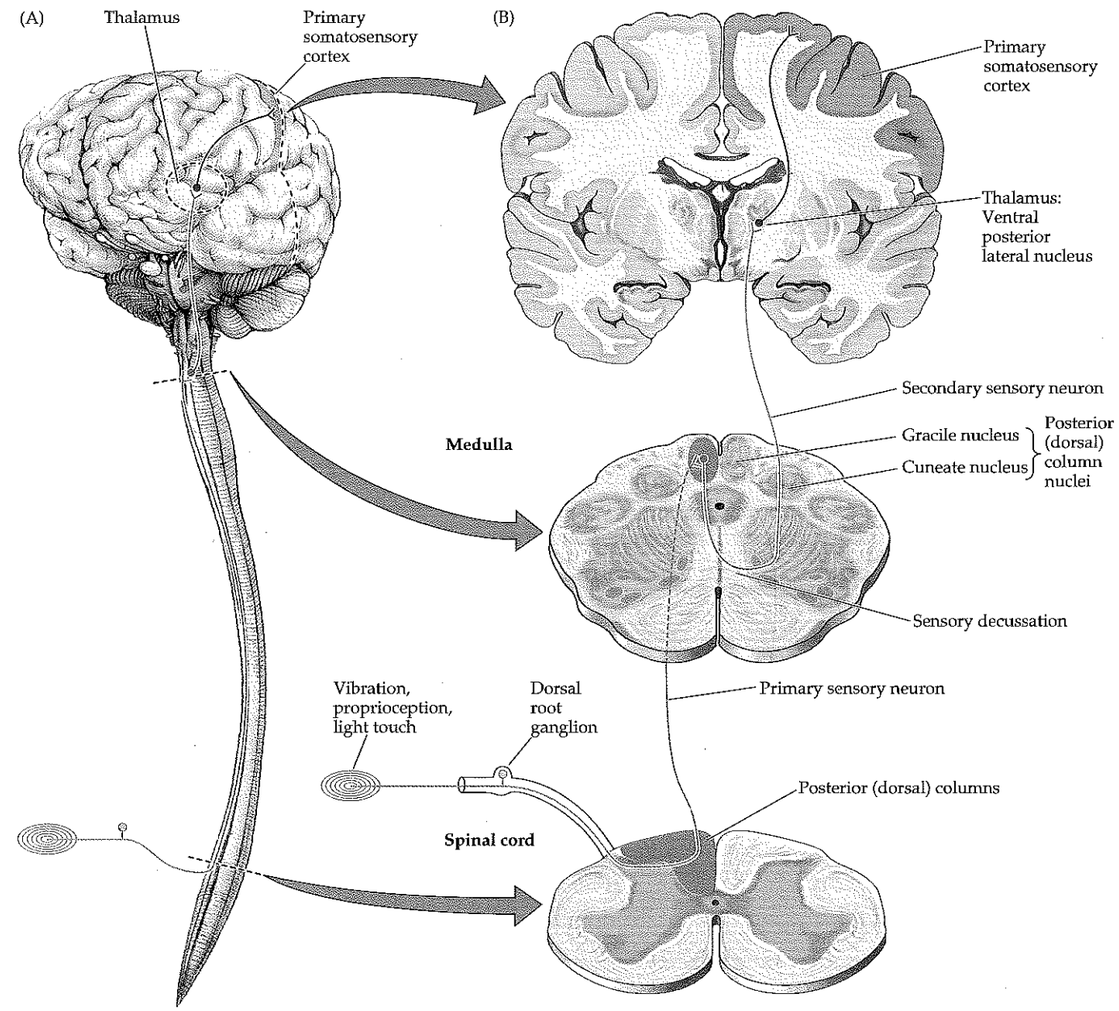

Figure 2.18 Posterior Column Sensory Pathway: Vibration, and Joint Position Sense (A) Pathway from periphery to somatosensory cortex. (B) Representative sections showing pathway through the spinal cord, medulla, thalamus, and cerebral cortex.

ANTEROLATERAL PATHWAY. Primary sensory neurons carrying information about pain, temperature sense, and crude touch also enter the spinal cord via the dorsal roots (see Figure 2.19). However, these axons make their first synapses immediately in the gray matter of the spinal cord. Axons from the secondary sensory neurons cross over to the other side of the spinal cord and ascend in the anterolateral white matter, forming the spinothalamic tract. After synapsing in the thalamus, the pathway again continues to the primary somatosensory cortex.

Thalamus

The thalamus is an important relay center. Nearly all pathways that project to the cerebral cortex do so after synapsing in the thalamus. The thalami are gray matter structures located deep within the cerebral white matter just above the brainstem and behind the basal ganglia (see Figures 2.17, 2.20). They are shaped somewhat like eggs, with their posterior ends angled out-

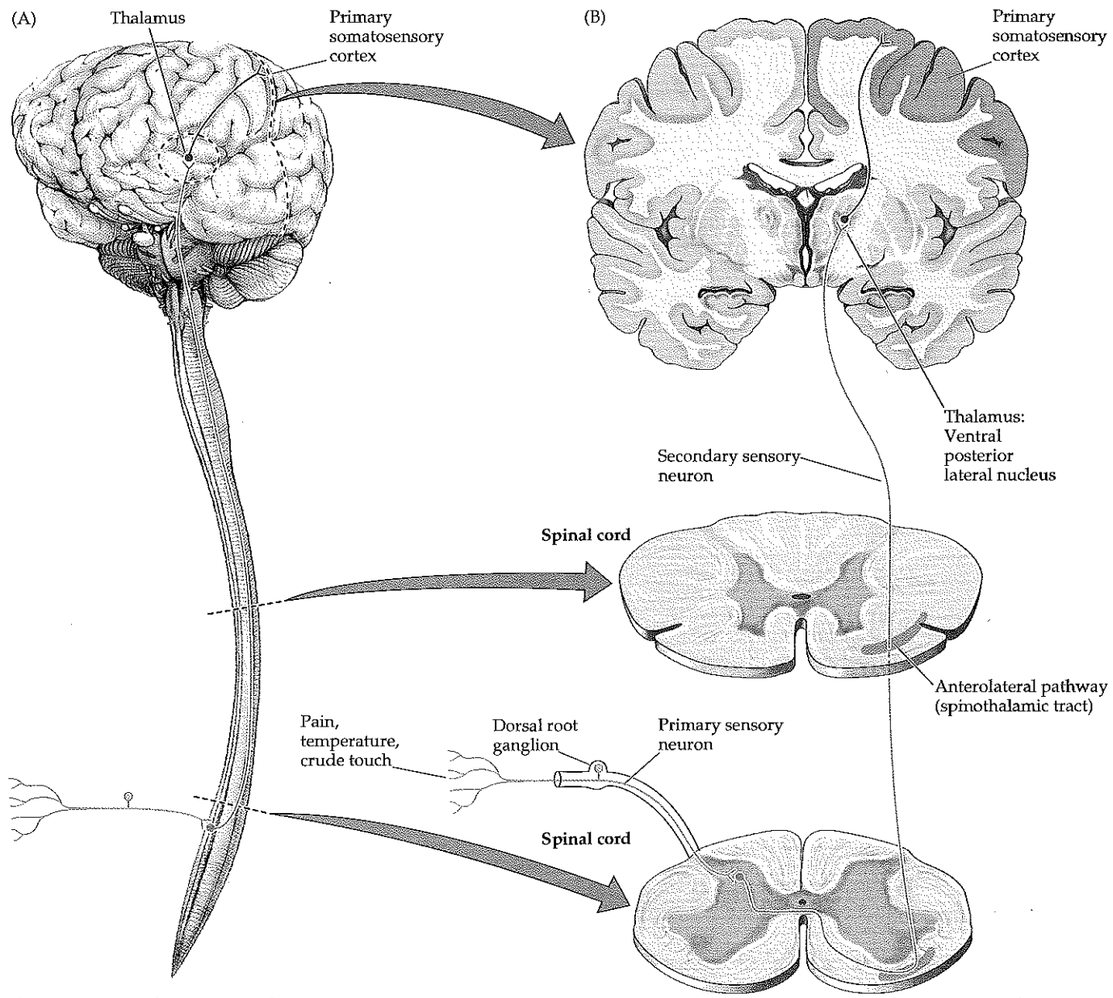

Figure 2.19 Spinothalamic Sensory Pathway: Pain and Temperature
(A) Pathway from periphery to somatosensory cortex. (B) Representative sections showing pathway through the spinal cord, thalamus and cerebral cortex.

ward, together forming an inverted V in horizontal sections (see Figures 2.7A, 2.20B). The thalamus consists of multiple nuclei. Each sensory modality, including vision, hearing, taste, and somatic sensation, has a different nuclear area where synapses occur before the information is relayed to the cortex (olfactory inputs are an exception and do not pass directly through the thalamus). Nonsensory pathways also relay in the thalamus. For example, there are thalamic nuclei that process information coming from the basal ganglia, cerebellum, limbic pathways, and brainstem reticular formation on the way to the cortex (see Figure 2.20A). An important feature of thalamic circuits is the reciprocal nature of cortical–thalamic connections. Thus, virtually all cortical regions project strongly via layer VI (see Table 2.3) back to the thalamic areas from which their major inputs arise.

As we discussed earlier in this chapter, the thalamus, together with the hypothalamus and epithalamus, form the diencephalon (see Figure 2.2). The hypothalamus is an important region for control of autonomic, neuroendocrine,

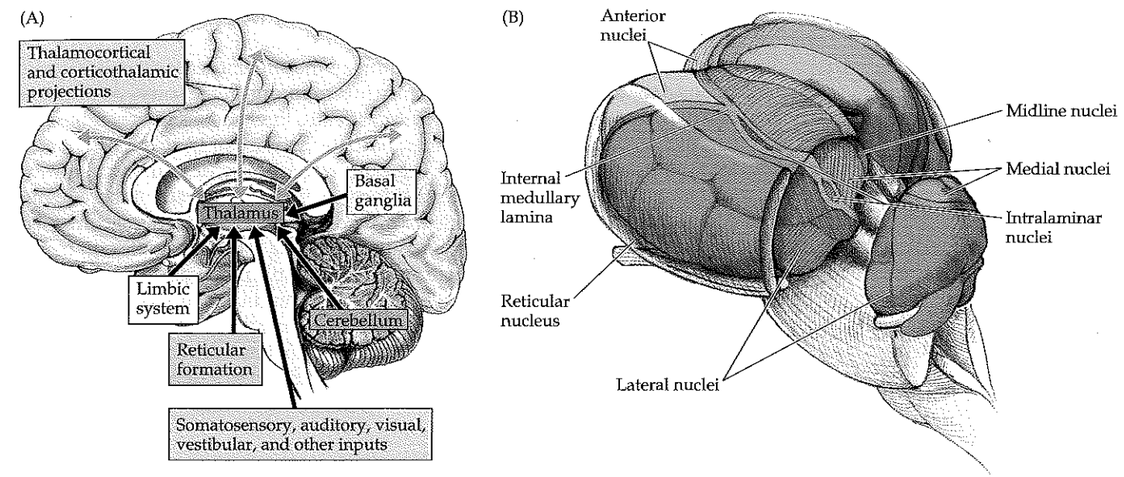

Figure 2.20 The Thalamus
(A) Summary of thalamic inputs and reciprocal connections with the cortex. (B) View of thalami sitting on top of brainstem, demonstrating the major thalamic nuclear divisions. (The posterior portion of the reticular nucleus has been removed.)

limbic, and other circuits. The epithalamus encompasses several small nuclei, including the pineal body (Figure 2.11B), habenula, and parts of the pretectum.

Stretch Reflex

The **monosynaptic stretch reflex** is a well-studied reflex arc that provides rapid local feedback for motor control. The reflex arc begins with specialized receptors called **muscle spindles,** which detect the amount and rate of stretch in muscles (Figure 2.21). This information is transmitted to the distal processes of sensory neurons and is then conveyed via the dorsal roots into the spinal gray matter. In the spinal gray matter the sensory neurons form multiple synapses, including some direct synapses onto LMNs in the anterior horn. The LMNs project via the ventral roots back out to the muscle, causing

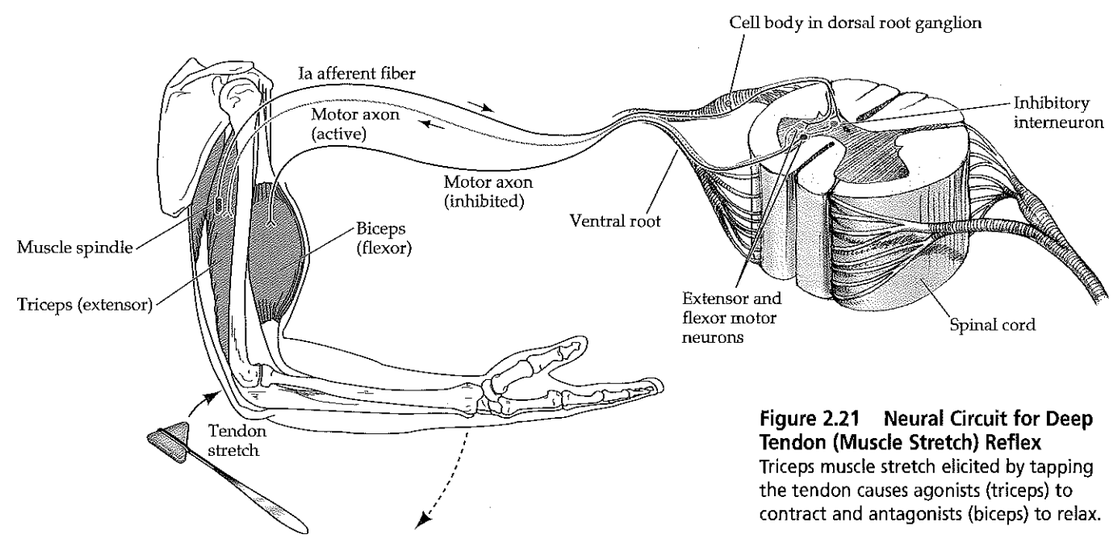

Figure 2.21 Neural Circuit for Deep Tendon (Muscle Stretch) Reflex
Triceps muscle stretch elicited by tapping the tendon causes agonists (triceps) to contract and antagonists (biceps) to relax.

it to contract. Damage anywhere in this pathway (see Figure 2.21) can cause the reflex to be diminished or absent.

In addition to the monosynaptic pathway, the afferent sensory neuron forms synapses onto excitatory and inhibitory **interneurons** in the spinal gray matter, which in turn make synapses onto LMNs. Thus, local circuits in the spinal cord can use sensory information to regulate the activity of LMNs without conscious input from higher centers. There are, nevertheless, descending pathways that modulate the activity of the stretch reflex. As we will learn, if these higher centers or their descending pathways are damaged, the stretch reflex may become **hyperactive** or **hypoactive.** Thus, by testing the stretch reflex on neurologic exam, one obtains information about multiple pathways, including sensory neurons and motor neurons in the PNS, and descending modulatory pathways in the CNS. Since the stretch reflex is often tested on neurologic exam by tapping over a tendon with the reflex hammer (see Chapter 3, or www.neuroexam.com), this is also commonly known as a **deep tendon reflex.**

Brainstem and Cranial Nerves

The overall structure of the brainstem can be seen in Figure 2.22. As discussed earlier, it is composed of the midbrain, pons, and medulla. The brainstem is connected to the diencephalon rostrally, the cerebellum dorsally, and the spinal cord caudally (see Figure 2.2C). Most of the **cranial nerves** arise from the brainstem. The cranial nerves are analogous in some ways to the spinal nerves, having both sensory and motor functions. However, they also

Figure 2.22 Brainstem and Cranial Nerves The cerebral hemispheres and cerebellum have been removed, but the thalami have been left intact at the top of the brainstem (midbrain, pons, and medulla). (A) Ventral view. (B) Dorsal view. (C) Lateral view.

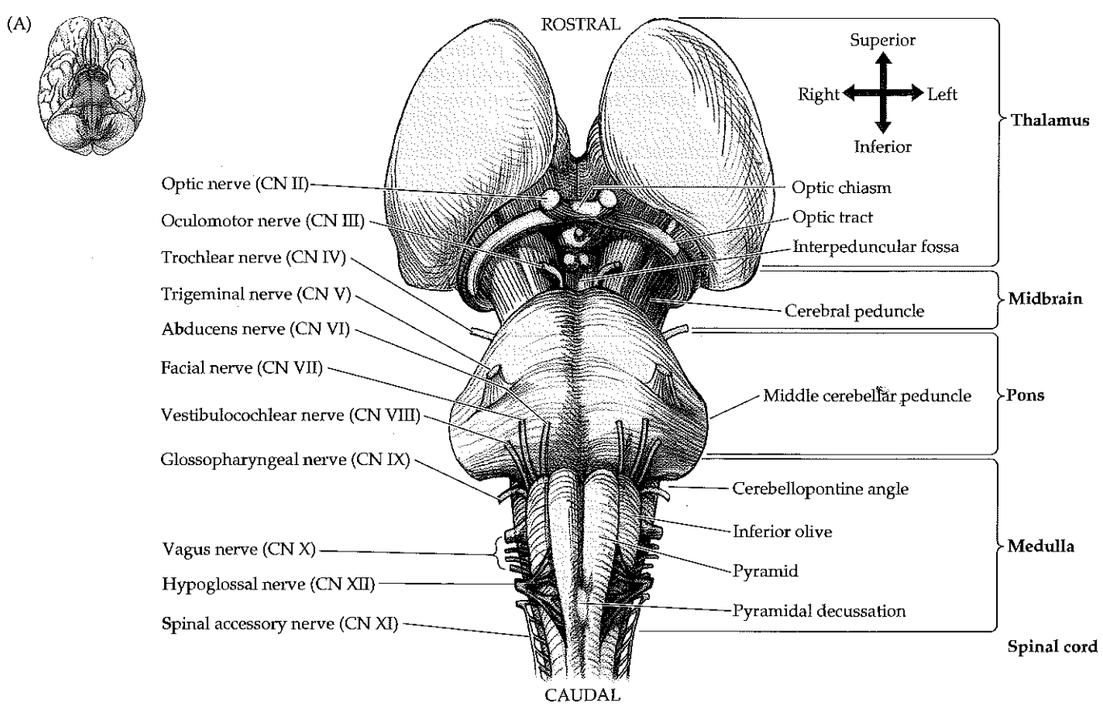

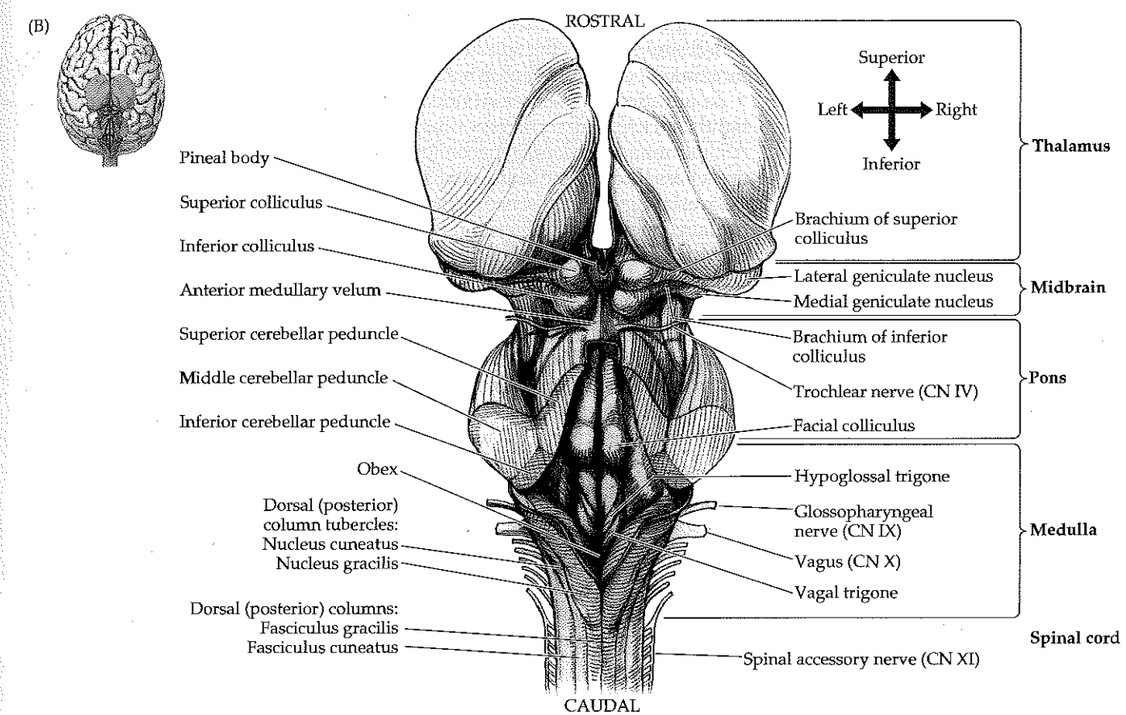

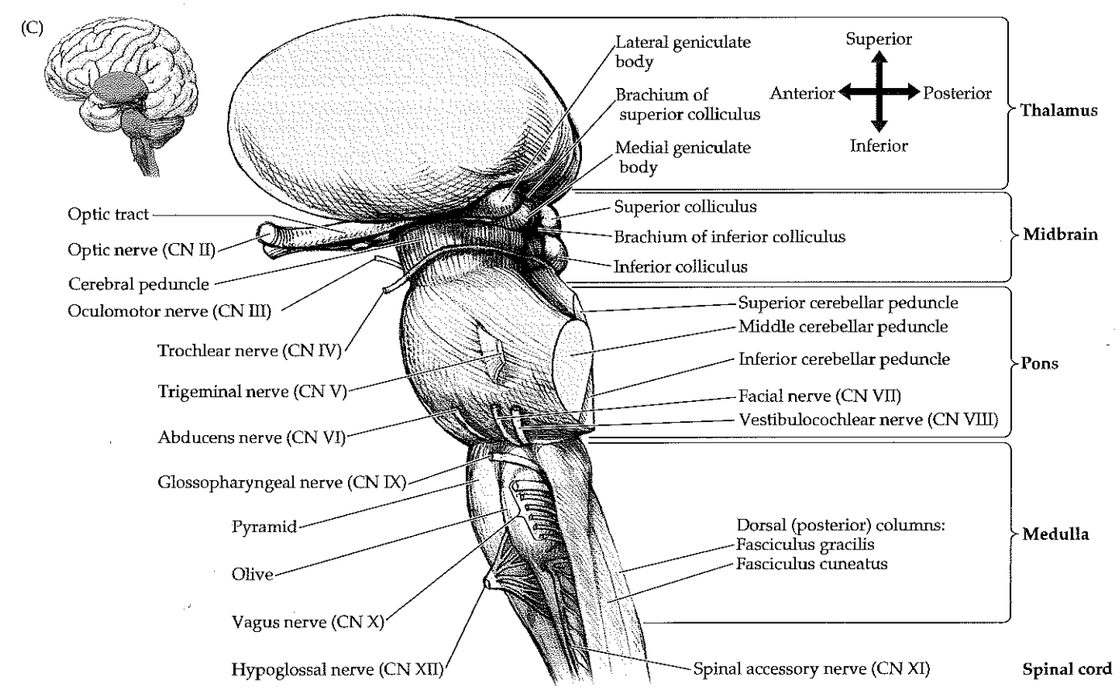

carry out more specialized functions relating to the organs of the head (Table 2.5). Examination of the cranial nerves provides crucial information about the functioning of the nervous system, as we will discuss in the next chapter.

In addition to the cranial nerve nuclei and pathways, the brainstem is tightly packed with numerous other important nuclei and white matter tracts. All information passing between the cerebral hemispheres and the spinal cord must pass through the brainstem. Therefore, lesions in the brainstem can have a devastating effect on sensory and motor function. In addition, the brainstem contains nuclei that play important roles in the motor system; nuclei that produce nausea and vomiting in response to certain chemicals; modulatory nuclei containing the neurotransmitters norepinephrine, serotonin, dopamine, and acetylcholine (see Table 2.2), which project widely throughout the CNS; nuclear areas involved in pain modulation; and nuclei controlling heart rate, blood pressure, and respiration, among other functions.

An important region of the brainstem that contains many of these nuclei is the **reticular formation.** Named for the networklike appearance of its fibers in histological sections, the reticular formation extends throughout the central portions of the brainstem from the medulla to the midbrain. The more caudal portions of the reticular formation in the medulla and lower pons tend to be involved mainly in motor and autonomic functions. The rostral reticular formation in the upper pons and midbrain plays an important role in regulating the **level of consciousness,** influencing higher areas mainly through modulation of thalamic activity (Figure 2.23). Thus, lesions that affect the pontomesencephalic reticular formation can cause lethargy and coma.

Cortical, thalamic, and other forebrain networks are also important in maintaining consciousness. Therefore, the level of consciousness can also be impaired in bilateral lesions of the thalami or in bilateral (or large unilateral) lesions of the cerebral hemispheres. Note that mass lesions above the brainstem often cause impaired consciousness indirectly when they exert pressure on the brainstem through mass effect, thus distorting or compressing the reticular formation.

REVIEW EXERCISE

As was suggested with the cerebral hemispheres (Figure 2.11), at this point you should become acquainted with the brainstem and cranial nerves by covering the labels in Figure 2.22A–C and attempting to name as many structures as possible. Also, cover the right columns in Table 2.5 and name the cranial nerves and their main functions. Like the cerebral hemipheres, the brainstem and cranial nerves will become familiar companions throughout this text.

TABLE 2.5 Overview of the Cranial Nerves

NERVE	NAME	FUNCTIONS
CN I	Olfactory nerve	Olfaction
CN II	Optic nerve	Vision
CN III	Oculomotor nerve	Extraocular muscles, except those innervated by CN IV and VI; parasympathetics to pupil constrictor and to ciliary muscles of lens for near vision
CN IV	Trochlear nerve	Superior oblique muscle; causes the eye to move downward and to rotate inward (depression and intorsion)
CN V	Trigeminal nerve	Sensations of touch, pain, temperature, vibration, and joint position for the face, mouth, nasal sinuses, and meninges; muscles of mastication; tensor tympani muscle
CN VI	Abducens nerve	Lateral rectus muscle; causes abduction (outward movement) of the eye
CN VII	Facial nerve	Muscles of facial expression; also stapedius muscle and part of digastric; taste from anterior two-thirds of tongue; sensation from a region near the ear; parasympathetics causing lacrimation and supplying the submandibular and sublingual salivary glands
CN VIII	Vestibulocochlear nerve	Hearing; vestibular sensation
CN IX	Glossopharyngeal nerve	Stylopharyngeus muscle; taste from posterior one-third of tongue; sensation from posterior pharynx, and from a region near the ear; chemo- and baroreceptors of the carotid body; parasympathetics to the parotid gland
CN X	Vagus nerve	Pharyngeal muscles (swallowing); laryngeal muscles (voicebox); parasympathetics to the heart, lungs, and digestive tract up to the splenic flexure; taste from epiglottis and pharynx; sensation from the pharynx, posterior meninges, and a region near the ear; aortic arch chemo- and baroreceptors
CN XI	Spinal accessory nerve	Sternomastoid muscle; upper part of the trapezius muscle
CN XII	Hypoglossal nerve	Intrinsic muscles of the tongue

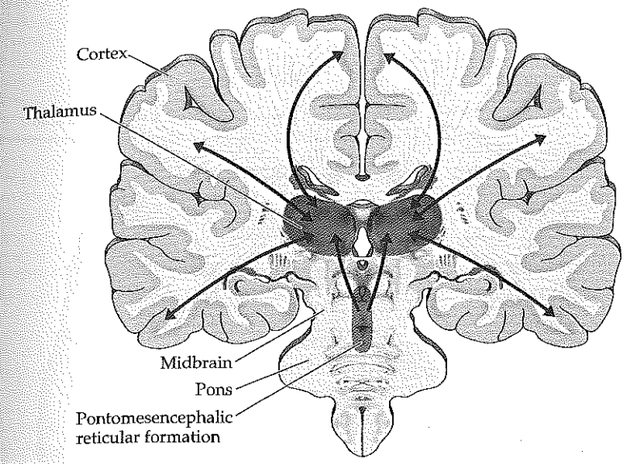

Figure 2.23 Simplification of Brainstem, Thalamic, and Cortical Circuits Important for Maintaining Consciousness

Limbic System

Several structures in the brain are referred to collectively as the **limbic system** because they are located near the medial edge or fringe (*limbus* in Latin) of the cerebral cortex (Figure 2.24). These structures have evolved from a system devoted mainly to olfaction in simpler animals to perform diverse functions, including the regulation of emotions, memory, appetitive drives, and autonomic and neuroendocrine control. The limbic system includes certain cortical areas located in the medial and anterior temporal lobes (Figure 2.24A), anterior insula (see Figure 2.24B), inferior medial frontal lobes, and cingulate gyri. It also includes deeper structures, such as the **hippocampal formation** and the **amygdala,** located within the medial temporal lobes (see Figure 2.24A), several nuclei in the medial thalamus, hypothalamus, basal ganglia, septal area, and brainstem. These areas are interconnected by a variety of pathways, including the **fornix,** a paired, arch-shaped white matter structure that connects the hippocampal formation to the hypothalamus and septal nuclei (see Figure 2.24A).

Lesions in the limbic system can cause deficits in the consolidation of immediate recall into longer-term memories. Thus, patients with lesions in these areas may have no trouble recalling remote events but have difficulty forming new memories. In addition, limbic dysfunction can cause behavioral changes and may underlie a number of psychiatric disorders. Finally, epileptic seizures most commonly arise from the limbic structures of the medial temporal lobe, resulting in seizures that may begin with emotions such as fear, memory distortions such as déjà vu, or olfactory hallucinations.

Association Cortex

In addition to the primary motor and sensory areas described earlier, the cerebral cortex contains a large amount of **association cortex** (Figure 2.25), which carries out higher-order information processing. In **unimodal** association cortex, higher-order processing takes place mostly for a single sensory or motor

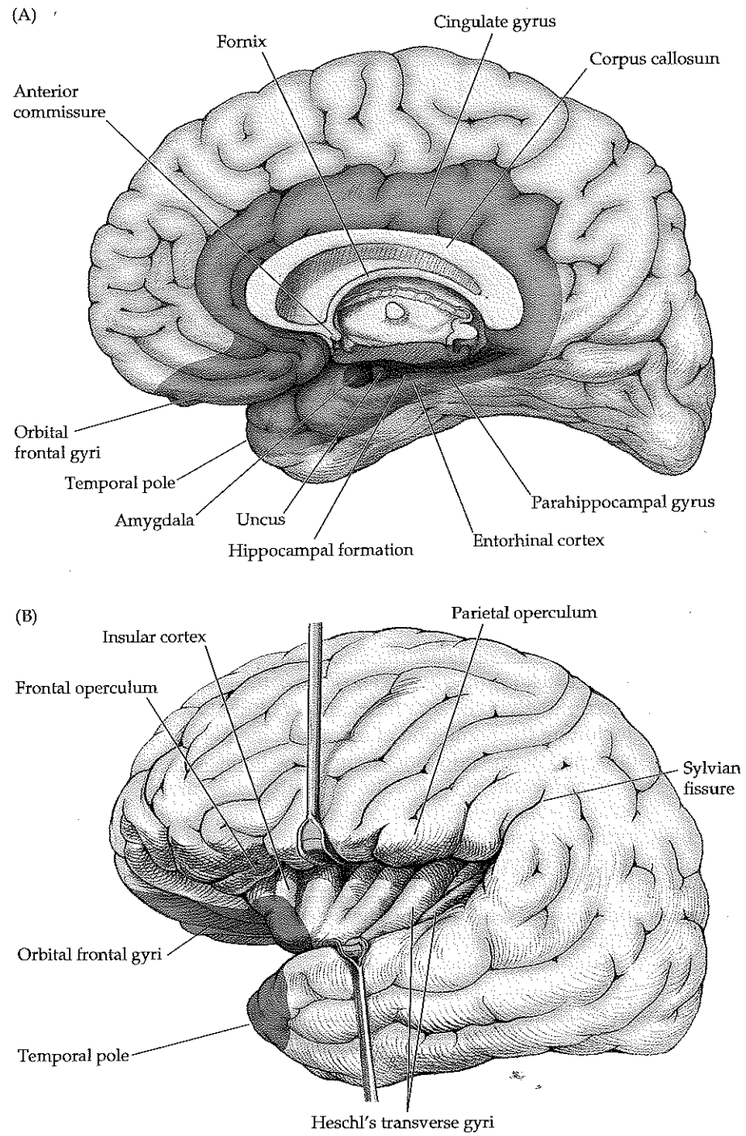

Figure 2.24 Limbic System Structures Components of the limbic system in the diencephalon and brainstem are not shown. (A) Medial view, with brainstem removed. (B) Lateral view, with Sylvian fissure opened using retractors.

modality. Unimodal association cortex is usually located adjacent to a primary motor or sensory area; for example, unimodal visual association cortex is located adjacent to the primary visual cortex, and unimodal motor association cortex (premotor cortex and supplementary motor area) is located adjacent to the primary motor cortex (see Figure 2.25). **Heteromodal** association cortex is involved in integrating functions from multiple sensory and/or motor modalities. We will now briefly review the functions of several clinically important areas of association cortex, particularly since we will describe how to examine these structures with the Mental Status exam in the next chapter.

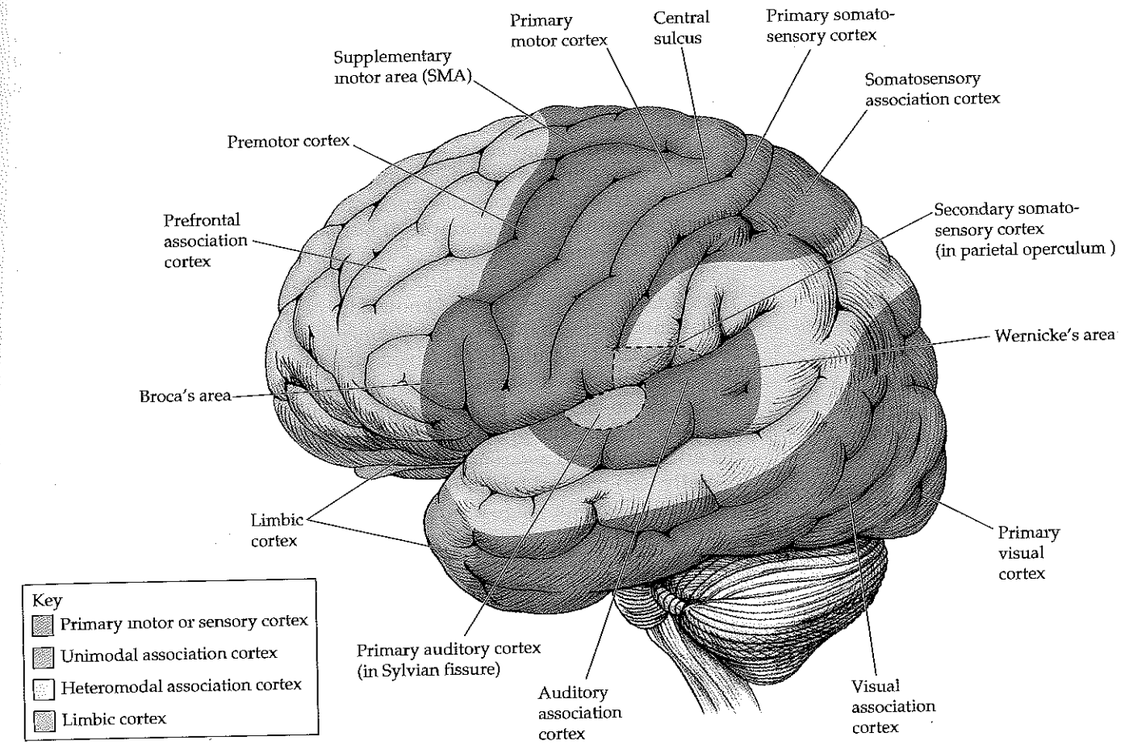

Figure 2.25 Association Cortex Lateral view of left hemisphere showing main areas of primary sensory and motor cortex, unimodal association cortex, and heteromodal association cortex.

Language is usually perceived first by the primary auditory cortex in the superior temporal lobe when we are listening to speech or by the primary visual cortex in the occipital lobes when we are reading. From here, cortical–cortical association fibers convey information to **Wernicke's area** in the **dominant** (usually left) **hemisphere** (see Figure 2.25). Lesions in Wernicke's area cause deficits in language comprehension, also sometimes called **receptive** or **sensory aphasia,** or **Wernicke's aphasia. Broca's area** is located in the frontal lobe, also in the left hemisphere, adjacent to the areas of primary motor cortex involved in moving the lips, tongue, face, and larynx. Lesions in Broca's area cause deficits in the production of language, with relative sparing of language comprehension. This is called **expressive** or **motor aphasia,** or **Broca's aphasia**, which can be remembered by the mnemonic "Broca's broken *boca*" ("*boca*" means "mouth" in Spanish).

MNEMONIC

The parietal lobe is divided by the intraparietal sulcus into a superior and inferior parietal lobule (see Figures 2.11A and 2.25). Lesions in the inferior parietal lobule in the left hemisphere can produce an interesting constellation of abnormalities, including difficulty with calculations, right–left confusion, inability to identify fingers by name (**finger agnosia**), and difficulties with written language. This group of abnormalities is called **Gerstmann's syndrome.**

Performance of complex motor tasks, such as brushing one's teeth or throwing a baseball, requires higher-order planning before the primary motor cortex can be activated. Motor planning appears to be distributed in many different areas of cortex. Thus, diffuse lesions of the cortex, or sometimes more focal lesions affecting the frontal or left parietal lobe, can produce abnormalities in motor conceptualization, planning, and execution called **apraxia.**

The parietal lobes also play an important role in spatial awareness. Thus, lesions in the parietal lobe, especially in the **nondominant** (usually right) **hemisphere** often cause a distortion of perceived space and neglect of the contralateral side. For example, right parietal lesions can cause left **hemineglect.** With this syndrome, patients will often ignore objects in their left visual field, but they may see them if their attention is strongly drawn to that side. They may draw a clock face without filling in any numbers on the left side of the clock. They may also be completely unaware of the left side of their body, thinking, for example, that their left arm belongs to someone else, and they may be unaware of any weakness or other deficits on that side. Unawareness of a deficit is called **anosognosia** (from the Greek *a*, "lack"; *nosos*, "disease"; *gnosis*, "knowledge").

Patients may also display a phenomenon called **extinction,** in which a tactile or visual stimulus is perceived normally when it is presented to one side only, but when it is presented on the side opposite the lesion **simultaneously** with an identical stimulus on the normal side, the patient neglects the stimulus on the side opposite the lesion. These severe abnormalities in spatial orientation and awareness are less common in lesions of the dominant (usually left) parietal lobe, possibly because the dominant hemisphere is more specialized for language than it is for visuospatial functions.

The frontal lobes are the largest hemispheres and contain vast areas of association cortex (see Figure 2.25). Lesions in the frontal lobes cause a variety of disorders in personality and cognitive functioning. **Frontal release signs** are "primitive" reflexes that are normal in infants, such as **grasp, root, suck,** and **snout reflexes,** but that can also be seen in adults with frontal lobe lesions. In addition, patients with frontal lobe lesions may have particular difficulty when asked to perform a sequence of actions repeatedly, or to change from one activity to another. In doing these tasks they tend to **perseverate,** meaning that they repeat a single action over and over without moving on to the next one. Personality changes with frontal lobe lesions may include impaired judgment, a cheerful lack of concern about one's illness, inappropriate joking, and other **disinhibited** behaviors. Other patients with frontal lobe lesions may be **abulic** (opposite of ebullient), with a tendency to stare passively and to respond to commands only after a long delay. Frontal lesions can also cause a characteristic unsteady **magnetic gait,** in which the feet shuffle close to the floor, and **urinary incontinence.** Lesions in the visual association cortex in the parieto-occipital and inferior temporal lobes can produce a variety of interesting phenomena, including **prosopagnosia** (inability to recognize faces), **achromatopsia** (inability to recognize colors), **palinopsia** (persistence or reappearance of an object viewed earlier), and other phenomena. Seizures in the visual association cortex can cause elaborate visual hallucinations.

Blood Supply to the Brain and Spinal Cord

There are two pairs of arteries that carry all the blood supply to the brain and one pair of draining veins (Figure 2.26A,B). The **internal carotid arteries** form the anterior blood supply, and the **vertebral arteries,** which join together in a single **basilar artery,** form the posterior blood supply (see Figure 2.26A). The anterior and posterior blood supplies from the carotid and vertebrobasilar systems, respectively, join together in an anastomotic ring at the base of the brain called the **circle of Willis** (Figure 2.26C). The main arteries supplying the cerebral hemispheres arise from the circle of Willis. Ordinarily, however, the **anterior** and **middle cerebral arteries** derive their main blood

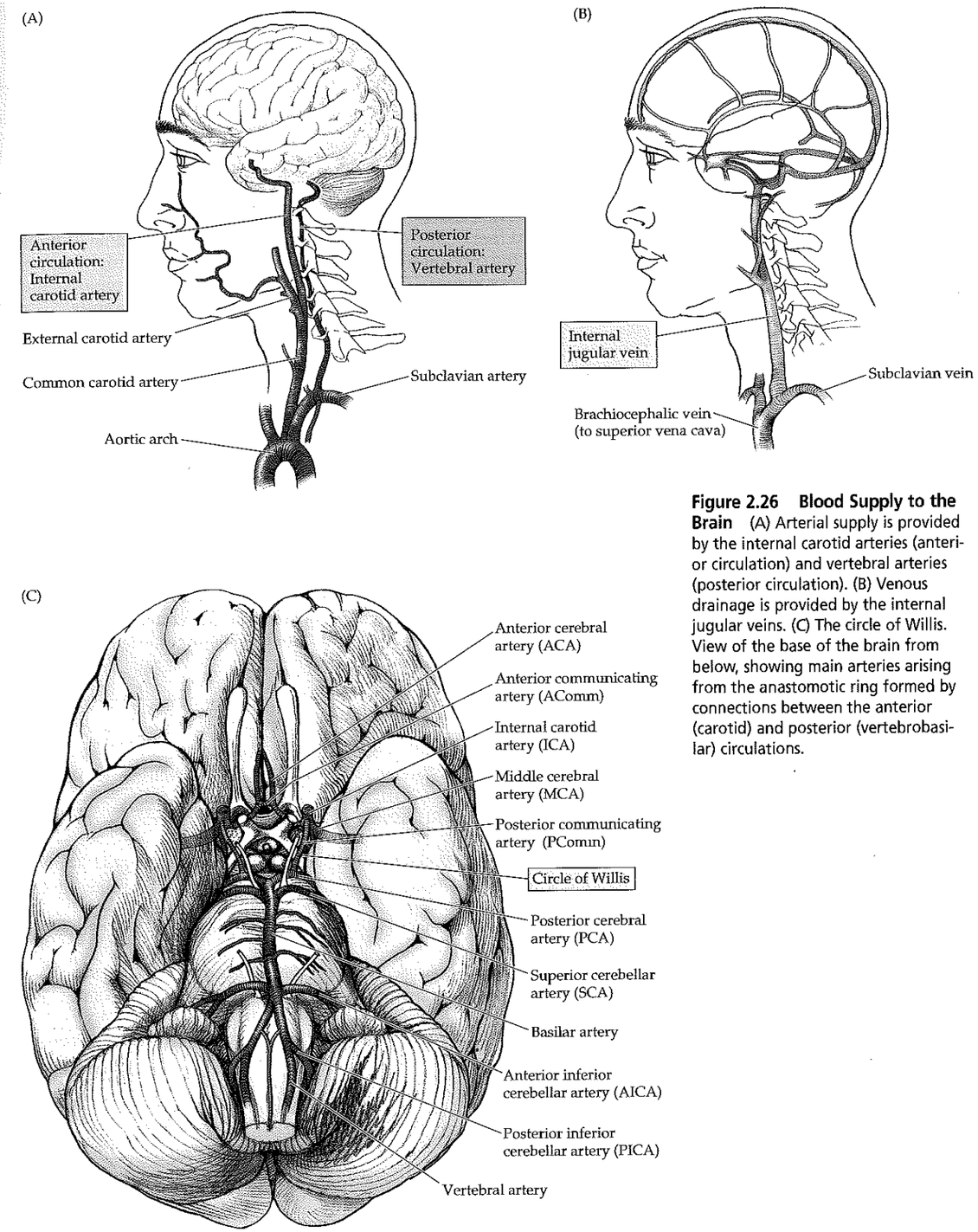

Figure 2.26 Blood Supply to the Brain (A) Arterial supply is provided by the internal carotid arteries (anterior circulation) and vertebral arteries (posterior circulation). (B) Venous drainage is provided by the internal jugular veins. (C) The circle of Willis. View of the base of the brain from below, showing main arteries arising from the anastomotic ring formed by connections between the anterior (carotid) and posterior (vertebrobasilar) circulations.

supply from the internal carotid arteries (anterior circulation), while the **posterior cerebral arteries** derive their main supply from the vertebrobasilar system (posterior circulation). The main arteries supplying the brainstem and cerebellum also arise from the vertebral and basilar arteries. These include the **superior, anterior inferior,** and **posterior inferior cerebellar arteries.** Venous drainage for the brain is provided almost entirely by the **internal jugular veins** (see Figure 2.26B).

The spinal cord receives its blood supply from the **anterior spinal artery,** which runs along the ventral surface of the cord in the midline and from the paired **posterior spinal arteries,** running along the right and left dorsal surfaces of the cord (see Figure 6.5). The anterior and posterior spinal arteries are supplied in the cervical region mainly by branches arising from the vertebral arteries (see Figure 2.26C). In the thoracic and lumbar regions, the spinal arteries are supplied by radicular arteries arising from the aorta.

Conclusions

In this chapter we have reviewed the overall structure and organization of the nervous system. In addition, we have discussed in general terms the functions of each of the main areas in the brain, spinal cord, and peripheral nervous system, and we have briefly reviewed the blood supply to the brain. This overview should provide a framework upon which important details will be filled in and reinforced through clinical cases in the chapters that follow. It also provides the necessary background for the next chapter, in which we will introduce the neurologic exam and explore what each portion of the exam can teach us about neuroanatomy. Thus you, the reader, have completed the rough sketch and now have before you an undertaking that will require innumerable finer and finer brush strokes, each subtly enhancing the final composition.

References

Carpenter MB. 1991. *Core Text of Neuroanatomy,* 4th Ed. Williams & Wilkins, Baltimore, MD.

Cooper JR, Bloom FE, Roth RH. 1996. *The Biochemical Basis of Neuropharmacology,* 7th Ed. Oxford, New York.

Gorman DG, Unutzer J. 1993. Brodmann's "missing" numbers. *Neurology* 43: 226–227.

Kandel ER, Schwartz JH, Jessell TM (eds.). 2000. *Principles of Neural Science,* 4th Ed. McGraw-Hill, New York.

Martin JH. 1996. *Neuroanatomy Text and Atlas,* 2nd Ed. Appleton & Lange, Stamford, CT.

Mesulam MM (ed.). 1985. *Principles of Behavioral Neurology.* FA Davis, Philadelphia.

Purves D, Augustine GJ, Fitzpatrick D, Katz LC, Lamantia A-S, McNamara JO, Williams SM (eds.). 2000. *Neuroscience,* 2nd Ed. Sinauer, Sunderland, MA.

Steriade M, Jones EG, McCormick DA. 1997. *Thalamus.* Elsevier, Oxford, England.

CHAPTER 3

The Neurologic Exam as a Lesson in Neuroanatomy

Overview of the Neurologic Exam

neuroexam.com

The Neurologic Exam: Examination Technique and What Is Being Tested

1. Mental Status
2. Cranial Nerves
3. Motor Exam
4. Reflexes
5. Coordination and Gait
6. Sensory Exam

The Neurologic Exam as a Flexible Tool

Coma Exam

General Physical Exam
1. Mental Status
2. Cranial Nerves
3. Sensory Exam and 4. Motor Exam
5. Reflexes
6. Coordination and Gait

Brain Death

Conversion Disorder, Malingering, and Related Disorders

The Screening Neurologic Exam

Conclusions

Throughout this book, we will encounter case presentations that include findings from the neurologic exam: "A 37-year-old woman suddenly developed pain and numbness in her right shoulder and fingers. Her general physical exam was unremarkable. A neurologic exam showed that her mental status and cranial nerves were normal; motor exam was notable for diminished right triceps strength; reflexes were absent in the right triceps muscle; coordination and gait were normal; and sensation was normal except for diminished pain and temperature sensation in her right index and middle fingers." Performing the neurologic exam carefully, and presenting findings clearly, are crucial to accurately diagnosing and effectively treating patients. Here we will learn about each part of the neurologic exam and its basis in functional neuroanatomy.

Overview of the Neurologic Exam

The neurologic exam as a diagnostic tool gained mythical proportions in the pre-CT/MRI era, when great clinicians could pinpoint a lesion in the nervous system with often astounding accuracy. Decisions for surgery and other interventions were frequently made entirely on the basis of the neurologic history and physical findings. Today, with the availability of modern imaging techniques, the neurologic exam takes on a new and equally important role in diagnosis and management. Rather than serving as an end in and of itself, the neurologic exam today is a critical way station in the clinical decision-making process. Does the patient who just collapsed on the street have cardiac disease or an intracranial bleed? Is the patient with leg weakness and numbness suffering from degenerative joint disease or from impending spinal cord compression? Does the patient with nausea and vomiting need a gastroenterology consult, a head CT, or emergency interventions to lower dangerously elevated intracranial pressure? These, and many similar questions that frequently arise for health care providers in all subspecialties, can quickly be answered by a carefully performed neurologic exam.

We will study the neurologic exam in this chapter with two goals in mind. First, since most of the remainder of the book is based on clinical case presentations, it is important for you to become familiar with the neurologic exam and how to interpret normal and abnormal findings. Second, we will use the neurologic exam in conjunction with the material presented in Chapter 2 to attain an overview of neuroanatomical function and clinical localization.

Although there are some variations in style among clinicians, we will describe the neurologic exam here with a fairly conventional format. This consists of the following six subdivisions:

1. Mental status
2. Cranial nerves
3. Motor exam
4. Reflexes
5. Coordination and gait
6. Sensory exam

REVIEW EXERCISE

For each part of the neurologic exam listed in Table 3.1, use the information from Chapter 2 to imagine what part of the nervous system is being tested, and how the test could be performed.

Table 3.1 provides a more detailed outline of the neurologic exam as it will be presented here.

As we discussed in Chapter 1, the neurologic exam is just one part of patient evaluation. Although we discuss it here separately, the neurologic exam should always be performed and interpreted in the context of a more general assessment. This includes the patient history, general physical exam, which includes the neurologic exam as one part, and finally, other diagnostic tests, such as radiological studies and blood tests. Review the neurologic information that can be learned from the general physical exam as discussed in Chapter 1. Some parts of the general exam with special neurologic significance are again summarized in Table 3.2.

A unique feature of the neurologic exam is that it tests *function*. Each part of the neurologic exam should be used to *titrate* the patient's level of function. To do this, several tests should be used, ranging from the easiest to the most difficult. With each examination, record the tests a patient can and cannot perform. This allows comparison with subsequent examinations, so that changes in the patient's status can be determined accurately.

In the first section of this chapter we will describe how each part of the neurologic exam is performed. We will include discussions of *what is being tested*, correlating clinical findings with neuroanatomy. Much of the material in this first section is also covered in **neuroexam.com** (discussed next), where it is supplemented by video demonstrations.

TABLE 3.1 Outline of the Neurologic Exam

I. MENTAL STATUS
1. Level of alertness, attention, and cooperation
2. Orientation
3. Memory
   - Recent memory
   - Remote memory
4. Language
   - Spontaneous speech
   - Comprehension
   - Naming
   - Repetition
   - Reading
   - Writing
5. Calculations, right–left confusion, finger agnosia, agraphia
6. Apraxia
7. Neglect and constructions
8. Sequencing tasks and frontal release signs
9. Logic and abstraction
10. Delusions and hallucinations
11. Mood

II. CRANIAL NERVES
1. Olfaction
2. Ophthalmoscopic exam (CN II)
3. Vision (CN II)
4. Pupillary responses (CN II, III)
5. Extraocular movements (CN III, IV, VI)
6. Facial sensation and muscles of mastication (CN V)
7. Muscles of facial expression and taste (CN VII)
8. Hearing and vestibular sense (CN VIII)
9. Palate elevation and gag reflex (CN IX, X)
10. Muscles of articulation (CN V, VII, IX, X, XII)
11. Sternocleidomastoid and trapezius muscles (CN XI)
12. Tongue muscles (CN XII)

III. MOTOR EXAM
1. Observation
   - Involuntary movements, tremor, hypokinesia
2. Inspection
   - Muscle wasting, fasciculations
3. Palpation
   - Tenderness, fasciculations
4. Muscle tone
5. Functional testing
   - Drift
   - Fine finger movements
   - Rapid toe tapping
6. Strength of individual muscle groups

IV. REFLEXES
1. Deep tendon reflexes
2. Plantar response
3. Reflexes tested in special situations
   - Suspected spinal cord damage
   - Frontal release signs
   - Posturing

V. COORDINATION AND GAIT
1. Appendicular coordination
   - Rapid alternating movements
   - Finger–nose–finger test
   - Heel–shin test
   - Overshoot
2. Romberg test
3. Gait
   - Ordinary gait
   - Tandem gait
   - Forced gait

VI. SENSORY EXAM
1. Primary sensation—asymmetry, sensory level
   - Pain (sharp versus dull)
   - Temperature (cold versus warm)
   - Vibration and joint position sense
   - Light touch and two-point discrimination
2. Cortical sensation
   - Graphesthesia
   - Stereognosis
3. Extinction

The remaining sections of this chapter describe the usefulness of the neurologic exam in a variety of special circumstances. Since impairment on any portion of the exam may interfere with the ability to test many other functions, examination strategies and limitations in these situations are discussed. Coma is a special situation in which the neurologic exam is pivotal in evaluation; therefore, a separate section is devoted to this topic. We also briefly discuss the neurologic exam in brain death and in patients with conversion disorder, malingering, and related disorders, before presenting a minimal screening form of the neurologic exam at the conclusion of the chapter.

TABLE 3.2 Parts of the General Physical Exam with Special Neurologic Significance

Vital signs, including orthostatics
Ophthalmoscopic exam
Signs of cranial trauma
Bruits
Meningismus
Straight-leg raising
Rectal tone

Note: See also Chapter 1.

The material presented here may be difficult to absorb fully on the first pass, either in print or on the Web. However, by referring back to it while attempting to localize lesions in the clinical cases, you will gradually become proficient in understanding both the neurologic exam and neuroanatomy.

neuroexam.com

A picture, or better yet, a moving picture is worth a thousand words. It is difficult to adequately describe in print the technique used in performing many aspects of the neurologic exam. Therefore, we have provided an interactive website, **neuroexam.com**, which demonstrates through brief streaming video clips how to perform each part of the neurologic exam. The website also includes much of the text contained in the next section, "The Neurologic Exam: Examination Technique and What Is Being Tested." Therefore, if you have access to the Internet, we suggest that you now surf over to neuroexam.com while reading the next section (text from this section also appears on the website). Note, however, that the second half of this chapter, covering the neurologic exam in a variety of special situations, including coma, does not appear on the website.

Some may prefer to read from the book and view video segments selectively. Therefore, in this chapter, and elsewhere in the book when discussing the neurologic exam, we will provide a cross-reference to the relevant video segment on neuroexam.com. The segments can be accessed directly through the "Video Menu" on the website. Alternatively, rather than viewing individual segments, the complete exam can be viewed from start to finish by watching *The NeuroExam Video* (see "How to Use This Book").

The Neurologic Exam: Examination Technique and What Is Being Tested

In this section we will describe the neurologic examination (see Table 3.1) and what is being tested by each part of the exam. Like the general physical examination, different parts of the neurologic exam may be done in more or less detail depending on the clinical suspicion that a particular lesion is present. For example, an emergency neurologic exam in a comatose patient can be performed in less than 2 minutes (see the "Coma Exam" section). In a patient where the suspicion for focal findings on neurological exam is low, a "screening exam" can be completed in the office setting in about 10 minutes, as described at the end of this chapter. In contrast, in a patient with unusual findings, where the diagnosis is uncertain, detailed testing for up to an hour may be required. Sometimes, certain parts of the exam can be combined, or performed in a slightly different order, to minimize the number of times the patient has to change positions. Understanding how to best tailor the exam to the clinical situation comes with experience and practice. The accomplished clinician uses the neurologic exam as a flexible tool. In experienced hands, the neurologic exam remains an unparalleled method both to screen for unsuspected lesions and to test hypotheses for localization.

1. Mental Status

There are many different versions of the mental status exam. The structure provided here follows a fairly standard format and is organized around the anatomy of the brain, as discussed in the section "Association Cortex" in Chapter 2 (see also Chapters 14, 18, and 19). Thus, we begin with tests that involve global brain function and that determine how well we will be able to perform the rest of the exam (level of alertness, attention, and cooperation). We next ask a few standard questions that make for easy comparisons between different patients or different exams of the same patient (orientation). This part of the exam is followed by testing of limbic and global functions (memory); testing of dominant (usually left) hemispheric language functions (language); and additional testing for left parietal dysfunction (Gerstmann's syndrome), right parietal dysfunction (neglect and constructions), and frontal dysfunction (sequencing tasks and frontal release signs). Finally, we conclude with a few more tests that are less localizing but provide important clues about brain dysfunction (apraxia, logic and abstraction, delusions, hallucinations, and mood).

LEVEL OF ALERTNESS, ATTENTION, AND COOPERATION. Be as specific as possible in documenting the level of alertness, making note of what the patient can or cannot do in response to which stimuli (see the section "Coma Exam" later in this chapter). One can test attention by seeing if the patient can remain focused on a simple task, such as spelling a short word forward and backward (W-O-R-L-D/D-L-R-O-W is a standard), repeating a string of integers forward and backward (**digit span**), or naming the months forward and then backward (see neuroexam.com Video 4). Normal digit span is six or more forward, and four or more backward, depending slightly on age and education. It normally takes up to twice as long to recite months backward as forward. Note that these tests of attention depend on language, memory, and some logic functions as well. Degree of cooperation should be noted, especially if it is abnormal, since this will influence many aspects of the exam.

■ ***What Is Being Tested?*** Level of consciousness is severely impaired in damage to the brainstem reticular formation, and in *bilateral* lesions of the thalami or cerebral hemispheres (see Figure 2.23). It may also be mildly impaired in unilateral cortical or thalamic lesions. Toxic or metabolic factors are also common causes of impaired consciousness because of their effects on the structures mentioned here (see KCC 14.2).

Generalized impaired attention and cooperation are relatively nonspecific abnormalities that can occur in many different focal brain lesions, in diffuse abnormalities such as dementia or encephalitis, and in behavioral or mood disorders (see KCC 19.14–19.16).

ORIENTATION: A CAVEAT TO THOSE WHO WRITE "A&O×3." Ask for the patient's full name, the location, and the date, and note the exact response (see neuroexam.com Video 5). It is common practice to use brief phrases in clinical notes such as "alert and oriented" or "alert and oriented to person, place, and time"—abbreviated as "A&O×3"—as a substitute for documenting the full mental status exam. Given realistic time constraints, it is probably reasonable in non-neurologic patients with *normal* mental status to write "A&O×3," as long as the meaning is clear. For patients with compromised mental status, however, it is very important to *document specifically the questions they were asked and how they answered.* This is really the only way to detect changes in a patient's mental status when different doctors are following a patient. For example, for the orientation section on a patient Harry Smith, you *should* write the following:

Name: "Harry Smith"
Location: "Hospital," but does not know which one
Date: "1942," and does not know month, date, or season

You should *never* write instead: "The patient was A&O×2," since this is ambiguous and makes it hard to know what the patient's true mental status was at the time of the exam.

■ *What Is Being Tested?* The main usefulness of this set of questions is that it is so standard. It tests mainly recent and longer-term memory (see below), but as in all other parts of the exam, the response is also influenced by level of alertness, attentiveness, and language capabilities.

MEMORY. **Recent memory.** Ask the patient to recall three items or a brief story for a delay of 3 to 5 minutes (see neuroexam.com Video 6). Be sure the information has been registered by asking the patient to repeat it immediately before initiating the delay. Provide distractions during the delay to prevent the patient from rehearsing the items repeatedly. A timer, such as a digital watch alarm, should be used to provide a consistent interval from patient to patient—and to prevent the examiner from forgetting to ask for the test items!

Remote memory. Ask the patient about historical or verifiable personal events (see neuroexam.com Video 7).

■ *What Is Being Tested?* Memory can be impaired on many different timescales. Impaired ability to register and recall something within a few seconds after it was said is an abnormality that blends into the category of impaired attention discussed earlier. If immediate recall is intact, then difficulty with recall after about 1 to 5 minutes usually signifies damage to the limbic memory structures located in the medial temporal lobes and medial diencephalon (see Figure 2.24; see also KCC 18.1). Dysfunction of these structures characteristically causes **anterograde amnesia,** meaning difficulty remembering new facts and events occurring after lesion onset, and **retrograde amnesia,** meaning impaired memory of events for a period of time immediately before lesion onset, with relative sparing of earlier memories. Loss of memory without these time characteristics may signify damage to areas other than the medial temporal and medial diencephalic structures, and can also occur in psychogenic amnesia.

LANGUAGE.

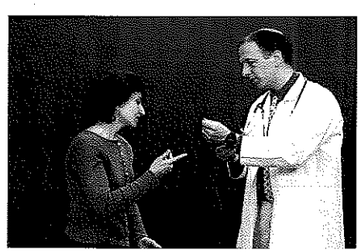

Naming



Reading and writing

1. **Spontaneous speech.** Note the patient's fluency, including phrase length, rate, and abundance of spontaneous speech (see neuroexam.com Video 8). Also note tonal modulation and whether **paraphasic errors** (inappropriately substituted words or syllables), **neologisms** (nonexistent words), or errors in grammar are present.
2. **Comprehension.** Can the patient understand simple questions and commands? Comprehension of grammatical structure should be tested as well; for example, "Mike was shot by John. Is John dead?" (See neuroexam.com Video 9.)
3. **Naming.** Ask the patient to name some easy (pen, watch, tie, etc.) and some more difficult (fingernail, belt buckle, stethoscope, etc.) objects (see neuroexam.com Video 10). Naming parts of objects is often more difficult and should also be tested. Write down what was said to enable follow-up comparisons.
4. **Repetition.** Can the patient repeat single words and sentences (a standard is "no ifs, ands, or buts")? Again, titrate function using tasks that range from easy to difficult, and write down what the patient says. (See neuroexam.com Video 11.)
5. **Reading.** Ask the patient to read aloud single words, a brief passage, and the front page of the newspaper and test for comprehension.
6. **Writing.** Ask the patient to write their name and write a sentence. (See neuroexam.com Video 12.)

■ *What Is Being Tested?* Different kinds of language abnormalities are caused by lesions in the dominant (usually left) frontal lobe, including Broca's area; the left temporal and parietal lobes, including Wernicke's area (see Figure 2.25); subcortical white matter and gray matter structures, including thalamus and caudate nucleus; as well as the nondominant hemisphere. For further details regarding the neuroanatomy of specific language disorders, see Chapters 2 and 19.

CALCULATIONS, RIGHT–LEFT CONFUSION, FINGER AGNOSIA, AGRAPHIA. Impairment of all four of these functions in an otherwise intact patient is referred to as **Gerstmann's syndrome.** Since Gerstmann's syndrome is caused by lesions in the dominant parietal lobe, aphasia is often (but not always) present as well, which can make the diagnosis difficult or impossible. Each of the individual components of Gerstmann's syndrome is poorly localizing on its own, but they are worth documenting as part of the assessment of overall cognitive function:

1. **Calculations.** Can the patient do simple addition, subtraction, and so on? (see neuroexam.com Video 13.)
2. **Right–left confusion.** Can the patient identify right and left body parts?
3. **Finger agnosia.** Can the patient name and identify each digit?
4. **Agraphia.** Can the patient write their name and a sentence?

These functions are often tested as part of language (discussed earlier). Right–left confusion and finger agnosia can both be quickly screened for with the classic command, "Touch your right ear with your left thumb." (See neuroexam.com Video 14.)

Right ear left thumb

■ *What Is Being Tested?* As we have noted, abnormality of all four of these functions that is out of proportion to other cognitive deficits is strongly localizing to the dominant (usually left) parietal lobe. Otherwise, each of the individual abnormalities can be seen in many different lesions and may be present in individuals with impaired attention, language, praxis (see the next section), constructions, logic and abstraction, and so on.

APRAXIA. The term **apraxia** will be used here to mean inability to follow a motor command that is not due to a primary motor deficit or a language impairment. It is caused by a deficit in higher-order planning or conceptualization of the motor task. You can test for apraxia by asking the patient to do complex tasks, using commands such as "Pretend to comb you hair" or "Pretend to strike a match and blow it out" and so on (see neuroexam.com Video 15). Patients with apraxia perform awkward movements that only minimally resemble those requested, despite having intact comprehension and an otherwise normal motor exam. This kind of apraxia is sometimes called **ideomotor apraxia.** In some patients, rather than affecting the distal extremities, apraxia can involve primarily the mouth and face, or movements of the whole body, such as walking or turning around.

Praxis

Unfortunately, the term "apraxia" has also been attached to a variety of other abnormalities—for example, "constructional apraxia" in patients who have visuospatial difficulty drawing complex figures, "ocular apraxia" in patients who have difficulty directing their gaze, "dressing apraxia" in patients who have difficulty getting dressed, and so on. It is unclear at present whether these various types of "apraxia" are related in some way or are caused by completely different mechanisms.

■ *What Is Being Tested?* Although apraxia indicates brain dysfunction, it can be caused by lesions in many different regions, so exact localization is often difficult. Apraxia is commonly present in lesions affecting the language areas and adjacent structures of the dominant hemisphere.

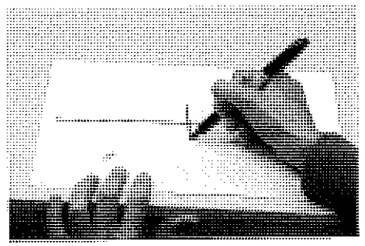

Neglect drawing tests

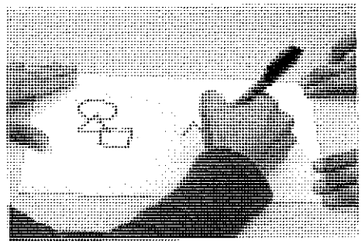

Copy drawing

This can make it challenging to prove that the deficit is apraxia rather than impaired language comprehension. The distinction can often be made by asking patients to perform a task, and then if they fail, demonstrating several tasks and asking them to choose the correct one.

NEGLECT AND CONSTRUCTIONS. Hemineglect is an abnormality in attention to one side of the universe that is not due to a primary sensory or motor disturbance. In sensory neglect, patients ignore visual, somatosensory, or auditory stimuli on the affected side, despite intact primary sensation (see KCC 19.9). This can often be demonstrated by testing for **extinction on double simultaneous stimulation**. Thus, patients may detect a stimulus on the affected side when presented alone, but when stimuli are presented simultaneously on both sides, only the stimulus on the unaffected side may be detected. In motor neglect, normal strength may be present; however, the patient does not move the affected limb unless attention is strongly directed toward it. Sensory and motor neglect are usually tested as part of the visual, auditory, somatosensory, and motor exams (to be described shortly). During the reading and writing portions of the language exam, patients may be noted to neglect one side of the page.

During the mental status exam, certain other aspects of neglect should be screened for. Patients should be asked, "Is anything wrong with you right now?" because patients with **anosognosia** may be strikingly unaware of severe deficits on the affected side of their body. For example, some patients with acute stroke who are completely paralyzed on the left side believe there is nothing wrong and may even be perplexed about why they are in the hospital. Some patients do not even comprehend that affected limbs belong to them. In addition, certain drawing tasks, such as asking the patient to bisect a line or draw a clock face, can demonstrate neglect (see neuroexam.com Video 16). **Construction tasks** involving drawing complex figures or manipulating blocks or other objects in space may be abnormal as a result of neglect or other visuospatial impairments (see neuroexam.com Video 17). However, constructional abilities can also be abnormal because of other cognitive difficulties, such as impaired sequencing (see next section) or apraxia.

■ *What Is Being Tested?* Hemineglect is most common in lesions of the right (nondominant) parietal lobe, causing patients to neglect the left side. Left-sided neglect can also occasionally be seen in right frontal lesions, right thalamic or basal ganglia lesions, and, rarely, in lesions of the right midbrain. In left parietal lesions a much milder neglect is usually seen affecting the patient's right side.

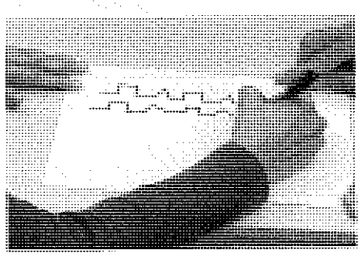

Written alternating sequencing test

Abnormal constructions demonstrating neglect can occur with right parietal lesions. In addition, other abnormalities in constructions can occur as well, as a result of lesions in many other parts of the brain. Generally, however, impaired visuospatial function is more severe with damage to the nondominant (right) hemisphere (see also KCC 19.9, 19.10).

Manual alternating sequencing test

SEQUENCING TASKS AND FRONTAL RELEASE SIGNS. Patients with frontal lobe dysfunction may have particular difficulty in changing from one action to the next when asked to perform a repeated sequence of actions. For example, when asked to continue drawing a silhouette pattern of alternating triangles and squares, they may get stuck on one shape and keep drawing triangles (Figure 3.1; see also neuroexam.com Video 20). This phenomenon is called **perseveration.** The **Luria manual sequencing task,** in which the patient is asked to tap the table with a fist, open palm, and side of open hand and then to repeat the sequence as quickly as possible, is also a useful test for perseveration (see neuroexam.com Video 19). Another common finding is **motor impersistence,** a form of distractibility in



Figure 3.1 Written Alternating Sequencing Task The patient was instructed to copy the pattern drawn by the examiner and to continue it to the end of the page.

which patients only briefly sustain a motor action in response to a command such as "Raise your arms" or "Look to the right." Ability to suppress inappropriate behaviors can be tested by the **Auditory Go-No-Go Test,** in which the patient moves a finger in response to one tap on the table, but must keep it still in response to two taps (see neuroexam.com Video 21). Additional support for frontal lobe pathology comes from the presence of **frontal release signs,** such as the grasp reflex (see neuroexam.com Video 18) described in the section on reflexes later in the chapter. Patients with frontal lobe lesions may also exhibit very slow responses termed **abulia** or may have changes in personality and judgment based on consecutive exams or reported by family members.



Auditory go-no-go

■ *What Is Being Tested?* The constellation of abnormalities just described helps localize lesions to the frontal lobes (see "Association Cortex" in Chapter 2 and KCC 19.11.)

LOGIC AND ABSTRACTION. Can the patients solve simple problems such as the following (see neuroexam.com Video 22): "If Mary is taller than Jane, and Jane is taller than Ann, who's the tallest?" How do they interpret proverbs such as "Don't cry over spilled milk"? How well can they comprehend similarities such as "How are a car and an airplane alike?" How well can they generalize and complete a series—for example, "Continue the following: AZ BY CX D_"? A more detailed evaluation can be done, when indicated, using formal neuropsychological testing batteries. Educational background must always be taken into account in interpretations of these tests.

■ *What Is Being Tested?* These functions can be abnormal in damage to a variety of brain areas involving higher-order association cortex and are not well localized.

DELUSIONS AND HALLUCINATIONS. Does the patient have any delusional thought processes? Does the patient have auditory or visual hallucinations? Ask questions such as, "Do you ever hear things that other people don't hear or see things that other people don't see?" "Do you feel that someone is watching you or trying to hurt you?" "Do you have any special abilities or powers?" (See neuroexam.com Video 23.)

■ *What Is Being Tested?* These abnormalities can be seen in toxic or metabolic abnormalities and other causes of diffuse brain dysfunction, and in primary psychiatric disorders (see KCC 18.3). In addition, abnormal sensory phenomena can be caused by focal lesions or seizures in visual, somatosensory, or auditory cortex, and thought disorders can be caused by lesions in the association cortex and limbic system.

MOOD. Does the patient have signs of depression, anxiety, or mania? Signs of **major depression** include depressed mood, changes in eating and sleeping patterns, loss of energy and initiative, low self-esteem, poor concentration, lack of enjoyment of previously pleasurable activities, and self-destructive or suicidal thoughts and behavior. Anxiety disorders are characterized by preoccupation with worrisome thoughts. Mania causes patients to be abnormally active and cognitively disorganized.

■ *What Is Being Tested?* These disorders are often considered psychiatric in origin and may be due to imbalances in neurotransmitter systems

in several different areas of the brain (see KCC 18.3). However, features of these disorders are also seen in focal brain lesions and in toxic or metabolic abnormalities such as thyroid dysfunction.

Some of the most difficult and interesting diagnostic dilemmas arise because of overlap and confusion between psychiatric and neurologic disorders. Thus, depressed patients with somatization or conversion disorders (which will be discussed later in the chapter) often have complaints such as pain, numbness, weakness, or even seizurelike activity and are therefore referred to neurologists for evaluation. Likewise, neurologic disorders such as brain tumors, strokes, metabolic derangements, encephalitis, vasculitis, and so on can produce confusional states or bizarre behavior that may be misinterpreted as psychiatric in origin.

Olfaction

Red desaturation

Ophthalmoscopic exam

Visual fields

2. Cranial Nerves

Perhaps more than any other part of the neurologic exam, cranial nerve testing can raise red flags that suggest specific neurologic dysfunction rather than a systemic disorder. For example, there are many medical causes of lethargy, unsteadiness, headaches, or dizziness. However, any of these symptoms together with cranial nerve abnormalities strongly suggests brainstem dysfunction as the cause (see Chapters 12–14). Careful testing of the cranial nerves, therefore, can reveal crucial information to help pinpoint disorders in the nervous system. While learning to test the cranial nerves, refer to Figure 2.22 and Table 2.5.

OLFACTION (CN I). Can the patient smell coffee or soap with each nostril? (See neuroexam.com Video 24.) Do not use noxious odors, since they may stimulate pain fibers from CN V. CN I is often not tested unless specific pathology such as a subfrontal brain tumor is suspected.

■ *What Is Being Tested?* Impairment can be due to nasal obstruction, damage to the olfactory nerves in the nasal mucosa, damage to the nerves as they cross the cribriform plate, or intracranial lesions affecting the olfactory bulbs (see Figure 2.11C).

OPHTHALMOSCOPIC EXAM (CN II). Examine both retinas carefully with an ophthalmoscope (see neuroexam.com Video 25).

■ *What Is Being Tested?* This exam allows direct visualization of damage to the retina or retinal vessels, optic nerve atrophic changes, papilledema (see KCC 5.3), and other important abnormalities.

VISION (CN II).

1. **Visual acuity.** Test visual acuity for each eye separately (by covering one eye at a time) using an eye chart.
2. **Color vision.** Test each eye separately for ability to distinguish colors. Test for **red desaturation,** a sign of subtle asymmetry in optic nerve function (as seen, for example, in optic neuritis described in KCC 11.4), by asking the patient to cover each eye alternately while looking at a red object and to report any relative dullness of the color in one eye (see neuroexam.com Video 26).
3. **Visual fields.** Test visual fields for each eye by asking the patient to fixate straight ahead and to report when a finger can be seen moving in each quadrant. Alternatively, ask the patient to report how many fingers are being shown in each quadrant (see neuroexam.com Video 27). More precise mapping of visual fields can be done in the laboratory for patients who will be followed over time (see KCC 11.2). In comatose or uncooperative patients (discussed later in the chapter), visual fields can be tested roughly using blink-to-threat.

4. **Visual extinction.** Test for visual extinction **on double simultaneous stimulation** by asking patients how many fingers they see when fingers are presented to both sides at the same time (see neuroexam.com Video 27). In visual extinction, a form of hemineglect, patients do not report seeing the fingers on the affected (usually left) side of the visual field, although they can see fingers when they are presented to that side alone.

■ *What Is Being Tested?* Damage anywhere in the visual pathway from the eye to the visual cortex can cause specific deficits in the visual fields of one or both eyes (see also Figure 11.15). Importantly, some visual information from each eye crosses to the opposite side at the **optic chiasm.** Therefore, lesions in front of the optic chiasm (eye, optic nerve) cause visual deficits in *one eye,* while lesions behind the optic chiasm (optic tract, thalamus, white matter, visual cortex) cause *visual field* deficits that are similar for *both eyes.*

Visual hemineglect or extinction is usually caused by contralateral parietal lesions, and less often by frontal or thalamic lesions. Neglect is usually more robust in lesions of the right hemisphere (see KCC 19.9).

PUPILLARY RESPONSES (CN II, III). First, record the pupil size and shape at rest. Next, note the **direct response,** meaning constriction of the illuminated pupil, as well as the **consensual response,** meaning constriction of the opposite pupil (see neuroexam.com Video 29).

In an **afferent pupillary defect** there is a decreased direct response caused by decreased visual function in one eye. This can be demonstrated with the **swinging flashlight test,** in which the light is moved back and forth between the eyes every 2 to 3 seconds (see neuroexam.com Video 30). The afferent pupillary defect becomes obvious when the flashlight is moved from the normal to the affected eye, and the affected pupil *dilates* in response to light. Under normal conditions, the pupil constricts in response to light. Brief oscillations of pupillary size called **hippus** occur normally in response to light and should not be confused with an afferent pupillary defect.

Finally, test the pupillary response to **accommodation.** Normally the pupils constrict while fixating on an object being moved toward the eyes (see neuroexam.com Video 31).

■ *What Is Being Tested?*

1. **Direct response (pupil illuminated).** The direct response is impaired in lesions of the ipsilateral optic nerve, the pretectal area, the ipsilateral parasympathetics traveling in CN III, or the pupillary constrictor muscle of the iris (see Figure 13.8).
2. **Consensual response (contralateral pupil illuminated).** The consensual response is impaired in lesions of the contralateral optic nerve, the pretectal area, the ipsilateral parasympathetics traveling in CN III, or the pupillary constrictor muscle (see Figure 13.8).
3. **Accommodation (response to looking at something moving toward the eye).** Accommodation is impaired in lesions of the ipsilateral optic nerve, the ipsilateral parasympathetics traveling in CN III, or the pupillary constrictor muscle, or in bilateral lesions of the pathways from the optic tracts to the visual cortex. Accommodation is spared in lesions of the pretectal area that may impair the pupillary light response.

See Chapter 13 for further details on the neuroanatomy of pupillary reflexes and pupillary abnormalities (see KCC 13.5).


Pupil light reflex

Swinging flashlight test

Smooth pursuit

EXTRAOCULAR MOVEMENTS (CN III, IV, VI). Check **extraocular movements** (eye movements) by having the patient look in all directions without moving their

Saccades

OKN


Oculocephalic testing


Corneal reflex

Masseter

head. While doing this, ask them if they experience any double vision. Test **smooth pursuit** by having the patient follow an object moved across their full range of horizontal and vertical eye movements (see neuroexam.com Video 32).

Test **convergence movements** by having the patient fixate on an object as it is moved slowly toward a point right between the patient's eyes.

Also, observe the eyes at rest to see if there are any abnormalities such as spontaneous nystagmus (discussed shortly) or **dysconjugate gaze** (eyes not both fixated on the same point), resulting in **diplopia** (double vision).

Saccades are eye movements used to rapidly refixate from one object to another. The examiner can test saccades by holding two widely spaced targets in front of the patient (such as the examiner's thumb on one hand and index finger on the other) and asking the patient to look back and forth between the targets (e.g., by saying, "Now look at my finger . . . thumb . . . finger . . . thumb"; see neuroexam.com Video 33).

Test **optokinetic nystagmus (OKN)** by moving a strip with parallel stripes on it in front of the patient's eyes and asking them to watch the stripes go by (see neuroexam.com Video 34). Normally, rhythmic eye movements called **nystagmus** occur, consisting of an alternating **slow phase** with slow pursuit movements in the direction of strip movement, and a **rapid phase** with quick, saccadic refixations back to midline. OKN testing can be very useful in detecting subtle abnormalities or asymmetries in saccadic or smooth pursuit eye movements.

In comatose or severely lethargic patients, eye movements can also be evaluated with **oculocephalic** or **caloric testing** (see "Coma Exam," later in this chapter; see neuroexam.com Video 35).

■ *What Is Being Tested?* Careful testing can often identify abnormalities in individual muscles or in particular cranial nerves (oculomotor, trochlear, or abducens)—in their course from the brainstem to the orbit, in the brainstem nuclei, or finally, in the higher-order centers and pathways in the cortex and brainstem that control eye movements (review Table 2.5; see also Chapter 13 for more details). Spontaneous nystagmus can indicate toxic or metabolic conditions such as drug overdose or alcohol intoxication, or peripheral or central vestibular dysfunction (see "Hearing and Vestibular Sense [CN VIII]" below).

FACIAL SENSATION AND MUSCLES OF MASTICATION (CN V). Test facial sensation using a cotton wisp and a sharp object. Also test for **tactile extinction** using double simultaneous stimulation (see above). The **corneal reflex,** which involves both CN V and CN VII, is tested by touching each cornea gently with a cotton wisp and observing any asymmetries in the blink response (see neuroexam.com Video 37).

Feel the masseter muscles during jaw clench (see neuroexam.com Video 38). Test for a **jaw jerk reflex** by gently tapping on the jaw with the mouth slightly open (see neuroexam.com Video 39).

■ *What Is Being Tested?* Facial sensation can be impaired by lesions of the trigeminal nerve (CN V), the trigeminal sensory nuclei in the brainstem, or ascending sensory pathways to the thalamus and somatosensory cortex in the postcentral gyrus (see Figures 7.9, 12.8). The corneal reflex is mediated by polysynaptic connections in the brainstem between the trigeminal (CN V) and facial (CN VII) nerves and can be impaired by lesions anywhere in this circuit (see KCC 12.4).

Extinction in the presence of intact primary sensation is usually caused by right parietal lesions.

Weakness of the muscles of mastication can be due to lesions in the upper motor neuron pathways synapsing onto the trigeminal (CN V) motor nucleus, in the lower motor neurons of the trigeminal motor nucleus in the pons or as

they exit the brainstem to reach the muscles of mastication, in the neuromuscular junction or in the muscles themselves.

Presence of a jaw jerk reflex is abnormal, especially if it is prominent. It is a sign of hyperreflexia associated with lesions of upper motor neuron pathways projecting to the trigeminal motor nucleus. Both the afferent and the efferent limbs of the jaw jerk reflex are mediated by CN V (see KCC 12.4).

MUSCLES OF FACIAL EXPRESSION AND TASTE (CN VII). Look for asymmetry in facial shape or in depth of furrows such as the nasolabial fold. Also look for asymmetries in spontaneous facial expressions and blinking. Facial weakness may be difficult to detect in cases where it occurs bilaterally, also known as **facial diplegia,** because the facial weakness is symmetrical. Ask patients to smile, puff out their cheeks, clench their eyes tight, wrinkle their brow, and so on (see neuroexam.com Video 40). Old photographs of the patient can often aid your recognition of subtle changes.

Check taste with sugar, salt, or lemon juice on cotton swabs applied to the lateral aspect of each side of the tongue (see neuroexam.com Video 41). Like olfaction, taste is often tested only when specific pathology is suspected, such as in lesions of the facial nerve or in lesions of the gustatory nucleus (nucleus solitarius).

■ *What Is Being Tested?* Facial weakness can be caused by lesions of upper motor neurons in the contralateral motor cortex or descending CNS pathways, lower motor neurons in the ipsilateral facial nerve nucleus (CN VII) or exiting nerve fibers, the neuromuscular junction, or the face muscles. Note that the upper motor neurons for the *upper face* (the upper portions of the orbicularis oculi and the frontalis muscles of the forehead) project to the facial nuclei *bilaterally* (see Figure 12.13). Therefore, **upper motor neuron lesions** such as a stroke cause contralateral face weakness sparing the forehead, while **lower motor neuron lesions** such as a facial nerve injury typically cause weakness involving the whole ipsilateral face.

HEARING AND VESTIBULAR SENSE (CN VIII). Can the patient hear fingers rubbed together or words whispered just outside of the auditory canal and identify which ear hears the sound? (See neuroexam.com Video 42.) A tuning fork can be used to distinguish neural from mechanical conductive hearing problems (see KCC 12.5). Vestibular sense is generally not specifically tested except in the following important situations:

1. **Patients with vertigo.** Certain maneuvers can help distinguish central from peripheral lesions (see KCC 12.6; see also neuroexam.com Video 43).
2. **Patients with limitations of horizontal or vertical gaze.** Testing the **vestibulo-ocular reflex** can help localize the lesion (see Chapter 13). The vestibulo-ocular reflex can be tested either using the **oculocephalic maneuver,** in which the eyes are held open and the head is turned rapidly either from side to side or up and down, or by using **caloric testing,** in which cold or warm water is instilled into one ear, producing asymmetrical stimulation of the semicircular canals. Further details of these tests and their significance are provided in the section "Coma Exam" later in this chapter, and in KCC 12.6.
3. **Patients in coma.** The vestibulo-ocular reflex is often the only way to test eye movements in these patients (see the discussion of comatose patients later in this chapter).

■ *What Is Being Tested?* Hearing loss can be caused by lesions in the acoustic and mechanical elements of the ear, the neural elements of the cochlea, or the acoustic nerve (CN VIII)(see Figure 12.15). After the hearing pathways enter the brainstem, they cross over at multiple levels and ascend *bilaterally* to the thalamus and auditory cortex (see Figure 12.16).

Jaw jerk reflex


Facial muscles

Taste

Hearing

Positional vertigo test

Therefore, clinically significant unilateral hearing loss is invariably caused by peripheral neural or mechanical lesions.

Abnormalities in vestibular testing can be associated with lesions in the vestibular apparatus of the inner ear (see Figure 12.15), the vestibular portion of CN VIII, the vestibular nuclei in the brainstem, the cerebellum, or pathways in the brainstem (such as the medial longitudinal fasciculus) that connect the vestibular and oculomotor systems (see Figure 12.18). Further details are provided in Chapter 12 and in the section "The Neurologic Exam in the Comatose or Uncooperative Patient" later in this chapter.

CN XI testing

PALATE ELEVATION AND GAG REFLEX (CN IX, X). Does the palate elevate symmetrically when the patient says, "Aah" (see neuroexam.com Video 44)? Does the patient gag when the posterior pharynx is brushed? The **gag reflex** needs to be tested only in patients with suspected brainstem pathology, impaired consciousness, or impaired swallowing.

■ *What Is Being Tested?* Palate elevation and the gag reflex are impaired in lesions involving CN IX, CN X, the neuromuscular junction, or the pharyngeal muscles.

MUSCLES OF ARTICULATION (CN V, VII, IX, X, XII). Is the patient's speech hoarse, slurred, quiet, breathy, nasal, low or high pitched, and so on (see neuroexam.com Video 45)? It is often important to ask if the patient's speech has changed from baseline. Note that **dysarthria** (see KCC 12.8), or abnormal pronunciation of speech, is not the same as **aphasia,** which is an abnormality in language production or comprehension.

■ *What Is Being Tested?* Abnormal articulation of speech can occur in lesions involving the muscles of articulation, the neuromuscular junction, or the peripheral or central portions of CN V, VII, IX, X, or XII. Furthermore, speech production can be abnormal as a result of lesions in the motor cortex, cerebellum, basal ganglia, or descending pathways to the brainstem.

STERNOCLEIDOMASTOID AND TRAPEZIUS MUSCLES (CN XI). Ask the patient to shrug their shoulders, turn their head in both directions, and raise their head from the bed flexing forward against the force of your hands (see neuroexam.com Video 46).

MNEMONIC

■ *What Is Being Tested?* Weakness in the sternocleidomastoid or trapezius muscles can be caused by lesions in the muscles, neuromuscular junction, or lower motor neurons of the accessory spinal nerve (CN XI) (see KCC 12.7). Unilateral upper motor neuron lesions in the cortex or descending pathways cause contralateral weakness of the trapezius, with relative sparing of sternocleidomastoid strength. This may be analogous to upper motor neuron facial lesions sparing the upper portion of the face. When sternocleidomastoid weakness is present with upper motor neuron lesions, there is weakness of head turning away from the side of the lesion (see also KCC 13.10).

Tongue protrusion

TONGUE MUSCLES (CN XII). Note any atrophy or **fasciculations** (spontaneous quivering movements) of the tongue while it is resting on the floor of the mouth. Ask the patient to stick their tongue straight out and note whether it curves to one side or the other (see neuroexam.com Video 47). Ask the patient to move their tongue from side to side and push it forcefully against the inside of each cheek.

■ *What Is Being Tested?* Fasciculations and atrophy are signs of lower motor neuron lesions (see Table 3.3). **Unilateral tongue weakness causes the tongue to deviate toward the weak side.** Tongue weakness can result from lesions of the tongue muscles, the neuromuscular junction, the lower motor neurons of the hypoglossal nerve (CN XII), or the upper motor neurons originating in the motor cortex. Lesions of the motor cortex cause contralateral tongue weakness.

TABLE 3.3 Signs of Upper Motor Neuron (UMN) and Lower Motor Neuron (LMN) Lesions

SIGN	UMN LESIONS	LMN LESIONS
Weakness	Yes	Yes
Atrophy	No[a]	Yes
Fasciculations	No	Yes
Reflexes	Increased[b]	Decreased
Tone	Increased[b]	Decreased

[a]Mild atrophy may develop as a result of disuse.
[b]With acute upper motor neuron lesions, reflexes and tone may be decreased.

3. Motor Exam

The motor exam has several steps, including (1) observation, (2) inspection, (3) palpation, (4) muscle tone testing, (5) functional testing, and (6) strength testing of individual muscle groups. Each of these steps will now be discussed in turn.

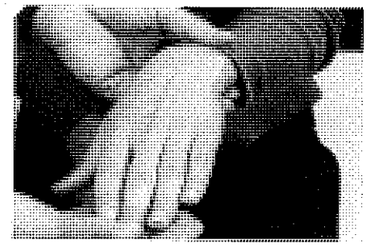
Atrophy? Fasciculations?

OBSERVATION. Carefully observe the patient to detect any twitches, tremors, or other involuntary movements, as well as any unusual paucity of movement (see KCC 15.2, KCC 16.1). Note also the patient's posture.

■ *What Is Being Tested?* Involuntary movements and tremors are commonly associated with lesions of the basal ganglia or cerebellum (see KCC 15.2, KCC 16.1). Tremors can also occasionally be seen with peripheral nerve lesions.

Upper extremity tone

INSPECTION. Inspect several individual muscles to see if muscle wasting, hypertrophy, or fasciculations are present (see neuroexam.com Video 48). The best muscles to look at for fasciculations in generalized lower motor neuron disorders are the intrinsic hand muscles, shoulder girdle, and thigh.

PALPATION. In cases of suspected myositis, palpate the muscles to see if there is tenderness.

MUSCLE TONE TESTING. Next test muscle tone. Ask the patient to relax, and then passively move each limb at several joints to get a feeling for any resistance or rigidity that may be present (see neuroexam.com Videos 49, 50).

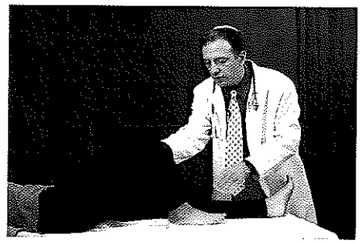
Lower extremity tone

■ *What Is Being Tested?* Many parts of the motor exam can help distinguish between **upper motor neuron** and **lower motor neuron** lesions (see Chapters 2 and 6). Recall that upper motor neurons project via the corticospinal tract to lower motor neurons located in the anterior horn of the spinal cord. Signs of lower motor neuron lesions (Table 3.3) include weakness, atrophy, fasciculations, and **hyporeflexia** (reduced reflexes; see the section "Reflexes" later in this chapter). Signs of upper motor neuron lesions include weakness, **hyperreflexia** (increased reflexes), and increased tone. The hyperreflexia and increased tone seen with corticospinal lesions is apparently caused by damage to pathways that travel in close association with the corticospinal tract rather than directly by damage to the cor-

Drift

Rapid hand movements



Rapid foot tapping

Upper extremity strength

Lower extremity strength

ticospinal tract itself. Note that with *acute* upper motor neuron lesions there is often *flaccid paralysis* with decreased tone and decreased reflexes. With time (hours to weeks), increased tone and hyperreflexia usually develop.

Increased tone can occur in upper motor neuron lesions, but can also occur in basal ganglia dysfunction (see KCC 16.1). In addition, slow or awkward fine finger movements or toe tapping in the absence of weakness can signify a subtle abnormality of the corticospinal pathways, but can also occur in lesions of the cerebellum or basal ganglia.

FUNCTIONAL TESTING. Before formally testing strength in each muscle, it is useful to do a few general functional tests that help detect subtle abnormalities. Check for **drift** by having the patient hold up both arms or both legs and close their eyes (see neuroexam.com Video 51). Check **fine movements** by testing rapid finger tapping, rapid hand pronation–supination (as in screwing in a light bulb), rapid hand tapping, and rapid foot tapping against the floor or other object (see neuroexam.com Videos 52, 53). Tests for subtle weakness are discussed further in KCC 6.4.

STRENGTH OF INDIVIDUAL MUSCLE GROUPS. Patterns of weakness can help localize a lesion to a particular cortical or white matter region, spinal cord level, nerve root, peripheral nerve, or muscle.

Test the strength of each muscle group and record it in a systematic fashion. It is wise to pair the testing of each muscle group immediately with testing of its contralateral counterpart to enhance detection of any asymmetries. Muscle strength is often rated on a scale of 0/5 to 5/5 as follows:

0/5: no contraction
1/5: muscle flicker, but no movement
2/5: movement possible, but not against gravity (test the joint in its horizontal plane)
3/5: movement possible against gravity, but not against resistance by the examiner
4/5: movement possible against some resistance by the examiner (sometimes this category is subdivided further into $4^-/5$, 4/5, and $4^+/5$)
5/5: normal strength

While testing **muscle strength**, it is important to keep in mind anatomical information such as which nerves, nerve roots, and brain areas control each muscle and to allow this information to guide the exam (see neuroexam.com Videos 54–57). Also, compare proximal vs. distal weakness, because these features can sometimes suggest muscle versus nerve disease, respectively.

■ ***What Is Being Tested?*** A detailed discussion of patterns of muscle weakness and localization is provided in KCC 6.3 and in Chapters 8 and 9. The actions tested are also demonstrated through video clips on the website neuroexam.com. In Tables 3.4 and 3.5, we briefly summarize some of the main actions, muscle groups, peripheral nerves, and nerve roots tested during the motor exam.

4. Reflexes

The **deep tendon reflexes** and **plantar response** should be checked in all patients. Certain other reflexes should also be tested in special situations, as described in the sections that follow.

DEEP TENDON REFLEXES. Check the deep tendon reflexes using impulses from a reflex hammer to stretch the muscle and tendon (see neuroexam.com Video 58). The limbs should be in a relaxed and **symmetrical** position, since these fac-

TABLE 3.4 Upper Extremity Strength Testing

ACTION	MUSCLES	NERVES	NERVE ROOTS
Finger extension	Extensor digitorum, extensor indicis, extensor digiti minimi	Radial nerve (posterior interosseous nerve)	**C7**, C8
Thumb abduction in plane of palm	Abductor pollicis longus	Radial nerve (posterior interosseous nerve)	**C7**, C8
Finger abduction	Dorsal interossei, abductor digiti minimi	Ulnar nerve	C8, **T1**
Finger and thumb adduction in plane of palm	Adductor pollicis, palmar interossei	Ulnar nerve	C8, **T1**
Thumb opposition	Opponens pollicis	Median nerve	C8, **T1**
Thumb abduction perpendicular to plane of palm	Abductor pollicis brevis	Median nerve	C8, **T1**
Flexion at distal interphalangeal joints, digits 2, 3	Flexor digitorum profundus to digits 2, 3	Median nerve	C7, **C8**
Flexion at distal interphalangeal joints, digits 4, 5	Flexor digitorum profundus to digits 4, 5	Ulnar nerve	C7, **C8**
Wrist flexion and hand abduction	Flexor carpi radialis	Median nerve	C6, C7
Wrist flexion and hand adduction	Flexor carpi ulnaris	Ulnar nerve	C7, **C8**, T1
Wrist extension and hand abduction	Extensor carpi radialis	Radial nerve	C5, **C6**
Elbow flexion (with forearm supinated)	Biceps, brachialis	Musculocutaneous nerve	C5, C6
Elbow extension	Triceps	Radial nerve	C6, **C7**, C8
Arm abduction at shoulder	Deltoid	Axillary nerve	**C5**, C6

Note: When one nerve root is more important than the others, it is shown in boldface.

TABLE 3.5 Lower Extremity Strength Testing

ACTION	MUSCLES	NERVES	NERVE ROOTS
Hip flexion	Iliopsoas	Femoral nerve, and L1–L3 nerve roots	L1, L2, **L3**, L4
Knee extension	Quadriceps	Femoral nerve	L2, **L3**, **L4**
Knee flexion	Hamstrings (semitendinosus, semimembranosus, biceps femoris)	Sciatic nerve	L5, **S1**, S2
Leg abduction	Glutius medius, gluteus mimmus, tensor fasciae latae	Superior gluteal nerve	**L4**, **L5**, S1
Leg adduction	Obturator externus, adductor longus, magnus, and brevis; gracilis	Obturator nerve	**L2**, **L3**, L4
Toe dorsiflexion	Extensor hallucis longus, extensor digitorum longus	Deep peroneal nerve	**L5**, S1
Foot dorsiflexion	Tibialis anterior	Deep peroneal nerve	L4, L5
Foot plantar flexion	Triceps surae (gastrocnemius, soleus)	Tibial nerve	S1, S2
Foot eversion	Peroneus longus, peroneus brevis	Superficial peroneal nerve	L5, S1
Foot inversion	Tibialis posterior	Tibial nerve	L4, L5

Note: When one nerve root is more important than the others, it is shown in boldface.

Deep tendon reflexes



Finger flexors

tors can influence reflex amplitude. As in muscle strength testing, it is important to compare each reflex immediately with its contralateral counterpart so that any asymmetries can be detected. If you cannot elicit a reflex, you can sometimes bring it out by certain **reinforcement** procedures. For example, have the patient gently contract the muscle being tested by instructing the patient to raise the limb very slightly, or to concentrate on forcefully contracting a different muscle group just at the moment when the reflex is tested. When reflexes are very brisk, **clonus** is sometimes seen. This is a repetitive vibratory contraction of the muscle that occurs in response to muscle and tendon stretch. Deep tendon reflexes are often rated according to the following scale:

0: absent reflex
1^+: trace, or seen only with reinforcement
2^+: normal
3^+: brisk
4^+: nonsustained clonus (i.e., repetitive vibratory movements)
5^+: sustained clonus

Deep tendon reflexes are normal if they are 1^+, 2^+, or 3^+ unless they are *asymmetrical* or there is a dramatic difference between the arms and the legs. Reflexes rated as 0, 4^+, or 5^+ are usually considered abnormal. In addition to clonus, other signs of hyperreflexia include **spreading** of reflexes to other muscles not directly being tested and **crossed adduction** of the opposite leg when the medial aspect of the knee is tapped. **Hoffmann's sign** also indicates heightened reflexes. You can elicit this sign by holding the patient's middle finger loosely and flicking the fingernail downward, causing the finger to rebound slightly into extension (see neuroexam.com Video 60). If the thumb flexes and adducts in response, Hoffmann's sign is present.

■ *What Is Being Tested?* Deep tendon reflexes (see Figure 2.21) may be diminished by abnormalities in muscles, sensory neurons, lower motor neurons, and the neuromuscular junction; acute upper motor neuron lesions; and mechanical factors such as joint disease. Abnormally increased reflexes are associated with upper motor neuron lesions (see Table 3.3). Note that deep tendon reflexes can be influenced by age, metabolic factors such as thyroid dysfunction or electrolyte abnormalities, and the anxiety level of the patient. The main spinal nerve roots involved in testing the deep tendon reflexes are summarized in Table 3.6.

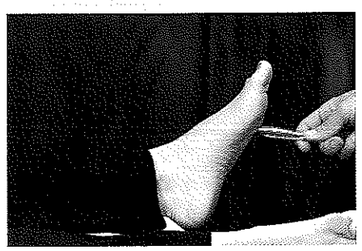

Plantar response

PLANTAR RESPONSE. Test the plantar response by scraping an object across the sole of the foot beginning from the heel, moving forward toward the small toe, and then arcing medially toward the big toe (Figure 3.2; see also neuroexam.com Video 59). The normal response is downward contraction of the toes. The abnormal response, called **Babinski's sign,** is characterized by an upgoing big toe and fanning outward of the other toes. In some patients the toes are "silent," moving neither up nor down. If the toes are downgoing on one side and silent on the other, the silent side is considered abnormal. The presence of Babinski's sign in an adult is always abnormal, but it is often present in infants, up to the age of about 1 year.

■ *What Is Being Tested?* Babinski's sign is associated with upper motor neuron lesions anywhere along the corticospinal tract. Note that it may not be possible to elicit Babinski's sign if there is severe weakness of the toe extensors.

A concise way to document reflexes at the biceps, triceps, brachioradialis, patellar, and Achilles tendons, as well as the plantar responses, is to illustrate them with a stick figure. An example for a normal patient is shown in Figure 3.3.

TABLE 3.6 Deep Tendon Reflexes

REFLEX	MAIN SPINAL NERVE ROOTS INVOLVED
Biceps	C5, C6
Brachioradialis	C6
Triceps	C7
Patellar	L4
Achilles tendon	S1

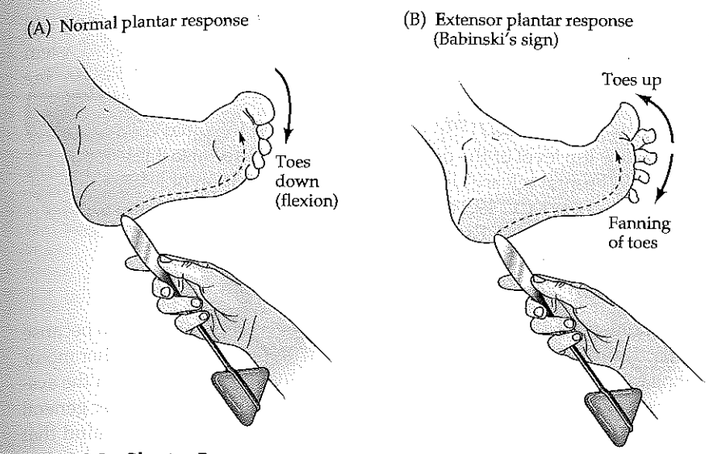

Figure 3.2 Plantar Response

REFLEXES TESTED IN SPECIAL SITUATIONS. Additional reflexes are tested in special situations such as coma, spinal cord injury, frontal lobe dysfunction, and neurodegenerative disorders.

With suspected **spinal cord damage,** absence of certain normal reflexes can help localize the level and ascertain the severity of the lesion (Table 3.7). Elicit **abdominal cutaneous reflexes** by scraping the abdominal skin on each side, above and below the umbilicus, and observing the abdominal muscle contractions. Elicit the **cremasteric reflex** in males by scraping the upper inner thigh and observing ascent of the testicle. The **bulbocavernosus reflex** is contraction of the rectal sphincter in response to pressure on the bulbocavernosus muscle. In males this response can be elicited by compressing of the glans penis; in females, since a Foley catheter is usually present in the urethra in this clinical setting, traction on the Foley catheter can elicit the response. **Anal wink** is contraction of the rectal sphincter in response to a sharp stimulus in the perianal area.

Frontal lobe lesions in adults can cause the reemergence of certain primitive reflexes that are normally present in infants but are pathological in adults. These so-called **frontal release signs** include the **grasp, snout, root,** and **suck reflexes** (see neuroexam.com Video 18 for a demonstration of the grasp reflex). Frontal release signs are sometimes tested for during the mental status exam if suspicion of frontal lobe pathology arises. Two other reflexes deserve mention, although they are less specific and can be seen in a wide variety of neurodegenerative conditions. Elicit the **glabellar response** by tapping with a finger repeatedly in the midline between the eyes and asking the patient to keep their eyes open. The normal patient may blink a few times, but the response then extinguishes. The abnormal response—to continue blinking with each tap (Myerson's sign)—is most commonly seen in neurodegenerative movement disorders such as Parkinson's disease. In the **palmomental reflex,** scraping the hypothenar eminence causes ipsilateral contraction of the mentalis muscles of the chin. This response is very nonspecific, and is present in some normal individuals.

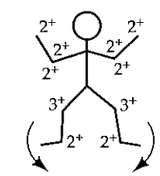

Figure 3.3 Reflex Stick Figure
Commonly tested deep tendon reflexes and plantar responses are summarized pictorially using stick figures, a widespread clinical shorthand.

TABLE 3.7 Additional Reflexes for Localizing Spinal Cord Lesions

REFLEX	SPINAL NERVE ROOTS INVOLVED
Abdominal cutaneous reflexes	
Above umbilicus	T8–T10
Below umbilicus	T10–T12
Cremasteric reflex	L1–L2
Bulbocavernosus reflex	S2–S4
Anal wink	S2–S4

In patients with damage to descending motor pathways, **posturing** can sometimes be seen. Posturing consists of complex reflexes involving brainstem and spinal cord circuitry and will be described further in the section on the coma exam later in this chapter.

■ *What Is Being Tested?* Special reflexes tested in spinal cord lesions help localize the level of the damage (see Table 3.7; see also Table 8.1 and Figure 8.4). Frontal release signs support the localization of lesions to the frontal lobes (see KCC 19.11). The localizing value of posturing will be discussed in the "Coma Exam" section.

5. Coordination and Gait

Coordination and gait are usually described under a separate section because cerebellar disorders can disrupt coordination or gait while leaving other motor functions relatively intact. There is much overlap, however, between the systems being examined in this section and those examined in the earlier general motor exam section as well as in other parts of the exam. Keep in mind that disturbances of coordination and gait can be caused by lesions in many systems other than the cerebellum.

The term **ataxia** is often used to describe the abnormal movements seen in coordination disorders (see KCC 15.2). In ataxia there are medium- to large-amplitude involuntary movements with an irregular oscillatory quality superimposed on and interfering with the normal smooth trajectory of movement (see Figure 3.4B). **Overshoot** is also commonly seen as part of ataxic movements and is sometimes referred to as **past pointing** when target-oriented movements are being discussed. Another feature of coordination disorders is **dysdiadochokinesia**—that is, abnormal alternating movements.

Cerebellar lesions can cause different kinds of coordination problems depending on their location. One important distinction is between truncal ataxia and appendicular ataxia (see KCC 15.2). **Appendicular ataxia** affects movements of the extremities and is usually caused by lesions of the cerebellar hemispheres and associated pathways (see Figure 15.3). **Truncal ataxia** affects the proximal musculature, especially that involved in gait stability, and is caused by midline damage to the cerebellar vermis and associated pathways.

Finger–nose–finger

Overshoot



Precision finger tap

APPENDICULAR COORDINATION. Fine movements of the hands and feet, as discussed earlier under the general motor exam, should be tested. **Rapid alternating movements,** such as wiping one palm alternately with the palm and dorsum of the other hand, should be tested as well (see neuroexam.com Video 62). Perhaps the most popular test of coordination, however, is the **finger–nose–finger test,** in which the patient is asked to alternately touch their nose and the examiner's finger as quickly as possible (Figure 3.4; see also neuroexam.com Video 64). Ataxia is best revealed if the examiner's finger is held at the extreme of the patient's reach, and if the examiner's finger is occasionally moved suddenly to a different location. Test for overshoot by having the patient raise both arms suddenly from their lap to the level of your hand (see neuroexam.com Video 66). In addition, you can apply pressure to the patient's outstretched arms and then suddenly release it. To test the accuracy of movements in a way that requires very little strength, you can draw a line on the crease of the patient's thumb and then ask the patient to touch the line repeatedly with the tip of their forefinger (see neuroexam.com Video 63). This test can help distinguish between irregular wavering movements caused by limb weakness and abnormal movements caused by ataxia.

Similar tests can be done with the legs. In the **heel–shin test** the patient is asked to touch the heel of one foot to the opposite knee and then to drag their heel in a straight line all the way down the front of their shin and back up again. In order to eliminate the effect of gravity in moving the heel down the shin, this test should always be done in the supine position (see neuroexam.com Video 65). Testing for ataxia is discussed further in KCC 15.2.

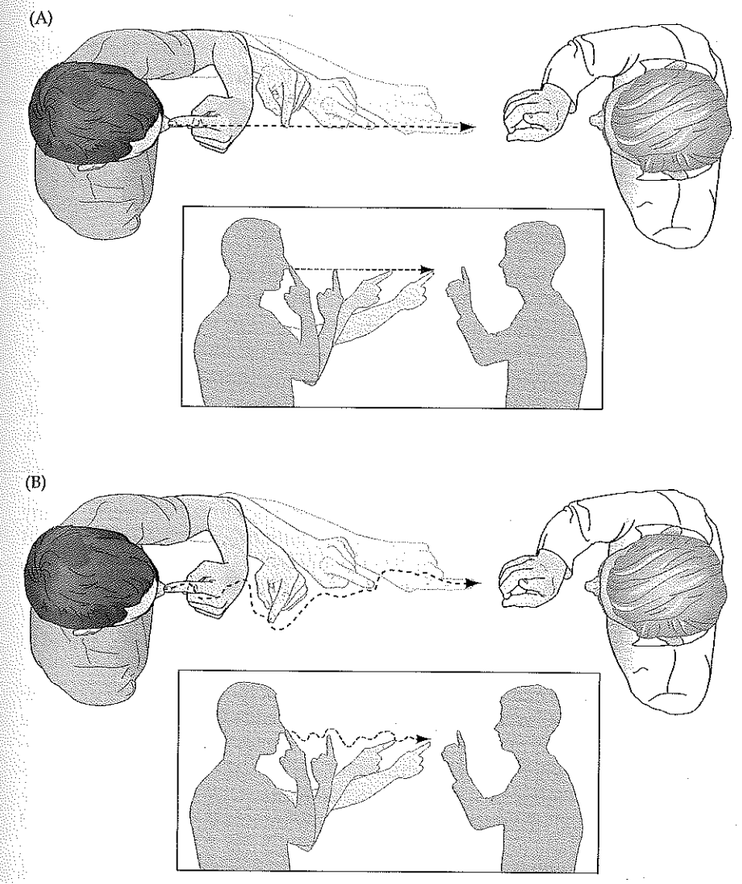

Figure 3.4 Finger–Nose–Finger Test
(A) Normal patient. (B) Patient with ataxia.

■ *What Is Being Tested?* Normal performance of these motor tasks depends on the integrated functioning of multiple sensory and motor subsystems. These include position sense pathways, visual pathways, lower motor neurons, upper motor neurons, the basal ganglia, and the cerebellum. Thus, in order to convincingly demonstrate that abnormalities are due to a cerebellar lesion, one must first test for normal joint position sense, vision, strength, and reflexes and confirm the absence of involuntary movements caused by basal ganglia lesions. As already mentioned, *appendicular ataxia* is usually caused by lesions of the cerebellar hemispheres and associated pathways, while *truncal ataxia* (see the next two sections, on the Romberg test and gait) is often caused by damage to the midline cerebellar vermis and associated pathways (see Figures 15.3 and 15.9).

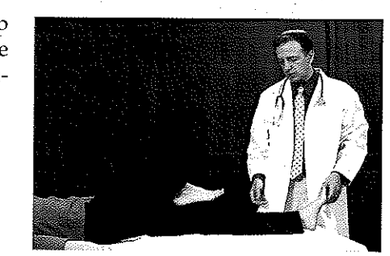

Heel–shin test

ROMBERG TEST. Ask the patient to stand with their feet together (touching each other). Then ask the patient to close their eyes. Remain close at hand in case the patient begins to sway or fall (see neuroexam.com Video 67).

Romberg test

■ *What Is Being Tested?* With the eyes open, three sensory systems provide input to the cerebellum to maintain truncal stability. These are vision, proprioception, and vestibular sense. If there is a mild lesion in the vestibular or proprioception systems, when the eyes are open the patient is usually able to compensate and remain stable. When the patient closes their eyes, however, visual input is removed and instability can be brought out. If there is a more severe proprioceptive or vestibular lesion, or if there is a midline cerebellar lesion causing truncal instability, the patient will be unable to maintain this position even with their eyes open.

Note that instability can also be seen with lesions in other parts of the nervous system, such as upper or lower motor neurons or the basal ganglia, so these should be tested separately in other parts of the exam.



Gait

GAIT. A patient's gait can be difficult to describe in a reproducible fashion. Observe the patient walking toward you and away from you in an open area with plenty of room. Note **stance** (how far apart the feet are), posture, stability, how high the feet are raised off the floor, trajectory of leg swing and whether there is **circumduction** (an arced trajectory in the medial to lateral direction), leg stiffness and degree of knee bending, arm swing, tendency to fall or swerve in any particular direction, rate and speed, difficulty initiating or stopping gait, and any involuntary movements that are brought out by walking. Turns should also be observed closely. When following a patient over several visits, it may be useful to time them walking a fixed distance, and to count the number of steps they took and the number of steps required to turn around. The patient's ability to rise from a chair with or without assistance should also be recorded.

To bring out abnormalities in gait and balance, ask the patient to do more difficult maneuvers. Test **tandem gait** by asking the patient to walk a straight line while touching the heel of one foot to the toe of the other with each step (see neuroexam.com Video 68). Patients with *truncal ataxia* caused by damage to the cerebellar vermis (see Figure 15.3) or associated pathways will have particular difficulty with this task, since they tend to have a wide-based, unsteady gait, and become more unsteady when attempting to keep their feet close together. To bring out subtle gait abnormalities or asymmetries, it may be appropriate in some cases to ask patients to perform so-called **forced gait** testing by asking them to walk on their heels, walk on their toes, walk on the insides or outsides of their feet, to stand or hop on one leg, or to walk up stairs (see neuroexam.com Video 69).

Gait apraxia is a perplexing (and somewhat controversial) abnormality in which the patient is able to carry out all of the movements required for gait normally when lying down, but is unable to walk in the standing position. It is thought to be associated with frontal disorders or normal pressure hydrocephalus (see KCC 5.7).

■ *What Is Being Tested?* As with tests of appendicular coordination, gait involves multiple sensory and motor systems. These include vision, proprioception, vestibular sense, lower motor neurons, upper motor neurons, basal ganglia, the cerebellum, and higher-order motor planning systems in the association cortex. Once again, it is important to test each of these systems for normal function before concluding that a gait disturbance is caused by a cerebellar lesion. Localization and diagnosis of gait disorders is described further in KCC 6.5 and Table 6.6.

6. Sensory Exam

The sensory exam relies to a large extent on the ability or willingness of patients to report what they are feeling. It can therefore often be the most difficult part of the exam to interpret with certainty. Tests should be performed in all extremities, as well as on the face and trunk, with the patient's eyes closed or covered to improve objectivity.

PRIMARY SENSATION, ASYMMETRY, SENSORY LEVEL. Light touch is best tested with a cotton-tipped swab, but a light finger touch will often suffice, as long as care is taken to make the stimulus fairly reproducible. You can test the relative sharpness of **pain sensation** by randomly alternating stimuli with the sharp or dull end of a safety pin (always use a new pin for each patient; see neuroexam.com Video 70). **Temperature sensation** can be tested with a cool piece of metal such as a tuning fork (see neuroexam.com Video 71). Test **vibration sense** by placing a vibrating tuning fork on the ball of the patient's right or left large toe or fingers and asking them to report when the vibration stops (see neuroexam.com Video 72). Take care not to place the tuning fork on a bone, since bones conduct the vibration to much more proximal sites, where they can be detected by nerves far from the location being tested. Test **joint position sense** by moving one of the patient's fingers or toes up and down and asking the patient to report which way it moves (see neuroexam.com Video 73). Hold the digit lightly by the sides while doing this so that tactile inputs don't provide significant clues to the direction of movement. The digit should be moved very slightly because normal individuals can detect movements that are barely perceptible by eye. **Two-point discrimination** can be tested with a special pair of calipers, or with a bent paper clip, alternating randomly between touching the patient with one or both points (see neuroexam.com Video 74). The minimal separation (in millimeters) at which the patient can distinguish these stimuli should be recorded in each extremity, and compared from side to side.

As in other parts of the exam, the patient's deficits, as well as the anatomy of the nerves, nerve roots, and central pathways, should be used to guide the exam (see Chapters 7–9). Comparisons should be made from one side of the body to the other and from proximal to distal on each extremity. Note especially if there is a **sensory level** corresponding to a particular spinal segment (see Figure 8.4) below which sensation abruptly changes, since such a change may indicate a spinal cord lesion requiring emergency intervention. Whenever there are uncertainties in the sensory exam, or other parts of the exam, a good strategy is to repeat the relevant portions of the exam several times.

CORTICAL SENSATION, INCLUDING EXTINCTION. Higher-order aspects of sensation, or **cortical sensation,** should be tested as well. To test **graphesthesia,** ask patients to close their eyes and identify letters or numbers that are being traced onto their palm or the tip of their finger (see neuroexam.com Video 75). To test **stereognosis,** ask patients to close their eyes and identify various objects by touch, using one hand at a time (see neuroexam.com Video 76). Test also for **tactile extinction** on double simultaneous stimulation (as described earlier; see neuroexam.com Video 77). Note that graphesthesia, stereognosis, and extinction cannot reliably be tested for unless primary sensation is intact bilaterally.

■ *What Is Being Tested?* Somatosensory deficits can be caused by lesions in peripheral nerves, nerve roots, the posterior columns or anterolateral sensory systems in the spinal cord or brainstem, the thalamus, or sensory cortex. Recall that position and vibration sense ascend in the posterior column pathway and cross over in the medulla, while pain and temperature sense cross over shortly after entering the spinal cord and then ascend in the anterolateral pathway (see Figures 2.13, 2.18, and 2.19). Intact primary sensation with deficits in cortical sensation such as

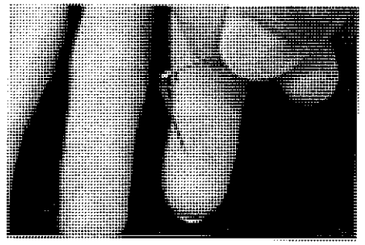

Pinprick

Temperature sensation

Vibration sense



Joint position sense

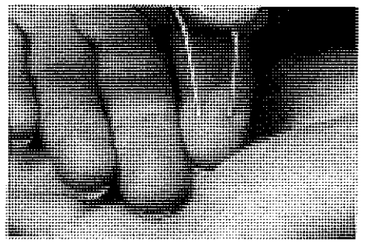

Two-point discrimination



Graphesthesia



Stereognosis

Tactile extinction

REVIEW EXERCISE

Now that we have discussed each part of the neurologic exam, review Table 3.1 once again. For each heading in the table, review in your mind (1) how that part of the exam is performed, and (2) what neuroanatomical systems are being tested.

agraphesthesia or astereognosis suggests a lesion in the contralateral sensory cortex. Note, however, that severe cortical lesions can cause deficits in primary sensation as well. Extinction with intact primary sensation is a form of hemineglect that is most commonly associated with lesions of the right parietal lobe. Like other forms of neglect, extinction can also occasionally be seen in right frontal or subcortical lesions, or in left hemisphere lesions causing mild right hemineglect.

The pattern of sensory loss can provide important information that helps localize lesions to particular nerves, nerve roots, and regions of the spinal cord, brainstem, thalamus, or cortex (see KCC 7.3, and Chapters 8 and 9).

The Neurologic Exam as a Flexible Tool

In actual clinical practice, the neurologic exam just described is hardly ever performed in its entirety from start to finish. As we mentioned earlier, with experience, one learns how to perform a screening exam covering the most important parts of the assessment and then focuses on relevant portions of the exam in greater detail depending on the clinical situation. In the sections that follow, we will discuss some alternative exam strategies and limitations in interpretation in certain situations, as well as examination techniques used for the following special circumstances: coma, brain death, and somatoform psychiatric disorders.

Exam Limitations and Strategies

One of the more challenging aspects of the neurologic exam is that impairments in one area can affect the patient's ability to perform other parts of the exam. If, for example, during the mental status exam a patient is not fully alert, attentive, cooperative, and possessing intact language functions, then during the motor exam, detailed testing of each individual muscle group will not be possible. Therefore, the examiner must be prepared to modify the exam appropriately on the basis of the patient's limitations.

In addition to strategies for working around limitations, it is important to know when parts of the exam cannot be done reliably in different situations. Documentation of the patient's limitations and how they affected the exam are essential. For example, in a patient with impaired attention, it is preferable to write "joint position sense testing was unreliable due to impaired attention" rather than "joint position sense was poor."

We will now describe a few specific strategies for examining patients with deficits. In mild to moderate **impairment of alertness or attention**, most aspects of the exam can be done with repeated stimulation of the patient. Patience is required. In severe impairment, the various strategies outlined later for the comatose patient are employed. With the **uncooperative patient**, different strategies are used depending on the situation. These include careful observation of spontaneous speech and movements and, when appropriate, some techniques from the coma exam (see next section).

With mild to moderate **impairment in language comprehension,** patients can often understand some simple questions or commands, and sometimes have an easier time understanding gestures or demonstrations of the action desired. For impaired expression, the patient can be asked yes–no or multiple-choice questions. For testing memory, several objects can be hidden around the room and the patient can be asked to find them after a delay. Again, patience and creativity are essential.

With **sensory and motor neglect**, some patients will show an improvement when the head is turned towards the affected side. With motor neglect, some patients show improved performance when their attention is repeatedly directed to the affected side, in response to pain, or during activities requiring bimanual coordination. When performing the motor exam on patients with **apraxia,** they may show improved strength if the movement is demonstrated or if their limbs are moved through the desired motion before allowing them to continue on their own. Sometimes, midline and appendicular motor functions are differentially affected. For example, some patients can close their eyes and stick out their tongue on command but cannot squeeze the examiner's hand. In **motor impersistence,** estimates of limb weakness or of gaze deficits must be made based on any deficits in the brief movements achieved by the patient.

In patients with bilateral **deafness,** communication can usually be achieved by writing or using a sign language interpreter, and nonauditory language comprehension can still be tested. In patients who are **unable to speak** due to motor deficits, or who are intubated, expressive communication can often be achieved by providing the patient with a pen and paper, computer keyboard, or other device or code, including eye movements or blinking for patients with severe motor impairment (see KCC 14.1).

Numerous additional strategies can be employed for examining patients in special situations, some of which will be described in the sections that follow.

Coma Exam

The coma exam is much simpler than the exam in the awake patient. The same general format is used; however, the exam is shorter because many things cannot be tested without the patient's cooperation. An advantage of the short length of the coma exam is that it can be done quickly in emergency situations, thus enabling a rapid assessment of neurologic status that often yields critical information for patient care.

For patients who are neither fully awake nor fully unconscious, various elements of the coma exam and the exam in the awake patient should be combined. Similarly, for the uncooperative but awake patient, some elements of the coma exam may be useful. Review the overall format of the coma exam shown in Table 3.8. Since many aspects of the coma exam are the same as in the general neurologic exam, these elements will be described more briefly here; refer to the previous discussion and earlier sections titled "What Is Being Tested?" for details.

General Physical Exam

As always, a good general physical exam should be performed in the comatose patient. Particular attention should be paid to parts of the exam that could reveal the cause of coma (see Table 3.2), such as vital signs, airway status, signs of cranial trauma (Table 3.9), nuchal rigidity (see KCC 5.9), and so on. If trauma is suspected, the neck should be immobilized with a rigid cervical collar.

1. Mental Status

Coma is defined by Plum and Posner (1980) as unarousable unresponsiveness in which the patient lies with eyes closed. There is a wide continuum of levels of consciousness between coma and the fully awake state. A variety of more

TABLE 3.8 Outline of the Neurologic Exam in the Comatose Patient

I. MENTAL STATUS

Document level of consciousness with a *specific statement* of what the patient did in response to particular stimuli

II. CRANIAL NERVES

1. Ophthalmoscopic exam (CN II)
2. Vision (CN II)
   - Blink to threat
3. Pupillary responses (CN II, III)
4. Extraocular movements and vestibulo-ocular reflex (CN III, IV, VI, VIII)
   - Spontaneous extraocular movements
   - Nystagmus
   - Dysconjugate gaze
   - Oculocephalic maneuver (doll's eyes test)
   - Caloric testing
5. Corneal reflex, facial asymmetry, grimace response (CN V, VII)
6. Gag reflex (CN IX, X)

III. SENSORY AND IV. MOTOR EXAM

1. Spontaneous movements
2. Withdrawal from a painful stimulus

V. REFLEXES

1. Deep tendon reflexes
2. Plantar response
3. Posturing reflexes
4. Special reflexes in cases of suspected spinal cord lesions (see Table 3.7)

VI. COORDINATION AND GAIT

Usually not testable

poorly defined terms are sometimes used to describe different states along this continuum, such as lethargy, stupor, obtundation, semicoma, and so on. Use of these terms without further details can be confusing to other physicians when they read the chart and try to assess the patient's progress. Therefore, it is essential to document the patient's level of alertness with a *specific statement* of what the patient did in response to particular stimuli, for example:

"The patient opens eyes and turns toward voice but obeys no verbal commands," or

"The patient responds only to painful sternal rub by moving the right arm and grimacing," or

"The patient is unresponsive to voice and sternal rub."

Level of consciousness is often the only part of the mental status exam that can be performed in these patients. Recall that consciousness can be impaired by damage to the brainstem reticular formation, and in bilateral lesions of the thalami or cerebral hemispheres (see Figure 2.23). It may also be mildly impaired in unilateral cortical or thalamic lesions. Toxic or metabolic factors are also common causes of impaired consciousness because of their effects on these structures (see KCC 14.2; KCC 19.14–19.16).

TABLE 3.9 Important External Signs of Cranial Trauma

NAME	DESCRIPTION
Bony step-off	Palpable discontinuity in shape of skull due to displaced fracture
CSF rhinorrhea	Exudation of cerebrospinal fluid from the nose due to base-of-skull fracture usually involving the ethmoid bone
CSF otorrhea	Exudation of cerebrospinal fluid from the ear due to base-of-skull fracture usually involving the temporal bone
Hemotympanum	Dark purple blood visible behind the tympanic membrane caused by base-of-skull fracture usually involving the temporal bone
Battle's sign	Dark purple ecchymoses visible in the skin overlying the mastoid processes due to base-of-skull fracture and blood exudation into the subcutaneous tissues
Raccoon eyes	Dark purple ecchymoses visible in the skin around the eyes due to base-of-skull fracture and blood exudation into the subcutaneous tissues

A number of conditions can be mistaken for coma but are actually quite different from coma in anatomy and pathophysiology. Large lesions involving the frontal lobes or their connections can cause a condition resembling coma called **akinesia** or **abulia** (see Table 14.3). In this state the patient has profoundly decreased initiative and minimal responsiveness, but the eyes are usually open and there may be occasional normal-appearing movements. **Catatonia** is another condition in which there is profoundly decreased responsiveness due to psychiatric illness. In **locked-in syndrome,** consciousness and sensation may be normal, but the patient is unable to move because of a lesion in the brainstem motor pathways or because of peripheral neuromuscular blockade (see KCC 14.1).



Ophthalmoscopic exam

2. Cranial Nerves

Examination of the cranial nerves provides crucial information about brainstem dysfunction as the possible cause of coma.

OPHTHALMOSCOPIC EXAM (CN II). Examine both retinas carefully with an ophthalmoscope, looking especially for papilledema, suggesting elevated intracranial pressure (see KCC 5.3; see also neuroexam.com Video 25).

Blink to threat

VISION (CN II). If the patient cannot cooperate with visual field testing, the **blink-to-threat** test can be used to roughly map visual fields. Observe whether the patient blinks in response to moving your hand rapidly toward their eyes from different directions (see neuroexam.com Video 28).

PUPILLARY RESPONSES (CN II, III). This is one of the most important parts of the exam in patients with impaired consciousness. Pupil size and responsiveness can be a helpful guide to the cause of coma (see Table 14.5; neuroexam.com Video 29). Although many exceptions exist, toxic or metabolic causes of coma often produce normal-sized, reactive pupils. Asymmetrical or bilateral dilated, unresponsive ("blown") pupils can indicate transtentorial herniation (see KCC 5.4) or other disorders affecting the midbrain. Bilateral small but responsive pupils are often seen in pontine lesions. Bilateral pinpoint pupils are seen in opiate overdosage.



Pupil light reflex

OKN



Oculocephalic testing

MNEMONIC



Corneal reflex

EXTRAOCULAR MOVEMENTS AND VESTIBULO-OCULAR REFLEX (CN III, IV, VI, VIII). Check for spontaneous extraocular movements, nystagmus, dysconjugate gaze, or fixed deviation of the eyes in a particular direction (see neuroexam.com Videos 32–35). OKN can sometimes be useful in eliciting eye movements and testing vision in uncooperative patients, but it is often suppressed when consciousness is impaired. If the patient cannot follow commands to move their eyes, the vestibulo-ocular reflex can be used to test whether brainstem eye movement pathways are intact (see Figures 12.18, 13.12). Elicit the **oculocephalic reflex** by holding the eyes open and rotating the head from side to side or up and down. These maneuvers obviously should not be performed in cases of head or neck injury until possible cervical spinal trauma has been ruled out by appropriate radiological studies. The oculocephalic reflex is present if the eyes move in the opposite direction of the head movements, and it is therefore sometimes called **doll's eyes.** Note that in awake patients, doll's eyes are usually not present. This is because voluntary eye movements mask the reflex. Thus, the absence of doll's eyes suggests brainstem dysfunction in the comatose patient but can be normal in the awake patient.

Another, more potent stimulus of the vestibulo-ocular reflex is **caloric stimulation.** Always examine the external auditory canal first with an otoscope. Then, with the patient lying in the supine position and the head elevated at 30°, infuse ice water into one ear. If the brainstem vestibulo-ocular reflex pathways are intact, this will produce nystagmus, with the fast phase directed opposite to the side of the cold water infusion. A useful mnemonic for interpreting the results of this test is **COWS** (**c**old **o**pposite, **w**arm **s**ame). After waiting 5 to 10 minutes for equilibration, try the second ear to drive the eyes in the opposite direction.

CORNEAL REFLEX, FACIAL ASYMMETRY, GRIMACE RESPONSE (CN V, VII). Look for facial asymmetry at rest, and asymmetrical spontaneous blinking or grimacing. Test the **corneal reflex** by touching each cornea gently with a cotton wisp (see KCC 12.4; see also neuroexam.com Video 37). Facial grimacing should also be observed in response to pain during the sensory and motor exam (to be discussed shortly) or in response to firm pressure applied to each orbital ridge.

GAG REFLEX (CN IX, X). Test the **gag reflex** by touching the posterior pharynx on each side with a cotton swab. In intubated patients the endotracheal tube can be shaken slightly to elicit a gag reflex. It is also helpful to ask personnel who were present at the time of intubation if a gag reflex was observed, or if a gag or cough reflex occurs during suctioning of the tracheal passages.

3. Sensory Exam and 4. Motor Exam

Look for spontaneous movements of all extremities. Test resting muscle tone. You can assess asymmetries in tone by raising each limb and letting it fall to the bed (see neuroexam.com Videos 49, 50).

Test each limb for **withdrawal from a painful stimulus,** such as nail bed pressure or skin pinch. Several different responses are possible, depending on the severity of damage to the nervous system. Beginning with the least severe, a lethargic but otherwise intact patient may wake up and shout at the examiner. Thus, out of consideration to the patient, painful stimuli should be used only when absolutely necessary. A more lethargic patient may not wake up fully, but may **localize** the stimulus by turning toward it and may use other limbs to attempt to stop the stimulus in addition to withdrawing the limb from the pain. Grimacing provides additional evidence that the pain sensory pathways are functioning. More severely impaired patients may simply withdraw the limb from the pain. The examiner must be careful to distinguish **purposeful withdrawal** from posturing (discussed in the next section). Finally, if the pain sensory pathways or motor pathways for the limb are not functional, there may be no response.

5. Reflexes

Test deep tendon reflexes and the plantar response as in the awake patient (see Tables 3.6, 12.18, 13.12; neuroexam.com Videos 58, 59).

Posturing reflexes can be seen in patients with damage to the descending upper motor neuron pathways. These reflexes depend on brainstem and spinal circuitry and are often seen in severe lesions associated with coma. Sherrington studied the effects of lesions at various levels in the brainstem on postural reflexes in the cat. In the **decorticate** preparation, the brainstem was transected above the level of the red nuclei; in the **decerebrate** preparation, the transection was performed below the red nuclei. In response to a painful stimulus the decorticate cat flexes its upper limbs and extends its lower limbs, while the decerebrate cat extends both upper and lower limbs. In humans, the anatomical interpretation of flexor or extensor posturing has not been localized to particular brainstem structures. Thus, although the terms "decorticate" and "decerebrate posturing" are sometimes used with patients, it is probably more correct instead to use the terms **flexor** and **extensor posturing** and to mention which limb is involved. Although there are many exceptions, in humans as well as animals, flexor (decorticate) posturing tends to occur with lesions higher in the neuraxis at the midbrain or above, whereas extensor (decerebrate) posturing tends to occur with more severe lesions extending lower down in the brainstem. (Mnemonic: in decorticate posturing the lesion is higher, and flexed arms point up toward the cortex; in decerebrate posturing the lesion is lower, and extended arms point down.) Extensor posturing may carry a slightly worse prognosis.

Flexor posturing of the upper extremities is shown in Figure 3.5A. In extensor posturing of the upper extremities, the arms are extended and rotated inward, as shown in Figure 3.5A,B. Extensor posturing of the lower extremities often accompanies either flexor or extensor upper extremity posturing, as is shown in Figure 3.5A,B). These reflexes depend on brainstem function. Their presence thus suggests damage to descending motor pathways, with some brainstem function left intact. They can occur unilaterally or bilaterally and can be different on the two sides. It is important to distinguish these reflexes from purposeful withdrawal. You can make this distinction by pinching the skin on the extensor and flexor sides of the limb and noting the direction of movement. For example,



Plantar response

MNEMONIC

Figure 3.5 Posturing and Triple Flexion (A) Flexor (decorticate) posturing. (B) Extensor (decerebrate) posturing. (C) Triple flexion.

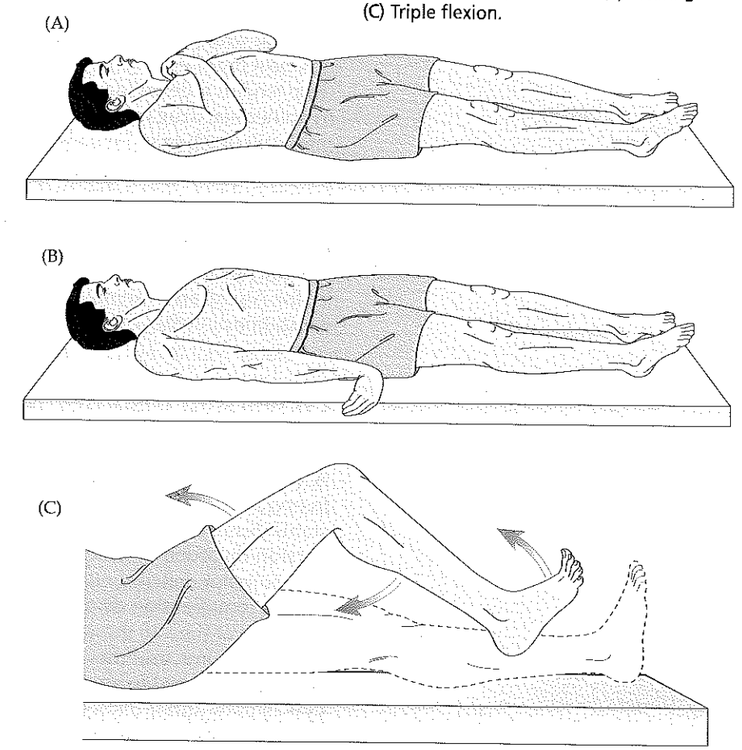

in flexor posturing the arm flexes even when the flexor side of the arm is pinched, thus moving *toward* the painful stimulus. In purposeful withdrawal, on the other hand, the movement is always *away from* the painful stimulus.

A flexion reflex in the lower extremity can sometimes be seen as well. This is called **triple flexion** because it involves flexion at the thigh and knee, and dorsiflexion at the ankle (see Figure 3.5C). In contrast to the other postural reflexes already mentioned, triple flexion does not require brainstem function and depends only on spinal cord circuitry. Once again, you can distinguish this reflex from purposeful withdrawal by pinching the dorsal and ventral aspects of the leg or foot.

In patients with suspected spinal cord injuries, the special reflexes listed in Table 3.7 may further aid in localization.

6. Coordination and Gait

These are usually not testable in this setting.

Brain Death

The definition of **brain death** is irreversible lack of brain function. The exact criteria used for brain death depend on the hospital; however, the mainstay of the evaluation is the neurologic exam. Generally speaking, there must be no evidence of brain function, including the brainstem. In addition to conducting the usual neurologic exam, in order to ensure that no brainstem function is present, the examiner does caloric testing, as well as an **apnea test,** in which lack of spontaneous respirations without the ventilator must be demonstrated despite certain standard changes in blood pH or pCO_2. In the United States, a patient with posturing reflexes involving the brainstem (see Figure 3.5) does not meet brain death criteria, although a patient with only triple flexion and deep tendon reflexes may. Reversible causes such as hypoxia, hypoglycemia, hypothermia, drug overdose, and so on must be tested for. At least two separate brain death examinations should be done to confirm the diagnosis. If part of the clinical evaluation is inconclusive, then confirmatory tests are done—for example, an angiogram that demonstrates no flow to the brain or an EEG that demonstrates electrocerebral inactivity. These tests, however, play a confirmatory role only, and the diagnosis of brain death remains a clinical one. Specific practice parameters for determining brain death have been published by the American Academy of Neurology (see References), and by similar organizations in other countries.

Conversion Disorder, Malingering, and Related Disorders

A number of disorders can mimic neurologic illness but in fact are psychiatric in origin. We have already discussed, under the mood portion of the mental status exam, how difficult this distinction can be. One such disorder is **conversion disorder,** in which psychiatric illness causes the patient to have sensory or motor deficits without a corresponding focal lesion in the nervous system. In **somatization disorder,** patients have multiple somatic complaints that change over time. In these two disorders patients are not consciously "faking" their symptoms, and they usually believe that they have a nonpsychiatric illness. It is essential to avoid being judgmental regarding such patients, since they usually suffer distress and functional impairment from their condition that is equal to or even worse than that of patients with identifiable lesions.

Other terms that are sometimes used for these types of disorders include *hypochondriasis* and *hysteria.* Some other related examples include *psychogenic amnesia* and *psychogenic coma.*

In a second, much less common class of disorders, patients do have conscious control over their symptoms, and they are intentionally using them for an ulterior motive. In **factitious disorder** (formerly known in severe cases as **Munchausen syndrome**) the ulterior motive is internal to the patient. It is believed that these patients feign illness, including neurologic illness, because they gain some form of emotional pleasure from assuming the role of patient. In **malingering,** the ulterior motive involves some *external gain* for the patient, such as avoiding work, obtaining disability benefits, or the like.

While it is difficult to distinguish these disorders from neurologic illness, it can often be even more difficult to distinguish these disorders from each other, and sometimes there is overlap. There is an unfortunate tendency to dismiss all such patients as "fakers." However, these patients may be severely impaired by their illnesses, and they deserve psychiatric care to help them recover and to help avoid future confusion with neurologic disease. In addition, overhasty labeling of a patient's symptoms as psychiatric in origin without appropriate investigation can lead to misdiagnosis, particularly when the neurologic findings are subtle or when neurologic and psychogenic diseases overlap, as is often the case.

The most important tool for identifying these patients and for ruling out focal lesions in the nervous system is a thorough knowledge of the neurologic exam and of neuroanatomy. Of the many techniques that can be used, only a few of the most clear-cut methods are described here (see the references at the end of this chapter for more complete discussion):

Hand-dropping test in pseudocoma. When a patient is truly in coma and their hand is released directly above their face, their hand should strike their face on its way down.

Saccadic eye movements in pseudocoma. Saccades should not be present in coma. Note, however, that they may be present if the patient is *locked in* (see KCC 14.1), or if they are experiencing sleep paralysis, as is seen in narcolepsy (see Chapter 14).

Variable resistance. A patient with psychogenic weakness of a limb may vary their resistance over a wide range up to normal strength when their strength is tested by variable resistance from the examiner. This must be distinguished from a similar condition called paratonia, often seen in frontal lobe lesions (see KCC 19.11)

Hoover test. In unilateral leg weakness, palpate the contralateral gastrocnemius while the patient tries to raise the affected leg off the bed. In normal individuals the contralateral gastrocnemius is used to exert force against the bed, and it should contract. Lack of gastrocnemius contraction demonstrates lack of effort.

Unconscious movements. Patients with psychogenic paralysis may be observed to move the affected limbs during sleep, or while being transferred onto a stretcher, or in other situations when distracted.

Midline change in vibration sense. Loss of vibration sense on only one side of the sternum or one side of the skull is nonphysiological, since vibration is readily conducted through the bone to the contralateral side.

Other neuroanatomical inconsistencies can sometimes be detected if the examiner uses common sense, a little experience, and a thorough neurologic exam in which uncertain portions of the exam are repeated. It is important, once again, to be cautious because lesions in the nervous system often present with atypical or unusual symptoms and signs for a given location, leading to apparent inconsistencies in the exam. Finally, it should be noted that a substantial number of patients have disorders in which neither a clear-cut neurologic nor a psychiatric diagnosis can be made. Patients of this kind are in danger of being treated by *neither* neurologists nor psychiatrists, who both may consider them out of their area of expertise. A better approach would be for these patients to be followed by *both* neurologists and psychiatrists until either a clear-cut diagnosis emerges, or they respond to empiric therapy.

The Screening Neurologic Exam

When evaluating patients, it is useful to be proficient in a brief form of the neurologic exam that can be performed in less than 10 minutes. While performing this abbreviated exam, it is essential to be highly vigilant for any suggestion of a subtle abnormality. Any suspicious part of the examination should then be repeated and evaluated more carefully with more detailed tests, including those described earlier in this chapter. In addition, any suspicions that arise from the patient history should be investigated more closely. For example, a patient with visual complaints should have a detailed visual exam. A patient with complaints of weakness should have a detailed motor exam.

There is no single standard for a screening neurologic exam. However, an example is listed in Table 3.10 that may be useful as a minimal starting point, from which more detailed testing should be done when appropriate.

TABLE 3.10 Minimal Screening Neurologic Exam[a]

PART OF EXAM	TESTS
Mental status	Level of alertness and orientation. Assess attention using months forward/backward. Immediate registration and delayed recall of 3 objects for 4 minutes (timed). Naming of watch parts. Note behavior, language, affect, etc., while taking history.
Cranial nerves	Pupil light reflexes. Ophthalmoscopic exam. Visual fields, including extinction testing. Horizontal and vertical smooth pursuit eye movements. Facial sensation to light touch including extinction testing. Facial symmetry during emotional smile. Hearing of finger rub bilaterally. Palate elevation. Note quality of voice during remainder of exam. Head turning and shoulder shrug against resistance. Tongue protrusion.
Motor exam	Drift. Rapid hand and foot tapping. Upper and lower extremity tone. Strength in several proximal and distal muscles in the upper and lower extremities bilaterally (e.g., finger extensors, finger abductors, wrist extensors, biceps, triceps, deltoids, iliopsoas, quadriceps, foot and toe dorsiflexors, and knee flexors).
Reflexes	Bilateral biceps, brachioradialis, patellar, Achilles tendon, and plantar reflexes.
Coordination and gait	Finger–nose–finger and heel–shin tests bilaterally. Gait and tandem gait.
Sensory exam	Light touch in hands and feet, including extinction testing. Pin prick or temperature testing in feet bilaterally. Vibration and joint position sense in feet bilaterally.

[a]Duration = 5 to 10 minutes

Conclusions

In this chapter we have reviewed techniques for performing the neurologic exam in many different situations. We have seen how the exam can be adapted to test patients who are awake and cooperative; comatose; or suffering from psychiatric disorders, malingering, or any combination of other impairments. In addition, we have begun to explore the neuroanatomical systems being tested and the effects of disease on function.

The lessons learned here will serve as the basis for understanding the clinical cases in Chapters 5 through 19 and will help localize lesions to particular areas of the nervous system. Once the clinical suspicion of a lesion has been raised as a result of the history and physical exam, several important decisions need to be made. Depending on the type and location of the lesion that is suspected, the options include emergency surgical or medical therapy; less urgent therapy; or further investigations, including blood tests, cerebrospinal fluid tests, electrophysiological studies, or neuroradiological imaging.

The clinician is guided in these difficult decisions by the information obtained from the history and the exam. For example, the decisions to do neuroimaging, which method to use, and what areas of the nervous system to study are based on conclusions made about the probable location and nature of the lesion derived from the history and physical exam. In the next chapter we will discuss the use of neuroimaging and its applications to understanding clinical cases in the context of the complete patient assessment.

References

Aids to the Examination of the Peripheral Nervous System. 1986. Baillière Tindall on behalf of the Guarantors of Brain, London.

Bickley LS, Hoekelman RA (eds.). 1999. *Bates' Guide to Physical Examination and History Taking*, 7th Ed. Lippincott-Raven, Philadelphia.

Blumenfeld H. 2001. *The NeuroExam Video.* Sinauer, Sunderland, MA.

Brazis PW, Masdeu JC, Biller J. 1996. *Localization in Clinical Neurology*, 3rd Ed. Little, Brown, Boston.

Devinsky O, Feldmann E. 1988. *Examination of the Cranial and Peripheral Nerves.* Churchill Livingstone, New York.

Gilman S. 2000. *Clinical Examination of the Nervous System.* McGraw-Hill, New York.

Goldberg S. 1987. *The Four-Minute Neurological Exam.* MedMaster, Miami, FL.

Haerer AF. 1992. *DeJong's The Neurologic Examination*, 5th Ed. Lippincott, Philadelphia.

Patten J. 1995. *Neurological Differential Diagnosis: An Illustrated Approach*, 2nd Ed. Springer Verlag, London.

Plum F, Posner JB. 1980. *The Diagnosis of Stupor and Coma*, 3rd Ed. FA Davis, Philadelphia.

Quality Standards Subcommittee, American Academy of Neurology. 1995. Practice parameters for determining brain death in adults (summary statement). *Neurology* 45(5): 1012–1014.

Russ RT. 1999. *How to Examine the Nervous System*, 3rd Ed. Appleton & Lange, Stamford, CT.

Strub RL, Black FW. 2000. *The Mental Status Examination in Neurology*, 4th Ed. FA Davis, Philadelphia.

CHAPTER 4

Introduction
Imaging Planes
Computerized Tomography
CT versus MRI
Magnetic Resonance Imaging
Neuroangiography
Functional Neuroimaging
NEURORADIOLOGICAL ATLAS

Introduction to Clinical Neuroradiology

Advances in clinical imaging, particularly in neuroradiology, are some of the most exciting recent advances in medicine. One patient, a 52-year-old woman, suddenly developed left-sided weakness and increased reflexes. Although her initial head CT and conventional MRI scans were normal, a diffusion-weighted MRI revealed an infarct involving the right motor cortex. An MR angiogram and carotid Doppler studies suggested severe narrowing of the right internal carotid artery, later confirmed by conventional neuroangiography. Based on these findings, a surgical procedure was performed to open the narrowing in her carotid artery, and she subsequently did well. In this chapter, we will learn about current neuroimaging techniques and their clinical applications.

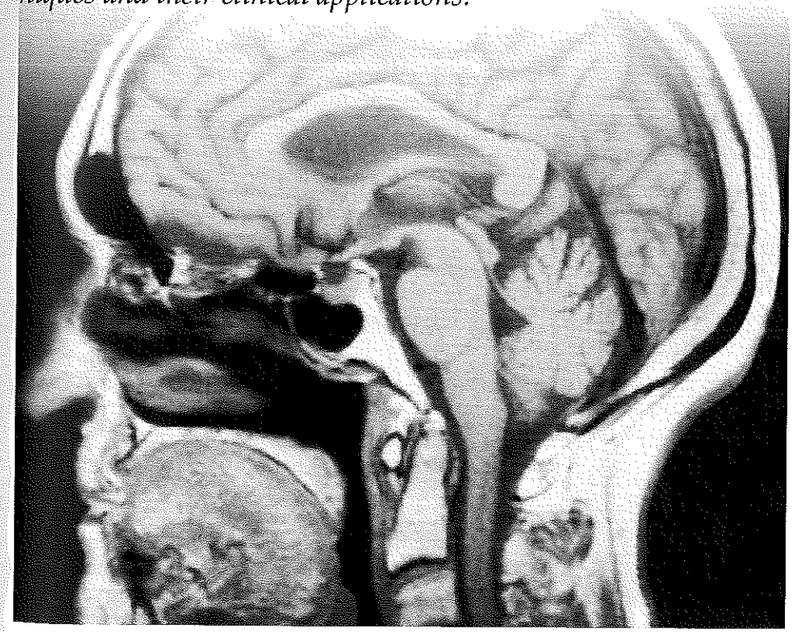

Introduction

Modern techniques of neuroimaging have revolutionized both clinical practice and neuroscience research. This chapter will focus on the three imaging modalities most commonly used in clinical practice: computerized tomography (CT), magnetic resonance imaging (MRI), and neuroangiography (including ultrasound, magnetic resonance angiography [MRA], and CT angiography). We will also briefly touch on functional imaging modalities such as positron emission tomography (PET), single photon emission computerized tomography (SPECT), and functional MRI (fMRI).

Imaging Planes

Most CT and MRI scan images are two-dimensional "slices" through the brain. The **imaging planes** used are similar to the horizontal (axial), coronal, and sagittal planes described in Chapter 2 (see Figure 2.5). However, the angle of the axial slices in CT scans is sometimes adjusted by a few degrees off the true axial plane (Figure 4.1). This adjustment enables the whole brain to be covered using fewer slices and decreases radiation exposure to the eyes. In MRI scans, the axial slices are usually true horizontal slices, although this may vary slightly depending on the institution. **Scout,** or **localizer, images** such as that shown in Figure 4.1 should be included on all CT and MRI films so that the exact angle of scanning can be documented. Although in practice a slight angulation off the horizontal plane does not greatly affect the appearance of images, it should be kept in mind, especially when carefully comparing scans for differences between them.

Figure 4.1 CT Scout (Localizer) Image Lateral view of skull is shown with imaging planes indicated by lines. The true horizontal plane is approximated by the orbitomeatal line, while the typical CT imaging plane is angled slightly upward anteriorly.

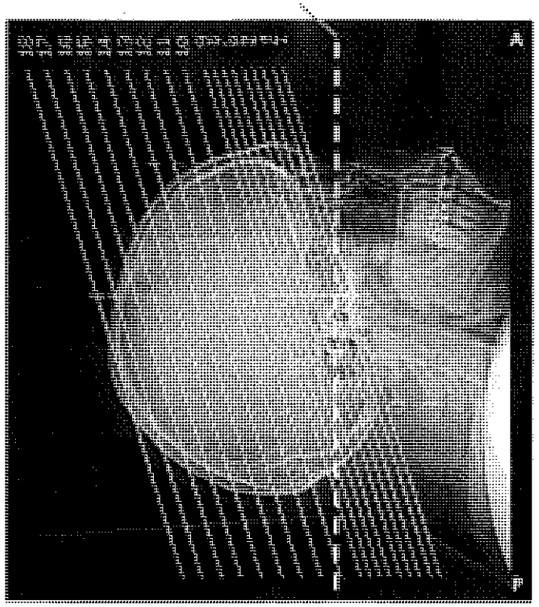

Computerized Tomography

Computerized tomography (CT) was developed directly from conventional X-ray technology and therefore shares many of the same principles. Like conventional X-ray radiographs, CT scans measure **density** of the tissues being studied. There are really only two differences from conventional X-rays:

1. Rather than taking one view, the X-ray beam is rotated around the patient to take many different views of a single **slice** of the patient; hence the term "tomography."
2. The X-ray data acquired in this way are then reconstructed by a computer to obtain a detailed image of all the structures in the slice (including soft tissues, liquid, and air, as well as bone) hence the term "computerized."

Recent advances in CT technology have now made it possible to acquire multiple CT slices simultaneously. For simplicity, we will first describe single-slice CT. The patient lies on a special table, which moves the patient in small steps through the scanner to obtain many horizontal slices. The scanner is shaped like a large ring (Figure 4.2). At each stop of the table a thin beam of X-rays is scanned through the patient from many different points around the ring and picked up by detectors on the opposite side of the ring. As a single beam of X-rays passes

through the patient in a CT scanner, it is partially absorbed by the tissues it encounters. The amount of energy absorbed depends on the *density* of the tissues traversed.

Since the X-ray beam is passed through the patient from many different directions, crossing and recrossing the same structures from different angles, enough information is obtained for the computer to calculate the density for every point within the horizontal slice. These densities are then displayed as an image that looks like a cross section through the head (Figure 4.3). More recently, **helical CT** scanners have been developed that can acquire data continuously as the patient moves through the scanner ring, without requiring stops. In addition, instead of acquiring single slices, up to four rows of detectors are now being used so that multiple overlapping slices can be obtained. These technical advances have greatly improved the resolution and speed of CT scanning.

As in conventional X-rays, dense structures like bone or other calcifications appear white in CT scans, and less dense materials such as air appear black (see Figure 4.3). The terms **hyperdense** and **hypodense** are frequently used to refer to brighter and darker areas, respectively, on CT scans. Structures of intermediate density similar to that of brain tissue appear gray and are called **isodense.** Cerebrospinal fluid (CSF) is dark gray, and fat tissue (seen subcutaneously just outside the skull) appears nearly black. Since fat is less dense than water, white matter (which has a high myelin content) appears slightly darker than the cellular gray matter (which has a high water content). Density in CT scans is often expressed in Hounsfield units (HU). The HU scale is based on the following values: HU = 0 for water, and HU = –1000 for air. Table 4.1 lists the HU numbers for several materials commonly imaged with CT scans. Take a few moments to review the series of normal CT scan images in Figure 4.12 in the Neuroradiological Atlas at the end of this chapter and to become acquainted with normal anatomy as seen in CT scans. Note that in horizontal (axial) sections through the brain (see Figures

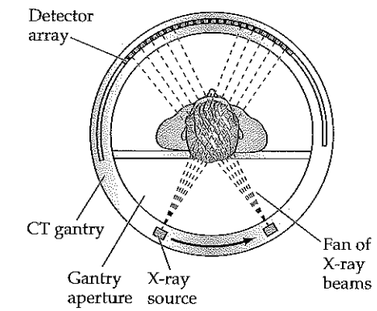

Figure 4.2 Schematic Diagram of CT Scanning Gantry

REVIEW EXERCISE

Cover the labels on the CT images in the Neuroradiological Atlas (see Figure 4.12) and name as many structures as possible.

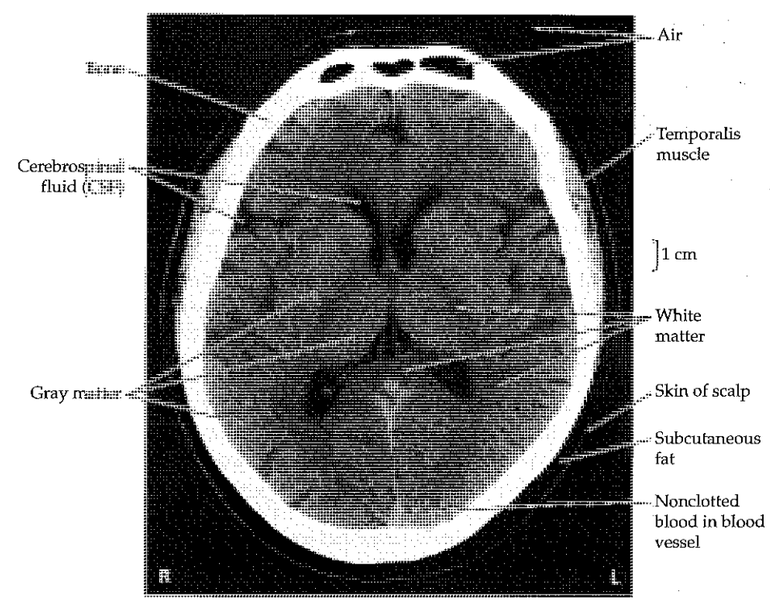

Figure 4.3 Typical CT Scan Image Image was acquired in an axial plane, without intravenous contrast. See also Table 4.1.

MNEMONIC

4.11C, 4.12J,K, and 4.13J,K), several important gyri form a sideways "T" shape, facilitating localization of the central sulcus. The superior frontal gyrus and the superior parietal lobule form the top of the "T," and the stem of the "T" is formed by the pre- and postcentral gyri together.

CT scans can be used to visualize a variety of different intracranial abnormalities. The appearance of **hemorrhage** on CT depends on how recently it occurred (see Figure 5.19). Fresh intracranial hemorrhage coagulates nearly immediately and therefore shows up on CT scans as hyperdense areas relative to brain. With typical image display settings, fresh hemorrhage may appear about as white as bone, although the actual HU is significantly lower (see Table 4.1). As the clot is broken down, after about a week it becomes isodense with brain tissue, and after 2 to 3 weeks it becomes hypodense (see Figure 5.19).

Acute **cerebral infarctions** often cannot be seen by CT scanning in the first 6 to 12 hours after the event. Subsequently, cell death and edema lead to an area of hypodensity seen in the distribution of the artery that has been occluded, along with some distortion of the local anatomy due to the edema (see Figures 10.19, 10.21). Over weeks to months, the brain tissue surrounding the infarct may shrink, producing a local area of prominent sulci or enlarged ventricles. Persistent areas of hypodensity in the brain tissue may be present as a result of gliosis, and of brain necrosis with replacement by CSF.

Neoplasms may appear hypodense, hyperdense, or isodense depending on the type and stage (see Figures 15.17, 19.19, and 19.24). They may contain areas of calcification, hemorrhage, or fluid-filled cysts. Neoplasms may produce surrounding edema that is hypodense. Intravenous contrast dye (discussed shortly) is often helpful in visualizing neoplasms.

Mass effect is anything that distorts the brain's usual anatomy by displacement. This can occur with edema, neoplasm, hemorrhage, and other conditions. It can be detected on CT by localized compression of the ventricles, effacement of sulci, or distortion of other brain structures seen, for example, in subfalcian herniation of brain structures across the midline (see Figure 5.28).

Intravenous contrast material is sometimes used in CT scanning, especially to facilitate visualization of suspected neoplasms or brain abscess. The contrast material contains iodine, which is denser than brain and will therefore appear hyperdense (white) in areas of increased vascularity or breakdown of the blood–brain barrier (see Figures 15.17, 19.19). Often images are obtained with and without intravenous contrast for comparison. Review the contrast CT image in Figure 4.4 and identify the structures that normally take up contrast by comparison to the noncontrast images. These structures include arteries, venous sinuses, the choroid plexus, and dura. In suspected intracranial hemorrhage, it is very important to obtain a **noncontrast** CT scan. This is because small hemorrhages often appear on CT as whitish areas at the base of the brain, which could be masked by the normal hyperdense contrast material in blood vessels and meninges at the brain base.

CT scanning is combined with another form of contrast enhancement in **myelography.** In this technique, a needle is introduced into the CSF, usually by lumbar puncture (see KCC 5.10), and an iodinated contrast dye is introduced into the CSF. This allows better radiological visualization of nerve roots and of abnormal impingements on the spinal CSF space—caused, for example, by a herniated intervertebral disc. In conventional myelography plain films are made (see Figure 8.17). In **CT-myelography,** a CT scan of the spine is performed as well, providing very clear visualization of the vertebral bones and the contents of the spinal canal (see Figure 8.21).

Images produced by CT can be adjusted to improve the contrast for tissues over a particular density range. To optimize contrast we adjust two parameters, the **window** and **level,** which determine the conversion between the calculated density values and the gray scale used for display. Thus, for example, images displayed with **bone windows** are used to carefully inspect the skull for fractures (see Figure 5.3), while soft tissue windows are used to look at brain structures.

TABLE 4.1 CT Hounsfield Units (HU) for Commonly Scanned Tissues

TISSUE	HU
Air	–1000 to –600
Fat	–100 to –60
Water	0
CSF	8–18
White matter	30–34
Gray matter	37–41
Freshly congealed blood	50–100
Bone	600–2000

CT versus MRI

MRI (see the next section) provides high-contrast, high-resolution imaging of the nervous system with striking anatomical detail. It is therefore the imaging method of choice for detecting low-contrast or small lesions such as multiple sclerosis plaques, low-grade astrocytomas, acoustic neuromas, and so on. In addition, unlike CT scanning, in which the dense bones at the base of the skull obscure the adjacent areas with "shadowing" artifact (see Figure 4.12B), MRI provides remarkably clear images of crucial basilar structures such as the brainstem, cerebellum, and pituitary fossa. The spinal cord is also more clearly visible on MRI for similar reasons.

Figure 4.4 CT Image with Intravenous Contrast This axial CT image demonstrates enhancement of arteries, venous sinuses, and dura mater (tentorium cerebelli).

MRI has its disadvantages as well. The main drawbacks are time, cost, and inferior performance in imaging fresh hemorrhage and bony structures. A typical MRI scan takes about 45 minutes to complete, while a quick CT scan in an unstable patient can be done in 5 to 10 minutes. A CT scan usually costs about two-thirds as much as an MRI. Finally, CT images depend on overall tissue density, while MRI depends on proton density and proton environment (see the next section). Therefore, bone (high overall density but low proton density) and fresh hemorrhage (high overall density due to fibrinogen but proton density and environment similar to CSF) are imaged better with CT than with MRI.

In summary (Table 4.2), CT is the preferred technique in patients with head trauma or suspected intracranial hemorrhage, and as a first screening method to detect most intracranial lesions, especially in the emergency setting. MRI is reserved for patients who, on the basis of the clinical story, are suspected of having low-contrast lesions or brainstem or skull-base lesions, or as a secondary technique when a lesion is suspected that was not visible on CT. In nonurgent situations, in which a single more definitive imaging method is desired, MRI is often the test of choice.

TABLE 4.2 CT versus MRI in Different Situations

SITUATION	CT BETTER	MRI BETTER
Head trauma	√	
Lower cost needed	√	
Subtle area of tumor, infarct, demyelination, etc.		√
Brainstem lesion		√[a]
Fresh hemorrhage	√	
Old hemorrhage		√
Speed needed	√[b]	
Skull fracture	√	
Calcified lesion	√	
Claustrophobic or obese (>250 lb) patient	√	
Pacemaker, or metallic fragments in heart or eye	√	
Anatomical detail needed		√

[a]CT is prone to shadowing artifact.
[b]Fast MRI technique, when available, is nearly as fast as CT.

Magnetic Resonance Imaging

The detailed physics of MRI are beyond the scope of this section (see the references at the end of this chapter for greater depth). Here we will discuss only a few basic

concepts that are of direct importance in viewing and interpreting MRI scans. **MRI (magnetic resonance imaging)** was developed from NMR (nuclear magnetic resonance). In both techniques a powerful magnetic field is applied that causes protons in the specimen (or person!) to align their intrinsic spins in parallel with the magnetic field (Figure 4.5A,B). Although protons are present in the nuclei of all atoms, the protons relevant to conventional MRI are only those forming hydrogen nuclei.

Radio waves are generated from an electrical coil that excites these protons, causing them to flip their spins away from the direction of the magnetic field. The longer the radio frequency pulse, the farther the net magnetization vector ***M*** will rotate away from the direction of the magnetic field (see Figure 4.5C). When the pulse stops, the proton spins relax back in parallel with the magnetic field and give off energy in the form of electromagnetic waves that are detected by the same emission–reception coil. In MRI, information from protons in different spatial regions can be obtained in three dimensions by the use of an additional set of coils called **magnetic gradient coils.**

Three properties of tissues determine the intensity of MRI signals for most MRI pulse sequences. One is **proton density.** The second and third are the **proton relaxation times** (T1 and T2). Proton relaxation from the excited state has two components—one along the *z-axis* parallel to the magnetic field (T1, also called longitudinal relaxation time) and one in the *x–y plane* perpendicular to the magnetic field (T2, also called transverse relaxation time) (see Figure 4.5).

T1 and T2 relaxation values for a given tissue depend on properties of the molecular environment such as efficiency in absorbing energy and proton–proton interactions that occur as protons relax from the excited state, as well as on slight inhomogeneities in the applied magnetic field. For biological tissues, T1 values range from about 300 to 2000 milliseconds, while T2 values range from about 30 to 150 milliseconds. In MRI, different radio wave pulse sequences are used to emphasize either T1 or T2 contrast. In the **spin echo (SE)** pulse sequence (the sequence most commonly used in MRI), two time intervals usually are indicated on films: **repetition time (TR)** and **echo time (TE)**.

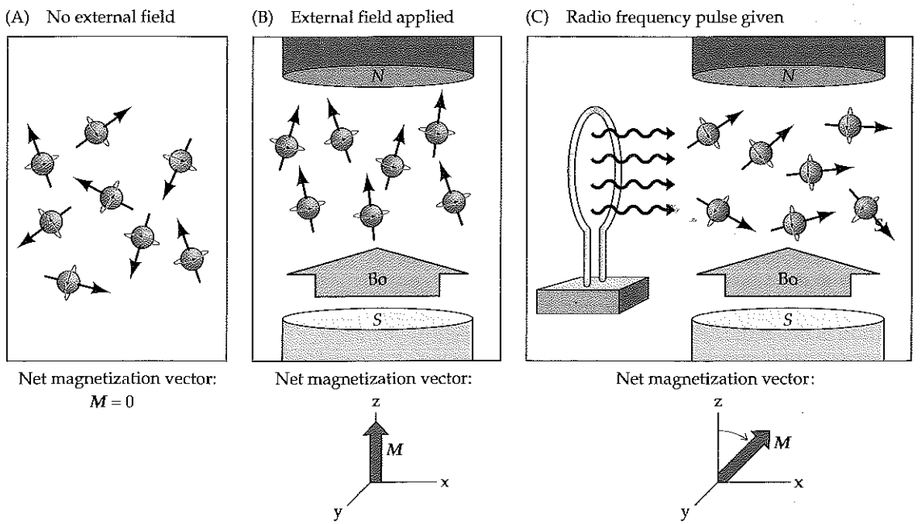

Figure 4.5 Physics of MRI Excitation Pulse (A) Proton spins are oriented randomly when no external field is present. Magnetic moments of the individual protons are indicated by small arrows. Net magnetization vector ***M*** is zero. (B) External magnetic field Bo is applied by the MRI scanner. Proton spins tend to align in parallel with Bo, resulting in a net magnetization vector ***M***, oriented along the z axis. (C) Radio frequency pulse is given by excitation/receiving coil. Energy is absorbed by protons and they begin to flip into a higher energy state, antiparallel to Bo. Net magnetization vector ***M***, therefore, rotates away from the z axis, towards the x–y plane.

The choice of TR determines the time during T1 relaxation when the MRI image is obtained, while TE determines when during T2 relaxation the MRI image is obtained. Contrast between different tissues is enhanced early during T1 relaxation, and late during T2 relaxation. Thus, a short TR (≤600 ms) and a short TE (≤30 ms) enhance T1 contrast maximally, and the resulting image is called a **T1-weighted image.** Conversely, a long TR (≥2000 ms) and a long TE (≥80 ms) enhance T2 contrast maximally, and the resulting image is called a **T2-weighted image.** A compromise—that is, an image obtained with a long TR and a short TE—is neither T1 nor T2 weighted and depends mainly on **proton density**.

MNEMONIC

So what does all this mean for looking at MRI scans? T1- and T2-weighted images look different from each other. As a rule of thumb, *T1-weighted images look like anatomical brain sections, while T2-weighted images look a bit like a film negative.* Thus, in T1-weighted images gray matter is gray and white matter is white, while in T2-weighted images the opposite is true (Table 4.3). T1-weighted images are often useful for identifying anatomy; T2-weighted images are better for detecting pathologic changes.

How can these differences between T1- and T2-weighted images be explained? Taking a somewhat simplified approach, the brightness in MRI images is determined mainly by

1. Water content
2. Fat content

Rather than talking about density, as in CT scans, MRI scans are described in terms of intensity, or brightness of the signal. Thus, brighter areas are referred to as **hyperintense** and darker areas as **hypointense.** The relative brightness of various tissues in T1, T2, and proton density images is summarized in Table 4.3. In **T1-weighted images,** water appears dark while fatty tissues appear bright (Figure 4.6A). Thus, T1-weighted images have the appearance of anatomical brain sections, with CSF appearing dark, gray matter appearing gray (higher water content), and white matter appearing white

TABLE 4.3 MRI Appearance of Commonly Scanned Tissues

TISSUE	T1-WEIGHTED	T2-WEIGHTED	PROTON DENSITY–WEIGHTED
Gray matter	Gray	Light gray	Light gray
White matter	White	Dark gray	Gray
CSF or water	Black	White	Dark gray
Fat	White	Black[a]	Black[a]
Air	Black	Black	Black
Bone or calcification	Black	Black	Black
Edema	Gray	White	White
Demyelination or gliosis	Gray	White	White
Ferritin deposits (e.g., in basal ganglia)	Dark gray	Black	Black
Ca^{2+} bound to protein	White	Dark gray	Dark gray
Proteinaceous fluid	White	Variable	Variable

[a]On fast spin echo (FSE) sequences (a faster variant of the SE sequence), fat appears bright in T2- and proton density–weighted images.

Figure 4.6 Typical MRI Images
T1-, T2-, and proton density–weighted images were obtained in an axial plane, without gadolinium contrast. See also Table 4.3. (A) T1-weighted image, acquired with spin echo (SE) pulse sequence. TR = 500, TE = 15. (B) T2-weighted image, acquired with fast spin echo (FSE) pulse sequence. TR = 4000, effective TE = 78. (C) Proton density–weighted image, acquired with FSE pulse sequence. TR = 4000, effective TE = 13.

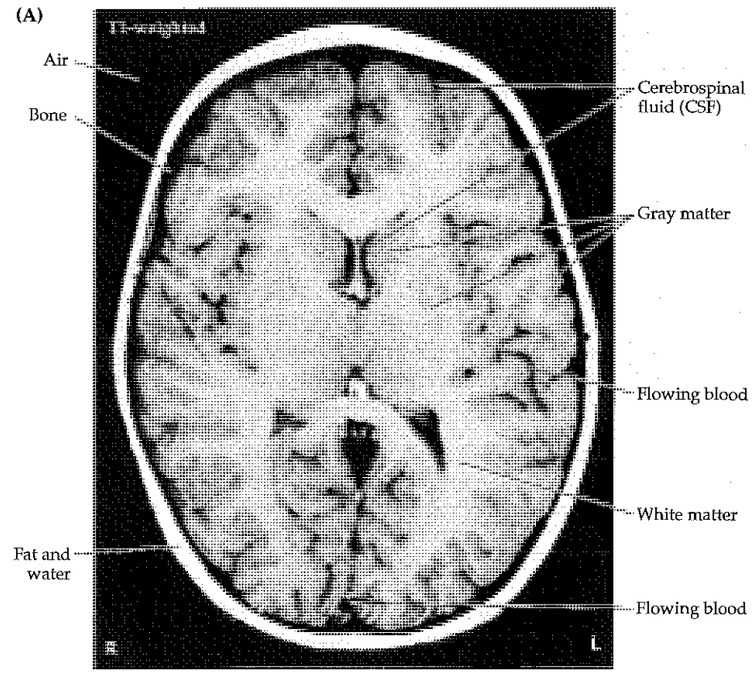

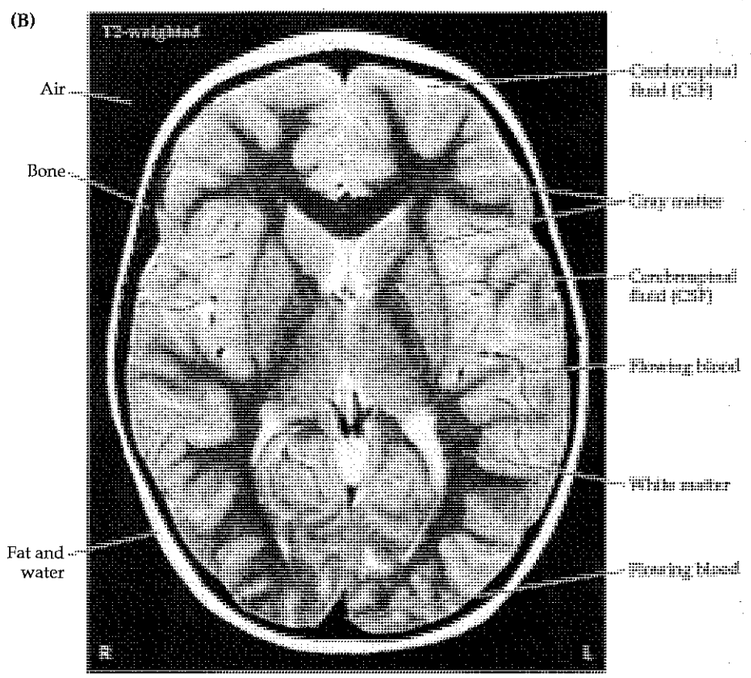

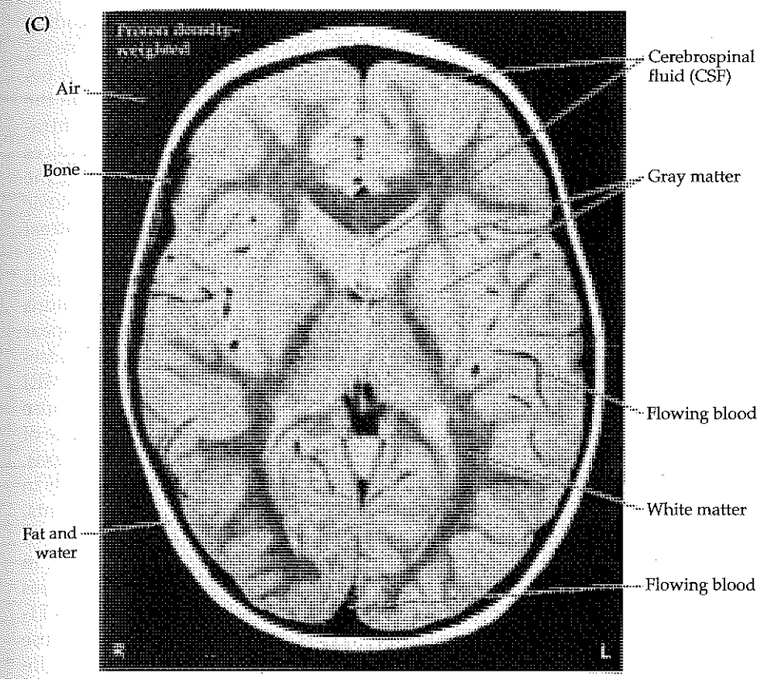

(higher lipid content). The resolution of fine anatomical detail can usually be seen better with T1-weighted images.

In **T2-weighted images,** on the other hand, water appears bright, and fat appears dark (see Figure 4.6B). Thus, CSF appears bright, while areas of brain edema, gray matter, and myelinated areas are, progressively, less bright, and epidural fat is very dark. T2-weighted images are generally noisier and have less resolution than T1-weighted images, but they have better contrast.

In **proton density–weighted images** (sometimes called **first echo** images), contrast between gray and white matter is generally reduced (see Figure 4.6C). The main utility of proton density images is that subtle abnormalities in the parenchyma, such as small areas of edema or infarction adjacent to the CSF, can be easily seen as bright regions. These small, bright abnormalities will also be present on T2 images; however, they are often harder to see on T2 images because of the relative brightness of adjacent CSF. A variety of additional specialized MRI pulse sequences and techniques exist that are beyond the scope of this discussion, but they are reviewed in the references listed at the end of the chapter.

In addition to fat and water content, the intensity of all MRI images depends on the number of measurable protons in the sample, or **proton density.** Simply put, the reason is that protons must be present in order for a signal to be generated. Therefore, on T1-weighted, T2-weighted, and proton density–weighted images, air appears black, and bony or calcified structures appear dark, because of the relative absence of water protons (see Table 4.3; Figure 4.6).

A number of other factors affect the intensity of MRI signals as well. **Paramagnetic** substances such as Ca^{2+} bound to protein, or iron in blood degra-

dation products, can cause either relatively bright or dark signals depending on the exact circumstances (see Tables 4.3 and 4.4). When special pulse sequences for **magnetic susceptibility** are used, even minute amounts of hemosiderin from an old hemorrhage can be detected as black areas on the scan. The paramagnetic substance **gadolinium** is used in MRI for intravenous contrast. In analogy with CT, gadolinium contrast injection produces a bright signal in regions of increased vascularity or breakdown of the blood–brain barrier. Gadolinium contrast agents are much less nephrotoxic and less prone to cause allergic reactions than are the iodinated contrast agents used in CT.

Another factor that can affect MRI signals is **flow artifact** in blood vessels and, to a lesser extent, in CSF. Flow artifact occurs as a result of protons moving rapidly into or out of the area being imaged. Some protons appear or disappear between the time that the excitation and recording radio frequency pulses occur. This change can cause increases or decreases in MRI signal intensity depending on the rate and direction of flow and on the pulse sequence used. Magnetic resonance angiography (MRA) takes advantage of these effects to create images of arterial blood flow (see the next section). MRI scans are also distorted by artifact in patients with metallic implants in the skull. Metallic fragments in the eye, pacemakers, cochlear implants, metallic heart valves, and older aneurysm clips can be moved or damaged by the powerful MRI magnet, and therefore will preclude MRI scanning in certain patients. **Intracranial hemorrhage** undergoes a characteristic series of changes on MRI images over time (Table 4.4). In simple terms, on both T1- and T2-weighted images, acute hemorrhage may be difficult to see because it is gray and resembles CSF. Subacute hemorrhage contains methemoglobin, causing it to appear white. Chronic hemorrhage contains dark areas resulting from hemosiderin deposition. Usually the center of the hemorrhage has a different composition from the periphery so that, particularly for older hemorrhages, there is a characteristic bright center with a dark rim. Eventually, the center of the hemorrhage may resorb, forming a fluid-filled cavity that is dark on T1-weighted images and bright on T2-weighted images (not shown in table).

We will now briefly summarize the above discussion (see Tables 4.3 and 4.4), and provide some examples. On MRI imaging, abnormal areas of increased fluid such as cysts, infarcts, edema, gliosis, or demyelination, appear dark on T1-weighted images (see Figures 7.20, 19.21) and bright on T2-weighted images (see Figures 6.16, 7.23, and 10.18). Regions of inflammation or neoplasms often enhance with intravenous gadolinium (see Figures 12.21, 15.18, and 18.18). Hemorrhage is difficult to see acutely, but becomes bright on subsequent imaging (see Figure 14.35), and then often develops both bright and dark regions (Table 4.4). New pulse sequences continually improve the clinical usefulness of MRI. For example, diffusion-weighted MRI (discussed later, in the section "Functional Neuroimaging") often allows visualization of acute cerebral infarcts far earlier than was possible previously (see Figures 14.23, 14.31).

Take a few moments now to review the series of normal T1-weighted MRI scan images in the Neuroradiological Atlas at the end of this chapter (see Figures 4.13–4.15) to become acquainted with normal anatomy as seen by MRI. The images in Figure 4.13 were obtained in approximately the same imaging planes as the CT images in Figure 4.12 (although the angle of the slices is somewhat more horizontal for the MRI images). Note the markedly superior resolution for the MRI images. In addition, note that the administration of intravenous gadolinium (Figure 4.7) causes enhancement of the arteries, venous sinuses, choroid plexus, and dura.

MRI scans are sometimes reformatted into three-dimensional surface representations. An example is shown in Figure 4.8. This method enables the detection of subtle abnormalities in sulcal morphology that may not be appreciated in two-dimensional sections. In addition, it can be helpful to represent functional neuroimaging data on a three-dimensional representation of the brain surface (see Figure 4.10).

TABLE 4.4 MRI Appearance of Intracranial Hemorrhage

TIME SINCE HEMORRHAGE	T1-WEIGHTED	T2-WEIGHTED
Acute: first 6–24 hours (intracellular oxyhemoglobin)	Gray	Light gray
Early subacute: 1–5 days (intracellular deoxyhemoglobin)	Gray	Dark gray
Middle subacute: 3–7 days (intracellular methemoglobin)	White	Dark gray
Late subacute: 3–30 days (extracellular methemoglobin)	White	White
Chronic: >14 days (hemosiderin, mainly on outer rim)	Dark gray	Black

Note: The actual sequence of changes in the appearance of hemorrhage on MRI scans can be fairly complicated and variable, depending on individual scanners.

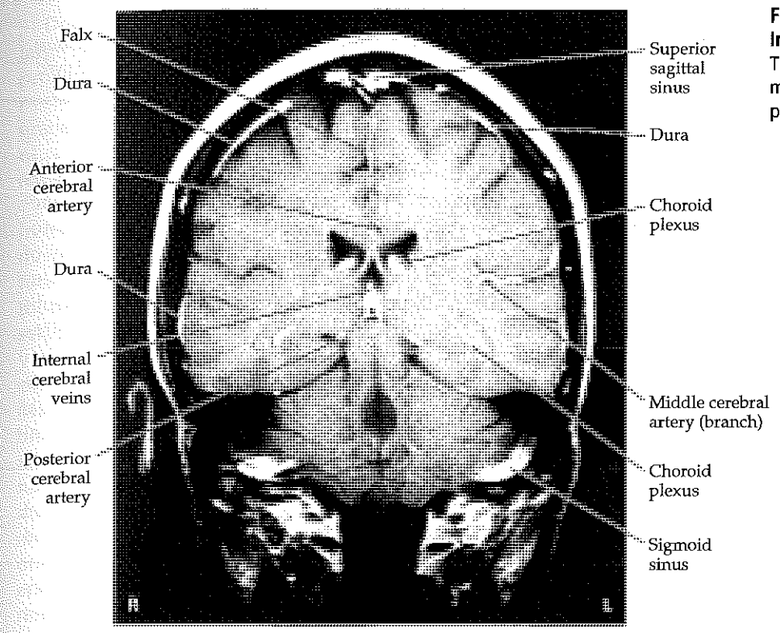

Figure 4.7 Coronal MRI Image with Intravenous Gadolinium Contrast
This MRI image demonstrates enhancement of arteries, venous sinuses, choroid plexus, and dura mater. TR = 650, TE = 27.

REVIEW EXERCISE

Study the MRI images in the Neuroradiological Atlas (see Figures 4.13–4.15) and identify (1) whether they are axial (horizontal), coronal, or sagittal (see Figure 2.5), and (2) whether they are T1-, T2-, or proton–density weighted. Then, cover the labels and try to name as many structures as possible.

Neuroangiography

Cerebral angiography is one of the oldest neuroradiological techniques, and its role has therefore evolved in many ways. Before the availability of CT and MRI, neuroangiography was often used to detect slight distortions in the patterns of blood vessels suggestive of intracranial mass lesions. These subtle angiographic changes were combined with findings from other techniques no longer used for this purpose (plain skull films, pneumoencephalography, and EEG) to provide circumstantial evidence for intracranial lesions that today can easily be visualized with CT or MRI.

Now that CT and MRI are widely available, neuroangiography is used mainly to visualize lesions of the blood vessels themselves, rather than to provide indirect information about surrounding structures. Lesions optimally seen by angiography include atherosclerotic plaques and other vessel nar-

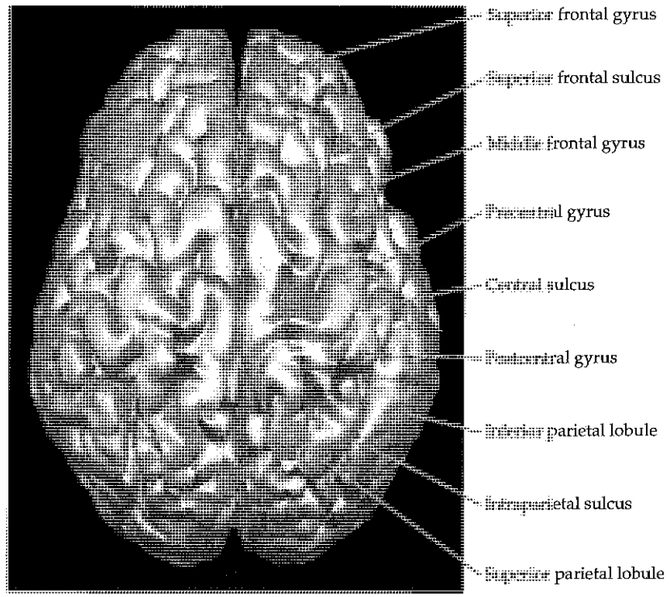

Figure 4.8 Three-Dimensional Surface Reconstruction This reconstruction of a normal MRI scan demonstrates anatomy of sulci and gyri. (Courtesy of Rik Stokking.)

rowings, aneurysms, and arteriovenous malformations. Angiography is also sometimes used during planning of neurosurgery to assess the vascular anatomy of tumors. In addition to diagnostic uses, neuroangiography can also be used therapeutically, as we will discuss at the end of this section.

Unlike CT and MRI, angiography is an invasive procedure. Under local anesthesia, a catheter is inserted, usually in the femoral artery (Figure 4.9), and threaded up the aorta under continuous X-ray guidance (fluoroscopy). Radio-opaque iodinated contrast material is then injected into the carotid and vertebral arteries on both sides, and sequential images are obtained at different times during the injection and runoff. The arteries are thus well visualized early in the series of images, while the veins are better visualized late. Images are generally taken from several different views to optimally visualize the vessels of both the anterior and posterior circulations. To become familiar with normal vascular anatomy as seen by conventional angiography, review the series of normal angiograms seen in Figures 4.16, 4.17.

A number of less invasive means for visualizing blood vessels and assessing flow have been developed more recently. These include Doppler ultrasound, magnetic resonance angiography, and spiral CT angiography. Although these methods are continually improving, none of them have yet achieved the sensitivity or specificity of conventional angiography for most purposes. Therefore, the risks and benefits must be weighed in each case to decide between conventional angiography and noninvasive assessment. In some cases a noninvasive technique is used first, and conventional angiography is then used only if the diagnosis remains unclear.

REVIEW EXERCISE

Study the Neuroradiological Atlas angiography images (see Figures 4.16 and 4.17) to determine whether the anterior (carotid) or posterior (vertebral) circulation has been injected, and whether the view is in the anterior–posterior or the lateral direction. Then, cover the labels and try to name as many structures as possible.

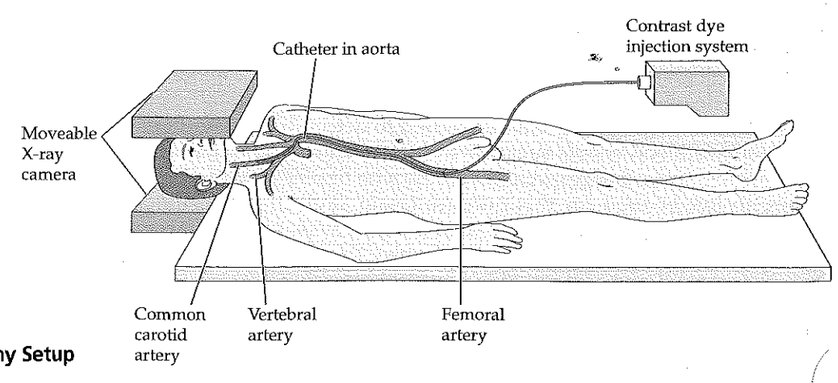

Figure 4.9 Neuroangiography Setup

Doppler ultrasound can be used to measure flow and lumen diameter of large blood vessels in the head and neck. It is most useful for assessing the proximal portions of the internal carotid, middle cerebral, anterior cerebral, posterior cerebral, vertebral, and basilar arteries. Smaller, more distal branches cannot be assessed. However, the technique is still quite useful because most significant atherosclerotic narrowings occur proximally. This technique usually cannot detect aneurysms or other vascular abnormalities.

Magnetic resonance angiography (MRA) takes advantage of the change in magnetic resonance signal that occurs in areas of flow as a result of the movement of protons into and out of the region being assessed between the time that the radio frequency excitation pulse is emitted and the time that the signal is collected. The direction and speed of flow to be detected can be selected via the computer. A series of normal MRA images of the intracranial vessels is shown in Figure 4.18. These images should be compared to the conventional angiographic images in Figures 4.16 and 4.17. Note that with MRA, although the major vessels can be seen, the smaller, more distal branches cannot. Like conventional angiography, MRA can also be used to image potential sites of narrowing or other pathology of the carotid and vertebral arteries in the neck (Figure 4.19), or even as they arise from the aortic arch (Figure 4.20A). MRA is used mainly to detect regions of decreased or absent arterial blood flow caused by atherosclerotic narrowing, thrombosis, or dissection. In addition, MRA can be useful for detecting some aneurysms and other vascular abnormalities. Venous flow can be visualized using **magnetic resonance venography (MRV)**. An example of MRV used to detect venous sinus thrombosis is shown in Figure 10.26.

Spiral CT angiography (CTA) is a relatively new method in which rapid injection of intravenous contrast is used together with helical CT scan techniques to obtain images of blood vessels quickly. The blood vessels are reconstructed in three dimensions by means of a computer. Information obtained from CTA can sometimes supplement that obtained from MRA, and CTA can be performed in patients in which MRA is contraindicated (e.g., patients with pacemakers).

Although noninvasive techniques have further narrowed the role of angiography in diagnosis, a new role has meanwhile emerged for neuroangiography in invasive functional testing and therapy. This field is known as **interventional neuroradiology.** For example, in the angiogram **Wada test** a sedative medication (amobarbital) is selectively infused into each carotid artery with the patient awake. This test can help localize the side of language and memory function and is useful in planning neurosurgery (see KCC 18.2). Brain aneurysms and arteriovenous malformations, which can cause massive intracranial hemorrhage (see Chapter 5), can sometimes be clotted off and rendered harmless by filling them with gluelike material or tiny metal springs via the angiography catheter. Finally, therapeutic trials are under way in acute stroke in which thrombolytic agents are infused via the catheter directly at the site of the clot to try to reestablish perfusion.

Functional Neuroimaging

In most clinical situations, the most important radiological information comes from a structural anatomical image of the abnormality produced by one of the techniques already described. Sometimes, however, it is also useful to assess the physiological function of the structures in question. Several different techniques can be used for measuring various aspects of brain function, and, as we will discuss in this section, exciting clinical applications

are beginning to emerge. Research applications of functional neuroimaging have seen a remarkable growth in recent years, giving rise to speculation that with these techniques we may soon be able to virtually "peer into someone's head and see what they are thinking."

The original method for measuring brain activity was the **electroencephalogram (EEG)**. In this technique an array of electrodes is applied to the surface of the scalp and connected to amplifiers to detect the weak electrical signals transmitted from the brain through the skull. The normal EEG pattern consists of waveforms of various frequencies that vary with the level of alertness of the patient. Abnormalities in large regions of brain produce abnormal or asymmetrical waveforms that can be detected with EEG. The sensitivity and spatial resolution of EEG in detecting focal brain lesions is poor, however, compared to modern neuroimaging methods. EEG remains very useful today in evaluating patients for epileptic (seizure-producing) brain activity (see KCC 18.2), or for detecting widespread abnormalities in brain function (see KCC 19.15, 19.16). **Evoked potentials** are a method similar to EEG in which brain electrical signals are recorded in response to specific stimuli. Additional refinements in electrical measurements of brain function have been developed. These include quantitative EEG analysis and magnetoencephalography (MEG), which uses a superconducting quantum interference device (SQUID) to detect the very weak magnetic signals from the brain. These techniques are presently used mainly for research purposes.

Other methods of functional assessment depend on brain metabolic activity. Brain metabolic activity is used as an indirect measure of brain electrical activity, or neuronal firing. Increased local neuronal firing causes increased brain metabolism which, in turn, leads to increased local blood flow and increased turnover of local blood volume. Techniques that can produce images based on blood flow or dynamic blood volume include: Xenon regional cerebral blood flow mapping (Xe rCBF), positron emission tomography (PET), single photon emission computerized tomography (SPECT), dynamic contrast functional MRI (perfusion MRI), and blood oxygen level–dependent functional MRI (BOLD fMRI). In addition to measuring cerebral blood flow, many of these techniques can be used to more directly measure brain function by other methods. For example, PET scanning can also be used to map local brain consumption of glucose, or local binding of various neurotransmitters.

Functional MRI (fMRI) refers to several different MRI techniques used to measure different aspects of brain function:

1. **Dynamic contrast fMRI (perfusion MRI)** involves rapid injection of gadolinium and rapid measurements with "echo planar" imaging to produced an image of dynamic blood volume.
2. **Blood oxygen level–dependent fMRI (BOLD fMRI)** measures relative changes in oxy- and deoxyhemoglobin, which occur with changes in regional cerebral blood flow.
3. **Diffusion MRI** uses rapid echo planar imaging and strong gradients to measure the diffusion coefficient of water in brain tissue. This sensitive technique can be used to detect early areas of ischemia long before conventional MRI shows any abnormalities.
4. **Magnetic resonance spectroscopy (MRS)** can be used to detect local concentrations of certain chemicals in the brain including some neurotransmitters.

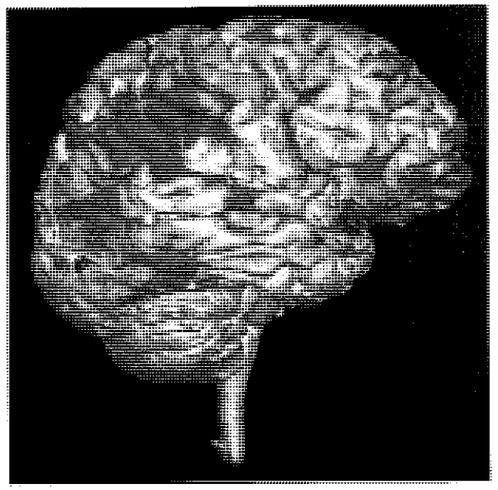

Figure 4.10 Ictal-Interictal SPECT Difference Imaging The patient was injected intravenously with Tc99 HMPAO during a seizure, and a SPECT scan was then performed (ictal SPECT). A second SPECT scan was performed at another time, when the patient was not having a seizure (interictal SPECT). The interictal SPECT was then subtracted from the ictal SPECT, and the results are displayed as a three-dimensional surface reconstruction of the patient's MRI scan. Increased cerebral perfusion is shown as a red–yellow color, and decreased perfusion is shown as blue–green. This scan helped localize the region of seizure onset in this patient (red–yellow) to the right temporal lobe, allowing successful surgical treatment to be performed. (Courtesy of George Zubal, Susan Spencer, Dennis Spencer, Rik Stokking, Colin Studholme, and Hal Blumenfeld, Yale University School of Medicine.)

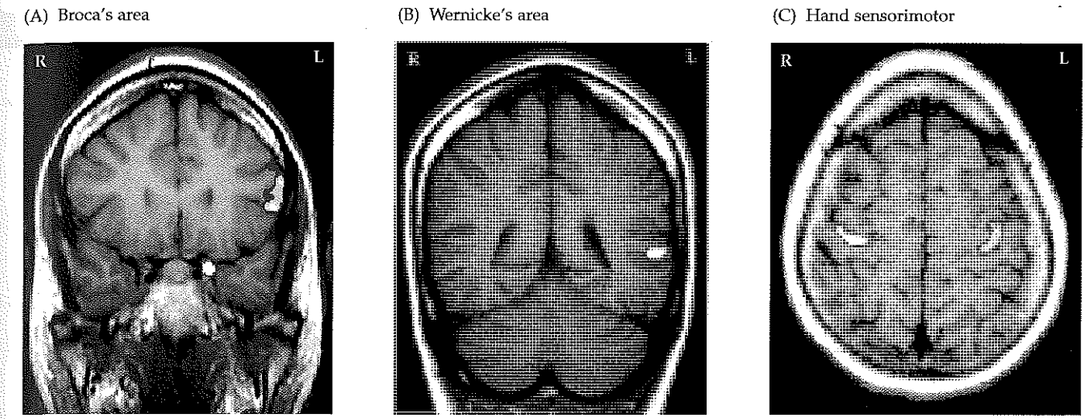

Figure 4.11 BOLD fMRI Mapping of Sensorimotor Cortex and Language Cortex (A, B) Language mapping. The subject was asked to read words and determine whether they were real words or nonsense syllables. This task caused activation of both Broca's area (A) and Wernicke's area (B). (C) Sensorimotor mapping. The subject squeezed a rubber ball repeatedly with his left hand, causing activation of the right sensorimotor hand cortex (reddish orange), and with his right hand, causing activation of the left sensorimotor hand cortex (blue). (Compare to Figure 4.13J.) (Courtesy of R. Todd Constable, Yale University School of Medicine.)

The functional neuroimaging methods discussed in this section have caused a virtual explosion in neuroscience research and are greatly advancing our knowledge of localized brain function. In addition, some important clinical applications are beginning to emerge. For example, fluorodeoxyglucose PET scans are often used in patients with dementia or epilepsy to localize regions of abnormal glucose metabolism (see Figure 18.22); they may also be useful for distinguishing metabolically active recurrent brain tumors from radiation-induced necrosis. Diffusion MRI is increasing in popularity as a method for detecting acute cerebral infarcts far earlier than conventional MRI or CT scans (see Figures 14.23, 14.31). SPECT scans can be used to indirectly measure regional brain activity during seizures and to help localize their region of onset. An example is shown in Figure 4.10. BOLD fMRI is being investigated as a method to help plan neurosurgery by allowing the neurosurgeon to know in advance where vital regions of brain function are located—as shown in Figure 4.11, BOLD fMRI can be used to localize regions of sensory-motor function and language function. Eventually, with further investigation, this method may replace the angiogram Wada test (see KCC 18.2). As time goes on, additional clinical applications of these powerful functional neuroimaging methods are likely to be found.

Conclusions

Neuroradiology plays an essential role in the diagnosis, and sometimes treatment, of patients with disease of the nervous system. However, it is the role of the clinician to decide, on the basis of the history and physical exam, what the most likely diagnoses are, so that neuroradiological methods are used appropriately. The clinician must first decide if a neuroradiological study is needed at all. Then the history and physical exam must be used to formulate hypotheses about both **localization** and the **pathophysiology** of lesions. Using this information, the clinician can decide whether CT, MRI, angiography, or other methods of evaluation are most appropriate, as well as which regions of the nervous system should be the focus so that an optimal study is obtained. By combining the clinical history, examination, and other methods of assessment together with the powerful neuroradiological methods available today, clinicians are able to offer an ever-increasing number of patients accurate neurologic diagnosis and appropriate treatment.

NEURORADIOLOGICAL ATLAS

Figure 4.12 CT Images Unenhanced axial CT images with major structures labeled.

(A)

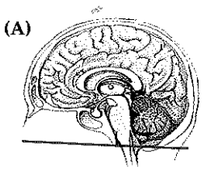

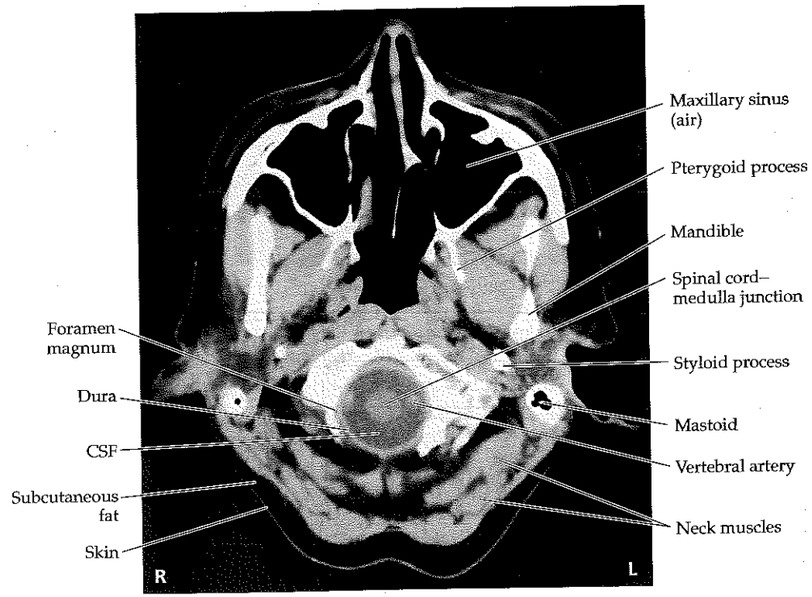

(B)

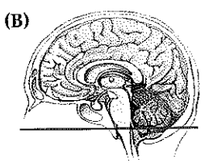

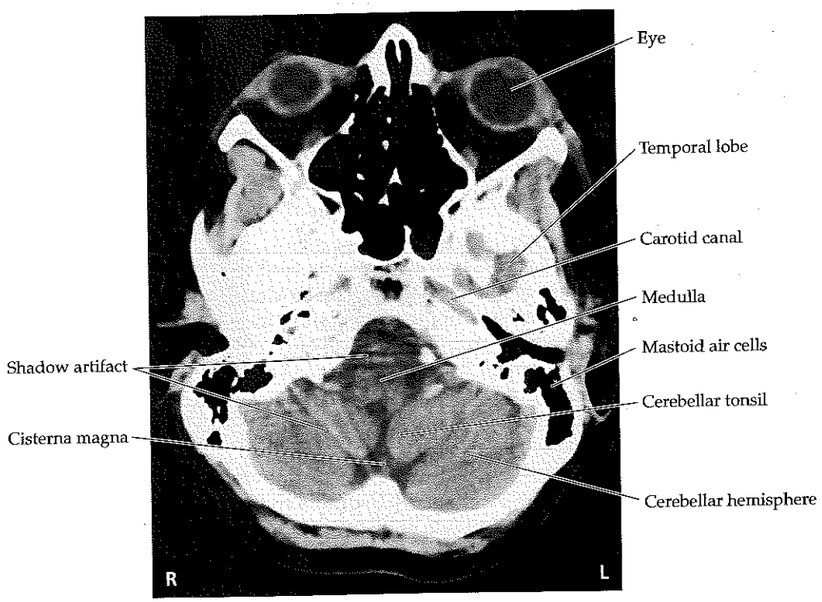

CT, AXIAL

(C)

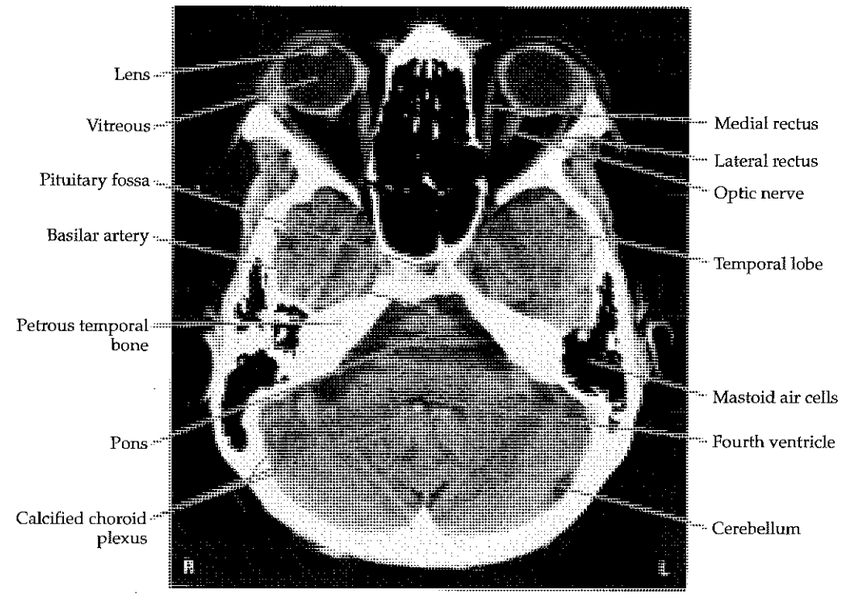

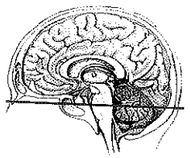

(D)

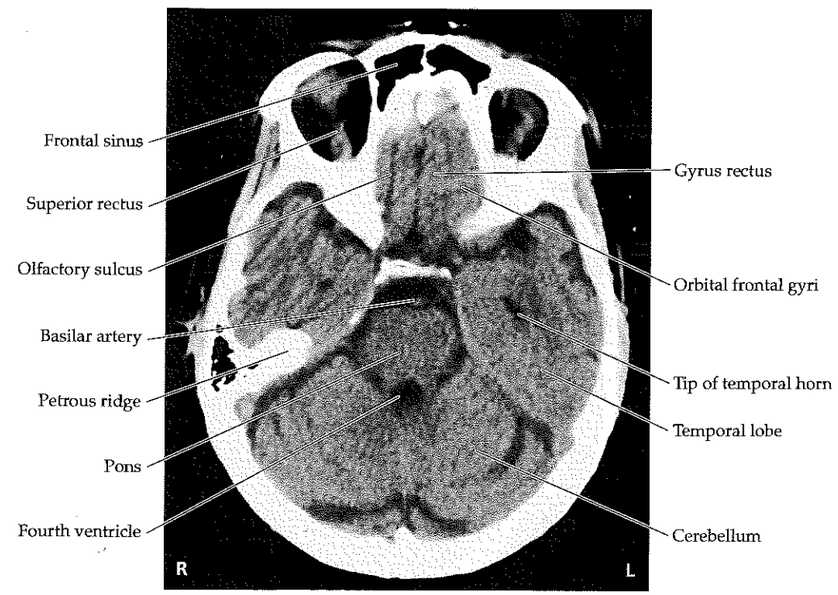

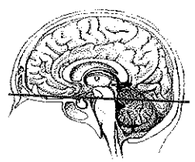

NEURORADIOLOGICAL ATLAS

Figure 4.12 (continued)

(E)

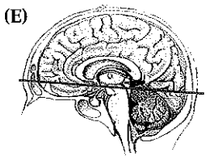

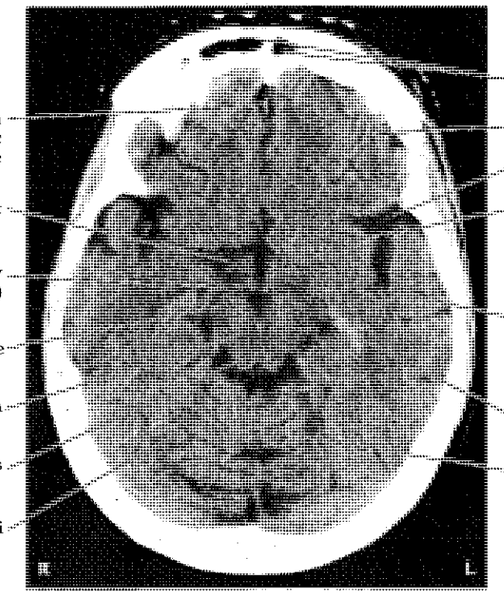

(F)

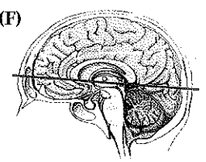

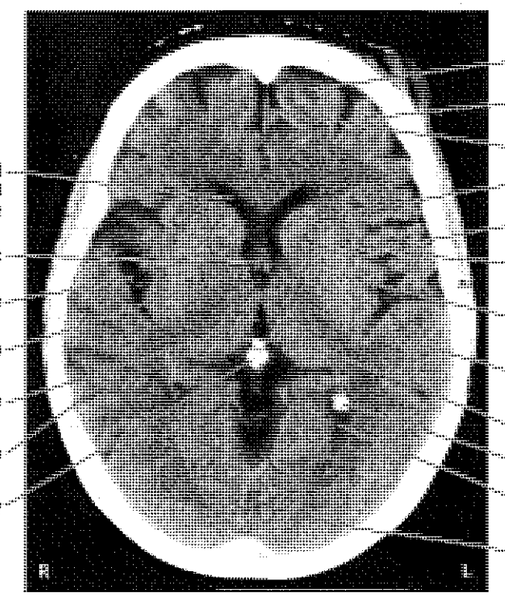

CT, AXIAL

(G)

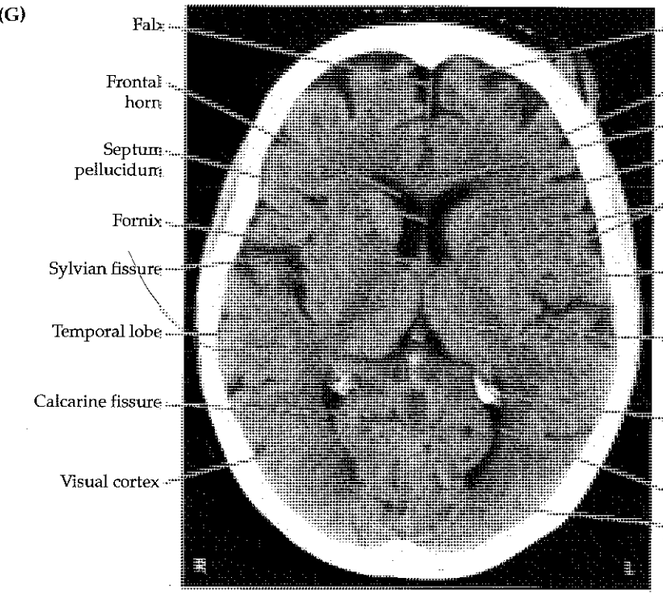

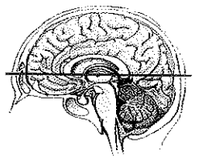

(H)

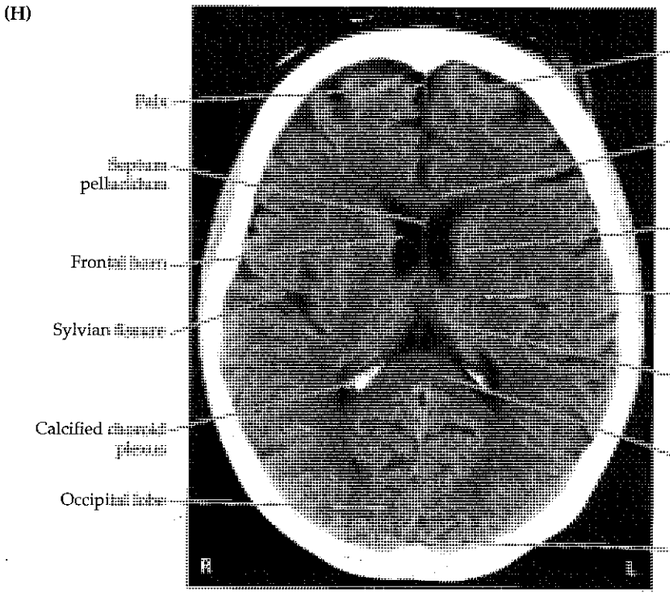

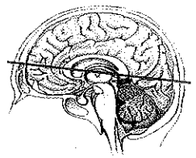

NEURORADIOLOGICAL ATLAS

Figure 4.12 (continued)

(I)

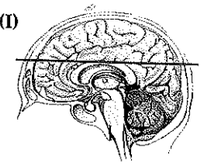

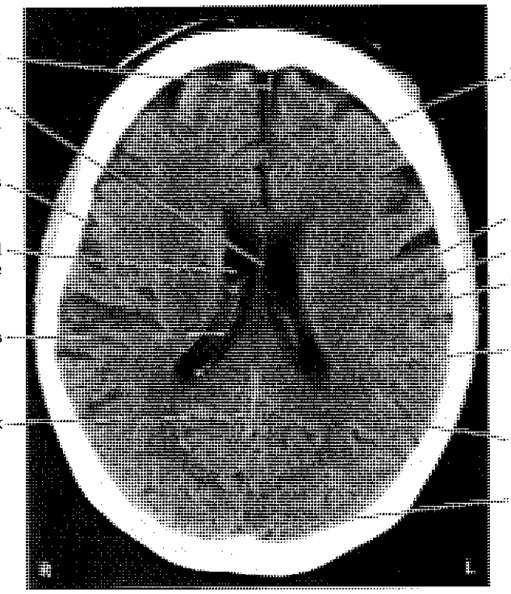

(J)

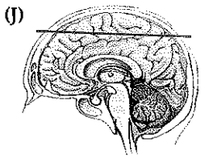

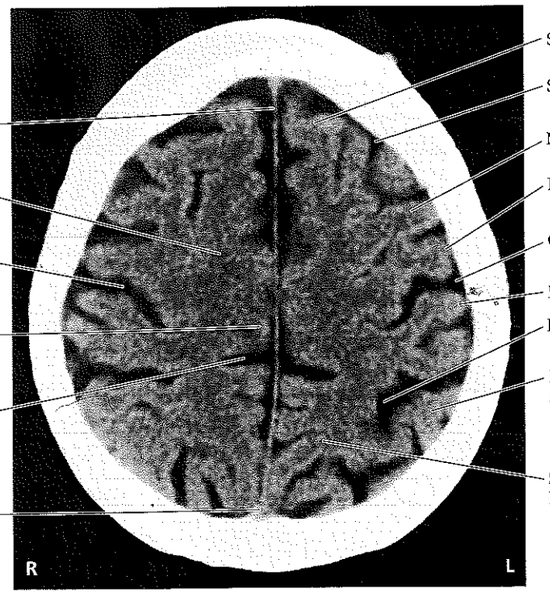

CT, AXIAL

(K)

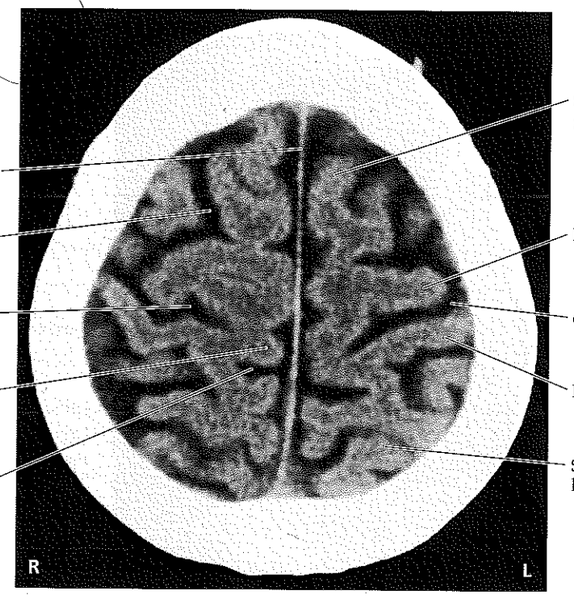

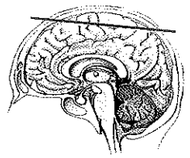

NEURORADIOLOGICAL ATLAS

Figure 4.13 MRI: Axial T1-Weighted Images Unenhanced axial MRI images with major structures labeled. TR = 500, TE = 11.

(A)

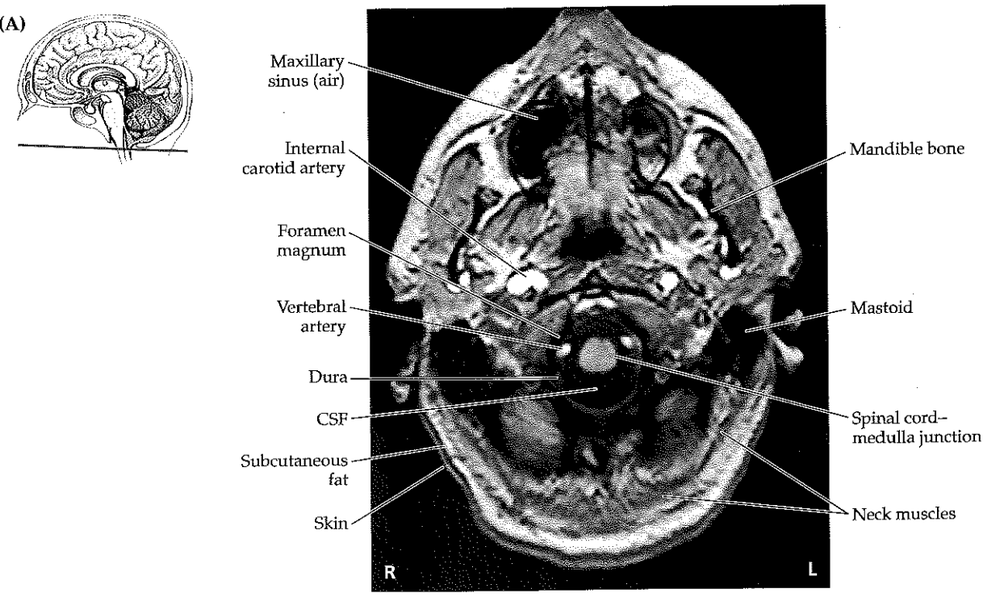

(B)

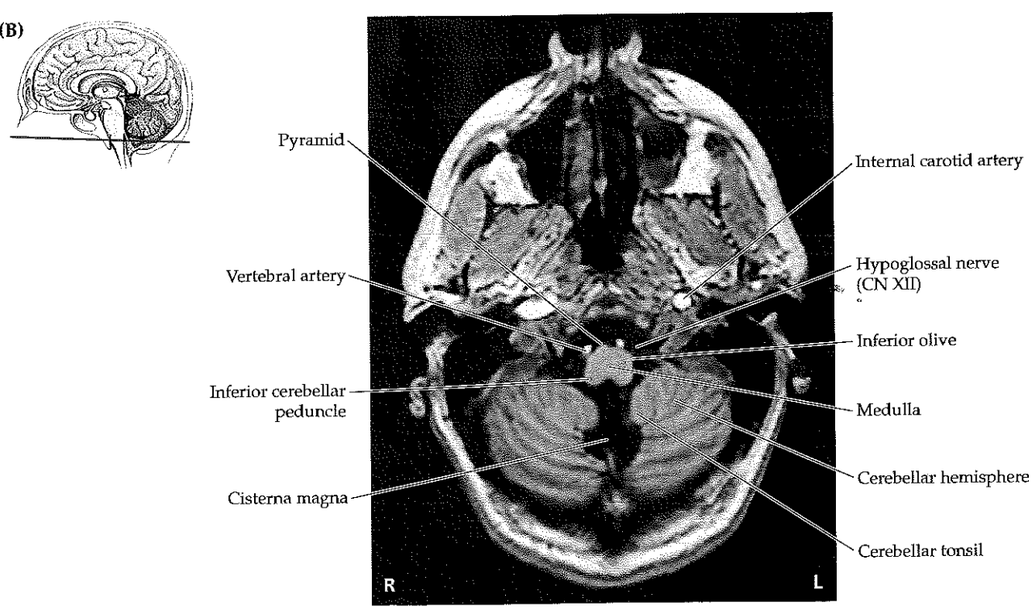

MRI, AXIAL T1-WEIGHTED

(C)

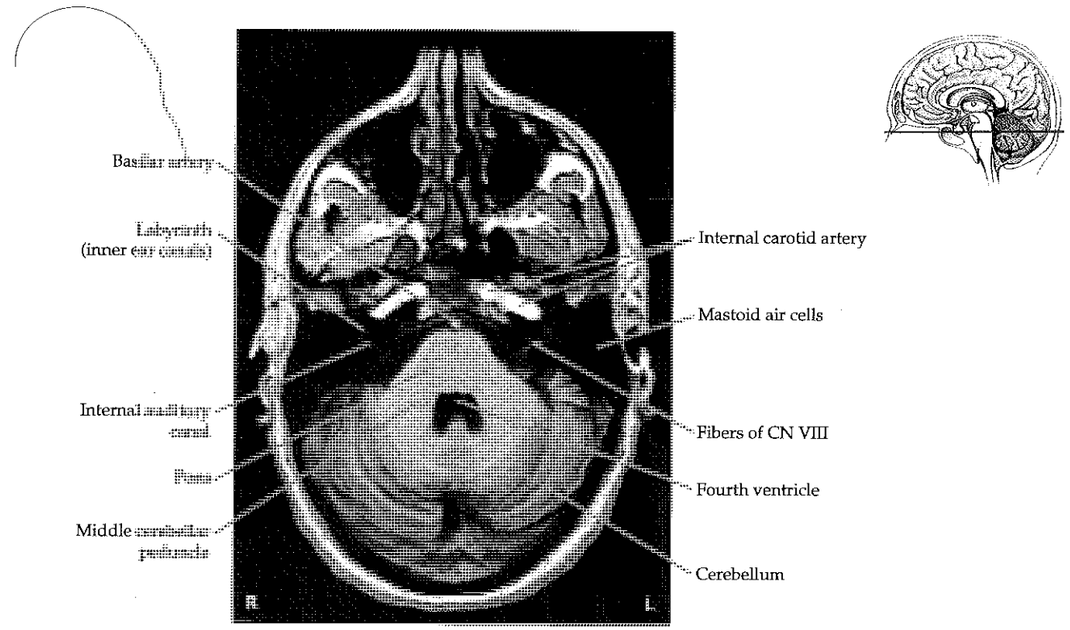

(D)

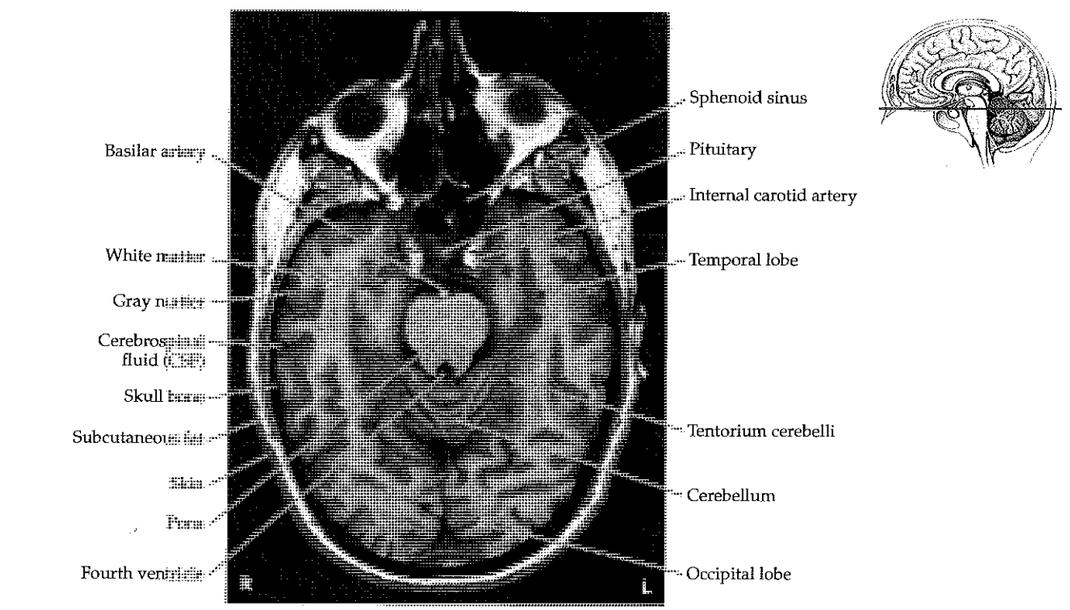

NEURORADIOLOGICAL ATLAS

Figure 4.13 (continued)

(E)

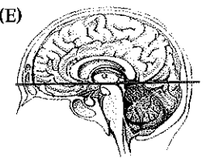

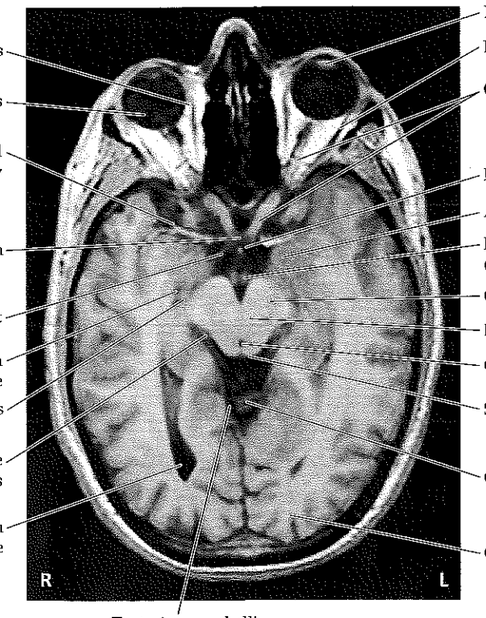

(F)

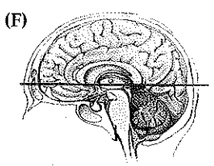

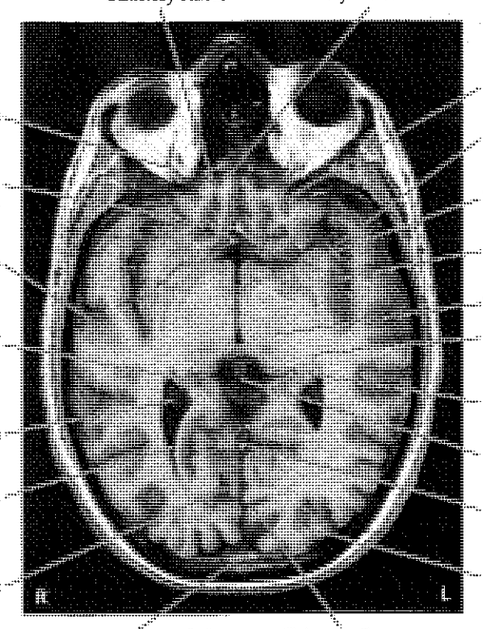

MRI, AXIAL T1-WEIGHTED

(G)

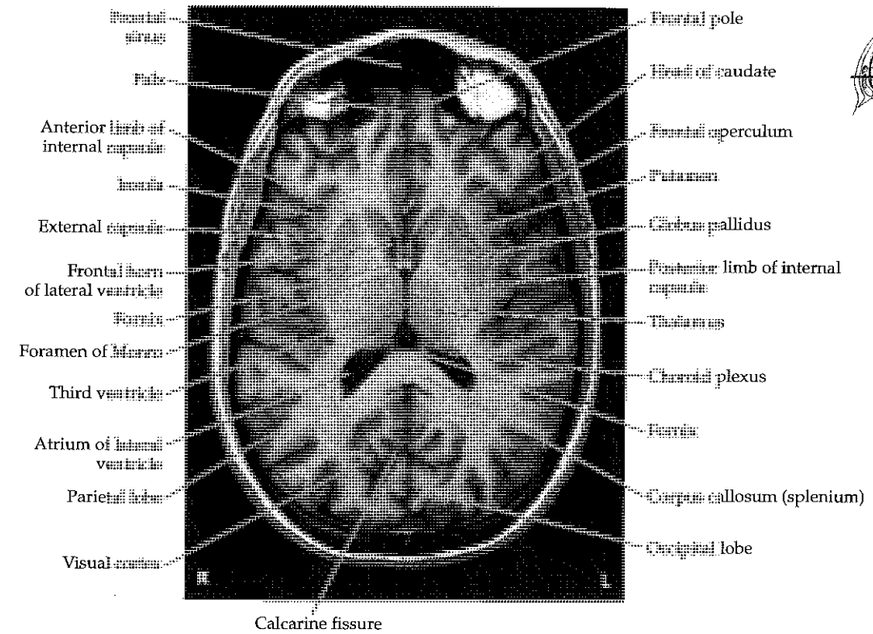

(H)

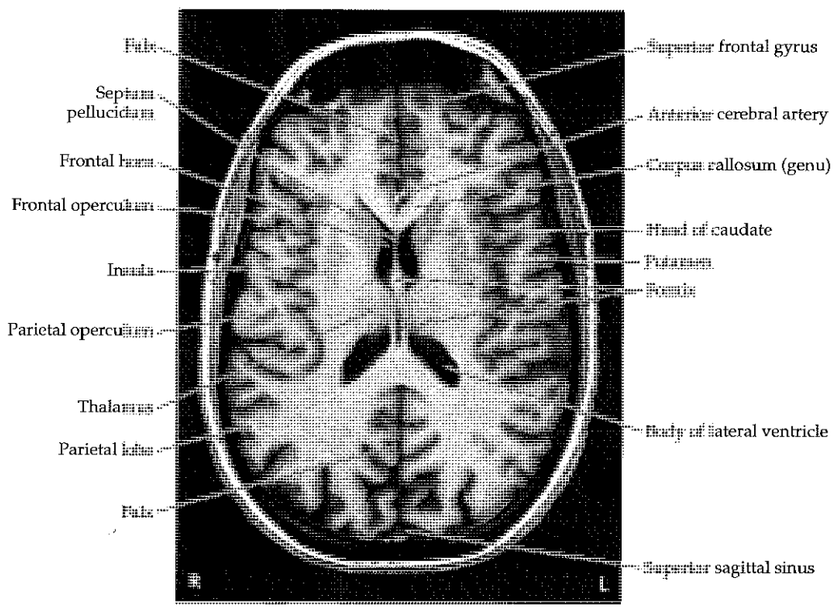

NEURORADIOLOGICAL ATLAS

Figure 4.13 (continued)

(I)

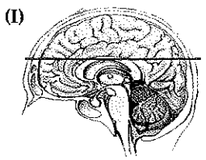

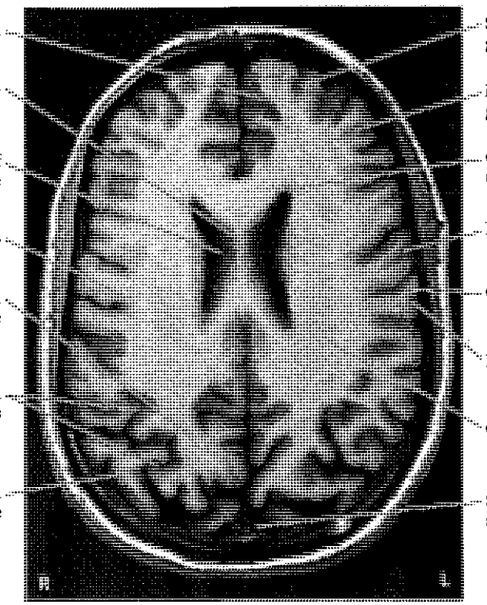

(J)

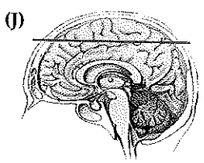

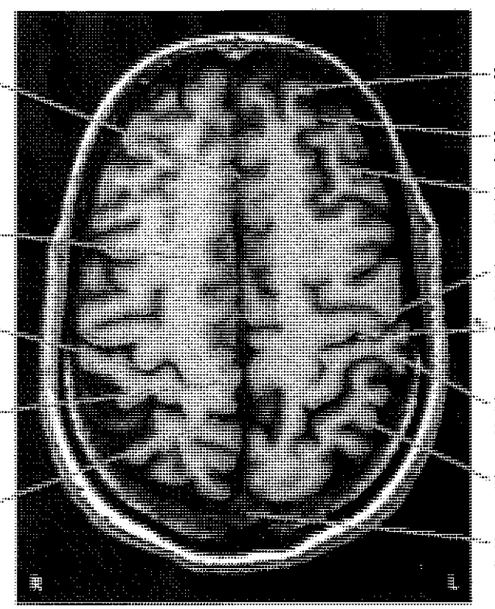

MRI, AXIAL T1-WEIGHTED

(K)

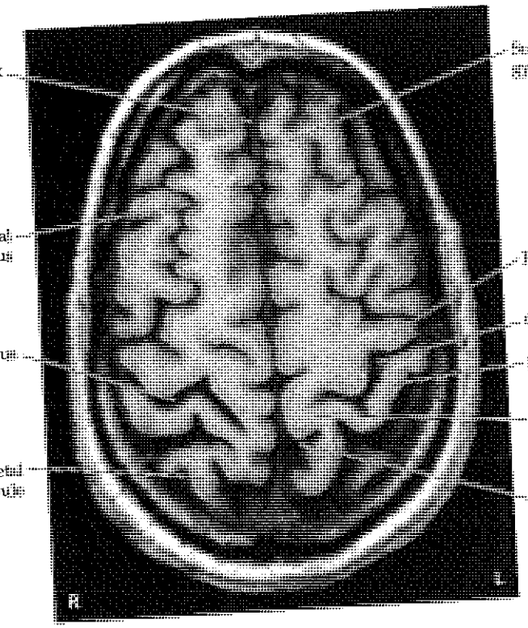

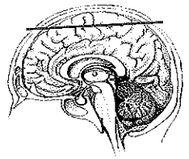

NEURORADIOLOGICAL ATLAS

Figure 4.14 MRI: Coronal T1-Weighted Images Unenhanced coronal MRI images with major structures labeled. Images acquired using 3D SPGR sequence with TR = 23, TE = 4.

(A)

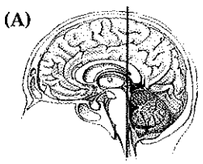

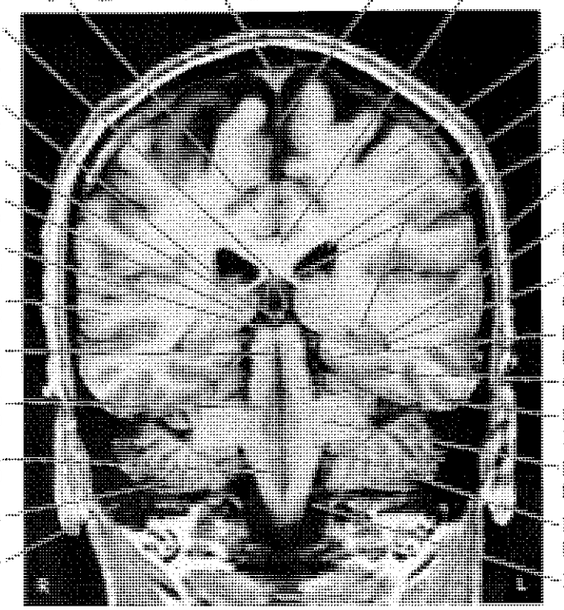

(B)

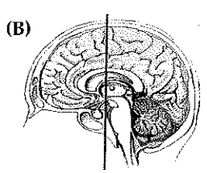

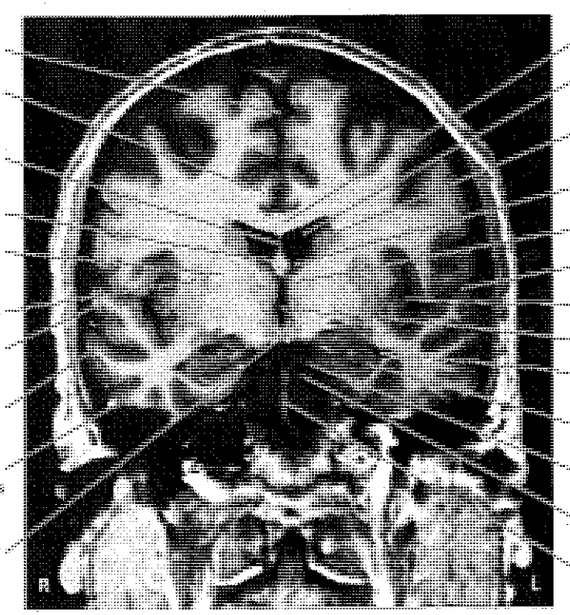

MRI, CORONAL T1-WEIGHTED

(C)

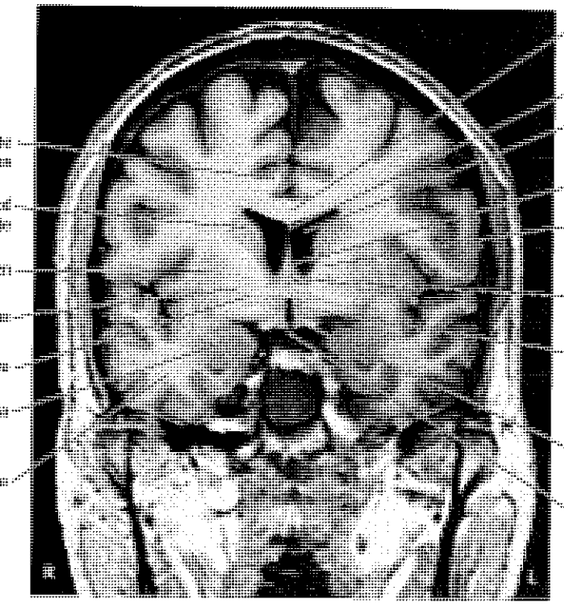

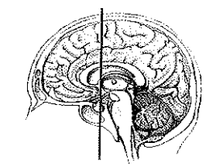

(D)

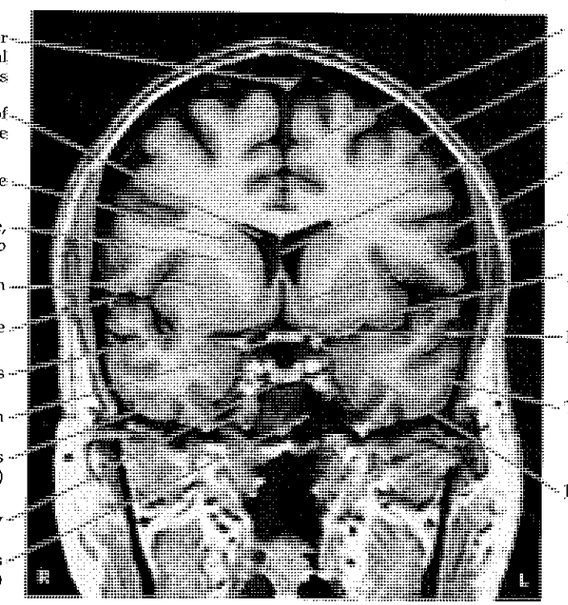

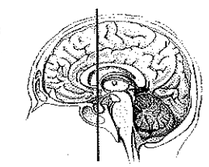

NEURORADIOLOGICAL ATLAS

Figure 4.15 MRI: Sagittal T1-Weighted Images
Unenhanced sagittal MRI images with major structures labeled. TR = 600, TE = 12.

(A)

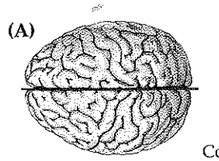

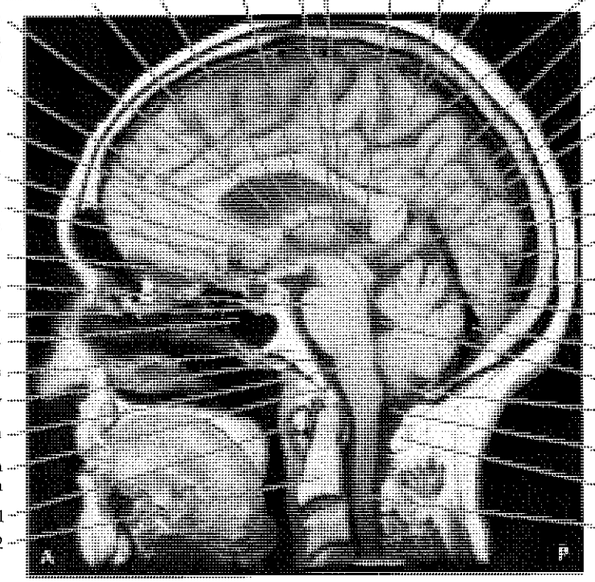

(B)

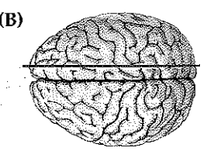

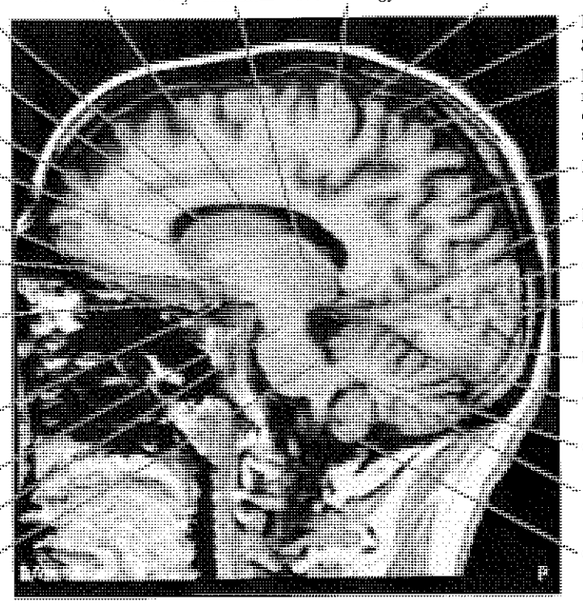

MRI, SAGITTAL T1-WEIGHTED

(C)

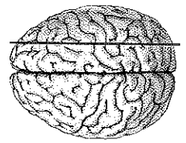

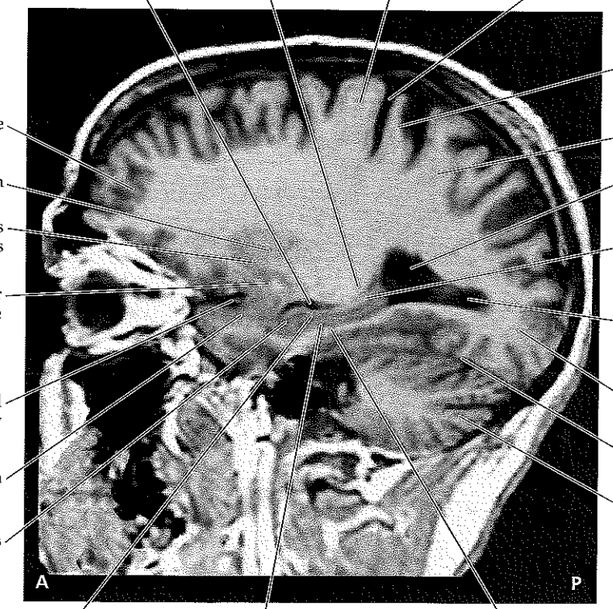

(D)

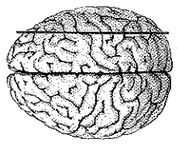

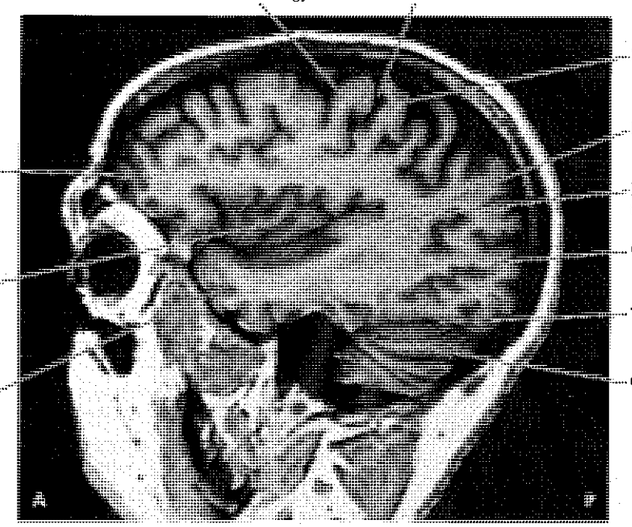

NEURORADIOLOGICAL ATLAS

Figure 4.16 Angiographic Images: Anterior Circulation (A) Anterior–posterior view following injection of left internal carotid artery, demonstrating filling of left anterior and middle cerebral arteries (ACA, MCA). (B) Close-up view of recurrent artery of Heubner arising from anterior cerebral artery and lenticulostriate arteries arising from middle cerebral artery. (C) Lateral view following injection of right internal carotid artery, demonstrating filling of right anterior and middle cerebral arteries. The Sylvian triangle is formed by hairpin loops that are made by branches of the middle cerebral artery as they pass from the insula over the operculum and onto the cortical surface.

(A)

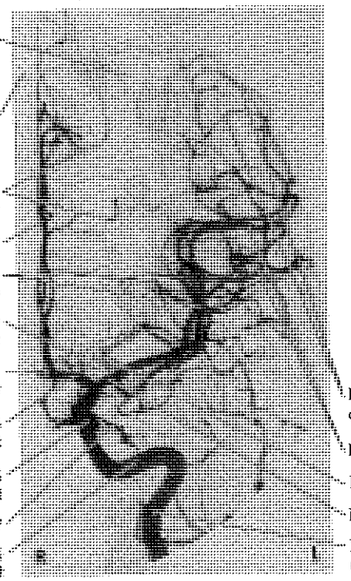

(B)

(C)

ANGIOGRAPHY

Figure 4.17 Angiographic Images: Posterior Circulation (A) Anterior–posterior view following injection of left vertebral artery. Reflux into the right vertebral artery can be seen. (B) Lateral view following injection of left vertebral artery.

(A)

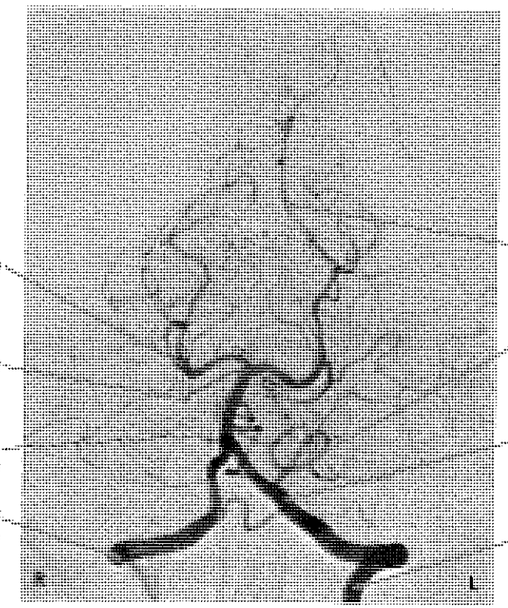

(B)

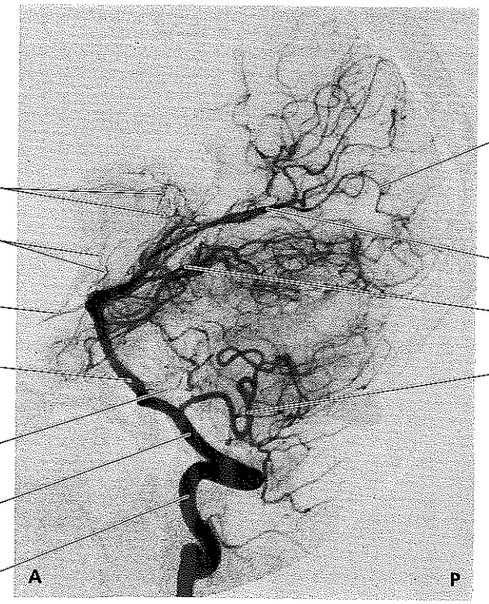

NEURORADIOLOGICAL ATLAS

Figure 4.18 MRA Images: Intracranial Circulation
(A) Superior view of circle of Willis. (B) Lateral view. Compare to Figures 4.16, 4.17.

(A)

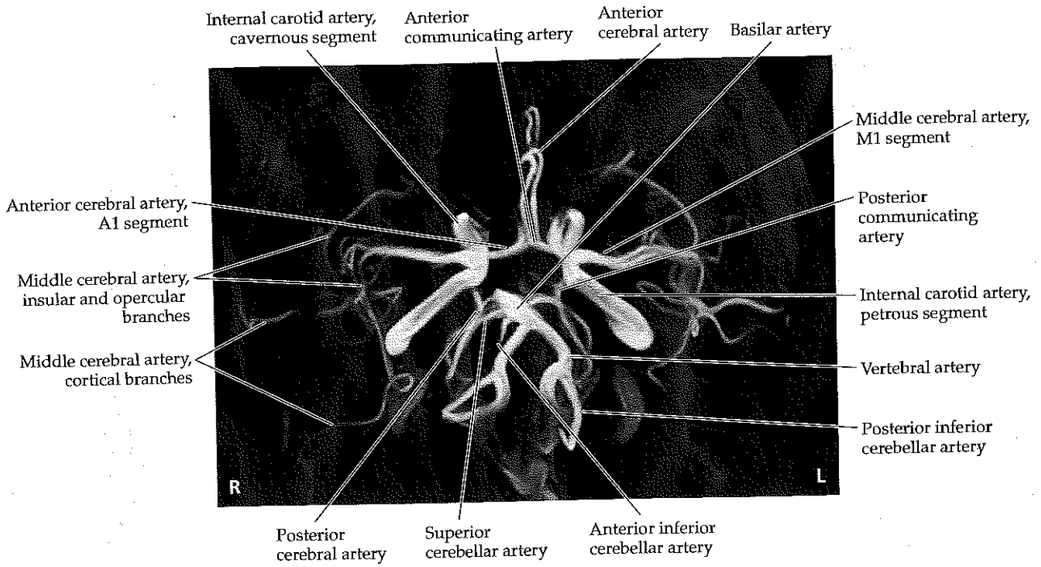

(B)

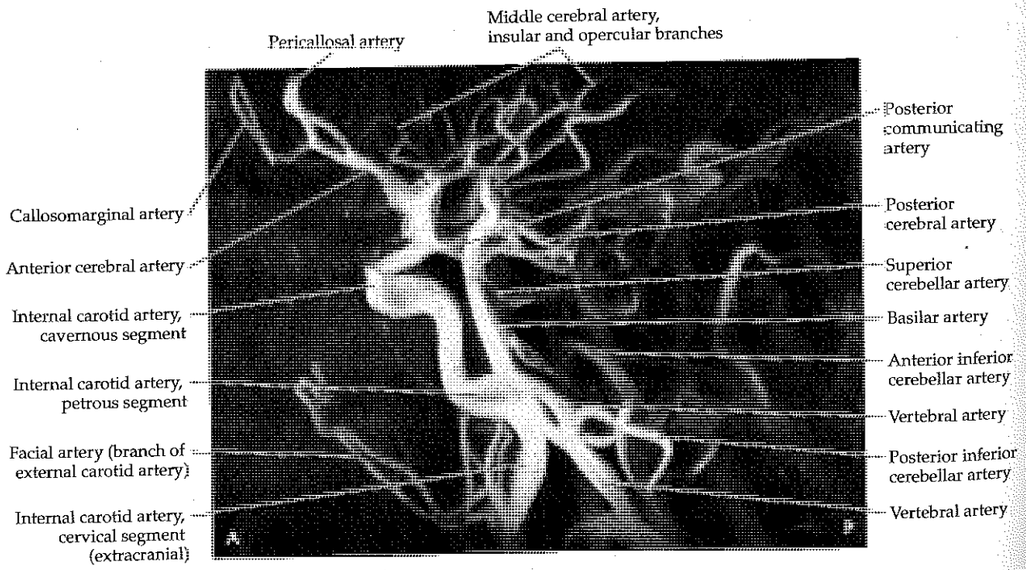

MAGNETIC RESONANCE ANGIOGRAPHY

Figure 4.19 MRA Images: Neck Vessels (A) Lateral view. (B) Close-up view of left carotid bifurcation. (C) Anterior–posterior view.

(A)

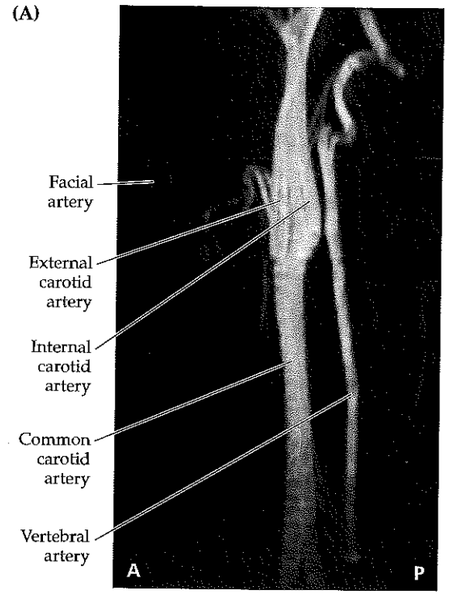

(B)

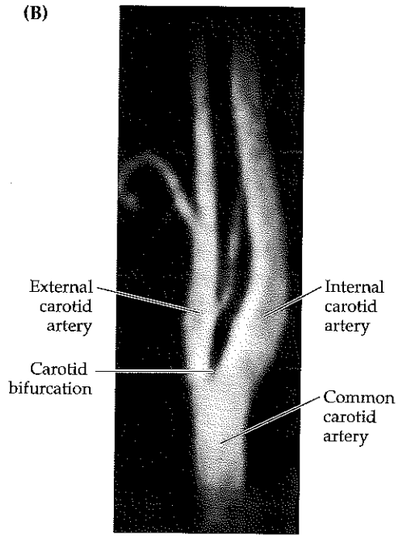

(C)

NEURORADIOLOGICAL ATLAS

Figure 4.20 MRA Images: Origins of Carotid and Vertebral Arteries Anterior–posterior view with successive slices progressing from anterior (A) to posterior (B). (A) Origin of common carotid arteries from aortic arch and brachiocephalic artery. (B) Origin of vertebral arteries from subclavian arteries.

(A)

(B)

References

General

Gilman S. 1998. Imaging the brain. First of two parts. *N Engl J Med* 338(12): 812–820.

Gilman S. 1998. Imaging the brain. Second of two parts. *N Engl J Med* 338(13): 889–896.

Osborn AG. 1994. *Diagnostic Neuroradiology.* Mosby, St. Louis, MO.

Ramsey RG. 1994. *Neuroradiology,* 3rd Ed. Saunders, Philadelphia.

Wolbarst AB. 1993. *Physics of Radiology.* Appleton & Lange, Norwalk, CT, Chapters 1, 42.

CT

Hu H. 1999. Multi-slice helical CT: Scan and reconstruction. *Med Phys* 26: 5–18.

Seeram E. 1994. *Computed Tomography: Physical Principles, Clinical Applications and Quality Control.* Saunders, Philadelphia, Chapter 6.

Takahashi S (ed.). 1983. *Illustrated Computer Tomography: A Practical Guide to CT Interpretations.* Springer, Berlin.

Weisberg L, Nice C. 1989. *Cerebral Computed Tomography: A Text Atlas,* 3rd Ed. Saunders, Philadelphia.

MRI

Chakeres DW, Schmalbrock P (eds). 1992. *Fundamentals of Magnetic Resonance Imaging.* Williams & Wilkins, Baltimore, MD, Chapters 7, 18.

Edelman RR, Zlatkin MB, Hesselink JR (eds.). 1996. *Clinical Magnetic Resonance Imaging,* 2nd Ed. Saunders, Philadelphia.

Vlaardingerbroek MT, den Boer JA. 1996. *Magnetic Resonance Imaging: Theory and Practice.* Springer, Berlin, Chapter 2.

Neuroangiography

Brott T, Kothari R, Broderick J. 1997. Thrombolytic therapy for cerebral infarction. In Batjer HH (ed.), *Cerebrovascular Disease,* Chapter 43. Lippincott-Raven, Philadelphia.

Jacobs JM, Osborn AG. 1999. *Diagnostic Cerebral Angiography,* 2nd Ed. Lippincott-Raven, Philadelphia.

Vinuela F, Duckwiler G, Gugielmi G. 1997. Principles of interventional neuroradiology. In Batjer HH (ed.), *Cerebrovascular Disease,* Chapter 57. Lippincott-Raven, Philadelphia.

Yucel EK (ed.). 1995. *Magnetic Resonance Angiography: A Practical Approach.* McGraw-Hill, New York, Chapter 2.

Functional Neuroimaging

Berns GS. 1999. Functional neuroimaging. *Life Sci* 65(24): 2531–2540.

Cutrer FM, O'Donnell A. 1999. Recent advances in functional neuroimaging. *Curr Opin Neurol* 12(3): 255–259.

Hubner KF, Collmann J, Buonocore E, Kabalka GW (eds.). 1992. *Clinical Positron Emission Tomography.* Mosby, St. Louis, MO.

Toga AW, Mazziotta JC, Frackowiak RSJ (eds.). 2000. *Brain Mapping: The Trilogy,* 3 vols. Academic Press, San Diego, CA.

CHAPTER 5

Brain and Environs: Cranium, Ventricles, and Meninges

ANATOMICAL AND CLINICAL REVIEW

Cranial Vault and Meninges

Ventricles and Cerebrospinal Fluid

Blood–Brain Barrier

KCC 5.1 Headache

KCC 5.2 Intracranial Mass Lesions

KCC 5.3 Elevated Intracranial Pressure

KCC 5.4 Brain Herniation Syndromes

KCC 5.5 Head Trauma

KCC 5.6 Intracranial Hemorrhage

KCC 5.7 Hydrocephalus

KCC 5.8 Brain Tumors

KCC 5.9 Infectious Disorders of the Nervous System

KCC 5.10 Lumbar Puncture

KCC 5.11 Craniotomy

CLINICAL CASES

5.1 An Elderly Man with Headaches and Unsteady Gait

5.2 Altered Mental Status Following Head Injury

5.3 Delayed Unresponsiveness after Head Injury

5.4 Headache and Progressive Left-Sided Weakness

5.5 Sudden Coma and Bilateral Posturing during Intravenous Anticoagulation

5.6 Severe Head Injury

5.7 A Child with Headaches, Nausea, and Diplopia

5.8 Headaches and Progressive Visual Loss

5.9 An Elderly Man with Progressive Gait Difficulty, Cognitive Impairment, and Incontinence

5.10 A Young Man with Headache, Fever, Confusion, and Stiff Neck

Additional Cases

BRIEF ANATOMICAL STUDY GUIDE

A Scuba Expedition through the Brain

After a domestic altercation in which he had fallen down a flight of cement stairs and injured his head, a 51-year-old man was arrested and taken to prison. He had been conscious and smelled of alcohol when the police had arrived, but the next morning he was found unresponsive and thrashing aimlessly in his cell. His left pupil was dilated. His right side was paralyzed and had brisk reflexes. As we shall see in this chapter, this case illustrates how head injury can cause abnormal shifts among various compartments in the head, including the cranial vault, ventricles, and meninges. We will learn about the normal anatomy and function of each of these compartments, as well as clinical consequences of injury or illness.

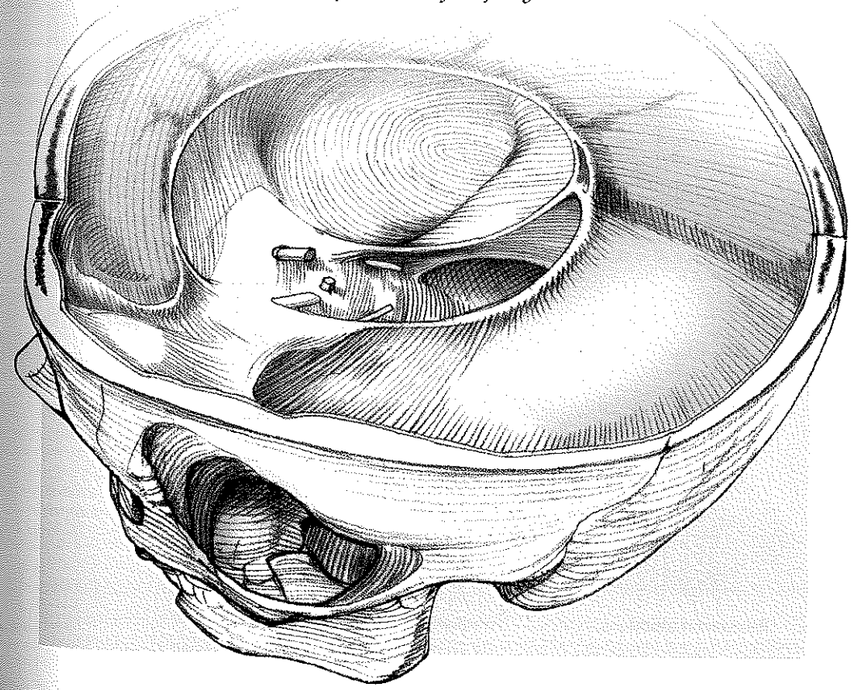

ANATOMICAL AND CLINICAL REVIEW

In the sections that follow we will briefly discuss the brain in relation to its local environment, including the skull, meninges, blood vessels, and cerebrospinal fluid. In addition, we will summarize several important clinical abnormalities that involve these structures, including headache, intracranial mass lesions, elevated intracranial pressure, brain herniation, intracranial hemorrhage, hydrocephalus, brain tumors, and infections of the nervous system. Since this is the first chapter in the book containing clinical cases, we will introduce many Key Clinical Concepts that will be used not just here, but throughout the remainder of the book. For now, you can skim these Key Clinical Concepts (KCC 5.1–5.11) once briefly. Later, while you're thinking through cases and attempting to make a diagnosis, it will be useful to refer back to these sections in more detail.

Cranial Vault and Meninges

The brain is encased in several protective layers that cushion it from trauma (Figure 5.1). Beneath the skin and subcutaneous tissues lie the hard bones that form the skull. The skull has many foramina, or holes, which allow the cranial nerves, spinal cord, and blood vessels to enter and leave the intracranial cavity. We will review these foramina in greater detail in Chapter 12, but for now it is important to recognize the largest foramen at the base of the skull: the **foramen magnum** (Figure 5.2). The point where the spinal cord meets the medulla, the **cervicomedullary junction,** occurs at the level of the foramen magnum (see Figures 2.2C and 5.10). You should be able to easily identify the foramen magnum and the other major foramina at the base of the skull on a CT scan (Figure 5.3).

Figure 5.1 Layers of Protection for the Brain

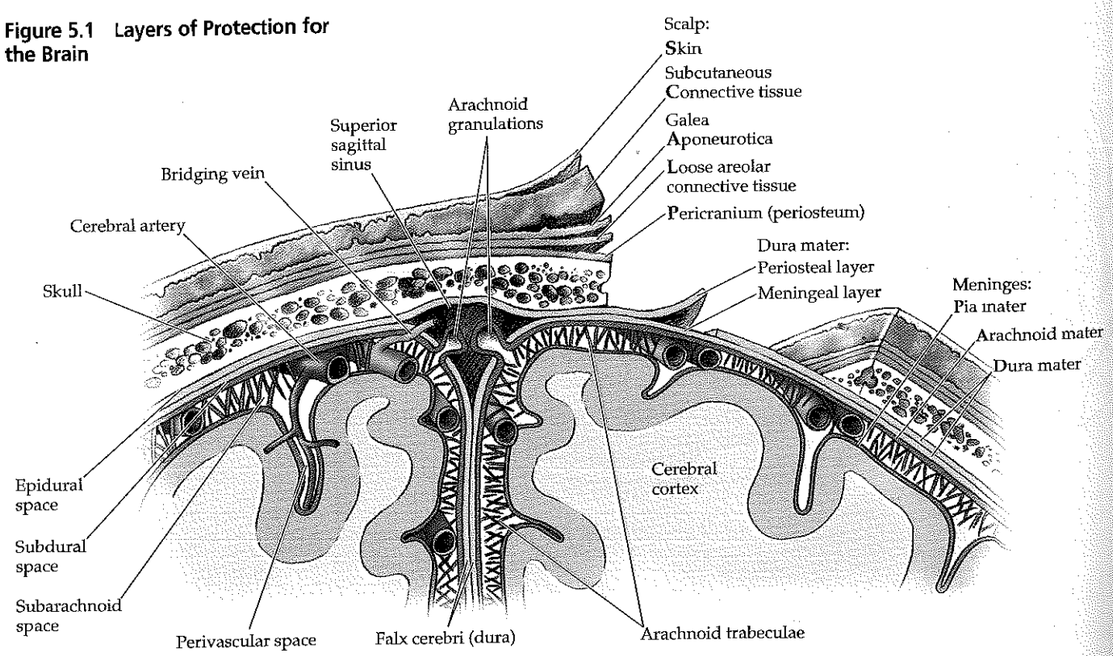

Figure 5.2 Major Foramina at the Base of the Skull
(A) View from below. (B) View from inside (above).

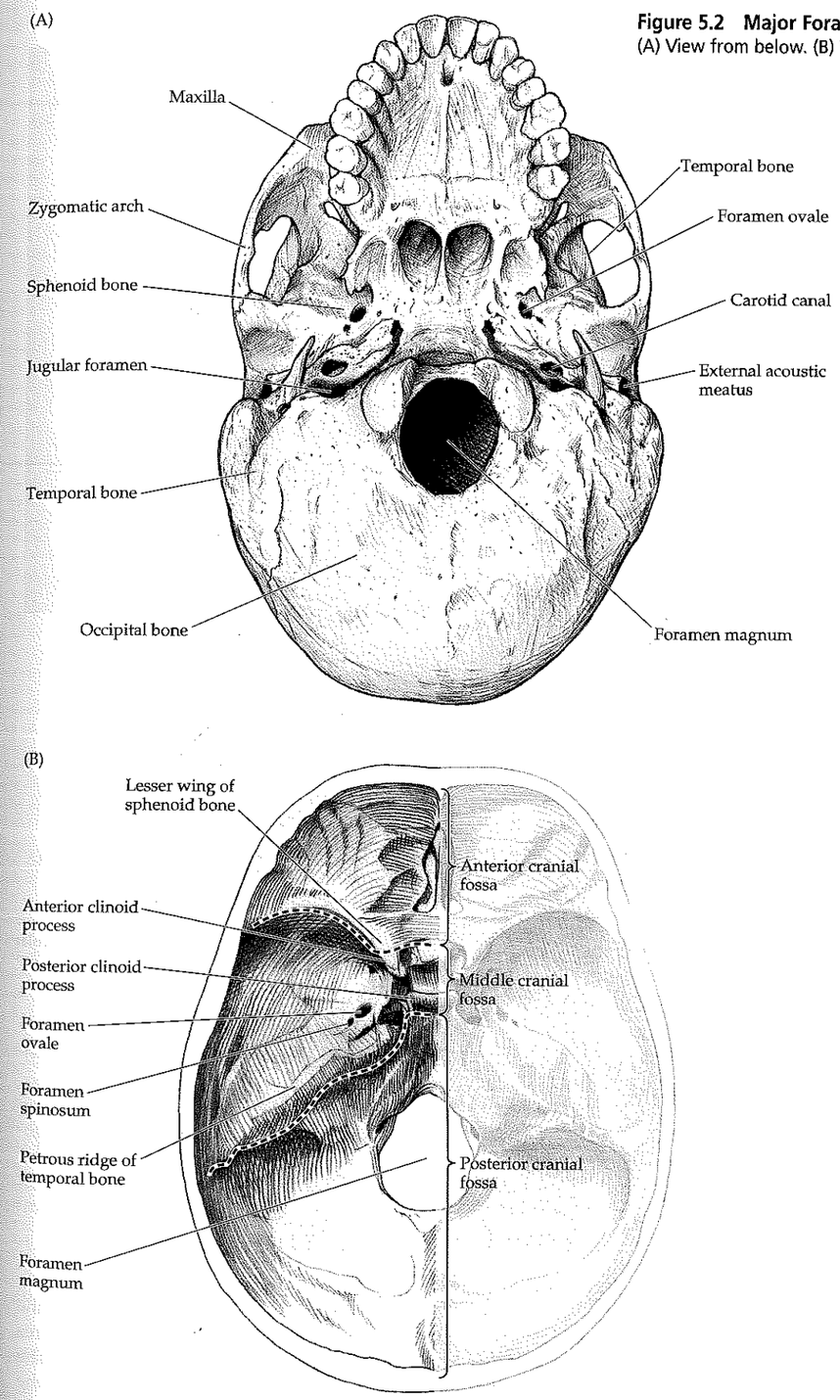

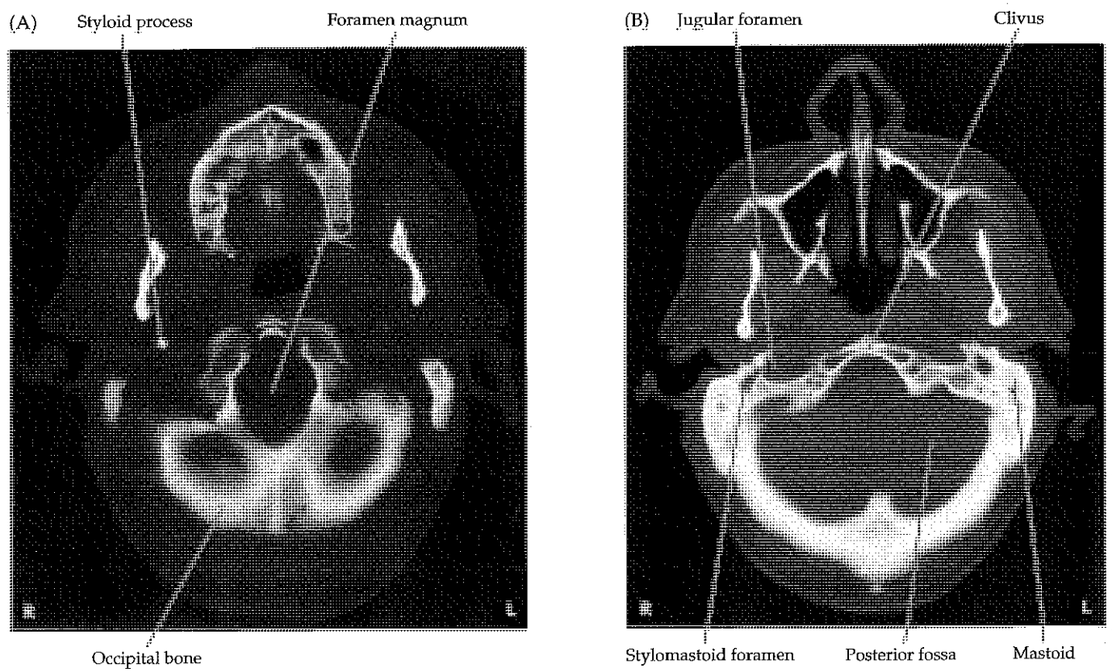

Figure 5.3 CT Scan: Bone Windows Showing Major Foramina at the Base of the Skull (A–C) Axial sections moving from inferior to superior through the posterior fossa.

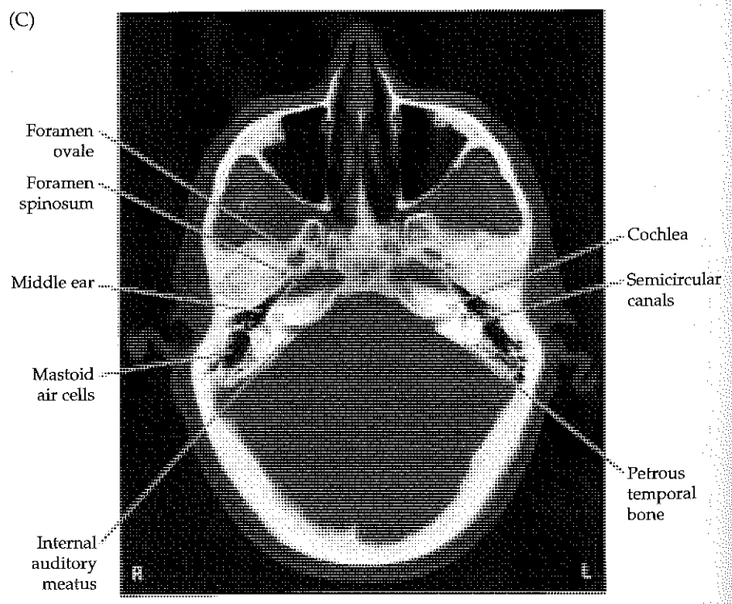

On the inner surface of the skull are several ridges of bone that divide the base of the cranial cavity into different compartments, or fossae (see Figures 5.2B and 5.4). The **anterior fossa** on each side contains the frontal lobe. The **middle fossa** contains the temporal lobe. The **posterior fossa** contains the cerebellum and brainstem. The anterior fossa is divided from the middle fossa

Figure 5.4 Anterior, Middle, and Posterior Fossae and Their Contents

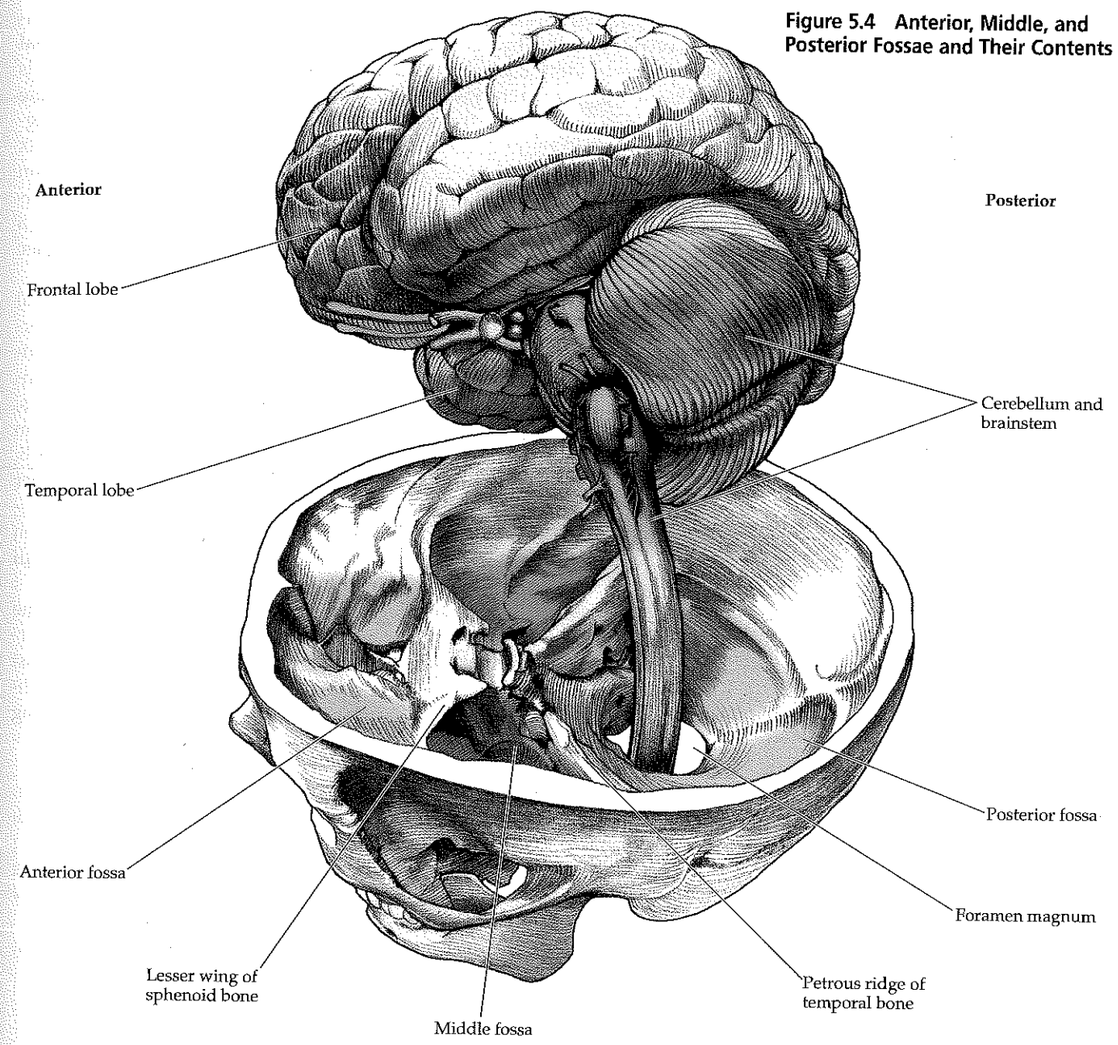

by the lesser wing of the sphenoid bone. The middle fossa is divided from the posterior fossa by the petrous ridge of the temporal bone, as well as by a sheet of meninges, which will be described next. These fossae can also be identified on CT and MRI scans (see Figures 4.12A–D and 4.13A–D).

The final layers of protection within the skull and surrounding the brain are the **meninges** and cerebral spinal fluid (see Figure 5.1). The three layers of meninges from inside to outside are

1. **Pia**
2. **Arachnoid**
3. **Dura**

Thus, a mnemonic for the meningeal layers is **PAD.** The term "mater" (meaning "mother") is sometimes added after these names—for example, pia mater, arachnoid mater, and dura mater. A mnemonic for the layers of the scalp (**SCALP**) is shown in Figure 5.1.

MNEMONIC

Moving now from outside to inside, the **dura,** meaning "hard," is composed of two tough fibrous layers (see Figure 5.1). The outer **periosteal layer** is adherent to the inner surface of the skull. This outer layer of dura is fused with the inner **meningeal layer** of dura except in a few places where the inner layer forms folds that descend far into the cranial cavity (see Figure 5.1). There are two main places where this occurs. The first is the **falx cerebri,** a flat sheet of dura that is suspended from the roof of the cranium and separates the right and left cerebral hemispheres, running in the interhemispheric fissure (Figure 5.5). The second is the **tentorium cerebelli,** a tentlike sheet of dura that covers the upper surface of the cerebellum (see Figures 5.5 and 5.6).

The tentorium cerebelli, together with the petrous portions of the temporal bones, divide the posterior fossa from the rest of the cranial vault. The portion of the intracranial cavity above the tentorium is referred to as **supratentorial,** while that below is called **infratentorial.** To understand the relationship between the tentorium cerebelli and the other intracranial structures, and how the tentorium is truly "tent" shaped, review the CT scan images in Figure 4.12D,E, and L and the MRI images in Figures 4.12D,E and 4.15A,B. Note that the occipital lobes and part of the temporal lobes rest on the upper surface of the tentorium. Recall that the midbrain connects the cerebral hemispheres with the brainstem and cerebellum. Thus, the midbrain can be seen to pass through an important narrow opening in the tentorium cerebelli called the **tentorial incisura,** or the **tentorial notch** (Figure 5.6).

The **arachnoid** is a wispy, "spidery" meningeal layer that adheres to the inner surface of the dura. Within the arachnoid, the cerebrospinal fluid percolates over the surface of the brain (see Figures 5.1, 5.10). The innermost meningeal layer is a very thin layer of cells called the **pia.** Unlike the arachnoid, the pia adheres closely to the surface of the brain and follows it along

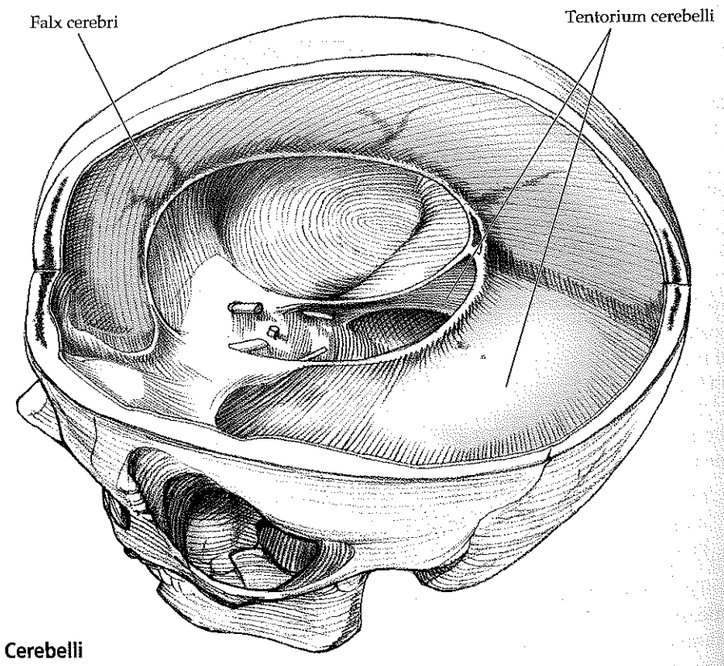

Figure 5.5 Falx Cerebri and Tentorium Cerebelli

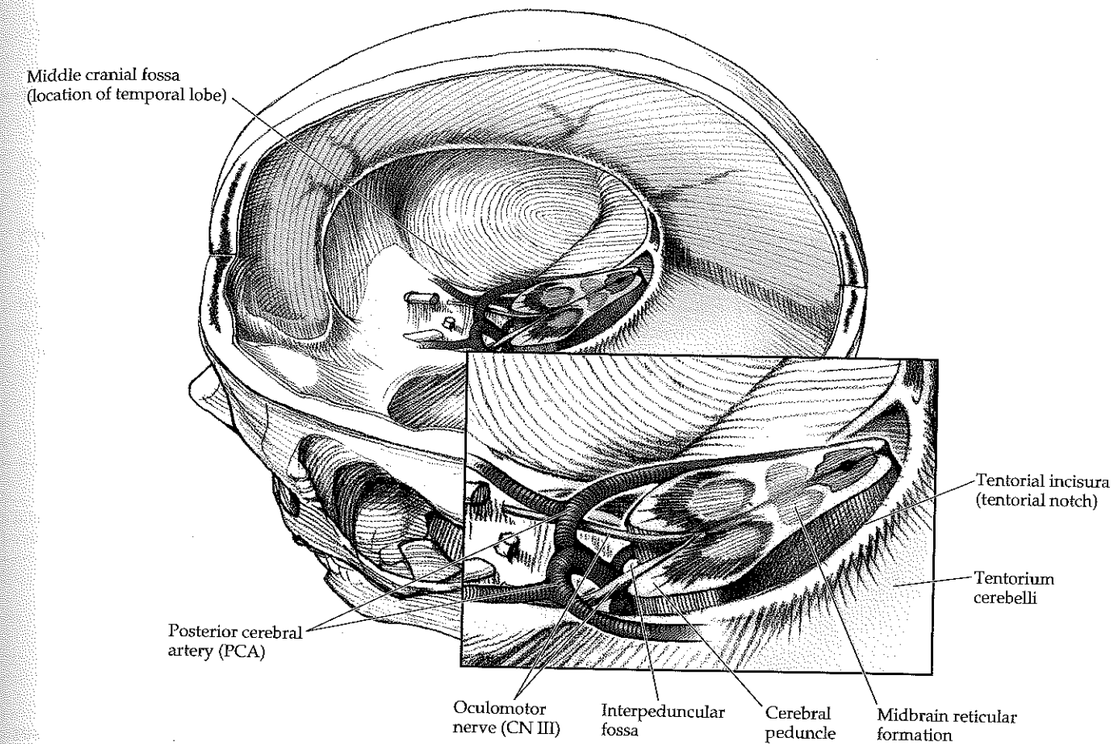

Figure 5.6 Tentorium Cerebelli and Structures Traversing the Tentorial Notch See also Figure 13.2.

all the gyri and into the depths of the sulci. The pia also surrounds the initial portion of each blood vessel as it penetrates the brain surface, forming a perivascular space (Virchow–Robin space), and then fuses with the blood vessel wall (see Figure 5.1).

The meninges form three spaces or potential spaces with clinical significance:

1. **Epidural space**
2. **Subarachnoid space**
3. **Subdural space**

There are some important blood vessels that can give rise to hemorrhage in each of these spaces (seeKCC 5.6). The **epidural space** is a potential space located between the inner surface of the skull and tightly adherent dura (see Figure 5.1). The **middle meningeal artery** enters the skull through the **foramen spinosum** (see Figures 5.2B, 5.3C) and runs in the epidural space between the dura and the skull (Figure 5.7). Grooves can often be seen on the inner surface of the skull that are formed by this artery and its many branches. Note that the middle *meningeal* artery is a branch of the external carotid artery (see Figure 2.26A) and supplies the dura, while the middle *cerebral* artery is a branch of the internal carotid artery and supplies the brain (see Figure 2.26C).

The **subdural space** is a potential space between the inner layer of dura and the loosely adherent arachnoid (see Figure 5.1). The **bridging veins** traverse the subdural space. These veins drain the cerebral hemispheres and pass

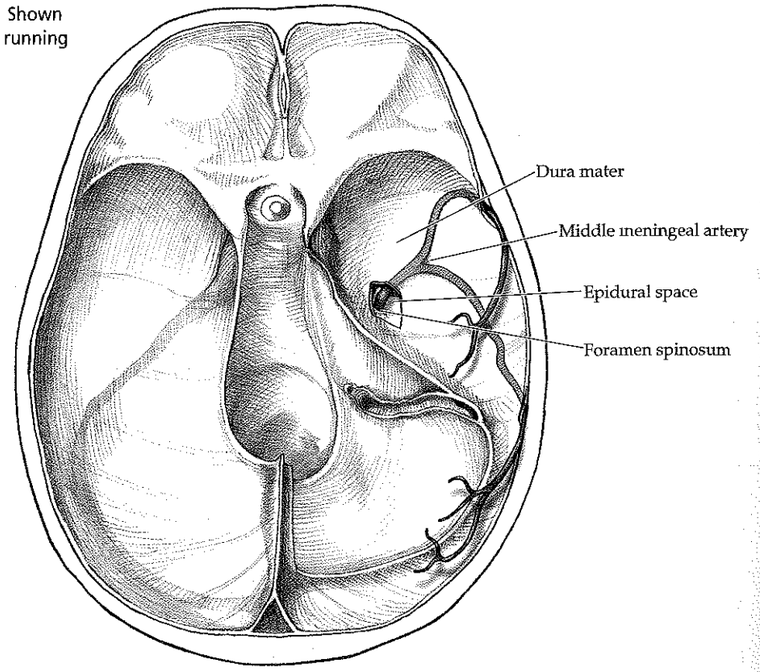

Figure 5.7 Middle Meningeal Artery Shown emerging from the foramen spinosum and running in epidural space between dura and skull.

REVIEW EXERCISE

For the epidural, subdural, and subarachnoid spaces:

1. Identify the two structures that bound each space (skull, dura, arachnoid, or pia).
2. State whether each space is a potential space or a CSF-filled space.
3. Name the main blood vessels running in each space.

through the subdural space en route to several large **dural venous sinuses** (Figures 5.8 and 5.9; see also Figure 5.1). Dural sinuses are large venous channels that lie enclosed within the two layers of dura. The dural sinuses drain blood mainly via the **sigmoid sinuses** to reach the **internal jugular veins.**

The cerebrospinal fluid–filled space between the arachnoid and the pia is called the **subarachnoid space** (see Figures 5.1, 5.10). In addition to cerebrospinal fluid, the major arteries of the brain travel within the subarachnoid space and then send smaller penetrating branches inward through the pia.

As the spinal cord exits through the foramen magnum and continues downward through the bony spinal canal, it is enveloped by the same three meningeal layers (Figure 5.10). The only significant difference is that there is a layer of **epidural fat** in the spinal canal (see Figure 8.2), while in the cranium the outer layer of dura adheres tightly to bone (see Figure 5.1).

Ventricles and Cerebrospinal Fluid

During development the neural tube forms several cavities within the brain called **ventricles** (see Figure 2.2). The ventricles contain **cerebrospinal fluid (CSF)** that is produced by a specialized vascular structure called the **choroid plexus,** which lies inside the ventricles (see Figure 5.10). The inner walls of the ventricles are lined with a layer of cells called **ependymal cells,** and the blood vessels of the choroid plexus are lined with similar-appearing cuboidal cells called **choroid epithelial cells** (see Figure 5.13C). There are two lateral ventricles (one inside each cerebral hemisphere), a third ventricle located within the diencephalon, and the fourth ventricle, which is surrounded by the pons, medulla, and cerebellum (Figure 5.11, Table 5.1).

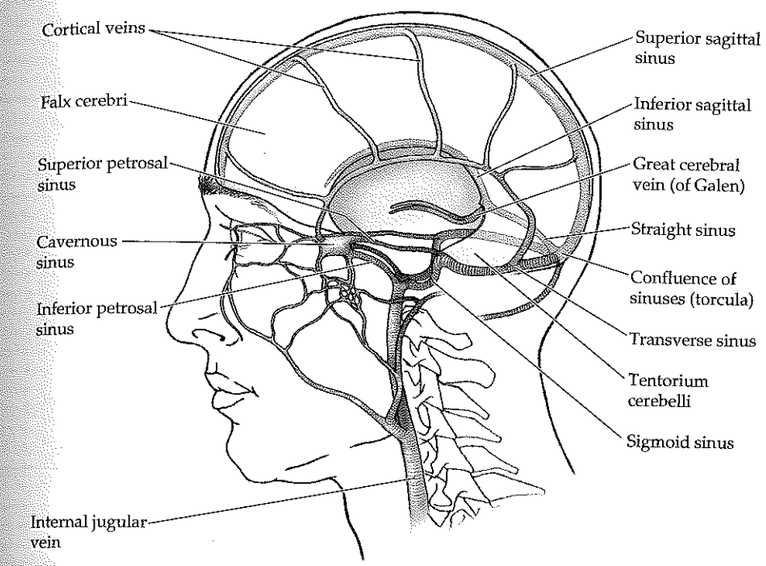

Figure 5.8 Dural Venous Sinuses and Internal Jugular Veins Lateral view.

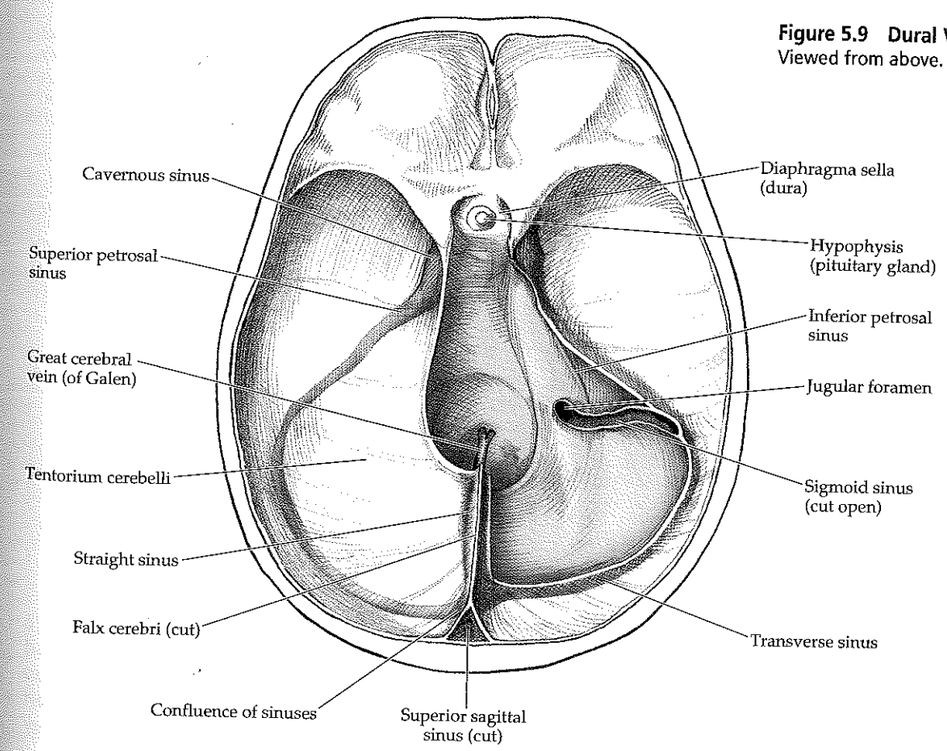

Figure 5.9 Dural Venous Sinuses Viewed from above.

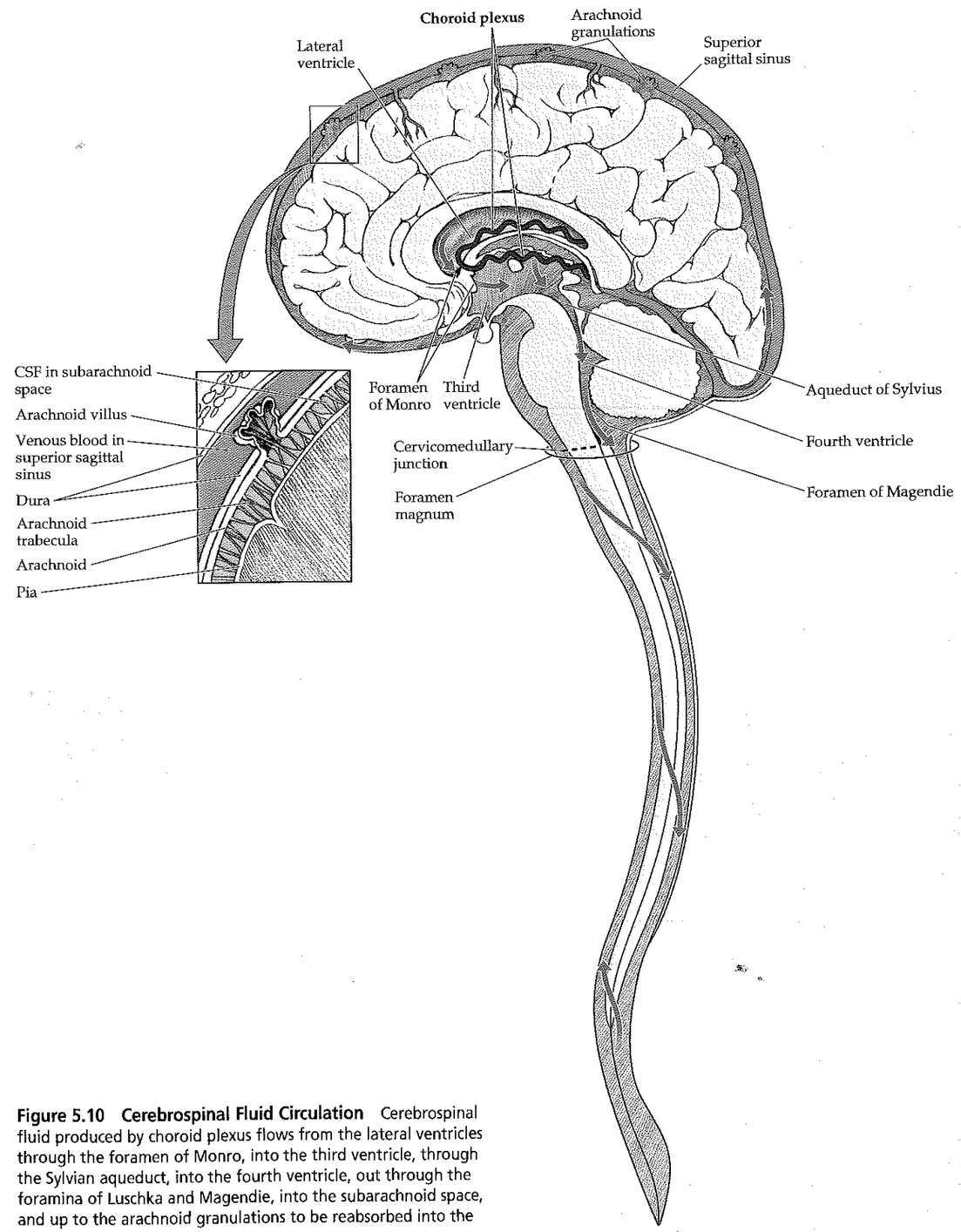

Figure 5.10 Cerebrospinal Fluid Circulation Cerebrospinal fluid produced by choroid plexus flows from the lateral ventricles through the foramen of Monro, into the third ventricle, through the Sylvian aqueduct, into the fourth ventricle, out through the foramina of Luschka and Magendie, into the subarachnoid space, and up to the arachnoid granulations to be reabsorbed into the bloodstream.

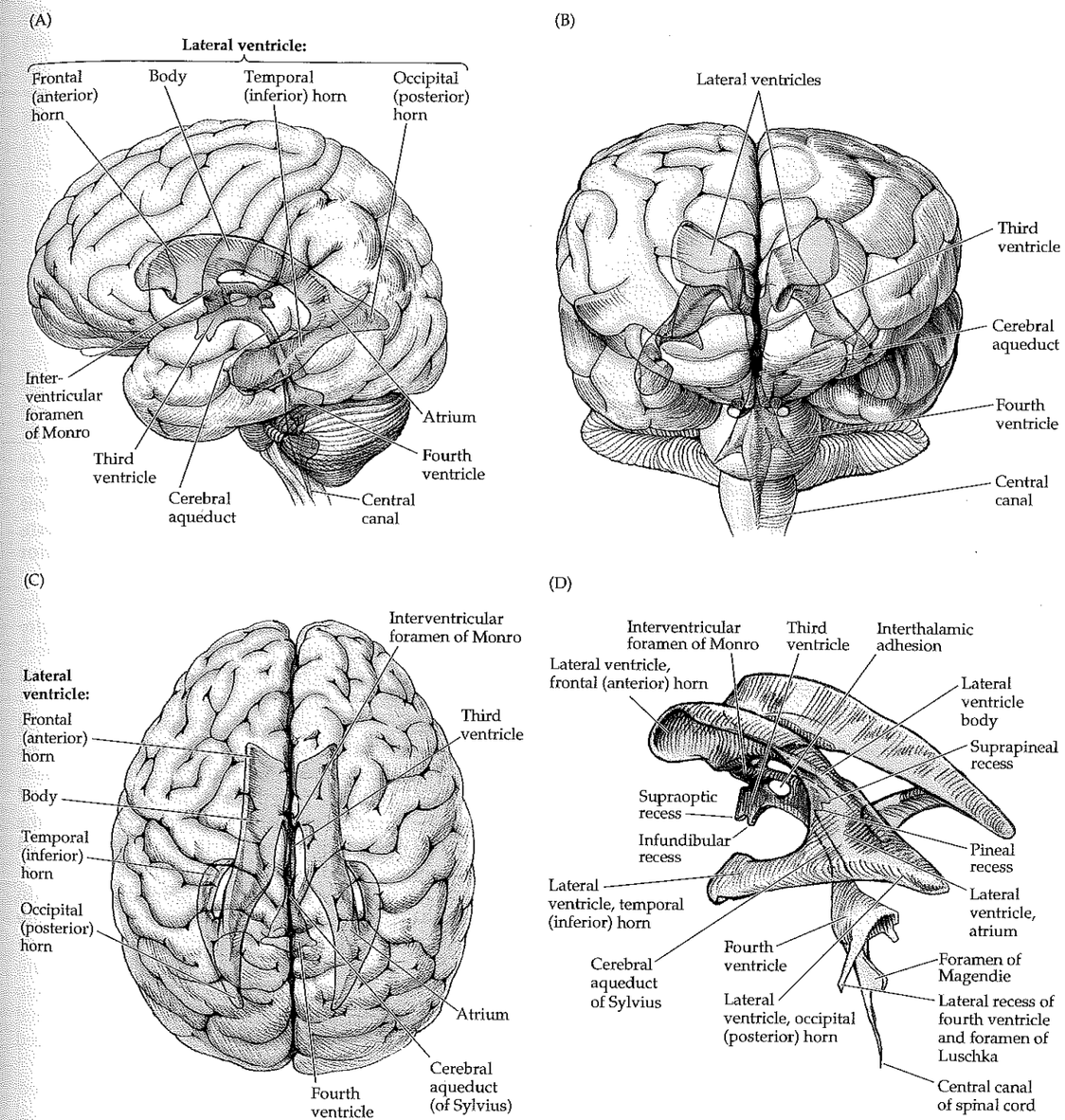

Figure 5.11 Brain Ventricles
(A) Ventricles viewed from lateral surface of brain. (B) Ventricles viewed from anterior surface of brain. (C) Ventricles viewed from superior surface of brain. (D) Details of ventricular structure.

The largest of the ventricles are the two **lateral ventricles** (see Figure 5.11), formerly called the first and second ventricles. The lateral ventricles have extensions called horns that are named after the lobes or after the direction in which they extend (see Table 5.1, Figure 5.11). The **frontal** or **anterior horn** of the lateral ventricle extends anteriorly from the **body** of the lateral ventricle into the frontal lobe. By definition, the frontal horn begins anterior

TABLE 5.1 Brain Ventricles

VENTRICLE	LOCATION
Lateral ventricle	Within the cerebral hemisphere
Frontal (anterior) horn	Begins anterior to the interventricular foramen of Monro and extends into the frontal lobe
Body	Posterior to the interventricular foramen of Monro, within the frontal and parietal lobes
Atrium (trigone)	Area of convergence of the occipital horn, the temporal horn, and the body of the lateral ventricle
Occipital (posterior) horn	Extends from the atrium posteriorly into the occipital lobe
Temporal (inferior) horn	Extends from the atrium inferiorly into the temporal lobe
Third ventricle	Within the thalamus and hypothalamus
Fourth ventricle	Within the pons, medulla, and cerebellum

REVIEW EXERCISE

Cover the labels in Figure 5.10 and name each space or foramen that CSF travels through en route from the choroid plexus of the lateral ventricles to the arachnoid granulations.

Next, use the Neuroradiological Atlas CT and MRI images (see Figures 4.12–4.15) to identify each of the structures listed in the left column of Table 5.1 and to identify the foramen of Monro and the cerebral aqueduct.

to the foramen of Monro, described below. The body of the lateral ventricle merges posteriorly with the **atrium** or **trigone**. The atrium connects three parts of the lateral ventricle—the body; the **occipital** or **posterior horn**, which extends back into the occipital lobe; and the **temporal** or **inferior horn**, which extends inferiorly and anteriorly into the temporal lobe.

There are several **"C"-shaped structures** in the brain that follow the curve of the lateral ventricles, including the caudate nucleus, corpus callosum, fornix, and stria terminalis. The spatial relationships between these structures are discussed at the end of this chapter in the Brief Anatomical Study Guide and in "A Scuba Expedition through the Brain."

The lateral ventricles communicate with the **third ventricle** (see Table 5.1) via the **interventricular foramen of Monro** (see Figures 5.10, 5.11). The walls of the third ventricle are formed by the thalamus and hypothalamus. The third ventricle communicates with the **fourth ventricle** via the **cerebral aqueduct,** also called the **aqueduct of Sylvius,** which travels through the midbrain (see Figures 5.10, 5.11). The roof of the fourth ventricle is formed by the cerebellum, and the floor is formed by the pons and medulla.

MNEMONIC

Cerebrospinal fluid leaves the ventricular system via several foramena in the fourth ventricle—the ***l*ateral foramina of *L*uschka,** and the ***m*idline foramen of *M*agendie** (see Figure 5.11D). Cerebrospinal fluid then percolates around the brain and spinal cord in the subarachnoid space and is ultimately reabsorbed by the **arachnoid granulations** (see Figures 5.1, 5.10) into the dural venous sinuses, and thus back into the bloodstream. The normal total volume of cerebrospinal fluid in an adult is about **150 cc**. It is produced by the choroid plexus at a rate of **20 cc/hour,** or about 500 cc/day.

The subarachnoid space widens in a few areas to form larger CSF collections called **cisterns.** The following cisterns come up fairly often in clinical practice (Figure 5.12):

- Perimesencephalic cisterns
  - Ambient cistern (cisterna ambiens)
  - Quadrigeminal cistern (cisterna quadrigemina)
  - Interpeduncular cistern
- Prepontine cistern (pontine cistern)
- Cisterna magna
- Lumbar cistern

The **ambient cistern** is located lateral to the midbrain; the **quadrigeminal cistern** is posterior to the midbrain, beneath the posterior portion of the corpus callosum (see Figure 5.12). The name "quadrigeminal" comes from the four bumps of the superior and inferior colliculi (see Figures 2.22B, 5.12). The **interpeduncular cistern,** also sometimes called the **interpeduncular fossa,** is located on the ventral surface of the midbrain, between the cerebral peduncles (see Figure 5.6). Note that the third nerve exits the midbrain through the interpeduncular fossa. The **prepontine cistern** is located just ventral to the pons. It contains the basilar artery and the sixth nerves (see Figures 2.22A, 2.26C) as they ascend from the pontomedullary junction up along the clivus (see Figure 5.3B). The **cisterna magna,** also known as the cerebellomedullary cistern, is the largest cistern and is located beneath the cerebellum near the foramen magnum (see Figure 5.12; see also Figure 4.15A). Finally, the **lumbar cistern,** located in the lumbar portions of the spinal column, contains the cauda equina (see Figure 2.8) and is the region from which cerebrospinal fluid is obtained during a **lumbar puncture,** or spinal tap (see KCC 5.10).

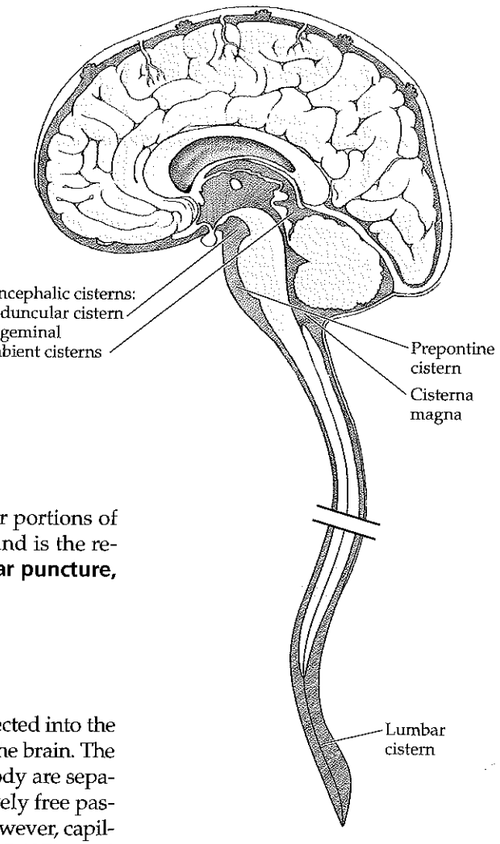

Figure 5.12 Principal CSF Cisterns in the Subarachnoid Space

Blood–Brain Barrier

Anatomists discovered in the 1800s that when a colored dye is injected into the bloodstream of an animal, all of its organs become stained except the brain. The reason is that the capillary wall endothelial cells in most of the body are separated from each other by clefts, or fenestrations, allowing relatively free passage of fluids and solute molecules (Figure 5.13A). In the brain, however, capillary endothelial cells are linked by **tight junctions** (Figure 5.13B), and substances entering or leaving the brain must travel through the endothelial

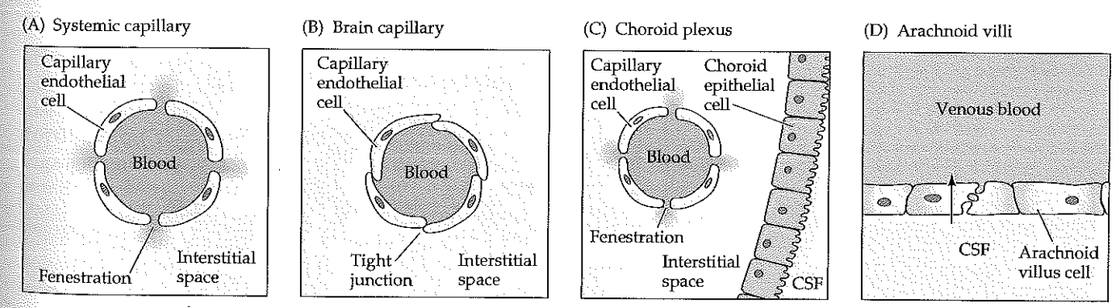

Figure 5.13 Blood–Brain and Blood–CSF Barriers (A) Typical fenestrated capillary lying outside the nervous system, allowing the passage of water and solutes. (B) Brain capillary with tight junctions between endothelial cells, forming the blood–brain barrier. Cellular transport across the endothelial layer is required for the passage of water-soluble substances between blood and brain. (C) The choroid plexus capillary allows the passage of water and solutes, but choroid plexus epithelial cells form the blood–CSF barrier, requiring cellular transport for passage. (D) The arachnoid villus cell carries out one-way bulk flow of CSF from the subarachnoid space to venous sinuses via giant vacuoles.

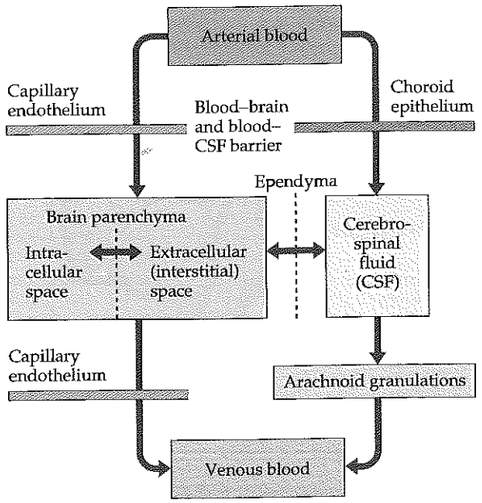

Figure 5.14 Fluid Compartments of the Nervous System Blood–brain and blood–CSF barriers separate arterial blood from brain parenchyma and CSF. Substances pass relatively freely between brain parenchyma interstitial space and CSF.

cells, mostly by active transport processes. These endothelial cells and the tight junctions between them form the **blood–brain barrier.**

A similar selective barrier exists between the choroid plexus and the CSF (Figure 5.13C), sometimes referred to as the blood–CSF barrier. The capillaries of the choroid plexus are freely permeable, but the **choroid epithelial cells** form a barrier between the capillaries and the CSF. Lipid-soluble substances, including O_2 and CO_2, permeate readily across the cell membranes of the blood–brain and blood–CSF barriers. However, most other substances must be conveyed in both directions through specialized transport systems, including active transport, facilitated diffusion, ion exchange, and ion channels. In contrast to these vascular barriers, substances can pass relatively freely across the ependymal layer between the CSF and brain parenchyma (Figure 5.14). CSF is reabsorbed at the arachnoid granulations, where **arachnoid villus cells** mediate one-way bulk transport of CSF through giant vacuoles large enough to engulf entire red blood cells (see Figure 5.13D).

Because synaptic transmission depends largely on chemical communication between neurons, the blood–brain and blood–CSF barriers protect brain function from most of the fluctuations in blood chemistry that occur on a continual basis. However, in certain specialized brain regions known as the **circumventricular organs,** the blood–brain barrier is interrupted, allowing the brain to respond to changes in the chemical milieu of the remainder of the body, and to secrete modulatory neuropeptides into the bloodstream (Figure 5.15). Best known among these are the **median eminence** and the **neurohypophysis,** which are involved in the regulation and release of pituitary hormones (see Chapter 17).

The **area postrema** is the only paired circumventricular organ, and it is located along the caudal wall of the fourth ventricle in the medulla. Also known as the **chemotactic trigger zone,** it is involved in detecting circulating toxins that cause vomiting. The other circumventricular organs have less known clinical relevance, and will be mentioned briefly only for the sake of

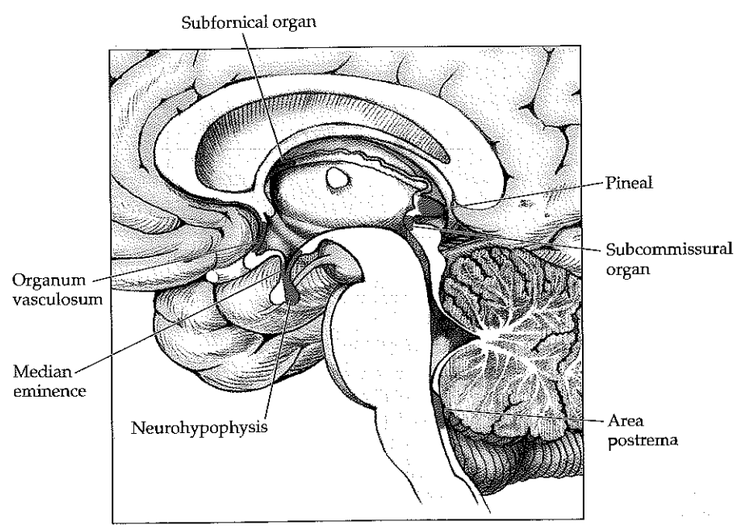

Figure 5.15 Circumventricular Organs Select regions where blood–brain barrier is interrupted, allowing chemical communication between the brain and the systemic circulation.

completeness. The organum vasculosum of the lamina terminalis may have neuroendocrine functions, the subfornical organ may regulate fluid balance, the **pineal** may be involved in melatonin-related circadian rhythms, and the function of the subcommissural organ is not known.

Brain tumors, infections, and other disorders can disrupt the blood–brain barrier, resulting in extravasation of fluids into the interstitial space (see Figure 5.14). This excessive extracellular fluid is called **vasogenic edema.** Cellular damage—for example, in cerebral infarction—can cause excessive intracellular fluid accumulation within brain cells, a condition known as **cytotoxic edema.** Both kinds of edema often occur simultaneously.

This concludes our anatomical review of the cranial vault, ventricles, and meninges. The sections that follow (KCC 5.1–5.11) introduce several clinical concepts that will be referred to frequently throughout this book. Therefore, you may choose to skim these sections only briefly now and move on to Clinical Cases 5.1–5.10 to solidify your knowledge of the anatomical material in this chapter.

KEY CLINICAL CONCEPT
HEADACHE

Headache is one of the most common neurologic symptoms. Although usually benign, it occasionally signals life-threatening conditions. Interestingly, there are no pain receptors in the brain parenchyma itself. Therefore, headache is caused by mechanical traction, inflammation, or irritation of other structures in the head that are innervated, including the blood vessels, meninges, scalp, and skull. The supratentorial dura (most of the intracranial cavity) is innervated by the trigeminal nerve (CN V), while the dura of the posterior fossa is innervated mainly by CN X, but also by CN IX and the first three cervical nerves. The side of the headache often, but not always, corresponds to the side of pathology. Most headaches can be classified as either vascular headache or tension headache (Table 5.2). A diverse list of other causes of headache is also found in Table 5.2, organized roughly according to the Arrowhead of Neurologic Differential Diagnosis discussed in Chapter 1 (see Figure 1.1).

The term **vascular headache** is used to mean migraine, as well as the less common but closely related disorder called cluster headache. The pathophysiology of vascular headache is not fully understood, but it is thought to involve inflammatory, autonomic, serotonergic, neuroendocrine, and other influences on blood vessel caliber in the head, leading to headache and other associated symptoms. In **migraine,** about 75% of patients have a positive family history, suggesting a genetic basis. Symptoms may be provoked by certain foods, stress, eye strain, the menstrual cycle, changes in sleep pattern, and a variety of other triggers. Migraine often is preceded by an **aura,** or warning symptoms, classically involving visual blurring, shimmering, scintillating distortions, or **fortification scotoma**—a characteristic region of visual loss bordered by zigzagging lines resembling the walls of a fort. The headache is often unilateral, but if it is always on the same side, an MRI scan is warranted to exclude a vascular malformation or other lesion as a trigger for the headaches. The pain is often throbbing and may be exacerbated by light (photophobia), sound (phonophobia), or sudden head movement. Nausea and vomiting may occur, and the scalp may be tender to the touch. Duration is typically 30 minutes to up to 24 hours, and relief often occurs after sleeping. The severity of migraine headaches ranges from mild to very severe in different individuals, and migraines may recur from once every few years to up to several times per week.

Complicated migraine may be accompanied by a variety of transient focal neurologic deficits (see KCC 10.3), including sensory phenomena, motor deficits (e.g., hemiplegia), visual loss, brainstem findings in **basilar migraine,** and impaired eye movements in **ophthalmoplegic migraine.** Migraine as a cause of these deficits should be a diagnosis of exclusion, and

TABLE 5.2 Differential Diagnosis of Headache

Vascular headache
Migraine
Cluster headache
Tension headache
Other causes[a]
Acute trauma
Intracranial hemorrhage
Cerebral infarct
Carotid or vertebral artery dissection
Venous sinus thrombosis
Post-ictal headache
Hydrocephalus
Pseudotumor cerebri
Low CSF pressure
Toxic or metabolic derangements
Meningitis
Epidural abscess
Vasculitis
Trigeminal or occipital neuralgia
Neoplasm
Disorders of the eyes, ears, sinuses, teeth, joints, or scalp

[a]Following format of Figure 1.1

should be accepted only in the setting of recurrent episodes, and only after appropriate tests have been done to exclude cerebrovascular disease, epilepsy, or other disorders.

Treatment of migraine is often quite effective. Acute attacks usually respond to nonsteroidal anti-inflammatory drugs, anti-emetics, triptans (serotonin agonists), ergot derivatives, or other medications, and to rest in a dark, quiet room. Preventive measures include avoiding triggers when possible, and for patients who have frequent attacks, treatment with prophylactic agents such as beta-blockers, tricyclic antidepressants, calcium channel blockers, valproate, or methysergide (note that methysergide carries a risk of retroperitoneal fibrosis).

Cluster headache is less than one-tenth as common as migraine. It occurs about five times more often in males than in females. Typically, clusters of headaches occur from once to several times per day every day over a few weeks and then vanish for several months. Headache pain is extremely severe, often described as a steady boring sensation behind one eye, lasting from about 30 to 90 minutes. It is usually accompanied by unilateral autonomic symptoms such as tearing, eye redness, Horner's syndrome (see KCC 13.5), unilateral flushing, sweating, and nasal congestion. Treatment is similar to that for migraine. In addition, inhaled oxygen is often effective in aborting attacks.

Tension headache, recently renamed **tension-type headache,** is a steady dull ache, sometimes described as a bandlike sensation. Although possibly related to excessive contraction of scalp and neck muscles, the pathophysiologic distinction between tension headache and migraine has been questioned. Tension-type headache includes the common type of mild to moderate headache that most individuals experience from time to time, lasting up to a few hours. However, some patients have tension-type headaches that occur continuously every day for years. This chronic form of headache is commonly associated with psychological stress, but it is often unclear which is cause and which is effect. Chronic daily headache of this kind is also commonly seen in **posttraumatic headache.** Treatment for tension-type headache includes muscle relaxation techniques, nonsteroidal anti-inflammatory drugs, other analgesics, and tricyclic antidepressants.

It is important for clinicians to be familiar with the other causes of headache listed in Table 5.2, since diagnosis and intervention with many of these disorders can be potentially lifesaving. We will mention only a few salient points here, and the specific disorders will be discussed in greater detail in the sections and chapters that follow. Sudden "explosive" onset of severe headache should always be taken seriously. A CT scan should be done urgently to see if a subarachnoid hemorrhage has occurred (see KCC 5.6; Figure 5.19F). It is less well recognized that headache is common in cerebral ischemia and infarction (see KCC 10.4), and in the post-ictal period following seizures (see KCC 18.2). Low CSF pressure can occur spontaneously, or following lumbar puncture (see KCC 5.10), resulting in headache that is worse while standing up and better while lying down. In contrast, in disorders such as neoplasms that can increase intracranial pressure, the headache may be worse when lying down during the night (see KCC 5.3).

Headache accompanied by fever or signs of meningeal irritation, such as stiff neck and sensitivity to light (see Table 5.5), should be evaluated and treated immediately for possible infectious meningitis, since patients with this condition can deteriorate rapidly if untreated.

Pseudotumor cerebri is a condition of unknown cause characterized by headache and elevated intracranial pressure (see KCC 5.3) with no mass lesion. It is most common in adolescent females, and it is treated with acetazolamide or, when severe, with shunting procedures (see KCC 5.7). **Temporal arteritis,** also called giant cell arteritis, is an important treatable cause of headache, seen most commonly in elderly individuals. In this disorder, vasculitis affects the temporal arteries, as well as other vessels, including those supplying the eye. The temporal artery is characteristically enlarged and firm. Diagnosis is made by measurement of the blood **erythrocyte sedimentation rate (ESR)** and by temporal artery biopsy. Prompt diagnosis and treatment with steroids is essential to prevent possible vision loss. ■

KEY CLINICAL CONCEPT
INTRACRANIAL MASS LESIONS

5.2 Anything abnormal that occupies volume within the cranial vault functions as a mass. Examples include tumor, hemorrhage, abscess, edema, hydrocephalus, and other disorders. Intracranial mass lesions can cause neurologic symptoms and signs by the following mechanisms:

1. Compression and destruction of adjacent regions of the brain can cause neurologic abnormalities.
2. A mass located within the cranial vault can raise the **intracranial pressure,** which causes certain characteristic symptoms and signs.
3. Mass lesions can displace nervous system structures so severely that they are shifted from one compartment into another, a situation called **herniation.**

In this section we will discuss local effects of the mass itself in the brain. In KCC 5.3 and 5.4 we will discuss elevated intracranial pressure and herniation.

Mass lesions can cause both local tissue damage and remote effects through mechanical distortion of adjacent structures. **Mass effect** is a descriptive term used for any distortion of normal brain geometry due to a mass lesion. Mass effect can be as subtle as a mild flattening, or **effacement,** of sulci next to a lesion seen on MRI scan but producing no symptoms. Depending on location and size, a mass can produce neurologic abnormalities due to local damage. For example, a lesion located in the primary motor cortex will cause contralateral weakness. If the mass distorts or irritates blood vessels or meninges, it may cause headache (see KCC 5.1). Compression of blood vessels can also cause ischemic infarction, and erosion through blood vessel walls can cause hemorrhage.

Disruption of the blood–brain barrier results in extravasation of fluid into the extracellular space, producing vasogenic edema (see Figures 5.13, 5.14). Compression of the ventricular system can obstruct CSF flow, producing hydrocephalus (see KCC 5.7). Lesions can provoke abnormal electrical discharges in the cerebral cortex, resulting in seizures (see KCC 18.2). In addition, remote effects may result from functional changes in regions receiving important synaptic connections from the damaged areas. Large masses can produce dramatic **midline shift** of brain structures away from the side of the lesion. Displacement and stretching of the upper brainstem impairs function of the reticular activating systems (see Figure 2.23) causing impaired consciousness and, ultimately, coma. The pineal calcification (see Figure 4.12F) is a useful landmark for measuring extent of midline shift at the level of the upper brainstem. The amount of pineal shift has been shown to correlate with impairment of consciousness. In the extreme, mass effect causes brain structures to shift from one compartment into another, leading to herniation (see KCC 5.4). ■

KEY CLINICAL CONCEPT
ELEVATED INTRACRANIAL PRESSURE

5.3 The contents of the intracranial space are confined by the hard walls of the bony skull. Of the three residents of this cavity—cerebrospinal fluid, blood, and brain tissue—not one is compressible (although they can be deformed). Therefore, whenever there is a space-occupying or mass lesion within the skull, something must leave the skull to accommodate the extra volume (Figure 5.16). Smaller lesions can be accommodated by a decrease in intracranial CSF and blood without causing much rise in intracranial pressure (flat part of the curve

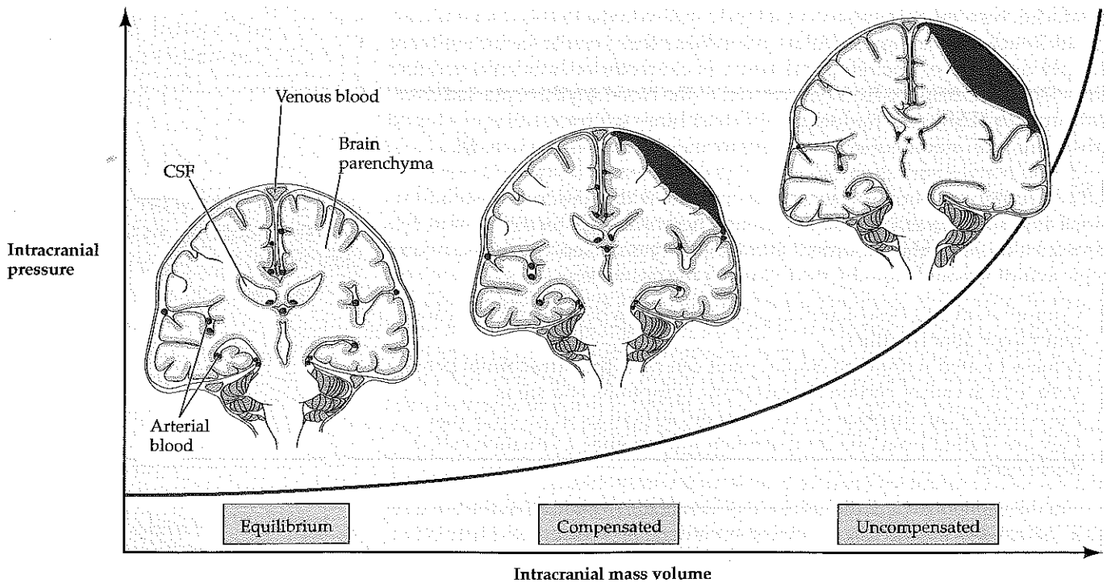

Figure 5.16 Intracranial Pressure versus Intracranial Mass Volume Small intracranial masses can be compensated for by reductions in intracranial CSF and blood volume. Larger masses lead to a steep rise in intracranial pressure, causing reduced cerebral perfusion and, ultimately, herniation. Note that the volume of CSF has been exaggerated in the equilibrium state (as seen in cerebral atrophy) for illustrative purposes.

TABLE 5.3 Common Symptoms and Signs of Elevated Intracranial Pressure

SYMPTOM OR SIGN
Headache
Altered mental status, especially *irritability and depressed level of alertness and attention*[a]
Nausea and vomiting
Papilledema
Visual loss
Diplopia (double vision)
Cushing's triad: hypertension, bradycardia, and irregular respirations

[a]This is often the most important indicator of elevated intracranial pressure.

in Figure 5.16). Larger lesions overcome this compensatory mechanism, and the intracranial pressure eventually begins to rise steeply. This can ultimately lead to herniation (see KCC 5.4) and death (right part of the curve in Figure 5.16)

Severely elevated intracranial pressure can cause decreased cerebral blood flow and brain ischemia. Cerebral blood flow depends on **cerebral perfusion pressure,** which is defined as the **mean arterial pressure minus the intracranial pressure (CPP = MAP – ICP)**. Therefore, as the intracranial pressure increases, cerebral perfusion pressure decreases. **Autoregulation** of cerebral vessel caliber can compensate for modest reductions in cerebral perfusion pressure, leading to relatively stable cerebral blood flow. However, large increases in intracranial pressure can exceed the capacity of autoregulation, leading to reduced cerebral blood flow and brain ischemia. Depending on the type of lesion, intracranial pressure can change suddenly or more slowly over days to weeks. If left untreated, severely elevated intracranial pressure causes irreversible brain damage and death, sometimes within a few hours.

It is essential for clinicians to recognize the **symptoms and signs of elevated intracranial pressure** (Table 5.3) so that appropriate treatment can be instituted without delay. Let's discuss each of the symptoms and signs in Table 5.3 in turn. **Headache** associated with intracranial mass lesions is often worse in the morning, since brain edema increases overnight from the effects of gravity in the reclining position. **Altered mental status**, especially *irritability and depressed level of alertness and attention*, is often the most important indicator of elevated intracranial pressure. The mechanisms giving rise to **nausea and vomiting** in elevated intracranial pressure are not known. Vomiting occasionally occurs suddenly and without much nausea. This is called **projectile vomiting**.

Elevated intracranial pressure is transmitted through the subarachnoid space to the optic nerve sheath, obstructing axonal transport and venous return in the optic nerve. Ophthalmoscopic exam (see neuroexam.com Video

25) may, therefore, reveal **papilledema,** in which there is engorgement and elevation of the optic disc, sometimes accompanied by retinal hemorrhages (Figure 5.17). This classic sign of elevated intracranial pressure takes several hours to days to develop and is *often not present in the acute setting*. Transient or permanent optic nerve injury can occur in association with papilledema, leading to visual blurring or **visual loss.** Areas of decreased vision most commonly include an **increased blind spot** or a **concentric visual field deficit** affecting mainly the peripheral margins of the visual field (see Figure 11.16A). **Diplopia** (double vision) can occur as a result of downward traction on CN VI, causing unilateral or bilateral abducens nerve palsies (see KCC 13.4). Finally, **Cushing's triad**—hypertension, bradycardia, and irregular respirations—is another classic sign of elevated intracranial pressure. Hypertension may be a reflex mechanism to maintain cerebral perfusion pressure, bradycardia may be a reflex response to the hypertension, and irregular respirations are caused by impaired brainstem function (see Figure 14.16). In reality, a variety of changes in vital signs other than Cushing's triad can be seen as a result of brainstem dysfunction, including hypotension and tachycardia.

The goal of treating elevated intracranial pressure is to reduce it to safe levels, providing time to treat the underlying disorder. **Normal intracranial pressure** in adults is **less than 20 cm H_2O,** or **less than 15 mm Hg (torr)**. (1 cm H_2O = 0.735 mm Hg; 1 mm Hg = 1.36 cm H_2O.) Another critical goal of therapy is to keep cerebral perfusion pressure above 50 mm Hg so that cerebral blood flow is maintained. Intracranial pressure can be measured in clinically stable patients during lumbar puncture (see KCC 5.10). However, lumbar puncture should not be performed in patients suspected of having severely elevated intracranial pressure due to risk of precipitating herniation (see KCC 5.4).

Ophthalmoscopic exam

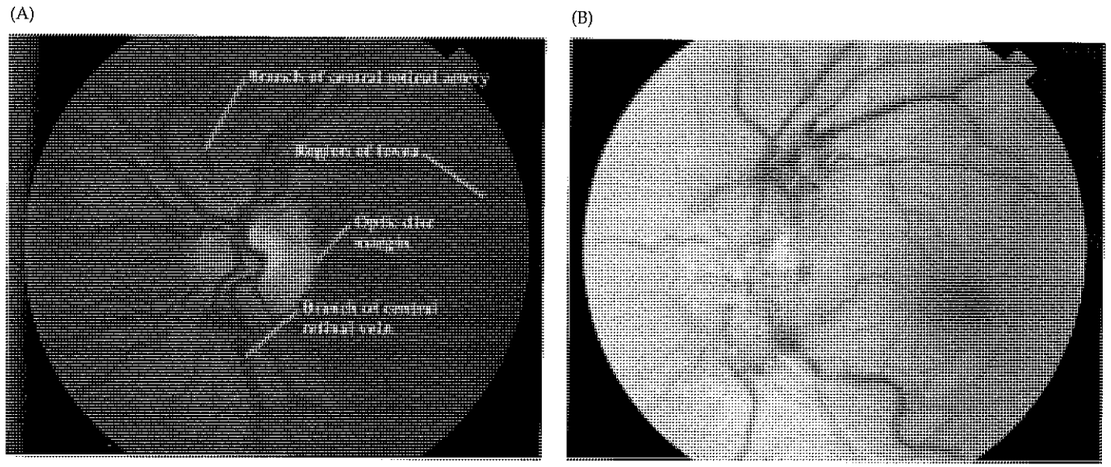

Figure 5.17 Papilledema (A) Funduscopic view of retina from a normal subject (left eye). Note sharp margins of the optic disc. (B) Papilledema in a patient with elevated intracranial pressure (left eye). This was a 43-year-old man who developed headaches, visual blurring, and horizontal diplopia. Lumbar puncture had an opening pressure of 40 cm H_2O. Magnetic resonance venogram revealed a bilateral sigmoid sinus venous thrombosis (see KCC 10.7). Blood studies showed an elevated anticardiolipin antibody (see KCC 10.4). The patient was treated successfully with chronic oral anticoagulation.

TABLE 5.4 Treatment Measures for Elevated Intracranial Pressure

INTERVENTION	TIME TO ONSET OF EFFECT	PROPOSED MECHANISM/COMMENTS
Elevate head of bed 30°, and maintain head straight to avoid obstructing jugular venous return.	Immediate	Promotes venous drainage
Intubate and hyperventilate to pCO_2 of 25–30 mm Hg.	30 seconds	Causes cerebral vasoconstriction
IV mannitol 1 g/kg bolus, then 0.25 mg/kg every 6 hours, aiming for serum osmolarity of 300–310 while maintaining normal volume status and normal blood pressure. Furosemide may also be added to promote diuresis of excess fluid.	5 minutes	Promotes removal of edema and other fluids from CNS while maintaining cerebral perfusion
Ventricular drainage	Minutes	Removal of CSF decreases intracranial pressure
If other measures fail, try barbiturate-induced coma.	1 hour	Causes cerebral vasoconstriction and reduced metabolic demands
Hemicraniectomy (removal of skull overlying mass lesion)	Immediate	Decompresses intracranial cavity. Experimental.
Steroids	Hours	Reduces cerebral edema, possibly by strengthening blood–brain barrier. May also work by other mechanisms. Often used with brain tumors. Not shown to improve outcome in acute head trauma, stroke, or hemorrhage.

In critically ill patients, intracranial pressure can be monitored continuously with a ventricular drain, intraparenchymal monitor, subarachnoid bolt, or a variety of other devices placed neurosurgically within the cranium and connected to a pressure transducer. Measures to lower intracranial pressure can then be instituted as described in Table 5.4 while the results are being monitored. Note that treatment of elevated intracranial pressure is somewhat controversial, and authorities differ as to which measures are actually beneficial (the list in Table 5.4 does not reflect this controversy). It should be reemphasized that all of these measures are temporary, and they are best used to buy time while treatment of the underlying cause of the elevated intracranial pressure is instituted. ■

KEY CLINICAL CONCEPT

BRAIN HERNIATION SYNDROMES

5.4 As discussed in KCC 5.2, intracranial tumors, hemorrhage, edema, and other masses cause a displacement of intracranial structures called mass effect. **Herniation** occurs when mass effect is severe enough to push intracranial structures from one compartment into another. Herniation between different compartments is associated with certain distinct clinical features. Some authors argue that herniation does not actually cause these clinical features, and that it is merely an epiphenomenon. Nevertheless, herniation remains a clinically useful concept and will therefore be discussed in more traditional terms in this section.

The three most clinically important herniation syndromes are caused by herniation through the tentorial notch (transtentorial herniation), herniation centrally and downward (central herniation), and herniation under the falx cerebri (subfalcine herniation), respectively (Figure 5.18).

Transtentorial Herniation

Transtentorial herniation (or simply, **tentorial herniation**) is herniation of the medial temporal lobe, especially the **uncus** (**uncal herniation**), inferiorly through the tentorial notch (see Figures 5.6, 5.18). Uncal herniation is her-

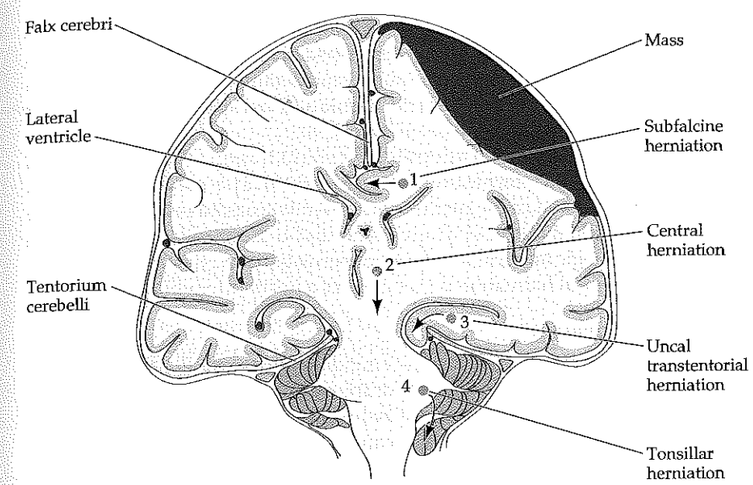

Figure 5.18 Herniation Syndromes Coronal section through brain and skull demonstrating subfalcine herniation (1), central herniation (2), transtentorial herniation (3), and tonsillar herniation (4) resulting from a mass lesion.

alded by the **clinical triad of a "blown" pupil, hemiplegia, and coma.** Compression of the oculomotor nerve (CN III), usually ipsilateral to the lesion, produces first a dilated, unresponsive pupil (a **blown pupil**), and later, impairment of eye movements. Compression of the cerebral peduncles can cause **hemiplegia** (paralysis of half of the body). *In uncal herniation, the dilated pupil is ipsilateral to the lesion in 85% of cases.*

The relationship of the hemiplegia to the side of the lesion is more complicated. Recall that the corticospinal tract crosses to the opposite side as it descends through the medulla into the spinal cord at the pyramidal decussation (see Figure 2.16). Thus, often the hemiplegia is contralateral to the lesion either because of uncal herniation compressing the ipsilateral corticospinal tract in the midbrain, or because of a direct effect of the lesion on the ipsilateral motor cortex, or both. However, sometimes in uncal herniation the midbrain is pushed all the way over until it is compressed by the opposite side of the tentorial notch (see Figure 5.6). In these cases the contralateral corticospinal tract is compressed, producing hemiplegia that is ipsilateral to the lesion. This is called **Kernohan's phenomenon.**

Distortion of the midbrain reticular formation leads to decreased level of consciousness and, ultimately, to **coma** (see KCC 14.2). In addition, the posterior cerebral arteries may be compressed as they pass upward through the tentorial notch (see Figure 5.6). The result can be infarction in the posterior cerebral artery territory (see Figure 10.5). Uncal transtentorial herniation can be unilateral or bilateral and is caused by supratentorial mass lesions. Occasionally, large mass lesions in the posterior fossa can cause *upward* transtentorial herniation.

Central Herniation

Central herniation is central downward displacement of the brainstem (see Figure 5.18). Central herniation can be caused by any lesion associated with elevated intracranial pressure, including hydrocephalus or diffuse cerebral edema. Mild central herniation causes traction on the abducens nerve (CN VI) during its long course over the clivus (see Figures 2.22A, 5.3B, and 13.4), producing lateral rectus palsy (see Table 2.5), which may be unilateral or bilateral. Larger supratentorial masses or elevated intracranial pressure can

produce significant central herniation through the tentorial opening, resulting in bilateral uncal herniation (as described already). With severe elevations in intracranial pressure, large supratentorial mass lesions, or mass lesions in the posterior fossa, central herniation can progress downward through the foramen magnum (see Figure 5.18).

Herniation of the cerebellar tonsils downward through the foramen magnum is called **tonsillar herniation** (see Figure 5.18). This condition is associated with compression of the medulla and usually leads to respiratory arrest, blood pressure instability, and death. Some studies have called into question the pathophysiologic importance of central herniation, and there is controversy over whether central herniation is seen only as a postmortem phenomenon.

Subfalcine Herniation

Unilateral mass lesions can cause the cingulate gyrus (see Figure 2.11B) and other brain structures to herniate under the falx cerebri (see Figure 5.5) from one side of the cranium to the other. The result is **subfalcine herniation** (see Figure 5.18). Usually no clinical signs can be attributed directly to the subfalcine herniation. Sometimes, however, one or both anterior cerebral arteries can be occluded under the falx, leading to infarcts in the anterior cerebral artery territory (see Figures 10.5, 10.6). ■

KEY CLINICAL CONCEPT
HEAD TRAUMA

5.5 Head trauma is, unfortunately, a common cause of morbidity and mortality, especially in the young adult and adolescent population. Mild head trauma causes **concussion,** defined as reversible impairment of neurologic function for minutes to hours following a head injury. The mechanism of concussion is unknown, but it may involve transient diffuse neuronal dysfunction. CT and MRI scans are normal. Clinical features of concussion include loss of consciousness; "seeing stars," followed by headache, dizziness, and occasionally nausea; and vomiting. Some of these features may result from migrainelike phenomena (see KCC 5.1) triggered by head injury. Occasionally, head trauma is accompanied by anterograde and retrograde amnesia (see KCC 18.1) for a period of several hours surrounding the injury. Recovery is usually complete, although occasional patients develop **postconcussive syndrome** even after relatively minor trauma, with headaches, lethargy, mental dullness, and other symptoms lasting up to several months after the accident. Even relatively mild head injuries can occasionally cause dissection of the carotid or vertebral arteries (see KCC 10.6), resulting in transient ischemic attacks or cerebral infarcts.

More severe head trauma can cause permanent injury to the brain through various mechanisms, including **diffuse axonal shear injury,** which causes widespread or patchy damage to the white matter and cranial nerves; **petechial hemorrhages,** or small spots of blood in the white matter; larger **intracranial hemorrhages** (see Figure 5.19; KCC 5.6); **cerebral contusion** (see Figure 5.21); and direct tissue injury by **penetrating trauma** such as gunshot wounds or open skull fracture. **Cerebral edema** may occur as well, with or without other injuries, contributing to elevated intracranial pressure in head injury.

In addition to the neurologic exam, certain signs on general physical examination may provide clues of significant head trauma (see Table 3.9). In all head injuries, the **spine** should be evaluated carefully as well because the same mechanism of injury may cause an unnoticed unstable spinal fracture. Spine X-rays are usually necessary in head injuries, especially when the patient is not fully responsive. Symptoms of intracranial hemorrhage resulting from head injury sometimes occur after a delay of up to several hours following the event (see KCC 5.6). Therefore, all patients with head injury that

causes neurologic deficits, even when transient, should undergo a **CT scan** and should be observed closely for signs of deterioration during the first 24 hours. Patients with more serious head injuries should be treated as discussed in KCC 5.3 and 5.6. ■

KEY CLINICAL CONCEPT
INTRACRANIAL HEMORRHAGE

5.6 Intracranial hemorrhage can be **traumatic** or **atraumatic.** It can occur in several different compartments within the cranial vault (Figure 5.19). Intracranial hemorrhages are classified according to location and are often abbreviated as follows:

1. Epidural hematoma (EDH)
2. Subdural hematoma (SDH)
3. Subarachnoid hemorrhage (SAH)
4. Intracerebral or intraparenchymal hemorrhage (ICH)

Specific traumatic or atraumatic causes are most common in each of these locations, as indicated in the discussion that follows.

Epidural Hematoma

Location: In the tight potential space between the dura and the skull.
Usual cause: **Rupture of the middle meningeal artery** (see Figure 5.7) due to **fracture of the temporal bone** by head trauma.
Clinical features and radiological appearance: Rapidly expanding hemorrhage under arterial pressure peels the dura away from the inner surface of the skull, forming a **lens-shaped biconvex** hematoma that often does not spread past the cranial sutures where the dura is tightly apposed to the skull (see Figure 5.19A). Initially the patient may have no symptoms (**lucid interval**). However, within a few hours the hematoma begins to compress brain tissue, often causing elevated intracranial pressure (see KCC 5.3) and, ultimately, herniation (see KCC 5.4) and death unless treated surgically.

Subdural Hematoma

Location: In the potential space between the dura and the loosely adherent arachnoid.
Usual cause: **Rupture of the bridging veins**, which are particularly vulnerable to shear injury as they cross from the arachnoid into the dura (see Figure 5.1).
Clinical features: Venous blood dissects relatively easily between the dura and the arachnoid, spreading out over a large area and forming a **crescent-shaped** hematoma. Two types of subdural hematoma—chronic and acute—are distinguished by different clinical features.

Chronic Subdural Hematoma

Often seen in elderly patients where atrophy allows the brain to move more freely within the cranial vault, thus making the bridging veins more susceptible to shear injury. This type of hematoma (see Figure 5.19D) may be seen with minimal or no known history of trauma. Oozing slowly, venous blood collects over weeks to months, allowing the brain to accommodate and therefore causing vague symptoms such as headache, cognitive impairment, and unsteady gait. In addition, **focal dysfunction of the underlying cortex may result in focal neurologic deficits.**

Acute Subdural Hematoma

For a significant subdural hematoma to occur immediately after an injury, the impact velocity must be quite high. Therefore, acute subdural hematoma is usually associated with other serious injuries, such as traumatic subarachnoid hemorrhage and brain contusion (to be discussed shortly). The progno-

Figure 5.19 Types of Intracranial Hemorrhage Demonstrated by CT Scans

(A) Epidural hematoma

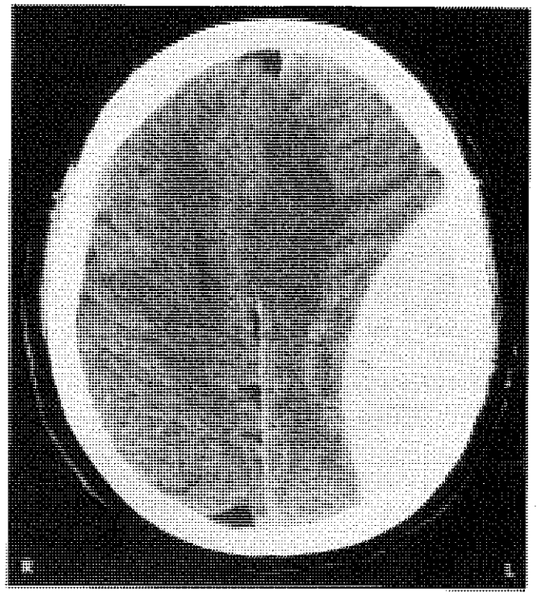

(B) Acute subdural hematoma

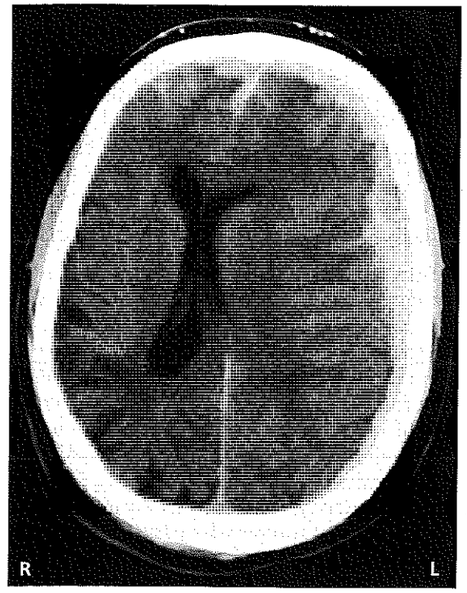

(C) Isodense subdural hematoma

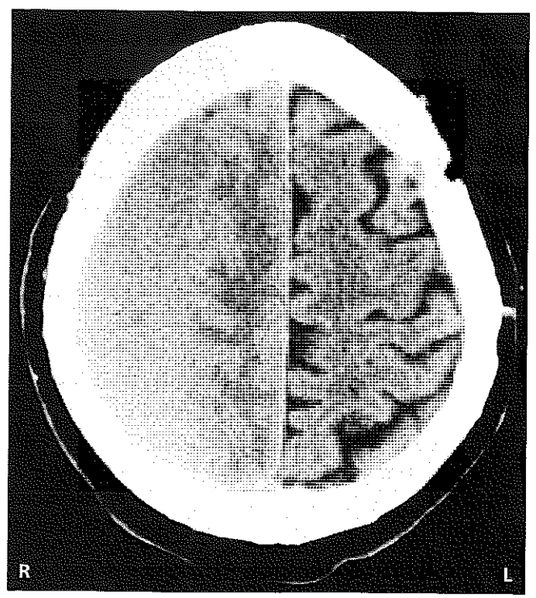

(D) Chronic subdural hematoma

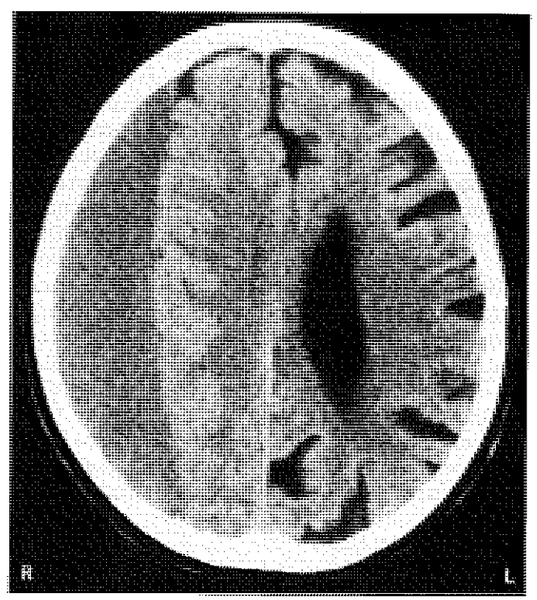

Figure 5.19 (continued)

(E) Hematocrit effect resulting from mixed acute and chronic subdural blood

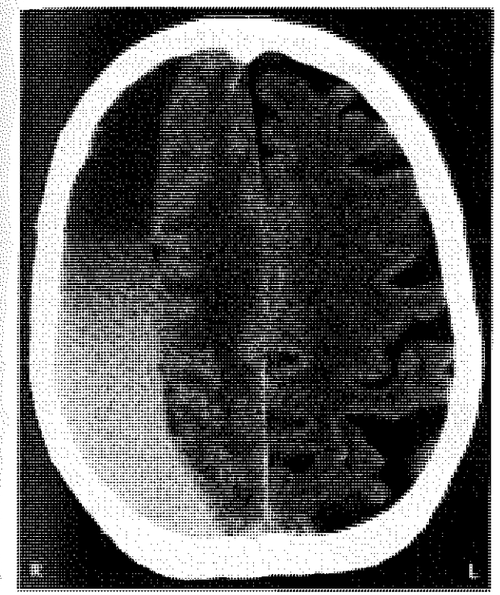

(F) Subarachnoid hemorrhage

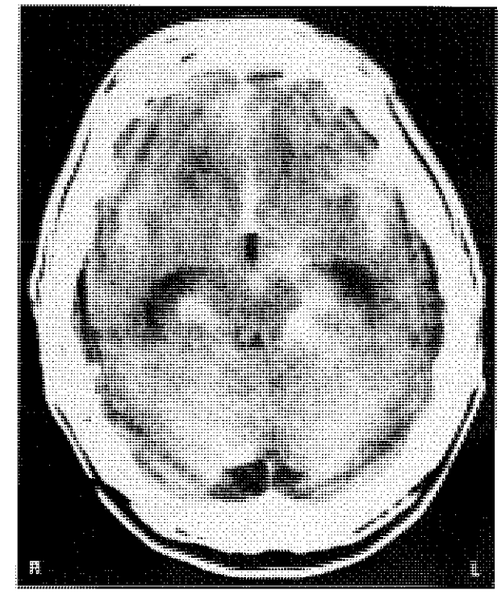

(G) Contusion

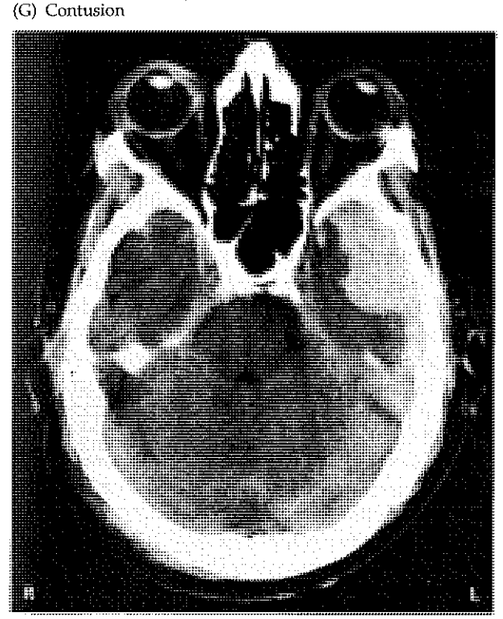

(H) Intraparenchymal (basal ganglia) hemorrhage

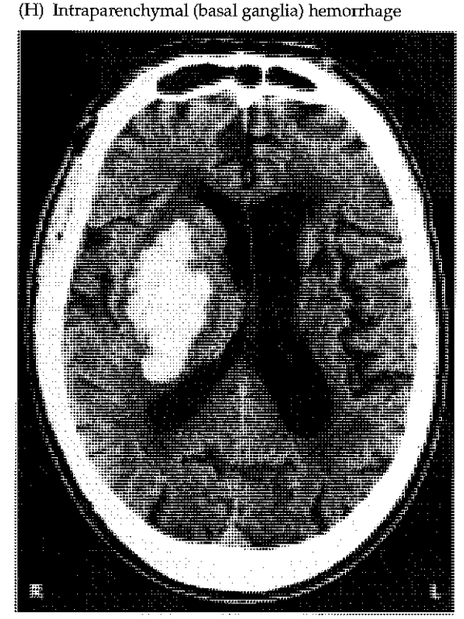

sis is thus usually worse than with chronic subdural hematoma or even epidural hematoma.

Radiological appearance: Subdural hematomas are typically crescent shaped and spread over a large area (see Figures 5.19B–E, H). Density depends on the age of the blood. Recall that acute blood is **hyperdense** (see Figure 5.19B) and therefore bright on CT scan (see Chapter 4). After 1 to 2 weeks the clot begins to liquefy and may appear **isodense** (see Figure 5.19C). If there is no further bleeding, after 3 to 4 weeks the hematoma will be completely liquefied and will appear uniformly **hypodense** (see Figure 5.19D). If there is continued occasional bleeding, however, there will be a **mixed density** appearance resulting from liquefied chronic blood mixed with clotted hyperdense blood. Sometimes, with mixed-density hematomas, the denser acute blood settles to the bottom, giving a characteristic **hematocrit effect** (see Figure 5.19E). Subdural hematoma is treated by surgical evacuation, except for small to moderate-sized chronic subdural hematomas, which, depending on the severity of symptoms, can first be followed clinically because some will resolve spontaneously.

Subarachnoid Hemorrhage

Location: In the CSF-filled space between the arachnoid and the pia, which contains the major blood vessels of the brain (see Figure 5.1).

Radiological appearance: Unlike subdural hematoma, blood can be seen on CT to track down into the sulci following the contours of the pia (see Figure 5.19F).

Usual cause: Subarachnoid hemorrhage is seen in two clinical settings: nontraumatic (spontaneous) and traumatic.

Nontraumatic (Spontaneous) Subarachnoid Hemorrhage

Spontaneous subarachnoid hemorrhage usually presents with a sudden catastrophic headache. Patients may describe this as the **"worst headache of my life"** or as feeling like the head is suddenly about to explode. In the vast majority of cases (75–80%), spontaneous subarachnoid hemorrhage occurs as a result of rupture of an arterial **aneurysm** in the subarachnoid space. Less often (4–5% of cases) it results from bleeding of an **arteriovenous malformation** and from other rarer or unknown causes. Risk factors for intracranial aneurysm include atherosclerotic disease, congenital anomalies in cerebral blood vessels, polycystic kidney disease, and connective tissue disorders such as Marfan's syndrome.

Saccular, or **berry, aneurysms** usually arise from arterial branch points near the circle of Willis (Figure 5.20). These are balloonlike outpouchings of the vessel wall that typically have a **neck** connecting it to the parent vessel and a fragile **dome** that can rupture. Over 85% occur in the anterior circulation (carotid artery and its branches). The most common locations, listed in descending order, are the anterior communicating artery (**AComm,** about **30%**), posterior communicating artery (**PComm,** about **25%**), and middle cerebral artery (**MCA,** about **20%**). Saccular aneurysms can also occur in the branches of the posterior circulation (**vertebrobasilar system,** about **15%**). Occasionally the main vessel itself becomes dilated, forming a **fusiform aneurysm** (see Figure 5.20), which is less prone to rupture than saccular aneurysms. Aside from symptoms caused by rupture, large unruptured aneurysms can occasionally present with symptoms due to mass effect or the compression of adjacent structures. An important example is **PComm aneurysm** arising from the internal carotid artery (see Figure 5.20), which can cause a **painful third-nerve palsy** (see Figures 5.6, 13.2; KCC 13.2). The PComm junction with the posterior cerebral artery can also give rise to aneurysms, but much less commonly than the PComm junction with the carotid.

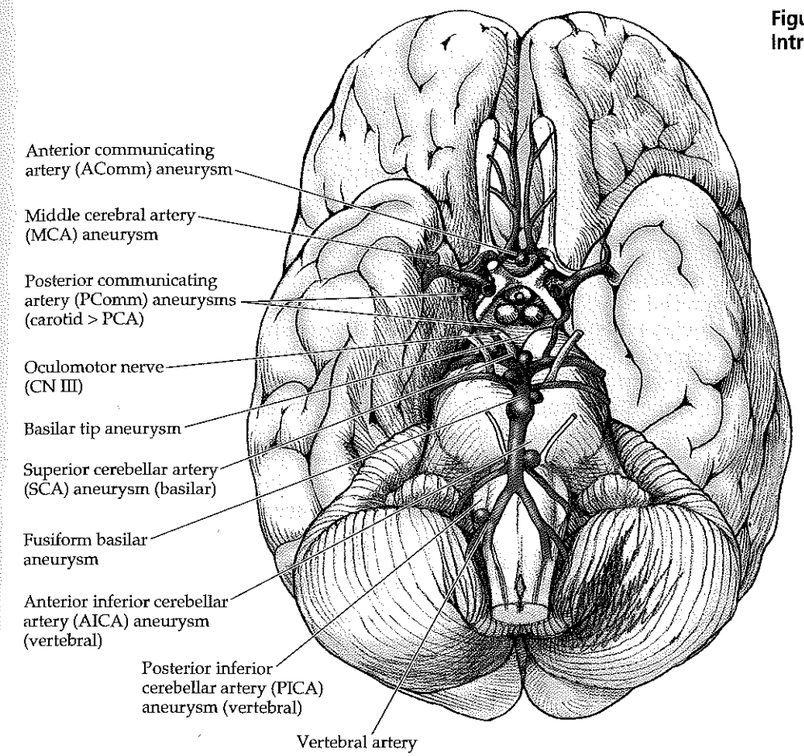

Figure 5.20 Common Sites of Intracranial Aneurysms

Risk factors for aneurysmal rupture include hypertension, cigarette smoking, alcohol consumption, and situations causing sudden elevation in blood pressure. The clinical effects of subarachnoid hemorrhage can range from headache and meningeal irritation (Table 5.5), causing nuchal rigidity and photophobia, to cranial nerve and other focal neurologic deficits, to impaired consciousness, coma, and death. Perhaps 25% of all patients with subarachnoid hemorrhage die in the immediate aftermath of the event and thus never reach the hospital for treatment. The overall mortality of subarachnoid hemorrhage is about 50%; however, the prognosis is better in mild cases. In subarachnoid hemorrhage due to ruptured aneurysm, the risk of rebleeding is 4% on the first day and 20% in the first 2 weeks. Therefore, prompt diagnosis and early treatment of aneurysmal subarachnoid hemorrhage is essential.

TABLE 5.5 Signs and Symptoms of Meningeal Irritation

Headache
Lethargy
Sensitivity to light (photophobia) and noise (phonophobia)
Fever
Nuchal rigidity (stiff neck): unable to touch chin to chest
Kernig's sign: pain in hamstrings when knees are straightened with hips flexed
Brudzinski's sign: flexion at neck causes hips to flex

CT scan performed within the first 3 days after rupture can detect the hemorrhage in over 95% of cases. It is important to perform a **CT scan without contrast** because both subarachnoid blood and contrast material appear white on the scan (see Figures 4.4, 5.19F), making it difficult to see a small hemorrhage. CT is better than MRI for detecting acute subarachnoid hemorrhage, although after about 2 days subarachnoid hemorrhage may no longer be visible on CT (see Chapter 4). **Lumbar puncture** (see KCC 5.10) should be performed in suspected subarachnoid hemorrhage with a negative CT, but not with a positive CT because increased transmural pressure across the aneurysm can occasionally precipitate rebleeding.

An **angiogram** (see Chapter 4) is next performed to define the exact location and size of the aneurysm. A four-vessel angiogram (both carotids and both vertebrals) should be performed since multiple aneurysms are often seen in different vessels. In mild subarachnoid hemorrhage, most neurosurgeons now prefer to operate as soon as possible, placing a clip across the neck of the aneurysm to prevent a second potentially cataclysmic event. The more traditional approach was to wait 1 to 2 weeks and then to perform surgery (if the patient survived), with a somewhat lower risk of intraoperative rebleeding.

Following subarachnoid hemorrhage, delayed **cerebral vasospasm** occurs in about half of all patients, with a peak severity about 1 week after the hemorrhage. This can lead to cerebral ischemia or infarction. Vasospasm is often treated with volume expansion and induced hypertension in the intensive care unit. Such treatment can be done safely after the aneurysm has been clipped, which is another reason that early surgery is preferred. Administration of calcium channel blockers such as nimodipine early after the hemorrhage can also improve the outcome, although the mechanism is uncertain because calcium channel blockers do not improve vasospasm angiographically.

Traumatic Subarachnoid Hemorrhage

Traumatic subarachnoid hemorrhage, which is caused by bleeding into the CSF from damaged blood vessels associated with cerebral contusions and other traumatic injuries, is actually more common than spontaneous subarachnoid hemorrhage. Like spontaneous subarachnoid hemorrhage, it is usually associated with severe headache due to meningeal irritation from blood in the CSF. Deficits are usually related to the presence of other cerebral injuries. Unlike aneurysmal subarachnoid hemorrhage, vasospasm is not usually seen.

Intracerebral or Intraparenchymal Hemorrhage

Location: Within the brain parenchyma in the cerebral hemispheres, brainstem, cerebellum, or spinal cord.
Usual cause: Once again, this type of hemorrhage may be traumatic or nontraumatic.

Traumatic Intracerebral or Intraparenchymal Hemorrhage

Contusions of the cerebral hemispheres occur in regions where cortical gyri abut the ridges of the bony skull (Figure 5.21; see also Figures 5.2, 5.4). Thus, contusions are most common at the temporal and frontal poles (see Figure 5.19G). Interestingly, they are less common at the occipital poles. Contusions occur on the side of the impact (**coup injury**) as well as on the side opposite the impact (**contrecoup injury**) because of rebound of the brain against the skull. Shearing forces can produce areas of bleeding in the white matter as well, including small petechial or larger confluent intraparenchymal hemorrhage. Severe injuries often are accompanied by a combination of contusion,

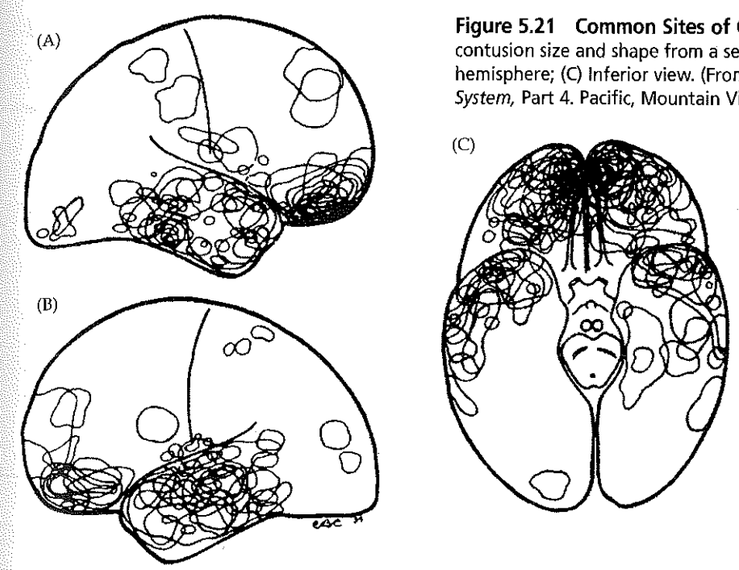

Figure 5.21 Common Sites of Cerebral Contusion Composite drawings of contusion size and shape from a series of 40 cases. (A) Right hemisphere; (B) Left hemisphere; (C) Inferior view. (From Courville CB. 1937. *Pathology of the Nervous System,* Part 4. Pacific, Mountain View, CA.)

subarachnoid hemorrhage, and subdural hemorrhage. When a combination of intraparenchymal, subarachnoid, and acute subdural hemorrhage is seen on CT scan, head trauma can be assumed.

Nontraumatic Intracerebral or Intraparenchymal Hemorrhage

There are many different **causes of intraparenchymal hemorrhage,** including hypertension, brain tumors, secondary hemorrhage after ischemic infarction, vascular malformations, blood coagulation abnormalities, infections, vessel fragility caused by deposition of amyloid protein in the blood vessel wall (amyloid angiopathy), vasculitis, mycotic (infectious) aneurysms in the setting of endocarditis, and so on.

Hypertensive hemorrhage is the most common cause, and it tends to involve small penetrating blood vessels (see Figure 5.19H). The pathogenesis is uncertain, but it may be related to chronic pathologic effects of hypertension on the small vessels, such as the lenticulostriate arteries (see Figure s 4.16B, 10.7), including **lipohyalinosis** and **microaneurysms of Charcot–Bouchard.** The **most common locations** for hypertensive hemorrhage, in decreasing order of frequency, are the **basal ganglia** (usually the putamen), **thalamus, cerebellum,** and **pons.** Some hemorrhages may involve the ventricles, either by extending from adjacent parenchyma or by arising from blood vessels in the ventricles themselves. These are described as **intraventricular extension** of an intraparenchymal hemorrhage or as **intraventricular hemorrhage,** respectively. Unlike aneurysmal hemorrhage, the rebleeding rate for hypertensive hemorrhage is low, although the hematoma often continues to enlarge, causing worsening clinical status for several hours after onset. **Edema** also gradually develops in the tissue surrounding the hemorrhage, causing a slow clinical worsening that reaches its peak about 3 days after onset.

In **lobar hemorrhage,** bleeding involves the occipital, parietal, temporal, or frontal lobe. The most common cause of lobar hemorrhage is probably **amyloid** (congophilic) **angiopathy.** In this condition, deposits of amyloid in the vessel wall of older patients (usually >50 years old) cause vascular fragility. Unlike hypertensive hemorrhage, in amyloid angiopathy the hemorrhages tend to be recurrent or multiple, and they are often more superficial in

location. Transient symptoms resembling transient ischemic attack (see KCC 10.3) or seizures can occur in amyloid angiopathy for weeks or months preceding hemorrhage. Lobar hemorrhage can also be seen in hypertension.

Certain **vascular malformations** are another important cause of intracranial hemorrhage. Vascular malformations are classified as:

1. Arteriovenous malformations
2. Cavernous malformations (sometimes called cavernous angiomas, cavernous hemangiomas, or cavernomas)
3. Capillary telangiectasias (capillary angiomas)
4. Venous angiomas (venous malformations, deep venous anomalies).

Of these, only arteriovenous and cavernous malformations have a high likelihood of causing intracranial hemorrhage.

Arteriovenous malformations (AVMs) are congenital abnormalities in which there are abnormal direct connections between arteries and veins, often forming a tangle of abnormal blood vessels visible as flow voids on MRI scan, but best seen on conventional angiography (see Figures 11.25, 11.26). Size can range from a few centimeters to half the brain. Aside from sudden severe symptoms from intracranial hemorrhage, patients also commonly present with seizures, or with migrainelike headaches in the absence of hemorrhage. Hemorrhage is usually intraparenchymal, but it can extend to the intraventricular or subarachnoid space as well. The risk of rebleeding is about 1% to 4% per year, much lower than in aneurysmal hemorrhage (discussed earlier). Treatments for AVM, which depend on clinical status, size, and location of the lesions, include neurosurgical removal, intravascular embolization, and stereotactic radiosurgery (see KCC 16.4).

Cavernous malformations are abnormally dilated vascular cavities lined by only one layer of vascular endothelium. They are not visible on conventional angiography, but with the advent of MRI the diagnosis of cavernous malformations has increased dramatically. They have a characteristic MRI appearance, with a central 1 to 2 cm core of increased signal on T1 or T2, surrounded by a dark rim on T2-weighted sequences because of the presence of hemosiderin (see Table 4.4). Some patients have multiple cavernous malformations, and a familial autosomal dominant form of this disorder exists. Patients often present with seizures. Risk of hemorrhage is between 0.1% and 2.7% per lesion per year, but the risk of hemorrhage increases after an initial bleed. Although still evolving, clinical criteria for operating on cavernous angiomas often include clinically significant hemorrhage or seizures, and favorable operative location.

Capillary telangiectasias are small regions of abnormally dilated capillaries that rarely give rise to intracranial hemorrhage. **Venous angiomas** are dilated veins visible on MRI scans as a single flow void extending to the brain surface. They are usually an incidental finding on MRI and are not known to cause any clinical symptoms themselves, but they can sometimes be seen in association with cavernous malformations.

Extracranial Hemorrhage

Head trauma can also cause hemorrhage in the inner ear, called hemotympanum; hemorrhage in subcutaneous tissues, resulting in Battle's sign; or raccoon eyes (see Table 3.9). Scalp hemorrhage can cause profuse bleeding. Hemorrhage in the loose space between the external periosteum and galea aponeurotica (see Figure 5.1) can produce a "goose egg," or **subgaleal hemorrhage.** In newborns, bleeding during delivery can occur between the skull and external periosteum (pericranium), called a **cephalohematoma,** which can occasionally be quite large. ■

KEY CLINICAL CONCEPT
HYDROCEPHALUS

Hydrocephalus (meaning "water in the head") is caused by excess CSF in the intracranial cavity. This condition can result from (1) excess CSF production, (2) obstruction of flow at any point in the ventricles or subarachnoid space, or (3) decrease in reabsorption via the arachnoid granulations.

Excess CSF production is quite rare as a cause of hydrocephalus; it is seen only in certain tumors, such as choroid plexus papilloma. **Obstruction of CSF flow** is a common cause of hydrocephalus and can be produced by obstruction of the ventricular system by tumors, intraparenchymal hemorrhage, other masses, and congenital malformations. This can occur anywhere along the path of CSF flow (see Figures 5.10, 5.11), but especially at narrow points such as the foramen of Monro, the cerebral aqueduct, or the fourth ventricle. Obstruction can also occur outside the ventricles in the subarachnoid space as a result of debri or adhesions from prior hemorrhage, infection, or inflammation. **Decreased CSF reabsorption** can cause hydrocephalus when the arachnoid granulations are damaged or clogged. Decreased reabsorption at the arachnoid granulations is difficult to distinguish clinically from obstruction of CSF flow in the subarachnoid space, and often has similar causes (i.e., prior hemorrhage, infection, inflammation, etc.). For this reason, in clinical practice, hydrocephalus is often divided into two categories:

1. **Communicating hydrocephalus** is caused by impaired CSF reabsorption in the arachnoid granulations, obstruction of flow in the subarachnoid space, or (rarely) by excess CSF production.
2. **Noncommunicating hydrocephalus** is caused by obstruction of flow within the ventricular system.

The main symptoms and signs of hydrocephalus are similar to those of any other cause of elevated intracranial pressure (see KCC 5.2, 5.3) and can be acute or chronic, depending on how quickly the hydrocephalus develops. These symptoms and signs include headache, nausea, vomiting, cognitive impairment, decreased level of consciousness, papilledema, decreased vision, and sixth-nerve palsies. In addition, ventricular dilation in hydrocephalus may compress descending white matter pathways from the frontal lobes, leading to frontal lobe–like abnormalities including an unsteady **magnetic gait** (feet barely leave the floor) and incontinence. In neonatal hydrocephalus when the cranial sutures have not yet fused, the skull expands to reduce elevated intracranial pressure, resulting in increased head circumference. A bulging anterior fontanelle is also an important sign of elevated intracranial pressure in infants.

It is important to recognize the eye movement abnormalities associated with hydrocephalus. In mild or slowly developing cases, only a sixth-nerve palsy may be seen, which causes incomplete or slow abduction of the eye in the horizontal direction. Interestingly, hydrocephalus may affect the sixth nerve of one or both eyes. When hydrocephalus is more severe, inward deviation of one or both eyes may be present at rest. Also, in more severe or rapidly developing cases, dilation of the **suprapineal recess** (see Figure 5.11D) of the posterior third ventricle can push downward onto the collicular plate of the midbrain, producing **Parinaud's syndrome.** This syndrome is described in greater detail in Chapter 13 (see KCC 13.9); however, the important abnormality to be aware of for now is limited vertical gaze, especially in the upward direction. Therefore, particularly in children with acute hydrocephalus, the ominous "setting sun" sign, consisting of bilateral deviation of the eyes downward and inward, may be seen. These abnormalities often reverse after treatment.

Treatment of hydrocephalus usually involves a procedure that allows cerebrospinal fluid to bypass the obstruction and drain from the ventricles. In an

external ventricular drain (also called ventriculostomy), the fluid from the lateral ventricles is drained into a bag outside of the head. A more permanent treatment is a **ventriculoperitoneal shunt,** in which the shunt tubing passes from the lateral ventricle out of the skull and is then tunneled under the skin to drain into the peritoneal cavity of the abdomen. A valve prevents flow of fluid in the reverse direction, from abdomen to ventricle. **Third ventriculostomy** has recently been gaining in popularity for treating hydrocephalus. In this procedure an endoscope is passed through the right frontal lobe into the frontal horn of the right lateral ventricle and through the foramen of Monro into the third ventricle. A blunt-tipped instrument is then used to make a perforation in the floor of the third ventricle just in front of the mamillary bodies, allowing CSF to drain into the interpeduncular cistern (see Figure 5.12).

In closing, two other forms of hydrocephalus should be mentioned. **Normal-pressure hydrocephalus** is a condition sometimes seen in elderly individuals that is characterized by chronically dilated ventricles. Patients with normal-pressure hydrocephalus typically present with the **clinical triad of gait difficulties, urinary incontinence, and mental decline.** Measurements of CSF pressure in normal-pressure hydrocephalus are usually not elevated; however, some studies have shown pressure elevations to occur only intermittently. Although the exact mechanism is not known, normal-pressure hydrocephalus is thought to be a form of communicating hydrocephalus with impaired CSF reabsorption at the arachnoid villi. Some cases improve dramatically after lumbar puncture or ventriculoperitoneal shunting.

Hydrocephalus ex vacuo is simply a descriptive term and is not itself responsible for any pathology. It refers to excess cerebrospinal fluid in a region where brain tissue was lost as a result of stroke, surgery, atrophy, trauma, or other insult. ■

KEY CLINICAL CONCEPT
BRAIN TUMORS

5.8 There are two broad categories of brain tumors. **Primary CNS tumors** arise from abnormal proliferation of cells originating in the nervous system. **Metastatic tumors** arise from neoplasms originating elsewhere in the body that spread to the brain. Common brain tumors in adults are shown in Table 5.6. The two most common brain tumors are glioblastoma and brain metastases, of which the more common varies from series to series depending on the methodology used to select patients. In some series, particularly those based on postmortem pathology, metastases are 5 to 8 times more common than all primary CNS tumors combined. The next most common brain tumor is meningioma, followed by astrocytoma, pituitary adenoma, schwannoma, and ependymoma.

In adults, about 70% of tumors are supratentorial and 30% are infratentorial, while in pediatric patients the reverse is true, with about 70% of tumors located in the posterior fossa and 30% supratentorially. The most common brain tumors in children are astrocytoma and medulloblastoma, followed by ependymoma. Since pediatric brain tumors are often in the posterior fossa, they tend to cause hydrocephalus (see KCC 5.7) through compression and obstruction of the fourth ventricle or aqueduct of Sylvius.

Symptoms of brain tumors depend on the location, size, and rate of growth of the tumor. Headache and other signs of elevated intracranial pressure (see Table 5.3) are common at presentation. Some tumors may present with seizures, or with focal symptoms and signs depending on the location of the tumor. The tumors most commonly associated with seizures are oligodendrogliomas and meningiomas.

Brain tumors are considered benign if they do not infiltrate or disseminate widely through the nervous system and maliguant if they have the potential to spread. Unlike systemic malignancies, however, malignant brain tumors only rarely undergo metastatic spread outside of the central nervous system. In addition, so-called benign brain tumors may be incurable, and ultimately fatal if they grow in vital areas of the brain where surgical excision is not possible.

Treatments for brain tumors depend on the histological type, location, and size of the tumor. Surgical removal of as much tumor as possible without causing serious deficits is usually pursued. Recent data suggest that the extent of surgical resection should be greater than 90% to have a positive effect on outcome. Next, depending on the lesion, **radiation therapy** and/or **chemotherapy** may be beneficial. **Steroids** are often used to reduce edema and swelling. Small, benign-looking tumors may simply be followed with serial MRI scans, depending on the clinical situation, especially in elderly patients.

Gliomas are subdivided into several different types (see Table 5.6). Glial tumors arising from astrocytes are called **astrocytomas.** Gliomas are usually classified by the Daumas–Dupont (St. Anne-Mayo) grading system, in which the most malignant is grade IV/IV, or **glioblastoma multiforme.** Unfortunately, glioblastoma is relatively common and usually leads to death within 1 year despite maximal resection, radiation, and chemotherapy.

Meningiomas arise from the arachnoid villus cells and occur, in order of decreasing frequency, over the lateral convexities, in the falx, and along the basal regions of the cranium. They grow quite slowly and appear on CT and MRI scans as homogeneous enhancing areas that arise from the meningeal layers. In female patients, meningiomas are associated with breast cancer. Meningiomas are treated by local excision. Five percent of meningiomas behave in an atypical or malignant fashion.

Pituitary adenomas can cause endocrine disturbances or compress the optic chiasm, usually resulting in a bitemporal visual field defect (see Figure 11.15C). Other lesions can arise in this area as well (including meningioma, craniopharyngioma, hypothalamic glioma, and others). Pituitary adenomas are discussed further in Chapter 17 (see KCC 17.1). Treatment with dopaminergic agonists often will shrink pituitary adenomas. If this is ineffective, transsphenoidal resection is performed (see KCC 17.1).

Schwannomas, which are most common on CN VIII, are discussed in Chapter 12 (see KCC 12.5).

Lymphoma of the central nervous system has been on the rise in recent years, only in part attributable to the increase in human immunodeficiency virus (HIV). This neoplasm arises from B lymphocytes and commonly involves regions adjacent to ventricles. It can often be controlled for several years with chemotherapy and radiation therapy and currently has a median survival rate of close to four years.

Pineal region tumors are relatively uncommon (less than 1% of CNS neoplasms) and include pinealomas (pineocytoma and pineoblastoma), germinoma, and rarely teratoma or glioma. Tumors in this region may obstruct the cerebral aqueduct, causing hydrocephalus (see KCC 5.7), or may compress the dorsal midbrain, causing Parinaud's syndrome (see KCC 13.9).

Brain metastases can occur with numerous tumor types. The most common are carcinomas of the lung, breast, kidneys, and gastrointestinal tract, and melanoma. Some brain metastases have a tendency to hemorrhage, including melanoma, renal cell carcinoma, thyroid carcinoma, and choriocarcinoma. Although lung cancer metastases do not often hemorrhage, the most common tumor-causing brain hemorrhage is lung cancer, simply because the incidence of lung cancer and metastases to the brain is so

TABLE 5.6 Intracranial Neoplasms in Adults

TYPE OF TUMOR	PERCENT OF TOTAL
Glioma	40
Glioblastoma multiforme	20
Astrocytoma grades I and II	10
Ependymoma	6
Medulloblastoma	2
Oligodendroglioma	1
Choroid plexus papilloma	1
Metastases	23
Meningioma	17
Pituitary adenoma	5
Schwannoma	5
Lymphoma	3
Miscellaneous (congenital tumors, PNETs[a])	7

[a]PNETs = primitive neuroectodermal tumors.

Source: Hochberg F, Pruitt A. Neoplastic diseases of the central nervous system. In Isselbacher ICJ, Braunwald E, Wilson JD, Martin JB, Fauci AS, Kasper DL (eds.). *Harrison's Principles of Internal Medicine,* 13th Ed, Chapter 369. McGraw-Hill, New York.

high. When solitary (or even two to three circumscribed) brain metastases occur, outcome is improved by complete surgical excision, when possible. Multiple or unresectable brain metastases are treated with radiation therapy.

In pediatric patients, the most common brain tumors are posterior fossa astrocytoma, medulloblastoma, and ependymoma. **Cerebellar astrocytoma** is a type of grade I/IV astrocytoma that can often be cured by surgical resection. **Medulloblastoma** and **ependymoma** of the posterior fossa have worse prognoses, although long-term survivors do occur following a combination of surgery, radiation, and chemotherapy. Medulloblastoma occurs before age 10 about 90% of the time, while it is less common for cerebellar astrocytoma to occur after age 10.

Paraneoplastic syndromes are relatively rare neurologic disorders caused by remote effects of cancer in the body, thought to result from autoimmune mechanisms. Examples of paraneoplastic syndromes include limbic or brainstem encephalitis, cerebellar Purkinje cell loss, spinal cord anterior horn cell loss, neuropathy, impaired neuromuscular transmission (Lambert–Eaton syndrome), and opsoclonus myoclonus, which is characterized by irregular jerking movements of the eyes and limbs. Tumors that most often cause paraneoplastic syndromes include small cell lung carcinoma, breast cancer, and ovarian cancer. ■

KEY CLINICAL CONCEPT

INFECTIOUS DISORDERS OF THE NERVOUS SYSTEM

5.9 Like all other parts of the body, the nervous system can be affected by a variety of infectious pathogens, including bacteria, viruses, parasites, fungi, and prions. In this section we will briefly review the diagnosis and treatment of common infections of the nervous system.

Bacterial Infections

Infections Caused by Cocci and Bacilli. Important bacterial infections of the nervous system caused by cocci and bacilli include bacterial meningitis, brain abscess, and epidural abscess. Bacteria most often gain access to the nervous system through the bloodstream, and they frequently originate from an infection elsewhere in the body, such as the respiratory tract or heart valves (endocarditis). In addition, infections can spread by direct extension from the oronasal passages. Finally, trauma or surgery can introduce bacteria into the nervous system from the skin.

Infectious meningitis is an infection of the cerebrospinal fluid in the subarachnoid space. It can be caused by bacteria, viruses, fungi, or parasites. Except for in elderly, very young, or immunocompromised patients, infectious meningitis is usually heralded by marked signs and symptoms of **meningeal irritation,** or **meningismus** (see Table 5.5). These **meningeal signs** can also be seen in subarachnoid hemorrhage, carcinomatous meningitis, and chemical meningitis. Common features of meningeal irritation include headache, lethargy, sensitivity to light (photophobia) and noise (phonophobia), fever, and nuchal rigidity. In **nuchal rigidity** the neck muscles contract involuntarily, resulting in resistance to active or passive neck flexion, accompanied by neck pain.

Depending on the cause of meningeal irritation, onset of symptoms may be gradual, over weeks to months in the case of some fungal or parasitic infections, or symptoms may progress rapidly, within hours in the case of many bacterial infections. Diagnosis is made by clinical evaluation, and by **sampling of cerebrospinal fluid by lumbar puncture** (see KCC 5.10; Table 5.7). A head CT should usually be performed before lumbar puncture is considered because removal of CSF in the presence of a mass lesion can occasionally precipitate herniation. However, *antibacterial therapy should not be delayed* while these procedures are performed, since bacterial meningitis can be rapidly fatal if left untreated. A single dose of intravenous antibiotics prior to CT and lumbar puncture may not reduce diagnostic yield, particularly now that bacterial antigen and PCR (polymerase chain reaction) analysis of CSF is available. We will discuss bacterial meningitis in this section, and meningitis caused by other pathogens (see Tables 5.7, 5.9) in the sections that follow.

TABLE 5.7 Cerebrospinal Fluid Profiles in Normal Adults and in Those with Infectious Meningitis

CONDITION	WHITE BLOOD CELLS (per mm³)	PROTEIN (mg/dl)	GLUCOSE (mg/dl)	COMMENTS
Normal (adults)	<10, lymphocytes only	15–45	50–100	If traumatic lumbar puncture,[a] expect 1 additional white blood cell for every ~700 red blood cells.
Acute bacterial meningitis	100–5000, usually polymorphonuclear leukocytes	100–1000	Reduced, <40	In patients with hyperglycemia, CSF glucose is abnormal if <50% of serum glucose.
Viral meningitis or "aseptic" meningitis (see Table 5.9)	10–300, usually lymphocytes	50–100	Normal	Glucose is occasionally reduced in herpes, mumps, and lymphocytic choriomeningitis virus.
Herpes meningoencephalitis	0–500, usually lymphocytes	50–100	Normal or reduced	Red blood cells or xanthochromia may be present.
Tuberculous meningitis or cryptococcal meningitis	10–200, usually lymphocytes	100–200	Reduced, <50	

[a] See also KCC 5.10 for discussion of lumbar puncture technique and interpretation of red blood cell count in CSF.

In acute **bacterial meningitis,** cerebrospinal fluid typically has a high white blood cell count with a polymorphonuclear predominance, high protein, and low glucose (see Table 5.7). Bacteria can sometimes be identified microscopically by Gram stain, bacterial antigen tests, PCR analysis, or cultures of CSF. The most common pathogens in bacterial meningitis depend on the patient's age (Table 5.8). Treatment, therefore, also depends on age, as shown in Table 5.8. Note that antibiotic therapy is constantly evolving, and current recommendations at the local institution should always be checked. It is essential to begin treatment as rapidly as possible in cases of suspected bacterial meningitis because these patients can deteriorate very quickly. Therapy should not be postponed during patient transport, or while awaiting the results or performance of diagnostic tests. Complications of bacterial meningitis include seizures, cranial neuropathies, cerebral edema, hydrocephalus, herniation, cerebral infarcts, and death.

Brain abscess is another important bacterial infection of the nervous system. Brain abscess presents as an expanding intracranial mass lesion, much like a brain tumor, but often with a more rapid course. Common presenting features include headache, lethargy, fever, nuchal rigidity, nausea, vomiting, seizures, and focal signs determined by the location of the abscess. Of note, fever is absent in about 40% of cases, and peripheral white blood cell count is not elevated in about 20% of cases, making the diagnosis of infection more difficult. The ESR (erythrocyte sedimentation rate) is usually elevated. Common infecting organisms include streptococci, *Bacteroides*, enterobacteriaceae, *Staphylococcus aureus*, and rarely, *Nocardia*. More than one organism is often present. Patients who are clinically stable and have abscesses less than about 2.5 cm in diameter can be treated with antibiotics (ceftriaxone plus metronidazole) and careful observation. Patients with larger abscesses (at risk for catastrophic rupture), or with clinical signs of

TABLE 5.8 Bacterial Meningitis: Common Pathogens and Treatment Based on Age

	BIRTH–1 MONTH	1–3 MONTHS	3 MONTHS–7 YEARS	7 YEARS–ADULT
Pathogens				
Escherichia coli	■			
Group B, D *Streptococcus*	■			
Listeria	■			■
Haemophilus influenzae		■	■	
Neisseria meningitidis		■	■	■
Streptococcus pneumoniae		■	■	■
Treatment[a]	Ampicillin + ceftriaxone	Ampicillin + ceftriaxone	Ceftriaxone	Ampicillin + ceftriaxone

[a](1) There is some evidence that treatment of adult patients with *S. pneumonaie* meningitis and of pediatric patients at risk for *H. influenzae* meningitis with dexamethasone prior to antibiotics may improve outcome. Vaccination has markedly decreased the incid ence of *H. influenzae* in recent years.

(2) Close household contacts of patients with *N. meningitidis* or *H. influenzae* meningitis should be treated prophylactically with oral rifampin.

(3) Patients who are elderly or immunocompromised, or who have had head trauma or neurosurgery, are also susceptible to *E. coli, Klebsiella, Pseudomonas, Staph. aureus, Staph. epidermidis,* and others. Therefore, additional antibiotics are often used in these populations.

(4) If herpes simplex meningoencephalitis is suspected, acyclovir should be added.

mass effect or progressive deterioration, should be treated with stereotactic needle aspiration (see KCC 16.4), as well as antibiotics. Another important cause of brain abscess other than bacteria is the parasite *Toxoplasma gondii,* discussed along with HIV later in this section.

Epidural abscess can occasionally occur, especially in the spinal canal, and requires prompt diagnosis and treatment. Common presenting features include back pain, fever, elevated peripheral white blood cell count, headache, and signs of nerve root or spinal cord compression. An emergency MRI scan should be performed when epidural abscess is suspected so that treatment can be initiated before spinal cord compression, paraparesis, and urinary and fecal incontinence occur. Epidural abscess is treated with surgical drainage and antibiotics (nafcillin and ceftriaxone). Early cases without progressive deterioration may be treatable with antibiotics alone. Common organisms are *Staphylococcus aureus,* streptococci, Gram-negative bacilli, and anaerobes. **Subdural empyema** is a collection of pus in the subdural space, usually resulting from direct extension from an infection of the nasal sinuses or inner ear. This condition is treated by urgent surgical drainage and antibiotics (ceftriaxone plus metronidazole).

In recent years, with the resurgence of tuberculosis in several urban centers in the United States, **tuberculous meningitis** has become more common as well. Headache, lethargy, and meningeal signs (see Table 5.5) usually appear over the course of several weeks. There is often an inflammatory response in the basal cisterns of the brain, which can affect the circle of Willis vessels, resulting in infarcts. If untreated, coma, hydrocephalus, and death ensue. Tuberculous involvement of the epidural space and vertebral bones can also occur, called Pott's disease. Populations at risk are intravenous drug abusers, patients with HIV, and people from areas where tuberculosis is endemic.

The meningeal involvement results from reactivation of previous tuberculosis infection, and signs of pulmonary tuberculosis are often not present at the time of presentation. Cerebrospinal fluid shows an elevated white

blood cell count with lymphocyte predominance (see Table 5.7), elevated protein, and low glucose. Early on, there may be a polymorphonuclear predominance. The *Mycobacterium tuberculosis* organisms that cause this infection are often not visible microscopically in the CSF. The diagnosis can be confirmed by culture, which takes several weeks, or more recently, by polymerase chain reaction (PCR). Tuberculous meningitis is treated with a combination of isoniazid, rifampin, ethambutol, and pyrazinamide.

As we will see in the sections that follow, **lymphocyte-predominant meningitis,** or "aseptic meningitis," can have numerous other causes in addition to tuberculosis (Table 5.9), but it is most commonly viral in origin.

Infections Caused by Spirochetes. The two most important spirochetal infections of the nervous system are neurosyphilis and Lyme disease. **Neurosyphilis** was fairly common in the pre-penicillin era and has had a resurgence in recent years, possibly related to HIV. Syphilis, formerly called lues, is caused by the spirochete *Treponema pallidum.* It is transmitted sexually and has various stages that occur at different times after primary infection. In primary syphilis, painless skin lesions called chancres appear at the site of infection, about 1 month after exposure. In secondary syphilis, more diffuse skin lesions appear within approximately 6 months, characteristically including the palms and soles. In tertiary syphilis, neurologic manifestations are often present.

Meningeal involvement can cause **aseptic meningitis** (see Table 5.9), sometimes with associated cranial nerve palsies, especially involving the optic, facial, and vestibulocochlear nerves. Later stages of neurologic involvement can occur following a latency of about 4 to 15 years. These are classified as meningovascular syphilis, general paresis, and tabes dorsalis. In **meningovascular syphilis,** chronic meningeal involvement causes an arteritis, typically involving medium-sized vessels, that results in diffuse white matter infarcts. If untreated, this condition eventually leads to **general paresis,** in which the accumulation of lesions causes dementia, behavioral changes, delusions of grandeur, psychosis, and diffuse upper motor neuron–type weakness. In another variant that often coexists with general paresis, patients with **tabes dorsalis** have involvement of the spinal cord dorsal roots, especially in the lumbosacral region, resulting in degeneration of the dorsal columns. Therefore, these patients have sensory loss in the lower extremities, sensory ataxia (see KCC 15.2) with a characteristic high-stepping tabetic gait(see KCC 6.5), and incontinence (see KCC 7.5). Other associated features include Argyll Robertson pupils (see KCC 13.5) and optic atrophy.

Diagnosis of neurosyphilis is based on blood tests for treponemes (FTA-ABS or MHA-TP), together with cerebrospinal fluid showing **lymphocyte-predominant meningitis.** So-called nontreponemal blood tests (RPR or VDRL) may be positive or negative in neurosyphilis, but cerebrospinal fluid VDRL is usually positive. Neurosyphilis is treated with intravenous penicillin G, and serial lumbar punctures should be performed to monitor the response to therapy.

Lyme disease is caused by the spirochete *Borrelia burgdorferi,* carried by *Ixodes* species of deer tick, which are endemic to certain areas of the United States, Europe, and Australia. The disease is named for the town of Lyme, Connecticut, where the disorder was first described. Primary infection is often heralded by a characteristic raised rash, called erythema chron-

TABLE 5.9 Differential Diagnosis of Lymphocyte-Predominant "Aseptic" Meningitis

Viral infections (numerous)
Partially treated bacterial meningitis
Tuberculous meningitis
Cryptococcal meningitis and other fungal infections
Parameningeal infection (e.g., epidural abscess)
Postinfectious encephalomyelitis
Postvaccination encephalomyelitis
Myelitis
Lyme disease
Neurosyphilis
Parasitic infections (eosinophils may also be present)
Carcinomatous (or other neoplastic) meningitis
Central nervous system vasculitis
Sarcoidosis
Venous sinus thrombosis
Subarachnoid hemorrhage several days previously
Drug reaction
Chemical irritation (e.g., from contrast material injected in CSF)

Note: See also Table 5.7.

icum migrans, which gradually shifts its location and enlarges over days to weeks. In some cases, neurologic manifestations occur. These usually appear after a delay of several weeks and include a lymphocyte-predominant meningitis (see Table 5.9) or mild meningoencephalitis, characterized by meningeal signs and emotional changes, with impaired memory and concentration.

Other features that may be present include cranial neuropathies (especially of the facial nerve), peripheral neuropathies, and, rarely, spinal cord involvement. Non-neurologic manifestations include arthritis and cardiac conduction abnormalities. Lyme disease is diagnosed by typical clinical features, lumbar puncture, and serological testing. Untreated cases can eventually show white matter abnormalities on MRI scan. Lyme disease with neurologic involvement is treated with intravenous ceftriaxone.

Viral Infections

Viral meningitis tends to be less fulminant than bacterial meningitis, and recovery usually occurs spontaneously within 1 to 2 weeks. Patients present with headache, fever, lethargy, nuchal rigidity, and other signs of meningeal irritation (see Table 5.5). Common causes include enteroviruses such as echovirus, coxsackievirus, and mumps virus. Often the causative agent is not identified. There is no specific treatment for most viral infections of the nervous system, except for herpes and HIV.

Cerebrospinal fluid in viral meningitis shows an elevated white blood cell count with a lymphocytic predominance, normal or mildly elevated protein, and normal glucose. In the early stages, a polymorphonuclear predominance may be present. The differential diagnosis of **lymphocytic,** or **lymphocyte-predominant meningitis** of the kind seen with viral meningitis is broad, occasionally making the diagnosis difficult (see Table 5.9; see also Table 5.7). Viral meningitis and other types of lymphocyte-predominant meningitis are sometimes called **aseptic meningitis** to distinguish them from bacterial meningitis. We have already discussed several other conditions characterized by lymphocyte-predominant meningitis, including tuberculous meningitis, neurosyphilis, and CNS Lyme disease.

When viral infections involve the brain parenchyma, they are called **viral encephalitis.** Unlike typical cases of viral meningitis, the clinical manifestations of viral encephalitis are often quite severe. The meninges are often also involved, resulting in **meningoencephalitis.** The most common cause of viral encephalitis is **herpes simplex virus** type 1 (type 2 also occasionally causes encephalitis). As discussed in Chapter 18, the herpes simplex virus has a tropism for limbic cortex. Patients often present with bizarre psychotic behavior, confusion, lethargy, headache, fever, meningeal signs, and seizures. Focal signs such as anosmia, hemiparesis, memory loss, and aphasia may be present as well. Herpes simplex encephalitis causes necrosis of unilateral or bilateral temporal and frontal structures often visible on MRI scan. Untreated, it usually progresses within days to coma and death. Therefore, it is essential to initiate therapy promptly with acyclovir.

Other characteristic features include periodic sharp waves seen over one or both temporal lobes on EEG. Cerebrospinal fluid shows a lymphocytic or mixed lymphocytic–polymorphonuclear predominance, with elevated protein and normal glucose (see Table 5.7). When necrosis is prominent, the CSF red blood cell count may be elevated and the glucose level decreased. The virus is difficult to culture from cerebrospinal fluid, but it can often be identified by polymerase chain reaction (PCR).

There are a variety of other causes of viral encephalitis, but unfortunately none of these have a specific treatment. Prognosis depends on the causative agent. In addition, **postinfectious encephalitis** can occur, usually several days after a viral infection, with diffuse autoimmune demyelination of the central nervous system. Prognosis is variable. Measles is occasionally associated with a delayed, slowly progressive fatal encephalitis called **subacute sclerosing panencephalitis.** Fortunately, the incidence of this disorder has dropped markedly since the introduction of the measles vaccine.

Herpes zoster, or shingles, is an infection caused by the same virus as chickenpox (varicella-zoster virus). The primary symptom is a painful rash conforming to nerve root distributions that will be discussed further in KCC 8.3.

Viral infections of the nervous system are also a common cause of **transverse myelitis** (see KCC 7.2). Important viral causes of myelitis include enteroviruses (such as coxsackie and poliomyelitis), varicella-zoster virus, HIV, or less commonly, Epstein–Barr virus, cytomegalovirus, herpes simplex, rabies, Japenese B virus, or HTLV-1.

HIV-Associated Disorders of the Nervous System. **Human immunodeficiency virus (HIV)** can increase susceptibility to numerous infectious disorders of the nervous system, including viral, bacterial, fungal, and parasitic infections. HIV itself can cause an aseptic meningitis at the time of seroconversion. This condition is sometimes associated with cranial neuropathies, especially involving the facial nerve (see KCC 12.3). **AIDS dementia complex** is the most common neurologic manifestation of HIV, with increased frequency late in the course of the illness. Treatment with the antiretroviral agent azidothymidine (AZT), often used in combination therapy (e.g., AZT + 3TC + protease inhibitor = highly active antiretroviral therapy, or HAART), can cause some improvement in AIDS-related dementia.

In addition to having an effect on the brain, the HIV virus has been associated with involvement of the spinal cord, peripheral nerves, and muscles (myelopathy, neuropathy, and myopathy, respectively). Other viral infections in patients with HIV include encephalitis caused by **herpes simplex virus, varicella-zoster virus,** or **cytomegalovirus.** Cytomegalovirus can also cause retinitis, which responds to ganciclovir, and a polyradiculitis that often involves the cauda equina (see KCC 8.4). **Progressive multifocal leukoencephalopathy (PML)** can occur in patients with HIV or other immunodeficiency states. This disorder is caused by a papovavirus called the JC virus and results in gradual demyelination of the brain, usually leading to death within 3 to 6 months. Survival time has improved to about 11 months for patients on HAART. MRI shows T2 bright white matter abnormalities, especially in the posterior regions of the brain.

Important bacterial infections of the nervous system in patients with HIV include tuberculous meningitis and neurosyphilis (discussed earlier). There is some evidence that neurosyphilis may have a more rapid or atypical course in patients with HIV. In the category of fungal infections, **cryptococcal meningitis** is common. It should be suspected in all HIV-positive patients with chronic headache and is diagnosed by lumbar puncture (see KCC 5.10). Cerebrospinal fluid may show an elevated white blood cell count with lymphocytic predominance (see Table 5.7), but it is occasionally normal. The presence of cryptococcal antigen in the CSF should therefore be checked. The organisms can also sometimes be identified by India ink stain. Cryptococcal meningitis is treated with intravenous amphotericin B, followed by oral fluconazole. Milder cases may be treated with fluconazole alone. Severe cases can cause progressive obtundation, neuropathies, seizures, hydrocephalus, and death.

A common parasitic infection of the nervous system in patients with HIV is **toxoplasmosis.** Central nervous system toxoplasmosis is caused by reactivation of infection with the parasite *Toxoplasma gondii.* Initial exposure is from cysts in cat feces or undercooked meat and is usually asymptomatic. In pa-

tients with AIDS or other causes of immunosuppression, the *Toxoplasma* infection becomes reactivated and spreads to the central nervous system, forming brain abscesses visible on MRI scans as ring-enhancing lesions: a nonenhancing center (dark on T1) surrounded by a ring of enhancement. Common presenting features are seizures, headache, fever, lymphocytic predominant meningitis, and focal signs, depending on the location of the lesions. Serological tests for toxoplasmosis are unreliable because much of the general population has been exposed (30% in the United States, 80% in France). Toxoplasmosis is the most common cause of intracranial mass lesions in patients with HIV. Therefore, when typical-appearing lesions are found on MRI scan in these patients, they are usually treated empirically with pyrimethamine and sulfadiazine for approximately 2 weeks, and a follow-up MRI scan is then performed. If there is improvement, therapy is continued. If not, a brain biopsy is recommended to establish the diagnosis.

Patients with AIDS are at increased risk for **primary central nervous system lymphoma** (see KCC 5.8). This B cell lymphoma can appear radiologically similar to toxoplasmosis, and it is the second most common cause of intracranial mass lesions in patients with HIV. The condition is diagnosed by brain biopsy, or by cerebrospinal fluid PCR for Epstein–Barr virus. Treatment with steroids and radiation therapy may be of some benefit, although the prognosis is much worse than for primary central nervous system lymphoma without HIV. Kaposi's sarcoma has only very rarely been reported to metastasize to the central nervous system.

Parasitic Infections

Parasitic infections that can involve the nervous system include cysticercosis, toxoplasmosis, malaria, African sleeping sickness (caused by the parasite *Trypanosoma brucei*), amebiasis, rickettsial illnesses, and schistosomiasis. In this section we will discuss cysticercosis. Toxoplasmosis was discussed earlier in the section on HIV. The other disorders, which are relatively uncommon in North America, are reviewed in the references at the end of this chapter.

Cysticercosis is caused by ingestion of the eggs of the pork tapeworm *Taenia solium*, found predominantly in Latin America and in certain regions of Africa, Asia, and Europe. The organism migrates through the bloodstream to the whole body, forming multiple small cysts in the muscles, eyes, and central nervous system. Seizures are a common result. Other common features are headache, nausea, vomiting, lymphocytic meningitis, and focal deficits, depending on cyst location. The spinal cord can also occasionally be involved. Obstruction of the ventricular system by cysts can cause hydrocephalus. CT scans in active infection typically show multiple small, 1 to 2 cm cysts in the brain parenchyma, with surrounding edema. The organisms eventually die, leaving numerous 1 to 3 mm calcifications scattered throughout the brain ("brain sand").

Cysticercosis is diagnosed by history in appropriate populations, by typical radiologic appearance, and by antibody tests of the serum and cerebrospinal fluid. Sometimes eosinophilia, parasites in the stool, and soft tissue calcifications on X-rays may be present as well. In questionable cases, biopsy may be necessary. The condition is treated with albendazole.

Fungal Infections

Fungal infections of the central nervous system are uncommon in immunocompetent hosts, but they can occur occasionally. Cryptococcal meningitis was discussed earlier in the section on HIV. Aspergillosis (caused by the fungus *Aspergillus*) and candidiasis (caused by *Candida*) can involve the brain parenchyma and are usually accompanied by an intense inflammatory response. Other fungi that can infect the brain parenchyma or meninges include *Histoplasma*, *Coccidioides*, and *Blastomyces*. *Aspergillus* can also occasionally spread from the nasal passages to the orbital apex, causing an orbital apex syndrome (see KCC 13.7). An important fungal infection to be aware of is **mucormycosis,** which occurs mainly in diabetics in the rhinocerebral form and also involves the orbital apex. Rhinocerebral mucormycosis causes ophthalmoplegia, facial numbness, visual loss, and facial weakness, with a typical violet coloration of the tips of the eyelids. Most fungal infections can be diagnosed only by biopsy, which should be pursued aggressively because early treatment is essential. Mucormycosis is treated with amphotericin B. Steroids can exacerbate fungal infections and should be avoided when a fungal infection is suspected.

Prion-Related Illnesses

In recent years, a novel protein-based infectious agent called the **prion** has been identified in certain neurologic disorders. Prions are unique in their ability to transmit illnesses from one animal to another, despite the fact that they apparently do not contain DNA or RNA. Pathologically, diffuse degeneration of the brain and spinal cord occurs, with multiple vacuoles resulting in a spongiform appearance. Human prion-related illnesses include Creutzfeldt–Jakob disease, Gerstmann–Sträussler–Scheinker disease, kuru, and fatal familial insomnia. These disorders are all relatively rare. The most common, Creutzfeldt–Jakob disease, has an incidence of approximately one new case per million individuals per year.

Typical presenting features of Creutzfeldt–Jakob disease are rapidly progressive dementia, an exaggerated startle response, myoclonus, visual distortions, and ataxia. EEG often shows periodic sharp wave complexes. Unfortunately, there is currently no treatment. Progressive neurologic deterioration and death usually occur within 6 to 12 months. Prion-related illnesses can occur in an inherited pattern, or they can be transmitted by exposure to infected tissues with an incubation period of 2 to 25 years (prions were formerly misnamed "slow viruses"). A recent cluster of atypical cases of Creutzfeldt–Jakob disease may have been caused by ingestion of cattle infected with bovine spongiform encephalopathy in Britain. ■

KEY CLINICAL CONCEPT
LUMBAR PUNCTURE

5.10 Lumbar puncture is an important procedure that provides direct access to the subarachnoid space of the lumbar cistern (Figure 5.22). It can be used to obtain samples of CSF, measure CSF pressure, to remove CSF in cases of suspected normal-pressure hydrocephalus, and occasionally to introduce drugs (such as antibiotics or cancer chemotherapy) or radiological contrast material (in myelography; see Chapter 4) into the CSF. Before a lumbar puncture is performed, the patient should be evaluated for evidence of elevated intracranial pressure (see KCC 5.3), and the safest practice is to perform a CT scan first to avoid risk of herniation. In addition, caution should be used in cases of impaired coagulation because of the risk of iatrogenic spinal epidural hematoma, which can compress the cauda equina.

The lumbar puncture procedure is performed with sterile technique under local anesthesia (see Figure 5.22). A hollow spinal needle is introduced through the skin with a stylus occluding the lumen to prevent the introduction of skin cells into CSF during needle insertion. The needle passes through subcutaneous tissues, ligaments of the spinal column, dura, and arachnoid, to finally encounter CSF in the subarachnoid space of the lumbar cistern. Note that the lumbar cistern is normally in direct communication with CSF in the ventricles and CSF flowing over the surface of the brain (see Figures 5.10, 5.12). The procedure may be done in the lying or seated position. A manometer tube is used to measure CSF pressure. Pressure measurements are more reliable in the lying position (see Figure 5.22A) because in

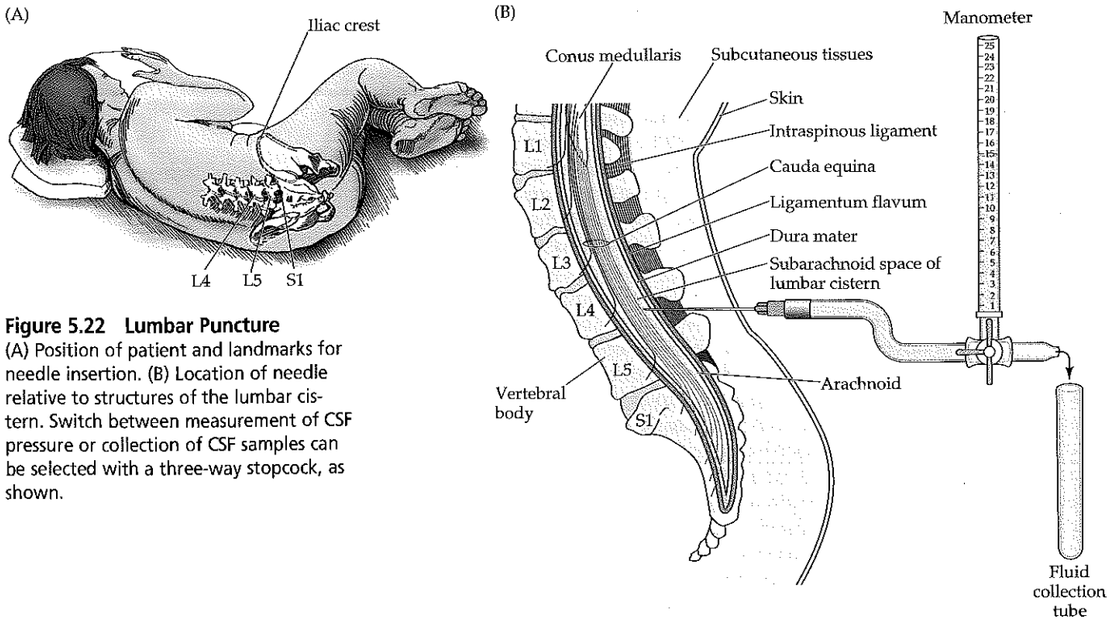

Figure 5.22 Lumbar Puncture
(A) Position of patient and landmarks for needle insertion. (B) Location of needle relative to structures of the lumbar cistern. Switch between measurement of CSF pressure or collection of CSF samples can be selected with a three-way stopcock, as shown.

the seated position the entire column of CSF in the spinal canal adds to the pressure measured in the lumbar cistern. Normal CSF pressure in adults is less than 20 cm H_2O (see KCC 5.3).

Note that the bottom portion of the spinal cord, or **conus medullaris,** ends at about the L1 or L2 level of the vertebral bones, and the nerve roots continue downward into the lumbar cistern, forming the **cauda equina,** meaning "horse's tail" (see Figure 5.22B). To avoid hitting the spinal cord, the spinal needle is generally inserted at the space between the L4 or L5 vertebral bones. As the tip of the needle enters the subarachnoid space, the nerve roots are usually harmlessly displaced. The posterior iliac crest serves as a landmark to determine the approximate level of the L5–L5 interspace.

The opening CSF pressure should be measured and recorded (see Figure 5.22B). CSF samples are then collected and sent for numerous studies, including cell count, protein, glucose, and microbiological testing. The CSF samples are collected in different tubes, which should be numbered sequentially, since the order in which CSF is taken can affect cell count, as we will discuss shortly. CSF profiles under normal conditions and in several infectious disorders are listed in Table 5.7, and causes of lymphocytic-predominant meningitis are listed in Table 5.9.

Normally, red blood cells are not present in the CSF. Red blood cells in the CSF can indicate subarachnoid hemorrhage (see KCC 5.6), hemorrhagic herpes encephalitis (see KCC 5.9), or they may simply have been introduced by damage to blood vessels by the spinal needle at the time of lumbar puncture, referred to as a **traumatic tap.** A traumatic tap can often be distinguished from pathological subarachnoid blood by the following guidelines: (1) The number of red blood cells usually decreases from the first to last tubes of CSF collected in a traumatic tap, but not in subarachnoid hemorrhage. (2) If the CSF is centrifuged, the supernatant may have a yellowish, or **xanthochromic,** appearance as a result of red blood cell lysis if hemorrhage occurred several hours previously, but no xanthochromia should be present in a traumatic tap if the CSF is centrifuged immediately after collection. A traumatic tap may also confound the analysis of CSF white blood cell count because white blood cells are introduced as well. In this case the ratio of red blood cells to white blood cells, and the white blood cell differential count, should be the same in the CSF as in the patient's peripheral blood smear. As a general guideline, in a traumatic tap *one white blood cell is introduced into the CSF for every 700 red blood cells.* Large amounts of hemorrhage in the CSF from any cause can also sometimes result in reduced CSF glucose or elevated protein.

In addition to diagnosing infection or hemorrhage, lumbar puncture can be useful for obtaining cytological specimens for the diagnosis of **neoplastic,** or **carcinomatous, meningitis,** and it can be useful for immunologic testing such as detection of **oligoclonal bands** in suspected multiple sclerosis (see KCC 6.6). ■

KEY CLINICAL CONCEPT
CRANIOTOMY

5.11 Archaeological evidence suggests that some forms of craniotomy have been practiced since prehistoric times. In the twentieth century, neurosurgery entered the modern era, with a dramatic decline in operative morbidity and mortality associated with more refined techniques and sterile operating methods. Craniotomy now provides access to the intracranial contents for a wide variety of therapeutic and diagnostic procedures that can be performed relatively safely by skilled neurosurgeons.

In craniotomy, the initial step is to position the head to provide optimal access to the desired structures. The hair is shaved, the scalp is cleaned with iodine solution, and an incision is then made to expose the skull. **Burr holes** are drilled through the skull at several locations in the operative field, and care is taken not to enter the dura. The burr holes are then joined together with a small saw so that a piece of bone called a **bone flap** can be removed, exposing the dura. The bone flap is usually saved so that it can be replaced after the procedure. The dura is then carefully opened and folded back, providing access to the intracranial contents. In addition to the usual monitoring performed during surgery, in neurosurgery the anesthesiologist must be constantly aware of interventions that will affect intracranial pressure and cerebral blood flow (see KCC 5.3). A lumbar drain is sometimes used to remove controlled amounts of CSF. When the procedure is complete, the dura is closed, the bone flap replaced, and the scalp sutured.

Different neurosurgical approaches are used to gain access to different regions of the intracranial cavity. The most common approaches are pterional, temporal, frontal, and suboccipital craniotomy. The pterion is the region over the temple where the frontal, parietal, temporal, and sphenoid bones meet. In **pterional craniotomy** this region of skull is removed, providing access to the inferior frontotemporal lobes. This approach is used for surgery on anterior circulation and basilar tip aneurysms, the cavernous sinus, and suprasellar tumors. In **temporal craniotomy** a more lateral approach is used for operating on the temporal lobe, including surgery to resect temporal lobe seizure foci (see KCC 18.2), and for decompression of most intracranial hematomas in head trauma (see KCC 5.6). **Frontal craniotomy** is used to operate on frontal lobe lesions, such as tumors. **Suboccipital craniotomy** provides access to posterior fossa structures such as the cerebellopontine angle (see KCC 12.5), vertebral artery, brainstem, and lower cranial nerves. Other specialized approaches, including the **transsphenoidal approach,** in which the pituitary region is reached via the nasal passages (see KCC 17.1), are used in special situations. In image-guided **stereotactic procedures** (see KCC 16.4), an instrument is introduced through a small burr hole and directed to a specific target deep within the brain. ■

CLINICAL CASES

CASE 5.1 AN ELDERLY MAN WITH HEADACHES AND UNSTEADY GAIT

CHIEF COMPLAINT
An 82-year-old man came to his physician with right-sided headaches and difficulty walking.

HISTORY
The patient was in a motor vehicle accident 3 months ago. He did not hit his head or lose consciousness, but the car was "demolished." He was examined in the emergency room and no abnormalities were found, so he was sent home. Ever since, he has complained of **generalized fatigue** and **right-sided headaches,** especially over the past 2 weeks. The headaches are worse at night, often keeping him awake. He has also recently stumbled several times while walking because of **left leg weakness.**

PHYSICAL EXAMINATION
General appearance: A thin elderly man in no acute distress.
Vital signs: T = 97°F, P = 86, BP = 146/80, R = 18.
Head: No evidence of trauma.
Neck: Supple with no bruits.
Lungs: Clear.
Heart: Regular rate with no murmurs, gallops, or rubs.
Abdomen: Normal bowel sounds; soft, nontender.
Extremities: Normal.
Neurologic exam:
MENTAL STATUS: Alert and oriented × 3. Speech fluent, with good naming and repetition. Able to count down from 100 by sevens (a test of attention and calculation skills).
CRANIAL NERVES (see Table 2.6): Pupils equal round and reactive to light (CN II, III). Extraocular movements intact (CN III, IV, VI). **Visual fields** (CN II) full, but with **extinction on the left to double simultaneous stimulation.** Facial sensation intact (CN V). Face symmetrical (CN VII). Normal gag (CN IX, X). Normal sternomastoid strength (CN XI). Tongue midline (CN XII).
MOTOR: **Pronator drift of left arm** (see KCC 6.4). **Mild left hemiparesis (4+/5 strength throughout left arm and leg).** Normal strength on the right side.
SENSORY: Intact except for **left extinction on double simultaneous stimulation.**
REFLEXES:

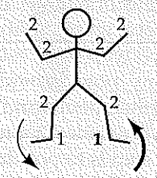

GAIT: Takes short steps, but with good speed. Able to perform tandem gait.
COORDINATION: Not tested.

LOCALIZATION AND DIFFERENTIAL DIAGNOSIS
1. On the basis of the symptoms and signs shown in **bold** above, what is the general location of the patient's lesion? Is it intracranial or extracranial? Is it on the left side or the right side?
2. Given the recent history of a motor vehicle accident in this elderly man and the fact that the headaches are worse at night, what is the most likely diagnosis? What are some other possibilities?

Discussion

1. The key symptoms and signs in this case are:
   - **Left hemiparesis, and left Babinski's sign**
   - **Visual and tactile extinction on the left**
   - **Right-sided headaches**
   - **Generalized fatigue**

   The patient has mild left arm and leg weakness with a left Babinski's sign, suggesting an upper motor neuron lesion (see Table 3.3) in the corticospinal system anywhere from the right motor cortex to the left cervical spine (see Figure 2.16). The visual and tactile extinction in this patient are forms of left hemineglect (see KCC 19.9), which is most commonly seen in right parietal lesions but can also be seen in right frontal or subcortical lesions. These findings are compatible with a right intracranial rather than a left spinal cord localization. Generalized fatigue is a nonspecific complaint, but in association with right-sided headaches it suggests a possible right intracranial mass lesion (see KCC 5.1–5.3). *The most likely clinical localization is a right hemisphere cortical and/or subcortical lesion affecting corticospinal and attentional pathways.*

2. This is an elderly patient with 3 months of headaches and generalized fatigue following a motor vehicle accident, who more recently developed a left hemiparesis. Chronic vague symptoms of this type, with stepwise worsening in an elderly patient following minor head injury are very suggestive of chronic subdural hematoma (see KCC 5.6). As a result of his multiple falls, there may be some more recent blood in the hematoma as well. Another possible but less likely diagnosis would be several small right-sided intracerebral hemorrhages over the past few months, caused by hypertension, tumor, vascular malformation, amyloid angiopathy, coagulation disorder, or trauma (contusions). In addition, it is possible that the car accident was a coincidence, or it may even have been an effect of the lesion rather than its cause. This would be the case if the patient had a preexisting right hemisphere lesion such as a tumor, infarct, demyelination, or infection that impaired driving skills.

Neuroimaging 166

The patient's physician decided to order a **head CT** (Figure 5.23).

1. How old is the blood in the hematoma seen on the head CT (see Figure 5.19 and Chapter 4)?
2. Cover the labels on Figure 5.23 and identify as many structures as possible on the CT scan.
3. Between what meningeal layers is the hemorrhage located, and what is the name of this kind of hematoma?

Discussion

1. The fluid collection is hypodense relative to the brain, but more dense than CSF. It generally takes about 2 to 3 weeks for a hematoma to become hypodense in appearance.
2. See labels on Figure 5.23.
3. A large, right-sided fluid collection is seen located between the brain and the skull. The crescent shape is characteristic of a subdural hematoma (KCC 5.6), which follows the contours of the brain as it expands in the potential space between the dura and the loosely adherent arachnoid. Since it is hypodense in appearance, this is a chronic subdural hematoma.

   Note that the underlying brain parenchyma on the right side is significantly compressed by the hematoma, including the area of the central sulcus and the frontal and parietal lobes. These structures can be better distinguished on the left side of the brain. Also note that there is a small amount of midline shift, amounting to mild subfalcine herniation (KCC 5.4). It is remarkable that the patient was not more severely impaired, given the appearance of the CT scan. This case demonstrates the ability of the brain to adapt to large lesions that expand slowly over a long period of time.

Clinical Course

The patient was admitted to the hospital and taken to the operating room for drainage of the hematoma. Two burr holes were drilled through the skull, one in the frontal area and a second in the parietal area. The dura was opened through the burr holes, releasing "crankcase oil–colored" (dark purple) fluid under a large amount of pressure. There was no evidence of any acute blood. The subdural space was irrigated with saline until there was no further oil-colored fluid.

The patient's hemiparesis showed immediate improvement after surgery. Follow-up exam in the physician's office 3 weeks later showed 5/5 strength, intact vision, intact somatic sensation, no hemineglect, and toes downgoing bilaterally. The patient had no further complaints of headaches or generalized fatigue.

CASE 5.1 AN ELDERLY MAN WITH HEADACHES AND UNSTEADY GAIT

Figure 5.23 Head CT Showing Chronic Subdural Hematoma
A hypodense right chronic subdural hematoma is present. Compare to Figure 4.12J.

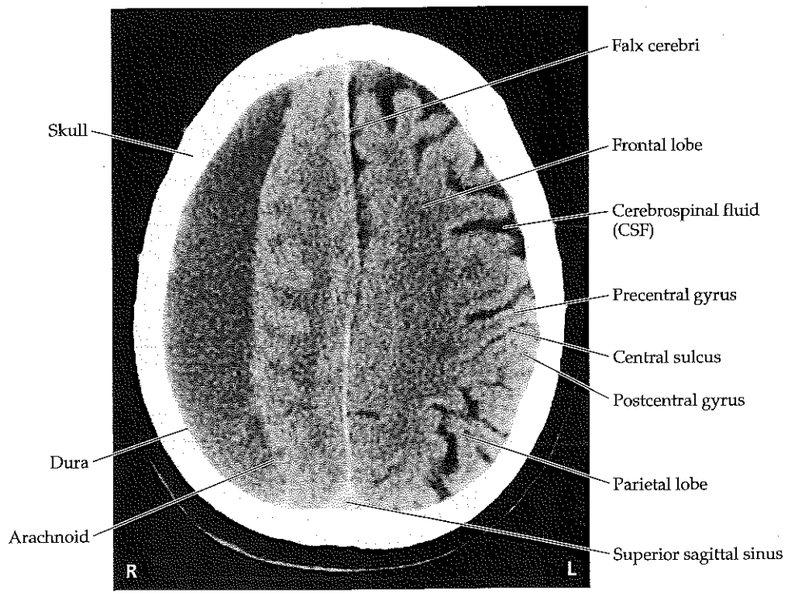

CASE 5.2 ALTERED MENTAL STATUS FOLLOWING HEAD INJURY

CHIEF COMPLAINT
A 67-year-old man was found at the bottom of a flight of stairs, lethargic and smelling of alcohol.

HISTORY
Little information could be obtained from the patient. He was discovered at the base of a staircase intoxicated and with a posterior scalp laceration and was therefore brought to the emergency room.

INITIAL PHYSICAL EXAMINATION
General appearance: An unkempt man lying on a stretcher.
Vital signs: T = 98°F, P = 90, BP = 176/89, R = 20.
Head: **Scalp laceration** over right occipital area; normal tympanic membranes (see Table 3.9).
Neck: In cervical stabilization collar put on by emergency personnel.
Lungs: Clear.
Heart: Regular rate with no murmurs, gallops, or rubs.
Abdomen: Normal bowel sounds; soft, nontender.
Extremities: No edema, normal pulses.
Rectal: Normal tone, heme negative.
Neurologic exam:
MENTAL STATUS: Lethargic **but arousable, with garbled speech. Stated his full name but** did not know his location or the date. Did not recall what happened to him, **saying "I'm all right." Followed simple commands.**
MOTOR: **Able to move all four extremities.**

LOCALIZATION AND DIFFERENTIAL DIAGNOSIS
1. Dysfunction of what regions of the nervous system could produce the mild to moderately depressed level of consciousness seen in this patient?
2. In broad terms, what are the two most likely causes of this patient's altered mental status?

Discussion

1. The patient was lethargic and disoriented. Little other information is provided; however, he presumably had no other major abnormalities. Depressed level of alertness and attention can be seen with diffuse bilateral cerebral dysfunction, or with dysfunction of the brainstem and diencephalic reticular activating systems (see Figure 2.23).
2. Although there are many possible causes of altered mental status that should be considered, there are two obvious causes in this patient. One is alcohol intoxication. The second is head trauma (KCC 5.5). There are many additional possible causes of altered mental status in this patient (see KCC 19.5, Table 19.14), including other toxic or metabolic derangements, seizures, infection, infarct, or brain tumor.

CASE 5.2 *(CONTINUED)*

CLINICAL COURSE IN THE EMERGENCY ROOM
The initial impression of the emergency room personnel was that the patient was intoxicated with alcohol and perhaps had a mild concussion, both of which should improve with observation over the next few hours. The patient was sent for X-rays of the cervical spine and chest. His blood alcohol level came back at 325 mg/dl (>100 mg/dl can cause intoxication, although chronic users can develop tolerance). While at the radiology department, he became **uncooperative and combative,** moving too much for the X-rays to be done. He then became **increasingly somnolent** and developed irregular respirations, requiring emergency intubation and mechanical ventilation. A second, rapid but more detailed neurologic exam was done, and the patient was taken for an emergency head CT scan.

FOLLOW-UP PHYSICAL EXAMINATION
Vital signs: P = 95, BP = 184/90.
The remainder of the general exam was unchanged.
Neurologic exam:
MENTAL STATUS: Unresponsive except for movement to painful stimuli.
CRANIAL NERVES: **Pupils 3 mm, constricting to 2 mm bilaterally. Oculocephalic maneuvers (see Chapter 3) were not done because of the cervical collar.** Corneal reflex **present on the left, but absent on the right.**
SENSORY AND MOTOR: **Moved left arm and leg in response to painful stimulation.** Right arm and leg did not move in response to pain.
PLANTAR REFLEXES: No response on the right, upgoing on the left.
COORDINATION AND GAIT: **Not tested.**

LOCALIZATION AND DIFFERENTIAL DIAGNOSIS
1. The neurologic exam was incomplete, but it suggests **depressed consciousness** together with **right hemiplegia** (unilateral paralysis) and/or right sensory loss. Decreased function in which structures could cause this picture? What is the most likely cause of this patient's sudden deterioration?
2. In what location(s) might we expect to see hemorrhage on CT scan in a patient with acute head trauma (see KCC 5.5, 5.6)? For each location, identify the inner and outer layers that confine the space (see Figure 5.1), and state whether it is an actual space or a potential space. To answer this question, complete the following table:

Locations of Hemorrhage Associated with Head Trauma

NAME	LOCATION	POTENTIAL OR ACTUAL SPACE	BOUNDED BY
Intraventricular hemorrhage			
Contusion with intracerebral or intraparenchymal hemorrhage			
Subarachnoid hemorrhage			
Subdural hematoma			
Epidural hematoma			
Subgaleal hematoma			

Discussion

1. The key symptoms and signs in this case are:
   - **Unresponsiveness except to painful stimuli**
   - **Absent right corneal reflex, and no right arm or leg movement to pain with plantar response absent on the right and upgoing on the left**

   Depressed consciousness can be caused by dysfunction of brainstem–diencephalic activating systems or of bilateral cerebral cortices (see Figure 2.23). Absent right face, arm, and leg movements in response to pain could be explained by impaired function in the motor pathways that begin in the left motor cortex (see Figures 2.13, 2.16), and/or by right body sensory loss (see Figure 2.19). The absent right plantar response is also compatible with corticospinal dysfunction because reflexes are sometimes depressed rather than increased in acute upper motor neuron lesions (see Table 3.3).

   Although unilateral arm and leg paralysis can be caused by lesions above or below the foramen magnum, the presence of hemiplegia, together with impaired consciousness, strongly suggests pathology within the cranial vault. Intracranial lesions of the left brainstem or left cerebral hemisphere can cause right hemiplegia. There is some evidence of right brain dysfunction as well, with an upgoing toe in the left foot, suggesting either that the lesion is so large that it compromises structures across the midline, or that a second lesion is present.

   In summary, one possible localization is the upper brainstem, with involvement of the pontomesencephalic reticular formation and of the left more so than the right corticospinal and corticobulbar tracts. Because of the cervical collar, eye movements could not be tested easily, and such testing might have helped further with localization (see neuroexam.com video 35). Another possibility is a large intracranial lesion affecting the left motor cortex or descending white matter pathways, and also compressing the upper brainstem–diencephalic junction through mass effect and transtentorial herniation (see KCC 5.4).

   The external evidence of head trauma (scalp laceration) is most suggestive of a rapidly expanding lesion in the left cranial cavity, which could impinge on the left hemisphere corticospinal system in both the cortex and the white matter. It could also impair consciousness through midline shift, distorting the reticular formation, and through elevated intracranial pressure. The most likely causes of an expanding lesion following trauma would be epidural hematoma, acute subdural hematoma, cerebral contusion, or cerebral edema (see KCC 5.5, 5.6). Although less likely, additional possibilities for the deterioration seen in this patient would include intracranial hemorrhage from a preexisting lesion such as a tumor, vascular malformation, or aneurysm; ischemic infarction of the left cerebral hemisphere or brainstem; hydrocephalus; or delayed absorption of an ingested toxin (although the last two possibilities should not by themselves cause hemiplegia).
2. See Table 5.10 and Figure 5.1.



Oculocephalic testing

Neuroimaging

In patients of this kind, there are several serious pitfalls in making the diagnosis of intracranial pathology. First, alcohol intoxication obscures the clinical picture, making it difficult to recognize mental status changes from other causes. Second, the restless agitation and combativeness present in this patient are frequently seen as a sign of acute worsening of intracranial hypertension or hydrocephalus (KCC 5.3, 5.7) but can easily be mistaken for an assaultive, intoxicated personality. Therefore, intoxicated patients require extra vigilance, and if a clear trend toward neurologic improvement is not seen, an urgent CT scan of the head is warranted. Our patient had an emergency **head CT** (Figure 5.24A–C) and was then rushed immediately to the operating room. The images in Figure 5.24A–C were taken just before surgery; those in Figure 5.24D–F were taken 1 year later.

TABLE 5.10 Locations of Hemorrhage Associated with Head Trauma

NAME	LOCATION	POTENTIAL OR ACTUAL SPACE	BOUNDED BY
Intraventricular hemorrhage	Ventricles (CSF)	Actual	Walls of the ventricles
Contusion with intracerebral or intraparenchymal hemorrhage	Cerebral hemispheres or elsewhere in brain parenchyma	Potential	Brain tissue
Subarachnoid hemorrhage	Subarachnoid space (CSF)	Actual	Pia and arachnoid
Subdural hematoma	Subdural space	Potential	Arachnoid and dura
Epidural hematoma	Epidural space	Potential	Dura and skull
Subgaleal hematoma	Subaponeurotic space (loose areolar connective tissue)	Potential	Periosteum of the skull and galea aponeurotica

1. How old is the hemorrhage in Figure 5.24A–C?
2. What kind of hemorrhages are present in this patient? (Hint: All the hemorrhages listed in Table 5.10 can be seen except for epidural hematoma.)

Discussion

1. All of the hemorrhage appears quite hyperdense, and on radiological grounds it is less than about 1 week old (see Chapter 4). On the basis of the clinical story, the blood is probably only a few hours old.
2. A thin, crescent-shaped hematoma on the left side extends over a large region, consistent with an acute subdural hematoma (see KCC 5.6). In addition, some blood can be seen to extend down into the sulci (see Figure 5.24C). Recall that the pia follows the brain surface down into the sulci, while the arachnoid does not (see Figure 5.1). The blood in the sulci must therefore be in the subarachnoid space, representing subarachnoid hemorrhage. Large, confluent areas of hemorrhage are present in the left temporal and inferior frontal poles, consistent with cerebral contusion (see Figure 5.24A,B). Note that on the right posterior scalp is an area of soft tissue swelling and subgaleal hemorrhage. One could draw an imaginary "line of force" from the right posterior scalp injury straight through to the left frontotemporal contusion. This is a classic **coup contrecoup** injury, in which a blow to one side of the head is accompanied by deceleration injury on the opposite side of the brain as it bangs against the inner surface of the skull. The frontal and temporal poles are especially susceptible to contusion where they abut the bony ridges of the anterior and middle cranial fossae (see Figure 5.21). A small amount of intraventricular blood can be seen layering the right occipital horn (see Figure 5.24B), which can be better appreciated by comparison to the follow-up study (see Figure 5.24E). Finally, there is an abnormally bright band of hyperdensity between the cerebellum and medial temporo-occipital lobes (see Figure 5.24A). Recall that the dura forms a fold extending into the cranial vault between these structures called the tentorium cerebelli (see Figure 5.6). This is therefore an acute subdural hematoma of the tentorium cerebelli, which can be seen on other images (not shown) to be a direct extension of the subdural hematoma on the

left cerebral convexity. Also not shown are the CT image bone windows that revealed a nondisplaced right occipital skull fracture.

Severe mass effect produced by hemorrhage and edema can also be seen on this scan. The **midline shift at the level of the pineal calcification** is a good indicator of how much the reticular formation is distorted at the midbrain–diencephalic junction. Our patient has approximately 11 mm of rightward pineal shift (see Figure 5.24B). More than 10 mm of shift is usually associated with profound coma. The midbrain appears elongated in the anterior to posterior dimension, and somewhat flattened from side to side (see Figure 5.24A). The left uncus and medial temporal lobe can be seen to extend across the region normally delineated by the tentorial edge, and to press up against the midbrain. This is consistent with early left uncal transtentorial herniation (see KCC 5.4). Marked mass effect is also demonstrated by the near-complete effacement of the basal cisterns (see Figure 5.24A) compared with after recovery (see Figure 5.24D). The left lateral ventricle and sulci are also nearly completely obliterated (see Figure 5.24A–C). The right ventricle, in contrast, is somewhat dilated because of partial obstruction of CSF flow and consequent mild hydrocephalus. The left hemisphere appears swollen and somewhat hypodense (see Figure 5.24B,C), consistent with diffuse cerebral edema.

Clinical Course

Emergency measures were instituted to lower intracranial pressure (see KCC 5.3), including intravenous administration of the hyperosmolar agent mannitol, and adjustment of the ventilator settings for hyperventilation, as the patient was taken directly to the operating room. During surgery an incision was made in the left scalp, and a large **bone flap** (see KCC 5.11) was removed, exposing the underlying dura, which appeared tense and blue. The dura was opened, revealing a large, freshly clotted subdural hematoma, which was then evacuated. There were also significant subarachnoid blood, swelling, and contusions of the left temporal and frontal poles. To further decompress the intracranial cavity, the severely contused portions of the anterior left temporal lobe, as well as the anterior inferior left frontal lobe, were removed, and a large left frontal intraparenchymal hematoma was evacuated. The dura was closed with sutures, and the bone flap was replaced before the scalp was closed.

In the intensive care unit, 3 hours after surgery, the patient remained intubated but was awake, with full extraocular movements and equal and reactive pupils. He would squeeze the examiner's hand or wiggle his toes bilaterally on verbal command, with greater strength on the left side. His left plantar reflex was downgoing, and right plantar silent. After a prolonged recovery period in the hospital and at a rehabilitation facility, the patient returned home, was able to function fully independently, and soon found his way back to the neighborhood bar. Follow-up head CT scan done 1 year later during another episode of intoxication (see Figure 5.24D–F) showed complete resolution of all hemorrhage and mass effect, with residual hypodensities present in the region of the left temporal and frontal poles representing glial scar and tissue loss (hydrocephalus ex vacuo). This case is somewhat unusual in showing such dramatic recovery despite the severe appearance of the patient's preoperative CT scan with multiple contusions, acute subdural blood, and marked distortion of the brainstem. He was fortunate to have had his acute deterioration occur in a place where emergency neurosurgery could be undertaken without delay, but unfortunate to have a continued addiction to alcohol.

CASE 5.2 ALTERED MENTAL STATUS FOLLOWING HEAD INJURY

Figure 5.24 Head CT Images Showing Acute Subdural Hematoma and Recovery (A–C) Acute left frontotemporal and tentorial subdural hematoma. A left frontotemporal contusion and subarachnoid blood are present as well. (D–F) Follow-up CT scans 1 year later.

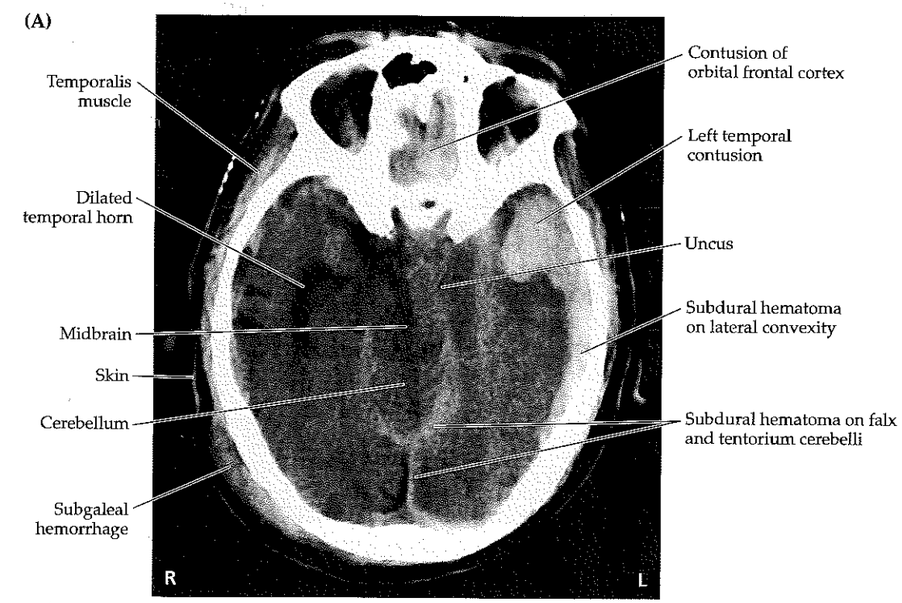

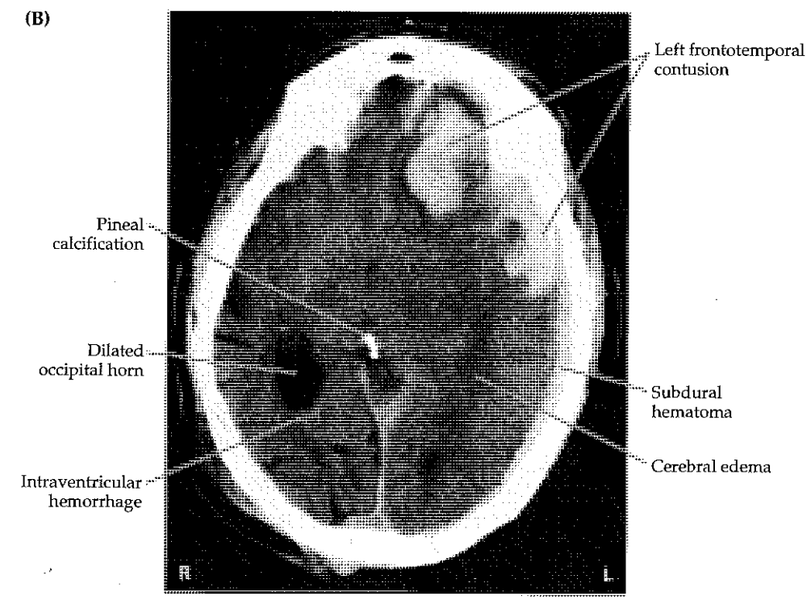

CASE 5.2 *(CONTINUED)*

(C)

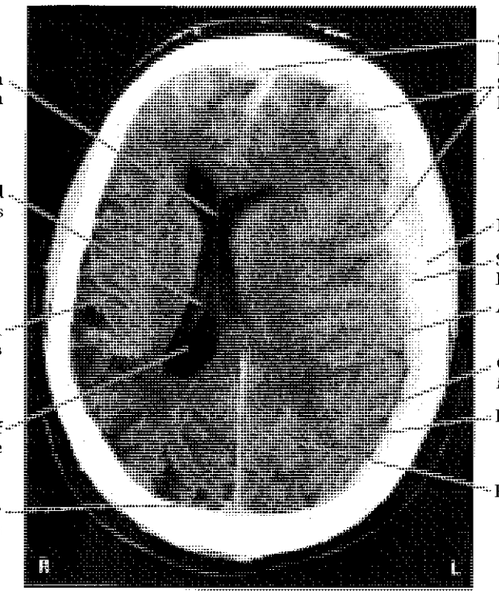

(D)

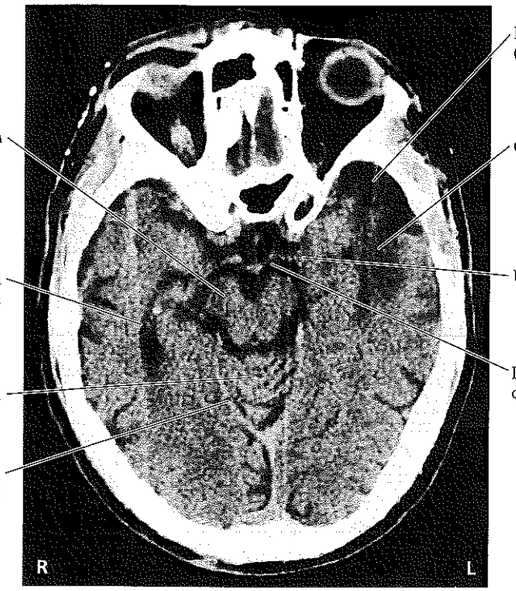

CASE 5.2 *(CONTINUED)*

(E)

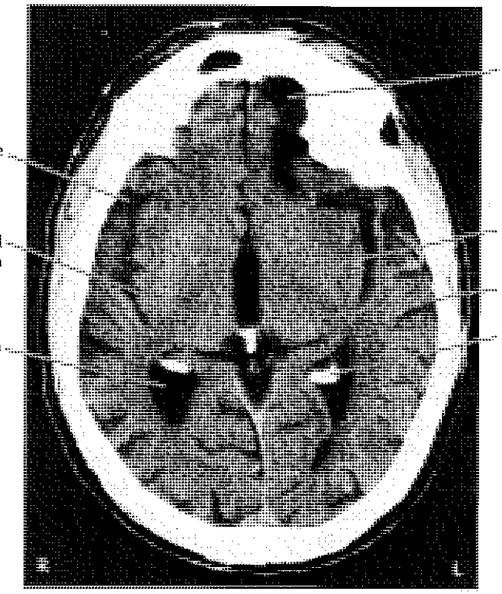

(F)

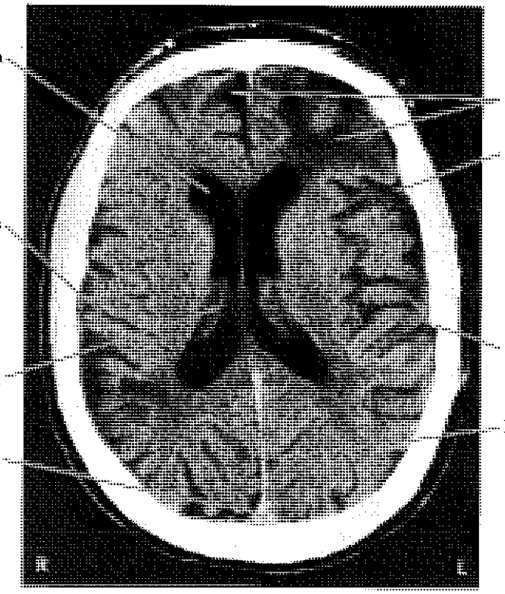

CASE 5.3 DELAYED UNRESPONSIVENESS AFTER HEAD INJURY

CHIEF COMPLAINT

A 51-year-old man was found to be **progressively unresponsive** the morning after a head injury.

HISTORY

The night before admission, the patient fell down a flight of cement stairs at 12:00 AM, following a domestic altercation. He struck his left temporal area and lost consciousness for about 15 minutes. By the time the police and ambulance arrived, however, he was fully awake, smelled of alcohol, and refused medical treatment. He was arrested on domestic violence charges and spent the night in prison. In the morning the guards came to summon him for a court appearance and found him **difficult to arouse, thrashing about incoherently.** He had vomited and defecated in the cell overnight. An ambulance was called, and he was brought to the emergency room for evaluation.

PHYSICAL EXAMINATION

General appearance: Disheveled-appearing man lying on a stretcher.
Vital signs: T = 98°F, P = 96, BP = 150/100, R = 28.
Head: Left forehead abrasion. No Battle's sign, raccoon eyes, CSF otorrhea, or rhinorrhea. Tympanic membranes normal (see Table 3.9).
Neck: In cervical stabilization collar put on by emergency personnel.
Lungs: Clear.
Heart: Regular rate with no murmurs, gallops, or rubs.
Abdomen: Normal.
Extremities: Normal.
Rectal: Normal tone, heme negative.
Neurologic exam:

MENTAL STATUS: **Unresponsive** to commands. Not speaking. Occasionally thrashed on stretcher in **agitated**, semipurposeful fashion.

CRANIAL NERVES: **Left pupil 5 mm, fixed** (no response to light). Right pupil 2 mm, constricting to 1 mm in response to light. Oculocephalic maneuvers not done because of cervical collar. Gag reflex present.

SENSORY AND MOTOR: Left arm and left leg moved spontaneously. Withdrew left arm and leg purposefully from painful stimulation. **Right arm and leg did not move**, even in response to pain.

REFLEXES:

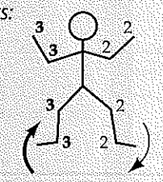

COORDINATION AND GAIT: Not tested.

Shortly after arriving in the emergency room the patient developed respiratory distress and was therefore intubated. He subsequently stopped moving his left side as well and became completely unresponsive.

LOCALIZATION AND DIFFERENTIAL DIAGNOSIS

1. For each of the symptoms and signs appearing in **bold** above, review the neuroanatomical pathways involved (see Figures 2.16, 2.23; Tables 2.5, 3.3). In what single brain region do these pathways intersect? Which herniation syndrome (see KCC 5.4) will cause compression of this brain region? On which side would you expect to find the cause of the compression?
2. Given the history of acute head injury, with delayed and progressive unresponsiveness over the course of several hours, what is the most likely diagnosis? What are some other possibilities?

Discussion

1. The key symptoms and signs in this case are:
   - **Agitation and decreased level of consciousness**
   - **Left pupil fixed and dilated**
   - **Right hemiplegia, right hyperreflexia, and right Babinski's sign**

   Impairment of consciousness could be caused by lesions affecting the brainstem–diencephalic reticular activating systems (either directly, or through compression and distortion from nearby lesions; see Figure 2.23), or by lesions affecting the cerebral hemispheres bilaterally. Pupillary constriction is mediated by parasympathetic fibers that travel with the oculomotor nerve (CN III) arising from the midbrain (see Figures 2.9, 2.22; Table 2.5). Therefore, a fixed, dilated left pupil could be caused by a lesion involving the left midbrain, CN III as it exits the brainstem and travels toward the eye, or possibly the pupillary constrictor muscle directly. The combination of right-sided weakness and increased reflexes suggests an upper motor neuron lesion (see Table 3.3) somewhere in the corticospinal pathway beginning in the left motor cortex and ending in the right spinal cord (see Figure 2.16). These three pathways or systems intersect in the midbrain, producing the triad of coma, a blown pupil, and hemiplegia seen in uncal herniation (see KCC 5.4; Figure 5.18). The dilated pupil on the left suggests that the lesion is on the left side of the intracranial cavity, compressing the left midbrain.

   The most likely *clinical localization* is left uncal herniation compressing the left midbrain.
2. The patient suffered a significant blow to the left temporal area. Recall that fracture of the temporal bone can lacerate the middle meningeal artery, resulting in epidural hematoma (see Figure 5.7; KCC 5.6). In addition, as can sometimes be seen with epidural hematomas, the patient initially regained consciousness during a **lucid interval** lasting several hours, and only later lapsed back into unconsciousness, probably because of progressive expansion of the hematoma. Recall that epidural hematomas are arterial in origin and therefore can cause rapid deterioration due to expansion. We have already seen in Case 5.2 that acute subdural hematoma, brain contusion, and edema can also sometimes cause progressive deterioration, so these diagnoses should be considered here as well. Finally, it is possible but less likely that during the night the patient had a cerebral infarct perhaps due to posttraumatic vertebral artery dissection (see KCC 10.6), or that he had an intracerebral hemorrhage caused by something not directly related to the head injury, such as hypertension, brain tumor, or vascular malformation (see KCC 5.6).

Neuroimaging 178

Because of the change in this patient's clinical status, an urgent **head CT** was done (Figure 5.25).

1. How recent is the hemorrhage seen on the CT scan (see Chapter 4)?
2. On the basis of its appearance, what kind of hemorrhage is this, and where is it located (see KCC 5.6)?
3. Identify the fracture on the bone windows (see Figure 5.25D). What bone does it involve?
4. Describe the mass effect (see KCC 5.2) caused by the hematoma and any herniation (see KCC 5.4) that can be identified on the CT.

Discussion

1. The hemorrhage is hyperdense and therefore occurred within the past week (see Chapter 4).
2. A large, lens-shaped fluid collection is seen along the inner surface of the left temporal and parietal bones. Note that this hematoma has a biconvex shape and is limited anteriorly by the coronal suture line (see Figure 5.25B,C) where the periosteal layer of dura forms a tight insertion. These features are characteristic of an epidural hematoma formed by high-pressure arterial blood dissecting between the dura and bone (see KCC 5.6).
3. A fracture of the left temporal bone can be seen (see Figure 5.25D). On higher cuts (not shown), the fracture was seen to extend into the left parietal bone as well.
4. There is extensive midline shift caused by the hematoma, with displacement of the entire brain to the right, compressing the left lateral ventricle (see Figure 5.25A,B). The left anteromedial temporal lobe, including the uncus, extends over the tentorial edge and compresses the left side of the midbrain (see Figure

5.25A), constituting left transtentorial herniation (see KCC 5.4). In addition, the cingulate gyrus is forced under the falx (see Figure 5.25B), causing subfalcine herniation (see Figure 5.18).

Clinical Course

Because of his rapid decline, the patient was taken immediately from the CT scanner to the operating room. Emergency measures to lower intracranial pressure (see KCC 5.3; Table 5.3), including hyperventilation and intravenous mannitol, were initiated en route. In the operating room, an incision was made from just above the left ear up to the crest of the head, revealing a large linear fracture in the temporal and parietal bones. A craniotomy was performed (see KCC 5.11), and a large fresh clot of blood was evacuated from the epidural space. Several tears in the middle meningeal artery were identified (see Figure 5.7), so the artery was coagulated down to the skull base. The patient had a prolonged hospital course postoperatively, but he gradually regained consciousness and the ability to ambulate and use his right hand. A follow-up CT scan performed a week and a half after the injury showed remarkable recovery of the normal intracranial anatomy following removal of the hematoma. This case demonstrates the importance of being able to recognize the neuroanatomical features of uncal herniation so that therapeutic measures can be initiated promptly, while recovery is still possible.

CASE 5.4 HEADACHE AND PROGRESSIVE LEFT-SIDED WEAKNESS

MINICASE

A 52-year-old lumber executive developed mild difficulty running, initially stubbing his left big toe, which progressed to constant left leg weakness over the course of 6 months. He also complained of **headaches.** Examination was normal except for **decreased left nasolabial fold** and **4+/5 weakness in the left triceps and left leg.**

LOCALIZATION AND DIFFERENTIAL DIAGNOSIS

1. On the basis of the limited information provided, is the lesion intracranial or extracranial (see Figures 2.13, 2.16)? Which side is the lesion on?
2. What is the most likely diagnosis? What are some other possibilities?

Discussion

1. The key symptoms and signs in this case are:
   - **Headaches**
   - **Left hemiparesis**

   Weakness affecting the left face, arm, and leg together is caused by lesions of the corticobulbar (face) and corticospinal (arm and leg) pathways originating in the right motor cortex (see Figures 2.13, 2.16). The lesion must be at or above the level of the pons, since the facial nerve (CN VII) nucleus is in the pons and exits the brainstem at the pontomedullary junction (see Figure 2.22; Table 2.5); lesions below this point would not cause face weakness. The presence of headaches further supports an intracranial localization.

   The most likely *clinical localization* is right intracranial lesion affecting corticobulbar and corticospinal tracts at or above the level of the pons.
2. Headache can have many causes (see KCC 5.1). New-onset headaches for a man in his 50s, together with a progressive neurologic deficit over a 6-month period, suggests brain tumor (see KCC 5.8), most commonly glioblastoma multiforme or metastasis. Other, less likely possibilities include infection, demyelination, multiple small hemorrhages or infarcts, or vasculitis.

Clinical Course

An MRI scan was consistent with the primary brain tumor called glioblastoma multiforme (see KCC 5.8) involving mainly the right hemisphere. The diagnosis was confirmed by biopsy. The patient was treated with surgical resection of as much tumor as possible, followed by radiation therapy. Nevertheless, about 1 year after his first symptoms he developed gradually worsening headaches, lethargy, and left-sided weakness. MRI revealed recurrent tumor. He was treated with high-dose steroids (dexamethasone) and intravenous mannitol (see KCC 5.3) but continued to worsen. On the day before he died, at 3:00 P.M. he was described as sleepy but arousable and "oriented × 3." Pupils were 4 mm and briskly responsive bilaterally. He was hemiplegic on the left. At 10:00 P.M. the same day, he was unresponsive even to deep pain. His right pupil was 7 mm and unreactive, left pupil 4 mm. A little later the pupils were 7 mm bilaterally and fixed. The dexamethasone and mannitol were increased further with no improvement. Given his untreatable condition, the family requested no resuscitation measures, and the patient stopped breathing the next day.

1. Impaired function in what brainstem region could explain the progressive hemiplegia, lapse in consciousness, and pupillary abnormalities seen just before death in this patient?
2. What herniation syndrome causes compression of this brain region?

Discussion

1. The midbrain (see Figures 2.16, 2.22A, 2.23; Tables 2.5, 3.3).
2. This patient had a long-standing left hemiparesis caused by a right hemispheric mass lesion, so it is difficult to invoke a herniation syndrome to explain the hemiplegia. However, impaired consciousness with a dilated, unreactive pupil is characteristic of the midbrain compression seen with uncal transtentorial herniation (see KCC 5.4). Elevated intracranial pressure (see KCC 5.3) may also have contributed to the impaired level of consciousness. Thus, when the patient became unresponsive, with a dilated, unreactive right pupil, he was probably undergoing right transtentorial herniation caused by the enlarging right hemisphere mass. Eventually, the midbrain was compromised bilaterally, as evidenced by the fact that the left pupil became dilated and unreactive as well.

Pathology 184

The patient's family requested an autopsy to confirm the cause of death (Figure 5.26). The brain weighed 1420 g (normal weight is 1250–1400 g) and appeared swollen and edematous. On surface examination, prominent grooves were seen on the inferior medial surfaces of the temporal lobes, especially on the right side, located 1.0 cm from the uncal tip on the right and 0.4 cm from the uncal tip on the left (see Figure 5.26A), consistent with bilateral uncal herniation, more severe on the right side. The midbrain appeared crowded at this level and deformed from right to left see (see Figure 5.26B). The right CN III appeared flattened for about 1.0 cm of its extent in the area adjacent to the right uncus (see Figure 5.26A).

Coronal sections (see Figure 5.26C,D) revealed a necrotic mass centered near the leg region of the motor strip in the right hemisphere, with mild pallor and dramatic enlargement of the right hemisphere white matter consistent with edema. The gyri appeared flattened from being pressed against the inner surface of the skull, and the sulci were effaced. The right uncus could again be seen to have a prominent groove caused by the tentorial edge, and

CASE 5.3 DELAYED UNRESPONSIVENESS AFTER HEAD INJURY

Figure 5.25 Head CT Showing Epidural Hematoma (A–C) Left epidural hematoma causing left uncal transtentorial herniation. Axial images progressing from inferior to superior. (D) Bone windows demonstrating left temporal bone fracture.

(A)

(B)

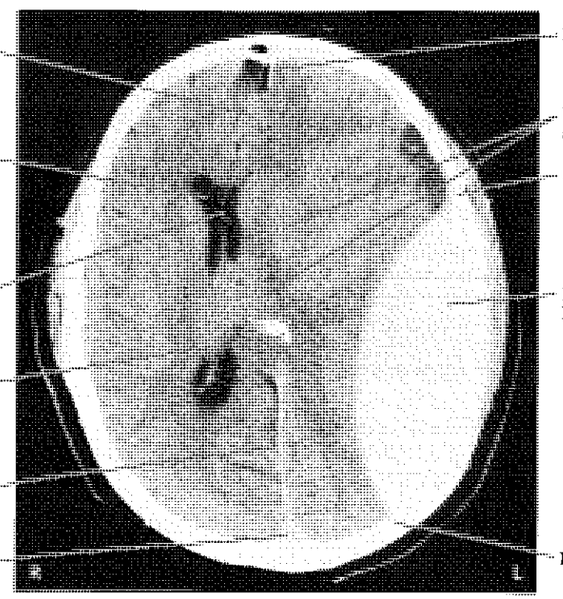

CASE 5.3 *(CONTINUED)*

(C)

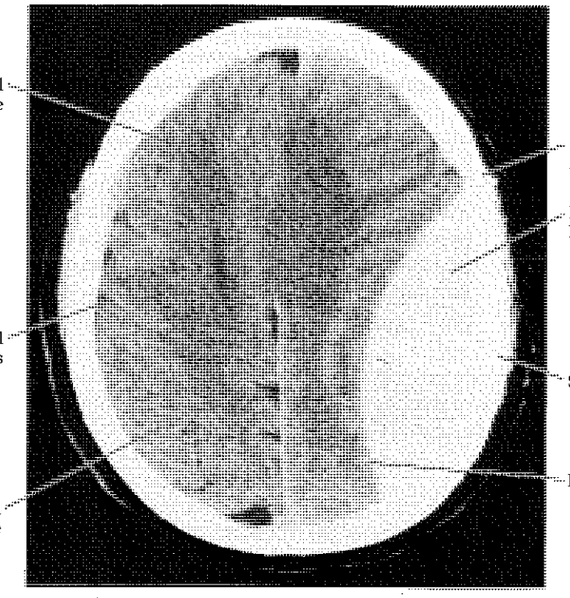

(D)

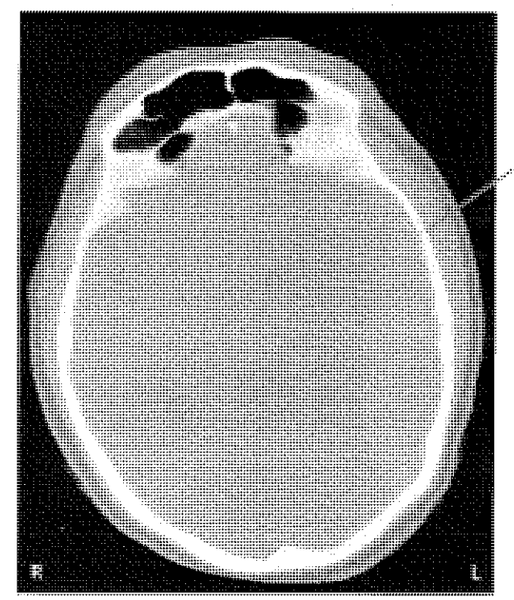

the midbrain–diencephalic junction appeared deformed and compressed (see Figure 5.26C). The right cingulate gyrus was shifted 1.0 cm from right to left of midline, consistent with subfalcine herniation. A brownish area was present in the right medial occipital lobe involving gray and white matter surrounding the calcarine fissure (see Figure 5.26D). This is consistent with an ischemic infarct in the territory of the right posterior cerebral artery, with subsequent petechial hemorrhage. Recall that the posterior cerebral artery passes through the tentorial notch and can therefore sometimes be compressed during transtentorial herniation, causing infarcts (see Figures 5.6, 10.5; KCC 5.4).

Transverse section through the midbrain (see Figure 5.26B) showed it to be markedly elongated in the anterior to posterior dimension, and distorted by compression from right to left. There was an irregular area of dark brown pigmentation in the center of the midbrain. This finding is called a **Duret-Bernard hemorrhage** and can be seen with severe compression of the midbrain and other brainstem areas during transtentorial herniation.

CASE 5.5 SUDDEN COMA AND BILATERAL POSTURING DURING INTRAVENOUS ANTICOAGULATION

MINICASE

A 61-year-old woman presented to the emergency room with 2 hours of left face and arm weakness. On examination at 8:00 A.M., she was fully alert, with mild left face and arm weakness completely sparing the left leg. She had a history of atrial fibrillation, which can cause blood clots to form in the cardiac atria as a result of stasis (see KCC 10.4). For this reason she was taking the oral anticoagulant warfarin (Coumadin). However, blood tests in the emergency room showed that she was not adequately anticoagulated on her current dosage. It was felt that she most likely had an embolus from the heart to the right side of the brain. A head CT within 3 hours of onset was unremarkable. This finding was consistent with the diagnosis, since it can take from 6 to 24 hours for an acute stroke to become visible on CT (see Chapter 4). She was therefore admitted to the hospital and started on the intravenous anticoagulant heparin because this approach can achieve a therapeutic range of anticoagulation more quickly than oral medications can. The patient remained stable throughout the day, but at 10:00 P.M. she was suddenly found to be **unarousable.** Exam was notable for **fixed, midsized pupils, no extraocular movements,** and **bilateral extensor (decerebrate) posturing of both arms and legs.** She was emergently intubated because of shallow respirations.

LOCALIZATION AND DIFFERENTIAL DIAGNOSIS

1. On the basis of the findings shown in **bold** above, where is the lesion located (see Figures 2.16, 2.22, 2.23, 3.5; Table 2.5)?
2. What is the most likely diagnosis?

Discussion

1. The key symptoms and signs in this case are:
   - **Unarousable**
   - **Bilateral fixed pupils and absent eye movements**
   - **Bilateral extensor posturing**

   Coma, together with absent eye movements and absent pupillary reflexes, suggests severe brainstem dysfunction involving the ascending activating systems (see Figure 2.23) as well as CNs III, IV, and VI (see Figure 2.22; Table 2.5). Bilateral extensor posturing signifies that the corticospinal tracts are involved bilaterally (Figure 2.16) but that some brainstem function remains, to enable this abnormal reflex (see Figure 3.5B).
2. Given the recent increase in the patient's anticoagulation therapy, the most likely diagnosis is hemorrhage. The hemorrhage could have occurred in the brainstem itself, or a large hemorrhage above the brainstem could be compressing the brainstem bilaterally through downward herniation (KCC 5.4; Figure 5.18). Another possibility, given her history of atrial fibrillation and recent possible embolic events, is a large brainstem infarct.

Neuroimaging 184

After intubation, the patient was taken for an emergency **head CT** (Figure 5.27). Images from the initial CT on admission are shown in Figure 5.27A–D, images after her change in status are shown in Figure 5.27E–H.

1. What kind of hemorrhage is seen on this CT scan (see KCC 5.6)?
2. Identify the foramen magnum, medulla, and cerebellar tonsils (see Figure 5.27A,B,E,F), as well as the midbrain and uncus bilaterally (see Figure 5.27C,G).
3. What kinds of herniation occurred in this patient (see KCC 5.4; Figure 5.18)?

Discussion

1. This patient has had a massive hemorrhage in the region of initial infarct, an occasional tragic complication of anticoagulation therapy. The hemorrhage is centered deep in the right hemisphere but is so large that essentially the whole brain is compressed. The blood has extended into the ventricular system, and several pockets of blood with CSF–blood levels can be seen (see Figure 5.27H). The cortical sulci and gyri are completely effaced by mass effect, the left ventricle appears dilated from obstructive hydrocephalus, and there is substantial midline shift. On the basis of the large volume of the bleed and the patient's poor level of neurologic function, her prognosis is quite poor.
2. See labels on Figure 5.27.
3. Note that before the hemorrhage, there was a large amount of CSF-filled space surrounding the cervicomedullary junction and caudal medulla at the level of the foramen magnum (Figure 5.27A,B). The cerebellar tonsils can be seen to extend into the cisterna magna at a distance somewhat removed from the medulla. After the hemorrhage, the cerebellar tonsils have been forced downward and inward, compressing the caudal medulla and extending downward through the foramen magnum (Figure 5.27E,F). Thus, **tonsillar herniation** has occurred. In this patient, tonsillar herniation has resulted from a massive supratentorial lesion that produced downward **central herniation** of the entire brainstem, a situation sometimes referred to as a **pressure cone.** At the level of the midbrain in this patient, there was also complete effacement of the basal cisterns and bilateral midbrain compression due to **bilateral uncal transtentorial herniation** (Figure 5.27C,G).

Clinical Course

In view of the patient's grim prognosis, the family decided not to pursue heroic measures, and the patient died the next day.

CASE 5.4 HEADACHE AND PROGRESSIVE LEFT-SIDED WEAKNESS

Figure 5.26 Pathologic Specimens Showing Herniations and PCA Hemorrhagic Infarcts (A) Inferior surface view showing effects of uncal transtentorial herniation on CN III. Herniation is more severe on the right side. (B) Transverse section revealing distortion of the midbrain and Duret–Bernard hemorrhages. (C) Coronal section showing evidence of uncal and subfalcine herniation. Necrotic tumor mass can be seen in the right hemisphere. (D) Coronal sections through occipital lobes with posterior cerebral artery (PCA) territory hemorrhagic infarct caused by compression of the PCA in the tentorial notch.

(A)

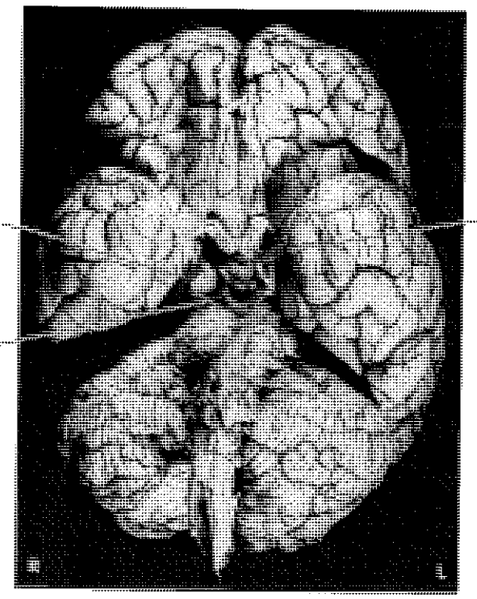

(B)

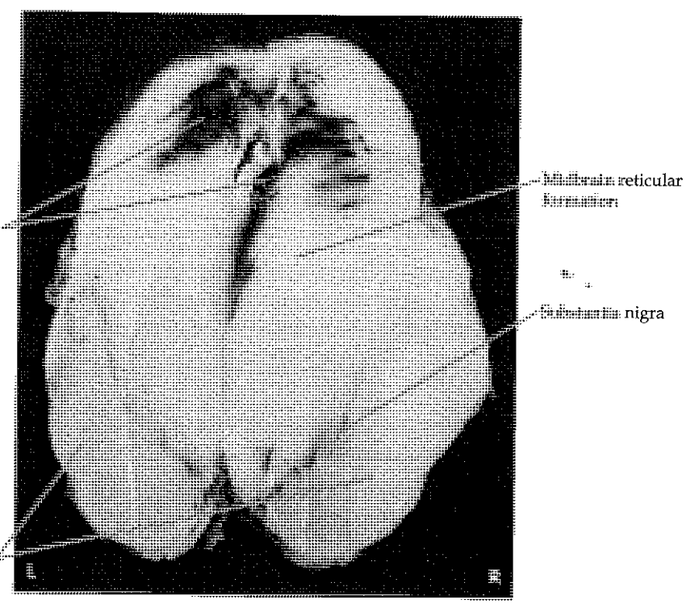

CASE 5.4 *(CONTINUED)*

(C)

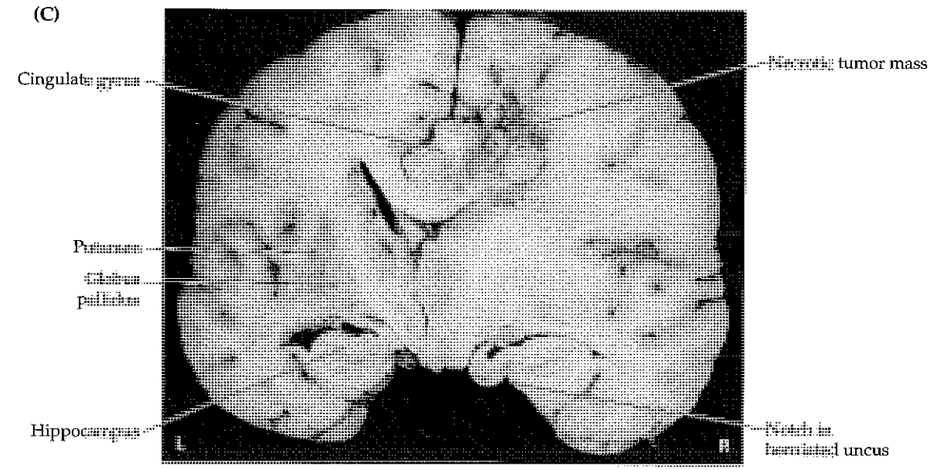

(D)

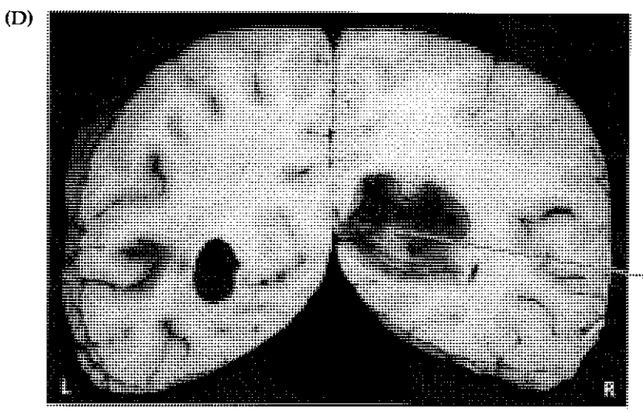

CASE 5.5 SUDDEN COMA AND BILATERAL POSTURING DURING INTRAVENOUS ANTICOAGULATION

Figure 5.27 CT Scan Images Showing Intracranial Hemorrhage Axial CT images progressing from inferior to superior. Baseline scans (A, C, E, G) compared with scans showing catastrophic intracranial hemorrhage with tonsillar and bilateral uncal herniation (B, D, F, H).

Baseline scan

(A)

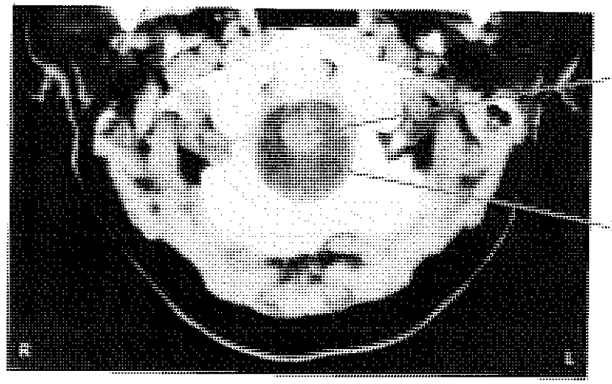

After hemorrhage

(B)

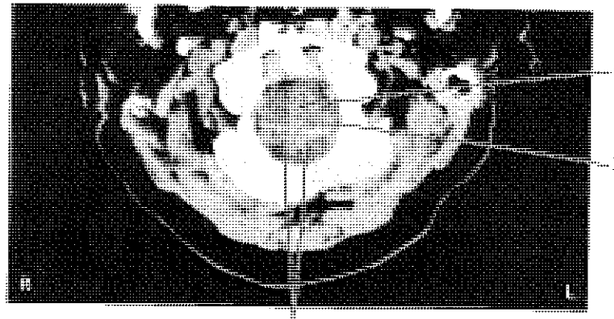

CASE 5.5 *(CONTINUED)*

Baseline scan

(C)

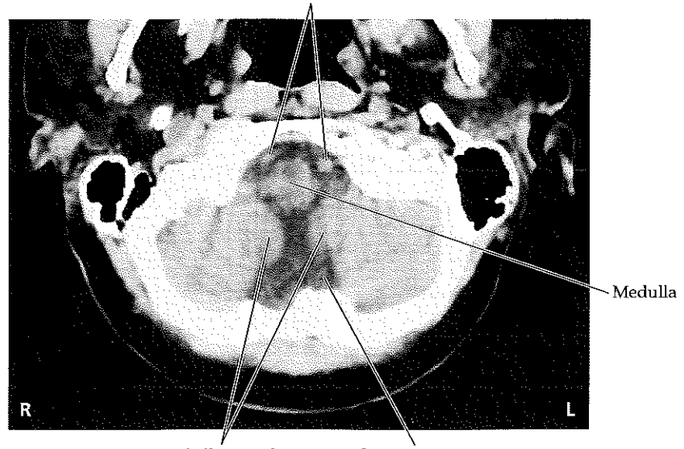

After hemorrhage

(D)

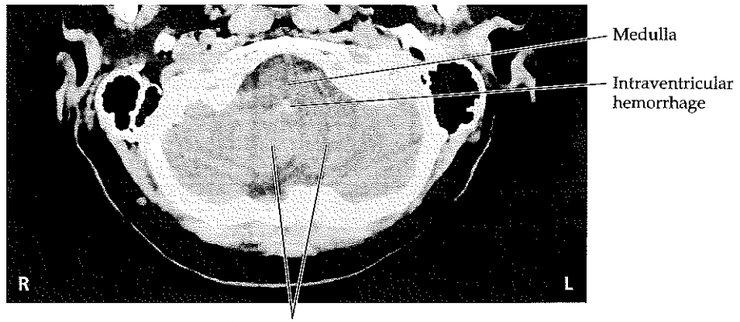

CASE 5.5 *(CONTINUED)*

(E)

Baseline scan

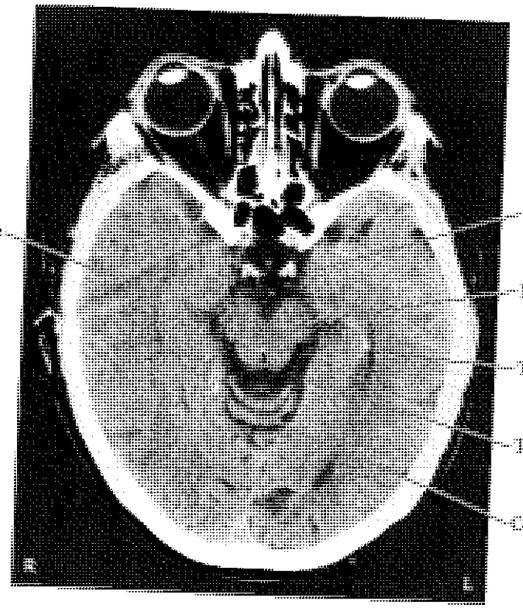

(F)

After hemorrhage

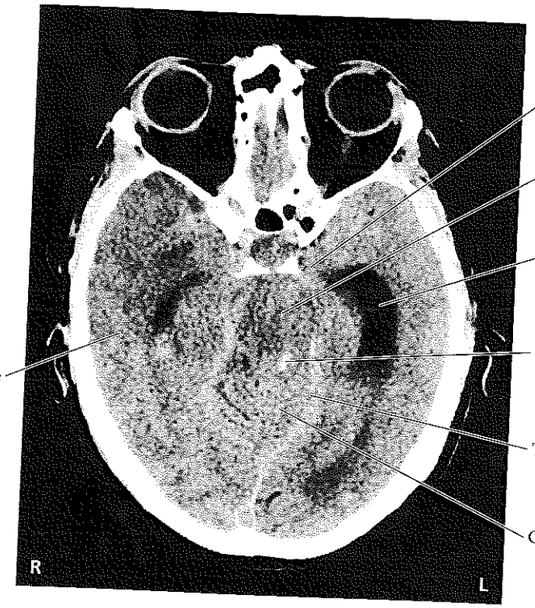

CASE 5.5 *(CONTINUED)*

(G)

Baseline scan

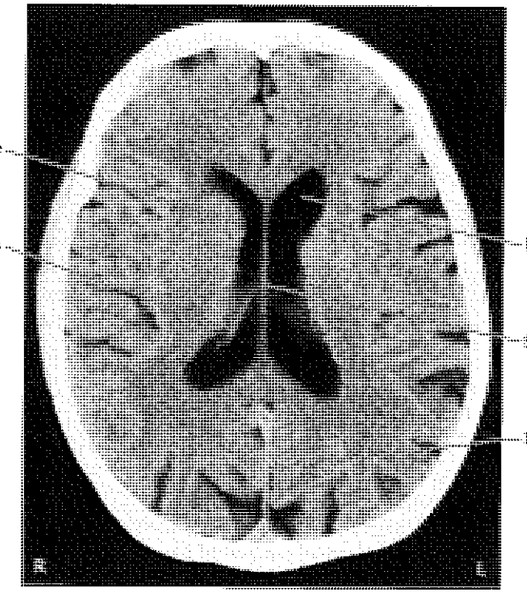

(H)

After hemorrhage

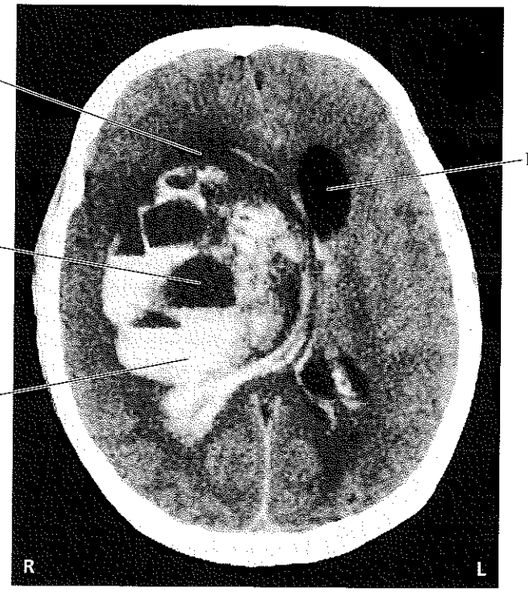

CASE 5.6 SEVERE HEAD INJURY

MINICASE
An 80-year-old man was found lying on the rocks under a 6-foot-high wall near the shoreline. He was conscious and speaking for a brief time before lapsing into a coma. On initial examination he had a right scalp abrasion; 6 mm right pupil and 5 mm left pupil, both nonreactive to light; no corneal reflexes; flexor (decorticate) posturing of the upper extremities to pain (see Figure 3.5A); and upgoing plantar responses bilaterally.

Neuroimaging 190

The patient was brought to the emergency room, where an emergency **head CT** was done, shown in Figure 5.28.

1. What kind of hemorrhage is present (see KCC 5.6)?
2. Severe herniation of what kind can be seen (see KCC 5.4; Figure 5.18)?

Discussion

1. A large, crescent-shaped, hyperdense fluid collection is seen between the right hemisphere and the skull, consistent with acute subdural hematoma. Note that some areas of decreased density are present toward the top of the hematoma, likely representing CSF (darker areas) and nonclotted blood or blood mixed with CSF (gray areas). Small amounts of blood can also be seen extending into the sulci, consistent with subarachnoid hemorrhage. There is also a small amount of blood in the right lateral ventricle (see Figure 5.28A).
2. Marked subfalcine herniation is present, with extrusion of a substantial amount of the right hemisphere under the falx. In addition to the findings already described, lower images on the CT demonstrated right transtentorial herniation and a right frontotemporal fracture.

Clinical Course

The patient was taken immediately to the operating room, and the subdural hematoma was evacuated. Unfortunately, he did not improve postoperatively. A follow-up CT scan was done the next day (see Figure 5.28B).

The subdural hematoma is no longer present, and there is no longer subfalcine herniation or midline shift. However, there are now two strips of hypodensity located on either side of the falx. These represent ischemic infarctions in the territory of the anterior cerebral arteries bilaterally (see Figure 10.6). Some spots of hemorrhage are located within these infarcts, suggesting hypoperfusion causing infarction, followed by reperfusion with hemorrhage into necrotic areas. The anterior cerebral arteries (see Figure 2.26C) probably were trapped under the falx by the severe degree of subfalcine herniation, leading to infarction and, later, reperfusion injury once the herniation was relieved.

The patient continued to decline medically and neurologically over the following days, and eventually died 8 days after admission.

CASE 5.7 A CHILD WITH HEADACHES, NAUSEA, AND DIPLOPIA

CHIEF COMPLAINT
An 11-year-old girl was brought to the pediatrician's office because of worsening headaches, nausea, and diplopia during the past week.

HISTORY
The patient was healthy until 1 week ago, when she developed persistent bifrontal **headaches and nausea.** Both symptoms **gradually worsened,** and for the past 2 days she has had multiple episodes of **vomiting.** Four or 5 days ago she also noticed **horizontal diplopia when looking to the left.** She denied any other symptoms. Her birth and developmental history were unremarkable, according to the parents. At the time of her appointment she was a sixth-grade honor student.

PHYSICAL EXAMINATION
Vital signs: T = 98.8°F, P = 76, BP = 120/68, R = 16.
Head circumference: 54 cm (75th percentile for age).
Neck: Supple with no bruits.
Lungs: Clear.
Heart: Regular rate with no murmurs, gallops, or rubs.
Abdomen: Normal bowel sounds; soft, nontender.
Extremities: Normal.
Neurologic exam:
MENTAL STATUS: **Alert and oriented × 3. Normal language and praxis.**
CRANIAL NERVES: **Pupils 5 mm, constricting to 3 mm with light bilaterally. Ophthalmoscopic exam:** Bilateral papilledema **(see Figure 5.17). Extraocular movements:** Left eye did not fully abduct on left lateral gaze. **Otherwise, intact horizontal and vertical eye movements, and intact convergence. Visual fields full. Facial sensation intact. Intact corneal reflex bilaterally. Face symmetric. Hearing normal to finger rub. Normal gag and normal palate elevation. Normal sternomastoid strength. Tongue midline.**
MOTOR: No pronator drift. Normal tone. Power 5/5 throughout.
SENSORY: Intact light touch, pinprick, joint position sense, and vibration sense.
REFLEXES:

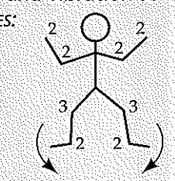

COORDINATION: Normal.
GAIT: Normal.

LOCALIZATION AND DIFFERENTIAL DIAGNOSIS
1. Horizontal diplopia with incomplete abduction of the left eye on left lateral gaze can be caused by dysfunction of which cranial nerve or which extraocular muscle (see Table 2.5; Figure 2.22)?
2. Headaches, nausea, vomiting, papilledema, and horizontal diplopia are signs of what disorder of the intracranial space (see KCC 5.3)? Given this patient's age and the gradually worsening symptoms over the course of a week, what are some possibilities for the diagnosis (see KCC 5.1, 5.7–5.9)?

Discussion

1. The key symptoms and signs in this case are:
   - **Headaches, nausea, and papilledema**
   - **Horizontal diplopia and incomplete abduction of the left eye when looking to the left**

   Dysfunction of the left abducens nerve (CN VI) or the left lateral rectus muscle could cause incomplete abduction of the left eye on left lateral gaze, and horizontal diplopia (see KCC 13.4).
2. This patient has worrisome signs of elevated intracranial pressure (see KCC 5.3). Interestingly, the abducens palsy produced by mildly elevated intracranial pressure can be unilateral (on either side), and may become bilateral with more severe pressure elevations.

   The progressively worsening signs of elevated intracranial pressure in this patient could be caused by a mass lesion such as a brain tumor (see KCC 5.8), hydrocephalus (see KCC 5.7), or pseudotumor cerebri (see KCC 5.1). Other, less likely possibilities include a slowly developing intracranial infection (see KCC 5.9) or perhaps a coagulation disorder causing sagittal sinus thrombosis (see Chapter 10).

CASE 5.6 SEVERE HEAD INJURY

Figure 5.28 CT Scan Images Showing Subfalcine Herniation and Anterior Cerebral Artery Infarcts (A) Subfalcine herniation caused by acute right subdural hematoma. (B) Follow-up scan 1 day later (following surgical removal of the hematoma), showing bilateral anterior cerebral artery infarcts.

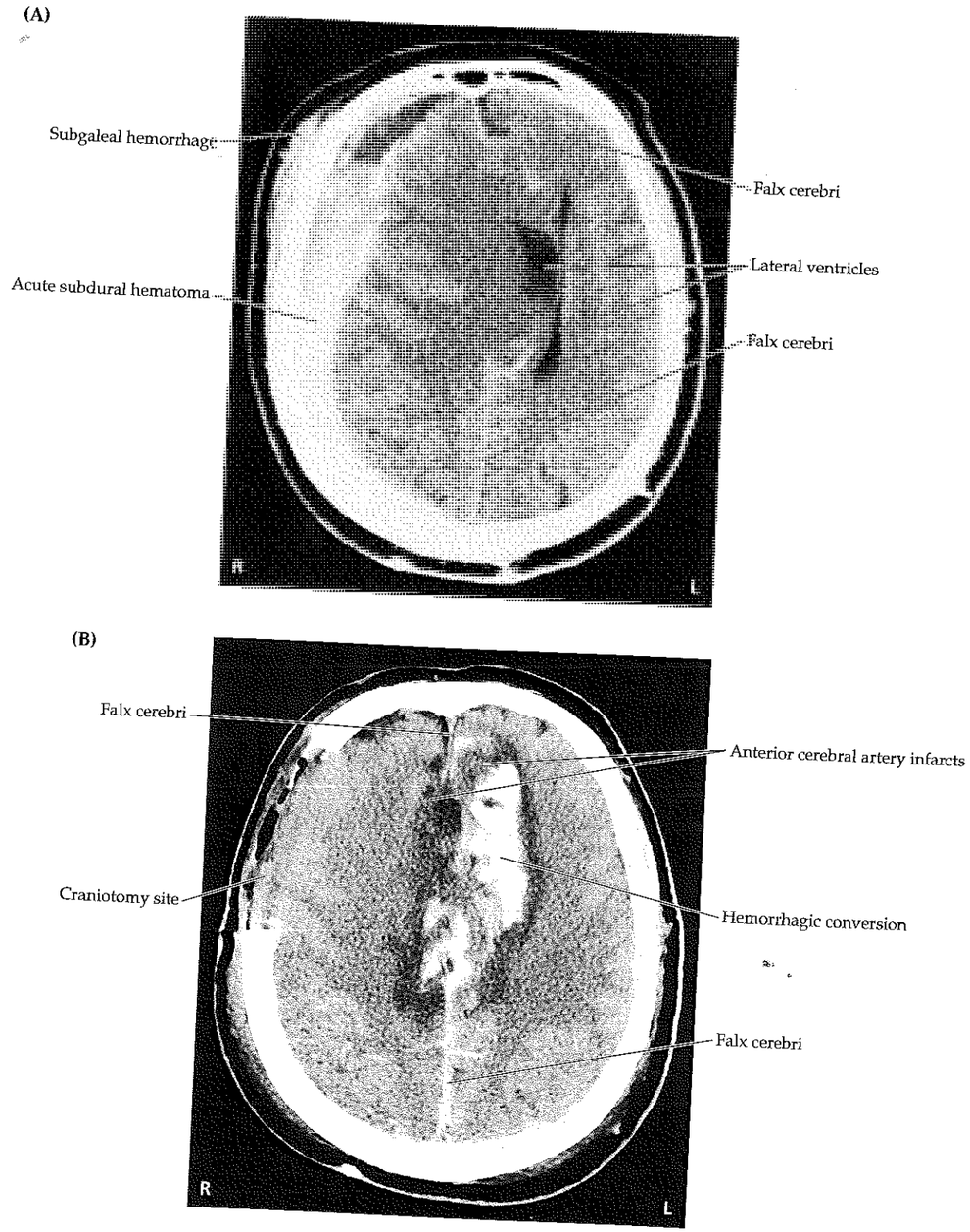

Neuroimaging 192

On the basis of the patient's symptoms and signs, the pediatrician decided to admit her to the hospital and ordered an **MRI scan** to be performed the same day (Figure 5.29).

1. Are these T1-, T2-, or proton density–weighted images (see Figure 4.6)? Are they horizontal, coronal, or sagittal (see Figure 2.5)?
2. Cover the labels in Figure 5.29A and B and identify as many structures as possible. In particular, review the pathway of CSF flow (see Figures 5.10, 5.11) from synthesis to reabsorption by identifying the following: choroid plexus, occipital and frontal horns of the lateral ventricles, region of foramen of Monro, third ventricle, cerebral aqueduct (of Sylvius), fourth ventricle, cisterna magna, foramen magnum, and finally, superior sagittal sinus.
3. Gadolinium was given intravenously for the image shown in Figure 5.29B, but not for that in Figure 5.29A. Describe the location of the mass lesion. Does the mass enhance with gadolinium?
4. What is the cause of the elevated intracranial pressure (see KCC 5.3) in this patient? Which ventricles appear dilated, and why?

Discussion

1. The TR (repetition time) and TE (echo time) are both relatively short, so these are T1-weighted images (see Chapter 4). Recall that in T1-weighted images CSF appears dark, and white matter appears relatively bright compared to gray matter, thus resembling a true brain section. Figure 5.29A is a sagittal section near the midline; Figures 5.29B and C are horizontal images.
2. See labels on Figure 5.29A,B. Compare to Figures 4.13 and 4.15.
3. An approximately 2-cm-diameter roundish mass lesion can be seen in the posterior third ventricle, located between the thalami (see Figure 5.29B) and extending slightly into the rostral midbrain (see Figure 5.29A). The mass appears bright in Figure 5.29B but dark in Figure 5.29A, demonstrating enhancement with gadolinium. Recall that enhancement (see Chapter 4) suggests increased vascularity, or breakdown of the blood–brain barrier that can be seen with inflammation, tissue damage, or tumors.
4. This patient has elevated intracranial pressure caused by hydrocephalus (see KCC 5.7). The mass lesion is located in the posterior third ventricle and blocks the **iter,** or opening, of the aqueduct of Sylvius, preventing CSF outflow into the fourth ventricle (see Figures 5.10, 5.11). The lateral ventricles and the third ventricle are therefore dilated, but the fourth ventricle is not. In the sagittal view (see Figure 5.29A) the corpus callosum appears somewhat thinned out and ballooned upward from the dilated ventricles. Note also that there are some regions of decreased intensity in the white matter adjacent to the frontal and occipital horns (see Figure 5.29B). This represents **transependymal absorption of CSF** from the ventricles into the white matter and is a sign that hydrocephalus has developed relatively recently and is severe. In addition, if the patient had hydrocephalus in infancy before closure of the cranial sutures, she may have had an enlarged head circumference; however, this patient's head circumference was normal, again suggesting the hydrocephalus had developed recently.

Clinical Course

The patient was taken to the operating room the day after admission for placement of a right **ventriculoperitoneal shunt** (see KCC 5.7). A small incision was made in the scalp over the right frontal area. A second small incision was made in the abdominal skin and extended down to the peritoneum. The shunt tubing was passed under the skin through the subcutaneous tissues extending from the scalp incision down to the abdomen. A hole was

CASE 5.7 A CHILD WITH HEADACHES, NAUSEA, AND DIPLOPIA

Figure 5.29 MRI Scan Images Showing Pineal Tumor and Recovery T1-weighted images with TR = 450, TE = 11. (A) Sagittal image. (B) Axial image with intravenous gadolinium, showing pineal tumor obstructing iter (opening of cerebral aqueduct) and causing noncommunicating hydrocephalus. (C) Follow-up axial images with gadoliniom 8 months after treatment.

(A)

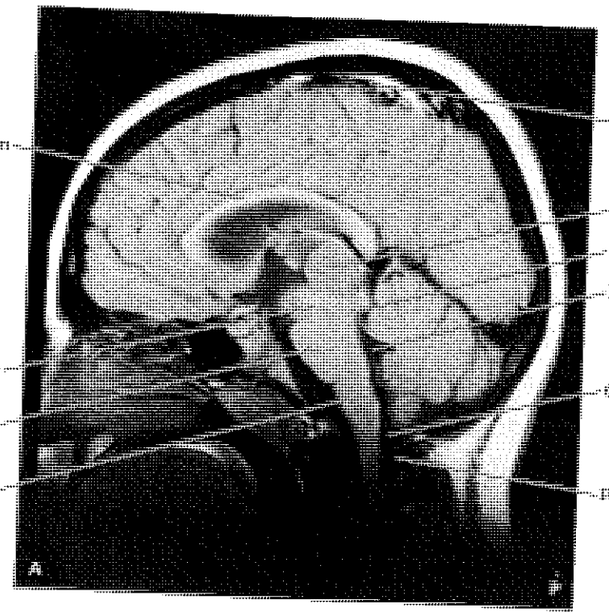

(B)

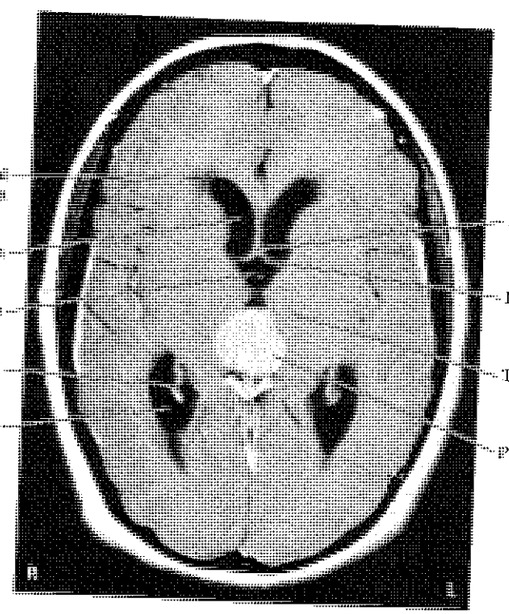

CASE 5.7 *(CONTINUED)*

(C)

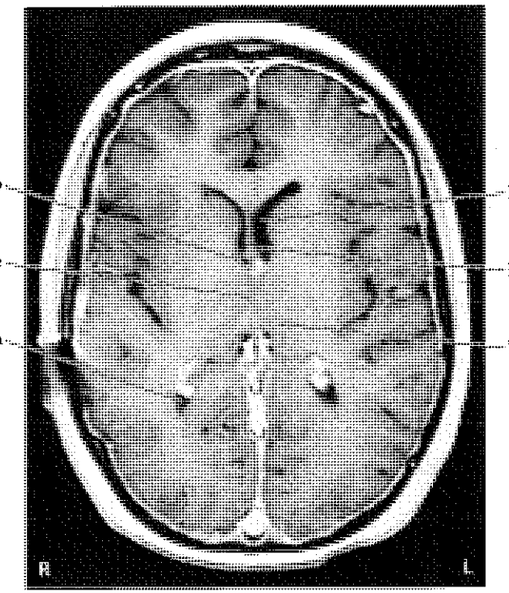

drilled through the skull, the dura was opened, and a catheter was passed through the right frontal lobe into the right lateral ventricle at a depth of approximately 6 cm from the surface. There was good flow of clear CSF under markedly elevated pressure. The catheter was connected to the shunt tubing through the scalp incision. Good flow was observed from the distal end of the tubing at the abdominal incision before it was inserted into the peritoneal cavity, and both incisions were closed with sutures. The shunt system contains a one-way flow valve to prevent fluid from traveling in the wrong direction. Postoperatively the patient's headaches and nausea resolved immediately, and her sixth-nerve paresis resolved more slowly but recovered completely by 2 months after surgery.

One week after admission, she was taken back to the operating room for a biopsy of the mass lesion. Because of its location deep within the brain adjacent to the midbrain, open surgical resection or biopsy was not feasible. Therefore, a **stereotactic needle biopsy** (see KCC 16.4) was performed.

The results of the biopsy in our patient showed that she had a primitive neuroectodermal tumor (PNET, see Table 5.6) of the pineal region, also called a pineoblastoma. This is an uncommon brain tumor, which often responds well to treatment but can eventually be fatal. The patient was treated with radiation and chemotherapy and returned to school several months later. A follow-up MRI scan 8 months after initial presentation showed nearly complete disappearance of the tumor with therapy (see Figure 5.29C). The hydrocephalus had also completely resolved. At 3-year follow-up, she continued to do well, with no further growth of the tumor.

Related Case. An MRI scan from another patient with hydrocephalus from obstruction at the iter is shown in Figure 5.30. This patient was a 42-year-old

CASE 5.7 RELATED CASE

Figure 5.30 MRI Scan Images Showing Cysticercosis Obstructing Iter and Causing Noncommunicating Hydrocephalus T1-weighted images. (A–C) Axial images. (D) Sagittal image. (E) Coronal image.

(A)

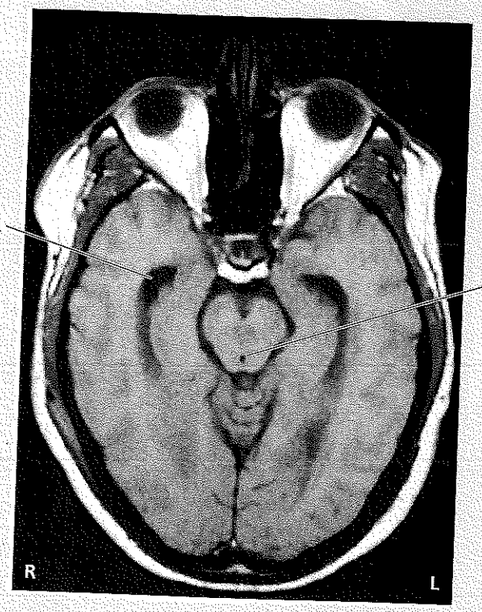

(B)

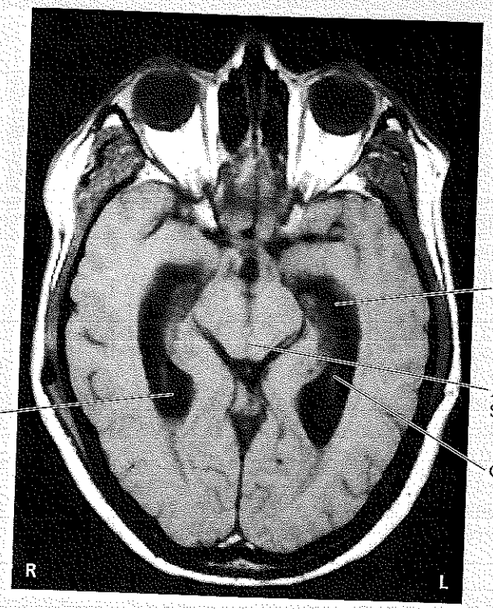

CASE 5.7 RELATED CASE (*CONTINUED*)

(C)

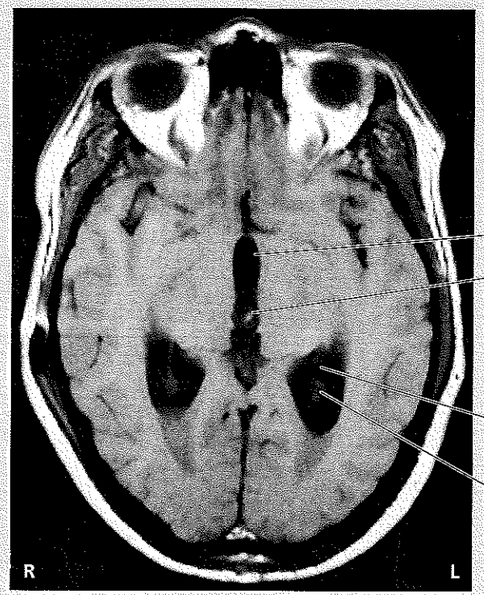

(D)

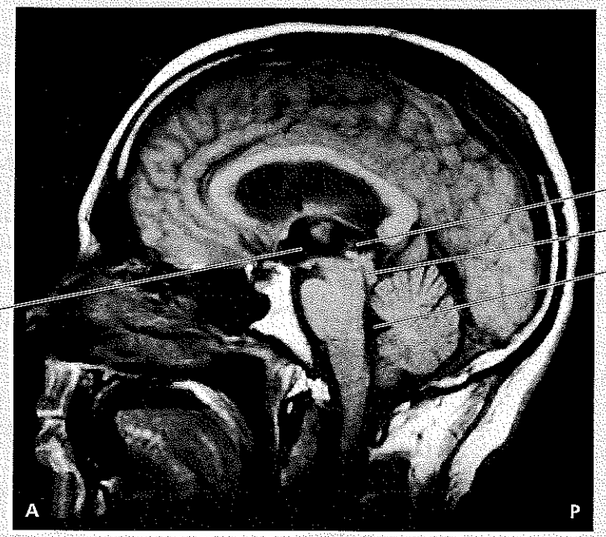

CASE 5.7 RELATED CASE (*CONTINUED*)

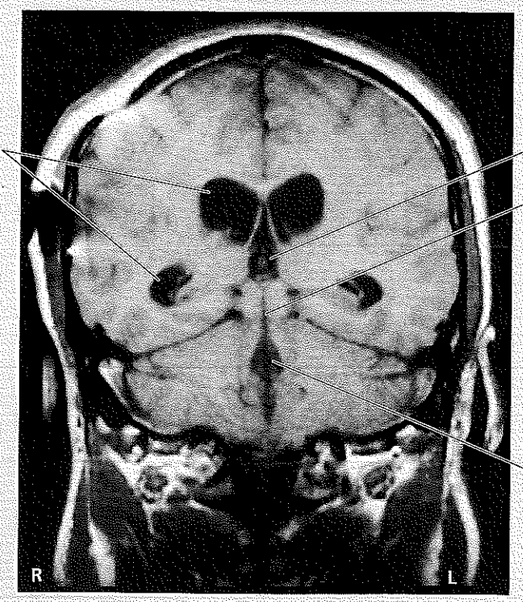

Portuguese-speaking man brought to the emergency room by his girlfriend after he became increasingly difficult to arouse, as well as agitated and confused over the course of 1 day. He had a past history of seizures. A CT scan showed multiple small calcifications consistent with CNS cysticercosis (see KCC 5.9). Note the presence of a cyst obstructing the iter visible on the MRI scan in the horizontal (see Figures 5.30A–C), sagittal (see Figure 5.30D), and coronal (see Figure 5.30E) views. He was treated by ventriculoperitoneal shunting (see KCC 5.7) and appropriate antiparasitic medication and made a full recovery.

CASE 5.8 HEADACHES AND PROGRESSIVE VISUAL LOSS

MINICASE

A 51-year-old man came to an ophthalmology appointment complaining of 8 months of progressive **visual loss** and **headaches.** He was found to have bilateral mild **papilledema,** with some pallor of the right optic disc, visual fields with **enlarged blind spots,** and **concentric loss of the peripheral visual fields in both eyes** (he could see only the center of the visual field with either eye; see Figure 11.16A). The remainder of his neurologic exam was normal.

LOCALIZATION AND DIFFERENTIAL DIAGNOSIS

1. Headaches, papilledema, and visual loss of this kind are seen in what syndrome?
2. What is the appropriate test to perform next?

Discussion

1. Headaches with papilledema are worrisome signs of elevated intracranial pressure (see KCC 5.3). Concentric visual loss can be caused by certain ophthalmologic conditions, but also by chronic or intermittent elevated intracranial pressure (see Table 5.3). Elevated intracranial pressure compresses the optic nerve, causing damage especially to the more superficial fibers nearest the nerve sheath, thus leading to concentric visual loss. Elevated intracranial pressure in this patient present over several months would most likely be caused by hydrocephalus (see KCC 5.7) or a mass lesion (see KCC 5.2), but it could also be caused by pseudotumor cerebri, sagittal sinus thrombosis, or other disorders.
2. The best test to perform next would be an MRI scan.

Neuroimaging 198

The attending ophthalmologist ordered an **MRI scan** (Figure 5.31).

1. Cover the labels on Figure 5.31 and identify the plane of section, image type (T1-, T2-, or proton density–weighted), and the labeled structures for each image (see Figures 2.5, 4.6). Again, review the pathway of CSF flow through the ventricles (see Figures 5.10, 5.11).
2. Which ventricles are dilated, and what does this suggest about the site of the obstruction?

Discussion

1. All images have relatively short TR and TE and are therefore T1-weighted (see Chapter 4). Figure 5.31A is coronal, 5.31B axial, and 5.31C sagittal.
2. The lateral ventricles are markedly dilated, while the third and fourth ventricles are not, suggesting obstruction bilaterally at the foramina of Monro. In fact, a small mass lesion can be identified in the anterior third ventricle, just underneath the fornix, obstructing the foramina of Monro in Figure 5.31A. This is the typical location and appearance of a colloid cyst of the third ventricle, a benign tumor that causes symptoms mainly through intermittent and sometimes fatal hydrocephalus (see KCC 5.7). Note the prominent dilation of the lateral ventricles bilaterally (see Figure 5.31).

Clinical Course

The patient was admitted to the hospital for surgery. An incision was made in the right scalp, and a large bone flap was carefully removed, exposing the dura over the right hemisphere and a portion of the superior sagittal sinus in the midline. The dura was opened in a longitudinal fashion to the right of the midline. A large bridging vein (see Figure 5.1) was encountered entering the superior sagittal sinus from the right side, and care was taken not to disrupt it. The dura was folded back, revealing the right cerebral cortex and the falx cerebri in the midline. The cortex was gently retracted laterally off the falx along the medial surface of the hemisphere, allowing the surgeon to peer down onto the top surface of the corpus callosum. The pericallosal vessels (see Figure 4.16) were carefully moved to either side, and a 2 cm longitudinal incision was made in the corpus callosum, providing access to both lateral ventricles, with the septum pellucidum visible in the midline. An operating microscope was used for the remainder of the procedure. The colloid cyst was easily visible through the right foramen of Monro and was gently aspirated, with care taken to avoid damaging the fornix. At the end of the procedure, all visible colloid cyst was removed, and excellent flow of irrigant

CASE 5.8 HEADACHES AND PROGRESSIVE VISUAL LOSS

Figure 5.31 MRI Scan Images Showing Colloid Cyst Causing Obstructive Hydrocephalus Colloid cyst of the third ventricle obstructing foramina of Monro and causing noncommunicating obstructive hydrocephalus. T1-weighted images with TR = 450, TE = 11. Coronal (A), axial (B), and sagittal (C) views. The coronal scan (A) was performed with intravenous gadolinium.

(A)

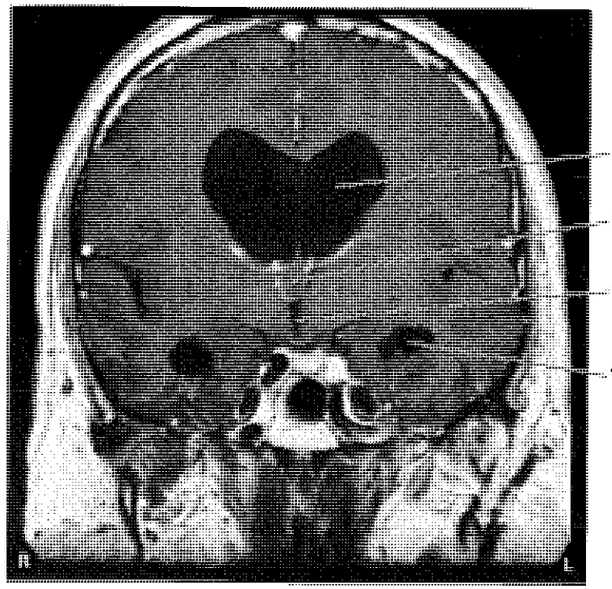

(B)

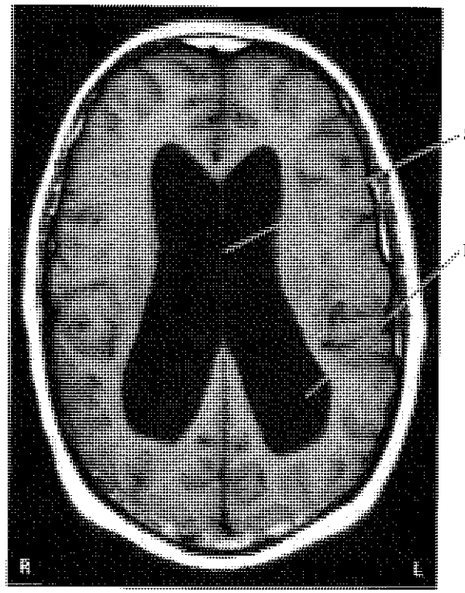

CASE 5.8 *(CONTINUED)*

(C)

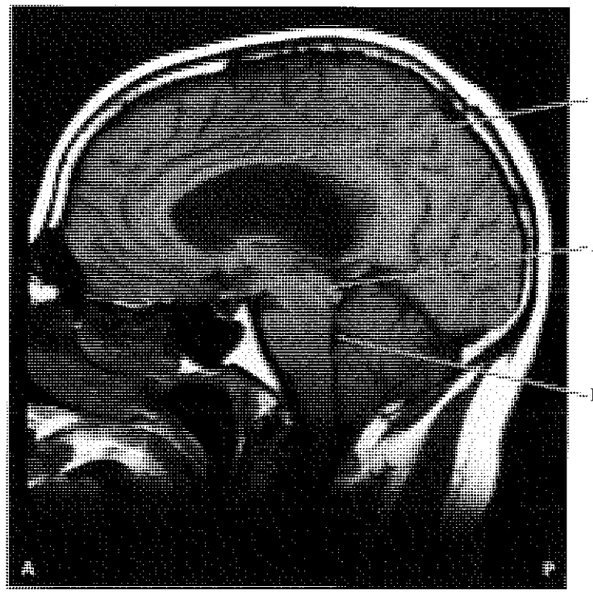

was attained through both foramina of Monro. The dura was then closed and the bone flap replaced before closing the scalp wound.

Postoperatively the patient did quite well, with no further headaches and no further worsening or perhaps even some mild improvement in his vision over the following months. An MRI done 1 week after surgery showed marked improvement in the hydrocephalus. The hole made in the corpus callosum caused no functional deficits because of its relatively small size (see KCC 19.8).

CASE 5.9 AN ELDERLY MAN WITH PROGRESSIVE GAIT DIFFICULTY, COGNITIVE IMPAIRMENT, AND INCONTINENCE

MINICASE

A 76-year-old man was admitted to the hospital because of progressive **gait unsteadiness, memory difficulty,** and **incontinence.** His gait unsteadiness developed over the course of about 1 year, beginning with a shuffling stride and difficulty rising from a chair. This unsteadiness progressed until he required a cane, and eventually assistance from another person, in order to ambulate. Urinary incontinence began 4 months prior to admission, and his family noted the onset of memory problems around the same time. Examination on admission was notable for recall of only one of three objects at 5 minutes, and an unsteady, shuffling gait, the patient barely lifting his feet off the floor.

Neuroimaging 201

A **head CT** was performed (Figure 5.32).

1. Cover the labels on Figure 5.32 and identify as many structures as possible on each image. Describe the appearance of the ventricles. Is this appearance due to generalized brain atrophy or to hydrocephalus (see KCC 5.7)?
2. What syndrome fits the clinical history, exam, and CT scan of this patient?

Discussion

1. See the labels on Figure 5.32 for specific structures. The lateral ventricles, third ventricle, and even fourth ventricle appear enlarged. Note that in patients with brain atrophy, both the sulci and the ventricles are proportionately increased in size. In hydrocephalus, however, the ventricles are increased out of proportion to the amount of sulcal prominence. In our patient the sulci are slightly prominent, while the ventricles are markedly enlarged, making this hydrocephalus (see KCC 5.7). This diagnosis can be best appreciated if you look near the top of the brain (see Figure 5.32D), where the sulci are not especially prominent in this patient. Patients with generalized brain atrophy usually have enlarged sulci in this area.
2. This patient has the clinical triad of shuffling "magnetic gait," incontinence, and mental decline, together with a head CT strongly supporting the diagnosis of normal-pressure hydrocephalus (see KCC 5.7).

Clinical Course

The patient was evaluated before and after CSF removal by lumbar puncture (see KCC 5.10). Two large-volume lumbar punctures were performed—one on hospital day 1, and one on hospital day 12—with 45 cc and 33 cc of CSF removed, respectively. Locomotion was evaluated before and after each lumbar puncture (see table), as well as on the intervening days (not shown). After each lumbar puncture, the patient showed dramatic improvement in the speed and stability of his gait, as well in his ability to stand up from a lying position. The improvement lasted several days after each lumbar puncture, but then his condition gradually worsened again. It is not known why a single removal of 30 to 40 cc of CSF by lumbar puncture should have an effect persisting longer than the time it takes to replace this volume of CSF (a few hours). It has been suggested that this extended effect may result from a small tear in the dura created by the lumbar puncture that continues to leak for a period of time.

Because of the patient's excellent but temporary response to lumbar puncture, and the clinical setting consistent with normal-pressure hydrocephalus, a right ventriculoperitoneal shunt was placed (see KCC 5.7). The result was lasting improvement. When the patient was seen in the office 7 months later, his gait was more stable, he lifted his feet higher off the floor, and he walked 15 feet in 9 seconds. He no longer had urinary incontinence. His memory and attention remained mildly impaired, however. For example, he recalled only three of six objects after 5 minutes.

Effects of CSF Removal via Lumbar Puncture (LP) on Locomotion

	Day 1, pre-LP	Day 2, 24 hours post-LP	Day 12, pre-LP	Day 12, 4 hours post-LP
Time to walk 15 feet (s; average of 3 trials)	10.5	6.5	14	8
Number of steps to walk 15 feet (average of 3 trials)	10	6	—	—
Number of steps to turn 180°	9	10	—	—
Time from lying to standing (s; 1 trial)	28	14	42	15
Subjective evaluation	Unsteady, shuffling	Improved stability	Very unsteady	Improved stability

CASE 5.9 AN ELDERLY MAN WITH PROGRESSIVE GAIT DIFFICULTY, COGNITIVE IMPAIRMENT, AND INCONTINENCE

Figure 5.32 Head CT Showing Dilated Ventricles Typical of Normal-Pressure Hydrocephalus (A–D) Axial images progressing from the inferior to superior direction.

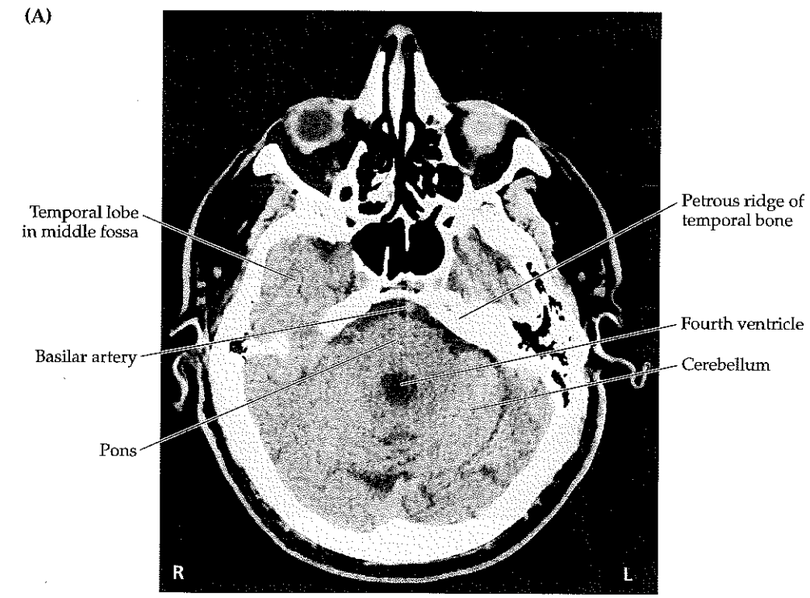

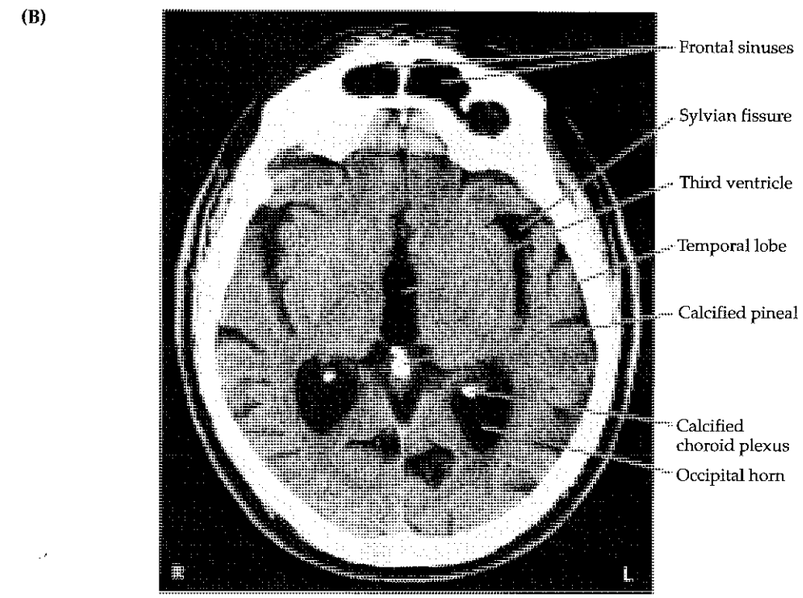

CASE 5.9 *(CONTINUED)*

(C)

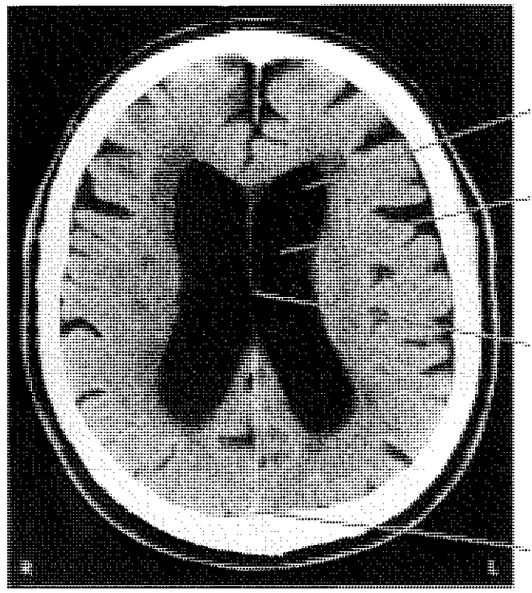

(D)

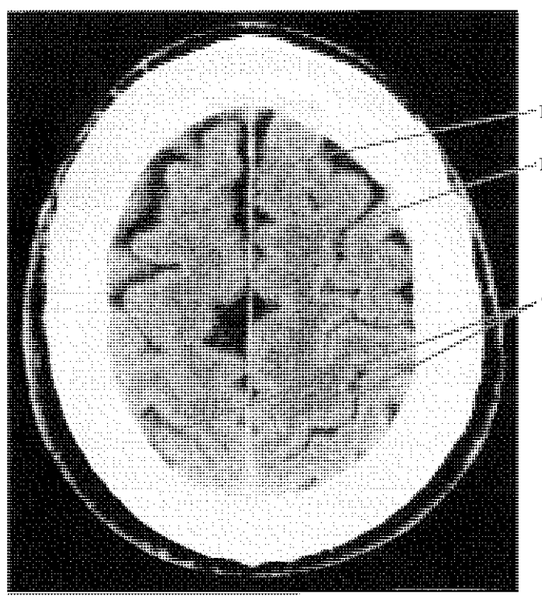

CASE 5.10 A YOUNG MAN WITH HEADACHE, FEVER, CONFUSION, AND STIFF NECK

CHIEF COMPLAINT

A 28-year-old man was brought to the emergency room with 1 day of worsening headache, fever, confusion, and stiff neck.

HISTORY

Previously healthy, the patient awoke on the day of admission at about 4:00 A.M. with chills and body aches. By noon he was breathing quickly and had nausea and vomiting, but then he felt better and took a nap. He awoke at 3:00 P.M. with a midfrontal **headache, photophobia,** and **stiff neck with a temperature of 102°F.** He took some acetaminophen and went to a party that evening. However, by 9:00 P.M. he appeared **confused,** talking about "ragtime" and "skirt party pick me up." His girlfriend then brought him to the emergency room by taxicab.

The patient had no known recent exposure to anyone ill and no HIV risk factors. He had visited a friend in Mississippi the previous week but had not recently traveled abroad, and he had not had any recent insect bites or rashes. He had no exotic pets. He worked as an air force pilot. He was not taking any medications and had no known drug allergies.

PHYSICAL EXAM

General appearance: Acutely ill–appearing young man lying on a stretcher.
Vital signs: **T = 101.7°F,** P = 110, BP = 136/84, R = 24.
Head: Normal tympanic membranes bilaterally. Dry oral mucosa. No oral thrush.
Neck: **Marked nuchal rigidity.** No bruits. No adenopathy.
Lungs: Clear.
Heart: Regular rate with no murmurs, gallops, or rubs.
Abdomen: Normal bowel sounds; soft, nontender.
Extremities: Normal.
Skin: **Nonblanching, purplish 2 to 3 mm petechiae scattered on arms, legs, and chest.**

Neurologic exam:
MENTAL STATUS: Lethargic **but arousable. Normal speech. Oriented to correct month and year, but not to date or name of hospital. The patient said he is a pilot for Northwest, but his *father* is actually a pilot for that airline. He did not recall where he lives. He spelled "w-o-r-l-d" forward but not backward.**
CRANIAL NERVES: Pupils 6 mm, constricting to 3 mm with light bilaterally. Ophthalmoscopic exam: Normal fundi bilaterally. Extraocular movements intact. Visual fields full. Facial sensation intact. Face symmetric. Hearing normal to finger rub bilaterally. Palate elevation normal. Tongue midline.
MOTOR: Normal tone. Power 5/5 throughout, with intermittent cooperation.
SENSORY: Intact light touch, pinch.
REFLEXES:

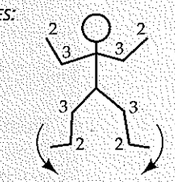

COORDINATION: Normal finger–nose–finger testing.
GAIT: Not tested.

LOCALIZATION AND DIFFERENTIAL DIAGNOSIS

1. Irritation of what structure(s) is suggested by the signs and symptoms seen in this patient? What is the most likely diagnosis?
2. What are the most likely pathogens, given this patient's age and history? What are some other possibilities?
3. What diagnostic test should be done, and what treatment should be started without delay?

Discussion

1. Headache, fever, photophobia, and nuchal rigidity are strongly suggestive of meningeal irritation (see Table 5.5). The lethargy and confusion suggest a process causing diffuse cerebral dysfunction as well (encephalopathy; see KCC 19.15). The acute progressive time course of this patient's presentation strongly suggests acute bacterial meningitis, or possibly viral meningoencephalitis.
2. Acute bacterial meningitis in immunocompetent adults is usually caused by *Streptococcus pneumoniae* or *Neisseria meningitidis,* but it can also be caused by *Listeria monocytogenes* (see Table 5.8). The purplish skin lesions are suggestive of *N. meningitidis,* although they can also be seen in rickettsial infections. Viral meningoencephalitis, including herpes encephalitis, should also be considered. Postinfectious meningitis or other less common forms of meningitis are also possible.

3. Patients with acute infectious meningitis can deteriorate within a matter of hours or even minutes, so rapid evaluation and treatment are essential. A head CT and lumbar puncture (see KCC 5.10) should be performed to narrow the diagnosis and help determine the most appropriate therapy (see Tables 5.7, 5.8). However, antimicrobial treatment should not be delayed if for any reason a lumbar puncture cannot be performed immediately.

Initial Clinical Course

The patient was started on intravenous ceftriaxone and ampicillin. A head CT was normal, and lumbar puncture was performed successfully about 20 minutes (see table). Blood toxicology screen was negative, and other routine blood tests were unremarkable. Chest X-ray was normal.

Results of Lumbar Puncture

Tube number	Red blood cells (per mm^3)	White blood cells (per mm^3)	Percent PMNs[a]	Percent lymphocytes
1	230	3280	100	0
4	220	2030	99	1

[a] PMNs = polymorphonuclear leukocytes.
Protein: 714 mg/dl; **Glucose**: <20 mg/dl.

1. From what space is CSF removed to perform lumbar puncture, and what two meningeal layers is it bounded by (see Figure 5.22B)? What landmark is used to enter the lumbar cistern at the appropriate level (see Figure 5.22A)?
2. What do the results of the CSF analysis in this patient suggest (compare Table 5.7)?

Discussion

1. In lumbar puncture, CSF is removed from the subarachnoid space of the lumbar cistern, bounded by the pia and the arachnoid (see Figures 5.1, 5.22B). The iliac crest is used as a landmark to enter the lumbar cistern at the L4–L5 interspace, well below the conus medullaris of the spinal cord (see KCC 5.10; Figure 5.22).
2. The CSF in this patient shows a very high protein level, low glucose level, and very high white blood cell count, consisting mostly of polymorphonuclear cells, consistent with acute bacterial meningitis (see Table 5.7).

   The CSF cultures grew no organisms. However, blood cultures performed prior to the administration of antibiotics grew *Neisseria meningitidis*. By 1 day after admission the patient's fevers had stopped and his mental status cleared. He was treated with a course of intravenous antibiotics and made an excellent recovery and was discharged 7 days later with no sequelae.

Additional Cases

Related cases can be found in other chapters for the following topics: **herniation** (Case 10.10); **intracranial hemorrhage** (Cases 10.1, 10.13, 14.9, 19.3, 19.4); **aneurysm** (Case 13.1); **arteriovenous malformation (AVM)** (Case 11.5); **hydrocephalus** (Case 15.3); **brain tumors** (Cases 7.4, 11.3, 11.4, 12.2, 12.3, 12.5–12.7, 13.9, 15.2, 17.1, 18.2, 18.4, 18.5, 19.7); and **infectious disorders of the nervous system** (Cases 8.4, 16.1, 18.3, 19.10). Other relevant cases can be found using the **Case Index.**

Brief Anatomical Study Guide

1. In this chapter, we have discussed the anatomy of the meninges (see Figure 5.1), including the **pia, arachnoid,** and **dura,** as well as the major dural infoldings (see Figures 5.5, 5.6).
2. The cranial cavity is composed of **anterior, middle, and posterior fossae,** which contain specific brain structures (see Figures 5.2–5.4).
3. The **blood–brain barrier** is formed by brain capillary endothelial cells sealed together by **tight junctions** (see Figures 5.13B, 5.14).
4. To gain a three-dimensional understanding of the ventricular system and its spatial relationships to adjacent structures, review Figures 5.10 and 5.11, and the Neurological Atlas MRI images in Figures 4.13–4.15. Several **C-shaped structures** follow the curve of the lateral ventricles, including the caudate nucleus, corpus callosum, and fornix (see Figure 4.15). We will now discuss the spatial relationships of these structures—both as a review of the anatomy of the ventricular system and to prepare you for the next section, "A Scuba Expedition through the Brain."
5. The **caudate nucleus** and **thalamus** bulge inward from the lateral walls of the **lateral ventricles** (see Figures 4.13, 4.14). The caudate nucleus forms a C-shaped structure that lies along the wall of the C-shaped lateral ventricle in all planes of section (see Figures 4.14, 16.4).
6. The **septum pellucidum** is a thin membrane that separates the two lateral ventricles in the midline. The septum pellucidum hangs from the **corpus callosum,** another C-shaped structure, which forms the roof of most parts of the lateral ventricles (see Figures 4.14, 4.15).
7. Dangling from the bottom of the septum pellucidum, the **fornix** (see Figure 18.13) again forms a C-shaped structure that parallels the curve of the lateral ventricles. The fornix is composed of a pair of archlike bundles of myelinated axons that connect structures in the temporal lobes to the hypothalamus and basal forebrain (see Figure 18.9).
8. The **hippocampal formation,** a structure involved in memory and other limbic functions (see Chapter 18) lies on the floor and the medial wall of the temporal horn of the lateral ventricles (see Figure 4.14).
9. The **interventricular foramina of Monro** are bounded by the fornix medially and superiorly, by the thalami laterally, and by the **anterior commissure** (a white matter tract connecting structures in the two temporal lobes) inferiorly (see Figures 16.4, 18.9A).
10. The **third ventricle** is bounded laterally by the thalami and hypothalamus; superiorly by the fornix; inferiorly by the hypothalamus; anteriorly by the anterior commissure, fornix, lamina terminalis, and hypothalamus; and posteriorly by the posterior commissure, pineal region, and hypothalamus (see Figures 4.15, 5.10).
11. The **cerebral aqueduct (of Sylvius),** a thin canal of cerebrospinal fluid, is located entirely within the midbrain gray matter (see Figure 5.10).

Brief Anatomical Study Guide (*continued*)

12. The **fourth ventricle** is a pyramid-shaped cavity with its base resting on the dorsal aspect of the pons and medulla and its apex covered by the cerebellum (see Figures 5.10, 5.11).
13. Note also the locations of the major **CSF cisterns** in the subarachnoid space (see Figure 5.12).
14. Finally, recall that the meninges make a "PAD" composed, from inside to outside, of the **pia, arachnoid, and dura** (see Figure 5.1).
15. CSF is produced in the **choroid plexus** and reabsorbed in the **arachnoid granulations** (see Figures 5.1, 5.10).

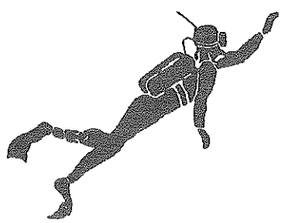

A Scuba Expedition through the Brain

Imagine your colleague has lost his memory just before the neuroanatomy final exam. Fortunately, a mutual friend owns a miniaturization ray and special electronic apparatus that, when plugged directly into the hippocampus, can immediately retrieve any lost memories. To help your friend, you bravely don your scuba gear and allow yourself to be miniaturized and injected via lumbar puncture into your friend's lumbar cistern (see Figure 5.22), taking along a set of your friend's MRI scans as a map (see Figures 4.13–4.15). *Your mission: Find the hippocampus.*

Looking around as you swim in the cerebrospinal fluid, you see many wispy spiderweb-like strands extending inward from the (1._____). You are in the (2._____) space (Figure 5.1), bounded externally by the (3._____) and internally by the (4._____). As you swim upward, you notice long ropelike strings descending all around you in the lumbar cistern that for some reason remind you of a horse's tail. This is the (5._____), consisting of spinal (6._____) roots. Soon you see a thick, gleaming, pinkish white structure, the (7._____). It has sensory roots entering its (8._____) surface, and motor roots exiting its (9._____) surface.

As you swim up the spinal canal in the subarachnoid space, eventually you come to a large ring-shaped hole leading into the cranial cavity. This entryway is the (10._____), bringing you into the cisterna (11._____). Above you is a pinkish gray structure with lots of bumps on it that seems to be furiously calculating coordination and other operations. It is the (12._____). You peek around to the sides at the lateral foramina of (13._____), but then you decide to swim straight up along the dorsal surface of the medulla and under the cerebellum to enter the midline foramen of (14._____). Suddenly, you feel a rush of clear cerebrospinal fluid against your face as it flows out into the subarachnoid space, and you need to kick a little harder with your flippers. You have entered a large cavity called the (15._____) ventricle. You let yourself sink to the ventral floor of the fourth ventricle and take a few steps forward. Beneath your flippers, the floor of the fourth ventricle is formed initially by the (16._____), and then, as you progress farther rostrally, by the (17._____).

Looking upward, you direct your headlight toward a large structure forming the roof of the cavern. This is the (18._____). You decide to swim farther rostrally to enter a narrow tunnel called the (19._____). To pass through this tunnel you have to wriggle your shoulders against the walls, which are part of the (20._____), and you continue to swim forward against the CSF current. Finally, you pop out of the top end of the tunnel and find yourself sinking down toward the floor of another cavity, called the (21._____) ventricle. As you sink downward, you look to the left and to the right, and you see walls made up first by the (22._____) and later by the (23._____). You decide not to let yourself sink to the bottom, which is also formed by the (23._____), but instead you look up at the roof and see two parallel gleaming white arches running from back to front, making up the roof of the third ventricle. This is the (24._____). You kick with your flippers and swim up toward the front of the third ventricle, where you see two holes, called the foramina of (25._____). You choose the foramen on the right and climb up onto the threshold of the hole and find yourself standing on the (26._____) commissure, with your left (medial) hand leaning up against the (27._____) and your right (lateral) hand leaning up against the (28._____). You swim forward and upward and find that you have entered another very large cavity, the right (29._____) ventricle. As you continue to swim forward in this cavity, you are entering the (30._____) horn of the lateral ventricle. Looking upward, you see a whitish "hard body" forming the roof, the (31._____). You soon reach a dead end, also formed by the (31._____) as it curves downward around the most anterior portions of the lateral ventricle.

You turn around 180° and start swimming back caudally toward the other portions of the lateral ventricle. You soon pass the foramen of (32._____) again and have to kick a little harder to avoid being sucked back down into the (33._____) ventricle. You have now entered the (34._____) of the right lateral ventricle. On your right side is a translucent membrane forming the medial wall of the ventricle, called the (35._____). It extends downward from the (36._____), which still forms the roof of the lateral ventricle, to the (37._____) on the medial floor. As you shine your powerful searchlight through this membrane, you can barely make out another, nearly identical cavity on the other side of the brain, the left (38._____) ventricle. Looking laterally (to your left), you see a large gray matter structure bulging inward into the ventricle and forming its lateral wall. Checking your map (Figures 4.13–4.15), you realize this is the (39._____) nucleus. As you swim farther back, another gray matter structure called the (40._____) bulges inward from the lateral wall. Suddenly you notice that your foot has become ensnared in a pulsatile tangle of blood vessels that seems to be secreting a clear fluid. This is the (41._____), which you had noticed all along the way inside the ventricles but had so far managed to avoid. Carefully you disentangle your flipper and soon enter another part of the ventricle, called the (42._____).

From here you seem to have three choices of where to swim next. You could turn around and swim forward into the (43._____) of the lateral ventricle, or you could swim downward into the (44._____) horn, but instead you choose to continue swimming toward the back of the brain and enter the (45._____) horn. However, you soon meet another dead end when you find yourself well within the (46._____) lobe. So you turn around and start walking forward, but then—WHOA! Suddenly you are sliding down a steep slope into the (47._____) horn. You stand up, brush yourself off, and lean your left hand against the medial wall. You look around and decide you must be deep within the (48._____) lobe. Then you look down at your feet and at your left hand, and what do you know, you're finally standing right on top of the (49._____). Congratulations! You have succeeded in reaching your goal, and in preserving many valuable memories.

Answers are found on page 210.

References

General

Greenberg MS. 2001. *Handbook of Neurosurgery*, 5th Ed. Thieme Medical Pub., Lakeland, FL.

Kaye, AH., Black P (eds.). 2000. *Operative Neurosurgery*. Churchill Livingstone, New York.

Laterra J, Goldstein GW. 2000. Ventricular organization of cerebrospinal fluid: blood-brain barrier, brain edema, and hydrocephalus. In Kandel ER, Schwartz JH, Jessell TM (eds.). *Principles of Neural Science*. 4th Ed., Appendix Part B. McGraw-Hill, New York.

Headache

Goadsby PJ, Silberstein SD (eds.). 1997. *Headache*. Butterworth-Heinemann Medical, Boston.

Jay GW. 1998. *The Headache Handbook: Diagnosis and Treatment*. CRC Press, Boca Raton, FL.

Quality Standards Subcommittee of the American Academy of Neurology. 1994. Practice parameter: the utility of neuroimaging in the evaluation of headache in patients with normal neurologic examinations (summary statement). *Neurology*. 44(7): 1353–1354.

Rose G, Edmeads J, Dodick D. 1998. *Critical Decisions in Headache Management*. Hamilton: B. C. Decker, Malden, MA.

Elevated Intracranial Pressure

1997. *Intracranial Pressure and Neuromonitoring in Brain Injury: Proceedings of the Tenth International ICP Symposium, Williamsburg*. Springer Verlag, New York.

Grady PA, Blaumanis OR. 1988. Physiologic parameters of the cushing reflex. *Surg Neurol* 29(6): 454–461.

Mayer SA, Dennis LJ. 1998. Management of Increased Intracranial Pressure. *The Neurologist* 4: 2–12.

Schrader H, Lofgren J, Zwetnow N. 1985. Regional cerebral blood flow and CSF pressures during the Cushing response induced by an infratentorial expanding mass. *Acta Neurol Scand* 72(3): 273–282.

Brain Herniation Syndromes

Fisher, CM. 1984. Acute brain herniation: A revised concept. *Sem Neurol* 4: 417–421.

Kernohan JW, Woltman HW. 1929. Incisura of the crus due to contralateral brain tumor. *Arch Neurol Psychiatry* 21: 274.

Plum F, Posner JB. 1982. Supratentorial lesions causing coma. In *The Diagnosis of Stupor and Coma*, Chapter 2. FA Davis, Philadelphia.

Rhoton AL, Ono M. 1996. Microsurgical anatomy of the region of the tentorial incisura. In Wilkins RH, Rengachary SS (eds.), *Neurosurgery*, 2nd Ed., Vol. 1, Chapter 91. McGraw-Hill, New York.

Ropper AH. 1989. A preliminary MRI study of the geometry of brain displacement and level of consciousness with acute intracranial masses. *Neurology* 39(5): 622–627.

Ross DA, Olsen, WL, Ross AM, Andrews BT, Pitts LH. 1989. Brain shift, level of consciousness, and restoration of consciousness in patients with acute intracranial hematoma. *J Neurosurg* 71(4): 498–502.

Head Trauma

Cameron MM. 1978. Chronic subdural haematoma: A review of 114 cases. *J Neurol Neurosurg Psychiatry* 41(9): 834–839.

Gallagher JP, Browder EJ. 1968. Extradural hematoma: Experience with 167 patients. *J Neurosurg* 29(1): 1–12.

McCormick WF. 1996. Pathology of closed head injury. In Wilkins RH, Rengachary SS (eds.), *Neurosurgery*, 2nd Ed., Vol. 1, Chapter 261. McGraw-Hill, New York.

McKissock W, Taylor JC, Bloom WH, et al. 1960. Extradural hematoma: Observation on 125 cases. *Lancet* 2: 167–172.

Stone JL, Rifai, MHS, Sugar O, Lang RGR, Oldershaw JB, Moody RA 1983. Subdural hematomas I. Acute subdural hematoma: Progress in definition, clinical pathology, and therapy. *Surg Neurol* 19(3): 216–231.

Vinken PJ, Bruyn GW, Klawans HL (eds.). 1990. *Head Injury*. (Handbook of Clinical Neurology, Vol. 57.) Elsevier, Amsterdam.

White RJ, Likavec MJ. 1992. The diagnosis and initial management of head injury. *N Engl J Med* 327(21): 1507–1511.

Intracranial Hemorrhage

The Arteriovenous Malformation Study Group. 1999. Arteriovenous malformations of the brain in adults. *N Engl J Med* 340(23): 1812–1818.

Broderick JP, Brott TG, Duldner JE, Tonsick T, Huster G. 1993. Volume of intracerebral hemorrhage: A powerful and easy-to-use predictor of 30-day mortality. *Stroke* 24(7): 987–993.

Edlow JA, Caplan LR. 2000. Avoiding pitfalls in the diagnosis of subarachoid hemorrhage. *N Engl J Med* 342(1): 29–36.

Franke CL, van Swieten JC, Algra A, van Gijn J. 1992. Prognostic factors in patients with intracerebral haematoma. *J Neurol Neurosurg Psychiatry* 55(8): 653–657.

The International Study of Unruptured Intracranial Aneurysms Investigators. 1998. Unruptured intracranial aneurysms—risk of rupture and risks of surgical intervention. *N Engl J Med* 339(24): 1725–1733.

Redekop G, Ferguson G. 1994. Intracranial Aneurysms. In Carter LP, Spetzler RF (eds.), *Neurovascular Surgery*, McGraw-Hill, New York. Chapter 32.

Teunissen LL, Rinkel GJE, Algra A, van Gijn J. 1996. Risk factors for subarachnoid hemorrhage: A systematic review. *Stroke* 27(3): 544–549.

Hydrocephalus

Adams RD, Fisher CM, Hakim S, Ojemann RG, Sweet WH. 1965. Symptomatic occult hydrocephalus with "normal" cerebrospinal fluid pressure—A treatable syndrome. *N Engl J Med* 273(3): 117–126.

Milhorat TH. 1996. Hydrocephalus: Pathophysiology and clinical features. In Wilkins RH, Rengachary SS (eds.), *Neurosurgery*, 2nd Ed., Vol. 3. McGraw-Hill, New York.

Rosenberg GA. 2000. Brain edema and disorders of cerebrospinal fluid circulation. In Bradley WG, Daroff RB, Fenichel GM, Marsden CD (eds.), *Neurology in Clinical Practice*, 3rd Ed., Vol. 2, Chapter 65. Butterworth-Hememann, Boston.

Vanneste J, Augustijn P, Tan WF, Dirven C. 1993. Shunting normal-pressure hydrocephalus: The predictive value of combined clinical and CT data. *J Neurol Neurosurg Psychiatry* 56(3): 251–256.

Brain Tumors

DeAngenlis LM. 2001. Brain tumors. *N Engl J Med* 344(2): 114–124.

Greenberg H, Chandler WF, Sandler HM. 1999. *Brain Tumors* (Contemporary Neurology Series, Vol. 54). Oxford, New York.

Morantz RA, Walsh JW (eds.). 1994. *Brain Tumors*. Marcel Dekker, New York.

Infectious Disorders of the Nervous System

Coyle PK. 1999. Overview of acute and chronic meningitis. *Neurol Clin*. 17(4): 691–710.

DeBiasi RL, Tyler KL. 1999. Polymerase chain reaction in the diagnosis and management of central nervous system infections. *Arch Neurol*. 56(10): 1215–1219.

Mandell GL, (ed.). 1995. *Central Nervous System and Eye Infections* (Atlas of Infectious Diseases, Vol. 3). Current Medicine, Philadelphia.

Marra CM. 1999. Bacterial and fungal brain infections in AIDS. *Semin Neurol*. 19(2): 177–184.

Rosenstein NE, Perkins BA, Stevens DS, Popovic T, Hughes JM. 2001. Meningococcal disease. *N Engl J Med* 344(18): 1378–1388.

Scheld M, Whitley RJ, Durack DT (eds.). 1997. *Infections of the Central Nervous System.* Lippincott, Philadelphia.

Lumbar Puncture

Quality Standards Subcommittee of the American Academy of Neurology. 1993. Practice parameter: lumbar puncture (summary statement). *Neurology* 43(3 Pt 1): 625–627.

Waldman W, Laureno R. 1999. Precautions for lumbar puncture: A survey of neurologic educators. *Neurology* 52(6): 1296.

Scuba Expedition through the Brain—Answers

1. arachnoid
2. subarachnoid
3. arachnoid
4. pia
5. cauda equina
6. nerve
7. spinal cord
8. dorsal (or posterior)
9. ventral (or anterior)
10. foramen magnum
11. magna
12. cerebellum
13. Luschka
14. Magendie
15. fourth
16. medulla
17. pons
18. cerebellum
19. cerebral aqueduct (of Sylvius)
20. midbrain (or mesencephalon)
21. third
22. thalamus
23. hypothalamus
24. fornix
25. Monro
26. anterior
27. fornix
28. thalamus
29. lateral
30. anterior (or frontal)
31. corpus callosum
32. Monro
33. third
34. body
35. septum pellucidum
36. corpus callosum
37. fornix
38. lateral
39. caudate
40. thalamus
41. choroid plexus
42. atrium (or trigonum)
43. body
44. temporal (or inferior)
45. occipital (or posterior)
46. occipital
47. temporal (or inferior)
48. temporal
49. hippocampus

CHAPTER 6

ANATOMICAL AND CLINICAL REVIEW
Motor Cortex, Sensory Cortex, and Somatotopic Organization
Basic Anatomy of the Spinal Cord
Spinal Cord Blood Supply
General Organization of the Motor Systems
Lateral Corticospinal Tract
Autonomic Nervous System
KCC 6.1 Upper Motor Neuron versus Lower Motor Neuron Lesions
KCC 6.2 Terms Used to Describe Weakness
KCC 6.3 Weakness Patterns and Localization
KCC 6.4 Detecting Subtle Hemiparesis at the Bedside
KCC 6.5 Unsteady Gait
KCC 6.6 Multiple Sclerosis
KCC 6.7 Motor Neuron Disease

CLINICAL CASES
6.1 Sudden Onset of Right Hand Weakness
6.2 Sudden Onset of Left Foot Weakness
6.3 Sudden Onset of Right Face Weakness
6.4 Pure Motor Hemiparesis I
6.5 Pure Motor Hemiparesis II
6.6 Progressive Weakness, Muscle Twitching, and Cramps
Additional Cases

BRIEF ANATOMICAL STUDY GUIDE

Corticospinal Tract and Other Motor Pathways

Movement is crucial to our normal functioning, and damage to the motor systems can be profoundly disabling. In this chapter, we will learn of a 74-year-old woman who awoke one morning and suddenly developed slurred speech and paralysis of the entire right side of her body, including her right face, arm, and leg. Her reflexes were brisk on the right side, and she also had a Babinski's sign on the right, but her sensory exam was normal. She was unable to walk or stand without assistance. To diagnose and treat patients with such symptoms, we must learn about the pathways in the brain and spinal cord that control movement of the body.

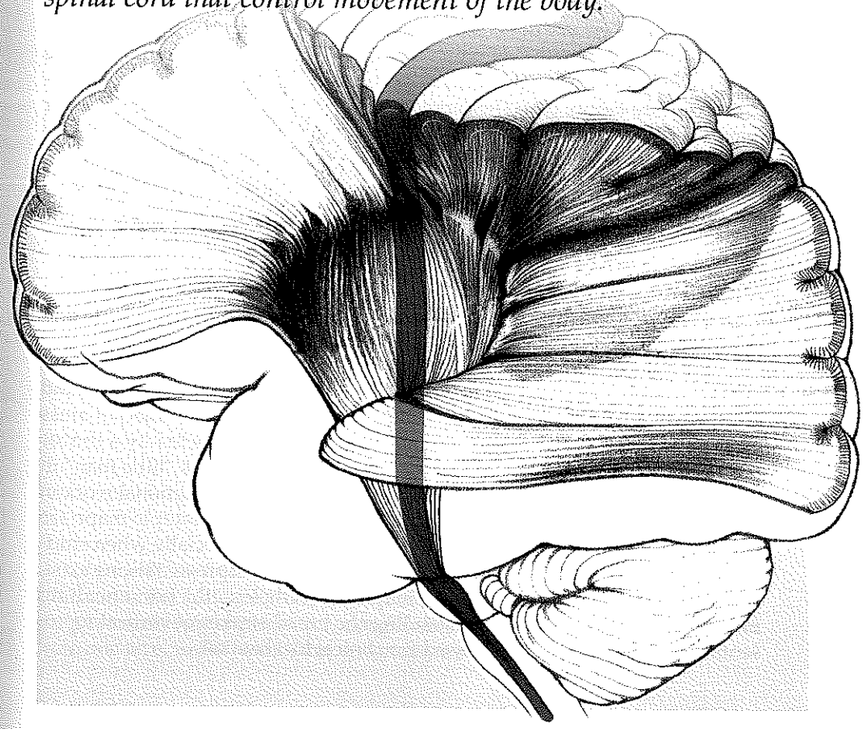

TABLE 6.1 Main Long Tracts of the Nervous System

PATHWAY	FUNCTION
Lateral corticospinal tract	Motor
Posterior columns	Sensory (vibration, joint position, fine touch)
Anterolateral pathways	Sensory (pain, temperature, crude touch)

ANATOMICAL AND CLINICAL REVIEW

In this chapter and the next we will focus on the three most important motor and sensory "long tracts" in the nervous system. Familiarity with these three pathways is essential and suffices for full neuroanatomical localization in many clinical cases. These three fundamental pathways and their functions are listed in Table 6.1.

Each of these pathways crosses over, or decussates, to the contralateral side at a specific point in its course. Knowledge of the crossover points is very helpful for localizing lesions. A second clue to localizing lesions often comes from an understanding of the topographical representation of different body parts in these pathways. In these two chapters (6 and 7), we will trace the routes of the main motor and sensory pathways through all levels of the nervous system and review their overall organization and functions, with special emphasis on the spinal cord. We will also briefly discuss other systems that involve the spinal cord, such as the autonomic nervous system, sphincter control mechanisms, and motor pathways other than the corticospinal tract.

Motor Cortex, Sensory Cortex, and Somatotopic Organization

The primary motor cortex and primary somatosensory cortex are shown in Figure 6.1. Recall from Chapter 2 that these areas are located on either side of the **central,** or **Rolandic, sulcus,** which divides the frontal lobe from the parietal lobe. The **primary motor cortex** (Brodmann's area 4) is in the **precentral gyrus,** while the primary somatosensory cortex (Brodmann's areas 3, 1, and 2) is in the **postcentral gyrus** (see Figure 6.1). Lesions in these areas cause motor or sensory deficits, respectively, in the contralateral body.

Several important areas of motor association cortex lie just anterior to the primary motor cortex, including the supplementary motor area and premotor cortex (see Figure 6.1). These regions are involved in higher-order motor planning and project to the primary motor cortex. Similarly, somatosensory association cortex in the parietal lobe receives inputs from primary somatosensory cortex and is important in higher-order sensory processing. Unlike lesions in the primary cortices, lesions in sensory or motor association cortex do not produce severe deficits in basic movement or sensation. Instead, lesions of the association cortex cause deficits in higher-order sensory analysis or motor planning, discussed further in Chapter 19. Interestingly, there are reciprocal connections between primary and association cortex, sensory and motor areas, as shown in Figure 6.1A.

Functional mapping and lesion studies have demonstrated that the primary motor and somatosensory cortices are **somatotopically organized** (Figure 6.2). That is, adjacent regions on cortex correspond to adjacent areas on the body surface. The cortical maps are classically depicted by a **motor homunculus** and a **sensory homunculus** (*homunculus* means "little man" in Latin). Since the original description of these homunculi, additional work in both humans and other animals has shown that the somatotopic maps are not as clear-cut and consistent as originally depicted, especially when studied at high spatial resolution. Multiple fractionated representations exist, more so for motor than for sensory maps. Nevertheless, the homunculi remain a useful concept for understanding the broad strokes of cortical representation, and they are widely used for clinical localization.

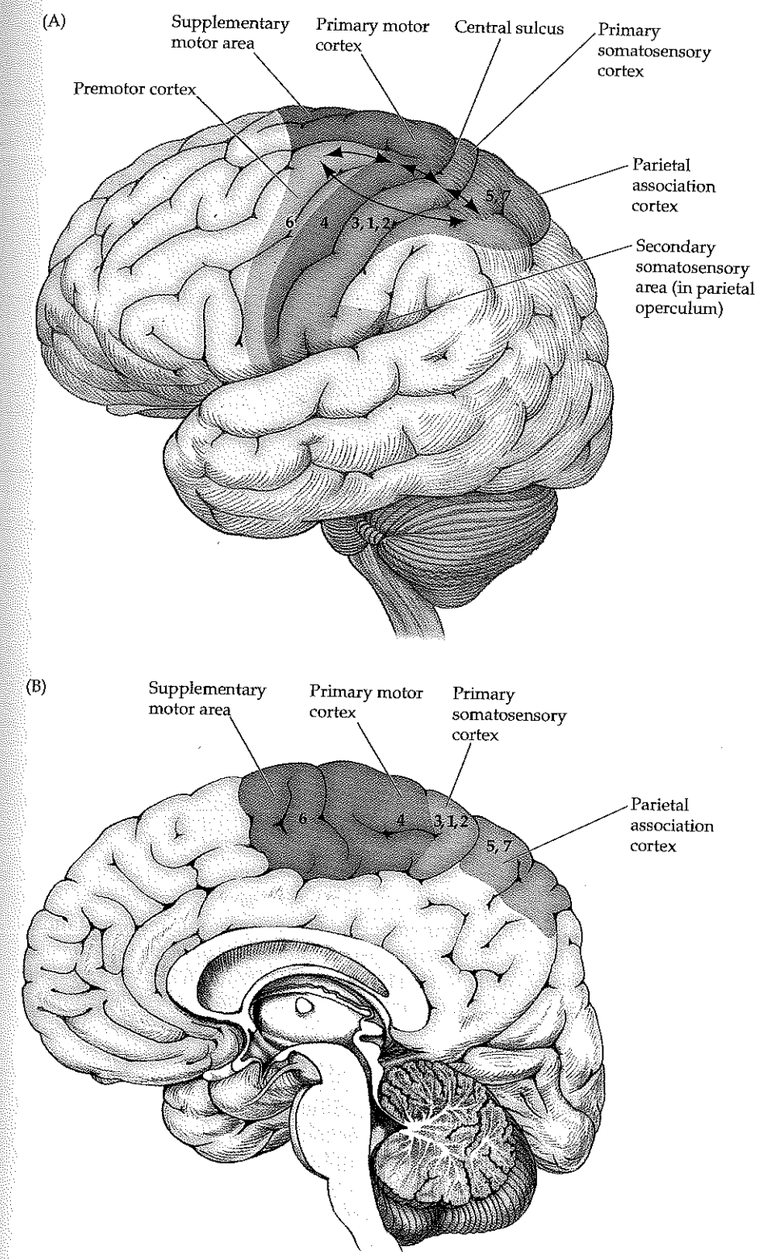

Figure 6.1 Motor and Somatosensory Cortical Areas
(A) Lateral view showing primary and association cortical areas of the sensory and motor cortex, and reciprocal connections between these regions. Numbers indicate corresponding Brodmann areas (see Figure 2.15). (B) Medial view.

As we will see in the sections that follow, somatotopic organization is not confined to the cortex. Rather, some motor and sensory pathways maintain a rough somatotopic organization along their entire length, which can be traced from one level to the next in the nervous system.

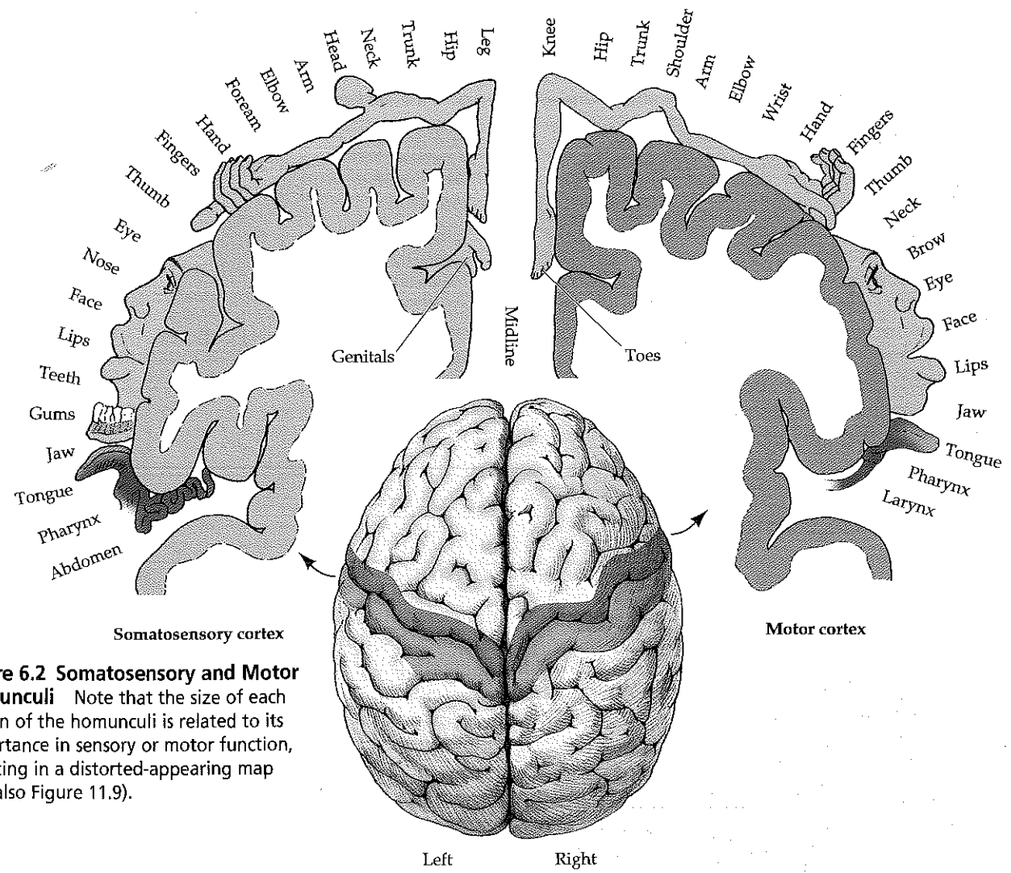

Figure 6.2 Somatosensory and Motor Homunculi Note that the size of each region of the homunculi is related to its importance in sensory or motor function, resulting in a distorted-appearing map (see also Figure 11.9).

MNEMONIC

A useful generalization for remembering the somatotopic representations is: *The arms are medial to the legs with two exceptions: the primary sensorimotor cortices and the posterior columns* (see, for example, Figures 6.2, 6.10, and 7.3).

REVIEW EXERCISE

Is a patient with face and arm weakness more likely to have a lesion on the lateral cortical surface or in the interhemispheric fissure? Is a patient with leg weakness more likely to have a lesion on the lateral cortical surface or in the interhemispheric fissure?

Basic Anatomy of the Spinal Cord

The spinal cord contains a butterfly-shaped **central gray matter** surrounded by ascending and descending white matter columns, or funiculi (Figure 6.3A). **Sensory neurons** in the **dorsal root ganglia** have axons that bifurcate. One branch conveys sensory information from the periphery, and the other carries this information through the **dorsal nerve root filaments** into the dorsal aspect of the spinal cord. The central gray matter has a **dorsal (posterior) horn** that is involved mainly in sensory processing, an **intermediate zone** that contains interneurons and certain specialized nuclei (Table 6.2), and a **ventral (anterior) horn** that contains motor neurons. Motor neurons send their axons out of the spinal cord via the **ventral nerve root filaments.** The spinal gray matter can also be divided into nuclei or, using a different nomenclature, into laminae named by Bror Rexed (see Figure 6.3B; Table 6.2), with different functions that we will discuss in this chapter and in Chapter 7. The spinal cord white

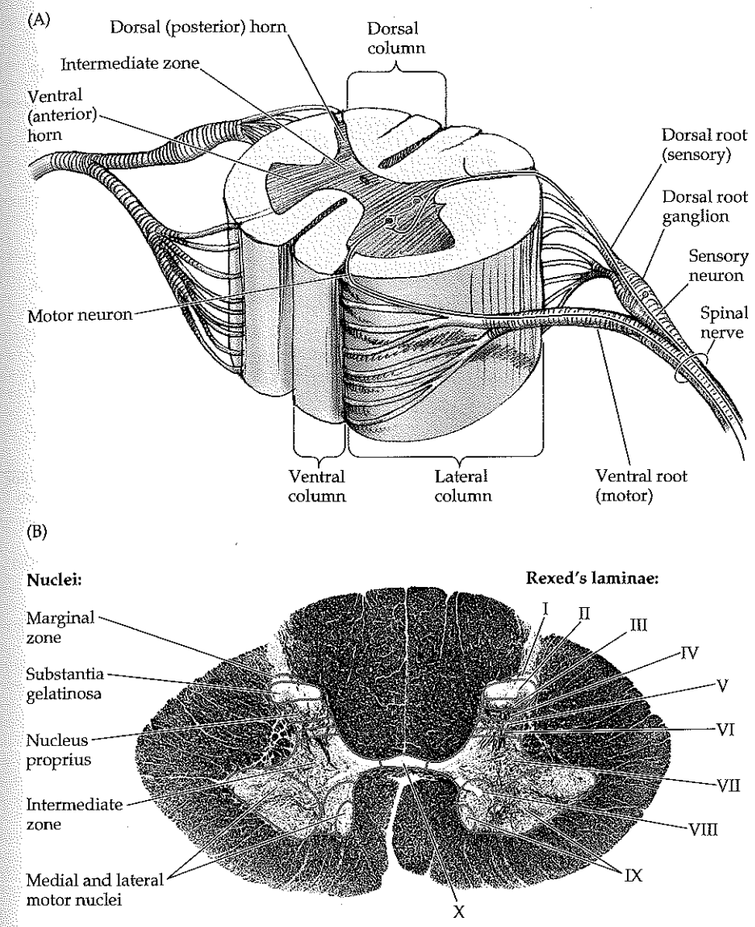

Figure 6.3 Basic Spinal Cord Anatomy (A) Gray matter, white matter, and dorsal and ventral roots. (B) Spinal cord nuclei (left) and Rexed's laminae (right). (See also Table 6.2.) (B from DeArmond SJ, Fusco MM, Maynard MD. 1989. *Structure of the Human Brain: A Photographic Atlas*, 3rd Ed. Oxford, New York.)

matter consists of **dorsal (posterior) columns, lateral columns,** and **ventral (anterior) columns** (see Figure 6.3A).

The spinal cord does not appear the same at all levels (Figure 6.4). The white matter is thickest in the cervical levels (see Figure 6.4C), where most ascending fibers have already entered the cord and most descending fibers have not yet terminated on their targets, while the sacral cord is mostly gray matter (see Figure 6.4F). In addition, the spinal cord has two enlargements (see Figure 6.4A). The **cervical enlargement** and the **lumbosacral enlargement** give rise to the nerve plexuses for the arms and legs. The spinal cord has more gray matter at the cervical and lumbosacral levels (see Figure 6.4C, E, and F) than at the thoracic levels

TABLE 6.2 Nuclei and Laminae of the Spinal Cord

REGION	NUCLEI	REXED'S LAMINAE
Dorsal horn	Marginal zone	I
Dorsal horn	Substantia gelatinosa	II
Dorsal horn	Nucleus proprius	III, IV
Dorsal horn	Neck of dorsal horn	V
Dorsal horn	Base of dorsal horn	VI
Intermediate zone	Clarke's nucleus, intermediolateral nucleus	VII
Ventral horn	Commissural nucleus	VIII
Ventral horn	Motor nuclei	IX
Gray matter surrounding central canal	Grisea centralis	X

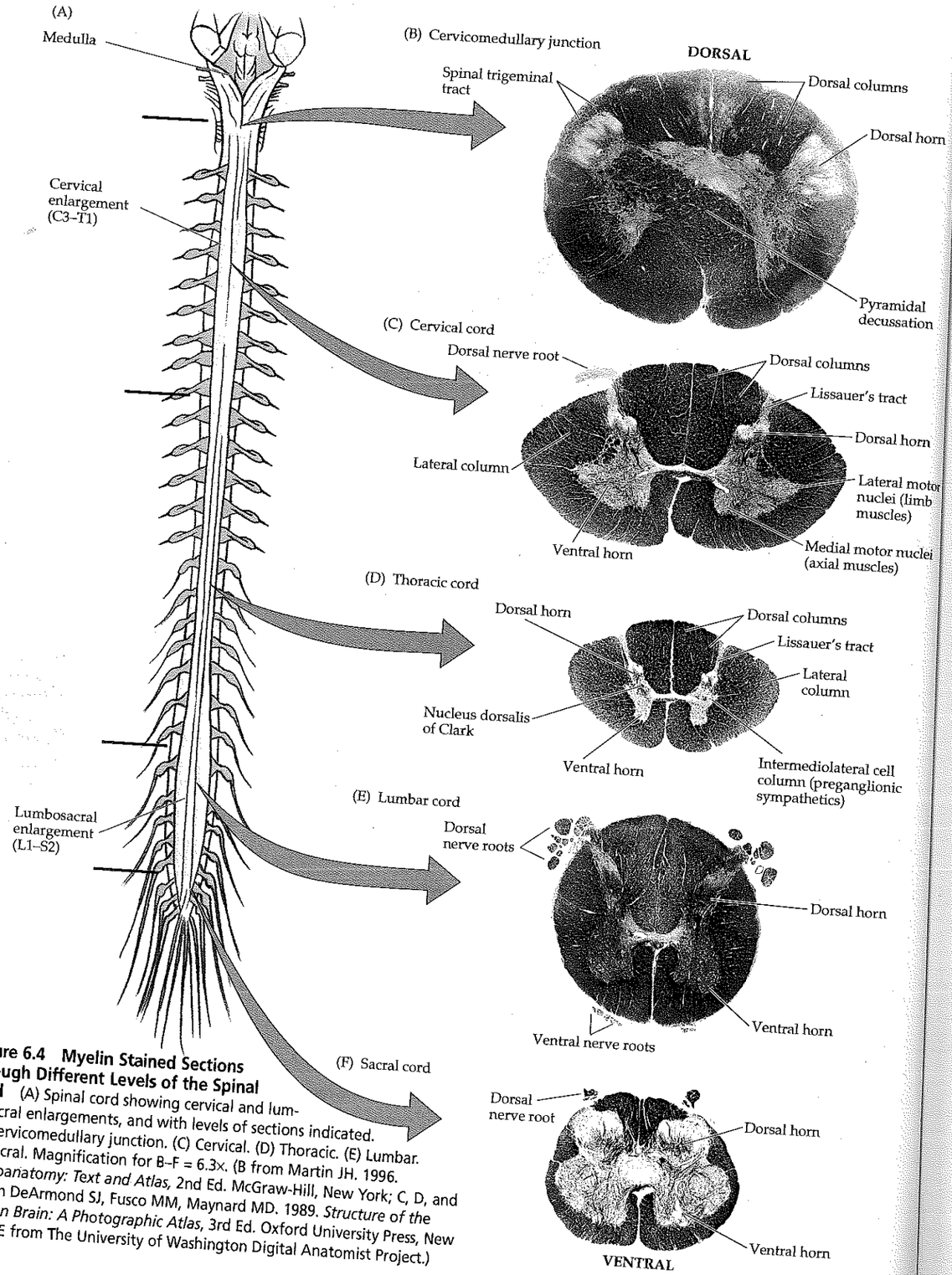

Figure 6.4 Myelin Stained Sections through Different Levels of the Spinal Cord (A) Spinal cord showing cervical and lumbosacral enlargements, and with levels of sections indicated. (B) Cervicomedullary junction. (C) Cervical. (D) Thoracic. (E) Lumbar. (F) Sacral. Magnification for B–F = 6.3x. (B from Martin JH. 1996. *Neuroanatomy: Text and Atlas,* 2nd Ed. McGraw-Hill, New York; C, D, and F from DeArmond SJ, Fusco MM, Maynard MD. 1989. *Structure of the Human Brain: A Photographic Atlas,* 3rd Ed. Oxford University Press, New York; E from The University of Washington Digital Anatomist Project.)

(see Figure 6.4D), particularly in the ventral horns, where lower motor neurons for the arms and legs reside. In the thoracic cord, a **lateral horn** is present (see Figure 6.4D) that contains the intermediolateral cell column.

REVIEW EXERCISE

Cover the labels in Figure 6.3A and Figure 6.4 and name as many structures as possible.

Spinal Cord Blood Supply

The **blood supply to the spinal cord** arises from branches of the vertebral arteries and spinal radicular arteries (Figure 6.5). The vertebral arteries give rise to the **anterior spinal artery** that runs along the ventral surface of the spinal cord (see Figure 2.26C). In addition, two **posterior spinal arteries** arise from the vertebral or posterior inferior cerebellar arteries and supply the dorsal surface of the cord. The anterior and posterior spinal arteries are variable in prominence at different spinal levels and form a **spinal arterial plexus** that surrounds the spinal cord (see Figure 6.5). Thirty-one segmental arterial branches enter the spinal canal along its length; most of the branches arise from the aorta and supply the meninges. Only six to ten of these reach the spinal cord as **radicular arteries,** arising at variable levels (see Figure

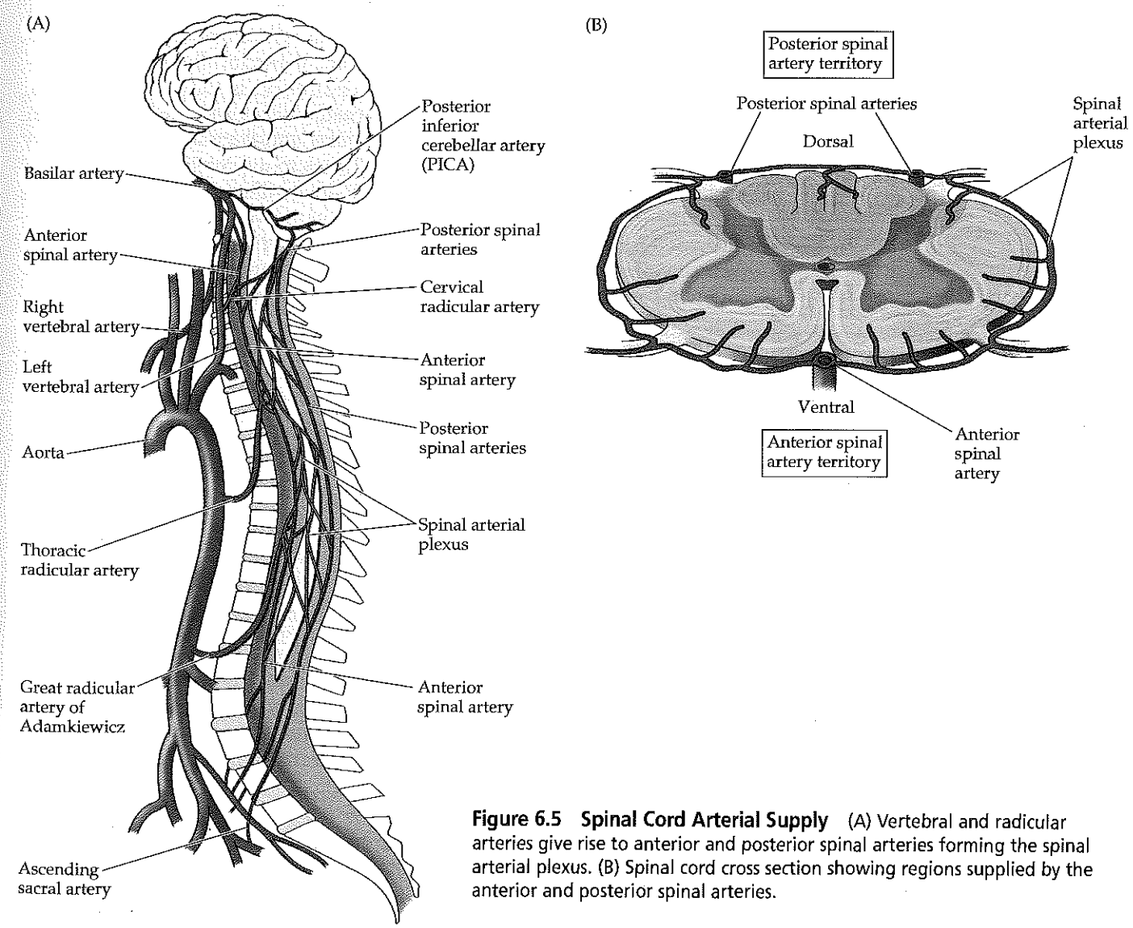

Figure 6.5 Spinal Cord Arterial Supply (A) Vertebral and radicular arteries give rise to anterior and posterior spinal arteries forming the spinal arterial plexus. (B) Spinal cord cross section showing regions supplied by the anterior and posterior spinal arteries.

6.5A). There is usually a prominent radicular artery arising from the left side, anywhere from T5 to L3, but usually between T9 and T12. This is called the **great radicular artery of Adamkiewicz**, and provides the major blood supply to the lumbar and sacral cord.

The mid-thoracic region, at approximately **T4 to T8** lies between the lumbar and vertebral arterial supplies and is a **vulnerable zone** of relatively decreased perfusion. This region is most susceptible to infarction during thoracic surgery or other conditions causing decreased aortic pressure. The anterior spinal artery supplies approximately the anterior two-thirds of the cord, including the anterior horns and anterior and lateral white matter columns (see Figure 6.5B). The posterior spinal arteries supply the posterior columns and part of the posterior horns. Venous return from the spinal cord occurs via a plexus of veins draining initially into the epidural space before reaching systemic circulation. The epidural veins, called **Batson's plexus** (see Figure 8.2), do not contain valves, so elevated intra-abdominal pressure can cause reflux of blood carrying metastatic cells (such as prostate cancer) or pelvic infections into the epidural space.

General Organization of the Motor Systems

Given the extraordinarily refined movements that can be carried out by a musician, gymnast, or surgeon, it should come as no surprise that motor systems form an elaborate network of multiple, hierarchically organized feedback loops. A summary of motor system pathways is shown in Figure 6.6. Only the most important loops are depicted, and sensory inputs have been omitted. Recall that the **cerebellum** and **basal ganglia** participate in important feedback loops in which they project back to the cerebral cortex via the **thalamus** and do not themselves project to lower motor neurons (see Figure 2.17). The roles of the cerebellum and basal ganglia in motor control will be discussed further in Chapters 15 and 16. Within the **cerebral cortex** itself, there are numerous important circuits for motor control. For example, circuits involving association cortex regions such as the supplementary motor area, premotor cortex, and parietal association cortex are crucial to the planning and formulation of motor activities (see Figure 6.1). As we will discuss in Chapter 19, lesions of these regions of association cortex can lead to **apraxia**, in which there is a deficit in higher-order motor planning and execution despite normal strength (neuroexam.com Video 15). Although not shown in Figure 6.6, **sensory inputs** clearly also play an essential role in motor control and participate in motor circuits and feedback loops that range from the level of the spinal cord (see Figure 2.21) to the cerebral cortex (see Figure 6.1).

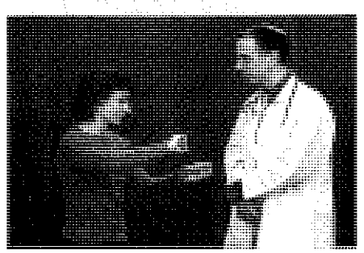

Praxis

Recall also that **upper motor neurons** carry motor system outputs to **lower motor neurons** located in the spinal cord and brainstem, which in turn, project to muscles in the periphery. Descending upper motor neuron pathways arise from the cerebral cortex and brainstem (see Figure 6.6). These descending motor pathways can be divided into **lateral motor systems** and **medial motor systems** based on their location in the spinal cord. Lateral motor systems travel in the

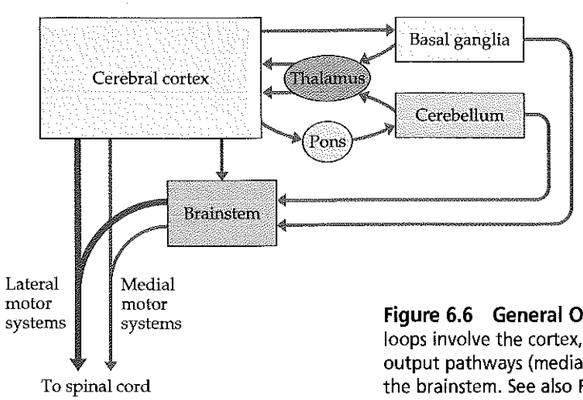

Figure 6.6 General Organization of the Motor Systems Multiple feedback loops involve the cortex, brainstem, cerebellum, basal ganglia, and thalamus. Motor output pathways (medial and lateral motor systems) arise from the cortex and from the brainstem. See also Figure 2.17.

lateral columns of the spinal cord and synapse on the more lateral groups of ventral horn motor neurons and interneurons (Figure 6.7). Medial motor systems travel in the anteromedial spinal cord columns to synapse on medial ventral horn motor neurons and interneurons.

The two lateral motor systems are the **lateral corticospinal tract** and the **rubrospinal tract** (Table 6.3). These pathways control the movement of the extremities (Figure 6.7). The lateral corticospinal

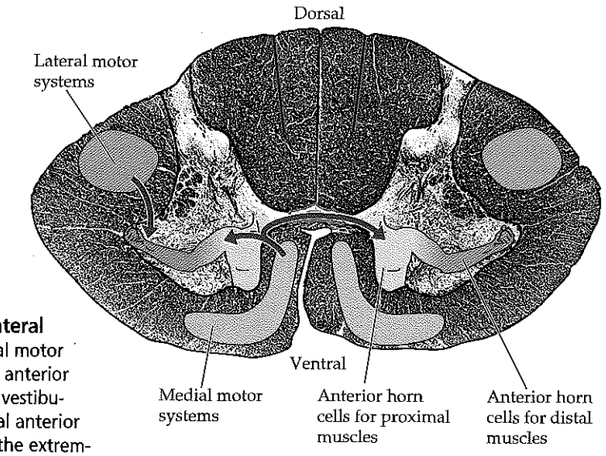

Figure 6.7 Somatotopic Organization of Medial and Lateral Motor System Projections to Anterior Horn Cells Lateral motor systems (corticospinal and rubrospinal tracts) project to lateral anterior horn cells, while medial motor systems (anterior corticospinal, vestibulospinal, reticulospinal, and tectospinal tracts) project to medial anterior horn cells. Lateral anterior horn cells control distal muscles of the extremities, while medial anterior horn cells control proximal trunk muscles. (Spinal cord section from DeArmond SJ, Fusco MM, Maynard MD. 1989. *Structure of the Human Brain: A Photographic Atlas*, 3rd Ed. Oxford University Press, New York.)

TABLE 6.3 Lateral and Medial Descending Motor Systems

TRACT	SITE OF ORIGIN	SITE OF DECUSSATION (WHERE RELEVANT)	LEVELS OF TERMINATION	FUNCTION
LATERAL MOTOR SYSTEMS				
Lateral corticospinal tract	Primary motor cortex, and other frontal and parietal areas	Pyramidal decussation, at the cervicomedullary junction	Entire cord (predominantly at cervical and lumbosacral enlargements)	Movement of contralateral limbs
Rubrospinal tract	Red nucleus, magnocellular division	Ventral tegmental decussation, in the midbrain	Cervical cord	Movement of contralateral limbs (function is uncertain in humans)
MEDIAL MOTOR SYSTEMS				
Anterior corticospinal tract	Primary motor cortex and supplementary motor area	—	Cervical and upper thoracic cord	Control of bilateral axial and girdle muscles
Vestibulospinal tracts (VSTs)[a]	Medial VST: medial and inferior vestibular nuclei; Lateral VST: lateral vestibular nucleus	—	Medial VST: Cervical and upper thoracic cord; Lateral VST: entire cord	Medial VST: positioning of head and neck; Lateral VST: balance
Reticulospinal tracts	Pontine and medullary reticular formation	—	Entire cord	Automatic posture and gait-related movements
Tectospinal tract	Superior colliculus	Dorsal tegmental decussation, in the midbrain	Cervical cord	Coordination of head and eye movement (uncertain in humans)

[a]Despite their names, both medial and lateral VSTs are medial motor systems.

tract in particular is essential for rapid, dextrous movements at individual digits or joints. Both of these pathways cross over from their site of origin and descend in the contralateral lateral spinal cord to control the contralateral extremities (see Table 6.3 and Figure 6.11A,B).

The four medial motor systems are the **anterior corticospinal tract,** the **vestibulospinal tracts,** the **reticulospinal tracts,** and the **tectospinal tract** (see Table 6.3). These pathways control the proximal axial and girdle muscles involved in postural tone, balance, orienting movements of the head and neck, and automatic gait-related movements (see Figure 6.7). The medial motor systems descend ipsilaterally or bilaterally. Some extend only to the upper few cervical segments (see Table 6.3 and Figure 6.11C–E).

The medial motor systems tend to terminate on interneurons that project to both sides of the spinal cord, controlling movements that involve multiple bilateral spinal segments. Thus, unilateral lesions of the medial motor systems produce no obvious deficits. In contrast, lesions of the lateral corticospinal tract produce dramatic deficits (see the next section). The rubrospinal tract in humans is small and its clinical importance is uncertain, but it may participate in taking over functions after corticospinal injury. It may also play a role in flexor (decorticate) posturing of the upper extremities (see Figure 3.5A), which is typically seen with lesions above the level of the red nuclei, in which the rubrospinal tract is spared.

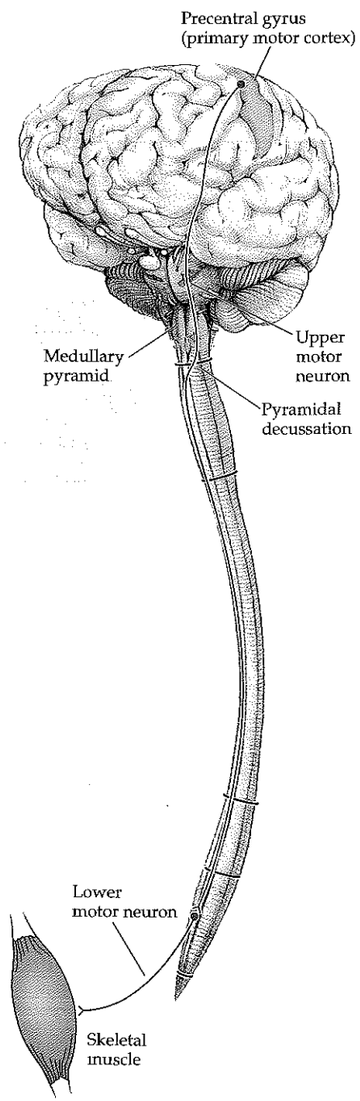

Lateral Corticospinal Tract

The corticospinal tract or, more specifically, the **lateral corticospinal tract,** is the most clinically important descending motor pathway in the nervous system. This pathway controls movement of the extremities, and lesions along its course produce characteristic deficits that often enable precise clinical localization. Let's follow the course of the corticospinal tract from cerebral cortex to spinal cord (Figure 6.8). Over half of the corticospinal tract fibers originate in the primary motor cortex (Brodmann's area 4) of the precentral gyrus. The remainder arise from the premotor and supplementary motor areas (area 6), or from the parietal lobe (areas 3, 1, 2, 5, and 7) (Figure 6.9A). The primary motor cortex neurons contributing to the corticospinal tract are located mostly in cortical layer 5 (see Figure 2.14A). Layer 5 pyramidal cell projections synapse directly onto motor neurons in the ventral horn of the spinal cord, as well as onto spinal interneurons. About 3% of corticospinal neurons are giant pyramidal cells called **Betz cells,** which are the largest neurons in the human nervous system.

Axons from the cerebral cortex enter the upper portions of the cerebral white matter, or **corona radiata** (see Figure 4.13J), and descend toward the internal capsule (see Figure 4.13G). In addition to the corticospinal tract, the cerebral white matter conveys bidirectional information between different cortical areas, and between cortex and deep structures such as the basal ganglia, thalamus, and brainstem (Figure 6.9B). These white matter pathways form a fanlike structure as they enter the internal capsule, which condenses down to fewer and fewer fibers as connections to different subcortical structures are made (see Figure 6.9A).

Figure 6.8 Lateral Corticospinal Tract Upper motor neuron in primary motor cortex (precentral gyrus) sends an axon downward to cross over at the pyramidal decussation. The axon then continues downward in the contralateral spinal cord before synapsing on lower motor neuron in the anterior horn.

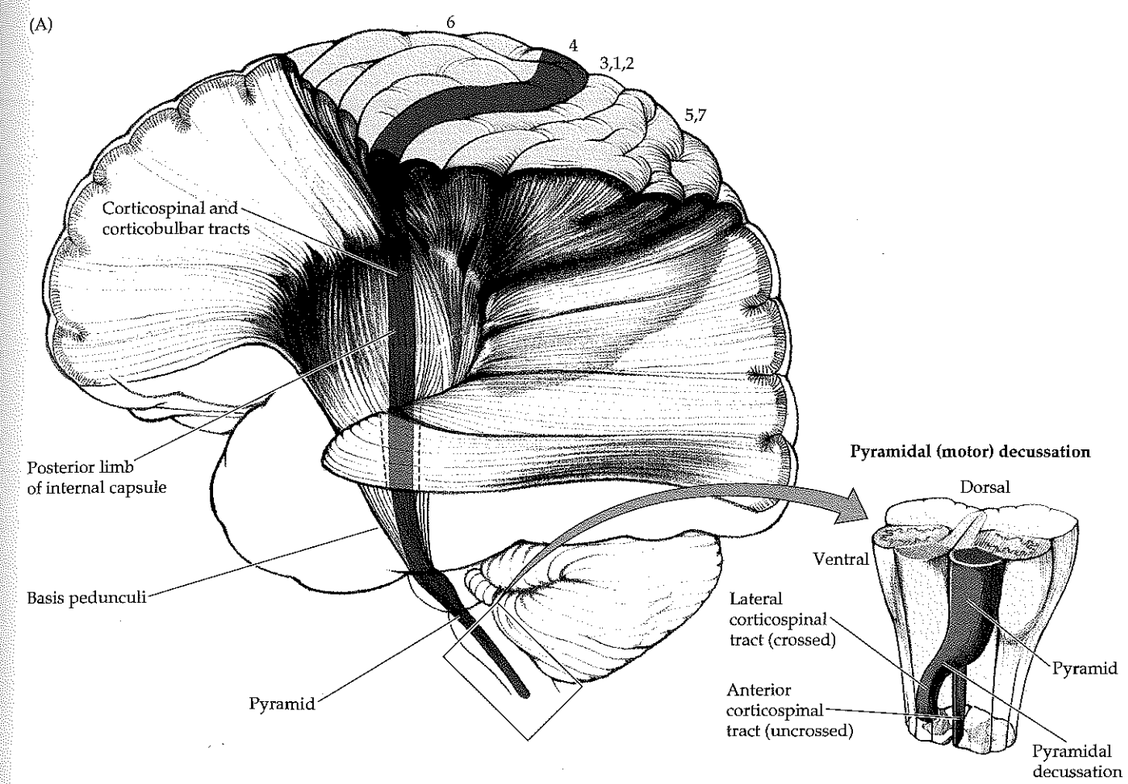

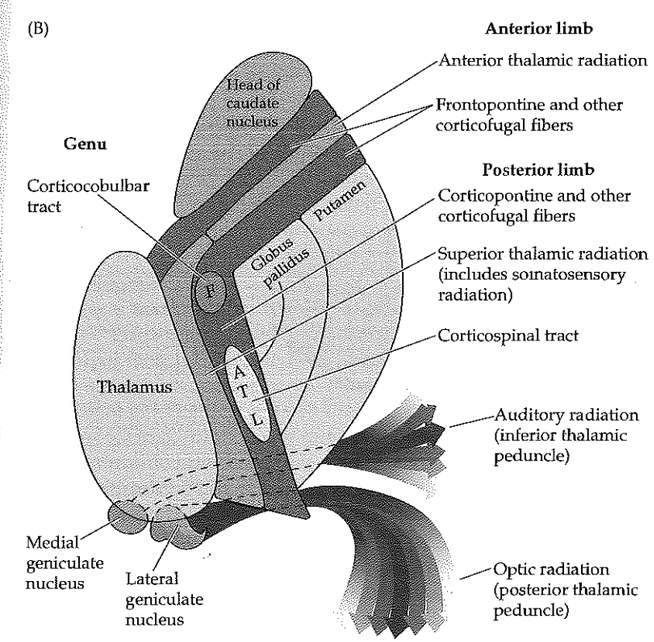

Figure 6.9 Internal Capsule (A) Three-dimensional representation of the internal capsule. Corticospinal and corticobulbar fibers arising from the primary motor cortex and adjacent regions form part of the internal capsule. Corticobulbar fibers project to lower motor neurons in the brainstem. 85% of corticospinal fibers cross over at the pyramidal decussation to form the lateral corticospinal tract, while the remaining fibers form the anterior corticospinal tract. (B) Horizontal section through internal capsule showing the anterior limb, genu, and posterior limb in relation to the thalamus, head of the caudate, and lentiform nucleus (putamen and globus pallidus). Major fiber pathways of the internal capsule are indicated.

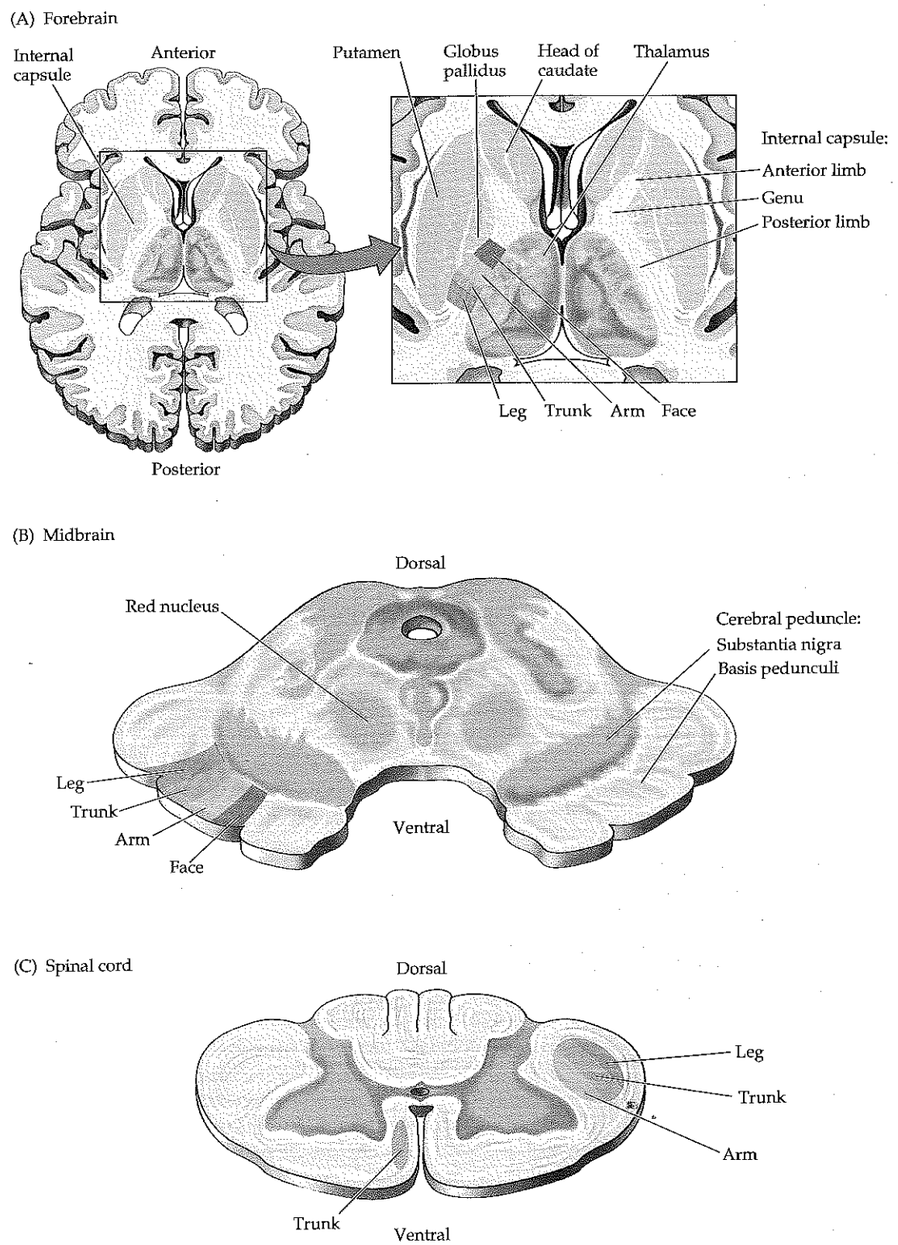

Figure 6.10 Somatotopic Organization of Corticobulbar and Corticospinal Tracts
(A) Horizontal section through the internal capsule. (B) Midbrain. (C) Spinal cord.

MNEMONIC

The **internal capsule** is best appreciated in horizontal brain sections (Figure 6.10A), in which the right and left internal capsules look like arrowheads or two letter Vs with their points facing inward. Note that the thalamus and caudate nucleus are always medial to the internal capsule, while the globus pallidus and putamen are always lateral to the internal capsule. There are three parts to the internal capsule: anterior limb, posterior limb, and genu. Note that the **anterior limb** of the internal capsule separates the head of the caudate from the globus pallidus and putamen, while the **posterior limb** separates the thalamus from the globus pallidus and putamen (see also Figures 16.2, 16.3). The **genu** ("knee" in Latin) is at the transition between the anterior and posterior limbs, at the level of the foramen of Monro. The **corticospinal tract lies in the posterior limb** of the internal capsule. The **somatotopic map** is preserved in the internal capsule, so motor fibers for the face are most anterior, and those for the arm and leg are progressively more posterior (see Figure 6.10A). Fibers projecting from the cortex to the brainstem, including motor fibers for the face, are called **corticobulbar** instead of corticospinal because they project from the cortex to the brainstem, or "bulb." Despite the somatotopic arrangement, the fibers of the internal capsule are compact enough that lesions at this level generally produce weakness of the entire contralateral body (face, arm, and leg) (see KCC 6.3; see Figure 6.14A). However, occasionally capsular lesions can also produce more selective motor deficits. Additional details of the fibers carried by the internal capsule other than the corticobulbar and corticospinal tracts are shown in Figure 6.9B

The internal capsule continues into the midbrain **cerebral peduncles,** meaning literally "feet of the brain" (see Figure 6.10B). The white matter is located in the ventral portion of the cerebral peduncles and is called the **basis pedunculi.** The **middle one-third of the basis pedunculi** contains corticobulbar and corticospinal fibers with the face, arm, and leg axons arranged from medial to lateral, respectively (see Figure 6.10B). The other portions of the basis pedunculi contain primarily corticopontine fibers (see Chapter 15).

REVIEW EXERCISE

Lesions of the corticospinal tract occurring above the pyramidal decussation produce contralateral weakness, whereas lesions below the pyramidal decussation produce ipsilateral weakness (see Figures 6.8, 6.11A). For a lesion in each of the following locations, state whether the weakness would be ipsilateral or contralateral to the lesion: cortex; internal capsule; midbrain; pons; medulla; spinal cord.

The corticospinal tract fibers next descend through the ventral pons, where they form somewhat scattered fascicles (Figure 6.11A). These collect on the ventral surface of the medulla to form the **medullary pyramids** (see Figures 6.8, 6.11A). For this reason the corticospinal tract is sometimes referred to as the **pyramidal tract** (this terminology, though widely used, is somewhat imprecise since the pyramids include reticulospinal and other brainstem pathways in addition to the corticospinal tract). The transition from medulla to spinal cord is called the **cervicomedullary junction,** which occurs at the level of the foramen magnum (see Figure 5.10). At this point about 85% of the pyramidal tract fibers cross over in the **pyramidal decussation** to enter the lateral white matter columns of the spinal cord, forming the lateral corticospinal tract (see Figures 6.8, 6.11A). A somatotopic representation is present in the lateral corticospinal tract, with fibers controlling the upper extremity located medial to those controlling the lower extremity (see Figure 6.10C). Finally, the axons of the lateral corticospinal tract enter the spinal cord central gray matter to synapse onto anterior horn cells (see Figures 6.7, 6.8, 6.11A). The remaining approximately 15% of corticospinal fibers continue into the spinal cord ipsilaterally, without crossing, and enter the anterior white matter columns to form the anterior corticospinal tract (see Figures 6.9A, 6.11C).

In addition to the lateral corticospinal tract, the other lateral and medial descending motor systems (see Table 6.3) are shown in Figure 6.11 as well, including the rubrospinal, anterior corticospinal, tectospinal, reticulospinal, and vestibulospinal tracts.

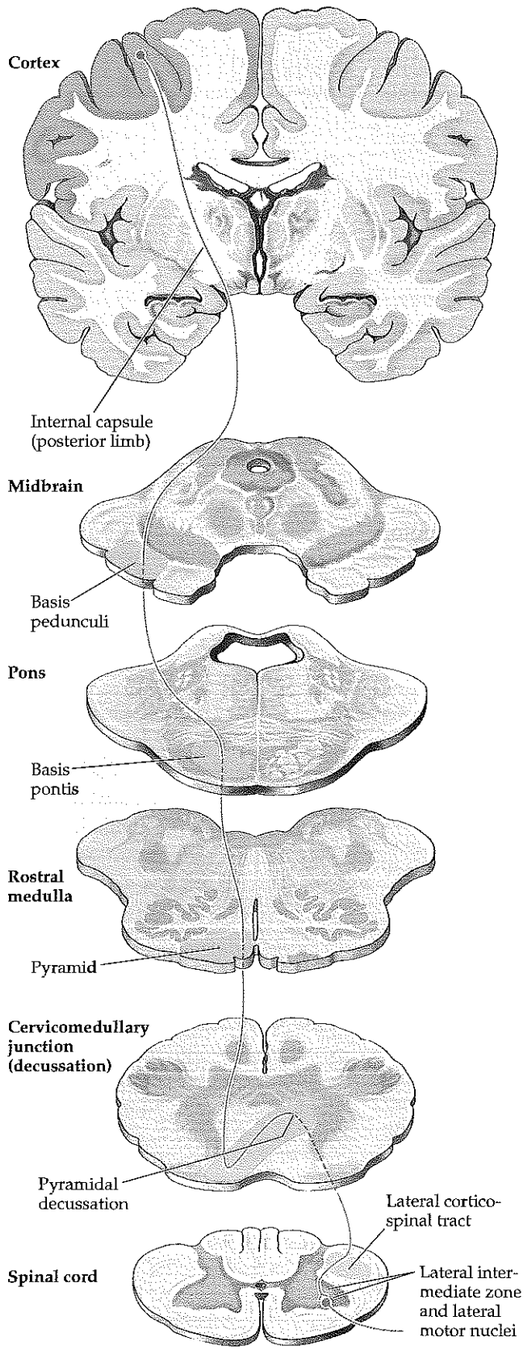

(A) **Lateral corticospinal tract**

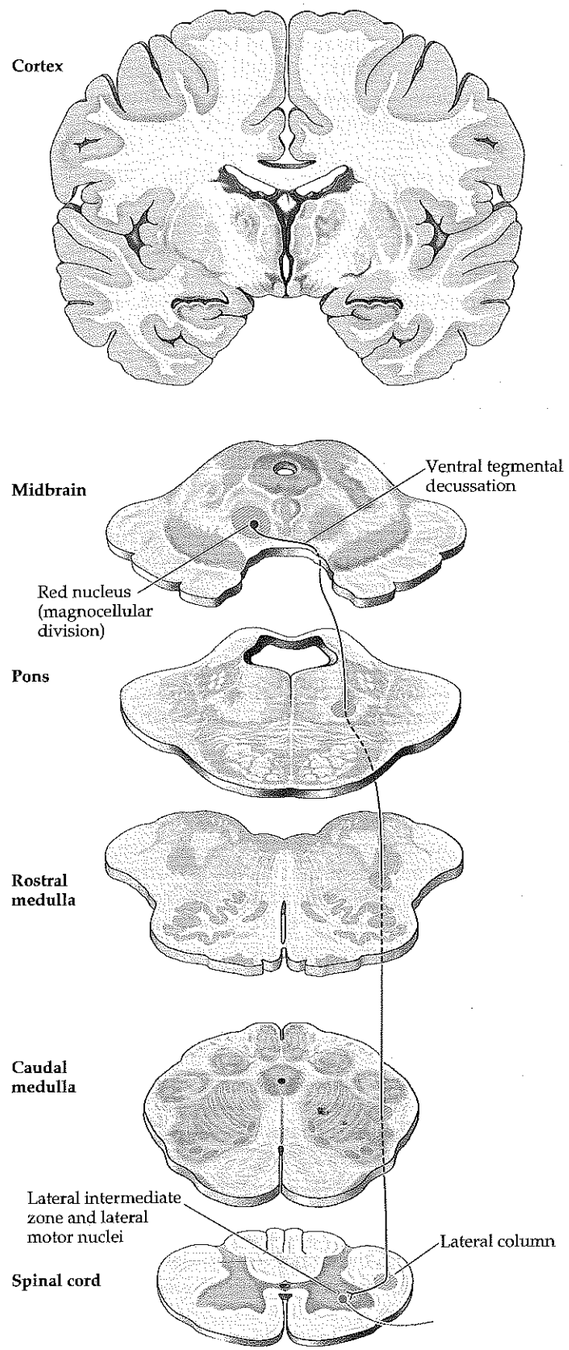

(B) **Rubrospinal tract**

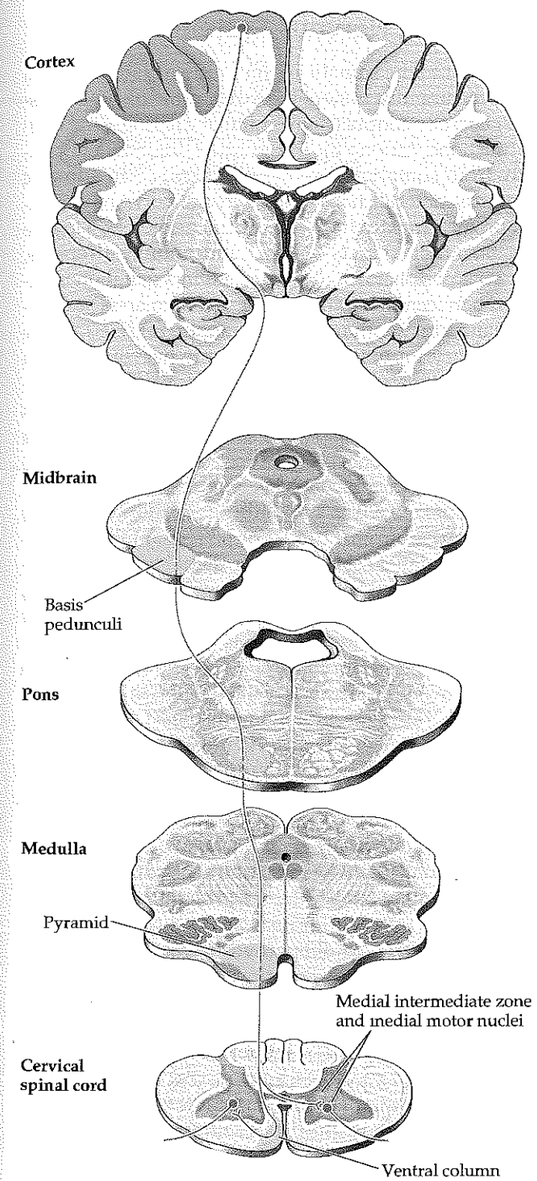

(C) **Anterior corticospinal tract**

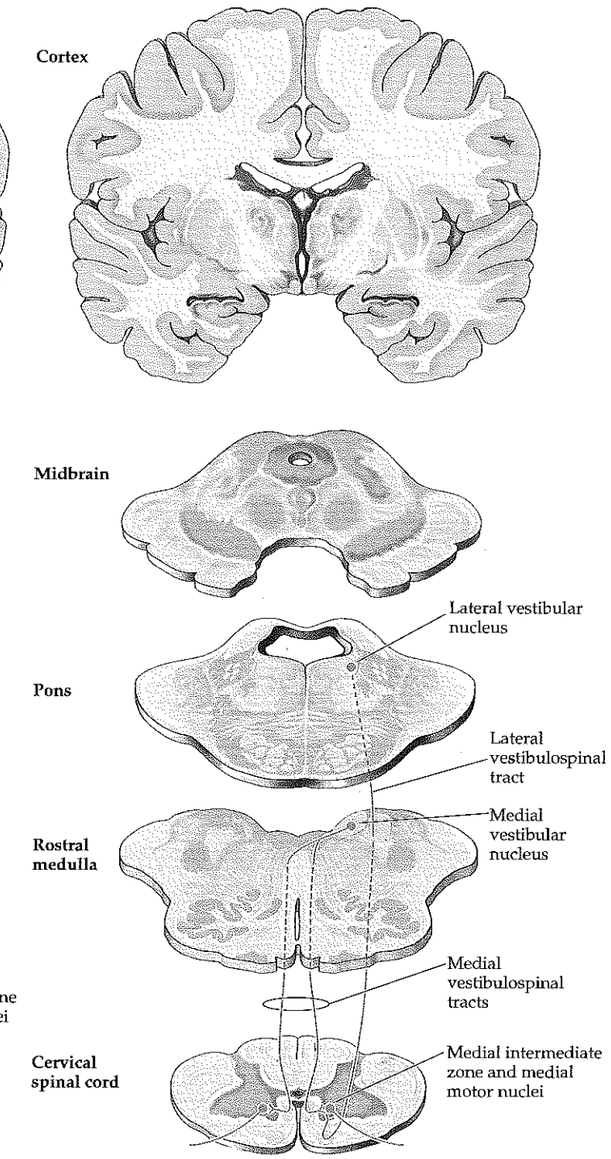

(D) **Vestibulospinal tracts**

Figure 6.11 Descending Motor Pathways Overleaf and page 228 (see also Table 6.3).

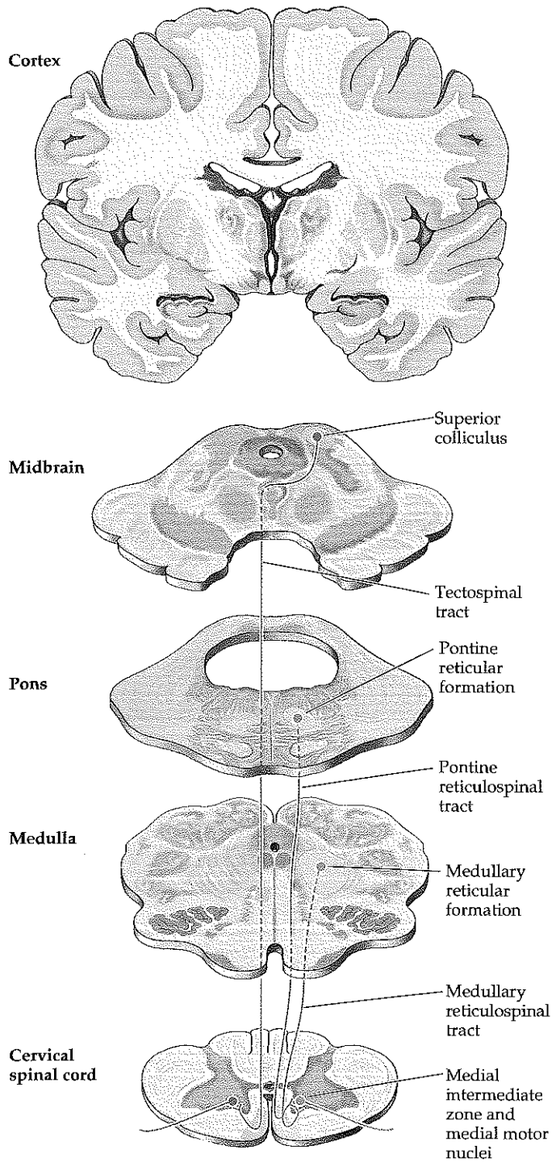

(E) Tectospinal tract and reticulospinal tract

Figure 6.11 (continued)

Autonomic Nervous System

In contrast to the somatic motor pathways described in the preceding discussion, the **autonomic nervous system** generally controls more automatic and visceral bodily functions. Autonomic efferents are different anatomically from somatic efferents (Figure 6.12). In **somatic efferents,** anterior horn cells or cranial nerve motor nuclei project directly from the central nervous system to skeletal muscle (Figure 6.12A). In **autonomic efferents,** there is a peripheral synapse located in a ganglion interposed between the central nervous system and the effector gland or smooth muscle (see Figure 6.12B,C). There are sensory inputs to the autonomic nervous system both centrally and in the periphery. However, the autonomic nervous system itself consists of only efferent pathways and is therefore discussed here with other motor systems.

The autonomic nervous system has two main divisions (Figure 6.13). The **sympathetic,** or **thoracolumbar, division** arises from T1 to L2 or L3 spinal levels and is involved mainly in such "fight-or-flight" functions as increasing heart rate and blood pressure, bronchodilation, and increasing pupil size. The **parasympathetic,** or **craniosacral, division,** in contrast, arises from cranial nerve nuclei and from S2 through S4 and is involved in "rest and digest" functions, such as increasing gastric secretions and peristalsis, slowing the heart rate, and decreasing pupil size. The **enteric nervous system,** considered a third autonomic division, consists of a neural plexus lying within the walls of the gut that is involved in controlling peristalsis and gastrointestinal secretions.

Preganglionic neurons of the sympathetic division are located in the **intermediolateral cell column** in lamina VII of spinal cord levels T1 to L2 or L3 (see Figures 6.4D, 6.12B, 6.13). There are two sets of sympathetic ganglia. The paired **paravertebral ganglia** form a chain called the **sympathetic trunk** (or sympathetic chain) running all the way from cervical to sacral levels on each side of the spinal cord. The sympathetic trunk allows sympathetic efferents, which exit only at thoracolumbar levels, to reach other parts of the body as well. For example, sympathetics are provided to the head and neck by the upper thoracic spinal cord (T1–T3) intermediolateral cell column via 3 sympathetic chain ganglia named the **superior, middle** (often absent), and **inferior** (stellate) **cervical ganglia** (see Figure 13.10). The other sympathetic ganglia are paired **prevertebral ganglia,** which are located in the celiac plexus surrounding the aorta and include the celiac ganglion, superior mesenteric ganglion, and inferior mesenteric ganglion. Axons of preganglionic sympathetic neurons thus have a fairly short distance to travel, while axons of **postganglionic neurons** travel a long distance to reach effector organs (see Figures 6.12B, 6.13). In contrast, parasympathetic preganglionic fibers must travel a long distance to reach the **terminal ganglia** located within or near the effector organs (see

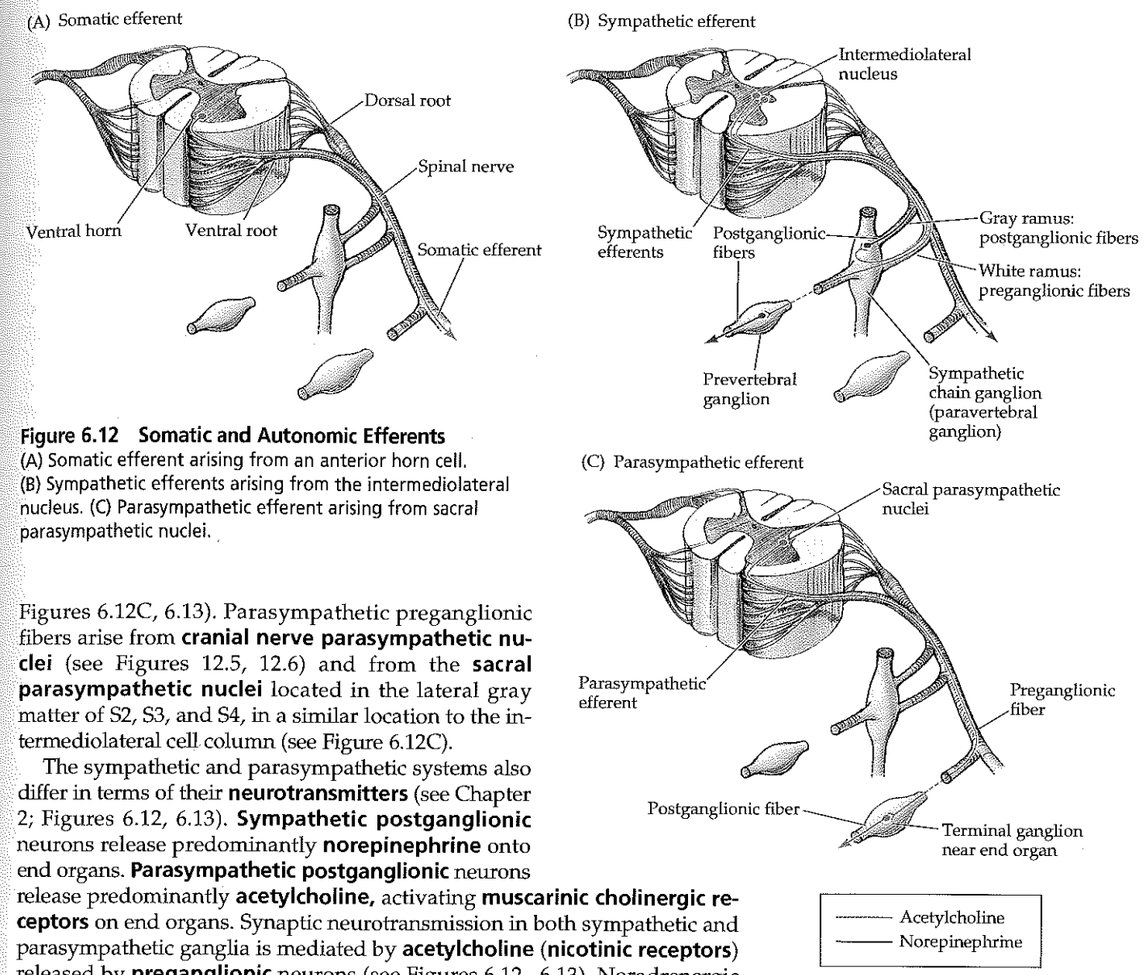

Figure 6.12 Somatic and Autonomic Efferents
(A) Somatic efferent arising from an anterior horn cell. (B) Sympathetic efferents arising from the intermediolateral nucleus. (C) Parasympathetic efferent arising from sacral parasympathetic nuclei.

Figures 6.12C, 6.13). Parasympathetic preganglionic fibers arise from **cranial nerve parasympathetic nuclei** (see Figures 12.5, 12.6) and from the **sacral parasympathetic nuclei** located in the lateral gray matter of S2, S3, and S4, in a similar location to the intermediolateral cell column (see Figure 6.12C).

The sympathetic and parasympathetic systems also differ in terms of their **neurotransmitters** (see Chapter 2; Figures 6.12, 6.13). **Sympathetic postganglionic** neurons release predominantly **norepinephrine** onto end organs. **Parasympathetic postganglionic** neurons release predominantly **acetylcholine,** activating **muscarinic cholinergic receptors** on end organs. Synaptic neurotransmission in both sympathetic and parasympathetic ganglia is mediated by **acetylcholine (nicotinic receptors)** released by **preganglionic** neurons (see Figures 6.12, 6.13). Noradrenergic (α_1, α_2, β_1, β_2, β_3) and cholinergic (M_1, M_2, M_3) receptor subtypes mediate different actions of these transmitters on end organs (see the References). In addition, various peptides and other substances (such as ATP and adenosine) are released at autonomic synapses. One notable exception to the norepinephrine/sympathetic, acetylcholine/parasympathetic rule for postganglionic neurotransmitters is the sweat glands, which are innervated by sympathetic postganglionic neurons that release acetylcholine (see Figure 6.13).*

Sympathetic and parasympathetic outflow are controlled both directly and indirectly by higher centers, including the hypothalamus (see Chapter 17), brainstem nuclei such as the nucleus solitarius (see Chapter 12), the amygdala, and several regions of limbic cortex (see Chapter 18). Autonomic responses are also regulated by afferent sensory information, including sig-

*For the interested reader, this point of relatively minor clinical significance can be remembered by noting that botulinum toxin, a blocker of cholinergic transmission, has recently been shown to be an effective treatment for hyperhidrosis (excessive sweating) when injected locally into the skin of the axilla.

MNEMONIC

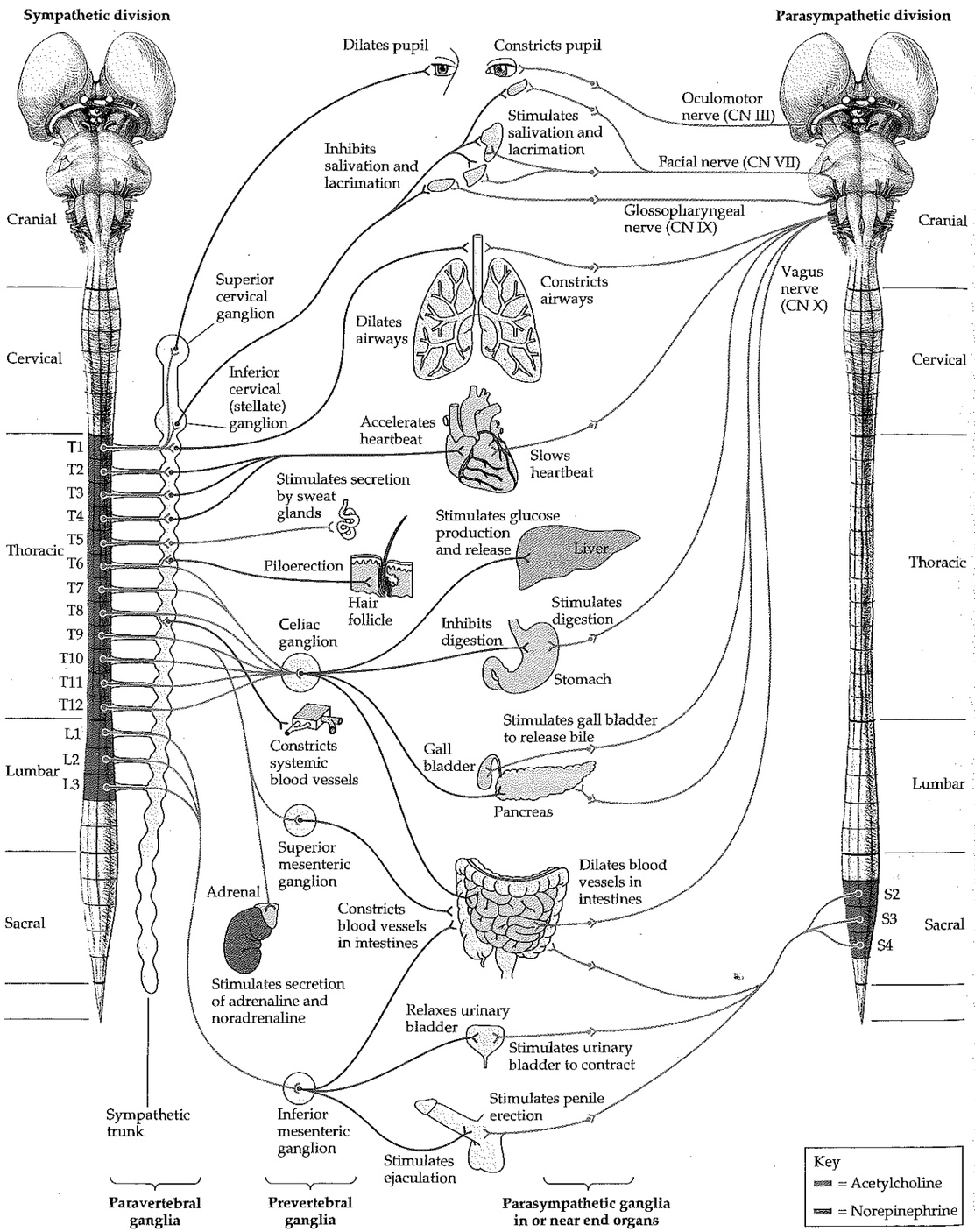

◀ **Figure 6.13 Sympathetic and Parasympathetic Divisions of the Autonomic Nervous System** Sympathetic outputs (left) arise from thoracolumbar spinal cord segments and synapse in paravertebral and prevertebral ganglia. Parasympathetic outputs (right) arise from craniosacral regions and synapse in ganglia in or near effector organs.

nals from internal receptors such as chemoreceptors, osmoreceptors, thermoreceptors, and baroreceptors.

KEY CLINICAL CONCEPT
UPPER MOTOR NEURON VERSUS LOWER MOTOR NEURON LESIONS

6.1 The concept of upper motor neuron versus lower motor neuron lesions is very useful in clinical localization (see Figure 6.8). **Upper motor neurons** of the corticospinal tract project from the cerebral cortex to lower motor neurons located in the anterior horn of the spinal cord. **Lower motor neurons** in turn project via peripheral nerves to skeletal muscle. An identical concept of upper and lower motor neurons applies to the corticobulbar tract and cranial nerve motor nuclei.

Signs of **lower motor neuron lesions** include muscle weakness, atrophy, fasciculations, and hyporeflexia (Table 6.4; see also neuroexam.com Video 48). **Fasciculations** are abnormal muscle twitches caused by spontaneous activity in groups of muscle cells. An example of a benign fasciculation not associated with motor neuron damage is the eyelid twitching often experienced during periods of fatigue, caffeine excess, and eye strain (such as while reading too much neuroanatomy in one night). Signs of **upper motor neuron lesions** include muscle weakness and a combination of increased tone (see neuroexam.com Videos 49 and 50) and hyperreflexia sometimes referred to as **spasticity.** Additional abnormal reflexes seen with upper motor neuron lesions, such as **Babinski's sign** (see Figure 3.2), Hoffmann's sign, posturing, and so on, are discussed in Chapter 3 (see also neuroexam.com Videos 58–60). Note that with acute upper motor neuron lesions there may initially be flaccid paralysis with decreased tone and decreased reflexes, which gradually, over hours or even months, develops into spastic paresis. Spinal shock is an example of this process (see KCC 7.2).

Increased tone and hyperreflexia do not occur in experimental animals when a selective lesion is made in the corticospinal tract alone. It has therefore been hypothesized that spasticity is caused by damage to descending inhibitory pathways that travel closely with the corticospinal tract, rather than by damage to the corticospinal tract itself. Loss of these descending inhibitory influences may lead to increased excitability of alpha motor neurons in the anterior horn, resulting in brisk reflexes and increased tone. Although this hypothesis fits available data, it has yet to be definitely proven. ■

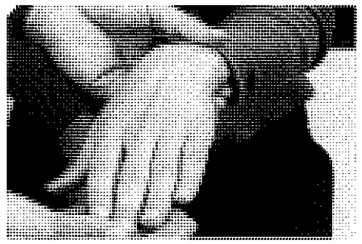
Atrophy? Fasciculations?

Lower extremity tone

TABLE 6.4 Signs of Upper Motor Neuron and Lower Motor Neuron Lesions

SIGN	UPPER MOTOR NEURON LESIONS	LOWER MOTOR NEURON LESIONS
Weakness	Yes	Yes
Atrophy	No[a]	Yes
Fasciculations	No	Yes
Reflexes	Increased[b]	Decreased
Tone	Increased[b]	Decreased

[a] Mild atrophy may develop due to disuse.
[b] With acute upper motor lesions, and tone may be decreased.

TABLE 6.5 Terms Commonly Used to Describe Weakness

TERM	DEFINITION	EXAMPLE	CLINICAL SYMPTOMS
DENOTING SEVERITY			
Paresis	Weakness (partial paralysis)	Hemiparesis	Weakness of one side of body (face, arm, and leg)
-plegia	No movement	Hemiplegia	No movement of one side of body (face, arm, and leg)
Paralysis	No movement	Leg paralysis	No movement of the leg
Palsy	Imprecise term for weakness or no movement	Facial palsy	Weakness or paralysis of face muscles
DENOTING LOCATION			
Hemi-	One side of body (face, arm, and leg)	Hemiplegia	No movement of one side of body (face, arm, and leg)
Para-	Both legs	Paraparesis	Weakness of both legs
Mono-	One limb	Monoparesis	Weakness of one limb (arm or leg)
Di-	Both sides of body equally affected	Facial diplegia	Symmetrical facial weakness
Quadri- or tetra-	All four limbs	Quadriplegia (tetraplegia)	Paralysis of all four limbs

KEY CLINICAL CONCEPT
TERMS USED TO DESCRIBE WEAKNESS

6.2 Weakness is one of the most important functional consequences of both upper and lower motor neuron lesions. Various terms are used in clinical practice to describe both the severity and distribution of weakness (Table 6.5). We will discuss localization of these different patterns of weakness in the next section. ■

KEY CLINICAL CONCEPT
WEAKNESS PATTERNS AND LOCALIZATION

6.3 Weakness can be caused by lesions or dysfunction at any level in the motor system, including the association and limbic cortices involved in volitional or motivational control of movement, the upper motor neurons of the corticospinal tract anywhere from cortex to spinal cord, the lower motor neurons anywhere from anterior horn to peripheral nerve, the neuromuscular junction, the muscles, and the mechanical functions of joints and tendons. The process of localizing lesions, as outlined in the sections that follow, involves choosing the correct motor system level, side, and specific neuroanatomical structures affected. In the illustrations in this section, lesions are shown in red and deficits are shown in purple.

Unilateral Face, Arm, and Leg Weakness or Paralysis

Other names: Hemiparesis or hemiplegia.

REVIEW EXERCISE

Cover the right two columns in Table 6.4. For each sign, state whether it is present, increased, or decreased with upper motor neuron lesions and with lower motor neuron lesions.

1. With No Associated Sensory Deficits (Figure 6.14A)

Other names: Pure motor hemiparesis.

Locations ruled out: Unlikely to be cortical because the lesion would have to involve the entire motor strip, in which case sensory involvement is hard to avoid. Unlikely to be muscle or peripheral nerve because in that case coincidental involvement of only half of the body would be required. Not the spinal cord or medulla because in that case the face would be spared.

Locations ruled in: Corticospinal and corticobulbar tract fibers below the cortex and above the medulla: posterior limb of the internal capsule, basis pontis, or middle third of the cerebral peduncle.

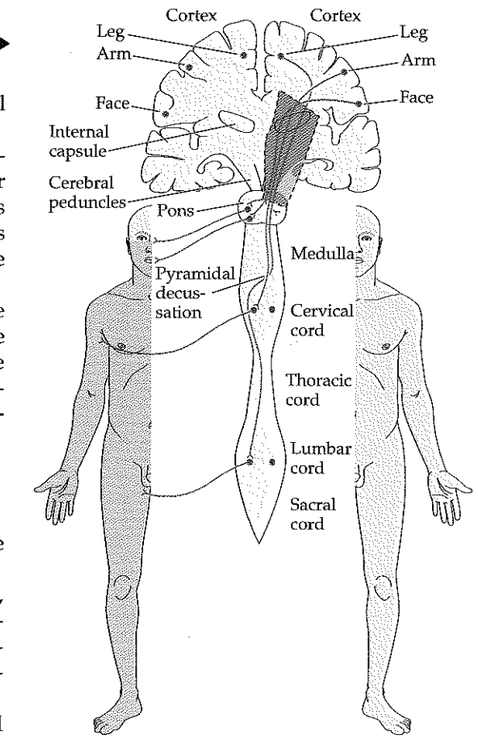

Figure 6.14A Pure Hemiparesis ▸

Side of lesion: Contralateral to weakness (above the pyramidal decussation).

Common causes: Lacunar infarct of the internal capsule (lenticulostriate branches of the middle cerebral artery or anterior choroidal artery; see Figures 10.7, 10.9; Table 10.3) or of the pons (median perforating branches of the basilar artery; see Figures 14.20B,C; Table 14.8). Infarct of the cerebral peduncle (see Figure 14.20A) is less common.

Associated features: Upper motor neuron signs (Table 6.4) are usually present. Dysarthria (see KCC 12.8) is common, giving rise to the name **dysarthria–pure motor hemiparesis.** Ataxia of the affected side may also occasionally be seen because of involvement of the cerebellar pathways, giving rise to the name **ataxia-hemiparesis** (see Table 10.3; KCC 15.2).

2. With Associated Somatosensory, Oculomotor, Visual, or Higher Cortical Deficits (Figure 6.14B)

Locations ruled out: Unlikely to be below the medulla, for the reasons listed in the previous section.

Locations ruled in: Entire primary motor cortex, including face, arm, and leg representations of the precentral gyrus, or corticospinal and corticobulbar tract fibers above the medulla (e.g, thalamocapsular lacune; see Table 10.3). The lesion can usually be further localized on the basis of other associated deficits.

Side of lesion: Contralateral to weakness (above the pyramidal decussation).

Associated features allowing further localization: In addition to somatosensory, oculomotor, visual, or higher cortical deficits such as aphasia or neglect, there may be dysarthria or ataxia. Upper motor neuron signs are usually present as well.

Common causes: Numerous, including infarct, hemorrhage, tumor, trauma, herniation, post-ictal state, and so on.

Unilateral Arm and Leg Weakness or Paralysis

(Figure 6.14C)

Other names: Hemiplegia or hemiparesis sparing the face; brachiocrural plegia or paresis.

Locations ruled out: Unlikely to be the corticospinal tract below the motor cortex above the medulla because the corticobulbar tract fibers are very nearby, and the face would thus usually be involved. Unlikely to be muscle or peripheral nerve because in that case coincidental involvement of only half of the body would be required. Not below C5 in the cervical cord because in that case some arm muscles would be spared.

Locations ruled in: Arm and leg area of the motor cortex; corticospinal tract from the lower medulla to the C5 level of cervical spinal cord.

Side of lesion: Motor cortex or medulla (above the pyramidal decussation): contralateral to weakness. Cervical spinal cord (below the pyramidal decussation): ipsilateral to weakness.

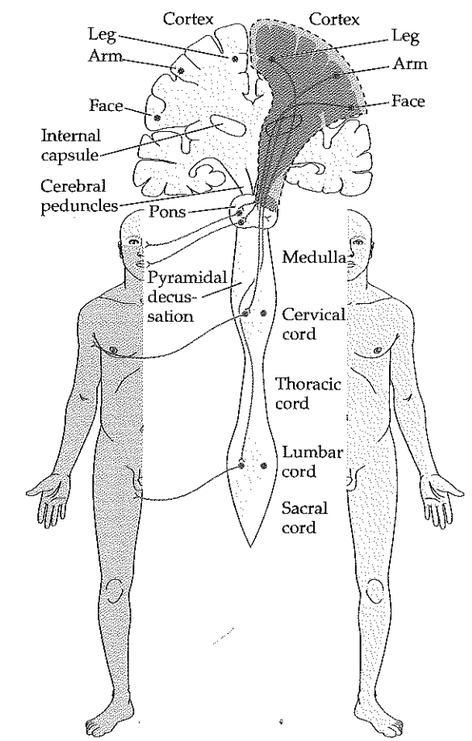

Figure 6.14B Hemiparesis with Additional Deficits ▸

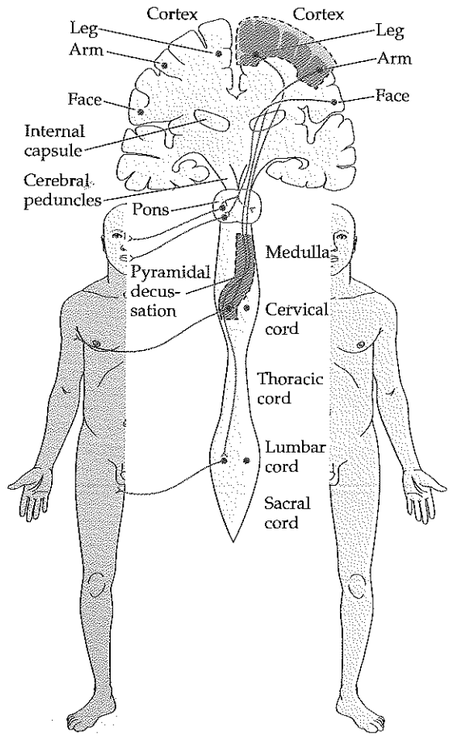

◀ **Figure 6.14C Hemiparesis Sparing the Face**

Associated features allowing further localization: Upper motor neuron signs are usually present. Cortical lesions sparing the face are often in a watershed distribution, and they affect proximal more than distal muscles ("man in the barrel" syndrome; see KCC 10.2). Cortical lesions may be associated with aphasia (see KCC 19.6) or hemineglect (see KCC 19.9). In medial medullary lesions there may be loss of vibration and joint position sense on the same side as the weakness, and tongue weakness on the opposite side (Figure 14.20D; Table 14.7). In lesions extending to the lateral medulla, the lateral medullary syndrome may be present (see KCC 14.3; Table 14.7). In lesions of the spinal cord, the Brown–Séquard syndrome may be present (see KCC 7.4). High cervical lesions may involve the spinal trigeminal nucleus and tract (see Figure 12.7), causing decreased facial sensation.

Common causes: Watershed infarct (anterior cerebral–middle cerebral watershed), medial or combined medial and lateral medullary infarcts, multiple sclerosis, lateral trauma, or compression of the cervical spinal cord.

Unilateral Face and Arm Weakness or Paralysis

(Figure 6.14D)

Other names: Faciobrachial paresis or plegia.

Locations ruled out: Unlikely to be muscle or peripheral nerve because in that case coincidental involvement of the face and arm would be required. Uncommon (but not impossible) in lesions at the internal capsule or below because the corticobulbar and corticospinal tracts are fairly compact, resulting in leg involvement with most lesions.

Locations ruled in: Face and arm areas of the primary motor cortex, over the lateral frontal convexity.

Side of lesion: Contralateral to weakness (above the pyramidal decussation).

Associated features allowing further localization: Upper motor neuron signs and dysarthria are usually present. In dominant-hemisphere lesions, Broca's aphasia is common (see KCC 19.6). In nondominant-hemisphere lesions, hemineglect may occasionally be present (see KCC 19.9). Sensory loss can occur if the lesion extends into the parietal lobe (see KCC 7.3).

Common causes: Middle cerebral artery superior division infarct is the classic cause (see Figures 10.1, 10.5). Tumor, abscess, or other lesions may also occur in this location.

Unilateral Arm Weakness or Paralysis (Figure 6.14E)

Other names: Brachial monoparesis or monoplegia; there are specific names for different weakness patterns associated with peripheral nerve injuries (see Table 8.1, KCC 9.1).

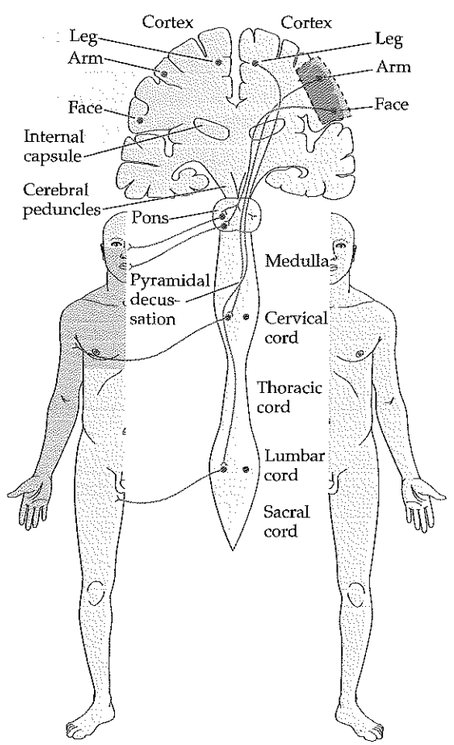

◀ **Figure 6.14D Unilateral Face and Arm Weakness**

Figure 6.14E Brachial Monoparesis ▶

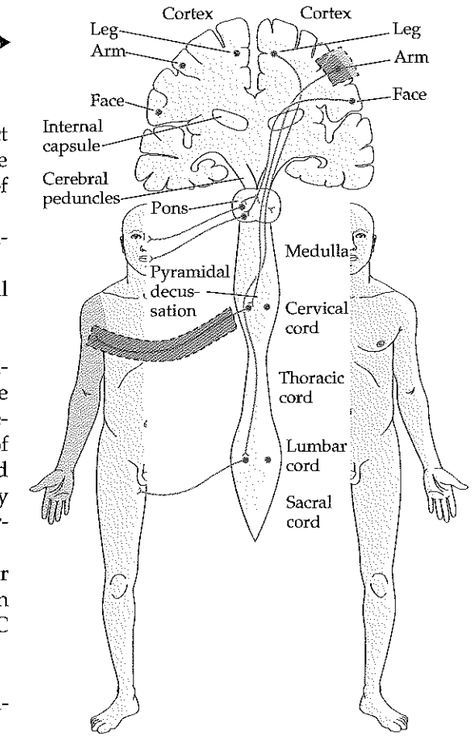

Locations ruled out: Unlikely anywhere along the corticospinal tract (internal capsule, brainstem, spinal cord), because in that case the face and/or lower extremity would also likely be involved. Rare cases of foramen magnum tumors may initially affect one arm.

Locations ruled in: Arm area of the primary motor cortex, or peripheral nerves supplying the arm.

Side of lesion: Motor cortex: contralateral to weakness. Peripheral nerves: ipsilateral to weakness.

Associated features allowing further localization:

Motor cortex lesions: There may be associated upper motor neuron signs, cortical sensory loss, aphasia (see KCC 19.6), or subtle involvement of the face or leg. Occasionally none of these are present. The weakness pattern may be incompatible with a lesion of peripheral nerves (see Table 8.1, KCC 9.1). For example, marked weakness of all finger, hand, and wrist muscles with no sensory loss and normal proximal strength does not occur with peripheral nerve lesions.

Peripheral nerve lesions: There may be associated lower motor neuron signs. Weakness and sensory loss may be compatible with a known pattern for a peripheral nerve lesion (see Table 8.1, KCC 9.1).

Common causes:

Motor cortex lesion: Infarct of a small cortical branch of the middle cerebral artery, or a small tumor, abscess, or the like.

Peripheral nerve lesion: Compression injury, diabetic neuropathy, and so on (see KCC 8.3, 9.1).

Unilateral Leg Weakness or Paralysis (Figure 6.14F)

Other names: Crural monoparesis or monoplegia; there are specific names for weakness patterns associated with various peripheral nerve or spinal cord lesions (see KCC 7.4, KCC 9.1; Table 8.1).

Locations ruled out: Unlikely to be in the corticospinal tract above the upper thoracic cord (internal capsule, brainstem, cervical spinal cord), because in that case the face and/or upper extremity would usually also be involved. Rarely, cervical cord tumors can initially cause leg weakness only.

Locations ruled in: Leg area of the primary motor cortex along the medial surface of the frontal lobe, lateral corticospinal tract below T1 in the spinal cord, or peripheral nerves supplying the leg.

Side of lesion: Motor cortex: contralateral to weakness. Spinal cord or peripheral nerves: ipsilateral to weakness.

Associated features allowing further localization:

Motor cortex lesions: There may be associated upper motor neuron signs, cortical sensory loss, frontal lobe signs such as a grasp reflex, or subtle involvement of the arm or face. Occasionally none of these are present. The weakness pattern may be incompatible with a lesion of peripheral nerves—for example, diffuse weakness of all muscles in one leg.

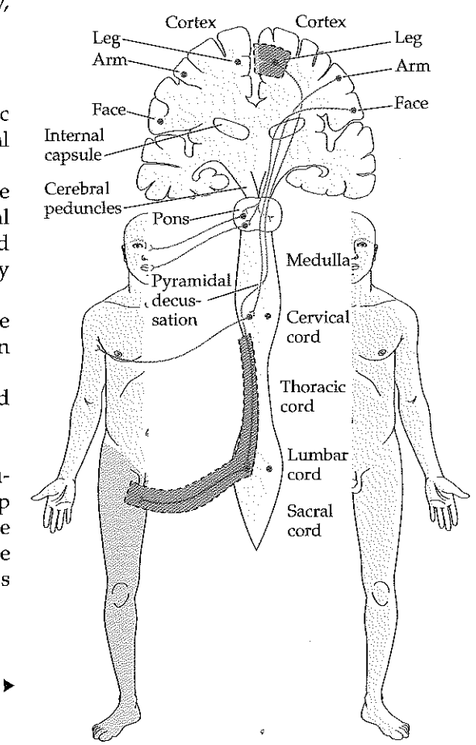

Figure 6.14F Crural Monoparesis ▶

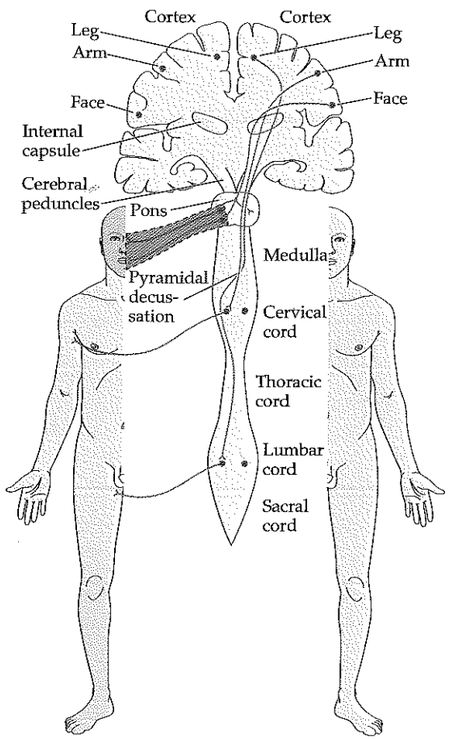

◀ **Figure 6.14G Facial Weakness (Lower Motor Neuron–Type)**

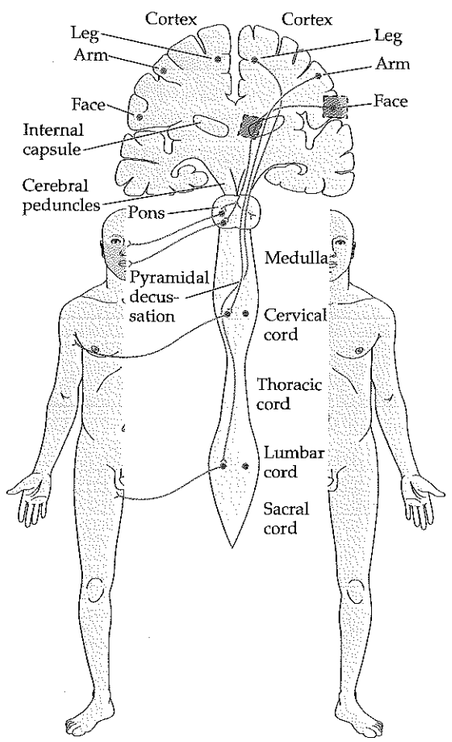

◀ **Figure 6.14H Facial Weakness (Upper Motor Neuron–Type)**

Spinal cord lesions: There may be associated upper motor neuron signs, a Brown–Séquard syndrome (see KCC 7.4), a sensory level, or some subtle spasticity of the contralateral leg. Sphincter function may be involved (see KCC 7.5). The weakness pattern may be incompatible with a lesion of peripheral nerves (see Table 8.1; KCC 9.1).

Peripheral nerve lesions: There may be associated lower motor neuron signs. Weakness and sensory loss may be compatible with a known pattern for a peripheral nerve lesion (see Chapters 8 and 9).

Common causes:

Motor cortex lesion: Infarct in the anterior cerebral artery territory, or a small tumor, abscess, or the like.

Spinal cord lesion: Unilateral cord trauma, compression by tumor, multiple sclerosis.

Peripheral nerve lesion: Compression injury, diabetic neuropathy, and so on.

Unilateral Facial Weakness or Paralysis (Figure 6.14G,H)

Other names: Bell's palsy (peripheral nerve); isolated facial weakness.

Locations ruled out: Unlikely with lesions below the rostral medulla.

Locations ruled in: Common: peripheral facial nerve (CN VII). Uncommon: lesions in the face area of the primary motor cortex or in the genu of the internal capsule (usually lesions in these locations cause arm and leg involvement as well); facial nucleus and exiting nerve fascicles in the pons or rostral lateral medulla.

Side of lesion: Facial nerve or nucleus: ipsilateral to weakness. Motor cortex or internal capsule: contralateral to weakness.

Associated features allowing further localization:

Facial nerve or nucleus lesions (lower motor neuron; see Figure 6.14G): The forehead and orbicularis oculi are not spared (see Figure 12.13, lesion B). With facial nerve lesions (e.g., Bell's palsy), there may be hyperacusis, decreased taste, and pain behind the ear on the affected side (see KCC 12.3). In facial nucleus lesions in the pons there are usually deficits associated with damage to nearby nuclei and pathways, such as CN VI, CN V, or the corticospinal tract (see Figures 12.11, 14.20C; Table 14.8). In rostral lateral medullary lesions, a lateral medullary syndrome will be present. Interestingly, some authors report the forehead to be spared (upper motor neuron pattern) in facial weakness caused by medullary lesions.

Motor cortex or capsular genu lesions (upper motor neuron; Figure 6.14H): The forehead is relatively spared (see Figure 12.13, lesion A). Dysarthria and unilateral tongue weakness are common. There may be subtle arm involvement. In cortical lesions, sensory loss or aphasia may be present.

Figure 6.14I Brachial Diparesis ▶

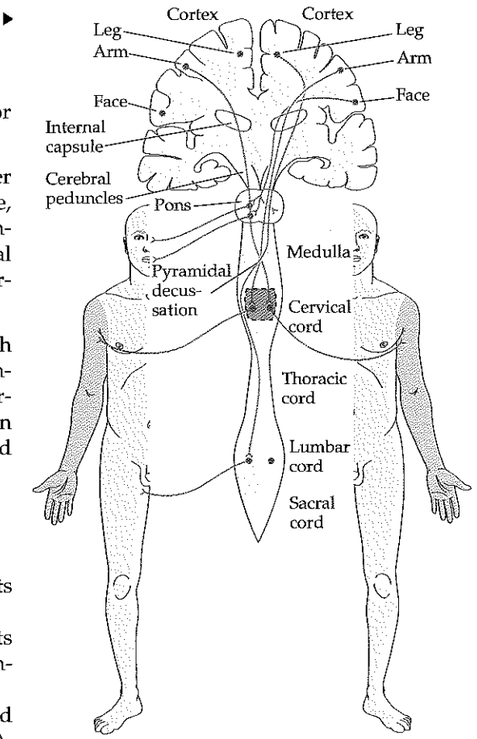

Common causes: Facial nerve: Bell's palsy, trauma, surgery. Motor cortex, capsular genu, pons, or medulla: infarct.

To summarize, only cases of isolated facial weakness of a lower motor neuron pattern, possibly with some hyperacusis, loss of taste, or retroauricular pain, can be localized with certainty to the peripheral facial nerve. The presence of sensory loss or any other cranial nerve or motor abnormalities requires evaluation for a central nervous system lesion.

Note that facial weakness may be difficult to detect in cases in which it occurs bilaterally, called **facial diplegia,** since the weakness is symmetrical. Causes include motor neuron disease (see KCC 6.7), bilateral peripheral nerve lesions (such as in Guillain–Barré syndrome or in bilateral Bell's palsy), or bilateral white matter abnormalities caused by ischemia or demyelination (such as in pseudobulbar palsy).

Bilateral Arm Weakness or Paralysis (Figure 6.14I)

Other names: Brachial diplegia.

Locations ruled out: Unlikely to be in the corticospinal tracts because in that case the face and/or legs would also be involved.

Locations ruled in: Medial fibers of both lateral corticospinal tracts (see Figure 6.10C); bilateral cervical spine ventral horn cells; peripheral nerve or muscle disorders affecting both arms.

Associated features allowing further localization: A central cord syndrome or anterior cord syndrome may be present (see KCC 7.4).

Common causes: Central cord syndrome: syringomyelia, intrinsic spinal cord tumor, myelitis. Anterior cord syndrome: anterior spinal artery infarct, trauma, myelitis. Peripheral nerve: bilateral carpal tunnel syndrome, or disc herniations.

Bilateral Leg Weakness or Paralysis (Figure 6.14J)

Other names: Paraparesis or paraplegia.

Locations ruled out: Unlikely to be in the corticospinal tracts above the upper thoracic cord (internal capsule, brainstem, cervical spinal cord) because in that case the face and/or upper extremities would also be involved. Rarely, cervical cord tumors can initially cause bilateral leg weakness without arm involvement.

Locations ruled in: Bilateral leg areas of the primary motor cortex along the medial surface of the frontal lobes; lateral corticospinal tracts below T1 in the spinal cord; cauda equina syndrome or other peripheral nerve or muscle disorders affecting both legs.

Associated features allowing further localization:

Bilateral medial frontal lesions: Upper motor neuron signs may be present. There may also be frontal lobe dysfunction (see KCC 19.11), including confusion, apathy, grasp reflexes, and incontinence.

Spinal cord lesions: Upper motor neuron signs (see Table 6.4), sphincter dysfunction, and autonomic dysfunction may be present.

Figure 6.14J Paraparesis ▶

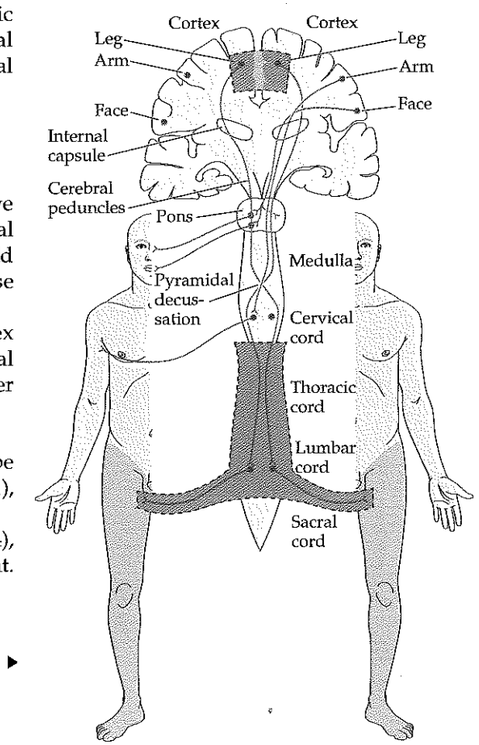

A sensory level (see Figure 8.4) or loss of specific reflexes (see Tables 3.6, 3.7) may help determine the segmental level of the lesion.

Bilateral peripheral nerve or muscle disorders: Cauda equina syndrome is associated with sphincter and erectile dysfunction, sensory loss in lumbar or sacral dermatomes, and lower motor neuron signs (see KCC 8.4). Distal symmetrical polyneuropathies (see KCC 8.1) tend to preferentially affect distal muscles, and may have associated distal "glove-stocking" sensory loss and lower motor neuron signs. Neuromuscular disorders and myopathies often (but not always) affect proximal more than distal muscles.

Common causes: Bilateral medial frontal lesions: parasagittal meningioma (see KCC 5.8), bilateral anterior cerebral artery infarcts (see Figure 10.5), cerebral palsy (bilateral periventricular leukomalacia).

Spinal cord lesions: Numerous, including tumor, trauma, myelitis (see KCC 7.2; Figure 7.10).

Bilateral peripheral nerve or muscle disorders: Cauda equina syndrome: tumor, trauma, disc herniation. Other peripheral nerve or muscle disorders (see KCC 8.1, 8.2, 9.1): The lower extremities are often clinically affected before the arms in Guillain–Barré syndrome, Lambert–Eaton syndrome, numerous muscle disorders, and distal symmetrical polyneuropathies (caused by diabetes and other toxic, metabolic, congenital, and inflammatory conditions).

Bilateral Arm and Leg Weakness or Paralysis (Figure 6.14K)

Other names: Quadriparesis, quadriplegia, tetraparesis, tetraplegia.

Locations ruled out: Unlikely to be below the motor cortex and above the medulla because the face would then be involved. Unlikely to be in the spinal cord below C5 because the arms would then be partly spared.

Locations ruled in: Bilateral arm and leg areas of the motor cortex; bilateral lesions of the corticospinal tracts from the lower medulla to C5. Peripheral nerve motor neuron or muscle disorders severe enough to affect all four limbs usually also affect the face, although in some cases face involvement may be relatively mild.

Associated features allowing further localization:

Bilateral motor cortex lesions: Cortical lesions sparing the face are often in a watershed distribution, and affect proximal more than distal muscles ("man in the barrel" syndrome; see KCC 10.2; Figure 10.10). Upper motor neuron signs are usually present, and there may be associated aphasia, neglect, or other cognitive disturbances (see Chapter 19).

Bilateral upper cervical cord lesions: Upper motor neuron signs (see Table 6.4) are usually present. There may be a sensory level (see Figure 8.4), sphincter dysfunction (see KCC 7.5), or autonomic dysfunction (gastric paresis, bladder atony, loss of erectile function, orthostatic hypotension). High cervical lesions may cause respiratory weakness and may involve the spinal trigeminal nucleus (see Figure 12.7), causing decreased facial sensation.

Lower medullary lesions: Upper motor neuron signs are usually present. There may be occipital headache (see KCC 5.1), tongue weakness (Figure 14.20D; Table 14.7), sensory loss, hiccups (see KCC 14.3), respiratory weakness, autonomic dysfunction, sphincter dysfunction (see KCC 7.5), or abnormal eye movements.

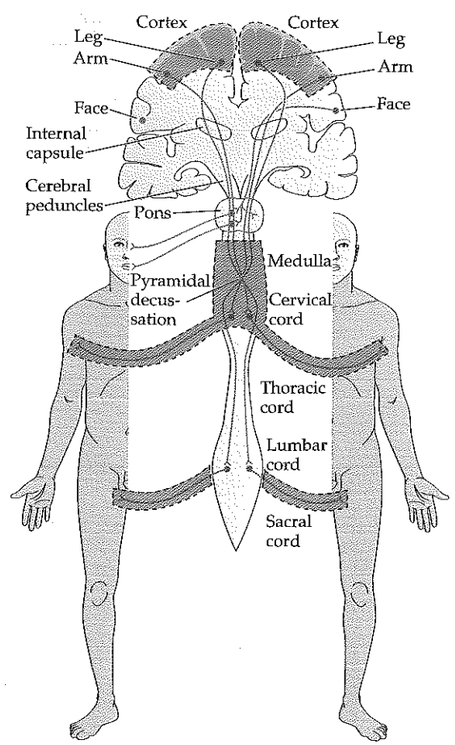

◂ **Figure 6.14K Quadriparesis**

Peripheral nerve or muscle disorders: Lower motor neuron signs may be present in nerve disorders.

Common causes:

Motor cortex lesions: Bilateral watershed infarcts (anterior cerebral–middle cerebral watershed) (see KCC 10.2).

Upper cervical cord and lower medullary lesions: Tumor, infarct, trauma, multiple sclerosis.

Peripheral nerve or muscle disorders: Numerous (see KCC 8.1, 8.2, 9.1).

Generalized Weakness or Paralysis

Locations ruled out: Small focal or unilateral lesions do not produce generalized weakness. Lesions of the lower medulla or spinal cord spare the face or upper extremities.

Locations ruled in: Bilateral lesions of the entire motor cortex; bilateral lesions of the corticospinal and corticobulbar tracts anywhere from corona radiata to pons; diffuse disorders involving all lower motor neurons, peripheral axons, neuromuscular junctions, or muscles.

Associated features allowing further localization: Bilateral cerebral or corticospinal lesions may be associated with upper motor neuron signs. Lesions of the peripheral nerves may be associated with lower motor neuron signs. Sensory loss, eye movement abnormalities, pupillary abnormalities, autonomic disturbances, or impaired consciousness may be present, and these features help determine the location and nature of the lesion. Respiratory depression is common with severe generalized weakness.

Common causes: Global cerebral anoxia, pontine infarct or hemorrhage (locked-in syndrome, see KCC 14.1), advanced amyotrophic lateral sclerosis (see KCC 6.7), Guillain–Barré syndrome, myasthenia, botulism (see KCC 8.1), and numerous other diffuse neoplastic, infectious, inflammatory, traumatic, toxic, or metabolic disturbances.

General Comment

For patterns of weakness not described here, consider two or multiple lesions, unusual lesions, anatomical variants, or non-neurologic weakness as the cause. See also Chapters 8 and 9 for additional details about weakness caused by specific peripheral nerve lesions, and Chapters 12–14 for weakness of extraocular muscles, jaw, neck, or tongue or of other specific muscles innervated by the cranial nerves. ■

KEY CLINICAL CONCEPT
DETECTING SUBTLE HEMIPARESIS AT THE BEDSIDE

6.4 Sometimes patients have no obvious weakness or upper motor neuron signs, yet clinical suspicion warrants additional probing for more subtle deficits. The following tests can help detect mild corticospinal damage. See Chapter 3 and neuroexam.com for a review of the basic motor exam.

Pronator drift: Patient holds arms extended, palms up, and closes eyes. Slight inward drifting rotation (pronation) of one forearm, or even a slight curling of the fingertips on one side, is abnormal (see neuroexam.com Video 51).

Finger extensors: Patient holds fingers extended and resists while examiner tries to flex them (see neuroexam.com Video 54). This is an excellent test because corticospinal damage generally spares flexors relative to extensors, and finger extensors are relatively weak muscles with large cortical representation.

Fine movements: Patient rapidly taps index finger and thumb together; taps each finger to the thumb in sequence; rapidly pronates and supinates the hand either by holding it up and "screwing in a lightbulb" or by alternately slapping the palm and dorsum of the hand against the thigh;

Drift

Rapid hand movements

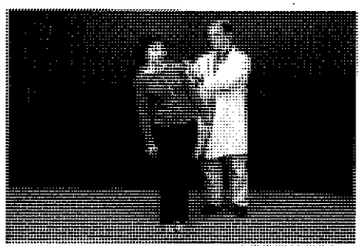

Romberg test

moves a coin from the palm to the fingers using one hand; taps the foot rapidly on the floor or bed (see neuroexam.com Videos 52, 53, 62, 63). The dominant hand or foot is normally only slightly faster at these tasks.

Isolated finger movements: Patient holds fingers abducted and extended and then moves one finger at a time.

Spastic catch: Feel for a subtle "catch" on one side only when holding the patient's hand in a handshake position and then rapidly supinating the patient's forearm (see neuroexam.com Video 49).

Subtle decreased nasolabial fold: Observe patient's face carefully in several different settings, including rest, spontaneous smiling (see neuroexam.com Video 40), and grimacing during exam, not just during voluntary smile.

Careful gait testing: Look for slight circumduction of one leg (the leg swings out in a circular arc with each step), or decreased arm swing. Also have the patient hop on each foot and walk on the toes (see neuroexam.com Videos 68, 69).

Forced gait: Patient walks on the outsides of the feet. Observe the hands carefully for subtle dystonic posturing on one side.

Silent plantar: If a normal flexor plantar response is present on the other side, a silent plantar response may represent a subtle Babinski's sign.

Quantitative testing: Under special circumstances, quantitative testing of motor power and speed may be helpful.

TABLE 6.6 Localization of Common Gait Disorders

NAME	LOCALIZATION	DESCRIPTION OF GAIT ABNORMALITIES	COMMON CAUSES
Spastic gait (see KCC 6.1)	Unilateral or bilateral corticospinal tracts	Unilateral or bilateral. Stiff-legged, circumduction, sometimes with scissoring of the legs and toe-walking (from increased tone in calf muscles), decreased arm swing, unsteady, falling toward side of greater spasticity.	Cortical, subcortical, or brainstem infarcts affecting upper motor neuron pathways; cerebral palsy; degenerative conditions; multiple sclerosis; spinal cord lesions
Ataxic gait (see KCC 15.2)	Cerebellar vermis or other midline cerebellar structures	Wide based, unsteady, staggering side to side, and falling toward side of worse pathology. Subtle deficit can be detected with tandem (heel-to-toe, or "drunk walk") gait testing.	Toxins such as alcohol; tumors of cerebellar vermis; infarcts or ischemia of cerebellar pathways; cerebellar degeneration
Vertiginous gait (see KCC 12.6)	Vestibular nuclei, vestibular nerve, or semicircular canals	Looks similar to ataxic gait, wide based and unsteady. Patients sway and fall when attempting to stand with feet together and eyes closed (Romberg sign).	Toxins such as alcohol; infarcts or ischemia of vestibular nuclei; benign positional vertigo; Meniere's disease
Frontal gait (see KCC 5.7, 19.11)	Frontal lobes or frontal subcortical white matter	Slow, shuffling, narrow or wide based, "magnetic" (barely raising feet off floor), unsteady. Sometimes resembles Parkinsonian gait. Some patients can perform cycling movements on their back much better than they can walk, giving rise to the term "gait apraxia" in this condition.	Hydrocephalus; frontal tumors such as glioblastoma or meningioma; bilateral anterior cerebral artery infarcts; diffuse subcortical white matter disease
Parkinsonian gait (see KCC 16.1, 16.2)	Substantia nigra or other regions of basal ganglia	Slow, shuffling, narrow based. Difficulty initiating walking. Often stooped forward, with decreased arm swing, and "en bloc turning." Unsteady, with "retropulsion," taking several rapid steps to regain balance when pushed backward.	Parkinson's disease; other parkinsonian syndromes, such as progressive supranuclear palsy, or use of neuroleptic drugs

General Comment

Keep in mind that damage to other systems, such as the cerebellum, basal ganglia, or even peripheral nerves, can also produce abnormalities in some of these tests, making it important to interpret the results in the context of a complete neurologic exam. ■

KEY CLINICAL CONCEPT
UNSTEADY GAIT

6.5 Gait disorders can be caused by abnormal function of almost any part of the nervous system, as well as by some orthopedic conditions. Careful examination of gait is therefore one of the most sensitive tests of subtle neurologic dysfunction (see neuroexam.com Videos 68, 69). Characteristic disorders of gait can be seen with lesions in specific systems, as described in Table 6.6. However, gait disorders alone often do not provide enough information for localization, and they must be analyzed in the context of a complete history and neurologic exam. In addition, in mild gait disorders only a few of the findings described in Table 6.6 may be present. ■

KEY CLINICAL CONCEPT
MULTIPLE SCLEROSIS

6.6 Multiple sclerosis is an autoimmune inflammatory disorder affecting central nervous system myelin. The cause is unknown, although there is mounting evidence that T lymphocytes may be triggered by a combination of genetic and environmental factors to react against oligodendroglial myelin. Myelin in the peripheral nervous system is not affected. Discrete

TABLE 6.6 *(continued)*

NAME	LOCALIZATION	DESCRIPTION OF GAIT ABNORMALITIES	COMMON CAUSES
Dyskinetic gait (see KCC 16.1, 16.3)	Subthalamic nucleus, or other regions of basal ganglia	Unilateral or bilateral dancelike (choreic), flinging (ballistic), or writhing (athetoid) movements occur during walking and may be accompanied by some unsteadiness.	Huntington's disease; infarct of subthalamic nucleus or striatum; side effect of levodopa; other familial or drug-induced dyskinesias
Tabetic gait (see KCC 7.4)	Posterior columns or sensory nerve fibers	High-stepping, foot-flapping gait, with particular difficulty walking in the dark or on uneven surfaces. Patients sway and fall in attempts to stand with feet together and eyes closed (Romberg sign).	Posterior cord syndrome; severe sensory neuropathy
Paretic gait (see KCC 8.3, 9.1)	Nerve roots, peripheral nerves, neuromuscular junction, or muscles	Exact appearance depends on location of lesion. With proximal hip weakness there may be a waddling, Trendelenburg gait. Severe thigh weakness may cause sudden knee buckling. Foot drop can cause a high-stepping, slapping gait, with frequent tripping.	Numerous peripheral nerve and muscle disorders
Painful (antalgic) gait	Peripheral nerve or orthopedic injury	Pain may be obvious based on patient's report or facial expression. Tends to avoid putting pressure on affected limb.	Herniated disc; peripheral neuropathy; muscle strain; contusions; fractures
Orthopedic gait disorder	Bones, joints, tendons, ligaments, and muscles	Depends on nature and location of the disorder. Peripheral nerve injury or spinal cord–related deficits may be present as well.	Arthritis; fractures; dislocations; contractures; soft tissue injuries
Functional gait disorder	Psychologically based	Can be hard to diagnose. Sometimes patients say they have poor balance, yet spontaneously perform highly destabilizing swaying movements while walking, without ever falling.	Conversion disorder; factitious disorder

plaques of demyelination and inflammatory response can appear and disappear in multiple locations in the central nervous system over time, eventually forming sclerotic glial scars. Demyelination causes slowed conduction velocity, dispersion or loss of coherence of action potential volleys, and ultimately conduction block. Because dispersion increases with temperature, some patients have worse symptoms when they are warm. In addition to demyelination, recent studies have shown that some axons may be destroyed as well in multiple sclerosis plaques.

Prevalence is about 0.1% in the United States, with a higher worldwide prevalence in whites from northern climates, and about a 2:1 female-to-male ratio. Lifetime risk of developing multiple sclerosis goes up to 3 to 5% if a first-degree relative is affected. Peak age of onset is 20 to 40 years. Onset before 10 or after 60 years is rare but not unheard of.

TABLE 6.7 Common Symptoms and Signs in Chronic Multiple Sclerosis

FUNCTIONAL SYSTEM	PERCENT FREQUENCY
MOTOR	
Muscle weakness	65–100
Spasticity	73–100
Reflexes (hyperreflexia, Babinski's sign, absent abdominals)	62–98
SENSORY	
Impairment of vibratory/position sense	48–82
Impairment of pain, temperature, or touch sense	16–72
Pain (moderate to severe)	11–37
Lhermitte's sign	1–42
CEREBELLAR	
Ataxia (limb/gait/truncal)	37–78
Tremor	36–81
Nystagmus (brainstem or cerebellar)	54–73
Dysarthria (brainstem or cerebellar)	29–62
CRANIAL NERVE/BRAINSTEM	
Vision affected	27–55
Ocular disturbances (excluding nystagmus)	18–39
Cranial nerves V, VII, VIII	5–52
Bulbar signs	9–49
Vertigo	7–27
AUTONOMIC	
Bladder dysfunction	49–93
Bowel dysfunction	39–64
Sexual dysfunction	33–59
Others (sweating and vascular abnormalities)	38–43
PSYCHIATRIC	
Depression	8–55
Euphoria	4–18
Cognitive abnormalities	11–59
MISCELLANEOUS	
Fatigue	59–85

Source: Rowland LP (ed.). 2000. *Merritt's Textbook of Neurology*, 10th Ed. Lippincott Williams and Wilkins, Baltimore, MD, Table 13.1.

The classic clinical definition of multiple sclerosis is *two or more deficits separated in neuroanatomical space and time*. In practice, the **diagnosis** is based on the presence of typical clinical features, together with MRI evidence of white matter lesions, slowed conduction velocities on evoked potentials, and the presence of oligoclonal bands in cerebrospinal fluid obtained by lumbar puncture (see KCC 5.10). **Oligoclonal bands** are abnormal discrete bands seen on CSF gel electrophoresis. They result from the synthesis of large amounts of relatively homogeneous immunoglobulin by individual plasma cell clones in the cerebrospinal fluid (CSF). Oligoclonal bands are present in over 85% of patients with clinically definite multiple sclerosis, but they can be seen in about 8% of patients with other disorders as well. CSF with more than 50 white blood cells or with nonlymphocytes is unusual for multiple sclerosis. MRI findings suggestive of multiple sclerosis include multiple T2-bright areas, representing demyelinative plaques located in the white matter. The plaques tend to extend into the white matter from periventricular locations (resulting in "Dawson's fingers"), and they occur in both supratentorial and infratentorial structures. Acute plaques may enhance with gadolinium. The clinical features described here need not all be present to make the diagnosis of multiple sclerosis. In unusual or atypical cases of suspected multiple sclerosis it is essential to test for other inflammatory, infectious, neoplastic, hereditary, and degenerative conditions that can have similar clinical features.

Multiple sclerosis can affect numerous systems (Table 6.7). When patients first present with obvious symptoms, more subtle previous episodes can often be elicited in retrospect. About 50% of patients with a single episode of optic neuritis (see KCC 11.4) or transverse myelitis (see Table 7.4) subsequently develop multiple sclerosis. The course of multiple sclerosis can be relapsing–remitting, progressive, or a mixture of these. Median survival from time of onset is 25 to 35 years and is continuing to increase with modern interventions. Current therapies include immunomodulators such as high-dose steroids, azathioprine, cyclophosphamide, interferon beta, and copolymer-1, which are not curative but can speed recovery from exacerbations and slightly delay progression. In addition, multidisciplinary treatment of symptoms such as spasticity; pain; impaired bowel, bladder and sexual function; diplopia; dysphagia; and psychiatric manifestations can impove quality of life and prolong survival. ■

KEY CLINICAL CONCEPT

MOTOR NEURON DISEASE

6.7 Several relatively uncommon disorders can selectively affect upper motor neurons, lower motor neurons, or both, producing motor deficits without sensory abnormalities or other findings. Most of these disorders are degenerative conditions referred to collectively as **motor neuron disease.** The classic example of motor neuron disease is **amyotrophic lateral sclerosis,** also known as **ALS** or **Lou Gehrig's disease.** ALS is characterized by gradually progressive degeneration of both upper motor neurons and lower motor neurons, leading eventually to respiratory failure and death. ALS has an incidence of 1 to 3 per 100,000 and is slightly more common in men, by a factor of about 1.5. Usual age of onset is in the 50s and 60s, although early-onset cases can be seen. Most cases occur sporadically, but there are also inherited forms that can have autosomal dominant, recessive, or X-linked transmission.

Initial symptoms are usually weakness or clumsiness, which *often begins focally* and then spreads to involve adjacent muscle groups. Painful muscle cramping and fasciculations are also common. Some patients present initially with predominantly bulbar complaints, such as dysarthria and dysphagia, or with respiratory symptoms. On neurologic examination, patients with ALS have weakness, with upper motor neuron findings such as increased tone and brisk reflexes, as well as lower motor neuron findings such as atrophy and fasciculations (see Table 6.4), sometimes best appreciated in the tongue muscles. A head droop is often present because of weakness of the neck muscles. Some patients have uncontrollable bouts of laughter or crying without the usual accompanying emotions, a finding known as pseudobulbar affect (see KCC 12.8). Sensory exam and mental status are typically normal. The extraocular muscles tend to be relatively spared. As the disease progresses, some patients can communicate only through eye movements. Electromyography (see KCC 9.2) shows evidence of muscle denervation and reinnervation in two or more extremities.

Unfortunately, there is no cure for this tragic disorder at present, and median survival from onset is 23 to 52 months. Riluzole, a blocker of glutamate release, has been shown to prolong survival by several months, and experimental trials with other agents are under way. Education of the patient and family about this disorder, and implementation of a comprehensive program of medical and psychosocial services, are imperative.

In evaluating patients with suspected ALS, it is important to test for other disorders that can rarely cause similar clinical findings. These include lead toxicity, dysproteinemia, thyroid dysfunction, vitamin B_{12} deficiency, vasculitis, paraneoplastic syndromes (see KCC 5.8), hexosaminidase A deficiency, multifocal motor neuropathy with conduction block, and other disorders. Cervical spine compression can occasionally produce a mixture of upper motor neuron signs (cord compression) and lower motor neuron signs in the upper extremities (nerve root compression). A cervical MRI is helpful to rule this out.

Some motor neuron disorders affect primarily upper motor neurons or primarily lower motor neurons. **Primary lateral sclerosis** is an example of an upper motor neuron disease, while **spinal muscular atrophy** affects lower motor neurons. Spinal muscular atrophy occurring in infancy is known as Werdnig–Hoffmann disease and usually leads to death by the second year of life. Much progress has been made recently in understanding the molecular basis of motor neuron disorders, offering some hope that we will have effective treatments for these devastating disorders in the near future. ■

CLINICAL CASES

CASE 6.1 SUDDEN ONSET OF RIGHT HAND WEAKNESS

CHIEF COMPLAINT
A 64-year-old man developed right hand weakness following cardiac arrest.

HISTORY
The patient had a history of hypertension and cigarette use but was otherwise healthy until the day of admission, when he suddenly collapsed in church. Family members at the scene administered immediate CPR, and when the ambulance arrived the patient received electrical defibrillation and promptly regained a normal cardiac rhythm. He was admitted to the cardiac intensive care unit and was found to have episodes of rapid atrial fibrillation. Several days after admission he was noted to have **weakness of the right hand,** and a neurology consult was requested.

PHYSICAL EXAMINATION
Vital signs: T = 98°F, P = 100, BP = 130/60.
Neck: Supple with no bruits.
Lungs: Clear.
Heart: Irregular rhythm, with a soft systolic murmur.
Abdomen: Normal bowel sounds; soft, nontender.
Extremities: Normal.
Neurologic exam:
MENTAL STATUS: Alert and oriented × 3. Language fluent, with intact naming, repetition, and reading. Able to recall 3/3 objects after 5 minutes.
CRANIAL NERVES: Normal, including no facial weakness.
MOTOR: Power 5/5 throughout, except for right hand and wrist: **Right wrist flexion, extension, and hand grip 3/5. Right finger extension, abduction, adduction, and thumb opposition 0/5.**
REFLEXES:

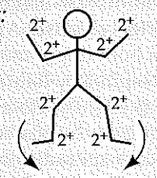

COORDINATION AND GAIT: Not tested.
SENSORY: Intact light touch, pinprick, joint position, and vibration sense. No extinction on double simultaneous stimulation.

LOCALIZATION AND DIFFERENTIAL DIAGNOSIS
1. On the basis of the symptoms and signs shown in **bold** above, where is the lesion?
2. Given the relatively acute onset of the deficits and the presence of atrial fibrillation, what is the most likely diagnosis? What are some other possibilities?

Discussion

1. The key symptom and sign in this case is:
   - **Isolated right-sided weakness of wrist flexion and extension, finger flexion, extension, abduction, and adduction, and thumb opposition**

   Isolated hand weakness can be caused by a lesion in the primary motor cortex or in peripheral nerves (see KCC 6.3; Figure 6.14E). There are no upper or lower motor neuron signs to help localization in this patient. However, weakness of all finger, hand, and wrist muscles with no sensory loss and no proximal weakness cannot be explained by a peripheral nerve lesion (see KCC 8.2, 9.1; Table 8.1).

   The most likely *clinical localization* is left precentral gyrus, primary motor cortex, hand area.
2. Given the presence of cardiac disease including atrial fibrillation, and the relatively acute onset of deficits, the most likely diagnosis is an embolic infarct (see KCC 10.4). An infarct of the left precentral gyrus hand area would be caused by occlusion of a small cortical branch of the left middle cerebral artery, superior division (see Figures 10.5, 10.6). Some other, much less likely causes of a lesion in the cortex in this setting include a small cortical hemorrhage, brain abscess, or tumor.

Clinical Course and Neuroimaging 246

A **head CT** (Figure 6.15) showed an area of hypodensity representing a cortical infarct in the left precentral gyrus in approximately the hand area (compare to Figure 6.2). Additional workup revealed that the patient had a dilated heart and continued to be at risk for atrial fibrillation and recurrent emboli. He was therefore treated with anticoagulation therapy and antiarrhythmic drugs. By 10 days after the initial consult, his right hand strength had improved substantially, with wrist flexors and extensors 5/5 strength, finger flexors $4^+/5$, and finger extensors $4^-/5$.

CASE 6.2 SUDDEN ONSET OF LEFT FOOT WEAKNESS

CHIEF COMPLAINT
An 81-year-old woman presented to the emergency room because of left foot weakness.

HISTORY
The patient was previously healthy except for a history of hypertension and diabetes. On the morning of admission, as she got out of bed she noticed difficulty when she first put her left foot on the floor. As she tried to walk, she felt that she was **dragging her left foot.** Nevertheless, she continued her usual morning activities, using a chair for support. Later in the morning, when the gait difficulty persisted, she called her children, who brought her to the emergency room. She had no other complaints except for a mild **right frontal headache.**

PHYSICAL EXAMINATION
Vital signs: Not recorded on admission.
Neck: Supple with no bruits.
Lungs: Clear.
Heart: Regular rate, with soft systolic murmur.
Abdomen: Benign, with normal bowel sounds.
Extremities: Normal.
Neurologic exam:
MENTAL STATUS: Alert and oriented × 3. Speech fluent, with intact naming and comprehension.
CRANIAL NERVES: Normal, including no facial weakness.
MOTOR: No pronator drift. Normal tone. Power 5/5 throughout, except for left foot and leg: **Left iliopsoas and hamstrings $4^+/5$, left ankle dorsiflexion and extensor hallucis longus 4/5.**
REFLEXES:

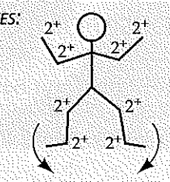

COORDINATION: Normal except for **slowing of heel-to-shin testing with left leg.**
GAIT: Not tested.
SENSORY: Intact light touch, temperature, joint position, and vibration sense.

LOCALIZATION AND DIFFERENTIAL DIAGNOSIS
1. On the basis of the symptoms and signs shown in **bold** above, where is the lesion?
2. Given the sudden onset of symptoms in an elderly patient with diabetes and hypertension, what is the most likely diagnosis? What are some other possibilities?

Discussion

1. The key symptoms and signs in this case are:
   - **Isolated left-sided weakness and slowness of the iliopsoas, hamstrings, ankle dorsiflexors, and extensor hallucis longus**
   - **Right frontal headache**

   Isolated leg weakness can be caused by a lesion in the primary motor cortex, spinal cord, or peripheral nerves (see KCC 6.3; Figure 6.14F). There are no upper or lower motor neuron signs to help localization. However, weakness in both a femoral and sciatic nerve distribution with no sensory loss (see Table 8.1; KCC 8.2, 9.1) makes a peripheral nerve or spinal cord lesion less likely. In addition, the right frontal headache suggests a cranial localization (see KCC 5.1).

The most likely clinical localization is: right precentral gyrus, primary motor cortex, leg area.

2. Given the presence of diabetes and hypertension and the relatively acute onset of deficits, the most likely diagnosis is an embolic infarct (see KCC 10.4). An infarct of the right precentral gyrus leg area would be caused by occlusion of a cortical branch of the right anterior cerebral artery (see Figure 10.5). Some other, less likely causes of a cortical lesion in this setting include a small hemorrhage, brain abscess, or tumor. A spinal cord lesion or motor neuron disease is unlikely but still possible.

Clinical Course and Neuroimaging 248

A **head MRI** (Figure 6.16) showed increased T2 signal representing an infarct in right primary motor cortex leg area. The strength in the patient's right foot gradually improved to the $4^+/5$ to 5/5 range by the time she was discharged home. A variety of tests were done (see KCC 10.4) but showed no obvious cause for the stroke. She was therefore entered into an experimental trial for strokes of unknown cause comparing treatment with aspirin to Coumadin.

CASE 6.1 SUDDEN ONSET OF RIGHT HAND WEAKNESS

Figure 6.15 Infarct in Left Precentral Gyrus Hand Area (A–C) Head CT with sequentially higher horizontal slices. The infarct in the left precentral gyrus hand area is visible in (B) and (C). (Compare to the normal CT in the Neuroradiological Atlas, Figure 4.12.)

(A)

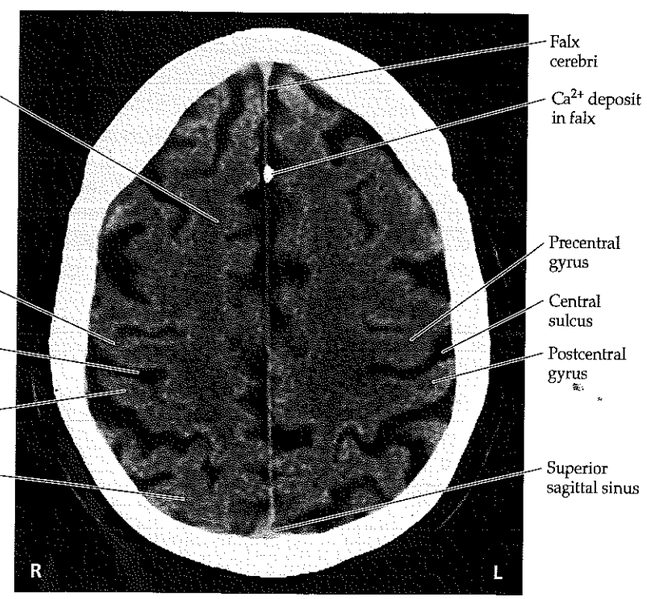

CASE 6.1 *(CONTINUED)*

(B)

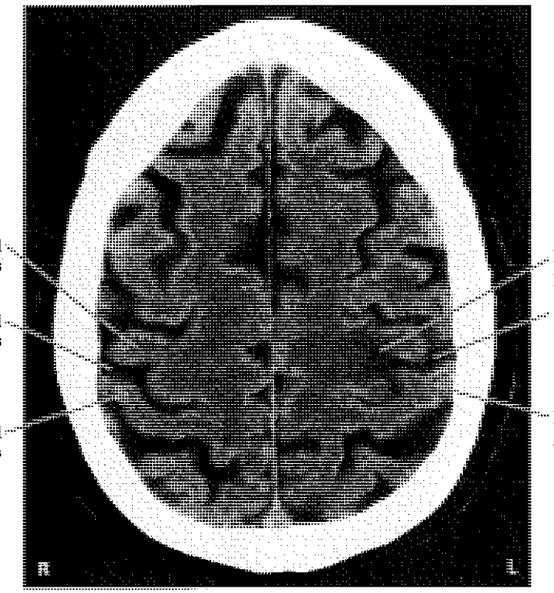

(C)

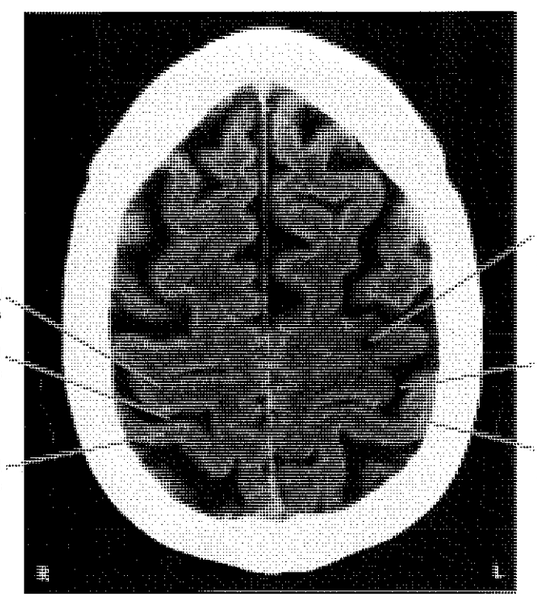

CASE 6.2 SUDDEN ONSET OF LEFT FOOT WEAKNESS

Figure 6.16 Infarct in Right Precentral Gyrus Leg Area (A–C) Sequentially higher axial (horizontal) T2-weighted MRI images. The infarct in the right precentral gyrus leg area is visible in (B) and (C). (Compare to normal MRIs in Neuroradiological Atlas Figures 4.6B and 4.14.)

(A)

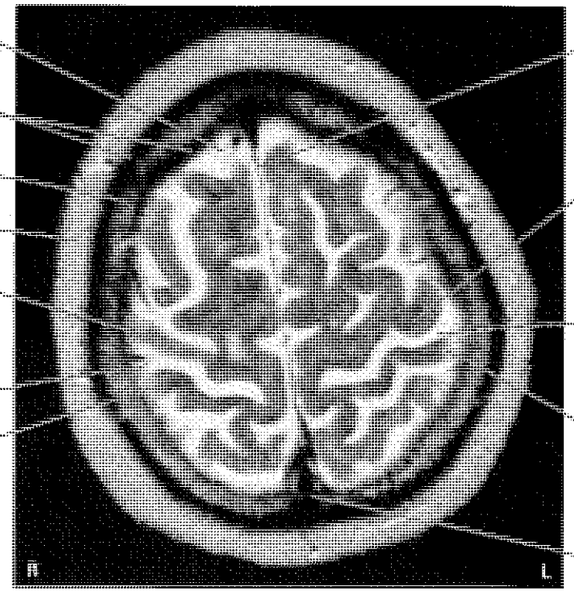

(B)

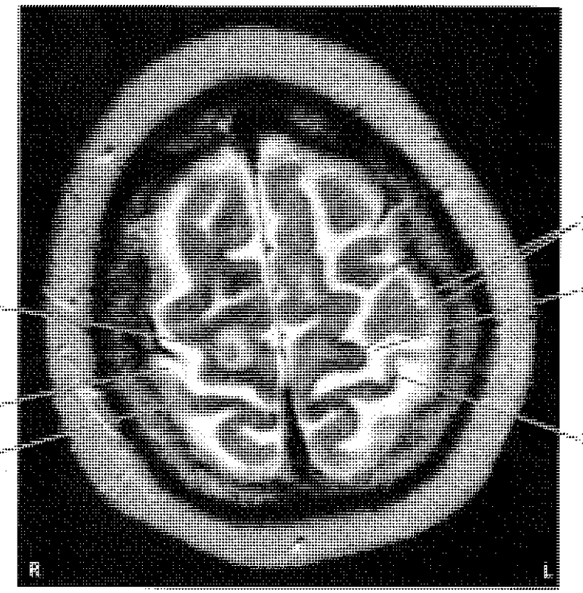

CASE 6.2 *(CONTINUED)*

(C)

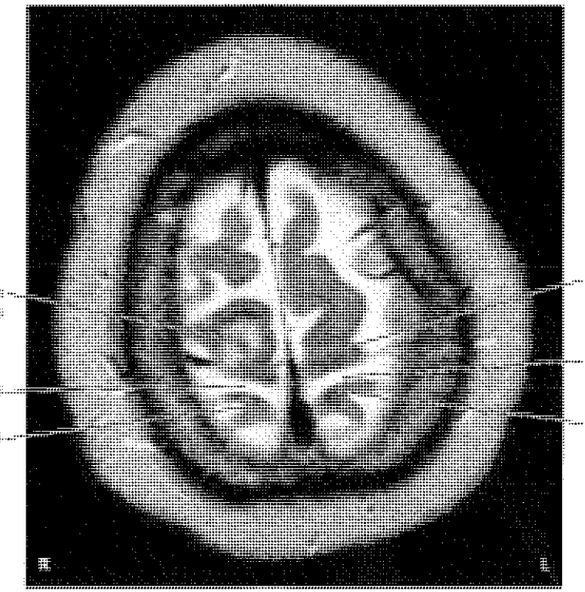

CASE 6.3 SUDDEN ONSET OF RIGHT FACE WEAKNESS

CHIEF COMPLAINT

A 62-year-old man came to the emergency room with right facial weakness.

HISTORY

The patient awoke in the morning with a "funny feeling" in his right eye and thought he might have conjunctivitis. He looked in the mirror and noticed his right eyebrow drooping. He also thought his speech sounded slightly slurred, so he called his wife to confirm this. She told him to go to the emergency room, and he complied. Past medical history was notable for diabetes.

PHYSICAL EXAMINATION

Vital signs: T = 97°F, P = 80, BP = 160/80, R = 18.
Neck: Supple with no bruits.
Lungs: Clear.
Heart: Regular rate and rhythm, with no murmurs, gallops, or rubs.
Abdomen: Normal bowel sounds; soft, nontender.
Extremities: Normal.

Neurologic exam:

MENTAL STATUS: Alert and oriented × 3. Speech fluent, with intact naming and repetition. Recalled 3/3 words after 5 minutes.

CRANIAL NERVES: Pupils 4 mm, constricting to 3 mm with light bilaterally. Visual fields full. Extraocular movements intact. Normal optokinetic nystagmus bilaterally. Intact pinprick sense, light touch sense, and graphesthesia in V_1, V_2, and V_3. Intact corneal reflex bilaterally. **Right eyebrow slightly depressed. Right lower face showed delay of movements with smile.** Taste on both sides of tongue intact in response to mustard or sweet preserves on a cotton swab. Hearing normal to finger rub. Normal gag and normal palate elevation. **Speech** sounded normal. (The patient felt it was still **mildly slurred,** but better than earlier in the day). Normal sternomastoid strength. Tongue midline.

MOTOR: No pronator drift. However, with pronation testing there was **trace curling of the right fingertips** (see KCC 6.4) with palms upward and eyes

CASE 6.3 *(CONTINUED)*

closed that was not seen on the left side. Normal tone. Normal finger and toe taps. Power 5/5 throughout.

REFLEXES:

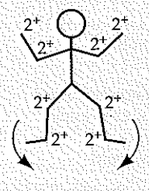

COORDINATION AND GAIT: Normal on finger-to-nose and heel-to-shin testing bilaterally. Normal reverse tandem gait. No Romberg sign.

SENSORY: Intact light touch, pinprick, and vibration sense and graphesthesia.

LOCALIZATION AND DIFFERENTIAL DIAGNOSIS

1. On the basis of the symptoms and signs shown in **bold** above, where is the lesion?
2. What is the most likely diagnosis? What are some other possibilities?

Discussion

1. The key symptoms and signs in this case are:
   - **Right eyebrow slightly depressed; right lower face showed delay of movements with smile; speech mildly slurred**
   - **Trace curling of the right fingertips**

   Unilateral facial weakness without other significant deficits is most commonly caused by peripheral lesions of the facial nerve (see KCC 6.3; Figure 6.14G). However, it can occasionally be seen in cortical lesions or in lesions of the internal capsule genu (see Figures 6.10A, 6.14H). Our patient's main problem was right facial weakness, but he also had other subtle neurological findings. The presence of mild dysarthria and finger curling suggests involvement of the corticobulbar and corticospinal tracts as well, respectively. Thus, the lesion is most likely located in the left motor cortex face area (see Figure 6.14H), with slight impingement on adjacent structures or in the left capsular genu. One unusual feature of this case is the slight involvement of the eyebrow, which is normally spared in upper motor neuron–type facial weakness.
2. Given the presence of diabetes and the relatively acute onset of deficits, the most likely diagnosis is an embolic infarct (see KCC 10.4). An infarct of the left precentral gyrus face area would be caused by occlusion of a cortical branch of the left middle cerebral artery (see Figure 10.6). Some other, less likely causes of a cortical lesion in this setting include a small hemorrhage, brain abscess, or tumor.

Clinical Course and Neuroimaging

A conventional MRI done in the emergency room was normal. However, a **diffusion-weighted MRI** (see Chapter 4) done at the same time revealed several small areas of decreased diffusion (increased signal) in the left precentral gyrus. The **"omega"** (or inverted omega) in the central sulcus, a landmark usually corresponding to the hand area on axial MRI sections (see Figures 4.11C, 4.13J), can be identified in Figure 6.17B. Note that the diffusion changes are lateral to this, suggesting that they are in the face motor cortex.

Within a few hours of his arrival in the emergency room, the trace curling of this patient's right fingertips on pronation testing disappeared. He was admitted to the hospital, and by the next day the patient and his wife no longer felt that his speech was slurred. However, his right face remained mildly weak. Investigations for an embolic source (see KCC 10.4) were negative. He was discharged home on aspirin to reduce his risk of future strokes.

CASE 6.4 PURE MOTOR HEMIPARESIS I

CHIEF COMPLAINT

A 31-year-old woman developed **left face, arm, and leg weakness.**

HISTORY

Three days prior to admission, while on a business trip, the patient noticed some difficulty walking, **veering slightly to the left and bumping into corners and walls on her left side.** The next day she had some **stuttering of her speech,** which subsequently resolved. She returned home, and on the morning of admission she noticed that her **left arm and hand were somewhat weak and clumsy.** She did not have any sensory symptoms, visual problems, headaches, or changes in bowel or bladder function. Her symptoms worsened in a warm meeting room and improved with a cold shower.

PHYSICAL EXAMINATION

Vital signs: T = 98.4°F, P = 85, BP = 132/81, R = 20.
Neck: Supple.
Lungs: Clear.
Heart: Regular rate with no murmurs.
Abdomen: Normal bowel sounds; soft, nontender.
Extremities: Normal.
Neurologic exam:

MENTAL STATUS: Alert and oriented × 3. Recalled 2/3 words after 5 minutes. Speech fluent, with intact comprehension and repetition. No neglect on drawing a clock face or on line cancellation tasks. Normal abstraction and judgment.

CRANIAL NERVES: Normal except for a **decreased left nasolabial fold.** No dysarthria on exam. Fundi normal.

MOTOR: No pronator drift. **Tone slightly increased in left arm. Rapid finger tapping slower on the left. Power 4+/5 in left deltoid, triceps, iliopsoas, quadriceps, and hamstrings.** Power otherwise 5/5 throughout.

REFLEXES:

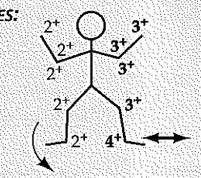

COORDINATION: Normal on finger-to-nose testing bilaterally.

GAIT: **Tends to veer to the left, especially with eyes closed. Decreased arm swing on the left. Unsteady tandem gait, falling to the left.**

SENSORY: Intact light touch, pinprick, temperature, vibration, and joint position sense.

LOCALIZATION AND DIFFERENTIAL DIAGNOSIS

1. On the basis of the symptoms and signs shown in **bold** above, where is the lesion?
2. What is the most likely diagnosis? What are some other possibilities?

Discussion

1. The key symptoms and signs in this case are:
   - **Left face, arm, and leg weakness, clumsiness, slowness, increased tone, hyperreflexia, and equivocal Babinski's sign**
   - **Dysarthria**
   - **Unsteady gait, falling to the left, with decreased left arm swing**

   This patient has pure motor hemiparesis, with left face, arm, and leg upper motor neuron–type weakness and no sensory or cortical deficits such as neglect, aphasia, or other cognitive or visual disorders. Pure motor hemiparesis can be caused by lesions of the contralateral corticobulbar and corticospinal tracts, most commonly in the internal capsule or pons (see KCC 6.3; Figure 6.14A). Dysarthria can be caused by lesions in numerous locations (see KCC 12.8) but often accompanies pure motor hemiparesis, giving rise to the term "dysarthria-hemiparesis." Similarly, the unsteady gait could be caused by numerous lesions (see KCC 6.5) but is most easily explained by the patient's spastic left hemiparesis.

   The most likely *clinical localization* is right corticobulbar and corticospinal tracts in the posterior limb of the internal capsule or ventral pons.
2. Pure motor hemiparesis is usually caused by lacunar infarction (see Table 10.3) of the contralateral internal capsule or pons. However, given that the patient is a woman in her 30s with no vascular risk factors whose symptoms worsen

with warm temperature, the possibility that this is the first episode of multiple sclerosis should be seriously considered (see KCC 6.6). Other, less likely possibilities include a small tumor, abscess, or hemorrhage in the right internal capsule, cerebral peduncle, or ventral pons.

Clinical Course and Neuroimaging 235

A **head MRI** (Figure 6.18) showed increased T2 signal in the posterior limb of the right internal capsule. Note that there was enhancement with gadolinium, signifying breakdown of the blood–brain barrier. This is often seen with inflammatory lesions such as demyelinative plaques (see KCC 6.6), but it can also be seen a few days after infarcts. There were a few additional areas of increased T2 signal adjacent to the left frontal horn, suggesting possible prior episodes of demyelination.

An extensive workup for thromboembolic, demyelinative, inflammatory, infectious, and neoplastic disorders was done. All results were negative, except for two oligoclonal bands in the patient's cerebrospinal fluid (see KCC 6.6). Her left-sided weakness was improving by the time of discharge, 1 week after admission. Fortunately, she continued to improve and had no further problems over the following year. At a follow-up appointment 15 months after admission, her neurologic exam was entirely normal except for slightly slow rapid alternating movements with the left hand, and 3^+ reflexes on the left side compared to 2^+ on the right. Her diagnosis remained uncertain, and she was subsequently followed periodically for the possible development of recurrent neurological signs.

CASE 6.3 SUDDEN ONSET OF RIGHT FACE WEAKNESS

Figure 6.17 Infarct in Left Precentral Gyrus Face Area Diffusion-weighted MRI with (A) and (B) sequentially higher horizontal slices. The infarct is visible in left precentral gyrus face area, just lateral to omega-shaped bend in central sulcus where the hand area is usually located.

(A)

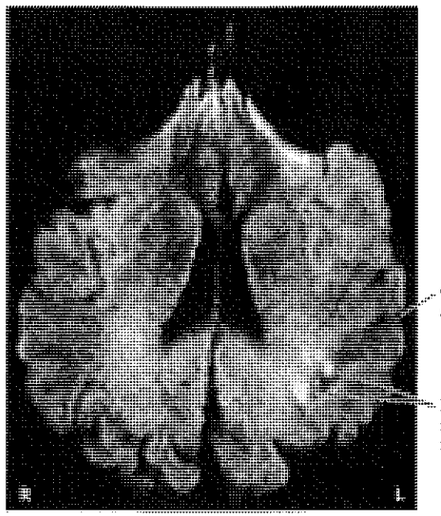

CASE 6.3 *(CONTINUED)*

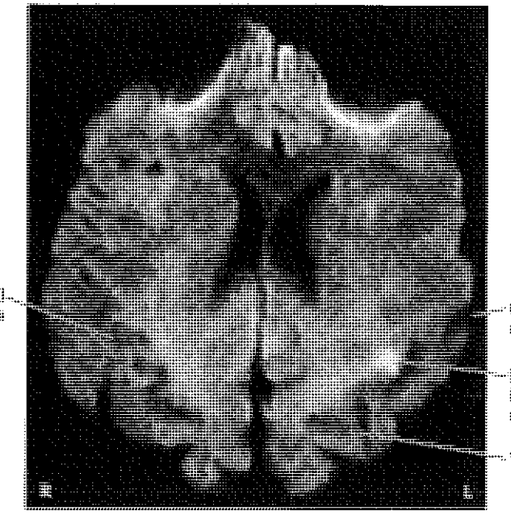

CASE 6.5 PURE MOTOR HEMIPARESIS II

CHIEF COMPLAINT

A 74-year-old woman developed **right face, arm, and leg weakness.**

HISTORY

The patient was residing in a rehabilitation facility while recovering from an infection. She was doing well until one morning, when she suddenly developed **slurred speech and right-sided weakness.** An emergency neurology consultation was called. Medical history was notable for hypertension, coronary artery disease, and recent onset of atrial fibrillation.

PHYSICAL EXAMINATION

Vitals: T = 99.3°F, P = 84, BP = 110/70, R = 18.
Neck: No bruits.
Lungs: Clear.
Heart: Regular rate with no murmurs.
Abdomen: Normal bowel sounds; soft.
Neurologic exam:

MENTAL STATUS: Alert and oriented × 3. Intact comprehension, repetition, and reading. Intact calculations.

CRANIAL NERVES: Pupils equal round and reactive to light. Visual fields full. Extraocular movements intact. Corneal reflex present bilaterally. **Decreased right nasolabial fold. Weak movements of the right face, but with only mild forehead involvement.** Gag reflex present, but with **decreased palate movement on the right. Speech slurred and dysarthric.** Normal sternomastoid strength. **Rightward tongue deviation.**

MOTOR: **Tone flaccid on right side,** normal on left. **Marked right hemiparesis, with power 2/5 in right deltoid, 0/5 in right triceps, biceps, and hand muscles. Power 2/5 in right iliopsoas and quadriceps, and 0/5 in right foot.**

REFLEXES:

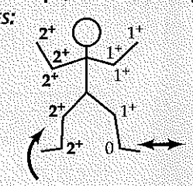

COORDINATION: Normal on the left; too weak to test on the right.

GAIT: Unable to stand.

SENSORY: Intact light touch, pinprick, and joint position sense. No extinction.

LOCALIZATION AND DIFFERENTIAL DIAGNOSIS

1. On the basis of the symptoms and signs shown in **bold** above, where is the lesion?
2. What is the most likely diagnosis? What are some other possibilities?

Discussion

1. The key symptoms and signs in this case are:
   - **Right face, arm, and leg weakness, hyperreflexia, and Babinski's sign**
   - **Dysarthria, decreased right palate movement, rightward tongue deviation**

   Like the patient in the previous case, this patient has pure motor hemiparesis with dysarthria (dysarthria-hemiparesis). The reflexes are decreased on the left side, probably from a chronic neuropathy (see KCC 8.1), and the reflexes on the right are relatively increased, confirming that this is an upper motor neuron lesion. Again, there are no sensory or cortical deficits such as neglect, aphasia, or other cognitive or visual disorders. Pure motor hemiparesis can be caused by lesions of the contralateral corticobulbar and corticospinal tracts, most commonly in the internal capsule or pons (see KCC 6.3; Figure 6.14A). Control of right CN IX and X (right palate movement) and right CN XII (rightward tongue deviation) have been affected as well, also probably because of a contralateral corticobulbar tract lesion.

   The most likely *clinical localization* is left corticobulbar and corticospinal tracts in the posterior limb of the internal capsule or ventral pons.
2. Pure motor hemiparesis is usually caused by lacunar infarction (see Table 10.3) of the contralateral internal capsule or pons. This patient has multiple vascular risk factors, and lacunar infarction from small-vessel disease (see KCC 10.4) is the most likely diagnosis. Given the history of atrial fibrillation, an embolus to a small perforating vessel of the left internal capsule or pons should be considered as well.

Clinical Course and Neuroimaging 256

The patient was transferred to a nearby hospital and started on anticoagulation therapy because of her history of atrial fibrillation. An **MRI scan** (Figure 6.19) showed a T2 bright area in the left ventral pons consistent with lacunar infarction (see also Figure 14.20B). A magnetic resonance angiogram (see Chapter 4) showed no significant narrowing of the circle of Willis vessels. The patient's hemiparesis had improved only slightly by the time of discharge, with power in the right arm and leg 3/5 proximally and 0/5 distally. Over the next year she had continued problems with dysarthria and swallowing difficulties, ultimately requiring a feeding tube for nutrition.

CASE 6.4 PURE MOTOR HEMIPARESIS I

Figure 6.18 Lesion in Posterior Limb of Right Internal Capsule. MRI of the brain. (A) Axial (horizontal) proton density–weighted section. (B) Coronal T1-weighted section after intravenous administration of gadolinium contrast.

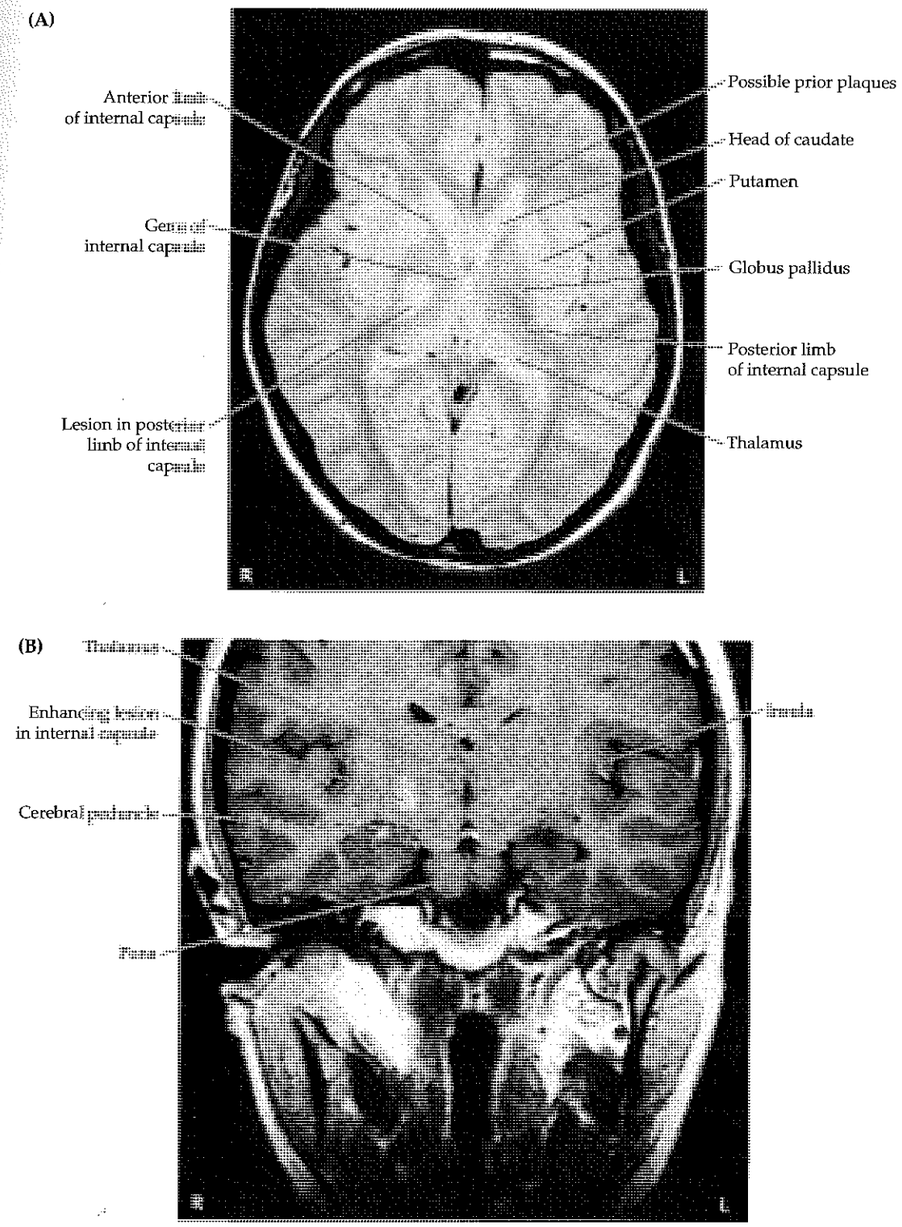

CASE 6.5 PURE MOTOR HEMIPARESIS II

Figure 6.19 Left Pontine Basis Infarct T-2 weighted axial (horizontal) head MRI showing infarct in the left ventral pons.

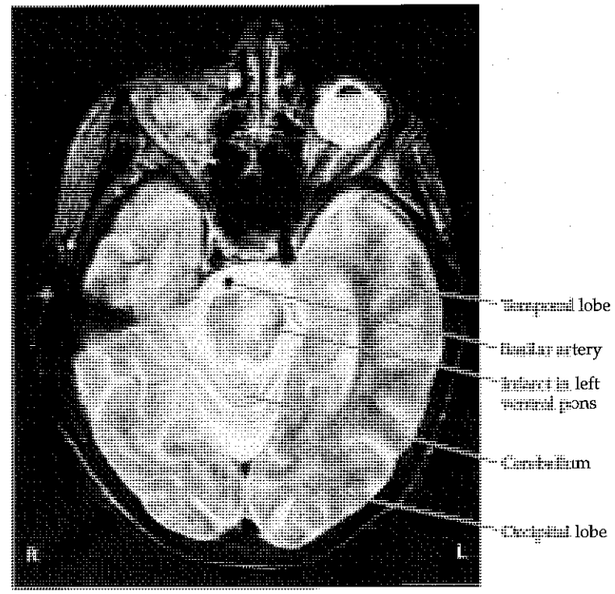

CASE 6.6 PROGRESSIVE WEAKNESS, MUSCLE TWITCHING, AND CRAMPS

CHIEF COMPLAINT

A 52-year-old right-handed man was referred to a neurologist for evaluation of weakness and difficulty walking.

HISTORY

The patient first noticed gait difficulty 6 months prior to the appointment. He felt "off balance" and over the next 2 months developed difficulty raising his feet off the floor while seated in a chair. A few months later his **leg weakness** had become worse, making it difficult to walk downstairs. In addition, his **arms and hands had become weak,** making it difficult for him to carry out his work as a carpenter. He also noticed constant **twitching of his arm and leg muscles** and painful **cramps in his legs.** He did not complain of diplopia, dysarthria, or dysphagia. There was no history of trauma or neck pain, and no history of toxin exposure. Family history was negative. Initial evaluation by his primary care physician included an MRI of the cervical spine, which was normal.

PHYSICAL EXAMINATION

Vitals: T = 98°F, P = 96, BP = 120/70, R = 18.
Neck: No bruits.
Lungs: Clear.
Heart: Regular rate with no murmurs.
Abdomen: Normal.
Extremities: Normal.
Neurologic exam:

MENTAL STATUS: Alert and oriented × 3. Intact naming, comprehension, and repetition.

CRANIAL NERVES: Pupils equal round and reactive to light. Extraocular movements intact. No nystagmus. No ptosis. Facial sensation intact. No facial weakness or asymmetry. Hearing good bilaterally. Tongue and palate midline, with no tongue fasciculations.

CASE 6.6 *(CONTINUED)*

MOTOR: **Increased tone in bilateral lower extremities. Nearly continuous fasciculations in all four extremities. Atrophy present in the left hand interosseous muscles and bilateral foot intrinsic muscles. Weakness present bilaterally (see the table below), affecting the legs more than the arms, and the right side slightly more than the left.**

REFLEXES: **Hoffmann's sign present bilaterally. Jaw jerk reflex present.**

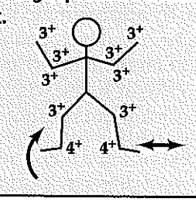

COORDINATION: Finger-to-nose, heel-to-shin, and rapid alternating movements normal.

GAIT: **Required assistance to walk. Paraparetic and spastic gait.**

SENSORY: Intact light touch, pinprick, vibration, and joint position sense. No extinction.

LOCALIZATION AND DIFFERENTIAL DIAGNOSIS

1. Which of the symptoms and signs shown in **bold** above are upper motor neuron signs? Which are lower motor neuron signs (see Table 6.4)? Could these findings be caused by cervical cord compression?
2. What is the most likely diagnosis? What are some other possibilities?

Results of Strength Testing

	ARM			WRIST		FINGER	
	DELTOID	BICEPS	TRICEPS	EXTENSORS	FLEXORS	EXTENSORS	GRIP
R	**4/5**	5/5	5/5	**4+/5**	5/5	**4+/5**	**4+/5**
L	**4/5**	5/5	5/5	**5−/5**	5/5	**4+/5**	**5−/5**

	NECK				LEG		
	FLEXORS	EXTENSORS	ILIOPSOAS	HAMSTRINGS	DORSIFLEXION	PLANTARFLEXION	QUADRICEPS
R	5/5	5/5	**4/5**	**4+/5**	**3−/5**	**5−/5**	5/5
L	5/5	5/5	**4+/5**	**4+/5**	**3−/5**	**5−/5**	5/5

Discussion

1. As Table 6.4 indicates, weakness is both an upper motor neuron and a lower motor neuron sign. Fasciculations and atrophy are lower motor neuron signs. Increased tone, spastic gait, and hyperreflexia including Babinski's sign, Hoffmann's sign, and jaw jerk reflex are upper motor neuron signs.

   Cervical cord compression can cause upper motor neuron findings in the arms and legs, as well as lower motor neurons findings in the arms due to local nerve root compression. In this patient, however, lower motor neuron findings of fasciculations and atrophy were present in the lower extremities as well. In addition, a jaw jerk reflex was present, which is a sign of hyperreflexia produced by upper motor neuron dysfunction in the corticobulbar pathways well above the level of the cervical cord. Thus, this patient's findings result from diffuse upper and lower motor neuron dysfunction extending from the brain to the lumbosacral spinal cord.
2. Focal weakness progressing to become more diffuse with upper and lower motor neuron signs, muscle cramping, and fasciculations with no sensory deficits form the classic presentation of amyotrophic lateral sclerosis (see KCC 6.7). Also possible, but far less likely, are paraneoplastic motor neuron disease, hexosaminidase deficiency, lead toxicity, or a variety of other disorders listed in KCC 6.7.

Clinical Course

The diagnosis of probable ALS and its implications were discussed at length with the patient and his family. He decided to try treatment with riluzole and was enrolled in a comprehensive rehabilitation program. Additional testing included an EMG (see KCC 9.2), which showed evidence of denervation and reinnervation in all four extremities, compatible with the diagnosis of ALS. Other tests included serum protein electrophoresis, serum B_{12}, folate, and complete blood count, all of which were normal.

The patient was followed over the following months as his symptoms worsened. Within 1 year after initial symptoms he was wheelchair bound because of increasing weakness. By approximately 2 years into the illness, at his last follow-up appointment, he had developed profound dysarthria, dysphagia, and tongue atrophy with fasciculations, and 0/5 to $4^-/5$ strength in his extremities. He continued to live at home with family supports and hospice care, and he died a few weeks later of respiratory failure.

Additional Cases

Related cases can be found in other chapters for the following topics: **weakness caused by corticospinal and corticobulbar dysfunction** (Cases 5.1–5.4, 7.3, 7.4, 10.2, 10.4, 10.5, 10.7–10.9, 10.11, 10.12, 12.8, 13.7, 14.1–14.3, 14.5, 14.6, 18.3). Other relevant cases can be found using the **Case Index.**

Brief Anatomical Study Guide

1. Motor and sensory pathways are **somatotopically organized**, with the cortical representations for the face located lateral to the hand, and with the leg represented most medially (see Figure 6.2).
2. The **spinal cord** has **dorsal sensory roots, ventral motor roots, central gray matter,** and surrounding **white matter columns** (see Figure 6.3). The appearance of the spinal cord varies at different levels and is thickest at the **cervical enlargement** and **lumbosacral enlargement,** where nerves for the arms and legs, respectively, arise (see Figure 6.4). **Blood supply** for the spinal cord derives from the **anterior and posterior spinal arteries** (see Figure 6.5).
3. The **lateral corticospinal tract** is the most clinically important pathway in the nervous system, and knowledge of its anatomy is sufficient to localize many neurologic disorders (see Figures 6.8, 6.11A). The lateral corticospinal tract originates mainly in the primary motor cortex of the **precentral gyrus,** descends through the **posterior limb of the internal capsule** (see Figure 6.10), down through the **cerebral peduncle** in the midbrain, and passes through the ventral pons to form fiber bundles along the ventral medulla called the **pyramids** (see Figure 6.11A; see also Figure 2.22A). The lateral corticospinal tract crosses to the opposite side at the **pyramidal decussation** located at the junction between the medulla and spinal cord—an essential piece of information for localizing lesions (see Figures 6.8, 6.11A, and 6.14). It then continues in the lateral spinal cord white matter to synapse onto motor neurons in the spinal cord **anterior (ventral) horn.**

Brief Anatomical Study Guide *(continued)*

4. Motor neurons projecting from the motor cortex to the spinal cord are called **upper motor neurons;** those projecting from the spinal cord to the muscles are called **lower motor neurons** (see Figure 6.8). **Upper motor neuron versus lower motor neuron signs** (see Table 6.4) often have important implications for determining whether patients are suffering from lesions of the central nervous system versus peripheral nerves.
5. **Patterns of weakness** can also be very useful for localizing lesions (see Figure 6.14).
6. Although the lateral corticospinal tract is clinically the most important, there are several additional descending motor pathways. Descending motor pathways are organized into **lateral motor systems,** such as the lateral corticospinal tract involved in **limb control**, and **medial motor systems,** which are involved in controlling **proximal trunk muscles** (see Table 6.3; Figures 6.6, 6.11).
7. The **autonomic nervous system** generally controls homeostatic body functions that are not under voluntary control and has two main divisions (see Figures 6.12, 6.13). The **sympathetic division** is involved in "fight-or-flight" functions such as increased heart rate and blood pressure and uses **norepinephrine** as its neurotransmitter on end organs. The **parasympathetic division** subserves "rest and digest" functions such as increased salivation and peristalsis, using **acetylcholine** as its peripheral neurotransmitter. Sympathetic **(thoracolumbar)** efferents arise from the **intermediolateral cell column** of the thoracic and upper lumbar spinal cord and synapse in paravertebral and prevertebral ganglia en route to their targets. Parasympathetic **(craniosacral)** efferents arise from brainstem and sacral spinal nuclei, synapsing in ganglia located in or near their end organs.

References

General References

Carpenter MB. 1991. *Core Text of Neuroanatomy,* 4th Ed. Williams & Wilkins, Baltimore, MD, Chapters 3, 4, 9.

Kandel ER, Schwartz JH, Jessell TM (eds.). 2000. *Principles of Neural Science,* 4th Ed. McGraw-Hill, New York, Chapters 33–38, 47.

Martin JH. 1996. *Neuroanatomy: Text and Atlas,* 2nd Ed. Appleton & Lange, Stamford, CT, Chapters 5, 9, 14.

Purves D, Augustine GJ, Fitzpatrick D, Katz LC, LaMantia A-S, McNamara JO, Williams SM (eds.). 2001. *Neuroscience,* 2nd Ed. Sinauer, Sunderland, MA, Chapters 16, 17, 21.

Motor Cortex, Sensory Cortex, and Somatotopic Organization

Kurata K. 1992. Somatotopy in the human supplementary motor area. *Trends Neurosci* 15(5): 159–160.

Nii Y, Uematsu S, Lesser R, Gordon B. 1996. Does the central sulcus divide motor and sensory function? Cortical mapping of the human hand areas as revealed by electrical stimulation through subdural grid electrodes. *Neurology* 46(2): 360–367.

Penfield W, Boldrey E. 1937. Somatic motor and sensory representation in the cerebral cortex of man as studied by electrical stimulation. *Brain* 60: 389–443.

Penfield W, Rasmussen T. 1950. *The Cerebral Cortex of Man: A Clinical Study of Localization of Function.* Macmillan, New York.

Sanes JN, Donoghue JP, Thangaraj V, Edelmann RR, Warach S. 1995. Shared neural substrates controlling hand movements in human motor cortex. *Science* 268(5218): 1775–1778.

Lateral Corticospinal Tract

Davidoff RA. 1990. The pyramidal tract. *Neurology* 40(2): 332–339.

Dum RP, Strick PL. 1991. The origin of corticospinal projections from the premotor areas in the frontal lobe. *J Neurosci* 11(3): 667–689.

Nathan PW, Smith MC, Deacon P. 1990. The corticospinal tract in man: Course and location of fibers at different segmental levels. *Brain* 113(Pt. 2): 303–324.

Other Medial and Lateral Descending Motor Systems

Muto N, Kakei S, Shinoda Y. 1996. Morphology of single axons of tectospinal neurons in the upper cervical spinal cord. *J Comp Neurol* 372(1): 9–26.

Nathan PW, Smith MC. 1982. The rubrospinal and central tegmental tracts in man. *Brain* 105(Pt. 2): 223–269.

Nathan PW, Smith M, Deacon P. 1996. Vestibulospinal, reticulospinal and descending propriospinal nerve fibres in man. *Brain* 119(Pt. 6): 1809–1883.

Nudo RJ, Sutherland DP, Masterton RB. 1993. Inter- and intra-laminar distribution of tectospinal neurons in 23 mammals. *Brain Behav Evol* 42(1): 1–23.

Teroa S, Takahashi M, Li M, Hashizume Y, Ikeda H, Mitsuma T, Sobue G. 1996. Selective loss of small myelinated fibers in the lateral corticospinal tract due to midbrain infarction. *Neurology* 47(2): 558–591.

Autonomic Nervous System

Robertson D, Low PA, Polinsky RJ (eds.). 1996. *Primer on the Autonomic Nervous System.* Academic Press, San Diego.

Wilson-Pauwels L, Stewart PA, Akesson EJ. 1997. *Autonomic Nerves.* B C Decker, Malden, MA.

Cooper JR, Roth RF, Bloom FE. 1996. *Biochemical Basis of Neuropharmacology,* 7th Ed. Oxford, New York.

Upper Motor Neuron versus Lower Motor Neuron Lesions

Young RR. 1994. Spasticity: A review. *Neurology* 44(Suppl 9): S12–S20.

Phillips CG, Landau WM. 1990. Clinical neuropathology VIII. Upper and lower motor neurons: The little old synecdoche that works. *Neurology* 40(6): 884–886.

Pure Motor Hemiparesis

Fisher CM, Curry HD. 1965. Pure motor hemiplegia of vascular origin. *Arch Neurol* 13: 30.

Gait Disorders

Nutt JG, Marsden CD, Thompson PD. 1993. Human walking and higher-level gait disorders, particularly in the elderly. *Neurology* 43(2): 268–279.

Rubino FA. 1993. Gait disorders in the elderly. *Postgrad Med* 93(6): 185–188.

Sudarsky L. 1990. Geriatrics: Gait disorders in the elderly. *N Engl J Med* 322(20): 1441–1446.

Multiple Sclerosis

Confavreux C, Vukusic S, Moreau T, Adeleine P. 2000. Relapses and progression of disability in multiple sclerosis. *N Engl J Med* 343(20): 1430–1438.

Lublin FD, Reingold SC. 1996. Defining the clinical course of multiple sclerosis: Results of an international survey. *Neurology* 46(4): 907–911.

Miller JR. 2000. Multiple sclerosis. In Rowland LP (ed.), *Merritt's Textbook of Neurology,* 10th Ed., Chapter 133. Williams & Wilkins, Baltimore, MD.

Noseworthy JH, Lucchinetti C, Rodriguez M, Weinshenker BG. 2000. Multiple sclerosis. *N Engl J Med* 343(13): 938–952.

Olek MJ, Dawson DM. 2000. Multiple sclerosis and other inflammatory demyelinating diseases of the central nervous system. In Bradley WG, Daroff RB, Fenichel GM, Marsden CD (eds.), *Neurology in Clinical Practice,* 3rd Ed., Chapter 60. Butterworth-Heinemann, Boston.

Rudick RA, Fisher E, Lee JC, Simon J, Jacobs L. 1999. Use of the brain parenchymal fraction to measure whole brain atrophy in relapsing-remitting MS. *Neurology* 53(8): 1698–1704.

Motor Neuron Disease

Houde SC, Mangolds V. 1999. Amyotrophic lateral sclerosis: a team approach to primary care. *Clin Excell Nurse Pract* 3(6): 337–345.

Miller RG, Bouchard SP, Duquette P, Eisen A, Gelinas D, Harati Y, Munsat TL, Powe L, Rothstein J, Salzman P, Sufit RL. 1996. Clinical trials of Riluzole in patients with ALS. *J Neurology* 47(6 Suppl. 4): S242–S250.

Ludolph AC, Meyer T, Riepe MW. 2000. The role of excitotoxicity in ALS—what is the evidence? *J Neurol* 247(Suppl 1): I7–16.

Rowland LP. 1999. Primary lateral sclerosis: disease, syndrome, both or neither? *J Neurol Sci* 170(1): 1–4.

Strober JB, Tennekoon GI. 1999. Progressive spinal muscular atrophies. *J Child Neurol* 14(11): 691–695.

Bromberg MB. 1999. Pathogenesis of amyotrophic lateral sclerosis: a critical review. *Curr Opin Neurol* 12(5): 581–588.

Swash M. 1999. An algorithm for ALS diagnosis and management. *Neurology* 53(8 Suppl 5): S58–S62.

CHAPTER 7

Somatosensory Pathways

ANATOMICAL AND CLINICAL REVIEW
Main Somatosensory Pathways
Posterior Column–Medial Lemniscal Pathway
Spinothalamic Tract and Other Anterolateral Pathways
Somatosensory Cortex
Central Modulation of Pain
The Thalamus
KCC 7.1 Paresthesias
KCC 7.2 Spinal Cord Lesions
KCC 7.3 Sensory Loss, Patterns, and Localization
KCC 7.4 Spinal Cord Syndromes
KCC 7.5 Anatomy of Bowel, Bladder, and Sexual Function

CLINICAL CASES
7.1 Sudden Onset of Right Arm Numbness
7.2 Sudden Onset of Right Face, Arm, and Leg Numbness
7.3 A Fall Causing Paraplegia and a Sensory Level
7.4 Left Leg Weakness and Right Leg Numbness
7.5 Sensory Loss over Both Shoulders
7.6 Body Tingling and Unsteady Gait
7.7 Hand Weakness, Pinprick Sensory Level, and Urinary Retention
Additional Cases

BRIEF ANATOMICAL STUDY GUIDE

A 71-year-old woman developed gradually worsening numbness and tingling in her right leg, along with weakness in her left leg. She also had experienced occasional urinary incontinence. A neurologic examination revealed decreased pinprick sensation on her right side below the level of the umbilicus and decreased vibration and joint position sense in the left foot. Her left leg had brisk reflexes and was slightly weak. In this patient, these complex sensory and motor deficits arose from a single lesion. In this chapter, we will learn about the pathways for sensations such as touch, pain, and position sense of the limbs, and we will use this knowledge to accurately localize lesions of these pathways in clinical cases.

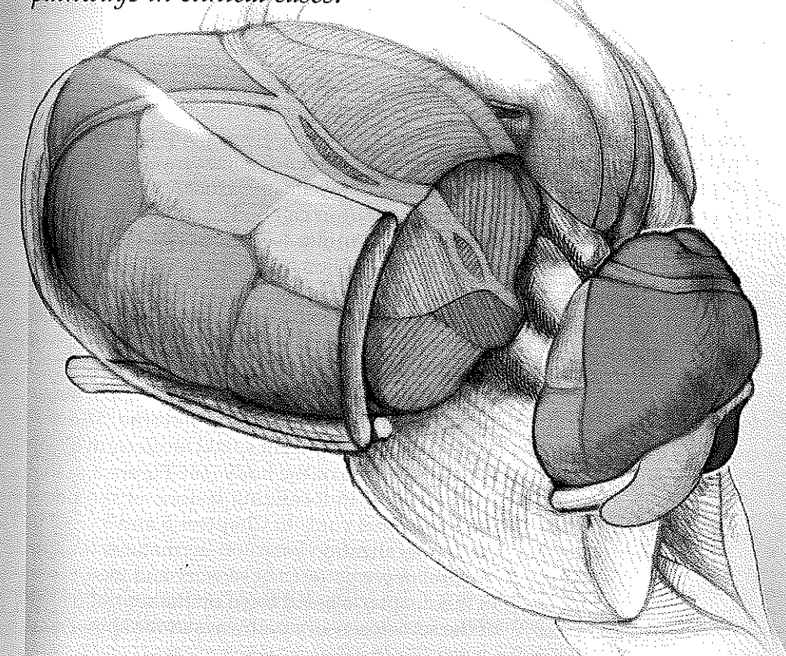

ANATOMICAL AND CLINICAL REVIEW

In Chapter 6 we discussed the anatomy of the corticospinal tract and other descending motor pathways. In this chapter we will discuss the other two major "long tracts" of the nervous system (Table 7.1). These are the somatosensory pathways: the **posterior column–medial lemniscal system** and the **anterolateral systems.** Like the corticospinal tract, these pathways are somatotopically organized (see Figure 6.2). Understanding the functions and points of decussation of the three major long tracts (see Table 7.1) is fundamental to clinical neuroanatomical localization.

In the sections that follow, we will learn to use the anatomy of the three major long tracts to localize lesions in the nervous system. We will discuss common disorders of the spinal cord and other locations that affect these pathways. In addition, brainstem and spinal cord mechanisms of pain modulation will be addressed. The organization of the thalamus, serving as the major relay for sensory and other information traveling to the cortex, will be reviewed as well. Finally, we will discuss the roles of sensory and motor pathways in bowel, bladder, and sexual function.

Main Somatosensory Pathways

The term **somatosensory** generally refers to bodily sensations of touch, pain, temperature, vibration, and **proprioception** (limb or joint position sense). There are two main pathways for somatic sensation (see Table 7.1; see Figures 7.1 and 7.2):

- The **posterior column–medial lemniscal pathway** conveys proprioception, vibration sense, and fine, discriminative touch (Figure 7.1).
- The **anterolateral pathways** include the **spinothalamic tract** and other associated tracts that convey pain, temperature sense, and crude touch (Figure 7.2).

Since some aspects of touch sensation are carried by both pathways, touch sensation is not eliminated in isolated lesions to either pathway.

Four types of sensory neuron fibers are classified according to axon diameter (Table 7.2). These different fiber types have specialized peripheral receptors that subserve different sensory modalities. Larger-diameter, myelinated axons conduct faster than smaller-diameter or unmyelinated axons.

Sensory neuron cell bodies are located in the **dorsal root ganglia** (see Figures 7.1, 7.2). Each dorsal root ganglion cell has a stem axon that bifurcates, resulting in one long process that conveys sensory information from the periphery, and a second process that carries information into the spinal cord through the dorsal nerve roots. A peripheral region innervated by sensory fibers from a single nerve root level is called a **dermatome.** The dermatomes for the different spinal levels form a map over the surface of the body (see Figure 8.4) that can be useful in localizing lesions of the nerve roots or spinal cord. In Chapters 8 and 9 we will discuss localization based on dermatome and peripheral nerve patterns of sensory and motor loss. In this chapter we will focus on the central course of the somatosensory pathways in the spinal cord

TABLE 7.1 Main Long Tracts of the Nervous System

PATHWAY(S)	FUNCTION	NAME (AND LEVEL) OF DECUSSATION
Lateral corticospinal tract	Motor	Pyramidal decussation (cervicomedullary junction)
Posterior column–medial lemniscal pathway	Sensory (vibration, joint position, fine touch)	Internal arcuate fibers (lower medulla)
Anterolateral pathways	Sensory (pain, temperature, crude touch)	Anterior commissure (spinal cord)

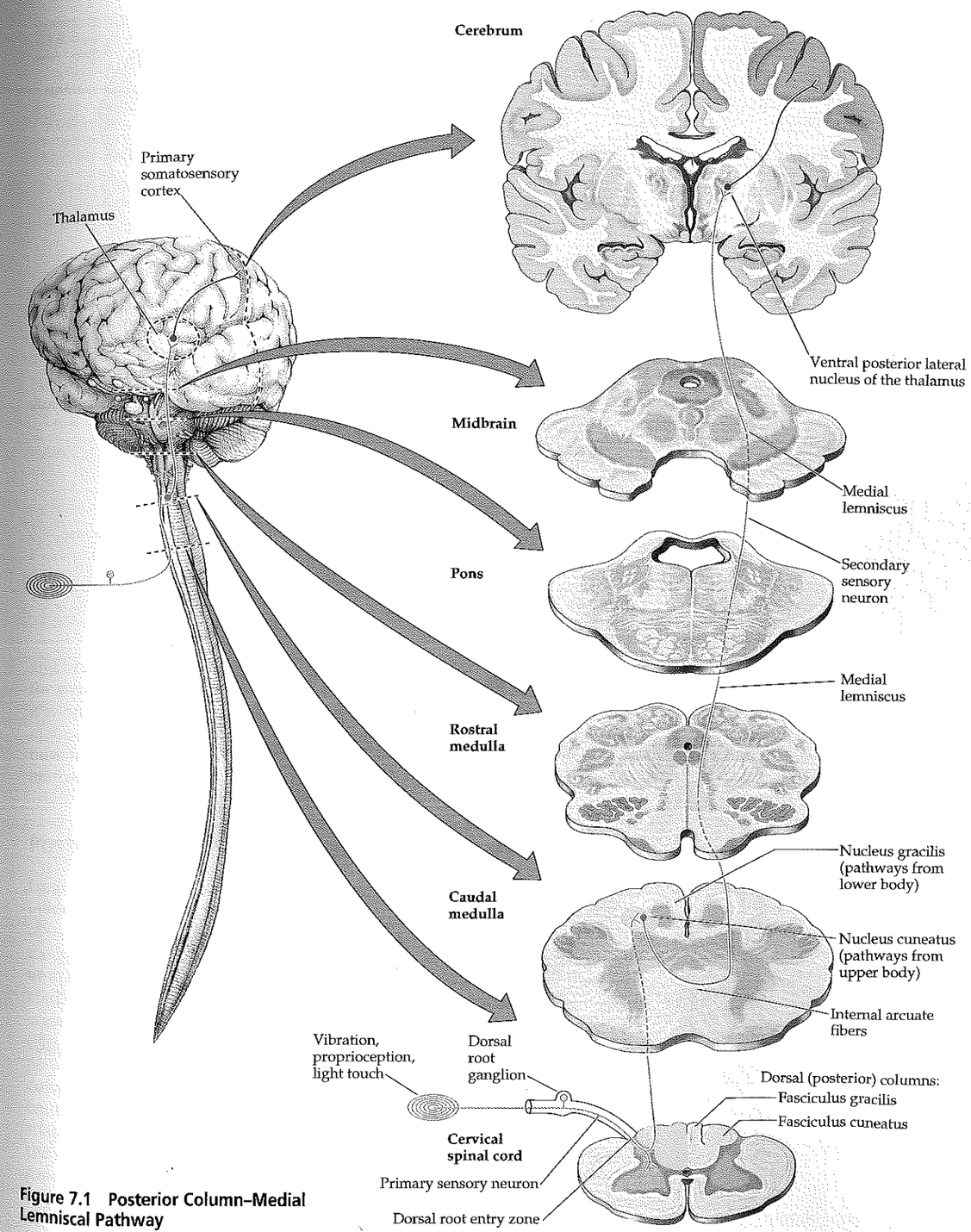

Figure 7.1 Posterior Column–Medial Lemniscal Pathway

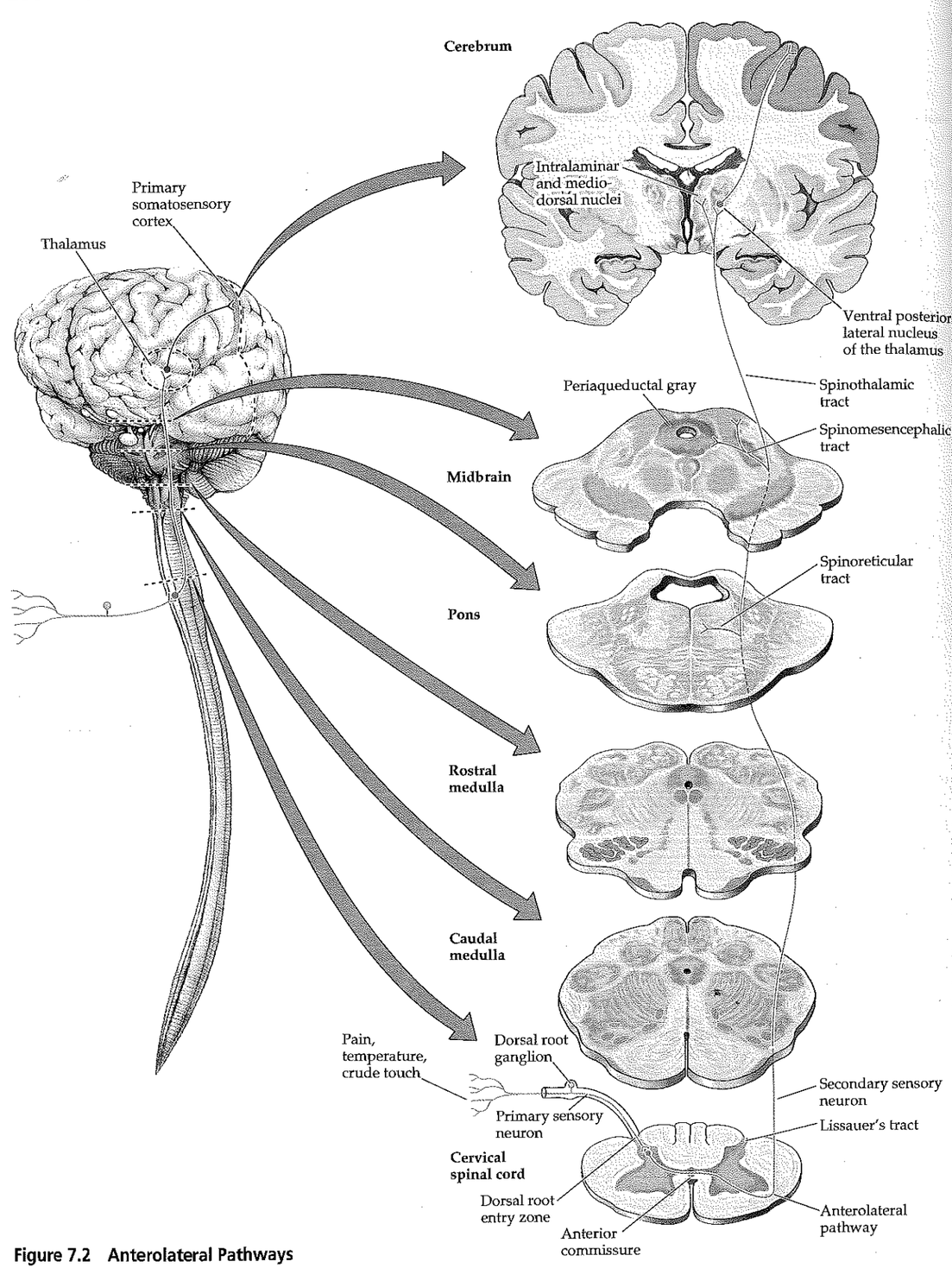

Figure 7.2 Anterolateral Pathways

TABLE 7.2 Sensory Neuron Fiber Types

NAME	ALTERNATE NAME	FIBER DIAMETER (μm)	MYELINATED	RECEPTORS	SENSORY MODALITIES
A-α	I	13–20	Yes	Muscle spindle	Proprioception
				Golgi tendon organ	Proprioception
A-β	II	6–12	Yes	Muscle spindle	Proprioception
				Meissner's corpuscle	Superficial touch
				Merkel's receptor	Superficial touch
				Pacinian corpuscle	Deep touch, vibration
				Ruffini ending	Deep touch, vibration
				Hair receptor	Touch, vibration
A-δ	III	1–5	Yes	Bare nerve ending	Pain
				Bare nerve ending	Temperature (cool)
C	IV	0.2–1.5	No	Bare nerve ending	Pain
				Bare nerve ending	Temperature (warm)
				Bare nerve ending	Itch

and brain. Just as our knowledge that the corticospinal tract crosses over at the pyramidal decussation helps us localize CNS lesions (see Figure 6.11A), it is equally important to know the points of decussation of the two main somatosensory pathways (see Table 7.1; Figures 7.1 and 7.2). We will therefore now trace the course of these pathways from spinal cord to primary somatosensory cortex.

Posterior Column–Medial Lemniscal Pathway

Large-diameter, myelinated axons carrying information about proprioception, vibration sense, and fine touch enter the spinal cord via the medial portion of the dorsal root entry zone (see Figure 7.1). Many of these axons then enter the ipsilateral **posterior columns** to ascend all the way to the **posterior column nuclei** in the medulla. In addition, some axon collaterals enter the spinal cord central gray matter to synapse onto interneurons and motor neurons. It is easier to remember the **somatotopic organization** of the posterior columns (Figure 7.3) if you picture fibers adding on laterally from higher levels as the posterior columns ascend. Thus, the medial portion, called the **gracile fasciculus** ("gracile" means "thin") carries information from the legs and lower trunk. The more lateral **cuneate fasciculus** ("cuneate" means "wedge shaped") carries information from the upper trunk above about T6, and from the arms and neck. The first-order sensory neurons that have axons in the gracile and cuneate fasciculi (also called fasciculus gracilis and fasciculus cuneatus) synapse onto second-order neurons in the **nucleus gracilis** and **nucleus cuneatus,** respectively (see Figure 7.1).

MNEMONIC

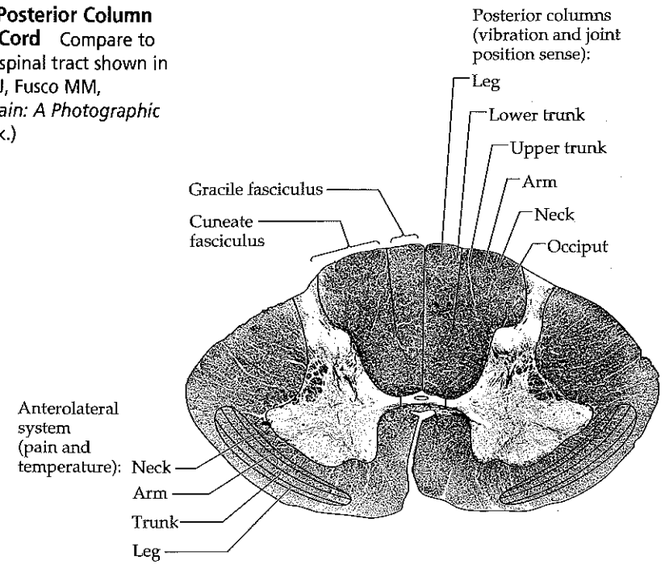

Figure 7.3 Somatotopic Organization of Posterior Column and Anterolateral Pathways in the Spinal Cord Compare to somatotopic organization of the lateral corticospinal tract shown in Figure 6.10C. (Spinal section from DeArmond SJ, Fusco MM, Maynard MD. 1989. *Structure of the Human Brain: A Photographic Atlas*, 3rd Ed. Oxford University Press, New York.)

Axons of these second-order neurons decussate as **internal arcuate fibers** and then form the **medial lemniscus** on the other side of the medulla (see Figure 14.5). The medial lemniscus initially has a vertical orientation, and then comes to occupy a progressively more lateral and inclined position as it ascends in the brainstem (see Figures 7.1, 14.3, and 14.4). The next major synapse occurs when the medial lemniscus axons terminate in the **ventral posterior lateral nucleus (VPL)** of the thalamus. The neurons of the VPL then project through the **posterior limb of the internal capsule** in the **thalamic somatosensory radiations** (see Figure 6.9B) to reach the **primary somatosensory cortex** (see Figure 6.1)(areas 3, 1, and 2) in the postcentral gyrus (see Figure 7.1). As we will discuss in Chapter 12 (see Figure 12.8), an analogous pathway called the trigeminal lemniscus conveys touch sensation for the face via the ventral posterior medial nucleus of the thalamus (VPM) to the somatosensory cortex. Synaptic inputs to the primary somatosensory cortex from both the face and body occur mainly in cortical layer IV and the deep portions of layer III, with some inputs also reaching layer VI (see Figure 2.14).

Spinothalamic Tract and Other Anterolateral Pathways

Smaller-diameter and unmyelinated axons carrying information about pain and temperature sense also enter the spinal cord via the dorsal root entry zone (see Figure 7.2). However, these axons make their first synapses immediately in the gray matter of the spinal cord, mainly in the dorsal horn **marginal zone (lamina I)**, and deeper in the dorsal horn, in **lamina V** (see Figure 6.3B; Table 6.2). Some axon collaterals ascend or descend for a few segments in **Lissauer's tract** before entering the central gray (see Figure 6.4, 7.2). Axons from the second-order sensory neurons in the central gray cross over in the **spinal cord anterior (ventral) commissure** to ascend in the anterolateral white matter. It should be noted that it takes **two to three spinal segments** for the decussating fibers to reach the opposite side, so a lateral cord lesion will affect contralateral pain and temperature sensation beginning a few segments below the level of the lesion. The anterolateral pathways in the spinal cord have a **somatotopic organization** (see Figure 7.3) in which the feet are most laterally represented. To help you remember this organization, picture fibers from the anterior commissure adding on medially as the anterolateral pathways ascend in the spinal cord. When the anterolateral pathways reach the medulla, they are located laterally, running in the groove between the olives and the inferior cerebellar peduncles (see Figures 7.2, 14.5). They then enter the pontine tegmentum to lie just lateral to the medial lemniscus in the pons and midbrain (see Figures 14.3, 14.4). The next major synaptic relay is, again, in the thalamus, which projects via the thalamic somatosensory radiations (see Figure 6.9B) to primary somatosensory cortex (see Figure 6.1) (areas 3, 1, and 2) in the postcentral gyrus (see Figure 7.2). Pain and temperature sensation for the face is carried by an analogous pathway called the trigeminothalamic tract, to be discussed further in Chapter 12 (see Figure 12.8).

MNEMONIC

The anterolateral pathways consist of three tracts (see Figure 7.2): the spinothalamic, spinoreticular, and spinomesencephalic tracts. The **spinothalamic tract** is the best known and mediates discriminative aspects of pain and temperature sensation, such as location and intensity of the stimulus. Like the posterior column–medial lemniscal pathway, the main relay for the spinothalamic tract is in the **ventral posterior lateral nucleus (VPL)** of the thalamus. However, the terminations of the spinothalamic tract and the posterior column–medial lemniscal pathway in the VPL are separate. There are also spinothalamic projections to other thalamic nuclei, including **intralaminar thalamic nuclei** (central lateral nucleus) and medial thalamic nuclei such as the **mediodorsal nuclei.**

These projections probably participate together with the **spinoreticular tract** in a phylogenetically older pain pathway responsible for conveying the emotional and arousal aspects of pain. The spinoreticular tract terminates on the medullary–pontine reticular formation, which in turn projects to the intralaminar thalamic nuclei (centromedian nucleus). Unlike the VPL, which projects specifically in a somatotopic fashion to the primary sensory cortex, the intralaminar nuclei project diffusely to the entire cerebral cortex and are thought to be involved in behavioral arousal (see the section on the thalamus later in this chapter).

The **spinomesencephalic tract** projects to the midbrain periaqueductal gray matter and the superior colliculi (see Figure 7.2). The **periaqueductal gray** participates in central modulation of pain, as we will discuss shortly.

The spinothalamic and spinomesencephalic tracts arise mainly from spinal cord laminae I and V, while the spinoreticular tract arises diffusely from intermediate zone and ventral horn laminae 6 through 8 (see Figure 6.3). In addition to pain and temperature, some crude touch sensation can be conveyed by the anterolateral pathways when the posterior columns are damaged. To summarize, if you step on a thumb tack with your left foot, your spinothalamic tract enables you to realize "something sharp is puncturing the sole of my left foot"; your spinothalamic intralaminar projections and spinoreticular tract cause you to feel "ouch! that hurts!"; and your spinomesencephalic tract leads to pain modulation, allowing you eventually to think "aah, that feels better."

A summary of spinal cord sensory and motor pathways is shown in Figure 7.4. (The sensory pathways shown on the left are discussed in this chapter; the spinocerebellar tracts are covered in Chapter 15. The motor pathways shown on the right are discussed in Chapter 6 [see Figure 6.11]). As we will see in KCC 7.4, clinical syndromes of the spinal cord provide a practical review of regional spinal cord anatomy. We will now discuss the continuation of the somatosensory pathways, from the thalamus to the cerebral cortex.

REVIEW EXERCISE

At what level does the decussation occur for the posterior column–medial lemniscal pathway (see Figure 7.1) and for the anterolateral pathways (see Figure 7.2)? Suppose that a patient has a lesion of the left half of the spinal cord. Which side of the patient's body will have decreased vibration and joint position sense below the level of the lesion? Which side of the patient's body will have decreased pain and temperature sensation below the level of the lesion? Which side will have weakness below the level of the lesion (see Figure 6.8)? Which side will these deficits be on if the lesion is in the left cerebral cortex?

MNEMONIC

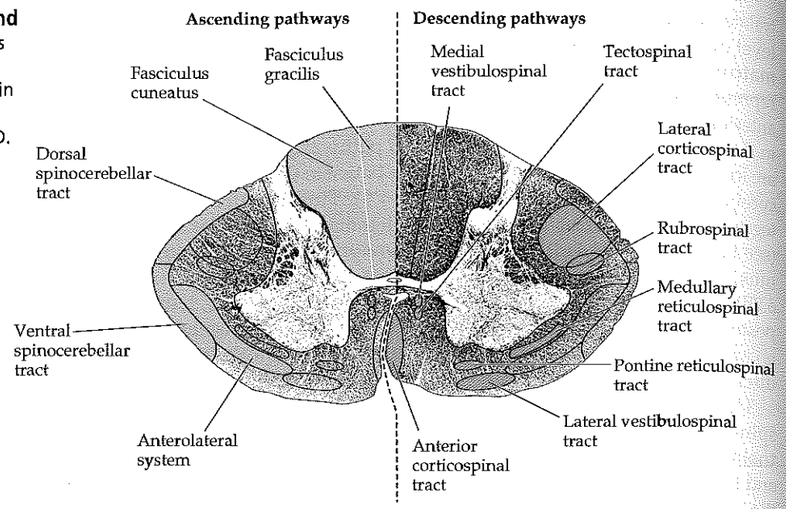

Figure 7.4 Spinal Cord Sensory and Motor Spinal Cord Pathways This diagram summarizes the sensory and motor spinal cord pathways discussed in Chapters 6 and 7. (Spinal section from DeArmond SJ, Fusco MM, Maynard MD. 1989. *Structure of the Human Brain: A Photographic Atlas*, 3rd Ed. Oxford University Press, New York.)

Somatosensory Cortex

From the thalamic VPL and VPM nuclei, somatosensory information is conveyed to the **primary somatosensory cortex** in the postcentral gyrus, which includes Brodmann's areas 3, 1, and 2 (see Figures 7.1, 7.2; see also Figure 6.1). Like the primary motor cortex, the primary somatosensory cortex is somatotopically organized, with the face represented most laterally, and the leg most medially (see Figure 6.2). Information from the primary somatosensory cortex is conveyed to the **secondary somatosensory association cortex** located within the Sylvian fissure, along its superior margin in a region called the parietal operculum (see Figure 6.1). The secondary somatosensory cortex is also organized somatotopically. Further processing of somatosensory information occurs in association cortex of the **posterior parietal lobule,** including Brodmann's areas 5 and 7 (see Figure 6.1). Primary somatosensory cortex and somatosensory association cortex also have extensive connections with the motor cortex. Lesions of the somatosensory cortex and adjacent regions produce characteristic deficits referred to as **cortical sensory loss** (see KCC 7.3).

Central Modulation of Pain

Pain modulation involves interactions between local circuits at the level of the spinal cord dorsal horn and long-range modulatory inputs (Figure 7.5). In a mechanism called the **gate control theory,** sensory inputs from large-diameter, nonpain A-β fibers (see Table 7.2) reduce pain transmission through the dorsal horn. Thus, for example, transcutaneous electrical nerve stimulation (TENS) devices work to reduce chronic pain by activating A-β fibers. This is also why shaking your hand after striking your thumb with a hammer temporarily helps relieve the pain. The **periaqueductal gray** receives inputs from the hypothalamus, amygdala, and cortex, and inhibits pain transmission in the dorsal horn via a relay in a region at the pontomedullary junction called the **rostral ventral medulla (RVM)** (see Figure 7.5). This region includes serotonergic (5-HT) neurons of the raphe nuclei (see Figure 14.12) that project to the spinal cord, modulating pain in the dorsal horn. The RVM also sends inputs mediated by the neuropeptide substance P to the locus ceruleus (see Figure 14.11), which in turn sends noradrenergic (NE) projections to modulate pain in the spinal cord dorsal horn (see Figure 7.5).

Opiate medications such as morphine are likely to exert their analgesic effects through receptors found in widespread locations throughout the nervous system, including receptors located on peripheral nerves. However, opiate receptors and **endogenous opiate peptides,** such as **enkephalin, β-endorphin,** and **dynorphin,** are found in particularly high concentrations at key points in the pain modulatory pathways. Thus, enkephalin- and dynorphin-containing neurons are concentrated in the periaqueductal gray, RVM, and spinal cord dorsal horn, while β-endorphin–containing neurons are concentrated in regions of the hypothalamus that project to the periaqueductal gray.

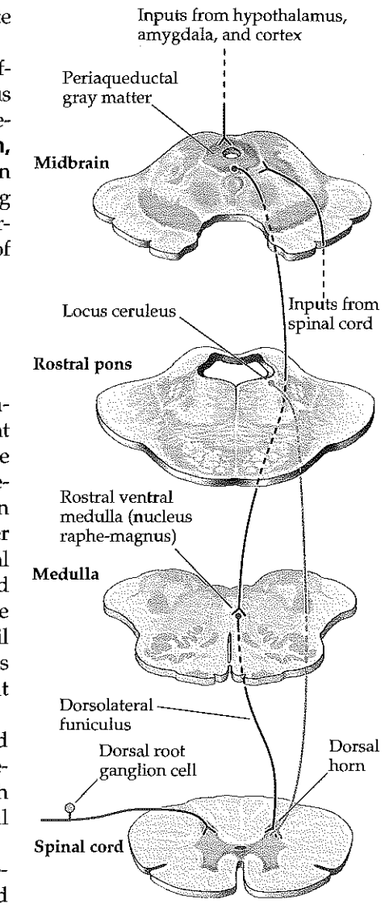

Figure 7.5 Central Pathways Involved in Pain Modulation

The Thalamus

The **thalamus** (meaning "inner chamber" or "bedroom" in Greek) is an important processing station in the center of the brain. Nearly all pathways that project to the cerebral cortex do so via synaptic relays in the thalamus. The thalamus is often thought of as the major sensory relay station, and it is therefore appropriate to introduce thalamic networks in this chapter. However, in addition to sensory information, the thalamus also conveys nearly all other inputs to the cortex, including motor inputs from the cerebellum and basal ganglia (see Chapters 15 and 16), limbic inputs (see Chapter 18), widespread modulatory inputs involved in behavioral arousal and sleep–wake cycles (see Chapter 14), and other inputs. We will introduce the thalamus in some detail here, both because of its relevance to sensory processing discussed in this chapter and because thalamic nuclei are important in several subsequent chapters.

Some thalamic nuclei have specific topographical projections to restricted cortical areas, while others project more diffusely. Thalamic nuclei typically receive dense reciprocal feedback connections from the cortical areas to which they project. In fact, corticothalamic projections outnumber thalamocortical projections.

As mentioned in Chapter 2, the thalamus is part of the **diencephalon,** together with the hypothalamus and epithalamus. The diencephalon is located just rostral to the midbrain (see Figure 2.2). The **hypothalamus,** located immediately ventral to the thalamus, is discussed in Chapter 17; the **epithalamus** consists of several small nuclei including the habenula, parts of the pretectum, and the pineal body. In horizontal sections, the thalami are visible as deep gray matter structures, shaped somewhat like eggs, with their posterior ends angled outward, forming an inverted V (see Figures 4.13, 6.9B, 6.10A, 16.3). The thalamus is divided into a **medial nuclear group, lateral nuclear group,** and **anterior nuclear group** by a Y-shaped white matter structure called the **internal medullary lamina** (Figure 7.6). Nuclei located within the internal medullary lamina itself are called the **intralaminar nuclei**. The **midline thalamic nuclei** are an additional thin collection of nuclei lying adjacent to the third ventricle, several of which are continuous with and functionally very similar to the intralaminar nuclei. Finally, the **thalamic reticular nucleus** (to be distinguished from the reticular nuclei of the brainstem) forms an extensive but thin sheet enveloping the lateral aspect of the thalamus. We will now discuss three main categories of thalamic nuclei (Table 7.3):

1. Relay nuclei
2. Intralaminar nuclei
3. Reticular nucleus

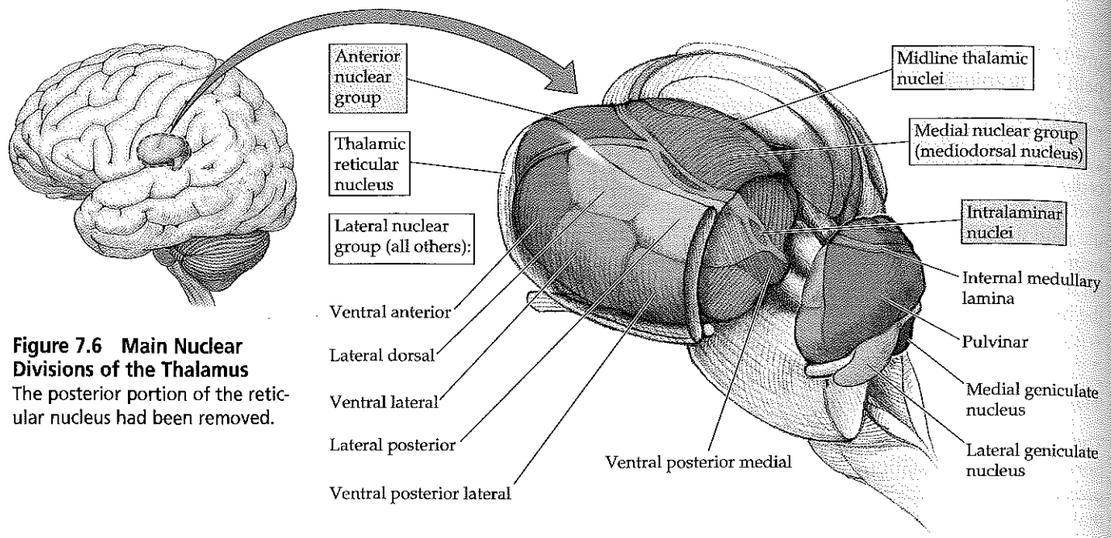

Figure 7.6 Main Nuclear Divisions of the Thalamus
The posterior portion of the reticular nucleus had been removed.

TABLE 7.3 Major Thalamic Nuclei

NUCLEI[a]	MAIN INPUTS[b]	MAIN OUTPUTS	DIFFUSENESS OF PROJECTIONS TO CORTEX[c]	PROPOSED FUNCTIONS
RELAY NUCLEI				
Lateral nuclear group				
Ventral posterior lateral nucleus (VPL)	Medial lemniscus, spinothalamic tract	Somatosensory cortex	+	Relays somatosensory spinal inputs to cortex
Ventral posteromedial nucleus (VPM)	Trigeminal lemniscus, trigeminothalamic tract, taste inputs	Somatosensory and taste cortex	+	Relays somatosensory cranial nerve inputs and taste to cortex
Lateral geniculate nucleus (LGN)	Retina	Primary visual cortex	+	Relays visual inputs to cortex
Medial geniculate nucleus (MGN)	Inferior colliculus	Primary auditory cortex	+	Relays auditory inputs to cortex
Ventral lateral nucleus (VL)	Internal globus pallidus, deep cerebellar nuclei, substantia nigra pars reticulata	Motor, premotor, and supplementary motor cortex	+	Relays basal ganglia and cerebellar inputs to cortex
Ventral anterior nucleus (VA)	Substantia nigra pars reticulata, internal globus pallidus, deep cerebellar nuclei	Widespread to frontal lobe, including prefrontal, premotor, motor, and supplementary motor cortex	+++	Relays basal ganglia and cerebellar inputs to cortex
Pulvinar	Tectum (extrageniculate visual pathway), other sensory inputs	Parietotemporo-occipital association	++	Behavioral orientation toward relevant visual and other stimuli
Lateral dorsal nucleus	See anterior nucleus	—	++	Functions with anterior nuclei
Lateral posterior nucleus	See pulvinar	—	++	Functions with pulvinar
Ventral medial nucleus	Midbrain reticular formation	Widespread to cortex	+++	May help maintain alert, conscious state

Relay Nuclei

Most of the thalamus is made up of **relay nuclei,** which receive inputs from numerous pathways and then project to the cortex. In addition, relay nuclei receive massive reciprocal connections back from the cortex. Projections of relay nuclei to the cortex may be fairly localized to specific cortical regions or more diffuse (Table 7.3).

SPECIFIC THALAMIC RELAY NUCLEI. Among the thalamic relay nuclei, projections to the primary sensory and motor areas tend to be the most localized. These specific relay nuclei lie mainly in the lateral thalamus. All sensory modalities, with the exception of olfaction, have specific relays in the lateral thalamus en route to their primary cortical areas (see Table 7.3; Figures 7.7, 7.8). For example, as we have discussed, somatosensory pathways from the spinal cord and cranial nerves relay in the **ventral posterior lateral (VPL)** and **ventral posterior medial (VPM)** nuclei, respectively. The VPL and VPM in turn project to the primary somatosensory cortex. Visual

TABLE 7.3 *(continued)*

NUCLEI[a]	MAIN INPUTS[b]	MAIN OUTPUTS	DIFFUSENESS OF PROJECTIONS TO CORTEX[c]	PROPOSED FUNCTIONS
Medial nuclear group				
Mediodorsal nucleus (MD)	Amygdala, olfactory cortex, limbic basal ganglia	Frontal cortex	++	Limbic pathways, major relay to frontal cortex
Anterior nuclear group				
Anterior nucleus	Mammillary body, hippocampal formation	Cingulate gyrus	+	Limbic pathways
Midline thalamic nuclei Paraventricular, parataenial, interanteromedial, intermediodorsal, rhomboid, reuniens (medial ventral)	Hypothalamus, basal forebrain, amygdala, hippocampus	Amygdala, hippocampus, limbic cortex	++	Limbic pathways
INTRALAMINAR NUCLEI				
Rostral intralaminar nuclei Central medial nucleus Paracentral nucleus Central lateral nucleus	Deep cerebellar nuclei, globus pallidus, brainstem, ascending reticular activating systems (ARAS), sensory pathways	Cerebral cortex, striatum	+++	Maintain alert consciousness; motor relay for basal ganglia and cerebellum
Caudal intralaminar nuclei **Centromedian nucleus** Parafascicular nucleus	Globus pallidus, ARAS, sensory pathways	Striatum, cerebral cortex	+++	Motor relay for basal ganglia
RETICULAR NUCLEUS	Cerebral cortex, thalamic relay and intralaminar nuclei, ARAS	Thalamic relay and intralaminar nuclei	None	Regulates state of other thalamic nuclei

[a]The most well known and clinically relevant nuclei are shown in **boldface.** Some additional smaller nuclei have not been included.
[b]In addition to the inputs listed, all thalamic nuclei receive reciprocal inputs from the cortex and from the thalamic reticular nucleus. Modulatory cholinergic, noradrenergic, serotonergic, and histaminergic inputs also reach most thalamic nuclei (see Chapter 14).
[c]+ = least diffuse (specific thalamic relay nuclei); ++ = moderately diffuse; +++ = most diffuse.

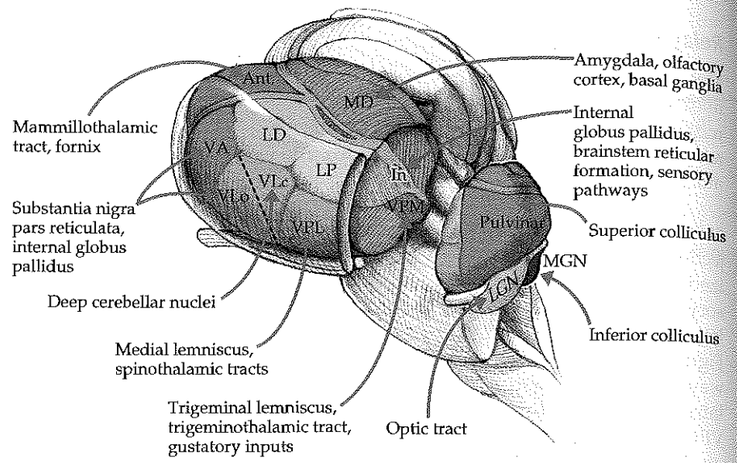

Figure 7.7 Noncortical Inputs to the Thalamus Main noncortical inputs to the different thalamic nuclei are shown. Cortical connections are shown in Figure 7.8. See Table 7.3 for additional details. Ant., anterior nuclear group; In, intralaminar nuclei; LD, lateral dorsal nucleus; LGN, lateral geniculate nucleus; LP, lateral posterior nucleus; MD, mediodorsal nucleus; MGN, medial geniculate nucleus; VA, ventral anterior nucleus; VLc, ventral lateral nucleus, pars caudalis; VLo, ventral lateral nucleus, pars oralis; VPL ventral posterior lateral nucleus; VPM, ventral posterior medial nucleus.

MNEMONIC

information is relayed in the **lateral geniculate nucleus** (**LGN**), as we will discuss further in Chapter 11, and auditory information is relayed in the **medial geniculate nucleus** (**MGN**), as we will discuss in Chapter 12 (see also Figure 6.9B). A useful mnemonic for these two nuclei is lateral light (vision), **m**edial **m**usic (audition). Motor pathways leaving the cerebellum and basal ganglia (see Figures 2.17, 15.9, and 16.6) also have specific thalamic relays in the **ventral lateral nucleus** (**VL**) en route to the motor, premotor, and supplementary motor cortex (see Table 7.3; Figures 7.7, 7.8). Even some limbic pathways (see Chapter 18) have fairly specific cortical projections, such as those carried by the **anterior nuclear group** to the anterior cingulate cortex. The anterior thalamic nuclear group forms a prominent bulge in the anterior superior thalamus (see Figure 7.6).

WIDELY PROJECTING (NONSPECIFIC) THALAMIC RELAY NUCLEI. Many thalamic nuclei have more widespread cortical projections (see Table 7.3; see Figures 7.7, 7.8). For example, visual and other sensory inputs to the **pulvinar** are relayed to large regions of the parietal, temporal, and occipital association cortex involved in behavioral orientation toward relevant stimuli. The pulvinar ("couch" or "cushion" in Latin) is a large, pillow-shaped nucleus that occupies most of the posterior thalamus (see Figure 7.6). Diffuse relays of limbic inputs, and other information involved in cognitive functions, occur in the **mediodorsal nucleus** (**MD**), as well as in the midline and intralaminar thalamic nuclei. The mediodorsal nucleus, sometimes called the dorsomedial nucleus, forms a large bulge lying medial to the internal medullary lamina, best seen in coronal sections (see Figure 16.4). The MD serves as the major thalamic relay for information traveling to the frontal association cortex (see Figure 7.8; see also Chapters 16, 18, 19). Other examples of widely projecting thalamic nuclei are also listed in Table 7.3.

Intralaminar Nuclei

The **intralaminar nuclei** lie within the internal medullary lamina (see Figure 7.6). Like the relay nuclei, they receive inputs from numerous pathways and have reciprocal connections with the cortex. They are sometimes classified along with other "nonspecific" relay nuclei. However, we have placed them in a separate category here because unlike relay nuclei, their main inputs and

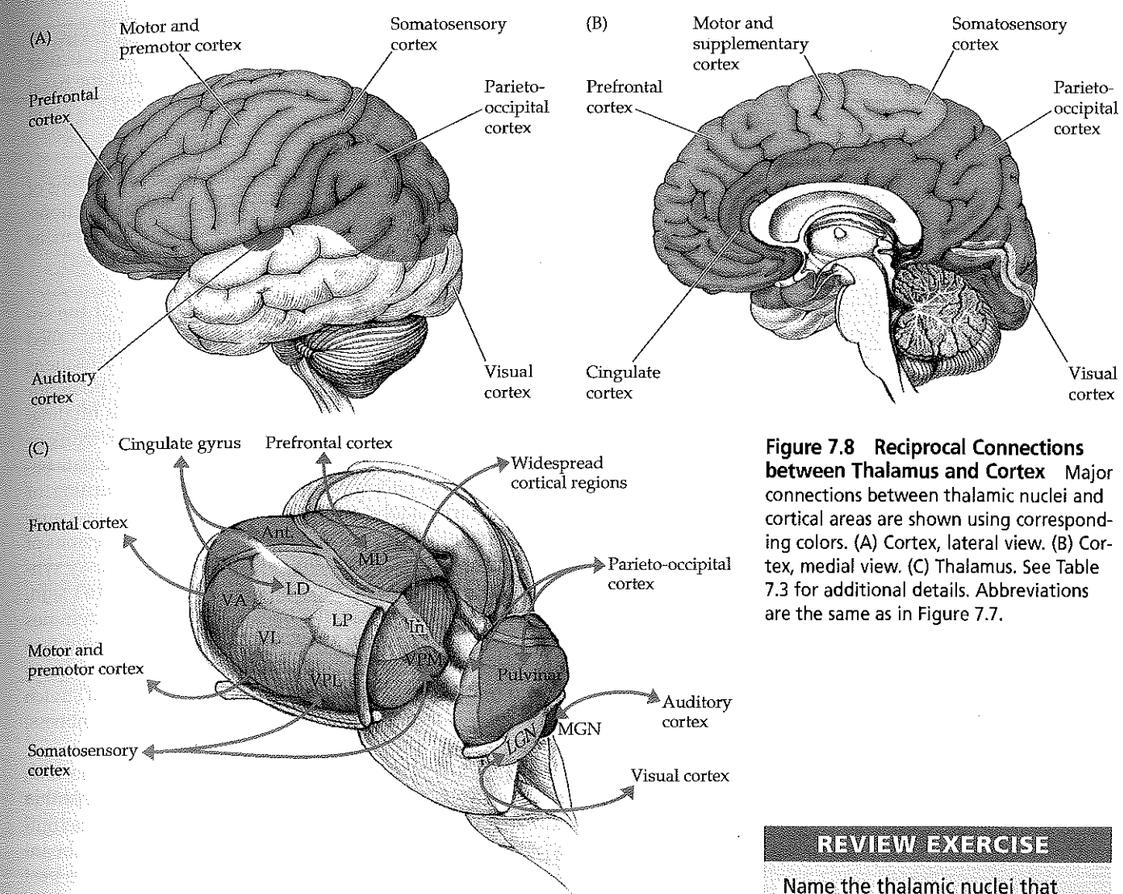

Figure 7.8 Reciprocal Connections between Thalamus and Cortex Major connections between thalamic nuclei and cortical areas are shown using corresponding colors. (A) Cortex, lateral view. (B) Cortex, medial view. (C) Thalamus. See Table 7.3 for additional details. Abbreviations are the same as in Figure 7.7.

REVIEW EXERCISE

Name the thalamic nuclei that are most important in relaying the following information to the cortex: somatosensory input, somatosensory face input, visual input, auditory input, basal ganglia and cerebellar input, limbic input (see the boldfaced entries in Table 7.3).

outputs are from the basal ganglia. Intralaminar nuclei can be divided into two functional regions (see Table 7.3): The **caudal intralaminar nuclei** include the large **centromedian nucleus** and are involved mainly in basal ganglia circuitry (see Chapter 16); the **rostral intralaminar nuclei** also have input and output connections with the basal ganglia. In addition, the rostral intralaminar nuclei appear to have an important role in relaying inputs from the **ascending reticular activating systems** (**ARAS**) to the cortex, maintaining the alert, conscious state (see Figure 2.23; Chapter 14).

Reticular Nucleus

The **reticular nucleus** forms a thin sheet located just lateral to the rest of the thalamus, and just medial to the internal capsule (see Figures 7.6, 16.4D). It should not be confused with the similarly named *reticular formation*, located in the brainstem (see Chapter 14). The reticular nucleus is the only nucleus of the thalamus that does not project to the cortex. Instead, it receives inputs mainly from other thalamic nuclei and the cortex and then projects back to the thalamus. The reticular nucleus consists of an almost pure population of inhibitory GABAergic neurons. This composition, together with its connec-

tions with the entire thalamus, make it well suited to regulate thalamic activity. In addition to cortical and thalamic inputs, other inputs to the reticular nucleus arising from the brainstem reticular activating systems and the basal forebrain may participate in modulating the state of alertness and attention (see Chapters 14, 19).

In summary, the thalamus has major reciprocal connections with all regions of the cerebral cortex. It contains many different nuclei with different functions. These nuclei convey information from other parts of the nervous system, as well as from the periphery to the cortex.

KEY CLINICAL CONCEPT
PARESTHESIAS

7.1 In addition to negative symptoms of sensory loss, lesions of the somatosensory pathways can cause abnormal positive sensory phenomena called **paresthesias.** Both the character and the location of these abnormal sensations reported by the patient can have localizing value. In lesions of the posterior column–medial lemniscal pathways, patients commonly describe a tingling, numb sensation, a feeling of a tight bandlike sensation around the trunk or limbs, or a sensation similar to gauze on the fingers when trying to palpate objects. In lesions of the anterolateral pathways, there is often sharp, burning, or searing pain. Lesions of the parietal lobe or primary sensory cortex may cause contralateral numb tingling, although pain can also be prominent. Lesions of the thalamus can cause severe contralateral pain, called **Dejerine–Roussy syndrome.** Lesions of the cervical spine may be accompanied by **Lhermitte's sign,** an electricity-like sensation running down the back and into the extremities upon neck flexion. Lesions of nerve roots often produce **radicular pain** (see KCC 8.3) that radiates down the limb in a dermatomal distribution, is accompanied by numbness and tingling, and is provoked by movements that stretch the nerve root. Peripheral nerve lesions, similarly, often cause pain, numbness, and tingling in the sensory distribution of the nerve.

In addition to "paresthesia," other common terms for sensory abnormalities include **dysesthesia** (unpleasant, abnormal sensation), and **hyperpathia** or **allodynia** (painful sensations provoked by minor stimuli such as light touch). The term **hypesthesia** means decreased sensation, but it may be interpreted (does the "hyp-" refer to "hyper-" or "hypo-"?) and is thus best avoided. ■

KEY CLINICAL CONCEPT
SPINAL CORD LESIONS

7.2 Spinal cord lesions are a major source of disability because they affect motor, sensory, and autonomic pathways. Suspected dysfunction of the spinal cord must therefore be treated as a medical emergency in an attempt to prevent irreversible damage. The most common causes of spinal cord dysfunction are compression due to trauma, and metastatic cancer. Other causes of spinal cord dysfunction are listed in Table 7.4.

Symptoms and signs of spinal cord dysfunction may be obvious when a **sensory level** and **motor dysfunction** corresponding to the level of the lesion are present (KCC 7.4). Reflex abnormalities, including **abnormal sphincteric function** can also help confirm the diagnosis (see Tables 3.6, 3.7; KCC 7.5). In more subtle cases, however, minor sensory or motor changes, back or neck pain, or fever (in epidural abscess) may be the only clues warning of incipient disastrous loss of function. Clinicians should therefore have a low threshold for ordering an urgent MRI scan in cases of suspected spinal cord lesions. In this regard note that although a sensory level can suggest the level of a lesion, sometimes the lesion may actually be much higher in the spinal cord. Therefore, higher levels, such as the thoracic and cervical cord, often must be imaged as well, even in cases of suspected lumbosacral pathology.

TABLE 7.4 Differential Diagnosis[a] of Spinal Cord Dysfunction

Trauma or mechanical	Tertiary syphilis
Contusion	Tropical spastic paraparesis
Compression	Schistosomiasis
Disc herniation	Inflammatory myelitis
Degenerative disorders of vertebral bones	Multiple sclerosis
Disc embolus	Lupus
Vascular (see Figure 6.5)	Postinfectious myelitis
Anterior spinal artery infarct	Neoplasms
Watershed infarct	Epidural metastasis
Spinal dural AVM (arteriovenous malformation)	Meningioma
Epidural hematoma	Schwannoma
Nutritional deficiency	Carcinomatous meningitis
Vitamin B_{12}	Astrocytoma
Vitamin E	Ependymoma
Epidural abscess	Hemangioblastoma
Infectious myelitis	Degenerative/developmental
Viral, including HIV	Spina bifida
Lyme disease	Chiari malformation
	Syringomyelia

[a]Following format of Figure 1.1.

In acute, severe lesions such as trauma, there is often initially a phase of **spinal shock** characterized by flaccid paralysis below the lesion, loss of tendon reflexes, decreased sympathetic outflow to vascular smooth muscle causing moderately decreased blood pressure, and absent sphincteric reflexes and tone. Over the course of weeks to months, spasticity and upper motor neuron signs usually develop. Some sphincteric and erectile reflexes may return, although often without voluntary control. Acute traumatic spinal cord lesions may have improved outcome if treated within the first 8 hours with high doses of steroids. In cord compression caused by tumors, it is essential to institute radiation and/or surgical intervention promptly to prevent irreversible loss of ambulation. An approximate rule of thumb is that 80% of patients treated for metastatic spinal cord compression after they lose ambulation will remain permanently nonambulatory, while 80% of patients treated before losing ambulation remain ambulatory for the rest of their lives. **Myelitis** is another important and common cause of spinal cord dysfunction, which can be infectious or inflammatory in etiology (see Table 7.4; see also KCC 5.9, 6.6). ■

KEY CLINICAL CONCEPT
SENSORY LOSS: PATTERNS AND LOCALIZATION

7.3 Sensory loss can be caused by lesions anywhere in the somatosensory pathways (see Figures 7.1, 7.2), including peripheral nerves, nerve roots, posterior column–medial lemniscal and anterolateral pathways, the thalamus, thalamocortical white matter pathways, and the primary somatosensory cortex. In this section and in KCC 7.4, we will review localizing patterns of sensory loss and associated deficits. Sensory loss in the face is discussed further in KCC 12.2. In the illustrations for this section, lesions are indicated in red, while regions of sensory loss are indicated in purple.

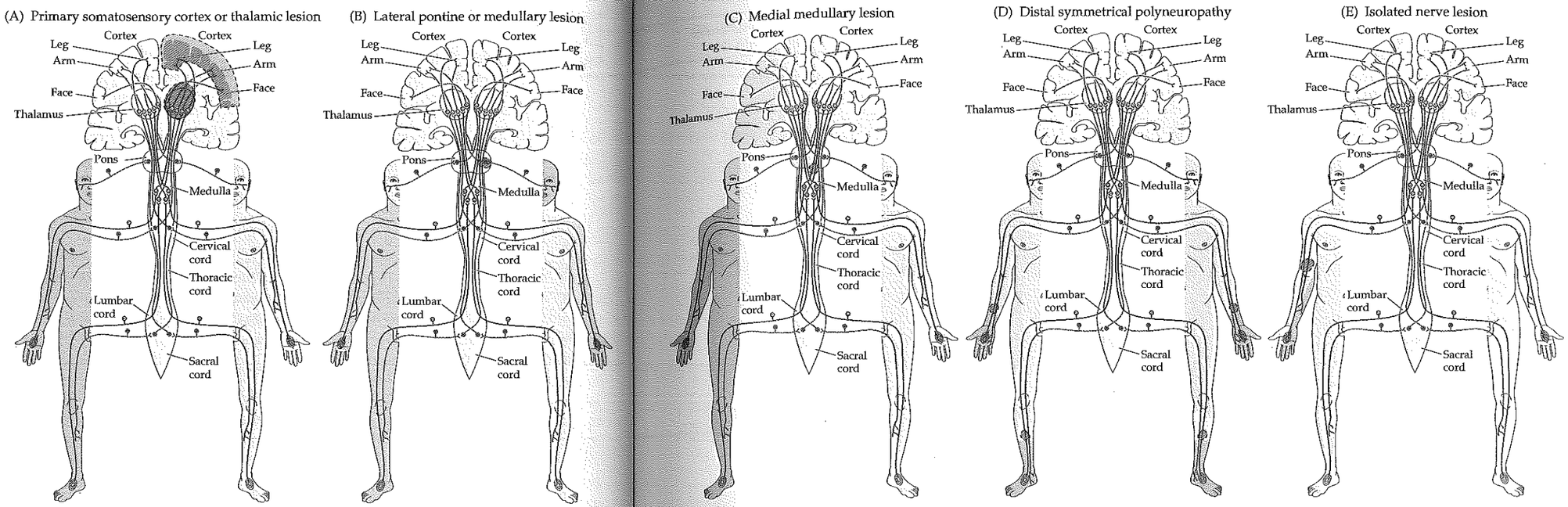

Figure 7.9 Patterns of Sensory Loss in Lesions of the Brain or Peripheral Nerves Lesions are shown in red; regions of sensory loss are shown in purple.

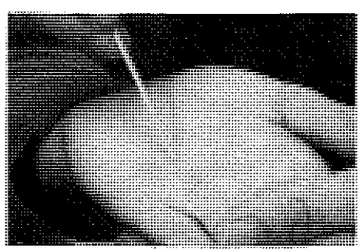

Graphesthesia

Primary Somatosensory Cortex (Figure 7.9A)

Deficit is contralateral to the lesion. Despite the depiction in Figure 7.9A, sensory loss does not begin neatly at the midline, and various subregions may be differentially affected depending on lesion size and location. Discriminative touch and joint position sense are often most severely affected (see neuroexam.com Videos 73, 74), but all modalities may be involved. Sometimes all primary modalities are relatively spared, but a pattern called **cortical sensory loss** is present, with extinction, or decreased stereognosis, and graphesthesia (see Chapter 3; neuroexam.com Videos 75–77). Associated deficits from involvement of adjacent cortical areas may include upper motor neuron–type weakness (Table 6.4), visual field deficits, or aphasia (see KCC 19.6).



Stereognosis

Thalamic Ventral Posterior Lateral (VPL) and Ventral Posterior Medial (VPM) Nuclei or Thalamic Somatosensory Radiations (Figure 7.9A)

Deficit is contralateral to the lesion. As with lesions of the primary somatosensory cortex, sensory loss does not begin neatly at the midline, and various subregions may be differentially affected. The deficit may be more noticeable in the face, hand, and foot than in the trunk or proximal extremities. All sensory modalities may be involved, sometimes with no motor deficit. Larger lesions may be accompanied by hemiparesis or hemianopia caused by involvement of the internal capsule, lateral geniculate, or optic radiations. Lesions of the thalamic somatosensory radiations can also cause contralateral hemisensory loss, which is associated with hemiparesis because of the involvement of adjacent corticobulbar and corticospinal fibers (see Figure 6.9B). Less commonly, lesions in other locations, such as the midbrain or upper pons, can cause contralateral somatosensory deficits involving the face, arm, and leg.

Lateral Pons or Lateral Medulla (Figure 7.9B)

The lesion involves anterolateral pathways and the spinal trigeminal nucleus on the same side. It causes loss of pain and temperature sensation in the body opposite the lesion, and loss of pain and temperature sensation in the face on the same side as the lesion. Associated deficits of the lateral pontine and the lateral medullary syndromes are discussed in KCC 14.3.

Medial Medulla (Figure 7.9C)

The lesion involves the medial lemniscus, causing contralateral loss of vibration and joint position sense. Associated deficits of the medial medullary syndrome are discussed in Chapter 14.

Spinal Cord

For patterns of sensory and motor loss in spinal cord lesions, see KCC 7.4.

Nerve Roots or Peripheral Nerves (Figure 7.9D,E)

Distal symmetrical polyneuropathies cause bilateral sensory loss in a "glove and stocking" distribution, in all modalities.

Specific nerve or nerve root lesions (Figure 7.9E) cause sensory loss in specific territories, as will be discussed in greater detail in KCC 8.3 and 9.1. Associated deficits of lesions of the peripheral nerves or nerve roots often include lower motor neuron–type weakness (see Table 6.4). ■

KEY CLINICAL CONCEPT
SPINAL CORD SYNDROMES

7.4 Common causes of spinal cord dysfunction were discussed earlier in this chapter in KCC 7.2. In this section, we will describe several important spinal cord syndromes that have sensory and motor findings that can often be used to localize the lesion.

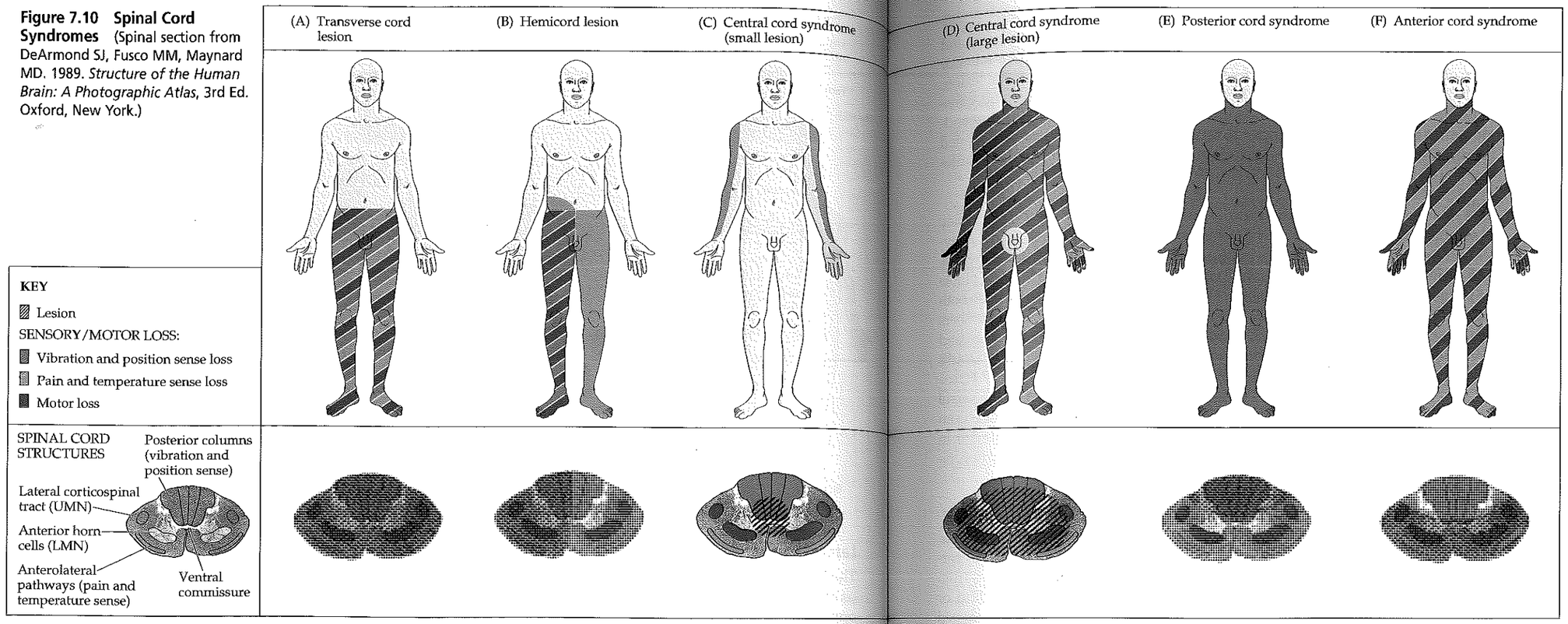

Figure 7.10 Spinal Cord Syndromes (Spinal section from DeArmond SJ, Fusco MM, Maynard MD. 1989. *Structure of the Human Brain: A Photographic Atlas*, 3rd Ed. Oxford, New York.)

Lower extremity strength

Deep tendon reflexes

Transverse Cord Lesion

See Figure 7.10A. All sensory and motor pathways are either partially or completely interrupted. There is often a **sensory level** corresponding to the level of the lesion (see Figure 8.4). The pattern of weakness and reflex loss can also help determine the spinal cord level (see Tables 3.4–3.7; KCC 8.2; neuroexam.com Videos 54, 56, and 58). Common causes of transverse cord lesions include trauma, tumors, multiple sclerosis, and transverse myelitis.

Hemicord Lesions: Brown–Séquard Syndrome

See Figure 7.10B. Damage to the lateral corticospinal tract causes *ipsilateral* upper motor neuron–type weakness. Interruption of the posterior columns causes *ipsilateral* loss of vibration and joint position sense. Interruption of the anterolateral systems, however, causes *contralateral* loss of pain and temperature sensation. This often begins slightly below the lesion because the anterolateral fibers ascend two to three segments as they cross in the ventral commissure. There may also be a strip of one or two segments of sensory loss to pain and temperature ipsilateral to the lesion, caused by damage to posterior horn cells before their axons have crossed over. Common causes of Brown–Séquard syndrome include penetrating injuries, multiple sclerosis, and lateral compression from tumors.

Central Cord Syndrome

See Figure 7.10C,D. In small lesions, damage to spinothalamic fibers crossing in the ventral commissure (see Figure 7.2) causes bilateral regions of **suspended sensory loss** to pain and temperature. Lesions of the cervical cord (see Figure 8.4) produce the classic **cape distribution;** however, suspended dermatomes of pain and temperature sensory loss can occur with lesions at other levels as well. With larger lesions (see Figure 7.10D), the anterior horn cells are damaged, producing lower motor neuron deficits at the level of the lesion. In addition, the corticospinal tracts are affected, causing upper motor neuron signs, and the posterior columns may be involved as well. Because the anterolateral pathways are compressed from their medial surface by large lesions, there may be near complete loss of pain and temperature sensation below the lesion except for in a region of **sacral sparing** (review the somatotopic distribution of anterolateral systems in the spinal cord; see Figure 7.3). Common causes of central cord syndrome include spinal cord contusion, posttraumatic syringomyelia, and intrinsic spinal cord tumors such as hemangioblastoma, ependymoma, or astrocytoma.

Posterior Cord Syndrome

See Figure 7.10E. Lesions of the posterior columns cause loss of vibration and position sense below the level of the lesion. With larger lesions, there may also be encroachment on the lateral corticospinal tracts, causing upper motor neuron–type weakness. Common causes include trauma, extrinsic compression from posteriorly located tumors, and multiple sclerosis. In addition, vitamin B_{12} deficiency and tabes dorsalis (tertiary syphilis; KCC 5.9) preferentially affect the posterior cord.

REVIEW EXERCISE

Cover the top and bottom rows in Figure 7.10. For each pattern of sensory and motor deficits, describe the spinal cord structures and side(s) involved, and name the syndrome

KEY CLINICAL CONCEPT

ANATOMY OF BOWEL, BLADDER, AND SEXUAL FUNCTION

Anterior Cord Syndrome

See Figure 7.10F. Damage to the anterolateral pathways causes loss of pain and temperature sensation below the level of the lesion, and damage to the anterior horn cells produces lower motor neuron weakness at the level of the lesion. With larger lesions, the lateral corticospinal tracts may also be involved, causing upper motor neuron signs. Incontinence is common because the descending pathways controlling sphincter function tend to be more ventrally located (Figure 7.11). Common causes include trauma, multiple sclerosis, and anterior spinal artery infarct. ■

7.5 Normal bowel, bladder, and sexual function requires the complex interplay of sensory and both voluntary and involuntary motor pathways at numerous levels in the nervous system. Sensory information from the rectum, bladder, urethra, and genitalia is conveyed to the spinal cord by sacral nerve roots S2 to S4 (Table 7.5). This information ascends to higher levels of the nervous system through both posterior and anterolateral columns (Figure 7.11). Voluntary somatic motor fibers arise from **anterior horn cells** at S2 to S4 to control the pelvic floor muscles, and from the specialized **sphincteromotor nucleus of Onuf** (also called simply **Onuf's nucleus**) at S2 to S4 to control the **urethral and anal sphincters** (Figure 7.11; see also Figure 7.12). Pelvic parasympathetics arise from the **sacral parasympathetic nuclei** at S2 to S4, and sympathetics arise from the **intermediolateral cell column** at T11 to L1 (see Table 7.5). In general, for lesions to affect bowel, bladder, or sexual function, bilateral pathways must be involved.

Bladder Function

Bladder emptying in normal adults is completely under voluntary control. A sense of bladder fullness reaches the sensory cortex, and micturition is initiated by descending pathways from **medial frontal micturition centers** that activate the **voiding,** or **detrusor, reflex** (see Figure 7.11). The detrusor reflex is mediated by intrinsic spinal cord circuits and regulated by the **pontine micturition center,** and possibly also by cerebellar and basal ganglia pathways. The reflex is normally initiated by voluntary relaxation of the external urethral sphincter, which triggers the inhibition of sympathetics to the bladder neck, causing it to relax, and the activation of parasympathetics, causing detrusor muscle contraction. The sensation of urine flow through the urethra activates continued sphincter relaxation and detrusor contraction. When flow stops, the urethral sphincters contract, thereby triggering detrusor relaxation through the **urethral reflex.** Flow can also be interrupted at any time by voluntary closure of the urethral sphincter, which similarly triggers detrusor relaxation.

Lesions affecting bilateral medial frontal micturition centers result in reflex activation of pontine and spinal micturition centers when the bladder is full. Urine flow and bladder emptying are normal; however, they are no longer under voluntary control, and the individual may or may not be aware of the incontinence. Common causes of frontal-type incontinence include hydrocephalus, parasagittal meningioma, bifrontal glioblastoma, traumatic brain injury, and neurodegenerative disorders.

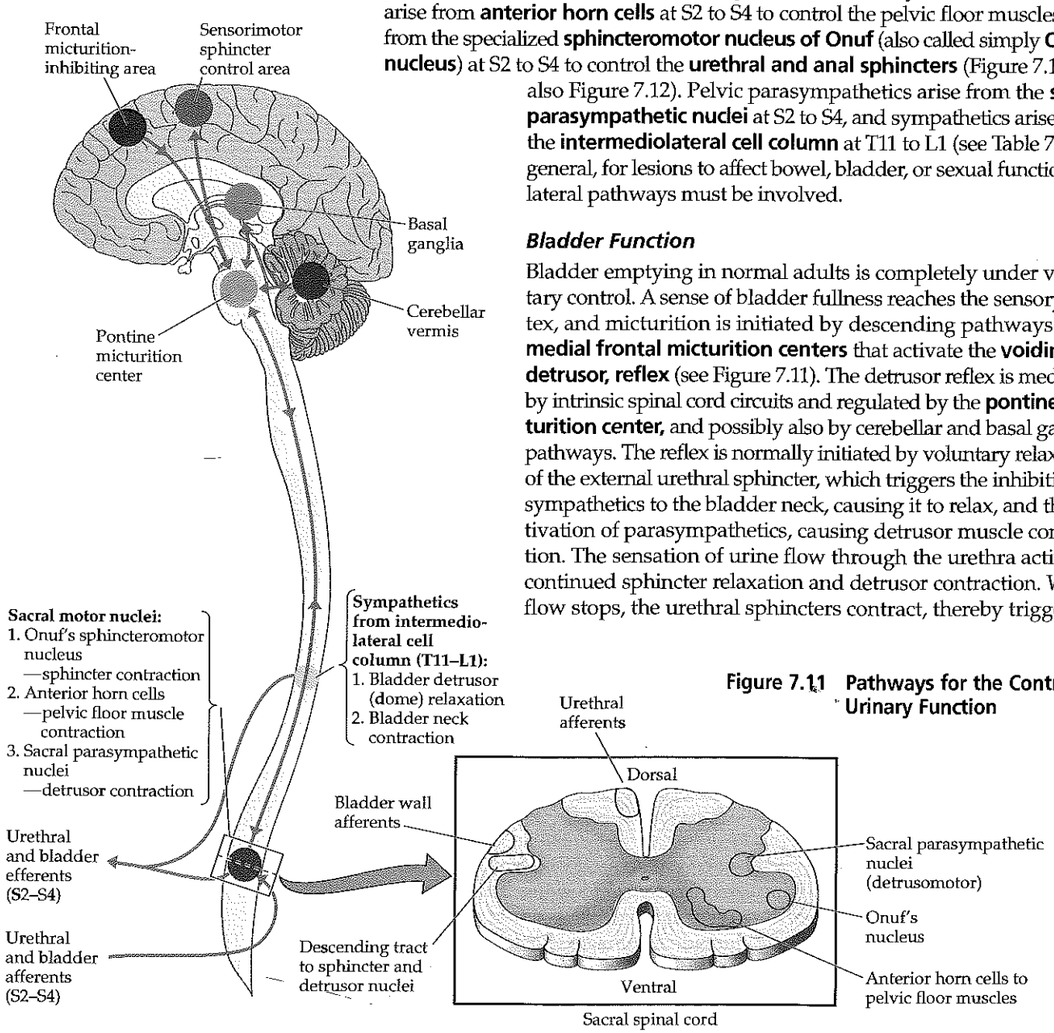

Figure 7.11 Pathways for the Control of Urinary Function

TABLE 7.5 Nuclei and Nerve Roots for Bladder, Bowel, and Sexual Function

PATHWAYS	NUCLEI, FOR MOTOR PATHWAYS	NERVE ROOTS[a]
BLADDER FUNCTION		
Detrusor and urethral afferents	—	S2, S3, S4
Somatic innervation of urethral sphincter	Onuf's nucleus	**S3**, S4
Somatic innervation of pelvic floor muscles	Anterior horn	S2, S3, S4
Parasympathetic innervation of detrusor	Sacral parasympathetic nucleus	S2, S3, S4
Sympathetic (α and β) innervation of bladder neck, urethra, and bladder dome	Intermediolateral cell column	T11, T12, L1
BOWEL FUNCTION[b]		
Rectal and pelvic floor afferents	—	S2, S3, S4
Somatic innervation of external anal sphincter	Onuf's nucleus	S3, **S4**
Somatic innervation of pelvic floor muscles	Anterior horn	S2, S3, S4
Parasympathetic innervation of internal anal sphincter, descending colon, and rectum	Sacral parasympathetic nucleus	S2, S3, S4
Parasympathetic innervation of gut above the splenic flexure	Dorsal motor nucleus of vagus	CN X
SEXUAL FUNCTION		
Genital afferents	—	S2, S3, S4
Parasympathetic innervation of Bartholin's glands	Sacral parasympathetic nucleus	S2, S3, S4
Sympathetic innervation of vaginal wall	Intermediolateral cell column	T11, T12, L1
Parasympathetic erectile pathway	Sacral parasympathetic nucleus	**S2**, S3, S4
Sympathetic erectile and anti-erectile pathways	Intermediolateral cell column	T11, T12, L1
Sympathetic ejaculatory pathway	Intermediolateral cell column	T11, T12, L1
Somatic motor pathway for ejection of semen	Anterior horn and Onuf's nucleus	S2, S3, S4

[a]Boldface indicates the most important nerve roots, where applicable.
[b]Bowel motility and secretions are also regulated by intrinsic networks of neurons in the wall of the gut referred to as the enteric nervous system (see Chapter 6).

(A) **Acute central lesion** Flaccid, acontractile (atonic) bladder with continued reflex contraction of urethral sphincter. Urinary retention, bladder distention, overflow incontinence

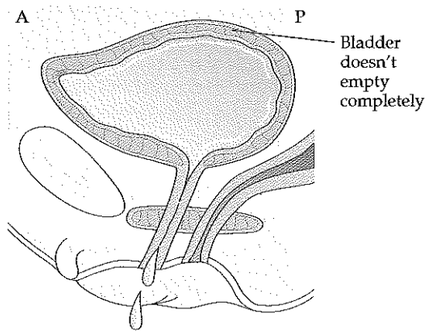

(B) **Chronic central lesion** Hyperreflexic (spastic) bladder. Urinary frequency and urge incontinence caused by detrusor–sphincter dyssynergia

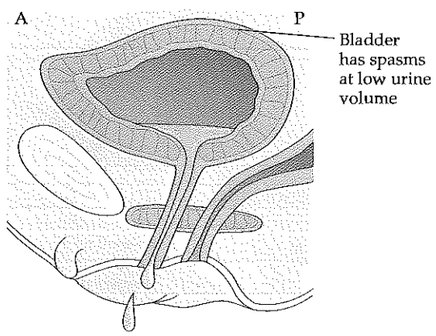

(C) **Peripheral lesion** Areflexic, acontractile (atonic) bladder. Overflow incontinence, stress incontinence

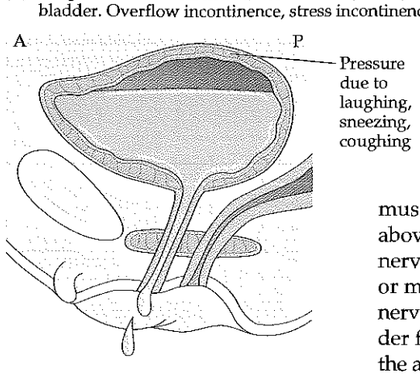

Figure 7.12 Types of Incontinence Resulting from Flaccid and Hyperreflexic Bladder Disorders
A = Anterior; P = Posterior.

Lesions below the pontine micturition center and above the conus medullaris levels S2 to S4 often initially cause a **flaccid, acontractile (atonic) bladder,** (Figure 7.12A) which usually evolves over weeks to months into a **hyperreflexic (spastic) bladder** (Figure 7.12B). When the bladder is atonic, reflex contractions of the urethral sphincters often persist, resulting in **urinary retention** and bladder distention (Figure 7.12A). Catheterization is usually necessary. The **post-void residual volume,** measured by catheterization after voluntary voiding, is increased in this condition (normal volume is less than 100 cc). In a hyperreflexic bladder (Figure 7.12B), **detrusor–sphincter dyssynergia** often occurs, in which both detrusor and urethral sphincter tone are increased in an uncoordinated, and at times antagonistic, fashion. When involuntary reflex bladder contractions occur, there may be a sense of **urinary urgency,** or **urge incontinence**. Often residual volume increases because of incomplete emptying, although volumes are typically smaller than with acontractile bladder. Common spinal cord lesions causing acontractile or hyperreflexic bladder include trauma, tumors, transverse myelitis, and multiple sclerosis.

Lesions of the peripheral nerves, or of the spinal cord at S2 to S4, usually cause a **flaccid areflexic bladder,** or significantly impaired bladder contractility resembling an acontractile bladder. This result can be due to loss of parasympathetic outflow to the detrusor and/or loss of afferent sensory information from the bladder and urethra. **Overflow incontinence** is often present. Common causes include diabetic neuropathy and compression of the conus medullaris or cauda equina by trauma, tumor, or disc herniation. Urinary retention and incontinence can also be caused by a large variety of non-neurologic conditions, such as prostatic hypertrophy, urethral strictures, and intrinsic sphincter deficiency. The term **neurogenic bladder** is a broad, nonspecific term used to refer to both flaccid and hyperreflexic bladder disorders of neurologic origin.

Bowel Function

Like urinary continence (see Figure 7.11), fecal continence is controlled by descending pathways originating mainly in the medial frontal lobes. Anal sphincter closure is maintained by an **internal smooth muscle sphincter** innervated by sacral parasympathetics, an **external striated muscle sphincter** innervated by pelvic nerves arising from Onuf's nucleus, and the **pelvic floor muscles** innervated by sacral anterior horn cells (see Figures 7.11, 7.12). Sensory inputs enter at S2 to S4 and play an important feedback role. Gastrointestinal motility depends on parasympathetics from S2 to S4 for colorectal smooth muscle beyond the splenic flexure. The portions of the gastrointestinal tract above the splenic flexure receive parasympathetic innervation from the vagus nerves (see Figure 6.13). Fecal incontinence can be caused by diffuse cerebral or medial frontal lesions, by spinal cord lesions, or by lesions of the sacral nerve roots or the pelvic or pudendal nerves (see the previous section, on bladder function, for examples of each type of lesion). In acute spinal cord lesions the anal sphincter is completely flaccid. There is also a loss of sacral parasympathetic outflow, causing severe constipation.

Sexual Lubrication, Erectile, and Ejaculatory Function

During sexual arousal, stimuli from multiple sensory modalities, together with internal psychological factors, result in activation of spinal cord autonomic pathways involved in sexual function. Sensation from the genitalia is conveyed by the pudendal nerve, reaching S2 to S4. In the female, secretion of lubricating mucus by Bartholin's glands is parasympathetically mediated, and increased vaginal blood flow and secretions are sympathetically mediated. In the male, both parasympathetic and sympathetic pathways contribute to erection (see Table 7.5), with the relative contributions of these two systems varying from individual to individual. Ejaculation occurs through sympathetically mediated contraction of smooth muscle (seminal vesicles, vas deferens, prostate, bladder neck), causing emission of semen into the urethra, followed by rhythmic reflex contractions of striated muscles (pelvic floor, urethral sphincter, bulbospongiosus, ischiocavernosus), resulting in forceful expulsion of semen.

In spinal cord lesions, reflex erection and reflex ejaculation may still occur, but this is highly variable. Peripheral nerve lesions, higher-order cortical lesions, and psychological factors can also cause sexual dysfunction. ■

CLINICAL CASES

CASE 7.1 SUDDEN ONSET OF RIGHT ARM NUMBNESS

CHIEF COMPLAINT
An 81-year-old right-handed man came to the emergency room because of right arm numbness and mild language difficulties.

HISTORY
The patient had not seen a doctor in many years. Past medical history was notable for hypertension, diabetes, and angina. At 6:30 P.M. on the day of admission, he suddenly became **confused** and **had difficulty combining words correctly into sentences.** He also complained that he **could not feel things with his right arm,** and that **it felt numb.** Furthermore, he had some difficulties using his right hand, saying he could not **"grape with it."** Finally, he also had a vague **blurring of vision** that he could not explain in greater detail.

PHYSICAL EXAMINATION
Vital signs: T = 98.7°F, P = 60, BP = 169/79, R = 12.
Neck: No bruits.
Lungs: Clear.
Heart: Regular rate with no murmurs.
Abdomen: Normal bowel sounds; soft, nontender.
Neurologic exam:
MENTAL STATUS: Alert and oriented × 3. Speech **fluent, but with occasional paraphasic errors, substituting some letters in words incorrectly** (see "History" above when the patient described use of his right hand). Good naming and repetition. No right–left confusion or finger agnosia. Was able to do simple calculations. Had difficulty with reading and writing.
CRANIAL NERVES: Pupils 2 mm, constricting to 1.5 mm in response to light. Poor cooperation on visual field testing, but seemed to have **difficulty at times seeing fingers on his right side.** Extraocular movements full. Facial sensation intact to light touch and pinprick. Symmetrical smile. Gag reflex present. Normal sternomastoid strength. Tongue midline.
MOTOR: **Mild right pronator drift.** Normal tone. 5/5 power throughout.
REFLEXES:

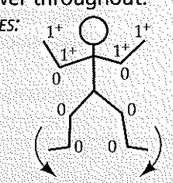

COORDINATION: Normal on finger-to-nose and heel-to-shin testing.
GAIT: Normal on limited testing.
SENSORY: Intact light touch and pinprick sense. Decreased vibration sense in both toes. **Graphesthesia and stereognosis** normal in the left hand, but **absent in the right hand. Occasional extinction in the right hand** on double simultaneous stimulation.

LOCALIZATION AND DIFFERENTIAL DIAGNOSIS
1. On the basis of the symptoms and signs shown in **bold** above, where is the lesion?
2. What is the most likely diagnosis? What are some other possibilities?

Discussion

1. The key symptoms and signs in this case are:
   - **Right arm numbness, extinction, agraphesthesia, and astereognosis with preserved primary sensory modalities**
   - **Mild fluent aphasia**
   - **Difficulty at times seeing fingers on his right side**
   - **Right pronator drift**

   The patient has a pattern of cortical sensory loss in the right arm consistent with a lesion in the left postcentral gyrus, primary somatosensory cortex, arm area (KCC 7.3). The loss of vibration sense in the toes is probably not relevant to his current problem and is likely due to long-standing distal symmetrical polyneuropathy (KCC 8.1), commonly seen in diabetics (this conclusion is also supported by the patient's generally diminished reflexes). The mild fluent aphasia can be explained by a lesion in the dominant (left) parietal lobe (see Chapter 19), as can his right-sided visual difficulties (see Chapter 11). The right pronator drift suggests some mild involvement of corticospinal fibers to the arm arising from the nearby motor cortex.

   The most likely *clinical localization* is left postcentral gyrus, primary somatosensory cortex, arm area, and some adjacent left parietal cortex.
2. The patient is an elderly man with hypertension, diabetes, and cardiac disease, with sudden onset of deficits suggesting embolic stroke (see KCC 10.4). An infarct of the left postcentral gyrus arm area and adjacent parietal cortex would be caused by occlusion of a cortical branch of the left middle cerebral artery (see Figure 10.6). Some other, less likely causes of a cortical lesion in this setting include a small hemorrhage, brain abscess, or tumor. A left subdural hematoma should also be considered, which could cause several mild left hemisphere deficits, as seen in this patient.

Clinical Course and Neuroimaging 289

A **head MRI** was done (Figure 7.13), showing an area of increased T2 signal consistent with an infarct in the left postcentral gyrus and adjacent parietal lobe. The patient was admitted to the hospital, and an embolic workup (see KCC 10.4) was significant only for regional wall movement abnormalities on his echocardiogram suggesting prior cardiac ischemia. His language improved back to normal within 5 days, and his right hand sensation also recovered. He was discharged home on aspirin.

CASE 7.2 SUDDEN ONSET OF RIGHT FACE, ARM, AND LEG NUMBNESS

CHIEF COMPLAINT

A 62-year-old, right-handed woman came to a medical clinic because of two days of numbness in her right face, arm, and leg.

HISTORY

On the morning prior to presentation the patient awoke with decreased sensation in her right face and arm "as though they were asleep." She had no difficulties with language, motor skills, or vision. Her symptoms continued until the next morning, when she also noticed loss of sensation in her right foot. She became concerned and came to her medical clinic for evaluation. Past medical history was notable for hypertension, cigarette smoking, and depression. Her father had a stroke at age 64.

PHYSICAL EXAMINATION

Vital signs: T = 97.4°F, P = 80, BP = 198/114, R = 16.
Neck: Supple with no bruits.
Lungs: Clear.
Heart: Regular rate with no murmurs, gallops, or rubs.
Abdomen: Normal bowel sounds; soft.
Extremities: No edema.
Neurologic exam:

MENTAL STATUS: Alert and oriented × 3. Recalled 3/3 words after 5 minutes. Language normal. Normal finger naming and calculations. No right–left confusion.

CASE 7.2 *(CONTINUED)*

CRANIAL NERVES: Pupils equal round and reactive to light. Fundi with A-V nicking (arteriovenous nicking is an ophthalmoscopic sign of chronic hypertension), but normal otherwise. Visual fields full. Extraocular movements intact. **Decreased pinprick, temperature, and light touch sensation in the right face,** especially near the mouth. Facial strength normal. Articulation and palate movements normal. Sternomastoid strength normal. Tongue midline.

MOTOR: No drift. Normal tone. Normal rapid alternating movements. 5/5 power throughout.

REFLEXES:

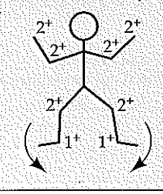

COORDINATION: Normal on finger-to-nose and heel-to-shin testing.

GAIT: Normal. Tandem gait normal.

SENSORY: **Decreased pinprick, temperature, light touch, and vibration sense on the right half of the body,** especially in the right hand and foot, and less so in the trunk. **Two-point discrimination 15 mm in the right index finger,** compared to 4 mm in the left index finger (using a ruler and the ends of a paper clip). Normal graphesthesia. No extinction on double simultaneous stimulation.

LOCALIZATION AND DIFFERENTIAL DIAGNOSIS

1. On the basis of the symptoms and signs shown in **bold** above, where is the lesion?
2. What is the most likely diagnosis? What are some other possibilities?

Discussion

1. The key symptoms and signs in this case are:
   - **Decreased pinprick, temperature, vibration, and light touch sensation in the right face and body, with decreased two-point discrimination in the right hand**

   Decreased primary sensation in half of the body, including the face, with no other deficits is sometimes thought to be psychologically based because there may be no objective findings on exam. However, this condition can be caused by lesions in the ventral posterior medial and ventral posterior lateral nuclei of the contralateral thalamus (see KCC 7.3).

   The most likely *clinical localization* is left ventral posterior thalamus.
2. Given the relatively sudden onset of deficits, and the history of hypertension, cigarette smoking, and family history of stroke, the most likely diagnosis is ischemic infarct of the left thalamus. Thalamic infarcts are usually caused by occlusion of small penetrating arteries such as the lenticulostriate (middle cerebral), anterior choroidal (internal carotid), or thalamoperforator (posterior cerebral) branches, resulting in lacunar infarction (see KCC 10.4; Table 10.3). Hemorrhage is also not uncommon in this location. Other possibilities include tumor or abscess.

Clinical Course and Neuroimaging 290

The patient was sent from the medical clinic to the emergency room, where a head CT showed a small hypodensity in the left thalamus. This was confirmed with a **head MRI** (Figure 7.14), showing increased T2 signal in the lateral thalamus consistent with a lacunar infarct. She was admitted to the neurology stroke service, and embolic workup did not reveal a cause for her infarct. She was started on medication to better control her hypertension and was entered into a clinical trial for patients with stroke of unknown cause, comparing aspirin to Coumadin in preventing stroke recurrence. Her numbness gradually improved and was completely gone by 5 days after admission.

CASE 7.3 A FALL CAUSING PARAPLEGIA AND A SENSORY LEVEL

MINICASE

A 24-year-old man was drinking heavily with some friends on the Fourth of July weekend and fell from a second-story balcony. He struck his back on a hard object on the way down and landed in a seated position. He immediately noticed **complete loss of movement and sensation in his legs.** In the emergency room, exam was notable for **flaccid tone and 0/5 strength throughout the lower extremities, decreased rectal tone, absent bulbocavernosus reflex, and a bilateral T10 sensory level to pinprick, touch, vibration, and joint position sense** (Figure 7.15; see Figure 8.4).

LOCALIZATION AND DIFFERENTIAL DIAGNOSIS

1. On the basis of the symptoms and signs shown in **bold** above, where is the lesion?
2. What is the most likely diagnosis?

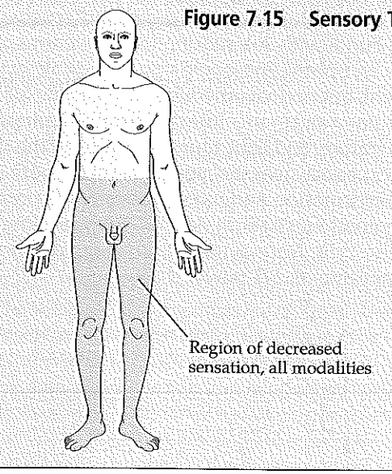

Figure 7.15 Sensory Testing

Discussion

1. The key symptoms and signs in this case are:
   - **Bilateral leg flaccid paralysis**
   - **Decreased rectal tone, and absent bulbocavernosus reflex**
   - **T10 sensory level to all modalities**

   Bilateral leg weakness can be caused by lesions of the bilateral medial frontal lobes, the spinal cord, nerve roots, peripheral nerves, or muscles (see KCC 6.3). However, complete paralysis of both legs with no weakness elsewhere, along with decreased rectal tone and reflexes (see KCC 7.4, 7.5; see also Tables 3.5, 3.7), strongly suggests a spinal cord or cauda equina lesion. The T10 sensory level localizes the lesion more specifically to the T10 level of the spinal cord (cauda equina cannot cause deficits above L1 or L2). The absent bulbocavernosus reflex supports an acute spinal cord injury causing spinal shock (see KCC 7.2, 7.5). The most likely *clinical localization* is spinal cord at T10 level (approximately T9 vertebral bone [see Figure 8.1], spinal cord, and root exit points).
2. Given the history of a significant fall, a fractured spine with cord compression at T10 is likely.

Clinical Course and Neuroimaging 290

The patient was given high-dose intravenous methylprednisolone (a steroid) in a standard protocol for acute spinal cord injuries. Plain radiographs were done, followed by a **CT of the spine** (Figure 7.16), showing a burst fracture of the T9 vertebral bone leading to near complete obliteration of the spinal canal. CT images at other levels showed less severe fractures of the T10 and T11 vertebral bones as well. Lateral radiographs showed anterior displacement of T9 on T10 by about 4 cm, further compressing the spinal canal. The patient was admitted to the intensive care unit and placed on a special bed for spinal stabilization. Because the spinal compression seemed complete, there was little hope for recovery of function. However, he was taken to the operating room to mechanically stabilize his thoracic spine, which is functionally important for maintaining a seated posture. A T6–T11 vertebral fusion was done with bone grafts and metal rods. The patient remained paraplegic at the time of transfer to a spinal cord rehabilitation center 2 weeks after admission.

CASE 7.1 SUDDEN ONSET OF RIGHT ARM NUMBNESS

Figure 7.13 Infarct in Left Postcentral Gyrus Somatosensory Cortex and Adjacent Parietal Lobe T2-weighted axial (horizontal) MRI sections. (A) More inferior. (B) More superior.

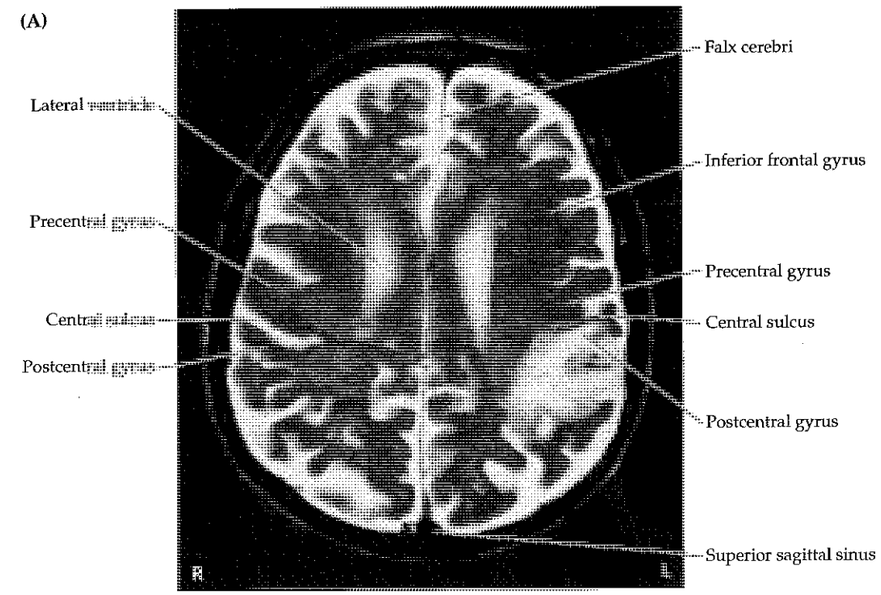

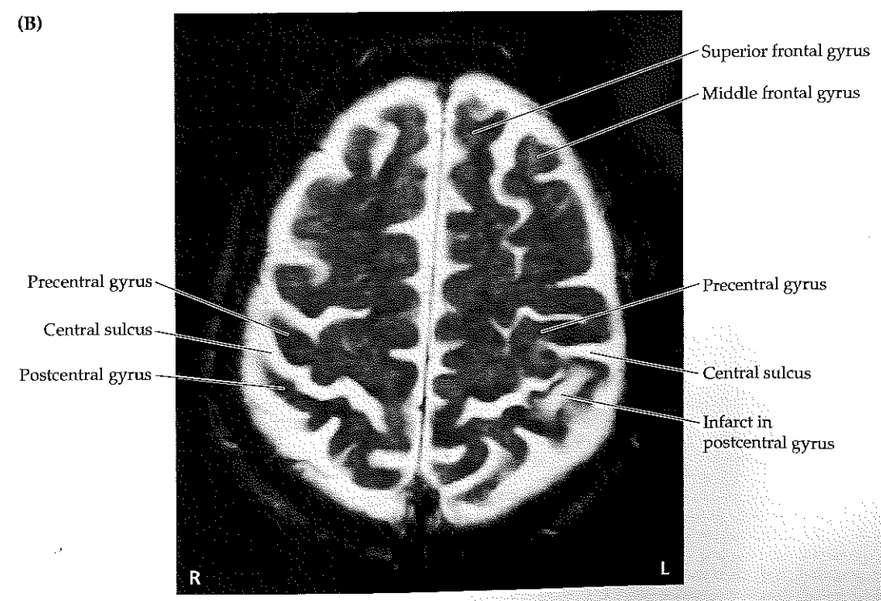

CASE 7.2 SUDDEN ONSET OF RIGHT FACE, ARM, AND LEG NUMBNESS

Figure 7.14 Lacunar Infarct in Left Thalamus Region of VPL and VPM
T2-weighted axial (horizontal) MRI section through thalamus and basal ganglia.

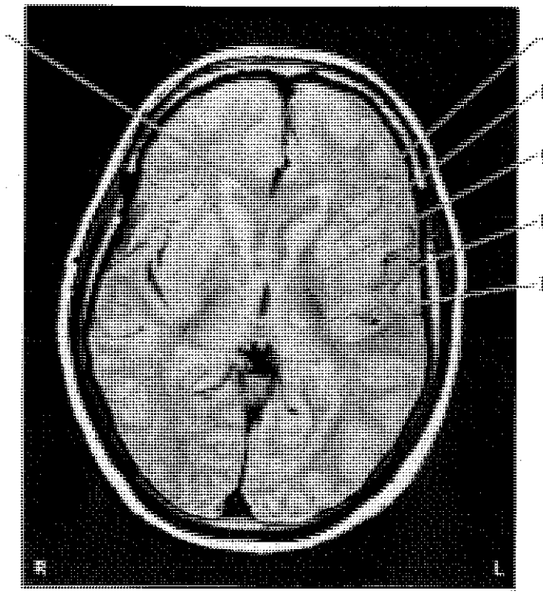

CASE 7.3 A FALL CAUSING PARAPLEGIA AND A SENSORY LEVEL

Figure 7.16 T10 Vertebral Fracture with Obliteration of Spinal Canal Axial CT of the spine. (A) Image at level of T10 vertebral body shows smashed T10 vertebral bone with obliteration of spinal canal and spinal cord at that level. (B) Image slightly lower, at level of T11, showing normal appearance of spinal canal.

(A)

CASE 7.3 *(CONTINUED)*

(B)

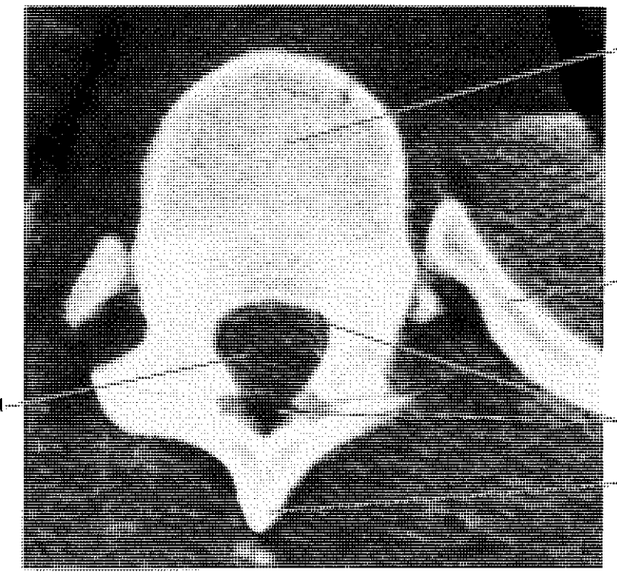

CASE 7.4 LEFT LEG WEAKNESS AND RIGHT LEG NUMBNESS

CHIEF COMPLAINT
A 71-year-old woman was referred to a neurologist with 10 months of progressive gait difficulty, right leg numbness, and urinary problems.

HISTORY
The patient was in good health, walking 3 to 4 miles per day until about 10 months prior to admission, when she first noticed mild **gait unsteadiness** and **bilateral leg stiffness.** She felt her feet were not fully under her control. Her **left leg gradually became weaker than her right,** with occasional left leg buckling when she walked. Meanwhile, her **right leg developed progressive numbness and tingling,** and she had intermittent **left-sided thoracic back pain.** Finally, she had increasing **urinary frequency, occasional urinary incontinence, and difficulty completing a bowel movement** despite several laxatives.

PHYSICAL EXAMINATION
Vital signs: T = 96.3°F, P = 78, BP = 136/76.
Neck: Supple.
Lungs: Clear.
Breasts: Normal.
Heart: Regular rate with no murmurs.
Abdomen: Soft; no masses.
Extremities: No edema.
Rectal: Normal tone; however, patient **could not voluntarily contract anal sphincter.** Stool was negative for occult blood.
Neurologic exam:
- *MENTAL STATUS:* Alert and oriented × 3. Mildly anxious, but otherwise normal.
- *CRANIAL NERVES:* Intact.
- *MOTOR:* Upper extremities: Normal bulk and tone; 5/5 strength throughout. Lower extremities: Normal bulk; **tone increased in left leg;** 5/5 strength throughout, except **4/5 strength in the left iliopsoas.**
- *REFLEXES:*

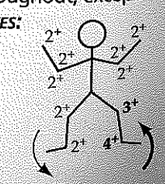

CASE 7.4 *(CONTINUED)*

COORDINATION: Normal on finger-to-nose and heel-to-shin testing.

GAIT: **Stiff-legged and unsteady.**

SENSORY: **Pinprick sensation decreased on the right side below the umbilicus** (Figure 7.17). **Vibration and joint position sense decreased in the left foot and leg.** Otherwise intact.

LOCALIZATION AND DIFFERENTIAL DIAGNOSIS

1. On the basis of the symptoms and signs shown in **bold** above, where is the lesion?
2. What is the most likely diagnosis? What are some other possibilities?

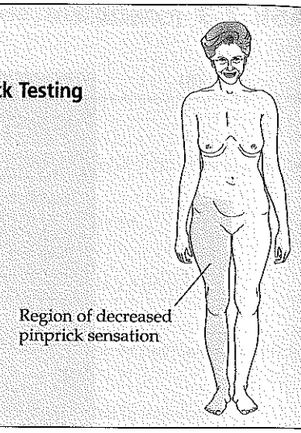

Figure 7.17 Pinprick Testing

Discussion

1. The key symptoms and signs in this case are:
   - **Left leg weakness, increased tone, hyperreflexia, and Babinski's sign**
   - **Decreased vibration and joint position sense in the left foot and leg**
   - **Decreased pinprick sensation on the right side below the umbilicus, with right leg numb, tingling paresthesias**
   - **Left-sided thoracic back pain**
   - **Stiff-legged, unsteady gait**
   - **Impaired bowel and bladder function**

   Unilateral weakness and upper motor neuron signs (see Table 6.4) in the leg could be caused by a lesion in the ipsilateral spinal cord or contralateral motor cortex (see KCC 6.3). The associated sensory abnormalities and left thoracic pain support a left hemicord lesion at approximately T9 or T10 (see Figure 8.4), producing a Brown–Séquard syndrome (KCC 7.4). The presence of bowel and bladder dysfunction suggests some bilateral involvement of the cord (KCC 7.5), as does the spastic gait (see KCC 6.5), which sounds as if it may have involved both legs.

   The most likely *clinical localization* is left T9 or T10 hemicord lesion, with possible mild involvement of the right cord as well.
2. Given the gradual, progressive onset of deficits over several months in an elderly woman, and the presence of local pain, the most likely diagnosis is a tumor compressing the thoracic spinal cord from the left side (see KCC 7.2; Table 7.4). Some other, less likely possibilities include arthritic bony changes compressing the spinal cord, or multiple sclerosis.

Clinical Course and Neuroimaging 294

The patient underwent a **spine MRI** (Figure 7.18), which showed a lesion arising from the dura consistent with a meningioma compressing the spinal cord from the left side at the T9 level. She was started on steroids and admitted to the hospital. Meningiomas are histologically benign (see KCC 5.8) and can often be treated effectively by local resection. She was therefore taken to the operating room, and a T8–T9 posterior laminectomy (see KCC 8.5) was performed. Once the dural sac was entered, a tannish mass was found on the left side and carefully dissected away from the spinal cord and nerve roots. Pathologic analysis was consistent with meningioma. The patient did well postoperatively, regaining pain and temperature sensation on the right, and position and vibration sense on the left, and experiencing improved ambulation and sphincter control.

CASE 7.5 SENSORY LOSS OVER BOTH SHOULDERS

MINICASE

A 46-year-old man was in a motor vehicle accident at age 18 years, sustaining C2 and C3 fractures. These fractures caused quadriparesis that gradually improved. In recent years, however, he has had **increasing difficulty walking.** He has also developed **pain and numbness in the shoulders and arms, more severe on the left side.** Exam was notable for **increased tone in all extremities and 3/5 to 4/5 power throughout.** These exam findings were slightly worse than in previous years. He had **brisk reflexes and bilateral upgoing toes.** Gait was **shuffling and slow.** He had **decreased pinprick sensation in the left arm from the shoulder down, and over the right shoulder** (Figure 7.19). Vibration sense was intact.

LOCALIZATION AND DIFFERENTIAL DIAGNOSIS

1. On the basis of the symptoms and signs shown in **bold** above, where is the lesion?
2. What is the most likely diagnosis? What are some other possibilities?

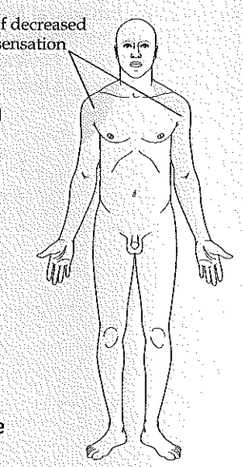

Figure 7.19 Pinprick Testing

Discussion

1. The key symptoms and signs in this case are:
   - **Decreased pinprick sensation and painful numb paresthesias in bilateral shoulders and in the left arm**
   - **Weakness, increased tone, and hyperreflexia in all extremities**
   - **Slow, shuffling gait**

   This patient has a region of suspended sensory loss to pinprick in a "cape" distribution over both shoulders consistent with a cervical central cord syndrome affecting approximately the C5 dermatomes bilaterally, and C6–T1 on the left (see KCC 7.4; see also Figure 8.4). A cervical central cord lesion could also explain the diffuse weakness with upper motor neuron signs and abnormal gait, since large central cord lesions can cause bilateral corticospinal dysfunction.

   The most likely *clinical localization* is central cord lesion above approximately C5.
2. Given the past history of spinal cord trauma, and delayed onset of a central cord syndrome, the most likely diagnosis is posttraumatic syringomyelia. **Syringomyelia** is a fluid-filled cavity in the spinal cord, which can occur with spinal cord tumors, with congenital abnormalities of the craniocervical junction, or following trauma. **Posttraumatic syringomyelia** is a delayed sequela of about 1% of spinal cord injuries, with symptoms beginning from a few months to up to 30 years after the injury (9 years on average). The pathophysiological mechanism is unknown, but patients present with a central cord syndrome that can progressively worsen or spontaneously stabilize. Surgical decompression has been tried, but the long-term benefits are uncertain. Aside from posttraumatic syringomyelia, other, less likely diagnoses in this patient include central cord involvement by multiple sclerosis or an intrinsic spinal cord tumor such as astrocytoma or ependymoma (see Table 7.4).

Clinical Course and Neuroimaging 295

A cervical **spine MRI** (Figure 7.20) showed a T1 dark cavity consistent with fluid in the center of the spinal cord representing a syrinx extending from C3 to C4. The patient underwent decompressive surgery and did well in the immediate postoperative period, but was subsequently lost to follow-up.

CASE 7.4 LEFT LEG WEAKNESS AND RIGHT LEG NUMBNESS

Figure 7.18 Intradural Mass Compatible with Meningioma Compressing Left Spinal Cord at T9
MRI scan. (A) Sagittal T1-weighted image with intravenous gadolinium, showing a homogeneous enhancing mass lesion within spinal canal at T9 level. (B) Axial T2-weighted image at T9 level, showing mass located within the dural sac but outside the spinal cord, compressing cord from the left side.

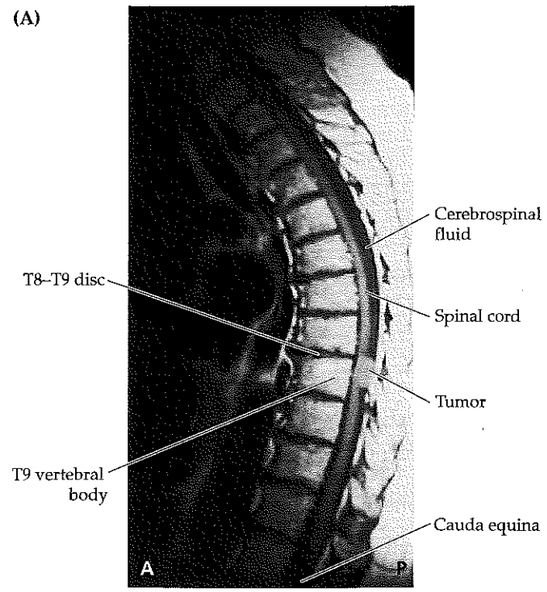

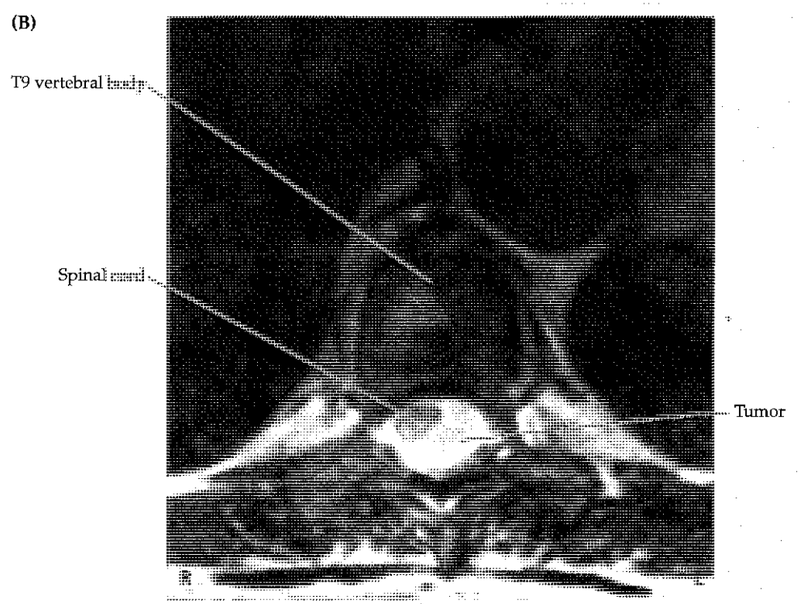

CASE 7.5 SENSORY LOSS OVER BOTH SHOULDERS

Figure 7.20 Fluid-Filled Syrinx in Cervical Spinal Cord at C3, C4 Levels
T1-weighted sagittal MRI.

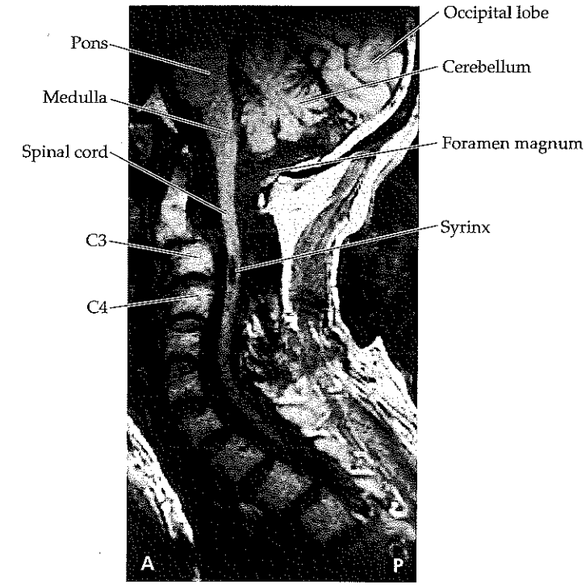

CASE 7.6 BODY TINGLING AND UNSTEADY GAIT

MINICASE

A 37-year-old woman came to the emergency room complaining of **tingling and numbness of her arms, legs, and trunk** of 1 week's duration. She also complained of **clumsiness when walking** quickly or up stairs and of **decreased dexterity in her hands.** She had no other complaints, except for an occasional brief **electricity-like sensation** that she felt beginning in her spine and running down her arms and legs that was brought on by neck movement. Exam was notable for **dysmetria** on finger-to-nose testing, which was markedly **worse with the eyes closed.** Tandem gait was somewhat **unsteady.** A **dramatic Romberg sign** was present. There was **profound loss of vibration sense,** absent in the toes, ankles, and knees and reduced in the knuckles. **Joint position sense** was moderately **decreased** in the toes and slightly decreased in the fingers. Pinprick and temperature sensation were intact, but testing elicited a **girdlelike band of increased sensation** extending from the lower chest to the abdomen. The remainder of the exam was normal.

LOCALIZATION AND DIFFERENTIAL DIAGNOSIS

1. On the basis of the symptoms and signs shown in **bold** above, where is the lesion?
2. What is the most likely diagnosis? What are some other possibilities?

Discussion

1. The key symptoms and signs in this case are:
   - **Loss of vibration and joint position sense in the arms and legs bilaterally**
   - **Clumsy, unsteady gait, with Romberg sign**
   - **Decreased dexterity, and dysmetria of the hands especially with eyes closed**
   - **Paresthesias: Diffuse tingling and numbness, Lhermitte's sign (see KCC 7.1), and girdlelike band of hyperpathia around the abdomen**

   Loss of vibration and joint position sense in all extremities with no other associated deficits can be caused by a lesion of the posterior columns in the cer-

vical spinal cord (see KCC 7.4) or by a large fiber neuropathy (see Table 7.2; KCC 8.1). The gait unsteadiness and Romberg sign (see KCC 6.5) can also be explained by the proprioceptive deficit, as can impaired coordination of the hands that is worse with the eyes closed. Lhermitte's sign (see KCC 7.1) suggests that the lesion is in the cervical spine.

The most likely *clinical localization* is posterior columns of the cervical spinal cord, extending above approximately C5 (arms are involved).

2. Given the relatively rapid onset of deficits localizable to central nervous system white matter tracts in a young woman, these symptoms could represent the first episode of multiple sclerosis (see KCC 6.6), presenting as myelitis (see KCC 7.2). Alternatively, it could represent myelitis (see Table 7.4) from another cause, such as infectious or postinfectious myelitis. Other conditions causing prominent posterior column involvement include tabes dorsalis of tertiary syphilis, and vitamin B_{12} deficiency (tabes dorsalis actually affects mainly the dorsal roots, with secondary degeneration of the posterior columns).

Clinical Course and Neuroimaging 298

A cervical **spine MRI** (Figure 7.21) showed increased T2 signal in the cervical posterior cord. Additional history was elicited of a paternal uncle with multiple sclerosis (see KCC 6.6). In addition, the patient had had a respiratory infection during the preceding month. Additional tests were negative, except for two oligoclonal bands (see KCC 6.6) present in the cerebrospinal fluid. The presumed diagnosis was either postinfectious myelitis or myelitis as a precursor to multiple sclerosis. The patient's gait unsteadiness and loss of vibration sense were improved but still present at the time of discharge.

CASE 7.7 HAND WEAKNESS, PINPRICK SENSORY LEVEL, AND URINARY RETENTION

MINICASE

A 26-year-old woman was pushing a shopping cart and suddenly developed neck pain, arm pain, and **bilateral hand weakness.** Shortly afterward she found that she had **urinary retention,** being unable to void voluntarily, as well as **fecal incontinence.** She went to the emergency room, where her exam was notable for **upper extremities with bilateral decreased tone, 3/5 triceps strength (C7), and 0/5 grip and finger extensors bilaterally (C8–T1), with absent triceps reflexes.** In addition, she had a **sensory level (see KCC 7.4) to pinprick and temperature sensation** as shown in Figure 7.22, with preserved vibration and joint position sense. **Rectal tone was absent, and she required urinary catheterization** to void.

LOCALIZATION AND DIFFERENTIAL DIAGNOSIS

1. Is the bilateral hand weakness caused by an upper motor neuron or a lower motor neuron lesion (see Table 6.4)? A lesion in what location can cause such weakness (see KCC 6.3)?
2. The reduced sensory level to pinprick occurs at what spinal level (see Figure 8.4)?
3. Lesions in what location can cause acute urinary retention and fecal incontinence with absent rectal tone (see KCC 7.5)?
4. On the basis of the symptoms and signs described above, where is the patient's lesion? What are some possible causes?

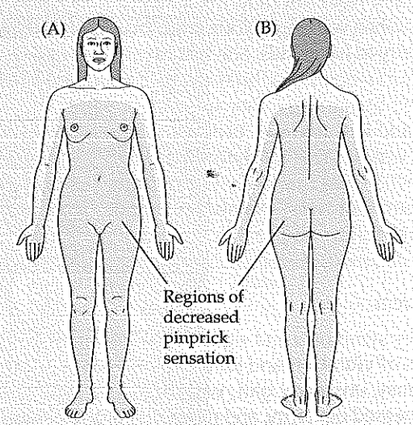

Figure 7.22 Pinprick Testing

Discussion

1. The key symptoms and signs in this case are:
   - **Bilateral hand and triceps weakness, hypotonia, and absent triceps reflexes**
   - **Sensory level to pinprick and temperature**
   - **Urinary retention, fecal incontinence, and absent rectal tone**

   The patient has weakness, absent reflexes, and hypotonia at C7–T1, suggesting either a lower motor neuron lesion, or an acute upper motor neuron lesion (see Table 6.4). Bilateral hand (C8–T1) and triceps (C7) weakness can be caused by bilateral anterior horn cell lesions at this level (see KCC 6.3; Figure 6.14I).
2. The reduced sensory level to pinprick occurs at spinal level C7.
3. Urinary retention caused by flaccid bladder with preserved hyperactive urinary sphincter reflexes can be caused by acute lesions below the pontine micturition center and above the conus medullaris (KCC 7.5). Fecal incontinence with absent rectal tone can be seen in cauda equina or acute spinal cord lesions. Therefore, the most likely localization is an acute spinal cord lesion.
4. C7–T1 lower motor neuron weakness, a C7 sensory level to pinprick, and urinary retention with fecal incontinence suggest an anterior cord syndrome (see KCC 7.4) at approximately the C7 to T1 levels. Some possible causes would include anterior spinal artery infarct, infectious or inflammatory myelitis, or possibly undisclosed trauma (see Table 7.4).

Clinical Course and Neuroimaging 298

A cervical **spine MRI** (Figure 7.23) showed increased T2 signal in the anterior cervical spinal cord extending from C5 to T1. A very extensive workup for inflammatory, infectious, and embolic disorders was carried out but was negative. The patient's strength and urinary retention gradually improved, and on a follow-up examination 1 year later she had recovered 4/5 strength in both hands. She continued, however, to have bothersome neck and shoulder pain requiring treatment in a comprehensive pain management program.

Additional Cases

Related cases of **somatosensory deficits** (Cases 8.1, 8.5–8.7, 8.11, 9.1, 9.3, 9.4, 9.6–9.10, 10.2, 10.8, 10.10, 10.11, 10.13, 12.2, 12.3, 13.5, 14.1, 14.4, 15.4, 19.6). Other relevant cases can be found using the **Case Index.**

Brief Anatomical Study Guide

1. This chapter completes our discussion of the three most clinically important long tracts in the nervous system: the **lateral corticospinal tract** (see Chapter 6), the **posterior column–medial lemniscal pathway,** and the **anterolateral pathways** (see Table 7.1). The posterior column–medial lemniscal pathway subserves the sensory modalities of **proprioception, vibration sense, and fine touch** and has its **major decussation in the lower medulla.** The anterolateral pathways convey the sensory modalities of **pain, temperature, and crude touch** and have their **major decussation in the spinal cord.**
2. In the posterior column–medial lemniscal pathway (proprioception, vibration sense, and fine touch), myelinated fibers enter the spinal cord dorsal roots, ascend in the posterior column **gracile fasciculus (legs)** or **cuneate fasciculus (arms)** to synapse in the **nucleus gracilis** or the **nucleus cuneatus** of the caudal medulla (see Figure 7.1).

CASE 7.6 BODY TINGLING AND UNSTEADY GAIT

Figure 7.21 Region of Hyperintensity in the Posterior (Dorsal) Cervical Spinal Cord at the C3, C4, C5 Levels Compatible with Demyelination
T2-weighted sagittal MRI of the spine.

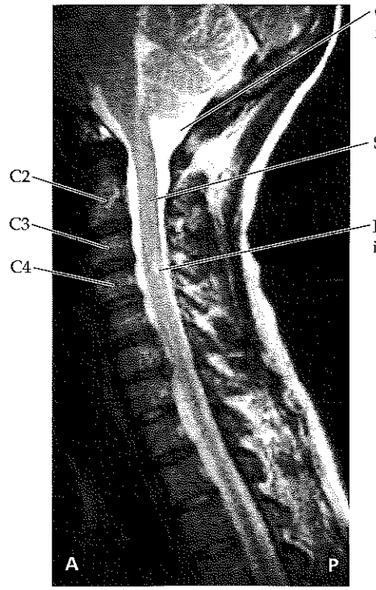

CASE 7.7 HAND WEAKNESS, PINPRICK SENSORY LEVEL, AND URINARY RETENTION

Figure 7.23 Anterior Spinal Cord Lesion at C5–T1 Levels T2-weighted MRI.
(A) Sagittal image showing lesion in anterior (ventral) spinal cord at the C5–T1 levels.
(B) Axial image at the C5 level showing anterior spinal cord lesion.

(A)

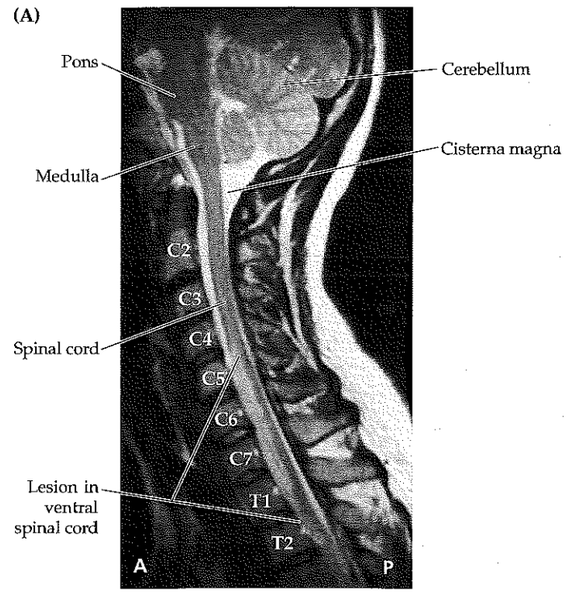

CASE 7.7 *(CONTINUED)*

(B)

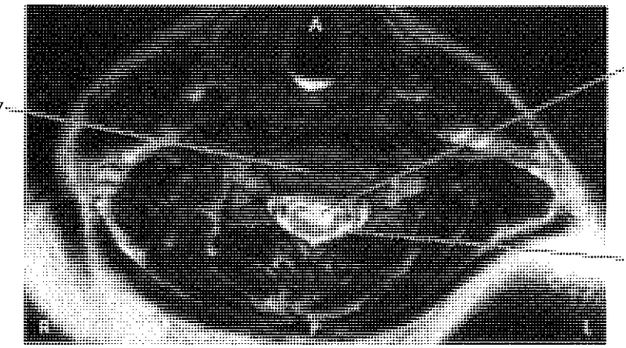

Brief Anatomical Study Guide *(continued)*

3. Second-order sensory neurons then **cross to the opposite side of the medulla** in the **internal arcuate fibers** to form the **medial lemniscus,** which ascends to the **ventral posterior lateral (VPL) nucleus** of the thalamus. Tertiary sensory neurons from the VPL project to the **primary somatosensory cortex** (Figure 7.1; see also Figure 6.1) via the posterior limb of the internal capsule.
4. The anterolateral system **spinothalamic pathway** mediates discriminative aspects of pain and temperature sensation, while other anterolateral pathways are more involved in the arousal, affective, and modulatory aspects of pain perception. In the spinothalamic pathway, small myelinated and unmyelinated fibers enter the spinal cord dorsal roots and synapse in the **dorsal horn marginal zone** and other layers (see Figure 7.2; see also Figure 6.3B).
5. Secondary sensory neurons in the dorsal horn have axons that **cross to the opposite side of the spinal cord** and then ascend in the ventral lateral part of the spinal cord and brainstem to reach the **VPL** of the thalamus. Once again, tertiary sensory neurons from the VPL then project to the **primary somatosensory cortex** (Figure 7.2; see also Figure 6.1) via the posterior limb of the internal capsule.
6. Like the lateral corticospinal tract, the somatosensory pathways are **somatotopically organized** (see Figure 7.3; see also Figure 6.2). Spinal cord pathways discussed in Chapters 6 and 7 are summarized in Figure 7.4.
7. The **thalamus** is the major subcortical relay station for signals traveling to all regions of the cortex. In addition to the VPL and VPM, which relays somatosensory information, the thalamus contains many other nuclei (see Table 7.3; Figures 7.6–7.8) that convey sensory, motor, limbic, associative, modulatory, or other signals to different cortical areas. The most clinically important nuclei of the thalamus are shown in bold in Table 7.3.

Brief Anatomical Study Guide *(continued)*

8. **Control of bladder, bowel, and genital function** involves afferent sensory information, as well as sympathetic, parasympathetic, and somatic motor pathways (see Table 7.5). Lesions at multiple levels can affect these functions, since they are controlled by local networks of the sacral spinal cord, as well as by descending inputs from the brainstem and forebrain, including the medial frontal lobes (see Figure 7.11).

References

General References

Carpenter MB. 1991. *Core Text of Neuroanatomy*, 4th Ed. Williams & Wilkins, Baltimore, MD, Chapters 3, 4, and 9.

Kandel ER, Schwartz JH, Jessell TM. 1991. *Principles of Neural Science*, 4th Ed. McGraw-Hill, New York, Chapters 21–24.

Martin JH. 1996. *Neuroanatomy: Text and Atlas*, 2nd Ed. Appleton & Lange, Stamford, CT, Chapters 5, 9, and 14.

Purves D, Augustine GJ, Fitzpatrick D, Katz LC, LaMantia A-S, McNamara JO, Williams SM (eds.). 2001. *Neuroscience*, 2nd Ed. Sinauer, Sunderland, MA, Chapters 9, 10.

Posterior Columns and Anterolateral Pathways

Apkarian AV, Hodge CJ. 1989. Primate spinothalamic pathways: I. A quantitative study of the cells of origin of the spinothalamic pathway. *J Comp Neurol* 288(3): 447–473.

Craig AD, Bushnell, MC, Zhang, ET, Blomqvist A. 1994. A thalamic nucleus specific for pain and temperature sensation. *Nature* 372(6508): 770–773.

Hodge CJ, Apkarian AV. 1990. The spinothalamic tract. *Crit Rev Neurobiol* 5(4): 363–397.

Light AR. 1988. Normal anatomy and physiology of the spinal cord dorsal horn. *Appl Neurophysiol* 51(2–5): 78–88.

Thalamus

Castro-Almanacos MA, Connors BW. 1997. Thalamocortical synapses. *Prog Neurobiol* 51(6): 581–606.

McCormick DA, Bal T. 1997. Sleep and arousal: Thalamocortical mechanisms. *Annu Rev Neurosci* 20: 185–215.

Steriade M, Jones EG, McCormick DA. 1997. *Thalamus*, Vol. 1. Elsevier, Amsterdam.

Sensory Loss in Stroke

Fisher CM. 1978. Thalamic pure sensory stroke: A pathologic study. *Neurology* 28(11): 1141–1144.

Mohr JP, Gautier JC, Hier DB. 1998. Middle cerebral artery disease. In Barnett JM, Mohr JP, Stein BM (eds.), *Stroke: Pathophysiology, Diagnosis, and Management*, 3rd Ed., Chapter 16. Churchill Livingstone, New York.

Derouesne C, Mas JL, Bolgert F, and Castaigne P. 1984. Pure sensory stroke caused by a small cortical infarct in the middle cerebral artery territory. *Stroke* 15(4): 660–662.

Shintani S. 1998. Clinical-radiological correlations in pure sensory stroke. *Neurology* 51(1): 297–302.

Spinal Cord Disorders

Bracken MB, Shepard MJ, Collins WF, et al. 1990. A randomized, controlled trial of methylprednisolone or naloxone in the treatment of acute spinal-cord injury. *N Engl J Med* 322(20): 1405–1411.

Breuer AC, Kneisley LW, Fischer EG. 1980. Treatable extramedullary cord compression. Meningioma as a cause of the Brown–Séquard syndrome. *Spine* 5(1): 19–22.

Brody IA, Wilkins RH. 1968. Brown Sequard syndrome. *Arch Neurol* 19(3): 347–348.

Cheshire WP, Santos CC, Massey W, Howard JF. 1996. Spinal cord infarction: Etiology and outcome. *Neurology* 47(2): 321–330.

Chiles BW, Cooper PR. 1996. Acute spinal injury. *New Engl J Med* 334(8): 514–520.

Mariani C, Cislaghi MG, Barbieri S, Filizzdo F, DiPalma F, Farina E, D'Aliberti G, Scarlato G. 1991. The natural history and results of surgery in 50 cases of syringomyelia. *J Neurol* 238(8): 433–438.

Ogilvy CS, Heros RC. 1993. Spinal cord compression. In Ropper AH (ed.), *Neurological and Neurosurgical Intensive Care*, 3rd Ed., Chapter 23. Raven, New York.

Schneider RC. 1955. The syndrome of acute anterior spinal cord injury. *J Neurosurg* 12: 95–122.

Schneider RC, Cherry G, Pantek H. 1954. The syndrome of acute central cervical spinal cord injury. *J Neurosurg* 11: 546–573.

Vernon JD, Chir B, Silver JR, Ohry A. 1982. Post-traumatic syringomyelia. *Paraplegia* 20(6): 339–364.

Anatomy of Bowel, Bladder, and Sexual Function

Madoff RD, Williams JG, Caushaj PF. 1992. Fecal incontinence. *New Engl J Med* 326(15): 1002–1007.

O'Donnell PD (ed.). 1997. *Urinary Incontinence*. Mosby, St. Louis, MO.

Rushton DN. 1996. Sexual and sphincter dysfunction. In Bradley WG, Daroff RB, Fenichel GM, Marsden CD (eds.), *Neurology in Clinical Practice: Principles of Diagnosis and Management*, 2nd Ed., Chapter 33. Butterworth-Heinemann, Boston.

Nitti V (ed.). 1998. *Practical Urodynamics*. Saunders, Philadelphia.

CHAPTER 8

Spinal Nerve Roots

ANATOMICAL AND CLINICAL REVIEW

Segmental Organization of the Nervous System

Nerve Roots in Relation to Vertebral Bones, Discs, and Ligaments

Dermatomes and Myotomes

KCC 8.1 Disorders of Nerve, Muscle, and Neuromuscular Junction

KCC 8.2 Back Pain

KCC 8.3 Radiculopathy

Simplification: Three Nerve Roots to Remember in the Arm

Simplification: Three Nerve Roots to Remember in the Leg

KCC 8.4 Cauda Equina Syndrome

KCC 8.5 Common Surgical Approaches to the Spine

CLINICAL CASES

8.1 Unilateral Neck Pain and Tingling Numbness in the Thumb and Index Finger

8.2 Unilateral Occipital and Neck Pain

8.3 Unilateral Shoulder Pain and Weakness

8.4 Blisters, Pain, and Weakness in the Left Arm

8.5 Unilateral Shoulder Pain and Numbness in the Index and Middle Fingers

8.6 Unilateral Neck Pain, Hand Weakness, and Numbness in the Ring and Little Fingers

8.7 Pain and Numbness in the Medial Arm

8.8 Low Back Pain Radiating to the Sole of the Foot and the Small Toe

8.9 Unilateral Thigh Weakness with Pain Radiating to the Anterior Shin

8.10 Low Back Pain Radiating to the Big Toe

8.11 Saddle Anesthesia with Loss of Sphincteric and Erectile Function

Additional Cases

BRIEF ANATOMICAL STUDY GUIDE

A 38-year-old man was thrown violently to the ground by an explosion while he was working on a road. While in the hospital recovering from burn injuries, he noticed mild back pain with a numb "pins and needles" sensation running down his left leg into the sole and pinky toe of his left foot. He was unable to stand on his toes with his left foot, and his left Achilles tendon reflex was absent. This patient's symptoms illustrate the kind of sensory and motor deficits associated with spinal nerve root damage. In this chapter, we will learn about the anatomical course of exiting spinal nerve roots, nerve root functions, and the clinical consequences of injury to these structures.

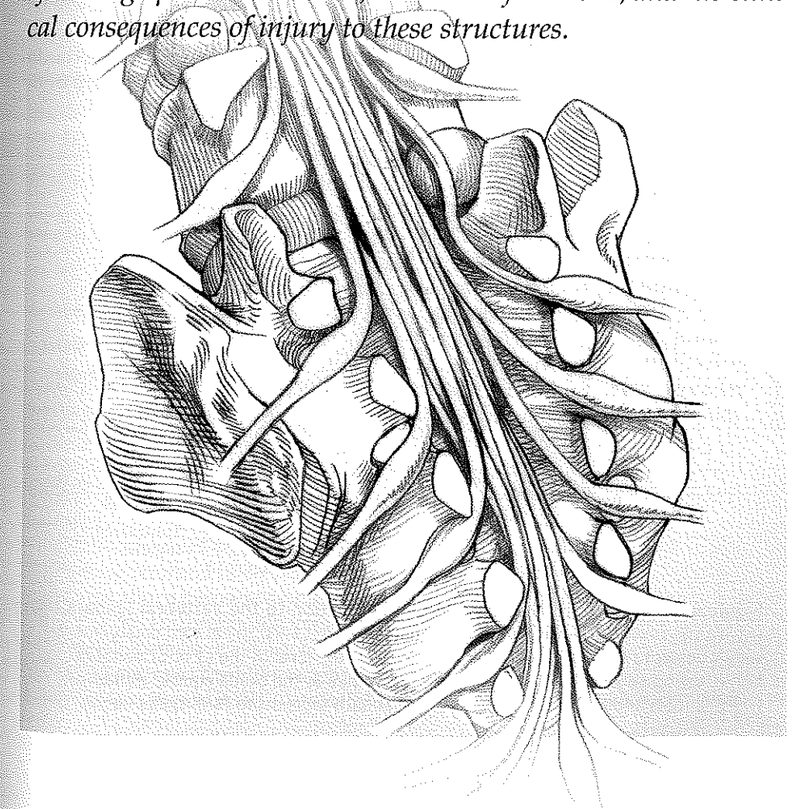

ANATOMICAL AND CLINICAL REVIEW

In the preceding two chapters we studied the three main motor and sensory pathways in the central nervous system (see Table 7.1). We will now follow these somatic sensory and somatic motor pathways into the peripheral nervous system (see Figure 2.1) to explore the anatomy and clinical disorders of the peripheral nerves. In this chapter, we will concentrate on the anatomy of spinal nerve roots and their relation to the vertebral structures, regions of innervation, and common clinical disorders. Peripheral autonomic functions were already discussed in Chapter 6. In Chapter 9, we will follow the nerves further into the periphery, and we will discuss the brachial and lumbosacral plexuses and peripheral nerve branches.

Segmental Organization of the Nervous System

Like their invertebrate ancestors, humans retain some degree of segmental organization, especially in the spinal cord. There are **8 cervical (C1–C8), 12 thoracic (T1–T12), 5 lumbar (L1–L5), 5 sacral (S1–S5), and 1 coccygeal (Co1) spinal segments** (Figure 8.1). During development, the bones of the spine continue to grow after the spinal cord has reached its full size. Therefore, in adults the spinal cord normally ends with the **conus medullaris** at the level of the **L1 or L2 vertebral bones.** The nerve roots (see Figure 8.1; see also Figure 6.3) travel downward to reach their exit points at the appropriate level. Below the L1 or L2 vertebral bones, the spinal canal contains nerve roots with no spinal cord, forming the **cauda equina,** meaning "horse's tail" (see Figures 8.1A, 8.3C). The conus medullaris tapers into the **filum terminale,** a thin strand of connective tissue running in the center of the cauda equina. The roots of the cauda equina are organized such that the most centrally located roots are from the most caudal segments of the spinal cord (see Figure 8.3C).

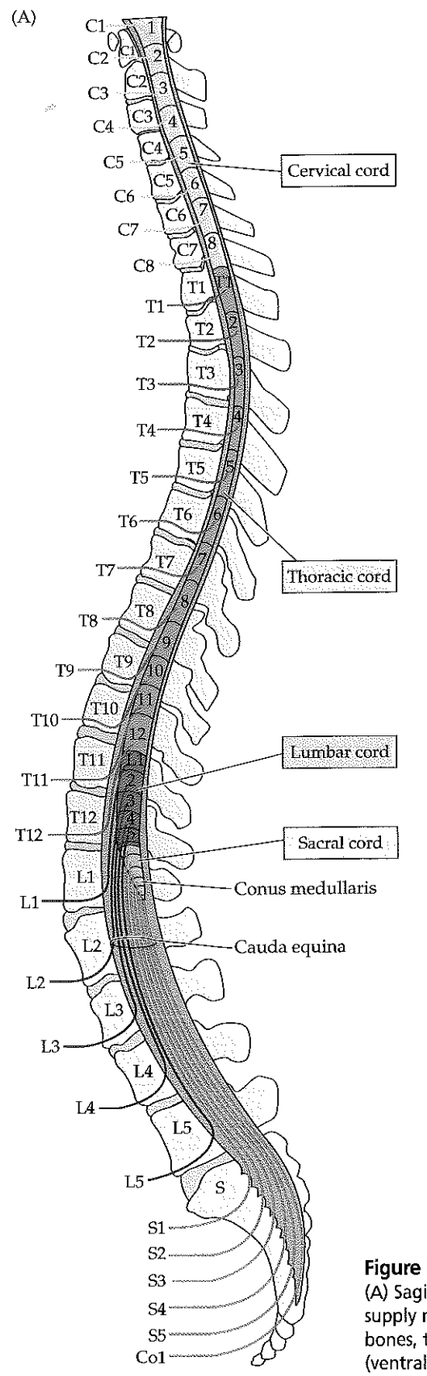

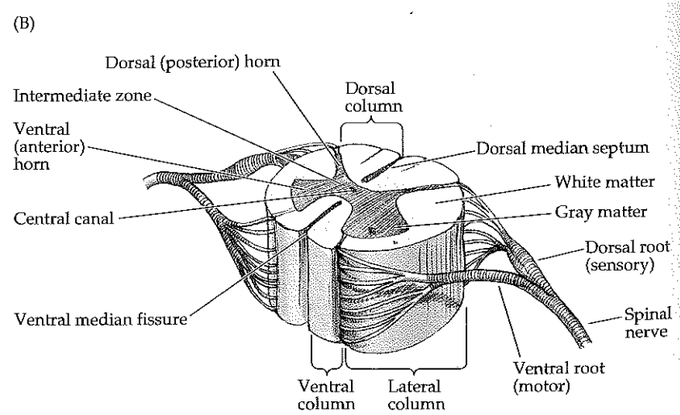

Figure 8.1 Spinal Cord and Nerve Roots in Relation to the Vertebral Spinal Canal (A) Sagittal view. The cervical (C5–T1) and lumbosacral (L1–S3) spinal cord enlargements supply nerves to the arms and legs, respectively. At the level of the L1 or L2 vertebral bones, the spinal cord ends, and nerve roots continue as the cauda equina. (B) Motor (ventral) roots and sensory (dorsal) roots join at each segment to form spinal nerves.

Left and right sensory and motor **nerve roots** arise from each segment of the spinal cord (see Figure 8.1B) except for the C1 and Co1 segments, which have no sensory roots. As discussed in Chapter 6, the **cervical enlargement** (C5–T1) gives rise to the nerve roots for the arms, and the **lumbosacral enlargement** (L1–S3) gives rise to the nerve roots for the legs (see Figure 8.1A). A short distance from the spinal cord, and before leaving the spinal canal, the sensory and motor nerve roots fuse to form a single **mixed spinal nerve** for each segment (see Figure 8.1B). The spinal nerves then further fuse and intermingle peripherally to form plexuses and nerve branches, as will be discussed in Chapter 9. In this chapter we will focus on the innervation provided by single spinal segments, and the distinct clinical disorders associated with damage to individual spinal nerve roots.

Nerve Roots in Relation to Vertebral Bones, Discs, and Ligaments

The vertebral bones function both as the central mechanical support for the body and as protection for the spinal cord. Each vertebral bone has a sturdy cylindrical **vertebral body** located anteriorly (Figure 8.2A,B). The vertebral bodies are separated from each other by connective tissue **intervertebral discs** consisting of a central **nucleus pulposus** surrounded by a capsule called the **annulus fibrosus** (see Figure 8.2C). Posteriorly, the neural elements are surrounded by an arch of bone formed by the **pedicles, transverse processes, laminae,** and **spinous processes** (see Figure 8.2B). The **superior and inferior articular processes** or **facet joints** form additional points of mechanical contact between adjacent vertebrae (see Figure 8.2A,B).

The spinal cord runs through the **spinal canal (vertebral foramen)** and is surrounded by pia, arachnoid, and dura mater (see Figure 8.2). As the dura exits the skull at the foramen magnum, the inner layer continues and the outer layer becomes indistinguishable from periosteum (see Figure 5.10). Unlike in the cranium, there is a layer of **epidural fat** between the dura and the periosteum in the spinal canal (see Figure 8.2C,D), which is a useful landmark on MRI scans. In addition, there is a valveless meshwork of epidural veins called **Batson's plexus** that is thought to play a role in the spread of metastatic cancers and infections in the epidural space. The elastic **ligamentum flavum** is particularly prominent in cervical and lumbar regions and can sometimes become hypertrophied and contribute to spinal cord or nerve root compression.

The nerve roots exit the spinal canal via the **neural (intervertebral) foramina** (see Figures 8.2A,D, 8.3). **Disc herniations** (see KCC 8.3) are most common at the cervical and lumbosacral levels. An understanding of the anatomy of the nerve roots and discs should make clear the following important rule of thumb: **For both cervical and lumbosacral disc herniations, the nerve root involved usually corresponds to the lower of the adjacent two vertebrae.** For example, a C5–C6 disc herniation usually produces a C6 radiculopathy, an L5–S1 disc usually produces an S1 radiculopathy, and so on. The explanation for this rule is different for cervical versus lumbosacral discs, as we will now discuss.

MNEMONIC

Thoracic, lumbar, and sacral nerve roots exit below the correspondingly numbered vertebral bone (see Figure 8.1). Cervical nerve roots, on the other hand, exit above the correspondingly numbered vertebral bone, except for C8, which has no corresponding vertebral bone and exits between C7 and T1. Cervical nerve roots have a fairly horizontal course as they emerge from the dural or **thecal sac** near the intervertebral disc and exit through the intervertebral foramen (see Figure 8.3B). Cervical discs are usually constrained by the **pos-**

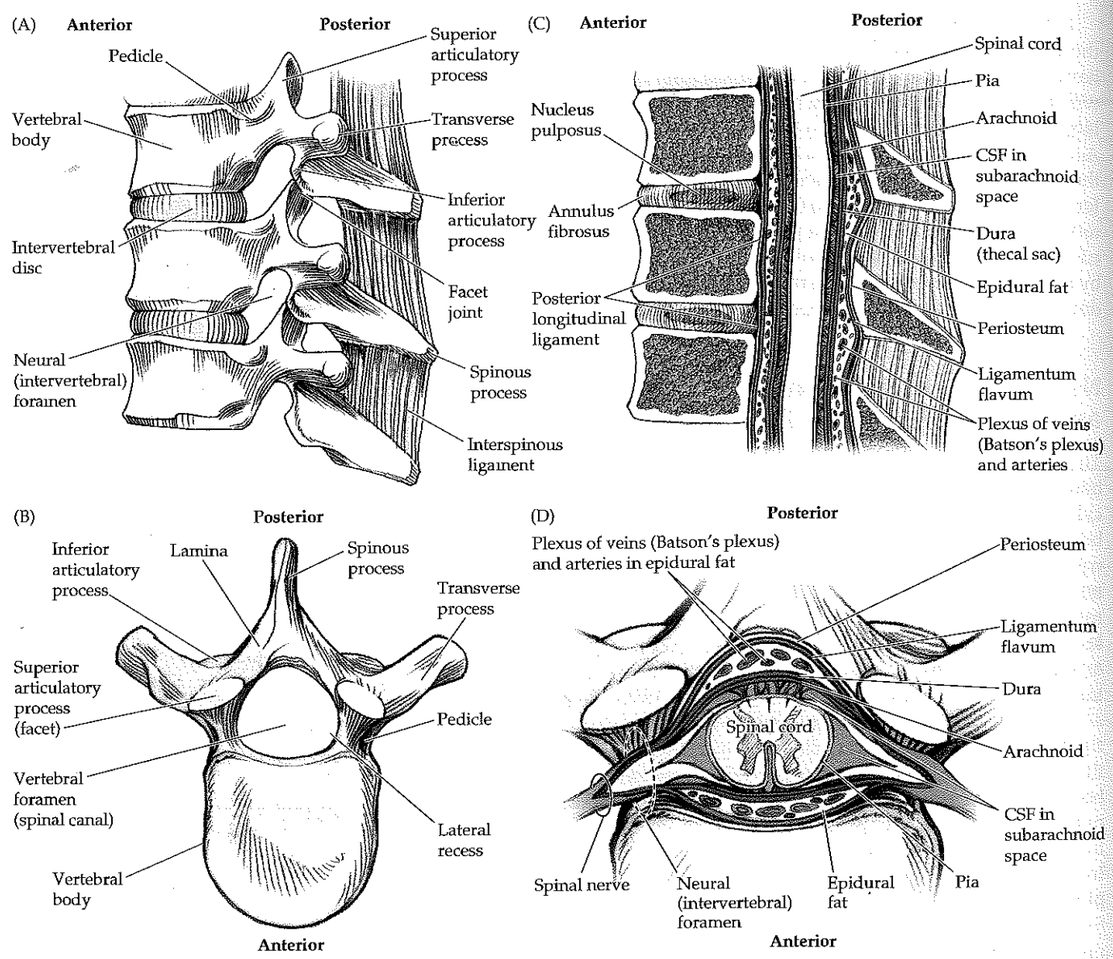

Figure 8.2 Vertebral Bones, Meninges, and Other Tissues
(A) Lateral view of vertebral spinal bones. (B) View of a vertebral bone from above. (C) Sagittal section of spinal column including vertebral bones, discs, ligaments, spinal cord, meninges, epidural fat, and blood vessels. (D) Axial section of spinal column and its contents.

terior longitudinal ligament to herniate laterally toward the nerve root, rather than centrally toward the spinal cord. Thus, in the cervical cord the nerve root involved usually corresponds to the lower vertebral bone of the disc space (see Figure 8.3A).

Unlike cervical nerve roots, lumbar and sacral nerve roots must travel downward several levels before they exit the spinal canal (see Figure 8.1). In addition, the intervertebral foramina of the lumbosacral spine are such that the nerve roots exit some distance *above* the intervertebral discs (Figures 8.2, 8.3B). As they are about to exit, the nerve roots move into the **lateral recess** of the spinal canal (see Figure 8.2B), and it is at this point that they are closest to the disc (see Figure 8.3B). Thus, **posterolateral disc herniations** in the lumbosacral spine usually impinge on nerve roots on their way to exit beneath the next lower vertebral bone, which corresponds to the number of the nerve root involved (Figure 8.3B,C).

Occasionally, a **far lateral disc herniation** will reach the nerve root exiting at that level, resulting in impingement of the next higher nerve root. For example, a far lateral L5–S1 disc herniation can cause an L5 radiculopathy (see

Figure 8.3 Relation of Cervical and Lumbosacral Nerve Roots to Intervertebral Discs (A) Cervical disc herniation usually compresses the nerve root exiting at that level. This corresponds to the number of the lower vertebral bone at that interspace. (B) Lumbosacral disc herniation usually spares the nerve root exiting at that level, and compresses the nerve root exiting at the next level down. However, this again corresponds to the number of the lower vertebral bone at the level of the herniation. (C) Far lateral lumbosacral disc herniation affects the nerve root exiting at that level, and central lumbosacral disc herniation can cause cauda equina syndrome (see KCC 8.4).

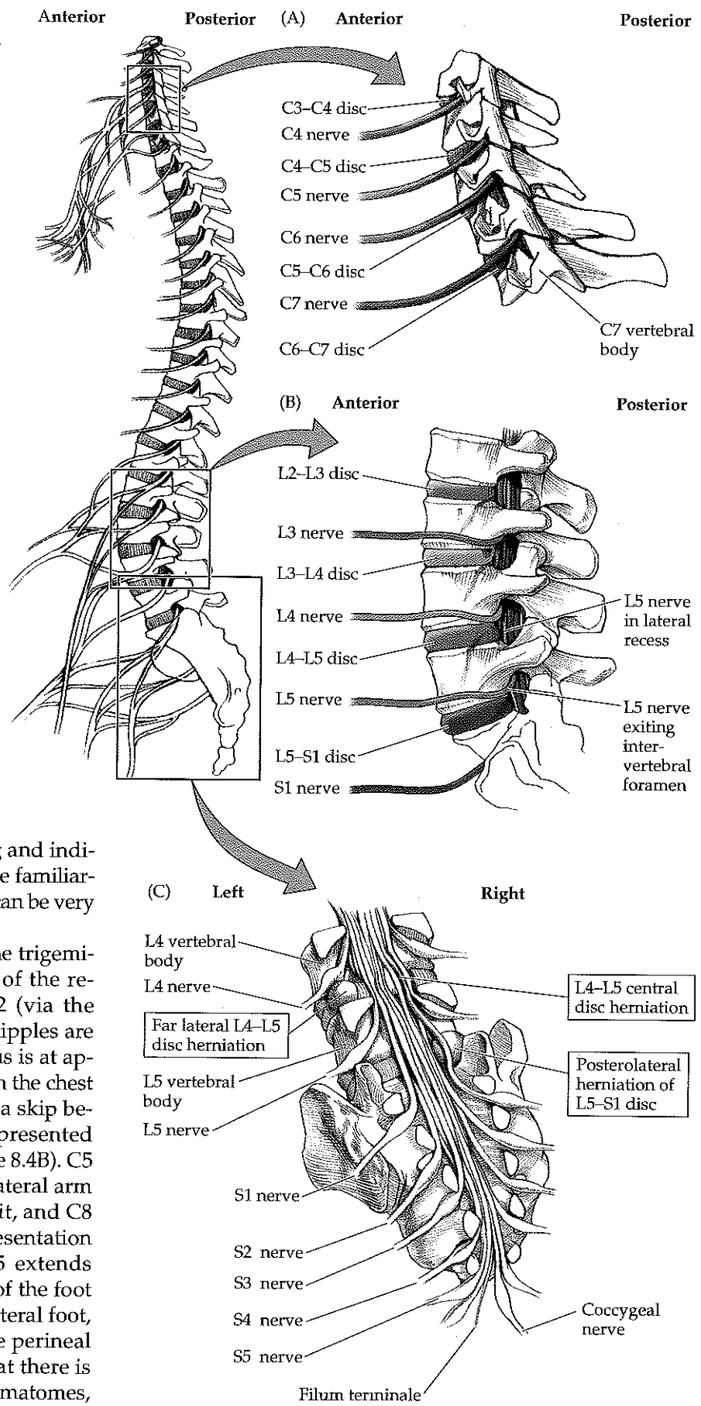

Figure 8.3C). In addition, a **central disc herniation** at the level of the cauda equina can impinge on nerve roots lower than the level of herniation, or it can compress the spinal cord if it occurs above L1.

Dermatomes and Myotomes

The sensory region of skin innervated by a nerve root is called a **dermatome** (Figure 8.4). Interestingly, dermatome maps vary somewhat from one text to the next. This variation is likely due to differences in both the methods of testing and individual patients studied. Nevertheless, some familiarity with the usual locations of dermatomes can be very helpful clinically for localizing lesions.

Sensation for the face is provided by the trigeminal nerve (see Figure 12.7), while most of the remainder of the head is supplied by C2 (via the greater and lesser occipital nerves). The nipples are usually at the T4 level, while the umbilicus is at approximately T10. When testing sensation on the chest or back, remember that there is normally a skip between C4 and T2, with C5 through T1 represented mainly on the upper extremities (see Figure 8.4B). C5 is represented in the shoulder, C6 in the lateral arm and first two digits, C7 in the middle digit, and C8 in the fourth and fifth digits. The L4 representation extends over the anteromedial shin, L5 extends down the anterolateral shin and dorsum of the foot to the big toe, and S1 is in the small toe, lateral foot, sole, and calf. S2, S3, and S4 innervate the perineal area in a saddlelike distribution. Note that there is considerable overlap between adjacent dermatomes,

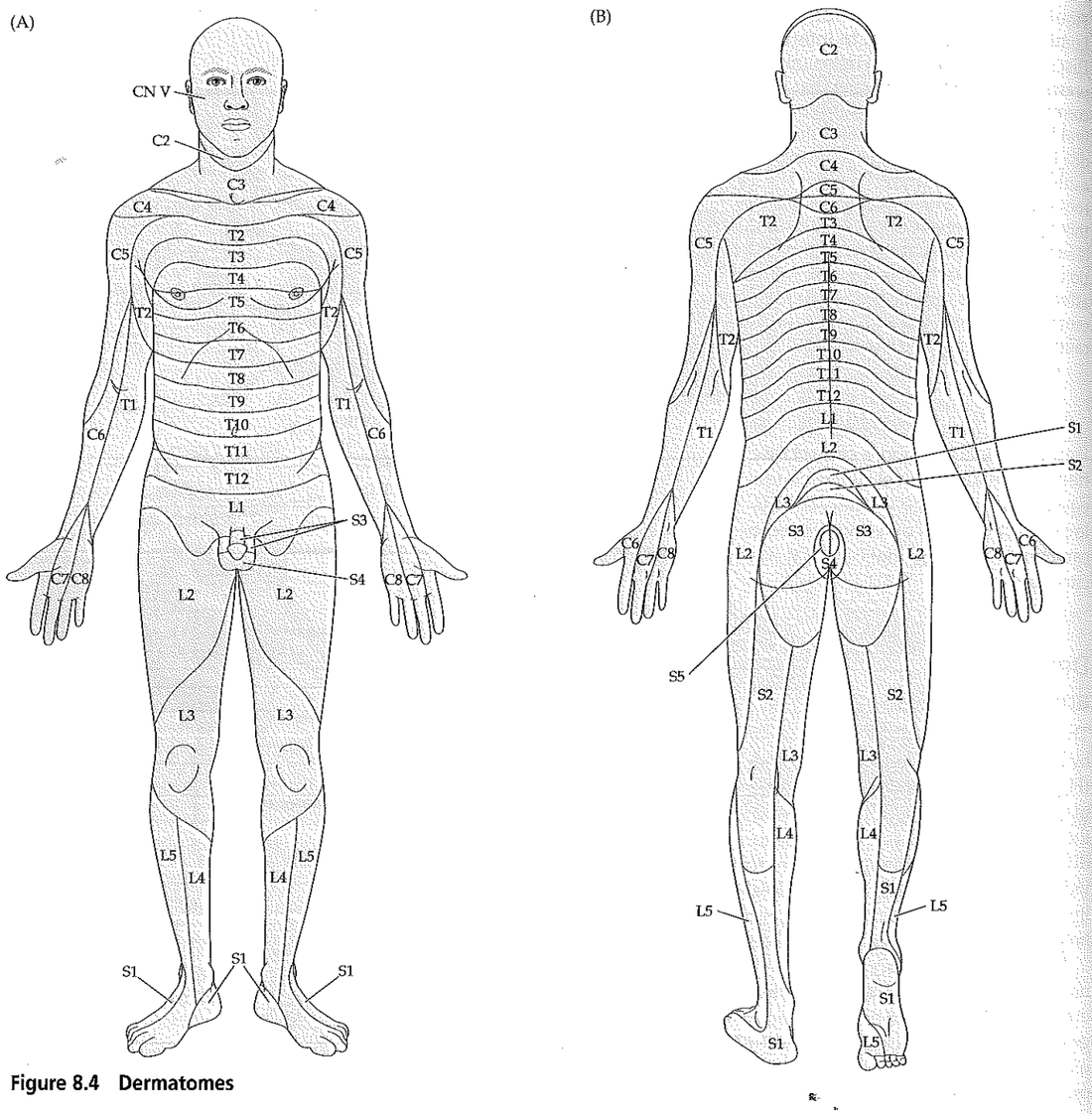

Figure 8.4 Dermatomes

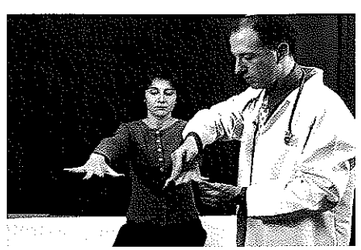

Upper extremity strength

so lesions of a single nerve root ordinarily cause a decrease but not a complete loss of sensation in a given dermatome. There may be less overlap for smaller fibers, so pinprick is a more sensitive test for dermatomal sensory loss than touch.

The muscles innervated by a single nerve root constitute a **myotome.** The segmental innervation of the muscles is summarized in Table 8.1. This table also includes a summary of nerve roots supplying each peripheral nerve, and the main functions of each muscle (see Chapter 9 for further details). Strength testing and reflexes for individual muscles, nerves, and nerve roots is discussed in Chapter 3 (see Tables 3.4–3.7) and is demonstrated on neuroexam.com Videos 54–60.

TABLE 8.1 Summary of Peripheral Nerves, Muscles, and Nerve Roots in the Upper and Lower Extremities

NERVE	MUSCLE(S)	FUNCTION OF THE MUSCLE(S)	NERVE ROOTS[a]
Spinal accessory nerve	Trapezius	Elevates shoulder/arm and fixes scapula	CN XI, C3, C4
Phrenic nerve	Diaphragm	Inspiration	C3, C4, C5
Dorsal scapular nerve	Rhomboids	Draw scapula up and in	C4, **C5**, C6
	Levator scapulae	Elevates scapula	C3, C4, C5
Long (Bell's) thoracic nerve	Serratus anterior	Fixes scapula on arm raise	C5, C6, C7
Lateral pectoral nerve	Pectoralis major (clavicular head)	Pulls shoulder forward	**C5**, C6
Medial pectoral nerve	Pectoralis major (sternal head)	Adducts and medially rotates arm	C6, **C7**, C8, T1
	Pectoralis minor	Depresses scapula and pulls shoulder forward	C6, C7, C8
Suprascapular nerve	Supraspinatus	Abducts humerus from 0 to 15°	**C5**, C6
	Infraspinatus	Externally rotates humerus	**C5**, C6
Subscapular nerve	Subscapularis	Internally rotates humerus	C5, C6
	Teres major	Adducts and internally rotates humerus	C5, C6, C7
Thoracodorsal nerve	Lattisimus dorsi	Adducts and internally rotates humerus	C6, **C7**, C8
Axillary nerve	Teres minor	Adducts and externally rotates humerus	C5, C6
	Deltoid	Abducts humerus beyond 15°	**C5**, C6
Musculocutaneous nerve	Biceps brachii	Flexes and supinates arm and forearm	C5, C6
	Brachialis	Flexes forearm	C5, C6
	Coracobrachialis	Flexes and adducts arm	C6, **C7**
Radial nerve	Triceps	Extends forearm	C6, **C7**, C8
	Brachioradialis	Flexes forearm	C5, **C6**
	Extensor carpi radialis (longus and brevis)	Extend wrist, abduct hand	C5, **C6**
Posterior interosseus nerve (branch of radial nerve)	Supinator	Supinates forearm	C6, C7
	Extensor carpi ulnaris	Extends wrist, adducts hand	**C7**, C8
	Extensor digitorum communis	Extends fingers (test at metacarpophalangeal joints)	**C7**, C8
	Extensor digiti quinti	Extends little finger	**C7**, C8
	Abductor pollicis longus	Abducts thumb in plane of palm	**C7**, C8
	Extensor pollicis (longus and brevis)	Extends thumb	**C7**, C8
	Extensor indicis proprius	Extends index finger	**C7**, C8
Median nerve	Pronator teres	Pronates and flexes forearm	C6, C7
	Flexor carpi radialis	Flexes wrist, abducts hand	C6, C7
	Palmaris longus	Flexes wrist	C7, **C8**, T1
	Flexor digitorum superficialis	Flexes metacarpophalangeal and joints proximal interphalangeal	C7, **C8**, T1
Muscles affected in carpal tunnel syndrome	Lumbricals (I, II)	For second and third digits, flex metacarpophalangeal joints, extend other joints	C8, **T1**
	Opponens pollicis	Flexes, opposes thumb	C8, **T1**
	Abductor pollicis brevis	Abducts thumb perpendicular to plane of palm	C8, **T1**
	Flexor pollicis brevis (superficial head)	Flexes first phalanx of thumb	C8, **T1**

Continued

TABLE 8.1 (*continued*)

NERVE		MUSCLE(S)	FUNCTION OF THE MUSCLE(S)	NERVE ROOTS[a]
Anterior interosseous nerve (branch of median nerve)		Flexor digitorum profundus (digits 2, 3)	Flexes second and third fingers (best tested in distal phalanges)	C7, **C8**
		Flexor pollicis longus	Flexes distal phalanx of thumb	C7, **C8**
		Pronator quadratus	Pronates forearm	C7, **C8**, **T1**
Ulnar nerve		Flexor carpi ulnaris	Flexes wrist, adducts hand	C7, **C8**, T1
		Flexor digitorum profundus (digits 4, 5)	Flexes fourth and fifth fingers (best tested in distal phalanges)	C7, **C8**
		Lumbricals (III, IV)	For fourth and fifth digits, flex metacarpo-phalangeal joints, extend other joints	C8, **T1**
		Palmar interossei	Adduct fingers, flex metacarpo-phalangeal joints, extend other joints	C8, **T1**
		Dorsal interossei	Abduct fingers, flex metacarpo-phalangeal joints, extend other joints	C8, **T1**
		Flexor pollicis brevis (deep head)	Flexes and adducts thumb	C8, **T1**
		Adductor pollicis	Adducts thumb	C8, **T1**
	Muscles of hypothenar eminence	Opponens digiti minimi	Internally rotates fifth finger	C8, **T1**
		Abductor digiti minimi	Abducts fifth finger	C8, **T1**
		Flexor digiti minimi	Flexes fifth finger at metacarpo-phalangeal joint	C8, **T1**
Obturator nerve		Obturator externus	Adducts and outwardly rotates leg	**L2**, **L3**, L4
		Adductor longus	Adducts thigh	**L2**, **L3**, L4
		Adductor magnus	Adducts thigh	**L2**, **L3**, L4
		Adductor brevis	Adducts thigh	**L2**, **L3**, L4
		Gracilis	Adducts thigh	**L2**, **L3**, L4
Femoral nerve	*Illiopsoas muscle*	Iliacus	Flexes leg at hip	L1, L2, **L3**
		Psoas	Flexes leg at hip	L2, **L3**, L4
	Quadriceps femoris	Rectus femoris	Extends leg at knee, flexes hip	L2, **L3**, **L4**
		Vastus lateralis	Extends leg at knee	L2, **L3**, **L4**
		Vastus intermedius	Extends leg at knee	L2, **L3**, **L4**
		Vastus medialis	Extends leg at knee	L2, **L3**, **L4**
		Pectineus	Adducts thigh	**L2**, **L3**, L4
		Sartorius	Inwardly rotates leg, flexes hip and knee	**L2**, **L3**, L4
Sciatic nerve		Adductor magnus	Adducts thigh	L4, L5, S1
	Hamstring muscles	Semitendinosus	Flexes knee, medially rotates thigh, extends hip	L5, **S1**, S2
		Semimembranosus	Flexes knee, medially rotates thigh, extends hip	L5, **S1**, S2
		Biceps femoris	Flexes knee, extends hip	L5, **S1**, S2
Tibial nerve (branch of sciatic nerve)	*Triceps surae muscles*	Gastrocnemius	Plantar flexes foot	S1, S2
		Soleus	Plantar flexes foot	S1, S2
Popliteus		Plantar flexes foot	L4, L5, S1	
		Tibialis posterior	Plantar flexes and inverts foot	L4, L5
		Plantaris	Spreads, brings together, flexes proximal phalanges	L4, L5, S1

TABLE 8.1 (*continued*)

NERVE	MUSCLE(S)	FUNCTION OF THE MUSCLE(S)	NERVE ROOTS[a]
	Flexor digitorum longus	Flexes distal phalanges, aids plantar flexion	L5, **S1**, **S2**
	Flexor hallucis longus	Flexes great toes, aids plantar flexion	L5, **S1**, **S2**
	Small foot muscles	Cup sole	S1, S2
Superficial peroneal nerve (branch of sciatic nerve)	Peroneus longus	Plantar flexes and everts foot	L5, S1
	Peroneus brevis	Plantar flexes and everts foot	L5, S1
Deep peroneal nerve (branch of sciatic nerve)	Tibialis anterior	Dorsiflexes and inverts foot	L4, L5
	Extensor digitorum longus	Extends phalanges, dorsiflexes foot	**L5**, S1
	Extensor hallucis longus	Extends great toe, aids dorsiflexion	**L5**, S1
	Peroneus tertius	Plantar flexes foot in pronation	L4, **L5**, S1
	Extensor digitorum brevis	Extends toes	L5, S1
Superior gluteal nerve	Gluteus medius	Abducts and medially rotates thigh	**L4**, **L5**, S1
	Gluteus minimus	Abducts and medially rotates thigh	**L4**, **L5**, S1
	Tensor fasciae latae	Abducts and medially rotates thigh	**L4**, **L5**, S1
Inferior gluteal nerve	Gluteus maximus	Extends, abducts, and laterally rotates thigh, extends lower trunk	**L5**, **S1**, S2

Source: Modified and reproduced with permission from Devinsky, O and Feldmann, E. 1988. *Examination of the Cranial and Peripheral Nerves.* Churchill Livingstone, New York.

[a]Boldface indicates the most important nerve roots, where applicable.

KEY CLINICAL CONCEPT

DISORDERS OF NERVE, MUSCLE, AND NEUROMUSCULAR JUNCTION

8.1 A variety of disorders can affect the peripheral nervous system at multiple levels. This text focuses on neuroanatomical localization, so in this chapter and in Chapter 9 we concentrate mainly on localized disorders of the spinal nerve roots, nerve plexuses, or individual nerve branches. Here, we will place these disorders in the wider context of peripheral nervous system disease, so that a more complete differential diagnosis can be formulated.

Disorders of the peripheral nervous system can often be distinguished from central nervous system dysfunction by the anatomical pattern of sensory or motor deficits (see KCC 6.3, 7.3; Table 8.1). In addition, presence of lower motor neuron signs (see KCC 6.1) such as atrophy, fasciculations, or hyporeflexia suggests peripheral nervous system dysfunction, as do parasthesias in a peripheral nerve distribution (see KCC 7.1). When the location of lesions in the central versus peripheral nervous system remains uncertain based on the history and physical examination, diagnostic tests such as neuroimaging studies (Chapter 4), blood tests, CSF analysis, and electrodiagnostic studies (see KCC 9.2) can be helpful. Disorders of the peripheral nervous system can be produced by a large number of mechanical, toxic, metabolic, infectious, autoimmune, inflammatory, degenerative, and congenital causes that are beyond the scope of this text (see references for additional details). We will now briefly discuss several common disorders of nerve, neuromuscular junction, and muscle.

Common Neuropathies

Neuropathy is a general term meaning nerve disorder. The site of pathology can be in the axons, myelin, or both, and can affect large-diameter fibers, small-diameter fibers, or both. Usually, neuropathies affect both sensory and motor fibers in the nerve, although one or the other may be preferentially involved. Damage can be reversible or permanent. The location of neuropathy

can be focal **(mononeuropathy),** multifocal **(mononeuropathy multiplex),** or generalized **(polyneuropathy).** Neuropathy affecting the spinal nerve roots is called **radiculopathy,** which we will discuss in greater detail in KCC 8.3. Motor neuron disorders (see KCC 6.7) can also cause lower motor neuron–type weakness, but do not cause sensory involvement as is usually seen in neuropathies.

Important causes of neuropathy include diabetes; mechanical causes; infectious disorders such as Lyme disease, HIV, CMV, varicella-zoster virus, or hepatitis B (see KCC 5.9); toxins; malnutrition; and immune disorders such as Guillain–Barré syndrome, among others.

Diabetic neuropathy is produced by a number of mechanisms, including compromise of the microvascular blood supply of the peripheral nerves. The most common pattern of diabetic neuropathy is **distal symmetrical polyneuropathy,** which results in a characteristic **glove and stocking** pattern of sensory loss (see Figure 7.9D). Mononeuropathies are also relatively common in diabetes. Acute diabetic mononeuropathy can affect any cranial or spinal nerve, but is most common in CN III and the femoral and sciatic nerves. Onset is usually fairly sudden, and sensorimotor deficits in the nerve distribution may be accompanied by painful paresthesias. There is often partial or complete recovery over the course of weeks to months after onset.

Mechanical causes of nerve injury include **extrinsic compression, traction, laceration,** or **entrapment** by intrinsic structures such as bone or connective tissue. Mild mechanical disruption of a nerve causes **neurapraxia** in which there is temporary impairment of nerve conduction, which usually resolves within hours to weeks. More severe injury can interrupt the axons, leading to **Wallerian degeneration** (degeneration of axons and myelin) distal to the site of injury. As long as the structural elements of the nerve are intact, **axonal regeneration** may occur at a rate of about 1 mm/day (3 cm/month). Occasional long-term complications include incomplete or aberrant reinnervation and the **complex regional pain syndrome causalgia** (also called reflex sympathetic dystrophy, or sympathetically mediated pain). In some situations, when peripheral nerves are severed or otherwise disrupted they can be reanastomosed surgically. In addition, some entrapment syndromes may be amenable to surgical decompression. Painful paresthesias associated with neuropathies of all causes are often treated with medications such as tricyclic antidepressants and anticonvulsants. Common mechanical neuropathies are discussed further in KCC 8.3 and 9.1.

Guillain–Barré syndrome, also known as **acute inflammatory demyelinating polyneuropathy (AIDP),** is an important form of neuropathy caused by immune-mediated demyelination of peripheral nerves. Onset typically occurs 1 to 2 weeks following a viral illness, *Campylobacter jejuni* enteritis, HIV infection, or other infections. Presentation is with progressive weakness, **areflexia,** and tingling paresthesias of the hands and feet with motor involvement typically much more severe than sensory involvement. Symptoms usually reach their worst point 1 to 3 weeks after onset; recovery occurs over many months. Diagnosis is based on typical clinical presentation, CSF demonstrating **elevated protein** without a significantly elevated white blood cell count, and EMG/nerve conduction studies compatible with **demyelination** (see KCC 9.2). Recovery occurs more quickly when patients are treated with plasmapheresis or intravenous immunoglobulin therapy. In severe cases, patients require intubation and mechanical ventilation. Autonomic dysfunction can be prominent in some cases, requiring careful monitoring. With good supportive care and immune therapy, the majority of patients enjoy complete or near-complete recovery, although about 20% of patients have some residual weakness 1 year after onset.

Common Disorders of the Neuromuscular Junction

Impaired neuromuscular transmission can lead to motor weakness without sensory deficits. Causes include myasthenia gravis, neuromuscular blocking agents and other drugs, Lambert–Eaton myasthenic syndrome (usually paraneoplastic), and botulism.

Myasthenia gravis is an immune-mediated disorder in which there are circulating antibodies against the postsynaptic nicotinic acetylcholine receptors at the neuromuscular junction of skeletal muscle cells. The disorder can sometimes be accompanied by other autoimmune phenomena such as hypothyroidism, lupus, rheumatoid arthritis, and vitiligo. Myasthenia gravis has a bimodal age-related onset, with onset in the second or third decades more common in women and onset in the sixth or seventh decades more common in men. The prevalence is 50 to 125 cases per million. Clinical features include generalized symmetrical weakness, especially of proximal limb muscles, neck muscles, the diaphragm, and eye muscles. Involvement of bulbar muscles can cause facial weakness, a nasal-sounding voice, and dysphagia (see KCC 12.8). Reflexes and sensory exam are normal. Characteristically, **weakness becomes more severe with repeated use of a muscle,** or during the course of the day. About 15% of cases have weakness involving only the extraocular muscles and eyelids, a condition called **ocular myasthenia.**

Diagnosis of myasthenia gravis is based on clinical features, and several diagnostic tests, including the Tensilon test, repetitive nerve stimulation, measurement of anti-acetylcholine antibodies, single fiber EMG, and chest CT or MRI. In the **Tensilon test,** a short-acting acetylcholinesterase inhibitor (edrophonium) is administered while observing clinical effects on involved muscles. This test should be performed where cardiac monitoring is available, and 1 to 2 mg of atropine should be administered first to prevent cardiac bradyarrhythmias. The patient is then given an intravenous test dose of 1 to 2 mg of edrophonium, an acetylcholinesterase inhibitor with onset of action within about 30 seconds and duration of about 5 minutes. If there are no adverse effects, the patient is then given 8 mg of edrophonium while carefully testing one or several weak muscles for transient improvement. In equivocal cases, intermediate-acting acetylcholinesterase inhibitors such as neostigmine can be helpful. Compound motor action potential measurement (see KCC 9.2) with **repetitive nerve stimulation at a rate of 3 per second** often produces a characteristic decrement in amplitude in myasthenia and is considered positive if there is a decrement greater than 10%. Single-fiber EMG is more sensitive (about 90%), but is not specific for myasthenia.

Anti-acetylcholine receptor antibodies are positive in about 85% of cases, but in only about 50% of cases of ocular myasthenia. About 12% of patients with myasthenia have **thymomas,** a tumor of the thymus gland, and many others have thymic hyperplasia, so CT or MRI of the chest should be performed. In addition, testing for associated conditions such as thyroid disease and other immune disorders is appropriate.

Treatment of myasthenia is with anticholinesterase medications and immune therapy. **Pyridostigmine (Mestinon)** is a long-acting cholinesterase inhibitor, with onset of action beginning about 30 minutes after oral administration, and duration of about 2 hours. Patients' doses are individually titrated, but should not ordinarily exceed about 120 mg every 3 hours, since excess anticholinesterase can actually worsen weakness. Most patients in the age range of adolescence to 60 years are treated surgically with **thymectomy** (whether a thymoma is present or not), as this usually leads to improvement by unclear mechanisms, likely involving a reduced autoimmune response. Use of thymectomy outside this age range, or in patients with ocular myasthenia is more controversial, but has been used in some cases as well. Thymectomy should be

TABLE 8.4 Common Causes of Radiculopathy

Disc herniation
Osteophytes
Spinal stenosis
Trauma
Diabetes
Epidural abscess
Epidural metastases
Meningeal carcinomatosis
Nerve sheath tumors (schwannomas and neurofibromas)
Guillain–Barré syndrome
Herpes zoster (shingles)
Lyme disease
Cytomegalovirus
Idiopathic neuritis

pain, as well as sensorimotor symptoms in a radicular distribution. As the spine degenerates over time, **osteophytes** (see Table 8.3) form that may contribute, together with disc material, to narrowing of the intervertebral foramina.

The **straight-leg raising test** can be helpful in the diagnosis of mechanical nerve root compression in the lumbosacral region (Figure 8.5A). In this test the patient lies supine, and the examiner slowly elevates the patient's leg at an increasing angle to the table while keeping the leg straight at the knee joint. This provides traction on the nerve roots, and the test is considered positive if it reproduces the patient's typical radicular pain and paresthesias. A response to less than 10° or more than 60° of straight-leg raising is probably not caused by root compression. In the **crossed straight-leg raising test,** elevating the asymptomatic leg causes typical symptoms in the symptomatic leg. The crossed straight-leg raising test has a specificity of over 90% for lumbosacral nerve root compression. Radicular symptoms may also be increased by the Valsalva maneuver (e.g., coughing, sneezing, straining). In cervical radiculopathy, radicular symptoms may be increased by flexing or turning of the head toward the affected side, likely because of increased narrowing of the intervertebral foramina by these movements. Pain on **percussion of the spine** (Figure 8.5B) may indicate metastatic disease, epidural abscess, osteomyelitis, or other disorders of the vertebral bones, although this sign is often absent in these conditions.

Back pain that is persistent, progressively worsens, or occurs in an older individual, in a patient with prior history of neoplastic disease, or where there is a possibility of epidural abscess, should always be evaluated with a neuroimaging study. An MRI of the spine is usually the test of choice (see Chapter 4). It is important, however, to carefully interpret the MRI in the context of the history and physical examination, since incidental disc bulges and other degenerative changes of the spine are common findings even in individuals without symptoms. In some cases, CT-myelography (Chapter 4) can help define abnormalities that are not well visualized on MRI. When diagnostic uncertainty remains, EMG and nerve conduction studies (see KCC 9.2) may be helpful.

Other causes of radiculopathy are listed in Table 8.4. **Spinal stenosis,** meaning "narrowing of the spinal canal," can arise congenitally, or gradually

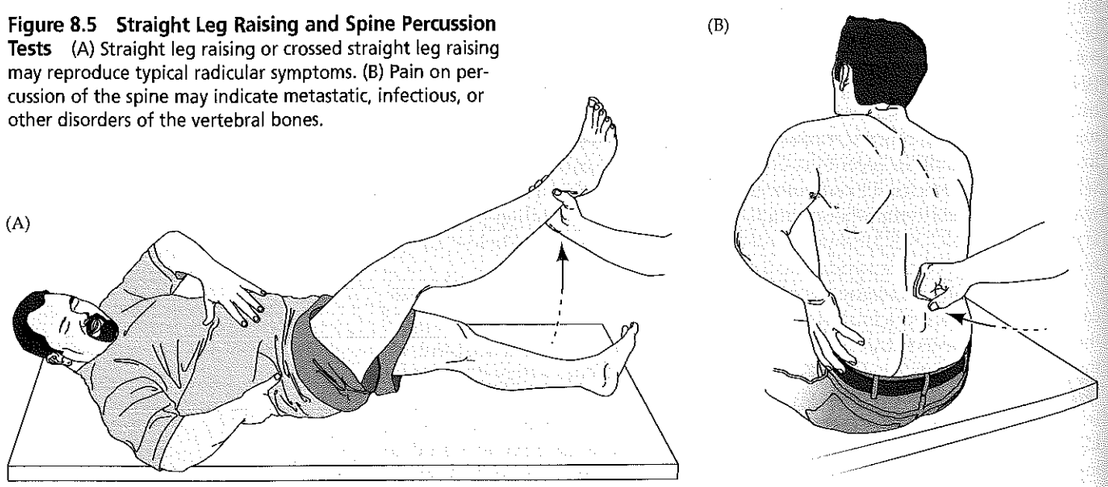

Figure 8.5 Straight Leg Raising and Spine Percussion Tests (A) Straight leg raising or crossed straight leg raising may reproduce typical radicular symptoms. (B) Pain on percussion of the spine may indicate metastatic, infectious, or other disorders of the vertebral bones.

as the result of degenerative processes, or by a combination of both factors. **Lumbar stenosis** may result in **neurogenic claudication,** in which bilateral leg pains and weakness occur with ambulation. **Cervical stenosis** can cause a mixture of radicular and long tract signs. Trauma produces radiculopathy through root compression, traction, or **avulsion** of nerve roots off the spinal cord. Diabetic neuropathy can occasionally involve nerve roots, particularly at thoracic levels, producing abdominal pain. **Epidural metastases** most commonly occur in the vertebral bodies, but they can extend laterally to compress nerve roots. Spread of cancer cells such as adenocarcinoma, lymphoma, medulloblastoma, and glioblastoma within the cerebrospinal fluid can involve the nerve roots.

Many causes of radiculopathy are similar to those causing neuropathy in general (see KCC 8.1) but may have an increased tendency to involve the nerve roots. For example, some autoimmune disorders, such as **Guillain–Barré syndrome,** have a predilection for nerve roots. Reactivation of latent **varicella-zoster virus** (chickenpox virus) in dorsal root ganglia produces the painful blistering lesions of **herpes zoster,** or **shingles.** These occur in a dermatomal distribution, associated with sensory, and less commonly motor, loss in the affected nerve roots. Herpes zoster is most common in thoracic dermatomes but can occur anywhere. Treatment with oral antiviral agents such as acyclovir or famcyclovir can shorten the duration of blistering lesions. Severe pain can persist after the blistering eruption, referred to as postherpetic neuralgia. When herpes zoster occurs in the ophthalmic division of the trigeminal nerve, it can threaten vision, and it is usually treated with intravenous acyclovir. **Lyme disease,** a tick-borne illness caused by the spirochete *Borrelia burgdorferi,* can cause radiculopathies. **Cytomegalovirus polyradiculopathy** can be seen in patients with HIV infection, most commonly in the lumbosacral roots. A mild form of radiculopathy can also be caused by HIV itself. Dumbbell-shaped nerve sheath tumors, such as **schwannomas** and **neurofibromas** (in neurofibromatosis), can occasionally occur in a neural foramen, producing radiculopathy. ■

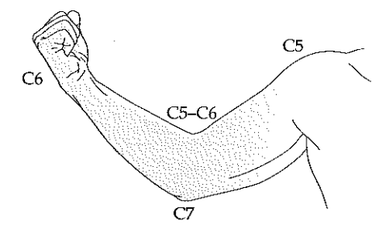

Figure 8.6 Three Roots to Remember in the Arm C5 mediates arm abduction at the shoulder; C5 and C6 mediate flexion at the elbow and the biceps reflex; C6 mediates wrist extension; C7 mediates elbow extension and the triceps reflex (see also Table 8.5).

Simplification: Three Nerve Roots to Remember in the Arm

For practical purposes, the most clinically important nerve roots in the arm are **C5, C6, and C7.** It is important to be familiar with the reflexes and the motor and sensory functions associated with these nerve roots, as summarized in Figure 8.6 and Table 8.5. When examining patients, it is helpful to have memorized at least one muscle that gets its major innervation from each of these three nerve roots. In addition to the nerve roots listed in Table 8.5, it is also worth knowing that C8 radiculopathy accounts for about 6% of cervical radiculopathies, is usually caused by C7–T1 disc herniation, and is associated with weakness of the intrinsic hand muscles and decreased sensation in the fourth and fifth digits and the medial forearm. About 20% of all cervical radiculopathies involve two or more cervical levels.

Simplification: Three Nerve Roots to Remember in the Leg

The most clinically important nerve roots in the leg are **L4, L5, and S1.** Reflexes and the motor and sensory functions associated with L4, L5, and S1 are summarized in Figure 8.7 and Table 8.6. As with the cervical nerve roots, it is helpful, when examining patients, to have memorized at least one muscle that gets its major innervation from each of these nerve roots.

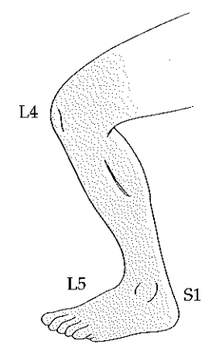

Figure 8.7 Three Roots to Remember in the Leg L4 mediates leg extension at the knee and the patellar tendon reflex; L5 mediates dorsiflexion at the ankle; S1 mediates plantar flexion at the ankle and the Achilles tendon reflex (see also Table 8.6).

TABLE 8.5 Three Important Nerve Roots in the Arm

NERVE ROOT	MAIN WEAKNESS[a]	REFLEX DECREASED[a]	REGION OF SENSORY ABNORMALITY[b]	USUAL DISC INVOLVED	APPROXIMATE PERCENTAGE OF CERVICAL RADICULOPATHIES
C5	Deltoid, infraspinatus, biceps	Biceps, pectoralis	Shoulder, upper lateral arm	C4–C5	7%
C6	Wrist extensors, biceps	Biceps, brachioradialis	First and second fingers, lateral forearm	C5–C6	18%
C7	Triceps	Triceps	Third finger	C6–C7	46%

[a]See Figure 8.6.

[b]See Figure 8.4.

KEY CLINICAL CONCEPT
CAUDA EQUINA SYNDROME

8.4 Impaired function of multiple nerve roots below L1 or L2 is called **cauda equina syndrome.** If the deficits begin at the S2 roots and below, there may be no obvious leg weakness. Sensory loss in an S2 to S5 distribution (see Figure 8.4) is sometimes called **saddle anesthesia.** Involvement of the S2, S3, and S4 nerve roots can produce a distended atonic bladder with urinary retention or overflow incontinence (see KCC 7.5), constipation, decreased rectal tone, fecal incontinence, and loss of erections. It is essential to detect and treat cauda equina syndrome promptly to avoid irreversible deficits. Cauda equina syndrome can sometimes be difficult to differentiate from **conus medullaris syndrome,** in which similar deficits occur as the result of a lesion in the sacral segments of the spinal cord (see Figure 8.1). **Causes of cauda equina syndrome** include compression by a central disc herniation (see Figure 8.3C), epidural metastases, schwannoma, meningioma, neoplastic meningitis, trauma, epidural abscess, arachnoiditis, and cytomegalovirus polyradiculitis. ■

KEY CLINICAL CONCEPT
COMMON SURGICAL APPROACHES TO THE SPINE

8.5 Most patients with radiculopathy caused by disc herniation recover within a few months without surgery. Indications for urgent surgery include the rare instances in which cord compression or cauda equina syndrome occurs. Semiurgent surgery is indicated in patients with progressive or severe motor deficits, or in the occasional patient with intolerable, medically intractable pain. Elective surgery is contemplated when a clear radiculopathy is present, and conservative measures such as rest, physical therapy, and traction have been tried for 1 to 3 months but were ineffective.

In the cervical spine, surgical options include a **posterior approach** with **laminectomy,** or removal of the lamina over affected levels (see Figure 8.2B), combined with **discectomy** to remove herniated disc material, and **foraminotomy** to widen the lateral recess through which the nerve root passes just before it exits the intervertebral foramen. An **anterior approach** can also be used in the cervical spine, in which an incision is made in the anterior neck and the dissection is carried down to the vertebral bodies. The anterior approach provides direct access to the discs without traversing the spinal canal, and also allows mechanical **fusion** of adjacent vertebral bodies, usually using a bone graft. An anterior approach is also often favored in cases of thoracic disc herniation, which is rare. In the lumbar spine, a posterior approach is generally used. Sometimes a variety of hardware is implanted to increase mechanical stability. ■

TABLE 8.6 Three Important Nerve Roots in the Leg

NERVE ROOT	MAIN WEAKNESS[a]	REFLEX DECREASED[a]	REGION OF SENSORY ABNORMALITY[b]	USUAL DISC INVOLVED	APPROXIMATE PERCENTAGE OF LUMBOSACRAL RADICULOPATHIES
L4	Iliopsoas, quadriceps	Patellar tendon (knee jerk)	Knee, medial lower leg	L3–L4	3–10%
L5	Foot dorsiflexion, big toe extension, foot eversion, inversion	None	Dorsum of foot, big toe	L4–L5	40–45%
S1	Foot plantar flexion	Achilles tendon (ankle jerk)	Lateral foot, small toe, sole	L5–S1	45–50%

[a]See Figure 8.7.

[b]See Figure 8.4.

CLINICAL CASES

CASE 8.1 UNILATERAL NECK PAIN AND TINGLING NUMBNESS IN THE THUMB AND INDEX FINGER

CHIEF COMPLAINT

A 30-year-old man came to his physician's office because of 4 weeks of left-sided neck and arm pain and tingling.

HISTORY

Previous history was unremarkable except for some minor sports injuries. These included a skiing accident 2 years ago in which he struck the left side of his neck and had local pain lasting about 3 weeks, and a backward fall during a softball game 1 year ago in which he struck his occiput without loss of consciousness but had some confusion for about 30 minutes. Four weeks ago he awoke one morning with severe **left neck and shoulder pain with tingling radiating down into the first and second fingers of the left hand** (thumb and index finger). The symptoms improved slightly after a few days but then recurred about 4 days ago, making sleep difficult. Over-the-counter pain medications helped but did not eliminate the pain. He did not notice any weakness, numbness, change in bowel or bladder function (see KCC 7.5), or Lhermitte's sign (see KCC 7.1).

PHYSICAL EXAMINATION

Vital signs: T = 98°F, P = 72, BP = 140/80.
Neck: Supple; no tenderness.
Lungs: Clear.
Heart: Regular rate.
Abdomen: Soft.
Extremities: Normal.

Neurologic exam:

MENTAL STATUS: Alert and oriented ×3. Normal language. Gave detailed history.

CRANIAL NERVES: Intact.

MOTOR: Normal tone. 5/5 power throughout, except for **4⁺/5 power in the left biceps, brachioradialis, and wrist extensors.**

REFLEXES:

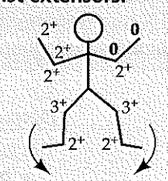

COORDINATION: Normal on finger-to-nose and heel-to-shin testing.

GAIT: Normal. Tandem gait normal. No Romberg sign.

SENSORY: Intact light touch, vibration, and joint position sense. **Mildly decreased pinprick sensation in the left first and second fingers. Two-point discrimination 4–5 mm in the left index finger,** compared to 3 mm in the right index finger (using a ruler and the ends of a paper clip).

LOCALIZATION AND DIFFERENTIAL DIAGNOSIS

On the basis of the symptoms and signs shown in bold above, where is the lesion? What is the most likely diagnosis?

Discussion

The key symptoms and signs in this case are:

- **Left neck and shoulder pain with tingling radiating down into the first and second fingers, accompanied by decreased pinprick and discriminative sensation**
- **Weakness of the left biceps, brachioradialis, and wrist extensors**
- **Absent left biceps and brachioradialis reflexes**

The patient has a typical left C6 radiculopathy (see KCC 8.3; Figures 8.4 and 8.6; Tables 8.1 and 8.5). It is very likely that the diagnosis in this setting is a left C5–C6 disc herniation (see Table 8.4 for less common causes).

Clinical Course and Neuroimaging 322

The patient underwent a **cervical spine MRI** (Figure 8.8), which confirmed a left C5–C6 disc herniation. He was referred to a neurosurgeon to discuss possible surgery to relieve the nerve root compression. The patient opted to wait for a few more weeks and to undergo surgery if his symptoms did not resolve. He used a hard cervical collar for traction, avoided physical exertion, and continued taking nonsteroidal anti-inflammatory pain medication. One month later his symptoms had resolved completely. His exam was normal except for a diminished left biceps reflex and barely detectable left biceps weakness, which continued to improve with physical therapy.

REVIEW EXERCISE

Using Figures 8.3A and 8.8, explain why a C5–C6 disc herniation usually causes a C6 radiculopathy.

CASE 8.2 UNILATERAL OCCIPITAL AND NECK PAIN

MINICASE

A 74-year-old man with a past history of bladder carcinoma developed **left-sided occipital and neck pain** over the course of 2 weeks. Exam was normal except for **questionable altered sensation over the left occipital area.** Head CT and cervical X-rays were normal. A bone scan and MRI of the cervical spine were therefore done.

LOCALIZATION AND DIFFERENTIAL DIAGNOSIS

On the basis of the symptoms and signs shown in **bold** above, where is the lesion? What is the most likely diagnosis?

Discussion

The key symptoms and signs in this case are:

- **Pain and sensory changes over the left occipital area**

The combination of pain and sensory loss in this territory suggests a peripheral nerve lesion. Sensation in the occipital scalp is provided by C2 (Figure 8.4), which gives rise to the greater and lesser occipital nerves.

The most likely *clinical localization* is left C2 nerve root or left occipital nerves. Given the patient's history of bladder cancer, one possible diagnosis is epidural metastasis compressing the left C2 nerve root, or left occipital nerves. Less likely possibilities include degenerative disease of the spine, or the other diagnoses listed in Table 8.4.

Clinical Course and Neuroimaging 324

A **cervical spine MRI** (Figure 8.9) was done, revealing a left cervical mass involving C2. The patient had a CT-guided needle biopsy of the mass, and pathology revealed metastatic transitional cell bladder carcinoma. Radiation therapy was instituted, but the patient gradually deteriorated and was ultimately referred for hospice care.

CASE 8.3 UNILATERAL SHOULDER PAIN AND WEAKNESS

MINICASE

A 50-year-old man with a past history of multiple high school and college football injuries was in a motor vehicle accident and developed **left shoulder pain and numbness** that occasionally radiated down the left arm into the thumb and was increased by neck extension. Exam was normal except for **4/5 deltoid power on the left** and **decreased pinprick sensation in the left shoulder.**

LOCALIZATION AND DIFFERENTIAL DIAGNOSIS

On the basis of the symptoms and signs shown in **bold** above, where is the lesion? What is the most likely diagnosis?

Discussion

The key symptoms and signs in this case are:

- **Left shoulder pain and decreased sensation**
- **Left deltoid weakness**

Sensation to the shoulder and motor innervation of the deltoid muscle is provided by the axillary nerve, which gets its predominant supply from the C5 nerve root (see Table 8.1; Figure 8.6). The most likely diagnosis is therefore a left C5 radiculopathy caused by C4–C5 disc herniation or osteophytes. Other, less likely causes of a C5 radiculopathy are listed in Table 8.4. An axillary neuropathy should also be considered (see Table 9.1). In addition, another diagnosis to be considered is rotator cuff tear, an injury to tendons and ligaments that can cause weakness of abduction and external rotation at the shoulder. However, such an injury would not explain this patient's sensory changes.

Clinical Course

The patient underwent a cervical spine MRI, which demonstrated bony osteophytes (see Table 8.3) causing narrowing of the intervertebral neural foramina at C4–C5 (not shown). He was taken to the operating room for laminectomy and decompression of the neural foramina (see KCC 8.5) and had a good postoperative recovery.

CASE 8.1 UNILATERAL NECK PAIN AND TINGLING NUMBNESS IN THE THUMB AND INDEX FINGER

Figure 8.8 Herniated C5–C6 Intervertebral Disc Obliterating Left C6 Neural (Intervertebral) Foramen MRI of the cervical spine. (A) Sagittal T1-weighted image showing herniated C5–C6 intervertebral disc. (B) Axial T2-weighted image at level of herniated C5–C6 intervertebral disc showing that the disc obliterates the left C6 neural foramen.

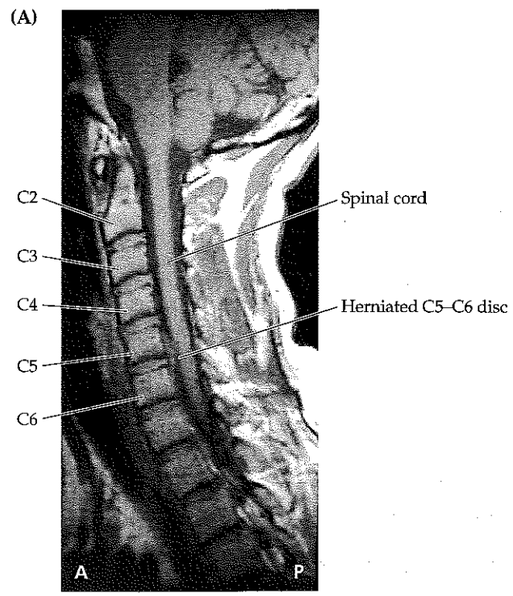

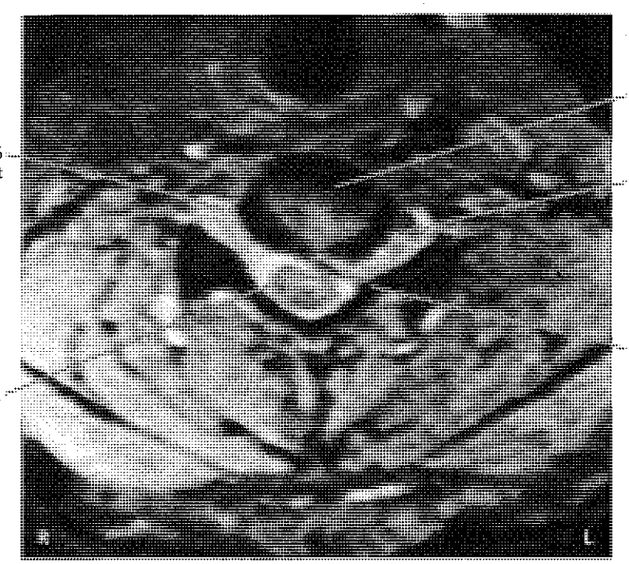

CASE 8.4 BLISTERS, PAIN, AND WEAKNESS IN THE LEFT ARM

MINICASE

A 68-year-old man awoke one morning with a painful blistering rash on his left shoulder and arm, accompanied by left arm weakness and numbness that progressed over the next week. He was eventually **unable to raise his left arm** but had good hand strength. He visited his family doctor, and on exam he had reddish blisters, some of which were scaled over, in the distribution shown in Figure 8.10. In addition, he had **2/5 left deltoid strength, 3/5 strength in the left arm external rotation, and 4/5 strength in the left biceps and brachioradialis. Left biceps and brachioradialis reflexes were absent,** while other reflexes were 2+. There was **decreased pinprick sensation in the same distribution as the rash** (see Figure 8.10). The remainder of the exam was unremarkable.

LOCALIZATION AND DIFFERENTIAL DIAGNOSIS

On the basis of the symptoms and signs shown in **bold** above, where is the lesion? What is the most likely diagnosis?

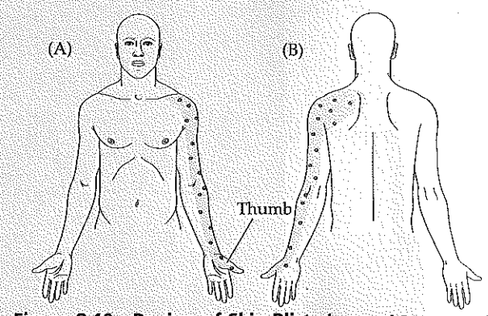

Figure 8.10 Region of Skin Blistering and Decreased Pinprick Sensation Compare to Figure 8.4.

Discussion

The key symptoms and signs in this case are:

- **Blistering rash and decreased pinprick sensation in the left shoulder and arm**
- **Weak left deltoid, arm external rotation, biceps, and brachioradialis, with absent left biceps and brachioradialis reflexes**

The herpetic skin lesions, together with sensory loss in a left C5–C6 distribution, make the most likely diagnosis herpes zoster of the left C5 and C6 nerve roots (see KCC 8.3). Although more common in thoracic dermatomes, herpes zoster can occur in other dermatomes as well, and can occasionally cause weakness. The muscle weakness and reflex loss in this patient are also consistent with C5 and C6 involvement, although C5 seems to be more severely affected, since wrist extension (C6) was not weak (see Tables 8.1 and 8.5; Figure 8.6).

Clinical Course

A lumbar puncture was done. The cerebrospinal fluid (CSF) was normal except for the presence of 224 white blood cells per cubic millimeter (normal is 0–5; see KCC 5.9 and 5.10; Table 5.7) with 89% lymphocytes. Viral cultures from CSF and from the skin lesions were negative; however, a polymerase chain reaction (PCR) test on CSF was positive for varicella-zoster virus. The patient was treated with intravenous, and later oral, acyclovir. A cervical spine MRI was negative, as was careful examination for cranial nerve involvement. When the patient was seen 3 months later in follow-up, the rash had resolved, and the pain and weakness in his left arm were improving but were still a significant problem.

CASE 8.2: UNILATERAL OCCIPITAL AND NECK PAIN

Figure 8.9 Metastatic Bladder Carcinoma Encasing Left C2 Nerve Root
Axial T1-weighted MRI of the cervical spine.

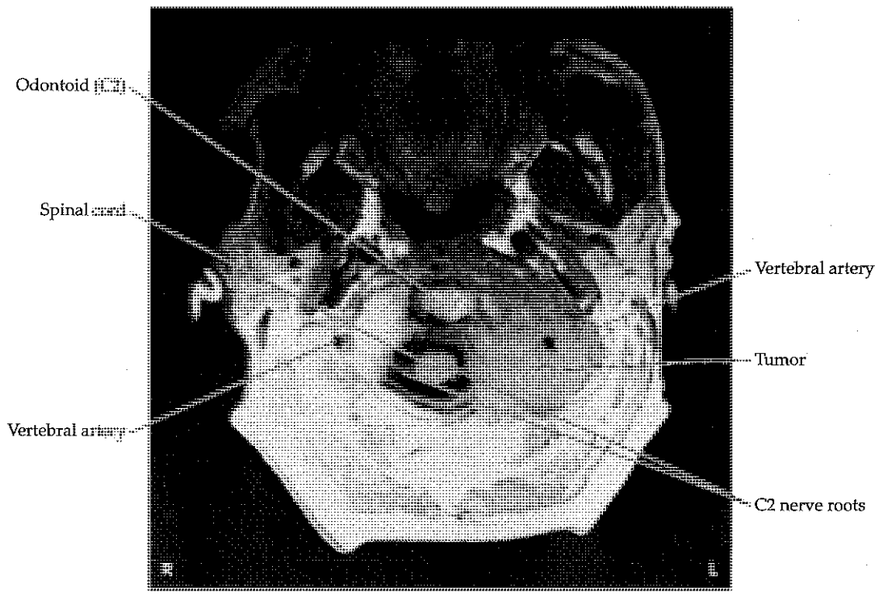

CASE 8.5 UNILATERAL SHOULDER PAIN AND NUMBNESS IN THE INDEX AND MIDDLE FINGERS

MINICASE
A 37-year-old physician had sudden onset of sharp **pain in her right shoulder,** followed by tingling and numbness radiating down her arm into her hand. She noticed that her **right second and third fingers felt numb.** She tried to comb her hair, but her **right arm kept bending at the elbow,** causing her hand to fall onto her head. She was fairly certain of the diagnosis at this point and scheduled an appointment with an orthopedic colleague. Her exam was notable only for **3/5 strength in the right triceps, 4+/5 strength in the right finger extensors, an absent right triceps reflex, and decreased sensation to pinprick and light touch in the right second finger and lateral half of the third finger** (Figure 8.11).

LOCALIZATION AND DIFFERENTIAL DIAGNOSIS
On the basis of the symptoms and signs shown in **bold** above, where is the lesion? What is the most likely diagnosis?

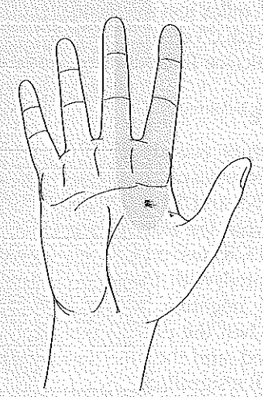

Figure 8.11 Region of Decreased Sensation
Compare to Figure 8.4.

Discussion

The key symptoms and signs in this case are:

- **Weakness of the right triceps and finger extensors, with absent right triceps reflex**
- **Right shoulder pain with paresthesias and decreased sensation in the right second finger and lateral half of the third finger**

The weakness, reflex loss, and decreased sensation in this patient are consistent with a right C7 radiculopathy (Tables 8.1, 8.5; Figures 8.4 and 8.6). Note that, as mentioned previously, dermatomal patterns can vary slightly; however, C7 radiculopathy usually affects the middle finger, and may involve the index finger as well. The most likely diagnosis is right C7 nerve root compression caused by right C6–C7 disc herniation. Other, less common possibilities are listed in Table 8.4.

Clinical Course

An MRI of the cervical spine revealed a C6–C7 disc herniation impinging on the right C7 nerve root (see Figure 8.8 for a similar scan at a different level). Despite conservative therapy, she continued to have pain and developed some atrophy of the right triceps muscle. She therefore underwent a partial laminectomy with a C6–C7 discectomy (see KCC 8.5). Postoperatively, her triceps strength recovered fully, although she continued to have some pain and numbness in the right arm and hand over the next few months.

CASE 8.6 UNILATERAL NECK PAIN, HAND WEAKNESS, AND NUMBNESS IN THE RING AND LITTLE FINGERS

MINICASE
A 34-year-old cardiothoracic surgeon developed **left neck and shoulder pain, with numbness and tingling radiating down the ulnar aspect of his arm into the fourth and fifth fingers.** On exam he had some **weakness of the intrinsic muscles of the left hand,** and **decreased sensation to pinprick and light touch over the left fourth and fifth fingers** (Figure 8.12). The remainder of the exam was normal.

LOCALIZATION AND DIFFERENTIAL DIAGNOSIS
On the basis of the symptoms and signs shown in **bold** above, where is the lesion? What is the most likely diagnosis?

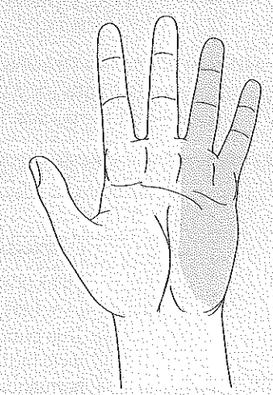

Figure 8.12 Region of Decreased Sensation
Compare to Figure 8.4.

Discussion

The key symptoms and signs in this case are:

- **Weakness of the intrinsic muscles of the left hand**
- **Left neck and shoulder pain, with paresthesias and decreased sensation in the left fourth and fifth fingers**

It would have been helpful for localization if additional details of the motor exam had been provided. Weakness of hand intrinsic muscles (lumbricals, interossei) can

be caused by lesions of the ulnar nerve, median nerve, lower trunk of the brachial plexus (see Chapter 9), C8, or T1 nerve roots (see Table 8.1). In addition, the distribution of abnormal sensation in this patient is consistent with a lesion of the ulnar nerve, lower trunk of the brachial plexus (C8, T1; see Chapter 9), or C8 nerve root (see Figure 8.4). Neck and shoulder pain suggests a radiculopathy. Therefore, a left C8 radiculopathy caused by leftward C7–T1 disc herniation is the most likely diagnosis (see also Table 8.4); however, an ulnar neuropathy or lower brachial plexus lesion should also be considered.

Clinical Course

An MRI showed a C7–T1 disc herniation (see Figure 8.8 for a similar scan at a different level). At the time of laminectomy, some free disc fragments were found compressing the left C8 nerve root and were removed. Postoperatively, the patient's pain was resolved, and his hand strength recovered fully.

CASE 8.7 PAIN AND NUMBNESS IN THE MEDIAL ARM

MINICASE

A 66-year-old executive had been suffering for 2 years with **pain and numbness in his left shoulder and medial arm.** Exam was notable for **decreased sensation to light touch in the left medial arm and forearm** (Figure 8.13), and was otherwise unremarkable. Several MRIs and a CT myelogram were done suggesting possible neural compression at multiple levels, including C6–C7, C7–T1, and T1–T2.

LOCALIZATION AND DIFFERENTIAL DIAGNOSIS

On the basis of the symptoms and signs shown in **bold** above, where is the lesion? What is the most likely diagnosis?

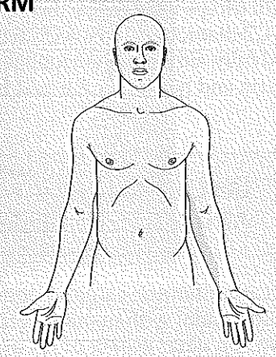

Figure 8.13 Region of Decreased Sensation
Compare to Figure 8.4.

Discussion

The key symptoms and signs in this case are:

- **Left shoulder pain, with decreased sensation in medial arm and forearm**

This patient had sensory changes in the left T1 dermatome (see Figure 8.4). Thoracic radiculopathy is uncommon, but can occasionally be seen as a result of disc herniation, or other disorders listed in Table 8.4. It should be noted that this patient had sensory findings only, with no motor involvement (see Table 8.1), which can occur with incomplete nerve root lesions (see KCC 8.3).

Clinical Course

Because the imaging studies did not provide a definite level, yet he had refractory pain, the patient was taken to the operating room for laminectomy and exploration of the left C7, C8, and T1 nerve roots. At the time of surgery the left T1 nerve root was found to be compressed by T1–T2 disc fragments, which were removed. This case illustrates that MRI or CT findings suggesting nerve root compression need to be interpreted in the context of clinical symptoms and signs, since asymptomatic radiological abnormalities are common. Postoperatively, the patient's pain improved markedly.

CASE 8.8 LOW BACK PAIN RADIATING TO THE SOLE OF THE FOOT AND THE SMALL TOE

CHIEF COMPLAINT

Following an accident, a 38-year-old man developed difficulty walking, and low back pain radiating to the lateral sole of his left foot.

HISTORY

The patient was working on a road when he was injured by an explosion. He suffered severe burns requiring plastic surgery. In addition, he experienced low back pain with **numbness and "pins and needles"** running down his left leg into the **sole and lateral aspect of the left foot, including the small toe.** He had some trouble walking, mostly because of pain, but he also noticed **difficulty standing on his toes with the left foot.** He denied changes in bowel, bladder, or erectile function.

PHYSICAL EXAMINATION

Vital signs: T = 98°F, P = 80, BP = 112/80.
Neck: Supple.
Lungs: Clear.
Heart: Regular rate with no murmurs, gallops, or rubs.
Abdomen: Normal bowel sounds; soft.
Extremities: Normal.
Dermatologic: Multiple scars on face and arms.
Neurologic exam:
- *MENTAL STATUS:* Alert and oriented ∞3. Fluent language.
- *CRANIAL NERVES:* Intact.
- *MOTOR:* 5/5 power throughout, except for **4/5 power in the left gastrocnemius and hamstrings** (semitendinosus, semimembranosus, and biceps femoris).
- *REFLEXES:*

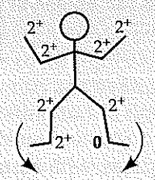

- *COORDINATION:* Normal on finger-to-nose testing.
- *GAIT:* Slow and painful. **Unable to stand on toes of left foot.**
- *SENSORY:* Intact except for **decreased light touch and pinprick sensation in the left lateral calf, left lateral foot including the small toe, and sole of the left foot** (Figure 8.14).

LOCALIZATION AND DIFFERENTIAL DIAGNOSIS

On the basis of the symptoms and signs shown in **bold** above, where is the lesion? What is the most likely diagnosis?

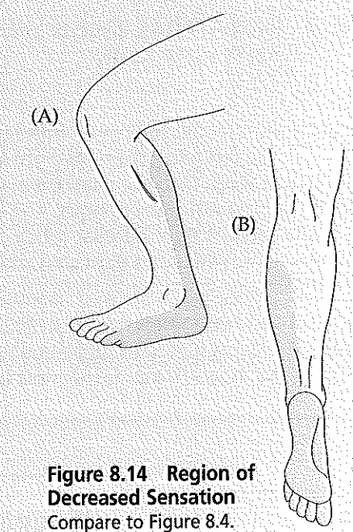

Figure 8.14 Region of Decreased Sensation
Compare to Figure 8.4.

Discussion

The key symptoms and signs in this case are:

- **Weakness of the left gastrocnemius and hamstrings, with absent left Achilles tendon reflex**
- **Paresthesias and decreased sensation in the left lateral calf, lateral foot including the small toe, and sole**

The weakness, reflex loss, and sensory changes in this patient are consistent with a left S1 radiculopathy (see Tables 8.1, 8.6; Figures 8.4, 8.7). The most likely diagnosis is a left posterolateral L5–S1 disc herniation compressing the left S1 nerve root (see also Table 8.4 for other possibilities).

REVIEW EXERCISE

Trace the course of the L4, L5, and S1 nerve roots in Figures 8.15 and 8.16 (see also Figure 8.3B,C) to demonstrate why an L4–L5 disc herniation usually causes an L5 radiculopathy and an L5–S1 disc herniation usually causes an S1 radiculopathy.

Clinical Course and Neuroimaging 330

A **spine MRI** was performed and showed a left L5–S1 disc herniation (Figures 8.15, 8.16). The patient's symptoms did not improve, and he was therefore taken to the operating room for a laminectomy, which revealed a herniated L5–S1 disc with a free disc fragment compressing the left S1 nerve root in the lateral recess. The fragment was removed, and the patient did well until 1 year later, when he had recurrent pain in the same distribution and mild calf weakness. Repeat MRI showed scar tissue surrounding the left S1 nerve root. This could not be treated surgically, and he was therefore treated with pain medications and local steroid injections with only partial relief.

Related Case. Figure 8.17 (page 332) shows an example from a different patient of a **myelogram** (see Chapter 4) demonstrating bilateral L5 nerve root compression by a herniated L4–L5 disc.

CASE 8.9 UNILATERAL THIGH WEAKNESS WITH PAIN RADIATING TO THE ANTERIOR SHIN

MINICASE

A 76-year-old man suffered for 1 year with relentless **pain and numbness radiating from his right buttock down the anterior thigh into the shin.** Exam was notable for **4^-/5 right quadriceps strength, 4^+/5 right iliopsoas strength, absent right patellar reflex, and decreased pinprick sensation in the right shin and medial calf** (Figure 8.18).

LOCALIZATION AND DIFFERENTIAL DIAGNOSIS

On the basis of the symptoms and signs shown in **bold** above, where is the lesion? What is the most likely diagnosis?

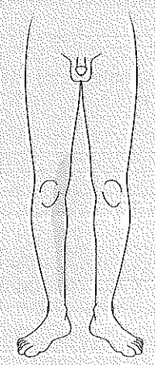

Figure 8.18 Region of Decreased Sensation Compare to Figure 8.4.

Discussion

The key symptoms and signs in this case are:

- **Weakness of the right quadriceps and iliopsoas, with absent right patellar reflex**
- **Paresthesias and decreased sensation in the anterior thigh, shin, and medial calf**

The pattern of weakness, reflex loss, and sensory changes is compatible with a right femoral neuropathy or L4 radiculopathy (see Tables 8.1, 8.6; Figures 8.4, 8.7; see also Table 9.3). **Lesions of the femoral nerve can sometimes be distinguished from an L4 radiculopathy by testing for weakness of thigh adduction,** which may be present in L4 radiculopathy but not femoral neuropathy (see Table 8.1). Unfortunately, thigh adduction testing was not documented in this patient. An L2 or L3 radiculopathy could also be considered in this patient; however, these radiculopathies do not usually produce sensory changes extending below the knee, and they are also much less common than an L4 radiculopathy. The most likely diagnosis is therefore right femoral neuropathy or right posterolateral L3–L4 disc herniation compressing the right L4 nerve root (see also Table 8.4 for other possibilities).

Clinical Course

Interestingly, rather than an L3–L4 posterolateral disc herniation, this patient's MRI (not shown) revealed a herniated right L4–L5 disc extending far upward and laterally to compress the right L4 nerve root (review Figure 8.3C). Following laminectomy and removal of the herniated disc material, the patient had complete resolution of the pain, and his right leg strength improved.

CASE 8.10 LOW BACK PAIN RADIATING TO THE BIG TOE

MINICASE

A 57-year-old man with low back pain for over 20 years tripped over a door ledge and had a sudden increase in **right-sided low back pain radiating down his leg to the right big toe.** He had some difficulty walking because of the pain, causing him to visit the emergency room several times over the next 3 months, where his exam was notable for **3/5 power in the right extensor hallucis longus and tibialis anterior, 4^+/5 power in the right foot invertors and evertors,** normal reflexes, and **decreased pinprick sensation in the right anterolateral calf and dorsum of the foot** (Figure 8.19). **Straight-leg raising** (see Figure 8.5A) beyond 30° on the left side had no effect, but on the right side **reproduced the patient's usual pain.**

LOCALIZATION AND DIFFERENTIAL DIAGNOSIS

On the basis of the symptoms and signs shown in **bold** above, where is the lesion? What is the most likely diagnosis?

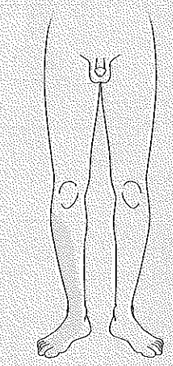

Figure 8.19 Region of Decreased Sensation Compare to Figure 8.4.

Discussion

The key symptoms and signs in this case are:

- **Weakness of the right extensor hallucis longus, tibialis anterior, and right foot invertors and evertors**
- **Pain radiating to the right big toe reproduced by straight-leg raising, with decreased sensation in the anterolateral calf and dorsum of the foot**

This patient has typical radicular pain, sensory loss, and weakness compatible with a right L5 radiculopathy (see Tables 8.1, 8.6; Figures 8.4, 8.7). A peroneal nerve palsy (see Tables 8.1, 9.3) can also produce similar decreased sensation and foot drop but does not cause painful paresthesias with straight-leg raising. In addition lesions of the peroneal nerve can sometimes be distinguished from an L5 radiculopathy by testing for weakness of foot inversion which may be present in L5 radiculopathy, but not in peroneal nerve palsy (see Table 8.1).

The most likely diagnosis is therefore right posterolateral L4–L5 disc herniation compressing the right L5 nerve root (see also Table 8.4 for other possibilities).

Clinical Course

An MRI showed a herniated L4–L5 disc compressing the right L5 nerve root (see Figure 8.16D for a similar scan at a different level). Surgery was discussed with the patient; however, he was lost to follow-up.

CASE 8.8 LOW BACK PAIN RADIATING TO THE SOLE OF THE FOOT AND THE SMALL TOE

Figure 8.15 L5–S1 Posterolateral Disc Herniation Compressing Left S1 Nerve Root in the Lateral Recess T1-weighted MRI of the spine. (A) Parasagittal view slightly to the left of midline, showing herniated L5.10 intervertebral disc. (B) Parasagittal view, further to the left of midline, showing neural foramina. Note that the foramen for the L5 root (L5–S1) is not obstructed.

(A)

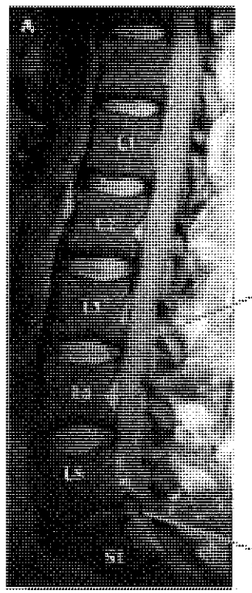

(B)



Figure 8.16 Axial Sections Showing Posterolateral Disc Herniation Compressing Left S1 Nerve Root in the Lateral Recess T1 weighted MRI of the spine. (A) Midsagittal view showing herniated L5–S1 intervertebral disc (as in Figure 8.15A), with levels of axial sections in B–E indicated. Sections B–E proceed from rostral to caudal. (B) Axial section at level of L5 vertebral body showing L5 nerve roots in lateral recesses. (C) Axial section at level of L5 neural foramen, above the level of the L5–S1 intervertebral disc (compare to Figure 8.3B,C). (D) Axial section at level of L5–S1 intervertebral disc showing herniation of disc into left lateral recess compressing left S1 nerve root (compare to Figure 8.3B,C). (E) Axial section at level of S1 body showing S1 nerve roots in lateral recess below the level of compression.

(A)



CASE 8.8 *(CONTINUED)*

(B)



(C)

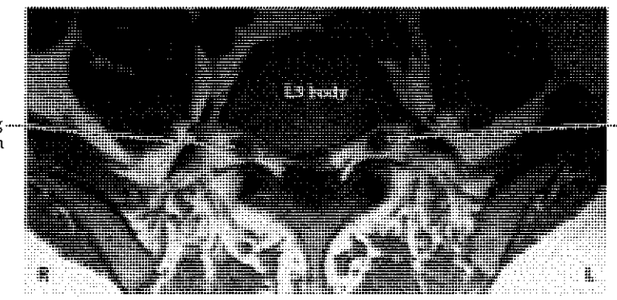

(D)

(E)

CASE 8.8 RELATED CASE

Figure 8.17 Example of Myelogram Showing Bilateral L5 Nerve Root Compression at the Level of the L4–L5 Intervertebral Disc An anterior–posterior plain X-ray film is shown after introduction of myelographic contrast material into the subarachnoid space (see Chapter 4; KCC 5.10). The normal L3, L4, S1, and S2 nerve root sleeves can be visualized in relation to vertebral bones (compare to Figure 8.3). The L5 nerve root sleeves are truncated bilaterally because of L4–L5 intervertebral disc herniation.

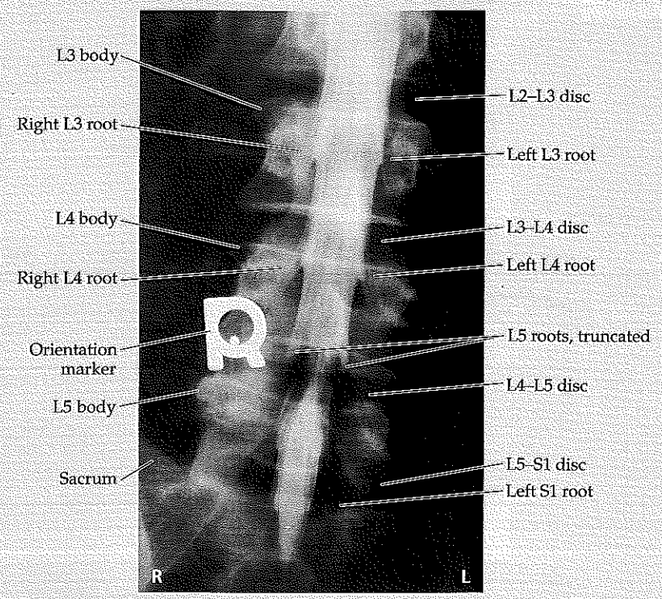

CASE 8.11 SADDLE ANESTHESIA WITH LOSS OF SPHINCTERIC AND ERECTILE FUNCTION

CHIEF COMPLAINT

A 39-year-old man came to the emergency room with 10 days of bilateral gluteal pain, numbness, and sphincteric dysfunction.

HISTORY

Ten days prior to admission the patient was doing heavy labor with concrete when he coughed and felt a sudden "pop" followed by sharp **pain in the gluteal region bilaterally. The** pain was only partly relieved by over-the-counter pain medications. During the following days he noticed that he **had no erections,** even upon awakening. In addition, he noticed a **loss of sensation over his genitals and buttocks.** When he sat down it felt as though he was "on air" because he could not feel the seat. He also became **constipated** and did not have any bowel movements for 10 days, despite frequent attempts. **Urination was also difficult,** and when he felt discomfort from bladder distention, he applied pressure over his lower abdomen to initiate flow. Because of increasing problems with urinary retention, he finally came to the emergency room.

PHYSICAL EXAMINATION

Vital signs: T = 98.6°F, P = 60, BP = 130/80, R = 16.
Neck: Supple with no bruits.
Lungs: Clear.
Heart: Regular rate with no murmurs, gallops, or rubs.
Abdomen: Normal bowel sounds; soft. **Firm, distended bladder palpable in lower abdomen above pubic bone.**
Extremities: No edema.
Rectal: **Rectal tone flaccid.**
Neurologic exam:
- *MENTAL STATUS:* Alert and oriented ×3. Normal language.
- *CRANIAL NERVES:* Intact II–XII.

CASE 8.11 *(CONTINUED)*

MOTOR: Normal bulk and tone. 5/5 power throughout.
REFLEXES:
No anal wink. Only trace bulbocavernosus reflex (see Table 3.7).
Cremasteric reflex was present.

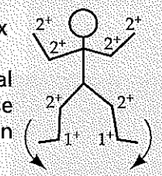

COORDINATION: Normal on finger-to-nose and heel-to-shin testing.
GAIT: Normal.
SENSORY: **Decreased pinprick and light touch sensation in a saddle distribution, including the genitals, perianal area, buttocks, and upper posterior thighs** (Figure 8.20). Pinprick, light touch, vibration, and joint position sense were normal in all other areas.
POSTVOID RESIDUAL VOLUME (see KCC 7.5): The patient was catheterized after attempting voluntary urination, and **1300 cc** of urine were obtained (normal volume is less than 100 cc).

LOCALIZATION AND DIFFERENTIAL DIAGNOSIS
On the basis of the symptoms and signs shown in **bold** above, where is the lesion? is the most likely diagnosis?

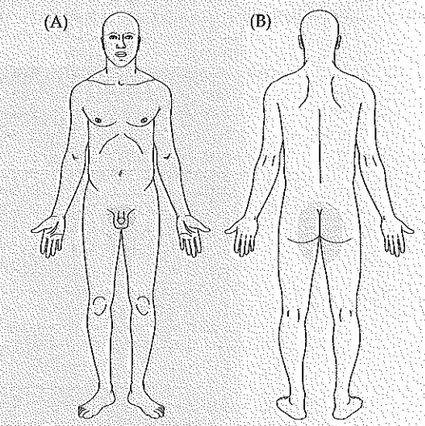

Figure 8.20 Region of Decreased Sensation
Compare to Figure 8.4.

Discussion

The key symptoms and signs in this case are:
- **Pain in the gluteal region bilaterally with loss of sensation in a saddle distribution over the genitals and buttocks**
- **Constipation, urinary retention, loss of erections, loss of rectal tone, no anal wink, and loss of bulbocavernosus reflex**

Impaired bowel, bladder, and sexual function can be caused by bilateral lesions of the cerebral hemispheres, spinal cord, conus medullaris, cauda equina, or peripheral nerves (see KCC 7.5.) The intact cremasteric reflex suggests that function of the L1–L2 nerve roots is preserved (see Table 3.7), and the normal lower extremity strength suggests preserved function down through S1. Meanwhile, the region of pain and sensory loss is in the bilateral S2 through S5 dermatomes (Figure 8.4), suggesting a lesion of the lower cauda equina or conus medullaris.

The most likely *clinical localization* is: cauda equina S2 through S5 roots, or conus medullaris.

Given the sudden onset of symptoms, a central disc herniation is likely as the diagnosis. Since the lower nerve roots are located more medially in the cauda equina (see Figure 8.3C), a central disc herniation tends to compress the lower nerve roots. For other, less likely causes of cauda equina syndrome in this patient, see KCC 8.4. Possible lesions of the conus medullaris include intrinsic tumors such as ependymoma, or astrocytoma, metastatic lesions, demyelinating processes, and sarcoidosis.

Clinical Course and Neuroimaging 334

The patient immediately underwent a **spinal CT/myelogram** (Figure 8.21), which showed an L5–S1 central disc herniation compressing the cauda equina. An urgent laminectomy was therefore performed. A large mass of disc mater-

CASE 8.11 SADDLE ANESTHESIA WITH LOSS OF SPHINCTERIC AND ERECTILE FUNCTION

Figure 8.21 Large Posterior L5–S1 Disc Herniation Compressing Cauda Equina Spinal CT-myelogram (see Chapter 4). Sections A–C proceed from rostral to caudal. (A) Section at level of L4–L5 intervertebral disc showing normal contrast agent–filled CSF space and cauda equina at this level. (B) Massive L5–S1 intervertebral disc herniation obliterating spinal canal at level of cauda equina. (C) Section at level of S1 vertebral body showing normal-appearing nerve roots, spinal canal, and other structures. Compare to Figure 8.3C.

(A)

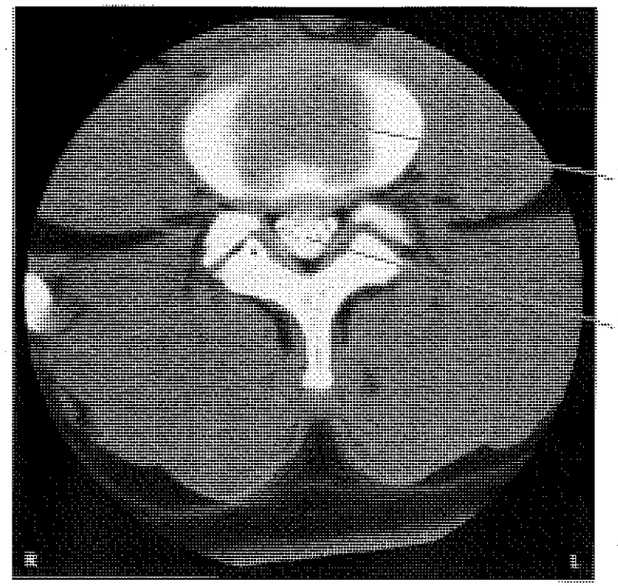

(B)

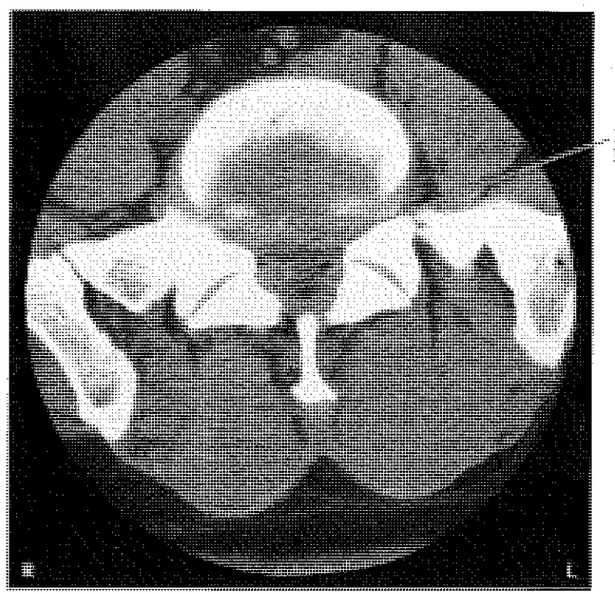

CASE 8.11 *(CONTINUED)*

(C)

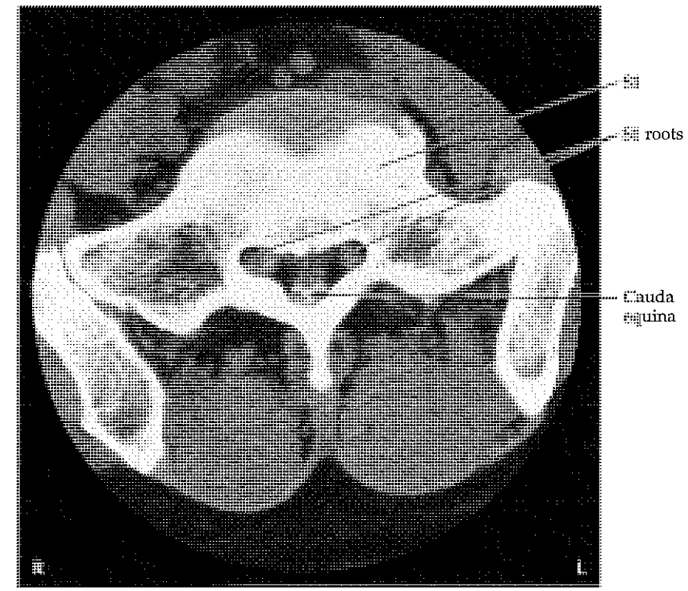

ial was found compressing the thecal sac from the anterior aspect at the L5–S1 intervertebral level. Following decompression the patient's pain improved, and he regained some gluteal sensation; however, he still had urinary retention and required intermittent catheterization at the end of his 11-day hospital stay.

Additional Cases

Related cases can be found in other chapters for the following topics: **peripheral nerve disorders** (Cases 9.1–9.11); **distal symmetric polyneuropathy** (Cases 6.5, 10.3); and **cranial neuropathy** (Cases 12.2–12.7, 13.1–13.3, 13.5). Other relevant cases can be found using the **Case Index.**

Brief Anatomical Study Guide

1. In this chapter we have discussed the segmental innervation of the body provided by **dorsal sensory** and **ventral motor nerve roots** that exit the spinal cord at **cervical, thoracic, lumbar, and sacral** levels (see Figure 8.1A) and fuse to form mixed spinal nerves (see Figure 8.1B). Because the vertebral bones outgrow the spinal cord during development, the lower roots continue **below the L1 or L2 vertebral bones** as the **cauda equina** (see Figure 8.1). The sensory regions innervated by nerve roots are called **dermatomes** (see Figure 8.4), and motor territories of nerve roots are called **myotomes.**
2. The most common cause of nerve root dysfunction, or **radiculopathy,** is **intervertebral disc herniation** at the cervical or lumbosacral

Brief Anatomical Study Guide *(continued)*

levels (see Figures 8.2, 8.3). The nerve root involved usually corresponds to the **vertebral body below the level of the herniated disc.** For example, an L5–S1 disc herniation usually causes an S1 radiculopathy. The **three most clinically relevant arm and leg nerve roots are C5, C6, and C7, and L4, L5, and S1, respectively.** A summary of the sensory and motor functions of these nerve roots is provided in Tables 8.5 and 8.6, and Figures 8.6 and 8.7.

References

General References

Aids to the Examination of the Peripheral Nervous System. 1986. Baillière Tindall on behalf of the Guarantors of Brain, London.

Bach JR. 1998. *Guide to the Evaluation and Management of Neuromuscular Disease.* Hanley & Belfus, Inc., Phildelphia.

Brazis PW, Masdeu JC, Biller J. 1996. The localization of spinal nerve and root lesions. In *Localization in Clinical Neurology,* 3rd Ed., Chapter 3. Little, Brown, Boston.

Devinsky O, Feldmann E. 1988. *Examination of the Cranial and Peripheral Nerves.* Churchill Livingstone, New York.

Deymeer FS (ed.). 2000. *Neuromuscular Disease: From Basic Mechanisms to Clinical Management.* (Monographs in Clinical Neuroscience, Vol. 18.) S. Karger AG, Farmington, CT.

Greenberg MS. 2001. *Handbook of Neurosurgery,* 5th Ed. Thieme, New York.

Preston DC, Shapiro BE. 1998. *Electromyography and Neuromuscular Disorders: Clinical-Electrophysiologic Correlations.* Butterworth-Heinemann, Boston.

Back Pain

Della-Giustina DA. 1999. Emergency department evaluation and treatment of back pain. *Emerg Med Clin North Am* 17(4): 877–893.

Deyo RA, Weinstein DO. 2001. Low back pain. *N Engl J Med* 344(5): 363–370.

Cervical Radiculopathy

Ahlgren BD, Garfin SR. 1996. Cervical radiculopathy. *Orthop Clin North Am* 27(2): 253–263.

Hanakawa T, Hashimoto S, Kawamura J, Nakamura M, Suenaga T, Matsuo M. 1997. Magnetic resonance imaging in a patient with segmental zoster paresis. *Neurology* 49(2): 631–632.

Poletti CE, Sweet WH. 1990. Entrapment of the C2 root and ganglion by the atlanto-epistrophic ligament: Clinical syndrome and surgical anatomy. *Neurosurgery* 27(2): 288–291.

Radhakrishnam K, Litchy WJ, O'Fallon WM, Kurland LT. 1994. Epidemiology of cervical radiculopathy: A population-based study from Rochester, Minnesota, 1976 through 1990. *Brain* 117(Pt. 2): 325–335.

Thoracic Radiculopathy

Currier BL, Eismont FJ, Green BA. 1992. Thoracic disc disease. In Rothman RH, Simeone FA (eds.), *The Spine,* 3rd Ed., Chapter 22. Saunders, Philadelphia.

Kumar R, Buckley TF. 1986. First thoracic disc protrusion. *Spine* 11(5): 499–501.

Kumar R, Cowie RA. 1992. Second thoracic disc protrusion. *Spine* 17(1): 120–121.

Levin KH. 1999. Neurologic manifestations of compressive radiculopathy of the first thoracic root. *Neurology* 53(5): 1149–1151.

Sellman MS, Mayer RF. 1988. Thoracoabdominal radiculopathy. *Southern Med J* 81(2): 199–201.

Lumbosacral Radiculopathy

Baba H, Imura S, Furusawa N, Tomita K. 1995. Lumbar radiculopathy associated with anterior intraspinal bony lesions. *Int Orthop* 19(3): 176–180.

Cohen MS, Wall EJ, Olmarker K, Rydevik BL, Garfin SR. 1992. Anatomy of the spinal nerve roots in the lumbar and lower thoracic spine. In Rothman RH, Simeone FA (eds.), *The Spine,* 3rd Ed., Chapter 4. Saunders, Philadelphia.

Fast A. 1988. Low back disorders: Conservative management. *Arch Phys Med Rehabil* 69(10): 880–891.

Cauda Equina Syndrome

Gindin RA, Volcan IJ. 1978. Rupture of the intervertebral disc producing cauda equina syndrome. *Am Surg* 44(9): 585–593.

Rai B, Chopra BK, Gupta RK. 1973. Cauda equina syndrome: A clinical study. *J Indian Med Assoc* 60(2): 47–48.

Ahn UM, Ahn NU, Buchowski JM, Garrett ES, Sieber AN, Kostuik JP. 2000. Cauda equina syndrome secondary to lumbar disc herniation: a meta-analysis of surgical outcomes. *Spine.* 25(12): 1515–1522.

CHAPTER 9

Major Plexuses and Peripheral Nerves

ANATOMICAL AND CLINICAL REVIEW
Brachial Plexus and Lumbosacral Plexus
Simplification: Five Nerves to Remember in the Arm
Simplification: Three Nerves Acting on the Thumb
Intrinsic and Extrinsic Hand Muscles
Simplification: Five Nerves to Remember in the Leg
KCC 9.1 Common Plexus and Nerve Syndromes
KCC 9.2 Electromyography (EMG) and Nerve Conduction Studies

CLINICAL CASES
9.1 Complete Paralysis and Loss of Sensation in One Arm
9.2 A Newborn with Weakness in One Arm
9.3 A Blow to the Medial Arm Causing Hand Weakness and Numbness
9.4 Nocturnal Pain and Tingling in the Thumb, Pointer, and Middle Finger
9.5 Hand and Wrist Weakness after a Fall
9.6 Numbness and Tingling in the Pinky and Ring Finger
9.7 Unilateral Thigh Pain, Weakness, and Numbness in a Diabetic
9.8 Tingling and Paralysis of the Foot after a Fall
9.9 A Leg Injury Resulting in Foot Drop
9.10 Lateral Thigh Pain and Numbness after Pregnancy
9.11 Dysarthria, Ptosis, and Decreased Exercise Tolerance
Additional Cases

BRIEF ANATOMICAL STUDY GUIDE

A 3-week-old infant was not moving her left arm normally. She was a large baby and had endured significant traction on her left shoulder during delivery. Her left arm had decreased tone and appeared internally rotated. She was able to extend her left arm at the elbow and could open and close her hand, but she could not abduct her left arm at the shoulder or flex it at the elbow. The left biceps reflex was absent. In this chapter, we will learn the sensory and motor functions of the major nerves in the arms and legs. As we shall see, this patient's symptoms are characteristic of injury to specific nerves.

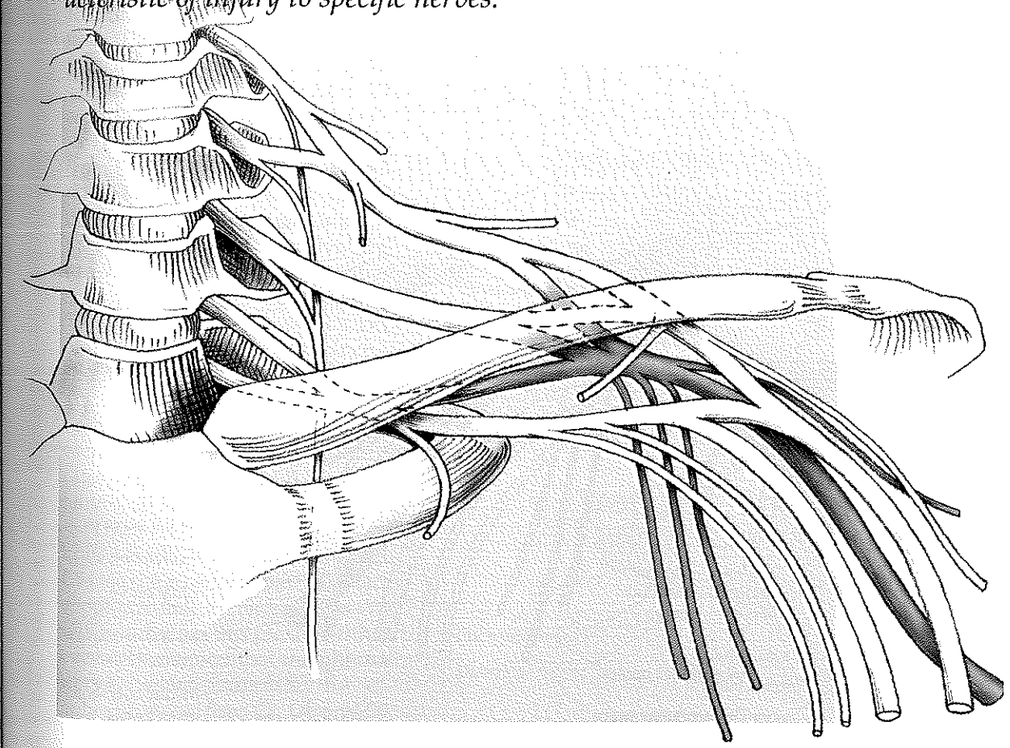

ANATOMICAL AND CLINICAL REVIEW

In this chapter we will discuss the functions of the brachial plexus, lumbosacral plexus, and nerve branches that arise from them. Knowledge of the motor and sensory territories of the spinal nerve roots (see Chapter 8), major plexuses, and peripheral nerves can be very useful clinically in identifying specific nerve lesions and in distinguishing them from lesions of the central nervous system. Disorders specifically affecting motor neurons were discussed in Chapter 6 (see KCC 6.7). Nerve roots and radiculopathies were discussed in Chapter 8, where we also introduced peripheral nerve and neuromuscular disorders in general (KCC 8.1). Here we will discuss the most important peripheral nerves in the upper and lower extremities, as well as common localized plexus and nerve syndromes.

Brachial Plexus and Lumbosacral Plexus

The **brachial plexus** is formed by nerve roots arising from the cervical enlargement at **C5, C6, C7, C8, and T1** (Figure 9.1). These nerve roots provide the major sensory and motor innervation for the upper extremities. The nerves of the brachial plexus are so clinically important that it is worth committing the structure of the brachial plexus to memory. A simplified schematic can be helpful in this regard (Figure 9.2). The parts of the brachial plexus can be remembered by this mnemonic: Robert (roots) Taylor (trunks) Drinks (divisions) Cold (cords) Beer (branches). It is also important to know the muscles innervated by each of the nerve branches (see Table 8.1). The five most clinically important nerve branches arising from the brachial plexus are the radial, median, ulnar, musculocutaneous, and axillary nerves (see the next section). A few more mnemonics may be helpful: The nerve branches of the posterior cord can be memorized with the mnemonic **STAR** or **ARTS** (Axillary, Radial, Thoracodorsal, Subscapularis). The muscles innervated by the musculocutaneous nerve are represented by the mnemonic **BBC** (Biceps, Brachialis, Coracobrachialis).

The **lumbosacral plexus** arises from **L1, L2, L3, L4, L5, S1, S2, S3, and S4** at the lumbosacral enlargement and provides innervation to the lower extremities and pelvis (Figure 9.3). Once again, a simplified schematic may be helpful (Figure 9.4). The muscles innervated by each of the lumbosacral nerve branches should be reviewed (see Table 8.1). The most clinically important nerve branches arising from the lumbosacral plexus are the femoral, obturator, sciatic, tibial, and peroneal nerves, as will be described shortly.

There is also a plexus formed by branches of CN XII and C1 through C5 called the **cervical plexus,** which supplies mainly the neck muscles. We will not discuss this plexus further, except to mention that the **phrenic nerve,** which supplies the diaphragm, arises from **C3, C4, and C5.**

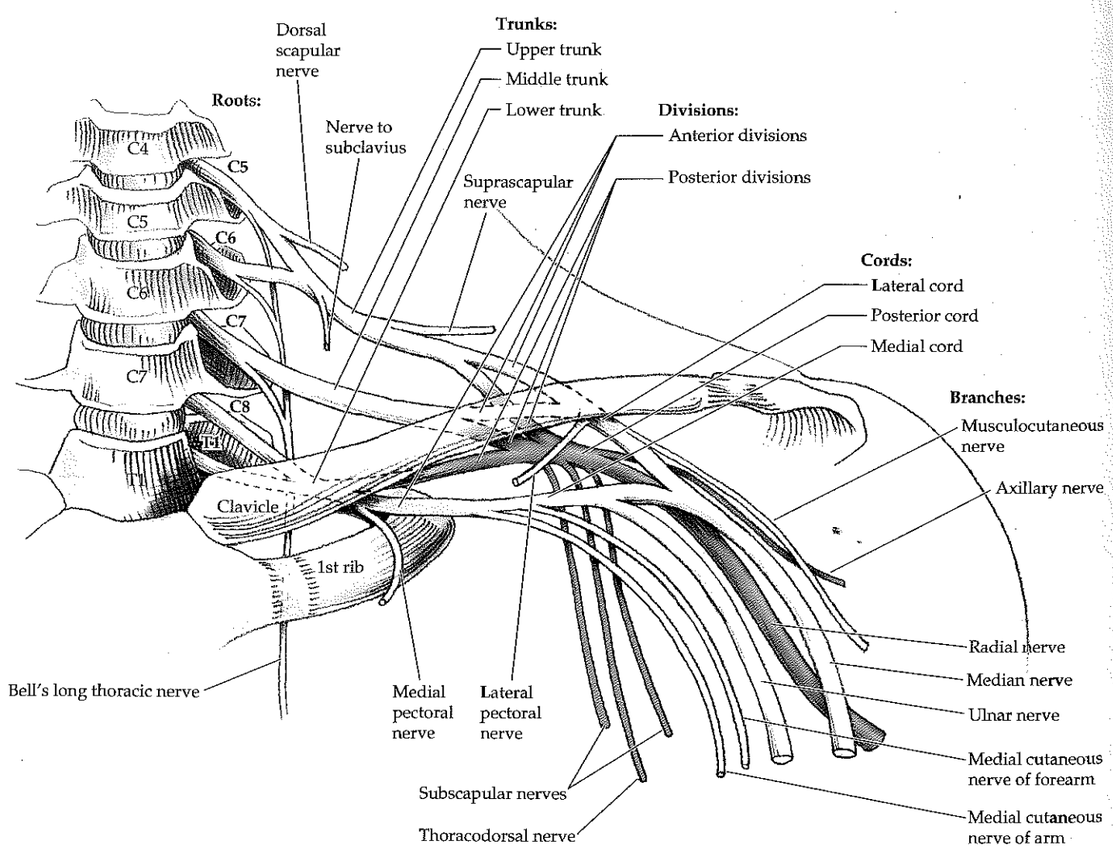

Figure 9.1 Brachial Plexus (After material supplied by M. O'Brien, Guy's and St. Thomas's Hospital, London.)

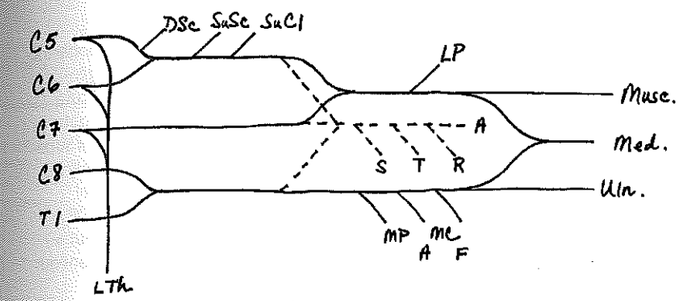

Figure 9.2 Brachial Plexus: Simplified Schematic DSc = dorsal scapular nerve; SuSc = suprascapular nerve; SuCl = nerve to subclavius; LP = lateral pectoral nerve; A = axillary nerve; R = radial nerve; T = thoracodorsal nerve; S = subscapular nerve; MP = medial pectoral nerve; MC,A = medial cutaneous nerve of arm; MC,F = medial cutaneous nerve of forearm; Musc. = musculocutaneous nerve; Med. = median nerve; Uln. = ulnar nerve.

MNEMONIC

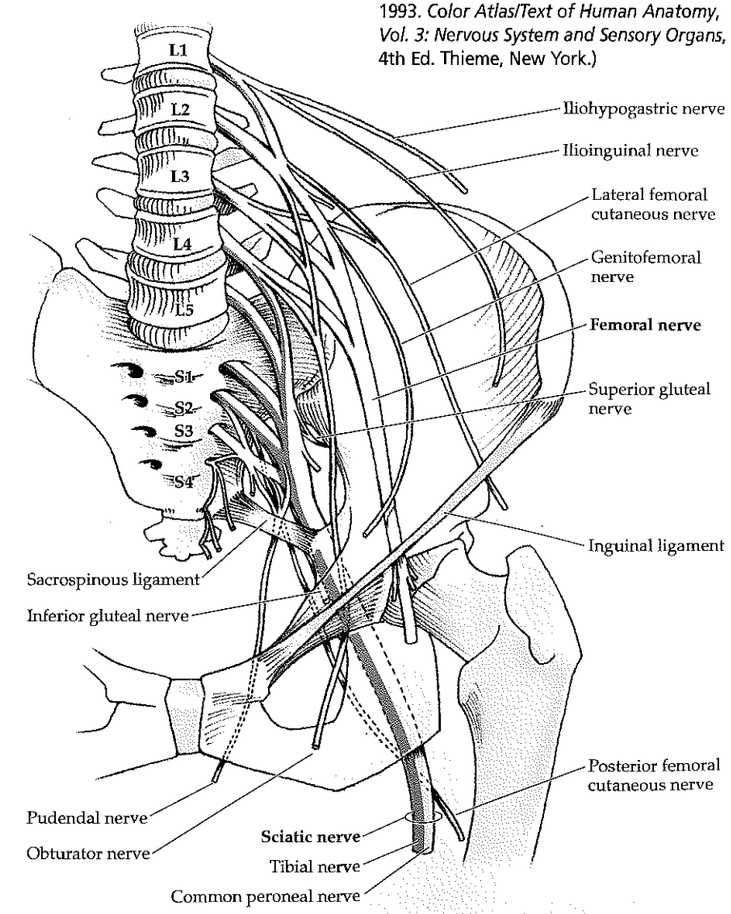

Figure 9.3 Lumbosacral Plexus (After Kahle W, Leonhardt H, Platzer W. 1993. *Color Atlas/Text of Human Anatomy, Vol. 3: Nervous System and Sensory Organs,* 4th Ed. Thieme, New York.)

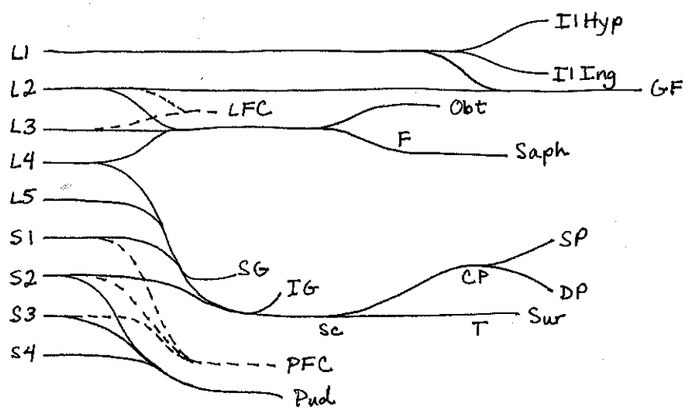

Figure 9.4 Lumbosacral Plexus: Simplified Schematic IIHyp = iliohypogastric nerve; IIIng = ilioinguinal nerve; GF = genitofemoral nerve; LFC = lateral femoral cutaneous nerve; F = femoral nerve; Obt = obturator nerve; Saph = saphenous nerve; SG = superior gluteal nerve; IG = inferior gluteal nerve; Sc = sciatic nerve; CP = common peroneal nerve; SP = superficial peroneal nerve; DP = deep peroneal nerve; T = tibial nerve; Sur = sural nerve; PFC = posterior femoral cutaneous nerve; Pud = pudendal nerve.

TABLE 9.1 Five Important Nerves in the Arm

NERVE	MOTOR FUNCTIONS	REGION OF SENSORY LOSS WITH NEUROPATHY
Radial nerve	Extension at all arm, wrist, and finger joints below the shoulder, forearm supination, thumb abduction in plane of palm	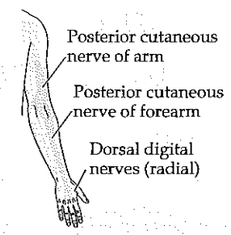
Median nerve	Thumb flexion and opposition, flexion of digits 2 and 3, wrist flexion and abduction, forearm pronation	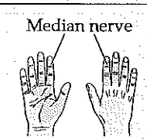
Ulnar nerve	Finger adduction and abduction other than thumb, thumb adduction, flexion of digits 4 and 5, wrist flexion and adduction	
Axillary nerve	Abduction of arm at shoulder beyond first 15°	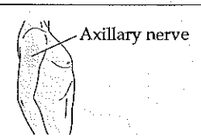
Musculocutaneous nerve	Flexion of arm at elbow, supination of forearm	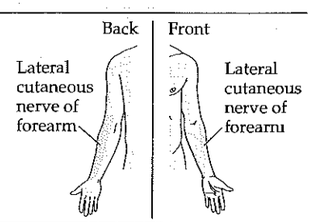

Regions of sensory innervation by cutaneous nerve branches are shown in Figure 9.5. The actual area of sensory loss following a nerve injury is somewhat smaller than the territories shown because of overlap from adjacent nerves. This should be compared to the dermatomal sensory distribution of nerve roots shown in Figure 8.4.

REVIEW EXERCISES

1. Practice drawing the simplified schematic of the brachial plexus shown in Figure 9.2.
2. Practice drawing the simplified schematic of the lumbosacral plexus shown in Figure 9.4.

Simplification: Five Nerves to Remember in the Arm

It is most clinically important to be familiar with the functions of the **radial, median, ulnar, axillary, and musculocutaneous nerves** in the arm. The motor and sensory functions of these nerves are summarized in Table 9.1 and are demonstrated on neuroexam.com Videos 54 and 55. Additional details are found in Table 8.1. In general, the radial nerve is important for extension of all joints in the arm and hand, the median nerve is important for the thumb side of the hand and wrist, and the ulnar nerve is important for the pinky side of the hand and wrist. Note that (1) the sensory territories shown here are smaller than in Figure 9.5 because adjacent nerves overlap somewhat, and (2) Table 9.1 shows regions of *sensory loss* with nerve injury rather than the whole region innervated by the nerve. Finger flexion is best tested at the distal interphalangeal joints (see neuroexam.com Video 55), where the flexor digitorum profundus (median nerve for digits 2 and 3; ulnar nerve for digits 4 and 5) acts without significant contributions from other muscles (Table 9.2).

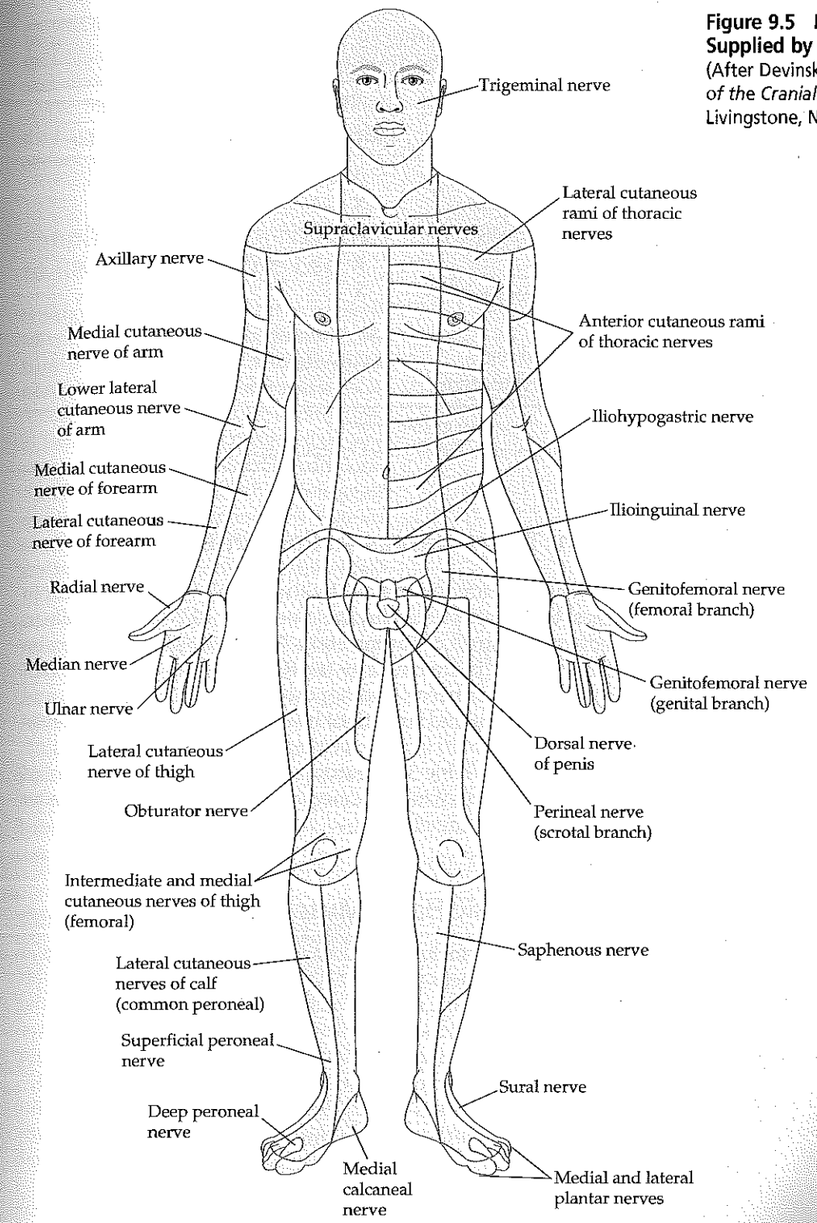

Figure 9.5 Regions of Sensory Innervation Supplied by Cutaneous Nerve Branches (After Devinsky O, Feldmann E. 1988. *Examination of the Cranial and Peripheral Nerves*. Churchill Livingstone, New York.)

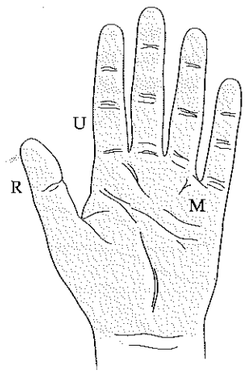

Figure 9.6 Three Nerves Acting on the Thumb The radial nerve abducts the thumb in the plane of the palm. The ulnar nerve adducts the thumb in the plane of the palm. The median nerve opposes the thumb. Note also that the abductor pollicis brevis (median nerve) abducts the thumb perpendicular to the plane of the palm (not shown).

TABLE 9.2 Muscles Contributing to Flexion and Extension at Finger Joints Other than the Thumb

	FLEXION[a]			EXTENSION[a]		
	MCP	PIP	DIP	MCP	PIP	DIP
Flexor digitorum profundus	X	X	**X**			
Flexor digitorum superficialis	X	**X**				
Flexor digiti minimi (fifth digit)	X					
Lumbricals	**X**				**X**	**X**
Palmar and dorsal interossei	X				X	X
Extensor digitorum				**X**	X	X
Extensor indicis (second digit)				X	X	X
Extensor digiti minimi (fifth digit)				X	X	X

Note: **Boldface** indicates the most important muscles.

[a]MCP, metacarpophalangeal joint; PIP, proximal interphalangeal joint; DIP, distal interphalangeal joint.

MNEMONIC

Simplification: Three Nerves Acting on the Thumb

Different thumb muscles are innervated by the radial, ulnar, and median nerves. It is easiest to remember these by the mnemonic RUM (**R**adial, **U**lnar, **M**edian), as shown in Figure 9.6. Thumb abduction in the plane of the palm (abductor pollicis longus) is mediated by the **R**adial nerve, adduction (adductor pollicis) by the **U**lnar nerve, and opposition (opponens pollicis) and flexion (flexor pollicis longus and superficial head of the flexor pollicis brevis) by the **M**edian nerve. It should also be recalled that thumb abduction perpendicular to the palm (see Table 3.4; neuroexam.com Video 55) is mediated by the abductor pollicis brevis, which is innervated by the median nerve after it passes through the carpal tunnel.

Intrinsic and Extrinsic Hand Muscles

The **intrinsic hand muscles** include the muscles of the **thenar eminence** at the base of the thumb (opponens pollicis, abductor pollicis brevis, flexor pollicis brevis, adductor pollicis), the muscles of the **hypothenar eminence** at the base of the pinky finger (opponens digiti minimi, abductor digiti minimi, flexor digiti minimi), the **lumbricals,** and the **interossei.** Intrinsic hand muscles are innervated by the ulnar nerve, except for the LOAF (**L**umbricals I and II, **O**pponens pollicis, **A**bductor pollicis brevis, **F**lexor pollicis brevis—superficial head) muscles, which are innervated by the median nerve after it passes through the carpal tunnel. All intrinsic hand muscles are supplied by **C8** and **T1** (see Table 8.1).

MNEMONIC

In addition to the intrinsic hand muscles, extrinsic muscles in the forearm are important for finger movements (see Table 8.1). Intrinsic and extrinsic muscles contributing to flexion and extension at finger joints other than the thumb are summarized in Table 9.2. As we have already mentioned, it should be clear from this table that the flexor digitorum profundus (median nerve for digits 2 and 3; ulnar nerve for digits 4 and 5) is best tested at the distal interphalangeal joints, since other muscles participate in flexion at the other joints. Similarly, the extensor digitorum (radial nerve and C7) is best tested at the metacarpophalangeal joints. See Tables 8.1 and 9.1 for muscles contributing to finger adduction, abduction, and opposition. Note, for example, that the **palmar interossei** adduct the fingers, while the **dorsal interossei** abduct them.

Simplification: Five Nerves to Remember in the Leg

It is most clinically important to be familiar with the functions of the **femoral, obturator, sciatic, tibial, and peroneal nerves** in the leg. The motor and sensory functions of these nerves are summarized in Table 9.3 and are demonstrated on neuroexam.com Videos 56 and 57. Additional details are found in Table 8.1. Note again that the sensory territories shown here are smaller than in Figure 9.5, since here we are interested in regions of sensory loss.

The tibial and common peroneal nerves are the two most important branches of the sciatic nerve. The **hamstring muscles** (semitendinosus, semimembranosus, and biceps femoris) are innervated by the sciatic nerve itself before it divides into the tibial and common peroneal nerves. The common peroneal nerve divides further to give rise to the **superficial and deep peroneal nerves** (see Figures 9.3, 9.4; Table 9.3).

REVIEW EXERCISES

1. Turn back to Tables 3.4–3.6 in Chapter 3, where we discussed strength and reflex testing (see also neuroexam.com Videos 54–58). In these tables, cover all columns except for the left-most column. For each action or reflex, list the appropriate muscle, nerves, and nerve roots being tested (refer to Table 8.1).

2. In Tables 9.1 and 9.3, cover the columns showing the regions of sensory loss and sketch the region of sensory loss for each of the five nerves in the arm and the leg.

TABLE 9.3 Important Nerves in the Leg

NERVE	MOTOR FUNCTIONS	REGION OF SENSORY LOSS WITH NEUROPATHY
Femoral nerve	Leg flexion at the hip, leg extension at the knee	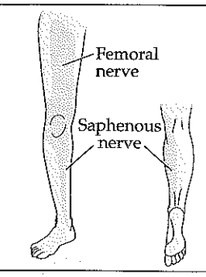
Obturator nerve	Adduction of the thigh	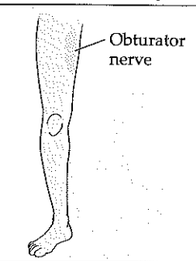
Sciatic nerve	Leg flexion at the knee (see also tibial and peroneal nerves below)	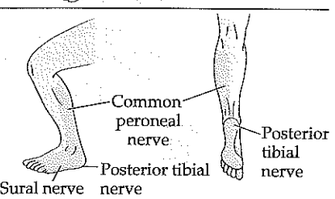
Tibial nerve	Foot plantar flexion and inversion, toe flexion	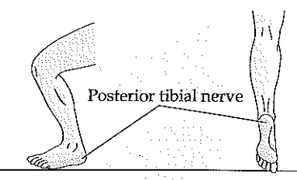
Superficial peroneal nerve	Foot eversion	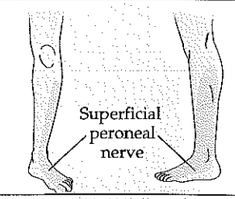
Deep peroneal nerve	Foot dorsiflexion, toe extension	

KEY CLINICAL CONCEPT
COMMON PLEXUS AND NERVE SYNDROMES

9.1 In Chapter 8, we introduced the general causes of neuropathy (see KCC 8.1). Here we will focus on clinical localization of common mononeuropathies and plexus syndromes caused by mechanical factors or diabetes. Note that in some cases trauma to a limb produces nerve injury, with the exact mechanism of such injury remaining unclear.

Upper-Extremity Nerve Injuries

Brachial Plexus, Upper Trunk Injury (Erb–Duchenne Palsy). Common causes include traction on an infant's shoulder during a difficult delivery and motorcycle accidents. Damage to the upper trunk of the brachial plexus (see Figures 9.1, 9.2) causes loss of function in C5- and C6-innervated muscles, resulting in prominent weakness of the deltoid, biceps, infraspinatus, and wrist extensors (see Table 8.1). The arm assumes a characteristic "bellman's tip" or "waiter's tip" pose, held at the side, internally rotated, and with the wrist flexed (Figure 9.7). Finger and hand movements are relatively spared. Most infants recover fully, but prognosis depends on the severity of the injury. Surgical repair of the plexus is occasionally pursued. Differential diagnosis includes traumatic avulsion of the C5 and C6 nerve roots, or other causes of a C5 and C6 radiculopathy (see KCC 8.3).

Brachial Plexus, Lower Trunk Injury (Klumpke's Palsy). Common causes include upward traction produced by grabbing a branch during a fall from a tree, thoracic outlet syndrome, and Pancoast's syndrome. Damage to the lower trunk of the brachial plexus (see Figures 9.1, 9.2) causes weakness of C8- and T1-innervated muscles, resulting in hand and finger extension weakness, and atrophy of the hypothenar muscles, together with sensory loss on the ulnar aspect of the hand and forearm. If the T1 nerve root is damaged proximal to the sympathetic trunk (see Figure 6.13), there may also be an associated Horner's syndrome (see KCC 13.5; see also Figure 13.10). Differential diagnosis includes ulnar neuropathy or C8–T1 radiculopathies.

In **thoracic outlet syndrome,** the lower brachial plexus is compressed as it passes between the clavicle and the first rib (see Figure 9.1). Symptoms may be increased by raising and external rotation of the arm, which may also decrease brachial arterial pulses. EMG and X-rays (looking for a cervical rib or other bony abnormalities) are important diagnostically. Treatments include exercises to strengthen shoulder muscles and surgical decompression for well-documented refractory cases. Treatment for equivocal cases has been a source of controversy.

In **Pancoast's syndrome,** an apical lung tumor (usually non-small cell carcinoma) extends into the lower brachial plexus. In addition to lower-plexus signs (sometimes including Horner's syndrome), the recurrent laryngeal nerve is occasionally involved as it loops downward into the thorax, producing hoarseness (see KCC 12.8). Ultimately, the entire brachial plexus may be invaded, producing a flail, insensate upper extremity.

Axillary Neuropathy. Dislocation or fracture of the proximal humerus can compress the axillary nerve, causing deltoid weakness and numbness in the shoulder (see Table 9.1). Differential diagnosis includes C5 radiculopathy, although axillary neuropathy does not involve the biceps, while C5 radiculopathy does.

Radial Neuropathy. Common causes include sleeping with the arm slung over a park bench ("Saturday night palsy"), compression in the axilla by improper crutch use ("crutch palsy"), or fracture of the humerus damaging the nerve as it travels in the spiral groove. There is weakness of all extensors of the arm, hand, and fingers below the shoulder, weakness of forearm supination, loss of the triceps reflex, and sensory loss in a radial nerve distribution (see Table 9.1). A **wrist drop** is often present (Figure 9.8A). The triceps may be spared, depending on how distal the lesion is in the arm. The posterior interosseous nerve is a purely motor branch of the radial nerve. Trauma or entrapment of the posterior interosseous nerve results in weakness of radial nerve–innervated muscles sparing the triceps (see Table 8.1) and with no sensory loss. Tight wrist bands or handcuffs can sometimes compress the superficial branch of the radial nerve, causing isolated sensory loss in the dorsal lateral hand.

Figure 9.7 "Bellman's" or "Waiter's Tip" Pose Assumed in Upper-Plexus Lesions

Median Neuropathy. Causes include sleeping with a lover's head resting on the upper arm ("honeymooner's palsy"). Fractures of the humerus or distal radius can occasionally injure the median nerve. In addition, entrapment (see KCC 8.1) can occur as the nerve passes through the pronator teres muscle in the forearm. There is weakness of wrist flexion and abduction, opposition of the thumb, and flexion of the second and third digits, together with sensory loss in a median nerve distribution (see Table 9.1). In an attempt to make a fist, the hand may assume a "preacher's hand" or "orator's hand" pose (see Figure 9.8B).

Carpal Tunnel Syndrome. This common entrapment syndrome is caused by compression of the median nerve as it passes together with the tendons of the hand under the flexor retinaculum on the flexor surface of the wrist. It is seen most often in women over age 30 and can be associated with activities such as typing or housepainting that can cause repetitive stress injury, edema, and inflammation in the wrist. Other causes include pregnancy, oral contraceptives, hypothyroidism, arthritis, wrist fracture, acromegaly, uremia, diabetes, and amyloidosis. Recall that after the median nerve passes through the carpal tunnel, it innervates the LOAF (Lumbricals I and II, Opponens pollicis, Abductor pollicis brevis, Flexor pollicis brevis—superficial head) muscles. The best muscle to test in suspected carpal tunnel syndrome is the abductor pollicis brevis, which abducts the thumb perpendicular to the plane of the palm (neuroexam.com Video 55), although thumb flexion and opposition (see Figure 9.6) may also be weak. Symptoms often include sensory loss in the first, second, and third digits, as well as prominent paresthesias (see KCC 7.1) that are most bothersome at night and can sometimes radiate into the upper arm. Patients often report shaking the hand to try and relieve symptoms (flick sign). In advanced cases, thenar atrophy may be present. Wrist flexion, flexion of the second and third digits, and sensation over the thenar eminence are typically spared, since nerves providing these functions branch off proximal to the carpal tunnel.

Differential diagnosis of carpal tunnel syndrome includes radiculopathy of C6 and C7, or compression of the median nerve proximal to the carpal tunnel, although these conditions usually include more proximal symptoms. Tests to provoke paresthesias in a median nerve distribution may be helpful, but they are not very sensitive or specific. These include Tinel's sign, in which the median nerve is percussed in the carpal tunnel, and Phalen's sign, in which the dorsal surfaces of the hands are pressed together, flexing the wrists for about 1 minute. Treatments include immobilization by a removable wrist splint, steroid injections, and surgical decompression of the carpal tunnel.

Ulnar Neuropathy. The medial epicondyle of the elbow carries the name "funny bone" because mild trauma to the ulnar nerve as it passes over the

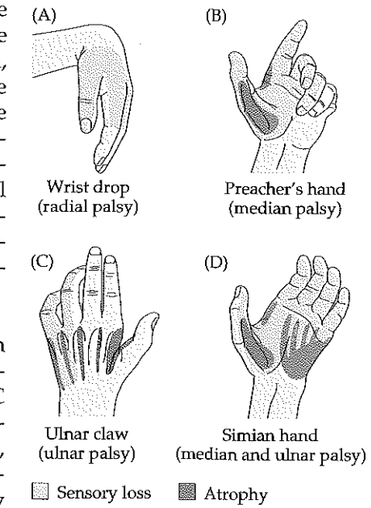

Figure 9.8 Classic Hand Poses in Lesions of the Radial, Median, and Ulnar Nerves (A) "Wrist drop" in radial nerve lesions, resulting from weakness of wrist extensors. (B) "Preacher's hand" or "orator's hand" in proximal median nerve lesions, resulting from weakness of the hypothenar and first two flexor digitorum profundus muscles when the patient is asked to make a fist. (C) "Ulnar claw" in chronic ulnar nerve lesions, resulting from weakness of the lumbricals (see Table 9.2) for digits 4 and 5. (D) "Simian hand" in chronic median plus ulnar nerve lesions, resulting from thenar and hypothenar atrophy and loss of thumb opposition.

MNEMONIC

elbow in the **ulnar groove** (between the olecranon and medial epicondyle) produces transient paresthesias (see KCC 7.1) in an ulnar distribution. A common cause of ulnar neuropathy is entrapment (see KCC 8.1) at the elbow in the cubital canal, which lies in the region of the ulnar groove. This condition is sometimes called tardy ulnar palsy, a delayed result of a posttraumatic, degenerative, or congenital increased carrying angle at the elbow. The ulnar nerve can also be damaged acutely by fractures of the medial epicondyle, or it may be compressed by a habit of resting the elbows on a hard table.

Findings include weakness of wrist flexion and adduction, finger adduction and abduction, and flexion of the fourth and fifth digits, together with sensory loss and paresthesias in an ulnar distribution (Table 9.1). As with most neuropathies, motor findings may be absent in mild cases. Severe cases may include atrophy and fasciculations in the hypothenar eminence. Because of weak lumbricals at the fourth and fifth digits, these fingers may assume a characteristic "ulnar claw" posture (see Figure 9.8C). Differential diagnosis includes C8 and T1 radiculopathy, Pancoast's syndrome, thoracic outlet syndrome, or other lesions of the brachial plexus inferior trunk or medial cord (see Figures 9.1, 9.2). Unlike ulnar neuropathy, these conditions sometimes produce a Horner's syndrome, sensory changes in the T1 dermatome of the upper medial arm (see Figure 8.4), or involvement of hand muscles innervated by the median nerve. Entrapment in the cubital canal at the elbow can be treated surgically by translocation of the ulnar nerve to the flexor side of the elbow.

Compression of the ulnar nerve in the hand as it passes over the hamate bone in Guyon's canal can occur from prolonged leaning forward while cycling. The result is weakness of finger adduction and abduction without sensory loss because the cutaneous branches of the ulnar nerve are given off more proximally.

Combination of chronic median and ulnar nerve lesions leads to thenar and hypothenar atrophy with lack of thumb opposition, resulting in a "simian hand" or "monkey's paw" (see Figure 9.8D).

Lower-Extremity Nerve Injuries

Femoral Neuropathy. The femoral nerve can occasionally be injured during pelvic surgery or compressed by a retroperitoneal hematoma or pelvic mass. Abnormalities include weakness of thigh flexion and knee extension, loss of the patellar reflex, and sensory loss in the anterior thigh (Table 9.3). Differential diagnosis includes L3 or L4 radiculopathy. L3 or L4 radiculopathy, however, may include weakness of thigh adduction (obturator nerve), whereas this feature is not associated with femoral neuropathy (see Table 8.1).

Sciatic Neuropathy. Causes of sciatic neuropathy include posterior hip dislocation, acetabular fracture, and intramuscular injection placed too medially and inferiorly in the buttocks. There is weakness of all foot and ankle muscles and of knee flexion, loss of the Achilles tendon reflex, and sensory loss in the foot and lateral leg below the knee (Table 9.3). Differential diagnosis includes lesions in the foot area of the motor cortex (see KCC 6.3; Figure 6.14).

The term "sciatica" is vague and refers to all disorders causing painful paresthesias in a sciatic distribution. The most common cause is compression of lumbosacral roots by disc material and osteophytes (see KCC 8.3). Rarely, the sciatic nerve may be compressed more distally by muscular or skeletal elements.

Peroneal Nerve Palsy. As the common peroneal nerve passes around the fibular head near the skin surface, it is vulnerable to laceration, stretch injury by forcible foot inversion, or compression by tight stockings, a cast, crossed legs, or trauma. In peroneal nerve palsy, there is "foot drop" with weakness of foot dorsiflexion and eversion, and sensory loss over the dorsolateral foot and shin. Most patients recover spontaneously when the mechanical cause is removed. A foot brace may improve function if foot drop is significant. Differential diagnosis includes L5 radiculopathy. However, L5 radiculopathy includes weakness of foot dorsiflexion, eversion, and inversion, while in peroneal palsy, foot inversion is normally spared because this function can be carried out by the tibialis posterior (innervated by the tibial nerve) (Table 9.3; see also Table 8.1).

Meralgia Paresthetica. The lateral femoral cutaneous nerve (which originates in L2 and L3; Figures 9.3 and 9.4) can be entrapped as it passes under the inguinal ligament or fascia lata producing paresthesias and loss of sensation in the lateral thigh (Figure 9.5). This entrapment syndrome includes no motor involvement or reflex changes. Common causes include obesity, pregnancy, weight loss, or heavy equipment belts, and symptoms may be worse after prolonged walking, standing, or sitting. Differential diagnosis includes L2 or L3 radiculopathy, although unlike meralgia paresthetica, these conditions usually include motor changes or decreased patellar reflex. Symptoms most often resolve spontaneously or by avoidance of mechanical precipitants; however, surgical decompression is occasionally attempted in refractory cases.

Morton's Metatarsalgia. Tight-fitting shoes can compress the digital nerves, especially of the third and fourth toes, producing patches of numbness and paresthesias.

In conclusion, familiarity with the patterns of sensory and motor loss in the common plexus and in the nerve syndromes discussed in this section, as well as those seen in radiculopathies (see KCC 8.3) and other disorders of nerves, muscles, and the neuromuscular junction (see KCC 8.1), can greatly aid in localizing neurological deficits and in distinguishing disorders of the peripheral and central divisions of the nervous system. When the diagnosis remains uncertain, electrodiagnostic tests can often be helpful, as discussed in the next section. ■

KEY CLINICAL CONCEPT
ELECTROMYOGRAPHY (EMG) AND NERVE CONDUCTION STUDIES

9.2 Electromyography (EMG) and nerve conduction studies are valuable diagnostic tools that can help localize and determine the causes of nerve and muscle disorders. In **nerve conduction studies,** stimulating electrodes are placed on the skin overlying a nerve, and recording electrodes are placed either at a different point along the same nerve or overlying a muscle innervated by the nerve (Figure 9.9A–C). When a stimulus is given to the nerve, a **compound motor action potential (CMAP)** can be recorded over the belly of a muscle innervated by that nerve, resulting from the summated electrical activity of muscle cells (see Figure 9.9D). If a distal nerve branch with purely sensory function is used for recording or stimulation, and a second set of stimulating or recording electrodes is placed somewhere along the nerve, a **compound sensory nerve action potential (SNAP)** can be recorded over the nerve, resulting from summated electrical activity in the sensory neuron axons of the nerve.

Lesions proximal to the dorsal root ganglia will leave the cell bodies and distal axons of sensory neurons intact (see Figure 8.1B). Therefore, SNAPs will be preserved. In contrast, proximal lesions of motor nerve roots will cause degeneration of the distal motor neuron axons, reducing or abolishing CMAPs. There are standard values for SNAP and CMAP latencies or conduction velocities for each major nerve when stimulated at various points along its course. These values allow nerve conduction studies to be used to determine if there is evidence for slowed nerve conduction—for example, in the case of **demyelination** (see

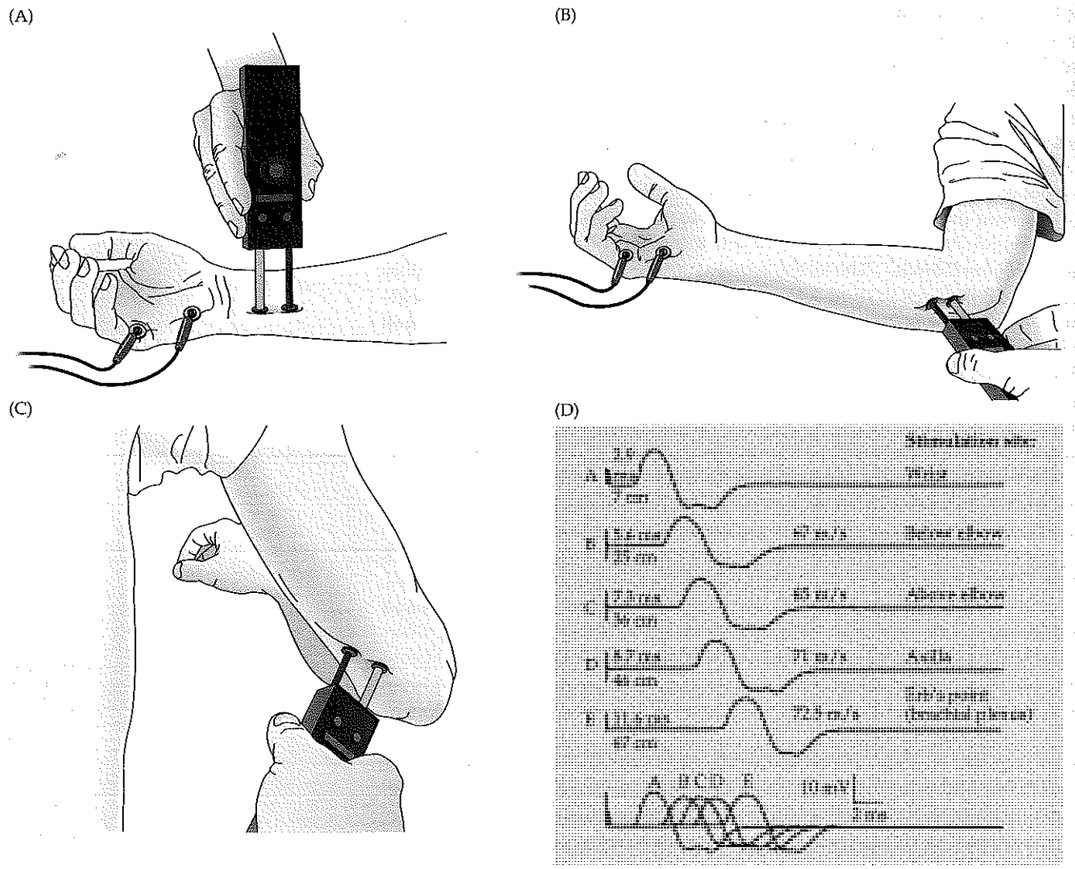

Figure 9.9 Nerve Conduction Study
The compound motor action potential (CMAP) of the ulnar nerve was recorded in this normal example at several stimulus locations. (A) Stimulation of the ulnar nerve at the wrist, and recording of CMAP from the abductor digiti quinti in the hypothenar eminence. (B) Ulnar nerve stimulation just distal to the ulnar groove. (C) Ulnar nerve stimulation just proximal to the ulnar groove. (D) CMAP recordings for different stimulation sites. For each trace, the distance from the recording electrode (in centimeters) and the latency to CMAP onset (in milliseconds) are indicated to the left. Conduction velocities between adjacent stimulation sites (in meters per second) were calculated by dividing the distance between the two stimulation sites by the difference in motor latencies for the two sites. (After Rajesh KS, Thompson LL. 1989. *The Electromyographer's Handbook*, 2nd Ed. Little, Brown, Boston.)

KCC 8.1). In addition, there are standard values for SNAP amplitudes. Decreased SNAP amplitudes suggest that conduction in some axons of the nerve has been interrupted, as is the case in **axonal damage.**

CMAP studies can be used to evaluate the function of the neuromuscular junction by the use of **repetitive stimulation.** Slow repetitive stimulation (2–3 Hz) depletes presynaptic stores of acetylcholine; faster repetitive stimulation (>5 Hz) increases presynaptic calcium, facilitating neurotransmitter release. Under normal conditions, repetitive stimulation does not significantly affect CMAP amplitude because there is a "safety factor," meaning that every presynaptic action potential results in a postsynaptic potential well above the threshold needed to produce a muscle cell action potential. Under pathologic conditions, however, failures in neuromuscular transmission occur. Therefore, for example in **myasthenia gravis** (see KCC 8.1), in which there is a decrease in postsynaptic acetylcholine receptors on muscle cells, slow repetitive stimulation results in a gradual **decrement** in CMAP amplitude. Decrement of >10% is considered abnormal. In **Lambert–Eaton myasthenic syndrome,** in which there is decreased presynaptic neurotransmitter release, fast repetitive stimulation (or active volitional muscle contraction) causes CMAPs to **increment** in amplitude from an abnormally low starting point.

In **electromyography (EMG)**, an electrode is inserted directly into a muscle, and motor unit action potentials (MUPs) are recorded from muscle cells. The EMG pattern provides information useful in distinguishing weakness caused by **neuropathic disorders** (nerve or motor disease) from that caused by **myopathic disorders** (muscle disease). In neuropathic disorders, **increased spontaneous activity** (fibrillation potentials and positive sharp waves) often is recorded on EMG, and is sometimes also visible on physical examination as **fasciculations** (see KCC 6.1). Fasciculations and other forms of spontaneous activity can occur due to chronic deinnervation of muscle cells. Deinnervation also causes adjacent motor axons to prout and reinnervate a larger region, resulting in abnormally large motor units (a motor unit consists of all the muscle cells innervated by a single motor neuron axon). Therefore, with neuropathic disorders, MUPs are of abnormally large amplitude and duration. Reduced MUP amplitude and duration suggests a **myopathic** disorder is present.

When a muscle is voluntarily contracted, the EMG normally shows a pattern of continuous firing of motor units referred to as a normal **recruitment pattern**. In neuropathic disorders, the recruitment pattern has normal amplitude but shows interrupted firing, since some motor units are not successfully activated. This phenomenon is referred to as decreased, reduced, or incomplete recruitment. In myopathic disorders, the recruitment pattern is continuous or even increased (since more motor units need to be activated for a given force), but the applitude is often decreased. ■

CLINICAL CASES

CASE 9.1 COMPLETE PARALYSIS AND LOSS OF SENSATION IN ONE ARM

CHIEF COMPLAINT
A 60-year-old man with a history of lung cancer gradually developed severe pain, weakness, and numbness in his right arm.

HISTORY
The patient smoked for 34 years. Two years ago he was diagnosed with lung cancer and underwent a right upper-lobe lung resection followed by radiation and chemotherapy. Six months ago he developed shooting **pain and swelling of the right arm.** He gradually **lost all strength and sensation in the entire right arm up to the shoulder** but continued to have severe burning pain. Past medical history was notable for right eye surgery following an assault with a baseball bat 20 years ago.

PHYSICAL EXAMINATION
Vital signs: T = 99.4°F, P = 110, BP = 130/80.
Neck: Supple; no tenderness.
Lungs: Clear.
Heart: Regular rate with no murmurs, gallops, or rubs.
Abdomen: Normal bowel sounds; soft, no masses.
Extremities: Right arm swollen, with two firm 5 cm discolored masses—one in the right axilla and one in the upper right chest wall. Also marked clubbing of the fingers bilaterally.
Neurologic exam:
MENTAL STATUS: Alert and oriented × 3.
CRANIAL NERVES: Intact, except for the right eye, which had an irregular pupil and diminished vision in both the lateral and medial fields.
MOTOR: Normal tone except for the **right arm,** which was **flaccid.** 5/5 power throughout, except for **0/5 power in the right shoulder, arm, and hand.**
REFLEXES:

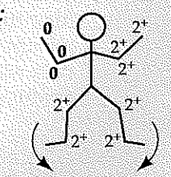

COORDINATION: Normal on finger-to-nose (except unable to test right arm) and heel-to-shin testing.
GAIT: Normal.

CASE 9.1 *(CONTINUED)*

SENSORY: **Absent light touch, pinprick, and vibration sense in the entire right arm up to the deltoid** (Figure 9.10). Sensation otherwise normal.

LOCALIZATION AND DIFFERENTIAL DIAGNOSIS

1. On the basis of the symptoms and signs shown in **bold** above, where is the lesion?
2. What is the most likely diagnosis?
3. This patient had an abnormal right eye due to prior trauma. If his right eye had been normal previously, what additional finding might be present on exam that would help with the localization?

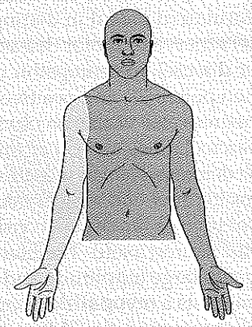

Figure 9.10 Region of Sensory Loss Compare to Figures 8.4 and 9.5.

Discussion

1. The key symptoms and signs in this case are:
   - **Paralysis, with decreased tone and absent reflexes in the entire right arm and hand**
   - **Absent light touch, pinprick, and vibration sense in the entire right arm up to the deltoid**
   - **Pain and swelling in the right arm**

   Weakness in one arm can be caused by peripheral nerve lesions or by lesions in the arm region of the motor cortex (see KCC 6.3; Figure 6.14E). However, it is unlikely that a cortical lesion would produce complete paralysis and sensory loss in the entire arm ending sharply at the shoulder, with no face or leg weakness at all. In addition, no single peripheral nerve lesion could produce this pattern. Therefore, the lesion must involve the entire right brachial plexus, or all right-sided nerve roots from C5 through T1.
2. The history of right apical lung tumor supports the possibility of a lesion invading the right brachial plexus from below (see the description of Pancoast's syndrome in KCC 9.1), as does the presence of swelling in the arm, suggesting obstruction of venous return.
3. A lesion of the proximal portion of the lower brachial plexus involving the T1 nerve root can cause a Horner's syndrome (see Figures 6.13, 13.10; KCC 13.5). This condition could be difficult to appreciate in this patient because of his prior history of right eye trauma.

Clinical Course and Neuroimaging 3-T

A **brachial plexus MRI** (Figure 9.11) showed extensive invasion of the apical lung mass into the region of the right brachial plexus. The cancer in this patient, unfortunately, was no longer amenable to treatment. However, his pain was managed by a multidisciplinary team using oral, intravenous, and epidural medications to provide adequate pain relief.

CASE 9.2 A NEWBORN WITH WEAKNESS IN ONE ARM

MINICASE

A 3-week-old infant girl was brought to the pediatrician because of left arm weakness. She was born at 42 weeks (2 weeks past the due date) weighing 10 pounds 11 ounces, and the delivery was complicated by shoulder dystocia (difficulty delivering the shoulder) resulting in significant traction on the left neck and shoulder during delivery. Left arm weakness was noted at birth that improved slightly but was still present at the appointment. Exam was normal except for the **left upper extremity,** which had **decreased tone and lay internally rotated at the infant's side with decreased spontaneous movements. She did not abduct the left arm or flex it at the elbow,** but did have spontaneous opening and closing of the hand with normal grip strength, normal elbow extension, and some wrist flexion. **The left biceps reflex was absent,** and other reflexes were 2^+ throughout.

LOCALIZATION AND DIFFERENTIAL DIAGNOSIS

On the basis of the symptoms and signs shown in **bold** above, where is the lesion? What is the most likely diagnosis?

Discussion

The key symptoms and signs in this case are:

- **Weakness of left arm external rotation, abduction, and elbow flexion, with decreased tone and absent biceps reflex**

The patient has typical findings consistent with a left brachial plexus upper trunk injury (Erb–Duchenne palsy), affecting C5 and C6 innervated muscles, caused by left shoulder traction at birth (KCC 9.1).

Clinical Course

A physical therapy program was initiated to preserve range of motion during recovery. At age 7 weeks the patient was able to lift her arm off the table and had some external rotation of the arm, as well as slight spontaneous elbow flexion. The left biceps reflex was still absent. By age 4 months she was able to reach for objects well with either hand, although she preferred to use her right hand, and she had $4^+/5$ left biceps strength when pulled to a seated position. Continued improvement was anticipated.

CASE 9.3 A BLOW TO THE MEDIAL ARM CAUSING HAND WEAKNESS AND NUMBNESS

MINICASE

A 38-year-old alcoholic man was seen to fall, catching his right arm on a garbage can. He was brought to the emergency room. He had an **abrasion and tenderness of the right upper medial arm.** Neurologic exam was normal except for **4/5 strength of right thumb opposition, second and third finger flexors, and wrist flexion and abduction.** There was also **decreased pinprick and light touch sense along the lateral surface of the right hand and first, second, and third fingers** (Figure 9.12).

LOCALIZATION AND DIFFERENTIAL DIAGNOSIS

On the basis of the symptoms and signs shown in **bold** above, where is the lesion? What is the most likely diagnosis?

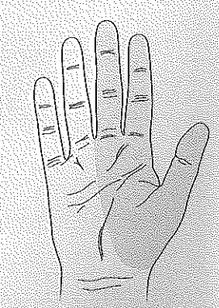

Figure 9.12 Region of Sensory Loss

Discussion

The key symptoms and signs in this case are:

- **Weakness of right thumb opposition, second and third finger flexors, and wrist flexion and abduction**
- **Decreased pinprick and light touch sense along the lateral surface of the right distal forearm, hand, and first, second, and third fingers**
- **Abrasion and tenderness of the right upper medial arm**

The pattern of weakness and sensory loss in this patient is consistent with a median nerve injury (Table 9.1; Figure 9.5; see also Table 8.1). The most likely cause is compression of the nerve in the upper medial arm, as evidenced by the tenderness in this area and the mechanism of injury.

Clinical Course

X-rays of the right arm revealed no fractures. The patient was discharged from the emergency room and did not return for follow-up.

CASE 9.1 COMPLETE PARALYSIS AND LOSS OF SENSATION IN ONE ARM

Figure 9.11 Right Apical Lung Cancer Extending into the Region of the Brachial Plexus T1-weighted coronal MRI scan of the chest.

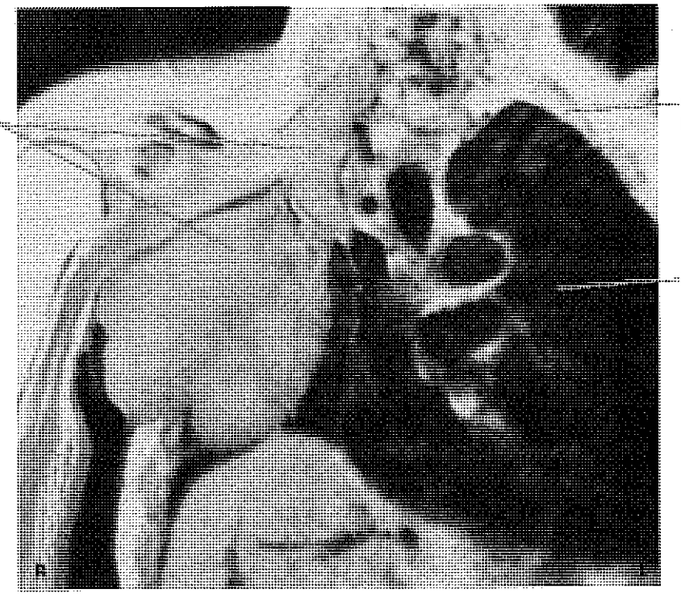

CASE 9.4 NOCTURNAL PAIN AND TINGLING IN THE THUMB, POINTER, AND MIDDLE FINGER

MINICASE

A 38-year-old man who works in a cola factory developed **pain and tingling in his right thumb, index, and middle fingers** over the past 2 months that occasionally radiates into the right arm and forearm. His symptoms are worse at night or when the arm is relaxed. He has also noticed some **decreased sensation of the fingertips of the same fingers** while buttoning his shirt. Exam was notable only for obesity and **4+/5 weakness of the right opponens pollicis and decreased pinprick sensation in the palmar aspect of the right first, second, and third fingers, sparing the thenar area** (Figure 9.13). Tinel's and Phalen's signs were not present.

LOCALIZATION AND DIFFERENTIAL DIAGNOSIS

On the basis of the symptoms and signs shown in **bold** above, where is the lesion? What is the most likely diagnosis?

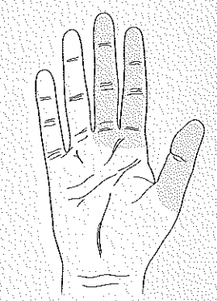

Figure 9.13 Region of Sensory Loss

Discussion

The key symptoms and signs in this case are:

- **Mild weakness of the right opponens pollicis**
- **Pain, tingling, and decreased pinprick sensation in the palmar aspect of the right first, second, and third fingers, sparing the thenar area**

The opponens pollicis is supplied by the median nerve (Table 9.1; see also Table 8.1). The fact that wrist flexion and abduction are spared, as is sensation over the thenar area, suggests a lesion of the median nerve after the branch to the flexor carpi radialis and the palmar cutaneous branch are given off, such as in the carpal tunnel (see KCC 9.1). Carpal tunnel syndrome of the right wrist is thus the most likely diagnosis. Other, less likely possibilities include a mild right C6 and C7 radiculopathy or a more proximal right median nerve lesion.

Clinical Course

Thyroid function tests and routine blood chemistries were normal. The patient was given a removable splint to hold his wrist in slight extension at night, and his symptoms gradually improved.

CASE 9.5 HAND AND WRIST WEAKNESS AFTER A FALL

MINICASE

A 20-year-old male waiter tripped while working at a restaurant and broke his fall by extending his left hand onto a table. That night he had pain in his left arm that resolved by the next day, but he then noticed **weakness of the left hand and wrist** and came to the emergency room. Exam was normal except for **3/5 strength in the left wrist extensors, finger extensors, and thumb abduction in the plane of the palm, and 4/5 strength in forearm supination.** Strength in all other muscles was intact, as was sensation.

LOCALIZATION AND DIFFERENTIAL DIAGNOSIS

On the basis of the symptoms and signs shown in **bold** above, where is the lesion? What is the most likely diagnosis?

Discussion

The key symptoms and signs in this case are:

- **Weakness of left forearm supination, wrist extensors, finger extensors, and abduction of the thumb in the plane of the palm**

These muscles are all supplied by the radial nerve (Table 9.1; see also Table 8.1). In particular, the facts that the triceps was spared and that there was no sensory loss suggest a lesion of the posterior interosseous nerve, a purely motor branch of the radial nerve. The posterior interosseous branch of the radial nerve was apparently injured during the fall, with the exact mechanism being unclear (see KCC 9.1).

Clinical Course

X-rays of the left arm did not reveal a fracture. The patient was given a splint to avoid developing contracture deformities and was followed by an occupational therapist as his strength gradually recovered. An EMG done 2 months after the injury was consistent with a lesion of the left radial nerve distal to the fibers innervating the triceps. By 4 months after the injury, strength had returned to $4^+/5$ in the affected muscles and was continuing to improve gradually. (Note: In posterior interosseous nerve injuries, the extensor carpi radialis is usually spared, so extension of the wrist in the radial direction is preserved. This was not tested for in this case.)

CASE 9.6 NUMBNESS AND TINGLING IN THE PINKY AND RING FINGER

MINICASE

A 32-year-old computer programmer developed 2 months of worsening **tingling and numbness in his left fifth digit, in the medial aspect of his left fourth digit, and along the medial surface of his left hand and forearm.** The symptoms were worse upon awakening in the morning and were exacerbated after resting his elbows on a hard surface. Exam was normal except for **4/5 strength in left fifth finger abduction, and decreased pinprick sensation in the left fifth digit and the medial half of the left fourth digit** (Figure 9.14). Symptoms were not worsened by arm abduction plus elevation.

LOCALIZATION AND DIFFERENTIAL DIAGNOSIS

On the basis of the symptoms and signs shown in **bold** above, where is the lesion? What is the most likely diagnosis?

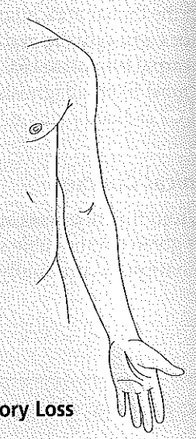

Figure 9.14 Region of Sensory Loss

Discussion

The key symptoms and signs in this case are:

- **Weakness of left fifth finger abduction**
- **Paresthesias and decreased pinprick sensation in the left fifth digit and the medial half of the left fourth digit**

The sensory and motor deficits in this patient could be caused by mild dysfunction in the ulnar nerve, the brachial plexus lower trunk (e.g., thoracic outlet syndrome), the brachial plexus medial cord, or the C8 or T1 nerve roots (Table 9.1; KCC 9.1; see also Table 8.1). The fact that the symptoms are worse after pressure on the elbow, are not accompanied by neck pain (common in cervical radiculopathy; see KCC 8.3), and are not exacerbated by arm abduction plus elevation (characteristic of thoracic outlet syndrome) suggests, but does not prove, that the ulnar nerve is the culprit.

Clinical Course

Nerve conduction studies (see KCC 9.2; Figure 9.9) were normal except in the ulnar nerves. To measure conduction velocity in the ulnar nerve, a recording electrode was placed on the skin over the belly of the abductor digiti minimi muscle, and a stimulating electrode was placed on the skin at various points on the arm over the course of the ulnar nerve. When a stimulus was given to the nerve, a compound motor action potential (CMAP) could be recorded over the muscle. Distal conduction velocity in this patient was normal when the ulnar nerve was stimulated below the medial epicondyle of the elbow, but was decreased when the ulnar nerve was stimulated just above the elbow, suggesting a conduction problem at the elbow.

The nerve conduction studies showed that both ulnar nerves were affected, although only the left one had produced symptoms. Nerve conduction studies of the median nerves were normal bilaterally. The patient was given elbow pads to wear while sleeping or while working at the computer, and he was instructed to avoid resting on his elbows. Two months later his paresthesias had improved markedly, strength in his finger abductors was normal, and he had only mildly decreased sensation in a left ulnar distribution.

CASE 9.7 UNILATERAL THIGH PAIN, WEAKNESS, AND NUMBNESS IN A DIABETIC

MINICASE

A 45-year-old man spent several weeks in the intensive care unit for diabetic ketoacidosis and severe bilateral pneumonia. When he finally stabilized and was transferred to a regular hospital floor, he noticed **weakness and numbness in the left leg, with numbness and tingling over the anterior thigh down to the medial calf above the foot.** A neurology consult was called, and on exam he had **4/5 strength in the left iliopsoas and quadriceps,** with preserved strength in all other muscle groups, including the thigh adductors. There was **decreased pinprick sensation in the left anterior thigh and medial calf** (Figure 9.15). Reflexes were normal and symmetrical except for an **absent left patellar reflex.**

LOCALIZATION AND DIFFERENTIAL DIAGNOSIS

On the basis of the symptoms and signs shown in **bold** above, where is the lesion? What is the most likely diagnosis?

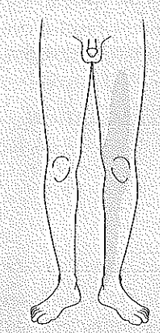

Figure 9.15 Region of Sensory Loss

Discussion

The key symptoms and signs in this case are:

- **Weakness of the left iliopsoas and quadriceps with absent patellar reflex**
- **Paresthesias and decreased pinprick sensation in the left anterior thigh and medial calf**

The pattern of weakness, reflex loss, and sensory changes in this patient could be caused by an L4 radiculopathy or a femoral neuropathy (Table 9.3; see also Tables 8.1, 8.6; Figure 8.4). The fact that thigh adduction is spared suggests a femoral neuropathy, since L4 contributes significantly to both the obturator and femoral nerves. The most likely diagnosis is left femoral neuropathy caused by diabetes (see KCC 8.1, 9.1). Less likely, insertion of a femoral vein catheter during the patient's stay in the intensive care unit may have caused an undetected hematoma compressing the femoral nerve. Compare this case to Case 8.9.

Clinical Course

The patient gradually recovered strength in the left leg. When seen 1 year later, he had 5/5 power in all muscle groups, but he had persistent sensory loss in a left femoral nerve distribution and an absent left patellar reflex.

CASE 9.8 TINGLING AND PARALYSIS OF THE FOOT AFTER A FALL

CHIEF COMPLAINT
A 30-year-old woman presented to the emergency room after a fall with **tingling and paralysis of the right foot.**

HISTORY
Two days ago the patient slipped on a wet floor in the supermarket and fell backward, landing on her back. She initially noticed no symptoms, but she awoke at 3:00 am to feed her 2-month-old baby and was **unable to move her right foot.** She also had a **tingling sensation in her right lateral lower leg and foot.** These symptoms did not resolve over the next 2 days, so she came to the emergency room. There was no back pain, and there were no bowel or bladder symptoms.

PHYSICAL EXAMINATION
Vital signs: T = 98°F, P = 84, BP = 136/68.
Neck: Supple with no bruits.
Lungs: Clear.
Heart: Regular rate.
Abdomen: Soft.
Extremities: Normal.
Back and spine: No tenderness.
Rectal: Normal tone with no masses.
Neurologic exam:
- *MENTAL STATUS:* Alert and oriented × 3. Fluent speech.
- *CRANIAL NERVES:* Intact.
- *MOTOR:* No drift. Normal tone, except for **diminished tone in the right foot.** 5/5 power throughout, except for **0/5 power in the right tibialis anterior, extensor hallucis longus, foot invertors, foot evertors, and gastrocnemius, and 3/5 power in the right hamstrings.**

REFLEXES:

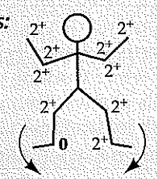

- *COORDINATION:* Normal on finger-to-nose testing.
- *GAIT:* **Flailing movements of the right foot while raising it off the floor with each step.**
- *SENSORY:* **Decreased light touch, pinprick, vibration, and joint position sense in the right lateral calf and in the entire right foot** (Figure 9.16). Sensation otherwise normal.

LOCALIZATION AND DIFFERENTIAL DIAGNOSIS
On the basis of the symptoms and signs shown in **bold** above, where is the lesion? What is the most likely diagnosis?

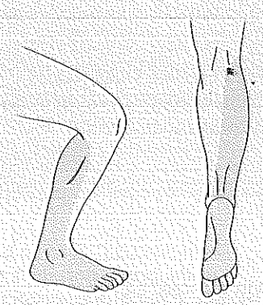

Figure 9.16 Region of Sensory Loss

Discussion

The key symptoms and signs in this case are:
- **Weakness of the right tibialis anterior, extensor hallucis longus, foot invertors, foot evertors, gastrocnemius, and hamstrings, with decreased right foot tone and absent right Achilles tendon reflex**
- **Paresthesias and decreased light touch, pinprick, vibration, and joint position sense in the right foot and lateral calf**

Right leg weakness, decreased tone, and hyporeflexia could be caused by a peripheral nerve lesion in the right leg or by an acute upper motor neuron lesion in the motor cortex or spinal cord (see KCC 6.1, 6.3; Figure 6.14F). The pattern of sensory loss is not consistent with a spinal cord lesion (see KCC 7.4) or cortical lesion (see KCC 7.3), but it does match that of a sciatic nerve lesion (see KCC 9.1; Table 9.3), as do the details of the motor exam. The most likely diagnosis is right sciatic neuropathy, probably caused by the fall, although the exact mechanism of injury is unclear.

Clinical Course and Neuroimaging 360

X-rays of the lumbosacral spine and pelvis revealed no fractures. A **lumbar plexus MRI** (Figure 9.17) revealed T2 bright signal in the right sciatic nerve, consistent with edema. The patient was treated with physical therapy and a right foot brace to aid ambulation. An EMG done 1 week after the onset of symptoms revealed inability to activate the muscles of the right sciatic nerve, including the gastrocnemius, tibialis anterior, flexor hallucis brevis, and medial hamstrings. A follow-up study was not done. The patient's strength gradually improved, and by 5 months after onset she felt almost back to normal. On exam 1 year after onset, she had 4/5 to 4+/5 strength in the right tibialis anterior, foot evertors, and invertors. Gastrocnemius strength was 5/5 bilaterally, and she had recovered sensation and the Achilles tendon reflex in the right foot.

CASE 9.9 A LEG INJURY RESULTING IN FOOT DROP

MINICASE
A 27-year-old man slipped on a wet tile floor and twisted his right foot toward the left, resulting in acute foot pain, followed by weakness. He was seen in the emergency room and had **0/5 power in his right tibialis anterior and extensor hallucis longus, and 3/5 power in his right foot evertors.** Power was otherwise 5/5, including the right foot invertors and gastrocnemius. He had **decreased sensation to pinprick on the dorsum of the right foot, which was especially pronounced in the web space between the first and second toes** (Figure 9.18).

LOCALIZATION AND DIFFERENTIAL DIAGNOSIS
On the basis of the symptoms and signs shown in **bold** above, where is the lesion? What is the most likely diagnosis?

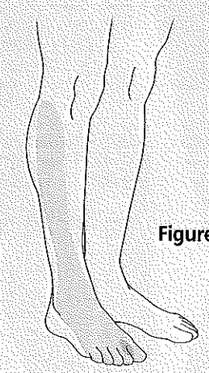

Partial sensory loss
Complete sensory loss

Figure 9.18 Region of Sensory Loss

Discussion

The key symptoms and signs in this case are:

- **Weakness in the right tibialis anterior, and extensor hallucis longus; moderate weakness of the right foot evertors**
- **Decreased sensation to pinprick on the dorsum of the right foot, especially between the first and second toes**

The pattern of weakness and sensory loss is consistent with injury to the common peroneal nerve (see Table 9.3; KCC 9.1; see also Table 8.1), which most likely occurred during the fall. Note that the deep peroneal nerve (tibialis anterior, extensor hallucis longus, sensation between first and second toes) appears to be more severely involved in this patient than the superficial peroneal nerve (foot eversion, sensation on dorsal foot and lateral shin). In addition, this should be distinguished from an L5 radiculopathy, in which there may also be weakness of foot inversion (compare to Case 8.10).

Clinical Course

An EMG (see KCC 9.2) 2 days after the injury showed abnormally low recruitment of motor unit action potentials in the right tibialis anterior, extensor hallucis longus, extensor digitorum brevis, and peroneus muscles, suggesting a neuropathic process. Motor nerve conduction studies showed decreased amplitudes when the right peroneal nerve was stimulated just above the fibular neck, and normal amplitudes when stimulated just below the fibular neck, suggesting nerve injury at the fibular neck. The patient gradually improved over the following months.

CASE 9.8 TINGLING AND PARALYSIS OF THE FOOT AFTER A FALL

Figure 9.17 Abnormal Bright Signal in the Right Sciatic Nerve, Compatible with Sciatic Neuropathy
MRI of the lumbar plexus. (A) Coronal T2-weighted MRI showing the plane of section for B. (B) Axial T2 weighted section, showing abnormal bright signal in the right sciatic nerve as it passes dorsal to the femur.

(A)

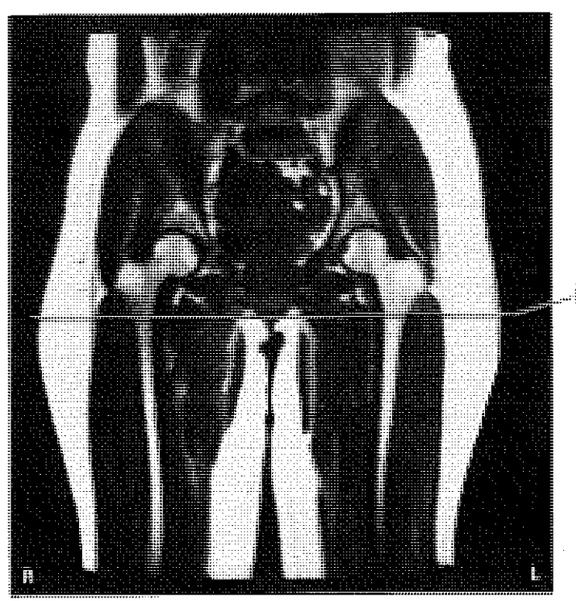

Plane of section for B

CASE 9.8 *(CONTINUED)*

(B) Femur

Bright signal in sciatic nerve

CASE 9.10 LATERAL THIGH PAIN AND NUMBNESS AFTER PREGNANCY

MINICASE

Two days after giving birth, a 24-year-old woman developed burning **pain and numbness in the right lateral thigh,** which was worsened by walking. Exam was normal except for a patch of **decreased sensation to light touch, pinprick, and cold on the right lateral thigh** (Figure 9.19). Specifically, reflexes and motor strength were normal.

LOCALIZATION AND DIFFERENTIAL DIAGNOSIS

On the basis of the symptoms and signs shown in **bold** above, where is the lesion? What is the most likely diagnosis?

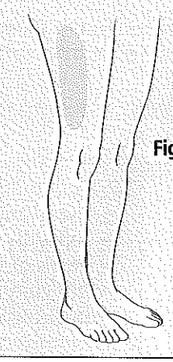

Figure 9.19 Region of Sensory Loss

Discussion

The key symptoms and signs in this case are:

- **Pain, paresthesias, and decreased sensation to light touch, pinprick, and cold on the right lateral thigh**

A purely sensory disorder affecting the lateral thigh is consistent with dysfunction of the lateral femoral cutaneous nerve, or meralgia paresthetica (Figure 9.5; KCC 9.1). An L2 or L3 radiculopathy could be considered; however, there were no motor or reflex abnormalities or back pain to support this possibility.

Clinical Course

The patient was reassured that her symptoms were caused by injury to a sensory nerve that would likely improve with time. Her symptoms gradually resolved over the following 5 months and required no specific treatment.

CASE 9.11 DYSARTHRIA, PTOSIS, AND DECREASED EXERCISE TOLERANCE

CHIEF COMPLAINT
A 35-year-old woman saw a neurologist because of worsening dysarthria and muscle fatigue.

HISTORY
The patient worked as a nurse and over the course of four months she noticed that at the end of her dictations, she had profound **difficulty enunciating her words.** This was **most apparent at the end of her work day.** Also, toward the end of her workday she had **difficulty producing a full smile.** Her symptoms disappeared with rest. She also noticed some mild neck discomfort and felt that it was **difficult at times to hold her head up.** In addition, she had **reduced exercise tolerance,** becoming short of breath sooner than previously when using the treadmill at her gym.

PHYSICAL EXAMINATION
Vital signs: T = 98° F, P = 80, BP = 90/70.
Neck: Supple, no bruits.
Lungs: Clear.
Heart: Regular rate.
Abdomen: Soft.
Extremities: Normal.
Neurologic exam:
MENTAL STATUS: Alert and oriented ×3. Fluent speech. Recalled 3/3 words after 5 minutes. Normal calculations.
CRANIAL NERVES: Intact visual fields and acuity. Pupils equal and reactive to light and accommodation. Extraocular movements intact with no nystagmus. **On prolonged upgaze she developed ptosis of the left eyelid.** Facial sensation was intact. Face movements were symmetrical. Hearing was normal. Palate elevation was normal and tongue was midline. **While reading a long passage aloud, her speech gradually became dysarthric.**
MOTOR: Normal tone. No fasciculations or tremor. 5/5 strength throughout.
REFLEXES:

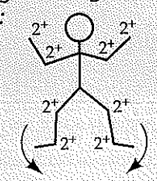

COORDINATION: Normal finger-to-nose and heel-to-shin testing.
SENSORY: Normal pinprick, temperature, vibration, and joint position sense. No extinction.

LOCALIZATION AND DIFFERENTIAL DIAGNOSIS
1. Based on the symptoms and signs shown in **bold** above, where is the lesion?
2. What is the most likely diagnosis?

Discussion

The key symptoms and signs in this case are:
- **Dysarthria, worse at the end of prolonged speech**
- **Difficulty producing a full smile at the end of the day**
- **Ptosis of the left eye on prolonged upgaze**
- **Difficulty holding head up at the end of the day**
- **Reduced strength and shortness of breath on treadmill**

1. Dysarthria can be caused by cranial nerve or upper motor neuron disorders (see KCC 12.8), as can facial weakness during smiling (see Figure 12.13). Ptosis can result from disorders of CN III supplying the levator palpebrae superior, or from Horner's syndrome (see KCC 13.6). Weakness of the neck muscles, legs, and respiratory muscles, likewise, can have central or peripheral causes. However, the weakness in these multiple locations, in the absence of any sensory findings, would be unusual for a neuropathy. In addition, there are no upper motor neuron signs to suggest a multifocal disorder affecting the central nervous system. Therefore, a peripheral disorder affecting the neuromuscular junction or muscles involved in speech, eyelid elevation, respiratory muscles, and proximal respiratory, neck, and leg muscles is most likely.
2. This pattern of weakness with no sensory loss and intact reflexes, together with the fact that the weakness was worse toward the end of the day or with repeated use of the muscles, is most suggestive of myasthenia gravis (see KCC 8.1). Other possible causes of diffuse, slowly progressive weakness without sensory loss, reflex loss, or upper motor neuron signs include Lambert–Eaton syndrome and myopathic disorders (see KCC 8.1).

Diagnostic Studies and Clinical Course 364

The neurologist performed a Tensilon test (see KCC 8.1) by evaluating the patient's ability to read a long passage aloud. Her dysarthria was markedly reduced after administration of Tensilon, so the test was considered positive. Acetylcholine receptor antibodies were also positive at 1.73 nmol/L (normal is less than 0.3 nmol/L). **Repetitive stimulation** (see KCC 9.2) of the ulnar nerve at 3 per second produced a 23% decrement of the CMAP amplitude recorded over the abductor digiti minimi muscle (Figure 9.20). Decrement of greater than 10% is considered abnormal and supports the diagnosis of myasthenia gravis (see KCC 9.2). Pulmonary function tests were normal. The patient underwent a chest CT, which revealed a 7 × 5 cm lobulated mass in the right anterior mediastinum extending over to the right side of the pericardium, consistent with a thymoma (see KCC 8.1). She was treated with the anticholinesterase medication pyridostigmine (Mestinon) and underwent surgical resection of the thymic mass, which was confirmed histologically to be a thymoma. Following surgery, her dysarthria and fatigue resolved completely, and she had a normal neurologic exam, including no dysarthria and no ptosis, even after prolonged upgaze.

Additional Cases

Related cases can be found in other chapters for the following topics: **radiculopathy** (Cases 8.1–8.11); **distal symmetric polyneuropathy** (Cases 6.5, 10.3); and **cranial neuropathy** (Cases 12.2–12.7, 13.1–13.3, 13.5). Other relevant cases can be found using the **Case Index.**

Brief Anatomical Study Guide

1. The **brachial plexus** arises from **C5 through T1** (see Figure 9.2), while the **lumbosacral plexus** arises from **L1 through S4** (see Figure 9.4).
2. The most clinically important nerves in the upper extremity are the **radial, median, ulnar, axillary, and musculocutaneous nerves;** the sensory and motor functions of these nerves are summarized in Table 9.1.
3. The most important nerves in the lower extremity are the **femoral, obturator, sciatic, tibial, and peroneal nerves;** the sensory and motor functions of these nerves are summarized in Table 9.3.

References

General References

Aids to the Examination of the Peripheral Nervous System. 1986. Bailliere Tindall on behalf of the Guarantors of Brain, London.

April EW. 1990. *Anatomy,* 2nd Ed. Wiley, New York.

Bach JR. 1998. *Guide to the Evaluation and Management of Neuromuscular Disease.* Hanley & Belfus, Philadelphia.

Dawson DM, Hallett M, Millender LH. 1990. *Entrapment Neuropathies,* 2nd Ed. Little, Brown, Boston.

Devinsky O, Feldmann E. 1988. *Examination of the Cranial and Peripheral Nerves.* Churchill Livingstone, New York.

CASE 9.11 DYSARTHRIA, PTOSIS, AND DECREASED EXERCISE TOLERANCE

Figure 9.20 Decrement on Repetitive Stimulation
Repetitive stimulation testing was performed by stimulating the ulnar nerve of the right arm and recording the CMAP over the right abductor digiti minimi muscle (see Figure 9.9; KCC 9.2). Stimulation was repeated at 3 per second for a total of 9 stimuli. Successive stimuli are shown displaced sequentially to the right (3 ms displacement per stimulus) to allow comparison of amplitudes of successive CMAPs: The first CMAP in the series is displayed farthest to the left and the 9th CMAP is displayed farthest to the right. There was a decrement in CMAP amplitude of 23%.

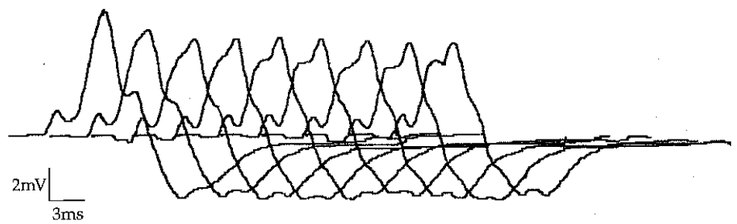

Deymeer FS (ed.). 2000. *Neuromuscular Disease: From Basic Mechanisms to Clinical Management*. (Monographs in Clinical Neuroscience, Vol. 18.) S Karger AG, New York.

Kline DG, Hudson AR. 1995. *Nerve Injuries: Operative Results for Major Nerve Injuries, Entrapments, and Tumors*. Saunders, Philadelphia.

Moore KL, Dalley AF. 1999. *Clinically Oriented Anatomy*, 4th Ed. Lippincott Williams & Wilkins, Philadelphia.

Preston DC, Shapiro BE. 1998. *Electromyography and Neuromuscular Disorders: Clinical–Electrophysiologic Correlations*. Butterworth-Heinemann, Boston.

Salter RB. 1999. *Textbook of Disorders and Injuries of the Musculoskeletal System*, 3rd Ed. Williams & Wilkins, Baltimore, MD.

Upper Extremity

Anto C, Aradhya P. 1996. Clinical diagnosis of peripheral nerve compression in the upper extremity. *Orthop Clin North Am* 27(2): 227–236.

Brachial Plexus

Arcasoy SM, Jett JR. 1997. Superior pulmonary sulcus tumors and Pancoast's syndrome. *N Engl J Med* 337(19): 1370–1376.

Kline DG, Hudson AR. 1995. Birth palsies. In Kline DG, Hudson AR (eds.), *Nerve Injuries: Operative Results for Major Nerve Injuries, Entrapments, and Tumors*. Saunders, Philadelphia.

Wilbourn AJ. 1993. Brachial plexus disorders. In Dyck PJ, Thomas PK (eds.), *Peripheral Neuropathy*, 3rd Ed., pp. 911–950. Saunders, Philadelphia.

Median Nerve

Katz RT. 1994. Carpal tunnel syndrome: A practical review. *Am Fam Physician* 49(6): 1371–1379.

Phalen GS, Kendrick JI. 1957. Compression neuropathy of the median nerve in the carpal tunnel. *JAMA* 164: 524.

Wertsch JJ, Melvin J. 1982. Median nerve anatomy and entrapment syndromes: A review. *Arch Phys Med Rehabil* 63(12): 623–627.

Radial Nerve

Kleinert JM, Mehta S. 1996. Radial nerve entrapment. *Orthop Clin North Am* 27(2): 305–315.

Ulnar Nerve

Khoo D, Carmichael SW, Spinner RJ. 1996. Ulnar nerve anatomy and compression. *Orthop Clin North Am* 27(2): 317–338.

Shea JD, McClain EJ. 1969. Ulnar-nerve compression syndromes at and below the wrist. *J Bone Joint Surg* 51(6): 1095–1103.

Vanderpool DW, Chalmers J, Lamb DW, Whiston TB. 1968. Peripheral compression lesions of the ulnar nerve. *J Bone Joint Surg* 50(4): 792–803.

Sciatic Nerve

Fassler PR, Swiontkowski MF, Kilroy AW, Routt ML, Jr. 1993. Injury of the sciatic nerve associated with acetubular fracture. *J Bone Joint Surg (Am)* 75(8): 1157–1166.

Peroneal Nerve

Berry H, Richardson PM. 1976. Common peroneal nerve palsy: A clinical and electrophysiological review. *J Neurol Neurosurg Psychiatry* 39(12): 1162–1171.

Meralgia Paresthetica

Kitchen C, Simpson J. 1972. Meralgia paresthetica: A review of 67 patients. *Acta Neurol Scand* 48(5): 547–555.

Nahabedian MY, Dellon AL. 1995. Meralgia paresthetica: Etiology, diagnosis, and outcome of surgical decompression. *Ann Plast Surg* 35(6): 590–594.

Sarala PK, Nishihara T, Oh SJ. 1979. Meralgia paresthetica: Electrophysiologic study. *Arch Phys Med Rehabil* 60(1): 30–31.

CHAPTER 10

Cerebral Hemispheres and Vascular Supply

ANATOMICAL AND CLINICAL REVIEW

Review of Main Functional Areas of Cerebral Cortex

Circle of Willis: Anterior and Posterior Circulations

Anatomy and Vascular Territories of the Three Main Cerebral Arteries

KCC 10.1 Clinical Syndromes of the Three Main Cerebral Arteries

KCC 10.2 Watershed Infarcts

KCC 10.3 Transient Ischemic Attack (TIA) and Other Transient Neurologic Episodes

KCC 10.4 Ischemic Stroke: Mechanisms and Treatment

KCC 10.5 Carotid Stenosis

KCC 10.6 Dissection of the Carotid or Vertebral Arteries

Venous Drainage of the Cerebral Hemispheres

KCC 10.7 Sagittal Sinus Thrombosis

CLINICAL CASES

10.1 Sudden-Onset Worst Headache of Life

10.2 Left Leg Weakness and Left Alien Hand Syndrome

10.3 Decreased Vision on One Side

10.4 Transient Episodes of Left Eye Blurriness or Right Hand Weakness

10.5 Nonfluent Aphasia with Right Face and Arm Weakness

10.6 Talking Ragtime

10.7 Dysarthria and Hemiparesis

10.8 Global Aphasia, Right Hemiplegia, and Hemianopia

10.9 Left Face and Arm Weakness

10.10 Left Hemineglect

10.11 Left Hemineglect, Hemiplegia, and Hemianopia

10.12 Unilateral Proximal Arm and Leg Weakness

10.13 Right Frontal Headache and Left Arm Numbness in a Woman with Gastric Carcinoma

Additional Cases

BRIEF ANATOMICAL STUDY GUIDE

A 45-year-old man with a history of cigarette smoking and hypertension staggered into a diner grunting incoherently, then tripped and fell to the floor. The manager called an ambulance, and in the emergency room the patient was found to have severe right face and arm weakness. Six days later, he was still able to utter only a few barely articulate words, but he could follow many simple commands and answered yes/no questions appropriately. Each area of the cerebral cortex belongs to a specific vascular "territory," and this patient's symptoms are typical of cortical damage to one such territory. To diagnose and treat patients with these disorders, we must learn about the local functions of different parts of the cerebrum and their associated blood supply, which are the focus of this chapter.

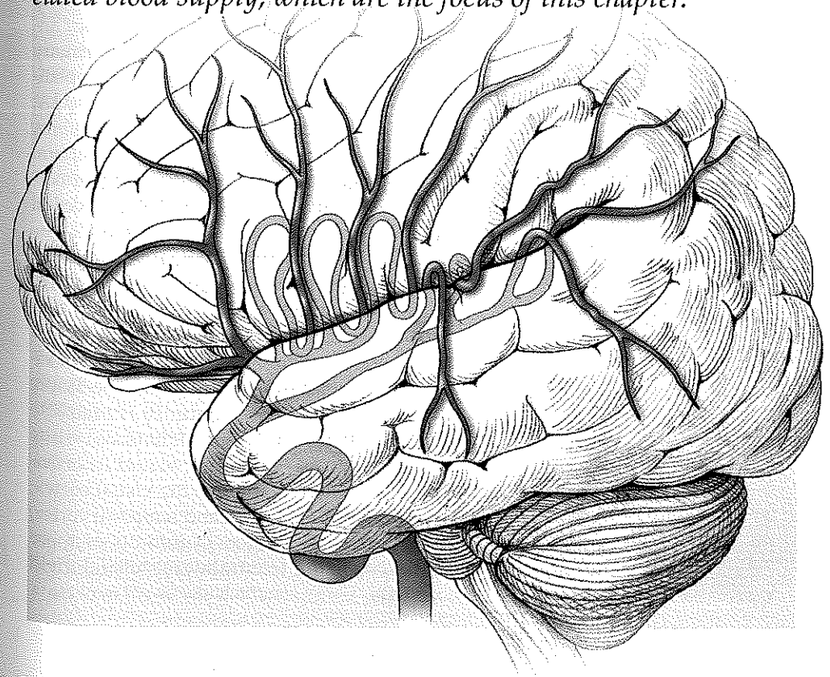

ANATOMICAL AND CLINICAL REVIEW

The cerebral hemispheres are what we usually envision when we think of the human brain. In this chapter we will review the functional anatomy of the cerebral hemispheres by studying their blood supply and the clinical–anatomical correlations that can be made when the blood supply is transiently or permanently disrupted. The blood supply and functional anatomy of the brainstem and cerebellum will be discussed in Chapters 14 and 15; the spinal cord blood supply was discussed in Chapter 6. Understanding the blood supply of the brain provides a useful review of regional brain anatomy, since blood vessel territories typically overlap several spatially adjacent functional systems. In addition, knowledge of blood vessel territories is clinically useful, since it enables the localization of common stroke syndromes on clinical grounds, allowing proper diagnostic and therapeutic interventions to be promptly initiated.

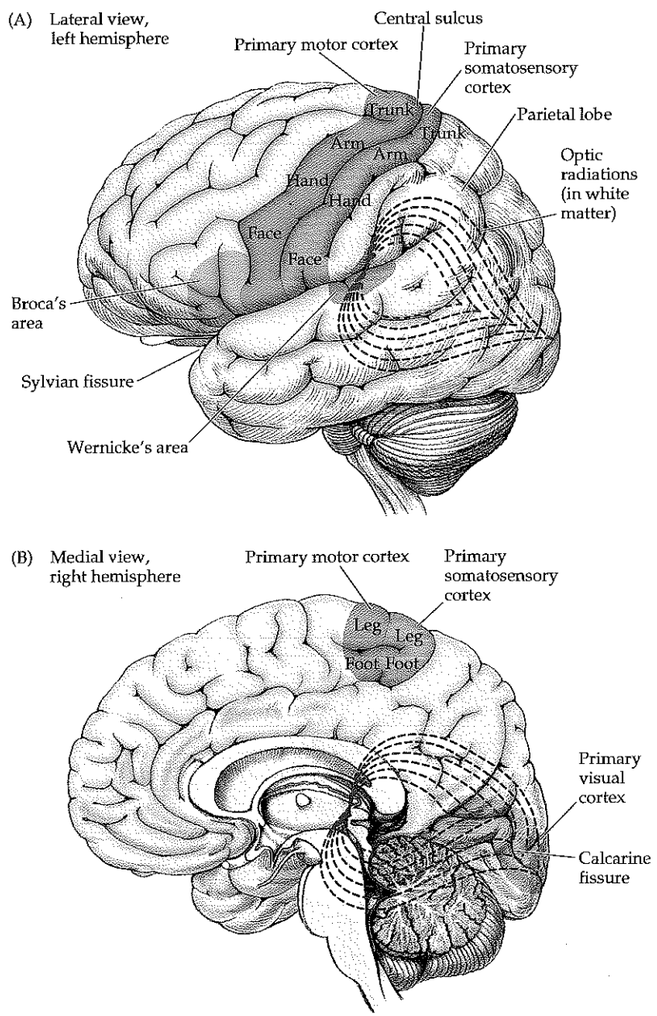

Figure 10.1 Some Important Functional Areas of the Cerebral Cortex (A) Lateral view of left hemisphere. (B) Medial view of right hemisphere.

Review of Main Functional Areas of Cerebral Cortex

We will now briefly review the main functional areas of the cerebral cortex that are commonly affected by cerebral infarcts (Figure 10.1). Additional details can be found in other chapters discussing motor, somatosensory, visual, and association cortex at greater length (see Chapters 2, 6, 7, 11, and 19.)

Recall that the face and hand areas of the sensorimotor homunculi are on the lateral convexities, while the leg areas are in the interhemispheric fissure (see Figure 6.2). In the dominant, usually left, hemisphere, Broca's area lies in the inferior frontal gyrus, just anterior to the articulatory areas of the primary motor cortex, a location well suited for planning the articulatory program (Figure 10.1A; see also Figure 19.2, KCC 19.4). Meanwhile, Wernicke's area lies in the superior temporal gyrus, adjacent to the primary auditory cortex (see also Figure 12.16), and is involved in language processing.

Association cortex in the nondominant, usually right, hemisphere is important for attention to the contralateral body and space, especially the right parietal lobe. Primary visual cortex for the contralateral visual hemifield lies along the calcarine fissure of the occipital lobe (Figure 10.1B; see also Figure 11.15). The optic radiations, white matter pathways carrying visual information from the thalamus to the visual cortex, pass under the parietal and temporal cortex; they can be damaged in infarcts of these lobes, causing contralateral visual field deficits.

Circle of Willis: Anterior and Posterior Circulations

The arterial supply to the cerebral hemispheres is derived from the **anterior circulation** provided by the bilaterally paired **internal carotid arteries,** as well as by the **posterior circulation** provided by the bilateral **vertebral arteries** (Figure 10.2). The anterior circulation arises from the common carotid arteries originating at the aorta or brachiocephalic arteries (see Figure 4.20A). At the carotid bifurcation, the common carotid splits forming the internal carotid and external carotid arteries (see Figure 4.19). The vertebral arteries, which supply the posterior circulation, arise from the subclavian arteries (see Figure 4.20B) and then ascend (see Figure 4.19) through foramina in the transverse processes of the cervical vertebrae (foramina transversaria; see Figure 10.2B) before entering the foramen magnum and joining to form the basilar artery. These anterior and posterior circulations meet in an anastomotic ring called the **circle of Willis,** from which all major cerebral vessels arise (Figure 10.3). The circle of Willis provides abundant opportunities for collateral flow; however, a complete ring is present in only approximately 25% of individuals. The main arteries supplying the cerebral hemispheres are the anterior, middle, and posterior cerebral arteries. The **anterior cerebral arteries** (**ACAs**) and **middle cerebral arteries** (**MCAs**) are the terminal branches of the internal carotid arteries. The anterior cerebral arteries anastomose anteriorly at the **anterior communicating artery** (**AComm**). The anterior and posterior circulations are linked to each other via the **posterior communicating arteries** (**PComm's**), which connect the internal carotids to the posterior cerebral arteries, thereby joining the anterior

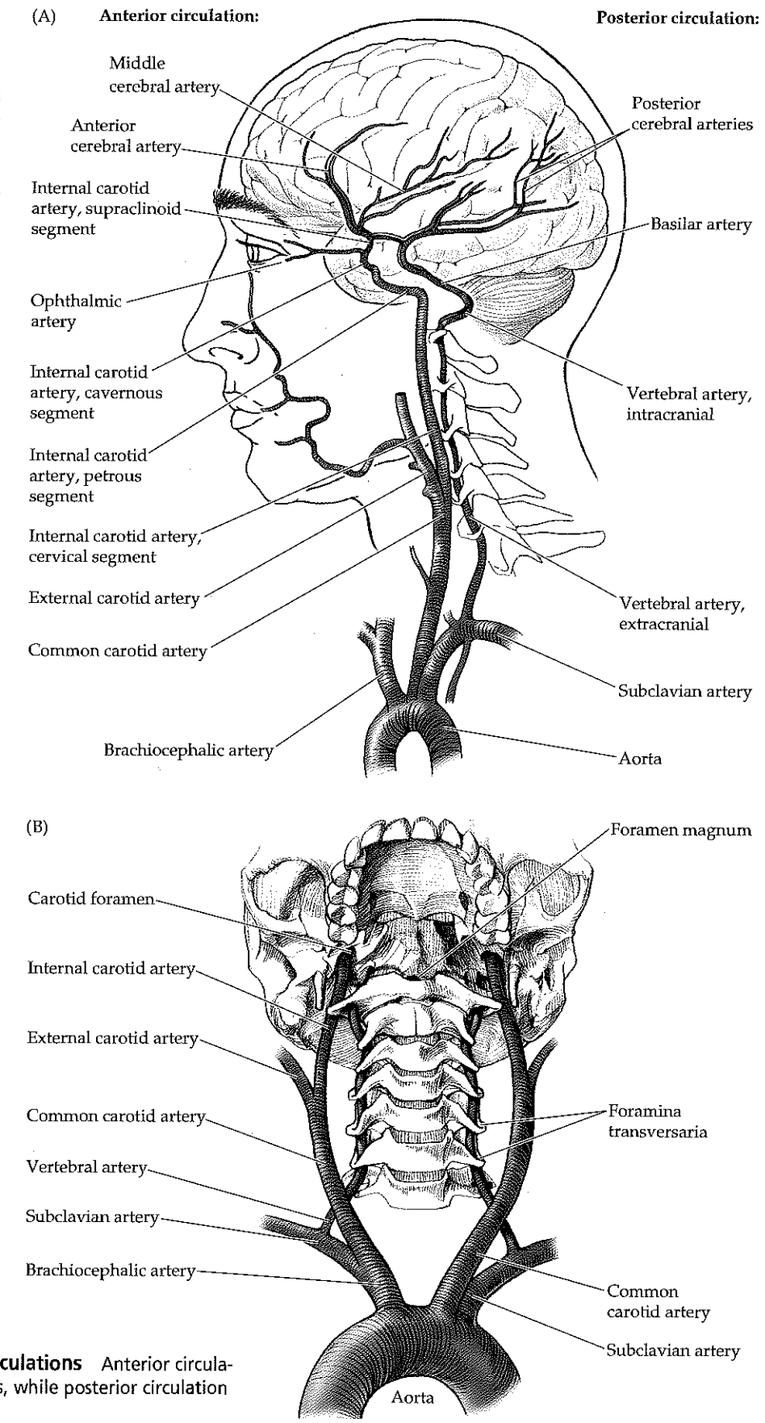

Figure 10.2 Anterior and Posterior Circulations Anterior circulation arises from the internal carotid arteries, while posterior circulation arises from the vertebral arteries.

Figure 10.3 Circle of Willis and Its Main Branches

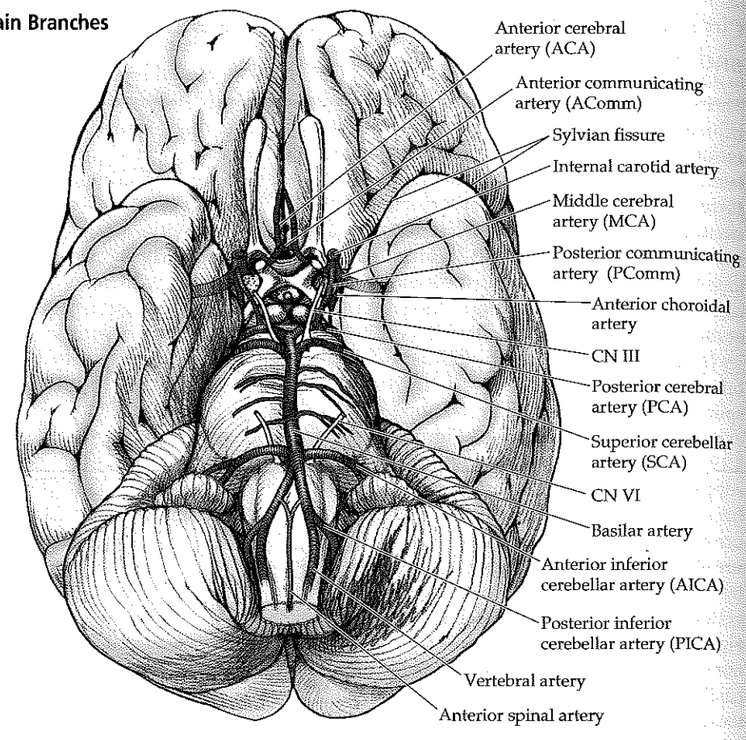

REVIEW EXERCISE

In the conventional angiograms and magnetic resonance angiograms of Figures 4.16–4.18, cover the labels and identify as many structures as possible. Identify especially the internal carotid arteries, vertebral arteries, basilar artery, ACA, MCA, PCA, AComm, and PComm.

MNEMONIC

and posterior circulations. The **posterior cerebral arteries** (**PCAs**) arise from the top of the basilar artery, which in turn is formed by the convergence of the two vertebral arteries. In addition to the posterior cerebral arteries, several branches to the brainstem and cerebellum arise from the vertebrobasilar system, as we will discuss in Chapters 14 and 15.

The internal carotid artery has several named segments during its course (see Figure 10.2). These can be well visualized in the angiogram images in Figures 4.16A,C and 4.18B. First comes the relatively vertical **cervical segment** in the neck, followed by a sharp horizontal bend as the internal carotid enters the temporal bone as the **petrous segment**. Next comes the **cavernous segment** as the internal carotid begins an S-shaped turn, also known as the **carotid siphon**, within the cavernous sinus (see Figure 13.11). It then passes the anterior clinoid process (see Figure 5.2B) to pierce the dura and bends posteriorly to enter the subarachnoid space as the **supraclinoid,** or **intracranial, segment** (see Figure 4.16C). Although there are several smaller branches, the main branches of the supraclinoid internal carotid artery can be remembered by the mnemonic **OPAAM** (if you can remember "OPAAM"), which stands for the Ophthalmic, Posterior communicating, Anterior choroidal, Anterior cerebral, and Middle cerebral arteries. The **ophthalmic artery** usually arises from the bend in the internal carotid just after it enters the dura (see Figure 4.16A,C). The ophthalmic artery enters the optic foramen with the optic nerve and provides the main blood supply to the retina.

Sometimes, in an alternative nomenclature, the terms **A1, M1,** and **P1** are used for the initial segments of the ACA, MCA, and PCA, respectively, and second- and third-order branches are referred to as A2, A3, etc.

Anatomy and Vascular Territories of the Three Main Cerebral Arteries

The three main cerebral arteries (ACA, MCA, PCA) give rise to numerous branches that travel in the subarachnoid space over the surface of the brain and into the sulci. Small penetrating branches arise from these vessels to supply the superficial portions of the brain, including the cortex and underlying white matter. The deep structures of the brain, such as basal ganglia, thalamus, and internal capsule, are supplied by small penetrating branches that arise from the initial segments of the main cerebral arteries near the circle of Willis at the base of the brain. We will now review the vascular territories of the superficial and deep structures of the cerebral hemispheres.

REVIEW EXERCISE

What are the three main arteries of the cerebral hemispheres (see Figure 10.2)? Which arise from the anterior circulation and which arise from the posterior circulation in most individuals?

Vascular Territories of the Superficial Cerebral Structures

The **anterior cerebral artery** passes foward to travel in the interhemispheric fissure as it sweeps back and over the corpus callosum (Figure 10.4). Two major branches commonly seen are the pericallosal and callosomarginal arteries (see Figures 4.16C and 4.18B). The anterior cerebral artery thus supplies most of the cortex on the anterior medial surface of the brain, from the frontal to the anterior parietal lobes (Figure 10.5), usually including the medial sensorimotor cortex (see Figure 10.1B).

The **middle cerebral artery** turns laterally to enter the depths of the Sylvian fissure (see Figure 10.3). Within the Sylvian fissure it usually bifurcates into the **superior division** and the **inferior division** (Figure 10.6). This is somewhat variable, and sometimes there are three or even four main branches of the middle cerebral artery. The branches of the middle cerebral

Figure 10.4 Anterior Cerebral Artery (ACA) and Posterior Cerebral Artery (PCA) Simplified course of the main ACA and PCA branches is shown on the medial surface of the brain.

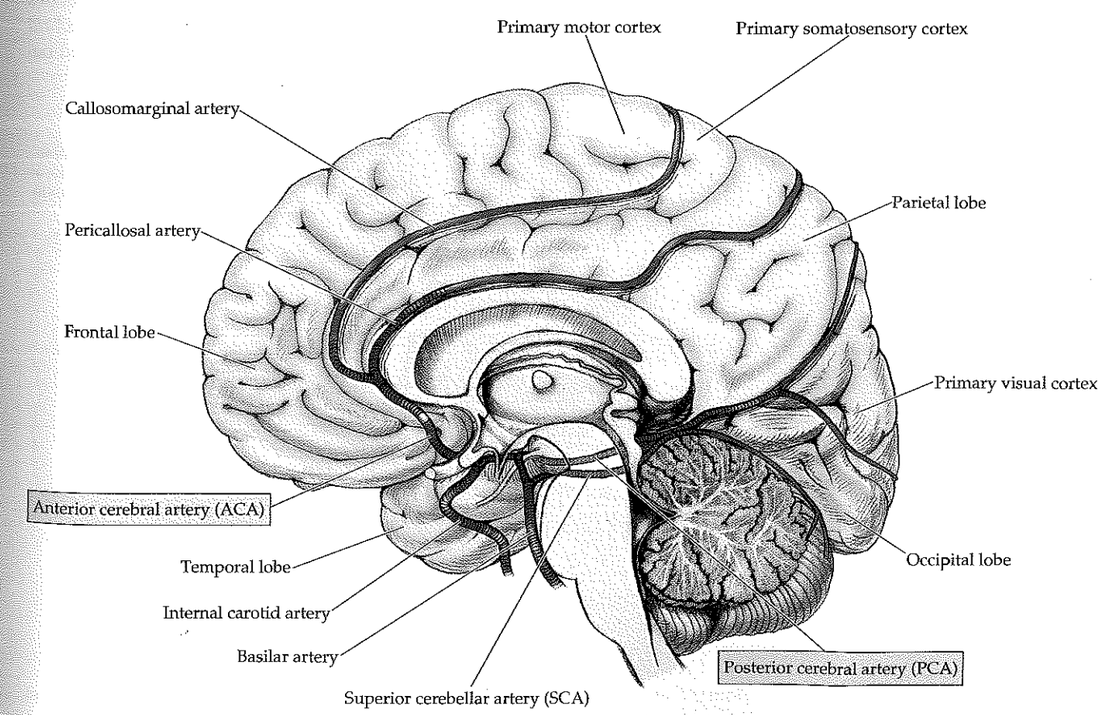

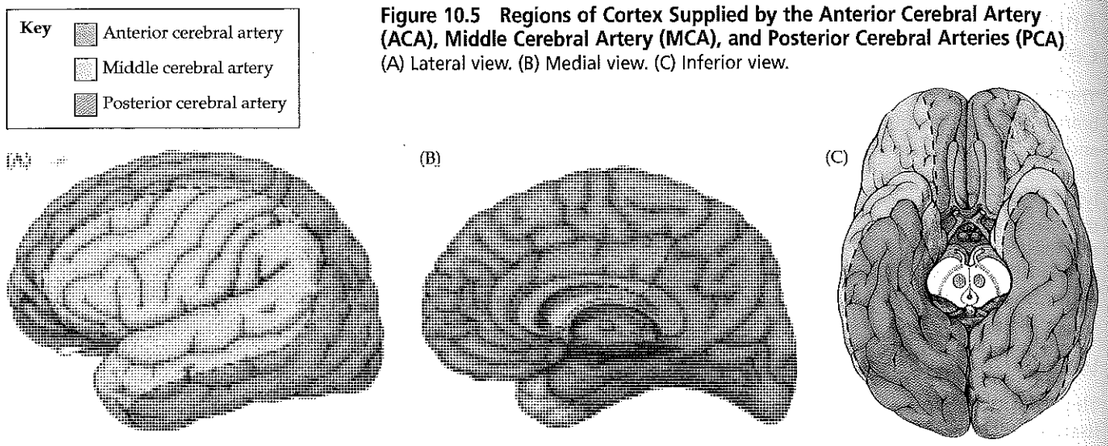

Figure 10.5 Regions of Cortex Supplied by the Anterior Cerebral Artery (ACA), Middle Cerebral Artery (MCA), and Posterior Cerebral Arteries (PCA) (A) Lateral view. (B) Medial view. (C) Inferior view.

REVIEW EXERCISE

Draw the vascular territories for the three main cerebral arteries (ACA, MCA, PCA) on the brain surfaces below. Refer to Figure 10.1 to deduce the deficits seen in infarcts of each of these three territories. This information has many important clinical applications (see KCC 10.1).

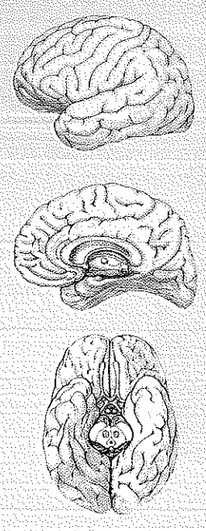

artery form loops as they pass over the insula and then around and over the operculum to exit the Sylvian fissure onto the lateral convexity (see Figures 4.16A,C and 4.18B). The superior division supplies the cortex above the Sylvian fissure, including the lateral frontal lobe and usually including the peri-Rolandic cortex (see Figure 10.6). The inferior division supplies the cortex below the Sylvian fissure, including the lateral temporal lobe and a variable portion of the parietal lobe. The middle cerebral artery thus supplies most of the cortex on the dorsolateral convexity of the brain (Figure 10.5).

The **posterior cerebral artery** curves back after raising from the top of the basilar and sends branches over the inferior and medial temporal lobes and over the medial occipital cortex (see Figure 10.4). The posterior cerebral artery territory therefore includes the inferior and medial temporal and occipital cortex (see Figure 10.5).

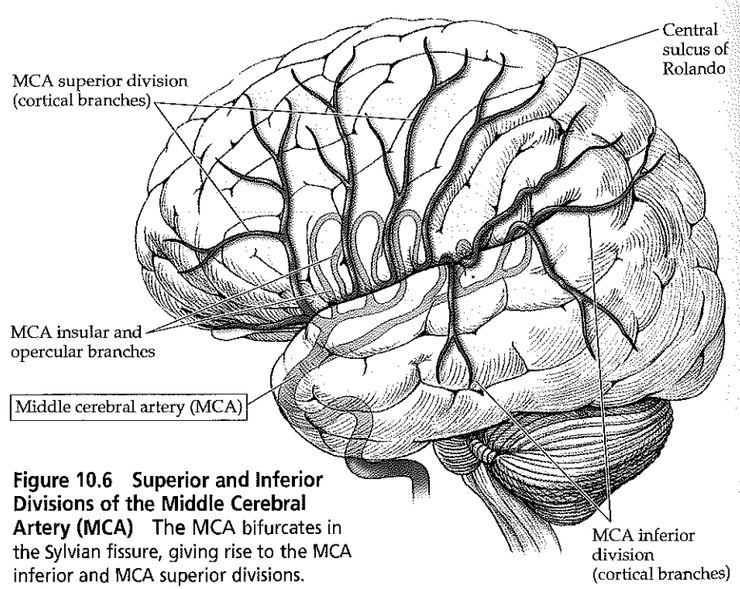

Figure 10.6 Superior and Inferior Divisions of the Middle Cerebral Artery (MCA) The MCA bifurcates in the Sylvian fissure, giving rise to the MCA inferior and MCA superior divisions.

Vascular Territories of the Deep Cerebral Structures

The most important penetrating vessels at the base of the brain are the **lenticulostriate arteries.** These small vessels arise from the initial portions of the middle cerebral artery, before it enters the Sylvian fissure (Figure 10.7), and they penetrate the anterior perforated substance (see Figure 2.11C) to supply large regions of the basal ganglia and internal capsule (Figure 10.8). In hypertension, the lenticulostriate arteries and other similar small vessels are particularly prone to narrowing, which can lead to lacunar infarction (KCC 10.4), as well as to rupture, causing intracerebral hemorrhage (see KCC 5.6).

Other small vessels supply deep structures as well, with some variability (see Figures 10.7, 10.8). The **anterior choroidal artery** arises from the internal carotid artery (see Figure 10.3). Its territory includes portions of the globus pallidus, putamen, thalamus (sometimes involving part of the lateral geniculate nucleus), and the posterior limb of the internal capsule (see Figure 6.9B) extending up to the lateral ventricle (see Figure 10.8, 10.9B). The **recurrent artery of Heubner** comes off the initial portion of the anterior cerebral artery to supply portions of the head of the caudate, anterior putamen, globus pallidus, and internal capsule (see Figures 10.7–10.9). Other variable branches may also come off the initial portions of the anterior cerebral arteries to supply deep structures. Small penetrating arteries that arise from the proximal posterior cerebral arteries near the top of the basilar artery include the **thalamoperforator arteries** (see Figure 10.8) (as well as the thalamogeniculate and posterior choroidal arteries), which supply the thalamus and sometimes extend to a portion of the posterior limb of the internal capsule. As we will see in Chapter 14, small penetrating vessels arising from the top of the basilar artery also supply the midbrain.

The superficial and deep territories of the main cerebral arteries are summarized in coronal and axial sections in Figure 10.9.

REVIEW EXERCISE

In the angiographic images shown in Figures 4.16B and 4.17B, identify (1) the lenticulostriate arteries arising from the middle cerebral artery, (2) the recurrent artery of Heubner arising from the anterior cerebral artery, and (3) the thalamoperforator and posterior choroidal arteries arising from the posterior cerebral arteries.

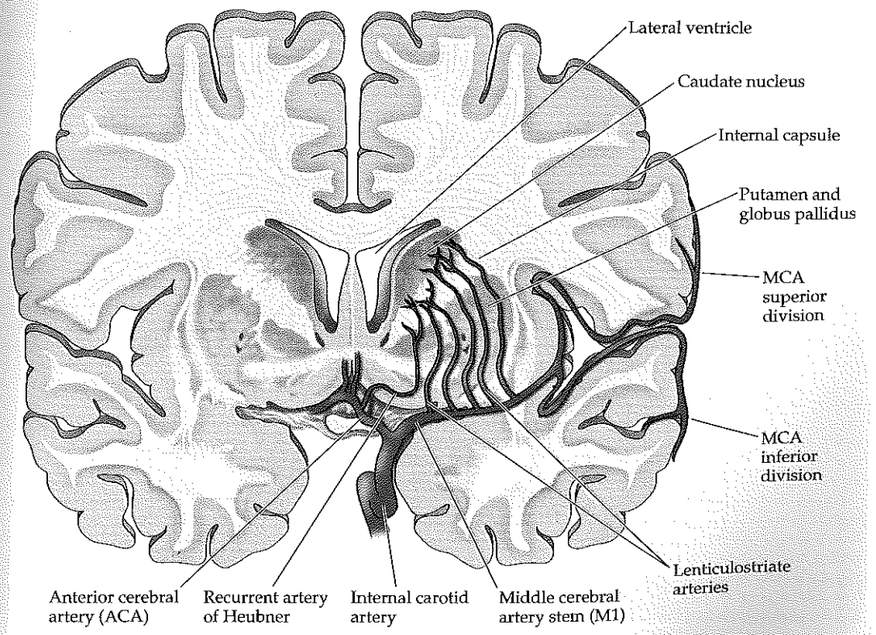

Figure 10.7 Lenticulostriate Arteries Coronal section showing the lenticulostriate arteries arising from the proximal middle cerebral artery and supplying the basal ganglia and internal capsule. The recurrent artery of Heubner arises from the anterior cerebral artery.

Figure 10.8 Blood Supply to Deep Cerebral Structures (A) Blood vessels supplying the basal ganglia and thalamus. (B) Blood supply to the internal capsule and globus pallidus.

(A) Blood vessels supplying the basal ganglia and thalamus

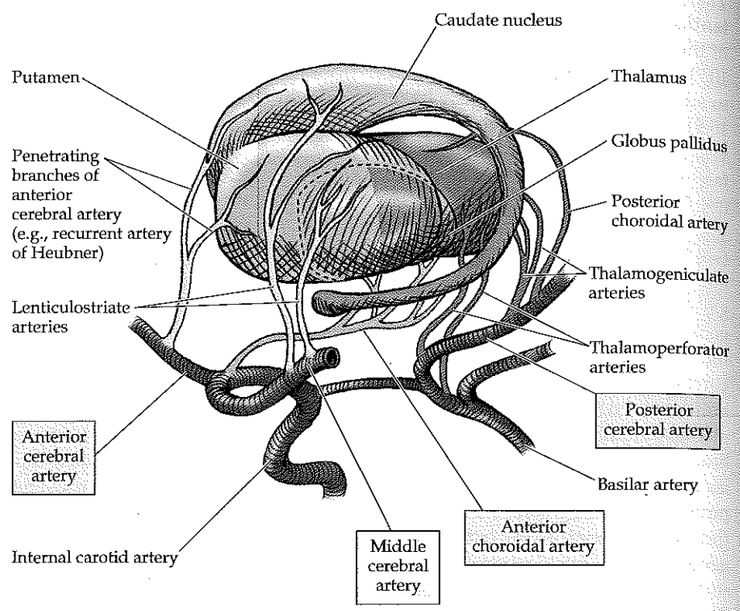

(B) Blood supply to the internal capsule and globus pallidus

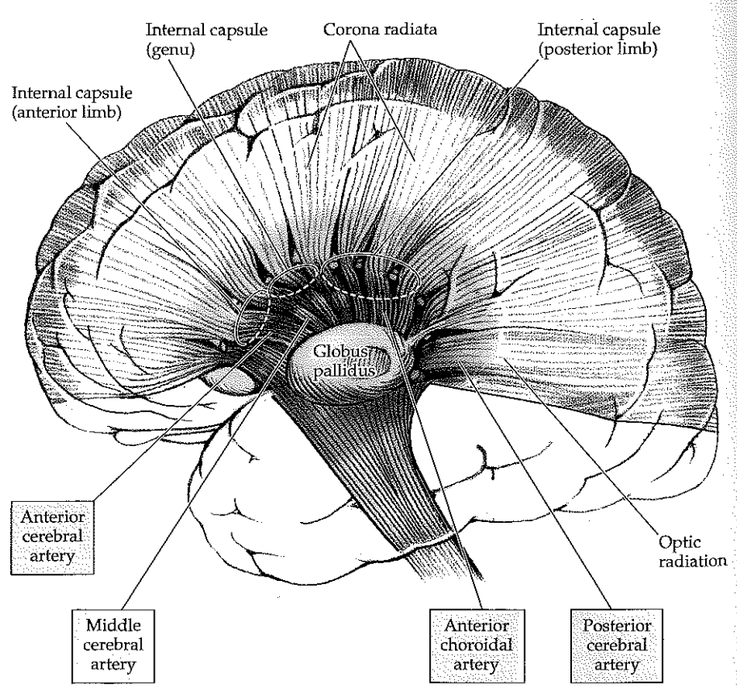

Figure 10.9 Summary of Superficial and Deep Blood Supply to the Cerebral Hemispheres (A) Coronal section. (B) Axial section.

(A)

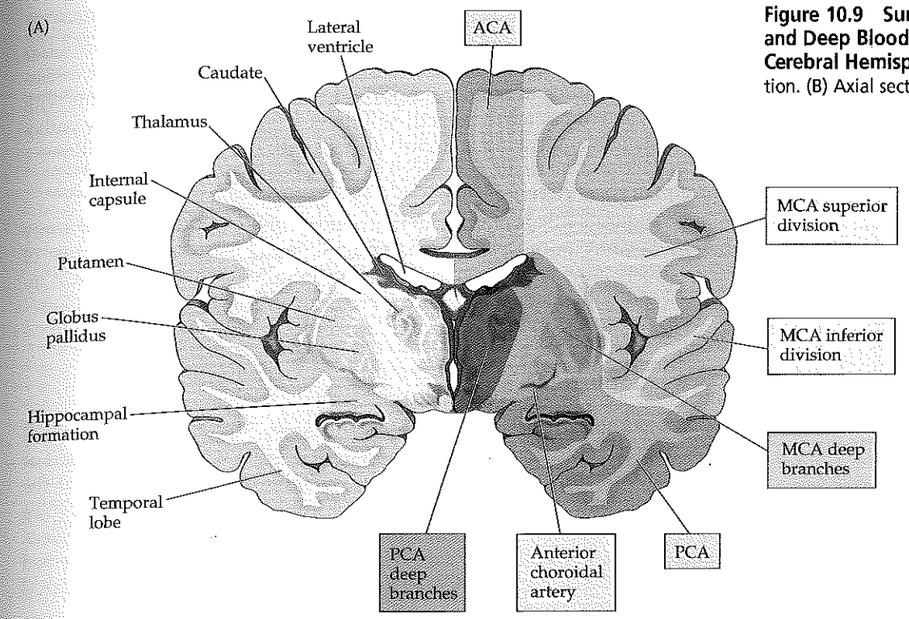

(B)

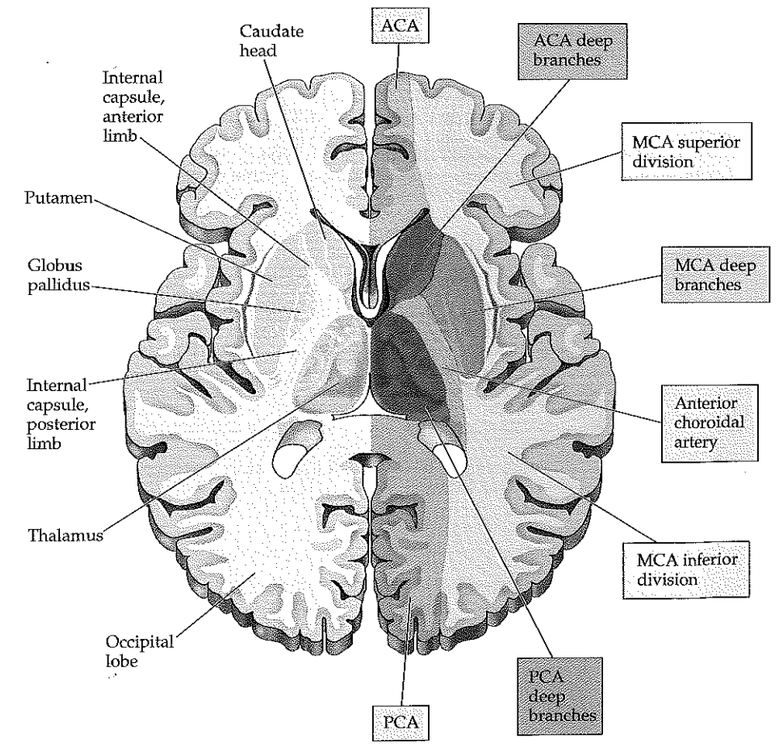

KEY CLINICAL CONCEPT

CLINICAL SYNDROMES OF THE THREE MAIN CEREBRAL ARTERIES

10.1 Recognition of the classic syndromes produced by infarcts of the middle cerebral artery (MCA), anterior cerebral artery (ACA), and posterior cerebral artery (PCA) territories remains a cornerstone of neurologic assessment and continues to play an important role in evaluating patients with acute stroke. We discuss localization of these syndromes here; stroke pathophysiology and clinical management are discussed in KCC 10.3 and 10.4.

Middle Cerebral Artery (MCA)

Infarcts and ischemic events are more common in the middle cerebral artery than in the anterior or posterior cerebral arteries, at least in part, because of the relatively large territory supplied by the middle cerebral artery. MCA infarcts occur in three general regions (see Figures 10.6, 10.7, and 10.9):

1. Superior division
2. Inferior division
3. Deep territory

Proximal MCA occlusions affecting all three of these regions are called MCA stem infarcts. The most common deficits seen with infarcts of left or right MCA territories are summarized in Table 10.1. Knowledge of the deficits associated with each of these territories is clinically useful since MCA infarcts are relatively common. Deficits such as aphasia, hemineglect, hemianopia, and face-arm or face-arm-leg sensorimotor loss are described further in KCC 6.3, 7.3, 11.2, 19.4, 19.5, and 19.9. Large MCA territory infarcts

TABLE 10.1 Major Clinical Syndromes of the MCA, ACA, and PCA Territories

LOCATION OF INFARCT	AFFECTED TERRITORY	DEFICITS[a]
Left MCA superior division		Right face and arm weakness of the upper motor neuron type, and a nonfluent, or Broca's, aphasia. In some cases there may also be some right face and arm cortical-type sensory loss.
Left MCA inferior division		Fluent, or Wernicke's, aphasia and a right visual field deficit. There may also be some right face and arm cortical-type sensory loss. Motor findings are usually absent, and patients may initially seem confused or crazy, but otherwise intact, unless carefully examined. Some mild right-sided weakness may be present, especially at the onset of symptoms.
Left MCA deep territory	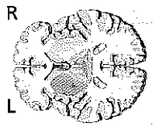	Right pure motor hemiparesis of the upper motor neuron type. Larger infarcts may produce "cortical" deficits as well, such as aphasia.
Left MCA stem		Combination of the above, with right hemiplegia, right hemianesthesia, right homonymous hemianopia, and global aphasia. There is often a left gaze preference, especially at the onset, caused by damage to left hemisphere cortical areas important for driving the eyes to the right.

TABLE 10.1 *(continued)*

LOCATION OF INFARCT	AFFECTED TERRITORY	DEFICITS[a]
Right MCA superior division		Left face and arm weakness of the upper motor neuron type. Left hemineglect is present to a variable extent. In some cases there may also be some left face and arm cortical-type sensory loss.
Right MCA inferior division		Profound left hemineglect. Left visual field and somatosensory deficits are often present; however, these may be difficult to test convincingly because of the neglect. Motor neglect with decreased voluntary or spontaneous initiation of movements on the left side can also occur. However, even patients with left motor neglect usually have normal strength on the left side, as evidenced by occasional spontaneous movements or purposeful withdrawal from pain. Some mild right-sided weakness may be present. There is often a right gaze preference, especially at onset.
Right MCA deep territory		Left pure motor hemiparesis of the upper motor neuron type. Larger infarcts may produce "cortical" deficits as well, such as left hemineglect.
Right MCA stem	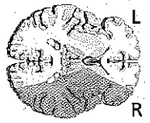	Combination of the above, with left hemiplegia, left hemianesthesia, left homonymous hemianopia, and profound left hemineglect. There is usually a right gaze preference, especially at the onset, caused by damage to right hemisphere cortical areas important for driving the eyes to the left.
Left ACA	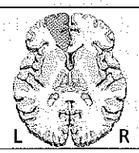	Right leg weakness of the upper motor neuron type and right leg cortical-type sensory loss. Grasp reflex, frontal lobe behavioral abnormalities, and transcortical aphasia can also be seen. Larger infarcts may cause right hemiplegia.
Right ACA		Left leg weakness of the upper motor neuron type and left leg cortical-type sensory loss. Grasp reflex, frontal lobe behavioral abnormalities, and left hemineglect can also be seen. Larger infarcts may cause left hemiplegia.
Left PCA	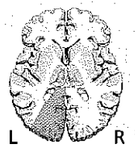	Right homonymous hemianopia. Extension to the splenium of the corpus callosum can cause alexia without agraphia. Larger infarcts including the thalamus and internal capsule may cause aphasia, right hemisensory loss and right hemiparesis.
Right PCA	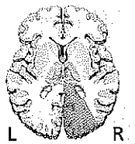	Left homonymous hemianopia. Larger infarcts including the thalamus and internal capsule may cause left hemisensory loss and left hemiparesis.

[a]Compare regions of infarcts to Figure 10.1.

often have a **gaze preference towards the side of the lesion** (see Figure 13.15) especially in the acute period, shortly after onset.

Other combinations not listed in Table 10.1, such as superior plus inferior division infarcts sparing deep territories, or superior division plus deep territories, can occasionally occur. In addition, there are sometimes partial or overlapping syndromes. Smaller cortical infarcts can also occur within one territory, producing more focal deficits, such as monoparesis (see KCC 6.3; Figure 6.14E,F).

Small deep infarcts involving penetrating branches of the MCA or other vessels are called lacunes, as we will discuss in KCC 10.4. Certain characteristic lacunar syndromes (see Table 10.3) can often be distinguished on clinical grounds from infarcts involving large blood vessel territories (see Table 10.1).

Anterior Cerebral Artery (ACA)

ACA infarcts typically produce contralateral lower extremity cortical-type sensory loss (see KCC 7.3) and weakness of the upper motor neuron type. There may also be a variable degree of frontal lobe dysfunction depending, in part, on the size of the infarct. Such dysfunction may include a grasp reflex, impaired judgment, flat affect, apraxia, abulia, and incontinence (see KCC 19.11). Sometimes damage to the supplementary motor area and other regions in the frontal lobe leads to an unusual "alien hand syndrome" characterized by semiautomatic movements of the contralateral arm that are not under voluntary control.

Posterior Cerebral Artery (PCA)

PCA infarcts typically cause a **contralateral homonymous hemianopia** (see Table 10.1, Figure 11.15). Smaller infarcts that do not involve the whole PCA territory may cause smaller homonymous visual field defects. Sometimes the small penetrating vessels that come off the proximal PCA are involved, leading to infarcts in the thalamus or posterior limb of the internal capsule. The result can be a contralateral sensory loss, contralateral hemiparesis, or even thalamic aphasia (see KCC 19.6), if the infarct is in the dominant (usually left) hemisphere thereby mimicking features of MCA infarcts. PCA infarcts that involve the left occipital cortex and the splenium of the corpus callosum can produce alexia without agraphia (see KCC 19.7).

Small perforating vessels arising from the proximal PCAs at the top of the basilar artery (see Figure 4.17B) supply the midbrain. Vascular syndromes of this region of the brainstem will be discussed in Chapter 14 (see KCC 14.3). ■

REVIEW EXERCISE

Cover all but the left-most column in Table 10.1. For each vessel territory, describe the regions of the brain involved (see Figures 10.5, 10.9) and the expected deficits (see Figure 10.1).

KEY CLINICAL CONCEPT
WATERSHED INFARCTS

10.2 When a cerebral artery is occluded, ischemia or infarction occurs in the territory supplied by that vessel, with regions near other vessels relatively spared. In contrast, when the blood supply to two adjacent cerebral arteries is compromised, the regions *between* the two vessels are most susceptible to ischemia and infarction. These regions between cerebral arteries are called **watershed zones** (Figure 10.10). Bilateral watershed infarcts in both the ACA–MCA and MCA–PCA watershed zones can occur with severe drops in systemic blood pressure. A sudden occlusion of an internal carotid artery or a drop in blood pressure in a patient with carotid stenosis (KCC 10.5) can cause an ACA–MCA watershed infarct, since these vessels are both fed by the carotid (see Figure 10.2).

Watershed infarcts can produce proximal arm and leg weakness ("man in the barrel" syndrome) because the regions of homunculus involved often include the trunk and proximal limbs (see Figure 10.1A). In the dominant

Figure 10.10 Watershed Zones for the Major Cerebral Arteries (A) Coronal section. (B) Axial section. Compare to Figure 10.9.

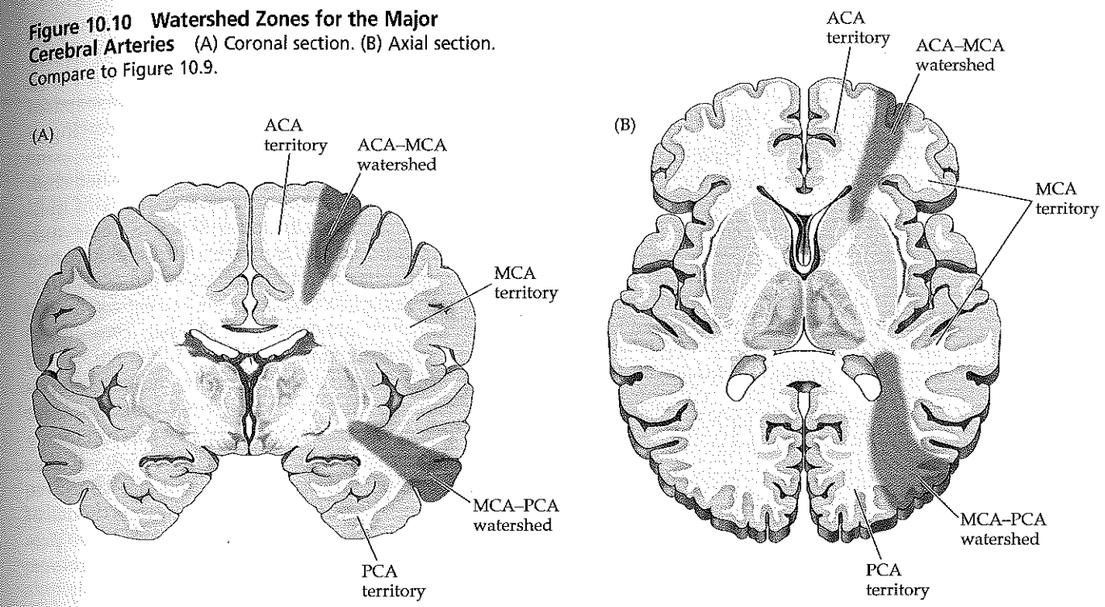

hemisphere, watershed infarcts can cause transcortical aphasia syndromes (see KCC 19.6). MCA–PCA watershed infarcts can cause disturbances of higher-order visual processing (see KCC 19.12). In addition to watershed infarcts between the superficial territories of different cerebral vessels, watershed infarcts can also occasionally occur between the superficial and deep territories of the MCA (see Figure 10.9). ■

KEY CLINICAL CONCEPT
TRANSIENT ISCHEMIC ATTACK AND OTHER TRANSIENT NEUROLOGIC EPISODES

10.3 Transient neurologic episodes are a common diagnostic problem. Symptoms and signs may be positive or negative, and they can be motor, somatosensory, visual, auditory, olfactory, kinesthetic, emotional, or cognitive in nature. Some causes of transient neurologic episodes are listed in Table 10.2. Of these, the **most common causes** are transient ischemic attack, migraine, seizures, and other non-neurologic conditions such as cardiac arrhythmia or hypoglycemia.

In this chapter we will be concerned primarily with transient neurologic episodes caused by cerebrovascular disease. A **transient ischemic attack,** or **TIA,** is classically defined as a neurologic deficit lasting less than 24 hours, caused by temporary brain ischemia. This concept has been revised in recent years for several reasons. First, although some transient ischemic deficits last longer, the more **typical duration for a TIA is about 10 minutes.** Second, improved imaging technology and animal studies suggest that ischemic deficits lasting more than about 10 minutes probably produce at least some permanent cell death in the involved region of the brain. TIAs lasting more than an hour, in fact, are usually small infarcts. On the other hand, despite the appearance of a small infarct on an MRI scan, complete functional recovery can sometimes occur within 1 day. The concept of a TIA remains useful, at the very least, as an important warning sign for a potentially larger ischemic injury to the brain.

Several mechanisms for TIAs have been proposed, each of which may occur in different situations. One possibility is that an embolus temporarily occludes the blood vessel but then dissolves, allowing return of blood flow

TABLE 10.2 Differential Diagnosis of Transient Neurologic Episodes[a]

CATEGORY	EXAMPLES
Structural/mechanical	Intermittent compression of spinal cord or peripheral nerves; Chiari malformation; platybasia
Vascular	Transient ischemic attack (TIA); migraine; arteriovenous malformation; amyloid angiopathy
Epileptic seizures	
CSF flow–related	Colloid cyst of the third ventricle
Genetic	Hypokalemic or hyperkalemic periodic paralysis; episodic ataxias
Toxic/metabolic	Medication related; toxin exposure; hypoglycemia; carcinoid; pheochromocytoma
Infectious/inflammatory	Encephalitis; multiple sclerosis
Movement disorders	Chorea; dystonia; tic disorders
Psychogenic	Panic attacks; dissociative disorders; somatization
Other	Benign paroxysmal positional vertigo; trigeminal neuralgia; narcolepsy
Other non-neurologic	Retinal detachment; shoulder dislocation; angina; cardiac arrhythmias; hypotension; hypoglycemia; peripheral vascular disease; breath-holding spells

[a]Following format of Figure 1.1.

before permanent damage occurs. Other possibilities include in situ thrombus formation on the blood vessel wall and/or vasospasm leading to temporary narrowing of the blood vessel lumen.

TIAs must be distinguished clinically from the other kinds of transient episodes listed in Table 10.2. When transient deficits occur in a typical vascular pattern (KCC 10.1; see also Chapter 14), especially in a patient with stroke risk factors (KCC 10.4), TIA must be high on the list of possible diagnoses, and an appropriate workup should be pursued. Other diagnoses that can commonly mimic TIAs include focal seizures (see KCC 18.2) and migraine (see KCC 5.1). Interestingly, episodes of hypoglycemia can sometimes produce transient focal neurologic deficits, especially in the elderly.

Transient loss of consciousness *without other focal features* is a special case of transient neurologic dysfunction. The most common cause by far is cardiogenic **syncope** including vasovagal transient episodes of hypotension ("fainting"), arrhythmias, and other non-neurologic causes. Neurologic causes are responsible for less than 5 to 10% of cases of syncope, and include seizures (see KCC 18.2), other causes of coma listed in Table 14.4, and rarely, TIA of the posterior circulation affecting the brainstem reticular activating systems (see KCC 14.3).

KEY CLINICAL CONCEPT

ISCHEMIC STROKE: MECHANISMS AND TREATMENT

10.4 Stroke is the third leading cause of death in the United States and a major cause of permanent disability. Recent improvements in the acute diagnostic and therapeutic management of stroke have made it clear that stroke should be handled as an emergency along similar lines to those currently used for cardiac emergencies. **Stroke** refers to both hemorrhagic events, such as intracerebral or subarachnoid hemorrhage, and to ischemic infarction of the brain. Sometimes ischemic strokes can cause blood vessels to become fragile and rupture, leading to secondary **hemorrhagic conversion.** Ischemic stroke is discussed in this section, and nontraumatic intracranial hemorrhage is discussed in KCC 5.6.

Mechanisms of Ischemic Stroke

Ischemic stroke occurs when there is inadequate blood supply to a region of the brain for enough time to cause infarction (death) of brain tissue. There are numerous mechanisms for ischemic stroke. In clinical practice, a distinction is often made between embolic and thrombotic infarcts. In an **embolic infarct** a piece of material (usually a blood clot) is formed in one place and then travels through the bloodstream to suddenly lodge in and occlude a blood vessel supplying the brain. In **thrombotic infarcts** a blood clot is formed locally on the blood vessel wall, usually at the site of an underlying atherosclerotic

plaque, causing the vessel to occlude. Embolic infarcts are considered to occur suddenly with maximal deficits at onset, while thrombotic infarcts may have a more stuttering course. In reality, this distinction is not often easy to make on clinical grounds alone.

Another important distinction is between large-vessel and small-vessel infarcts. **Large-vessel infarcts** involve the major blood vessels on the surface of the brain, such as the middle cerebral artery and its main branches (see KCC 10.1). Large-vessel infarcts are most often caused by emboli, although thrombosis can also occasionally occur, especially in large proximal vessels such as the vertebral, basilar (see KCC 14.3), and carotid arteries. **Small-vessel infarcts** involve the small penetrating vessels that supply deep structures. In the cerebral hemispheres these include the basal ganglia, thalamus, and internal capsule (see Figures 10.7, 10.8), while in the brainstem these include the medial portions of the midbrain, pons, and medulla (see Figures 14.18, 14.20). Small-vessel infarcts are sometimes also called **lacunar infarcts** because they resemble small lakes or cavities when the brain is examined on pathologic section.

In embolic infarcts, the goal is to determine the **source of the embolus** so that future strokes may be prevented. Emboli are most commonly composed of thrombotic material (blood clot). In **cardioembolic infarcts** the embolus originates in the heart. Cardioembolic infarcts occur in conditions such as **atrial fibrillation,** in which thrombi form in the fibrillating left atrial appendage; **myocardial infarction,** in which thrombi form on hypokinetic or akinetic regions of infarcted myocardium; and **valvular disease** or mechanical prostheses, in which thrombi form on the valve leaflets or prosthetic parts. **Artery-to-artery emboli** can also occur. These include emboli arising from a stenosed segment of the internal carotid artery (KCC 10.5), vertebral stenosis, or an ectatic dilated basilar artery. **Dissection** of the carotid or vertebral arteries (KCC 10.6) often results in thrombus formation, which can embolize to the brain. In addition, atherosclerotic disease of the aortic arch is increasingly being recognized as an important potential source of artery-to-artery thromboembolic material. Occasionally, a **patent foramen ovale** can allow a thromboembolus formed in the venous system to bypass the lungs and pass directly from the right to the left side of the heart, reaching the brain.

Aside from thrombus, emboli composed of other materials can, less commonly, lead to stroke. Examples include **air emboli** in deep-sea divers or iatrogenic introduction of air into the circulation; **septic emboli** in bacterial endocarditis, which can lead to mycotic aneurysms and hemorrhage; **fat or cholesterol emboli** in trauma to long bones or to arterial walls; proteinaceous emboli in **marantic endocarditis; disc emboli** in cervical trauma; **amniotic fluid emboli** during childbirth; platelet aggregates; and foreign materials introduced into the circulation (such as talc or other contaminants of illicit intravenous drugs).

Lacunar infarcts are usually associated with small-vessel disease caused by chronic hypertension. In hypertension, small penetrating vessels become occluded by a pathologic process known as **lipohyalinosis.** Small vessels can also be occluded by atherosclerotic disease, in situ thrombosis, or small emboli. Abnormalities of the parent vessel wall such as thrombosis, atheroma formation, or dissection can occlude the openings to one or more small vessels. Numerous characteristic **lacunar syndromes** have been described, and some of the more common ones are listed in Table 10.3. The clinical features of these lacunar syndromes can help localize infarcts and can help distinguish them from large vessel infarcts (see Table 10.1). **Pure motor hemiparesis** (Table 10.3) was already discussed in KCC 6.3 (see also Figure 6.14A). In **ataxic hemiparesis,** the ataxia (see KCC 15.2) is caused by damage to proprioceptive or cerebellar circuitry rather than by damage to the cerebellum itself.

Thalamic lacunes can cause contralateral somatosensory deficits (see KCC 7.3; Figure 7.9A), sometimes followed by a thalamic pain syndrome. **Basal ganglia lacunes** can occasionally cause movement disorders such as hemibalismus (see KCC 16.1). For additional details on less common lacunar syndromes, see the references at the end of this chapter.

Cortical vs. subcortical lesions can sometimes be differentiated clinically based on the absence or presence of so called **cortical signs**, including aphasia (see KCC 19.6), neglect (see KCC 19.9), homonymous visual field defects (see KCC 11.2), and cortical sensory loss (see KCC 7.3). However, each of these deficits can be seen in some cases of subcortical lesions as well. Presence of a typical lacunar syndrome (Table 10.3), such as pure motor hemiparesis, suggests that a subcortical lesion is present. Clinical differentiation between **hemispheric vs. brainstem lesions** will be discussed in KCC 14.3.

In addition to **focal neurological deficits** (see KCC 10.1, 10.2, 11.3, and 14.3), ischemic stroke can be associated with **headache**, or less commonly, **seizures**. Headache (see KCC 5.1) occurs in 25% to 30% of ischemic strokes. When headache is unilateral, it is more commonly on the side of the infarct, although exceptions do occur. Headache may be more common for posterior than for anterior circulation infarcts, and is often seen in dissection of the carotid or vertebral arteries (see KCC 10.6). Seizures (see KCC 18.2) occur in 10% to 15% of stroke patients, occasionally as the presenting abnormality.

TABLE 10.3 Common Lacunar Syndromes

SYNDROME	CLINICAL FEATURES	POSSIBLE LOCATIONS FOR INFARCT	POSSIBLE VESSELS INVOLVED
Pure motor hemiparesis or dysarthria hemiparesis	Unilateral face, arm, and leg upper motor neuron–type weakness, with dysarthria	Posterior limb of internal capsule (common)	Lenticulostriate arteries (common), anterior choroidal artery, or perforating branches of posterior cerebral artery
		Ventral pons (common)	Ventral penetrating branches of basilar artery
		Corona radiata	Small middle cerebral artery branches
		Cerebral peduncle	Small middle cerebral artery branches
Ataxic hemiparesis	Same as pure motor hemiparesis, but with ataxia on same side as weakness	Same as pure motor hemiparesis	Same as pure motor hemiparesis
Pure sensory stroke (thalamic lacune)	Sensory loss to all primary modalities in the contralateral face and body	Ventral posterior lateral nucleus of the thalamus (VPL)	Thalamoperforator branches of the posterior cerebral artery
Sensorimotor stroke (thalamocapsular lacune)	Combination of thalamic lacune and pure motor hemiparesis	Posterior limb of the internal capsule, and either thalamic VPL or thalamic somatosensory radiation	Thalamoperforator branches of the posterior cerebral artery, or lenticulostriate arteries
Basal ganglia lacune	Usually asymptomatic, but may cause hemiballismus (see KCC 16.1)	Caudate, putamen, globus pallidus, or subthalamic nucleus	Lenticulostriate, anterior choroidal, thalamoperforator, or Heubner's arteries

To summarize:

- Emboli usually cause large-vessel infarcts involving cerebral or (less commonly) cerebellar cortex, with sudden onset of maximal deficits.
- Lacunes are small-vessel infarcts usually seen in chronic hypertension, commonly affecting the deep white matter and nuclei of the cerebral hemispheres and brainstem.
- Thrombosis occasionally occurs in large proximal vessels such as vertebral, basilar, and carotid arteries and may also contribute to lacunar infarction.

Stroke Risk Factors

Certain patients are at increased risk for vascular disease, including ischemic stroke. When the history is being taken, patients should be asked if they have the following common vascular risk factors: hypertension, diabetes, hypercholesterolemia, cigarette smoking, family history, or prior history of stroke or other vascular disease (Table 10.4). In addition, certain cardiac disorders are important risk factors for stroke, especially atrial fibrillation, mechanical valves or other valvular abnormalities, patent foramen ovale (mentioned in the preceding section), and a severely decreased ejection fraction.

Less commonly, several other systemic medical conditions may affect the coagulation pathways or work through other mechanisms to increase both thrombotic and embolic infarcts (Table 10.5). These hypercoagulate states also increase the risk for venous thrombosis (see KCC 10.7).

Ischemic stroke is relatively uncommon in young individuals because the cumulative effects of the major stroke risk factors (see Table 10.4) tend to worsen with age. When stroke does occur in a **young patient,** conditions such as arterial dissection (see KCC 10.6), patent foramen ovale, or the disorders listed in Table 10.5 should be considered in addition to the usual causes.

Treatment and Diagnostic Workup of Ischemic Stroke and TIA

There is a growing movement to treat stroke or TIA as an acute medical emergency or **brain attack,** similar to heart attack. Prompt medical attention allows early therapeutic interventions that improve outcome. When the history and exam suggest a possible ischemic event, an imaging study of the brain should be done immediately to rule out hemorrhage. In most emergency rooms, CT scans can be performed more quickly than MRI scans, and a CT will suffice for this purpose. Remember that an infarct will often not be visible on the initial CT scan, especially if it is done within a few hours of symptom onset; however, a hemorrhage will almost always be visible (see Chapter 4). Meanwhile, routine blood chemistries, cell counts, and coagulation studies should be sent. Specialized coagulation studies can be sent when clinically appropriate (Table 10.5), such as in a young individual with no known vascular risk factors.

Once a hemorrhage has been ruled out by CT, many physicians treat patients with thrombolytic agents, such as **tissue plasminogen activator (t-PA)**, in acute ischemic stroke. This treatment has been demonstrated to be effective, and it improves the chances of a good functional outcome if given *within 3 hours* of stroke onset; however, it does carry some increased risk of intracranial hemorrhage. In patients with stroke who are not eligible for t-PA, or in patients who have had a TIA, **heparin** anticoagulation is often used while further diagnostic studies are being performed. As with t-PA, it is essential to rule out the presence of intracranial hemorrhage before administering this treatment. There is some controversy over the use of heparin in acute stroke, and further studies will be needed to investigate its safety and efficacy.

Other acute interventions being investigated include intra-arterial thrombolysis. This is performed by catheterization of the occluded vessel

TABLE 10.4 Common Stroke Risk Factors

- Hypertension
- Diabetes
- Hypercholesterolemia
- Cigarette smoking
- Positive family history
- Cardiac disease (valvular disease, atrial fibrillation, patent foramen ovale, low ejection fraction)
- Prior history of stroke or other vascular disease

TABLE 10.5 Medical Conditions Leading to Hypercoagulability

- Protein S deficiency
- Protein C deficiency
- Antithrombin III deficiency
- Other hereditary coagulation factor disorders
- Dehydration
- Adenocarcinoma
- Surgery, trauma, childbirth
- Disseminated intravascular coagulation
- Antiphospholipid antibody syndromes
- Vasculitis (effects on vessel wall in addition to hypercoagulability):
  - Temporal arteritis
  - Primary central nervous system vasculitis (granulomatous angiitis)
  - Systemic lupus erythematosus
  - Polyarteritis nodosa
  - Wegener's granulomatosis
  - Other rheumatological disorders
  - Infections
  - Neoplasms
- Sickle cell disease
- Polycythemia
- Leukemia
- Cryoglobulinemia
- Homocystinuria (increases risk of atherosclerosis)

(see Figure 4.9), which allows direct administration of the thrombolytic agent to the thrombus. In addition, several compounds are being tested that may preserve brain tissue before irreversible cell damage occurs, such as antioxidants, calcium channel blockers, and glutamate receptor antagonists. Angioplasty and stenting of stenosed vertebral, carotid, and intracranial vessels are being tried along the lines of similar procedures in coronary arteries. Finally, **hyperglycemia** should be corrected in acute stroke because it can worsen infarctions, possibly by increasing local tissue acidosis and blood–brain barrier permeability.

Patients are best managed in an inpatient setting, and some studies suggest improved outcomes on specialized stroke units. The **diagnostic evaluation** begins with the patient history and exam, including questions about stroke risk factors (see Table 10.4), and continues with certain diagnostic tests, which we will now discuss. **Blood flow in the major cranial and neck vessels** should be assessed with Doppler ultrasound and/or magnetic resonance angiography (MRA; see Figures 4.18, 4.19). *This is particularly important in suspected internal carotid artery stenosis,* since carotid endarterectomy may be required (see KCC 10.5). Conventional angiography may be needed in cases where the degree of stenosis is uncertain based on these invasive tests.

The possibility of a cardioembolic source should be investigated with an **electrocardiogram** to look for evidence of cardiac ischemia or arrhythmias, and an **echocardiogram** to look for structural abnormalities or thrombi. Some practitioners perform a 24-hour Holter monitor test to look for arrhythmias, although the diagnostic yield of this test may be low if used in all patients. Studies have shown that *patients with atrial fibrillation are at increased risk of embolic stroke,* and that this risk is significantly reduced when they are treated with Coumadin oral anticoagulation. As already mentioned, young patients with stroke or other patients with suggestive history should also be evaluated for the less common conditions listed in Table 10.5.

In patients with large MCA infarcts, there may be subtantial edema and mass effect, which can sometimes lead to herniation (see KCC 5.4) and death. One therapeutic measure that is being investigated for such patients is **hemicraniectomy,** in which a portion of skull is temporarily removed over the region of swelling and is later replaced after the danger of herniation has passed.

Because stroke often occurs in conjunction with other serious medical disorders, a multidisciplinary treatment approach is appropriate. Careful attention to medical complications, high quality nursing care, and a comprehensive rehabilitation program can substantially reduce morbidity and mortality.

Preventive measures are most important in reducing the incidence of stroke. Modifiable risk factors such as hypertension, smoking, and hypercholesterolemia should be addressed. In addition, antiplatelet drugs such as aspirin have been shown to reduce the risk of ischemic stroke recurrence. ■

KEY CLINICAL CONCEPT
CAROTID STENOSIS

10.5 Atherosclerotic disease commonly leads to stenosis of the internal carotid artery just beyond the carotid bifurcation (see Figures 4.19B, 10.2). Thrombi formed on a stenotic internal carotid artery can embolize distally, giving rise to TIAs or infarcts of various carotid branches, especially the MCA, ACA, and ophthalmic artery. Carotid stenosis is thus associated with MCA territory symptoms such as contralateral face–arm or face–arm–leg weakness, contralateral sensory changes, contralateral visual field defects, aphasia, or neglect. In addition, there may be ophthalmic artery symptoms such as ipsilateral monocular visual loss (see KCC 11.3), and ACA territory symptoms such as contralateral leg weakness.

Carotid stenosis can sometimes be detected on physical examination as a whooshing sound, or **bruit,** that continues into diastole and is best heard with the bell of the stethoscope applied lightly just below the angle of the jaw (see neuroexam.com Video 2). The severity of carotid stenosis can usually be estimated noninvasively with Doppler ultrasound and MRA, although conventional angiography remains the gold standard. Recent studies have demonstrated an important role for **carotid endarterectomy** in symptomatic carotid stenosis. In this procedure the carotid artery is exposed surgically and temporarily clamped. A longitudinal incision is made in the artery, and atheromatous material is shelled out from the internal carotid lumen, eliminating the stenosis. Carotid endarterectomy has been compared prospectively with medical therapy in patients who had a stroke or TIA on the side of a >70% stenosis of the internal carotid artery. Over 2 years of follow-up in one major trial (the North American Symptomatic Carotid Endarterectomy Trial), the rate of stroke on the side of the stenosis was 26% in the medically treated group, compared to 9% in the group that underwent endarterectomy. Studies have also suggested that in less severe (50% to 70%) carotid stenosis with symptoms or severe carotid stenosis even without symptoms, outcome may be improved by surgery, although the data is less convincing than in symptomatic carotid stenosis.

Carotid auscultation

Sometimes an internal carotid artery can gradually or suddenly become 100% occluded, causing infarcts in the MCA, ACA, or ACA–MCA watershed territories (see KCC 10.1, 10.2). **Carotid occlusion** may be completely asymptomatic if there is adequate collateral flow via the anterior or posterior communicating arteries (see Figures 10.2, 10.3). The occlusion usually occurs just beyond the carotid bifurcation, and the vessel then becomes filled with thrombus up to the level of the ophthalmic artery, which is perfused by collateral flow. Emboli may become dislodged from the top of the thrombus and cause TIAs or strokes. In contrast to carotid stenosis, endarterectomy is not usually performed in cases of 100% carotid occlusion because of the risk of dislodging more emboli, and because the procedure has no proven benefit. Because of the different therapeutic implications, it is thus critical to distinguish severe carotid stenosis from carotid occlusion.

Another mechanism for infarction with carotid stenosis is a sudden drop in systemic blood pressure, leading to infarction in the ACA–MCA watershed territory (see KCC 10.2). ■

KEY CLINICAL CONCEPT
DISSECTION OF THE CAROTID OR VERTEBRAL ARTERIES

10.6 Head or neck trauma, and sometimes even minor events such as a cough or sneeze, can cause a small tear to form on the intimal surface of the carotid or vertebrate arteries. This may allow blood to burrow into the vessel wall, producing a **dissection.** A flap then protrudes into the vessel lumen, under which thrombus forms that can embolize distally. Patients with a dissection may describe feeling or hearing a pop at the onset. In **carotid dissection** they may hear a turbulent sound with each heartbeat and have an ipsilateral Horner's syndrome (see KCC 13.5) and pain over the eye. In **vertebral dissection,** there is often posterior neck and occipital pain. TIAs or infarcts occur in the anterior circulation with carotid dissection, and in the posterior circulation with vertebral dissection. There may be a delay of hours to up to several weeks between onset of dissection and ischemic events. Dissection is usually treated with intravenous heparin anticoagulation followed by oral Coumadin anticoagulation to prevent thromboembolic events. The required duration of therapy has not been studied, but most practitioners continue anticoagulation for several months and perform follow-up MRAs to ensure adequate vessel patency before discontinuing anticoagulation. Sometimes dissection, particularly of the vertebral artery, leads to formation of a pseudoaneurysm that may rarely rupture, causing subarachnoid hemorrhage. ■

Venous Drainage of the Cerebral Hemispheres

Like the arterial system, the venous drainage of the brain has superficial and deep territories. The **superficial veins** drain mainly into the **superior sagittal sinus** and the **cavernous sinus,** while the **deep veins** drain into the **great vein of Galen** (Figure 10.11). Ultimately, nearly all venous drainage for the brain reaches the **internal jugular veins.** As we discussed in Chapter 5, the major cerebral venous sinuses lie enclosed within folds of the two layers of dura (see Figure 5.1).

Figure 10.11 Venous Drainage of the Cerebral Hemispheres

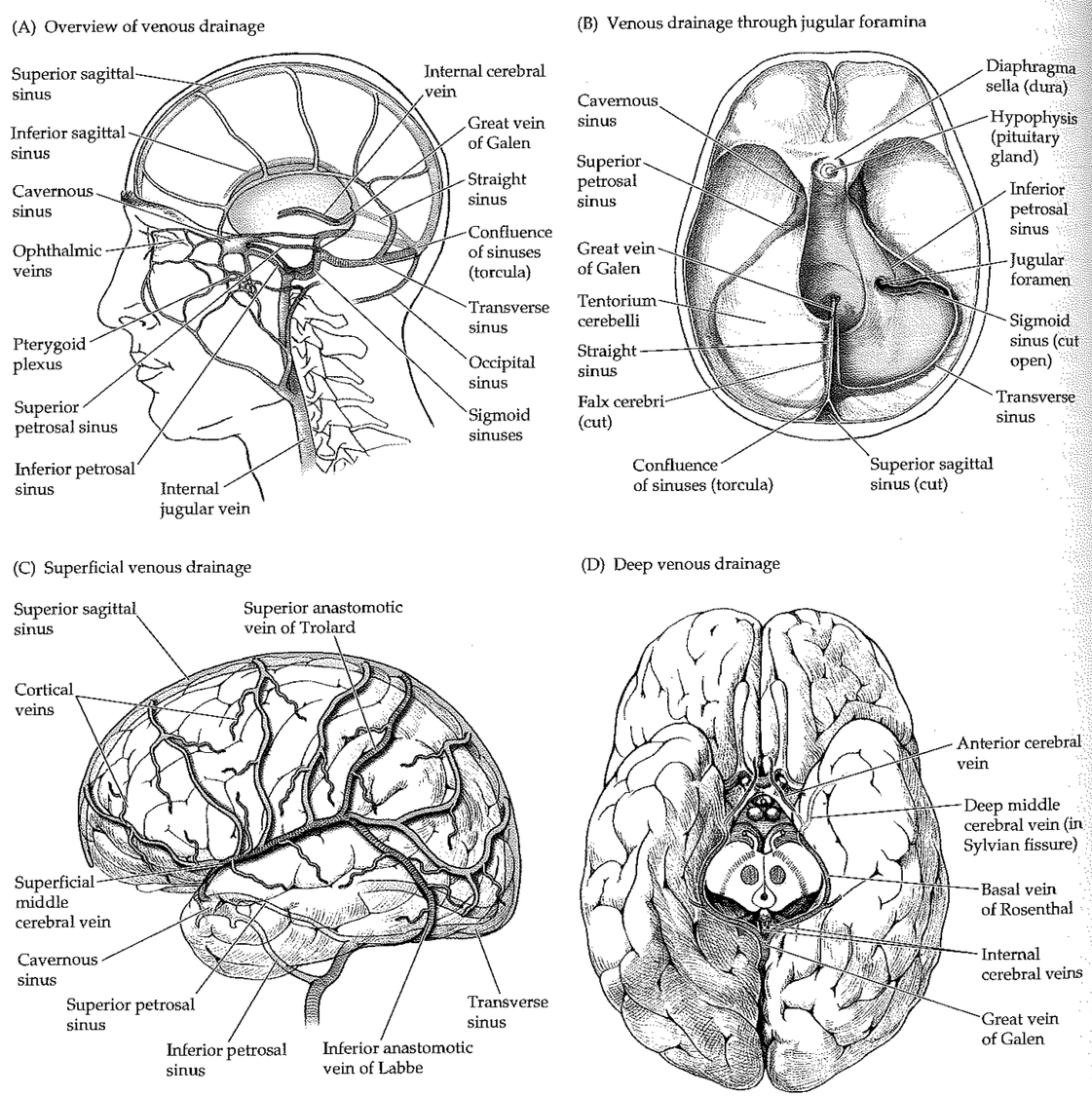

The superior sagittal sinus sweeps back and drains into the two **transverse sinuses** (Figure 10.11A,B). Each of these sinuses turns downward to become a **sigmoid sinus** that exits the skull through the **jugular foramen,** forming the internal jugular vein. The **cavernous sinus** is a plexus of veins located on either side of the sella turcica that surrounds portions of the internal carotid artery and cranial nerves III, IV, V, and VI (see also Figure 13.11). The cavernous sinus drains via the **superior petrosal sinus** into the transverse sinus, and via the **inferior petrosal sinus** into the internal jugular vein (see Figure 10.11A,B). The deep structures drain into the **internal cerebral veins** (see Figure 4.7), the **basal veins of Rosenthal,** and other veins to reach the **great cerebral vein of Galen** (see Figure 10.11B,D). The great vein of Galen enters the dura of the tentorium and is joined by the **inferior sagittal sinus** to form the **straight sinus,** or **sinus rectus** (see Figure 10.11B; see also Figure 4.15A).

The **confluence of the sinuses,** also known as the **torcular Herophili** (or more simply as the **torcula**), occurs where the superior sagittal, straight, and occipital sinuses join together and are drained by the transverse sinuses (see Figure 10.11A,B). The torcula is often shaped in such a manner that most blood from the superior sagittal sinus enters the right transverse sinus, while most blood from the straight sinus enters the left transverse sinus.

Although **cortical veins** are highly variable, a few major, fairly constant veins include the **inferior anastomotic vein of Labbe,** which drains into the transverse sinus, the **superior anastomotic vein of Trolard,** which drains into the superior sagittal sinus, and the **superficial middle cerebral vein,** which drains into the cavernous sinus (see Figure 10.11C). The **anterior cerebral veins** and **deep middle cerebral veins** drain into the **basal veins of Rosenthal,** which then join the internal cerebral veins to form the great vein of Galen (see Figure 10.11D).

REVIEW EXERCISE

Which sinuses receive most of the venous blood from the cortical surface? What vein receives most of the venous blood from deep structures (see Figure 10.11C,D)?

KEY CLINICAL CONCEPT

SAGITTAL SINUS THROMBOSIS

10.7 Sagittal sinus thrombosis is often associated with one of the hypercoagulable states listed in Table 10.5. It occurs with increased frequency in pregnant women and within the first few weeks post partum. Obstruction of venous drainage usually causes elevated intracranial pressure (see KCC 5.3). Back pressure in cortical veins can cause parasagittal hemorrhages. In addition, the increased venous pressure can decrease cerebral perfusion, leading to infarcts. Seizures are common. Patients often have headaches and papilledema, and they may have depressed level of consciousness. The superior sagittal sinus can normally be seen as a triangular region on axial CT and MRI scan images (see Figures 4.12, 4.13). The sinus normally fills with intravenous contrast (see Figure 4.4), but in sagittal sinus thrombosus there may be a central, darker-filling defect, called the **empty delta sign**. More subtle radiological signs of sagittal sinus thrombosus include increased density of the sagittal sinus on CT due to coagulated blood (see Table 4.1), or increased T1 signal on MRI (see Table 4.4). In suspected sagittal sinus thrombosus, regardless of whether these subtle radiological findings are present, a more definitive study should be performed, such as magnetic resonance venography (MRV) or a conventional angiogram. Treatment usually involves anticoagulation therapy, although this is controversial when hemorrhage has occurred. Seizures (see KCC 18.2) and elevated intracranial pressure (see KCC 5.3) should be treated as well when present.

Thrombosis can also occur less commonly in the deep cerebral veins or in a major cortical vein, leading to infarcts or hemorrhage in the territories of these vessels. ■

CLINICAL CASES

CASE 10.1 SUDDEN-ONSET WORST HEADACHE OF LIFE

MINICASE

A 68-year-old man suddenly developed **"the worst headache of my life."** He had a history of severe diffuse atherosclerosis, including coronary artery disease and peripheral vascular disease requiring multiple bypass operations. He was also a heavy smoker for over 40 years. On the morning of admission he was walking in the hallway at home, and at 10:00 AM he suddenly developed an explosive headache worse than anything he had ever experienced. The headache began in the bifrontal area and over the next few minutes spread all over his head and down his neck. He denied nausea, vomiting, loss of consciousness, or vision changes. Examination was unremarkable except for **mild nuchal rigidity.**

LOCALIZATION AND DIFFERENTIAL DIAGNOSIS

1. What diagnosis should be suspected in cases with this kind of clinical presentation (see Chapter 5)?
2. What is the most common cause of this disorder, and what vessels are most commonly affected?
3. What is the significance of the nuchal rigidity?
4. What tests should be performed?

Discussion

1. Sudden onset of severe headache that is worse than any experienced previously should be considered a subarachnoid hemorrhage until proven otherwise (see KCC 5.1, 5.6).
2. In about 80% of cases, spontaneous subarachnoid hemorrhage is caused by rupture of an arterial aneurysm in the subarachnoid space. The most common locations for aneurysms are the origin of the anterior communicating artery, posterior communicating artery, or bifurcation points of the middle cerebral artery (see Figure 5.20).
3. Nuchal rigidity is often a sign of meningeal irritation (see Table 5.5) caused by inflammation, infection, or hemorrhage in the subarachnoid space.
4. In suspected subarachnoid hemorrhage an emergency head CT should be performed. Rarely, the CT is negative in subarachnoid hemorrhage, so if the clinical situation suggests subarachnoid hemorrhage, a lumbar puncture should then be performed (see KCC 5.10). Lumbar puncture should not be performed if the CT is positive, especially since lumbar puncture can occasionally cause aneurysmal rupture by increasing the pressure across the wall of the aneurysm. If the patient is a candidate for surgery, once the diagnosis of subarachnoid hemorrhage has been confirmed, an angiogram should be performed to localize the aneurysm so that it can promptly be treated surgically.

Neuroimaging 393

The patient underwent an emergency **head CT** (Figure 10.12A), which demonstrated regions of hyperdensity in the subarachnoid space consistent with diffuse subarachnoid hemorrhage layering in the interhemispheric fissure, in the Sylvian fissures, and around the brainstem. In addition, the lateral ventricles appeared mildly dilated, compatible with hydrocephalus. This can occur from impaired CSF flow in the subarachnoid space because of the hemorrhage (see KCC 5.7). Next the patient was taken for an **angiogram** (see Figure 10.12B–D).

1. What blood vessel was injected with contrast dye to produce the images in Figure 10.12B–D? Cover the labels on Figure 10.12 and identify the internal carotid, anterior cerebral, and middle cerebral arteries (including the lenticulostriate arteries). Note the presence of a saccular aneurysm measuring approximately 1 cm in diameter.
2. What is the site of origin of the aneurysm?

Discussion

1. Injection of the left carotid artery caused opacity of the left internal and external carotid arteries, of the left middle cerebral artery (including the lenticulostriate arteries), and, through the anterior communicating artery, of the anterior cerebral arteries bilaterally.
2. In the oblique view (Figure 10.12D), the aneurysm can be clearly seen to arise in the region of the anterior communicating artery. The patient underwent craniotomy (see KCC 5.11) and clipping of the aneurysm, and subsequently recovered fully.

CASE 10.2 LEFT LEG WEAKNESS AND LEFT ALIEN HAND SYNDROME

CHIEF COMPLAINT

A 67-year-old woman suddenly developed left leg weakness and difficulty using her left hand.

HISTORY

Past history was notable for hypertension, peripheral vascular disease, and smoking one pack per day for 40 years. On the morning of admission, after finishing breakfast the patient tried to stand up and suddenly found she could not support her weight. She fell against a door, scraping her left side, but managed to reach a telephone and call an ambulance.

PHYSICAL EXAMINATION

Vital signs: T = 98°F, P = 76, BP = 140/90, R = 14.
Neck: Supple with no bruits.
Lungs: Clear.
Heart: Regular rate.
Abdomen: Soft.
Extremities: A few abrasions present on the left arm and leg.
Neurologic exam:

MENTAL STATUS: Alert and oriented × 3. The patient seemed **unaware at times of any weakness on her left side and did not complain about her abrasions.** Language was fluent.

CRANIAL NERVES: Normal, except for a **minimally decreased left nasolabial fold and mild dysarthria.**

MOTOR: Power 5/5 throughout, except for **1/5 to 2/5 strength in the left leg, both proximally and distally, and 4/5 strength in the proximal left arm.**

REFLEXES:

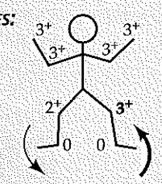

COORDINATION AND GAIT: Not tested.

SENSORY: **There was inconsistent decreased response to pinprick on the left side.**

CLINICAL COURSE

The patient's weakness temporarily worsened, so that by 2 days after admission she had 0/5 strength in both the left leg and arm. She also had **extinction on the left side to double simultaneous tactile stimulation.** One month later the patient had recovered 3/5 strength in the left arm but continued to have 0/5 strength in the left leg. Interestingly, she felt that her **left arm was "out of control."** Her left arm would occasionally grab onto things without her being aware of it, and she then had to use her right arm to release its **grasp.** She could not localize her left arm in space and had difficulty using the left hand to perform voluntary activities, with marked **motor impersistence.** When distracted, however, she could use both hands to perform certain automatic overlearned behaviors, such as folding a piece of paper in half.

LOCALIZATION AND DIFFERENTIAL DIAGNOSIS

1. On the basis of the symptoms and signs shown in **bold** above, where is the lesion?
2. What is the most likely diagnosis, and what are some other possibilities?

Discussion

1. The key symptoms and signs in this case are:
   - **Profound weakness of the left leg, with mild weakness of the left arm and face, mild dysarthria, left leg hyperreflexia, and Babinski's sign**
   - **Left grasp reflex and motor impersistence**
   - **Left arm "out of control"**
   - **Unawareness of left-sided weakness and abrasions, decreased response to pinprick on the left, tactile extinction on the left**

   Upper motor neuron–type weakness of the left leg could be caused by a lesion in the right primary motor cortex leg area, or the left thoracolumbar spinal cord (see KCC 6.3; Figure 6.14F). However, since there was also mild dysarthria and some left face and arm weakness, there must also have been some milder involvement of corticobulbar and corticospinal fibers for the face and arm, ruling out a spinal cord lesion. A grasp reflex and motor impersistence suggest a frontal lobe lesion (see KCC 19.11). The unusual behavior of her left arm is compatible with an alien hand syndrome (see KCC 10.1), sometimes seen in lesions of the supplementary motor area (see Figure 6.1). Anosognosia and contralateral neglect (see KCC 19.10) can be seen in nondominant (usually right) hemisphere lesions, especially in the parietal lobe, but sometimes also in the frontal lobe. In addition, some of the patient's apparent left-sided weakness may have been due to left motor neglect rather than to actual weakness, as suggested by her preserved ability to use her left hand well at times.

   The most likely *clinical localization* is right primary motor cortex foot area, supplementary motor area, and other adjacent regions of the right frontal or parietal lobes.
2. Given the sudden onset of the deficits, together with the patient's age, history of hypertension, smoking, and peripheral vascular disease, the most likely diagnosis is an embolic stroke (KCC 10.4). An infarct of the right medial frontal lobe including foot motor cortex and supplementary motor area would be caused by occlusion of the right anterior cerebral artery (KCC 10.1). Another, less likely cause of a lesion in the cortex in this setting would be a hemorrhage. Since the deficits improved over time, a tumor or infection is unlikely as the cause.

Neuroimaging 395

A head CT scan done shortly after admission suggested probable right anterior cerebral artery infarct. Follow-up **head CT scan** 1 month after admission (Figure 10.13) confirmed the presence of a hypodense area on the anterior medial aspect of the right hemisphere consistent with a right anterior cerebral artery infarct (compare to Figures 10.4, 10.5, and 10.9).

CASE 10.3 DECREASED VISION ON ONE SIDE

CHIEF COMPLAINT

A 63-year-old woman went to an ophthalmologist because of episodes of decreased vision in her "right eye" and headaches.

HISTORY

Past medical history was notable for diabetes, elevated cholesterol, and coronary artery disease. About 5 or 6 weeks ago the patient began having **episodes of sudden "blurry wavy" appearance of her vision. She believed this was mostly in the right eye,** but she did not try looking with one eye at a time. The episodes would last 15 to 20 minutes, occurring three to four times per week, and were accompanied by a **severe left retro-orbital headache.** She was able to recognize faces during the episodes but had difficulty reading. She denied any other symptoms. Two days ago an episode began that resulted in persistent decreased vision on the right.

CASE 10.3 *(CONTINUED)*

PHYSICAL EXAMINATION

Vital signs: T = 98.6°F, P = 84, BP = 180/78, R = 20.
Neck: Supple with no bruits.
Lungs: Clear.
Heart: Regular rate with no murmurs.
Abdomen: Soft, nontender.
Neurologic exam:

MENTAL STATUS: Alert and oriented × 3. Speech fluent.

CRANIAL NERVES: Pupils 3 mm, constricting to 2 mm bilaterally. Normal fundi. Visual acuity 20/30 right eye, 20/25 left eye. Visual field testing (see KCC 11.2) revealed a **right homonymous hemianopia** (Figure 10.14). Extraocular movements intact. Facial sensation intact to light touch and pinprick. Face symmetrical. Normal palate elevation. Normal shoulder shrug. Tongue midline.

MOTOR: No drift. Normal tone. 5/5 power throughout.

REFLEXES:

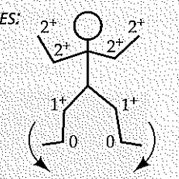

COORDINATION: Normal on finger-to-nose and heel-to-shin testing.

GAIT: Normal.

SENSORY: Intact pinprick and joint position sense. Pinprick and vibration sense diminished in both feet (likely related to diabetic neuropathy).

LOCALIZATION AND DIFFERENTIAL DIAGNOSIS

On the basis of the symptoms and signs shown in **bold** above, where is the lesion? What is the most likely diagnosis, and what are some other possibilities?

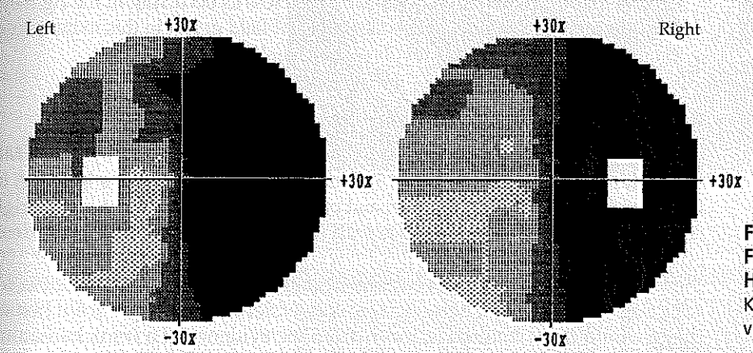

Figure 10.14 Automated Visual Field Mapping Showing Right Homonymous Hemianopia See KCC 11.2 for discussion of automated visual field mapping.

Discussion

The key symptoms and signs in this case are:

- **Right homonymous hemianopia**
- **Left retro-orbital headache**

As we will discuss in Chapter 11, a right homonymous hemianopia can be caused by a lesion in the left hemisphere visual pathways anywhere from the left optic tract to the left primary visual cortex (see Figure 11.15). The transient episodes of 15 to 20 minutes of decreased right-sided vision occurring

over several weeks, followed by a persistent deficit, are suggestive of TIAs (see KCC 10.3) preceding a cerebral infarct (see KCC 10.4). In addition, the patient's age and history of diabetes, hypercholesterolemia, and coronary artery disease raise the suspicion for cerebrovascular disease as the cause. Following the visual pathways from front to back, the optic tract and lateral geniculate nucleus of the thalamus are supplied by multiple small vessels. Infarcts of the optic tract are rare, and infarcts of the lateral geniculate nucleus are usually accompanied by damage to the adjacent internal capsule, causing contralateral hemiparesis. Infarcts of the entire optic radiation can occur, with large MCA infarcts causing a hemianopia; however, this would also result in a contralateral hemiplegia and other deficits. Thus, the most common cause of hemianopia without other deficits is infarction of the primary visual cortex caused by occlusion of the posterior cerebral artery. The patient's left retro-orbital headache is also consistent with left PCA disease (see KCC 10.4). Occasionally, proximal PCA occlusion can involve small penetrating vessels (see Figures 10.8, 10.9), resulting in infarction of the thalamus or internal capsule as well. However, this patient did not have somatosensory or motor deficits, so the most proximal segment of the PCA must be spared. Other, less likely diagnoses in this setting include hemorrhage, tumor, abscess, or demyelination in the left occipital cortex.

The most likely *clinical localization* and *diagnosis* is: Left primary visual cortex lesion caused by left posterior cerebral artery infarct.

Note that the patient described her vision loss as occurring in the right eye. It is common for patients to describe a visual field defect in this manner even though in reality the defect involves the visual fields of both eyes.

Clinical Course and Neuroimaging 396

An initial CT scan suggested left PCA infarct, and a follow-up **head MRI scan** a few days later (Figure 10.15) confirmed the presence of a left PCA infarct involving the left primary visual cortex. Note the presence of T2 bright signal in Figure 10.15A, consistent with increased water content from edema and necrosis. In addition, on the T1-weighted images (see Figure 10.15C) there were some bright areas consistent with methemoglobin (see Table 4.4) resulting from petechial hemorrhagic conversion. A more significant hemorrhage would have resulted in more dramatic evidence of a frank hematoma seen on both T1- and T2-weighted images.

The patient was admitted to the hospital and placed on intravenous heparin anticoagulation while testing was done, including a cardiac Holter monitor, an echocardiogram, and Doppler studies of the neck vessels to look for a source for the embolus (see KCC 10.4). These tests were negative; however, a magnetic resonance angiogram revealed multiple stenoses of the cerebral vessels compatible with diffuse intracranial atherosclerotic disease. It was therefore felt that the patient most likely had an artery-to-artery embolus, or a PCA thrombosis caused by severe atherosclerotic disease, and she was treated with long-term oral anticoagulation. Her right hemianopia did not improve, but over time she learned to adapt to her deficit with improved reading and extra caution to avoid bumping into objects on her right side.

CASE 10.1 SUDDEN-ONSET WORST HEADACHE OF LIFE

Figure 10.12 Subarachnoid Hemorrhage Caused by Aneurysmal Bleeding (A) Head CT axial image demonstrating subarachnoid blood and hydrocephalus. (B) Angiogram, anterior–posterior view. (C) Angiogram, lateral view. (D) Angiogram, oblique view.

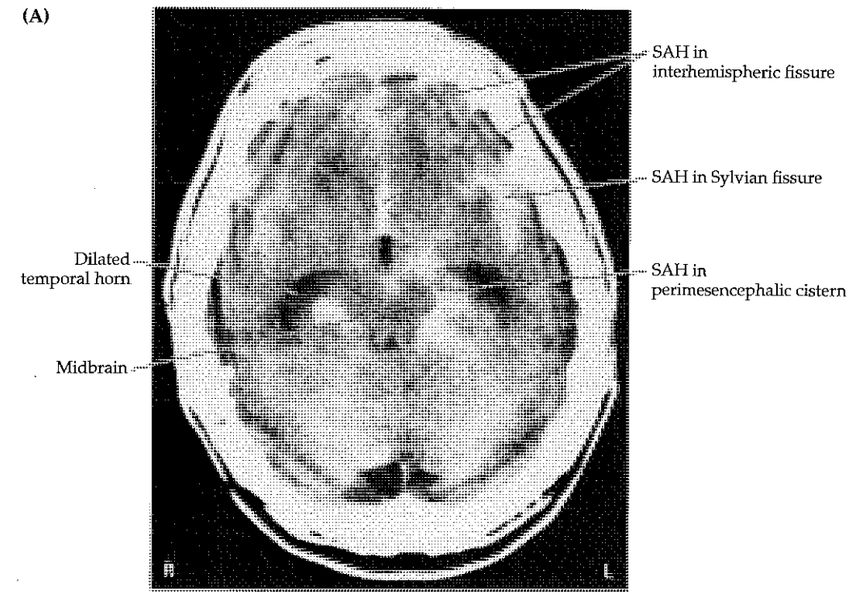

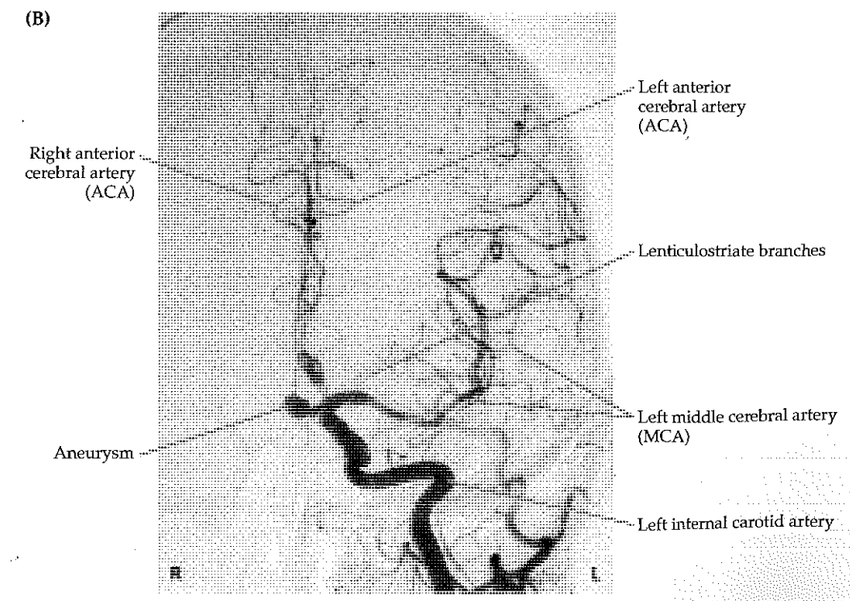

CASE 10.1 *(CONTINUED)*

(C)

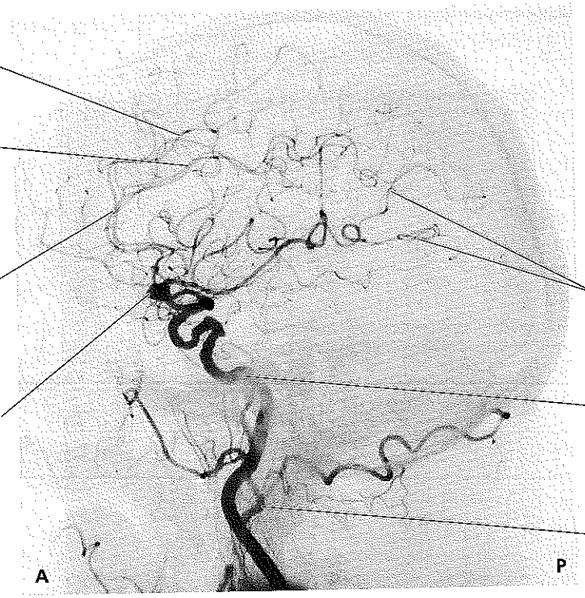

(D)

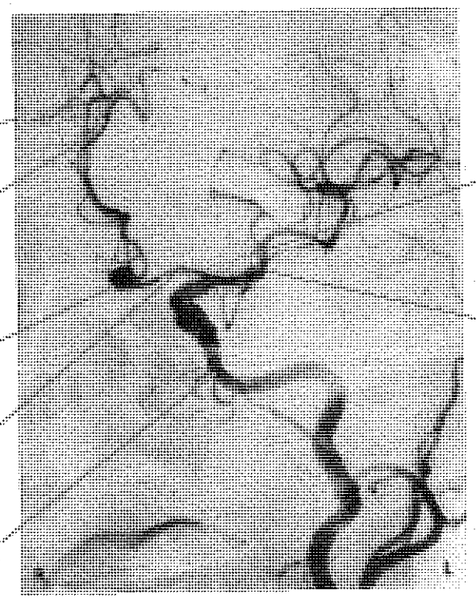

CASE 10.2 LEFT LEG WEAKNESS AND LEFT ALIEN HAND SYNDROME

Figure 10.13 Right Anterior Cerebral Artery (ACA) Infarct (A, B) Axial CT images progressing from inferior to superior. The central sulcus was located by following it down from higher sections (not shown; compare to Figure 4.12).

(A)

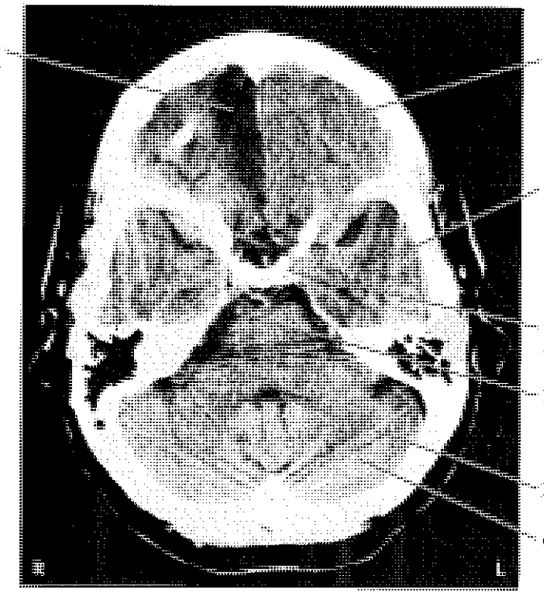

(B)

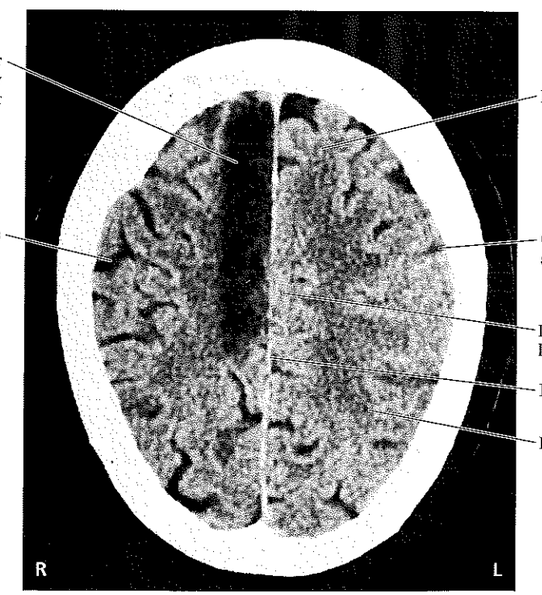

CASE 10.3 DECREASED VISION ON ONE SIDE

Figure 10.15 Left Posterior Cerebral Artery (PCA) Infarct MRI of the brain. (A,B) Axial T2-weighted images proceeding from inferior to superior. (C) Parasagittal T1-weighted image of left hemisphere showing bright areas consistent with petecheal hemorrhage in the region of the PCA infarct. (D) Parasagittal T1-weighted image of normal right hemisphere from the same patient for comparison, showing locations of calcarine and parieto-occipital fissures.

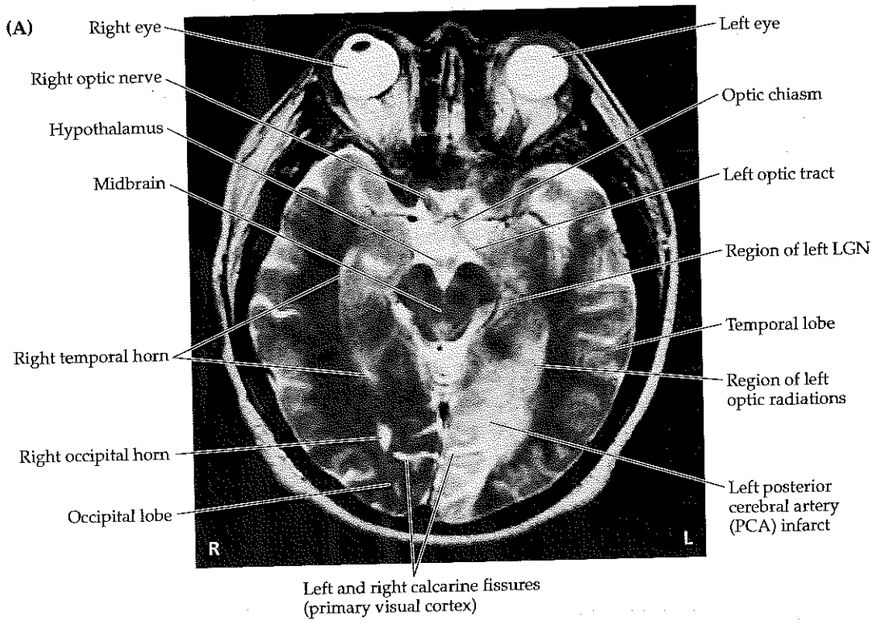

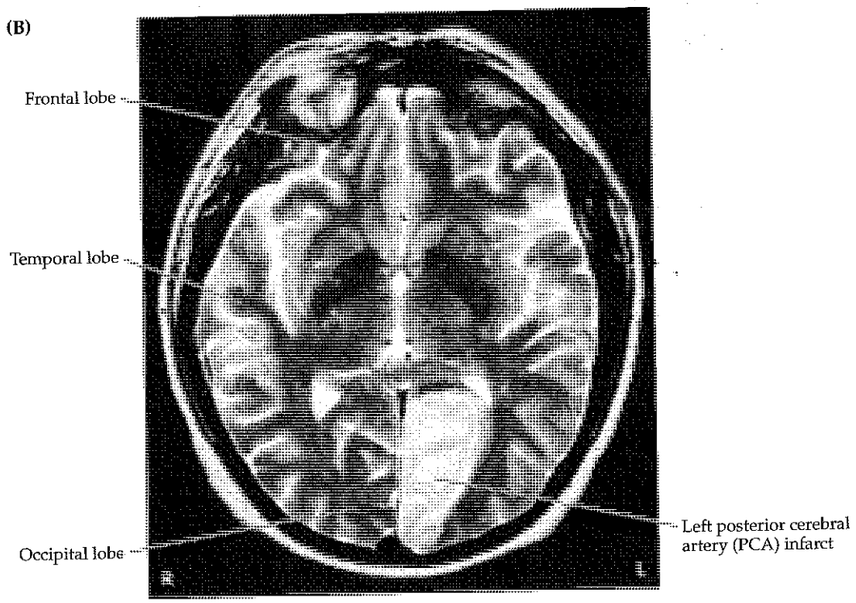

CASE 10.3 *(CONTINUED)*

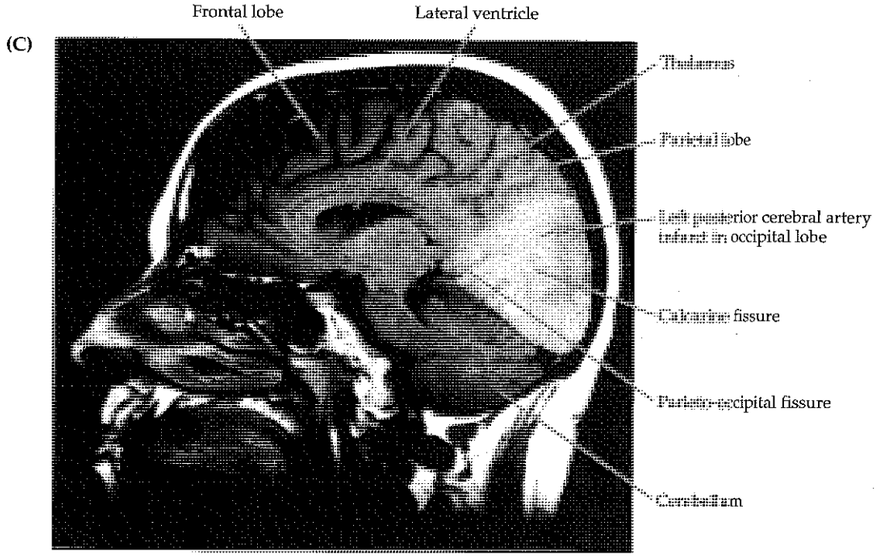

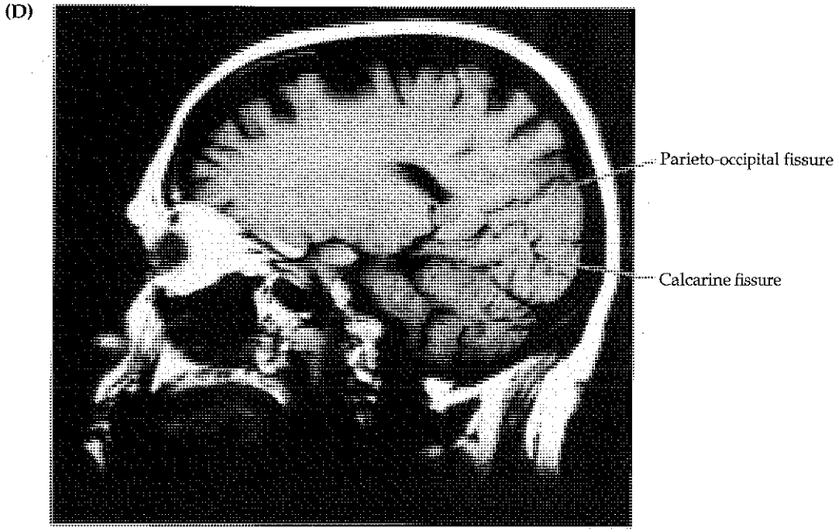

CASE 10.4 TRANSIENT EPISODES OF LEFT EYE BLURRINESS OR RIGHT HAND WEAKNESS

MINICASE

A 71-year-old right-handed man with a long history of cigarette smoking and hypertension had an episode 5 months before admission of **right hand weakness and speech difficulty "mixing up words."** Since then, he has had several episodes, lasting a few minutes each, of **dim blurry vision in the left eye.** Finally, he fell on three separate occasions when his **right leg suddenly gave out,** most recently on the day of admission. Examination was normal except for a **high-pitched bruit audible over the left carotid artery.**

LOCALIZATION AND DIFFERENTIAL DIAGNOSIS

1. What is the most likely cause of this patient's transient neurologic episodes? What are some other possibilities?
2. For each type of episode shown in **bold** above, identify a branch of the internal carotid artery that could be responsible for the patient's symptoms.

Discussion

1. Given the patient's age and history of smoking and hypertension, atherosclerotic cerebrovascular disease is likely. The episodes lasted for a few minutes each and fit with a vascular anatomical pattern (see the localization discussion that follows) suggesting TIAs (see KCC 10.3). In addition, the **left carotid bruit** is a "smoking gun" that heightens the suspicion further for TIAs caused by left internal carotid stenosis. Other, less likely possibilities are listed in Table 10.2.
2. The three types of episodes in this case are:
   - **Right hand weakness and speech difficulty "mixing up words":** Symptomatic branch of internal carotid = Left MCA superior division (see KCC 10.1).
   - **Right leg weakness:** Symptomatic branch of internal carotid = Left ACA (see KCC 10.1).
   - **Decreased vision in the left eye:** Symptomatic branch of internal carotid = Left ophthalmic artery (see KCC 10.5, 11.3).

   Interestingly, unlike the case in this patient, internal carotid stenosis often causes TIAs mainly in one carotid branch, resulting in recurrent, nearly stereotyped episodes. For example, a patient may have several episodes of contralateral hand weakness, numbness, and tingling, or several episodes of transient monocular visual loss.

Clinical Course

Carotid Doppler studies showed a very tight stenosis of the left internal carotid artery. This was confirmed by MRA. The patient underwent an endarterectomy of the left internal carotid artery. In this procedure the carotid is temporarily cross-clamped, an incision is made in the artery, atherosclerotic plaque is carefully shelled out, and the artery wall is then stitched back together (see KCC 10.5). A large atheromatous plaque was removed in this patient, and when it was examined pathologically, it was found to have a residual lumen of only 0.1 cm in diameter. The patient did very well postoperatively, with no further episodes of weakness or vision changes.

Related Cases. Typical MRA findings in a different patient with critical stenosis of the right internal carotid artery are shown in Figure 10.16. This patient presented with two episodes, lasting 5 minutes each, of left hand numbness, tingling, and a feeling like it was not part of her body. A pathologic specimen from yet another patient removed at the time of carotid endarterectomy is shown in Figure 10.17.

CASE 10.5 NONFLUENT APHASIA WITH RIGHT FACE AND ARM WEAKNESS

CHIEF COMPLAINT

A 45-year-old man was brought to the emergency room because of right face and arm weakness and inability to speak.

HISTORY

The patient had a past history of alcohol use, cigarette smoking, and hypertension. He ate breakfast at the same diner every day but had not shown up there for 2 days. On the morning of admission, he staggered back into the diner grunting incoherently, tripped, and fell on the floor. The manager noticed that the patient was having trouble moving his right arm, so he called an ambulance.

PHYSICAL EXAMINATION

Vital signs: T = 97°F, P = 88, BP = 218/116, R = 16.
Neck: Supple with no bruits.
Lungs: Clear.
Cardiac: Regular rate with no murmurs. S4 gallop.
Abdomen: Soft, nontender.
Extremities: No edema.
Neurologic exam:

MENTAL STATUS: Alert. **Grunted only, producing no words. Followed no commands except to close eyes or open mouth.** Obeyed gestures to raise arms or legs.

CRANIAL NERVES: Pupils 3 mm, constricting to 2 mm bilaterally. Preserved blink to threat bilaterally. Extraocular movements intact. **Decreased right nasolabial fold at rest, and decreased movements of right face, sparing forehead.**

MOTOR: **No right arm movement except for slight flexion toward a painful stimulus. Able to raise right leg off bed, but not against resistance.** Good, purposeful movements of left arm and leg against resistance.

REFLEXES:

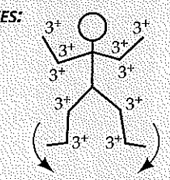

COORDINATION AND GAIT: Not tested.

SENSORY: Grimaced in response to pinch in all extremities.

INITIAL CLINICAL COURSE

The patient's global aphasia quickly evolved into a Broca's aphasia (see KCC 19.4). By 6 days after admission he was still **able to utter only a few barely articulate words,** and he **could not repeat, but he could follow, many simple commands** and answer yes/no questions appropriately.

LOCALIZATION AND DIFFERENTIAL DIAGNOSIS

1. On the basis of the symptoms and signs shown in **bold** above, where is the lesion?
2. What is the most likely diagnosis, and what are some other possibilities?

Discussion

1. The key symptoms and signs in this case are:
   - **Decreased movements of right face (sparing forehead), profound right arm weakness, and mild right leg weakness**
   - **Nonfluent (Broca's) aphasia**

   Unilateral face and arm weakness are usually caused by a lesion in the contralateral face and arm areas of the motor cortex (see KCC 6.3; Figure 16.14). In support of this, the pattern of facial weakness fits with an upper motor neuron lesion. Note that there was no hyperreflexia on the right side, but this is not unusual in an acute upper motor neuron lesion. The slight right arm flexion toward the painful stimulus likely represents a fragment of flexor posturing (see Figure 3.5A). Another possible localization would be a deep lesion involving the internal capsule; however, the leg is only mildly involved, making this less likely. In addition, the Broca's aphasia in this patient is compatible with a lesion involving the left frontal cortex. Note that the patient initially had a global aphasia, which evolved to Broca's aphasia. This is a pattern commonly seen with large acute lesions involving Broca's area and adjacent regions of the left frontal lobe (see KCC 19.4). Note also that the intact visual fields are very helpful for ruling out a more posterior lesion.

The most likely *clinical localization* is left primary motor cortex face and arm areas, Broca's area, and adjacent left frontal cortex.

2. The patient was not elderly; however, given the history of hypertension and cigarette smoking, and the anatomical distribution of his deficits, the most likely diagnosis is a left MCA superior division infarct (KCC 10.1). Other, less likely diagnoses include a hemorrhage, tumor, or abscess affecting the left frontal lobe.

Clinical Course 402

A head CT done in the emergency room showed a left MCA superior division infarct that appeared more than 24 hours old. The patient was admitted and placed on intravenous heparin anticoagulation while an embolic workup was done (see KCC 10.4). A **brain MRI scan** done 4 days after admission confirmed the left MCA superior division infarct (Figure 10.18). Note the presence of a T2 bright area consistent with increased water from edema and necrosis in the territory of the left MCA superior division (see Figures 10.5, 10.6, 10.9; KCC 10.1). The sulci appear effaced when compared to the same region in the opposite hemisphere, representing mass effect. The infarct can be seen to involve the left frontal operculum (Broca's area) and the face and arm motor areas on the lateral convexity of the frontal lobe. However, the leg motor area, lying superiorly in the interhemispheric fissure, was spared, as was the posterior limb of the internal capsule (see Figure 10.1, 10.9B).

Carotid Doppler studies and magnetic resonance angiography showed no flow in a segment of the left internal carotid artery. Because of the critical importance of distinguishing carotid occlusion from a tight stenosis (see KCC 10.5), a conventional angiogram was performed that confirmed carotid occlusion (see Case 10.10 for angiographic findings in carotid occlusion). Thus, the patient most likely had an embolus that formed in the occluded left internal carotid and migrated upward to the left middle cerebral artery superior division. He was discharged on oral anticoagulation therapy to try and prevent further emboli. Note that embolic infarcts can also occur with carotid stenosis (rather than occlusion), in which case endarterectomy may be indicated (see KCC 10.5).

As already noted, the patient's global aphasia quickly evolved into a Broca's aphasia, but he continued to have some difficulty comprehending more complex commands. His right leg strength recovered fully, and his right arm strength also improved. By the sixth hospital day he was able to extend his fingers and move most muscles in the right arm against gravity but not against resistance.

CASE 10.4 RELATED CASES

Figure 10.16 Internal Carotid Artery Stenosis
Magnetic resonance angiogram (MRA) of the carotid arteries from a patient with TIAs consisting of left-hand numbness. (A) Right carotid MRA showing a "skip lesion" consistent with severe stenosis of the right internal carotid artery just beyond the carotid bifurcation. (B) Left carotid MRA showing normal flow.

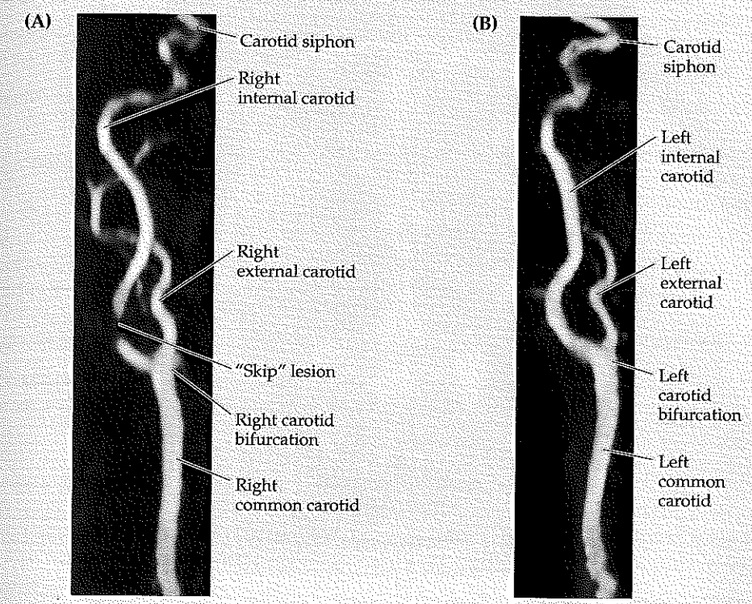

Figure 10.17 Serial Pathologic Sections of Severe Internal Carotid Artery Stenosis Caused by Atherosclerosis

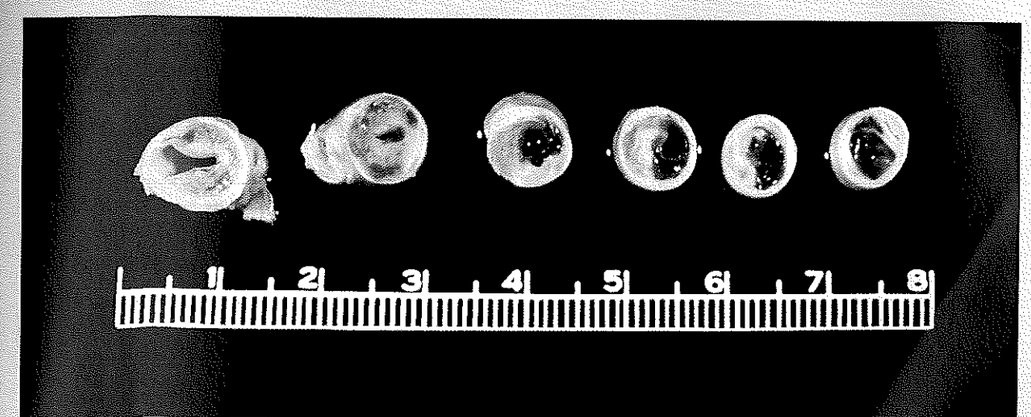

CASE 10.5 NONFLUENT APHASIA WITH RIGHT FACE AND ARM WEAKNESS

Figure 10.18 Left Middle Cerebral Artery (MCA) Superior Division Infarct
T-2 weighted MRI axial sections, with A and B progressing from inferior to superior.

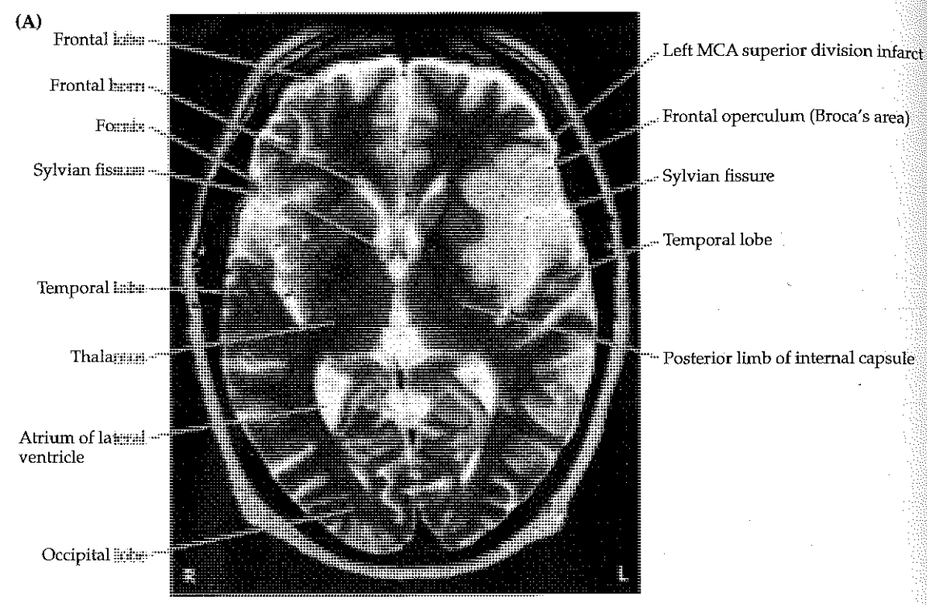

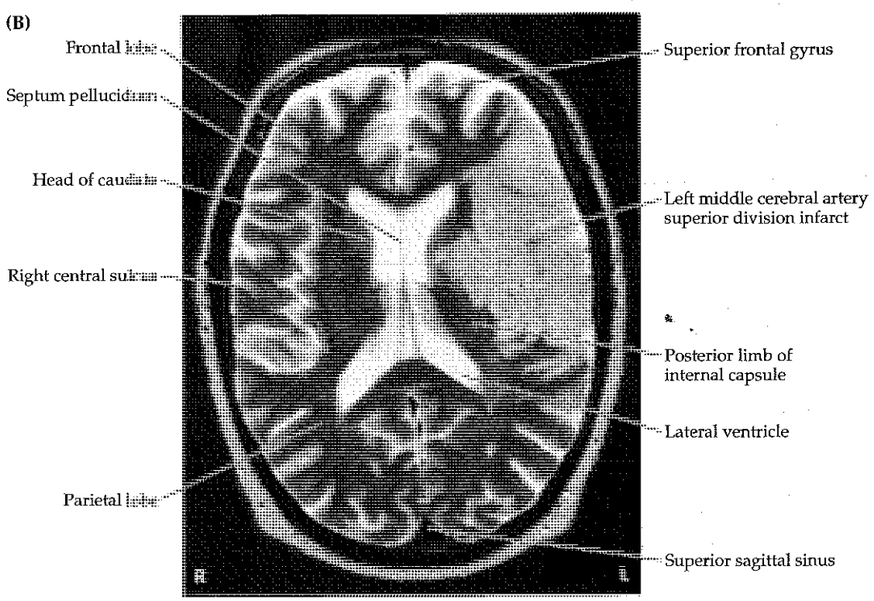

CASE 10.6 TALKING RAGTIME

CHIEF COMPLAINT
A 64-year-old right-handed man with a history of schizophrenia suddenly began talking nonsense and repeating himself over and over again.

HISTORY
The patient had a history of chronic schizophrenia, with occasional auditory hallucinations and paranoid delusions treated with antipsychotic medications in the past. He also had hypertension and a recent episode of chest pain. On the day of admission he was last seen in his usual state of health at 12:00 noon. His wife went out shopping, and when she returned at 4:00 P.M., he was seated at the kitchen table **saying meaningless syllables and irrelevant phrases over and over and would not respond to any of her questions.** She also noticed that his right arm was hanging down at his side, and she called an ambulance.

PHYSICAL EXAMINATION
Vital signs: T = 98.4°F, P = 67, BP = 153/82, R = 20.
Neck: No bruits.
Lungs: Clear.
Heart: Regular rate with no mumurs, gallops, or rubs.
Abdomen: Soft, nontender.
Extremities: Mild ankle edema.
Rectal: Normal.
Neurologic exam:
MENTAL STATUS: Alert. Mildly agitated. **Responded to all questions by saying only "Yup, yup" or "I don't know" repeatedly. Followed no commands, named no objects, and could not repeat.** Occasionally asked, "What time is it?" or repeated other **irrelevant phonemes,** such as "Jillian" or "lexi" multiple times. Did not follow written commands. Mimicked some gestures, but only when shown in the left visual field.
CRANIAL NERVES: Pupils 4 mm, constricting to 2 mm bilaterally. Normal fundi. **Blink to threat was present only on the left.** Extraocular movements intact. Facial grimace symmetrical. No dysarthria.
MOTOR: **Slightly increased tone in the right arm.** Moved all four extremities and was **able to hold his right arm over his head, but not as readily** as the left arm.
REFLEXES:

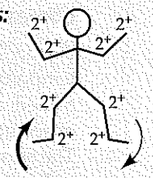

COORDINATION: Not tested.
GAIT: Stood cautiously and took short tentative steps without support.
SENSORY: Grimaced and withdrew in response to pinprick in all extremities. **Grimaced more in response to pinprick on the left side than the right.**

LOCALIZATION AND DIFFERENTIAL DIAGNOSIS
1. On the basis of the symptoms and signs shown in **bold** above, where is the lesion?
2. What is the most likely diagnosis, and what are some other possibilities?

Discussion
1. The key symptoms and signs in this case are:
   - **Fluent aphasia with impaired comprehension and repetition**
   - **Blink to threat present only on the left**
   - **Greater grimace in response to pinprick on the left side than the right**
   - **Slightly increased tone in the right arm, with right Babinski's sign**

   This patient had a Wernicke's aphasia (see KCC 19.5), with fluent, meaningless speech, together with severely impaired comprehension and repetition. This syndrome suggests a lesion in the left temporoparietal cortex, including Wernicke's area. The right visual field defect could also be explained by a lesion in this area if the optic radiations were involved (Figure 10.1A). Movements on the right side are relatively spared, suggesting that the primary motor cortex was not directly involved. However, the right sensory loss, mild right-sided upper motor neuron findings, and possible mild right neglect (as evidenced by the patient's reluctance to use his right arm) suggest involvement of the left parietal lobe and left primary sensory cortex, with mild impingement on corticospinal tract fibers.

The most likely *clinical localization* is left temporal and parietal lobes, including Wernicke's area, optic radiations, and somatosensory cortex.

2. The anatomical distribution of the lesion fits with a left MCA inferior division infarct (KCC 10.1). This diagnosis is further supported by the patient's age, history of hypertension, and possible cardiac disease (chest pain). Other, less likely possibilities include hemorrhage, abscess, or tumor in the left temporoparietal region.

   Interestingly, this patient had a history of schizophrenia, which can also cause nonsensical speech and disregard for verbal questions or commands. The other neurologic findings enabled the diagnosis of a neurologic rather than a psychiatric disorder in this case. However, in left MCA inferior division infarcts, sensory and motor deficits are often absent, making the diagnosis more difficult. Once again visual field testing is essential to detect posterior lesions, although the results may be hard to interpret even with blink to threat if the patient is sufficiently agitated.

Clinical Course 406

Head CT in the emergency room showed a region of hypodensity in the left temporoparietal lobes, and follow-up **head CT** 2 days after admission confirmed a left MCA inferior division infarct (Figure 10.19). Note the sulcal effacement in the region of hypodensity in the left temporal and parietal lobes. The stroke can be seen to include Wernicke's area (see Figure 10.1A), the optic radiations, and left parietal cortex, but to spare the precentral gyrus and internal capsule. Recall that the margin between the MCA superior and inferior divisions is somewhat variable in the parietal lobe. For example, in inferior division infarcts, often less of the parietal lobe is involved than in this case.

The patient was admitted for a workup, which revealed no embolic source (see KCC 10.4). Nevertheless, he was treated with intravenous and, later, oral anticoagulation. By the second hospital day he had nearly normal movements on the right side and no longer had an upgoing toe on the right. His aphasia improved somewhat, with more varied and intermittently coherent spontaneous speech. He was fluent but continued to have severely impaired language comprehension and decreased vision on the right side.

CASE 10.7 DYSARTHRIA AND HEMIPARESIS

MINICASE

An 84-year-old woman with a history of hypertension and diabetes had two episodes of slurred speech and right-sided weakness on two consecutive days, and on the third day she developed persistent **dysarthria and right hemiplegia.** Exam was normal except for **right facial weakness sparing the forehead, dysarthria, decreased right-sided tone, 0/5 power in the right arm and leg, and right upgoing plantar response.**

LOCALIZATION AND DIFFERENTIAL DIAGNOSIS

1. On the basis of the symptoms and signs shown in **bold** above, where is the lesion?
2. What is the most likely diagnosis, and what are some other possibilities?

Discussion

1. The key symptoms and signs in this case are:
   - **Dysarthria and right face, arm, and leg paralysis with a right Babinski's sign**

   This patient has pure motor hemiplegia, without sensory abnormalities or cortical signs such as aphasia or neglect. This can be localized to the contralateral corticobulbar and corticospinal tracts, most commonly in the internal capsule or ventral pons (see KCC 6.3; Figure 6.14A). Dysarthria is commonly present as well, giving rise to the term "dysarthria hemiparesis" (see Table 10.3). In addition, the facial weakness is of the upper motor neuron type, since the forehead is spared. The right Babinski's sign also supports an upper motor neuron lesion.

   The most likely *clinical localization* is left corticobulbar and corticospinal tracts in the internal capsule or ventral pons.

2. Given the patient's age and the history of hypertension and diabetes, an ischemic infarct is the most likely diagnosis. Internal capsule infarcts are most commonly caused by occlusion of the lenticulostriate arteries, which take their origin from the proximal MCA and supply the deep MCA territories (Figures 4.16B, 10.7–10.9). Infarcts of this kind are often called lacunes (see KCC 10.4). Other vessels that can cause internal capsule lacunes include the anterior choroidal artery and small penetrating vessels from the proximal PCA. Infarcts in the ventral pons can be caused by occlusion of the small paramedian perforators arising from the basilar artery (see Figures 14.18–14.20). Aside from a lacunar infarct, other possibilities include hemorrhage, tumor, abscess, or demyelination in the left posterior limb of the internal capsule, ventral pons, corona radiata, or cerebral peduncle (compare to Cases 6.4 and 6.5.).

Clinical Course and Neuroimaging 409

Head CT in the emergency room showed a hypodensity in the left internal capsule, which appeared more clearly on a follow-up **head CT** 10 days later (Figure 10.20). Note that lacunar infarcts are often smaller than the one seen in this patient, and an infarct of this size is sometimes called a giant lacune. The patient was admitted to the hospital, and an MRA revealed bilateral severe stenosis of the middle cerebral arteries. It was felt that thrombus or atheroma forming along the wall of the vessel might have occluded several lenticulostriate vessels coming off the proximal left middle cerebral artery (see Figures 4.16B, 10.7). She was therefore treated with anticoagulation with no further progression, but she continued to have severe right-sided weakness.

CASE 10.8 GLOBAL APHASIA, RIGHT HEMIPLEGIA, AND HEMIANOPIA

CHIEF COMPLAINT

A 63-year-old right-handed man was brought to the emergency room with **sudden onset of inability to speak and right face, arm, and leg paralysis.**

HISTORY

The patient was on vacation with his wife, and one morning at breakfast he dropped a pat of butter. He stood up to look for it but then suddenly began **looking only to the left** and slid back down into his chair. He was **unable to speak or follow commands and could not move his right arm or leg.** His wife immediately called an ambulance. Past medical history was notable for hypertension and aortic valve replacement 7 years previously with a porcine valve. He was taking antihypertensive medications and aspirin.

PHYSICAL EXAMINATION

Vital signs: T = 97.4°F, P = 80, BP = 150/80.
Neck: Supple with no bruits.
Lungs: Mild bibasilar crackles.
Heart: Irregular rate; loud systolic and diastolic murmurs at right upper sternal border.
Abdomen: Soft, nontender.
Extremities: Normal.
Neurologic exam:
MENTAL STATUS: Alert and somewhat agitated. **Occasionally made unintelligible sounds, but no words. Could not repeat. Followed no commands except "close your eyes" and answered no questions.**

CASE 10.6 TALKING RAGTIME

Figure 10.19 Left Middle Cerebral Artery (MCA) Inferior Division Infarct
CT scan axial sections with A, B progressing from inferior to superior.

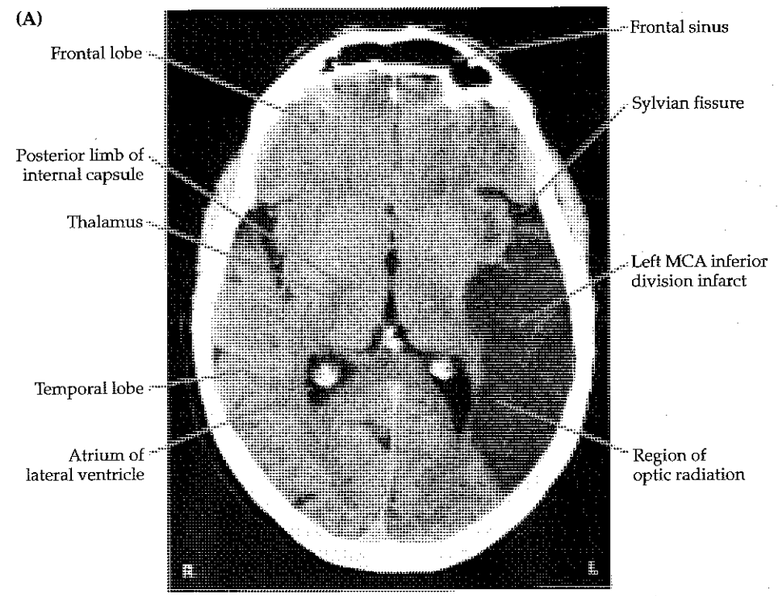

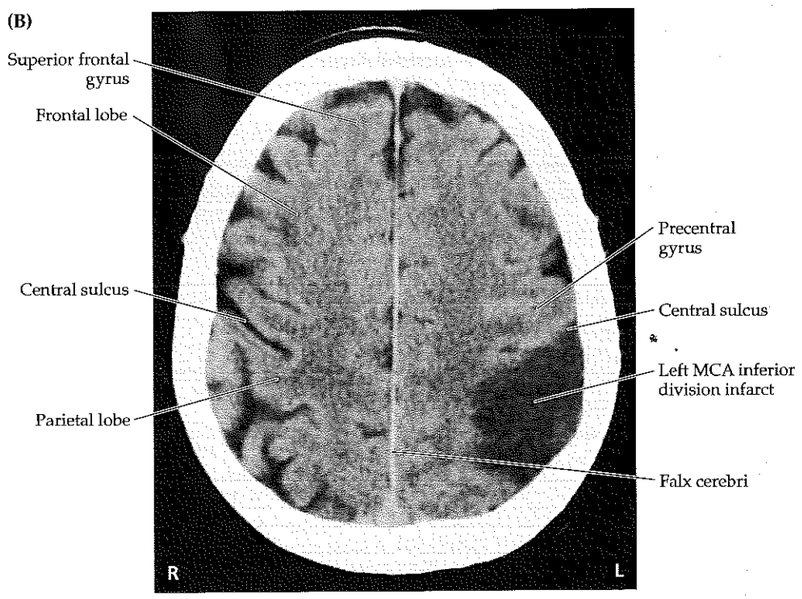

CASE 10.8 *(CONTINUED)*

CRANIAL NERVES: Pupils 3 mm, constricting to 2 mm bilaterally. Normal fundi. **No blink to threat on the right. Left gaze preference. On visual tracking, eyes moved fully to the left but did not cross the midline to the right. Right corneal reflex was decreased. Right face had severely decreased movements, with relative sparing of the forehead.** Gag reflex present.

MOTOR: **No movement of the right arm, even in response to pain. Right leg with slight flexion only, moving toward painful stimulus.** Left arm and leg with spontaneous purposeful movements. Able to raise left arm or leg off the bed.

COORDINATION AND GAIT: Not tested.

REFLEXES:

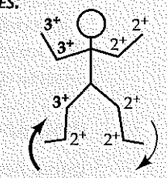

SENSORY: **No response to pain on right side except for weak flexion of right leg** (see above). Grimace and purposeful withdrawal to pain on the left.

LOCALIZATION AND DIFFERENTIAL DIAGNOSIS

1. On the basis of the symptoms and signs shown in **bold** above, where is the lesion?
2. What is the most likely diagnosis, and what are some other possibilities?

Discussion

1. The key symptoms and signs in this case are:
   - **Right face, arm, and leg paralysis, with right hyperreflexia and Babinski's sign**
   - **No response to pain on the right side except for weak flexion of the right leg**
   - **Global aphasia**
   - **No blink to threat on the right**
   - **Left gaze preference**
   - **Decreased right corneal reflex**

   This unfortunate man had the deficits of all three patients from Cases 10.5, 10.6, and 10.7 combined. Right hemiplegia with upper motor neuron signs can be caused by a large lesion affecting the entire left motor cortex, or by a lesion of the corticobulbar and corticospinal tracts (see KCC 6.3; Figure 6.14A,B). The slight flexion of the right leg into the painful stimulus seen in this patient is probably part of a reflex response such as triple flexion (see Figure 3.5C), which can be mediated by local spinal cord circuits. Loss of response to pain on the right side could be due partly to the hemiplegia; however, one would expect at least to see a grimace on the left face or uncomfortable movements of the left body if the painful stimulus were felt. Therefore, there is probably right hemisensory loss, caused by a large lesion of the left somatosensory cortex, by a lesion of the left thalamic somatosensory radiations, or by a lesion of the left thalamus (see KCC 7.3; Figure 7.9A). Decreased corneal response (see KCC 12.4) can be produced by damage to ipsilateral brainstem or cranial nerves V or VII. However, it can also be seen in contralateral supratentorial lesions of the somatosensory pathways. Global aphasia (see KCC 19.6) can be caused by large dominant-hemisphere lesions. Note that the ability to follow simple midline commands such as "close your eyes" is sometimes preserved even in global aphasia. Loss of blink to threat on the right can be caused by a lesion of the left optic tract, thalamus, optic radiations, or visual cortex (see Figure 11.15). An ipsilateral gaze preference (see KCC 13.15) can also be seen with large cortical lesions, in which there is loss of the ability to drive the eyes toward the side opposite the lesion.

   The most likely *clinical localization* is a large lesion affecting the entire left cerebral cortex, or a left hemisphere lesion involving a large region of cortex plus all subcortical pathways.

2. The patient's age and history of hypertension and cardiac disease suggest possible cerebrovascular disease. A left MCA stem infarct could produce all of the deficits described above (see Table 10.1). Other possibilities include massive left hemisphere hemorrhage or, less likely given the time course, an abscess or tumor.

Clinical Course 4:10

Initial head CT within a few hours of onset was negative, except for a hyperdensity in the proximal left MCA, consistent with a blood clot. An EKG revealed atrial fibrillation, suggesting that an embolus had formed in the left atrium and traveled to the left MCA stem. Thrombolysis and other acute interventions were not available at the time this patient was admitted. A repeat **head CT** 1 day after admission again showed a hyperdensity in the left MCA stem, but also showed a massive area of hypodensity consistent with infarction of the entire left MCA territory (Figure 10.21). Note that the infarct involved both the superficial and the deep MCA territories (compare to Figures 10.8 and 10.9), while sparing the thalamus, inferior temporal lobe, and medial occipitoparietal cortex (PCA territory), in addition to the medial frontoparietal cortex (ACA territory). Note also that the sulci over the left hemisphere appear effaced, and there is considerable left-to-right shift under the falx in the region of the midline, and deformation of the midbrain in the region of the tentorium, suggesting incipient uncal herniation (see KCC 5.4).

Three days after admission the patient became increasingly somnolent, and a repeat CT scan showed increased swelling of the left hemisphere, with about 1 cm of left-to-right midline shift and some effacement of the basal cisterns. The patient was intubated and treated with intravenous mannitol in an attempt to decrease brain swelling by osmotic diuresis (see KCC 5.3). However, by the fourth hospital day the patient was unresponsive, exhibiting bilateral extensor posturing of the arms and legs (see Figure 3.5B). The family had a living will written previously by the patient stating that he did not want extreme measures to be taken to sustain his life if he had an illness with poor prognosis for good functional recovery. He was therefore extubated and given pain medications, and he died the next day with his family at the bedside.

CASE 10.9 LEFT FACE AND ARM WEAKNESS

MINICASE

A 91-year-old right-handed woman with a history of paroxysmal atrial fibrillation called her daughter one morning because she was **unable to get her arm through the left sleeve of her dress.** The patient's **speech sounded slightly slurred** over the telephone, so her daughter called an ambulance. Examination was notable for **left facial weakness sparing the forehead, mild dysarthria, left arm pronator drift, 4/5 strength in the left arm, and brisk 3+ reflexes in the left arm** compared to 2+ reflexes in the right arm. In addition, there was **occasional extinction on the left side to double simultaneous visual or tactile stimulation.** The remainder of the exam was essentially normal, including intact visual fields and normal leg strength.

LOCALIZATION AND DIFFERENTIAL DIAGNOSIS

1. On the basis of the symptoms and signs shown in **bold** above, where is the lesion?
2. What is the most likely diagnosis, and what are some other possibilities?

Discussion

1. The key symptoms and signs in this case are:
   - **Left facial weakness sparing the forehead, left arm weakness, and hyperreflexia**
   - **Mild dysarthria**

   - **Occasional extinction on the left side to double simultaneous visual or tactile stimulation**

Unilateral face and arm weakness are usually caused by contralateral lesions of the face and arm motor cortex (see KCC 6.3; Figure 6.14D). Dysarthria can be caused by numerous lesions (see KCC 12.8), including the face and mouth motor cortex. Extinction suggests mild hemineglect (see KCC 19.9), which is most often caused by right parietal lesions but can also be seen in right frontal lesions.

The most likely *clinical localization* is right primary motor cortex face and arm areas and adjacent right frontal lobe.

2. Given the patient's history of atrial fibrillation, her age, the acute onset, and the typical clinical pattern fitting the anatomical distribution of the right middle cerebral artery superior division (see Table 10.1), the most likely diagnosis is right MCA superior division infarct. Other, less likely possibilities include hemorrhage, infection, or tumor located in the right frontal lobe.

Clinical Course

Initial head CT showed a subtle hypodensity in the right frontal lobe. Follow-up head CT 4 days later confirmed a right MCA superior division infarct that appeared very similar to the infarct in Case 10.5 (see Figure 10.18), except on the other side of the brain. As already noted, the patient had a known history of paroxysmal atrial fibrillation. Despite the increased bleeding risk at her age, the patient was treated with intravenous heparin and later switched over to oral anticoagulation, which she tolerated well. During a stay at an inpatient rehabilitation facility, she had gained partial recovery of strength and function in the left arm.

CASE 10.7 DYSARTHRIA AND HEMIPARESIS

Figure 10.20 Left Middle Cerebral Artery (MCA) Deep Territory Infarct Head CT scan axial section showing "giant" lacune in the left genu and posterior limb of the internal capsule, probably caused by occlusion of lenticulostriate arteries.

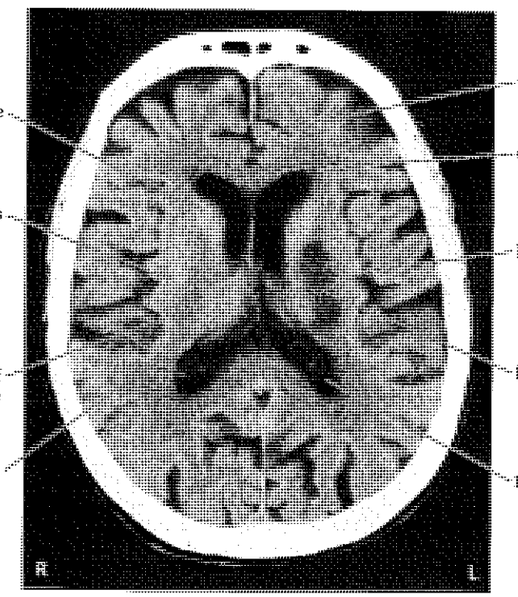

CASE 10.8 GLOBAL APHASIA, RIGHT HEMIPLEGIA, AND HEMIANOPIA

Figure 10.21 Left Middle Cerebral Artery (MCA) Stem Infarct, Causing Significant Mass Effect Head CT scan axial sections, with A–C progressing from inferior to superior.

(A)

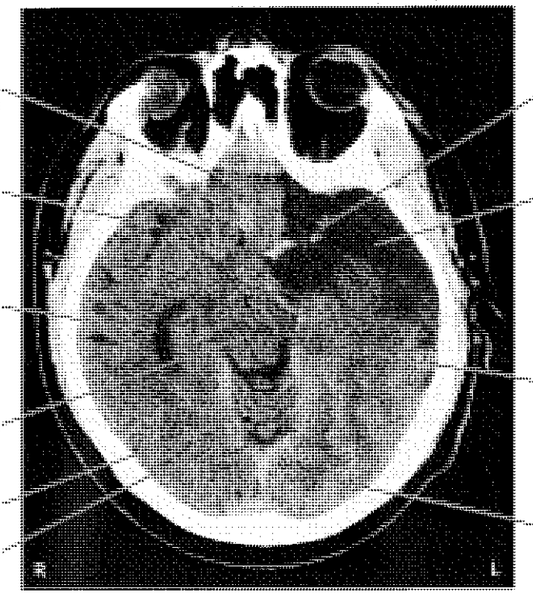

(B)

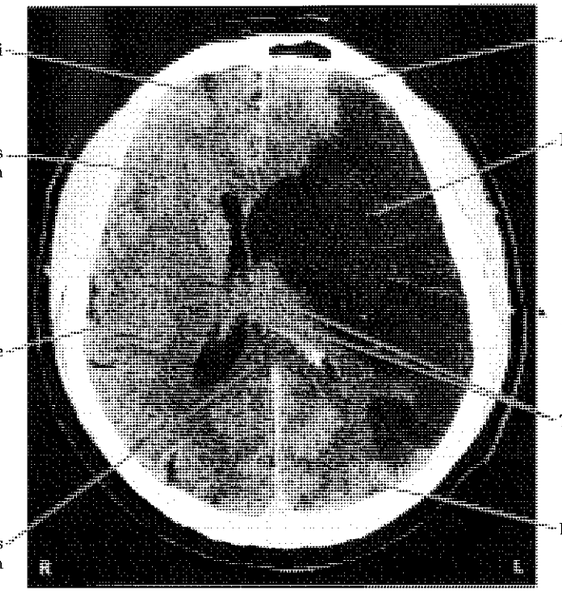

CASE 10.8 *(CONTINUED)*

(C)

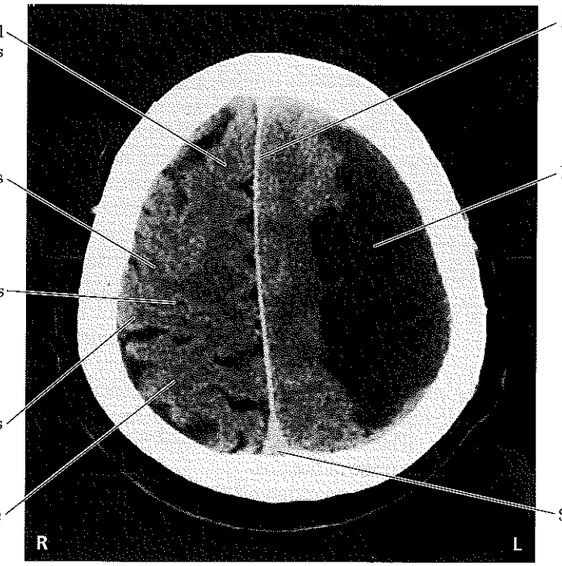

CASE 10.10 LEFT HEMINEGLECT

MINICASE

A 61-year-old left-handed security guard had an **episode of left hand tingling lasting less than an hour** that was reported to medical staff by a friend. The next day he was at the grocery store buying a lottery ticket and reportedly slumped briefly to the floor. He **denied that anything was wrong** but said, "They called an ambulance because they said I had a stroke." On examination he was **unaware of having any deficits** and wanted to go home. He had **profound left visual neglect,** describing only the curtains to the far right in a picture of a complex visual scene and reading only the right two words on each line of a magazine article. When trying to write, he **moved the pen in the air off to the right of the page.** He had **no blink to threat on the left, a marked right gaze preference, and mildly decreased left nasolabial fold.** Spontaneous **movements were decreased on the left side,** but with provocation he was able to achieve 4/5 strength in the left arm and leg. He was able to feel touch on the left side but had **extinction on the left to double simultaneous tactile stimulation. Reflexes were slightly brisker on the left.**

LOCALIZATION AND DIFFERENTIAL DIAGNOSIS

1. What is the significance of the transient episode of hand tingling?
2. On the basis of the symptoms and signs shown in **bold** above, where is the lesion?
3. What is the most likely diagnosis, and what are some other possibilities?

Discussion

1. The key symptoms and signs in this case are:
   - **Anosognosia, left visual neglect, extinction on the left to double simultaneous tactile stimulation, moving the hand to the right of the page, and decreased spontaneous movements on the left side**
   - **Right gaze preference**

- **No blink to threat on the left**
- **Decreased spontaneous movements on the left side, with mildly decreased left nasolabial fold, and slightly brisker reflexes on the left**

The transient episode of hand tingling occurring the day before the onset of a fixed deficit is suggestive of a TIA forewarning an ischemic stroke. Left hand tingling could be caused by compromised flow in the right middle cerebral artery, most commonly from a cardiogenic embolus, or from a right carotid stenosis. Other possible causes of transient neurologic symptoms are listed in Table 10.2.

2. This patient exhibits several forms of neglect (see Chapter 19). In addition to anosognosia, he has left sensory neglect to visual and tactile stimuli, as well as left motor neglect. These features are most commonly seen in patients with nondominant (usually right) parietal lobe lesions, but can also occasionally be seen with lesions in the right frontal lobe, and in other locations. The right gaze preference further supports a right hemisphere frontal or parietal localization. However, decreased blink to threat is ordinarily caused by damage to primary visual pathways, and not by neglect. Therefore, the decreased blink to threat on the left suggests that the lesion is more posteriorly located, possibly involving the optic radiations as they travel beneath the right temporal and parietal lobes (Figure 10.1A). Mild corticobulbar and corticospinal findings can also be seen in parietal lesions, especially acutely (KCC 10.1).

   The most likely *clinical localization* is right temporoparietal lobe, including the optic radiations.

3. Given the sudden onset of the deficits and the patient's age, the most likely diagnosis is TIA followed by ischemic infarct. The right temporoparietal lobe is supplied by the right MCA inferior division (see Table 10.1; Figures 10.7, 10.9). Another possibility is that the initial episode was a focal seizure, and that the patient had a tumor, hemorrhage, or infection with deficits that had previously been neglected by the patient, which became more severe on the day of admission.

Clinical Course and Neuroimaging 414

Head CT on the day of admission showed a mild hypodensity in the right temporoparietal area. Follow-up head CT 10 days later confirmed right MCA inferior division infarct that appeared very similar to Figure 10.19 (Case 10.6), except on the other side of the brain. Carotid Doppler studies and an MRA suggested occlusion versus critical stenosis of the right carotid artery (see KCC 10.5), so a conventional **cerebral angiogram** was done (see Chapter 4). Injection of the right carotid showed occlusion of the right common carotid artery (Figure 10.22A). Injection of the left carotid resulted in cross-filling to the right ACA and right MCA via the anterior communicating artery (Figure 10.22B). Therefore, the patient most likely had a right carotid occlusion, possibly on the day prior to admission, followed by thrombus formation in the carotid, with embolization to the right MCA inferior division. This is similar to the cause of the infarct in Case 10.5, and should be contrasted with the case of carotid stenosis seen in Case 10.4.

The patient was treated with intravenous and, later, oral anticoagulation to try and reduce the risk of further emboli from his carotid. By 3 days after admission he was able to look voluntarily to the left, strength was normal on the left side when he was motivated, and reflexes were symmetrical. He still had decreased blink to threat on the left, and occasional (1/3 trials) left extinction on double simultaneous tactile stimulation. Coumadin was eventually stopped, and in follow-up 1 year later the patient had a normal exam except for a left visual field cut (not precisely mapped out by the examiner).

CASE 10.11 LEFT HEMINEGLECT, HEMIPLEGIA, AND HEMIANOPIA

MINICASE

A 62-year-old right-handed woman with a history of hypertension, hyperthyroidism, and atrial fibrillation awoke one morning with pain behind her right eye. She tried to walk to the bathroom but fell at the doorway. Her family found her **unable to move her left side,** and as they called the ambulance she kept repeating "Do not call anyone" because **she believed nothing was wrong.** On exam, when **shown her left hand and asked what it was, she replied, "Someone's hand."** When asked whose hand it was, she replied, "The doctor's." She had **no blink to threat on the left and no voluntary gaze to the left past the midline, and there was marked weakness of the lower portion of the left face. Strength was 0/5 in the left arm and leg, the left plantar response was upgoing, and there was no response to pinprick on the left side.**

LOCALIZATION AND DIFFERENTIAL DIAGNOSIS

1. On the basis of the symptoms and signs shown in **bold** above, where is the lesion?
2. What is the most likely diagnosis, and what are some other possibilities?

Discussion

1. The key symptoms and signs in this case are:
   - **Anosognosia, hemiasomatognosia**
   - **Left face, arm, and leg plegia with left Babinski's sign**
   - **No blink to threat on the left**
   - **No voluntary gaze to the left past the midline**
   - **No response to pinprick on the left side**

   This patient clearly has a large lesion of the right hemisphere, including the entire corticobulbar and corticospinal systems, the retrochiasmal visual pathways, the somatosensory systems, and the pathways responsible for personal awareness and for directing gaze into the contralateral hemifield. This is similar to Case 10.8, but since the right hemisphere is involved, instead of aphasia the patient has loss of awareness of illness and of her entire left body. She has all the deficits of Case 10.9 and 10.10, plus a left hemiplegia and hemisensory loss. In summary, she must have a large lesion affecting the entire right cerebral cortex and/or all right hemisphere subcortical pathways.
2. Given her age, the sudden onset of deficits, and the history of hypertension and atrial fibrillation, the most likely diagnosis is a right MCA stem infarct (see Table 10.1). A large right hemisphere hemorrhage is also possible. Less likely, given the time course, is a large abscess or tumor.

Initial Clinical Course

The patient was admitted and initially given intravenous heparin anticoagulation. Head CT on admission was compatible with early right MCA stem infarct, and this was confirmed by MRI and MRA. Two days after admission the patient became increasingly **difficult to arouse,** and she eventually developed a **dilated right pupil** with **flexor posturing in the right arm and an upgoing toe on the right side.**

1. What clinical syndrome do the new findings in **bold** constitute, and what is its localization?
2. What are some possible causes in this patient?

Discussion

1. The combination of impaired consciousness, dilated right pupil, and new right corticospinal findings is compatible with right uncal transtentorial herniation (see KCC 5.4). These three findings would be caused by compression of the midbrain reticular activating system, right CN III, and left cerebral peduncle, respectively.

2. Right uncal herniation would be caused by an expanding mass lesion in the right cranial cavity. Possible causes in this setting would include increased swelling and edema from the infarct, or hemorrhagic conversion.

CASE 10.10 LEFT HEMINEGLECT

Figure 10.22 Right Carotid Occlusion (A) Injection of right carotid showing occlusion of right common carotid artery. (B) Injection of left carotid showing cross-filling via the anterior communicating artery (AComm) to the right anterior cerebral artery (ACA) and the right middle cerebral artery (MCA). A1 = initial segment of ACA, proximal to the first major branch at the AComm.

(A)

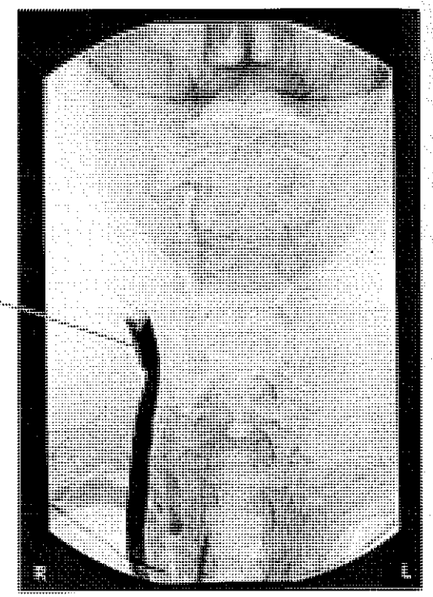

(B)

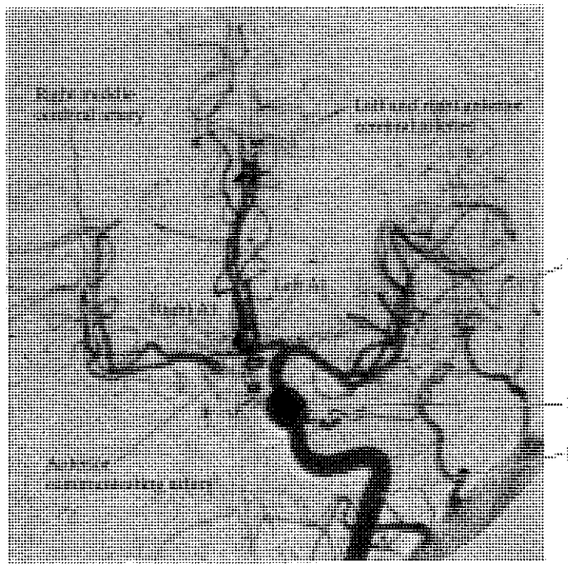

Clinical Course and Neuroimaging 457

An urgent head CT demonstrated increased swelling of the right hemisphere, with right-to-left midline shift and effacement of the interpeduncular cistern. The patient was intubated, hyperventilated, and given intravenous mannitol, which led to temporary improvement. Over the next 2 days an intracranial pressure (ICP) monitoring bolt was used, together with the neurologic exam, to gauge the response to escalating ICP-lowering measures (see KCC 5.3). On hospital day 4, however, the patient's right pupil became dilated, her ICP rose, and she developed bradycardia and hypertension (Cushing response, see Table 5.3), which did not respond to mannitol. Therefore, after discussion with the family she was taken to the operating room for an investigational procedure called a hemicraniectomy (see KCC 10.4), in which a large piece of skull is temporarily removed to decompress the underlying brain (Figure 10.23A). After a long, complicated hospital course and an inpatient rehabilitation stay, she was eventually discharged home with her family. On follow-up exam 2 months after presentation, she was soft-spoken and somewhat lethargic, and she had a persistent left hemiplegia and left hemianopia. However, she knew the correct month and year, and she was able to write her name and identify family members. Follow-up head CT after replacement of the bone flap showed resolution of the brain swelling (see Figure 10.23B).

CASE 10.12 UNILATERAL PROXIMAL ARM AND LEG WEAKNESS

CHIEF COMPLAINT

A 52-year-old right-handed woman went to her physician the morning after developing **difficulty raising her left arm.**

HISTORY

Past history was notable for hypertension and heavy cigarette smoking. After supper on the evening prior to admission the patient tried to reach for a cup of coffee with her left hand but was **unable to raise her left arm.** As she turned to walk away, this movement caused her left arm to flop up in the air slightly and knock the coffee on the floor. She did not make much of this and went to sleep. The next morning, while shopping in the supermarket with her husband, she noticed that she could not raise her left arm to take items off the shelves. On the way home they stopped at her physician's office.

PHYSICAL EXAMINATION

Vital signs: T = 99.3°F, P = 84, BP = 140/70, R = 18.
Neck: Supple, with a **right carotid bruit continuing into diastole.**
Lungs: Clear.
Cardiac: Regular rate, with an S4 gallop.
Abdomen: Normal bowel sounds; soft.
Extremities: Normal.
Neurologic exam:

MENTAL STATUS: Alert and oriented × 3. Normal language. Normal simple calculations. Drew a clockface normally.

CRANIAL NERVES: Normal, except for **decreased leftward fast phases of optokinetic nystagmus** (see Chapter 13).

MOTOR: Normal fine finger movements. Power was 5/5 throughout on the right side. **Left arm power was as follows: shrug 4^+/5, deltoid 4^-/5, triceps 4/5, biceps 4^+/5,** wrist extensors 5/5, fingers 5/5. **Left leg power was as follows: hip flexors 4/5,** hip extensors 5/5, thigh adductors 5/5, thigh abductors 5/5, distal muscles 5/5.

REFLEXES:

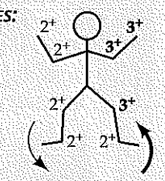

COORDINATION: Slowed finger-to-nose testing in the left arm because of weakness.

GAIT: **Tended to veer to the left. Fell to the left on attempted tandem (heel-to-toe) walking.**

SENSORY: Intact light touch, pinprick, joint position sense, and vibration sense. Normal graphesthesia, no extinction on double simultaneous stimulation.

LOCALIZATION AND DIFFERENTIAL DIAGNOSIS

1. On the basis of the symptoms and signs shown in **bold** above, where is the lesion?
2. What is the most likely diagnosis, and what are some other possibilities?

Discussion

1. The key symptoms and signs in this case are:
   - **Weakness of the proximal left arm and leg, with left hyperreflexia and Babinski's sign**
   - **Unsteady gait, veering to the left**
   - **Decreased leftward fast phases of optokinetic nystagmus**
   - **Right carotid bruit**

   This patient has unilateral proximal arm and leg weakness of the upper motor neuron type (see KCC 6.1), sparing the face. This pattern of weakness, sometimes called "man in the barrel" syndrome, is consistent with a lesion in the contralateral motor cortex proximal arm–trunk–proximal leg areas (see Figure 10.1). Damage to this region can be caused by ACA–MCA watershed infarcts (KCC 10.2). Gait unsteadiness with veering to the left can result from lesions in many locations (see KCC 6.5), including the right leg motor cortex. Leftward fast phases of optokinetic nystagmus can be impaired by right frontal lobe lesions.
2. The patient's vascular risk factors include hypertension and cigarette smoking. Meanwhile, the presence of a right carotid bruit suggests right carotid stenosis. In this setting, decreased right carotid perfusion could occur if the systemic blood pressure suddenly decreased, or if the stenosis suddenly worsened—for example, from thrombus formation. The most likely diagnosis is therefore decreased right carotid perfusion, resulting in watershed infarct in the right ACA–MCA territory, including the right motor cortex proximal arm and leg areas and the right frontal lobe. Other possibilities include another type of cortical lesion in the same location, such as as hemorrhage, tumor, or abscess.

Clinical Course 418

The patient's physician sent her to the emergency room. A diffusion-weighted **MRI scan** (see Chapter 4) revealed an acute infarct in the right ACA–MCA watershed territory (see Figure 10.24A), which was confirmed 2 days later by conventional MRI (see Figure 10.24B; compare to Figure 10.10). The patient was admitted and started on intravenous heparin anticoagulation. MRA and carotid Doppler studies revealed a high-grade stenosis of the right internal carotid artery just above the carotid bifurcation. The patient therefore underwent a right carotid endarterectomy (see KCC 10.5). Pathologic examination of the endarterectomy specimen revealed severe atherosclerosis with superimposed mural thrombus, resulting in a 90% stenosis of the lumen. This finding suggests that thrombus could have temporarily occluded the artery at one time, causing the watershed infarct. After surgery the anticoagulant therapy was changed from heparin to aspirin, and her strength gradually improved. When seen in follow-up 5 weeks after surgery, she had normal strength throughout, except for trace $4^{+}/5$ weakness of the left deltoid and iliopsoas.

CASE 10.11 LEFT HEMINEGLECT, HEMIPLEGIA, AND HEMIANOPIA

Figure 10.23 Right Middle Cerebral Artery (MCA) Stem Infarct, Treated with Hemicraniectomy Head CT axial images. (A) Scan performed four days after admission, shortly after hemicraniectomy. A large swollen infarct is present in the right MCA territory with areas of increased density consistent with peticheal hemorrhage. Removal of the overlying skull prevented fatal uncal herniation. A ventriculostomy was also temporarily placed in the left lateral ventricle to prevent hydrocephalus (see KCC 5.7). (B) Follow-up scan six weeks later. The infarct is no longer swollen, and the skull bone flap has been replaced.

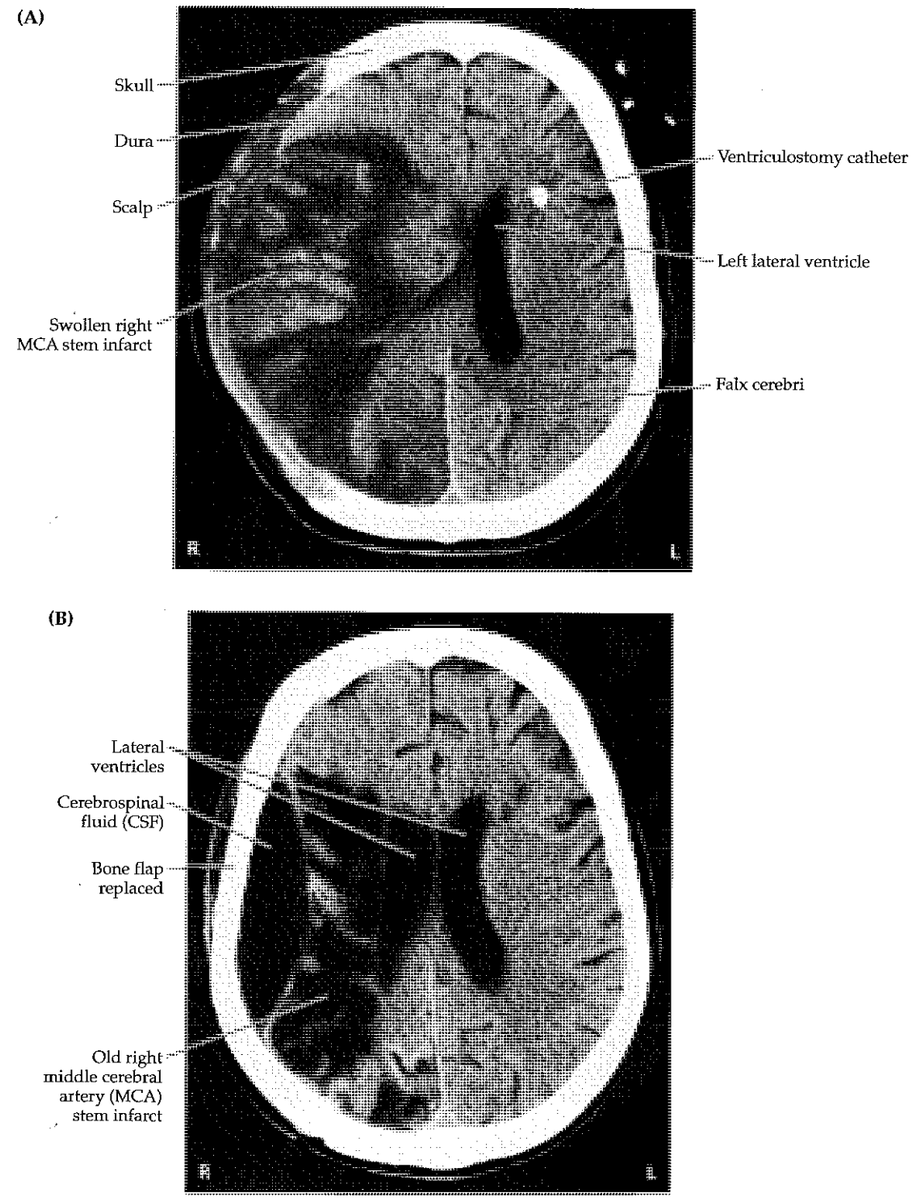

CASE 10.12 UNILATERAL PROXIMAL ARM AND LEG WEAKNESS

Figure 10.24 Right ACA–MCA Watershed Infarct
(A) Coronal view from diffusion weighted MRI on the day of admission showing acute right ACA–MCA watershed infarct. (B) Axial view from conventional T2 weighted MRI 2 days later, confirming infarct in this distribution.

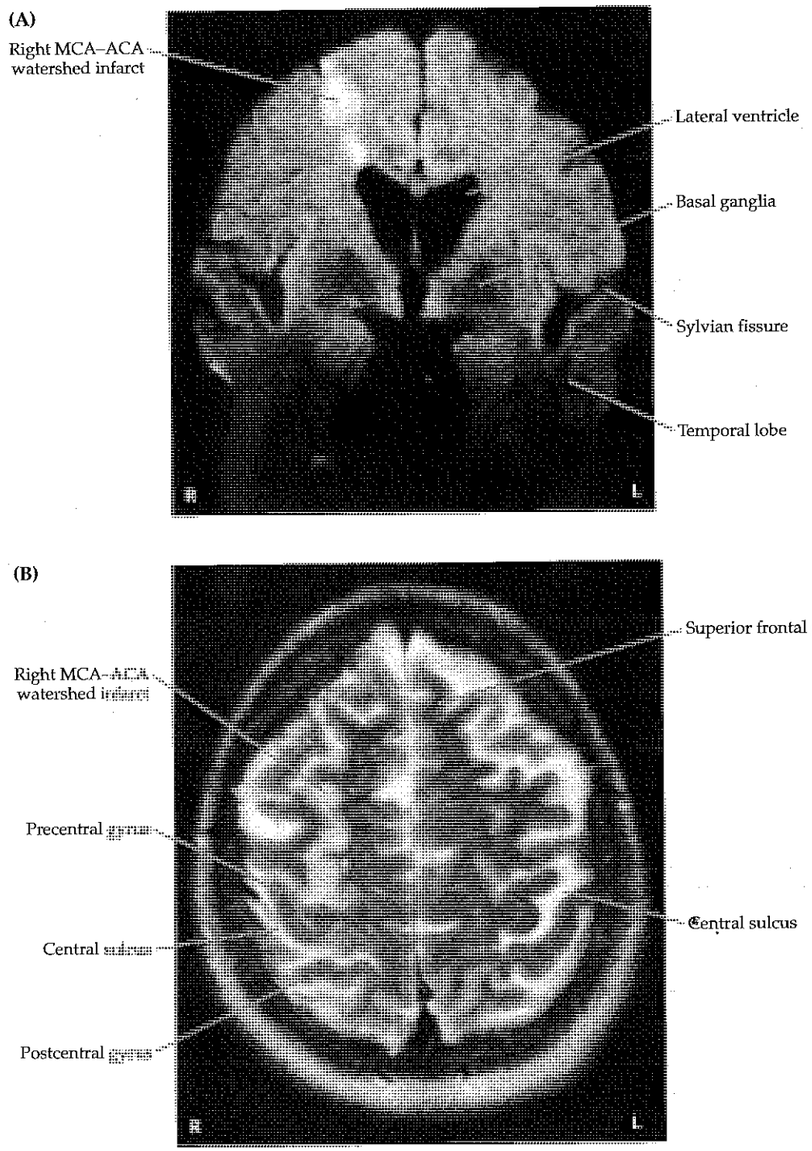

CASE 10.13 RIGHT FRONTAL HEADACHE AND LEFT ARM NUMBNESS IN A WOMAN WITH GASTRIC CARCINOMA

CHIEF COMPLAINT
A 75-year-old right-handed woman was admitted for gastric carcinoma and then developed a right frontal headache with left arm numbness and weakness.

HISTORY
Two weeks prior to admission, the patient noticed difficulty eating. She was admitted to the hospital on the general surgery service when a large mass was found in her abdomen, and an endoscopic biopsy revealed gastric carcinoma. On the evening after admission, the nurse found her **lying on her left arm in an awkward position.** The patient complained of a **right frontal headache and left arm numbness.** The surgical intern found that she had left-sided weakness, and a neurology consult was called.

PHYSICAL EXAMINATION
Vital signs: T = 97.4°F, P = 80, BP = 130/80.
Neck: Supple with no bruits.
Lungs: Clear.
Heart: Regular rate with no murmurs.
Abdomen: Normal bowel sounds. An approximately 15 cm mass was palpable in the midabdomen with mild tenderness.
Extremities: No edema.
Neurologic exam:
MENTAL STATUS: Alert and oriented × 3. Language normal. Able to recall 1/3 objects after 5 minutes, and 2/3 objects with prompting.
CRANIAL NERVES: Pupils 3 mm, constricting to 1 mm bilaterally. Normal fundi. Visual field full, but with **extinction on the left side to double simultaneous stimulation.** Extraocular movements full, but with a **right gaze preference. Facial sensation mildly decreased on the left side to light touch and pinprick. Mild left facial weakness, sparing the forehead.** Normal hearing. Normal gag, palate elevation, and articulation. Tongue midline.
MOTOR: **Left pronator drift.** Power 5/5 throughout on the right side. **Left arm strength 3/5 to 4/5.** Left iliopsoas and quadriceps 5/5, and **left extensor hallicus longus 4+/5.**
REFLEXES:

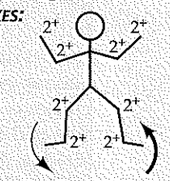

COORDINATION: Normal rapid alternating movements on the right. Left side not tested.
GAIT: Not tested.
SENSORY: **Mildly decreased light touch, pinprick, temperature, vibration, and joint position sense on the left side. Dramatic extinction on the left to double simultaneous stimulation. Decreased stereognosis and graphesthesia in the left hand.**

LOCALIZATION AND DIFFERENTIAL DIAGNOSIS
1. On the basis of the symptoms and signs shown in **bold** above, where is the lesion?
2. What is the most likely diagnosis, and what are some other possibilities?

Discussion
1. The key symptoms and signs in this case are:
   - **Right frontal headache**
   - **Weakness of the left face and arm more than the leg, with left Babinski's sign**
   - **Mildly decreased light touch, pinprick, temperature, vibration, and joint position sense on the left side, with decreased left stereognosis and graphesthesia**
   - **Left visual and tactile extinction**

   Weakness in the left face and arm that is greater than in the leg is usually caused by a lesion of the right face and arm motor cortex (see KCC 6.3; Figure 6.14D). The Babinski's sign supports the presence of an upper motor neuron lesion. Impaired primary and cortical sensation on the left side suggests a lesion in the right somatosensory cortex. The left neglect implies that the lesion may extend into parietal or, less likely, frontal association cortex. Right frontal headache has numerous possible causes (see KCC 5.1), including a lesion in the right hemisphere.

The most likely *clinical localization* is right primary motor cortex face and arm areas, right somatosensory cortex, and right parietal association cortex.

2. Given the patient's age, the sudden onset of deficits, and the hypercoagulability associated with carcinoma (Table 10.5), the most likely diagnosis is ischemic stroke. Although the findings do not neatly fit a right MCA superior or inferior division infarct (see KCC 10.1), they might be explained by an infarct overlapping these territories. A hemorrhage in this area could also explain her deficits. Other possibilities include an abscess, or a tumor such as brain metastasis, especially given this patient's history. It should be noted that in about 10% of brain tumors, symptoms develop rapidly in a "strokelike" manner.

Initial Clinical Course 422

A **head CT** (Figure 10.25A) showed hemorrhage with surrounding edema in the right parietal lobe extending to the face and arm regions of the precentral gyrus. The initial impression was hemorrhage into a brain metastasis, or cerebral infarct with hemorrhagic conversion. An MRI scan with gadolinium and an embolic workup were planned to investigate these possibilities. However, shortly after her head CT the patient suddenly became unresponsive and had left facial twitching, consistent with a **seizure** (see KCC 18.2). She was treated with intravenous anticonvulsants (diazepam and phenytoin) and she improved, although she had two more brief seizures over the next day and remained **difficult to arouse.** Repeat head CT showed no change in the bleed, and **head CT with intravenous contrast** (Figure 10.25B) did not show any enhancing lesions consistent with metastases. On careful review of the contrast CT, an empty delta sign was noted in the superior sagittal sinus (see Figure 10.25B).

1. What is the significance of the empty delta sign?
2. What possible diagnosis should now be considered, and what tests should be done to investigate this possibility?

Discussion

1. The sagittal sinus normally fills uniformly with contrast, and a relatively dark region in the middle suggests a filling defect, possibly due to a blood clot (see Figure 10.25B). Note that in retrospect, there was a suggestion of dense material (bright signal) in the sagittal sinus on the noncontrast scan as well (see Figure 10.25A).
2. Given this finding, superior sagittal sinus thrombosis should be strongly suspected (see KCC 10.7). Other features consistent with (but not specific to) superior sagittal thrombosis include the headache, parasagittal hemorrhage, depressed level of consciousness, and seizures. The empty delta sign is suggestive but is not conclusive evidence for this diagnosis, so additional tests should be done, such as a magnetic resonance venogram or conventional angiography.

Clinical Course and Neuroimaging 423

A **magnetic resonance venogram** (Figure 10.26A) showed no appreciable flow in the superior sagittal sinus. This should be compared to the normal MR venogram from another patient (Figure 10.26B). Despite her hemorrhage, the patient was treated with low-level anticoagulation using subcutaneous heparin, to prevent further thrombosis. She spent 3 weeks in inpatient rehabilitation, with improvement in her left arm strength and ambulation, and eventually underwent abdominal surgery for her gastric carcinoma.

Brief Anatomical Study Guide

1. The **main functions of the cerebral hemispheres** are summarized in Figure 10.1. The three main cerebral arteries are the **anterior cerebral artery (ACA), middle cerebral artery (MCA),** and **posterior cerebral artery (PCA).** The ACA and MCA arise from the **anterior circulation,** or **carotid territory** of the **circle of Willis,** while the PCA arises from the **posterior circulation,** or **vertebrobasilar system** (see Figures 10.2 and 10.3).
2. The **ACA** supplies the medial frontal and medial parietal lobes, including the sensorimotor cortex for the lower extremity (see Figure 10.4). The **PCA** supplies the medial and inferior occipital and temporal lobes, including the primary visual cortex. The **MCA** supplies the entire lateral surface of the cerebral hemispheres, including the face and arm sensorimotor cortex and many regions of association cortex (see Figure 10.5).
3. The MCA territory has the following three major subdivisions (see Table 10.1): the **MCA superior division** supplies most of the cortex above the Sylvian fissure, including the lateral frontal cortex and the face and arm peri-Rolandic cortex. The **MCA inferior division** supplies the cortex of the lateral temporal and occipital lobes below the Sylvian fissure, as well as a variable portion of the lateral parietal cortex. The **MCA deep territory** includes the internal capsule and much of the basal ganglia (see Figures 10.7–10.9).
4. The **ACA** also has a **deep territory,** including portions of the anterior basal ganglia and internal capsule, while the **deep territory of the PCA** includes the thalamus, midbrain, and variable parts of the posterior internal capsule (Figure 10.8). The superficial and deep territories of all three major cerebral vessels are summarized in Figures 10.6 and 10.9. Deficits caused by occlusion of the three main cerebral arteries or their branches are summarized in Table 10.1.
5. Blockage of a cerebral artery or its branches often causes an infarct in a specific vascular territory. Infarcts can also occur through another mechanism when the systemic blood pressure drops, or when a parent vessel (such as the carotid artery) supplying more than one major cerebral vessel (e.g., the ACA and MCA) becomes blocked, resulting in infarction of the most distal territories of overlap of these vessels. These territories are called **watershed zones** (see Figure 10.10).
6. Venous drainage of the cerebral hemispheres occurs through a system of superficial and deep cerebral veins. The superficial veins drain mainly into the **superior sagittal sinus** and **cavernous sinus,** while the deep veins drain into the **great vein of Galen** (see Figure 10.11). Ultimately, all venous drainage for the brain reaches the **internal jugular veins,** mostly via the **transverse** and **sigmoid sinuses.**

Additional Cases

Related cases can be found for the following: **cerebral infarct,** or **TIA** (Cases 5.5, 6.1–6.3, 6.5, 7.1, 7.2, 11.1, 13.7, 14.1–14.8, 15.1, 18.3, 19.1–19.4, 19.6, 19.8, 19.9); **aneurysm** (Case 13.1); **arteriovenous malformation (AVM)** (Case 11.5); **dissection** (Case 13.6); and **intracranial hemorrhage** (Cases 5.1–5.3, 5.5, 5.6, 14.9, 19.3, 19.4). Other relevant cases can be found using the **Case Index**.

CASE 10.13 RIGHT FRONTAL HEADACHE AND LEFT ARM NUMBNESS IN A WOMAN WITH GASTRIC CARCINOMA

Figure 10.25 Right Parietal Hemorrhage, and Empty Delta Sign (A) Noncontrast scan showing right parietal hemorrhage with surrounding edema. (B) Repeat scan with intravenous contrast, showing empty delta sign.

(A)

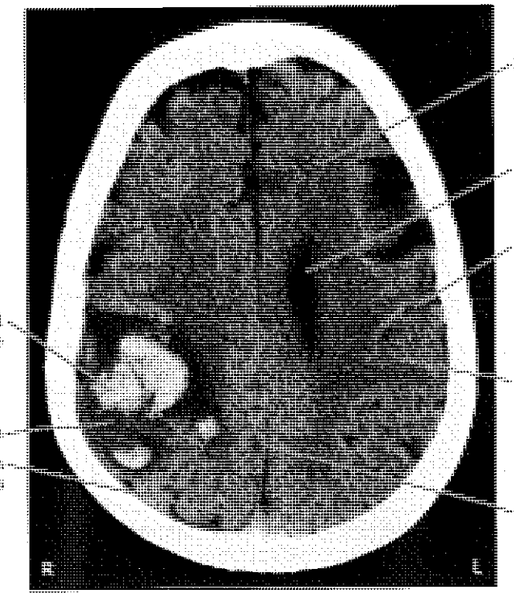

(B)

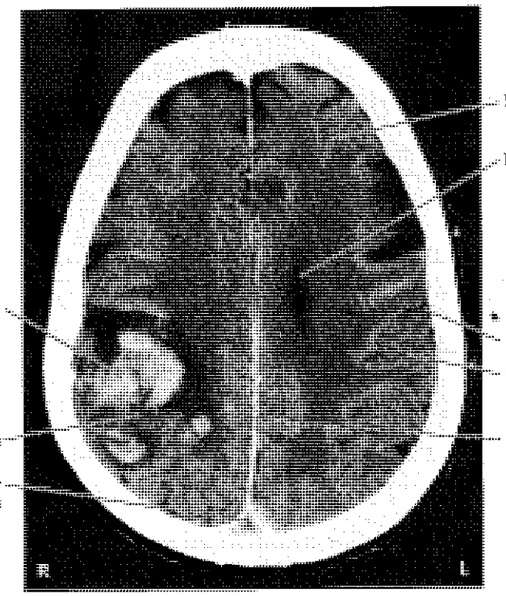

CASE 10.13 *(CONTINUED)*

Figure 10.26 Superior Sagittal Sinus Thrombosis Magnetic resonance venogram (MRV). (A) MRV from patient in Case 10.13, showing absence of flow in the superior sagittal sinus, likely due to thrombosis. (B) MRV in a normal patient, showing normal flow in the superior sagittal sinus, and cortical veins. Note that the transverse sinuses are not well seen in both A and B, because their initial portions near the torcula are being viewed end-on, and their more lateral portions are truncated by the imaging method. Compare to Figure 10.11.

(A)

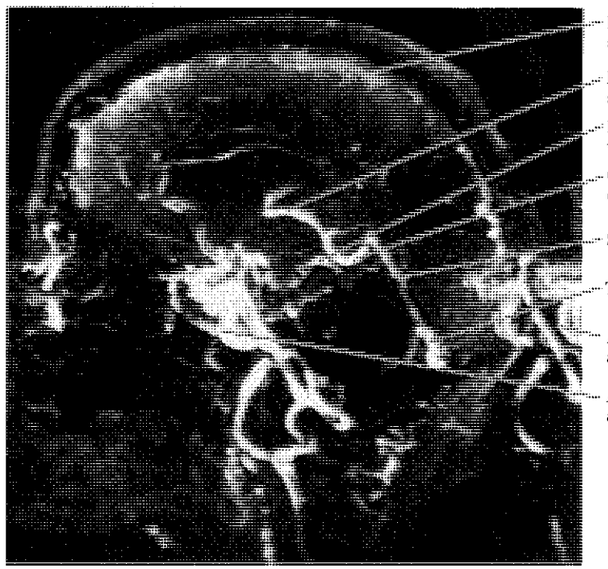

(B)

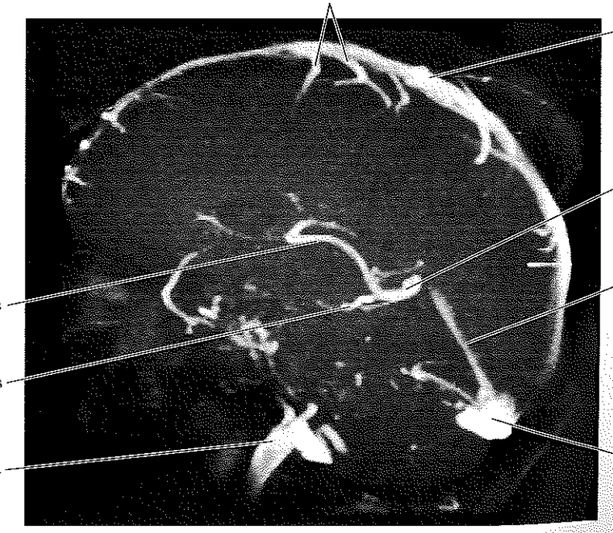

References

General References

Damasio H. 1987. Vascular territories defined by computed tomography. In Wood JH (ed.), *Cerebral Blood Flow: Physiologic and Clinical Aspects*, Chapter 20. McGraw-Hill, New York.

Osborn AG, Tong KA. 1995. *Handbook of Neuroradiology: Brain and Skull*, 2nd Ed. Mosby, St. Louis, MO.

Renfro MB, Day AL, Rhoton AL. 1997. The extracranial and intracranial vessels: Normal anatomy and variations. In Batjer HH (ed.), *Cerebrovascular Disease*, Chapter 1. Lippincott-Raven, Philadelphia.

Tatu L, Moulin T, Bogousslavsky J, Duvernay H. 1998. Arterial territories of the human brain: Cerebral hemispheres. *Neurology* 50(60): 1699–1708.

Anterior Cerebral Artery

Bogousslavsky J, Regli F. 1990. Anterior cerebral artery territory infarction in the Lausanne Stroke Registry: Clinical and etiologic patterns. *Arch Neurol* 47(2): 144–150.

Brust JCM. 1998. Anterior cerebral artery. In Barnett HJM, Mohr JP, Stein BM (eds.), *Stroke: Pathophysiology, Diagnosis, and Management*, 3rd Ed., Chapter 18. Churchill Livingstone, New York.

Klatka LA, Depper MH, Marini AM. 1998. Infarction in the territory of the anterior cerebral artery. *Neurology* 51(2): 620–622.

Middle Cerebral Artery

Caplan L, Babilkian V, Helgason C, Hier DB, DeWitt D, Patel D, Stein R. 1985. Occlusive disease of the middle cerebral artery. *Neurology* 35(7): 975–982.

Heinsius T, Bogousslavsky J, Van Melle G. 1998. Large infarcts in the middle cerebral artery territory: Etiology and outcome patterns. *Neurology* 50(2): 341–350.

Lhermitte F, Gautier JC, Derouesne C. 1970. Nature of occlusions of the middle cerebral artery. *Neurology* 20(1): 82–88.

Mohr JP, Lazar RM, Marshall RS, Gautier JC. 1998. Middle cerebral artery disease. In Barnett HJM, Mohr JP, Stein BM (eds.), *Stroke: Pathophysiology, Diagnosis, and Management*, 3rd Ed., Chapter 19. Churchill Livingstone, New York.

Moulin T, Cattin F, Crépin-Leblond T, Tatu L, Chavot D, Piotin M, Viel JF, Rumbach L, Bonneville JF. 1996. Early CT signs in acute middle cerebral artery infarction: Predictive value for subsequent infarct locations and outcome. *Neurology* 47(2): 366–374.

Waddington MM, Ring BA. 1968. Syndromes of occlusions of middle cerebral artery branches. *Brain* 91(4): 685–696.

Posterior Cerebral Artery

Chambers BR, Brooder RJ, Donnan GA. 1991. Proximal posterior cerebral artery occlusion simulating middle cerebral artery occlusion. *Neurology* 41(3): 385–390.

DeRenzi E, Zambolin A, Crisi G. 1987. The pattern of neuropsychological impairment associated with left posterior cerebral artery infarcts. *Brain* 110(Pt. 5): 1099–1116.

Hayman LA, Berman SA, Hinck VC. 1981. Correlation of CT cerebral vascular territories with function: II. Posterior cerebral artery. *Am J Neuroradiol* 2: 219–225.

Mohr JP, Pessin MS. 1998. Posterior cerebral artery disease. In Barnett HJM, Mohr JP, Stein BM (eds.), *Stroke: Pathophysiology, Diagnosis, and Management*, 3rd Ed., Chapter 20. Churchill Livingstone, New York.

Pessin MS, Kwan ES, DeWitt LD, Hedges TR, Gale D, Caplan LR. 1987. Posterior cerebral artery stenosis. *Ann Neurol* 21(1): 85–89.

Lacunar Infarcts and Other Subcortical Infarcts

Adams HP Jr, Damasio HC, Putman SF, Damasio AR. 1983. Middle cerebral artery occlusion as a cause of isolated subcortical infarction. *Stroke* 14(6): 948–952.

Boiten J, Lodder J. 1991. Discrete lesions in the sensorimotor control system. A clinical topographical study of lacunar infarcts. *J Neurol Sci* 105(2): 150–154.

Fisher CM. 1965. Lacunes: Small, deep cerebral infarcts. *Neurology* 15: 774–784.

Fisher CM. 1991. Lacunar infarcts—A review. *Cerebrovasc Dis* 1: 311–320.

Fisher CM, Curry HD. 1965. Pure motor hemiplegia of vascular origin. *Arch Neurol* 13: 30–44.

Ghika J, Bogousslavsky J, Regli F. 1991. Infarcts in the territory of lenticulostriate branches from the middle cerebral artery. Etiological factors and clinical features in 65 cases. *Schweiz Arch Neurol Psychiatr* 142(1): 5–18.

Lodder J, Barnford J, Kappelle J, Boiten J. 1994. What causes false clinical prediction of small deep infarcts? *Stroke* 25(1): 86–96.

Melo TP, Bogousslavsky J, van Melle G, Regli F. 1992. Pure motor stroke: A reappraisal. *Neurology* 42(4): 789–795.

Stroke Mechanisms and Treatment

Barnett HJM, Eliasziw M, Meldrum HE. 1995. Drugs and surgery in the prevention of ischemic stroke. *N Engl J Med* 332(4): 238–248.

Barnett HJM, Taylor DW, Eliasziw M, et al. 1998. Benefit of carotid endarterectomy in patients with symptomatic moderate or severe stenosis. *N Engl J Med* 339(20): 1415–1425.

Biller J, Love BB. 2000. Vascular diseases of the nervous system. In Bradley WG, Daroff RB, Fenichel GM, Marsden CD (eds.), *Neurology in Clinical Practice*, 3rd Ed., Chapter 57. Butterworth-Heinemann, Boston.

Bronner LL, Kanter DS, Manson JE. 1995. Primary prevention of stroke. *N Engl J Med* 333(21): 1392–1400.

Brott T, Bogousslavsky J. 2000. Treatment of acute ischemic stroke. *N Engl J Med* 343(10): 710–722.

Bruno A, Biller J, Adams HP, Jr, Clarke WR, Woolson RF, Williams LS, Hansen MD. 1999. Acute blood glucose level and outcome from ischemic stroke. *Neurology* 52(2): 280–284.

Delashaw JB, Broaddus WC, Kassell NF, Haley EC, Pendleton GA, Vollmer DG, Maggio WW, Grady MS. 1990. Treatment of right cerebral infarction by hemicraniectomy. *Stroke* 21(6): 874–881.

Easton JD (ed.). 1998. Current advances in the management of stroke. *Neurology Suppl* 51(3) Suppl. 3: S1–S73.

Hacke W (ed.). 1999. Advances in stroke management: Update 1998. *Neurology Suppl* 53(7) Suppl. 4: S1–S37.

Nadeau SE. 1994. Transient ischemic attacks: Diagnosis, and medical and surgical management. *J Fam Pract* 38(5): 495–504.

NINDS Stroke rt-PA Stroke Study Group. 1995. Tissue plasminogen activator for acute ischemic stroke. *N Engl J Med* 333(24): 1581–1587.

Watershed Infarcts

Bladin CF, Chambers BR. 1993. Clinical features, pathogenesis, and computed tomographic characteristics of internal watershed infarction. *Stroke* 24(12): 1925–1932.

Bogousslavsky J, Regli F. 1986. Unilateral watershed cerebral infarcts. *Neurology* 36(3): 373–377.

Wodarz R. 1980. Watershed infarctions and computed tomography. A topographical study in cases with stenosis or occlusion of the carotid atrery. *Neuroradiology* 19(5): 245–248.

Headache and Stroke

Jorgensen HS, Jespersen HF, Nakayamu H, Raaschou HO, Olsen TS. 1994. Headache in stroke: The Copenhagen stroke study. *Neurology* 44(10): 1793–1797.

Vestergaard K, Andersen G, Nielsen MI, Jensen TS. 1993. Headache in stroke. *Stroke* 24(11): 1621–1624.

Cerebral Venous Anatomy and Thrombosis

Capra NF, Anderson KV. 1984. Anatomy of the cerebral venous system. In Kapp JP, Schmidek HH (eds.), *The Cerebral Venous System and Its Disorders*, Chapter 1. Grune & Stratton, Orlando, FL.

Einhaupl KM, Villringer A, Meister W, Mehraein S, Garner C, Pellkofer M, Haberl RL, Pfister HW, Schmeidck P. 1991. Heparin treatment of venous sinus thrombosis. *Lancet* 338(8767): 597–600.

Isensee C, Reul J, Thron A. 1994. Magnetic resonance imaging of thrombosed dural sinuses. *Stroke* 25(1): 29–34.

Virapongse C, Cazenave C, Quisling R, Sarwar M, Hunter S. 1987. The empty delta sign: Frequency and significance in 76 cases of dural sinus thrombosis. *Radiology* 162(3): 779–785.

CHAPTER 11

ANATOMICAL AND CLINICAL REVIEW
Eyes and Retina
Optic Nerves, Optic Chiasm, and Optic Tracts
Lateral Geniculate Nucleus and Extrageniculate Pathways
Optic Radiations to Primary Visual Cortex
Visual Processing in the Neocortex
KCC 11.1 Assessment of Visual Disturbances
KCC 11.2 Localization of Visual Field Defects
KCC 11.3 Blood Supply and Ischemia in the Visual Pathways
KCC 11.4 Optic Neuritis

CLINICAL CASES
11.1 A Dark Spot Seen with One Eye
11.2 Vision Loss in One Eye
11.3 Menstrual Irregularity and Bitemporal Hemianopia
11.4 Hemianopia after Treatment for a Temporal Lobe Tumor
11.5 Visual Changes Caused by Migraine Headaches?
Additional Cases

BRIEF ANATOMICAL STUDY GUIDE

Visual System

Because of their structure, a single lesion in the visual pathways can affect both eyes, causing significant functional impairments. A 57-year-old man repeatedly visited the emergency room because of headaches. He experienced throbbing bilateral or right occipital pain and saw zigzagging lines in his visual field. He had also recently noticed a vision problem that caused him to frequently bump into objects on his left side. On examination, he was unable to see anything in the left lower quadrant of his visual fields in both eyes. In this chapter, we will learn about the normal anatomy and function of the neural pathways from the retina to the cortex, and we will use this knowledge to accurately diagnose and localize lesions in clinical cases.



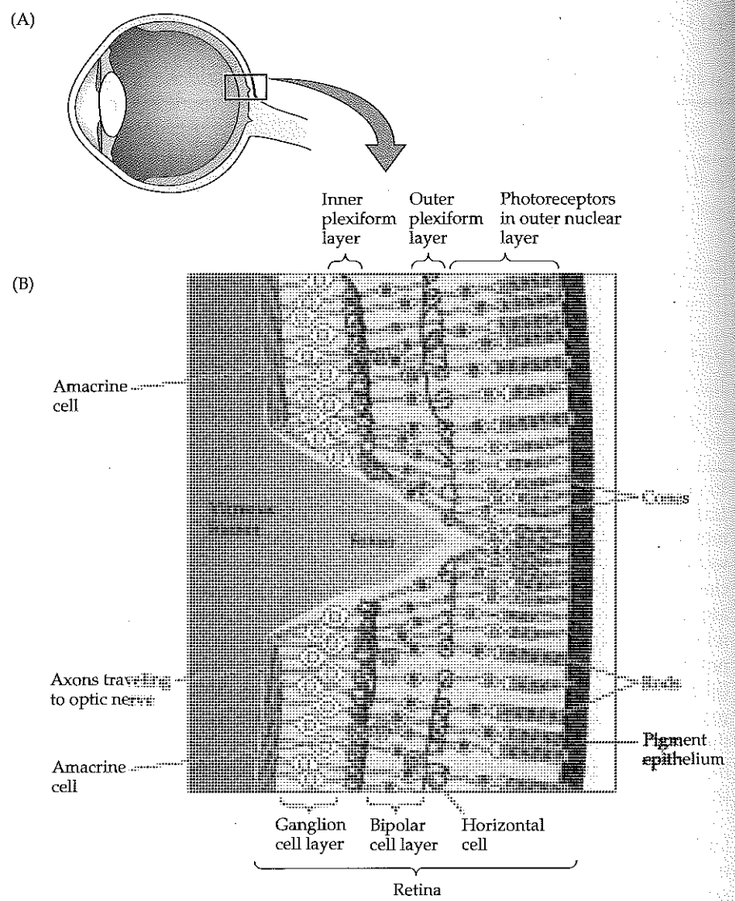

Figure 11.4 The Retina (A) Spatial relationships between the retina and other structures of the eye. (B) Magnified view of the fovea, where light reaches photoreceptors (rods and cones) without passing through intervening layers. The main cells and cell layers of the retina are indicated.

REVIEW EXERCISE

Name each of the five layers of the retina, proceeding from the outside toward the center of the eye. For each layer, describe the main cell types or synapses that occur (see Figure 11.4).

onto **ganglion cells,** which send their axons into the optic nerve (see Figure 11.4). Unlike other neurons, photoreceptors and bipolar cells do not fire action potentials. Instead, information is conveyed along the length of these cells by passive electrical conduction, and they communicate through "nontraditional" synapses that release neurotransmitter in a graded fashion that depends on membrane potential. Ganglion cells, on the other hand, do fire action potentials as they convey information into the optic nerve.

In addition to this direct, or vertical, pathway through the retina, there are also interneurons called **horizontal cells** and **amacrine cells** (see Figure 11.4). These interneurons have lateral inhibitory or excitatory connections with nearby bipolar and ganglion cells. Therefore, a small spot of light on the retina causes excitation (or inhibition) of bipolar and ganglion cells directly in its path, and inhibition (or excitation) of the surrounding bipolar and ganglion cells. As a result of these lateral connections, bipolar and ganglion cells have receptive fields with a **center–surround** (concentric) configuration (Figure 11.5).

There are two classes of center–surround cells. **On-center** cells are excited by light in the center of their receptive field and inhibited by light in the surrounding area. Conversely, **off-center** cells are inhibited by light in the center and excited by light in the surrounding area. Beginning with the bipolar cells, many neurons in the visual pathway, including ganglion cells, lateral geniculate neurons, and input neurons of the primary visual cortex have center–surround receptive fields, which are either on-center or off-center. Beyond the input neurons of the visual cortex, neurons involved in vision have more sophisticated receptive field properties, which will be discussed later.

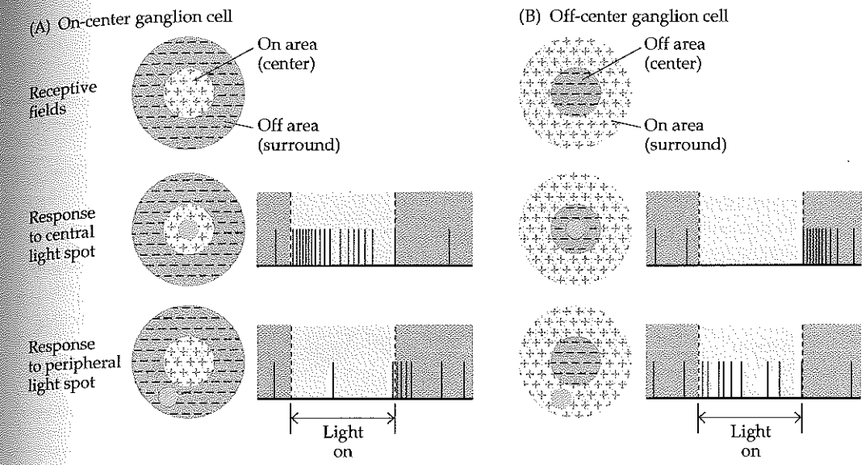

Figure 11.5 Retinal Ganglion Cells with Center–Surround (Concentric) Receptive Fields (A) Receptive fields and response patterns of an on-center cell. Duration of the light stimulus and action potential firing pattern, recorded extracellularly, are shown to the right. (B) Receptive fields and response patterns of an off-center cell. (After Kuffler SW. 1953. Discharge patterns and functional organization of mammalian retina. *J Neurophysiol* 16: 37–68.)

Retinal ganglion cells can be further classified as **M cells** (or Pα or A cells), which have large receptive fields, and respond best to gross stimulus features and movement, and **P cells** (or Pβ or B cells), which have small receptive fields, are more numerous, and are sensitive to fine visual detail and to colors. M cells have larger-diameter fibers and project to the magnocellular layers of the lateral geniculate nucleus of the thalamus (see Figure 11.7), while P cells have smaller-diameter fibers and project to the parvocellular layers of the lateral geniculate. There are also other retinal ganglion cells that fit neither class, some of which are sensitive to overall light intensity. M and P cells can be either on- or off-center cells.

Optic Nerves, Optic Chiasm, and Optic Tracts

The retinal ganglion cells send their axons into the **optic nerve,*** which exits through the orbital apex via the optic canal of the sphenoid bone (see Figure 12.3A,C) to enter the cranial cavity. There is a partial crossing of fibers in the **optic chiasm** (see Figure 11.15). Thus, fibers from the left hemiretinas of both eyes end up in the left **optic tract,** while fibers from the right hemiretinas end up in the right optic tract. Note that in order to accomplish this, the nasal (medial) retinal fibers for each eye, which are responsible for the temporal (lateral) hemifields, cross over in the optic chiasm. Lesions of the optic

*The optic nerve is not truly a nerve. Retinal bipolar cells are analogous to primary somatosensory neurons (dorsal root ganglion cells), while retinal ganglion cells are analogous to secondary somatosensory neurons that project to the thalamus. Thus, the pathway formed by the retinal ganglion cell axons actually lies entirely within the central nervous system. However, by convention, the initial portion of this pathway (anterior to the optic chiasm) is called the optic nerve, while the more proximal portion of this pathway (posterior to the optic chiasm) is called the optic tract (see Figure 11.15).

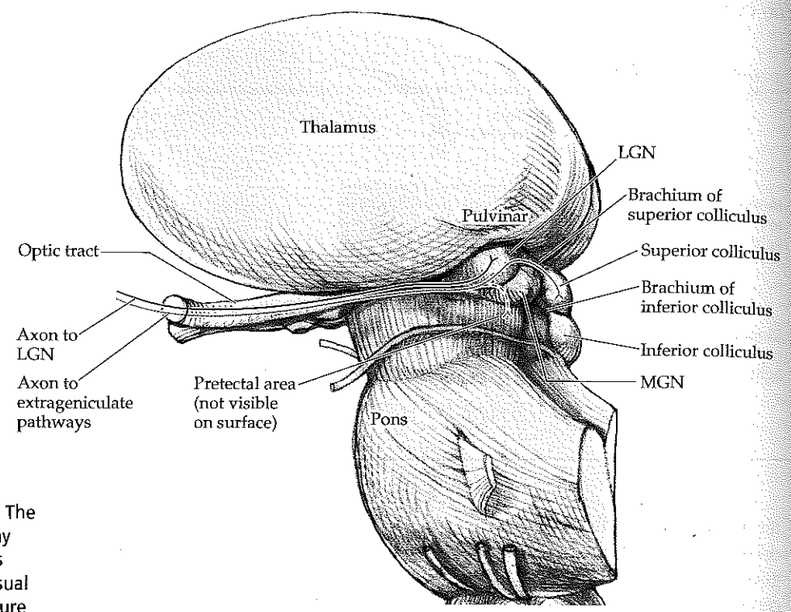

Figure 11.6 Geniculate and Extrageniculate Visual Pathways The geniculate (or geniculostriate) pathway relays in the lateral geniculate nucleus (LGN) and continues to the primary visual cortex via the optic radiations (see Figure 11.15). The extrageniculate pathways bypass the LGN via the brachium of the superior colliculus and relay in the pretectal area and superior colliculus. Projections from the pretectal area and superior colliculus then continue to the pulvinar en route to temporoparieto-occipital association cortex. The medial geniculate nucleus (MGN) and inferior colliculus also shown here are important relays in the auditory system that will be discussed in Chapter 12.

chiasm therefore often produce **bitemporal (bilateral lateral) visual field defects** (see Figure 11.15C). Lesions of the eye, retina, or optic nerves produce **monocular visual field defects** (see Figure 11.15A,B). Because of the crossover in the optic chiasm, lesions proximal to the chiasm (optic tracts, lateral geniculate, optic radiations, or visual cortex) generally produce **homonymous visual field defects,** meaning that the defect occurs in the same portion of the visual field for each eye (see Figure 11.15D,G,H).

The optic chiasm lies on the ventral surface of the brain, beneath the frontal lobes, and just in front of the pituitary gland (see Figure 17.2B). It is therefore susceptible to compression by pituitary tumors and other lesions in this vicinity. The optic tracts wrap around the midbrain laterally to reach the lateral geniculate nucleus (LGN) of the thalamus (Figure 11.6).

Lateral Geniculate Nucleus and Extrageniculate Pathways

The axons of retinal ganglion cells in the optic tracts form synapses on neurons in the **lateral geniculate nucleus (LGN)** of the thalamus, which in turn project to the primary visual cortex. A minority of fibers in the optic tract bypass the LGN to enter the **brachium of the superior colliculus** (see Figure 11.6). These retinal fibers form the **extrageniculate visual pathways,** which project mainly to the pretectal area and superior colliculus. As we will see in Chapter 13, the **pretectal area** is important in the pupillary light reflex and projects to the parasympathetic nuclei controlling the pupils (see Figure 13.8). The **superior colliculus** and pretectal area are important in directing visual attention and eye movements toward visual stimuli. The superior colliculus and pretectal area therefore project to numerous brainstem areas in-

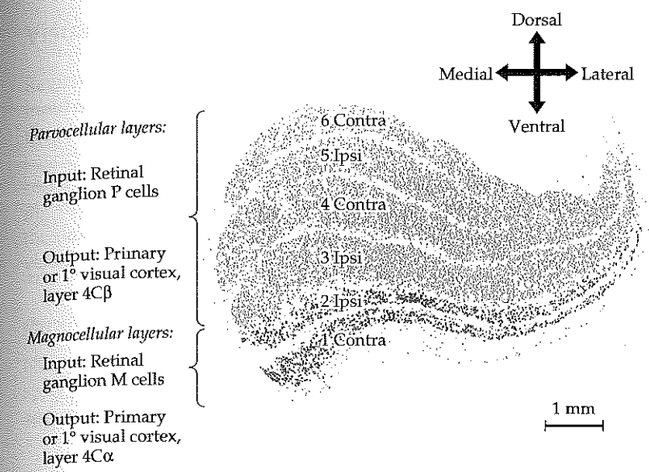

Figure 11.7 Layers of the Lateral Geniculate Nucleus The lateral geniculate nucleus (LGN) is composed of six layers, numbered from ventral to dorsal. As shown, the more dorsal parvocellular layers receive inputs from retinal ganglion P cells, and send outputs to visual cortex layer 4Cβ. The more ventral magnocellular layers receive inputs from retinal ganglion M cells, and send outputs to visual cortex layer 4Cα. Contra = input is from retinal ganglion cells of the contralateral eye; Ipsi = input is from retinal ganglion cells of the ipsilateral eye. (Courtesy of Tim Andrews and Dale Purves, Duke University School of Medicine.)

volved in these functions, as well as to **association cortex** (lateral parietal cortex and frontal eye fields of prefrontal cortex) via relays in the **pulvinar** and lateral posterior nucleus of the thalamus (see Figure 11.6; see also Figures 7.7 and 7.8). Thus, the retino-tecto-pulvinar-extrastriate cortex pathway functions in visual attention and orientation, while the retino-geniculo-striate pathway functions in visual discrimination and perception.

The LGN has six layers, numbered 1 to 6 from ventral to dorsal (Figure 11.7). The first two **magnocellular layers** relay information from M cells of the retina, while layers 3 through 6, the **parvocellular layers,** relay information from P cells. The information from each eye remains segregated even after passing through the LGN. The segregation is preserved because axons from the ipsilateral and contralateral retinas synapse onto different layers of the LGN (see Figure 11.7). There are also **intralaminar neurons** that are important for relaying information regarding color vision. Most neurons of the LGN have on or off center–surround receptive fields, similar to retinal neurons (see Figure 11.5). However, some LGN neurons, particularly in the magnocellular layers, are **on/off cells.** These cells detect changes and fire transiently to both on and off stimuli.

Optic Radiations to Primary Visual Cortex

The axons leaving the LGN enter the white matter to sweep over and lateral to the atrium and temporal horn of the lateral ventricle (through the C shape of the lateral ventricle) and then back toward the primary visual cortex in the occipital lobe (Figure 11.8). As they do so, these axons fan out over a wide area, forming the **optic radiations.** Axons from the contralateral and ipsilateral retinal layers of the LGN (see Figure 11.7) are intermingled in the optic radiations, so lesions of the optic radiations usually cause homonymous defects affecting the contralateral visual field (see Figure 11.15E–G).

The fibers of the inferior optic radiations arc forward into the temporal lobe, forming **Meyer's loop** (see Figures 11.8, 11.15). The inferior optic radiations carry information from the inferior retina or the superior visual field (see Figure 11.1A). Temporal lobe lesions can therefore cause a **contralateral homonymous superior quadrantanopia** ("pie in the sky" visual field defect) (see Figure 11.5E). Conversely, the upper optic radiations pass under

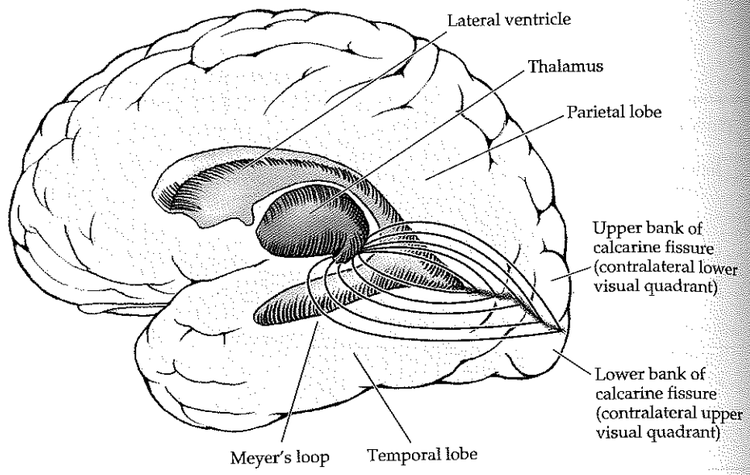

Figure 11.8 Optic Radiations Inferior fibers (Meyer's loop) pass through the temporal lobe. Superior fibers of the optic radiations pass through the parietal lobe.

REVIEW EXERCISE

Do the optic radiations pass laterally to the lateral ventricles, or do they remain medial to the lateral ventricles for their entire course? (See Figure 11.8.)

the parietal lobe (see Figure 11.8). Therefore, parietal lobe lesions can sometimes cause a **contralateral homonymous inferior quadrantanopia** ("pie on the floor" visual field defect) (see Figure 11.15F).

The **primary visual cortex** lies on the banks of the **calcarine fissure** in the occipital lobe (Figure 11.9). The upper portions of the optic radiations project to the superior bank of the calcarine fissure; the inferior optic radiations terminate on the lower bank (see Figure 11.8). Upper-bank lesions thus cause contralateral inferior quadrant defects, while lower-bank lesions cause contralateral superior quadrant defects (see Figure 11.15I,J). The primary visual cortex, like many other parts of the visual pathways, is **retinotopically organized.** The region of the fovea is represented near the occipital pole, while more peripheral regions of the ipsilateral retinas and contralateral visual fields are represented more anteriorly along the calcarine fissure (see Figure 11.9). Note that despite its small retinal area, because it is the region of highest visual acuity, the fovea has a disproportionate cortical representation, occupying about 50% of the primary visual cortex.

MNEMONIC

The portions of the medial occipital lobe above and below the calcarine fissure, respectively, are named the cuneus (meaning "wedge") and lingula (meaning "little tongue") (Figure 11.10).

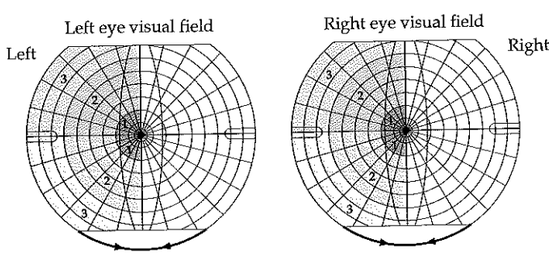

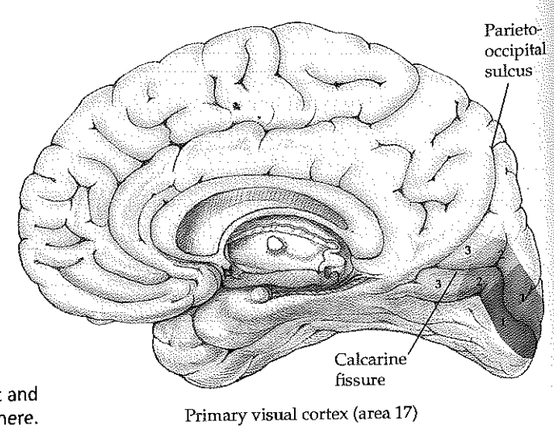

Figure 11.9 Retinotopic Map Left visual hemifields of the left and right eyes mapped to the primary visual cortex of the right hemisphere.

Visual Processing in the Neocortex

Review the different cortical layers and their functions (see Figure 2.14). Most input to primary visual cortex arrives at cortical **layer 4.** Because of its functional importance in this region of the brain, layer 4 is relatively thick and is subdivided into sublaminae 4A, 4B, 4Cα, and 4Cβ (see Figure 11.10). Layer 4B contains numerous myelinated axon collaterals resulting in the pale-appearing **stria of Gennari,** which is visible in sections of the gray matter even with the naked eye. Because of this distinctive stria (see Figure 11.10), the **primary visual cortex (area 17)** is sometimes referred to as **striate cortex.**

Parallel Channels for Analyzing Motion, Form, and Color

Numerous channels of information undergo parallel processing in the visual system. The three best-characterized channels are for analyzing **motion, form,** and **color.** As already discussed, some of the information for these channels is

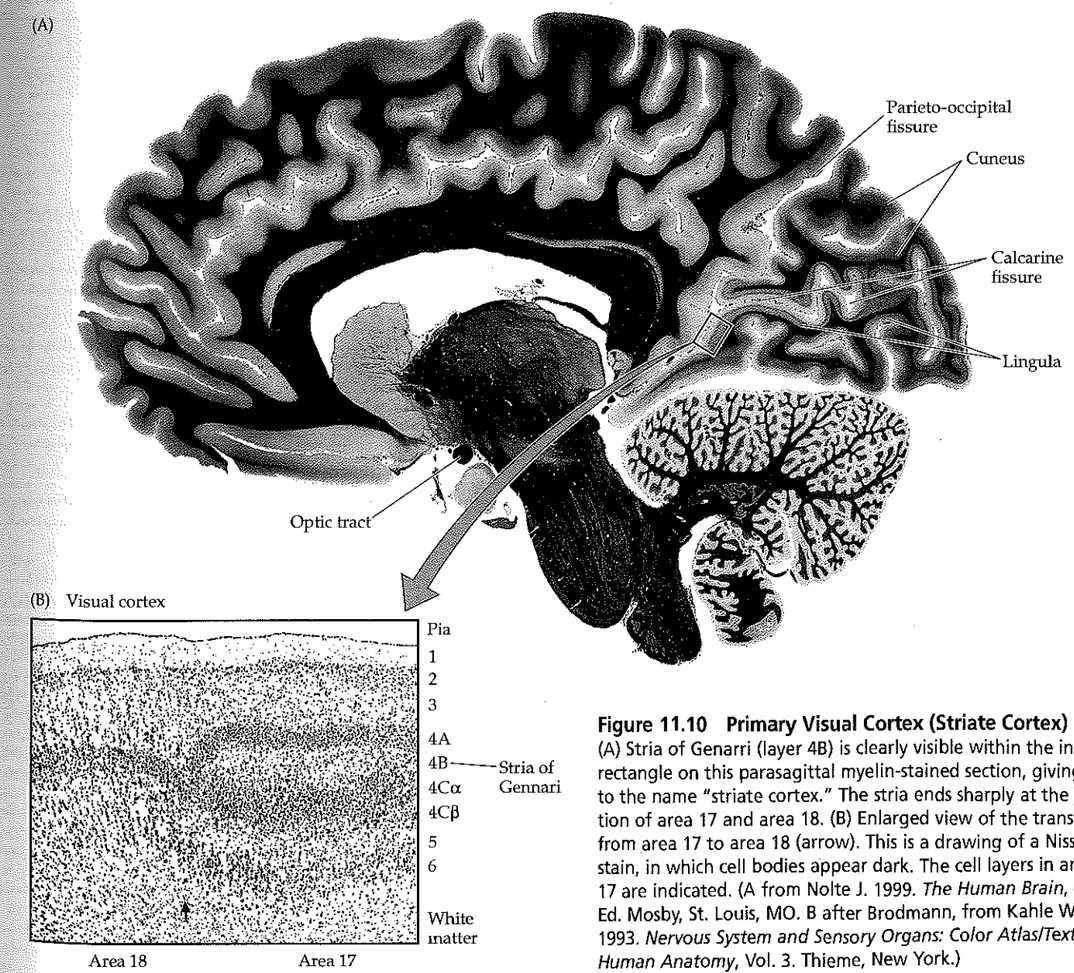

Figure 11.10 Primary Visual Cortex (Striate Cortex) (A) Stria of Genarri (layer 4B) is clearly visible within the inset rectangle on this parasagittal myelin-stained section, giving rise to the name "striate cortex." The stria ends sharply at the junction of area 17 and area 18. (B) Enlarged view of the transition from area 17 to area 18 (arrow). This is a drawing of a Nissl stain, in which cell bodies appear dark. The cell layers in area 17 are indicated. (A from Nolte J. 1999. *The Human Brain*, 4th Ed. Mosby, St. Louis, MO. B after Brodmann, from Kahle W. 1993. *Nervous System and Sensory Organs: Color Atlas/Text of Human Anatomy*, Vol. 3. Thieme, New York.)

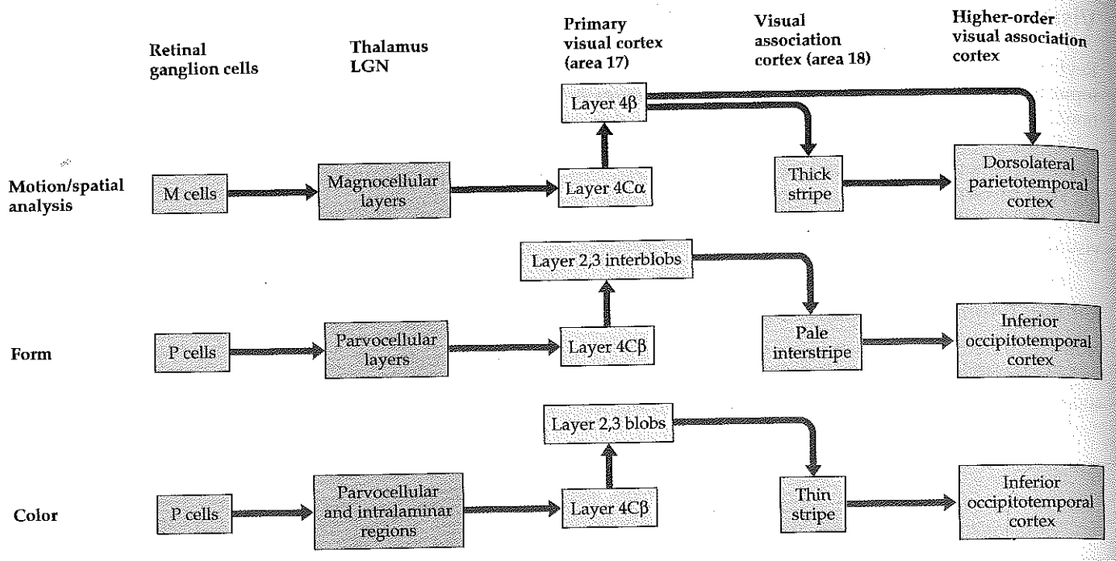

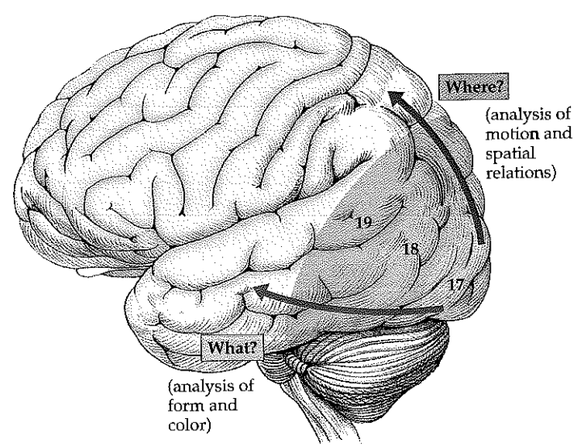

Figure 11.11 Visual Processing Pathways (Top) Three parallel channels of visual information processing. (Bottom) Dorsal and ventral streams of higher-order visual processing.

segregated as early as the retinal ganglion cells and LGN. These three channels also project to different layers of the primary visual cortex (Figure 11.11A). The magnocellular layers of the LGN, conveying information about movement and gross spatial features, project mainly to **layer 4Cα.** The parvocellular layers of the LGN, carrying fine spatial information, terminate mainly in **layer 4Cβ.** Information about color is also relayed by the parvocellular layers, as well as by the interlaminar zones, to specialized regions of cortical **layers 2 and 3** called **blobs** (see Figure 11.14) because of their appearance on staining with the histochemical marker cytochrome oxidase.

From the primary visual cortex, or area 17, neurons project to **extrastriate** regions of **visual association cortex,** including areas 18, 19, and other regions of the parieto-occipital and occipitotemporal cortex (see Figure 11.11A). In the monkey, the three channels of information processing described here have been shown to project to distinct regions of area 18 named thin stripes, thick stripes, and interstripes on the basis of their staining patterns with cytochrome oxidase. From primary and secondary visual cortex (areas 17 and 18), two main streams of higher-order visual processing have been demonstrated in both animals and humans (see Figure 11.11B). The **dorsal pathways** project to parieto-occipital association cortex. These pathways answer the question "**Where?**" by analyzing motion and spatial relationships between objects, and between the body and visual stimuli. The **ventral pathways** project to occipitotemporal association cortex. These pathways answer the question "**What?**" by analyzing form, with specific regions identifying colors, faces, letters, and other visual stimuli. The effects of lesions in these two streams of higher-order visual processing will be discussed in Chapter 19.

Ocular Dominance Columns and Orientation Columns

The classic work of David Hubel and Torsten Wiesel in the 1960s demonstrated that the visual cortex has a **columnar organization.** As in the LGN, inputs to the primary visual cortex are segregated on the basis of whether they originated from the contralateral or ipsilateral eye. However, instead of terminating on different layers, inputs from each eye terminate in different alternating bands of cortex, each about 1 millimeter wide, called **ocular dominance columns** (Figure 11.12A; see also Figure 11.14). The original studies by Hubel, Weisel, and collaborators demonstrated the ocular dominance columns using autoradiography and histological techniques on postmortem tissue from animals. Today, it is possible to image the ocular dominance columns and other patterns of cortical activity in living animals (including humans) using intrinsic optical signals related to neural activity, as shown in Figure 11.12A. In this experiment, optical signals were recorded from primary visual cortex with a camera looking down at the pial surface of the brain during presentation of visual stimuli. A visual stimulus presented to the right eye activated regions shown in white, while a stimulus presented to the left eye activated regions shown in black. This produced a typical pattern of ocular dominance columns consisting of alternating stripes of increased and decreased activation corresponding to inputs from the right and left eyes, respectively.

The receptive fields of neurons in the primary visual cortex input layers, such as layer 4, are mainly on and off center–surround cells (Figure 11.13A). However, these cells project to other neurons, above and below layer 4, which have more sophisticated receptive fields. **Simple cells** respond to

REVIEW EXERCISE

Does analysis of motion and spatial relations take place in the dorsal or ventral stream of visual association cortex? What about analysis of form and color? (See Figure 11.11)



Figure 11.12 Intrinsic Optical Signals Demonstrating Ocular Dominance Columns, and Orientation Columns View is looking down onto the pial surface of the brain. (A) Ocular dominance columns. Visual stimuli were presented monocularly to the right eye and to the left eye of a macaque monkey. Intrinsic optical signals were then recorded from primary visual cortex. The intrinsic optical signal is correlated with the ratio of oxyhemoglobin to deoxyhemoglobin in the tissue, which in turn is related to the amount of neuronal activity. Regions that receive input mainly from the right eye appear light, while regions that receive input mainly from the left eye appear dark. Dimensions of the region of cortex shown here are 8 × 5 mm. (B) Orientation columns. Arrays of parallel lines of different orientations were presented binocularly. Regions with a particular orientation selectivity respond most strongly to lines oriented in the preferred direction. Intrinsic optical signals recorded with stimuli of different orientations are represented here by different colors. Line orientation relative to horizontal and color codes, respectively are: 0° = red; 45° = yellow; 90° = green; 135° = blue. The region of cortex imaged was identical to that shown in (A). (Courtesy of Anna Roe, Yale University School of Medicine.)

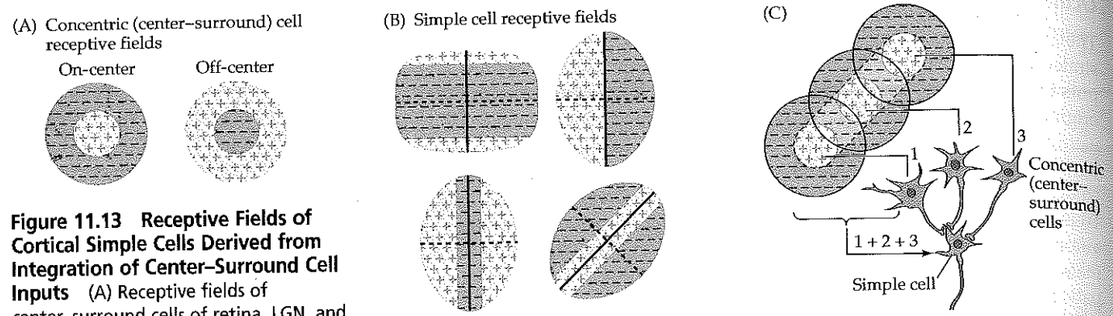

Figure 11.13 Receptive Fields of Cortical Simple Cells Derived from Integration of Center–Surround Cell Inputs (A) Receptive fields of center–surround cells of retina, LGN, and cortical input layer. (B) Receptive fields of simple cells of primary visual cortex. Exact fields vary, but they always contain orientation-selective regions of excitation and inhibition. (C) Model proposed by Hubel and Wiesel for summation of center–surround inputs to generate the receptive field of a simple cell with orientation selectivity. (After Hubel DH, Wiesel TN. 1962. Receptive fields, binocular interaction and functional architecture in the cat's visual cortex. *J Physiol (Lond)* 160: 106–154.)

lines or edges that occur at a *specific location*, and with a specific angular orientation within their receptive field (Figure 11.13B). Figure 11.13C shows a model for how the summation of activity from several concentric cells with adjacent receptive fields can generate the receptive field of a single simple cell having a specific orientation selectivity. Activity from simple cells, in turn, summates to generate the receptive field properties of **complex cells**, the next level of neuronal processing. Complex cells respond to lines or edges that occur at *any location* in their receptive field, with a specific angular orientation. Several subclasses of these cell types exist, and there are also neurons with even more sophisticated receptive fields.

The orientation selectivity of simple cells, complex cells, and other neurons remains the same within a vertical column of cortex, from pia to white matter. In contrast, as one moves horizontally in the cortex, the orientation selectivity varies continuously, so that a complete 180 degree sequence of orientation selectivity occurs over a cortical distance of about 1 mm (see Figure 11.14). The vertical columns of uniform orientation selectivity are called **orientation columns**, which can also be imaged in living animals using optical imaging (see Figure 11.12B).

Ocular dominance and orientation columns intersect, so a given region of about 1 square millimeter of cortex will contain a complete sequence of both ocular dominance and orientation columns (Figure 11.14). Such functional units were referred to by Hubel and Wiesel as **hypercolumns.** It is likely that additional columns for functions other than ocular dominance and orientation selectivity also exist in the visual cortex.

KEY CLINICAL CONCEPT

ASSESSMENT OF VISUAL DISTURBANCES

Ophthalmoscopic exam

11.1 The localization and diagnosis of visual disturbances involves two major steps. The first step is a detailed description of the **nature of the visual disturbance,** including its time course and whether positive phenomena such as brightly colored lights or negative phenomena such as regions of decreased vision are present. The second step is a description of the regions of the **visual field** for each eye that are involved. In this section we will discuss the localizing information that can be derived from the nature of the visual disturbance; in the next section we will discuss the visual field defects seen with lesions in specific locations.

As with other disorders, the evaluation of visual disturbances involves taking a detailed history, followed by a complete exam, which includes examination of the eyes with an ophthalmoscope (see neuroexam.com Video 25), as well as testing of visual acuity and of visual fields for each eye (see neuroexam.com Video 27). **Visual acuity** is often reported using the **Snellen notation** of 20/X. In this notation, the smallest line of the eye chart seen by the subject at 20 feet can be seen by a normal individual at the distance given in the denominator. Visual acuity can be impaired by a variety of ophthalmological disorders that are beyond the scope of this text (see References at the end of the chapter for details). Note that visual field defects do not typically affect visual acuity.

The distinction between a **monocular or binocular** visual disturbance is essential for localization. However, patients often describe visual changes as being in one eye, when in reality the left or right sides of the visual fields for both eyes are affected. While describing a transient visual disturbance, patients are sometimes able to recall improvement on covering one eye, suggesting a true monocular disorder. Often it is only by examination of the patient while the problem is still present that this distinction can be confirmed. Similarly, **"blurred" vision** is hard to interpret without further description; it can mean anything from corneal disease to a lesion in the visual cortex. "Blurred" vision can sometimes even be a sign of subtle diplopia, suggesting an ocular motility disorder (see Chapter 13).

Some important terms used to describe visual disturbances are listed in Table 11.1. Visual changes are often divided into positive and negative phenomena. Negative phenomena such as a **scotoma** or a **homonymous visual field defect** (see Table 11.1) can be caused by lesions at various locations in the visual pathways (see Figure 11.15; KCC 11.2). Patients may be aware of a dark brown, purplish, or white region of their vision where they cannot see. At other times they are unaware of the defect, and the region that cannot be seen is experienced in a manner similar to the physiological blind spot (see Figure 11.2), or to locations behind the head that are normally out of view. Regions of absent vision of this kind are nearly always a result of a lesion of the central visual pathways, while black, dark brown, or purplish scotomas are most often produced by retinal lesions.

Positive visual phenomena may be simple or formed. **Simple visual phenomena** such as lights, colors, or geometric shapes are caused by disturbances anywhere from the eye to the primary visual cortex. Important ophthalmological causes of positive phenomena include light flashes in retinal detachment and rainbow-colored halos around objects in acute glaucoma, although positive phenomena can be caused by numerous other ophthalmological diseases that are beyond the scope of this discussion. In migraine (see KCC 5.1), patients may experience visual blurring and scotomas that sometimes have a scintillating appearance or consist of jagged alternating light

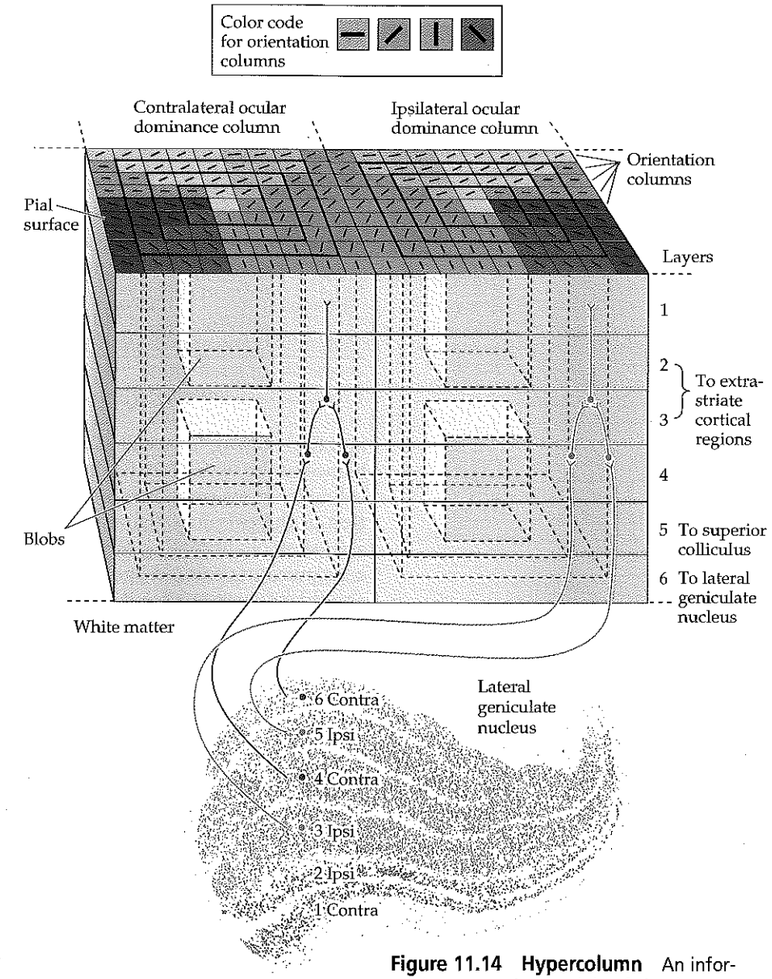

Figure 11.14 Hypercolumn An information-processing module of visual cortex containing a complete set of ocular dominance columns, orientation columns, blobs, and interblobs. Inputs from the lateral geniculate nucleus are shown as well. Contra = input from contralateral eye; Ipsi= input from ipsilateral eye. (Top illustration after Rosenzweig MR, Breedlove SM, Leiman AL. 2002. *Biological Psychology*, 3rd Ed. Sinauer, Sunderland, MA; bottom courtesy of Tim Andrews and Dale Purves, Duke University School of Medicine.)

TABLE 11.1 Some Terms to Describe Visual Disturbances

TERM	DEFINITION
Scotoma	A circumscribed region of visual loss
Homonymous defect	A visual field defect in the same region for both eyes
Refractive error	Indistinct vision improved by corrective lenses
Photopsias	Bright, unformed flashes, streaks, or balls of light
Phosphenes	Photopsias produced by retinal shear or optic nerve disease
Entopic phenomena	Seeing structures in one's own eye
Illusions	Distortion or misinterpretation of visual perception
Hallucination	Perception of something that is not present

and dark zigzag lines called a **fortification scotoma** (because of its resemblance to the water fortifications of medieval towns in Europe). These typical migrainous phenomena are thought to be related to transient dysfunction of the primary visual cortex (e.g., zigzagging lines may result from activation of alternating orientation columns). When patients instead experience pulsating colored lights or moving geometric shapes, occipital seizures should be suspected, although occipital seizures may also produce migrainelike visual phenomena at times.

Formed visual hallucinations (see Table 11.1), such as people, animals, or complex scenes, arise from the inferior temporo-occipital visual association cortex. Common causes of formed visual hallucinations include toxic or metabolic disturbances (especially hallucinogens, anticholinergics, and cyclosporin), withdrawal from alcohol or sedatives, focal seizures, complex migraine, neurodegenerative conditions such as Creutzfeldt–Jakob disease or Lewy body disease, narcolepsy, midbrain ischemia (peduncular hallucinosis; see KCC 14.3), or psychiatric disorders. Of note, in psychiatric disorders visual hallucinations are less common than auditory hallucinations, and they usually occur with accompanying sound. Formed visual hallucinations can also appear as a **release phenomenon.** Thus, patients with visual deprivation in part or all of their visual fields caused by either ocular or central nervous system lesions may occasionally see objects, people, or animals in the region of vision loss, especially during the early stages of the deficit. Visual hallucinations that occur in elderly patients as a result of impaired vision have been called Bonnet syndrome. ■

KEY CLINICAL CONCEPT

LOCALIZATION OF VISUAL FIELD DEFECTS

Visual fields

11.2 Once the nature of a visual disturbance has been established (see KCC 11.1), including the time course and other clinical features, such as whether positive, negative, simple, or elaborate visual phenomena are present, the next step is to evaluate which portions of the visual fields are involved. We will first describe the methods used for visual field testing and then discuss the interpretation and localizing value of specific visual field defects.

Visual Field Testing

Basic **visual field testing** can be done at the bedside, using **confrontation testing** (see neuroexam.com Video 27). The examiner should test each eye separately, by covering one eye at a time. The patient is instructed to look at the examiner's eye while the examiner holds visual stimuli such as fingers or a small cotton-tipped stick halfway between the patient and examiner. In this way, the examiner's visual field is being tested at the same time, which serves as a check on the patient's field. The examiner should test each quadrant while watching the patient carefully for central fixation. Moving or wiggling fingers are easier to see but are less sensitive for detecting regions of mildly decreased vision. Fingers should be held up simultaneously on the right and left sides at some point during the exam to test for extinction, a sign of visual neglect (see KCC 19.9). By convention, visual fields are recorded with the right eye on the right side of the page, as if viewing your own visual field (see Figure 11.1). **Blink to threat** can be a useful way of testing crude visual fields in the uncooperative or lethargic patient (see neuroexam.com Video 28).

Blink to threat

More **formal visual field testing** can be done, when appropriate, using **Goldmann perimetry,** with small lights of different sizes and intensities displayed on a screen in front of the patient (Figure 11.2). The normal visual field extends about 60° nasally and superiorly, and slightly farther inferiorly and temporally. In addition to manually performed Goldmann perimetry, automated computerized perimetry is increasingly being used in some settings. However, automated perimetry usually only tests the central 30° of the visual field.

Visual Field Defects

The position and shape of the scotoma, and whether it affects one eye or both, are the most important pieces of information allowing localization of abnormalities in the visual pathways. Figure 11.15 summarizes the effects of lesions at various points in the pathways from retina to primary visual cortex that we have been discussing in this chapter, and review again here. A lesion of the retina causes a **monocular scotoma** (see Figure 11.15A), with the location, size, and shape depending on the location and extent of the lesion. Common causes include retinal infarcts (KCC 11.3), hemorrhage, degeneration, or infection. If the lesion is severe enough, the entire retina may be involved, causing **monocular visual loss** (see Figure 11.15B). In addition to retinal disorders, monocular disturbances of vision can result from numerous other diseases of the eye (see ophthalmology texts for additional details).

Lesions of the optic nerve cause monocular visual loss or monocular scotomas (see Figure 11.15A,B), which may be partial or incomplete depending on the severity of the lesion. Common causes include glaucoma, optic neuritis, elevated intracranial pressure, anterior ischemic optic neuropathy, optic glioma, schwannoma, meningioma, and trauma.

The optic chiasm is located near the pituitary gland (see Figure 17.2B) and can be compressed by lesions arising in this area. Damage to the optic chiasm typically causes a **bitemporal hemianopia** (see Figure 11.15C), which is often more asymmetrical than shown in the figure. Common lesions in this area include pituitary adenoma, meningioma, craniopharyngioma, and hypothalamic glioma, although numerous other lesions can also occur in this location.

Retrochiasmal lesions, including the optic tracts, LGN, optic radiations, or visual cortex, generally cause **homonymous** visual field defects, meaning that the same regions of the fields for both eyes are involved. However, since the fibers from each eye are less fully mingled in the optic tract and LGN, visual field defects may not be perfectly congruous for more anterior retrochiasmal lesions, while they are usually perfectly congruous for lesions of the visual cortex.

Lesions of the optic tracts are relatively uncommon, and usually cause a **contralateral homonymous hemianopia** (see Figure 11.15D). Possible lesions include tumors, infarct, or demyelination.

Lesions of the lateral geniculate nucleus are also usually associated with a contralateral homonymous hemianopia (see Figure 11.15D), although sometimes more unusual visual field defects can occur, such as a keyhole-

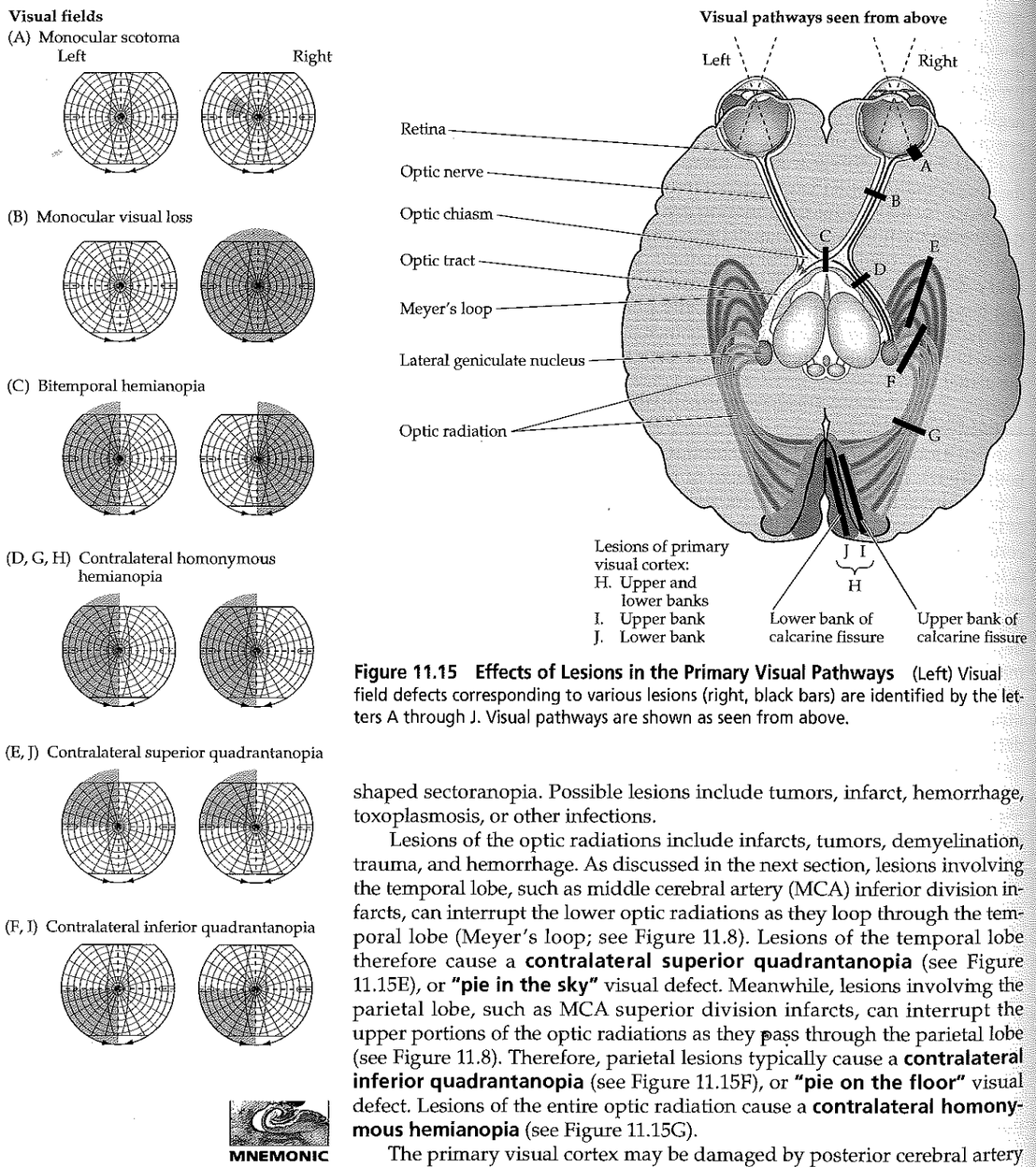

Figure 11.15 Effects of Lesions in the Primary Visual Pathways (Left) Visual field defects corresponding to various lesions (right, black bars) are identified by the letters A through J. Visual pathways are shown as seen from above.

shaped sectoranopia. Possible lesions include tumors, infarct, hemorrhage, toxoplasmosis, or other infections.

Lesions of the optic radiations include infarcts, tumors, demyelination, trauma, and hemorrhage. As discussed in the next section, lesions involving the temporal lobe, such as middle cerebral artery (MCA) inferior division infarcts, can interrupt the lower optic radiations as they loop through the temporal lobe (Meyer's loop; see Figure 11.8). Lesions of the temporal lobe therefore cause a **contralateral superior quadrantanopia** (see Figure 11.15E), or **"pie in the sky"** visual defect. Meanwhile, lesions involving the parietal lobe, such as MCA superior division infarcts, can interrupt the upper portions of the optic radiations as they pass through the parietal lobe (see Figure 11.8). Therefore, parietal lesions typically cause a **contralateral inferior quadrantanopia** (see Figure 11.15F), or **"pie on the floor"** visual defect. Lesions of the entire optic radiation cause a **contralateral homonymous hemianopia** (see Figure 11.15G).

MNEMONIC

The primary visual cortex may be damaged by posterior cerebral artery (PCA) infarcts, tumors, hemorrhage, infections, or trauma to the occipital poles. Lesions to the upper bank of the calcarine fissure cause a **contralateral inferior quadrantanopia** (see Figure 11.15I), while lesions to the lower bank cause a **contralateral superior quadrantanopia** (see Figure 11.15J). Damage to the entire primary visual cortex causes a **contralateral homonymous hemianopia** (see Figure 11.15H). Smaller lesions cause homonymous scotomas in the appropriate portion of the contralateral visual field (see Figure 11.9).

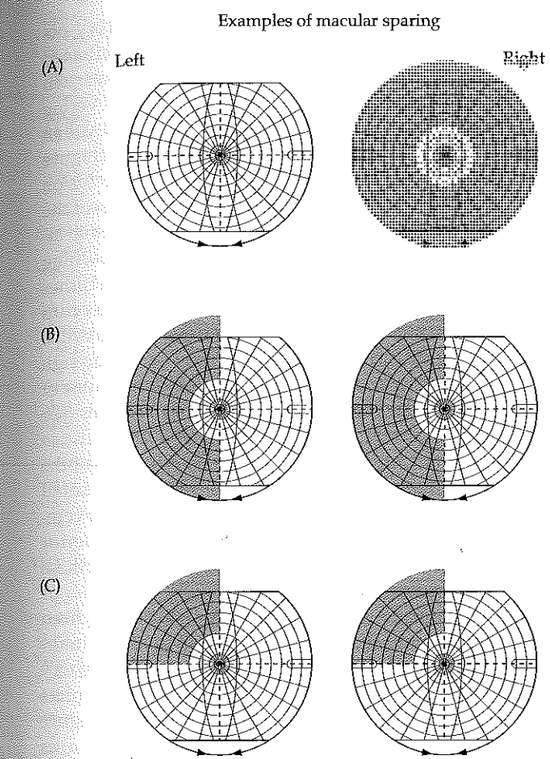

Figure 11.16 Examples of Macular Sparing (A) Monocular concentric visual loss caused, for example, by chronically elevated intracranial pressure or retinitis pigmentosa. (B) Left homonymous hemianopia with macular sparing caused, for example, by a right posterior cerebral artery infarct preserving the occipital pole. (C) Left superior quadrantanopia with macular sparing caused, for example, by a lesion of the inferior bank of the right calcarine fissure preserving the occipital pole.

Partial lesions of the visual pathways occasionally result in a phenomenon called **macular sparing** (Figure 11.16). This occurs because the fovea has a relatively large representation for its size, beginning in the optic nerve and continuing to the primary visual cortex (see, for example, Figure 11.9). Macular sparing can also occur in visual cortex because either the MCA or the PCA may provide collateral flow to the representation of the macula in the occipital pole (see Figure 10.5). Although the term "macular sparing" is usually used in the context of cortical lesions, other lesions may cause a relative sparing of central vision as well. For example, external compression of the optic nerve, as is seen in elevated intracranial pressure, may cause **concentric visual loss** (constricted visual field; see Figure 11.16A).

Disorders of higher-order visual processing caused by lesions of the visual association cortex are discussed in Chapter 19. ■

REVIEW EXERCISE

First, cover all the visual fields in Figure 11.15, and for each lesion marked on the brain (A–J), draw the visual fields expected in a patient with that lesion. Next, cover the brain illustration, and for each visual field defect shown in the figure, state all possible locations where a lesion could be found to cause such a deficit.

11.3 The retina receives its blood supply primarily from branches of the **ophthalmic artery,** which originates just above the genu of the internal carotid artery (see Figure 10.2A). The retinal arteries and veins can be well visualized as they emerge from the optic disc by use of an **ophthalmoscope** (see neuroexam.com Video 25; see also Figure 5.17). The three main causes of impaired blood flow in the ophthalmic artery and its branches are (1) **emboli,** often atheromatous material arising from ipsilateral internal carotid stenosis; (2) **stenosis,** usually associated with diabetes, hypertension, or elevated intracranial pressure; and (3) **vasculitis,** as seen, for example, in temporal arteritis.

KEY CLINICAL CONCEPT

BLOOD SUPPLY AND ISCHEMIA IN THE VISUAL PATHWAYS

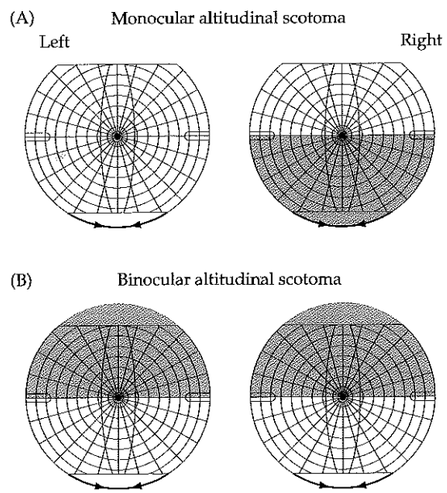

Figure 11.17 Altitudinal Scotomas
(A) Monocular altitudinal scotoma caused, for example, by occlusion of the inferior branch of the right ophthalmic artery by an embolus. (B) Binocular altitudinal scotoma caused, for example, by bilateral occlusion of the posterior cerebral artery (PCA) branches supplying the lingular gyri (inferior banks of calcarine fissures).

Central retinal artery occlusion and **branch retinal artery occlusion** can cause infarction of the entire retina or of the affected retinal sector, respectively. The retinal artery usually has two major branches—one covering the upper half, the other covering the lower half of the retina. An **altitudinal** scotoma in one eye can therefore result from occlusion of one of these branches (Figure 11.17). Smaller monocular scotomas can also occur from occlusion of smaller branches (see Figure 11.15A). Transient occlusion of the retinal artery caused by emboli results in a transient ischemic attack (TIA) of the retina called **amaurosis fugax,** with browning out or loss of vision in one eye for about 10 minutes, sometimes described as being "like a window shade" moving down or up over the eye. This condition deserves to be worked up just like any other TIA (see KCC 10.3, 10.4), since it may be a warning sign for an impending retinal or cerebral infarct. A common cause of amaurosis fugax is ipsilateral internal carotid artery stenosis (see KCC 10.5), which causes artery-to-artery emboli.

The optic tracts, optic chiasm, and intracranial segment of the optic nerves receive their blood supply from numerous small branches arising from the proximal portions of the anterior cerebral artery (ACA), middle cerebral artery (MCA), and anterior and posterior communicating arteries. Clinically significant infarcts of these structures are therefore rarely seen.

The lateral geniculate nucleus has a variable blood supply arising from several vessels, including the anterior choroidal artery (branch of the internal carotid), thalamogeniculate artery, and posterior choroidal artery (branches of the posterior cerebral artery). Infarcts of the lateral geniculate generally produce a contralateral homonymous hemianopia (see Figure 11.15D), although more unusual field defects can also sometimes be seen, as mentioned earlier. In addition, there may be an associated contralateral hemiparesis or hemisensory loss due to involvement of the nearby posterior limb of the internal capsule and thalamic somatosensory radiations (see Figures 6.9B, 10.8B).

The optic radiations pass through the parietal and temporal lobes, where they may be damaged by infarcts of the superior and inferior divisions of the middle cerebral artery, respectively (see Figure 11.8; see also Figure 10.6; Table 19.1). Damage to the upper portions of the optic radiations in the parietal lobe cause a contralateral inferior quadrantanopia (see Figure 11.15F), while damage to Meyer's loop in the temporal lobe causes a contralateral superior quadrantanopia (see Figure 11.15E).

The primary visual cortex is supplied by the posterior cerebral artery (PCA; see Figure 10.5). Infarcts of the entire primary visual cortex cause a contralateral homonymous hemianopia (see Figure 11.15H). Smaller infarcts cause smaller contralateral homonymous defects (see Figure 11.15I,J; 11.16C). Sometimes disease of the basilar artery, which supplies both PCAs (see Figure 10.3), can cause bilateral PCA ischemia or infarcts. A bilateral altitudinal scotoma (see Figure 11.17B) is strongly suggestive of vertebrobasilar insufficiency causing bilateral infarcts or TIAs.

The inferior occipitotemporal visual association cortex ("what?" stream; see Figure 11.11B) is supplied by the PCA (see Figure 10.5). The lateral parieto-occipital visual association cortex ("where?" stream) lies in the MCA–PCA watershed territory (see Figures 10.5, 10.10). Infarcts of the inferior occipitemporal or dorsolateral parieto-occipital visual association cortex cause characteristic disorders of higher-order visual processing that will be discussed in Chapter 19 (see KCC 19.13). ■

KEY CLINICAL CONCEPT
OPTIC NEURITIS

11.4 **Optic neuritis** is an inflammatory demyelinating disorder of the optic nerve that is epidemiologically and pathophysiologically related to multiple sclerosis (see KCC 6.6). Like multiple sclerosis, mean age of onset is in the 30s, onset after age 45 is rare, and there is about a 2:1 female-to-male ratio. With careful follow-up, about 50% or more of patients with an isolated episode of optic neuritis will eventually develop multiple sclerosis.

The usual clinical features at onset include eye pain, especially with movement, and monocular visual problems. The visual impairment typically includes a monocular **central scotoma** (visual loss in the center of the visual field), decreased visual acuity, and impaired color vision. In severe cases, complete loss of vision in one eye may occur. Ophthalmoscopic exam may reveal a swollen optic disc if the inflammation extends to the fundus, causing **papillitis,** or the fundus may appear normal if the neuritis is entirely **retrobulbar** (meaning behind the eye). Sometimes the disc will appear pale, termed **optic disc pallor,** suggesting prior episodes of optic neuritis.

A fairly sensitive way to detect impaired cone function in central vision is to test for **red desaturation,** by asking the patient to compare the appearance of a bright red object seen with each eye (see neuroexam.com Video 26). In patients with past or present optic neuritis, the object will often appear duller in the affected eye. Another very useful way to detect optic nerve dysfunction is to test for an **afferent pupillary defect** using the **swinging flashlight test** (see neuroexam.com Video 30; see also KCC 13.5). In addition, **visual evoked potentials** can provide evidence of impaired conduction in the visual pathways. In this test the patient is shown a shifting checkerboard pattern, which elicits a voltage waveform that can be detected over the occipital cortex by electrodes placed on the scalp. The normal latency for visual evoked potentials is less than about 115 milliseconds. Prolonged latency with preserved amplitude suggests slowed conduction consistent with demyelination.

Swinging flashlight test

Onset of optic neuritis can be acute or slowly progressive over several days to weeks. Near complete recovery is commonly seen within 6 to 8 weeks, and sometimes over a few months. In some cases, especially after repeated bouts, there may be some permanent visual loss. A second episode occurs in about one-third of cases. Treatment for isolated optic neuritis is controversial at present. Another area of controversy is whether to perform further diagnostic tests to explore a possible diagnosis of multiple sclerosis. Most practitioners will have a frank discussion with the patient about the association between optic neuritis and multiple sclerosis and let the patient's preferences guide the extent of the workup. One practical issue is that unless recovery has already begun to occur, it is important to perform an MRI scan to rule out an infiltrative or compressive lesion of the optic nerve as the cause of symptoms.

If any atypical features are present, such as age over 45 years, lack of eye pain, bilateral symptoms, or lack of recovery, further investigations are warranted, including MRI with gadolinium, and blood tests including erythrocyte sedimentation rate, Lyme titer, syphilis serologies, Epstein–Barr virus, human immunodeficiency virus, B_{12}, folate, serological tests for rheumatological disorders, and possibly lumbar puncture. ■

CLINICAL CASES

CASE 11.1 A DARK SPOT SEEN WITH ONE EYE

MINICASE

A 67-year-old man woke up one morning, and when he turned on the bathroom light he noticed a **dark purplish brown spot in the upper part of his vision that disappeared when he covered his right eye.** This did not improve over the following week, so he went to see an ophthalmologist. Initial exam was normal except for a **soft right carotid bruit** and a **scotoma in the upper nasal quadrant of the right eye** on visual field testing (Figure 11.18).

LOCALIZATION AND DIFFERENTIAL DIAGNOSIS

On the basis of the symptoms and signs shown in **bold** above, where is the lesion? What is the most likely diagnosis, and what are some other possibilities? What is the next step in evaluating this patient?

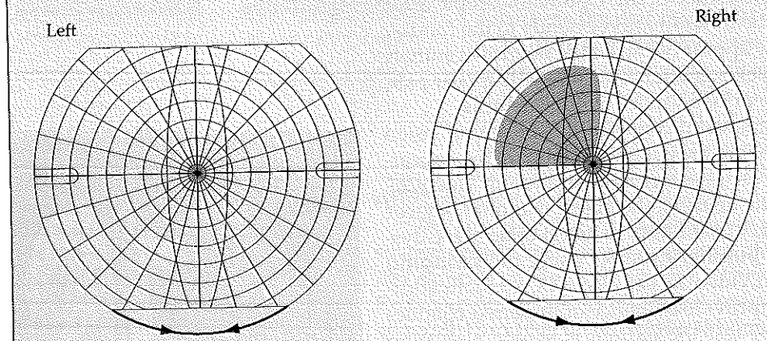

Figure 11.18 Visual Fields
Fields were evaluated by confrontation testing.

Discussion

The key symptoms and signs in this case are:

- **Scotoma in the upper nasal quadrant of the right eye**
- **Right carotid bruit**

The monocular scotoma seen in this patient could be produced by a lesion of the retina in the right eye (see KCC 11.2; Figure 11.15A). A visual field defect in the upper nasal quadrant would be caused by a lesion in the lower temporal portion of the retina (see Figure 11.1). Given the patient's age and the presence of a right carotid bruit, the most likely diagnosis is an embolus arising from the right internal carotid artery (see KCC 10.5), resulting in a branch retinal artery occlusion in the right eye (see KCC 11.3). Additional possibilities include other disorders of the retina, such as hemorrhage, or a disorder of the optic nerve. The next step in the evaluation should be an examination of the retina with an ophthalmoscope.

Clinical Course

A dilated exam of the retina was done, revealing a pale, wedge-shaped area in the inferior, temporal portion of the right retina, consistent with an infarct caused by a branch retinal artery occlusion (KCC 11.3). The patient was admitted and placed on intravenous heparin. Carotid Doppler studies and an MRA showed a tight stenosis of the right internal carotid artery. The patient underwent a right carotid endarterectomy and had no further ischemic events, although the right eye scotoma remained.

CASE 11.2 VISION LOSS IN ONE EYE

MINICASE

A 39-year-old man awoke one morning with **blurred vision in the left eye, as if it were covered with a shaded piece of glass.** This condition progressed over the next few days to **nearly complete loss of vision in the left eye.** He scheduled an appointment with an ophthalmologist, but by the time he was seen, about 2 weeks after the onset of symptoms, the patient felt his vision was 90% back to normal. There was no eye pain, but he did have a generalized headache. On exam, there was slight **pallor of the left optic disc** when viewed with an ophthalmoscope. **When a light was shone into the left pupil, the constriction of both pupils was less** than when a light was shone into the right pupil. This result was best demonstrated with the swinging flashlight test (see KCC 11.4; 13.5). This patient's visual fields are shown in Figure 11.19. The remainder of the examination was normal.

LOCALIZATION AND DIFFERENTIAL DIAGNOSIS

1. On the basis of the symptoms and signs shown in **bold** above, where is the lesion?
2. What is the most likely diagnosis, and what are some other possibilities?

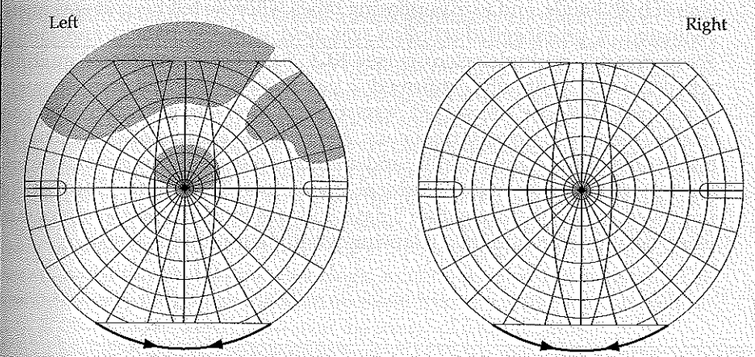

Figure 11.19 Visual Fields
Fields were evaluated by confrontation testing.

Discussion

1. The key symptoms and signs in this case are:
   - **Monocular visual loss in the left eye, improving to a monocular central scotoma**
   - **Left afferent pupillary defect**
   - **Left optic disc pallor**

   Monocular visual loss or a monocular scotoma can be caused by a lesion in any location anterior to the optic chiasm, including the eye, retina, or optic nerve (see KCC 11.2; Figure 11.15A,B). The afferent pupillary defect (see KCC 11.4, KCC 13.5) in the left eye also supports a lesion in these locations. On ophthalmoscopic exam, the eye and retina were unremarkable, but the left optic disc, which is the entrance point of the optic nerve to the retina (see Figure 11.1), appeared pale, suggesting that there had been a previous lesion in the left optic nerve.

   The most likely *clinical localization* is left optic nerve.
2. Given the patient's relatively young age, the improvement within a few weeks, and the characteristic central scotoma, the most likely diagnosis is optic neuritis of the left eye (KCC 11.4). Other possibilities include an ischemic lesion of the optic nerve caused by small-vessel disease (anterior ischemic optic neuropathy), but this is more common in older individuals with diabetes or hypertension. A neoplasm (meningioma, optic glioma, lymphoma, metastasis) or inflammatory process (sarcoid, Lyme disease) com-

pressing or infiltrating the optic nerve is possible, but these conditions do not usually improve spontaneously.

Clinical Course

Visual evoked potentials (see KCC 11.4) showed a latency of 104 ms in the right eye and 148 ms in the left eye (normal is less than 115 ms). An MRI scan showed no infiltrative or compressive lesions of the optic nerve; however, there were several areas of increased T2 signal in the periventricular regions of the brain, suggesting possible demyelination (see KCC 6.6). On further discussion with the patient, some important additional history came to light. Five years previously, he had had a similar episode of visual loss in the left eye that resolved spontaneously in a few weeks and likely represented a prior episode of optic neuritis. This previous episode may account for the optic pallor seen during the current episode, since this finding often takes time to develop. He also admitted to occasionally having tingling in the fingers of both hands, and to experiencing times when he felt his gait was uncoordinated. A prolonged discussion was held with the patient and family about possible multiple sclerosis (see KCC 6.6). The diagnosis of multiple sclerosis was eventually confirmed 2 years later, when he unfortunately developed diplopia, decreased sensation in the left arm and leg, gait unsteadiness, and urinary frequency. A repeat MRI scan showed a new T2 bright area in the right medulla, and a lumbar puncture was normal except for the presence of two oligoclonal bands (see KCC 5.10). The patient improved spontaneously within 5 days and was then enrolled in a program using beta interferon to treat relapsing remitting multiple sclerosis.

CASE 11.3 MENSTRUAL IRREGULARITY AND BITEMPORAL HEMIANOPIA

MINICASE

A 50-year-old woman went to an ophthalmologist because of several months of worsening vision that had begun to interfere with her driving. Past history was notable for **long-standing menstrual irregularity and infertility.** Exam was normal except for **decreased vision** primarily in the **temporal portions of the visual fields bilaterally** (Figure 11.20).

LOCALIZATION AND DIFFERENTIAL DIAGNOSIS

On the basis of the symptoms and signs shown in **bold** above, where is the lesion? What is the most likely diagnosis, and what are some other possibilities?

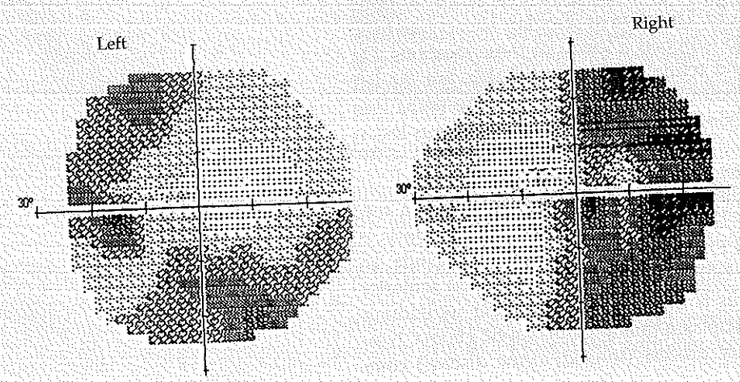

Figure 11.20 Visual Fields
Fields were evaluated by automated computerized perimetry.

Discussion

The key symptoms and signs in this case are:

- **Bitemporal hemianopia**
- **Long-standing menstrual irregularity and infertility**

Bitemporal hemianopia is usually caused by lesions of the optic chiasm (see KCC 11.2; Figure 11.15C). Note that in this patient, like many patients with optic chiasm lesions, the bitemporal hemiopia is not perfectly symmetrical. The history of a menstrual irregularity and infertility suggests an endocrine disorder, which further supports the diagnosis of a lesion in the vicinity of both the pituitary gland and the optic chiasm. The most likely diagnosis is a pituitary adenoma (see KCC 17.1). Other tumors or masses in the sellar and suprasellar region could also produce these abnormalities, including a meningioma, craniopharyngioma, optic or hypothalamic glioma, lymphoma, or sarcoid.

Clinical Course and Neuroimaging 450

A **brain MRI** (Figure 11.21) revealed a homogeneously enhancing mass in the suprasellar region, compressing the optic chiasm. Note that the mass had a "dural tail," suggesting that it arose from the meninges. The patient was referred to a neurosurgeon and was admitted for resection of the mass. The operative approach was through the right frontal and temporal bones. Cerebrospinal fluid was drained from the lumbar cistern, causing the lateral ventricles to collapse partly, thus making the frontal lobes easier to gently lift away from the tumor. The mass was seen to arise from the dura of the diaphragma sellae (see Figure 5.9) and the anterior sphenoid bone. All visible portions of the tumor were resected with careful preservation of the adjacent vasculature, optic nerves, and infundibular stalk. Pathologic sections revealed a meningioma. Following surgery the patient made an excellent recovery, with near complete return of vision in her lateral fields over the course of 6 to 7 months.

CASE 11.4 HEMIANOPIA AFTER TREATMENT FOR A TEMPORAL LOBE TUMOR

MINICASE

A 29-year-old man was referred to a neuro-ophthalmologist because of **worsening vision in his left visual fields.** Past history was notable for complex partial seizures for 5 or 6 years, beginning with an olfactory aura. One year ago an MRI revealed a left temporal lobe tumor. On resection, the tumor was found to be an oligoastrocytoma, and he was treated with chemotherapy and radiation therapy with an initially good response. Current exam was remarkable only for a **left homonymous hemianopia** (Figure 11.22).

LOCALIZATION AND DIFFERENTIAL DIAGNOSIS

On the basis of the symptoms and signs shown in **bold** above, where is the lesion? What is the most likely diagnosis, and what are some other possibilities?

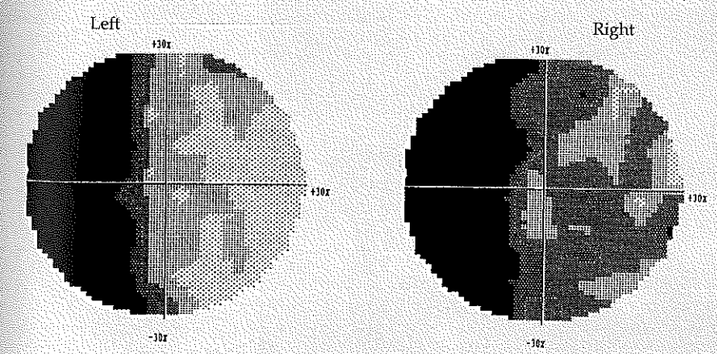

Figure 11.22 Visual Fields
Fields were evaluated by automated computerized perimetry.

Discussion

The key symptoms and signs in this case are:

- **Left homonymous hemianopia**

  A left homonymous hemianopia can be caused by a lesion anywhere in the right retrochiasmal visual pathways, including the optic tract, lateral geniculate nucleus, optic radiations, or primary visual cortex (see KCC 11.2; Figure 11.15D, G, H). Given the previous history of a tumor, the most likely diagnosis is a recurrence of the tumor involving one or more of these structures on the right side of the brain. Note that the original tumor was in the left temporal lobe, so we would have to propose recurrence in a region somewhat removed from the original resection. Other, less likely possibilities include delayed radiation-induced necrosis, hemorrhage, infarct, demyelination, or brain abscess.

Clinical Course and Neuroimaging 452

A **brain MRI** (Figure 11.23) revealed abnormal enhancement of the right optic tract, extending to the right lateral geniculate nucleus. The patient was admitted and treated with high-dose steroids with no significant improvement. His vision continued to deteriorate over the next 2 weeks, and he was readmitted for stereotactic biopsy of an enhancing area in the right temporal lobe, which showed malignant astrocytoma. Additional chemotherapy was tried, but he continued to worsen, developing progressive left hemiparesis, and he was ultimately transferred to a hospice for comfort care.

CASE 11.3 MENSTRUAL IRREGULARITY AND BITEMPORAL HEMIANOPIA

Figure 11.21 Brain MRI Showing a Meningioma of the Suprasellar Region Compressing the Optic Chiasm (A) Coronal T1-weighted image showing meningioma located just dorsal to the pituitary, and compressing the optic chiasm from below. (B) Sagittal T1-weighted image with intravenous gadolinium contrast enhancement, showing characteristic features of a meningioma, including relatively uniform contrast enhancement, location adjacent to the meninges, and a tapering extension along the dural surface ("dural tail"). As in (A), the tumor can be seen to compress the optic chiasm from below.

(A)

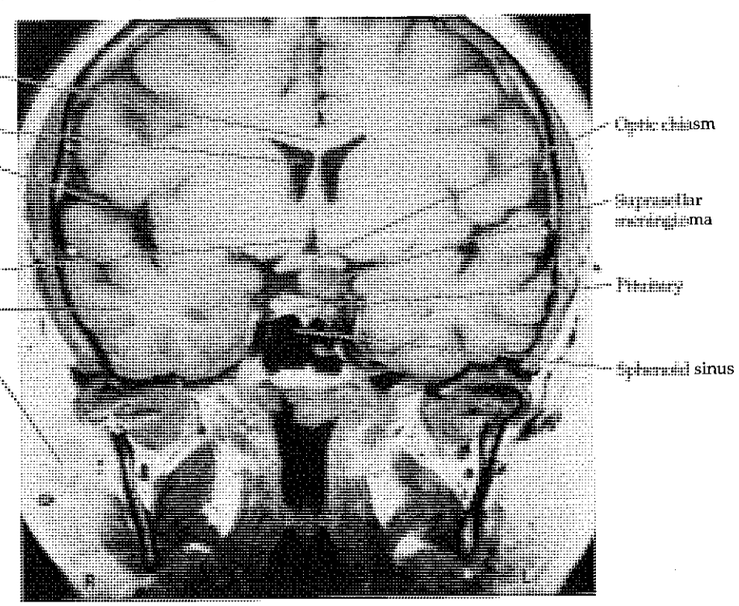

CASE 11.3 *(CONTINUED)*

(B)

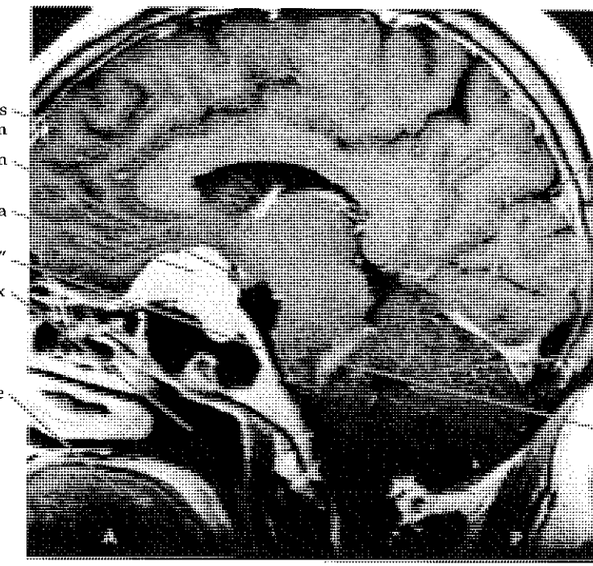

CASE 11.5 VISUAL CHANGES CAUSED BY MIGRAINE HEADACHES?

MINICASE

A 57-year-old right-handed man visited the emergency room several times because of headaches that had begun 4 months previously. He had **throbbing bilateral or right occipital pain, and zigzagging lines** in his field of vision. The headaches were often more severe in the afternoon, and they were relieved by nonsteroidal pain medication (naproxen). He had not previously had headaches of this kind, and he had no family history of migraines. Recently he noticed a vision problem causing him to frequently bump into objects on his left side. He was referred to a neurologist, and examination was normal except for a **left inferior quadrantanopia** (Figure 11.24). The examiner did not listen for a cranial bruit.

LOCALIZATION AND DIFFERENTIAL DIAGNOSIS

On the basis of the symptoms and signs shown in **bold** above, where is the lesion? What is the most likely diagnosis, and what are some other possibilities?

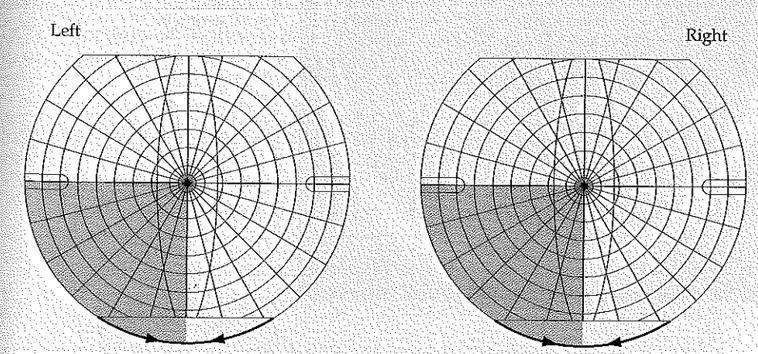

Figure 11.24 Visual Fields Fields were evaluated by confrontation testing by the examiner.

CASE 11.4 HEMIANOPIA AFTER TREATMENT FOR A TEMPORAL LOBE TUMOR

Figure 11.23 Brain MRI Showing a Tumor Involving the Right Optic Tract T1-weighted axial images with intravenous gadolinium contrast enhancement. (A) and (B) are adjacent sections progressing from inferior to superior.

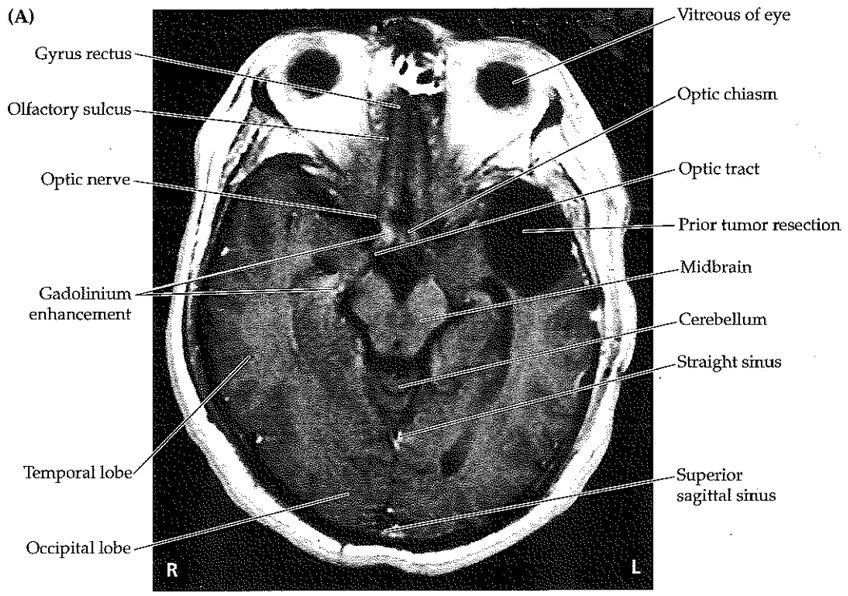

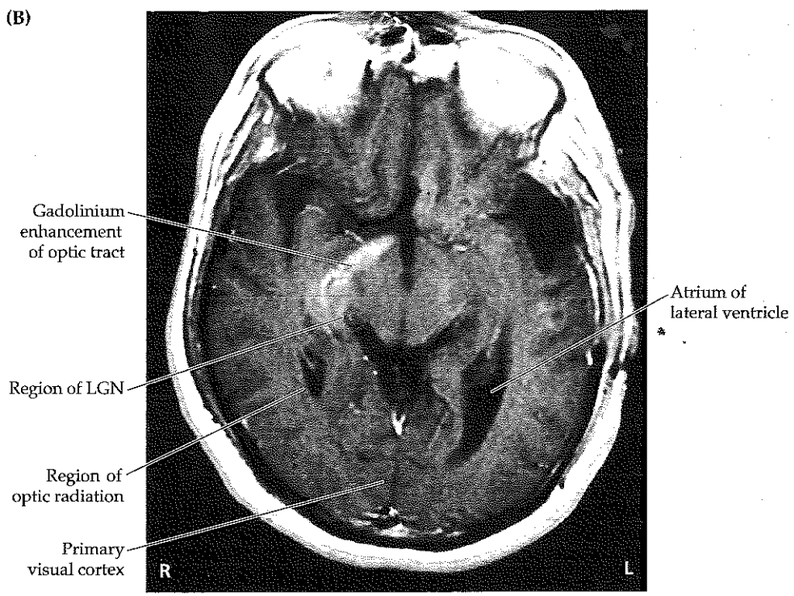

Discussion

The key symptoms and signs in this case are:

- **Left inferior homonymous quadrantanopia**
- **Right occipital headaches**

A left inferior homonymous quadrantanopia can be caused by a lesion of the right superior optic radiations or the right superior bank of the calcarine fissure (see Figure 11.15F, I). The right occipital headache also suggests a lesion in the right occipital area. The throbbing quality of the headache and the fortification scotoma with zigzagging lines are typical features of migraine headaches (see KCC 5.1). However, it would be unusual for a man in his late 50s, with no family history, suddenly to develop new-onset migraine. In addition, headache always occurring on the same side of the head is worrisome, and the fixed visual field defect suggests a more permanent deficit. Given his age, a brain tumor such as glioblastoma or brain metastasis should be considered first as the cause of his migrainelike headaches and visual field cut. Other possibilities include hemorrhage, infarct, or abscess. Of note, arteriovenous malformations (AVMs) can cause migraine headaches that recur in the same location (see KCC 5.1, 5.6). They can also cause hemorrhage, ischemia, or infarcts, resulting in focal deficits.

Clinical Course and Neuroimaging 454

A **brain MRI** (Figure 11.25) showed multiple dark flow voids, consistent with a large AVM involving the superior portions of the right occipital lobe. Note that the AVM was located predominantly above the calcarine fissure and therefore affected the contralateral inferior quadrant of the visual field (see Figure 11.15I). An **angiogram** was done to help guide therapy. On injection of the right carotid, the AVM was found to be fed by a large, tortuous, abnormal branch of the right MCA (Figure 11.26). Injection of the posterior circulation showed that it was also supplied by a similar abnormal branch of the right PCA (not shown). Numerous smaller branches supplied the AVM as well. It was decided that because of its large size and complicated vascular supply, the AVM was not amenable to treatment with surgery or embolization. The patient's headaches resolved spontaneously, and he remained stable when seen in follow-up over the next 4 years. This case should be compared to the visual field defect seen with a larger cortical lesion in Case 10.3.

Additional Cases

Related cases in other chapters: **localization of lesions in the visual pathways** (Cases 5.1, 5.2, 5.8, 10.3, 10.4, 10.6, 10.8, 10.10, 10.11, 14.8, 17.2, 19.2); **disorders of higher-order visual processing** (Cases 19.5, 19.6, 19.8, 19.9). Other relevant cases can be found using the **Case Index**.

Brief Anatomical Study Guide

1. This chapter covers the **visual pathways** from retina to optic nerve, to optic tract, to lateral geniculate nucleus of the thalamus, to optic radiations, to visual cortex (see Figure 11.15).
2. Throughout these pathways there are **three parallel channels** for processing information related to **motion/spatial analysis, form,** and **color** (see Figure 11.11).

CASE 11.5 VISUAL CHANGES CAUSED BY MIGRAINE HEADACHES?

Figure 11.25 Brain MRI Showing an Arteriovenous Malformation (AVM) in the Superior Bank of the Right Calcarine Cortex T1-weighted images. (A) Coronal section. (B) Sagittal section. Dark regions represent flow voids in the AVM.

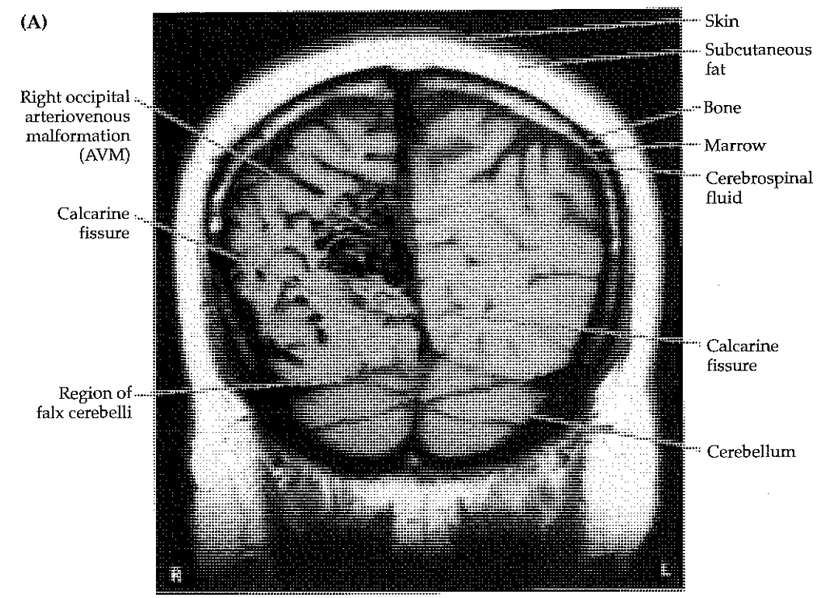

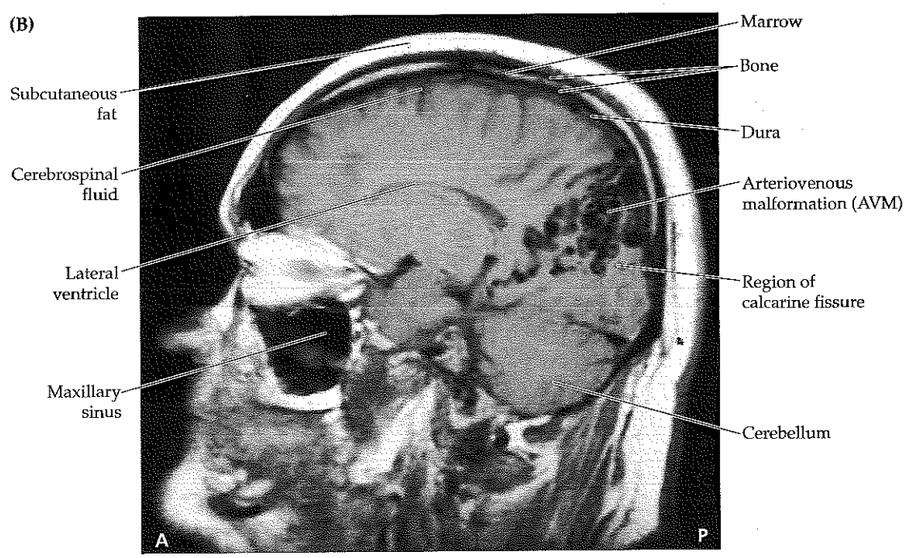

CASE 11.5 *(CONTINUED)*

Figure 11.26 Arteriovenous Malformation (AVM) in the Right Superior Occipital Cortex Cerebral angiogram, lateral view, following injection of the right internal carotid artery. The AVM can be seen to fill via abnormal branches of the right middle cerebral artery (MCA).

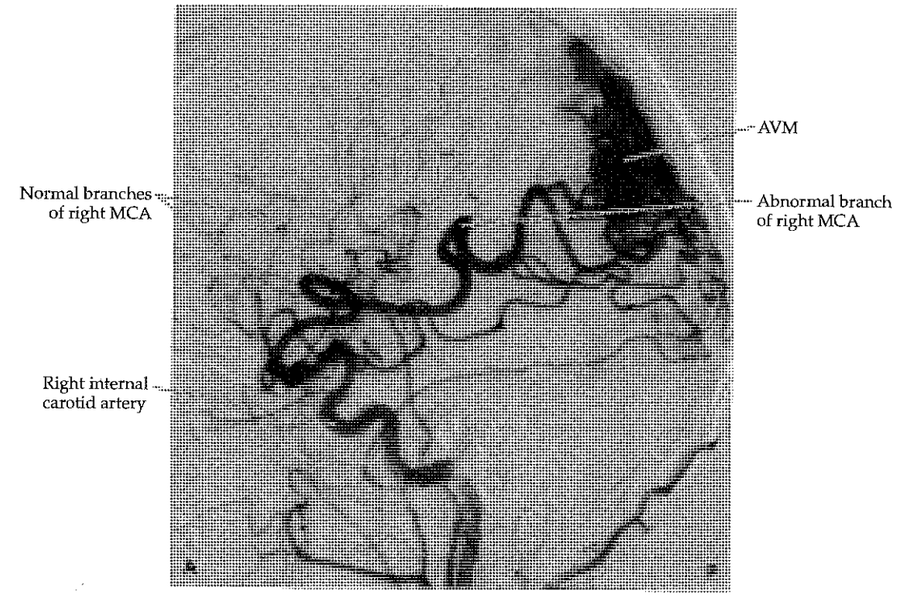

Brief Anatomical Study Guide *(continued)*

3. The **retina** (see Figure 11.4) has several different cell types, including photoreceptor **rods,** which are more sensitive to low levels of illumination; **cones,** which have higher spatial and temporal resolution and detect colors; and **ganglion cells,** which form the output layer of the retina.
4. Most retinal ganglion cells can be classified as M cells or P cells. **M cells** have large receptive fields, respond best to gross stimulus features and movement, and project to the **magnocellular layers** of the lateral geniculate nucleus. **P cells** are more numerous, have small receptive fields, are sensitive to fine visual detail and colors, and project to the **parvocellular layers** of the lateral geniculate nucleus.
5. The **lateral geniculate nucleus (LGN)** has six layers (see Figure 11.7), with inputs from each eye segregated in different layers. These segregated inputs are preserved in projections to **layer 4** of the **primary visual cortex (area 17),** forming **ocular dominance columns** (see Figure 11.12A).

Brief Anatomical Study Guide *(continued)*

6. Information processing by **visual association cortex (areas 18 and 19)** and **higher-order association cortex** takes place via a **dorsal "where?" stream** dedicated to analysis of motion and spatial relations and a **ventral "what?" stream** involved in analysis of form and color (see Figure 11.11B).

7. Lesions in the primary visual pathways produce characteristic **visual field defects** (see Figure 11.15). Lesions anterior to the optic chiasm produce monocular defects (see Figures 11.15A, 11.16A, 11.17A). In the optic chiasm the nasal fibers for each eye, carrying visual information from the lateral (temporal) visual hemifields, cross to the opposite side. Therefore, visual pathways posterior to the optic chiasm carry information from both eyes corresponding to the contralateral visual field. Lesions of the optic tract (see Figure 11.15D), lateral geniculate nucleus, optic radiations (see Figure 11.8), or visual cortex therefore cause contralateral homonymous ("same named") visual field defects affecting both eyes (see Figures 11.15D–J, 11.16B,C). Lesions of the optic chiasm itself produce bitemporal (bilateral lateral) visual field defects (see Figure 11.15C). Understanding the basic anatomy of visual pathways is essential in clinical diagnosis and differentiation of eye disorders and lesions of the central nervous system.

References

General References

Kandel ER, Schwartz JH, Jessell TM. 2000. *Principles of Neural Science*, 4th Ed. McGraw Hill, New York, Chapters 25–29.

Newman NM. 1992. The visual afferent pathways: Anatomic considerations. In *Neuro-Ophthalmology: A Practical Text*, Chapter 1. Appleton & Lange, Norwalk, CT.

Wray SH. 1998. Neuro-ophthalmologic diseases. In Rosenberg RN, Pleasure DE (eds.), *Comprehensive Neurology*, 2nd Ed. Chapter 19. Raven, New York.

Retinal Artery Occlusion

Biousse V. 1997. Carotid disease and the eye. *Curr Opin Ophthalmol* 8(6): 16–26.

Burde RM. 1989. Amaurosis fugax. *J Clin Neuroophthalmol* 9(3): 185–189.

Feinberg AW. 1992. The evaluation of amaurosis fugax. *Hosp Pract (Off Ed)* 27(4A): 47–57.

Karjalainen K. 1971. Occlusion of the central retinal artery and branch arterioles: A clinical, tonographic and fluorescein angiographic study of 175 patients. *Acta Ophthalmol Suppl* 109: 1–95.

Oshinskie L. 1987. Branch retinal artery occlusion and carotid artery stenosis. *Am J Optom Physiol Optics* 64(2): 144–149.

Sharma S. 1998. The systemic evaluation of acute retinal artery occlusion. *Curr Opin Ophthalmol* 9(3): 1–5.

Tomsak RL, Hanson M, Gutman FA. 1979. Carotid artery disease and central retinal artery occlusion. *Cleve Clin Q* 46(1): 7–11.

Optic Neuritis

Cornblath WT, Quint DJ. 1997. MRI of optic nerve enlargement in optic neuritis. *Neurology* 48(4): 821–825.

Merandi SF, Kudryk BT, Murtagh FR, Arrington JA. 1991. Contrast-enhanced MR imaging of optic nerve lesions in patients with acute optic neuritis. *Am J Neuroradiol* 12(5): 923–926.

Nikoskelainen E. 1975. Symptoms, signs and early course of optic neuritis. *Acta Ophthalmol* 53(2): 254–272.

Purvin V. 1998. Optic neuritis. *Curr Opin Ophthalmol* 9(6): 3–9.

Optic Nerve Injury Due to Orbital Trauma

Steinsapir KD, Goldberg RA. 1994. Traumatic optic neuropathy. *Survey Ophthalmol* 38(6): 487–518.

Suprasellar Meningioma

Ehlers N, Malmros R. 1973. The suprasellar meningioma. A review of the literature and presentation of a series of 31 cases. *Acta Ophthalmol Suppl* 1–74.

Optic Tract Lesions

Savino PJ, Paris M, Schatz NJ, Orr LS, Corbett JJ. 1978. Optic tract syndrome. *Arch Ophthalmol* 96(4): 656–663.

Lateral Geniculate Nucleus Lesions

Acheson JF, Sanders MD. 1997. *Common Problems in Neuro-Ophthalmology*. Saunders, London.

Miller NR. 1985. *Walsh and Hoyt's Clinical Neuro-ophthalmology*, 4th Ed., Vol. 2. Williams & Wilkins, Baltimore, MD.

Optic Radiation and Visual Cortex Lesions

Adams RD, Victor M, Ropper AH. 1997. *Principles of Neurology*, 6th Ed. McGraw-Hill, New York, Chapter 13.

CHAPTER 12

Brainstem I: Surface Anatomy and Cranial Nerves

ANATOMICAL AND CLINICAL REVIEW
Surface Features of the Brainstem
Skull Foramina and Cranial Nerve Exit Points
Sensory and Motor Organization of the Cranial Nerves
Functions and Course of the Cranial Nerves
CN I: Olfactory Nerve
KCC 12.1 Anosmia (CN I)
CN II: Optic Nerve
CN III, IV, and VI: Oculomotor, Trochlear, and Abducens Nerves
CN V: Trigeminal Nerve
KCC 12.2 Trigeminal Nerve Disorders (CN V)
CN VII: Facial Nerve
KCC 12.3 Facial Nerve Lesions (CN VII)
KCC 12.4 Corneal Reflex and Jaw Jerk Reflex (CN V, VII)
CN VIII: Vestibulocochlear Nerve
KCC 12.5 Hearing Loss (CN VIII)
KCC 12.6 Dizziness and Vertigo (CN VIII)
CN IX: Glossopharyngeal Nerve
CN X: Vagus Nerve
CN XI: Spinal Accessory Nerve
CN XII: Hypoglossal Nerve
KCC 12.7 Disorders of CN IX, X, XI, and XII
KCC 12.8 Hoarseness, Dysarthria, Dysphagia, and Pseudobulbar Affect
Review: Cranial Nerve Combinations

CLINICAL CASES
12.1 Anosmia and Visual Impairment
12.2 Cheek Numbness and a Bulging Eye
12.3 Jaw Numbness and Episodes of Loss of Consciousness
12.4 Isolated Facial Weakness
12.5 Hearing Loss and Dizziness
12.6 Hoarse Voice Following Cervical Disc Surgery
12.7 Hoarseness, with Unilateral Wasting of the Neck and Tongue Muscles
12.8 Uncontrollable Laughter, Dysarthria, Dysphagia, and Left-Sided Weakness
Additional Cases

BRIEF ANATOMICAL STUDY GUIDE

A 41-year-old woman noticed that she could not hear anything when the phone receiver was on her left ear. Also, over the previous year, she sometimes felt as though the room was spinning slightly when she moved her head. She developed some pain on the left side of her face and decreased taste on the left side of her tongue, as well as a decreased corneal reflex on the left side. This patient illustrates the complex variety of abnormalities that patients with cranial nerve disorders may experience. In this chapter, we will learn about the origins of cranial nerves in the brainstem, their courses to the periphery, and their various functions.

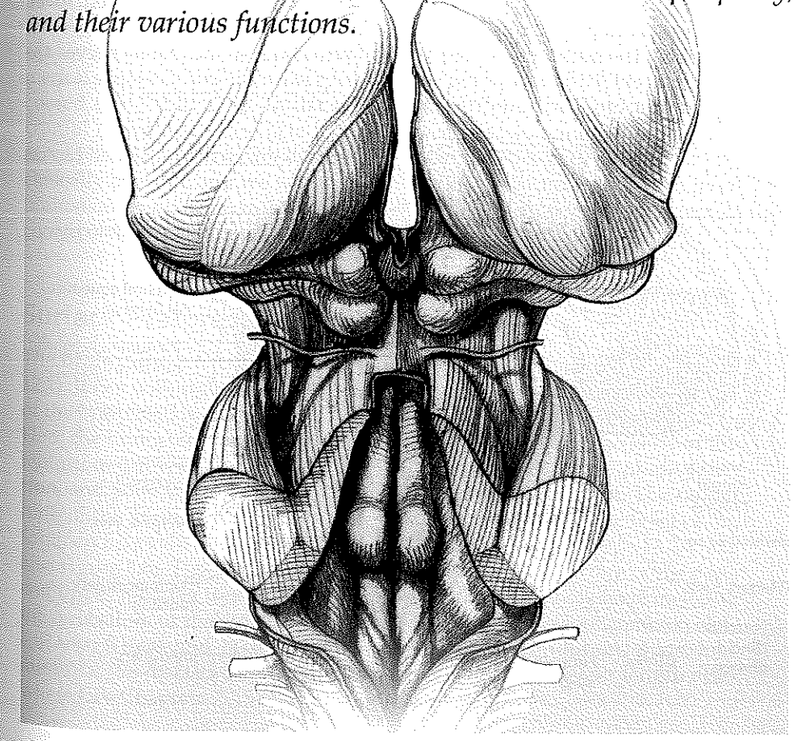

ANATOMICAL AND CLINICAL REVIEW

Located at the base of the cerebral hemispheres, the **brainstem** is a compact, stalklike structure that carries nearly all information between the brain and the remainder of the body (Figure 12.1). This tight space is the corridor to all major sensory, motor, cerebellar, and cranial nerve pathways. However, the brainstem is not simply a conduit for information. It also contains numerous important nuclei of its own, which control the cranial nerves, level of consciousness, cerebellar circuits, muscle tone, posture, and cardiac, respiratory, and numerous other essential functions. If the brain were a city, then the brainstem would be both the Grand Central Station and Central Power Supply packed into one location. Thus, small lesions in the brainstem can result in substantial deficits, often involving multiple motor, sensory, and neuroregulatory modalities.

An intimate knowledge of brainstem anatomy is a powerful clinical tool. Armed with an understanding of brainstem nuclei and pathways, the clinician can intelligently decide on appropriate diagnostic and therapeutic measures for patients with brainstem disorders. Brainstem anatomy is so complex yet so clinically relevant that we have devoted three full chapters (Chapters 12 through 14) to understanding it in detail. Thus, in this chapter we will first review the surface features of the brainstem and then discuss the course and functions of each cranial nerve. Next, in Chapter 13 we will focus in greater detail on the cranial nerves and central pathways mediating eye movements and pupillary control. Finally, in Chapter 14 we will study the vascular supply and internal structures of the brainstem, including the major ascending and descending tracts, reticular formation, and other important brainstem nuclei.

Learning the cranial nerves initially requires some memorization. Over time, however, they become very familiar because of their important clinical relevance. The numbers, names, and main functions of the cranial nerves are

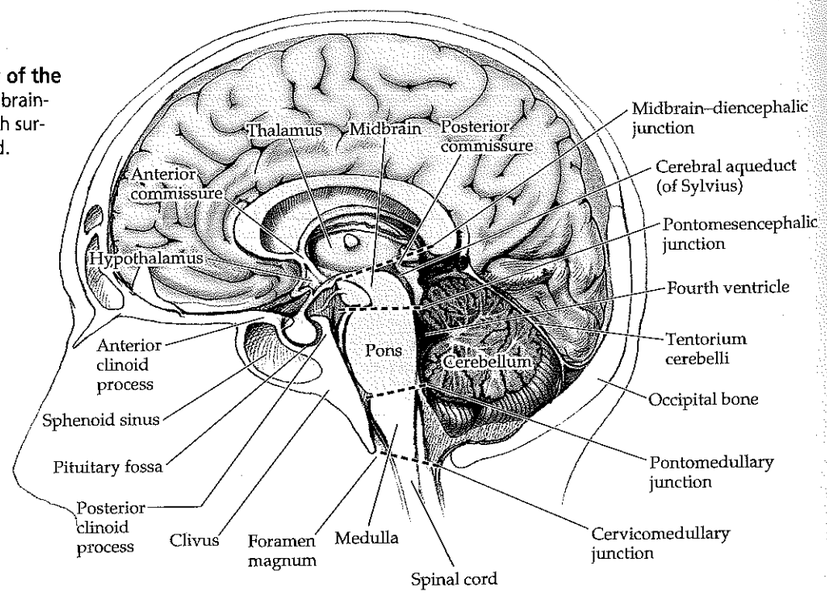

Figure 12.1 Midsagittal View of the Brainstem In Situ Parts of the brainstem and spatial relationships with surrounding structures are illustrated.

TABLE 12.1 Cranial Nerve Names and Main Functions

CN	NAME	MAIN FUNCTION(S)
CN I	Olfactory nerve	Olfaction
CN II	Optic nerve	Vision
CN III	Oculomotor nerve	Eye movements; pupil constriction
CN IV	Trochlear nerve	Eye movements
CN V	Trigeminal nerve	Facial sensation; muscles of mastication
CN VI	Abducens nerve	Eye movements
CN VII	Facial nerve	Muscles of facial expression; taste; lacrimation; salivation
CN VIII	Vestibulocochlear nerve	Hearing; equilibrium sense
CN IX	Glossopharyngeal nerve	Pharyngeal muscles; carotid body reflexes; salivation
CN X	Vagus nerve	Parasympathetics to most organs; laryngeal muscles (voice); pharyngeal muscles; aortic arch reflexes
CN XI	Spinal accessory nerve	Head turning (trapezius and sternomastoid muscles)
CN XII	Hypoglossal nerve	Tongue movement

listed in Table 12.1. Note that the cranial nerves have both sensory and motor functions. To learn the cranial nerves and their functions, two different review strategies are useful. In one, the **cranial nerves** are listed in numerical sequence and the sensory and motor functions of each nerve are discussed (see Table 12.4). In the second, the different sensory and motor **cranial nerve nuclei** are listed, and the functions and cranial nerves subserved by each nucleus are discussed (see Table 12.3). Both approaches are clinically relevant, and we will use both strategies at various points in these brainstem chapters to integrate knowledge of the peripheral and central course of the cranial nerves.

REVIEW EXERCISE

Cover the two right columns in Table 12.2. For each numbered cranial nerve, provide its name and main functions.

Surface Features of the Brainstem

The **brainstem** consists of the **midbrain, pons, and medulla** (see Figure 12.1). It lies within the posterior fossa of the cranial cavity. The rostral limit of the brainstem is the **midbrain–diencephalic junction** (see Figure 12.1). Here the brainstem meets thalamus and hypothalamus at the level of the tentorium cerebelli. Midbrain joins pons at the **pontomesencephalic junction,** and pons meets medulla at the **pontomedullary junction.** The caudal limit of the brainstem is the **cervicomedullary junction,** at the level of the foramen magnum and pyramidal decussation (see Figures 12.1, 12.2A; see also Figure 6.8). The cerebellum is attached to the dorsal surface of the pons and upper medulla (see Figure 12.1). Although some authors have included the cerebellum or thalamus in the term "brainstem," we adopt common clinical usage here and take brainstem to imply only midbrain, pons, and medulla. We discuss the thalamus and cerebellum at greater length elsewhere (see Chapters 7, 15).

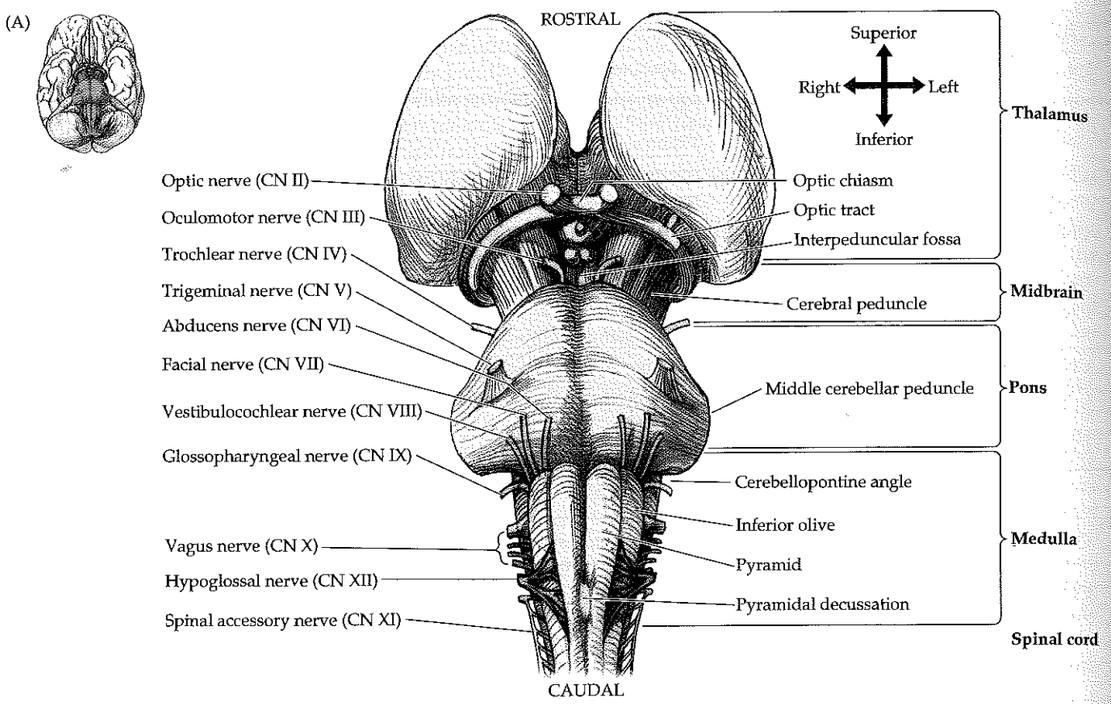

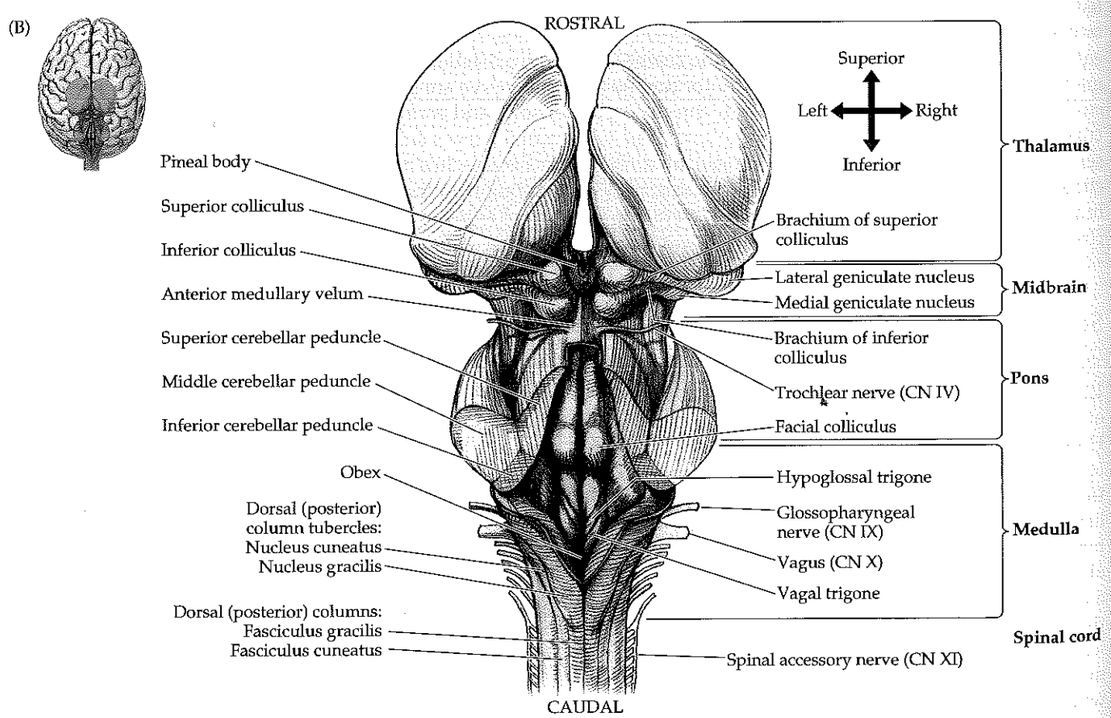

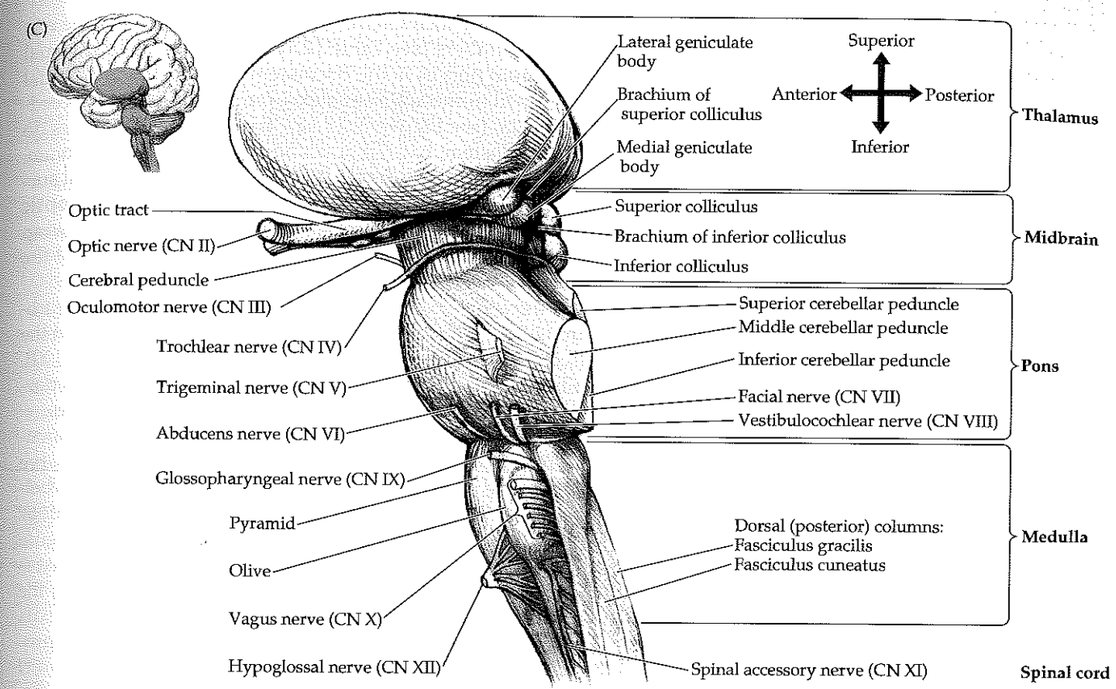

Figure 12.2 Surface Anatomy of the Brainstem and Cranial Nerves
(A) Ventral view with cerebral hemispheres removed. (B) Dorsal view with cerebellum removed, exposing floor of the fourth ventricle. (C) Lateral view.

On the dorsal surface of the **midbrain** are two pairs of bumps called the **superior colliculi** and **inferior colliculi** (see Figure 12.2B). Together, these form the **tectum** (meaning "roof") of the midbrain. The ventral surface of the midbrain is formed by the **cerebral peduncles,** between which the **interpeduncular fossa** lies (see Figure 12.2A; see also Figure 5.6). The **pons** is limited dorsally by the **fourth ventricle** (see Figure 12.1). More dorsolaterally, the pons is attached to the cerebellum by large white matter tracts called the **superior, middle, and inferior cerebellar peduncles** (see Figure 12.2B). On the ventral surface of the **medulla,** the **pyramids** can be seen descending from the pontomedullary junction to the **pyramidal decussation** (see Figure 12.2A). It is often useful to divide the medulla into a rostral and a caudal portion. In the **rostral medulla** the prominent bulges of the **inferior olivary nuclei** can be seen just lateral to the pyramids (see Figure 12.2A). In the **caudal medulla** the inferior olivary nuclei are no longer seen, but the **posterior columns** and **posterior column nuclei** are visible on the dorsal surface (see Figure 12.2B).

The floor of the fourth ventricle extends from the pons to the rostral half of the medulla. Along the floor of the fourth ventricle, several bumps are visible. These include the **facial colliculi,** formed by the abducens nuclei and fibers of the facial nerve (see Figure 12.2B; see also Figure 14.1F). The **hypoglossal trigone** and **vagal trigone** (see Figure 12.2B) are formed by the hypoglossal nucleus (CN XII) and the dorsal motor nucleus of CN X, respectively. Recall that rostrally the fourth ventricle joins the cerebral aqueduct, which runs through the midbrain (see Figure 12.1). Caudally the fourth ventricle drains into the subarachnoid space via the foramina of Luschka (located laterally) and foramen of Magendie (located in the midline). The fourth ventricle ends caudally at the **obex** (see Figure 12.2B), marking the entry to the spinal cord central canal, which in adults is normally closed.

For those who are verbally inclined, several mnemonics exist for the cranial nerve names and numbers (see Table 12.1). However, the best visual mnemonic for the cranial nerves is the brainstem itself, since the cranial nerves emerge roughly in numerical sequence from I through XII proceeding from rostral to caudal (see Figure 12.2). The first two cranial nerves do not emerge from the brainstem, but rather connect directly to the forebrain. The **olfactory bulbs** and **olfactory tracts** (**CN I**) run along the ventral surface of the frontal lobes in the **olfactory sulci** (see Figure 18.6). The **optic nerves** (**CN II**) meet at the optic chiasm, forming the optic tracts, which wrap laterally around the midbrain to enter the lateral geniculate nuclei of the thalamus (see Figures 11.6, 11.15).

Cranial nerves III through XII exit the brainstem either ventrally or ventrolaterally (see Figure 12.2A,C). The one exception is CN IV, which exits from the dorsal midbrain (see Figure 12.2B). We will see shortly that CN III, VI, and XII, which exit ventrally near the midline, together with CN IV, which exits dorsally, form a distinct functional group innervating somatic motor structures.

The **oculomotor nerves** (**CN III**) emerge ventrally from the interpeduncular fossa of the midbrain (see Figure 12.2A). Note that the oculomotor nerve usually passes between the posterior cerebral artery and the superior cerebellar artery (see Figure 14.17A). As we have just mentioned, the **trochlear nerve** (**CN IV**) is exceptional in exiting dorsally from the midbrain (see Figure 12.2B). The fibers of CN IV cross over as they emerge, an arrangement that is also unique to this cranial nerve. The **trigeminal nerve** (**CN V**) exits from the ventrolateral pons (see Figure 12.2A,C). The **abducens nerve** (**CN VI**) exits ventrally, at the pontomedullary junction (see Figure 12.2A,C). Then, proceeding in sequence, the **facial nerve** (**CN VII**), **vestibulocochlear nerve** (**CN VIII**), **glossopharyngeal nerve** (**CN IX**), and **vagus nerve** (**CN X**), exit ventrolaterally from the pontomedullary junction and rostral medulla. The region where CN VII, VIII, and IX exit the brainstem is called the **cerebellopontine angle.** The **spinal accessory nerve** (also known as the **accessory spinal nerve**) (**CN XI**) arises laterally from multiple rootlets along the upper cervical spinal cord. The **hypoglossal nerve** (**CN XII**) exits the medulla ventrally, between the pyramids and inferior olivary nuclei (see Figure 12.2A).

REVIEW EXERCISE

Cover the labels on the left side of Figure 12.2A. For each cranial nerve, state the cranial nerve number and name. Next, cover the remaining labels in Figure 12.2 A–C and name as many structures as possible.

Skull Foramina and Cranial Nerve Exit Points

When we discuss each cranial nerve in the sections that follow, we will describe its course in detail. For now, we will simply introduce the foramina through which the cranial nerves exit the skull (Figure 12.3; Table 12.2).

The olfactory nerves exit via the **cribriform plate,** and the optic nerve via the **optic canal** (see Figure 12.3; Table 12.2). The **superior orbital fissure** transmits several nerves (CN III, IV, VI, and V_1) into the orbit (see Figure 12.3A, C). CN III, IV, and VI mediate eye movements. The ophthalmic division of CN V (CN V_1) conveys sensation for the eye and upper face. The maxillary (CN V_2) and mandibular (CN V_3) divisions of the trigeminal nerve exit via the **foramen rotundum** and **foramen ovale,** respectively, providing sensation to the remainder of the face (see Figure 12.7). CN VII and VIII both exit the cranial cavity via the **internal auditory meatus** to enter the **auditory canal.** CN VIII innervates the inner ear deep within the temporal bone. CN VII exits the skull to reach the muscles of facial expression via the **stylomastoid foramen** (see Figure 12.3B). The **jugular foramen** transmits CN IX, X, and XI (see Figure 12.3A,B). Finally, the hypoglossal nerve (CN XII), controlling tongue movements, exits the skull via its own foramen, the **hypoglossal canal,** which lies just in front of the foramen magnum.

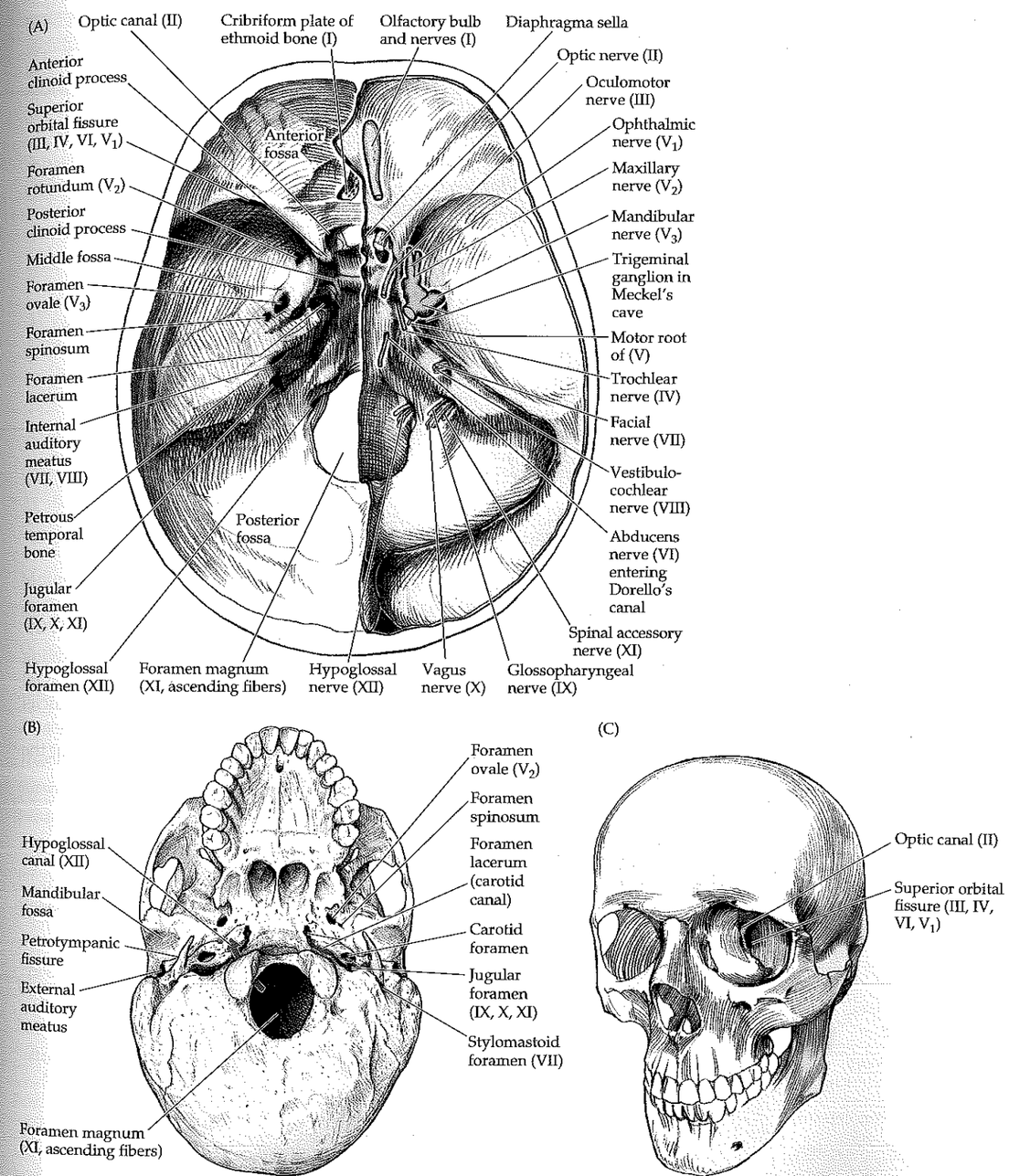

Figure 12.3 Skull Foramina Serving as Cranial Nerve Exit Points (A) Inside view of the base of the skull, seen from above, with cranial nerves shown on the right and exit foramina shown on the left. (B) View of the base of the skull, seen from below. (C) Anterior view of the skull and foramina.

REVIEW EXERCISE

Cover the right column in Table 12.2. Name the exit foramina for each cranial nerve (see Figure 12.3).

TABLE 12.2 Cranial Nerve Exit Foramina

CN	NAME	EXIT FORAMEN
CN I	Olfactory nerves	Cribriform plate
CN II	Optic nerve	Optic canal
CN III	Oculomotor nerve	Superior orbital fissure
CN IV	Trochlear nerve	Superior orbital fissure
CN V	Trigeminal nerve	V_1: Superior orbital fissure
		V_2: Foramen rotundum
		V_3: Foramen ovale
CN VI	Abducens nerve	Superior orbital fissure[a]
CN VII	Facial nerve	Auditory canal (stylomastoid foramen)
CN VIII	Vestibulocochlear nerve	Auditory canal
CN IX	Glossopharyngeal nerve	Jugular foramen
CN X	Vagus nerve	Jugular foramen
CN XI	Spinal accessory nerve	Jugular foramen (*enters* skull via foramen magnum)
CN XII	Hypoglossal nerve	Hypoglossal foramen (canal)

[a] The abducens nerve first exits the dura through Dorello's canal (see Figure 12.3) and travels a long distance before exiting the skull at the superior orbital fissure.

Sensory and Motor Organization of the Cranial Nerves

The cranial nerves are analogous in some ways to the spinal nerves, having both sensory and motor functions. Also like the spinal cord, motor cranial nerve nuclei are located more ventrally, while sensory cranial nerve nuclei are located more dorsally (Figure 12.4). However, cranial nerve sensory and motor functions are more specialized because of the unique anatomy of the

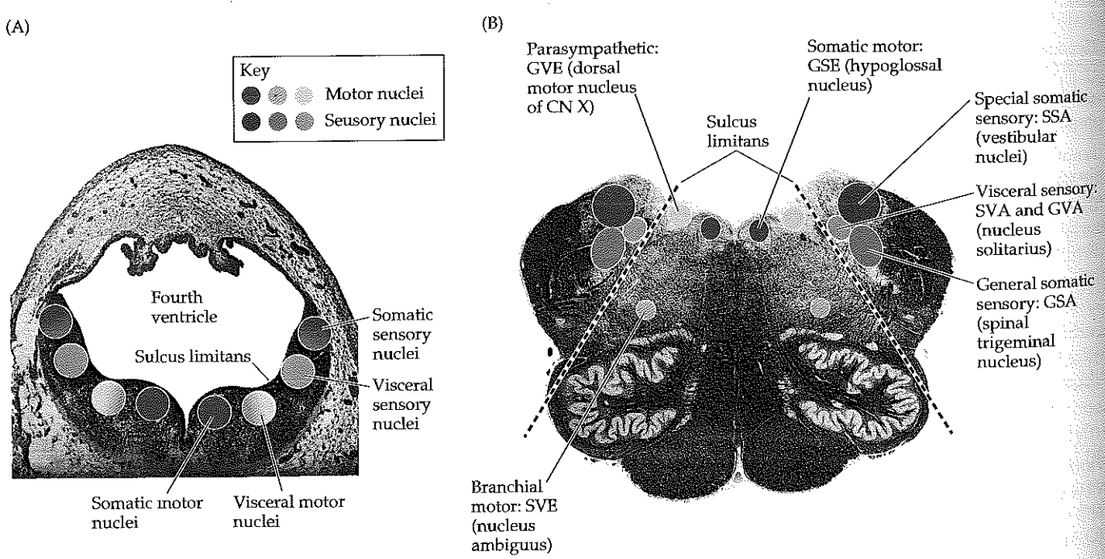

Figure 12.4 Development of Cranial Nerve Nuclei Sensory and Motor Longitudinal Columns (A) Cross section of human myelencephalon at 45 days showing locations of sensory and motor cranial nerve nuclei functional columns. (B) Adult medulla, with locations of functional columns indicated. Examples of the nuclei in these columns for a section at this level are indicated in parentheses. (A after Tuchman-Duplessis H., Auroux M., and Haegel P. 1974. *Illustrated Human Embryology.* Volume 3. *Nervous System and Endocrine Glands.* Masson & Company, Paris. B after Martin JH. 1996. *Neuroanatomy: Text and Atlas,* 2nd Ed. McGraw-Hill, New York.)

head and neck. During embryological development, the cranial nerve nuclei lie adjacent to the ventricular system (see Figure 12.4A). As the nervous system matures, **three motor columns** and **three sensory columns** of cranial nerve nuclei develop that run in an interrupted fashion through the length of the brainstem (see Figures 12.4, 12.5). Each column subserves a different motor or sensory cranial nerve function, which can be classified as shown in Table 12.3. The color codes for each column used in Figures 12.4 and 12.5 and in Table 12.3 will be preserved throughout this chapter. Let's review each of these columns in more detail, moving from medial to lateral.

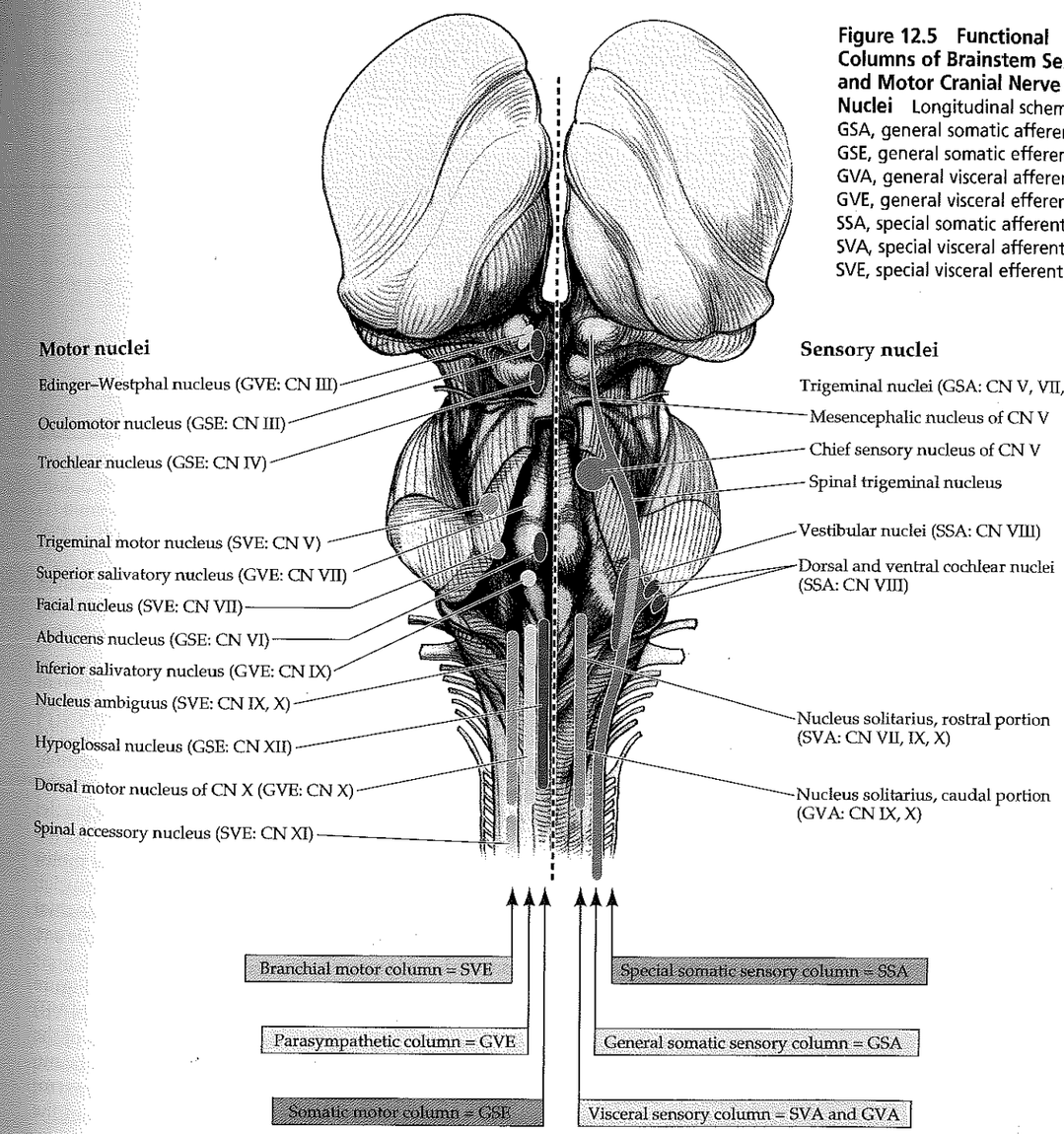

Figure 12.5 Functional Columns of Brainstem Sensory and Motor Cranial Nerve Nuclei Longitudinal schematic. GSA, general somatic afferent; GSE, general somatic efferent; GVA, general visceral afferent; GVE, general visceral efferent; SSA, special somatic afferent; SVA, special visceral afferent; SVE, special visceral efferent.

TABLE 12.3 Classification of Cranial Nerve Nuclei into Motor and Sensory Columns

CLASSIFICATION	FUNCTION(S)	BRAINSTEM NUCLEI	CRANIAL NERVE(S)
MOTOR			
Somatic motor (general somatic efferent)	Extraocular muscles, intrinsic tongue muscles	Oculomotor, trochlear, abducens, and hypoglossal	CN III, IV, VI, XII
Branchial motor (special visceral efferent)	Muscles of mastication, facial expression, middle ear, pharynx, larynx, sternomastoid, upper portion of trapezius	Motor nucleus of CN V Facial nucleus Nucleus ambiguus Accessory spinal nucleus	CN V CN VII CN IX, X CN XI
Parasympathetic (general visceral efferent)	Parasympathetic innervation of head and thoracoabdominal viscera above splenic flexure	Edinger–Westphal nucleus Superior salivatory nucleus Inferior salivatory nucleus Dorsal motor nucleus of CN X	CN III CN VII CN IX CN X
SENSORY			
Visceral sensory (special visceral afferent)	Taste	Nucleus solitarius (rostral portion, gustatory nucleus)	CN VII, IX, X
(general visceral afferent)	Inputs for control of cardiorespiratory and digestive function	Nucleus solitarius (caudal portion, cardiorespiratory nucleus)	CN IX, X
General somatic sensory (general somatic afferent)	Touch, pain, temperature, position, and vibration sense for face, sinuses, and meninges	Trigeminal nuclei	CN V, VII, IX, X
Special somatic sensory (special somatic afferent)	Olfaction, vision, hearing, vestibular sensation (olfaction and vision do not have sensory nuclei in the brainstem)	Cochlear nuclei, vestibular nuclei	CN VIII

The **somatic motor nuclei** are the oculomotor (CN III), trochlear (CN IV), abducens (CN VI), and hypoglossal (CN XII) nuclei, all of which remain adjacent to the midline (see Figures 12.4, 12.5; Table 12.3). These nuclei send their fibers to exit the brainstem close to the midline as well (see Figure 12.2). The somatic motor nuclei innervate the extraocular and intrinsic tongue muscles, which are derived embryologically from the **occipital somites.**

The **visceral motor nuclei** (see Figure 12.4A) separate into two different columns of nuclei: branchial motor nuclei and parasympathetic nuclei (see Table 12.3). The **branchial motor nuclei** are the trigeminal motor nucleus (CN V), facial nucleus (CN VII), nucleus ambiguus (CN IX, X), and spinal accessory nucleus (CN XI) (see Table 12.3). During development, the branchial motor nuclei initially lie just lateral to the somatic motor nuclei (see Figure 12.4A), but they gradually migrate ventrolaterally into the tegmentum (see Figures 12.4B, 12.5). Both the somatic and branchial motor nuclei innervate *striated muscles.* However, unlike the somatic motor nuclei, the **branchial motor nuclei** innervate muscles derived from the **branchial arches,** including the muscles of mastication, facial expression, middle ear, pharynx, larynx, sternomastoid, and upper portion of the trapezius.

The next column comprises the **parasympathetic nuclei** (see Figure 12.5). These are the Edinger–Westphal nucleus (CN III), superior (CN VII) and inferior (CN IX) salivatory nuclei, and the dorsal motor nucleus of the vagus (CN X) (see Table 12.3; see also Figure 12.6). The parasympathetic nuclei do not innervate striated muscle. They provide preganglionic parasympathetic fibers innervating *glands, smooth muscle, and cardiac muscle* of the

head, heart, lungs, and digestive tract above the splenic flexure (see also Figure 6.13).

Continuing laterally, the sensory nuclei also form three columns (see Figures 12.4, 12.5). The **visceral sensory column** contains a single nucleus, the nucleus solitarius, which has two parts. The rostral nucleus solitarius, or gustatory nucleus, receives taste inputs from primarily CN VII, but also CN IX and X. The caudal nucleus solitarius, or cardiorespiratory nucleus, receives inputs for regulation of cardiac, respiratory, and gastrointestinal function from CN IX and X (see Table 12.3). As discussed in Chapter 14, the nucleus solitarius has other functions as well, such as sleep regulation.

The **general somatosensory nuclei,** or **trigeminal nuclei** (see Table 12.3; Figures 12.4, 12.5), mediate touch, pain, temperature, position, and vibration sense for the face, sinuses, and meninges. As we will see, sensory inputs to the trigeminal sensory nuclei are mostly from the trigeminal nerve (CN V), but there are also smaller sensory inputs from CN VII, IX, and X (see Figure 12.7B).

By definition, the **special senses** are olfaction, vision, hearing, vestibular sense, and taste. Olfaction and vision do not have their primary sensory nuclei in the brainstem. The brainstem **special somatic sensory nuclei** are the cochlear nuclei mediating hearing (CN VIII) and the vestibular nuclei mediating positional equilibrium (CN VIII) (see Figures 12.4, 12.5; Table 12.3). Note that although taste is one of the special senses, it has been classified here in the visceral sensory column (nucleus solitarius).

In another commonly used classification scheme, which we will occasionally use as well, cranial nerve functions are referred to as either general or special, somatic or visceral, and afferent or efferent. Combinations of these terms result in a total of eight categories, such as general somatic efferent (GSE), special visceral afferent (SVA), and so on (see Table 12.3). However, this scheme still results in the same six longitudinal columns of nuclei (three motor, three sensory) described above (see Figure 12.5). The reasons are that (1) there are no special somatic efferent (SSE) nuclei, and (2) the nucleus solitarius contains both the special and general visceral afferents.

Note that most cranial nerve nuclei project to or receive inputs from predominantly one cranial nerve (see Table 12.3). The three exceptions can be remembered with the mnemonic **SAT** for **S**olitarius, **A**mbiguus, and **T**rigeminal, all of which are long nuclei extending into the medulla (see Figure 12.5).

MNEMONIC

REVIEW EXERCISE

Draw a sketch of the brainstem as in Figure 12.5. Fill in the three columns of motor nuclei and three columns of sensory nuclei. For each nucleus, state its name as well as the cranial nerves that it supplies (see Figure 12.5; Table 12.3). You should be able to draw this sketch from memory.

Functions and Course of the Cranial Nerves

In the sections that follow we will review each of the cranial nerves and their functions in detail. Table 12.4 lists the motor and sensory functions of each cranial nerve. Note that some cranial nerves are **purely motor** (CN III, IV, VI, XI, XII), some are **purely sensory** (CN I, II, VIII), and some have **both motor and sensory** functions (CN V, VII, IX, X). The information contained in Table 12.4 is of central importance to understanding the cranial nerves and should be very familiar to you by the time you complete this chapter. The relevant portions of Table 12.4 will be repeated as we introduce each cranial nerve in the sections that follow.

In addition to describing sensory and motor functions, we will review the course of each cranial nerve from brainstem nuclei to peripheral terminations, including the intracranial course of each cranial nerve, skull exit points (see Table 12.2), cranial nerve branches, and peripheral sensory or parasympathetic ganglia (Table 12.5). As we discuss each cranial nerve, we will also review common clinical disorders associated with it.

TABLE 12.4 Cranial Nerves: Sensory and Motor Functions

NERVE	NAME	FUNCTIONAL CATEGORIES	FUNCTIONS
CN I	Olfactory nerve	Special somatic sensory	Olfaction
CN II	Optic nerve	Special somatic sensory	Vision
CN III	Oculomotor nerve	Somatic motor	Levator palpebrae superior, and all extraocular muscles, except for superior oblique and lateral rectus
		Parasympathetic	Parasympathetics to pupil constrictor and ciliary muscles for near vision
CN IV	Trochlear nerve	Somatic motor	Superior oblique muscle; causes depression and intorsion of the eye
CN V	Trigeminal nerve	General somatic sensory	Sensations of touch, pain, temperature, joint position, and vibration for the face, mouth, anterior two-thirds of tongue, nasal sinuses, and meninges
		Branchial motor	Muscles of mastication and tensor tympani muscle
CN VI	Abducens nerve	Somatic motor	Lateral rectus muscle; causes abduction of the eye
CN VII	Facial nerve	Branchial motor	Muscles of facial expression, stapedius muscle, and part of digastric muscle
		Parasympathetic	Parasympathetics to lacrimal glands, and to submaxillary, submandibular, and all other salivary glands except parotid
		Visceral sensory (special)	Taste from anterior two-thirds of tongue
		General somatic sensory	Sensation from a small region near the external auditory meatus
CN VIII	Vestibulocochlear nerve	Special somatic sensory	Hearing and vestibular sensation
CN IX	Glossopharyngeal nerve	Branchial motor	Stylopharyngeus muscle
		Parasympathetic	Parasympathetics to parotid gland
		General somatic sensory	Sensation from middle ear, region near the external auditory meatus, pharynx, and posterior one-third of tongue
		Visceral sensory (special)	Taste from posterior one-third of tongue
		Visceral sensory (general)	Chemo- and baroreceptors of carotid body
CN X	Vagus nerve	Branchial motor	Pharyngeal muscles (swallowing) and laryngeal muscles (voice box)
		Parasympathetic	Parasympathetics to heart, lungs, and digestive tract down to the splenic flexure
		General somatic sensory	Sensation from pharynx, meninges, and a small region near the external auditory meatus
		Visceral sensory (special)	Taste from epiglottis and pharynx
		Visceral sensory (general)	Chemo- and baroreceptors of the aortic arch
CN XI	Spinal accessory nerve	Branchial motor	Sternomastoid and upper part of trapezius muscle
CN XII	Hypoglossal nerve	Somatic motor	Intrinsic muscles of the tongue

Note: See Table 12.3 and Figure 12.5 for nuclei.

TABLE 12.5 Cranial Nerves: Peripheral Sensory and Parasympathetic Ganglia

NERVE	NAME	PERIPHERAL GANGLIA	FUNCTION(S) OF GANGLIA
CN I	Olfactory nerve	None	—
CN II	Optic nerve	None (retina)	—
CN III	Oculomotor nerve	Ciliary ganglion	Parasympathetics to iris and ciliary muscle
CN IV	Trochlear nerve	None	—
CN V	Trigeminal nerve	Trigeminal ganglion (semilunar or gasserian ganglion)	Primary sensory neuron cell bodies for sensation in the face, mouth, sinuses, and supratentorial meninges
CN VI	Abducens nerve	None	—
CN VII	Facial nerve	Sphenopalatine ganglion (pterygopalatine ganglion)	Parasympathetics to lacrimal glands and nasal mucosa
		Submandibular ganglion	Parasympathetics to submandibular and sublingual salivary glands
		Geniculate ganglion	Primary sensory neuron cell bodies for taste sensation in anterior two-thirds of tongue, and for sensation near outer ear
CN VIII	Vestibulocochlear nerve	Spiral ganglion	Primary sensory neuron cell bodies for hearing
		Scarpa's vestibular ganglion	Primary sensory neuron cell bodies for vestibular sensation
CN IX	Glossopharyngeal nerve	Otic ganglion	Parasympathetics to parotid gland
		Superior (jugular) glossopharyngeal ganglion	Primary sensory neuron cell bodies for sensation from middle ear, external auditory meatus, pharynx, and posterior one-third of tongue
		Inferior (petrosal) glossopharyngeal ganglion	Primary sensory neuron cell bodies for sensation from middle ear, external auditory meatus, pharynx, posterior one-third of tongue, and for taste from posterior tongue, and carotid body inputs
CN X	Vagus nerve	Parasympathetic ganglia in end organs	Parasympathetics to heart, lungs, and digestive tract to level of splenic flexure
		Superior (jugular) vagal ganglion	Primary sensory neuron cell bodies for sensation from pharynx, outer ear, and infratentorial meninges
		Inferior (nodose) vagal ganglion	Primary sensory neuron cell bodies for laryngeal sensation for taste from epiglottis, and for reflex inputs from aortic arch receptors and other thoracoabdominal viscera
CN XI	Spinal accessory nerve	None	—
CN XII	Hypoglossal nerve	None	—

CN I: Olfactory Nerve

Functional category: Special somatic sensory **Function:** Olfaction

Olfactory stimuli are detected by specialized chemoreceptors on bipolar primary sensory neurons in the olfactory neuroepithelium of the upper nasal cavities. Axons of these neurons travel via short **olfactory nerves** that traverse the **cribriform plate** of the ethmoid bone (see Figure 12.3A; Table 12.2) to synapse in the **olfactory bulbs** (see Figure 18.5, 18.6). From the olfactory bulbs, information travels via the **olfactory tracts,** which run in the olfactory sulcus between the gyrus rectus and orbital frontal gyri to reach olfactory processing areas, as discussed in Chapter 18. Note that although the ol-

factory bulbs and tracts are sometimes called CN I, these structures are actually not nerves, but are part of the central nervous system. ■

KEY CLINICAL CONCEPT
ANOSMIA (CN I)

Olfaction

12.1 Patients with unilateral **anosmia,** or olfactory loss, are rarely aware of the deficit because olfaction in the contralateral nostril can compensate. Therefore, when testing olfaction, the examiner must test each nostril separately (neuroexam.com Video 24). Patients are often aware of bilateral anosmia and may complain of decreased taste because of the important contribution of olfaction to the perception of flavor.

Loss of the sense of smell can be caused by head trauma, which damages the olfactory nerves as they penetrate the cribriform plate of the ethmoid. In addition, viral infections can damage the olfactory neuroepithelium. Obstruction of the nasal passages can impair olfaction. Intracranial lesions that occur at the base of the frontal lobes near the olfactory sulci can interfere with olfaction. Possible lesions in this location include meningioma, metastases, basal meningitis, or sarcoidosis (a granulomatous inflammatory disorder that occasionally involves the nervous system, often causing cranial neuropathies). As we will discuss in KCC 19.11, frontal lobe deficits are often difficult to detect clinically, especially with small lesions. Therefore, lesions at the base of the frontal lobes can sometimes grow to a very large size, causing little obvious dysfunction other than anosmia. Large lesions of the olfactory sulcus region (typically meningiomas) can also sometimes produce a condition called Foster–Kennedy syndrome, in which there is anosmia together with optic atrophy in one eye (caused by ipsilateral tumor compression) and papilledema in the other eye (caused by elevated intracranial pressure). ■

CN II: Optic Nerve

Functional category: Special somatic sensory **Function:** Vision

As we discussed in Chapter 11, the optic nerve carries visual information from the retina to the lateral geniculate nucleus of the thalamus and to the extrageniculate pathways (see Figures 11.6, 11.15; Figure 12.2A). The retinal ganglion cells are actually part of the central nervous system, so the optic nerves are, strictly speaking, tracts and not nerves. Nevertheless, by widely accepted convention the portion of the visual pathway in front of the optic chiasm is called the **optic nerve,** and beyond this point it is referred to as the **optic tract.** The optic nerves travel from the orbit to the intracranial cavity via the **optic canal** (see Figure 12.3A, C; Table 12.2). The anatomy and disorders of visual pathways are discussed in greater detail in Chapter 11.

CN III, IV, and VI: Oculomotor, Trochlear, and Abducens Nerves

CN III	**Functional category:**	Somatic motor	**Function:** Levator palpebrae superior, and all extraocular muscles, except for superior oblique and lateral rectus
	Functional category:	Parasympathetic	**Function:** Parasympathetics to pupil constrictor and ciliary muscles for near vision
CN IV	**Functional category:**	Somatic motor	**Function:** Superior oblique muscle; causes depression and intorsion of the eye
CN VI	**Functional category:**	Somatic motor	**Function:** Lateral rectus muscle; causes abduction of the eye

These nerves, which are responsible for controlling the extraocular muscles, are discussed in detail in Chapter 13. Briefly, CN VI abducts the eye laterally in the horizontal direction; CN IV acts through a trochlea, or pulleylike structure in the orbit, to rotate the top of the eye medially and move it downward; and CN III subserves all other eye movements. The **oculomotor** (**CN III**) and **trochlear** (**CN IV**) nuclei are located in the midbrain, and the **abducens** (**CN VI**) nucleus is in the pons (Figures 12.5, 14.3, 14.4C). Recall that CN III exits the brainstem ventrally in the interpeduncular fossa, CN IV exits dorsally from the inferior tectum, and CN VI exits ventrally at the pontomedullary junction (see Figure 12.2). CN III, IV, and VI then traverse the **cavernous sinus** (see Figure 13.11), and exit the skull via the **superior orbital fissure** (see Figure 12.3A,C; Table 12.2) to reach the muscles of the orbit. CN III also carries parasympathetics to the **pupillary constrictor** and to the **ciliary muscle** of the lens. The preganglionic parasympathetic neurons are located in the **Edinger–Westphal nucleus** in the midbrain (see Figure 12.5). They synapse in the **ciliary ganglion** located in the orbit (Figure 12.6). Postganglionic parasympathetic fibers then continue to the pupillary constrictor and ciliary muscles.

Figure 12.6 Summary of Cranial Nerve Parasympathetic Pathways

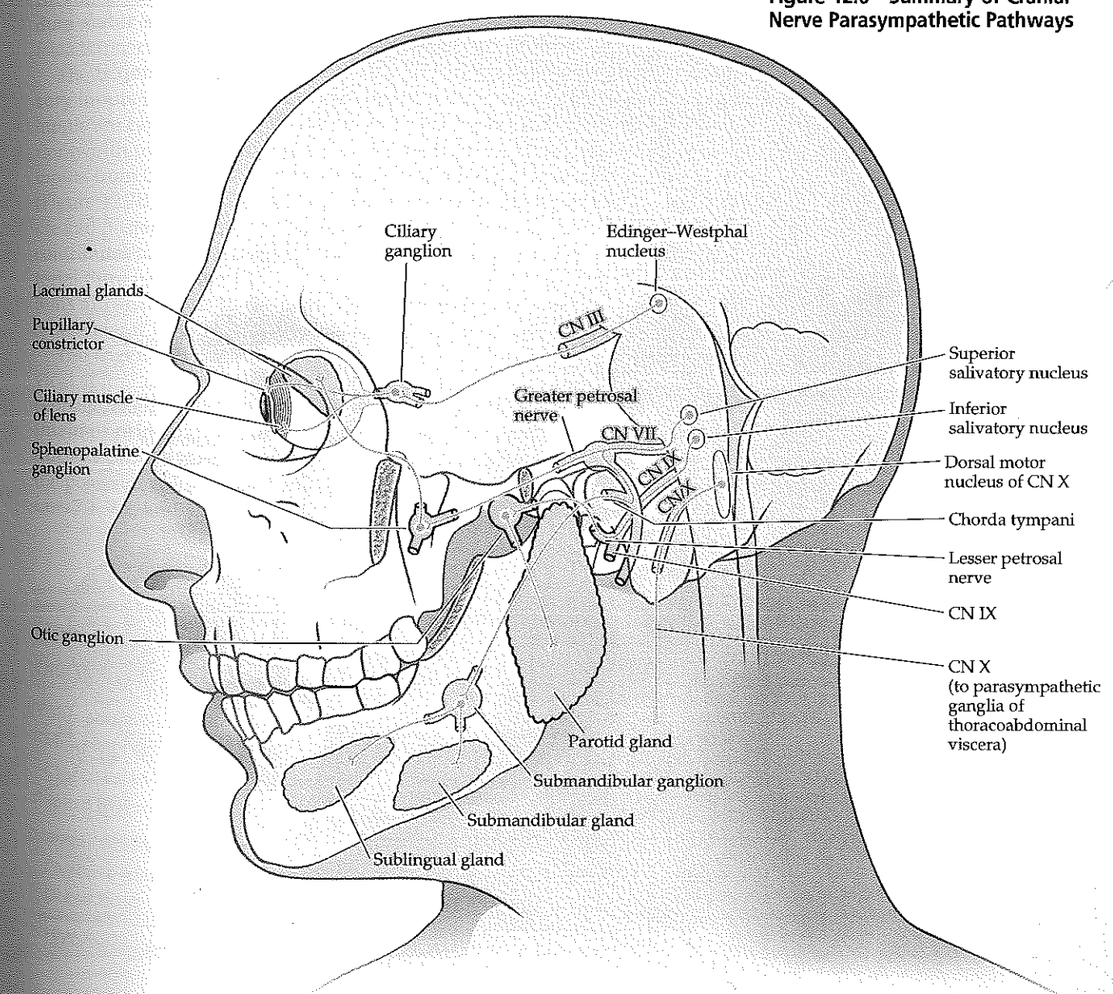

CN V: Trigeminal Nerve

Functional category:	General somatic sensory	**Function:**	Sensations of touch, pain, temperature, joint position, and vibration for the face, mouth, anterior two-thirds of tongue, nasal sinuses, and meninges
Functional category:	Branchial motor	**Function:**	Muscles of mastication and tensor tympani muscle

The name "trigeminal" was given to this nerve because it has three major branches: the **ophthalmic division** (V_1), **maxillary division** (V_2), and **mandibular division** (V_3) (Figure 12.7). The trigeminal nerve provides **sensory** innervation to the face and should be distinguished from the facial nerve, which controls the muscles of facial expression. The trigeminal nerve

Figure 12.7 Trigeminal Nerve (CN V) (A) Summary of trigeminal sensory and motor pathways. (B) General somatic sensory innervation to the face is provided by the trigeminal nerve, as well as by CN VII, IX, and X. These inputs all travel to the trigeminal nuclei (see Figure 12.9). The occiput and neck, on the other hand, are supplied by cervical nerve roots C2 and C3. Sensory innervation of the supratentorial dura is provided by CN V (not shown)

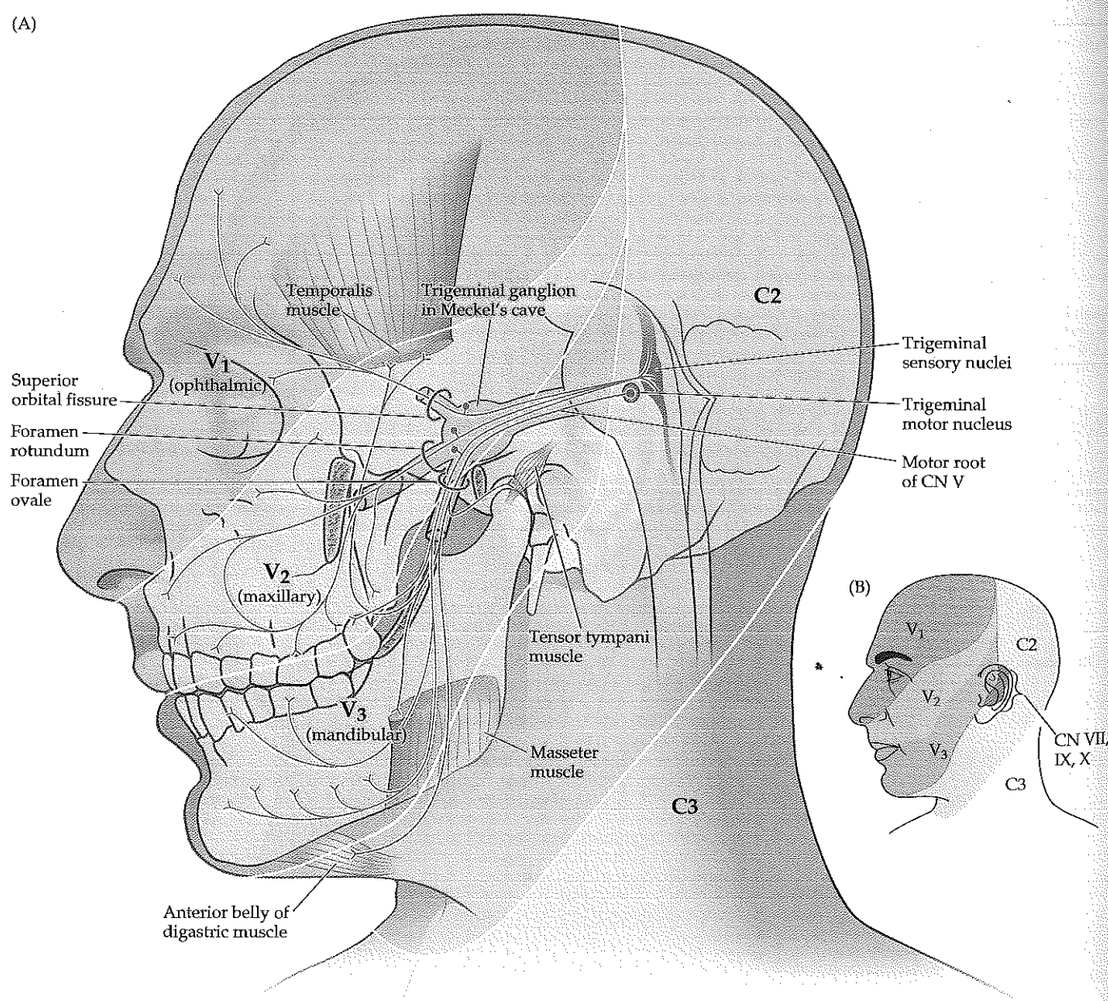

also has a small branchial **motor root** (see Figure 12.7), which travels with the mandibular division and is responsible for controlling the muscles of mastication and some other smaller muscles.

The trigeminal nerve exits the brainstem from the ventrolateral pons (see Figure 12.2A,C). It then enters a small fossa just posterior and inferolateral to the cavernous sinus called **Meckel's cave.** The **trigeminal ganglion,** also known as the **semilunar** or **gasserian ganglion,** lies in Meckel's cave and is the sensory ganglion of the trigeminal nerve (Figure 12.7; Table 12.5). The ophthalmic division (V_1) travels through the inferior part of the cavernous sinus to exit the skull via the **superior orbital fissure** (Figures 12.3A,C, 12.7A; Table 12.2; see also Figure 13.11). The maxillary division (V_2) exits via the **foramen rotundum,** and the mandibular division (V_3) via the **foramen ovale.** A mnemonic for the exit points of these three branches is **Single Room Occupancy,** or **SRO** (for Superior, Rotundum, Ovale). The sensory territories of V_1, V_2, and V_3 are shown in Figure 12.7B. Recall that sensation to the occiput is conveyed by C2 (see Case 8.2). The trigeminal nerve also provides touch and pain sensation for the nasal sinuses, inside of the nose, mouth, and anterior two-thirds of the tongue. In addition, pain sensation for the **supratentorial dura mater** is supplied by the trigeminal nerve, while the dura of the posterior fossa is innervated by CN X and upper cervical nerve roots.

MNEMONIC

The **trigeminal nuclei** (Figures 12.8, 12.9) receive **general somatic sensory** inputs from CN V and other cranial nerves (see Table 12.3). The main inputs are carried by CN V and provide sensation for the face, mouth, anterior two-thirds of the tongue, nasal sinuses, and supratentorial dura. Smaller inputs from CN VII, IX, and X provide sensation for part of the external ear (Figure 12.7B; Table 12.4). In addition, CN IX provides sensation to the middle ear, posterior one-third of the tongue, and pharynx. CN X probably also contributes to pharyngeal sensation, and provides sensation for the infratentorial dura (see Table 12.4). As we will now see, the trigeminal sensory systems are analogous to the posterior column–medial lemniscal system and anterolateral systems of the spinal cord (Table 12.6).

The trigeminal nuclear complex runs from the midbrain to the upper cervical spinal cord (see Figure 12.8) and consists of three nuclei: the mesencephalic, chief sensory, and spinal trigeminal nuclei (see Table 12.6). The **chief** (**main** or **principal**) **trigeminal sensory nucleus** and the **spinal trigeminal nucleus** provide sensory systems for the face and head that are analogous to the posterior columns and anterolateral systems, respectively (compare Figures 7.1, 7.2, and 12.8; see Table 12.6). The primary sensory neurons for these

REVIEW EXERCISE

1. Name the three sensory divisions of the trigeminal nerve and describe their sensory territories (see Figure 12.7).
2. What are the motor functions of the trigeminal nerve?

TABLE 12.6 Analagous Trigeminal and Spinal Somatosensory Systems

NUCLEUS	SENSORY MODALITIES	MAIN PATHWAY TO THALAMUS	MAIN THALAMIC NUCLEUS[a]
TRIGEMINAL SENSORY SYSTEMS			
Mesencephalic trigeminal nucleus	Proprioception	—	—
Chief trigeminal sensory nucleus	Fine touch, dental pressure	Trigeminal lemniscus	VPM
Spinal trigeminal nucleus	Crude touch, pain, temperature	Trigeminothalamic tract	VPM
SPINAL SENSORY SYSTEMS			
Posterior column nuclei	Fine touch, proprioception	Medial lemniscus	VPL
Dorsal horn	Crude touch, pain, temperature	Spinothalamic tract	VPL

[a]VPL, ventral posterior lateral nucleus; VPM, ventral posterior medial nucleus.

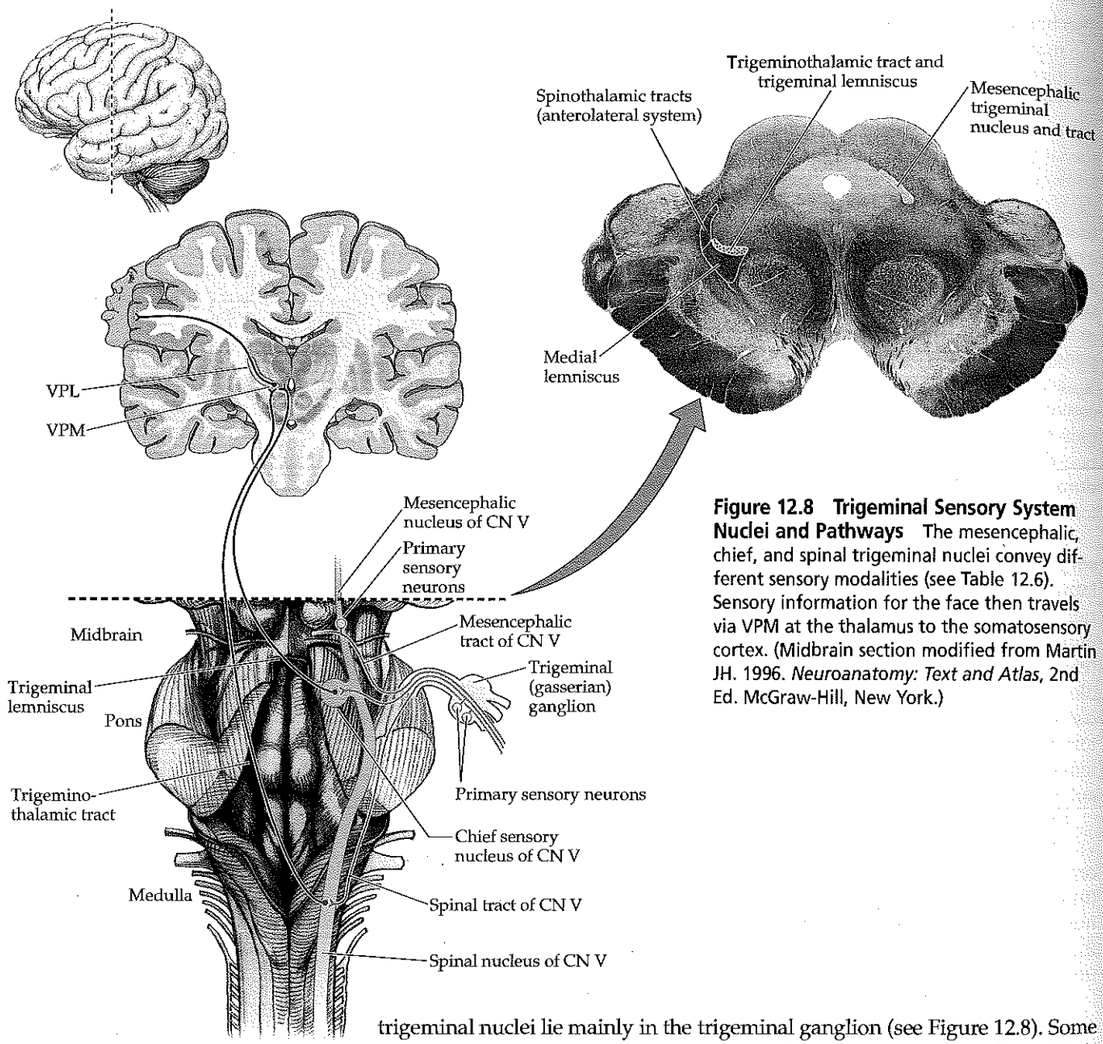

Figure 12.8 Trigeminal Sensory System Nuclei and Pathways The mesencephalic, chief, and spinal trigeminal nuclei convey different sensory modalities (see Table 12.6). Sensory information for the face then travels via VPM at the thalamus to the somatosensory cortex. (Midbrain section modified from Martin JH. 1996. *Neuroanatomy: Text and Atlas*, 2nd Ed. McGraw-Hill, New York.)

trigeminal nuclei lie mainly in the trigeminal ganglion (see Figure 12.8). Some also lie in the peripheral sensory ganglia of CN VII, IX, and X (see Table 12.5). Large-diameter primary sensory neuron fibers mediating fine touch and dental pressure enter the lateral pons to synapse in the **chief trigeminal sensory nucleus** (see Figure 12.8; see also Figure 14.4BA). This nucleus is similar in structure and function to the dorsal column nuclei (see Figures 7.1 and 14.5B). The **trigeminal lemniscus** crosses to the opposite side of the brainstem to ascend with the medial lemniscus toward the thalamus (see Figure 14.3). While the medial lemniscus travels to the ventral posterior lateral nucleus (VPL), the trigeminal lemniscus travels to the **ventral posterior medial nucleus (VPM)**. From there, tertiary sensory neurons travel to the face area of the primary somatosensory cortex. A second, smaller pathway, called the dorsal trigeminal tract (or dorsal trigeminothalamic tract), travels from the chief trigeminal sensory nucleus to the ipsilateral VPM, without crossing. This pathway appears to convey touch and pressure sensation from the oral cavity, including the teeth.

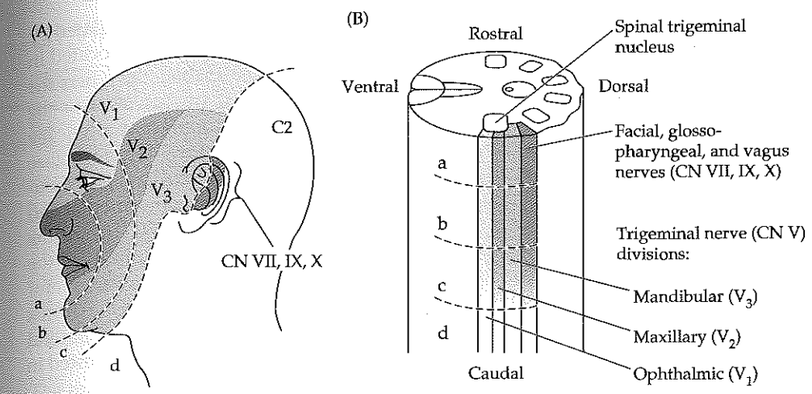

Figure 12.9 Somatotopic Maps of the Spinal Trigeminal Nucleus (A) Concentric regions (a–d) emanating from the mouth are indicated as they correspond with rostral to caudal regions of the spinal trigeminal nucleus shown in (B). (B) Regions of spinal trigeminal tract supplying each trigeminal nerve division, as well as CN VII, IX and X. In addition, rostral to caudal regions of the nucleus and tract (a–d) are indicated, corresponding to the concentric regions shown in (A).

Medium- and small-diameter primary sensory fibers conveying crude touch, pain, and temperature sensation enter the lateral pons with the trigeminal nerve and descend in the **spinal trigeminal tract** to synapse in the **spinal trigeminal nucleus.** Examine the spinal trigeminal nucleus and tract in the serial sections shown in Figures 14.4C and 14.5A–C. It should be clear from these sections that the spinal trigeminal nucleus is the rostral extension of the dorsal horn. Similarly, the spinal trigeminal tract is analogous to Lissauer's tract (see Figures 6.4, 7.2). Secondary sensory neurons from the spinal trigeminal nucleus cross the brainstem to ascend as the **trigeminothalamic tract** (or ventral trigeminothalamic tract). The trigeminothalamic tract is analogous to the spinothalamic tract (see Table 12.6) and the pathways travel together to the thalamus (see Figures 12.8, 14.3). Trigeminothalamic tract fibers synapse in the thalamic **ventral posterior medial nucleus (VPM)**, and tertiary sensory neurons then travel in the internal capsule to the primary somatosensory cortex. Like the anterolateral systems in the spinal cord, there are also pathways from the spinal trigeminal nucleus to intralaminar thalamic nuclei, the reticular formation, and other areas, to mediate the affective and arousal aspects of facial pain.

The spinal trigeminal tract and nucleus are somatotopically organized, with the mandibular division represented dorsally, the ophthalmic division represented ventrally, and the maxillary division in between (see Figure 12.9). In addition, concentric rings form an **"onion skin"**–like representation, with perioral areas represented more rostrally in the nucleus, and areas more removed from the mouth represented more caudally.

The **mesencephalic trigeminal nucleus and tract** run along the lateral edge of the periaqueductal gray matter of the midbrain (see Figure 14.3A,B) and mediate proprioception (see Table 12.6). The neurons of the mesencephalic trigeminal nucleus are the only case in which **primary sensory neurons** lie within the central nervous system instead of in peripheral ganglia (see Figure 12.8). The peripheral processes of these bipolar neurons convey proprioceptive input from the muscles of mastication and probably also from the tongue, and from the extraocular muscles. In the monosynaptic **jaw jerk reflex** (see KCC 12.4; neuroexam.com Video 39), processes of mesencephalic trigeminal neurons descend to the pons and synapse in the motor trigeminal nucleus (see Figure 12.7A). Ascending and descending fibers form the mesencephalic trigeminal tract (see Figure 12.8; see also Figure 14.3A,B). Other central pathways of the mesencephalic trigeminal nucleus are still under investigation.

REVIEW EXERCISE

1. Cover the second column from the left in Table 12.6. For each nucleus in the left column, provide the sensory modalities served and the location of the nucleus (see Figure 12.8).

2. Which thalamic nucleus is most important for relaying somatosensory information from the face, and which is most important for relaying somatosensory information from the rest of the body to the cortex?

The **branchial motor** functions of the trigeminal nerve are mediated by the **trigeminal motor nucleus** (see Figure 12.7). This nucleus is located in the upper-to-mid pons (see Figures 12.5 and 14.4B), near the level where the trigeminal nerve exits the brainstem. The branchial **motor root** of the trigeminal nerve runs inferomedial to the trigeminal ganglion along the floor of Meckel's cave and then joins V_3 to exit via the foramen ovale (see Figure 12.3A). It then supplies the **muscles of mastication** (see neuroexam.com Video 38), including the masseter, temporalis, and medial and lateral pterygoid muscles, as well as several smaller muscles, such as the **tensor tympani,** tensor veli palatini, mylohyoid, and anterior belly of the digastric. The **upper motor neuron control** reaching the trigeminal motor nucleus is predominantly bilateral, so unilateral lesions in the motor cortex or corticobulbar tract usually cause no deficit in jaw movement. Bilateral upper motor neuron lesions, however, can cause hyperreflexia manifested in a brisk jaw jerk reflex (see KCC 12.4).

KEY CLINICAL CONCEPT
TRIGEMINAL NERVE DISORDERS (CN V)

12.2 Disorders of the trigeminal nerve are relatively uncommon, except for **trigeminal neuralgia** (tic douloureux). In this condition, patients experience recurrent episodes of brief severe pain lasting from seconds to a few minutes, most often in the distribution of V_2 or V_3. Attacks usually begin after age 35. Painful episodes are often provoked by chewing, shaving, or touching a specific trigger point on the face. Neurologic exam, including facial sensation, is normal. The cause of trigeminal neuralgia in most cases is unknown. In some cases, compression of the trigeminal nerve by an aberrant vessel has been demonstrated, but the significance of this finding is uncertain. It is important to perform an MRI scan to exclude tumor or other lesions in the region of the trigeminal nerve as the cause. Trigeminal neuralgia can also occur in multiple sclerosis (see KCC 6.6), possibly caused by demyelination in the trigeminal nerve entry zone of the brainstem. Initial treatment of trigeminal neuralgia is with carbamazepine or baclofen. Refractory cases have been successfully treated with various procedures, including radiofrequency ablation, gamma knife (see KCC 16.4), or surgical decompression of the trigeminal nerve.

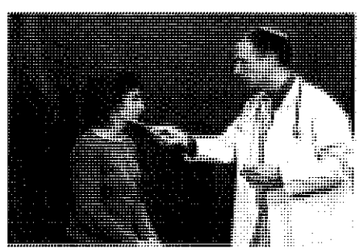
Facial sensation

Sensory loss in the distribution of the trigeminal nerve or its branches (see neuroexam.com Video 36) can be caused by trauma, metastatic disease—especially in isolated jaw numbness, herpes zoster (see KCC 8.3), aneurysms of the petrous portion of the internal carotid artery (see Figures 4.16C, 12.3A), cavernous sinus or orbital apex disorders (see KCC 13.7), trigeminal or vestibular schwannoma (see KCC 12.5), or sphenoid wing meningioma (see KCC 5.8). Lesions of the trigeminal nuclei in the brainstem cause *ipsilateral* loss of facial sensation because the primary sensory fibers do not cross before entering the nucleus (see Figure 12.8). Common causes include infarcts (see Chapter 14), demyelination, or other brainstem lesions. Often lesions of the trigeminal nucleus in the pons or medulla also involve the nearby spinothalamic tract (see Figures 7.2, 14.4C, 14.5A,B). This combination of spinal trigeminal and spinothalamic tract involvement in lateral brainstem lesions leads to a well-recognized pattern with sensory loss in the face ipsilateral to the lesion, but in the body contralateral to the lesion (see KCC 7.3; Figure 7.9B). ■

CN VII: Facial Nerve

Functional category:	Branchial motor	**Function:**	Muscles of facial expression, stapedius muscle, and part of digastric muscle
Functional category:	Parasympathetic	**Function:**	Parasympathetics to lacrimal glands, and to submaxillary, submandibular, and all other salivary glands except parotid
Functional category:	Visceral sensory (special)	**Function:**	Taste from anterior two-thirds of tongue
Functional category:	General somatic sensory	**Function:**	Sensation from a small region near the external auditory meatus

The main function of the facial nerve is to control the muscles of facial expression (see neuroexam.com Video 40); however, it has several other important functions as well. The main nerve trunk carries the **branchial motor** fibers controlling facial expression, while a smaller branch called the **nervus intermedius** carries fibers for the parasympathetic (tears and salivation), visceral sensory (taste), and general somatosensory functions (see Figure 12.10; see also Figure 12.6).


Facial muscles

The **facial nucleus** is located in the branchial motor column, more caudally in the pons than the trigeminal motor nucleus (see Figure 12.5; see also Figure 14.4B,C). The fascicles of the facial nerve loop dorsally around the abducens nucleus, forming the **facial colliculus** on the floor of the fourth ventricle (Figures 12.2B, 12.11). The nerve then exits the brainstem ventrolaterally at the pontomedullary junction (see Figure 12.2A,C). Upper motor neuron control of the facial nucleus is discussed in KCC 12.3 (see Figure 12.13). Briefly, lesions in the cortex or corticobulbar tracts cause contralateral face weakness that spares the forehead, while lesions of the facial nucleus, nerve fascicles in the brainstem, or peripheral nerve cause ipsilateral weakness of the entire face.

The facial nerve exits the brainstem ventrolaterally at the pontomedullary junction, lateral to CN VI in a region called the **cerebellopontine angle** (see Figure 12.2A,C). It then traverses the subarachnoid space and enters the **internal auditory meatus** (see Figure 12.3A; see also Figure 4.13C) to travel in the **auditory canal** of the **petrous temporal bone** together with the vestibulocochlear nerve (see Figure 12.14). At the **genu** of the facial nerve, the nerve takes a turn posteriorly and inferiorly in the temporal bone to run in the **facial canal,** just medial to the middle ear (see Figures 12.10, 12.14). The **geniculate ganglion** lies in the genu and contains primary sensory neurons for taste sensation in the anterior two-thirds of the tongue, and for general somatic sensation in a region near the external auditory meatus (see Table 12.5; Figure 12.7B). The main portion of the facial nerve exits the skull at the **stylomastoid foramen** (see Figures 12.3B, 12.10). It then passes through the parotid gland and divides into five major **branchial motor** branches to control the muscles of facial expression: the **temporal, zygomatic, buccal, mandibular,** and **cervical** branches (see Figure 12.10). Other smaller branchial motor branches innervate the **stapedius** (see Figures 12.10, 12.15), occipitalis, posterior belly of the digastric, and stylohyoid muscles. The cranial nerves controlling the middle ear muscles can be recalled by the mnemonic **T**rigeminal for **T**ensor **T**ympani and **S**eventh for **S**tapedius. Both the tensor tympani and the stapedius dampen movements of the middle ear ossicles (see the section on CN VIII later in this chapter), providing feedback modulation of acoustic signal intensity.

MNEMONIC

Figure 12.10 Facial Nerve (CN VII) Summary of facial nerve sensory and motor pathways.

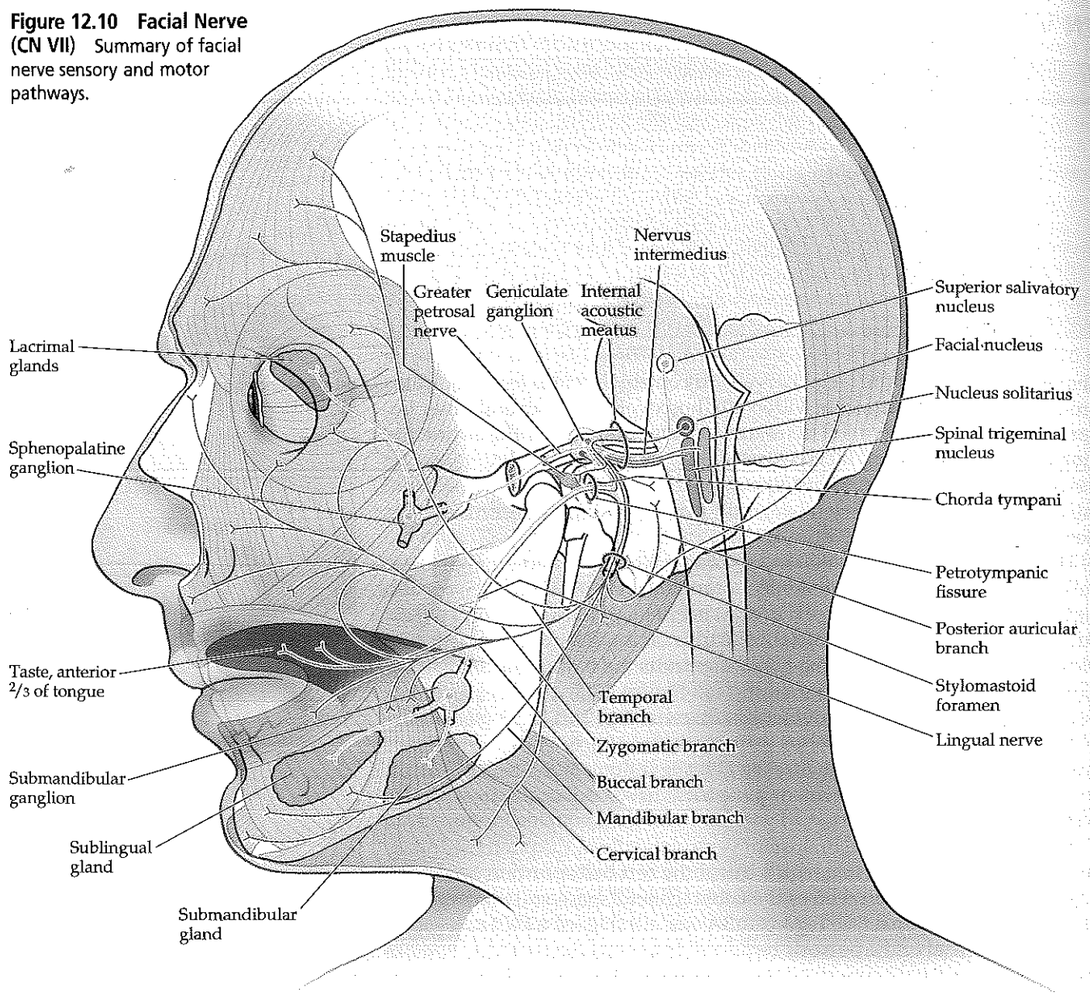

Taste

The preganglionic **parasympathetic** fibers of the facial nerve originate in the **superior salivatory nucleus** (see Figure 12.10) and are carried by two small branches off the main trunk of the facial nerve. The **greater petrosal nerve** takes off at the genu of the facial nerve (see Figure 12.14) to reach the **sphenopalatine (pterygopalatine) ganglion,** where postganglionic parasympathetic cells project to the lacrimal glands and nasal mucosa (see Figure 12.10). The **chorda tympani** leaves the facial nerve just before the stylomastoid foramen and travels back upward to traverse the middle ear cavity before exiting the skull at the **petrotympanic fissure** (see Figures 12.3B, 12.10), just medial and posterior to the temporomandibular joint. The chorda tympani then joins the **lingual nerve** (a branch of CN V_3) to reach the **submandibular ganglion,** where postganglionic parasympathetics arise to supply the submandibular and submaxillary salivary glands.

The lingual nerve and chorda tympani also carry **special visceral sensory** fibers mediating **taste sensation** (see neuroexam.com Video 41) for the an-

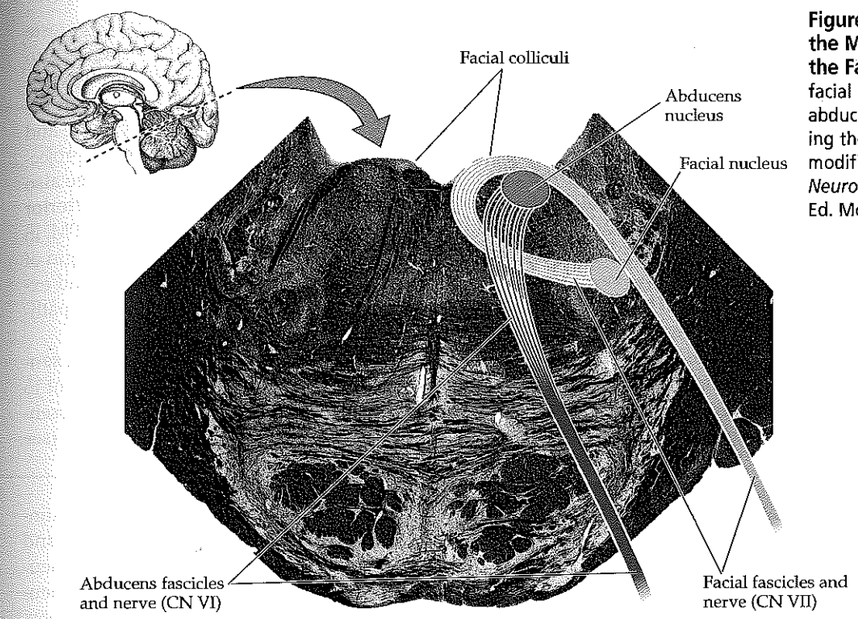

Figure 12.11 Axial Section of the Mid-to-Lower Pons, Showing the Facial Colliculus Fibers of the facial nerve (CN VII) loop around the abducens nucleus (CN VI) before exiting the brainstem. (Brainstem section modified from Martin JH. 1996. *Neuroanatomy: Text and Atlas*, 2nd Ed. McGraw-Hill, New York.)

Figure 12.12 Central Taste Pathways

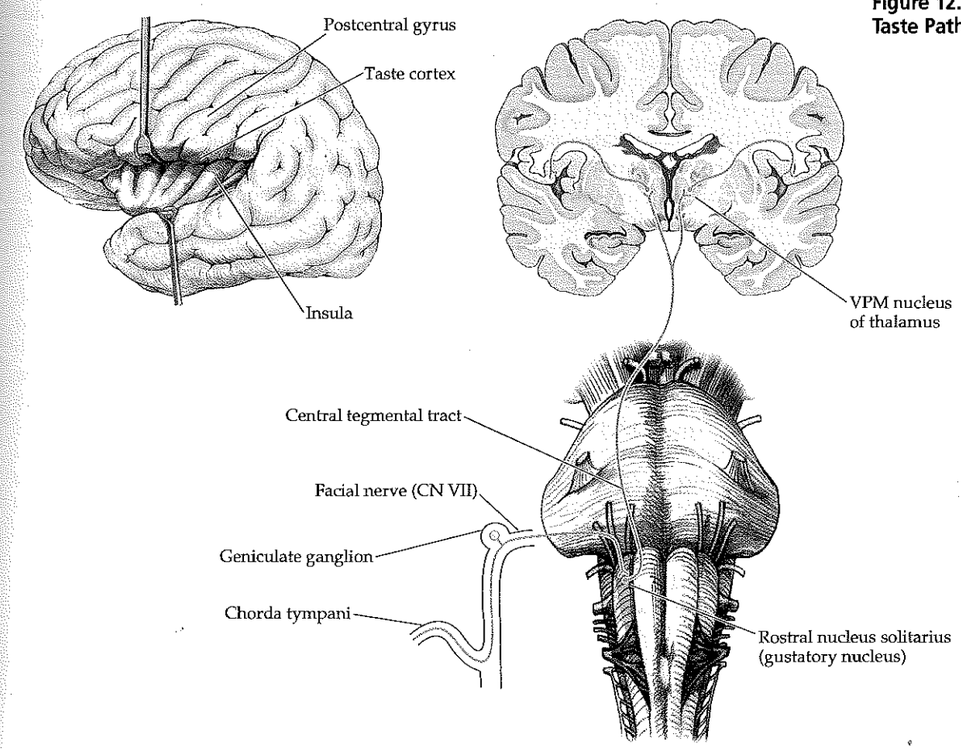

terior two-thirds of the tongue (see Figure 12.10) . The primary sensory taste fibers have their cell bodies in the geniculate ganglion (Figure 12.12; see also Figure 12.14, Table 12.5). These cells synapse onto secondary sensory neurons in the **rostral nucleus solitarius** (see Figure 14.5A,B), also known as the gustatory nucleus. There are also taste inputs for the posterior tongue and pharynx that travel via CN IX and X to enter this nucleus. Ascending projections continue via the **central tegmental tract** (see Figure 12.12; see also Figures 14.3, 14.4) to reach tertiary sensory neurons in the **ventral posterior medial nucleus (VPM)** of the thalamus. Thalamic neurons from the VPM, in turn, project to the **cortical taste area,** which lies at the inferior margin of the postcentral gyrus adjacent to the tongue somatosensory area and extends into the parietal operculum and insula (see Figure 12.12). Taste pathways ascend mainly ipsilaterally in monkeys and cats.

REVIEW EXERCISE

Describe the branchial motor, parasympathetic, visceral sensory, and general somatic sensory functions of the facial nerve. Name the nucleus subserving each function. (See Figure 12.10.)

Finally, a small branch of the facial nerve provides **general somatic sensation** for a region near the external auditory meatus that lies adjacent to similar regions supplied by CN IX and X (see Figure 12.7B). The somatosensory fibers for CN V, VII, IX, and X all synapse in the trigeminal nuclei (see Figure 12.5; Table 12.3).

KEY CLINICAL CONCEPT

FACIAL NERVE LESIONS (CN VII)

12.E As we discussed briefly in KCC 6.3, it is clinically important to distinguish between facial weakness caused by upper motor neuron lesions and facial weakness caused by lower motor neuron lesions. Upper motor neurons in the face area of the primary motor cortex control lower motor neurons in the contralateral facial nucleus of the pons (Figure 12.13). In addition, for the superior portions of the face, projections descend from the ipsilateral motor cortex as well as from the contralateral motor cortex. Thus, the lower motor neurons supplying the forehead and part of the orbicularis oculi receive upper motor neuron inputs from bilateral motor cortices. As a result, unilateral **upper motor neuron lesions** tend to spare the forehead and cause only mild contralateral orbicularis oculi weakness resulting in a slightly widened palpebral fissure, or inability to fully bury the eyelash on forced eye closure. In upper motor neuron lesions the weakness affects mainly the inferior portions of the contralateral face (see Figure 12.13, lesion A). **Lower motor neuron lesions,** in contrast, affect the entire half of the face and do not spare the forehead (see Figure 12.13, Lesion B). Additional clues that are sometimes present in upper motor neuron–type weakness include neighborhood effects such as hand or arm weakness, sensory loss, aphasia, or dysarthria, none of which are present in lower motor neuron lesions. The connections shown in Figure 12.13 are somewhat oversimplified; in reality the upper motor neuron corticobulbar fibers controlling the facial nucleus project mainly to pontine interneurons that project, in turn, to lower motor neurons in the facial nucleus.

The most common facial nerve disorder by far is **Bell's palsy,** in which all divisions of the facial nerve are impaired within a few hours or days and then gradually recover. The cause is unknown, although viral or inflammatory mechanisms have been suggested. The most striking feature is unilateral facial weakness of the lower motor neuron type, which can be mild but is often severe (see Figure 12.13, lesion B). Diagnosis is based on clinical history and exam (see neuroexam.com Videos 40, 41). Patients often initially complain of some retroauricular pain, likely caused by involvement of the general somatosensory component of CN VII (see Figure 12.7B). Hyperacusis can occur because of stapedius muscle weakness (see Figures 12.10, 12.15). In addition, patients may suffer from "dry eye," resulting from decreased lacrimation with parasympathetic involvement (see Figure 12.10). Neurologic examination is notable for unilateral lower motor neuron–type

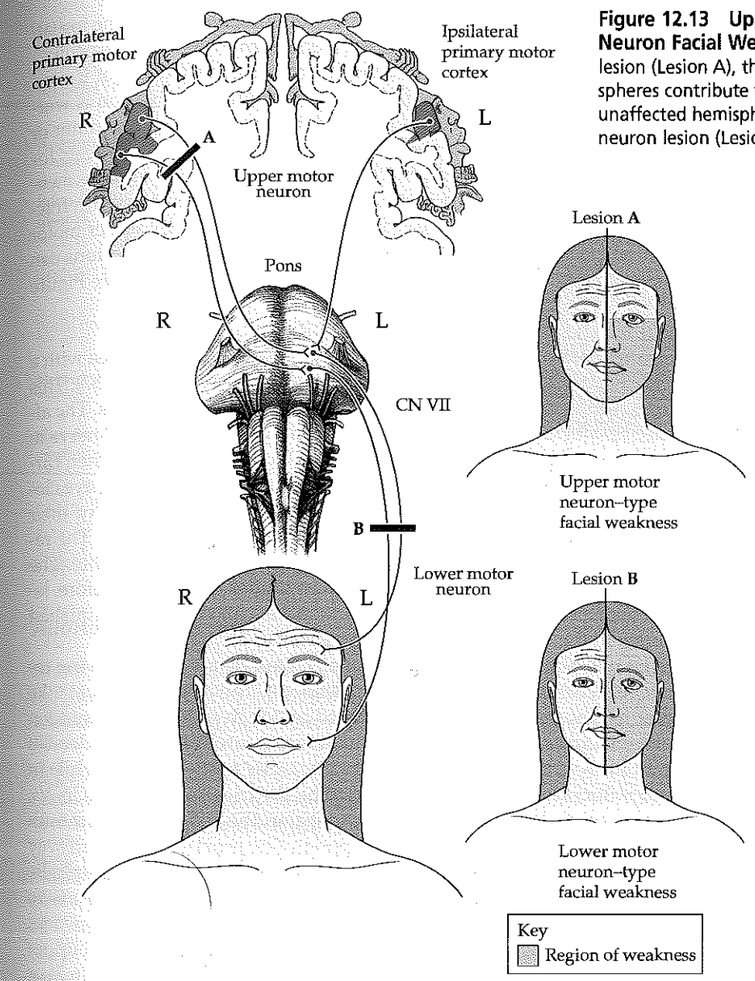

Figure 12.13 Upper Motor Neuron versus Lower Motor Neuron Facial Weakness With an upper motor neuron lesion (Lesion A), the upper face is spared because both hemispheres contribute to movement of the upper face, and the unaffected hemisphere can compensate. With a lower motor neuron lesion (Lesion B), the entire face is affected on one side.

facial weakness, sometimes associated with loss of taste on the ipsilateral tongue (test with mustard or sugar applied with a cotton swab). The remainder of the exam should be normal in Bell's palsy. The presence of hand weakness, sensory loss, dysarthria, or aphasia suggests an upper motor neuron lesion. In clinically typical cases, imaging studies are not necessary.

Treatment of Bell's palsy is controversial, although some practitioners use steroids in certain cases. Incomplete eye closure and decreased tearing can cause corneal ulcerations. Therefore, patients should be given lubricating eyedrops and instructions to tape the eye shut at night. About 80% of patients recover fully from Bell's palsy within 3 weeks, although some are left with variable degrees of residual weakness. During recovery, regenerating facial nerve fibers sometimes reach the wrong target. For example, aberrant regeneration of parasympathetic fibers (see Figure 12.6) can result in the phenomenon of "crocodile tears," in which patients experience lacrimation instead of salivation when they see food. Aberrant regeneration of different motor branches of the facial nerve sometimes results in **synkinesis,** meaning abnormal move-

ment together. For example, if the patient is asked to close one eye, the ipsilateral platysma muscle may contract slightly, along with the orbicularis oculi.

In cases of bilateral lower motor neuron–type facial weakness, or if a patient experiences a second episode, a more thorough investigation is warranted. This should include an MRI scan with contrast looking for tumor or other infiltrative disorders, lumbar puncture (see KCC 5.10), and tests for Lyme disease, sarcoidosis, and HIV. In addition to the causes already mentioned, facial nerve injury can occur in head trauma, particularly with fractures of the petrous temporal bone. Facial weakness caused by upper motor neuron lesions is discussed in KCC 6.3. In addition, brainstem lesions can occasionally involve the facial nucleus or exiting nerve fascicles (see Figure 12.11; see also KCC 14.3). ■

KEY CLINICAL CONCEPT

CORNEAL REFLEX AND JAW JERK REFLEX (CN V, VII)



Corneal reflex

Jaw jerk reflex

12.4 The **corneal reflex** is elicited by gentle stroking of each cornea with a cotton swab; the response is eye closure (see neuroexam.com Video 37). This reflex is mediated by both monosynaptic and polysynaptic pathways. The afferent limb is conveyed by the ophthalmic division of the trigeminal nerve to the chief sensory and spinal trigeminal nuclei. The efferent limb is then carried by the facial nerve to reach the orbicularis oculi muscles causing eye closure. A lesion of the trigeminal sensory pathways, the facial nerve, or their connections causes a decreased corneal reflex in the ipsilateral eye. The response of the contralateral eye in brainstem lesions is more variable. The corneal reflex is also modulated by inputs from higher centers. Therefore, lesions of sensorimotor cortex and its connections can cause a diminished corneal reflex in the eye contralateral to the lesion.

Since an eye blink response can also be elicited by an object moving toward the eye, when eliciting the corneal response the examiner must take care to ensure that the blink has been elicited by touch rather than a sudden movement toward the eye. In blink to threat (see neuroexam.com Video 28) the afferent limb of the reflex is carried by the optic nerve (CN II), while in the corneal reflex, the afferent limb is carried by the trigeminal nerve (CN V).

The **jaw jerk reflex** is elicited by tapping on the chin with the mouth slightly open; the jaw jerks forward in response. The monosynaptic pathway for this reflex consists of primary sensory neurons in the mesencephalic trigeminal nucleus (see Figure 12.8), which send axons to the pons to synapse in the motor trigeminal nucleus. In normal individuals the jaw jerk reflex is minimal or absent (see neuroexam.com Video 39). In bilateral upper motor neuron lesions, such as amyotrophic lateral sclerosis (see KCC 6.7) or diffuse white matter disease, the jaw jerk reflex may be brisk.

CN VIII: Vestibulocochlear Nerve

Functional category: Special somatic sensory	**Function:** Hearing and vestibular sensation

This nerve carries the **special somatic sensory** functions of hearing and vestibular sense from the structures of the inner ear. The vestibulocochlear nerve exits the brainstem at the pontomedullary junction just lateral to the facial nerve, in a region called the **cerebellopontine angle** (see Figure 12.2A,C). It then traverses the subarachnoid space to enter the **internal auditory meatus** (see Figure 12.3A) together with the facial nerve and travels in the **auditory canal** of the petrous temporal bone to reach the cochlea and vestibular organs (Figure 12.14; see also Figure 4.13C). In the subsections that follow we will discuss the auditory and vestibular functions of CN VIII in turn.

Figure 12.14 Superior View of Internal Auditory Canal and Inner Ear Structures

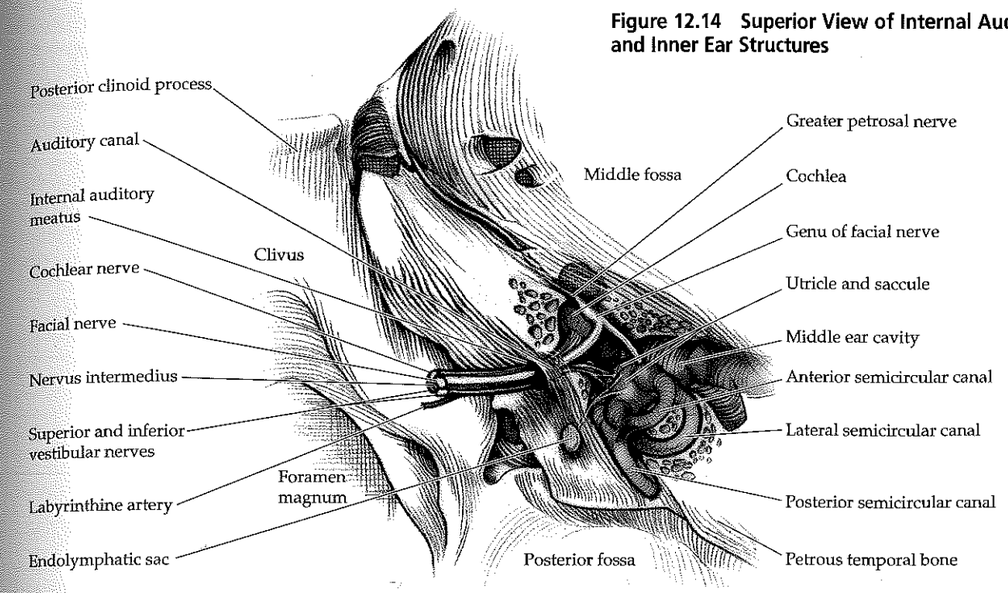

Auditory Pathways

Sound waves are transmitted by the **tympanic membrane** and amplified by the middle ear ossicles—the **malleus, incus,** and **stapes**—to reach the **oval window** (Figure 12.15). The movements of the malleus are dampened by the tensor tympani muscle, and movements of the stapes are dampened by the stapedius in response to loud sounds. From the oval window, vibrations reach the inner ear structures. The **inner ear,** or **labyrinth,** consists of the **cochlea, vestibule,** and **semicircular canals** (see Figure 12.15). The labyrinth is composed of a **bony labyrinth,** which is lined with compact bone and contains the **membranous labyrinth.** The bony labyrinth is filled with fluid called **perilymph,** within which the structures of the membranous labyrinth are suspended. Interestingly, perilymph communicates with the subarachnoid space through a small perilymphatic duct (not shown). The membranous labyrinth, in turn, is filled with a fluid of slightly different ionic composition, called **endolymph.** The membranous labyrinth includes the **cochlear duct, utricle, saccule,** and **semicircular canals** (see Figure 12.15).

Acoustic vibrations from the oval window reach the **scala vestibuli** and are transmitted along the snail-shaped **cochlea** to the end, where it joins the **scala tympani,** and the pressure waves are ultimately relieved at the **round window** back in the wall of the middle ear. The vibrations also reach the **cochlear duct** (scala media) (see Figure 12.15, inset), where mechanoreceptor cilia on the **hair cells** are activated by movement of the **basilar membrane** relative to the stiff **tectorial membrane.** The hair cells form excitatory synapses onto the terminals of primary sensory neurons. These bipolar sensory neurons have their cell bodies in the **spiral ganglion,** located along the central rim of the cochlea, and send their axons into the cochlear nerve (see Figures 12.14, 12.15). The hair cells of the cochlea, together with their supporting cells, are called the **organ of Corti.** There is a **tonotopic representation** along the length of the organ of Corti such that higher-frequency sounds activate hair cells near the oval window, while lower-frequency sounds activate hair cells near the apex of the cochlea (see Figure 12.15).

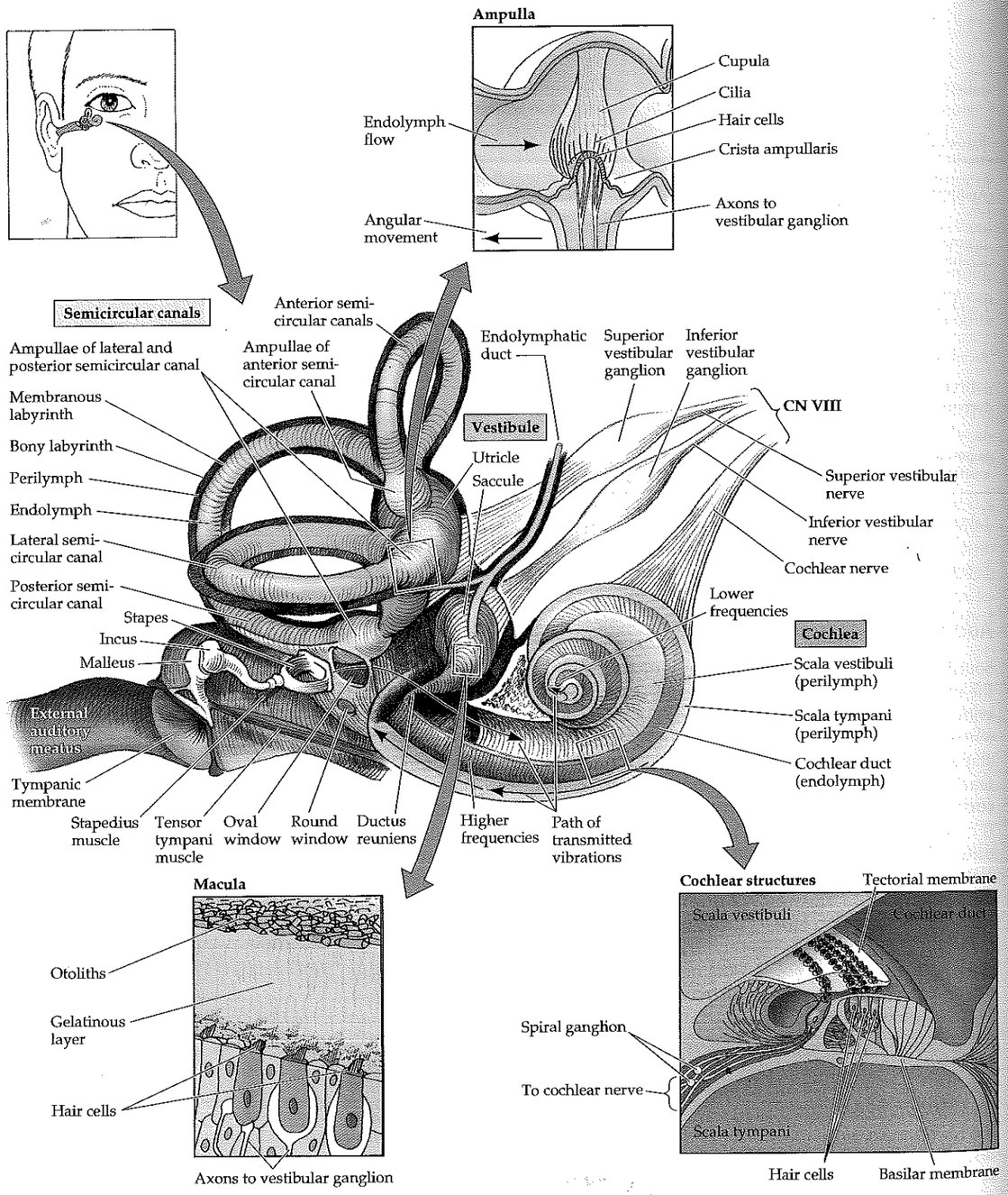

Figure 12.15 Summary of Vestibular and Cochlear Structures Sound waves enter the external auditory meatus, are transmitted mechanically by the middle ear to the cochlea, and are transduced by hair cells to neural signals carried centrally by the cochlear nerve. The ampullae of the semicircular canals detect angular acceleration, and the maculae of the otolith organs (utricle and saccule) detect linear acceleration and head tilt, and transmit this information to the vestibular nerves. (Insets from Rosenzweig MR, Breedlove SM, Leiman AL. 2002. *Biological Psychology*, 3rd Ed. Sinauer, Sunderland, MA.)

Let's follow the pathways for hearing centrally, from the cochlear nuclei to the primary auditory cortex (Figures 12.16, 12.17). Auditory information throughout these pathways is tonotopically organized. Primary sensory neurons in the **spiral ganglion** send their axons in the cochlear division of CN VIII to reach the **dorsal and ventral cochlear nuclei,** which are wrapped around the lateral aspect of the inferior cerebellar peduncle at the pontomedullary junction (see Figures 12.16, 12.17C). The hearing pathways then ascend through the brainstem *bilaterally* through a series of relays to reach the inferior colliculi, medial geniculate nuclei, and, ultimately, the auditory cortex. Because auditory information from each ear ascends bilaterally in the brainstem, with decussations occurring at multiple levels, *unilateral hearing loss is not seen in lesions in the central nervous system proximal to the cochlear nuclei.*

Fibers from the **dorsal cochlear nucleus** pass dorsal to the inferior cerebellar peduncle, cross the pontine tegmentum, and ascend in the contralateral

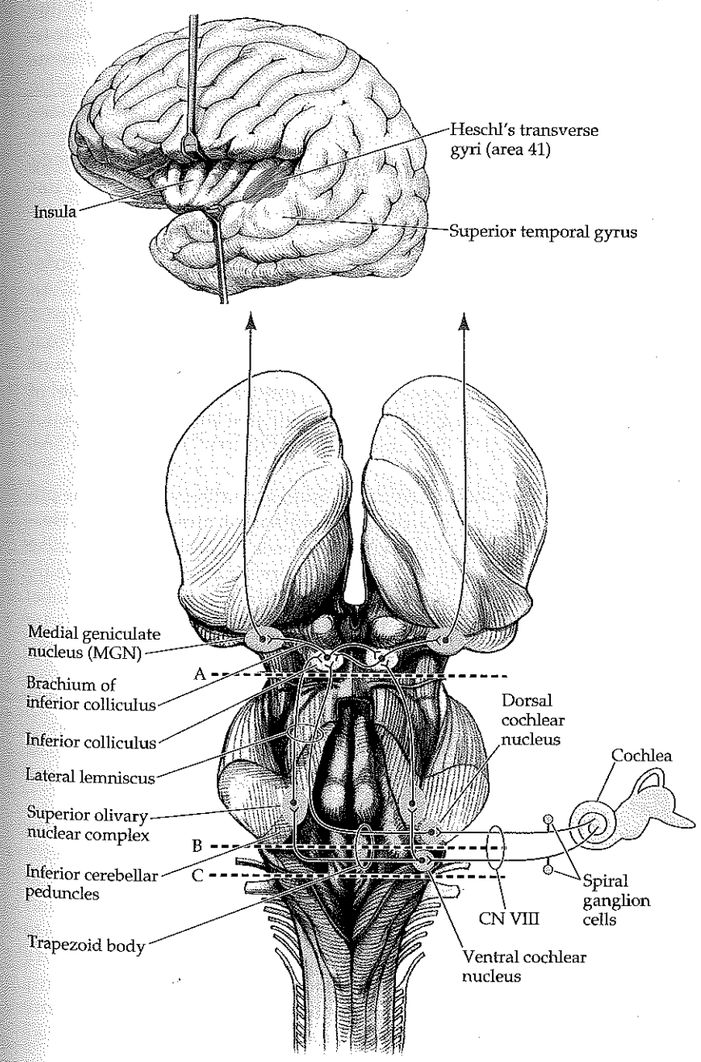

Figure 12.16 Central Auditory Pathways Main nuclei and pathways are shown from the cochlear nerve to the auditory cortex. Levels of sections for Figure 12.17 are indicated.

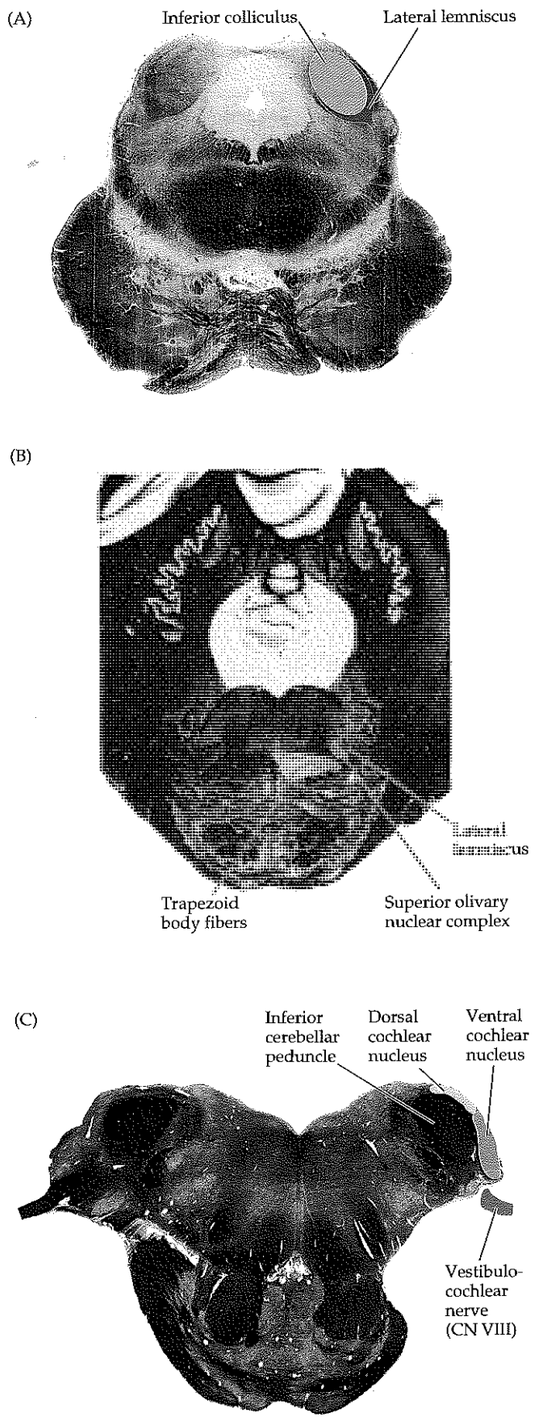

Figure 12.17 Brainstem Sections of Auditory Pathways Levels of sections are as indicated in Figure 12.16. (A) Midbrain inferior colliculi. (B) Caudal pons at the level of the superior olivary nucleus and trapezoid body. (C) Rostral medulla showing entry of cochlear (auditory) nerve to cochlear nuclei. Myelin-stained cross sections of the human brainstem. (A and B modified from Martin JH. 1996. *Neuroanatomy Text and Atlas*, 2nd Ed. McGraw-Hill, New York. C from The University of Washington Digital Anatomist Project.)

lateral lemniscus (see Figures 12.16, 12.17A,B). The lateral lemniscus is an important ascending auditory pathway in the pons and lower midbrain that terminates in the inferior colliculus. Many fibers of the **ventral cochlear nucleus** pass ventral to the inferior cerebellar peduncle to synapse bilaterally in the **superior olivary nuclear complex** of the pons (see Figures 12.16, 12.17B). The superior olivary nuclei appear to function in localizing sounds horizontally in space. Crossing auditory fibers at this level form a white matter structure called the **trapezoid body** (see Figures 12.16, 12.17B). The trapezoid body is traversed at right angles by the medial lemniscus.

From the superior olivary nuclear complex, fibers ascend bilaterally in the lateral lemniscus to reach the **inferior colliculi** of the midbrain (see Figures 12.16, 12.17A). Decussating fibers at the level of the inferior colliculi pass both dorsal and ventral to the cerebral aqueduct. From the inferior colliculi, fibers ascend via the **brachium of the inferior colliculi** to the **medial geniculate nuclei** of the thalamus, which are located just lateral to the superior colliculi of the midbrain (see Figures 11.6, 12.16, 14.3A). From this thalamic relay, information continues in the **auditory radiations** to the primary auditory cortex. The **primary auditory cortex** (Brodmann's area 41) lies on **Heschl's transverse gyri.** We can see these straight, fingerlike gyri in brain specimens by opening the Sylvian fissure and looking at the superior surface of the temporal lobe, just medial to the superior temporal gyrus (Figure 12.16; see also Figure 4.15D). The nearby areas of cortex in the temporal and parietal lobes are auditory association cortex, including Wernicke's area, which will be discussed in Chapter 19. In addition to the nuclei already mentioned, there are several smaller nuclei in the hearing pathway, including the nuclei of the trapezoid body and the nuclei of the lateral lemniscus.

As noted already, lesions in the central nervous system proximal to the cochlear nuclei do not cause unilateral hearing loss because auditory information crosses bilaterally at multiple points in the brainstem. However, auditory information ascending through the brainstem and thalamus to the auditory cortex does contain a relatively greater contribution from the contralateral ear. In auditory seizures, caused by abnormal electrical discharges in the auditory cortex, patients often perceive a tone or roaring sound like

an airplane or a train coming from the side opposite the auditory cortex involved. Bilateral damage to the auditory cortex causes cortical deafness (see KCC 19.7).

Efferent feedback pathways from the brainstem to the cochlea in the vestibulocochlear nerve modulate the sensitivity of the hair cells in response to sounds of varying intensities. In addition, reflex pathways from the ventral cochlear nuclei reach the facial and trigeminal motor nuclei to contract the stapedius and tensor tympani muscles. These muscles dampen the response of the middle ear to loud sounds.

REVIEW EXERCISE

Follow the auditory pathways from the cochlear nerve to the auditory cortex in Figures 12.16 and 12.17.

Vestibular Pathways

The **vestibular nuclei** are important for adjustment of posture, muscle tone, and eye position in response to movements of the head in space (Figure 12.18). Not surprisingly, therefore, the vestibular nuclei have intimate connections with the cerebellum, and with the brainstem motor and extraocular systems. In addition, an ascending pathway through the thalamus to the cortex provides an awareness of head position that is integrated with visual and tactile spatial information in the parietal association cortex.

The **semicircular canals** (see Figures 12.14, 12.15) detect angular acceleration around three orthogonal axes by the movement of endolymph

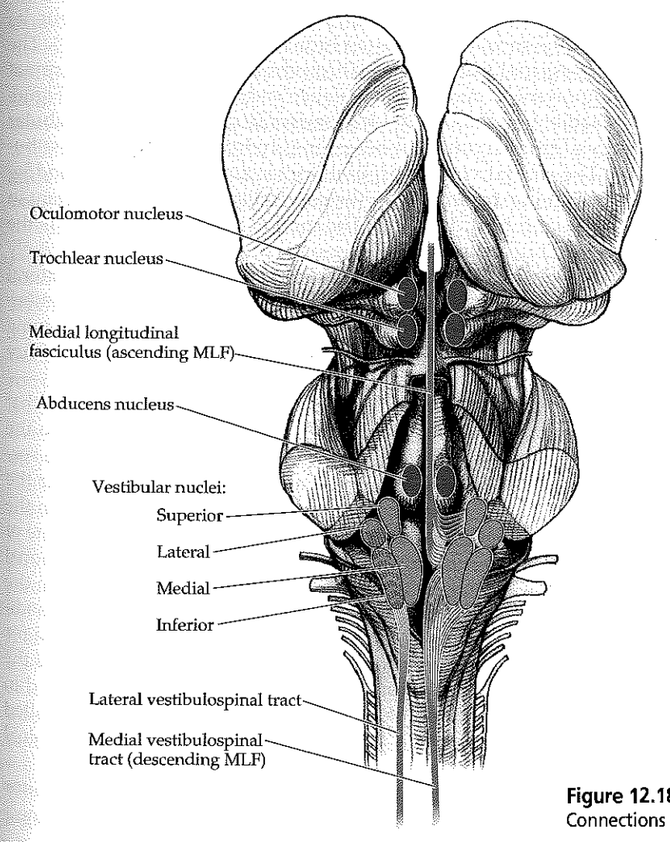

Figure 12.18 Vestibular Nuclei and Vestibular Tracts Connections with the cerebellum and forebrain are not shown.

through the **ampullae** (see Figure 12.15, inset). This fluid movement deforms the gelatinous **cupula** within which the mechanoreceptor cilia of hair cells are embedded. The hair cells are located in a ridge within each ampulla, called the **crista ampullaris.** The hair cells activate terminals of bipolar primary sensory neurons that have their cell bodies in the **vestibular ganglia of Scarpa** and send axons into the vestibular nerves (see Figure 12.15). The utricle and saccule contain structures called **maculae** that resemble the cristae ampullaris, but rather than angular acceleration, they detect linear acceleration and head tilt (see Figure 12.15, inset). The macula consists of calcified crystals called **otoliths** sitting on a gelatinous layer within which mechanoreceptor hair cells are embedded. Gravity or other causes of linear acceleration pull on the crystals and activate these hair cells. The **superior vestibular ganglion** receives input from the utricle, anterior saccule, and anterior and lateral semicircular canals. The **inferior vestibular ganglion** receives input from the posterior saccule and posterior semicircular canal.

Primary sensory neurons in the vestibular ganglia (see Figure 12.15) convey information about angular and linear acceleration from the semicircular canals and otolith organs, respectively, through the vestibular division of CN VIII to the vestibular nuclei. There are **four vestibular nuclei** on each side of the brainstem, lying on the lateral floor of the fourth ventricle, in the pons and rostral medulla (see Figure 12.18). These nuclei can also be seen in the myelin sections in Figures 14.4C and 14.5A. The **lateral vestibular nucleus** gives rise to the **lateral vestibulospinal tract,** which, despite its name, is part of the medial descending motor systems (see Table 6.3). The lateral vestibulospinal tract extends throughout the length of the spinal cord and is important in maintaining balance and extensor tone (see Figure 6.11D). The **medial vestibulospinal tract** arises from the **medial vestibular nucleus,** with additional contributions primarily from the **inferior vestibular nucleus.** The medial vestibulospinal tract is also a medial descending motor system, but it extends only to the cervical spine and is important in controlling neck and head position. The medial vestibular nucleus is the largest of the vestibular nuclei. The inferior vestibular nucleus is relatively easy to identify on myelin-stained sections because fibers of the lateral vestibular nucleus (also called Deiters' nucleus) traverse the inferior vestibular nucleus as they descend toward the spinal cord (see Figure 12.18), giving the inferior vestibular nucleus a characteristic "checkerboard" appearance (see Figure 14.5A).

MNEMONIC

The **medial longitudinal fasciculus** (**MLF**) is an important pathway that connects the nuclei involved in eye movements to each other and to the vestibular nuclei (see Figure 12.18). The MLF can be identified in the sections in Figures 14.3–14.5 as a heavily myelinated tract running near the midline on each side, just under the oculomotor and trochlear nuclei in the midbrain, and just under the floor of the fourth ventricle in the midline of the pons. Fibers arising from the **medial vestibular nucleus,** with additional contributions mainly from the **superior vestibular nucleus,** ascend in the MLF to the oculomotor, trochlear, and abducens nuclei. This pathway mediates the **vestibulo-ocular reflex,** in which eye movements are adjusted for changes in head position (see neuroexam.com Video 35). The function of the MLF in interconnecting the abducens and oculomotor nuclei is discussed in Chapter 13. In another commonly used nomenclature, what we have called the MLF is referred to as the ascending MLF, and the medial vestibulospinal tract is referred to as the descending MLF (see Figure 12.18).



Oculocephalic testing

The vestibular nuclei have numerous important reciprocal connections with the cerebellum. As we will discuss in Chapter 15, vestibular connections are mainly with the flocculonodular lobes and cerebellar vermis. These regions of the cerebellum are often called the vestibulocerebellum. A small number of primary vestibular sensory neurons bypass the vestibular nuclei and project directly to the vestibulocerebellum.

Ascending pathways from the vestibular nuclei relay in the ventral posterior nucleus of the thalamus to reach the **cerebral cortex.** These pathways are still being investigated; however, one important cortical region for vestibular sensation appears to lie in the parietal association cortex, possibly in Brodmann's area 5. ■

KEY CLINICAL CONCEPT

HEARING LOSS (CN VIII)

12.5 Unilateral hearing loss can be caused by disorders of the external auditory canal, middle ear, cochlea, eighth nerve, or cochlear nuclei (see Figures 12.14, 12.15). As we have emphasized already, once the auditory pathways enter the brainstem, information immediately crosses bilaterally at multiple levels (see Figure 12.16). Therefore, unilateral hearing loss is not caused by lesions in the central nervous system proximal to the cochlear nuclei. (Disturbances of higher-order auditory processing and auditory hallucinations are described in KCC 19.7 and 19.13.)

Hearing

Impaired hearing is usually divided into **conductive hearing loss,** caused by abnormalities of the external auditory canal or middle ear, and **sensorineural hearing loss,** usually caused by disorders of the cochlea or eighth nerve. When evaluating a patient for hearing loss, the practitioner should first examine the ears with an otoscope. Hearing can be tested with sounds of different frequencies, such as finger rubbing, whispering, or a ticking watch (see neuroexam.com Video 42). Conductive and sensorineural hearing loss can often be distinguished with a simple 256- or 512-Hz tuning fork. In the **Rinne test,** air conduction is compared to bone conduction for each ear. We measure **air conduction** by holding a vibrating tuning fork just outside each ear, and **bone conduction** by placing a tuning fork handle on each mastoid process (see neuroexam.com Video 42). Normal individuals hear the tone better by air conduction. In conductive hearing loss, bone conduction is greater than air conduction because bone conduction bypasses problems in the external or middle ear. In sensorineural hearing loss, air conduction is greater than bone conduction in both ears (as in normal hearing); however, hearing is decreased in the affected ear. In the **Weber test** the tuning fork is placed on the vertex of the skull in the midline, and the patient is asked to report the side where the tone sounds louder (see neuroexam.com Video 42). Normally, the tone sounds equal on both sides. In sensorineural hearing loss, the tone is louder on the normal side. In conductive hearing loss, the tone is louder on the affected side. You can verify this on yourself by producing temporary unilateral conductive hearing loss by closing each ear alternately. If you then hum, the tone should be louder on the occluded side.

Other tests that can help localize the cause of hearing loss include audiometry and brainstem auditory evoked potentials. An MRI scan with fine cuts through the auditory canal should be performed when disorders of the eighth nerve are suspected. Common causes of conductive hearing loss include cerumen in the external auditory canal, otitis, tympanic membrane perforation, and sclerosis of the middle ear ossicles. Causes of sensorineural hearing loss include exposure to loud sounds, meningitis, ototoxic drugs, head trauma, viral infections, aging, Meniere's disease (see KCC 12.6), cerebellopontine angle tumors, and rarely, internal auditory artery infarct (see KCC 14.3).

Cerebellopontine angle tumors include acoustic neuroma (vestibular schwannoma), meningioma, cerebellar astrocytoma, epidermoid, glomus jugulare, and metastases. The most common tumor by far in this location is

acoustic neuroma, accounting for 5 to 10% of intracranial neoplasms in adults (see Table 5.6). Mean age of onset is 50 years, and the tumor is nearly always unilateral. The exception is in neurofibromatosis type 2, in which the tumors are bilateral and usually occur before age 21. This slow-growing tumor develops at the transitional zone between Schwann cells and oligodendrocytes, which occurs at the point where CN VIII enters the internal auditory meatus (see Figures 12.3A, 12.14). The term "acoustic neuroma" is a misnomer because the tumor is actually a **schwannoma,** not a neuroma, and it nearly always arises from the vestibular, not acoustic, division of the eighth nerve. Initially the tumor grows within the bony auditory canal, but then it expands into the cerebellopontine angle (see Figure 12.2A,C). Common early symptoms are unilateral hearing loss, **tinnitus** (ringing in the ear), and unsteadiness. The next cranial nerve to be affected is usually the nearby trigeminal nerve, with facial pain and sensory loss. Often the first sign of trigeminal involvement is a subtle decrease in the corneal reflex (see KCC 12.4). Interestingly, although the vestibular and facial nerves are compressed within the auditory canal, true vertigo is not usually a prominent symptom (although some unsteadiness is common), and the facial nerve does not usually become involved until the tumor is quite large. Eventually there is facial weakness, sometimes with decreased taste sensation on the side of the tumor.

With large tumors, cerebellar and corticospinal pathways are compressed, causing ipsilateral ataxia and contralateral hemiparesis. Impairment of swallowing and the gag reflex (CN IX and X) and unilateral impaired eye movements (CN III and VI) occur only in very large tumors. Ultimately, if left untreated, the tumor will compress the fourth ventricle, causing CSF outflow obstruction, hydrocephalus, herniation, and death. With appropriate clinical evaluation and MRI scanning, acoustic nerve tumors can be detected at an early stage, when they still lie entirely within the auditory canal. Treatment has traditionally been by surgical excision. With small tumors, preservation of the facial nerve is often possible, and occasionally some hearing may even be spared in the affected ear. Recently, stereotactic radiosurgery (see KCC 16.4) has been used as an alternative to surgery for acoustic neuromas, particularly in elderly individuals.

Schwannomas can occur on other cranial nerves, as well as on spinal nerve roots, causing radiculopathy or spinal cord compression. **Trigeminal neuroma** is the second most common form of schwannoma affecting the cranial nerves. Schwannomas of the other cranial nerves are very rare. ■

KEY CLINICAL CONCEPT

DIZZINESS AND VERTIGO (CN VIII)

12.6 "Dizziness" is a vague term used by patients to describe many different abnormal sensations. In taking the history, the examiner should clarify whether the patient is referring to **true vertigo,** meaning a spinning sensation of movement, or one of the other meanings of dizziness. Other uses of "dizziness" include light-headedness or faintness, nausea, and unsteadiness on one's feet. True vertigo is more suggestive of vestibular disease than these other symptoms are. However, the situation is complicated by the fact that the other sensations listed here often accompany vertigo, and in some cases they may be the only presenting symptoms of vestibular disease.

Vertigo can be caused by lesions anywhere in the vestibular pathway, from labyrinth, to vestibular nerve, to vestibular nuclei and cerebellum, to parietal cortex. Most cases of vertigo are caused by **peripheral disorders** involving the inner ear, with **central disorders** of the brainstem or cerebellum being less common. It is essential to distinguish these possibilities because some central causes of vertigo, such as incipient brainstem stroke or posterior fossa hemorrhage, require emergency treatment to prevent serious sequelae. In taking the history of a patient with vertigo, it is therefore crucial to ask if any other symptoms suggestive of posterior fossa disease are present (see Table 14.6), such as *diplopia, other visual changes, somatosensory changes, weakness, dysarthria, incoordination, or impaired consciousness.* Patients with any of these abnormalities accompanying vertigo should be considered to have posterior fossa disease until proven otherwise and should be treated on an urgent basis. The general physical exam should always include **orthostatic** measurements of blood pressure and pulse in the supine and sitting or standing positions. Normally the systolic blood pressure drops by only about 10 millimeters of mercury, and the pulse increases by about 10 beats per minute when measured a few minutes after going from supine to a seated position with the legs dangling. Substantially greater changes suggest that the patient's symptoms may be caused by hypovolemia, antihypertensive medications, or cardiovascular or autonomic disorders, rather than by a vestibular lesion. In addition, during the general exam the tympanic membranes should be examined with an otoscope. A careful neurologic exam should be done to detect any abnormalities that may suggest a central cause for the vertigo.

Bárány or **Dix–Hallpike positional testing** is a useful part of the exam that can help distinguish peripheral from central causes of vertigo (see neuroexam.com Video 43). The patient sits on the bed or examining table. The examiner then supports the head of the patient as the patient lies back with the head turned so that one ear is down and the head extends over the edge of the table. This maneuver should be done rapidly but gently. The patient is asked to keep their eyes open and report any sensations of vertigo, while the examiner looks for nystagmus. This change of position causes maximal stimulation of the posterior semicircular canal of the ear that is down (the anterior semicircular canal of the ear that is up is probably also stimulated). The maneuver is then repeated with the other ear down.

Positional vertigo test

With **peripheral lesions** affecting the inner ear there is usually a delay of 2 to 5 seconds before the onset of nystagmus and vertigo (Table 12.7). The nystagmus is horizontal or rotatory and does not change directions while the patient remains in the same position. Nystagmus and vertigo then fade away within about 30 seconds. If the same maneuver is repeated, there is often adaptation (often called habituation or fatiguing), so that the nystagmus and vertigo are briefer and less intense each time. In contrast, with **central lesions** the nystagmus and vertigo may begin immediately, and there tends to be no adaptation (see Table 12.7). Horizontal or rotatory nystagmus can also be seen with central lesions. However, vertical nystagmus, nystagmus that changes directions while remaining in the same position, or prominent nystagmus in the absence of vertigo is seen only in central, and not in peripheral, lesions.

TABLE 12.7 Positional Testing to Distinguish Peripheral from Central Causes of Vertigo and Nystagmus

TYPE OF LESION	ONSET OF NYSTAGMUS	ADAPTATION (HABITUATION)	CHARACTERISTICS OF NYSTAGMUS AND VERTIGO
Peripheral (inner ear)	Delayed	Yes	Horizontal or rotatory, not vertical; does not change directions; prominent nystagmus only if vertigo is present as well.
Central (brainstem or cerebellum)	Immediate or delayed	No	Horizontal, rotatory, or vertical; may change directions; prominent nystagmus may occur in the absence of vertigo.

Let's briefly review a few specific peripheral and central causes of vertigo. **Benign paroxysmal positional vertigo** is possibly the most common cause of true vertigo. Patients experience brief episodes of vertigo lasting for a few seconds and occurring with change of position. When the symptom first occurs, the patient may be dizzy for several hours. However, after the first episode it is usually brief and occurs only with change of position. In some cases, the vertigo may be so intense that patients cannot walk. The presence of pieces of debris in the semicircular canals (especially the posterior canal) that push against the cupula (see Figure 12.15, inset) has been proposed as the mechanism for this disorder. Symptoms occur especially when the patient attempts to sleep and lies with the affected ear down, or if the patient turns to the affected side; however, if the patient remains still, the dizziness typically abates. Turning away from the affected ear or sitting up may also provoke symptoms. Adaptation exercises may be beneficial.

Viral infections or idiopathic inflammation of the vestibular ganglia or nerve may cause **vestibular neuritis,** a monophasic illness resulting in several days of intense vertigo and sometimes a feeling of unsteadiness that can last from weeks to months. In **Meniere's disease,** patients have recurrent episodes of vertigo, accompanied by fluctuating and sometimes stepwise, progressive hearing loss. Patients with Meniere's disease also often complain of tinnitus and a full feeling in the ear. The etiology is thought to be excess pressure in the endolymphatic system (see Figure 12.14, 12.15). Meniere's disease is most frequently treated with salt restriction and diuretics, although there have been no controlled studies of those therapies. There are multiple surgical procedures that have been effective in some patients, including vestibular nerve section, labrynthectomy, endolymphatic saculotomy (decompression), and transtympanic gentamycin (to cause permanent loss of vestibular function on the affected side). **Acoustic neuroma** (vestibular schwannoma) can also be associated with vertigo and hearing loss (see KCC 12.5). However, patients with acoustic neuroma often complain of unsteadiness rather than true vertigo, and they do not usually have discrete episodes as in Meniere's disease.

Common central causes of vertigo include **vertebrobasilar ischemia or infarct.** Involvement of the vestibular nuclei or cerebellum causes vertigo, often with other symptoms and signs of vertebrobasilar disease (see KCC 14.3; Table 14.6). It is essential to recognize this entity so that treatment is not delayed. Similarly, a small **hemorrhage** in the cerebellum or, rarely, in the brainstem may initially present mainly with vertigo and should be treated as soon as possible to prevent catastrophe. Cerebellar hemorrhage that presents initially with some nausea and dizziness, only to rebleed a few hours later, has been called "fatal gastroenteritis." **Encephalitis, tumors,** or **demyelination** in the posterior fossa can cause vertigo. In addition, numerous **drugs and toxins,** including alcohol and anticonvulsant medications, cause dysfunction of the vestibular nuclei and cerebellum, producing vertigo along with other symptoms. Ototoxic drugs such as Gentamicin cause unsteadiness of gait and oscillopsia (perception of oscillating vision) rather than true vertigo. Anemia and thyroid disorders can also produce dizziness and should be tested for in all patients complaining of vertigo where etiology is unclear. Finally, epileptic seizures (see KCC 18.2) are an uncommon cause of vertigo; however, patients with seizures involving the parietal regions responsible for motion perception may report vertigo as a manifestation of their seizures. ■

CN IX: Glossopharyngeal Nerve

Functional category:	Branchial motor	**Function:** Stylopharyngeus muscle
Functional category:	Parasympathetic	**Function:** Parasympathetics to parotid gland
Functional category:	General somatic sensory	**Function:** Sensation from middle ear, region near the external auditory meatus, pharynx, and posterior one-third of tongue
Functional category:	Visceral sensory (special)	**Function:** Taste from posterior one-third of tongue
Functional category:	Visceral sensory (special)	**Function:** Chemo- and baroreceptors of carotid body

The glossopharyngeal nerve was named for its role in sensation for the posterior tongue and pharynx; however, it has additional functions as well. It exits the brainstem as several rootlets along the upper ventrolateral medulla, just below the pontomedullary junction and just below CN VIII, between the inferior olive and the inferior cerebellar peduncle (see Figure 12.2A,C). The nerve traverses the subarachnoid space to exit the skull via the **jugular foramen** (see Figure 12.3A, B; Table 12.2).

The **branchial motor** portion of the nerve supplies one muscle, the **stylopharyngeus** (Figure 12.19), which elevates the pharynx during talking and swallowing and contributes (with CN X) to the gag reflex. There is evidence that the glossopharyngeal nerve may provide some innervation to other pharyngeal muscles; however, most pharyngeal muscles are supplied primarily by the vagus (see the next section). The branchial motor component of CN IX arises from the **nucleus ambiguus** in the medulla (see Figure 12.19). "Ambiguus" is Latin for "ambiguous," and this name can be remembered because the nucleus is difficult to discern on conventional stained sections (see Figure 14.5A,B). **Parasympathetic** preganglionic fibers in the glossopharyngeal nerve arise from the **inferior salivatory nucleus** in the pons (see Figure 12.19). These parasympathetic fibers leave the glossopharyngeal nerve via the **lesser petrosal nerve** and synapse in the **otic ganglion** to provide postganglionic parasympathetics to the **parotid gland.**

MNEMONIC

The **general visceral sensory** portion of the glossopharyngeal nerve conveys inputs from baroreceptors and chemoreceptors in the **carotid body.** These afferents travel to the **caudal nucleus solitarius** of the medulla, also known as the **cardiorespiratory nucleus** (see Figure 12.19). Glossopharyngeal **special visceral sensation** mediates **taste** for the posterior one-third of the tongue, which reaches the **rostral nucleus solitarius,** or **gustatory nucleus** (see Figures 12.5, 12.12, 12.19). **General somatic sensory** functions of CN IX are the sensation of touch, pain, and temperature from the posterior one-third of the tongue, pharynx, middle ear, and a region near the external auditory meatus (see Figure 12.7B). The glossopharyngeal nerve has two sensory ganglia located within or just below the jugular foramen (see Table 12.5). General and special **visceral sensation** are conveyed by bipolar primary sensory neurons in the **inferior (petrosal) glossopharyngeal ganglion. General somatic sensation** is conveyed by bipolar primary sensory neurons in both the inferior and **superior (jugular) glossopharyngeal ganglion.**

REVIEW EXERCISE

Which cranial nerve contributes to the greater petrosal nerve? Which contributes to the lesser petrosal nerve? (See Figure 12.6.)

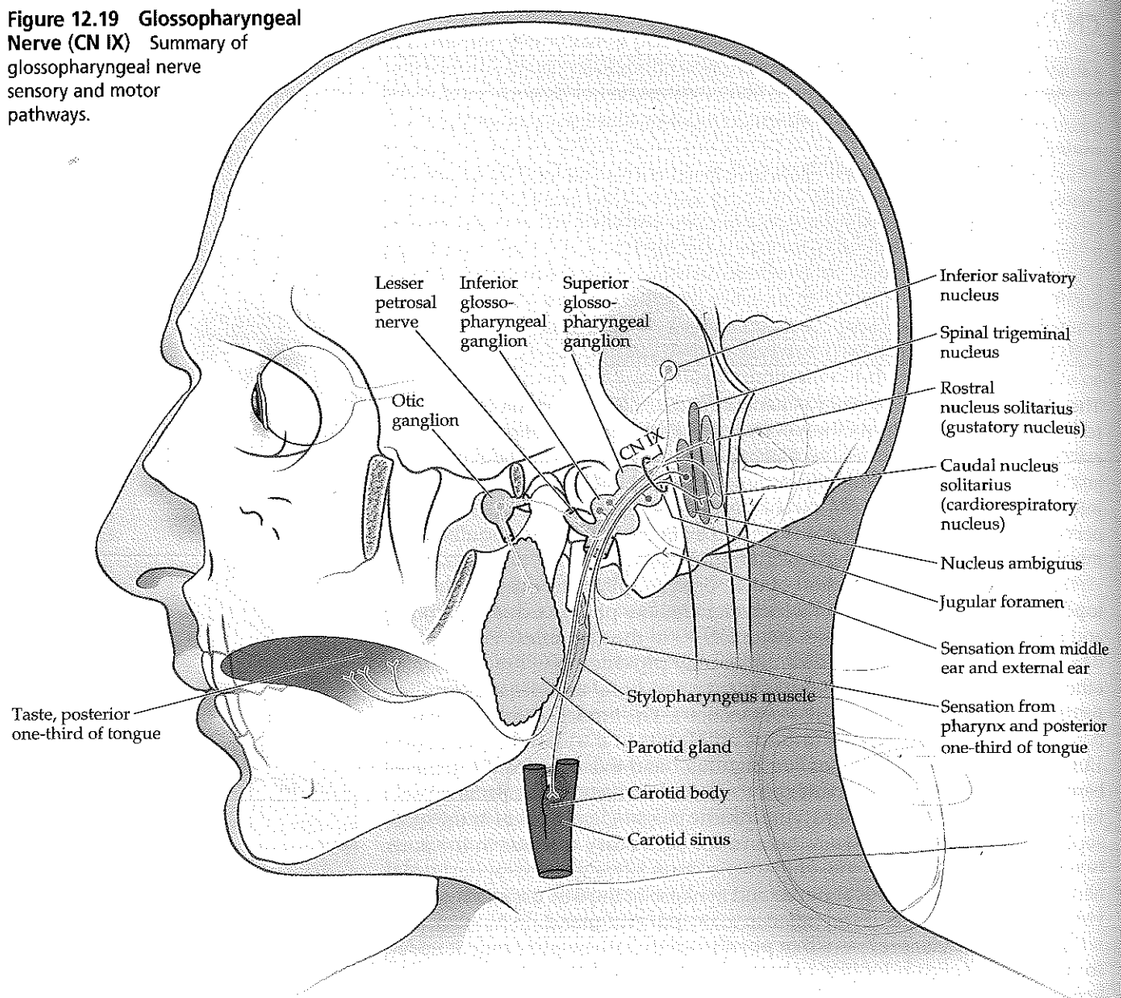

Figure 12.19 Glossopharyngeal Nerve (CN IX) Summary of glossopharyngeal nerve sensory and motor pathways.

CN X: Vagus Nerve

Functional category:	Branchial motor	**Function:**	Pharyngeal muscles (swallowing) and laryngeal muscles (voice box)
Functional category:	Parasympathetic	**Function:**	Parasympathetics to heart, lungs, and digestive tract down to the splenic flexure
Functional category:	General somatic sensory	**Function:**	Sensation from pharynx, meninges, and a small region near the external auditory meatus
Functional category:	Visceral sensory (special)	**Function:**	Taste from epiglottis and pharynx
Functional category:	Visceral sensory (general)	**Function:**	Chemo- and baroreceptors of the aortic arch

The vagus nerve derives its name from the wandering course it takes in providing parasympathetic innervation to organs throughout the body ("vagus" means "wandering" in Latin). Other important functions are also served by the vagus, as we will discuss here. The vagus nerve exits the ventrolateral medulla as several rootlets just below CN IX, between the inferior olive and the inferior cerebellar peduncle (see Figure 12.2A,C). It crosses the subarachnoid space and then leaves the cranial cavity via the **jugular foramen** (see Figures 12.3A,B, 12.20).

The largest part of the vagus nerve provides **parasympathetic** innervation to the heart, lungs, and digestive tract, extending nearly to the splenic flexure (see Figures 6.13, 12.20). Parasympathetic preganglionic fibers arise from the **dorsal motor nucleus of CN X,** which runs from the rostral to the caudal medulla (see Figure 14.5A,B). The dorsal motor nucleus of CN X forms the **vagal trigone** on the floor of the fourth ventricle, just lateral to the hypoglossal trigone, near the obex (see Figure 12.2B). Postganglionic parasympathetic neurons innervated by the vagus are found in **terminal ganglia** located within or near the effector organs. Recall that parasympathetics to the gastrointestinal tract beyond the splenic flexure, and to the urogenital system, are provided by parasympathetic nuclei in the sacral spinal cord (see Figure 6.13).

The **branchial motor** component of the vagus (Figure 12.20) controls nearly all pharyngeal muscles (swallowing and gag reflex) and the muscles of the larynx (voice box). The **nucleus ambiguus** supplies branchial motor fibers that travel in the vagus nerve to the muscles of the palate, pharynx and larynx, and in the glossopharyngeal nerve (CN IX) to the stylopharyngeus (see Figure 12.19).

A branch of the vagus called the **recurrent laryngeal nerve** (see Figure 12.20) loops back upward from the thoracic cavity to control all intrinsic laryngeal muscles except for the cricothyroid, which is innervated by another branch of the vagus, the **superior laryngeal nerve.** The fibers in the recurrent laryngeal nerve arise from the caudal portion of the nucleus ambiguus. After they exit the brainstem, these fibers travel briefly with CN XI before joining CN X (see the next section). Some texts consider these caudal fibers of the nucleus ambiguus part of CN XI and refer to the caudal nucleus ambiguus as the cranial nucleus of CN XI. However, we include these fibers with CN X because they spend the majority of their course traveling with CN X, not CN XI. Upper motor neuron innervation to the nucleus ambiguus controlling the voice and voluntary swallowing is from bilateral motor cortex (see Figure 6.2).

General somatic sensory fibers of the vagus (see Figure 12.20) supply the pharynx, larynx, meninges of the posterior fossa, and a small region near the external auditory meatus (see Figure 12.7B). Note that below the larynx and pharynx, conscious (general somatic) sensation from the viscera is carried by spinal and not cranial nerves. However, unconscious, **general visceral sensation** from chemoreceptors and baroreceptors of the aortic arch, cardiorespiratory system, and digestive tract is carried to the brainstem by the vagus nerve. Many of these general visceral afferents reach the **caudal nucleus solitarius** (cardiorespiratory nucleus; see Figures 12.5, 14.5B). The vagus nerve also contains a small number of **special visceral sensory** fibers that carry **taste** sensation from the epiglottis and posterior pharynx to the **rostral nucleus solitarius** (gustatory nucleus) (see Figures 12.5, 14.5A).

The primary sensory neuron cell bodies for CN X general and special visceral sensation are located in the **inferior (nodose) vagal ganglion** (Table 12.5), located just below the jugular foramen. Cell bodies for general somatic sensation are located in both the inferior vagal ganglion and the **superior (jugular) vagal ganglion,** which lies within or just below the jugular foramen.

REVIEW EXERCISE

List the branchial motor, parasympathetic, general somatic sensory, and visceral sensory functions of CN IX and CN X. Name the nucleus subserving each function. (See Figures 12.19 and 12.20.)

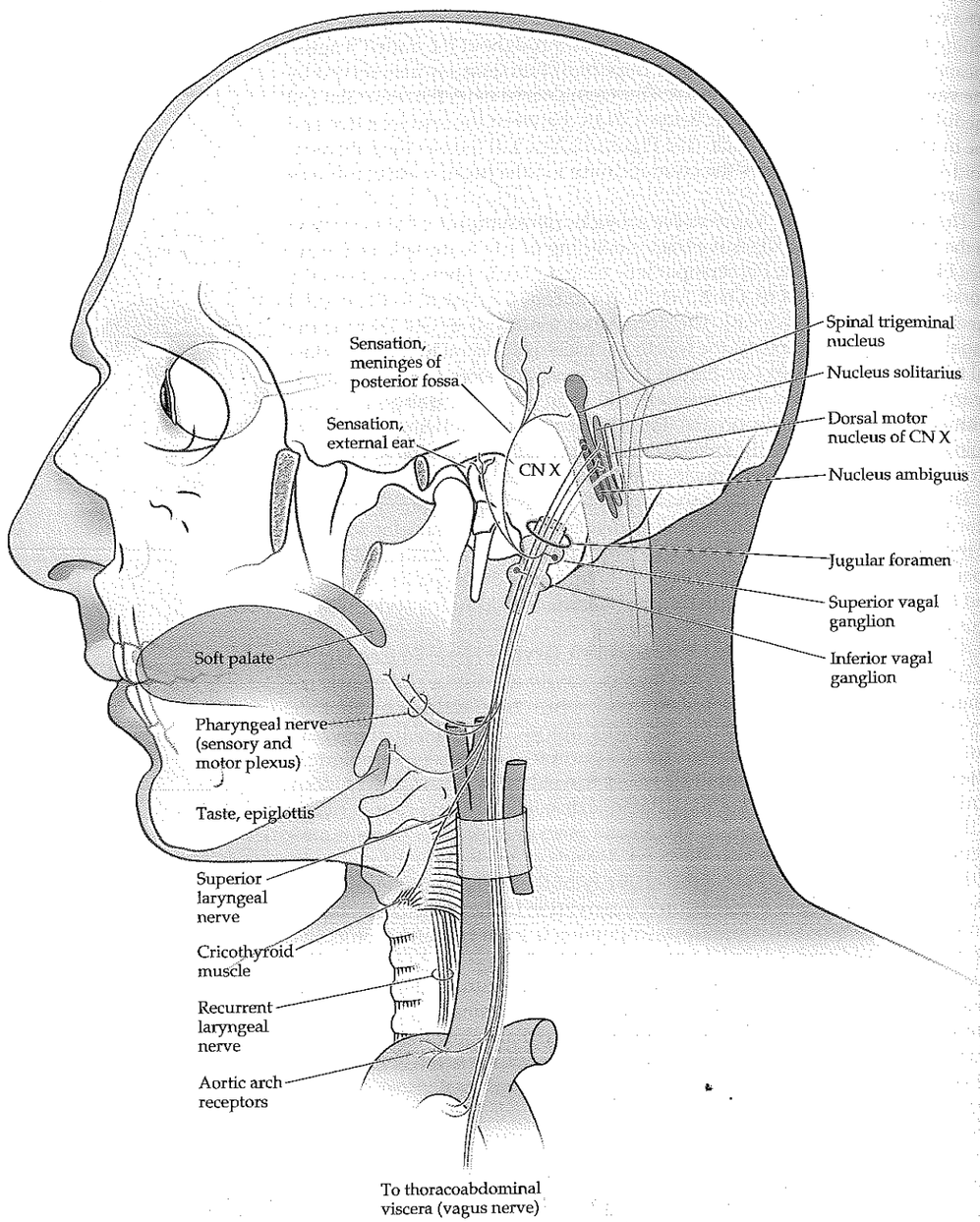

Figure 12.20 Vagus (CN X) Summary of vagal sensory and motor pathways.

CN XI: Spinal Accessory Nerve

Functional category: Branchial motor **Function:** Sternomastoid and upper part of trapezius muscle

As its name implies, this nerve does not arise from the brainstem, but rather from the upper five or six segments of the cervical spinal cord (see Figure 12.2). The **spinal accessory nucleus** (also known as the accessory spinal nucleus) protrudes laterally between the dorsal and ventral horns of the spinal cord central gray matter (see Figure 14.5D) providing **branchial motor** fibers to this nerve. Nerve rootlets leave the spinal accessory nucleus and exit the lateral aspect of the spinal cord between the dorsal and ventral nerve roots just dorsal to the dentate ligament and ascend through the foramen magnum to reach the intracranial cavity (see Figures 12.2A, 12.3A,B). CN XI then exits the cranium again via the **jugular foramen** to supply the **sternomastoid** and upper portions of the **trapezius muscle.** The sternomastoid muscle turns the head toward the opposite side, and the trapezius is involved in elevating the shoulder (see neuroexam.com Video 46). The lower portions of the trapezius are usually supplied mainly by cervical nerve roots C3 and C4.

CN XI testing

Note that the *left* sternomastoid turns the head to the *right,* and vice versa. Therefore, **lower motor neuron lesions** of CN XI may cause some ipsilateral weakness of shoulder shrug or arm elevation, and weakness of head turning *away* from the lesion. In turning the head, other neck muscles can sometimes compensate for the sternomastoid; therefore, in subtle cases, it is best to palpate the sternomastoid with one hand for contractions while the patient attempts turning their head against resistance offered by the examiner's other hand. **Upper motor neuron lesions** can also cause deficits of head turning, toward the side opposite the lesion. Therefore, it is thought that the central pathways for head turning project to the *ipsilateral* spinal accessory nucleus. However, the deficit in head turning to the side opposite the lesion in cortical lesions is often more of a gaze preference than true weakness. With upper motor neuron lesions causing contralateral hemiparesis, the shoulder shrug is also often weak on the side of the hemiparesis.

Before it exits the cranium, the spinal accessory nerve is briefly joined by some fibers arising from the caudal nucleus ambiguus that exit from the lateral medulla adjacent to the vagus nerve. These fibers rejoin the vagus within a few centimeters and ultimately form the recurrent laryngeal nerve. As noted in the previous section, because these fibers travel briefly with CN XI, some textbooks refer to them as the **cranial root of CN XI.** Despite this name, the recurrent laryngeal nerve fibers spend the majority of their course traveling with CN X and can functionally be considered part of the vagus.

CN XII: Hypoglossal Nerve

Functional category: Somatic motor **Function:** Intrinsic muscles of the tongue

The hypoglossal nerve exits the ventral medulla as multiple rootlets between the pyramid and inferior olivary nucleus (see Figure 12.2A,C). This nerve exits through its own foramen, the **hypoglossal foramen** (Figure 12.3A, B), and provides **somatic motor** innervation to all intrinsic and extrinsic tongue muscles except for the palatoglossus, which is supplied by CN X (see neuroexam.com Video 47). The **hypoglossal nucleus** is located near the midline on the floor of the fourth ventricle in the medulla (see Figure


Tongue protrusion

14.5A,B), forming the **hypoglossal trigone,** just medial to the dorsal nucleus of CN X (see Figures 12.2B, 12.4B, 12.5).

Upper motor neurons for tongue movement arise from the tongue region of the primary motor cortex (see Figure 6.2) and travel in corticobulbar pathways that decussate before reaching the hypoglossal nuclei. Therefore, lesions in the primary motor cortex or internal capsule will cause **contralateral tongue weakness,** while lesions of the hypoglossal nucleus, exiting fascicles, or nerve cause **ipsilateral tongue weakness.** Note that unilateral tongue weakness causes the tongue to deviate toward the weak side when it is protruded. Thus, a lesion of the hypoglossal nerve will cause the tongue to deviate toward the side of the lesion. ■

KEY CLINICAL CONCEPT
DISORDERS OF CN IX, X, XI, AND XII

12.7 Peripheral lesions of the lower cranial nerves are relatively uncommon. Most disorders of these cranial nerves are associated with central lesions (see Chapter 14). Like all other nerves, however, the lower cranial nerves are occasionally affected by diabetic neuropathy, demyelination, motor neuron disease, and traumatic, inflammatory, neoplastic, toxic, or infectious conditions. Let's briefly discuss a few disorders of the lower cranial nerves.

Glossopharyngeal neuralgia is clinically similar to trigeminal neuralgia but involves the sensory distribution of CN IX, causing episodes of severe throat and ear pain. Injury to the **recurrent laryngeal nerve** (a branch of CN X) can occur during surgery of the neck (such as carotid endarterectomy, cervical disc surgery, or thyroid surgery) and produces unilateral vocal cord paralysis and hoarseness (see KCC 12.8). The recurrent laryngeal nerve can also be infiltrated by apical lung tumors during its looping course through the upper thoracic cavity (see Figure 12.20), which produces hoarseness as part of Pancoast's syndrome (see KCC 9.1). **Glomus tumors** are a rare disorder that can affect the lower cranial nerves. Glomus bodies are normal small epithelioid structures that resemble the carotid bodies histologically, but whose function is unknown. Like the carotid bodies, they are richly innervated by CN IX but are located adjacent to the jugular foramen and along branches of CN IX leading to the middle ear cavity. Tumors arising from the glomus bodies are known by a variety of names, including glomus tumor and **glomus jugulare.** Patients with glomus jugulare often present with impairments of CN IX, X, and XI, resulting from compression of these nerves in the jugular foramen. In addition, the tumor often extends to the nearby CN XII and can grow upward to affect CN VIII and VII in the temporal bone. When the tumor grows into the middle ear, it can sometimes be seen on otoscopic exam as a fleshy vascular mass. Treatment is by resection, although radiation therapy is also used in some cases.

Clinical examination of CN IX through XII and the functional effects of lesions of these cranial nerves was discussed in the previous sections and is discussed in further detail in KCC 12.8. ■

REVIEW EXERCISES

1. A peripheral lesion of the left spinal accessory nerve (CN XI) causes weakness of head turning in which direction?

2. A peripheral lesion of the left hypoglossal nerve (CN XII) causes the tongue to deviate in which direction upon tongue protrusion?

KEY CLINICAL CONCEPT
HOARSENESS, DYSARTHRIA, DYSPHAGIA, AND PSEUDOBULBAR AFFECT

12.8 Disorders of speech and swallowing can be very disabling, or even fatal in some cases. Causes of these disorders can range from upper motor neuron lesions (corticobulbar pathways) to lower motor neuron lesions to disorders of the neuromuscular junction or muscles themselves, and can also result from cerebellar or basal ganglia dysfunction. Let's discuss some of the more common causes of each of these disorders.

Voice disorders occur when the larynx and **vocal cords** (more correctly called the vocal folds, or true vocal cords) are not functioning properly. Such malfunction can occur as the result of mechanical factors or neural or muscular disorders. **Hoarseness** of the voice usually results from disorders of the vocal cords causing asynchronous vibratory patterns. Hoarseness is

often caused by mechanical factors such as swelling, nodules, polyps, or neoplasms of the vocal cords. **Breathiness** of the voice is caused by paralysis or paresis of the vocal cord(s), which results in incomplete adduction of one or both of the vocal cords and an air leak at the glottis. In common language, breathiness is often called "hoarseness," although this is not strictly correct. Recall that the muscles of the larynx are innervated by the branchial motor portion of CN X. The recurrent laryngeal nerve can be injured during surgery in the neck or chest, or compressed by lung cancer as it loops through the upper thoracic cavity (see Figure 12.20). Voice disorders can also occur from lesions of CN X as it exits the brainstem, such as glomus jugulare (see KCC 12.7), or of the nucleus ambiguus in the medulla (see Figures 12.19, 12.20). The most common lesion of the medulla affecting the nucleus ambiguus is a lateral medullary infarct (see Figure 14.20D, Table 14.7). An abnormal, gravelly sounding voice can also occur in Parkinson's disease and other related movement disorders (see KCC 16.2). Spasmodic dysphonia is an uncommon form of dystonia (see KCC 16.1) involving the larynx, presumably resulting from dysfunction of basal ganglia circuitry. Vocal cord lesions or abnormal vocal cord movements can best be evaluated by **fiberoptic laryngoscopy,** in which a flexible scope is used to directly visualize the vocal cords during speech.

Dysarthria is abnormal articulation of speech (see neuroexam.com Video 45). Dysarthria should be distinguished from aphasia (see KCC 19.2). Whereas dysarthria is a motor articulatory disorder, aphasia is a disorder of higher cognitive functioning in which language formulation or comprehension is abnormal. Depending on the lesion, aphasia and dysarthria can occur together, or one can occur without the other. Dysarthria can range in severity from mild slurring to unintelligible speech. It can occur in lesions involving the muscles of articulation (jaw, lips, palate, pharynx, and tongue), the neuromuscular junction, or the peripheral or central portions of CN V, VII, IX, X, or XII. In addition, speech articulation can be abnormal because of dysfunction of the motor cortex face area (see Figure 6.2), cerebellum, basal ganglia, or descending corticobulbar pathways to the brainstem. Common causes of dysarthria include infarcts, multiple sclerosis, or other lesions affecting corticobulbar pathways (see KCC 6.3); brainstem lesions; lesions of cerebellar pathways or basal ganglia; toxins (e.g., alcohol); other causes of diffuse encephalopathy; myasthenia gravis; and other disorders of neuromuscular junction, muscle, or peripheral nerves. A few other important but less common specific causes to be aware of include amyotrophic lateral sclerosis (see KCC 6.7), botulism, and Wilson's disease.

Dysphagia is impaired swallowing. Dysphagia can be caused by esophageal strictures, neoplasms, or other local lesions, or it may have a neural or neuromuscular basis. When dysphagia is caused by neural or neuromuscular disorders, it often has the same causes as, and occurs together with, dysarthria (although dysarthria and dysphagia can occur independently as well). **Swallowing** is classically divided into four phases: the **oral preparatory phase** (preparation of the food bolus for swallowing by mastication); **oral phase** (movement of the bolus in an anterior–posterior direction by the oral tongue); **pharyngeal phase** (propulsion of the bolus through the pharynx by base-of-tongue driving force, aided by anterior–superior movement of the larynx); and the **esophageal phase** (opening of the upper esophageal sphincter, esophageal peristalsis, and emptying into the stomach). Thus, dysphagia can be caused by dysfunction of muscles of the tongue, palate, pharynx, epiglottis, larynx, or esophagus; by lesions of CN IX, X, XII, or their nuclei; or by dysfunction at the neuromuscular junction; or in the descending corticobulbar pathways.

Impaired oral and pharyngeal swallowing function and impaired reflex closure of the entrance to the trachea by the epiglottis and laryngeal muscles can lead to aspiration of food, and esophageal reflux can lead to aspiration of gastric secretions into the lungs. **Aspiration pneumonia,** caused by impaired swallowing function, is difficult to treat and is a common cause of death in disorders of the nervous system. Pharyngeal reflexes can be tested by the **gag reflex.** This reflex is elicited by stroking of the posterior pharynx with a cotton-tipped swab. The gag reflex is mediated by sensory and motor fibers from both CN IX and X, although CN IX may be more important for the afferent limb, while CN X provides primarily the efferent limb. Although an impaired gag reflex may be indicative of impaired motor or sensory function of the pharynx, its absence or presence is not absolutely predictive of aspiration risk.

A simple way to assess soft palate function is to observe **palate elevation** with a penlight while asking the patient to say, "Aah" (see neuroexam.com Video 44). In unilateral lesions of CN X or of the nucleus ambiguus, the uvula and soft palate will deviate toward the normal side, while the soft palate on the abnormal side hangs abnormally low, producing the **stage curtain sign.**

Brainstem nuclei involved in laughing and crying include CN VII, IX, X, and XII. Lesions of corticobulbar pathways in the subcortical white matter or brainstem can occasionally produce a bizarre syndrome called **pseudobulbar affect.** Patients with this syndrome exhibit uncontrollable bouts of laughter or crying without feeling the usual associated emotions of mirth or sadness. Pseudobulbar affect may be likened to an "upper motor neuron" disorder in which there is abnormal reflex activation of laughter and crying circuits in the brainstem, leading to **emotional incontinence.** The term **pseudobulbar palsy** is sometimes used to describe dysarthria and dysphagia caused by lesions not of the brainstem (bulb), but rather of the upper motor neuron fibers in the corticobulbar pathways (hence "pseudo"). Another neurologic cause of episodes of inappropriate laughter is a rare seizure disorder called **gelastic epilepsy,** which is usually associated with hypothalamic lesions (hypothalamic hamartoma) but can occasionally be seen in temporal lobe seizures (see KCC 18.2). ■

Review: Cranial Nerve Combinations

The preceding material is quite detailed, yet as we will see, it has numerous important clinical applications. Let's review several functional combinations to help consolidate the details of cranial nerve anatomy and to clarify some regional aspects of sensory and motor function. Functional combinations involving the eye muscles will be discussed in Chapter 13.

1. **Sensory and motor innervation of the face:** Sensation is provided by the trigeminal nerve (CN V), while movement of the muscles of facial expression is provided by the facial nerve (CN VII).

2. **Taste and other sensorimotor functions of the tongue and mouth:** The anterior two-thirds and posterior one-third of the tongue are derived from different branchial arches and therefore have different innervation. For the anterior two-thirds of the tongue, taste is provided by the facial nerve (CN VII, chorda tympani), while general somatic sensation is provided by the trigeminal nerve (V_3, mandibular division). For the posterior one-third of the tongue, both taste and general somatic sensation are provided by the glossopharyngeal nerve (CN IX). Taste for the epiglottis and posterior pharynx is provided by the vagus nerve (CN X). General sensation for the teeth, nasal sinuses, and inside of the mouth, above the pharynx and above the posterior one-third of the tongue, is provided by the trigeminal nerve (CN V).
3. **Sensory and motor innervation of the pharynx and larynx:** For the pharyngeal **gag reflex,** general somatic sensation is provided by both the glossopharyngeal and the vagus nerves (CN IX and X), but branchial motor innervation is provided mainly by the vagus (CN X). For the larynx, the vagus provides both sensory and motor innervation. General somatic sensation for organs below the level of the larynx is provided by the spinal nerves.
4. **Sensory and motor innervation of the ear:** General somatic sensation for the middle ear and inner tympanic membrane is provided by the glossopharyngeal nerve (CN IX), while sensation for the external ear and outer surface of the tympanic membrane is provided by the trigeminal (V_3, mandibular branch), facial (CN VII), glossopharyngeal (CN IX), and vagus (CN X) nerves (see Figure 12.7B). Hearing and vestibular sense travel in the vestibulocochlear nerve (CN VIII). Branchial motor innervation for the tensor tympani comes from the trigeminal nerve (CN V), while innervation for the stapedius comes from the facial nerve (CN VII). An aid to remembering this information is the fact that "tensor tympani" and "trigeminal" start with the letter "T," while "stapedius" and cranial nerve "seven" start with "S." Similarly, the tensor veli palatini is supplied by the trigeminal nerve, while all other muscles of the soft palate are supplied by the vagus.
5. **Sensation from the meninges:** Sensation from the supratentorial dura mater is carried by the trigeminal nerve (CN V), while the dura of the posterior cranial fossa is supplied by the vagus (CN X) and by the upper cervical nerve roots.
6. **General visceral sensation:** Unconscious, general visceral sensation from baroreceptors and chemoreceptors is carried by the glossopharyngeal nerve (CN IX) for the carotid body and sinus, and by the vagus nerve (CN X) for the aortic arch and other thoracoabdominal viscera.

Additional understanding of cranial nerve combinations will be gained through clinical practice.

MNEMONIC

REVIEW EXERCISES

1. For each cranial nerve (I through XII) state its exit point from the brainstem (see Figure 12.2), and its exit point from the cranium (see Figure 12.3, Table 12.2).

2. Now it's time to go for broke: For each cranial nerve, list each sensory and motor category, and all associated functions (see Table 12.4).

CLINICAL CASES

CASE 12.1 ANOSMIA AND VISUAL IMPAIRMENT*

MINICASE

A 51-year-old man began having difficulty reading over the course of 5 to 6 weeks. He saw his doctor, and on review of systems it was noted that he had **lost his sense of smell** about 3 years earlier. On exam, he had a visual acuity of 20/20 in the right eye and **20/40 in the left eye.** He was **unable to smell coffee or soap with either nostril.**

LOCALIZATION AND DIFFERENTIAL DIAGNOSIS

1. On the basis of the symptoms and signs shown in **bold** above, where is the lesion?
2. What is the most likely diagnosis, and what are some other possibilities?

Discussion

1. The key symptoms and signs in this case are:
   - **Bilateral anosmia**
   - **Difficulty reading and left decreased visual acuity**

   The anosmia could be caused by bilateral lesions of the olfactory mucosa or the olfactory nerves, bulbs, or tracts (see KCC 12.1). Decreased acuity in the left eye is consistent with a disorder in the left eye or the left optic nerve (see KCC 11.2). Deficits of CN I and CN II together suggest a lesion at the base of the frontal lobes, where these two cranial nerves briefly run in proximity (see Figure 18.6) before CN II exits the cranium via the optic canal (see Figure 12.3A). It is also possible that the anosmia is an unrelated incidental finding.

   The most likely *clinical localization* is bilateral orbital frontal areas.
2. Given the prolonged course, a slow-growing tumor at the base of the frontal lobes such as a meningioma should be suspected. Other tumors or chronic inflammatory disorders in this region are also possible, but less likely.

Clinical Course and Neuroimaging 506

The patient underwent a **brain MRI** (Figure 12.21B,C). Figure 12.21A shows a normal MRI demonstrating the anatomical structures at the base of the frontal lobes. With the labels covered, identify the olfactory bulbs, olfactory sulcus, gyrus rectus, and cribriform plate. The images of our patient in this case, taken with gadolinium enhancement, are shown in Figure 12.21B and C. An enhancing mass at the base of the frontal lobes extends along the dural surface in the region of the olfactory bulbs and erodes through the cribriform plate into the upper nasal passages (see Figure 12.21B). The mass also extends back to encase the left optic nerve (see Figure 12.21C). On the basis of its appearance and the patient's history, it was felt that this was most likely a meningioma, although the irregular borders of the lesion that appeared to infiltrate adjacent structures were somewhat unusual for a meningioma. A biopsy of the mass was performed through the nose, via a transethmoidal approach. Interestingly, pathology revealed noncaseating granulomas consistent with sarcoidosis (see KCC 12.1). Additional workup supported the diagnosis of sarcoidosis confined to the nervous system. The patient was treated with steroids, and his vision improved in the left eye, but he remained unable to smell.

*This patient was described previously as a case report in *The New England Journal of Medicine,* Volume 335, pp. 1668–1674, 1996.

CASE 12.2 CHEEK NUMBNESS AND A BULGING EYE

MINICASE

A 51-year-old woman saw an ophthalmologist because she noticed that her left eye seemed to be bulging out increasingly for the past 3 to 4 years, and she had recently developed **left-sided headaches.** Exam was normal except for an **outward bulging of her left eye (proptosis)** and **decreased sensation to touch and pinprick over her left cheek.**

LOCALIZATION AND DIFFERENTIAL DIAGNOSIS

1. Which division of which cranial nerve provides sensation to the cheek? Where does this nerve exit the skull?
2. What diagnosis is suggested by the slowly developing left proptosis over the course of several years, together with the cheek sensory deficit and left-sided headache?

Discussion

1. The key symptoms and signs in this case are:
   - **Left-sided headaches**
   - **Left proptosis**
   - **Decreased sensation to touch and pinprick over the left cheek**

   The maxillary division of the trigeminal nerve (CN V_2) provides sensation to the cheek (see Figure 12.7). This branch of the trigeminal nerve exits the skull through the foramen rotundum (see Figures 12.3, 12.7; Table 12.2).
2. The history and exam findings suggest a slow-growing mass lesion such as a meningioma (see KCC 5.8) involving the left foramen rotundum area causing V_2 sensory loss, and extending into the left orbit, causing proptosis.

Clinical Course and Neuroimaging 506

The patient underwent an **MRI scan** with gadolinium enhancement (Figure 12.22) that revealed an enhancing mass lying outside the brain in the region of the left foramen rotundum (compare Figure 12.3A) and extending into the left orbit. This appearance was felt to be consistent with a meningioma (see KCC 5.8). Because of concern that the mass would soon lead to impaired vision in the left eye, the patient was referred to a neurosurgeon. A left frontotemporal craniotomy was performed (see KCC 5.11), and a firm grayish reddish mass was carefully dissected off the sphenoid wing and removed from the orbit. Pathologic examination confirmed the diagnosis of meningioma. Postoperatively the patient did well, and she had no further problems.

CASE 12.1 ANOSMIA AND VISUAL IMPAIRMENT

Figure 12.21 Mass in Orbital Frontal Region T1-weighted MRI images with intravenous gadolinium enhancement. (A) Coronal image from a normal patient showing relation of olfactory bulbs to the frontal lobes, and cribriform plate. (B, C) Coronal images from patient in Case 12.1, with B and C progressing from anterior to posterior.

(A)

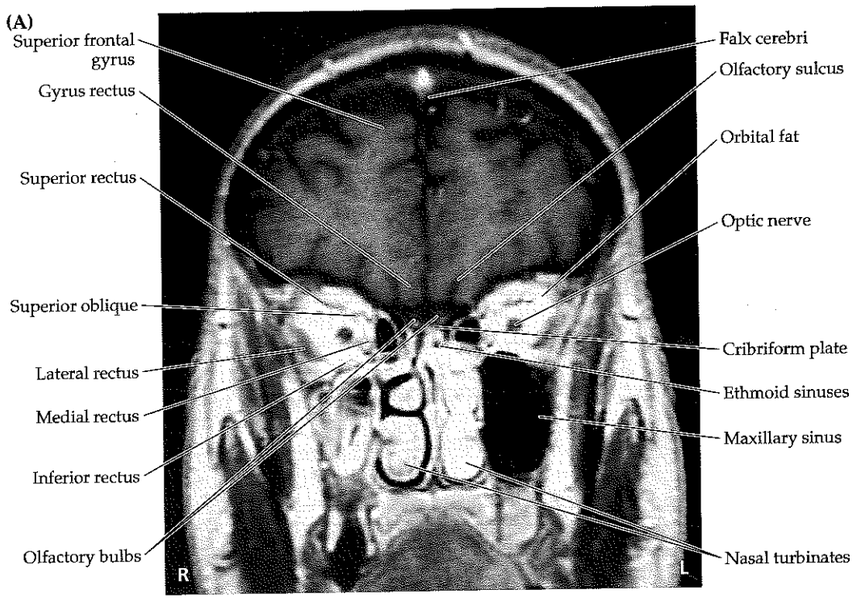

(B)

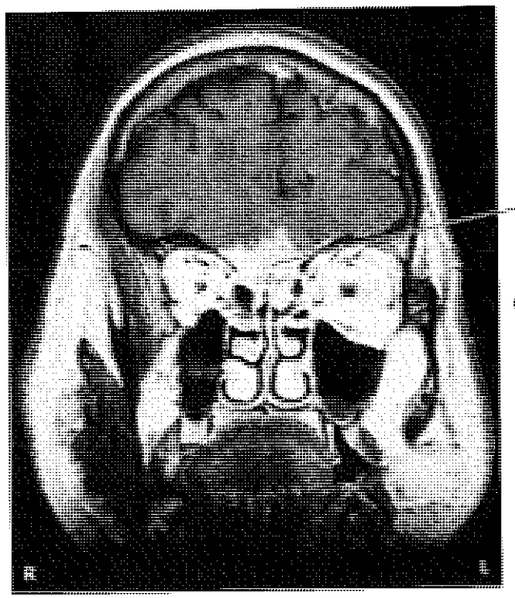

CASE 12.1 *(CONTINUED)*

(C)

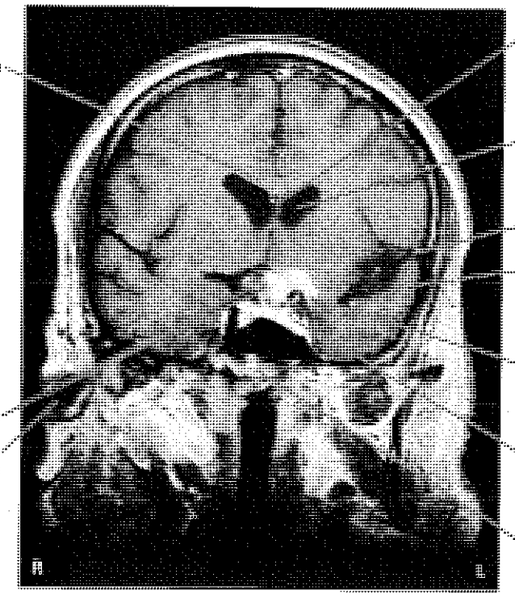

CASE 12.2 CHEEK NUMBNESS AND A BULGING EYE

Figure 12.22 Meningioma in Region of Left Foramen Rotundum
Axial T1-weighted MRI with intravenous gadolinium contrast enhancement.

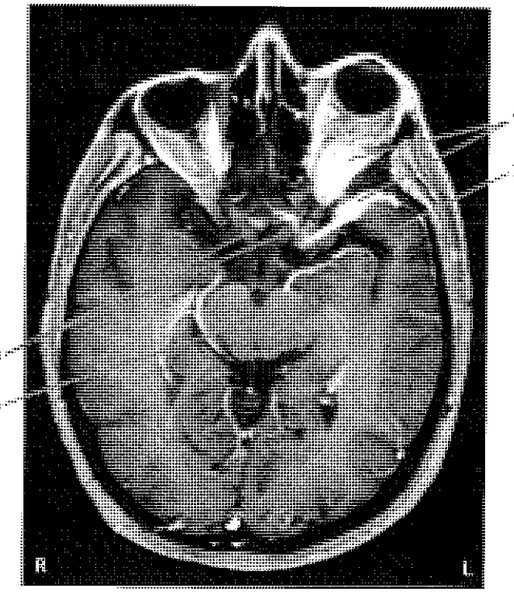

CASE 12.3 JAW NUMBNESS AND EPISODES OF LOSS OF CONSCIOUSNESS

MINICASE

A 24-year-old woman was admitted to the cardiology service after an episode of syncope. Upon further probing, it was found that the patient had had three prior episodes of loss of consciousness over recent years, during which she was **unresponsive for a few minutes,** had some poorly described **shaking movements, and was then confused for up to a half an hour.** On review of systems, the patient described a patch of numbness over her left jaw that had been present for approximately 2 years. Exam was normal except for **decreased light touch, pinprick, and temperature sensation in the left jaw and lower face** (Figure 12.23).

LOCALIZATION AND DIFFERENTIAL DIAGNOSIS

1. On the basis of the symptoms and signs shown in **bold** above, where is the lesion?
2. What is the most likely diagnosis, and what are some other possibilities?



Figure 12.23 Region of Decreased Sensation

Discussion

1. The key symptoms and signs in this case are:
   - **Decreased light touch, pinprick, and temperature sensation in the left jaw and lower face**
   - **Episodes of unresponsiveness lasting for a few minutes, with shaking movements, followed by confusion for up to a half an hour**

   The patient's sensory loss was in the distribution of the mandibular division of the trigeminal nerve (CN V_3; see Figure 12.7B). A lesion near the foramen ovale or of the mandibular division of CN V could, therefore, explain this deficit (see Figures 12.3A, 12.7A). Brief episodes of unresponsiveness can have numerous causes (see KCC 10.3; Table 10.2). Over 90% of cases are non-neurologic in origin and are caused by transient hypotension (vasovagal syncope), cardiac arrhythmias, or other medical conditions. However, patients with cardiogenic syncope typically recover immediately after the episode ends. Persistent deficits, such as the confusion seen in our patient, suggest a neurologic cause such as seizures (see KCC 18.2), vertebrobasilar transient ischemic attack (see KCC 10.3, 14.3), or vertebrobasilar migraine (see KCC 5.1). The shaking reported in this patient is suggestive of seizures, although a better description would have been helpful. One way to unify this patient's findings into a single diagnosis would be to postulate a mass lesion near the left foramen ovale that extends to the adjacent left medial temporal lobe, causing seizures. We will see in Chapter 18 that the limbic structures of the temporal lobes are especially prone to epileptic seizures.
2. Possible causes of a lesion in the vicinity of the foramen ovale and medial temporal lobe include metastases, meningioma, trigeminal neuroma, aneurysm of the petrous segment of the internal carotid artery, or sarcoidosis (see KCC 12.1, 12.2).

Clinical Course and Neuroimaging 510

The patient underwent both an **MRI** and a **CT scan** of the head (Figure 12.24). Figure 12.24A is an axial proton density–weighted MRI image showing a roundish mass compressing the left medial temporal lobe, lying in the path of CN V in Meckel's cave. Figure 12.24B is a coronal T1-weighted MRI image with gadolinium showing enhancement of the mass and extension downward through the foramen ovale. The "dumbbell" shape of this mass, extending through a bony foramen is typical of a schwannoma (see KCC 12.5). Figure 12.24C is an axial CT scan image, using bone windows to demonstrate erosion of the mass through the temporal bone in the region of the left foramen ovale. The mass appeared to lie outside the substance of the brain and was felt to represent a schwannoma (trigeminal neuroma), meningioma, or giant aneurysm. The patient was started on anticonvulsant medications, and an angiogram was done, but no aneurysm was visualized. Therefore, she underwent a left frontotemporal craniotomy, and a tannish white mass was identified under the left temporal lobe. The tumor was carefully removed in a 10-hour operation, with care taken not to damage adjacent cranial nerves or blood vessels. Pathologic examination was consistent with a schwannoma. Postoperatively the patient made an excellent recovery, with no further seizures, but she had persistent numbness of the left jaw.

CASE 12.4 ISOLATED FACIAL WEAKNESS

MINICASE

A 26-year-old woman developed **pain behind her left ear** one evening. When she looked in the mirror the next morning, she noticed that her **left face was drooping.** In addition, her **left ear was sensitive to loud sounds.** She saw her physician, who gave her some medication for the pain, but over the next 2 days her **left eye developed a "scratchy" painful sensation,** so she came to the emergency room. Exam was notable for marked **left facial weakness, including the forehead.** Taste was not tested. The remainder of the exam was normal.

LOCALIZATION AND DIFFERENTIAL DIAGNOSIS

1. On the basis of the symptoms and signs shown in **bold** above, where is the lesion?
2. What is the most likely diagnosis, and what are some other possibilities?

Discussion

1. The key symptoms and signs in this case are:
   - **Left retroauricular pain, hyperacusis, and facial weakness including the forehead**
   - **Painful, scratchy sensation in left eye**

   This patient had lower motor neuron–type facial weakness (see Figure 12.13), together with hyperacusis and retroauricular pain on the left side. These findings are compatible with a lesion of the left facial nerve affecting branchial motor and general somatic sensory function (see Table 12.4; Figures 12.7B, 12.10).

   The painful, scratchy eye is a bit of a puzzle. However, patients with a facial nerve lesion may have parasympathetic involvement (see Figure 12.10) causing decreased lacrimation; also they are often not able to completely close the affected eye, especially while they are sleeping, which can lead to corneal desiccation and corneal ulcers.
2. The time course, retroauricular pain, and lack of other medical problems or other findings on exam make Bell's palsy the most likely diagnosis. For some other, less likely possibilities, see KCC 12.3.

Clinical Course

The patient was examined by an ophthalmologist but did not have corneal damage. She was given lubricating eyedrops and instructed to tape her left eyelid shut at night. In addition, she was treated with a brief course of oral steroids. Lyme titer, antinuclear antibody (ANA), and venereal disease research laboratory (VDRL) tests were undertaken and were negative. When

the patient was seen in follow-up 1 month later, her facial weakness had completely resolved. She also no longer had ear pain or hyperacusis.

Related Case. A CT scan from another patient with left facial weakness including the forehead is shown in Figure 12.25 (page 514). This patient was a 19-year-old woman who fell off the back of a pickup truck, striking her occiput on the pavement without loss of consciousness. In addition to left lower motor neuron–type facial weakness, her exam was notable for left hemotympanum (see Table 3.9) and decreased taste on the left side of the tongue (tested by use of a cotton swab and mustard; see neuroexam.com Video 41). Figure 12.25 shows CT scan sagittal reconstructions, which allow the course of CN VII to be followed through the temporal bone from medial to lateral. Note the presence of blood in the middle ear, and several fractures of the temporal bone. At the time of discharge, this patient's facial weakness was unchanged, and she did not return for follow-up.

CASE 12.3 JAW NUMBNESS AND EPISODES OF LOSS OF CONSCIOUSNESS

Figure 12.24 Trigeminal Schwannoma Eroding through Left Foramen Ovale (A) Axial proton density–weighted MRI image. (B) Coronal T1-weighted image with intravenous gadolinium. (C) Axial CT scan image using bone windows.

(A)

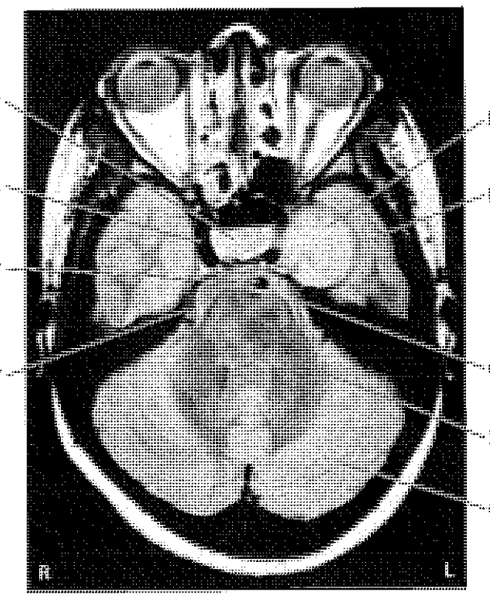

CASE 12.3 *(CONTINUED)*

(B)

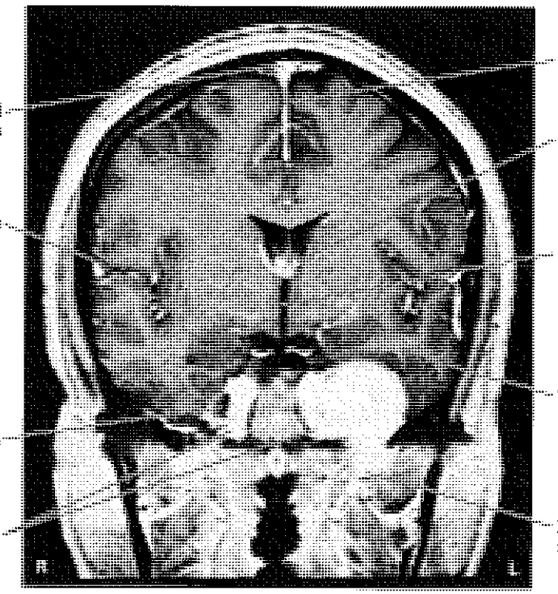

(C)

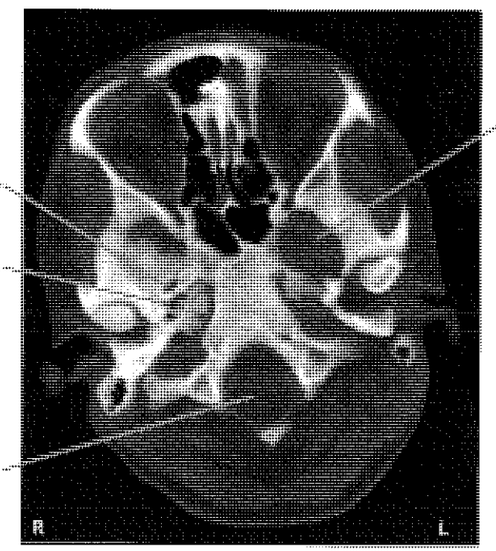

CASE 12.5 HEARING LOSS AND DIZZINESS

CHIEF COMPLAINT

A 41-year-old woman was referred to an otolaryngologist for **dizziness and progressive hearing loss in the left ear.**

HISTORY

One year ago the patient began having episodes of mild dizziness, which felt like the room was spinning when she moved her head. Two months ago she noticed greatly reduced hearing in her left ear, making it impossible to use the telephone receiver unless it was on her right ear. In addition, she had some left facial pain and decreased taste on the left side of her tongue. Past medical history was notable for a melanoma resected from the right hip region 6 months previously, with one positive lymph node.

PHYSICAL EXAMINATION

Vital signs: T = 99.1°F, P = 72, BP = 110/80, R = 12.
Ears: Normal otoscopic exam of the external auditory canals and tympanic membranes.
Neck: Supple.
Lungs: Clear.
Heart: Regular rate with no murmurs or gallops.
Abdomen: Benign.
Extremities: No edema.
Dermatologic: No skin lesions.
Neurologic exam:
MENTAL STATUS: Alert and oriented × 3. Mildly anxious, but otherwise normal.
CRANIAL NERVES: Pupils equal round and reactive to light. Normal fundi. Visual fields full. Extraocular movements intact. Facial sensation intact to light touch, but **decreased corneal reflex on the left.** Face symmetrical. **Hearing greatly diminished to finger rub or whispering in the left ear. A vibrating tuning fork sounded louder when held just outside the left ear than when the handle was touched to the left mastoid process (air conduction greater than bone conduction).** Taste was not tested. Voice and palate elevation normal. Sternomastoid strength normal. Tongue midline.
MOTOR: Normal tone. 5/5 power throughout.
REFLEXES:

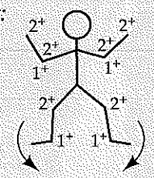

COORDINATION: Normal on finger-to-nose and heel-to-shin testing.
GAIT: Normal.
SENSORY: Intact pinprick, vibration, and joint position sense.

LOCALIZATION AND DIFFERENTIAL DIAGNOSIS

1. On the basis of the symptoms and signs shown in **bold** above, where is the lesion?
2. What is the most likely diagnosis, and what are some other possibilities?

Discussion

1. The key symptoms and signs in this case are:
   - **Decreased hearing in the left ear, with air conduction greater than bone conduction**
   - **Episodes of mild dizziness**
   - **Left facial pain and decreased left corneal reflex**
   - **Decreased taste on the left side of the tongue**

   The patient had hearing loss with a sensorineural pattern that localized to the left cochlea or the left vestibulocochlear nerve (see KCC 12.5). Episodic dizziness can be caused by dysfunction anywhere in the pathways of vestibular sensation, including the labyrinth, vestibular ganglia, CN VIII, vestibular nuclei, or parietal cortex (see KCC 12.6). Given the sensorineural hearing loss, however, the dizziness is probably also caused by a problem in the left inner ear or CN VIII. Similarly, left facial pain (CN V), decreased corneal reflex (CN V_1 or CN VII; see KCC 12.4) and decreased taste (CN VII) could each result from peripheral lesions of the respective cranial nerves, or from lesions in the left brainstem. Since unilateral hearing loss must be caused by a lesion outside of the brainstem (see KCC 12.5), the most parsimonious explanation is a lesion in the left cerebellopontine angle, where CN V, VII, and VIII all lie in close proximity (see Figure 12.2A,C).

   The most likely *clinical localization* is CN V, VII, and VIII in the left cerebellopontine angle.
2. The most common lesion of the cerebellopontine angle is acoustic neuroma (see KCC 12.5). Our patient in this case recently had a melanoma, so metastases should also be considered, especially since melanoma often metastasizes to the brain. Other, less likely possibilities include meningioma, epidermoid, and glioma. Meniere's disease (see KCC 12.6) could account for hearing loss and dizziness, but not for this patient's abnormalities of CN V and VII.

Clinical Course and Neuroimaging ⊞

The otolaryngologist ordered a **brain MRI** with gadolinium and special thin cuts through the region of the internal auditory canal (Figure 12.26). In these T1-weighted images, an enhancing mass can be seen in the left cerebellopontine angle. The mass appears to lie entirely outside of the brainstem and has a lateral knob extending into the left internal auditory meatus in the petrous portion of the temporal bone. These findings are highly suggestive of an acoustic neuroma (vestibular schwannoma; see KCC 12.5).

The patient was referred to a neurosurgeon and admitted for removal of the tumor. As is often the case with this kind of surgery, the procedure was a collaboration between neurosurgery and otolaryngology. The left occipital bone was opened behind the transverse sinus, the dura was opened, and the left cerebellar hemisphere was gently retracted to reveal the tumor. The tumor was carefully dissected away from the adjacent cerebellum; pons; CN V, VII, IX, and X; and branches of the posterior inferior cerebellar artery (see Figure 15.2). The functioning of the facial nerve was monitored continuously during the resection by use of a stimulating electrode placed on CN VII and by EMG (electromyography; see KCC 9.2) leads placed in the orbicularis oculi and labial muscles. Thus, although the facial nerve was severely distorted by the tumor, its function was preserved. CN VIII, however, was sacrificed because it was completely encapsulated by tumor, resulting in unilateral deafness. The pathology report confirmed schwannoma. Postoperatively the patient suffered from vertigo (see KCC 12.6) and had nystagmus at rest for 1 to 2 days, which then resolved. She also had complete left facial paralysis that resolved over the course of several months, and she subsequently did well.

CASE 12.4 RELATED CASE

Figure 12.25 Left Temporal Bone Fracture in Region of Facial Canal Reconstructed sagittal CT scan images through the left temporal bone, with (A) through (D) progressing from medial to lateral.

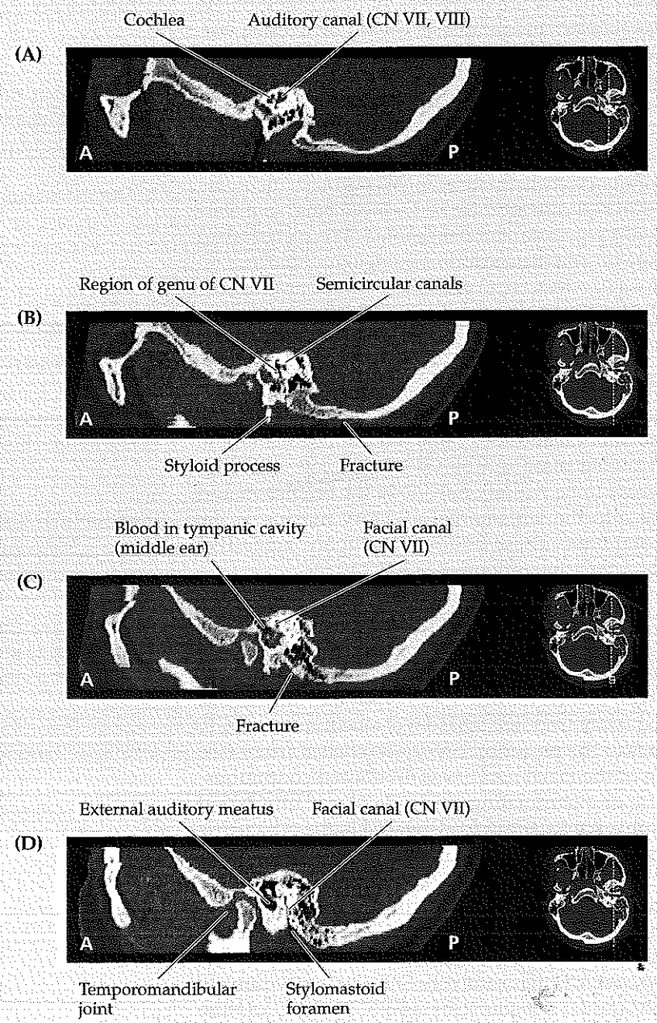

CASE 12.5 HEARING LOSS AND DIZZINESS

Figure 12.26 Left Acoustic Neuroma (Vestibular Schwannoma) Axial T1-weighted MRI images with intravenous gadolinium contrast. (A) and (B) are adjacent sections progressing from inferior to superior.

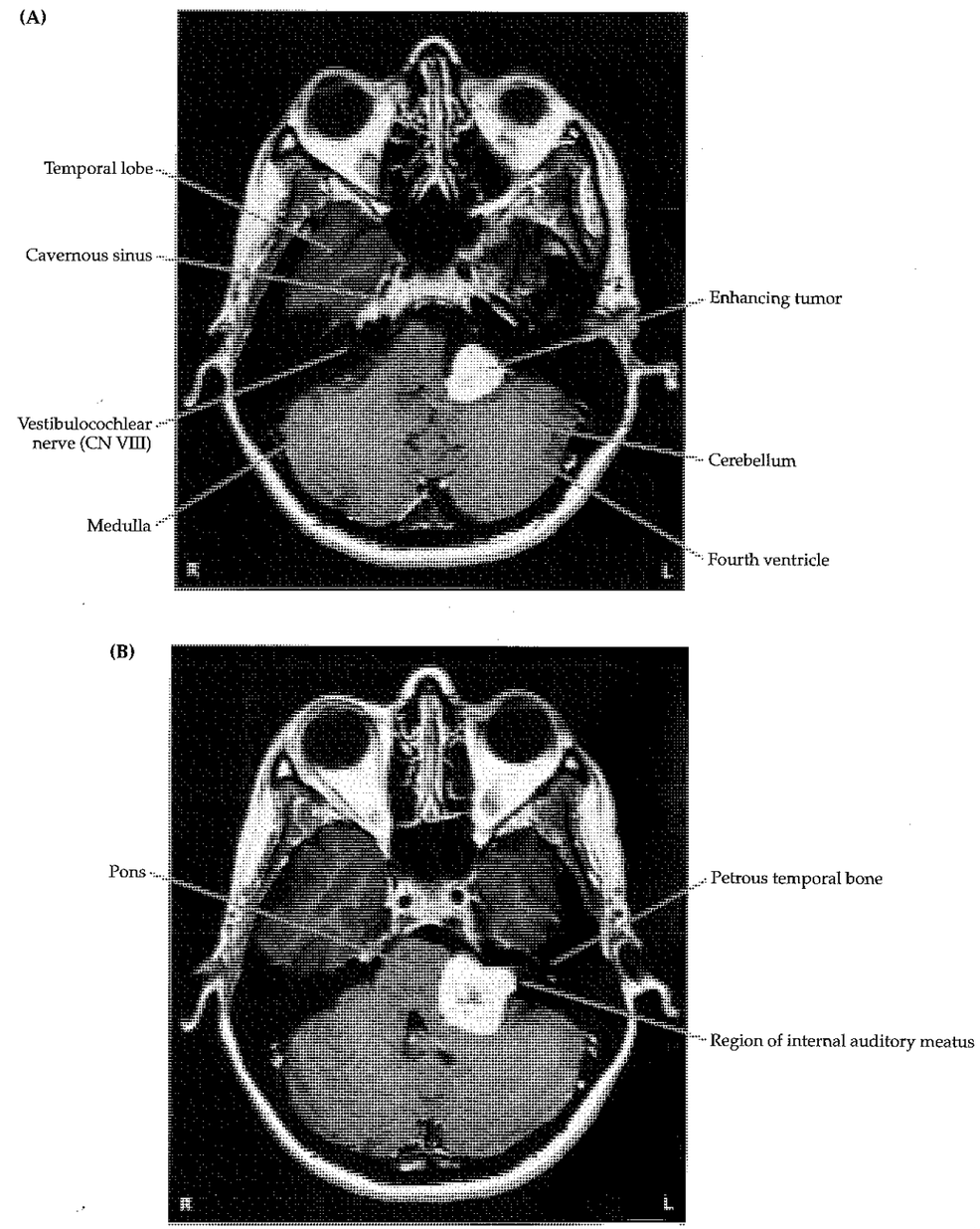

CASE 12.6 HOARSE VOICE FOLLOWING CERVICAL DISC SURGERY

MINICASE

A 38-year-old saleswoman developed left neck and shoulder pain and evaluation revealed a cervical disc herniation, for which she underwent a discectomy and fusion via an anterior approach through the neck (see KCC 8.5). Her symptoms of cervical radiculopathy resolved. However, in the recovery room following surgery she noticed a **marked change in her voice,** which now had a **breathy, "hoarse"** quality. She was reassured that this was a temporary effect of the intubation. Nevertheless, over the next 2 months she continued to have severe breathiness of her voice, making it difficult for her to do her work as a personal shopper. She was referred to an otolaryngologist for evaluation. Exam was normal, aside from the breathiness. Her voice had a soft breathy quality suggesting that an air leak was present in her larynx.

LOCALIZATION AND DIFFERENTIAL DIAGNOSIS

On the basis of the symptoms and signs shown in **bold** above, where is the lesion, and what is the most likely cause?

Discussion

The key symptoms and signs in this case are:

- **Breathy "hoarse" voice**

Breathiness of the voice (often called hoarseness, although this is not strictly accurate) can be caused by any disorder that prevents complete closure of the vocal folds (true vocal cords) during phonation (see KCC 12.8). Incomplete vocal cord closure can be caused by lesions anywhere in the pathway from the nucleus ambiguus, to the vagus nerve (CN X), to the recurrent laryngeal nerve, to the muscles of the larynx (see Figure 12.20). Given this patient's history of surgery on the left side of her neck, the most likely diagnosis is stretch injury or laceration of the left recurrent laryngeal nerve. Note that injury to the superior laryngeal nerve does not usually cause noticeable deficits, since it only supplies the cricothyroid muscle (a subtle deficit in reaching high notes is occasionally noted by professional singers), and injury of the vagus itself is uncommon during neck surgery because of its deeper location.

Clinical Course and Videostroboscopic Imaging 519

To confirm the diagnosis, the otolaryngologist performed fiberoptic video imaging of the larynx using a laryngoscope inserted through the mouth (Figure 12.27). The process of stroboscopy matches the phonatory frequency to a strobe light and by offsetting the phase slightly, it gives the illusion of slow-motion vibratory cycles of the true vocal cords. This process demonstrated normal movement of the right cord during phonation and during breathing. However, the left cord was paralyzed, and remained in an abducted position. Thus, her left-cord paralysis resulted in incomplete closure of the glottis during phonation and caused this patient's breathiness.

Although recurrent laryngeal nerve injuries sometimes recover over time, this patient was eager to have the problem fixed immediately because of the severity of her deficit, its duration, and the importance of her voice for her work. Therefore, she underwent a procedure in which a precisely carved silastic insert was placed into the left paraglottic space. The insertion was performed while visualizing the cords and testing voice quality until the left cord was restored to a sufficiently medial position to allow normal approximation of the cords during phonation. Follow-up over time showed that her left recurrent laryngeal nerve injury was indeed permanent. However, the procedure enabled an immediate and complete recovery of her normal voice.

CASE 12.7 HOARSENESS, WITH UNILATERAL WASTING OF THE NECK AND TONGUE MUSCLES

CHIEF COMPLAINT

A 34-year-old man was referred to an otolaryngologist for progressive hoarseness, dysphagia, and weakness of the left sternomastoid and tongue.

HISTORY

Four months prior to presentation, the patient developed a persistent cough and respiratory infection that did not resolve. Soon afterward he noticed **difficulty swallowing** thick foods, and his voice gradually became **hoarse.** Three weeks prior to presentation, he began to have **decreased hearing in the left ear,** some **alteration in taste,** and mild **left-sided headache.** He lost 40 pounds during the 4 months since developing symptoms.

PHYSICAL EXAMINATION

Vital signs: T = 98.1°F, P = 84, BP = 118/86, R = 18.
Neck: Supple; no adenopathy or palpable masses.
Lungs: Clear.
Heart: Regular rate with no gallops or murmurs.
Abdomen: Soft, nontender.
Extremities: Normal.
Neurologic exam:

MENTAL STATUS: Alert and oriented × 3. Normal language. Gave detailed history.

CRANIAL NERVES: Pupils 4 mm, constricting to 2 mm bilaterally. Visual fields full. Normal optic discs. Extraocular movements intact. Facial sensation intact to light touch and pinprick. Intact corneal reflexes. **Mildly decreased left nasolabial fold. Decreased hearing to finger rub on the left.** Gag intact. **Uvula deviated to the right with palate elevation. Voice hoarse and breathy in quality. Left trapezius and sternomastoid muscles had fasciculations and strength of 4/5. Tongue had marked asymmetrical atrophy and fasciculations of the left side, with tongue deviating to the left on protrusion. On laryngoscopic examination, the left vocal cord was paralyzed** (see Case 12.6).

MOTOR: No pronator drift. 5/5 power throughout.

REFLEXES:

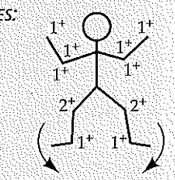

COORDINATION: Normal on finger-to-nose and heel-to-shin testing.

GAIT: Normal.

SENSORY: Intact light touch, pinprick, and joint position sense.

LOCALIZATION AND DIFFERENTIAL DIAGNOSIS

1. On the basis of the symptoms and signs shown in **bold** above, where is the lesion?
2. What are some possible lesions in this location?

Discussion

1. The key symptoms and signs in this case are:

- **Difficulty swallowing, decreased left palate movement, hoarseness, and left vocal cord paralysis**
- **Left trapezius and sternomastoid weakness and fasciculations**
- **Left tongue deviation, atrophy, and fasciculations**
- **Decreased hearing in the left ear**
- **Mildly decreased left nasolabial fold**
- **Alteration in taste**
- **Left-sided headache**

This patient has multiple abnormalities of the cranial nerves on the left side of the head. Although each individual abnormality could be explained by a small brainstem lesion, all of the relevant nuclei could not be involved together without also involving other nearby structures, such as the anterolateral system, inferior cerebellar peduncle, and descending sympathetic pathway (see Figure 14.20D). In addition, as in Case 12.5, the unilateral hearing loss suggests that the lesion lies outside of the brainstem (see KCC 12.5).

Taking each of the above deficits in turn, the swallowing muscles of the pharynx and the left palate are innervated by the left CN X, although CN IX may contribute to the gag reflex as well. A lesion of the left CN X could also

explain hoarseness (breathiness) and left vocal cord paralysis, since the larynx is innervated by the vagus as well. Left trapezius and sternomastoid weakness and fasciculations suggest a lower motor neuron lesion (see KCC 6.1) of the left spinal accessory nerve (CN XI). Similarly, deviation of the tongue to the left, together with atrophy and fasciculations, suggests a lower motor neuron lesion of the left hypoglossal nerve (CN XII). Decreased hearing in the left ear can be caused by a lesion in the left external auditory canal, middle ear, cochlea, or vestibulocochlear nerve (CN VIII). Although a decreased left nasolabial fold could be caused by upper motor neuron– or mild lower motor neuron–type weakness, given the other findings a peripheral lesion of the left facial nerve (CN VII) is more likely. A facial nerve lesion could also explain the alteration in taste. Unilateral headaches can have many causes (see KCC 5.1), but in this setting they support the presence of an intracranial lesion on the left side of the head.

To summarize, this lesion involves CN VII, VIII, IX, X, XI, and XII on the left side. These cranial nerves exit the left lower brainstem and leave the cranium via the internal auditory meatus, jugular foramen, and hypoglossal canal (see Figures 12.2A,C; 12.3A,B; Table 12.2). Note that large lesions of the cerebellopontine angle usually involve CN V (see KCC 12.5 and Case 12.5). Since CN V was spared in this case, it suggests that the lesion lies farther down.

The most likely *clinical localization* is a large lesion lying just outside of the left ventrolateral medulla, or in the vicinity of the left internal auditory meatus, jugular foramen, and hypoglossal canal.

2. Possible lesions in this location include meningioma, schwannoma, metastases, granulomatous disease, and glomus tumors (see KCC 12.7).

Clinical Course and Neuroimaging 520

A **brain MRI** with gadolinium was ordered (Figure 12.28). Figure 12.28A shows an axial T1-weighted image demonstrating an enhancing mass filling the left jugular foramen, just behind the left internal carotid artery. Note that the mass extends into the posterior fossa near the region where the left hypoglossal nerve exits the medulla to traverse the subarachnoid space. Figure 12.28B is a coronal T2-weighted image revealing that the mass extends up into the left petrous temporal bone to reach the vicinity of the left seventh and eighth cranial nerves. These findings are compatible with a left glomus jugulare tumor (see KCC 12.7).

The patient was initially treated with radiation therapy, resulting in no progression of his deficits. He was actively involved in a speech therapy program to help him work on his voice and swallowing. Four years later, however, he began to have worsening hoarseness, severe left facial weakness, and left mastoid pain. Since his tumor appeared to be growing, surgery was planned. Because glomus tumors tend to be very vascular and can bleed profusely during surgery, he had a preoperative angiogram during which an interventional neuroradiologist (see Chapter 4) embolized as much of the tumor as possible. This procedure was followed by a prolonged operation involving collaboration between two teams of neurosurgeons and otolaryngologists and accomplishing complete removal of all visible tumor. Unfortunately, on pathologic analysis, rather than the usual benign appearance of glomus tumors, this lesion had malignant features including mitotic figures (indicating active cellular proliferation) and necrosis. He remained stable until 1 year later, when he had worsening left ear pain and an MRI showed recurrence of the tumor. Again, he underwent embolization followed by surgery. However, soon afterward he developed aspiration pneumonia with overwhelming sepsis, and he died five and a half years after the onset of his initial symptoms.

CASE 12.6 HOARSE VOICE FOLLOWING CERVICAL DISC SURGERY

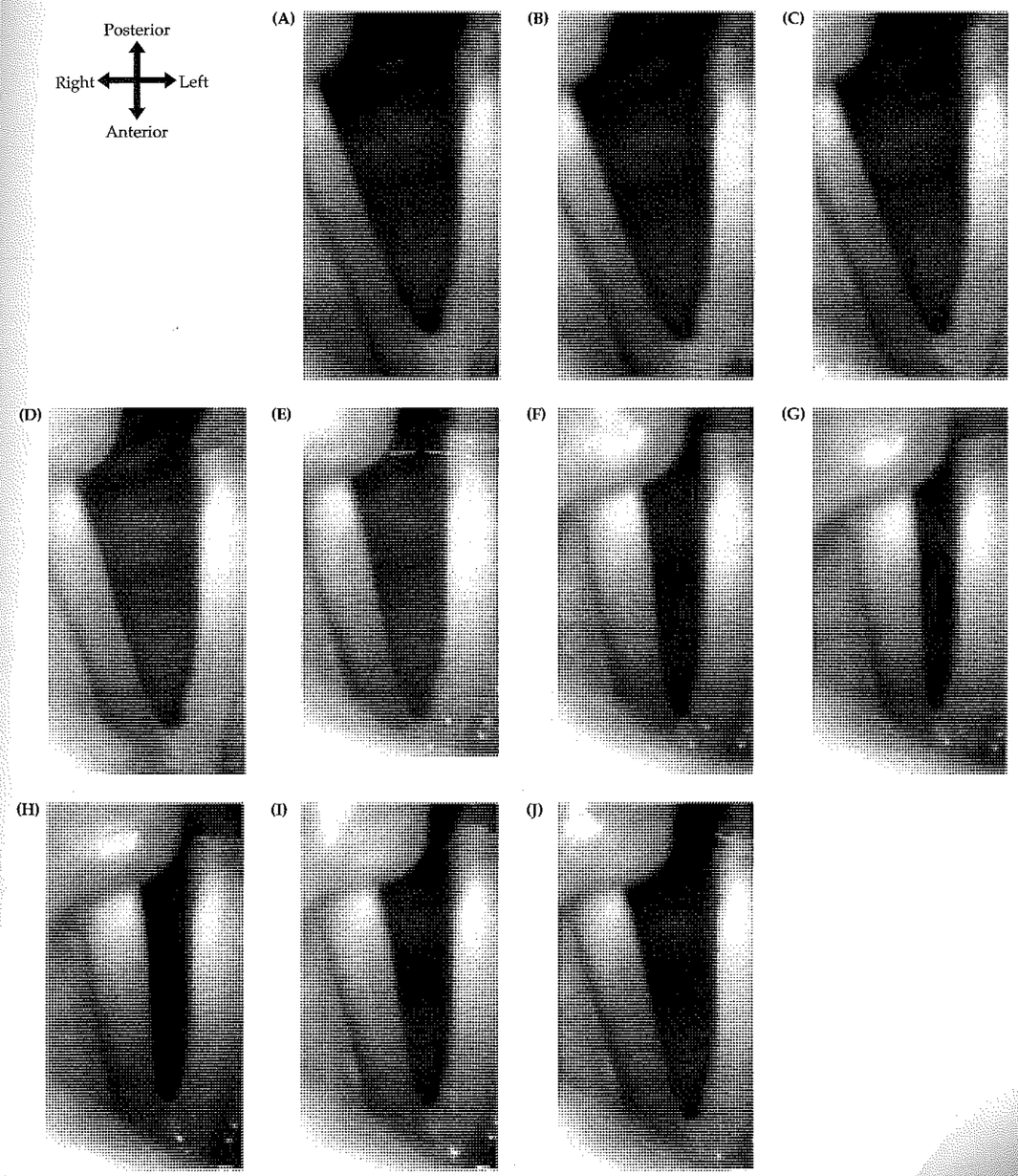

Figure 12.27 Left Vocal Cord Paralysis
Videostroboscopic images through the laryngoscope during a cycle of phonation (adduction) and inspiration (abduction). (A–G) During phonation, the right cord adducts medially, while the left cord remains immobile, causing an air leak to occur. (H–J) During inspiration, the right cord abducts laterally, while the left cord remains immobile. (Courtesy of Michael Goldrich, Robert Wood Johnson Medical School, University of Medicine and Dentistry of New Jersey.)

CASE 12.7 HOARSENESS, WITH UNILATERAL WASTING OF THE NECK AND TONGUE MUSCLES

Figure 12.28 Left Glomus Jugulare Tumor (A) Axial T1-weighted MRI image with gadolinium. (B) Coronal T2-weighted MRI image.

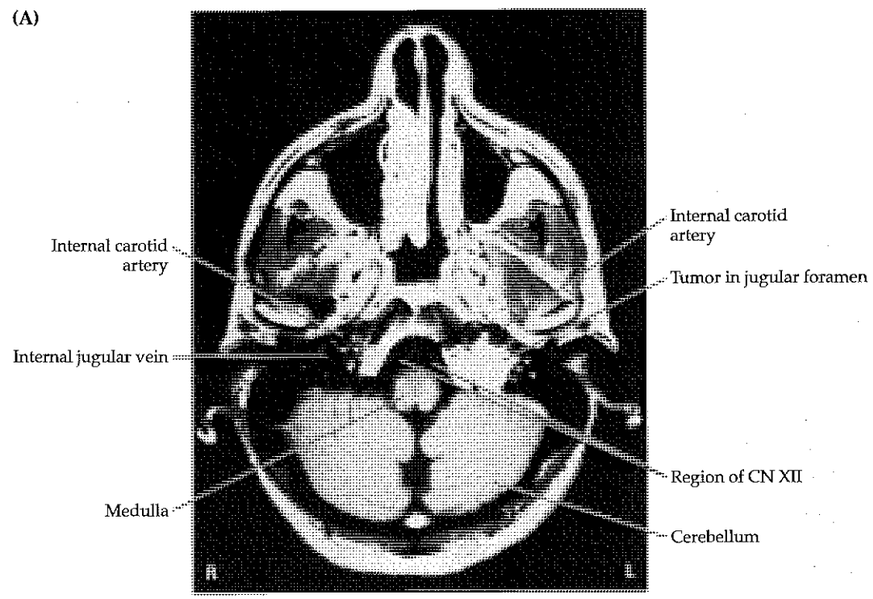

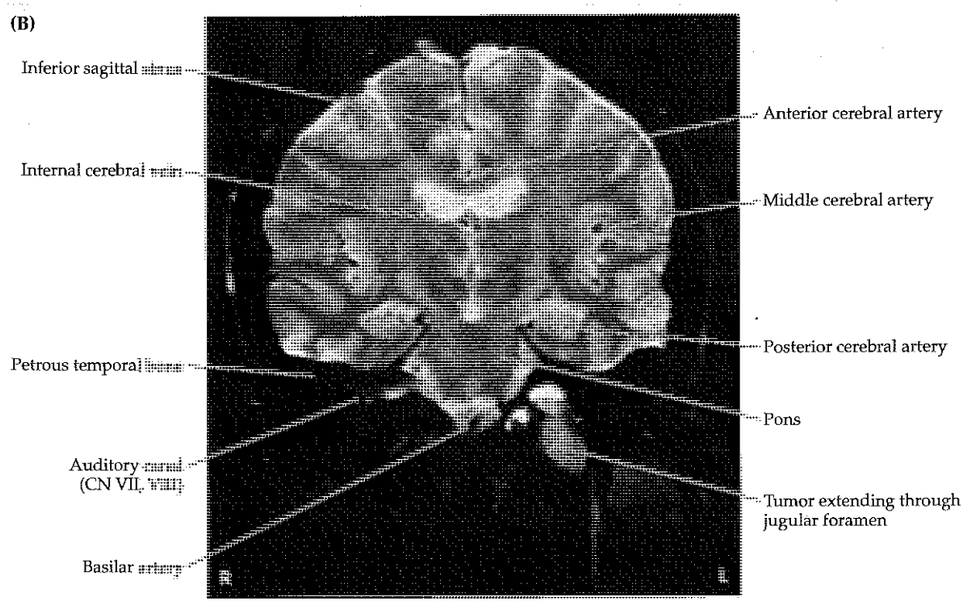

CASE 12.8 UNCONTROLLABLE LAUGHTER, DYSARTHRIA, DYSPHAGIA, AND LEFT-SIDED WEAKNESS*

CHIEF COMPLAINT

A 27-year-old male saxophone player came to the emergency room because of worsening dysarthria, dysphagia, left-sided weakness, and episodes of uncontrollable laughter.

HISTORY

Two and a half years prior to presentation, the patient developed **episodes of left face and mouth pain** precipitated by chewing. One year prior to presentation, he started having **episodes of uncontrollable laughter,** not accompanied by appropriate affect. When he persisted in laughing repeatedly at his girlfriend's father's wake, he was referred to a psychiatrist, who tried behavior modification therapy without benefit. Two to 3 months prior to presentation, he developed increasing difficulty playing the saxophone, and he noticed **slurred speech** and occasional **choking on his food.** He found he also had an **unstable gait, bumping into objects on his left side, difficulty buttoning his shirt with his left hand, and urinary urgency and difficulty initiating urination.**

PHYSICAL EXAMINATION

Vital signs: T = 98°F, P = 72, BP = 130/70, R = 12.
Neck: Supple with no bruits.
Lungs: Clear.
Heart: Regular rate with no gallops or murmurs (but difficult exam because of frequent laughter).
Abdomen: Soft, nontender.
Extremities: Normal.
Neurologic exam:

MENTAL STATUS: Alert and oriented × 3. Recalled 3/3 objects after 5 minutes. Normal language. Normal constructions. Denied depression or anxiety.

CRANIAL NERVES: Pupils 4 mm, constricting to 2 mm bilaterally. Visual fields full. Normal optic discs. Extraocular movements intact. **Mildly decreased left nasolabial fold.** Normal hearing to finger rub bilaterally. **Absent gag reflex. Speech mildly dysarthric. Had intermittent bouts of uncontrollable laughter about once per minute without accompanying emotion. Mild weakness of head turning to the left.** Tongue midline, with no fasciculations.

MOTOR: **Mild left pronator drift. Slowed finger tapping in the left hand. Tone slightly increased in left lower extremity. Power 4/5 in left deltoid, triceps, wrist extensors, finger extensors, iliopsoas, hamstrings, tibialis anterior, and extensor hallucis longus,** but otherwise 5/5 throughout.

REFLEXES:

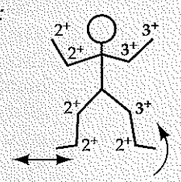

COORDINATION: Finger-to-nose and heel-to-shin testing slowed, but without ataxia.

GAIT: **Slightly unsteady, with stiff left lower extremity.**

SENSORY: Intact light touch, pinprick, temperature, vibration, and joint position senses and graphesthesia.

LOCALIZATION AND DIFFERENTIAL DIAGNOSIS

1. On the basis of the symptoms and signs shown in **bold** above, which nerves (see Table 12.4) and which long tracts (see Chapters 6 and 7) are affected by the lesion?
2. In what general region of the nervous system can a single lesion produce all of these findings?
3. What are some possible lesions in this location?

Discussion

1. The key symptoms and signs in this case are:
   - **Episodes of left face and mouth pain**
   - **Episodes of uncontrollable laughter not accompanied by appropriate affect**
   - **Dysarthria, dysphagia, absent gag reflex**
   - **Mild weakness of head turning to the left**

*This patient was described previously as a case report by Shafqat et al. in *Neurology,* Volume 50, pp. 1918–1919, 1998.

- **Left face arm and leg weakness, with increased tone, hyperreflexia, and gait unsteadiness**
- **Urinary urgency and difficulty with initiation**

The episodes of left face and mouth pain precipitated by chewing were initially suggestive of a trigeminal nerve (CN V) disorder, such as trigeminal neuralgia (see KCC 12.2). However, later findings suggest a lesion affecting central nervous system pathways. These include the development of pseudobulbar affect, suggesting a lesion of the corticobulbar pathways (see KCC 12.8), left hemiparesis with upper motor neuron signs compatible with corticobulbar and corticospinal dysfunction (see KCC 6.3), and urinary dysfunction, also compatible with impairment of descending pathways controlling micturition (see KCC 7.5). Dysarthria, dysphagia, and absent gag reflex (CN IX, X) in this patient, along with impaired CN XI function, further support a combination of cranial nerve dysfunction along with involvement of long tracts. These findings suggest a lesion affecting CN V, IX, X, and XI, as well as corticobulbar, corticospinal, and descending sphincteric pathways.

2. A lesion of the brainstem in the region of the pons and medulla could affect these multiple cranial nerves and long tracts. A lesion affecting this many brainstem structures while preserving other brainstem nuclei and pathways would have to be fairly extensive, yet cause patchy involvement.
3. Given the gradual onset of symptoms over several years involving multiple brainstem structures, one possibility would be multiple sclerosis (see KCC 6.6) affecting primarily the brainstem. Other possibilities include a brainstem vascular malformation (see KCC 5.6), a granulomatous disorder such as sarcoidosis (see KCC 12.1), or a slow-growing tumor such as a brainstem glioma or meningioma (see KCC 5.8).

Clinical Course and Neuroimaging 524

The patient underwent a head CT scan in the emergency room revealing a mass lesion, which was better visualized by MRI scan (Figure 12.29). Note the presence of a large mass lying outside of the brain adjacent to the dura and enhancing uniformly with gadolinium, consistent with a meningioma (see KCC 5.8). The mass could be seen to cause severe compression and distortion of the pons and left middle cerebellar peduncle (see Figure 12.29A). The patient's relatively mild deficits given this degree of distortion attest to the chronic nature of this lesion. The mass could also be seen to extend into the region of Meckel's cave adjacent to the left cavernous sinus (see Figure 12.29B), possibly explaining the patient's early symptoms of left facial pain. The patient underwent a multistage resection, involving preoperative embolization by interventional radiology, and two collaborative operations involving teams of neurosurgeons and otolaryngologists. He made an excellent recovery with minimal deficits. On follow-up examination 1 year later, he still had rare episodes of inappropriate laughter, and he had some mild diplopia that he had developed following surgery, but he was otherwise without deficits. Repeat MRI scan showed near complete removal of the tumor (see Figure 12.29C), with only a small portion left where it was adherent to CN IV.

Additional Cases

Related cases can be found in other chapters for: **upper or lower motor neuron cranial nerve disorders** (Cases 5.2, 5.3, 5.7, 5.8, 6.3, 6.5, 10.4, 10.5, 10.11, 11.1, 11.2, , 13.1–13.3, 13.5, 14.1, 14.4, 14.7, 15.4, 17.2, 18.2). Other relevant cases can be found using the **Case Index**.

Brief Anatomical Study Guide

1. The main parts of the **brainstem** are the **midbrain, pons,** and **medulla,** as shown in Figure 12.1. The **cranial nerves** (see Table 12.1) exit the brainstem roughly in numerical sequence from rostral to caudal (see Figure 12.2), except for CN I and CN II, which arise from the forebrain. Each cranial nerve exits the skull through a specific **foramen,** as summarized in Table 12.2 and Figure 12.3.
2. As in the spinal cord gray matter, the cranial nerve nuclei for **motor functions are located more ventrally** in the brainstem, and those for **sensory functions are located more dorsally** (see Figure 12.4).
3. Along the long axis of the brainstem are **three motor columns** and **three sensory columns** of cranial nerve nuclei (see Figures 12.4, 12.5). The functions, nuclei, and cranial nerves for each of these columns are summarized in Table 12.3. Note that each nucleus can be involved in the motor or sensory functions of one or more cranial nerves. Similarly, each cranial nerve can have both sensory and motor functions, and connections with one or more cranial nerve nuclei (see Table 12.4).
4. Some cranial nerves have peripheral **ganglia** that contain either primary sensory neurons or parasympathetic postganglionic neurons (see Table 12.5; Figure 12.6).
5. The **olfactory nerves (CN I)** (see Figures 18.5, 18.6) traverse the cribriform plate of the ethmoid bone to synapse in the **olfactory bulbs** (see Figure 12.3A). Olfactory information then travels to the olfactory cortex (see Chapter 18) via the olfactory tracts.
6. The optic nerve (CN II) enters the cranial cavity via the optic canal (see Figure 12.3A,C), carrying visual information from the retina to the lateral geniculate nucleus and extrageniculate pathways (see Chapter 11).
7. The oculomotor (CN III), trochlear (CN IV), and abducens (CN VI) nerves are involved in eye movements and pupillary control (CN III) and are discussed at length in Chapter 13.
8. The **trigeminal nerve (CN V)** provides sensation for the face, mouth, and meninges of the supratentorial cranial cavity via three major branches: the **ophthalmic division (V_1), maxillary division (V_2),** and **mandibular division (V_3)** (see Figure 12.7). These branches enter the skull via the **superior orbital fissure, foramen rotundum,** and **foramen ovale,** respectively (see Figures 12.3A, 12.7), with primary sensory neurons located in the **trigeminal ganglion.** The **trigeminal sensory nuclei** include the **mesencephalic trigeminal nucleus** mediating proprioception, the **chief trigeminal sensory nucleus** mediating discriminative touch, and the **spinal trigeminal nucleus** mediating pain and temperature sensation (see Figures 12.5, 12.8; Table 12.6). Trigeminal sensory information travels to the cortex via the **trigeminal lemniscus** and **trigeminothalamic tract,** with a relay in the **VPM** of the thalamus (see Figure 12.8; Table 12.6). The trigeminal nerve also has a small **motor root** that travels with CN V_3, supplying the **muscles of mastication** (see Figure 12.7).

CASE 12.8 UNCONTROLLABLE LAUGHTER, DYSARTHRIA, DYSPHAGIA, AND LEFT-SIDED WEAKNESS

Figure 12.29 Meningioma Compressing the Pons T1-weighted MRI images with intravenous gadolinium enhancement. (A) Sagittal view. (B) Axial view. (C) Follow-up MRI axial view 1 year after surgery.

(A)

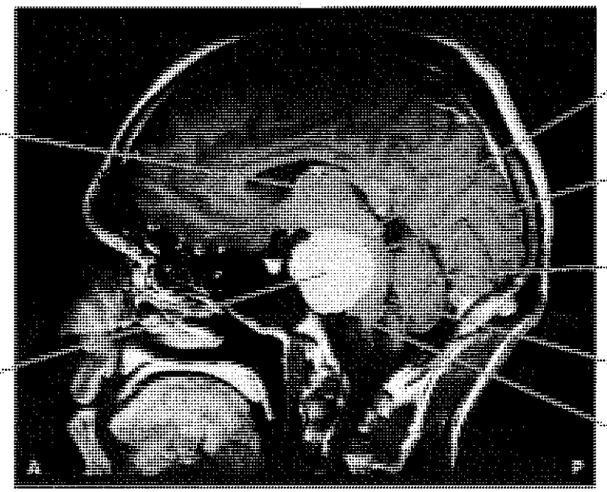

(B)

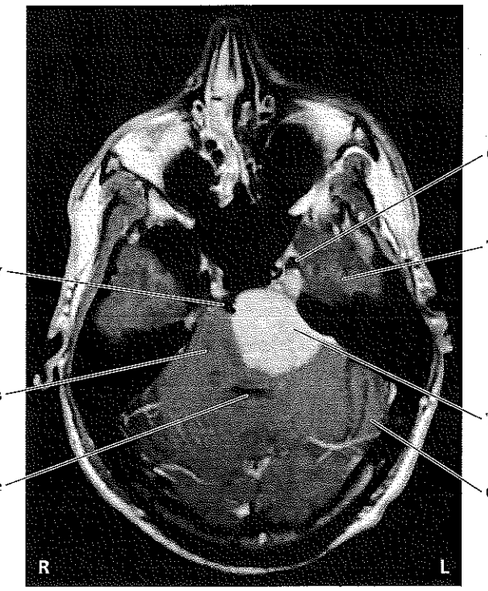

CASE 12.8 *(CONTINUED)*

(C)

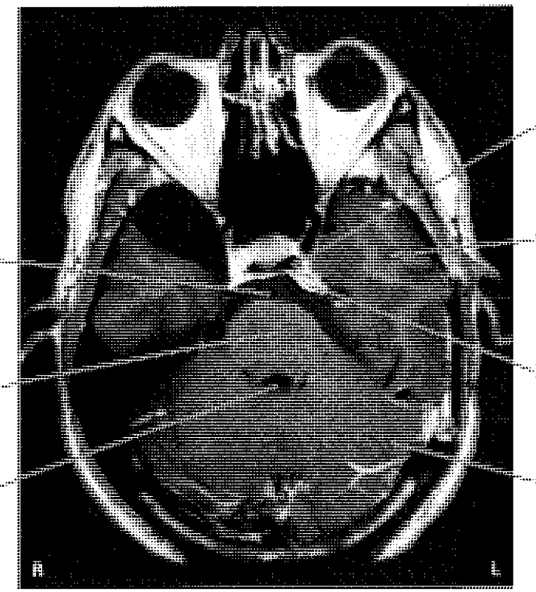

Brief Anatomical Study Guide *(continued)*

9. The **facial nerve (CN VII)** controls the muscles of facial expression (to be distinguished from the trigeminal nerve that mediates facial sensation) via fibers that arise from the **facial nucleus** in the pons (see Figure 12.11). The facial nerve travels along with CN VIII in the auditory canal and then exits the skull via the stylomastoid foramen (see Figures 12.3B, 12.10). **Upper motor neuron control** of the facial nucleus is **bilateral for the upper parts of the face,** so in unilateral upper motor lesions the contralateral side can compensate, resulting in sparing of the upper face muscles (see Figure 12.13). The facial nerve also has sensory fibers that provide taste sensation for the anterior two-thirds of the tongue reaching the nucleus solitarius (see Figure 12.12), and somatic sensation fibers for a region around the outer ear traveling to the trigeminal nuclei (see Figure 12.7B). Sensory cell bodies lie in the **geniculate ganglion.** Parasympathetics arising from the superior salivatory nucleus travel in CN VII via the sphenopalatine ganglion and submandibular ganglion, respectively, to the lacrimal glands and salivary glands (see Figure 12.6).

10. The **vestibulocochlear nerve (CN VIII)** carries auditory information from the cochlea to the **dorsal and ventral cochlear nuclei** (see Figures 12.15–12.17). The primary sensory cell bodies lie in the spiral ganglion. Central auditory pathways cross multiple times, so unilateral lesions in the central nervous system do not cause clinically significant unilateral hearing loss (see Figure 12.16). Information about head position and acceleration is carried by the vestibular portions of CN VIII arising from the **semicircular canals and otolith**

Brief Anatomical Study Guide *(continued)*

organs (see Figure 12.15). Primary cell bodies are in the vestibular ganglia, and this information travels to the **vestibular nuclei** in the brainstem to influence unconscious posture and balance, eye movements, and conscious perception of movement through multiple pathways (see, e.g., Figure 12.18).

11. The **glossopharyngeal nerve (CN IX)** exits the skull via the jugular foramen (see Figures 12.3A,B, 12.19; Table 12.2). Motor fibers arising from the **nucleus ambiguus** provide innervation of the stylopharangeus muscle, important for pharynx elevation during speech and swallowing. Sensory fibers from chemoreceptors and baroreceptors in the carotid body reach the caudal nucleus solitarius (cardiorespiratory nucleus). Taste sensory fibers from the posterior one-third of the tongue travel to the rostral nucleus solitarius (gustatory nucleus). Somatic sensation from the posterior tongue, pharynx, middle ear, and external ear travels via CN IX to the trigeminal nuclei. Finally, parasympathetics arising from the inferior salivatory nucleus activate the parotid salivary gland via the otic ganglion.

12. The **vagus nerve (CN X)** also has multiple functions, providing parasympathetic innervation for the viscera arising from the **dorsal motor nucleus of CN X** (see Figures 12.5, 12.20; see also Figure 14.5A,B). In addition, motor fibers of the vagus arising from the **nucleus ambiguus** supply the pharynx (swallowing) and larynx (voice). Sensory fibers from the aortic arch travel to the caudal nucleus solitarius. Sensory fibers for the pharynx, larynx, outer ear, and meninges of the posterior fossa travel to the trigeminal nuclei.

13. The **spinal accessory nerve (CN XI)** (see Figure 12.2A,C) arises from the **spinal accessory nucleus** (see Figure 12.5) and innervates the sternomastoid and upper portions of the trapezius muscles. Because of the mechanical attachments of the sternomastoid muscle, lesions of CN XI cause weakness of head turning to the side opposite the lesion.

14. The **hypoglossal nerve (CN XII)** (see Figure 12.2A,C) arises from the hypoglossal nucleus (see Figures 12.4, 12.5) and supplies intrinsic tongue muscles. Hypoglossal nerve lesions cause the tongue to deviate toward the side of the lesion when the tongue is protruded.

References

General References

Wilson-Pauwels L, Akesson EJ, Stewart PA. 1988. *Cranial Nerves: Anatomy and Clinical Comments*. B. C. Decker, Toronto, Ontario.

Cribriform and Suprasellar Meningiomas

1996. Meningiomas. In Youmans JR (ed.), *Neurological Surgery: A Comprehensive Reference Guide to the Diagnosis and Management of Neurosurgical Problems*, 4th Ed., Saunders, Philadelphia.

Solero CL, Giombini S, Morello G. 1983. Suprasellar and olfactory meningiomas. Report on a series of 153 cases. *Acta Neurochir* 67: 181–194.

Central Nervous System Sarcoidosis

Scully RE, Mark EJ, McNeely WF, Ebeling SH (eds.). 1996. Case records of the Massachusetts General Hospital. *N Engl J Med* 335: 1668–1674.

Pentland B, Mitchell JD, Cull RE, Ford MJ. 1985. Central nervous system sarcoidosis. *Q J Med* 220: 457–465.

Stern BJ, Krumholz A, Johns C, Scott P, Nissim J. 1985. Sarcoidosis and its neurological manifestations. *Arch Neurol* 42: 909–917.

Trigeminal Nerve Lesions

Bordi L, Compton J, Symon L. 1989. Trigeminal neuroma: A report of eleven cases. *Surg Neurol* 31: 272–276.

Campbell JK, Caselli RJ. 1991. Headache and other craniofacial pain. In Bradley WG, Daroff RB, Fenichel GM, Marsden CD (eds.), *Neurology in Clinical Practice: The Neurological Disorders*, Vol. 2, Chapter 74. Butterworth-Heinemann, Boston.

Fromm GH. 1989. Trigeminal neuralgia and related disorders. *Neurol Clin* 7: 305–319.

Gibson RD, Cowan IA. 1989. Giant aneurysm of the petrous carotid artery presenting with facial numbness. *Neuroradiology* 31: 440–441.

Morantz RA, Kirchner FR, Kishore P. 1976. Aneurysms of the petrous portion of the internal carotid artery. *Surg Neurol* 6: 313–318.

Rorick MB, Chandar K, Colombi BJ. 1996. Inflammatory trigeminal sensory neuropathy mimicking trigeminal neurinoma. *Neurology* 46: 1455–1457.

Rovit RL. 1992. Trigeminal neuralgia. *Compr Ther* 18: 17–21.

Facial Nerve Lesions

Adour KK. 1991. Medical management of idiopathic (Bell's) palsy. *Otolaryngol Clin North Am* 24: 663–673.

Adour KK, Wingerd J, Bell DN, Manning JJ, Hurley JP. 1972. Prednisone treatment for idiopathic facial paralysis (Bell's palsy). *N Engl J Med* 287: 1268–1272.

Coker NJ, Kendall KA, Jenkins HA, Alford BR. 1987. Traumatic intratemporal facial nerve injury: Management rational for preservation of function. *Otolaryngol Head Neck Surg* 97: 262–269.

Marsh MA, Coker NJ. 1991. Surgical decompression of idiopathic facial palsy. *Otolaryngol Clin North Am* 24: 675–689.

Rowland LP. 1972. Treatment of Bell's palsy. *N Engl J Med* 287: 1298–1299.

Wolf SM, Wagner JH, Davidson S, Forsythe A. 1978. Treatment of Bell palsy with prednisone: A prospective, randomized study. *Neurology* 28: 158–161.

Acoustic Neuroma

Cohen ME. 1991. Primary and secondary tumors of the nervous system. In Bradley WG, Daroff RB, Fenichel GM, Marsden CD (eds.), *Neurology in Clinical Practice: Principles of Diagnosis and Management*, Vol. 2, Chapter 59. Butterworth-Heinemann, Boston.

Matthies C, Samii M. 1997. Management of 1000 vestibular schwannomas (acoustic neuromas): Clinical presentation. *Neurosurgery* 40: 1–9.

Ogawa K, Kanzaki J, Ogawa S, Tsuchihashi N, Ikeda S. 1991. Progression of hearing loss in acoustic neuromas. *Acta Otolaryngol* Suppl 487: 133–137.

Ojemann RG. 1996. Acoustic neuroma (vestibular schwannoma). In Youmans JR (ed.), *Neurological Surgery: A Comprehensive Reference Guide to the Diagnosis and Management of Neurosurgical Problems*, 4th Ed., Chapter 129. Saunders, Philadelphia.

Glomus Jugulare

Ghani GA, Sung Y, Per-Lee JH. 1983. Glomus jugulare tumors—Origin, pathology, and anesthetic considerations. *Anesth Analg* 62: 686–691.

CHAPTER 13

Brainstem II: Eye Movements and Pupillary Control

ANATOMICAL AND CLINICAL REVIEW

Extraocular Muscles, Nerves, and Nuclei

KCC 13.1 Diplopia

KCC 13.2 Oculomotor Palsy (CN III)

KCC 13.3 Trochlear Palsy (CN IV)

KCC 13.4 Abducens Palsy (CN VI)

The Pupils and Other Ocular Autonomic Pathways

KCC 13.5 Pupillary Abnormalities

KCC 13.6 Ptosis

Cavernous Sinus and Orbital Apex

KCC 13.7 Cavernous Sinus Syndrome (CN III, IV, VI, V_1) and Orbital Apex Syndrome (CN II, III, IV, VI, V_1)

Supranuclear Control of Eye Movements

KCC 13.8 Brainstem Lesions Affecting Horizontal Gaze

KCC 13.9 Parinaud's Syndrome

KCC 13.10 Right-Way Eyes and Wrong-Way Eyes

CLINICAL CASES

13.1 Double Vision and Unilateral Eye Pain

13.2 A Diabetic with Horizontal Diplopia

13.3 Vertical Diplopia

13.4 Left Eye Pain and Horizontal Diplopia

13.5 Unilateral Headache, Ophthalmoplegia, and Forehead Numbness

13.6 Ptosis, Miosis, and Anhidrosis

13.7 Wrong-Way Eyes

13.8 Horizontal Diplopia in a Patient with Multiple Sclerosis

13.9 Headaches and Impaired Upgaze

Additional Cases

BRIEF ANATOMICAL STUDY GUIDE

Damage to the eye movement pathways can interfere with normal vision and can also affect pupil and eyelid control. A 48-year-old woman developed gradually worsening left eye pain and double vision over the course of 18 months. Her left pupil appeared dilated and did not constrict in response to light. Her left eye had limited upgaze, downgaze, and medial gaze, but normal lateral gaze. In addition, her left upper eyelid drooped about 3 mm lower than the right one. In this chapter we will learn about the brainstem circuits, nerves, and muscles involved in movement of the eyes, eyelids, and pupils, and about the effects of lesions or illness on these functions.

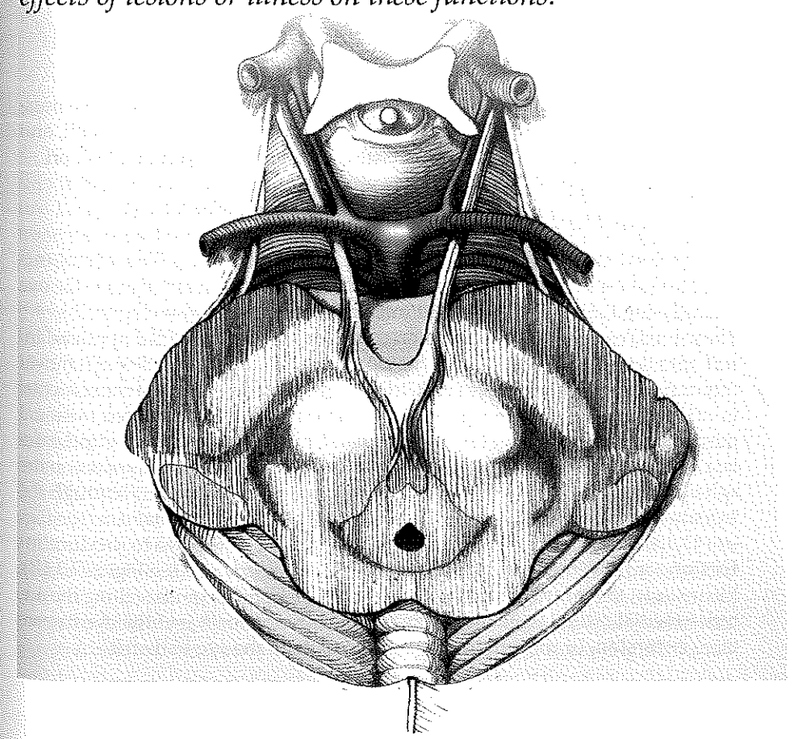

ANATOMICAL AND CLINICAL REVIEW

Movement of the eyes and pupils occurs continuously, mostly imperceptibly to us, and enables us to maximize the information derived from the relatively small visual area represented in the fovea. Abnormalities of the pupils and eye movements are often warning signs of pathology in the brainstem or cranial nerves and should therefore be evaluated carefully. In this chapter we will discuss the anatomy of both the **extraocular muscles** that cause the eyes to move within the orbits and the **internal ocular muscles** that control pupillary size and lens accommodation. We will also discuss common disorders affecting these systems. Eye movement disorders and pathways are often separated into two levels:

1. **Nuclear and infranuclear pathways** involve the brainstem nuclei of CN III, IV, and VI; the peripheral nerves arising from these nuclei; and the eye movement muscles.
2. **Supranuclear pathways** involve brainstem and forebrain circuits that control eye movements through connections with the nuclei of CN III, IV, and VI.

We will follow this bipartite organization in this chapter. First we will discuss the peripheral course of CN III, IV, and VI; the muscles innervated by them; and the locations of their brainstem nuclei. Next we will discuss the central and peripheral pathways involved in pupillary control. Then we will discuss CNS supranuclear pathways that control extraocular movements through connections with the nuclei of CN III, IV, and VI. By understanding the anatomy of eye movements and pupillary control, we can often use the neurologic exam to localize a lesion in the central nervous system or the periphery, providing essential guidance to further diagnostic tests and therapeutic interventions.

Extraocular Muscles, Nerves, and Nuclei

The mechanical systems and information processing involved in eye movement control constitute a remarkable design in natural engineering. The muscles, nerves, and nuclei described in this section enable precise, smooth, and rapid eye movements to occur in a synchronized and coordinated fashion.

Extraocular Muscles

There are six **extraocular muscles** for each eye (Figure 13.1). The **lateral rectus, medial rectus, superior rectus,** and **inferior rectus** muscles move the eye laterally, medially, superiorly, and inferiorly, respectively (see Figure 13.1A). These muscles originate in a common tendinous ring at the orbital apex and insert onto the sclera. In addition to the simple horizontal and vertical eye movements performed by the rectus muscles, there are also **torsional** movements, in which the eye is rotated slightly about its axis. To provide balanced torsional movements, there are two more extraocular muscles: the superior and inferior obliques (see Figure 13.1B). The **superior oblique** muscle originates on the sphenoid bone in the posterior medial orbit and passes anteriorly through the **trochlea,** a pulleylike fibrous loop on the medial superior orbital rim (see Figure 13.1B,D). It then inserts on the superior surface of the eye to produce **intorsion,** or movement of the upper pole of the eye inward (see Figure 13.1B). Meanwhile, the **inferior oblique** has no trochlea, but it originates along the anterior medial orbital wall and inserts on the inferior surface of the eye to produce **extorsion,** or movement of the upper pole of the eye outward.

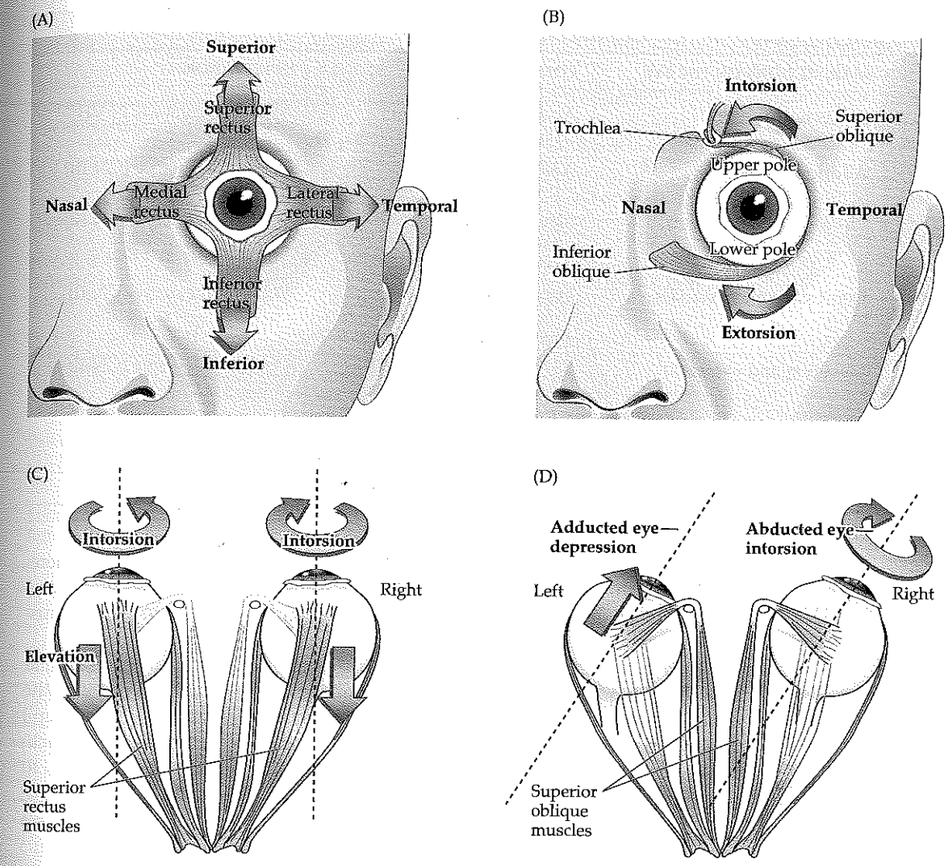

Figure 13.1 Extraocular Muscles and Actions (A) Rectus muscles. (B) Superior and inferior oblique muscles. (C) Dual actions of superior rectus muscles. (D) Dual actions of superior oblique muscles.

The movement produced by an extraocular muscle depends on the direction in which the muscle pulls relative to the main axis of the eye (see Figure 13.1C,D). Therefore, as the eyes move by rotating in the orbit, the extraocular muscles can have different actions (Table 13.1). Thus, depending on eye position, the rectus muscles can also produce torsional eye movements, and the oblique muscles can make important contributions to vertical eye movements. For example, when the eyes are facing forward, the superior rectus attaches to the eye at an angle of 23° to the eye's main axis (see Figure 13.1C). Therefore, contraction of the superior rectus causes both elevation and intorsion of the eye. Conversely, contraction of the inferior rectus causes depression and extorsion. If an eye is **abducted** (moving horizontally toward the temple) by 23° so that its axis lines up with the superior rectus muscle, this muscle will now cause a pure elevation movement of the eye. If the eye is **adducted** (moving horizontally toward the nose), the superior rectus has more of an intorsion action. Similarly, as shown in Figure 13.1D, the superior and inferior oblique muscles contribute to vertical movements of the eye. For example, when the eye is adducted (left eye in Figure 13.1D), the superior oblique comes more in line with the axis of the eye and therefore causes depression. Likewise, the inferior oblique causes elevation, especially when the eye is adducted. However, as the eye is abducted (right eye in Figure 13.1D)

TABLE 13.1 Actions and Innervation of the Extraocular Muscles

MUSCLE	MAIN ACTIONS ON THE EYE	COMMENTS	INNERVATION
Lateral rectus	Abduction	Abduction = temporal (lateral) movement of eye	Abducens nerve (CN VI)
Medial rectus	Adduction	Adduction = nasal (medial) movement of eye	Oculomotor nerve (CN III)
Superior rectus	Elevation and intorsion	Elevation increases with abduction; intorsion increases with adduction	Oculomotor nerve (CN III)
Inferior rectus	Depression and extorsion	Depression increases with abduction; extorsion increases with adduction	Oculomotor nerve (CN III)
Inferior oblique	Elevation and extorsion	Elevation increases with adduction; extorsion increases with abduction	Oculomotor nerve (CN III)
Superior oblique	Depression and intorsion	Depression increases with adduction; intorsion increases with abduction	Trochlear nerve (CN IV)

the superior oblique becomes more perpendicular to the eye's axis and therefore causes mainly intorsion. Similarly, the inferior oblique causes mainly extorsion when the eye is abducted. The main actions of the extraocular muscles are summarized in Table 13.1.

Other eye muscles will be discussed in this chapter that are not extraocular muscles. These include the **levator palpebrae superior,** which elevates the eyelid; the **pupillary constrictor** and **dilator muscles,** which cause the pupil to become smaller and larger; and the **ciliary muscle,** which adjusts the thickness of the lens in response to viewing distance.

Extraocular Nerves and Nuclei

The oculomotor (CN III), trochlear (CN IV), and abducens (CN VI) nerves pass through the cavernous sinus and then enter the orbit through the superior orbital fissure (see Figure 12.3A,C). The **oculomotor nerve (CN III)** supplies all extraocular muscles except the lateral rectus and superior oblique. Shortly after entering the orbit, the oculomotor nerve splits into two major branches. The **superior division** supplies the superior rectus and also innervates the **levator palpebrae superioris,** a muscle important for eyelid elevation. The **inferior division** of the oculomotor nerve supplies the medial rectus, inferior rectus, and inferior oblique muscles. The oculomotor nerve also carries preganglionic parasympathetic fibers to the pupillary constrictor muscles and to the ciliary muscles of the lens (see Figure 12.6). The **trochlear nerve** innervates the superior oblique muscle, and the **abducens nerve** innervates the lateral rectus (see Table 13.1).

Recall that the oculomotor (CN III), trochlear (CN IV), and abducens (CN VI) nuclei, together with the hypoglossal (CN XII) nucleus, constitute the somatic motor column of cranial nerve nuclei (see Figure 12.5; Table 12.3). These nuclei all lie near the midline, adjacent to the ventricular system, and their fibers exit the brainstem ventrally near the midline, with the exception of CN IV, which exits dorsally (see Figure 12.2). Let's discuss each of these nuclei and the intracranial segments of these nerves in more detail.

The **oculomotor nuclei** are located in the upper midbrain at the level of the superior colliculi and red nuclei, just ventral to the periaqueductal gray matter

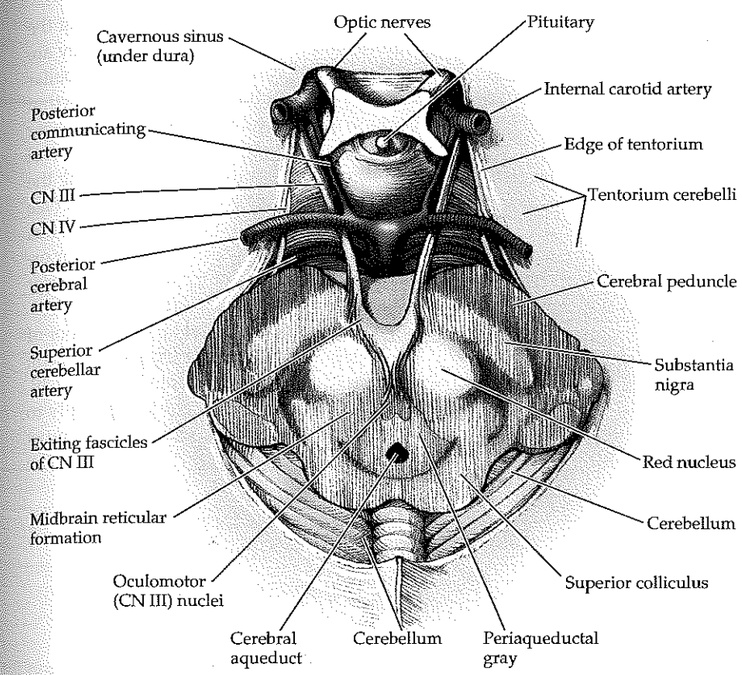

Figure 13.2 Oculomotor Nerves (CN III) in Situ View is from above, with the forebrain removed, showing the oculomotor nuclei in the rostral midbrain and the oculomotor nerves (CN III) in relation to adjacent structures.

(Figures 13.2, 14.3A). Fascicles of the oculomotor nerve exit the brainstem as CN III in the interpeduncular fossa between the posterior cerebral and superior cerebellar arteries (see Figure 13.2; see also Figure 10.3). The **Edinger–Westphal nuclei,** containing preganglionic parasympathetic fibers, form a V shape as they curve over the dorsal aspect of the oculomotor nuclei and fuse anteriorly in the midline (Figures 13.3, 14.3A). The parasympathetic fibers controlling pupil constriction run in the superficial portion of the oculomotor nerve as it travels in the subarachnoid space, and they are susceptible to compression from aneurysms, particularly arising from the nearby posterior communicating artery (see Figure 13.2). The oculomotor nerve then enters the cavernous sinus and continues to the orbit via the superior orbital fissure, as already described (see Figure 12.3A,C). The oculomotor nucleus actually consists of several subnuclei (see Figure 13.3; Table 13.2). These subnuclei and their connections are of relatively minor clinical significance, except for the following points: (1) Unilateral weakness of the levator palpebrae superior, or unilateral pupillary dilation, cannot arise from unilateral lesions of the oculomotor nucleus. (2) Lesions of the oculomotor nucleus affect the *contralateral* superior rectus. Lesions of the oculomotor nucleus will actually affect the ipsilateral superior rectus since the crossing fibers traverse the oculomotor nucleus before exiting in the third nerve fascicles.

The **trochlear nuclei** are located in the lower midbrain at the level of the inferior colliculi and the decussation of the superior cerebellar peduncle (Figures 13.4, 14.3B). Like the oculomotor nuclei, they lie just ventral to the periaqueductal gray matter and are bounded ventrally by the fibers of the medial longitudinal fasciculus. The trochlear nerves are the only cranial nerves to exit the brain dorsally (see Figure 12.2B). In addition, unlike any other cranial nerve, the trochlear nerves exit the brainstem in a completely crossed fashion (see Figure 13.4). They travel caudally for a short distance and then cross to the op-

REVIEW EXERCISE

For each of the six extraocular muscles, list the main action(s) of the muscle and the cranial nerve it is innervated by (refer to Table 13.1 and Figure 13.1). For the cranial nerves CN III, CN IV, and CN VI, list all muscles innervated (intraocular and extraocular) and state the brainstem nuclei from which the fibers arise (refer to Tables 12.4, 13.1, and Figure 12.5).

TABLE 13.2 Subnuclei of the Oculomotor Nucleus (CN III) and Their Functions[a]

SUBNUCLEUS	MUSCLES INNERVATED	SIDE INNERVATED
[illegible]	[illegible]	[illegible]
Inferior	Inferior oblique	Ipsilateral
Medial	Medial rectus	Ipsilateral
Edinger-Westphal (parasympathetic)	Pupillary constrictors and lens ciliary muscles	Bilateral
Central caudal	Levator palpebrae superior	Bilateral
Medial	Superior rectus	Contralateral

[a]Subnuclei are color coded with Figure 13.3.

posite side before exiting at the level of the anterior medullary velum, where they are susceptible to compression from cerebellar tumors. The trochlear nerves are very thin and are relatively easily damaged by shear injury from head trauma. They travel through the subarachnoid space along the underside of the tentorium cerebelli (see Figure 13.3) and then enter the cavernous sinus to reach the orbit via the superior orbital fissure, and they innervate the superior oblique muscles (see Figure 13.1).

The **abducens nuclei** lie on the floor of the fourth ventricle under the facial colliculi in the mid-to-lower pons (see Figures 12.2B, 12.11). Abducens fibers travel ventrally to exit at the pontomedullary junction (see Figure 12.2A). The abducens nerve must then follow a long course in the subarachnoid space, ascending between the

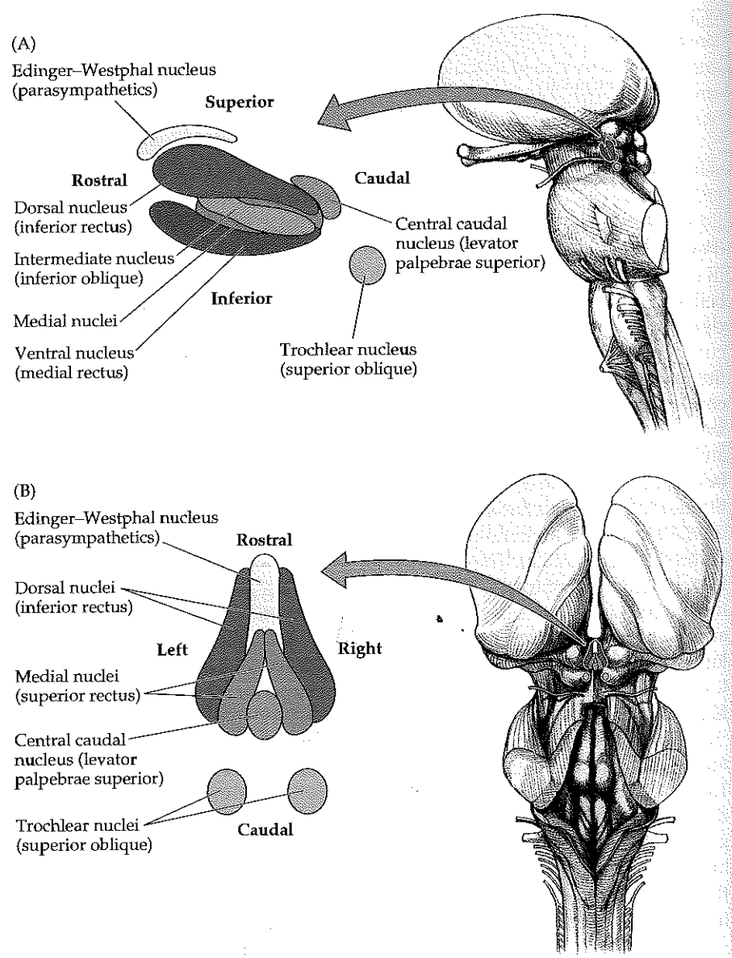

Figure 13.3 Oculomotor Nuclear Complex (A) Left lateral view. (B) Dorsal view. The trochlear nuclei are also shown.

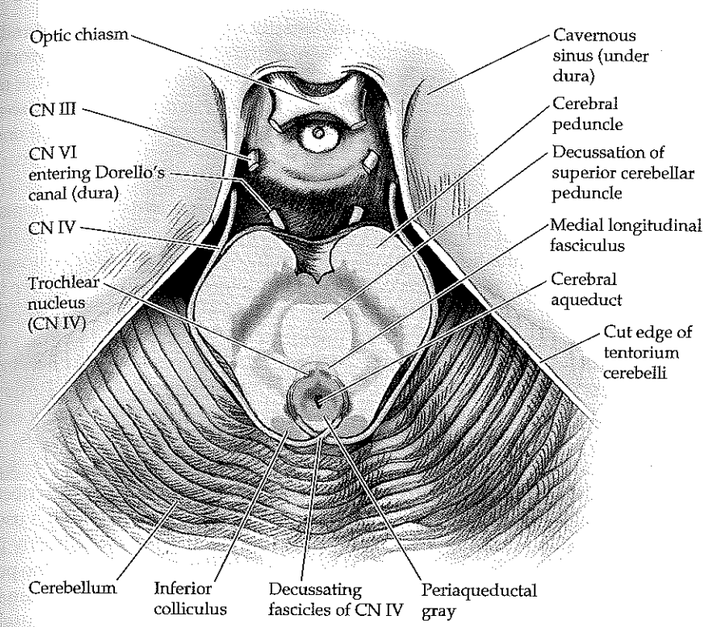

Figure 13.4 Trochlear Nerves (CN IV) and Abducens Nerves (CN VI) in Situ View is from above, with the forebrain and upper midbrain removed, showing the trochlear nuclei in the caudal midbrain and the trochlear nerves (CN IV) in relation to adjacent structures. Also shown are abducens nerves (CN VI) originating from the pontomedullary junction (not visible; see Figure 12.2A) and ascending along the clivus, and piercing the dura to enter Dorello's canal.

pons and clivus (see Figure 12.1). The abducens nerve then exits the dura to enter **Dorello's canal,** running between the dura and skull, under the petroclinoid ligament (see Figures 12.3A, 13.4). It next makes a sharp bend as it passes over the petrous tip of the temporal bone to reach the cavernous sinus (see Figure 13.11). This long vertical course may explain why the abducens nerve is highly susceptible to downward traction injury produced by elevated intracranial pressure (see KCC 5.3). After traversing the cavernous sinus, the abducens nerve enters the orbit via the superior orbital fissure to innervate the lateral rectus muscle (see Figure 13.1).

KEY CLINICAL CONCEPT
DIPLOPIA

Diplopia (double vision) can be caused by (1) mechanical problems such as orbital fracture with muscle entrapment; (2) disorders of the extraocular muscles such as thyroid disease, or orbital myositis (orbital pseudotumor); (3) disorders of the neuromuscular junction such as myasthenia gravis; or (4) disorders of CN III, IV, VI and their central pathways. In the following sections we will review some disorders of CN III, IV, and VI and their brainstem nuclei that cause diplopia. Diplopia can also occasionally be caused by disorders involving the supranuclear oculomotor pathways such as internuclear ophthalmoplegia (INO) (see KCC 13.8), skew deviation (see KCC 13.3), and ingestion of toxins such as alcohol or anticonvulsant medications.

In taking the history from patients with previous episodes of diplopia, the examiner should ask if the diplopia went away during the episodes when the patient closed or covered one eye. This symptom suggests that the diplopia was caused by an eye movement abnormality. In mild dysconjugate gaze, patients may report only visual blurring, without actual diplopia. Monocular diplopia or polyopia (three or more images) can be caused by ophthalmological disease, disorders of the visual cortex, or psychiatric conditions, but not by eye movement abnormalities. In addition, patients should be asked if the diplopia was worse with near or far objects, when looking up or down or to the left or right, because this information can help localize the cause of diplopia, as we will see later in the chapter.

MNEMONIC

On examination, eye movements are usually reported in degrees or millimeters from the primary position. When an extraocular muscle is not working properly, **dysconjugate gaze** results, causing diplopia. A helpful rule of thumb is that the *image farther toward the direction of gaze is always the one seen by the abnormal eye.* For example, when looking at an object to the right, if one eye does not move to the right then it will form a second image that appears displaced to the right.

The **red glass test** can also be helpful in examining patients with diplopia. A transparent piece of red glass or plastic is held over one eye, usually the right, and a small white light is held directly in front of the patient. The image seen by the right eye is therefore red, and the image seen by the left eye is white. The patient is then asked to follow the light as it is moved to nine different positions of gaze, and to report the locations of the white and red images. Normally the white and red images are fused in all positions of gaze. Examples of the red glass test in different kinds of diplopia are shown in Figures 13.5–13.7. More quantitative methods for measuring diplopia—usually employed by eye movement specialists—are also available.

Abnormal lateral deviation of one eye is called **exotropia,** and abnormal medial deviation is called **esotropia.** Vertical deviation is usually described only with respect to the eye that is higher, and it is called **hypertropia.** A useful test for subtle dysconjugate gaze is to shine a flashlight from directly in front of the patient on both eyes simultaneously, and then to examine the position of the reflection of the light on each cornea. Normally the reflection is symmetrical on the two corneas. Another helpful test for subtle eye muscle weakness is the **cover–uncover test.** Visual input normally helps maintain the eyes yoked in the same direction. Therefore, when an eye is covered while looking in the direction of a weak muscle, it may drift slightly back toward the neutral position. This mild weakness present ouly with an eye covered is called a **phoria** (as in exophoria, esophoria, etc.) in contrast to a tropia.

In young children, because the visual pathways are still developing, congenital eye muscle weakness can produce **strabismus** (dysconjugate gaze) that over time causes suppression of one of the images, resulting in **amblyopia** (decreased vision in one eye). For this reason, early intervention is essential. ■

KEY CLINICAL CONCEPT
OCULOMOTOR PALSY (CN III)

13.2 Complete disruption of oculomotor nerve function causes paralysis of all extraocular muscles except for the lateral rectus and superior oblique. Therefore, the only remaining movements of the eye are some abduction and some depression and intorsion (see Figure 13.1; Table 13.1). Because of decreased tone in all muscles except the lateral rectus and superior oblique, the eye may come to lie in a **"down and out"** position at rest (Figure 13.5A). In addition, paralysis of the levator palpebrae superior causes the eye to be closed (complete ptosis) unless the upper lid is raised with a finger. The pupil is dilated and unresponsive to light because of involvement of the parasympathetic fibers that run with the oculomotor nerve.

MNEMONIC

Partial impairment of oculomotor nerve function can cause different combinations of these findings to appear in milder form. For example, the eye movements may be impaired, with minimal pupil abnormalities, or the pupil may be involved, with only mild eye movement abnormalities.

When the examiner takes the history of someone with oculomotor palsy, the patient may report that the diplopia is worse when looking at near objects and better when looking at distant objects, since convergence is impaired. Red glass testing in third-nerve palsy generally reveals **diagonal diplopia** that is most severe when looking up and medially with the affected eye (see Figure 13.5B).

Common causes of oculomotor nerve palsy include diabetic neuropathy and head trauma in which shearing forces damage the nerve. Another important cause of oculomotor palsy is compression of the nerve by intracranial aneurysms, most often arising from the junction of the posterior communicating artery (Pcomm) with the internal carotid artery (see Figures 13.2, 5.6; KCC 5.6). Less commonly, third-nerve palsy can be caused by aneurysms arising from the PComm–posterior cerebral artery (PCA) junction, from the basilar artery–PCA junction, or from the basilar artery–superior cerebellar artery (SCA) junction (see Figure 5.20). The oculomotor nerve can also be damaged by other abnormalities in the subarachnoid space, cavernous sinus, or orbit, such as infection, tumor, or venous thrombosis. Herniation of the medial temporal lobe over the edge of the tentorium cerebelli can compress the oculomotor nerve (see Figure 13.2; see also Figure 5.6). Recall that in addition to an ipsilateral oculomotor palsy, transtentorial uncal herniation also often causes coma and hemiplegia (see KCC 5.4). Ophthalmoplegic migraine is a condition usually seen in children that causes reversible oculomotor nerve palsy. Lesions in the midbrain such as lacunar infarcts (see KCC 10.4), or other infarcts involving the oculomotor nucleus or the exiting nerve fascicles, can also cause an oculomotor palsy (see Figure 14.20A; Table 14.9; see also Table 13.2). In addition, muscle disorders, or disorders of the neuromuscular junction such as myasthenia gravis (see KCC 8.1), can sometimes mimic the eye movement abnormalities and ptosis seen in oculomotor palsy.

Since aneurysms can cause life-threatening intracranial hemorrhage (see KCC 5.6), there should be a high index of suspicion for aneurysms in patients presenting with third-nerve palsy. Aneurysms classically cause a **painful oculomotor palsy that involves the pupil.** The oculomotor palsy may be subtle or complete. These patients should be considered to have a PComm aneurysm until proven otherwise. A good-quality CT or MRI/MRA scan should be done without delay, followed immediately by a conventional four vessel **angiogram,** to establish the diagnosis and guide treatment. ***Complete* oculomotor palsy that *spares* the pupil** is not caused by aneurysms (with rare exceptions); it is usually caused by diabetes. The reason is thought to be that the parasympathetic fibers are located near the surface of the nerve, and if the nerve compression is severe enough to cause complete paralysis of the muscles innervated by CN III, then the pupillary fibers should be involved as well. In **partial oculomotor palsy that spares the pupil,** the findings could be caused by partial compression of CN III by an aneurysm, so an angiogram is usually necessary.

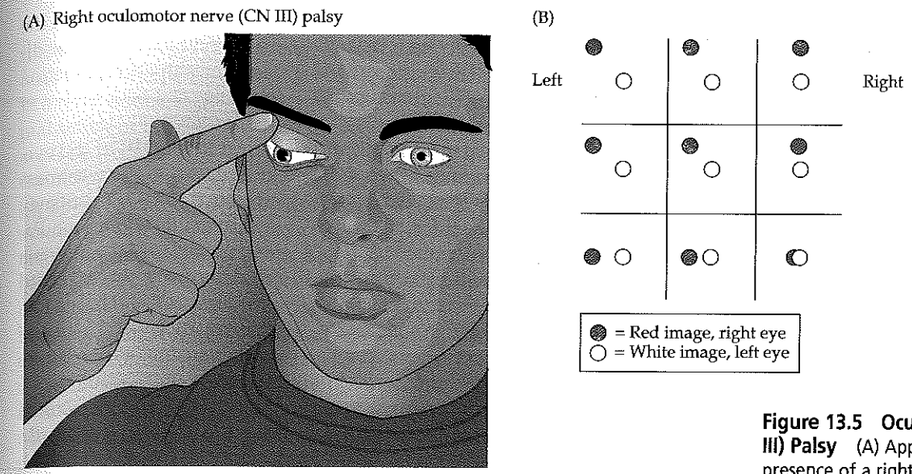

Figure 13.5 Oculomotor Nerve (CN III) Palsy (A) Appearance of eyes in the presence of a right oculomotor nerve palsy. (B) Results of red glass testing with right oculomotor nerve palsy. Red glass was placed over the right eye.

REVIEW EXERCISE

How would the eyes appear for a patient with a complete *left* oculomotor nerve palsy? Draw the expected results of red glass testing for this patient. (Compare to Figure 13.5.)

Lesions of the oculomotor nerve within the orbit can sometimes affect the superior division or inferior division in isolation. A lesion of the superior division causes weakness of the superior rectus and levator palpebrae superior, producing so-called double elevator palsy. ■

KEY CLINICAL CONCEPT
TROCHLEAR PALSY (CN IV)

13.3 The trochlear nerve produces **depression and intorsion** of the eye. Therefore, in trochlear nerve palsy there is **vertical diplopia.** If the weakness is severe, the affected eye may show **hypertropia** (Figure 13.6A). There may also be extorsion of the eye, which is not usually visible to the examiner. Patients with trochlear nerve palsy often report that they can improve the diplopia by looking up (chin tuck) and by **tilting the head away from the affected eye** because these maneuvers compensate for the hypertropia and extorsion, respectively (see Figure 13.6A). In addition, recall that the depressing action of the superior oblique is most pronounced when the eye is adducted (see Figure 13.1D; Table 13.1). Therefore, the vertical diplopia is most severe when the affected eye is looking downward and toward the nose, which can be confirmed with red glass testing (see Figure 13.6B). To summarize, diagnosing a fourth-nerve palsy usually involves demonstrating typical findings through the following **four steps** (Bielschowsky three step test, plus the "missing step"):

1. The affected eye has hypertropia.
2. Vertical diplopia worsens when the affected eye looks nasally.
3. Vertical diplopia improves with head tilt away from the affected eye.
4. Vertical diplopia worsens with downgaze.

MNEMONIC

Another test that is sometimes useful is to have the patient look at a horizontal line. In a trochlear-nerve palsy, the patient will see two lines, with the lower line tilted (see Figure 13.6C). These two lines form an arrowhead with the "point" directed toward the affected side.

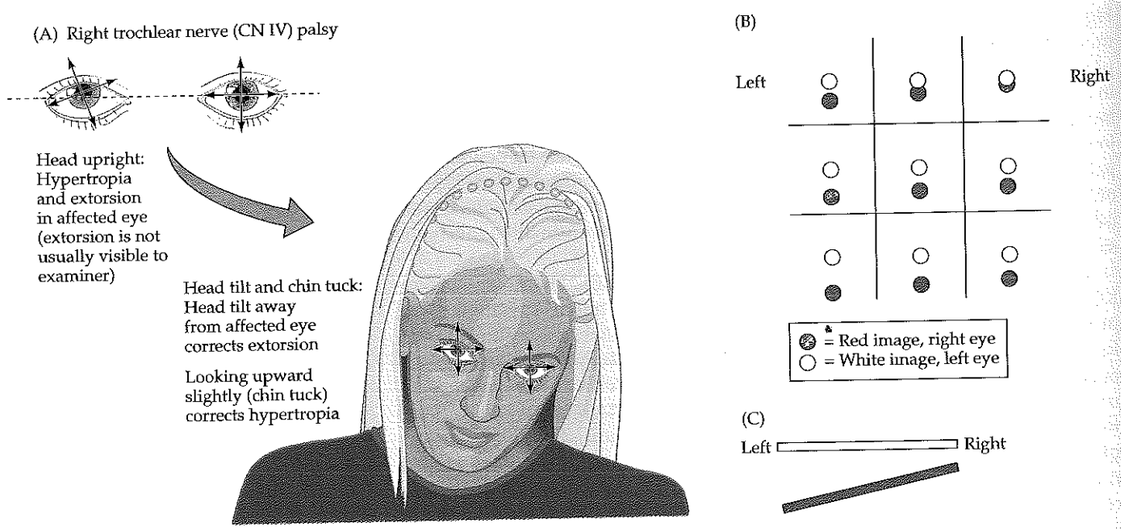

Figure 13.6 Trochlear Nerve (CN IV) Palsy (A) Appearance of eyes in the presence of a right trochlear nerve palsy. Hypertropia can be compensated for by tucking the chin and looking up slightly. Extorsion can be compensated for by tilting the head away from the affected eye. (B) Results of red glass testing with right trochlear nerve palsy. Red glass was placed over the right eye. (C) Appearance of a horizontal white line to the patient with a red glass over the right eye.

MNEMONIC

The relationship between compensatory head positions and eye movement abnormalities can easily be remembered because *the head movement is always in the direction of action normally served by the affected muscle.* For example, in a right trochlear palsy the head is held down and tilted to the left; the normal action of the right trochlear nerve is depression and intorsion of the eye.

The trochlear nerve is the most commonly injured cranial nerve in head trauma, probably because of its long course and thin caliber, making it susceptible to shear injury. Other causes of trochlear nerve pathology in the subarachnoid space, cavernous sinus, or orbit include neoplasm, infection, and aneurysms. In many cases the cause remains unknown, and these cases may be caused by microvascular damage to the nerve, especially in patients with diabetes. Vascular or neoplastic disorders within the midbrain or near the tectum (e.g., pineal gland or anterior cerebellum) can also affect the trochlear nuclei or nerve fascicles.

Other causes of **vertical diplopia** include disorders of extraocular muscles, myasthenia gravis, lesions of the superior division of the oculomotor nerve affecting the superior rectus, and skew deviation. **Skew deviation** is defined as a vertical disparity in the position of the eyes of supranuclear origin. Unlike trochlear palsy, in skew deviation the vertical disparity is typically (but not always) relatively constant in all positions of gaze. Skew deviation can be caused by lesions of the cerebellum, brainstem, or even the inner ear.

Other causes of **head tilt** include cerebellar lesions, meningitis, incipient tonsillar herniation, and torticollis. It is often helpful to look at old photographs to establish if the head tilt is old or new. ■

REVIEW EXERCISE

How would the eyes appear and what head position would be seen in a patient with a complete *left* trochlear nerve palsy? Draw the expected results of red glass testing for this patient. (Compare to Figure 13.6.)

KEY CLINICAL CONCEPT
ABDUCENS PALSY (CN VI)

13.4 Lesions of the abducens nerve produce **horizontal diplopia.** In some cases esotropia (see KCC 13.1) of the affected eye may be present as well. In contrast to a third-nerve palsy, patients report that the diplopia is better when they are viewing near objects and worse when they are viewing far objects. On examination, the affected eye does not abduct normally (Figure 13.7A). In milder abducens palsy these may simply be **incomplete "burial of the sclera,"** on lateral gaze. Diplopia worsens when the patient tries to abduct the affected eye, which can be confirmed by red glass testing (Figure 13.7B). Some patients may tend to turn the head toward the affected eye in an effort to compensate for the diplopia. A subtle sixth-nerve palsy can sometimes be detected

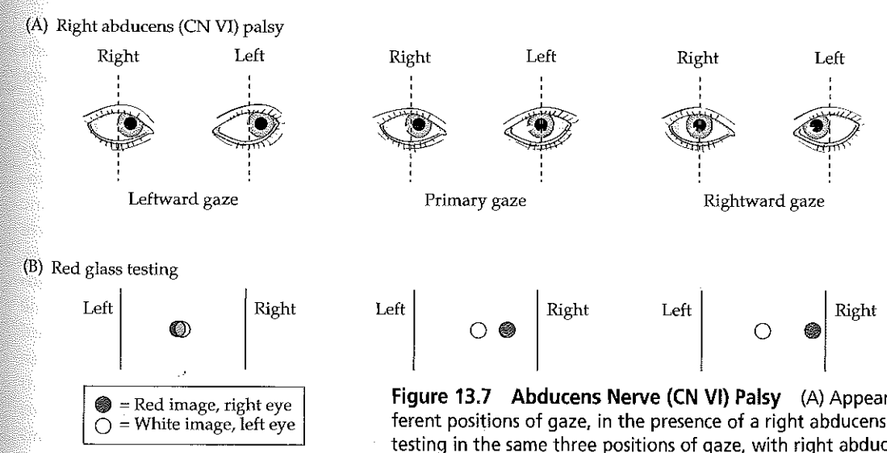

Figure 13.7 Abducens Nerve (CN VI) Palsy (A) Appearance of eyes in three different positions of gaze, in the presence of a right abducens nerve palsy. (B) Red glass testing in the same three positions of gaze, with right abducens nerve palsy. Red glass was placed over the right eye.

REVIEW EXERCISE

How would the eyes appear in primary gaze for a patient with a complete *left* abducens nerve palsy? Draw the expected results of red glass testing for this patient. (Compare to Figure 13.7.)

by testing bilateral horizontal saccades (see neuroexam.com Video 33) and observing the slight lag in abduction of the affected eye, or by using the cover–uncover test while the affected eye looks laterally (see KCC 13.1).

Because of its long course along the clivus and over the sharp ridge of the petrous temporal bone (see Figures 13.4, 12.1, 12.2A, 12.3A), the abducens nerve is particularly susceptible to injury from downward traction caused by elevated intracranial pressure (see KCC 5.3). Abducens palsy is therefore an important early sign of supratentorial or infratentorial tumors, pseudotumor cerebri, hydrocephalus, and other intracranial lesions. The abducens palsy seen with elevated intracranial pressure can be unilateral or bilateral. Other causes of damage to the sixth nerve can occur in the subarachnoid space, cavernous sinus, or orbit. Common disorders include head trauma, infection, neoplasm, inflammation, aneurysms, and cavernous sinus thrombosis. As with oculomotor and trochlear palsies, many cases of acute abducens palsy lack a demonstrated cause, and this condition may result from a microvascular neuropathy like that seen in diabetes.

Pontine infarcts or other disorders affecting the exiting abducens fascicles in the pons (see Figure 12.11) cause weakness of ipsilateral eye abduction resembling a peripheral abducens nerve lesion. However, lesions of the abducens nucleus in the pons produce not a simple abducens palsy, but instead a horizontal *gaze* palsy in the direction of the lesion. As we will discuss in the section on supranuclear control of eye movements later in this chapter, in a **gaze palsy**, movements of *both* eyes in one direction are decreased (see Figure 13.13B, Lesion 2). In addition, lesions of the abducens nucleus often affect the nearby fibers of CN VII in the facial colliculus, resulting in ipsilateral facial weakness (see Figure 12.11; Table 14.8).

Other causes of **horizontal diplopia** include myasthenia gravis and disorders of the extraocular muscles caused by thyroid disease, tumors, inflammation, or orbital trauma. Supranuclear disorders of horizontal gaze and convergence will be discussed later in this chapter. ■

The Pupils and Other Ocular Autonomic Pathways

The pupils are controlled by both parasympathetic and sympathetic pathways. The **parasympathetic** pathways involved in pupillary constriction are shown in Figure 13.8 (see also Figure 12.6). Light entering one eye activates retinal ganglion cells, which project to both optic tracts because of fibers crossing over in the optic chiasm. Fibers in the extrageniculate pathway continue in the brachium of the superior colliculus past the lateral geniculate nucleus to reach the **pretectal area** (Figure 13.8; see also Figure 11.6) just rostral to the midbrain. After synapsing, axons then continue bilaterally to the **Edinger–Westphal nuclei,** which contain preganglionic parasympathetic neurons. Some of the crossing fibers travel in the **posterior commissure** (see Figure 13.8; see also Figure 12.1). The Edinger–Westphal nuclei lie just dorsal and anterior to the oculomotor (CN III) nuclei near the midline (see Figures 13.3, 14.3A). Preganglionic parasympathetic fibers travel bilaterally from the Edinger–Westphal nuclei via the oculomotor nerves to reach the **ciliary ganglia** in the orbit (see Figure 13.8). From there, postganglionic parasympathetics continue to the **pupillary constrictor muscles** to cause the pupils to become smaller. Note that a light shone in one eye causes a **direct response** in the same eye and a **consensual response** in the other eye (see neuroexam.com Video 29) because information crosses bilaterally at multiple levels.



Pupil light reflex

Bilateral pupillary constriction also occurs through a slightly different circuit during the **accommodation response** (see neuroexam.com Video 31). This

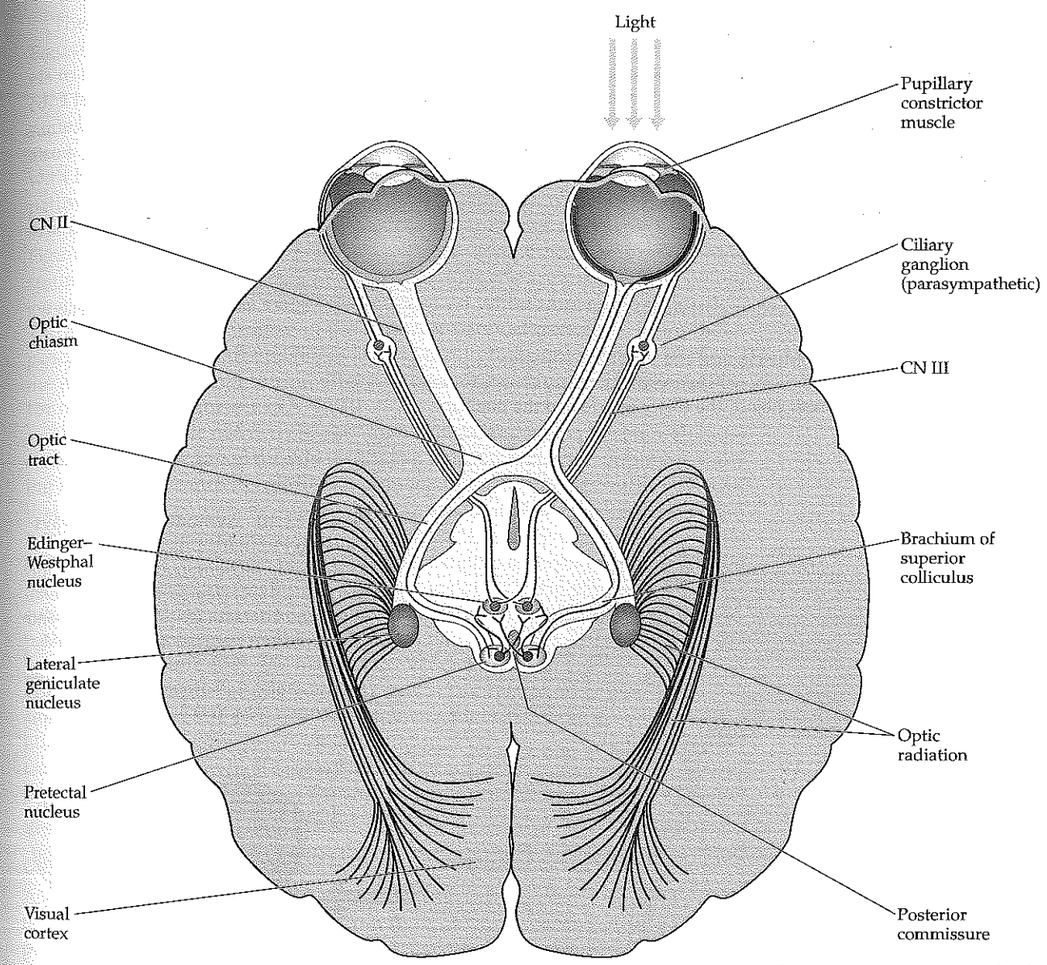

Figure 13.8 Parasympathetic Pathways Causing Pupillary Constriction

response occurs when a visual object moves from far to near, and it has the following three components:

- Pupillary constriction
- Accommodation of the lens ciliary muscle
- Convergence of the eyes

The accommodation response is activated by visual signals relayed to the **visual cortex** (see Figure 13.8). From there, through pathways still under investigation, the pretectal nuclei are again activated, causing bilateral pupillary constriction mediated by the parasympathetic pathways shown in Figure 13.8. Contraction of the **ciliary muscle** of the lens is parasympathetically mediated by the same pathway. Note that the lens is normally under tension from the suspensory ligament (Figure 13.9A). The ciliary muscle acts as a sphincter (like the pupillary constrictor), so when it contracts it causes the suspensory ligament to relax, producing a rounder, more convex lens shape (Figure 13.9B). Convergence is mediated by mechanisms described later in this chapter.

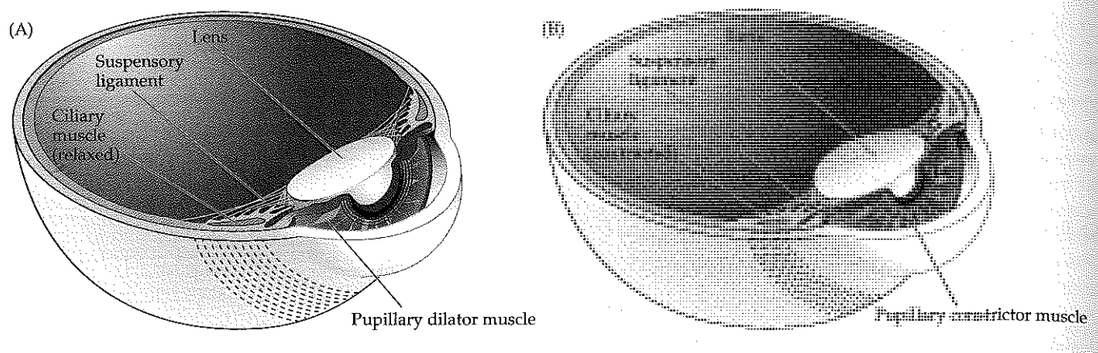

Figure 13.9 Actions of the Ciliary Muscle and the Pupillary Muscles
(A) When viewing a distant object, the ciliary muscle and the pupillary constrictor muscle are relaxed. (B) When viewing a near object, the ciliary muscle and the pupillary constrictor muscle contract.

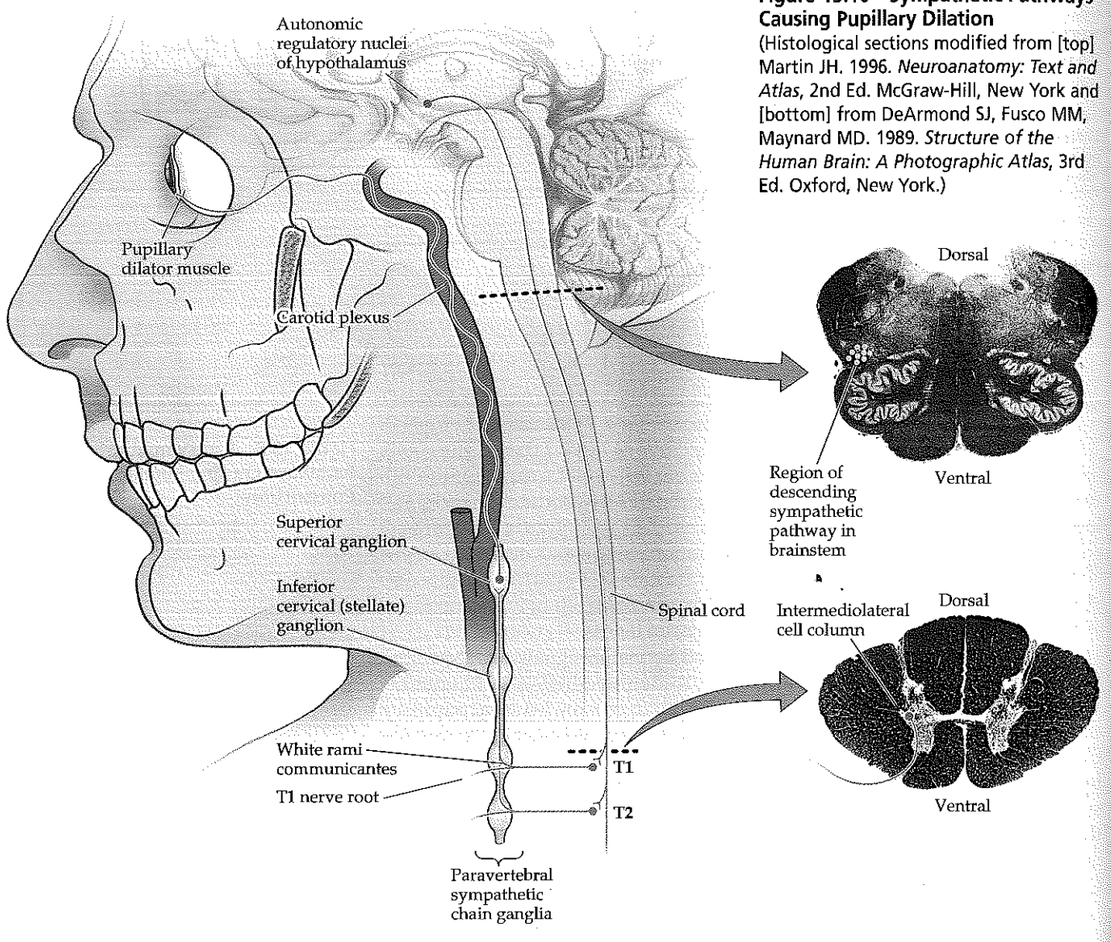

Figure 13.10 Sympathetic Pathways Causing Pupillary Dilation
(Histological sections modified from [top] Martin JH. 1996. *Neuroanatomy: Text and Atlas*, 2nd Ed. McGraw-Hill, New York and [bottom] from DeArmond SJ, Fusco MM, Maynard MD. 1989. *Structure of the Human Brain: A Photographic Atlas*, 3rd Ed. Oxford, New York.)

The **sympathetic** pathway responsible for pupillary dilation is shown in Figure 13.10. A descending sympathetic pathway from the hypothalamus travels in the lateral brainstem and cervical spinal cord to reach thoracic spinal cord levels T1 and T2. This pathway is thought to be in approximately the same location in the brainstem as the spinothalamic tract (see Figure 13.10; see also Figure 7.2) because lesions of the spinothalamic tract tend to be associated with Horner's syndrome (see KCC 13.5, 13.6). This descending sympathetic pathway activates preganglionic sympathetic neurons in the **intermediolateral cell column** of the upper thoracic cord (see Figure 13.10, inset; see also Figures 6.12B, 6.13). Axons of the preganglionic sympathetic neurons exit the spinal cord via ventral roots T1 and T2, and skirt the apex of the lung before joining the **paravertebral sympathetic chain** via **white rami communicantes.** The axons ascend to synapse in the **superior cervical ganglion.** From there, postganglionic sympathetic fibers ascend through the **carotid plexus** along the walls of the internal carotid artery, ultimately reaching the **pupillary dilator muscle** (see Figures 13.9A, 13.10).

This sympathetic pathway is also important in controlling the smooth muscle of the **superior tarsal muscle (Müller's)**, which elevates the upper lid, causing a wide-eyed stare in conditions of increased sympathetic outflow. Recall that the levator palpebrae superior is composed of skeletal muscle and also functions in eyelid opening under the control of CN III. Sympathetics from the pathway shown in Figure 13.10 also innervate the smooth muscle **orbitalis (Müller's)**, which prevents the eye from sinking back in the orbit, as well as the cutaneous arteries and sweat glands of the face and neck. These various sympathetic functions are impaired in Horner's syndrome (see KCC 13.5, 13.6). ■

REVIEW EXERCISE

Fill in the blanks: Preganglionic parasympathetic fibers travel from the _____ nucleus in the midbrain via the _____ nerve to reach neurons in the _____ ganglion. The postganglionic parasympathetic fibers, in turn, project to the pupillary _____ muscle of the iris. (See Figure 13.8.)

KEY CLINICAL CONCEPT
PUPILLARY ABNORMALITIES

13.5 Abnormalities of the pupil can be caused by peripheral or central lesions, by sympathetic or parasympathetic lesions, or by disorders of the iris muscle or visual pathways. Pupillary abnormalities can be bilateral or can affect one side only, in which case **anisocoria,** or pupillary asymmetry, is present. In the subsections that follow, we will review the anatomical basis of several important pupillary abnormalities.

Oculomotor Nerve Lesion

As discussed earlier under oculomotor palsy (see KCC 13.2), lesions of the efferent parasympathetic pathway from the Edinger–Westphal nucleus to the pupillary constrictor muscle (see Figure 13.8) can cause **impaired pupillary constriction,** resulting in a unilateral **dilated pupil.** When the lesion is complete, the pupil is very large and is sometimes called a "blown pupil." The anisocoria is more obvious in ambient light than in a darkened room (Table 13.3A). There is a decreased or absent direct response when light is shone in the affected eye, as well as a decreased or absent consensual response when light is shone in the opposite eye.

Horner's Syndrome

This important constellation of findings is caused by disruption of sympathetic pathways to the eye and face (see Figure 13.10). The classic syndrome consists of **ptosis, miosis, and anhidrosis,** as well as several other minor abnormalities. **Ptosis,** or upper eyelid drooping, is caused by loss of innervation to Müller's smooth muscle in the upper lid. **Miosis,** or decreased pupillary size, is caused by loss of sympathetic innervation to the pupillary dilator muscle, resulting in **impaired dilation of the pupil.** Unlike oculomotor nerve lesions, anisocoria is more obvious in the dark than in ambient light (see Table 13.3B). Careful observation can reveal that the pupil still has a direct and consensual constricting response to light. However, there is a **dilation lag** relative to the normal pupil when the light is removed. Testing the **ciliospinal reflex** is some-

REVIEW EXERCISE

Fill in the blanks: Fibers controlling sympathetic outflow descend from the hypothalamus through the _____ (medial or lateral) brainstem and spinal cord to reach preganglionic sympathetic neurons in the _____ cell column. These exit via the _____ and _____ roots and ascend in the sympathetic chain to synapse on neurons in the _____ ganglion. The postganglionic sympathetic fibers then ascend along the carotid plexus to ultimately reach the pupillary _____ muscle of the iris. (See Figure 13.10.)

TABLE 13.3 Common Pupil Abnormalities

LESION OR CONDITION	DARK ROOM	AMBIENT LIGHT	DIRECT RESPONSE: LIGHT IN AFFECTED EYE	CONSENSUAL RESPONSE: LIGHT IN UNAFFECTED EYE	COMMENTS
A. Left oculomotor nerve lesion					There may be associated ptosis and eye movement abnormalities.
B. Left Horner's syndrome					There is a dilation lag in going from light to dark. Other features of Horner's syndrome (ptosis, anhidrosis) may be present.
C. Left afferent pupillary defect					The swinging flashlight test (neuroexam.com Video 30) is useful in subtle cases.
D. Benign essential anisocoria					The same relative anisocoria is present in all lighting conditions. No dilation lag.

times useful. In this test a painful pinch to the neck activates sympathetic outflow, causing pupillary dilation on the normal side but not on the side with Horner's syndrome. **Anhidrosis,** or decreased sweating of the ipsilateral face and neck, is also caused by loss of sympathetic innervation. A simple way to test for this finding is to rub a finger along the skin, which may feel smoother on the affected side because of decreased moisture.

Horner's syndrome can be caused by lesions anywhere along the sympathetic pathway shown in Figure 13.10. Therefore, **possible locations for lesions causing Horner's syndrome** include:

1. Lateral brainstem (e.g., infarct or hemorrhage; see KCC 14.3)
2. Spinal cord (e.g., trauma)
3. First and second thoracic roots (e.g., apical lung tumor [Pancoast syndrome] or trauma; see KCC 9.1)
4. Sympathetic chain (e.g., tumor or trauma)
5. Carotid plexus (e.g., carotic dissection; see KCC 10.6)
6. Cavernous sinus (e.g., thrombosis, infection, aneurysm, or neoplasm; see KCC 13.7)
7. Orbit (e.g., infection or neoplasm; see KCC 13.7)

Postganglionic lesions are not usually associated with anhidrosis because the sympathetics for sudomotor innervation diverge from the oculosympathetic pathway before the superior cervical ganglion. Large bilateral lesions of the pons are sometimes associated with **pontine pupils,** in which both pupils are small but reactive to light. This small pupillary size is probably caused by bilateral disruption of the descending sympathetic pathways.

Afferent Pupillary Defect (Marcus Gunn Pupil)

In this condition the direct response to light in the affected eye is decreased or absent, while the consensual response of the affected eye to light in the opposite eye is normal (see Table 13.3C). The afferent pupillary defect is caused by **decreased sensitivity of the affected eye to light,** resulting from lesions of the optic nerve, retina, or eye. Recall that lesions at or behind the optic chiasm would affect inputs from both eyes (see Figure 13.8) and therefore do not generally produce a Marcus Gunn pupil.* A useful way to detect an afferent pupillary defect is with the **swinging flashlight test** (neuroexam.com Video 30). The flashlight is moved back and forth between the eyes every 2 to 3 seconds. The afferent pupillary defect becomes obvious when the flashlight is moved from the normal to the affected eye, and the affected pupil *dilates* in response to light (see Table 13.3C). This abnormal dilation should be distinguished from **hippus,** which is a normal brief oscillation of the pupil size that sometimes occurs in response to light.

Swinging flashlight test

Benign (Essential, Physiological) Anisocoria

A slight pupillary asymmetry of less than 0.6 millimeters is seen in 20% of the general population. This asymmetry can vary from one examination to the next, sometimes within a few hours. There are no other associated abnormal findings, such as dilation lag, changes in the asymmetry with lighting conditions, or eye movement abnormalities (see Table 13.3D).

Pharmacological Miosis and Mydriasis

Numerous pharmacological agents can affect pupillary size and can cause confusion in diagnosis, particularly in the comatose patient. Opiates cause bilateral pinpoint pupils, and barbiturate overdose can also cause bilateral small pupils, mimicking pontine lesions. Anticholinergic agents affecting muscarinic receptors, such as scopolamine or atropine, can cause dilated pupils. Pupillary dilation may be unilateral if topical exposure occurs in one eye only, mimicking uncal herniation. When exposure to anticholinergic agents is suspected, 1% pilocarpine eyedrops can be useful because they cause pupillary constriction in parasympathetic lesions but cannot overcome pharmacological muscarinic blockade. In general, diagnosis and treatment of suspected acute brainstem lesions should not be delayed, but the history should include possible drug exposure, and laboratory testing must include a toxicology screen. Pharmacological testing using eyedrops containing cocaine, hydroxyamphetamine, or different strengths of pilocarpine can be useful for establishing the diagnosis in cases of anisocoria with equivocal or subtle findings (see the References for additional details).

Light–Near Dissociation

In **light–near dissociation,** the pupils constrict much less in response to light than to accommodation (see Figure 13.8). The mechanism for this disparity is not known for certain, and the mechanism may not be the same in different disorders. The classic example of light–near dissociation is the **Argyll Robertson pupil** associated with neurosyphilis, in which, in addition to light–near dissociation, the pupils are also small and irregular. Light–near dissociation can also be seen in diabetes and Adie's myotonic pupil (see the next subsection), and as

*Optic tract lesions (an uncommon disorder) can reportedly be associated with a contralateral afferent pupillary defect. In addition, with specialized testing (in which a light is shone onto one-half of the retina at a time), an afferent pupillary defect can be demonstrated in the ipsilateral hemiretina of both eyes for lesions behind the optic chiasm.

part of Parinaud's syndrome (see KCC 13.9), which is associated with compression of the dorsal midbrain.

Adie's Myotonic Pupil

This disorder is characterized by degeneration of the ciliary ganglion or postganglionic parasympathetic neurons (see Figure 13.8) resulting in a mid-dilated pupil that reacts poorly to light. Some pupillary constriction can be elicited with the accommodation response, but the pupil then remains constricted and dilates very slowly. The cause is not known.

Midbrain Corectopia

In this relatively rare condition, lesions of the midbrain can sometimes cause an unusual pupillary abnormality in which the pupil assumes an irregular, off-center shape. ■

KEY CLINICAL CONCEPT
PTOSIS

13.6 **Eye opening** is performed by striated skeletal muscle of the levator palpebrae superior (CN III) together with Müller's smooth muscle in the upper lid (sympathetics). The frontalis muscle of the forehead (CN VII) performs an accessory role. **Eye closure** is performed by the orbicularis oculi muscle (CN VII).

Ptosis, or drooping of the upper eyelid, can be seen in Horner's syndrome, as discussed in KCC 13.5. Other causes of unilateral or bilateral ptosis include oculomotor nerve palsy affecting the levator palpebrae superior, myasthenia gravis, and redundant skin folds associated with aging (pseudoptosis). Causes of bilateral ptosis or closed eyes without loss of consciousness include nondominant parietal lobe lesions, dorsal lesions of the oculomotor nuclei affecting the central caudal nucleus (see Figure 13.3; Table 13.2), and voluntary eye closure associated with photophobia in migraine or meningeal irritation.

Weakness of the orbicularis oculi caused by facial nerve or upper motor neuron lesions (see Figure 12.13) can cause a widened palpebral fissure that may be mistaken for ptosis in the opposite eye. Careful examination of the lids using the irises as a reference point can usually resolve this dilemma: In ptosis the upper lid comes down farther over the iris in the affected eye (see Figure 13.05A), while in facial weakness the palpebral fissure is widened mainly because of sagging of the lower lid in the affected eye (see Figure 12.13). ■

Cavernous Sinus and Orbital Apex

We will now briefly discuss the cavernous sinus and orbital apex because CN III, IV, and VI all pass through this region and lesions here produce characteristic syndromes that often affect eye movements (see KCC 13.7). The **cavernous sinus** consists of a collection of venous sinusoids located on either side of the pituitary that receives venous blood from the eye and superficial cortex and ultimately drains via several pathways into the internal jugular vein (see Figure 10.11A,B). Like other venous sinuses, the cavernous sinus lies between the periosteal and dural layers of the dura mater. The cavernous sinus surrounds the **carotid siphon** and several important nerves (Figure 13.11; see also Figures 12.3A, 13.2, and 13.4): the **abducens nerve (CN VI)**, which lies closest to the carotid; and the **oculomotor (CN III)**, **trochlear (CN IV)**, and **ophthalmic (CN V_1)** nerves, which run in sequence within the lateral wall of the cavernous sinus (see Figure 13.11). These nerves pass forward to enter the orbital apex via the superior orbital fissure (see Figure 12.3A,C). The **maxillary nerve (CN V_2)** skirts the lower portion of the cavernous sinus and often runs through it for a short distance before exiting via the foramen rotundum (see Figure 12.3A). **Sympathetic fibers** traveling in the carotid plexus (see Figure 13.10) en route to the pupillary dilator muscle traverse the cavernous sinus as well.

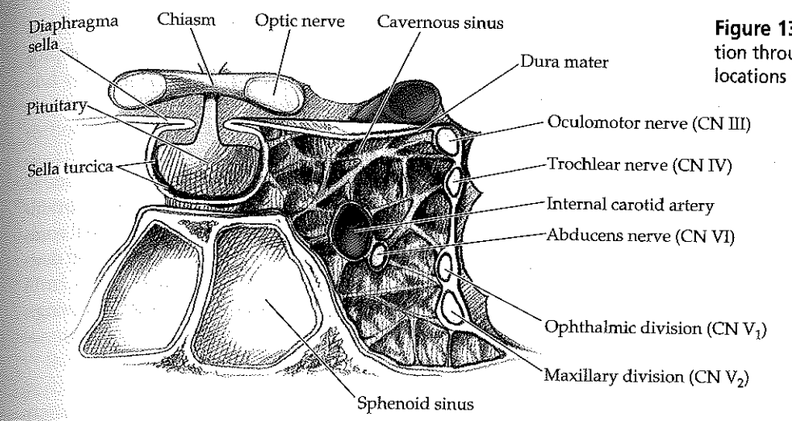

Figure 13.11 Cavernous Sinus Coronal section through the cavernous sinus, showing the locations of important nerves and blood vessels.

The optic nerve lies just above the cavernous sinus and enters the orbital apex via the optic canal (see Figures 12.3A, 13.2). The **orbital apex** is the region where nearly all nerves, arteries, and veins of the orbit converge before communicating with the intracranial cavity via the optic canal and superior orbital fissure (see Figure 12.3C). It is important to be familiar with the structures of the cavernous sinus and orbital apex to understand how lesions in these regions can affect multiple cranial nerves (see KCC 13.7).

KEY CLINICAL CONCEPT
CAVERNOUS SINUS SYNDROME (CN III, IV, VI, V_1) AND ORBITAL APEX SYNDROME (CN II, III, IV, VI, V_1)

13.7 Lesions of the cavernous sinus or orbital apex can affect isolated nerves, or they can affect all the nerves traversing these structures (see Figure 13.11). A complete lesion of the cavernous sinus disrupts CN III, IV, and VI, causing total ophthalmoplegia, usually accompanied by a fixed, dilated pupil. Involvement of CN V_1 and variable involvement of V_2 causes sensory loss in these divisions of the trigeminal nerve. Horner's syndrome can also occur because of disruption of ocular sympathetics, but this condition may be difficult to appreciate in the setting of a third nerve lesion (sometimes the Horner's syndrome is apparent in the affected eye in the dark; see Table 13.3). Orbital apex lesions produce the same deficits as cavernous sinus syndrome, but they are more likely to involve CN II also, causing visual loss, and often are associated with proptosis, or bulging of the eye, due to mass effect in the orbit. In both cavernous sinus and orbital apex lesions, partial deficits of the nerves mentioned here often occur when the lesion is less severe. Since the cavernous sinus and orbital apex are contiguous, both structures can be affected by a single lesion. Impaired venous drainage in both disorders can cause vascular engorgement of the orbital structures.

Causes of cavernous sinus syndrome include metastatic tumors, direct extension of nasopharyngeal tumors, meningioma, pituitary tumors or pituitary apoplexy, aneurysms of the intracavernous carotid, cavernous carotid arteriovenous fistula, bacterial infection causing cavernous sinus thrombosis, aseptic thrombosis, idiopathic granulomatous disease (Tolosa–Hunt syndrome), and fungal infections such as aspergillosis or mucormycosis. In cavernous carotid aneurysms or fistulas, the abducens nerve is often involved first because it lies closest to the carotid artery (see Figure 13.11). In pituitary apoplexy, there is hemorrhage within the pituitary gland, often in the setting of a pituitary tumor, which can sometimes extend into the adjacent cavernous sinus. Orbital apex syndrome can be caused by metastatic tumors, orbital cellulitis (bacterial infection), idiopathic granulomatous disease (orbital myositis or pseudotumor), and fungal infections such as aspergillosis. Cavernous sinus and orbital apex syndromes are medical emergencies requiring prompt recog-

nition, diagnosis, and treatment. When MRI scans with contrast enhancement and lumbar puncture do not reveal a specific diagnosis and symptoms are progressive, emergency orbitotomy and biopsy are warranted. ■

Supranuclear Control of Eye Movements

Circuits for the supranuclear control of eye movements extend from the brainstem and cerebellum to the forebrain and exert their influence on the final common output nuclei of CN III, IV, and VI. There appear to be at least three dedicated circuits in the brainstem that feed much of the information from supranuclear control systems to the output nuclei, generating the following:

- Horizontal eye movements
- Vertical eye movements
- Vergence eye movements

We will first discuss the brainstem pathways generating movements in these three directions. Next, for each of these movement directions we will discuss how larger-scale networks, including the cortex, basal ganglia, cerebellum, and vestibular nuclei, generate different types of eye movements for different purposes. These different types of eye movements include the following:

- **Saccades** are rapid eye movements reaching velocities of up to 700° per second (see neuroexam.com Video 33). They function to bring targets of interest into the field of view. Vision is transiently suppressed during saccadic eye movements. Saccades are the only type of eye movements that can easily be performed voluntarily, although they can be elicited by reflexes as well.
- **Smooth pursuit** eye movements are not under voluntary control, and they reach velocities of only 100° per second (see neuroexam.com Video 32). They allow stable viewing of moving objects.
- **Vergence** eye movements maintain fused fixation by both eyes as targets move toward or away from the viewer (see neuroexam.com Video 32). The velocity is about 20° per second.
- **Reflex** eye movements include optokinetic nystagmus (see neuroexam.com Video 34) and the vestibulo-ocular reflex (see neuroexam.com Video 35). **Nystagmus** is a rhythmic form of reflex eye movements composed of slow eye movements in one direction interrupted repeatedly by fast saccadelike eye movements in the opposite direction.

Figure 13.12 Brainstem Pathways for Control of Horizontal Eye Movements

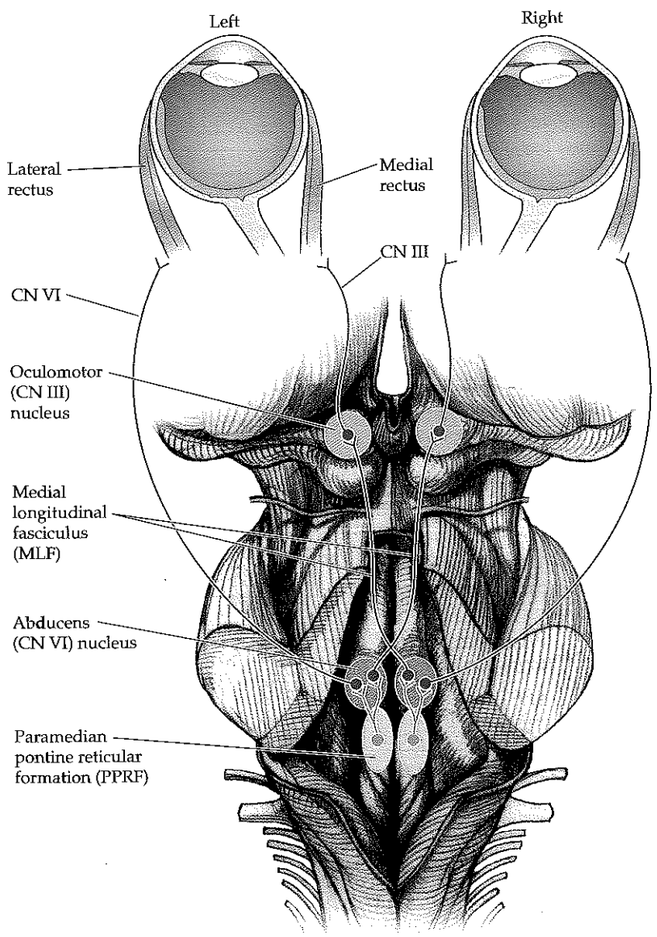

Brainstem Circuits for Horizontal Eye Movements

Horizontal eye movements are generated by the lateral rectus and medial rectus muscles, controlled by the abducens and oculomotor nuclei, respectively (Figure 13.12). As we discussed in Chapter 12, the **medial longitudinal fasciculus (MLF)** interconnects the oculomotor, trochlear, abducens, and vestibular nuclei (see Figure 12.18). Through connections in the MLF, eye movements are normally yoked together, resulting in conjugate gaze in all directions. For example, during horizontal eye movements the actions of the abducens and oculomotor nuclei are coordinated through connections in the MLF, as shown in Figure 13.12. Through this circuit, the abducens nucleus does more than just control abduction of the ipsilateral eye. In reality, the abducens nucleus is a **horizontal gaze center,** controlling horizontal movement of *both* eyes in the direction ipsilateral to the side of the nucleus (see Figure 13.12). Thus, some neurons in the abducens nucleus project to the ipsilateral lateral rectus muscle, while others project via the MLF to the contralateral oculomotor nucleus, which in turn, activates the contralateral medial rectus muscle.

In the pontine tegmentum near the abducens nucleus is an additional important horizontal gaze center called the **paramedian pontine reticular formation (PPRF)** that provides inputs from the cortex and other pathways to the abducens nucleus, resulting in lateral horizontal gaze (see Figure 13.12). As we will discuss later in this chapter, the vestibular nuclei also connect to the extraocular nuclei via the MLF, resulting in vestibulo-ocular reflexes.

KEY CLINICAL CONCEPT
BRAINSTEM LESIONS AFFECTING HORIZONTAL GAZE

13.8 Examination of Figure 13.13 should make clear how different lesions in the brainstem affect horizontal gaze. Lesions of the abducens nerve cause impaired abduction of the ipsilateral eye (see Figure 13.13, Lesion 1; see also KCC 13.4). Lesions of the abducens nerve should be distinguished from lesions of the abducens nucleus, which produce an ipsilateral **lateral gaze palsy** involving both eyes because of the connections through the MLF (see Figure

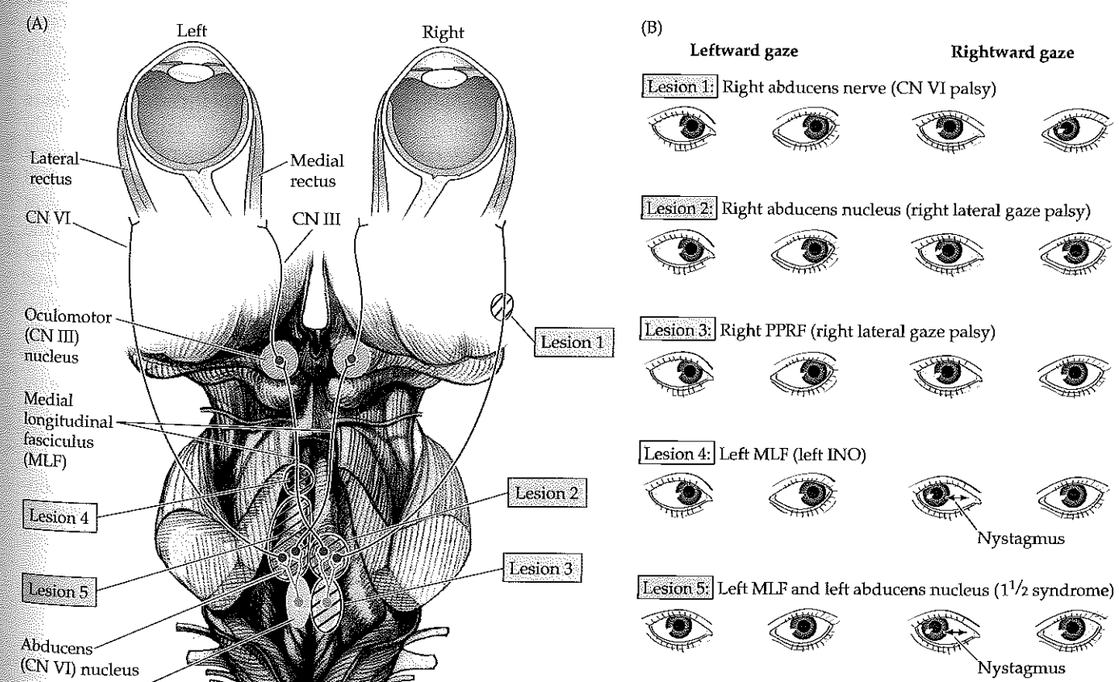

Figure 13.13 Effects of Lesions in Brainstem Pathways for Horizontal Eye Movements (A) Locations of lesions. (B) Eye movements during leftward and rightward gaze with lesions shown in (A).

REVIEW EXERCISE

1. Cover Figure 13.13B. For each lesion in Figure 13.13A, describe the expected eye positions on leftward and rightward gaze.

2. Cover the labels in Figure 13.13B. State the possible lesion locations and the side involved that would produce the eye movement abnormalities shown.

13.13, Lesion 2). Similarly, lesions of the PPRF cause an ipsilateral lateral gaze palsy (see Figure 13.13, Lesion 3).*

Lesions of the MLF interrupt the input to the medial rectus. Therefore the eye ipsilateral to the lesion does not adduct fully on attempted horizontal gaze (see Figure 13.13, Lesion 4). In addition, for uncertain reasons there is also nystagmus of the opposite eye, possibly because of mechanisms trying to bring the eyes back into alignment. This classic neurologic syndrome produced by an MLF lesion is called an **internuclear ophthalmoplegia (INO)**. By definition, the side of the INO is the side of the lesion in the MLF. In an INO, eye adduction on the affected side is impaired with horizontal gaze but is often spared during convergence because the inputs to the oculomotor nucleus mediating convergence (see the next section) arise from the pretectal region and hence do not travel in the caudal MLF. Common causes of INO include multiple sclerosis plaques, pontine infarcts, or neoplasms involving the MLF. A subtle INO can sometimes be detected only by testing of horizontal saccades in both directions (neuroexam.com video 33), and observation of a slight lag in the adduction of the eye on the affected side.

Finally, if a lesion involves both the MLF and the adjacent abducens nucleus or PPRF, there is a combination of an ipsilateral INO and an ipsilateral lateral gaze palsy (see Figure 13.13, lesion 5). Thus, the ipsilateral eye cannot move at all horizontally, and the contralateral eye loses half of its movements, preserving only its ability to abduct, resulting in the quaint name **one-and-a-half syndrome** for this disorder. ■

Brainstem Circuits for Vertical and Vergence Eye Movements

Vertical eye movements are mediated by the superior and inferior rectus and superior and inferior oblique muscles (see Figure 13.1; Table 13.1). Brainstem centers controlling vertical eye movements are located in the **rostral midbrain reticular formation and pretectal area.** The **ventral** portion of this region is thought to mediate **downgaze,** while the more **dorsal** region (in the vicinity of the posterior commissure) mediates **upgaze.** One important nucleus that is thought to mediate downgaze is the **rostral interstitial nucleus of the MLF.** Other lesser nuclei in this area that may also play a role include the nucleus of Darkschewitsch and the interstitial nucleus of Cajal. Lesions such as infarcts or tumors (discussed in the next section) of the dorsal parts of the vertical eye movement center cause impaired upgaze, while lesions in the ventral part cause impaired downgaze. In addition, in locked-in syndrome (see KCC 14.1) large pontine lesions can disrupt the bilateral corticospinal tracts and abducens nuclei, eliminating body movements and horizontal eye movements. However, sometimes the vertical eye movement centers in the midbrain are spared, allowing the patient to communicate entirely through vertical eye movements.

Convergence of the eyes is produced by the medial recti, **divergence** by the lateral recti. The exact anatomical locations for centers in the brainstem controlling **vergence** have not been defined, but there appear to be separate pools of neurons in the midbrain reticular formation mediating either convergence or divergence movements. Vergence movements are under the control of descending inputs from the visual pathways in the occipital and parietal cortex and constitute part of the accommodation response discussed previously.

*Interestingly, the vestibular nuclei project directly to the abducens nuclei as well as to the PPRF. Therefore, the horizontal gaze palsy with a PPRF lesion (but not an abducens nucleus lesion) may be overcome by vestibular inputs such as the oculocephalic maneuver (see neuroexam.com Video 35) or ice water calorics.

KEY CLINICAL CONCEPT
PARINAUD'S SYNDROME

13.9 Some clinical aspects of the brainstem circuits that control vertical eye movements were discussed in the preceding section and in KCC 13.3. In this section we will discuss an additional syndrome that includes vertical eye movement abnormalities. **Parinaud's syndrome** is a constellation of eye abnormalities usually seen with lesions compressing the dorsal midbrain and pretectal area. The four components of Parinaud's syndrome are:

1. Impairment of **vertical gaze, especially upgaze.** This may be due to compression of the dorsal part of the vertical gaze center (see the preceding section).
2. **Large, irregular pupils** that do not react to light but sometimes may react to near–far accommodation. This **light–near dissociation** (KCC 13.5) may occur as a result of disruption of optic tract fibers traveling to the Edinger–Westphal nuclei via dorsal pathways including the posterior commissure (see Figure 13.8), while fibers descending from the visual cortex take a different route and are relatively spared.
3. **Eyelid abnormalities** ranging from bilateral lid retraction or "tucking" to bilateral ptosis.
4. **Impaired convergence,** and sometimes **convergence–retraction nystagmus,** especially on attempted upgaze (the eyes rhythmically converge and retract in the orbits).

The most common causes of Parinaud's syndrome are pineal region tumors (see KCC 5.8) and hydrocephalus (see KCC 5.7). Hydrocephalus can cause dilation of the suprapineal recess of the third ventricle (see Figure 5.11), which pushes downward onto the collicular plate (tectum) of the midbrain. Thus, hydrocephalus, especially in children, can produce the bilateral **setting-sun sign,** in which the eyes are deviated inward because of bilateral sixth-nerve palsies (see KCC 13.4) and downward because of a Parinaud's syndrome. ■

Control of Eye Movements by the Forebrain

Multiple parallel pathways descend from the cerebral cortex to control eye movement circuits in the brainstem; we will mention only a few of the better-known pathways here. Descending cortical pathways travel either directly to the brainstem centers for horizontal, vertical, or convergence eye movements (discussed earlier) or via relays in the midbrain **superior colliculi.**

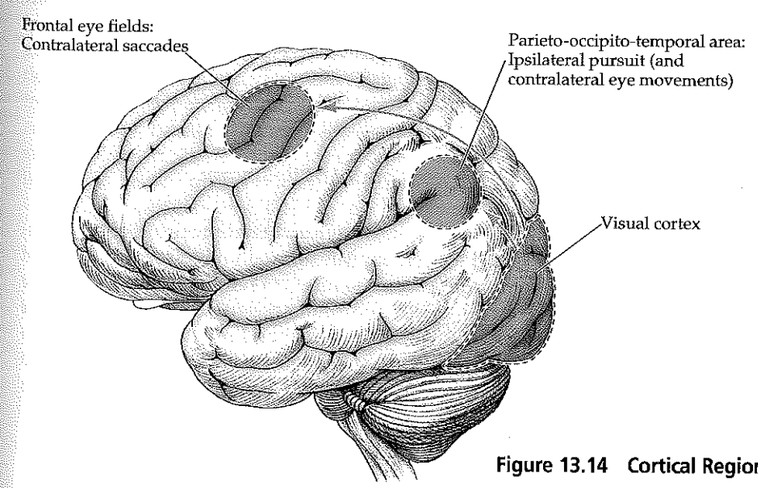

Figure 13.14 Cortical Regions Important in Eye Movement Control

The best-known cortical area that controls eye movements consists of the **frontal eye fields** (Figure 13.14). Based mainly on animal studies, this was formerly believed to correspond to Brodmann's area 8 (see Figure 2.15). However, recent functional imaging studies have suggested that the frontal eye fields in humans may lie more posteriorly, at the junction between the superior frontal sulcus and the precentral sulcus, in Brodmann's area 6. Some authors consider the frontal eye fields to overlap the premotor and prefrontal cortices (see Figure 19.11A), reflecting their roles in eye movements and selective attention, respectively. The frontal eye fields generate **saccades** in the **contralateral** direction via connections to the contralateral PPRF (Figure 13.12). More posterior cortical regions of the **parieto-occipito-temporal cortex** (see Figure 13.14) are primarily responsible for **smooth pursuit** movements in the **ipsilateral** direction, via connections with the vestibular nuclei, cerebellum, and PPRF, as we will discuss in the section on reflex eye movements. The parieto-occipital-temporal cortex may make some contribution to contralateral eye movements as well. Cortical descending control of eye movements is heavily influenced by **visual inputs** arriving at the primary visual cortex and visual association cortex (see Figure 13.14).

The **basal ganglia** also play a role in modulatory control of eye movements, and characteristic disorders of eye movements can be seen in basal ganglia dysfunction (see Chapter 16).

KEY CLINICAL CONCEPT

RIGHT-WAY EYES AND WRONG-WAY EYES

13.10 Lesions of the **cerebral hemispheres** normally impair eye movements in the contralateral direction, often resulting in a **gaze preference toward the side of the lesion.** This gaze preference is typically accompanied by weakness contralateral to the cortical lesion (if the corticospinal pathways are involved), so that the **eyes look away from the side of the weakness** (Figure 13.15A).

Certain clinical situations can cause the eyes to look **toward the side of the weakness.** This condition is called **wrong-way eyes** (Figure 13.15B). Causes of wrong-way eyes include **seizure activity in the cortex,** which can drive the eyes in the contralateral direction because of activation of the frontal eye fields (see Figure 13.14), while also causing abnormal or decreased movements of the contralateral side of the body because of involvement of motor association cortex and other structures. In addition, for unclear reasons, large lesions such as **thalamic hemorrhage** can disrupt the corticospinal pathways of the internal capsule, causing contralateral weakness, yet may also cause the eyes to deviate toward the side of the weakness. Lesions in the thalamic region causing wrong-way eyes are usually accompanied by deep coma. Finally, lesions of the **pontine basis and tegmentum** (see Figure 13.13; Lesions 2, 3; see also Figure 14.20C; Table 14.8) can cause wrong-way eyes because disruption of the corticospinal fibers causes contralateral hemiplegia, while involvement of the abducens nucleus or PPRF causes ipsilateral gaze weakness. ■

OKN

Cerebellar, Vestibular, and Spinal Control of Voluntary and Reflex Eye Movements

The cerebellum, vestibular nuclei, and cervical spinal proprioceptors influence ongoing voluntary eye movements and contribute to several forms of reflex eye movements. Two well-described forms of reflex eye movements are optokinetic nystagmus and the vestibulo-ocular reflex (VOR). The examiner can elicit **optokinetic nystagmus (OKN)** in the horizontal direction by moving a thick ribbon with vertical stripes (called an OKN strip) horizontally in front of the eyes (see neuroexam.com Video 34). The eyes alternate between

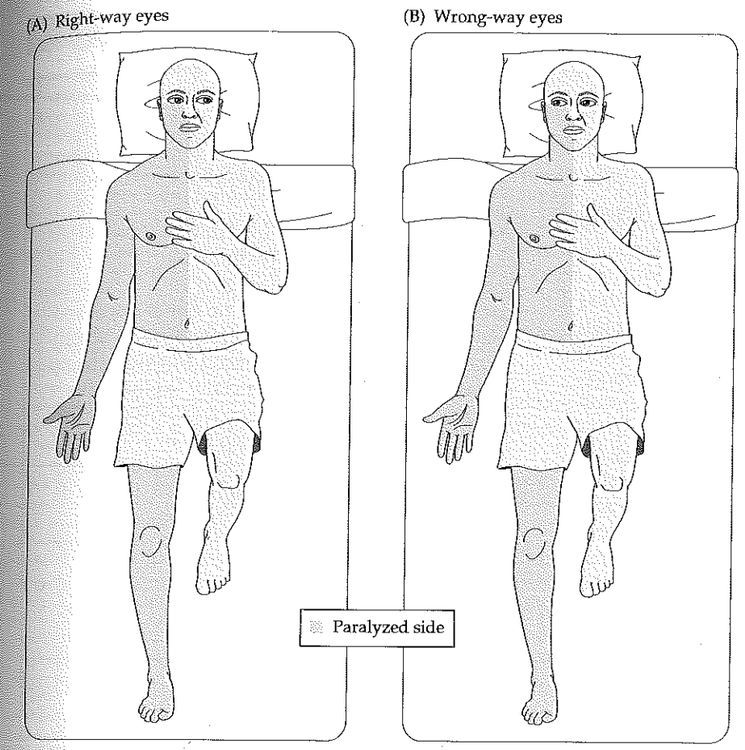

Figure 13.15 Right-Way and Wrong-Way Eyes (A) Right-way eyes caused, for example, by a left cortical lesion affecting corticospinal pathways and frontal eye fields. (B) Wrong-way eyes caused, for example, by a left pontine lesion affecting corticospinal pathways and the PPRF.

smooth pursuit movements in the direction of stripe movement and backup (corrective) saccades opposite the direction of stripe movement in an attempt to stabilize the image. OKN is sometimes called train nystagmus because it can be observed in the eyes of fellow passengers as they watch the passing visual scene through an open window.

The **slow phase,** or smooth pursuit phase, of OKN is mediated by the ipsilateral posterior cortex (see Figure 13.14), with connections to the vestibular nuclei and flocculonodular lobe of the cerebellum projecting to the PPRF and abducens nuclei (see Figure 13.12). The **fast phase,** or saccadic phase, of OKN is mediated by the frontal eye fields projecting ultimately to the contralateral PPRF (see Figure 13.12). Therefore, lesions of the frontal cortex or anywhere in the saccadic pathways disrupt the fast phases of OKN, while the slow phases are disrupted by lesions in the smooth pursuit pathways. OKN testing is thus useful to check for subtle dysfunction in the eye movement pathways. OKN can also be elicited in the vertical direction.

The **vestibulo-ocular reflex (VOR)** stabilizes the eyes on the visual image during head and body movements. Inputs from the vestibular nuclei, especially the medial vestibular nuclei, travel in the MLF to control the extraocular nuclei (see Figure 12.18). The VOR can be tested with the **oculocephalic maneuver** (see neuroexam.com Video 35) or with **cold water calorics** (see the section on the coma exam in Chapter 3). **Proprioceptive inputs** also help stabilize the eyes on the visual image, especially during head and neck movements.



Oculocephalic testing

CLINICAL CASES

CASE 13.1 DOUBLE VISION AND UNILATERAL EYE PAIN

CHIEF COMPLAINT

A 48-year-old woman came to the emergency room with worsening **left eye pain and intermittent double vision.**

HISTORY

Approximately 4 or 5 years previously, the patient had begun to have **left frontal and left retro-orbital headaches** that occurred intermittently at first, and then on an almost daily basis. An MRI scan was reportedly normal, and she was diagnosed with cluster migraine. The headaches continued to occur but were relieved by ibuprofen. One and a half years prior to presentation she began to have intermittent **drooping of the left eyelid and dilation of the left pupil.** She also noticed that her **left eye occasionally drifted to the left,** causing diplopia. This patient was very observant, and she noticed that her **diplopia was worse when looking to the right.** When covering each eye alternately, she reported that the two images did not overlap. In fact, the **image from her left eye appeared to the right and slightly above the image from her right eye.** These symptoms gradually progressed from intermittent to continuous, and her headaches were no longer relieved by up to 12 ibuprofen tablets per day, so she came to the emergency room.

PHYSICAL EXAMINATION

Vital signs: T = 98.7°F, P = 78, BP = 180/90.
Neck: Supple with no bruits.
Lungs: Clear.
Heart: Regular rate with no murmurs.
Abdomen: Soft, nontender.
Neurologic exam:

MENTAL STATUS: Alert and oriented × 3. Speech fluent, with intact naming and repetition. 3/3 words recalled after 5 minutes.

CRANIAL NERVES: Visual fields full. Fundi normal. Right pupil 4 mm, constricting to 3 mm with direct and consensual light stimulation, and with accommodation. **Left pupil 6 mm, with no direct or consensual response to light and no response to accommodation. Left eye had limited but not absent upgaze, downgaze, and adduction.** Normal left eye abduction. Normal right eye movements. **Left ptosis,** with left palpebral fissure 6 mm and right 9 mm. Corneal reflexes intact. Facial sensation intact. Face symmetrical, other than left ptosis already described. Normal palate and tongue movements.

MOTOR: No drift. Normal tone. 5/5 power throughout.

REFLEXES:

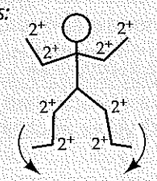

COORDINATION: Normal on finger-to-nose and heel-to-shin testing.

GAIT: Not tested.

SENSORY: Intact light touch, pinprick, vibration, and joint position sense. Normal graphesthesia; no extinction.

LOCALIZATION AND DIFFERENTIAL DIAGNOSIS

1. On the basis of the symptoms and signs shown in **bold** above, where is the lesion?
2. What is the most likely diagnosis, and what are some other possibilities?

Discussion

1. The key symptoms and signs in this case are:
   - **Left frontal and retro-orbital headaches**
   - **History of left eye drifting to the left, and diplopia with image from left eye above and to right of image from right eye, with diplopia worse when looking to the right**
   - **Left eye with limited but not absent upgaze, downgaze, and adduction, left ptosis, and a fixed dilated left pupil**

   This patient has a history of diplopia and findings on exam that are compatible with an oculomotor nerve (CN III) palsy (see KCC 13.2; Figure 13.5). Her left pupil was dilated and unresponsive. Although left eye adduction, upgaze, and downgaze were decreased, they were not absent, suggesting a partial third-nerve palsy. In addition, there was no description of an abnormal eye position at rest. Headaches can have numerous causes (see KCC 5.1); when they are always on the same side, however, an intracranial abnormality on that side should be suspected.

   The most likely *clinical localization* is left oculomotor nerve (CN III).
2. Painful third-nerve palsy should be treated as an aneurysm until proven otherwise. The most common aneurysm causing CN III palsy occurs where the posterior communicating artery (PComm) branches off from the internal carotid (see Figures 5.20, 13.2; KCC 5.6), although aneurysms of the internal carotid, posterior cerebral, and superior cerebellar arteries should also be considered. For other causes of CN III palsy, see KCC 13.2.

Clinical Course and Neuroimaging 556

A head CT (not shown) revealed an egg-shaped, 1 cm mass near the left edge of the posterior clinoid process (see Figure 12.3A) that enhanced with intravenous contrast. A **cerebral angiogram** was performed (Figure 13.16), showing a 1.2 cm aneurysm arising in the region where the PComm branches off the internal carotid (compare to Figure 4.16C). The PComm itself could not be seen on the angiogram. The aneurysm had a well-visualized neck, and its dome pointed posteriorly, along the course of the third nerve. The patient was taken to the operating room and underwent a left frontotemporal craniotomy. The left frontal and temporal lobes were carefully retracted and the left internal carotid artery visualized. Using an operating microscope, the neurosurgeons identified the neck of the aneurysm. The dome of the aneurysm was seen to project posteriorly and inferiorly under the edge of the tentorium cerebelli. A small PComm artery was found to arise from the internal carotid adjacent to the neck of the aneurysm. The neurosurgeons carefully placed a clip across the neck of the aneurysm, being cautious to avoid occluding any other small vessels such as the PComm. The dome of the aneurysm immediately became less tense and could be safely opened with microscissors, and some blood was evacuated, leading to decompression of adjacent structures. Postoperatively the patient did quite well; 1 week after surgery her left pupil was still nonreactive, but she had nearly full movement of the left eye, no diplopia, and no headaches.

CASE 13.2 A DIABETIC WITH HORIZONTAL DIPLOPIA

MINICASE

A 54-year-old man with a history of diabetes awoke one morning with **horizontal diplopia that increased on gaze to the left and decreased on gaze to the right.** He initially had some pain in the left periorbital area, which resolved after a few days. Exam was normal except for **incomplete abduction of the left eye.** He was able to move the left eye slightly past the midline toward the left; however, he was unable to fully "bury the sclera," as he could with the right eye when looking to the right. He had **horizontal diplopia with no vertical component, which was worse on left gaze.**

LOCALIZATION AND DIFFERENTIAL DIAGNOSIS

1. On the basis of the symptoms and signs shown in **bold** above, where is the lesion?
2. What is the most likely diagnosis, and what are some other possibilities?

Discussion

1. The key symptoms and signs in this case are:
   - **Horizontal diplopia, worse on left gaze, with incomplete abduction of the left eye**

     This patient has dysfunction of the left lateral rectus muscle causing disconjugate horizontal gaze, and diplopia (see Figures 13.1, 13.7, and 13.13). Possible causes of incomplete left eye abduction include dysfunction of the left abducens nerve (CN VI) or the lateral rectus muscle, or a mechanical problem in the orbit.
2. Given the patient's history of diabetes and the lack of any other associated findings, the most likely diagnosis is an isolated abducens nerve palsy, caused by microvascular disease. Other possible causes of abducens nerve palsy and horizontal diplopia are discussed in KCC 13.1 and 13.4.

Clinical Course

A head CT was normal. When seen in follow-up 2 weeks later, the patient showed no change, but after 2 months his diplopia was less severe and he was able to bury the sclera almost completely on leftward gaze. Three months after presentation his exam was normal, and he had no symptoms except for occasional transient diplopia when looking in the distance to the left. Review Case 5.7 for another important cause of abducens palsy.

CASE 13.1 DOUBLE VISION AND UNILATERAL EYE PAIN

Figure 13.16 Left Posterior Communicating Artery (PComm) Aneurysm Angiogram from left internal carotid artery injection. Lateral view

CASE 13.3 VERTICAL DIPLOPIA

MINICASE

A 74-year-old man awoke one morning with **vertical diplopia.** The diplopia was relieved by covering of either eye and did not vary in severity at different times of the day. He had no history of head trauma. Past medical history was notable only for hypertension. Exam was normal except for a **right hypertropia and incomplete downgaze with the right eye when looking medially.** He was tested with a red glass over the right eye (Figure 13.17) and had **vertical diplopia, with the image from the right eye located below the image from the left eye.** The diplopia **worsened with downward and leftward gaze and improved with leftward head tilt.**

LOCALIZATION AND DIFFERENTIAL DIAGNOSIS

1. On the basis of the symptoms and signs shown in **bold** above, where is the lesion?
2. What is the most likely diagnosis, and what are some other possibilities?

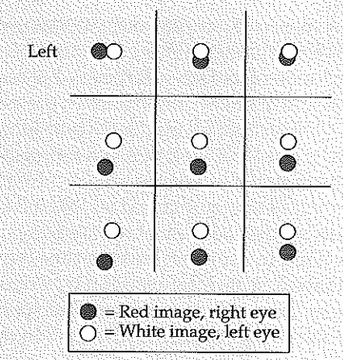

Figure 13.17 Results of Red Glass Testing Red glass was held over the patient's right eye.

Discussion

1. The key symptoms and signs in this case are:
   - **Right hypertropia, and vertical diplopia worse with downward and leftward gaze and worse with rightward head tilt**

     The findings in this patient are compatible with a right trochlear palsy (see KCC 13.3; Figure 13.6). A disorder of the superior oblique muscle itself is also possible.
2. The most likely cause of the isolated trochlear palsy in this patient is, as in Case 13.2, an idiopathic neuropathy of presumed microvascular origin. For other possible causes of trochlear nerve palsy and vertical diplopia, see KCC 13.1 and 13.3.

Clinical Course

A head CT was normal, Tensilon test (see KCC 8.1) was negative, and hemoglobin A_{1c} (an indicator of average blood glucose) was borderline, elevated at 7.7%, suggesting possible diabetes. The patient initially wore an eye patch over his right eye because this eliminated his diplopia and made it easier for him to function normally. He gradually improved, and 3 months later he no longer needed the eye patch and had diplopia only while reading, which involves looking down.

CASE 13.4 LEFT EYE PAIN AND HORIZONTAL DIPLOPIA

MINICASE

A 27-year-old man with no previous medical problems came to the emergency room because of 1 week of worsening left-sided headaches, left eye pain, and horizontal diplopia. He awoke 1 week prior to presentation with a severe left frontal headache. Two days later the headache had moved to his left eye, and he began noticing horizontal diplopia on rightward gaze. He went to his primary medical doctor and had an MRI scan, which was reportedly normal. Because of continued symptoms, he finally decided to come to the emergency room for further evaluation, where he was seen by a neurology consult resident. Examination was normal except for **mild erythema of the left orbital conjunctiva** and **slightly decreased adduction of the left eye on right lateral gaze.** He had **horizontal diplopia and left eye pain on rightward gaze, and the rightmost image vanished when the left eye was covered.** There was also **minimal horizontal diplopia on leftward gaze, with the leftmost image vanishing when the left eye was covered.**

LOCALIZATION AND DIFFERENTIAL DIAGNOSIS

1. On the basis of the patient's symptoms and his findings on neurologic exam, what is the most likely location for a lesion in this patient causing horizontal diplopia (see KCC 13.1 and 13.4)?
2. Given the pain and erythema of the left orbital conjunctiva, what are some possibilities for the diagnosis?

Discussion

1. The key symptoms and signs in this case are:
   - **On right gaze: left eye pain, limited adduction, and horizontal diplopia, with the right image vanishing when the left eye was covered**
   - **On left gaze: mild horizontal diplopia, with the left image vanishing when the left eye was covered**
   - **Pain and erythema of the left orbital conjunctiva**

   The examination reveals bilateral limitations of horizontal eye movement of the left eye, with more difficulty looking to the right. Relatively isolated dysfunction of both the left medial and lateral rectus muscles would be difficult to explain on the basis of nerve or CNS lesions (see Figure 13.1; Table 13.1; KCC 13.1, 13.4). In addition, the eye pain that worsens with movement suggests a possible mechanical cause in the orbit. One possibility would be a lesion that restricts movement of the left lateral rectus muscle, limiting its ability to stretch on right lateral gaze and decreasing its ability to contract on left lateral gaze.
2. The differential diagnosis includes orbital trauma (although there was none based on history); thyroid disease (although pain and subacute onset don't fit with this diagnosis); myasthenia gravis (again, this condition should not cause pain); or more likely, especially given the pain and erythema, an infectious, inflammatory, or neoplastic disorder such as orbital cellulitis, orbital lymphoma, orbital myositis (orbital pseudotumor), sarcoidosis, Tolosa–Hunt syndrome, fungal infection, or cavernous sinus thrombosis.

Clinical Course and Neuroimaging 563

In the emergency room the patient underwent a head CT scan. In addition, he had a lumbar puncture (see KCC 5.10), and cerebrospinal fluid studies were normal. On careful review of the CT scan, the left lateral rectus muscle appeared slightly thickened. The patient was therefore admitted, and a **brain MRI** with gadolinium was done (Figure 13.18). The MRI revealed marked enhancement and thickening of the left lateral rectus muscle, compatible with the diagnosis of orbital myositis (orbital pseudotumor), a relatively uncommon inflammatory condition of the extraocular muscles. The patient was treated with oral steroids and discharged home. His symptoms had improved when he was seen 1 week later in the outpatient office, but he was subsequently lost to follow-up because his insurance would not cover visits to a neurologist outside of his program.

CASE 13.5 UNILATERAL HEADACHE, OPHTHALMOPLEGIA, AND FOREHEAD NUMBNESS

CHIEF COMPLAINT

A 24-year-old woman with a history of pituitary adenoma suddenly developed severe headache, left forehead and cheek numbness, and inability to move the left eye.

HISTORY

The patient presented 2 years previously with Cushing's syndrome (see KCC 17.1) and underwent two operations to resect a pituitary adenoma. She did well until 2 weeks before admission, when she started having **left frontal headaches,** especially around the left eye and nose. An MRI scan showed recurrent pituitary adenoma, and radiation therapy was planned. Two days prior to admission, however, she had onset of **horizontal diplopia** and was found by her endocrinologist to have a **left CN VI palsy.** She was admitted to an outside hospital and treated with steroids to try to reduce swelling. However, the next day she had a sudden worsening of her headache, with **pain and numbness involving the left cheek and forehead; a dilated, fixed left pupil; and almost no movement of the left eye.** She was therefore urgently transferred to a tertiary care center for further evaluation and treatment.

PHYSICAL EXAMINATION

General appearance: Crying, anxious young woman in apparent pain.
Vital signs: T = 97°F, P = 92, BP = 172/112.
Neck: Supple with no bruits.
Lungs: Clear.
Heart: Regular rate with no murmurs.
Abdomen: Benign.
Neurologic exam:
MENTAL STATUS: Alert and oriented × 3.
CRANIAL NERVES: Right pupil 3 mm, constricting to 2 mm. **Left pupil 6 mm, with no direct or consensual response to light.** Visual fields full. Fundi normal. Normal movements of the right eye, but the **left eye had no extraocular movements and a marked left ptosis.** She had diplopia in all directions of gaze. **Sensation was slightly decreased to pinprick in the left forehead, eyelid, left bridge of the nose, and upper cheek** (Figure 13.19). Face was symmetrical, aside from the left ptosis noted above. Shoulder shrug was normal, and tongue was midline.
MOTOR: No pronator drift. 5/5 power throughout.
REFLEXES: Not tested.
COORDINATION: Normal on finger-to-nose testing.
GAIT: Not tested.
SENSORY: Intact light touch and pinprick sensation.



Figure 13.19 Region of Decreased Sensation

LOCALIZATION AND DIFFERENTIAL DIAGNOSIS

1. On the basis of the symptoms and signs shown in **bold** above, where is the lesion?
2. Given the patient's history of a pituitary adenoma and the sudden onset of her deficits, what is the most likely diagnosis? What are some other possibilities?

Discussion

1. The key symptoms and signs in this case are:
   - **Initial left abducens palsy, evolving to ophthalmoplegia, ptosis, and a fixed dilated pupil**
   - **Pain, paresthesia, and decreased sensation to pinprick in the left forehead, eyelid, bridge of nose, and upper cheek**

   This patient had dysfunction of the left CN III, IV, VI, and V_1, constituting a left cavernous sinus syndrome (see KCC 13.7; Figure 13.11). Lack of involvement of the optic nerve suggests that the disorder was not in the orbital apex. Interestingly, the initial abnormal finding was an abducens palsy, suggesting a lesion that expanded from medial to lateral within the left cavernous sinus (see Figure 13.11).

   The most likely *clinical localization* is the left cavernous sinus.

2. This patient has a history of recurrent pituitary adenoma. The progress of her symptoms, however, is too rapid to be explained easily by extension of the tumor into the cavernous sinus. The sudden worsening of her symptoms could be explained by hemorrhage into the tumor, or pituitary apoplexy (see KCC 17.3). Interestingly, pituitary apoplexy often recurs in patients without a previously known history of adenoma. Other possibilities include cavernous carotid aneurysm or fistula, cavernous sinus thrombosis, or infection (see KCC 13.7).

Clinical Course and Neuroimaging 565

The tertiary care center to which the patient was transferred had an MRI scanner readily available. Therefore, an **MRI** was performed on an urgent basis because of the better resolution of MRI than CT for structures in the pituitary and cavernous sinus region (Figure 13.20). Figure 13.20A is a coronal T1-weighted image showing a large hemorrhage extending from the pituitary fossa into the left cavernous sinus. Note that the optic tract was not affected, and more anteriorly (not shown), the optic nerves were also spared. Figure 13.20B is an axial T2-weighted image, again showing the hemorrhage. The trigeminal nerve is nicely demonstrated in Figure 13.20B and can be seen to enter Meckel's cave on both sides (compare to Figure 12.3A). Cerebrospinal fluid surrounding the trigeminal ganglion in Meckel's cave appears white on T2-weighted images.

Because of these findings, the patient was taken to the operating room for a transsphenoidal resection (see KCC 17.1) of the hemorrhage and pituitary adenoma. Hemorrhagic tissue was removed from the left cavernous sinus, and hemostatic packing was inserted. By postoperative day 1, the patient had recovered some limited left extraocular movements and slight left pupillary responses. She was transferred back to the hospital closer to her home for the remainder of her recovery.

CASE 13.6 PTOSIS, MIOSIS, AND ANHIDROSIS

MINICASE

A 17-year-old male got into an argument with his sister while intoxicated, and she shot him in the neck with a steel pellet gun. He was brought to the emergency room and treated for a left pneumothorax (collapsed lung). The emergency room physician noticed unequal pupils and called a neurology consult. On exam, the patient had an entry wound at the base of his neck just above the left clavicle (Figure 13.21). There was no neck swelling. The right pupil was 4 mm, constricting to 3 mm in response to light, and the **left pupil was 2 mm, constricting to 1.5 mm. The left eyelid had 3 mm of ptosis compared to the right. The left forehead felt smoother than the right,** suggesting decreased sweat production. When the right neck was pinched, the right pupil dilated **(ciliospinal reflex). Pinching the left neck caused no change in the left pupil.** The remainder of the exam was normal.

LOCALIZATION AND DIFFERENTIAL DIAGNOSIS

1. On the basis of the symptoms and signs shown in bold above, where is the lesion?
2. What is the most likely diagnosis, and what are some other possibilities?

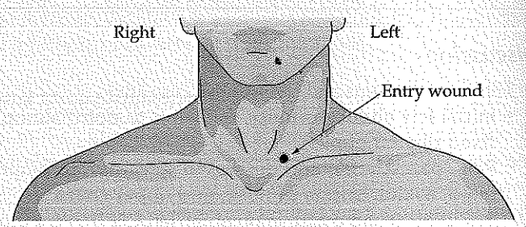

Figure 13.21 Location of Entry Wound

Discussion

1. The key symptoms and signs in this case are:
   - **Left ptosis**
   - **Small, reactive left pupil, with decreased ciliospinal reflex**
   - **Decreased left facial sweating**

   This patient has Horner's syndrome (see KCC 13.5, 13.6). Horner's syndrome can be caused by a lesion anywhere in the sympathetic pathway to the eye (see Figure 13.10). However, given the history of a penetrating neck wound, the lesion is probably located in the sympathetic chain or sympathetics of the carotid plexus. The entry wound was low in the neck (see Figure 13.21), making direct injury to the sympathetics in the carotid plexus unlikely (see Figure 13.10). In addition, impaired sweating is more common with preganglionic lesions. Nevertheless, the carotid artery may have been injured low in the neck, causing a carotid dissection (see KCC 10.6) extending superiorly, resulting in a Horner's syndrome. A lesion of the upper thoracic nerve roots or spinal cord is unlikely, given the absence of any other neurologic findings, although the pneumothorax suggests the pellet traversed the region of the lung apex.
2. Possible causes of Horner's syndrome in this pattern include direct traumatic injury to the sympathetic chain in the neck (see Figure 13.10) or carotid dissection (see KCC 10.6).

   In summary, the most likely *clinical localization* is left sympathetic chain in the vicinity of the lower neck or lung apex, or left carotid plexus.

Clinical Course and Neuroimaging 566

Because of the possibility of a carotid dissection, an angiogram was done (Figure 13.22). No dissection was seen. The steel pellet took a slightly downward course to lodge behind the carotid artery, at the level of the T1 and T2 nerve root exit points. Injury to the lower cervical or upper thoracic sympathetic trunk during the steel pellet's trajectory through the neck was therefore the most likely diagnosis. Because of the pellet's location adjacent to vital structures, it was not removed. Social services and psychiatry were consulted because of the circumstances of his injury. When seen 1 month later in follow-up, the patient was doing well, but his left ptosis and miosis remained essentially unchanged.

Related Case. Figure 13.23 (page 566) shows an MRI of the neck from a different patient with ptosis and miosis. This 43-year-old woman struck her head against the steering wheel in a car accident. She was well until 2 weeks later, when she developed pain over her right eye, with right ptosis and miosis. The T1-weighted MRI image in Figure 13.23 demonstrates a white crescent of clotted blood (see Table 4.4) in the false lumen of a carotid dissection (see KCC 10.6). In this case, the Horner's syndrome was associated with a carotid dissection. She was treated with anticoagulation for several months to prevent emboli.

CASE 13.7 WRONG-WAY EYES

MINICASE

A 71-year-old man with a history of diabetes collapsed on the street and was unable to stand up, so he was brought to the emergency room by ambulance. On examination, he was awake but **lethargic,** had a **rightward gaze preference,** and was **unable to move either eye past the midline toward the left.** In addition, he had **weakness of the right lower face** and **2/5 strength in the right arm and leg,** with an **upgoing plantar response on the right.** Examination was otherwise unremarkable.

LOCALIZATION AND DIFFERENTIAL DIAGNOSIS

1. Lesions in which locations can cause the constellation of symptoms and signs shown in **bold** above?
2. Given the patient's age and the time course of his presentation, what is the most likely diagnosis, and what are some other possibilities?

Discussion

1. The key symptoms and signs in this case are:
   - **Lethargy**
   - **Rightward gaze preference, with inability to move either eye past the midline toward the left**
   - **Right face, arm, and leg weakness, with upgoing plantar response on the right**

   This patient has a combination of a left horizontal gaze palsy and right hemiparesis constituting so-called wrong-way eyes (see KCC 13.10; Figure 13.15). Wrong-way eyes can be caused by ongoing seizure activity in one of the cerebral hemispheres, by lesions in the region of the thalami, or by lesions in the pons affecting the corticospinal tract (contralateral hemiparesis) and abducens nucleus (ipsilateral gaze preference). The patient's lethargy suggests possible mild involvement of brainstem activating systems (see Chapter 14). Lesions in the vicinity of the thalami causing wrong-way eyes usually do so in the setting of profound coma, which this patient did not have.
2. Given the patient's age and history of diabetes, the most likely diagnosis is an infarct in the left pons involving the left corticospinal and corticobulbar fibers as well as the left abducens nucleus (or PPRF). A hemorrhage in this location is also a possibility. Another possibility is that the patient could be having ongoing seizure activity (focal status epilepticus) in the left hemisphere, causing the rightward gaze preference and right-sided weakness, but this is less likely given the history.

Clinical Course and Neuroimaging 567

The patient's CT scan showed an area of increased density at the top of the basilar artery, so he was taken for an emergency angiogram with a plan for intra-arterial thrombolysis (see KCC 10.4). However, the angiogram revealed a patent basilar artery, and it was concluded that the increased density seen in the basilar artery on CT scan was calcification rather than thrombosis (see Table 4.1). He was therefore treated with intravenous heparin while an embolic evaluation was pursued (see KCC 10.4). An MRI scan (Figure 13.24) revealed an area of increased T2 signal in the left pons consistent with an infarct from a penetrating vessel arising from the basilar artery (see KCC 14.3; Figure 14.20C; Table 14.8). The patient was found to have paroxysmal atrial fibrillation and was treated with chronic oral anticoagulation and transferred to an inpatient rehabilitation facility. When seen in the office 4 months later, however, he still had severe 3/5 right hemiparesis and a left horizontal gaze palsy.

CASE 13.4: LEFT EYE PAIN AND HORIZONTAL DIPLOPIA

Figure 13.18 Orbital Pseudotumor Involving Left Lateral Rectus Muscle T1-weighted axial MRI image with intravenous gadolinium demonstrating abnormal enhancement and thickening of the left lateral rectus muscle compatible with orbital pseudotumor.

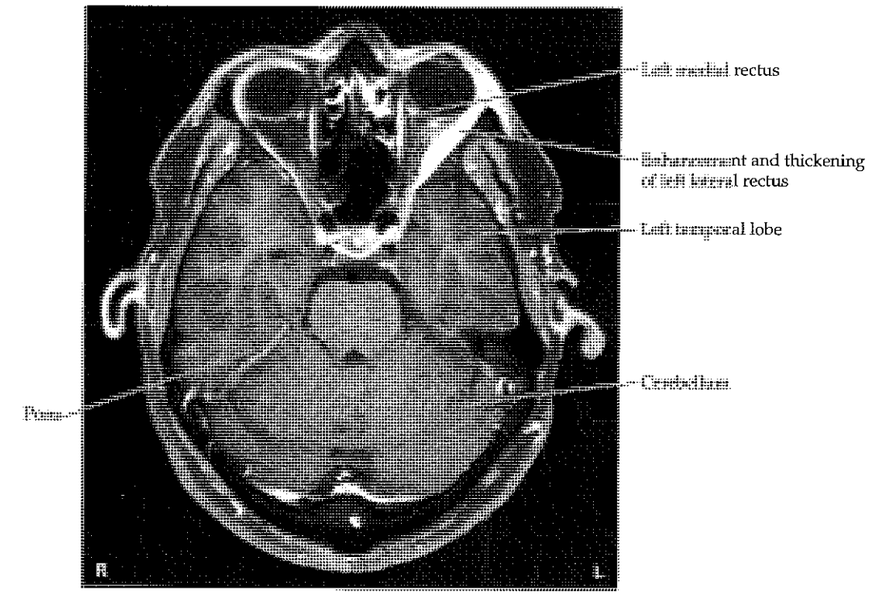

CASE 13.8 HORIZONTAL DIPLOPIA IN A PATIENT WITH MULTIPLE SCLEROSIS

MINICASE

A 25-year-old woman had a 2-year history of multiple sclerosis with relapsing and remitting episodes of weakness and sensory deficits in her extremities. Two weeks prior to evaluation, she had onset of horizontal diplopia. Compared to previous exams, the new findings consisted of an **abnormality of rightward horizontal gaze** such that the **left eye did not adduct past the midline,** and the **right eye had sustained end gaze nystagmus on abduction.** In contrast, when convergence was tested, the left eye was able to adduct past the midline. Leftward horizontal gaze was normal.

LOCALIZATION AND DIFFERENTIAL DIAGNOSIS

1. Draw the positions of this patient's eyes on leftward horizontal gaze, on rightward horizontal gaze, and during convergence.
2. What is the location of this patient's lesion, and which side is it on?
3. What is the most likely cause?

Discussion

1. The key symptoms and signs in this case are:
   - **Left eye did not adduct past the midline**
   - **Right eye had sustained end gaze nystagmus on abduction**

   The positions of this patient's eyes during leftward and rightward gaze are shown in Figure 13.13B, lesion 4. Convergence was normal.
2. These findings constitute a left INO localized to the left MLF (see Figure 13.13A, lesion 4).

3. Given the patient's history, the most likely diagnosis is a multiple sclerosis plaque (see KCC 6.6) in the left MLF.

Initial Clinical Course and Neuroimaging 569

A **brain MRI** showed a new region of increased T2 signal along the floor of the fourth ventricle in the region of the left MLF (Figure 13.25).

CASE 13.8 *(CONTINUED)*

During the next few days the patient gradually developed problems with leftward horizontal gaze as well, so **neither eye would move past the midline when looking to the left.** On rightward gaze, she continued to have **no adduction of the left eye.** Thus, the only remaining horizontal eye movement was **right eye abduction,** which continued to have **end gaze nystagmus,** as before.

LOCALIZATION AND DIFFERENTIAL DIAGNOSIS

1. Draw the positions of this patient's eyes on leftward horizontal gaze and on rightward horizontal gaze following her clinical worsening.
2. What is the location of this patient's lesion now?

Discussion

1. The key symptoms and signs in this case are:
   - **Inability of either eye to move past the midline when looking to the left**
   - **No adduction of the left eye**
   - **End gaze nystagmus on right eye abduction**

   The positions of this patient's eyes during leftward and rightward gaze are shown in Figure 13.13B, lesion 5.
2. These findings constitute a left INO plus a left horizontal gaze palsy, also called one-and-a-half syndrome (see KCC 13.8). Most likely her demyelinative plaque in the left MLF enlarged to involve the left abducens nucleus or PPRF (see Figure 13.13A, lesion 5).

Clinical Course

The patient was treated with steroids, and her eye movements and diplopia gradually improved. On follow-up examination she was able to move her eyes fully in all directions; in tests of saccades to the right, however, her right eye could be seen to move quickly to the right while her left eye moved more slowly to the right, lagging slightly behind. This is a way to test for a mild INO on physical examination (see KCC 13.8) and demonstrated a slight residual deficit in this patient.

CASE 13.5 UNILATERAL HEADACHE, OPHTHALMOPLEGIA, AND FOREHEAD NUMBNESS

Figure 13.20 Pituitary Apoplexy Causing Left Cavernous Sinus Syndrome (A) Coronal T1-weighted image demonstrating hemorrhage extending from the region of the pituitary fossa into the left cavernous sinus. (B) Axial T2-weighted image, again demonstrating hemorrhage in the left cavernous sinus, adjacent to Meckel's cave.

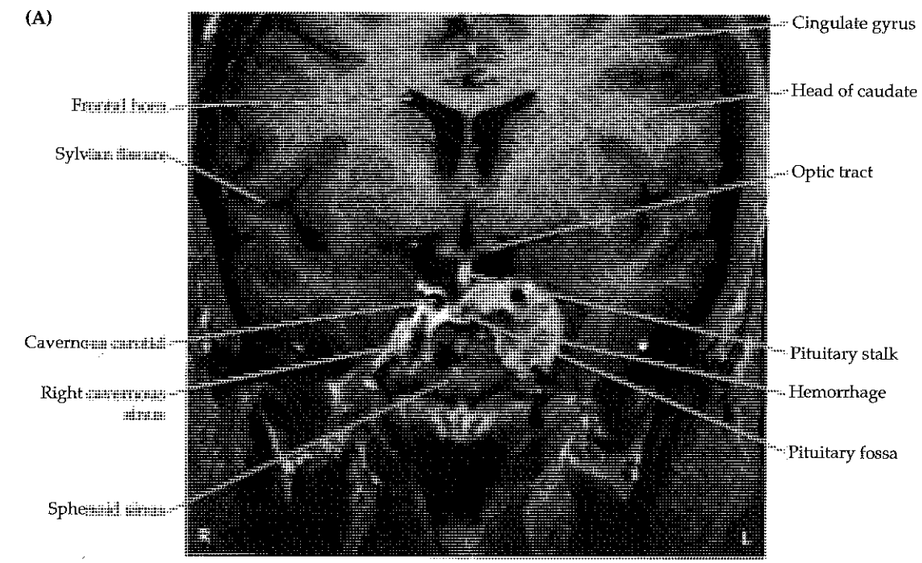

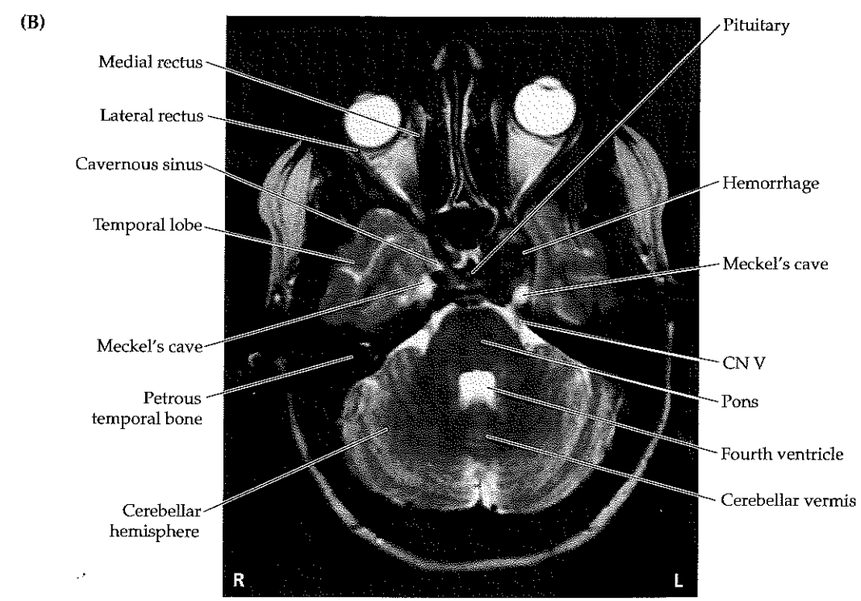

CASE 13.6 PTOSIS, MIOSIS, AND ANHIDROSIS

Figure 13.22 Steel Pellet in Region of the Sympathetic Trunk Angiogram from aortic arch injection. Left anterior oblique view. The trajectory made by the steel pellet from the entry site to its final location traverses the region of the left T1 and T2 nerve roots and the junction between the thoracic and cervical portions of the symathetic trunk (compare to Figure 13.10).

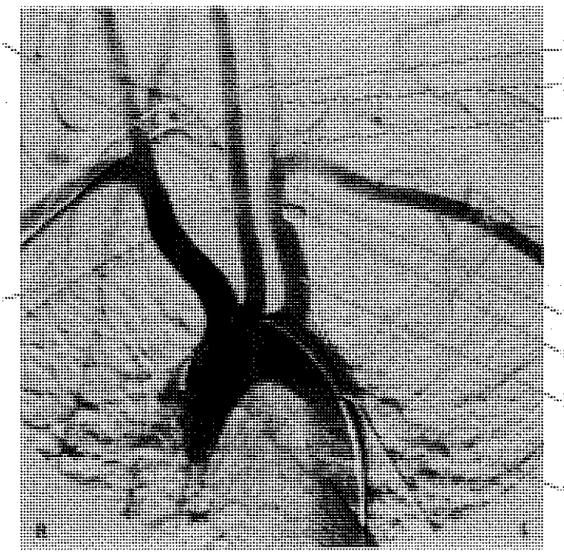

CASE 13.6 RELATED CASE

Figure 13.23 Right Carotid Dissection Axial, T1-weighted MRI image through the neck and skull base reveals a crescent of blood in the right carotid, consistent with a right carotid dissection.

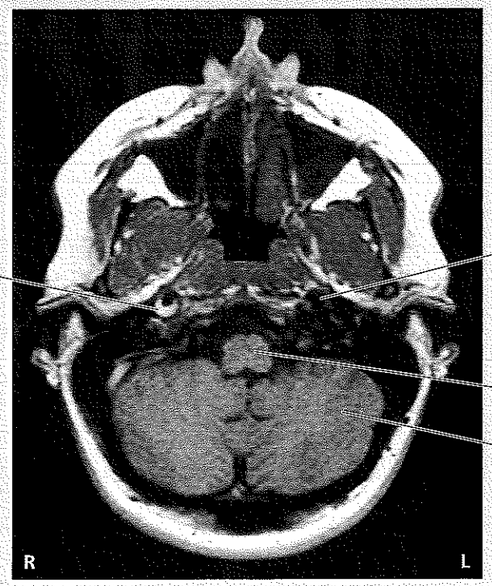

CASE 13.7 WRONG-WAY EYES

Figure 13.24 Infarct in Left Medial Pontine Basis and Tegmentum Axial, T2-weighted MRI image. An infarct is present in the left pons in the region of the left corticospinal tract, PPRF, and possibly the abducens nucleus.

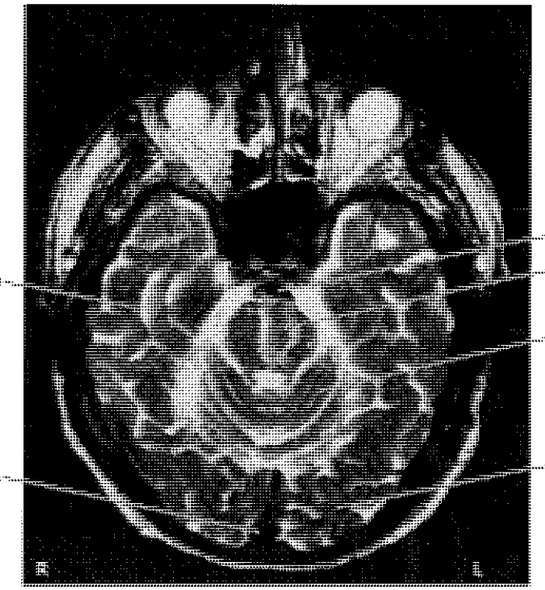

CASE 13.9 HEADACHES AND IMPAIRED UPGAZE

MINICASE

A 23-year-old aerospace engineer developed mild **headaches** and difficulty looking up over the course of 3 weeks, so he went to see his family physician. On examination, his **pupils were about 6 mm in diameter bilaterally and had minimal reaction to light**, but they did constrict during accommodation. He was **unable to look upward at all** past the horizontal plane, but he had otherwise full eye movements in other directions. When attempting to look upward, or after closing and opening his eyes, he had **retraction of the upper eyelids and convergence–retraction nystagmus** of both eyes. Examination was otherwise normal.

LOCALIZATION AND DIFFERENTIAL DIAGNOSIS

1. On the basis of the symptoms and signs shown in **bold** above, what syndrome does this patient have affecting his eye movements, and what is the usual localization of this syndrome?
2. What is the most likely diagnosis, and what are some other possibilities?

Discussion

1. The key symptoms and signs in this case are:
   - **Headaches**
   - **Large pupils with minimal reaction to light but preserved reaction to accommodation (light–near dissociation)**
   - **Inability to look upward**
   - **Lid retraction and convergence–retraction nystagmus**

   The patient has a classic Parinaud's syndrome (see KCC 13.9). Parinaud's syndrome is usually caused by compression of or lesions in the dorsal midbrain

and pretectal area. Impaired upgaze is probably caused by dysfunction of the upgaze portion of the vertical gaze center located in the dorsal part of the rostral midbrain reticular formation. Light–near dissociation probably occurs because fibers from the optic tract reaching the Edinger–Westphal nuclei travel via dorsal pathways including the posterior commissure and have been disrupted, while fibers descending from the visual cortex take a different route and are relatively spared (see KCC 13.5; Figure 13.8). Headaches of the kind seen in this patient can have many causes (see KCC 5.1) but also support the presence of intracranial pathology.

2. Given the presence of a gradually progressive Parinaud's syndrome, the most likely diagnosis in this patient is a pineal region tumor (see KCC 5.8) that has enlarged to compress the dorsal midbrain. In young children before the cranial sutures close, hydrocephalus can present with Parinaud's syndrome as the main abnormality. In an adult, however, if the hydrocephalus were severe enough to cause these findings, then intracranial pressure would likely be severely elevated as well, causing impaired consciousness (see KCC 5.3), which this patient does not have. Therefore, the most likely diagnosis is a primary neoplasm of the pineal region. Another, less likely possibility is that the patient has another lesion in this region, including metastatic tumor, infection, or vascular malformation.

Clinical Course and Neuroimaging 570

A **brain MRI** with intravenous gadolinium showed an enhancing lesion in the pineal region causing severe compression of the dorsal midbrain and pretectal area (Figure 13.26). He was referred to a neurosurgeon and underwent a biopsy of the lesion performed stereotactically (see KCC 16.4). The pathologic diagnosis was uncertain, revealing either an intermediate-grade pineocytoma or a pineal teratoma. He was treated with multiple cycles of chemotherapy and with radiation therapy, with repeated worsening and temporary improvement in his symptoms, but he remained relatively stable at last follow-up, 2 years after initial presentation.

Additional Cases

Related cases can be found in other chapters for the following topics: **abnormalities of eye movements or pupillary responses** (Cases 5.2–5.7, 10.8, 10.10–10.12, 11.2, 14.1, 14.5–14.8, 15.3, 15.4, 16.2, 16.4, 18.3). Other relevant cases can be found using the **Case Index**.

Brief Anatomical Study Guide

1. There are **six extraocular muscles** for each eye, each with a different function (see Figure 13.1; Table 13.1). The **medial and lateral rectus** muscles move the eye medially and laterally, respectively. The **superior and inferior rectus** and **superior and inferior oblique** muscles are involved in vertical and torsional eye movements.

2. Three cranial nerves control eye movements: The **oculomotor nerve (CN III)** supplies all extraocular muscles except the lateral rectus and superior oblique (see Table 13.1; Figure 13.2). In addition, it supplies the **levator palpebrae superior** muscle, which elevates the upper eyelid. The **trochlear nerve (CN IV)** innervates the superior oblique muscle, and the **abducens nerve (CN VI)** innervates the lateral rectus (see Table 13.1; Figure 13.4).

CASE 13.8 HORIZONTAL DIPLOPIA IN A PATIENT WITH MULTIPLE SCLEROSIS

Figure 13.25 Plaque in the Left MLF Axial, proton density–weighted MRI images progressing from inferior (A) to superior (B). A bright plaque is visible in the region of the left MLF along the floor of the fourth ventricle (compare to Figure 14.4).

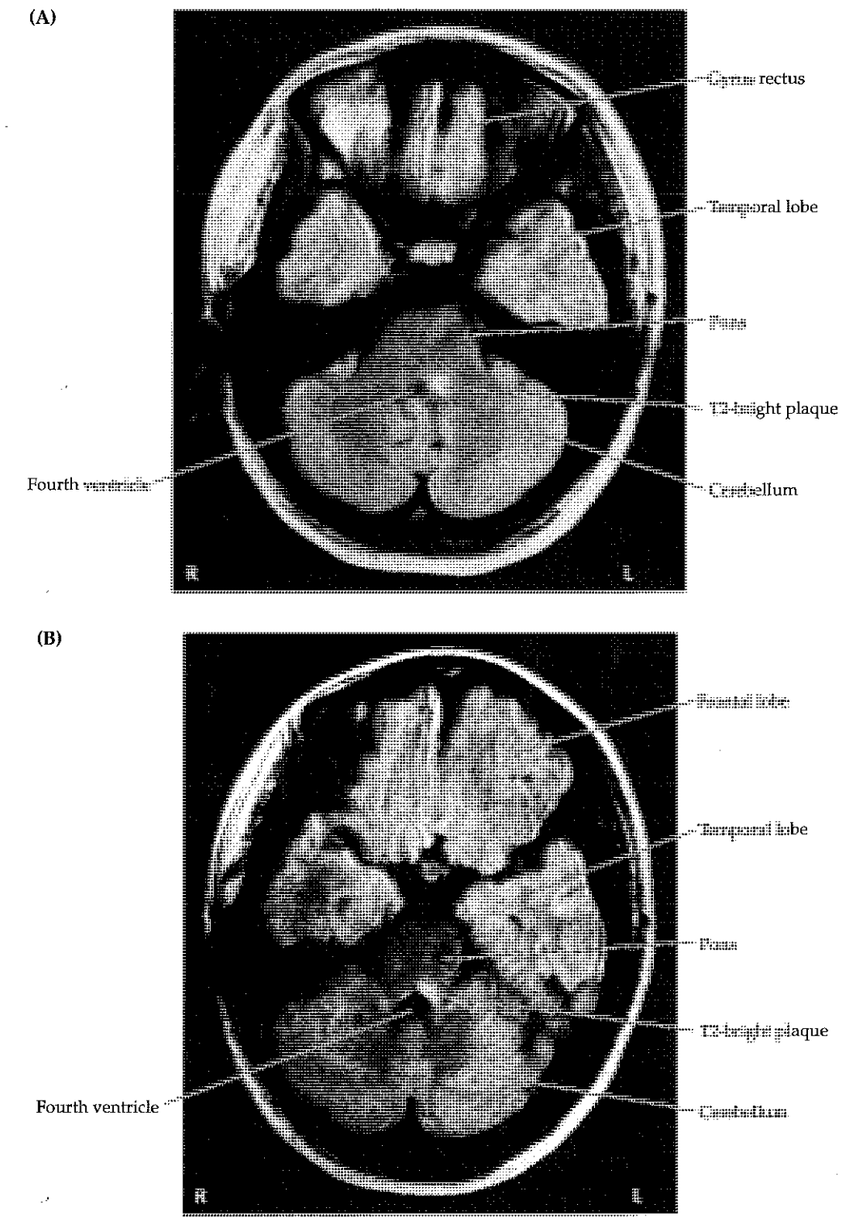

CASE 13.9 HEADACHES AND IMPAIRED UPGAZE

Figure 13.26 Pineal Region Tumor Compressing the Tectum T1-weighted MRI images with intravenous gadolinium. (A) Axial image demonstrating a large enhancing lesion in the pineal region. (B) Sagittal image showing the enhancing lesion compressing the dorsal midbrain and pretectal area.

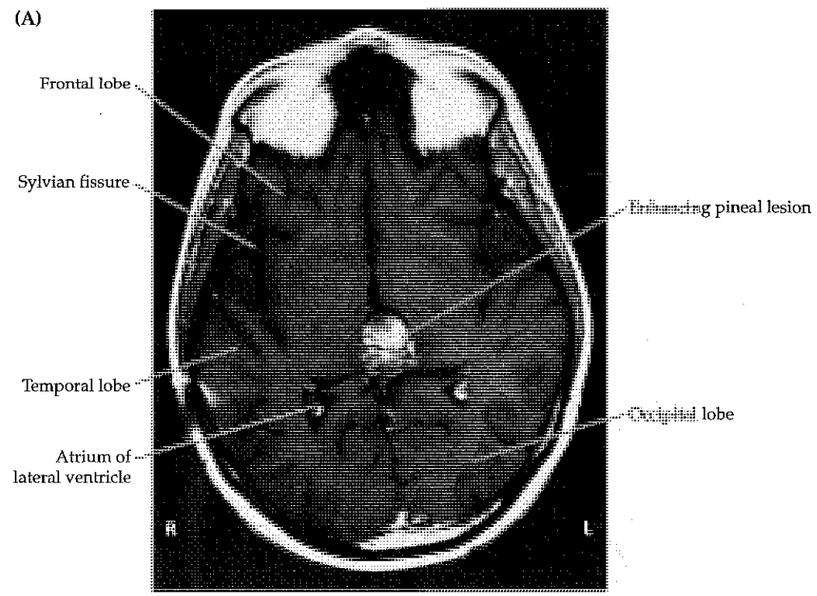

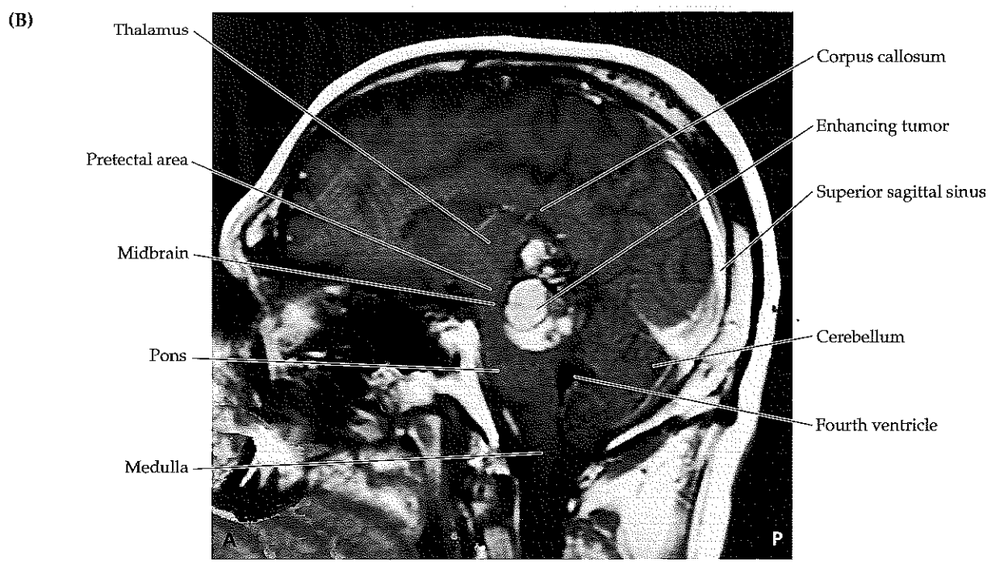

Brief Anatomical Study Guide *(continued)*

3. The **oculomotor nucleus** is located in the rostral midbrain at the level of the superior colliculus and red nucleus (see Figures 13.2, 14.3A). Fascicles of the oculomotor nerve exit the midbrain ventrally in the interpeduncular fossa between the posterior cerebral and superior cerebellar arteries. The nerve then runs adjacent to the posterior communicating artery, where it is susceptible to compression by aneurysms or by downward herniation of the temporal lobe over the tentorial edge.

4. The **trochlear nucleus** is located in the caudal midbrain at the level of the inferior colliculus and decussation of the superior cerebellar peduncles (Figure 13.4). Fascicles of the trochlear nerve decussate and exit the brainstem dorsally. The thin trochlear nerve is particularly susceptible to injury from shearing forces in head trauma.

5. The **abducens nucleus,** together with fibers of the facial nerve, forms the facial colliculus on the floor of the fourth ventricle in the midpons (see Figure 12.11). Fascicles of the abducens nerve travel ventrally to exit the brainstem at the pontomedullary junction (see Figure 12.2A). The abducens nerve then ascends a long distance along the clivus and over the petrous ridge (see Figure 13.4; see also Figure 12.1), making it susceptible to injury from downward traction in elevated intracranial pressure.

6. As the oculomotor, trochlear, and abducens nerves (CN III, IV, and VI) exit the cranial cavity, they travel through the **cavernous sinus** (see Figure 13.11) in close association with the ophthalmic division of the trigeminal nerve (CN V_1) and then enter the orbit via the **superior orbital fissure** (see Figure 12.3A,C). Lesions in the cavernous sinus or orbital apex can affect multiple cranial nerves involved in eye movement control.

7. The pupils are under both parasympathetic and sympathetic control. **Parasympathetic** pathways mediate **pupillary constriction** via the pathways summarized in Figure 13.8. Preganglionic parasympathetic fibers arise from the **Edinger–Westphal** nucleus. Note that the parasympathetic fibers travel with the oculomotor nerve, so damage to this nerve often produces an abnormally dilated pupil. **Sympathetic** pathways mediate **pupillary dilation** via pathways summarized in Figure 13.10. Sympathetic pathways can be interrupted at multiple levels from the brainstem to the nerve fibers ascending in the neck to the eye, resulting in **Horner's syndrome** (see KCC 13.5, 13.6).

8. Central pathways for control of eye movements that impinge on the oculomotor, trochlear, and abducens nuclei are referred to as **supranuclear pathways.** The pathways involve a distributed network including brainstem, cerebellar, basal ganglia, cortical, and other circuits. For horizontal eye movements, the final common pathway and main **horizontal gaze center** in the brainstem is the **abducens nucleus,** which controls horizontal gaze for both the ipsilateral and contralateral eyes through the **medial longitudinal fasciculus (MLF)** (see Figures 13.12, 13.13). The **paramedian pontine reticular formation (PPRF)** is another important horizontal gaze center with inputs to the abducens nucleus.

Brief Anatomical Study Guide *(continued)*

9. **Vertical gaze** is controlled by nuclei in the rostral midbrain and pretectal region, including the **rostral interstitial nucleus of the MLF.** Control of **vergence eye movements** probably arises from nuclei in the midbrain reticular formation. Descending cortical inputs from the **frontal eye fields** (see Figure 13.14) decussate to reach the contralateral PPRF, producing contralateral lateral horizontal gaze. However, descending cortical inputs from more posterior areas of the parieto-occipito-temporal junction tend to cause ipsilateral deviation of gaze.

10. **Nystagmus** refers to rhythmic alternating **slow phases** of eye movements that move in one direction, interrupted by **fast phases** of eye movements in the opposite direction. Nystagmus is abnormal when it occurs at rest (without changing visual or vestibular inputs). Normal nystagmus occurs during attempts to view a visual scene or a series of stripes moving in front of the eyes and is called **optokinetic nystagmus (OKN).** Vestibular inputs are relayed via the MLF to stabilize the eyes on a visual image during head and body movements. This is called the **vestibulo-ocular reflex (VOR).**

References

General References

Liu GT, Volpe NJ, Galetta S. 2000. *Neuro-Ophthalmology: Diagnosis and Management.* Saunders, Philadelphia.

Miller NR, Newman NJ, Hoyt WF (eds.). 1998. *Walsh and Hoyt's Clinical Neuro-Ophthalmology.* Lippincott Williams & Wilkins, Philadelphia.

Wilson-Pauwels L, Akesson EJ, Stewart PA. 1988. *Cranial Nerves: Anatomy and Clinical Comments.* B. C. Decker, Toronto, Ontario.

Wray SH. 1998. Neuro-ophthalmologic diseases. In Rosenberg RN, Pleasure DE (eds.), *Comprehensive Neurology,* 2nd Ed. Chapter 19. Raven, New York.

Oculomotor, Trochlear, and Abducens Nerve Palsies

Brazis PW. 1993. Palsies of the trochlear nerve: Diagnosis and localization—Recent concepts. *Mayo Clin Proc* 68(5): 501–509.

Bronstein AM, Morris J, DuBoulay G, Gresty MA, Rudge P. 1990. Abnormalities of horizontal gaze. Clinical, oculographic and magnetic resonance imaging findings. I. Abducens palsy. *J Neurol Neurosurg Psychiatry* 53(3): 194–199.

Galetta SL, Smith JL. 1989. Chronic isolated sixth nerve palsies. *Arch Neurol* 46(1): 79–82.

Leivo S, Hernesniemi J, Luukkonen M, Vapalanti M. 1996. Early surgery improves the cure of aneurysm-induced oculomotor palsy. *Surg Neurol* 45(5): 430–434.

Mansour AM, Reinecke RD. 1986. Central trochlear palsy. *Survey Ophthalmol* 30(5): 279–297.

Moster ML, Savino PJ, Sergott RC, Bosley TM, Schatz NJ. 1984. Isolated sixth-nerve palsies in younger adults. *Arch Ophthalmol* 102(9): 1328–1330.

Raja IA. 1972. Aneurysm-induced third nerve palsy. *J Neurosurg* 36(5): 548–551.

Richards BW, Jones R, Younge BR. 1992. Causes and prognosis in 4,278 cases of paralysis of the oculomotor, trochlear, and abducens cranial nerves. *Am J Ophthalmol* 113(5): 489–496.

Rucker CW. 1961. The causes of paralysis of the third, fourth and sixth cranial nerves. *Am J Ophthalmol* 61: 1293–1298.

Soni SR. 1974. Aneurysms of the posterior communicating artery and oculomotor paresis. *J Neurol Neurosurg Psychiatry* 37(4): 475–484.

Tiffin PA, MacEwen CJ, Craig EA, Clayton G.1996. Acquired palsy of the oculomotor, trochlear and abducens nerves. *Eye* 10(Pt. 3): 377–384.

Cavernous Sinus and Orbital Apex Syndromes

Barrow DL, Spector RH, Braun IF, Landman JA, Tindall SC, Tindall GT. 1985. Classification and treatment of spontaneous carotid-cavernous sinus fistulas. *J Neurosurg* 62(2): 248–256.

Bosley TM, Schatz NJ. 1983. Clinical diagnosis of cavernous sinus syndromes. *Neurol Clin* 1(4): 929–953.

Cardoso ER, Peterson EW. 1984. Pituitary apoplexy: A review. *Neurosurgery* 14(3): 363–373.

Hartwick RW, Batsakis JG. 1991. Sinus aspergillosis and allergic fungal sinusitis. *Ann Otol Rhinol Laryngol* 100(5 Pt. 1): 427–430.

Hedges TR, Leung LS. 1976. Parasellar and orbital apex syndrome caused by aspergillosis. *Neurology* 26(2): 117–120.

Keane JR. 1996. Cavernous sinus syndrome: Analysis of 151 cases. *Arch Neurol* 53(10): 967–971.

Linskey ME, Sekhar LN, Hirsch W, Yonas H, Horton JA. 1990. Aneurysms of the intracavernous carotid artery: Clinical presentation, radiographic features, and pathogenesis. *Neurosurgery* 26(1): 71–79.

Linskey ME, Sekhar LN, Hirsch WL, Yonas H, Horton JA. 1990. Aneurysms of the intracavernous carotid artery: Natural history and indications for treatment. *Neurosurgery* 26(6): 933–937.

Rolih CA, Ober KP. 1993. Pituitary apoplexy. *Endocrinol Metab Clin North Am* 22(2): 291–302.

Sekhar LN, Dujovnt M, Rao GR. 1980. Carotid-cavernous sinus thrombosis caused by *Aspergillus fumigatus. J Neurosurg* 52(1): 120–125.

Standaert DG, Hurst RW, Galetta SL, Chawluk JB. 1992. Magnetic resonance angiography in the evaluation of dural carotid-cavernous fistulas. *J Neuroimaging* 2: 208–211.

Vinuela F, Fox AJ, Debrum GM, Peerless SJ, Drake CG. 1984. Spontaneous carotid-cavernous fistulas: Clinical, radiological, and therapeutic considerations. *J Neurosurg* 60(5): 976–984.

Horner's Syndrome

Fields CR, Barker FM. 1992. Review of Horner's syndrome and a case report. *Optom Vis Sci* 69(6): 481–485.

Martin JH. 1996. *Neuroanatomy: Text and Atlas,* 2nd Ed. Appleton and Lange, Stamford, CT.

Mokri B, Silbert PL, Schievink WI, Piepgras DG. 1996. Cranial nerve palsy in spontaneous dissection of the extracranial internal carotid artery. *Neurology* 46(2): 356–359.

Horizontal Gaze Disorders

Tijssen CC. 1994. Contralateral conjugate eye deviation in acute supratentorial lesions. *Stroke* 25(7): 1516–1519.

Wall M, Wray SH. 1983. The one-and-a-half syndrome—A unilateral disorder of the pontine tegmentum: A study of 20 cases and review of the literature. *Neurology* 33(8): 971–980.

Vertical Gaze Disorders and Parinaud's Syndrome

Trojanowski JQ, Wray SH. 1980. Vertical gaze ophthalmoplegia: Selective paralysis of downgaze. *Neurology* 30(6): 605–610.

Segarra JM. 1970. Cerebral vascular disease and behavior. I. The syndrome of the mesencephalic artery (basilar artery bifurcation). *Arch Neurol* 22(5): 408–418.

Baloh RW, Furman JM, Yee RD. 1985. Dorsal midbrain syndrome. *Neurology* 35(1): 54–60.

Moffie D, Ongerboer de Visser BW, Stefanko SZ. 1983. Parinaud's syndrome. *J Neurol Sci* 58(2): 175–183.

CHAPTER 14

Brainstem III: Internal Structures and Vascular Supply

ANATOMICAL AND CLINICAL REVIEW

Main Components of the Brainstem

Brainstem Sections

Cranial Nerve Nuclei and Related Structures

Long Tracts

KCC 14.1 Locked-in Syndrome

Cerebellar Circuitry

Reticular Formation and Related Structures

Widespread Projection Systems of Brainstem and Forebrain: Consciousness, Attention, and Other Functions

Anatomy of the Sleep–Wake Cycle

KCC 14.2 Coma and Related Disorders

Reticular Formation Motor, Reflex, and Autonomic Systems

Brainstem Vascular Supply

KCC 14.3 Vertebrobasilar Vascular Disease

CLINICAL CASES

14.1 Face and Contralateral Body Numbness, Hoarseness, Horner's syndrome, and Ataxia

14.2 Hemiparesis Sparing the Face

14.3 Dysarthria and Hemiparesis

14.4 Unilateral Face Numbness, Hearing Loss, and Ataxia

14.5 Locked In

14.6 Wrong-Way Eyes, Limited Upgaze, Decreased Responsiveness, and Hemiparesis with an Amazing Recovery

14.7 Diplopia and Unilateral Ataxia

14.8 Intermittent Memory Loss, Diplopia, Sparkling Lights, and Somnolence

14.9 Intractable Hiccups

Additional Cases

BRIEF ANATOMICAL STUDY GUIDE

A 22-year-old woman felt her neck "snap" during treatment by a chiropractor. As she left the office, she felt dizzy and staggered out to her car, falling to the left. She also developed numbness and tingling on the left side of her face, a hoarse voice, a small left pupil, a drooping left upper eyelid, and decreased sensation on the right side of her body. This patient's symptoms illustrate the complicated deficits that follow interruption of the blood supply to one part of the brainstem. In Chapter 10 we learned about the functions of various cortical regions and their blood supply. Here we will learn about the functions of brainstem nuclei and pathways, and the blood supply that is vital to each brainstem region.

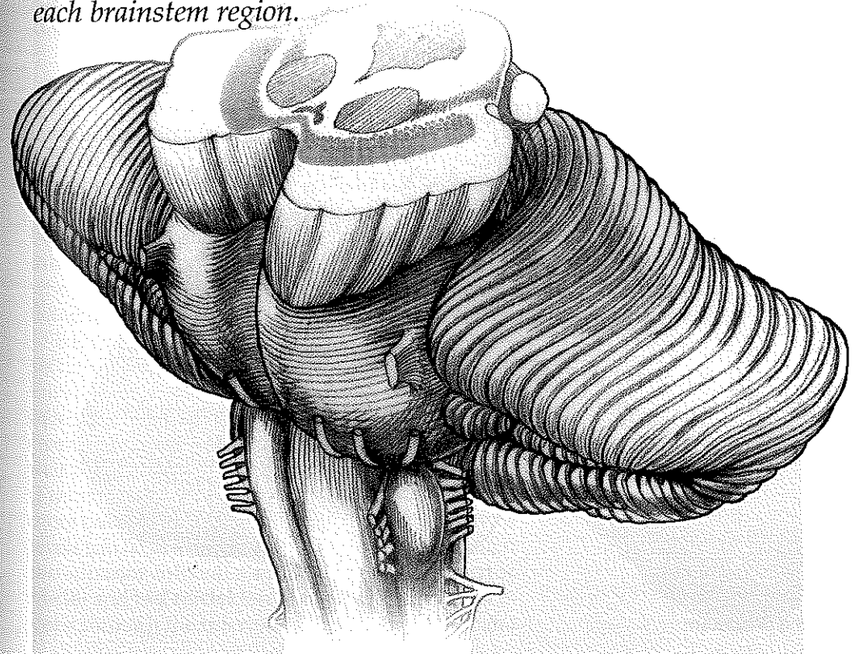

ANATOMICAL AND CLINICAL REVIEW

No region of the nervous system inspires more awe in the clinician than the brainstem, perhaps because small lesions in this structure can have devastating consequences, or perhaps because of the elegant and complex anatomy of this compact structure juxtaposed between the cerebral hemispheres on the one hand and the spinal cord and cranial nerves on the other. Or finally, perhaps the brainstem inspires respect because it is the most evolutionarily ancient brain region (together with the basal forebrain), harking back to the simpler nervous systems of our reptilian ancestors. Whatever the reason, a thorough knowledge of brainstem anatomy is essential for the clinician's ability to diagnose and treat the often life-threatening disorders of this region of the brain.

In the previous two chapters we discussed the role of the brainstem in cranial nerve function, eye movements, and pupillary control. In this chapter we will examine the inner workings of the brainstem in greater detail, including some important nuclei and white matter pathways. After introducing these structures, we will identify them in the traditional manner by reviewing a series of brainstem sections. Next, several brainstem structures not discussed in other chapters will be examined in greater depth, especially those constituting the reticular formation and related structures. Finally, we will discuss the vascular territories of the brainstem, and the characteristic syndromes that result from damage to particular groups of brainstem structures located in close proximity to one another. Discussion of these vascular syndromes is diagnostically useful and also serves as an excellent review of regional brainstem neuroanatomy.

Main Components of the Brainstem

We can summarize the main components of the brainstem in a simplified manner, as shown in Figure 14.1, by using the following four functional groupings:

1. Cranial nerve nuclei and related structures
2. Long tracts
3. Cerebellar circuitry
4. Reticular formation and related structures

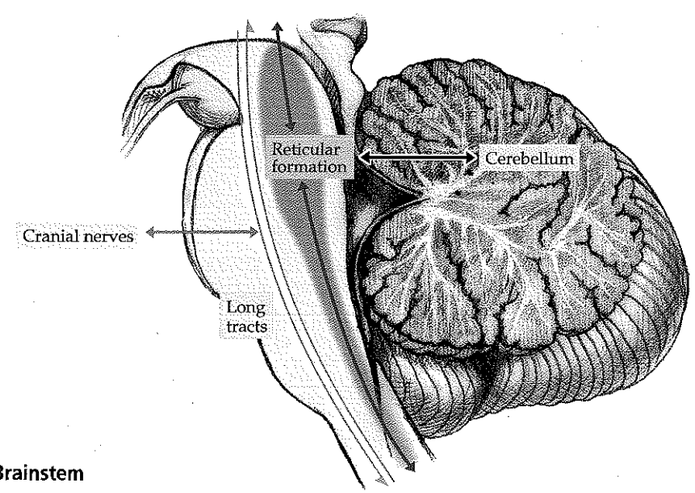

Figure 14.1 Main Components of the Brainstem

As would be expected from these functional groupings, brainstem lesions are often associated with cranial nerve abnormalities, long-tract findings, ataxia, and impairments related to reticular formation dysfunction such as impaired level of consciousness and autonomic dysregulation. It can be helpful to think of these four functional groupings when imagining the effects of lesions in different parts of the brainstem.

The cranial nerve nuclei and related structures were discussed in Chapters 12 and 13, the long tracts were discussed in Chapters 6 and 7, and the cerebellar pathways will be discussed in Chapter 15. In this chapter we will review these structures briefly and discuss the brainstem reticular formation and related structures in greater detail. The subcomponents of each grouping are listed in Table 14.1. Before proceeding further, let's identify these structures in the brainstem through the traditional, but so far unparalleled, method of examining stained brainstem sections.

Brainstem Sections

There is no substitute, when learning brainstem anatomy, for examining its detailed structures in stained serial sections of the human brainstem. The sections in Figures 14.3, 14.4, and 14.5 were prepared with a stain for myelin, so that myelin appears dark and gray matter appears light. We will refer to these sections as we review different nuclei, pathways, and functional systems in this chapter. A useful technique for anatomical self-study and review is to follow a given structure or pathway from start to finish as it appears in multiple adjacent sections.

Recall that the brainstem consists of the midbrain, pons, and medulla oblongata (see Figure 12.1). As in the spinal cord, motor nuclei in the brainstem are located more ventrally, while sensory nuclei are located more dorsally. During development, the sensory and motor nuclei are demarcated by the **sulcus limitans** (see Figure 12.4). In the adult, the sulcus limitans is still visible along the lateral wall of the fourth ventricle, dividing **motor nuclei** ventromedially from **sensory nuclei** dorsolaterally.

Another set of terminology that is sometimes used in discussing the brainstem is "tectum," "tegmentum," and "basis" (Figure 14.2). The **tectum,** meaning "roof" in Latin, is obvious only in the midbrain and consists of the superior and inferior colliculi, which lie dorsal to the cerebral aqueduct. The **tegmentum,** meaning "covering," lies ventral to the cerebral aqueduct in the midbrain and ventral to the fourth ventricle in the pons and medulla. The tegmentum makes up the main bulk of the brainstem nuclei and reticular formation, which we will discuss in this chapter. The **basis** is the most ventral portion, where the large collections of fibers making up the corticospinal and corticobulbar tracts lie.

For overall orientation, let's review the brainstem sections briefly, proceeding from rostral to caudal. Functional details of the many structures mentioned here are discussed elsewhere. The **midbrain** is relatively short, and most axial sections cut through either the **superior colliculi,** which are more rostral (Figure 14.3A), or the **inferior colliculi,** which are more caudal (see Figure 14.3B). Sections at these two levels can be distinguished because sections through the superior colliculi also include the **oculomotor nuclei** and **red nuclei** (see Figure 14.3A), while sections through the inferior colliculi also include the

Figure 14.2 Brainstem Basis, Tegmentum, and Tectum Axial section through the midbrain at the level of the superior colliculi. (Brainstem section modified from Martin JH. 1996. *Neuroanatomy: Text and Atlas*, 2nd Ed. McGraw-Hill, New York.)

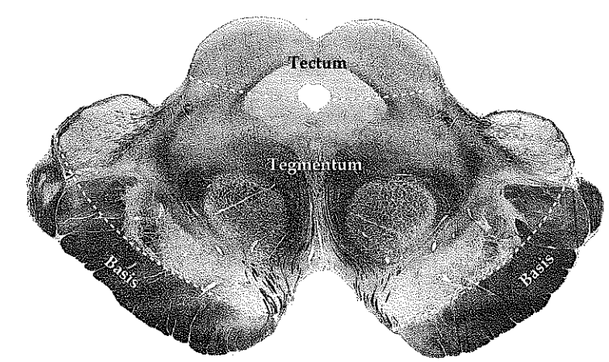

TABLE 14.1 Summary of Brainstem Structures

MAIN FUNCTIONAL GROUPINGS	SUBCOMPONENTS
1. Cranial nerve nuclei and related structures (see Chapters 12, 13)	Somatic motor column (GSE)[a] Oculomotor, trochlear, abducens, and hypoglossal nuclei
	Branchial motor column (SVE) Motor trigeminal, facial, ambiguus, and spinal accessory nuclei
	Parasympathetic column (GVE) Edinger–Westphal, superior and inferior salivatory nuclei, dorsal motor nucleus of CN X
	General somatic sensory column (GSA) Trigeminal nuclear complex
	Special somatic sensory column (SSA) Vestibular nuclei, cochlear nuclei
	Visceral sensory column Nucleus solitarius: rostral portion (SVA); caudal portion (GVA)
	Additional nuclei and pathways associated with eye movements Pretectal area; superior colliculus; medial longitudinal fasciculus (MLF); rostral interstitial nucleus of the MLF; convergence center; paramedian pontine reticular formation; accessory hypoglossal nucleus
	Additional nuclei and pathways associated with hearing Superior olivary nuclear complex; trapezoid body; lateral lemniscus; inferior colliculus
	Other nuclei and pathways associated with cranial nerve function Reticular formation; central tegmental tract
2. Long tracts (see Chapters 6, 7)	Motor pathways Corticospinal and corticobulbar tracts; other descending somatomotor pathways; descending autonomic pathways
	Somatosensory pathways Posterior column–medial lemniscal system; anterolateral system
3. Cerebellar circuitry (see Chapter 15)	Superior, middle, and inferior cerebellar peduncles Pontine nuclei; red nucleus; (parvocellular portion); central tegmental tract; inferior olivary nucleus
4. Reticular formation and related structures	Systems with widespread projections Reticular formation; cholinergic nuclei; noradrenergic nuclei; serotonergic nuclei; dopaminergic nuclei; other projecting systems
	Nuclei involved in sleep regulation
	Pain modulatory systems Periaqueductal gray; rostral ventral medulla
	Brainstem motor control systems: somatic, branchial, and autonomic Posture and locomotion (reticular formation; vestibular nuclei; superior colliculi; red nucleus [magnocellular portion]; substantia nigra; pedunculopontine tegmental nucleus) respiration; cough, hiccup, sneeze, shiver, swallow; nausea and vomiting (chemotactic trigger zone); autonomic control, including heart rate and blood pressure; sphincter control, including pontine micturition center

Note: The structures listed here reflect our interest in learning clinically relevant neuroanatomy. There are numerous additional brainstem structures beyond the scope of this text.

[a]GSA, general somatic afferent; GSE, general somatic efferent; GVA, general visceral afferent; GVE, general visceral efferent; SSA, special somatic afferent; SVA, special visceral afferent; SVE, special visceral efferent.

Figure 14.3 Myelin-Stained Sections of the Midbrain Axial planes of section, are shown in the inset. (A) Rostral midbrain (×3.1). (B) Caudal midbrain (×3.0). (From Martin JH. 1996. *Neuroanatomy: Text and Atlas,* 2nd Ed. McGraw-Hill, New York.)

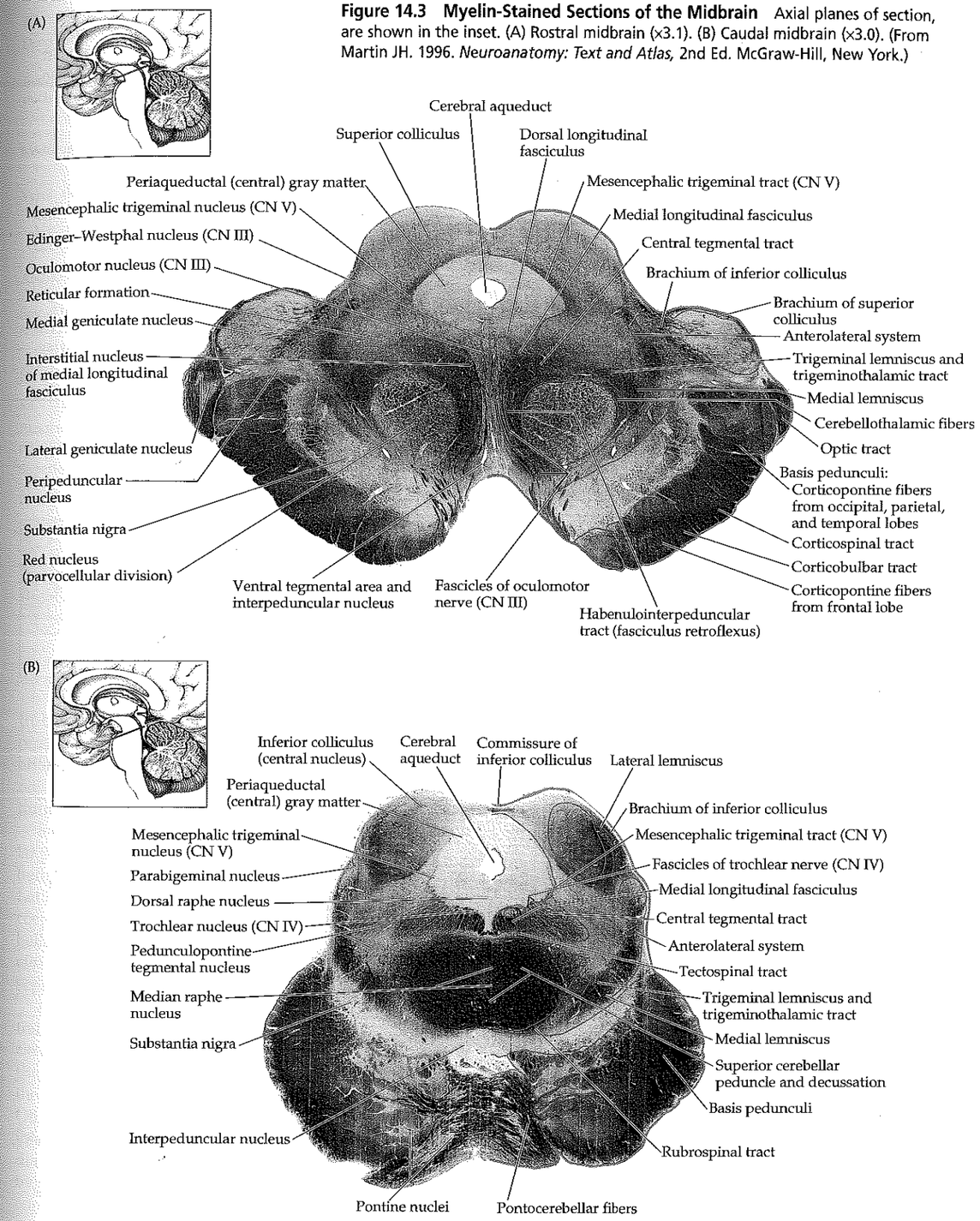

Figure 14.4 Myelin-Stained Sections of the Pons Axial planes of section are shown in the insets. (A) Pontomesencephalic junction (×3.3). (B) Rostral to mid pons (×3.3). (C) Caudal pons (×3.0). (A from the University of Washington Digital Anatomist project; B from DeArmond SJ, Fusco MM, Maynard MD. 1989. *Structure of the Human Brain: A Photographic Atlas*, 3rd Ed. Oxford, New York; C from Martin JH. 1996. *Neuroanatomy: Text and Atlas*, 2nd Ed. McGraw-Hill, New York.)

(A)

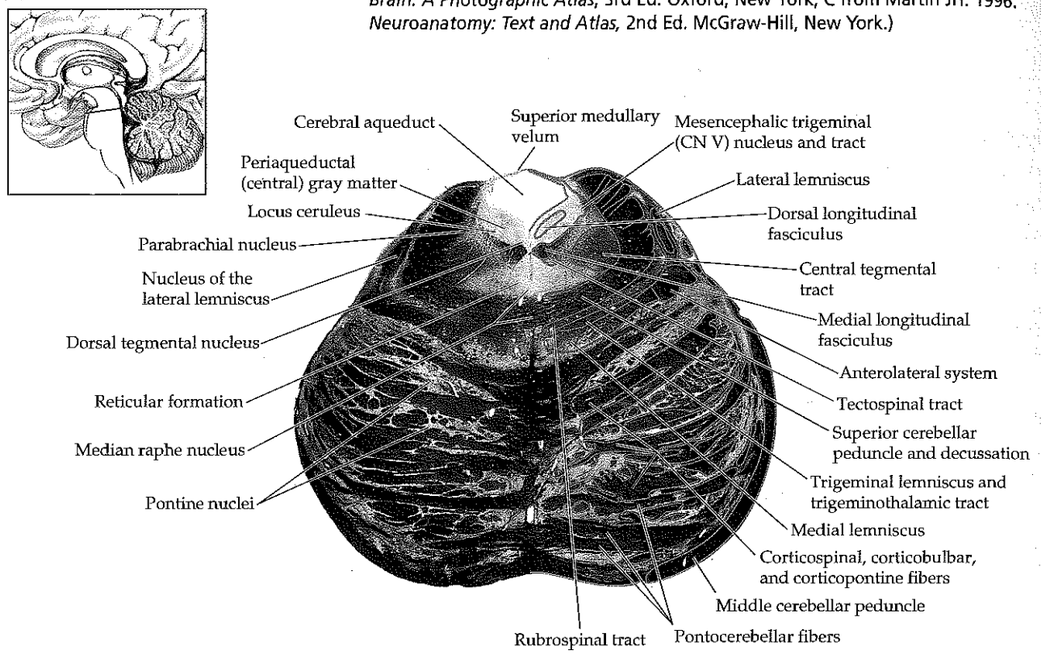

(B)

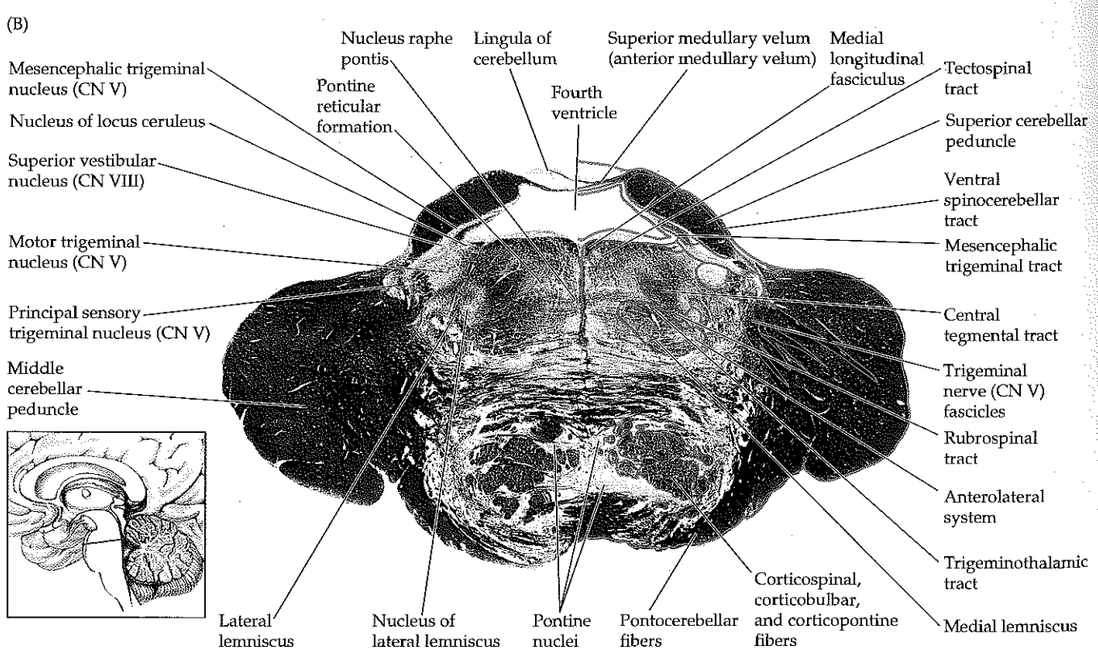

(C)

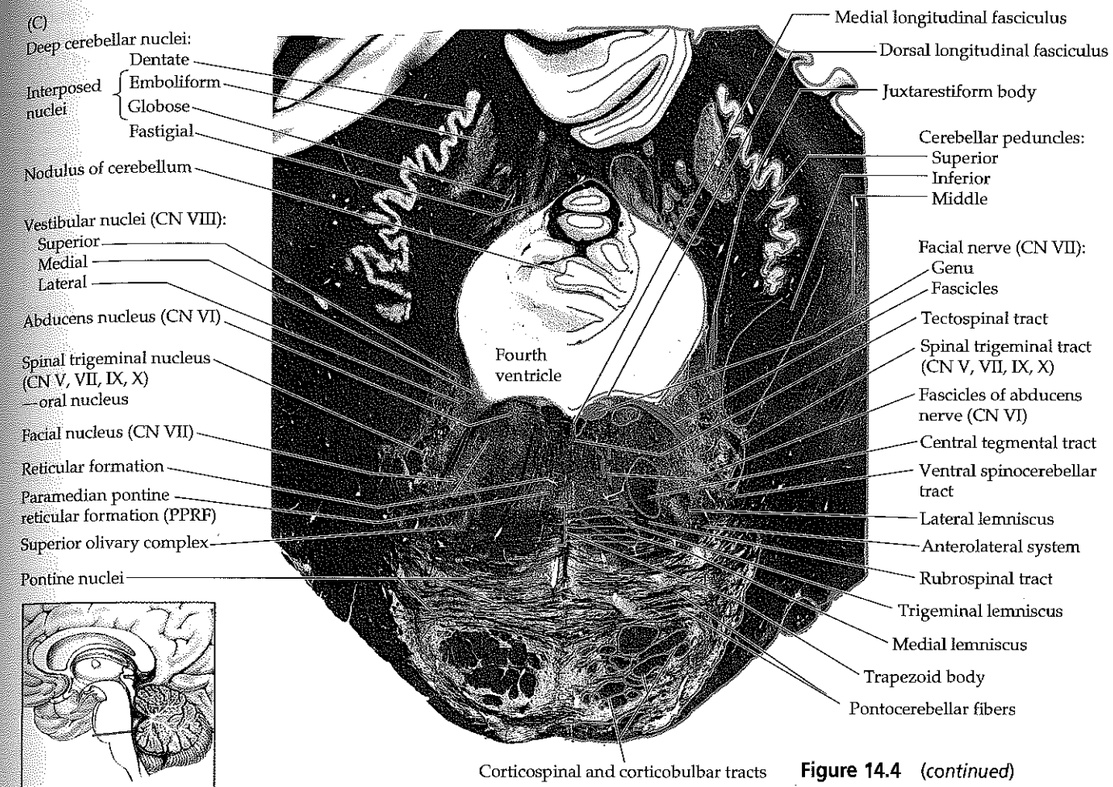

Figure 14.4 *(continued)*

trochlear nuclei and **brachium conjunctivum** (decussation of the superior cerebellar peduncles) (see Figure 14.3B). Other important landmarks in midbrain sections include the cerebral aqueduct, periaqueductal gray, midbrain reticular formation, medial lemniscus, anterolateral system, and **cerebral peduncles** (= substantia nigra + basis pedunculi [see Figure 14.3]).

In sections through the **pons** (Figure 14.4), the large thick middle cerebellar peduncles are visible laterally. These large peduncles connecting to the cerebellum on either side inspired the name "pons," which means "bridge" in Latin. The ventral pons consists of the **basis pontis,** which includes the corticospinal and corticobulbar tracts, as well as the pontine nuclei involved in cerebellar function. The **pontine tegmentum** contains numerous important nuclei and pathways, which we will discuss shortly. The **fourth ventricle** separates the pontine tegmentum from the cerebellum.

As in the midbrain, sections through the medulla can be thought of as rostral or caudal. In sections through the **rostral medulla,** the inferior olivary nucleus is present, as is the fourth ventricle (Figure 14.5A). In the **caudal medulla,** the inferior olivary nucleus and fourth ventricle are no longer present but the posterior columns and posterior column nuclei appear (see Figure 14.5B). Other important landmarks seen in sections through the medulla include the inferior cerebellar peduncles, pyramidal tracts, anterolateral system, and medial lemniscus. The transition between the medulla and spinal cord is marked by the **pyramidal decussation** (see Figure 14.5C). The upper cervical spinal cord contains the **accessory spinal nucleus** (see Figure 14.5D).

REVIEW EXERCISE

Cover the labels and insets in Figures 14.3–14.5. For each section shown in these figures, identify the level in the brainstem and name as many labeled structures as possible. These structures will be reviewed again in the discussion that follows.

Figure 14.5 Myelin-Stained Sections of the Medulla and Cervical Spine
Axial planes of section are shown in the insets. (A) Rostral medulla (×5.0). (B) Caudal medulla (×6.9). (C) Cervicomedullary junction (×9.6). (D) Rostral cervical spinal cord (C2) (×12.6). (A–C from Martin JH. 1996. *Neuroanatomy: Text and Atlas*, 2nd Ed. McGraw-Hill, New York; D from the University of Washington Digital Anatomist project.)

(A)

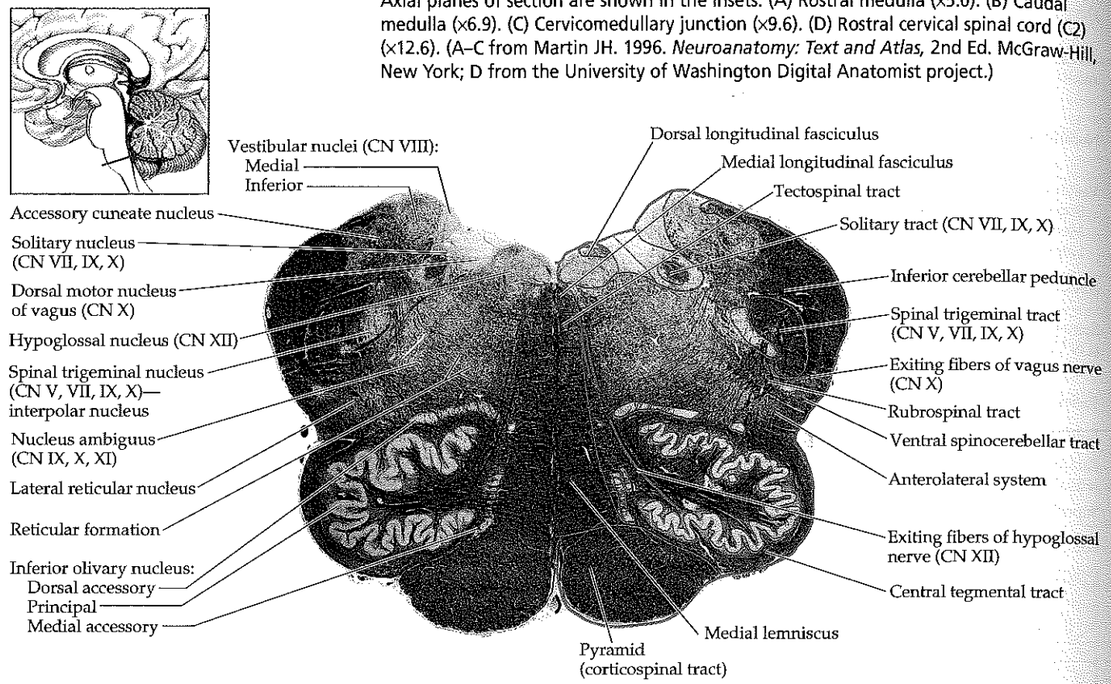

(B)

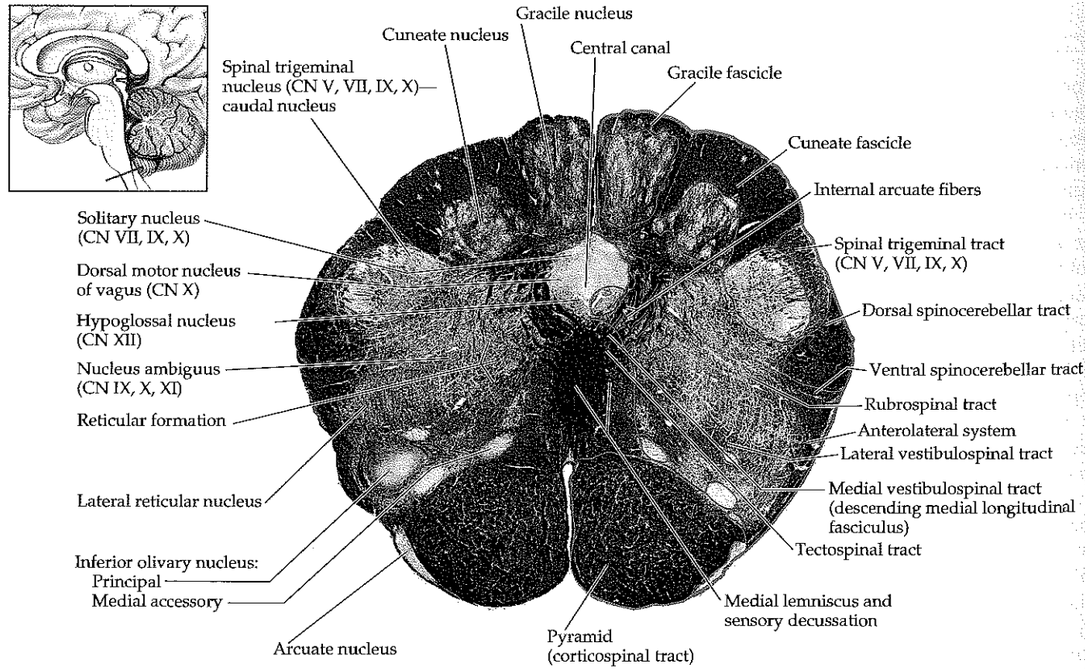

Figure 14.5 *(continued)*

(C)

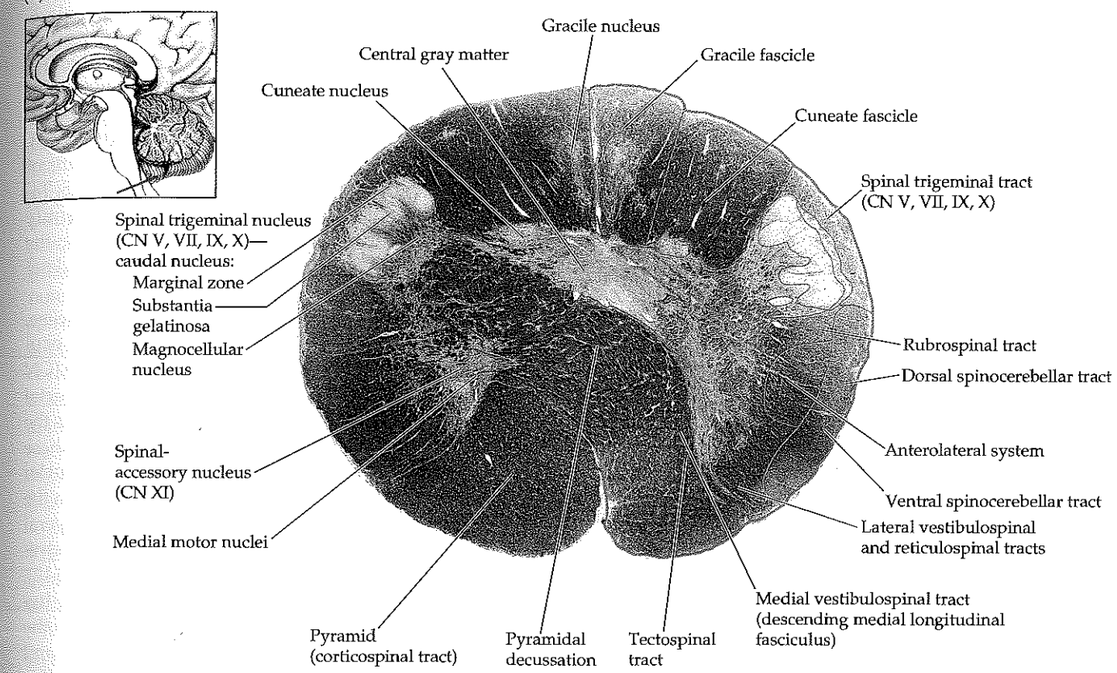

(D)

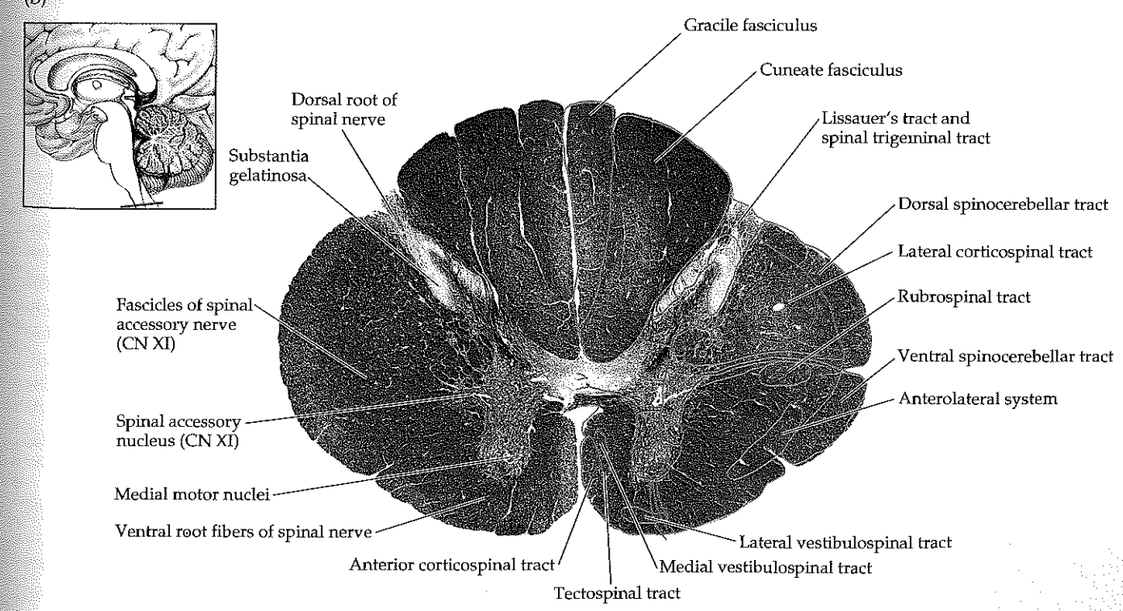

Now that we have reviewed the overall architecture of the brainstem, we are ready to discuss each of the four main functional groupings (see Table 14.1) in more detail.

Cranial Nerve Nuclei and Related Structures

As discussed in Chapter 12, the cranial nerve motor nuclei are located ventral to the sulcus limitans, and the sensory nuclei dorsal to the sulcus limitans, in an arrangement similar to that of the spinal cord (see Figure 12.4). There are three longitudinal columns of motor nuclei and three columns of sensory nuclei, covered in detail in Chapters 12 and 13 (see Figure 12.5; Tables 12.3, 12.4). We will review these nuclei again briefly here, and identify them in the brainstem sections. Knowing the locations of these nuclei in the brainstem is essential for localizing brainstem infarcts, as we will discuss later in this chapter.

The **somatic motor nuclei** (GSE) are the oculomotor, trochlear, abducens, and hypoglossal nuclei, all of which remain adjacent to the midline. The **oculomotor nuclei** (CN III) are in the rostral midbrain, the **trochlear nuclei** (CN IV) in the caudal midbrain; both nuclei lie just ventral to the periaqueductal gray (see Figure 14.3A,B). The **medial longitudinal fasciculus (MLF)** forms the ventral border of the oculomotor and trochlear nuclei, and interconnects these nuclei, the abducens nuclei, and the vestibular nuclei. The **abducens nuclei** (CN VI) help form the facial colliculus on the floor of the fourth ventricle in the mid- to lower pons (see Figure 14.4C). As we discussed in Chapter 13, several other brainstem regions are important for the supranuclear control of eye movements, including the paramedian pontine reticular formation (see Figure 13.12), the rostral interstitial nucleus of the MLF, and the convergence center. The **hypoglossal nuclei** (CN XII) form the hypoglossal trigones on the floor of the fourth ventricle in the medulla (see Figure 14.5A; see also Figure 12.2B) and have a longitudinal sausage shape continuing into the caudal medulla (see Figure 14.5B). As can be seen in these sections, three sausage-shaped nuclei bear a constant relation to each other as they run along the floor of the ventricle or central canal of the medulla. These are, from medial to lateral, the hypoglossal, dorsal motor X, and solitary nuclei (see Figure 14.5A,B; see also Figure 12.5).

The **branchial motor nuclei** (SVE) are the trigeminal motor nucleus (CN V), facial nucleus (CN VII), nucleus ambiguus (CN IX, X), and spinal accessory nucleus (CN XI; also known as the accessory spinal nucleus). Recall that the branchial motor nuclei initially lie just lateral to the somatic motor nuclei, but they gradually migrate ventrolaterally into the tegmentum (see Figure 12.4). The **trigeminal motor nucleus** is located in the upper-to-mid pons (see Figure 14.4B), just ventral to the chief trigeminal sensory nucleus, near the level where the trigeminal nerve exits the brainstem. The **facial nucleus** is located more caudally in the pontine tegmentum (see Figure 14.4C) and gives rise to the looping fibers of the facial colliculus. The **nucleus ambiguus** is difficult to distinguish from the surrounding brainstem (see Figure 14.5A,B). It runs longitudinally through the medulla in a similar position to the facial nucleus. The **spinal accessory nucleus** (also known as the accessory spinal nucleus), as its name implies, is located not in the brainstem, but rather in the upper five segments of the cervical spinal cord (see Figure 14.5D). It protrudes laterally between the dorsal and ventral horns of the spinal cord central gray matter.

The **parasympathetic nuclei** (GVE) are the Edinger–Westphal nucleus (CN III), superior (CN VII) and inferior (CN IX) salivatory nuclei, and dorsal motor nucleus of CN X. The **Edinger–Westphal nuclei** form a V-shaped cap as they fuse in the midline and curve over the dorsal and rostral aspect of the oculomotor nuclei (see Figure 14.3A; see also Figure 13.3). The **superior and inferior salivatory nuclei** lie in the pontine tegmentum (see Figure 12.5), and do not form discrete, easily visible nuclei on standard sections.* The **dorsal motor nucleus of CN X** runs from the rostral to the caudal medulla, just lateral to the hypoglossal nucleus (see Figure 14.5A,B). It forms the **vagal trigone** on the floor of the fourth ventricle, just lateral to the hypoglossal trigone (see Figure 12.2B).

General somatic sensory (GSA) inputs from the cranial nerves (CN V, VII, IX, X) all travel to the trigeminal nuclear complex. The **trigeminal nuclear complex** runs from the midbrain to the upper cervical spinal cord (see Figures 14.3–14.5) and consists of three nuclei: the mesencephalic, chief sensory, and spinal trigeminal nuclei (see Table 12.6). The **mesencephalic trigeminal nucleus and tract,** subserving proprioception, run along the lateral edge of the periaqueductal gray matter of the midbrain (see Figures 14.3, 14.4A). The **chief (main, principal) trigeminal sensory nucleus** is located in the upper-to-mid pons just dorsolateral to the trigeminal motor nucleus (see Figure 14.4B). The **spinal trigeminal nucleus** and **spinal trigeminal tract** run the length of the lateral pons and medulla (see Figures 14.4C, 14.5A–C). It should be clear from reviewing Figure 14.5C and D that the spinal trigeminal nucleus is the rostral extension of the dorsal horn of the spinal cord. Recall that these systems are analogous, subserving pain and temperature sensation for the face and body (see Table 12.6). Similarly, the chief trigeminal nuclei (see Figure 14.4B) are analogous to the dorsal column nuclei (see Figure 14.5B) in that they both subserve fine discriminative touch.

Special somatic sensory (SSA) inputs for hearing and vestibular sense (CN VIII) reach the cochlear and vestibular nuclei, respectively. The **dorsal and ventral cochlear nuclei** wrap around the lateral aspect of the inferior cerebellar peduncle at the pontomedullary junction (see Figure 12.17C). After entering the brainstem, the hearing pathways decussate at multiple levels, as discussed in Chapter 12. Many fibers from the cochlear nuclei decussate in the trapezoid body in the caudal pons (see Figure 14.4C; see also Figures 12.16, 12.17B). Some fibers synapse in the **superior olivary nuclear complex** of the pons (see Figure 14.4C). Auditory information then ascends in the **lateral lemniscus** (see Figures 14.3B, 14.4) to reach the **inferior colliculus** (see Figure 14.3B). From there, fibers ascend via the **brachium of the inferior colliculi** to the **medial geniculate nuclei** of the thalamus, located just lateral to the superior colliculi of the midbrain (see Figure 14.3A). Information then continues in the auditory radiations to the primary auditory cortex (see Figure 12.16).

There are **four vestibular nuclei—superior, inferior, medial,** and **lateral**—on each side of the brainstem, lying on the lateral floor of the fourth ventricle, in the pons and rostral medulla (see Figures 14.4B,C, 14.5A; see also Figure 12.18). As we discussed in Chapter 12, the vestibular nuclei convey perception of head position and acceleration to the cerebral cortex via relays in the ventral posterior thalamus. However, most functions of the vestibular nuclei are not at the level of conscious perception. Thus, the medial and lateral vestibulospinal tracts (see Figure 6.11D) are involved in posture and muscle tone, and they arise primarily from the medial and lateral vestibular nuclei, respectively. The medial vestibular nucleus is the largest of the vestibular nuclei (see Figure 14.5A). The inferior vestibular nucleus is also relatively easy to identify be-

*Some authors propose abandoning the names "superior and inferior salivatory nuclei" because, among other reasons, they are too limited: In addition to parasympathetic innervation of the salivary glands, these nuclei innervate the lacrimal glands, the secretory glands of the nasal mucosa, and the cerebral blood vessels. For now, however, these names remain in wide use.

MNEMONIC

cause fibers of the lateral vestibular nucleus traverse the inferior vestibular nucleus as they descend to the spinal cord, giving the inferior vestibular nucleus a characteristic "checkerboard" appearance on myelin-stained sections (see Figure 14.5A).

As we mentioned earlier in this section, the MLF is an important pathway, connecting the vestibular nuclei and nuclei involved in extraocular movements (see Figure 12.18). The **MLF** can be identified as a heavily myelinated tract running near the midline on each side, just under the floor of the fourth ventricle in the midline of the pons (see Figure 14.4), and just under the oculomotor and trochlear nuclei in the midbrain (see Figure 14.3). Fibers arising from the medial vestibular nucleus, with additional contributions mainly from the superior vestibular nucleus, ascend in the MLF to the oculomotor, trochlear, and abducens nuclei, mediating vestibulo-ocular reflexes (see Chapter 13). Finally, as we will discuss in Chapter 15, the vestibular nuclei have numerous important reciprocal connections with the cerebellum, primarily with the inferior cerebellar vermis and flocculonodular lobes.

MNEMONIC

All **visceral afferents,** whether special or general, travel to the **nucleus solitarius** (see Figure 14.5A,B), located just lateral to the dorsal motor nucleus of CN X. Note that the nucleus solitarius has a unique appearance in myelin sections, with the heavily stained central solitary tract surrounded by the lightly stained tube-shaped (donut-shaped in cross section) solitary nucleus. **Special visceral afferents** (SVA) for taste (CN VII, IX, X) reach the rostral nucleus solitarius, also known as the gustatory nucleus, while **general visceral afferents** (GVA) from the cardiorespiratory (and gastrointestinal) systems (CN IX, X) reach the caudal nucleus solitarius, also known as the cardiorespiratory nucleus. As discussed in Chapter 12, the taste pathway continues rostrally via the **central tegmental tract** (see Figures 12.12, 14.3, 14.4) to reach the ventral posterior nucleus (VPM) of the thalamus, which projects to the cortical taste area in the parietal operculum and insula.

Long Tracts

The major long tracts that pass through the brainstem were discussed in Chapters 6 and 7. The major descending motor pathways are summarized in Figure 6.11 and Table 6.3. Recall that the **corticospinal and corticobulbar tracts** travel in the middle third of the cerebral peduncles in the midbrain (see Figure 14.3; see also Figure 6.10B). The other portions of the cerebral peduncles carry predominantly corticopontine fibers involved in cerebellar circuitry (see Chapter 15). The corticospinal fibers continue from the midbrain cerebral peduncles to run through the basis pontis (see Figure 14.4) and then emerge as the pyramids in the ventral medulla (see Figure 14.5A,B). The pyramidal decussation occurs at the cervicomedullary junction (see Figure 14.5C), giving rise to the lateral corticospinal tract (seeFigure 14.5D).

The major ascending somatosensory pathways are summarized in Figures 7.1 and 7.2, and in Table 7.1. Recall that axons in the **posterior columns,** subserving vibration, joint position sense, and fine touch, synapse onto neurons in the **posterior column nuclei,** consisting of the more medial **nucleus gracilis** for the legs, and the more lateral **nucleus cuneatus** for the arms (see Figure 14.5B–D). The posterior column nuclei give rise to the **internal arcuate fibers,** which cross to the opposite side (see Figure 14.5B) and then ascend through the brainstem as the **medial lemniscus** (see Figures 14.3, 14.4, 14.5A) to reach the VPL (ventral posterior lateral nucleus) of the thalamus (see Figure 7.1). The **anterolateral systems,** including the **spinothalamic tract,** subserve pain, temperature, and crude touch. The anterolateral systems decussate in the

spinal cord—not the brainstem—and they assume a fairly fixed, lateral position as they ascend through the brainstem (see Figures 14.3–14.5).

One additional descending pathway that is clinically relevant is the descending sympathetic pathway running through the lateral brainstem in close proximity to the anterolateral systems (see Figure 13.10). Recall that damage to this pathway can cause Horner's syndrome (see KCC 13.5).

KEY CLINICAL CONCEPT
LOCKED-IN SYNDROME

14.1 Patients who have absent motor function but maintain intact sensation and cognition are said to be "locked in." The usual cause is an infarct in the ventral pons (see KCC 14.3) affecting the bilateral corticospinal and corticobulbar tracts. The spinal cord and cranial nerves receive no input from the cortex, and the patient is unable to move. Sensory pathways and the brainstem reticular activating systems are spared. Patients are thus fully aware and able to feel, hear, and understand everything in their environment. This condition can mimic—but should be carefully distinguished from—coma, which is discussed later in this chapter (see KCC 14.2).

As we saw in Chapter 13, vertical eye movements and eyelid elevation are controlled by a region in the tegmentum of the rostral midbrain. Horizontal eye movements, however, depend on pontine circuits (see Figure 13.12). Therefore, locked-in syndrome often spares vertical eye movements and eye opening. Patients with this syndrome can thus communicate using eye movements. Special computer interfaces based on eye movements have been developed for patients with locked-in syndrome. The French editor Jean-Dominique Bauby even wrote an entire book (*Le Scaphandre et le Papillon*, or *The Diving Bell and the Butterfly*) after becoming locked in, spelling out one letter at a time to a transcriptionist by using eye movements. The prognosis is generally poor: About 60% of locked-in patients eventually succumb to respiratory infection or other complications of paralysis. Some patients, however, do regain some motor function over time, and rarely, a near-complete recovery can occur.

In addition to bilateral ventral pontine infarcts, other lesions in the ventral pons, such as hemorrhage, tumor, encephalitis, multiple sclerosis, or central pontine myelinolysis can also occasionally cause locked-in syndrome. Less commonly, lesions in the bilateral cerebral peduncles of the midbrain, or in the internal capsules, can be the cause. In addition, a locked-in condition can result from severe disorders of motor neurons, peripheral nerves, muscles, or the neuromuscular junction (see KCC 8.1). ■

Cerebellar Circuitry

The cerebellum is discussed in detail in Chapter 15; however, here we will briefly mention a few prominent brainstem structures that participate in cerebellar circuitry. As we will see in Chapter 15, lesions of the cerebellar circuitry produce a characteristic uncoordinated wavering movement abnormality called **ataxia.** Ataxia typically occurs *ipsilateral* to the side of the lesion because cerebellar circuits tend to decussate twice before reaching lower motor neurons

The cerebellum is connected to the brainstem via three large white matter pathways called the cerebellar peduncles (see Figure 15.3). The **superior cerebellar peduncle** contains mainly cerebellar outputs (see Figure 14.4). The **decussation of the superior cerebellar peduncles** occurs in the midbrain at the level of the inferior colliculi (see Figure 14.3B). Cerebellar output fibers then continue rostrally to reach the **red nucleus** of the midbrain at the level of the superior colliculi (see Figure 14.3A). Other fibers continue rostrally to ultimately influence primary motor cortex and premotor cortex via relays in the ventrolateral nucleus of the thalamus. The **middle cerebellar peduncle** is the

largest of the cerebellar peduncles (see Figure 14.4B,C). It contains massive inputs to the cerebellum arising from the **pontine nuclei** scattered through the basis pontis (see Figure 14.4). The pontine nuclei, in turn, receive inputs from the corticopontine fibers of the cerebral peduncles (see Figure 14.3). The **inferior cerebellar peduncle** mainly carries inputs to the cerebellum from the spinal cord (see Figure 14.5A).

In addition to the pontine nuclei, several other brainstem nuclei participate in cerebellar circuitry. We will mention only a few of these here. As we have just discussed, the red nucleus receives inputs from the superior cerebellar peduncle (see Figure 14.3A). The rostral (parvocellular) portion of the red nucleus sends fibers via the central tegmental tract (see Figures 14.3B, 14.4) to reach the inferior olivary nucleus in the rostral medulla (see Figure 14.5A), which in turn sends fibers back to the cerebellum via the inferior cerebellar peduncle. Interruption of this circuit from cerebellum to brainstem and back to cerebellum results in a characteristic, though rare, movement disturbance called palatal myoclonus, which is characterized by continuous rhythmic clicking movements of the palate. In addition, as mentioned earlier, the vestibular nuclei are intimately interconnected with the cerebellum.

Reticular Formation and Related Structures

The **reticular formation** is a central core of nuclei that runs through the entire length of the brainstem (Figure 14.6). It is continuous rostrally with certain diencephalic nuclei, and caudally with the intermediate zone of the spinal cord. Simplifying somewhat, we can say that these rostral and caudal extensions highlight the two main functions of the reticular formation. Thus, the **rostral reticular formation** of the mesencephalon and upper pons function together with diencephalic nuclei to maintain an alert conscious state in the forebrain. Meanwhile, the **caudal reticular formation** of the pons and medulla works together with the cranial nerve nuclei and the spinal cord to carry out a variety of important motor, reflex, and autonomic functions. Although there are numerous exceptions, this simplified rostral and caudal conceptualization can be heuristically and clinically useful.

Definitions vary as to which nuclei to include in the reticular formation. The reticular formation has no obvious nuclear divisions when viewed with conventional histological staining. In addition, as we will discuss shortly, some neurons in the reticular formation have very widespread projection patterns, adding to the impression that this structure is diffusely organized. With more refined techniques, however, numerous specific nuclei can be identified within the reticular formation, some of which have quite precisely organized projection patterns. In addition, some cranial nerve nuclei, such as the superior and inferior salivatory nuclei, or the nucleus ambiguus, lie buried within the reticular formation. For our purposes, we will define the reticular formation as simply that portion of the brainstem tegmentum in which clearly defined nuclei are not generally visible with conventional staining.*

In addition to the reticular formation, the brainstem tegmentum contains numerous other nuclei that we refer to here simply as **related structures** (see Table 14.1). These include the periaqueductal gray matter in the midbrain, which is involved in pain modulation, and the chemotactic trigger zone in the medulla, involved in causing nausea.

*Clearly visible subnuclei do appear in some regions; for example, the nucleus reticularis gigantocellularis, which is located in the medial rostral medulla.

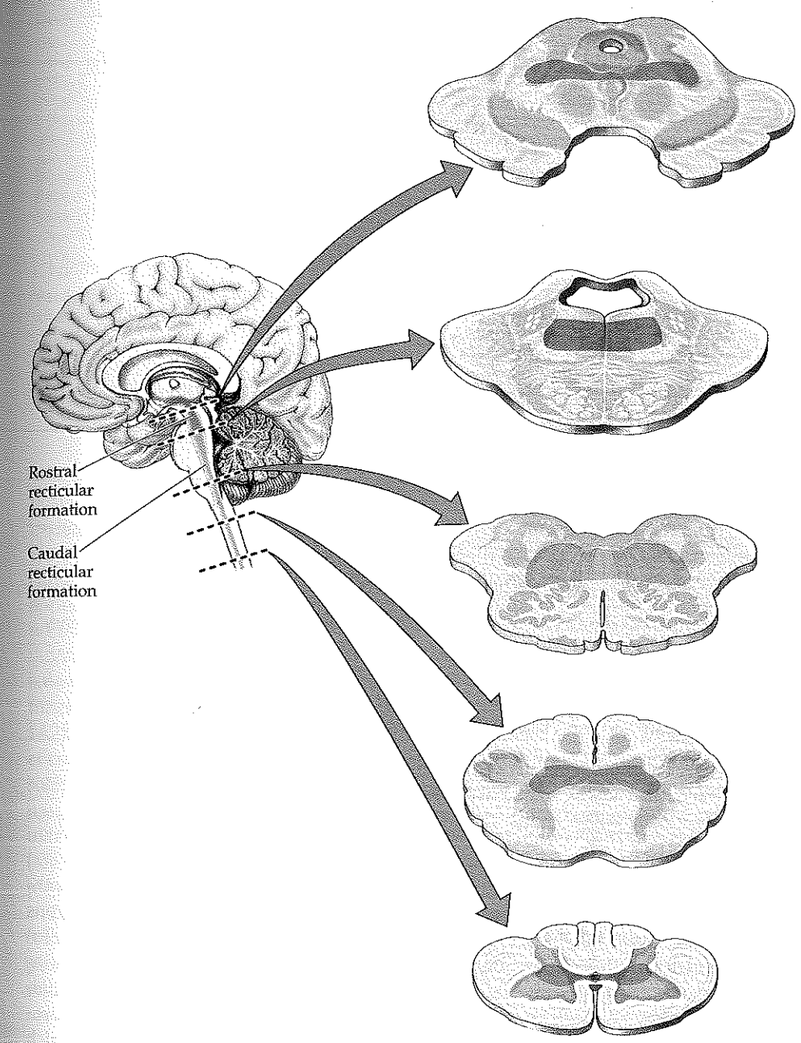

Figure 14.6 Brainstem Reticular Formation Location at multiple levels is shown. The reticular formation merges caudally with the spinal cord intermediate zone, and rostrally with the subthalamic region and lateral hypothalamus.

Widespread Projection Systems of Brainstem and Forebrain: Consciousness, Attention, and Other Functions

Most pathways in the nervous system project from one structure to a limited number of other structures. In contrast, some pathways, often called **diffuse** (or **widespread**) **projection systems,** each emanate from a single region to innervate many structures or even the entire nervous system (Table 14.2). Many of these projection systems originate in the region of the rostral brainstem reticular formation in the midbrain and upper pons. However, other widely projecting systems are also found in the hypothalamus, thalamus, and basal forebrain. Some of these systems are truly diffuse, with individual neurons

TABLE 14.2 Widespread Projection Systems in the Nervous System

PROJECTION SYSTEM	LOCATION(S) OF CELL BODIES	MAIN TARGET(S)	NEUROTRANSMITTER RECEPTOR(S)[a,b]	FUNCTION(S)[c]
Reticular formation	Midbrain and rostral pons	Thalamic intralaminar nuclei, hypothalamus, basal forebrain	Unknown (glutamate?)	Alertness
Intralaminar nuclei	Thalamic intralaminar nuclei	Cortex, striatum	(Glutamate?)	Alertness
Midline thalamic nuclei	Midline thalamic nuclei	Cortex	(Glutamate?)	Alertness
Norepinephrine	Pons: locus ceruleus and lateral tegmental area	Entire CNS	α_{1A-D}, α_{2A-D}, β_{1-3}	Alertness, mood elevation
Dopamine	Midbrain: substantia nigra pars compacta and ventral tegmental area	Striatum, limbic cortex, amygdala, nucleus accumbens, prefrontal cortex	D_{1-5}	Movements, initiative, working memory
Serotonin	Midbrain and pons: raphe nuclei	Entire CNS	5-HT_{1A-F}, 5-HT_{2A-C}, 5-HT_{3-7}	Mood elevation
Histamine	Hypothalamus: tuberomammillary nucleus; midbrain: reticular formation	Entire brain	H_{1-3}	Alertness
Acetylcholine	Basal forebrain: nucleus basalis, medial septal nucleus, and nucleus of diagonal band	Cerebral cortex	Muscarinic (M_{1-5}), nicotinic subtypes	Alertness, memory
	Pontomesencephalic region: pedunculopontine nucleus and laterodorsal tegmental nucleus	Thalamus, cerebellum, pons, medulla	Muscarinic (M_{1-5}), nicotinic subtypes	Alertness, memory

[a]Many of the neurons releasing the neuromodulatory transmitters listed here also release a variety of peptides, which are likely to play a neuromodulatory role as well.
[b]Several of the receptor subtypes listed here have been cloned, and additional receptor subtypes are constantly being added.
[c]Functions listed are highly simplified here; see text and References for additional details.

projecting over targets including large regions of the nervous system. In others, the system as a whole has widespread projections, but individual neurons have very specific projections, enabling focal control of specific targets. Together, these projection systems are essential for maintaining an alert conscious state, and for regulating attention, the sleep–wake cycle, and emotional balance. In the sections that follow we will discuss the major widespread projection systems—some with identified neurotransmitters, and others for which the neurotransmitters are still under investigation.

Brainstem Reticular Formation and Thalamus

The **pontomesencephalic reticular formation** forms a circuit together with certain thalamic nuclei that is critical to maintaining normal consciousness (Figure 14.7). On the basis of animal experiments and human patients studied in the 1930s and 1940s, it was found that lesions in the rostral brainstem reticular formation and medial diencephalon can cause coma, while stimulation of the same regions can lead to behavioral and electrographic arousal from deep anesthesia. Moruzzi and Magoun named these regions of the brain the ascending reticular activating system (ARAS). Although it has subsequently been found that these systems are not all ascending (descending cor-

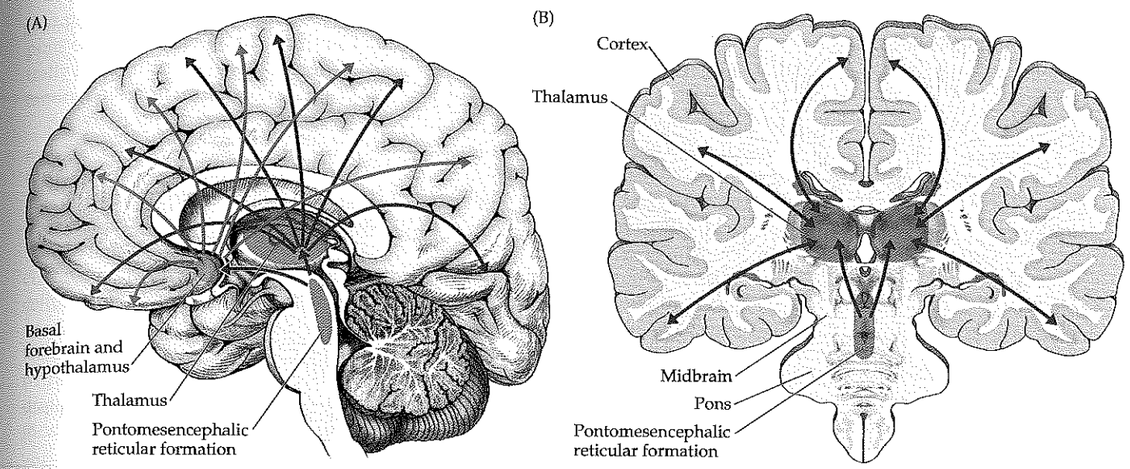

Figure 14.7 Ascending Reticular Activating Systems Midsagittal view (A); coronal view (B). Widespread projections to the cortex arise from outputs of the pontomesencephalic reticular formation relayed via the thalamic intralaminar nuclei, basal forebrain, and hypothalamus.

tical influences are critical as well) and do not all originate in the reticular formation, the term is still in wide use today. The concept of a fragile region in the upper brainstem–diencephalic junction where focal lesions can cause coma remains clinically useful, although rather than a single "system," there appear to be multiple interconnected systems acting in parallel to maintain normal consciousness.

Where in the brain can a lesion cause coma? Classically, coma is caused either by dysfunction of the **upper brainstem reticular formation,** or by dysfunction of extensive **bilateral regions of the cerebral cortex** (see also KCC 14.2). Lesions in other regions of the brainstem do not typically affect the level of consciousness. For example, lesions located more caudally in the brainstem, such as the lower pons or medulla (see Figure 14.6), do not affect consciousness. Similarly, in lesions of the ventral midbrain or pons that spare the reticular formation, consciousness is typically spared, as in locked-in syndrome (see KCC 14.1). However, **bilateral lesions of the thalamus,** particularly those involving the medial and intralaminar regions, can also cause coma.

Consciousness can be divided into the **content of consciousness,** comprised of systems mediating sensory, motor, memory, and emotional functions (discussed in other chapters throughout the book); and the **level of consciousness.** Control of the level of consciousness involves at least three processes, which can be remembered by the mnemonic **AAA** (for Alertness, Attention, Awareness). The first process, **alertness,** depends on normal functioning of the pontomesencephalic reticular formation, the thalamus, and the cortex. The second process is **attention,** which appears to use many of these same circuits, together with additional processing in frontoparietal association cortex and other systems to be discussed in Chapter 19. The third, and most poorly understood, process is that which leads to our subjective and personal experience of **awareness.** This process presumably depends on our ability to combine various higher-order forms of sensory, motor, emotional, and mnemonic information from disparate regions of the brain into a unified state of awareness, and it is still under active investigation. Here we will focus on widespread projection systems, leaving discussion of the higher-order aspects of consciousness for Chapter 19. First we will discuss the important brainstem reticular and thalamic circuits (see Figure 14.7), for which neurotransmitters have only tentatively been identified. In the sections that follow, we will dis-

MNEMONIC

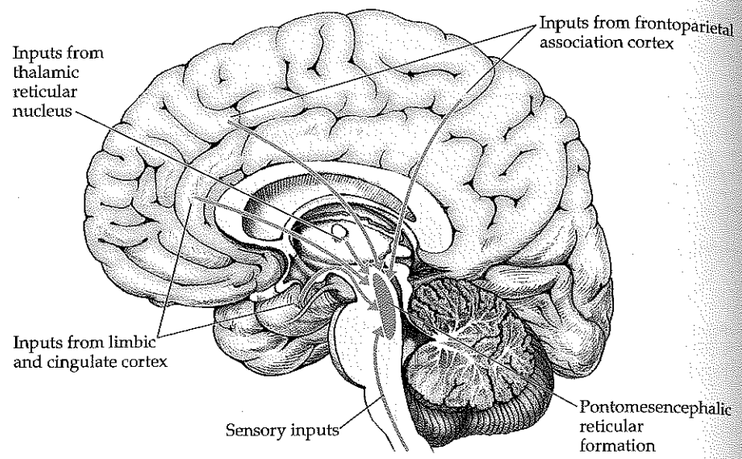

Figure 14.8 Major Inputs to the Pontomesencephalic Reticular Formation

cuss several identified neurotransmitter systems that participate in consciousness and other functions.

The pontomesencephalic reticular formation projects to the **thalamic intralaminar nuclei** (see Figure 14.7). The neurotransmitters for these projections have not been identified with certainty, although many neurons in this pathway contain glutamate. The thalamic intralaminar nuclei have numerous reciprocal connections with the basal ganglia (see Table 7.3; Figure 7.7). In addition, however, the intralaminar nuclei, particularly the **rostral intralaminar nuclei** (central lateral, paracentral, and central medial nuclei) have widespread projections to the cerebral cortex (see Figure 7.8). These projections, together with other widespread projections from the thalamus, such as those arising from the adjacent **midline thalamic nuclei** (see Figure 7.6), are thought to be important for maintaining normal alertness. In addition to projections to the intralaminar nuclei, the pontomesencephalic reticular formation projects to the **hypothalamus** and **basal forebrain** (see Figure 14.7). Widespread projections from these regions, in turn, may also participate in the alerting functions of the pontomesencephalic reticular formation.

What activates this system of behavioral arousal and alertness? The reticular formation gets inputs from sensory pathways, especially the anterolateral system spinoreticular pathway involved in pain transmission (Figure 14.8; see also Figure 7.2). In addition, numerous regions of association cortex and limbic cortex project to the pontomesencephalic reticular formation (as well as to the intralaminar nuclei), so that cognitive processes and emotions, respectively, can lead to an increased level of alertness through this system. Other circuits that may play a role in attentional mechanisms include the superior colliculi, cerebellum, and thalamic reticular nucleus, as we will discuss in Chapter 19. These mechanisms are still under active investigation.

REVIEW EXERCISE

Which of the following lesions are usually associated with coma, and which are not?

1. Unilateral frontal cortex
2. Bilateral pontomesencephalic reticular formation
3. Bilateral basis pontis
4. Bilateral medullary reticular formation
5. Bilateral diffuse regions of cortex
6. Bilateral thalami

(Answer: only 2, 5, and 6 are usually associated with coma.)

Identified Neurotransmitter Systems

Aside from the brainstem reticular formation and certain thalamic nuclei, several identified neurotransmitter systems have widespread projection patterns (see Table 14.2). These include acetylcholine, dopamine, norepinephrine, serotonin, and histamine. Interestingly, like the reticular formation already discussed, most neurotransmitter systems that project in a rostral direction to innervate the forebrain arise from the midbrain and rostral pons, while those

that project to the brainstem, cerebellum, or spinal cord arise from the lower pons or medulla. In addition, some neurotransmitter systems that project rostrally have their main source outside the brainstem in the hypothalamus (histamine) or basal forebrain (acetylcholine).

As we discussed in Chapter 2 (see Table 2.2), neurotransmitters have two general types of functions. One is to mediate communication between neurons through fast excitatory or inhibitory postsynaptic potentials acting in the millisecond time range. The main excitatory and inhibitory neurotransmitters in the central nervous system are glutamate and gamma-aminobutyric acid (GABA), respectively. The second function is **neuromodulation,** generally occurring over slower time scales. Neuromodulation includes a broad range of cellular mechanisms involving signaling cascades that regulate synaptic transmission, neuronal growth, and other functions. Neuromodulation can either facilitate or inhibit the subsequent signaling properties of the neuron. The neurotransmitters of the diffuse projection systems, including acetylcholine, dopamine, norepinephrine, serotonin, and histamine, have a mainly neuromodulatory role in the central nervous system. In addition, it is likely that a variety of peptides, small molecules, and other, as yet unidentified transmitters participate as well. Depending on the specific receptors present, these transmitters can have a facilitatory or inhibitory effect on neuronal signaling. Some transmitters even have both a facilitatory and an inhibitory neuromodulatory effect at different synapses or different receptor sites. The functional effects of these transmitters also depend on the regions of the brain being modulated, and they include effects on level of consciousness, the sleep–wake cycle, emotional states, motor behavior, and many other diverse functions. The details of these neuromodulatory actions are beyond the scope of this text (see the references at the end of this chapter for more information). Here, we will focus instead on the anatomical distribution of these neurotransmitter systems and their functional roles only in the most general terms.

Note that, unlike gross lesions of the pontomesencephalic reticular formation, lesions or pharmacological blockades of the individual projecting neurotransmitter systems discussed in this section do not result in coma. Lesions or blockades of some neurotransmitter systems, especially acetylcholine and histamine, can cause profound confusion and drowsiness, but not coma. Thus, it appears likely that maintenance of the normal awake state does not depend on a single projection system. Rather, it probably depends on intact functioning of multiple anatomical and neurotransmitter systems acting in parallel, including the pontomesencephalic reticular formation and other brainstem projection pathways, bilateral thalamic intralaminar nuclei, and bilateral cerebral cortex. The individual neurotransmitter systems discussed here do play an important role in attentional mechanisms, memory, and emotional states, as will be discussed.

ACETYLCHOLINE. **Acetylcholine** is the major efferent neurotransmitter of the peripheral nervous system, found at the neuromuscular junction, preganglionic autonomic synapses, and postganglionic parasympathetic synapses (see Chapter 6). Cholinergic neurons play a more limited role in the central nervous system, functioning primarily in neuromodulation rather than neurotransmission (recall that the major excitatory neurotransmitter of the central nervous system is glutamate). Neuromodulatory cholinergic neurons with widespread projections are found mainly in two locations (Figure 14.9): the pontomesencephalic region of the brainstem, and the basal forebrain. Neurons of the brainstem cholinergic projection system are found mainly in the **pedunculopontine tegmental nuclei** and the **laterodorsal tegmental nuclei** (see Figure 14.9). These nuclei are located, respectively, in the lateral portion of the reticular formation and periaqueductal gray, at the junction between the mid-

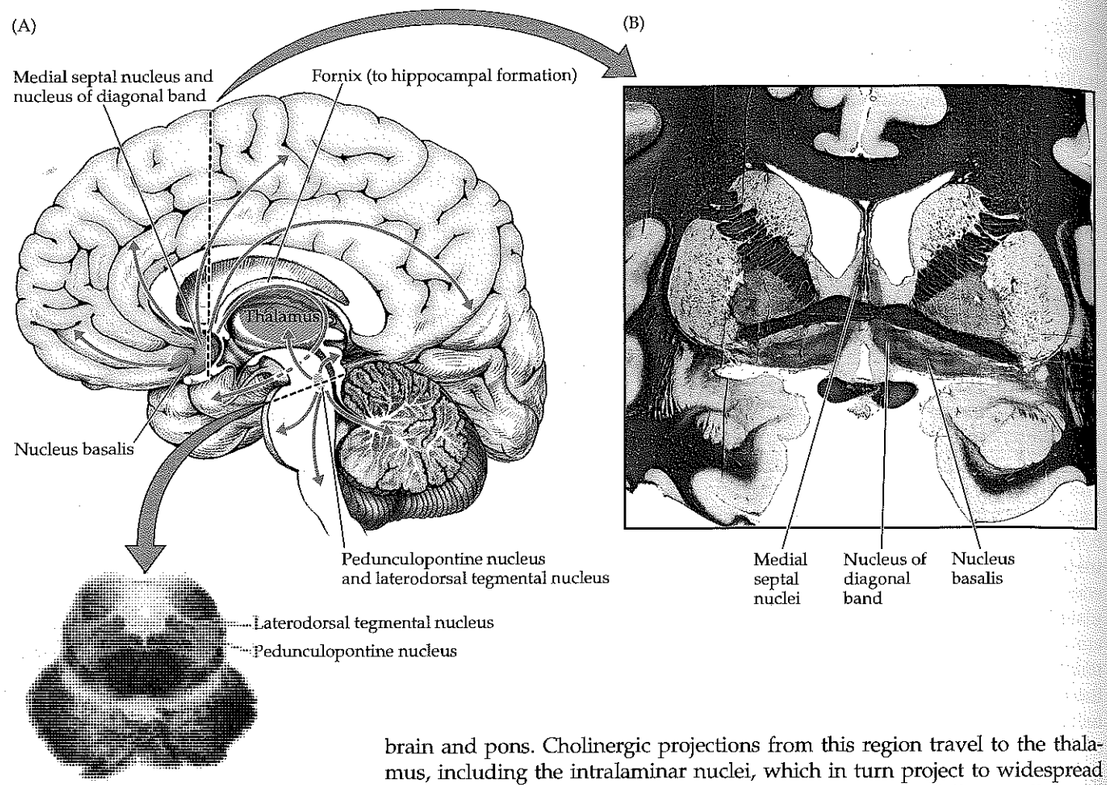

Figure 14.9 Cholinergic Projection Systems See also Table 14.2. (A and B sections modified from Martin JH. 1996. *Neuroanatomy: Text and Atlas,* 2nd Ed. McGraw-Hill, New York.)

brain and pons. Cholinergic projections from this region travel to the thalamus, including the intralaminar nuclei, which in turn project to widespread regions of the cortex (see Figure 14.7). Acetylcholine has different effects on different regions of the thalamus. In addition to its possible role in arousal, the pedunculopontine nucleus has a role in motor systems, and it is sometimes referred to as the mesencephalic locomotor region. Electrical stimulation of this region in animals causes coordinated locomotor movements. In this capacity, the pedunculopontine and laterodorsal tegmental nuclei have extensive connections with the basal ganglia, tectum, deep cerebellar nuclei, pons, medulla, and spinal cord.

Cholinergic inputs to the thalamus generally have an arousal effect mediated indirectly by facilitation of excitatory projections from the thalamus to the cortex. However, direct cholinergic inputs to the cortex do not arise from the brainstem to any significant extent; instead, they come mainly from the basal forebrain (see Figure 14.9). The **nucleus basalis** (of Meynert) contains cholinergic neurons that project to almost the entire cerebral cortex. Cholinergic projections to the hippocampal formation arise from the **medial septal nuclei** and from the **nucleus of the diagonal band** (of Broca). Cholinergic effects on the cortex and hippocampus are generally facilitatory. The cholinergic projections to the hippocampus are involved in generating a rhythmic oscillation, called the hippocampal theta rhythm, that has been postulated to play a role in the memory functions of this brain region.

In addition to cholinergic neurons with long-range projections, the central nervous system also contains cholinergic interneurons with more short-range local connections. Such cholinergic interneurons are found in the striatum (see Figure 16.7) and, to a more limited extent, in the cerebral cortex. There is also a cholinergic projection from the medial habenula to the interpeduncular nucleus.

Classically, the main cholinergic receptor type in the central nervous system is **muscarinic** (see Table 14.2). However, **nicotinic** receptors may play an important role in the central nervous system as well. The main functions of acetylcholine in the central nervous system are attention, memory, and learning. Pharmacological blockade of central cholinergic transmission causes delirium (see KCC 14.2, 19.15) and memory deficits. Degeneration of cholinergic neurons in the basal forebrain may be one of the mechanisms for memory decline in Alzheimer's disease (see KCC 19.16). The effects of cholinergic blockade on striatal neurons in movement disorders are discussed in Chapter 16.

DOPAMINE. **Dopamine** is found mainly in neurons located in the ventral midbrain: in the **substantia nigra pars compacta** and the nearby **ventral tegmental area** (see Figures 14.3, 14.10). Three projection systems have been described arising from these nuclei in the mesencephalon. The **mesostriatal** (nigrostriatal) pathway arises mainly from the substantia nigra pars com-

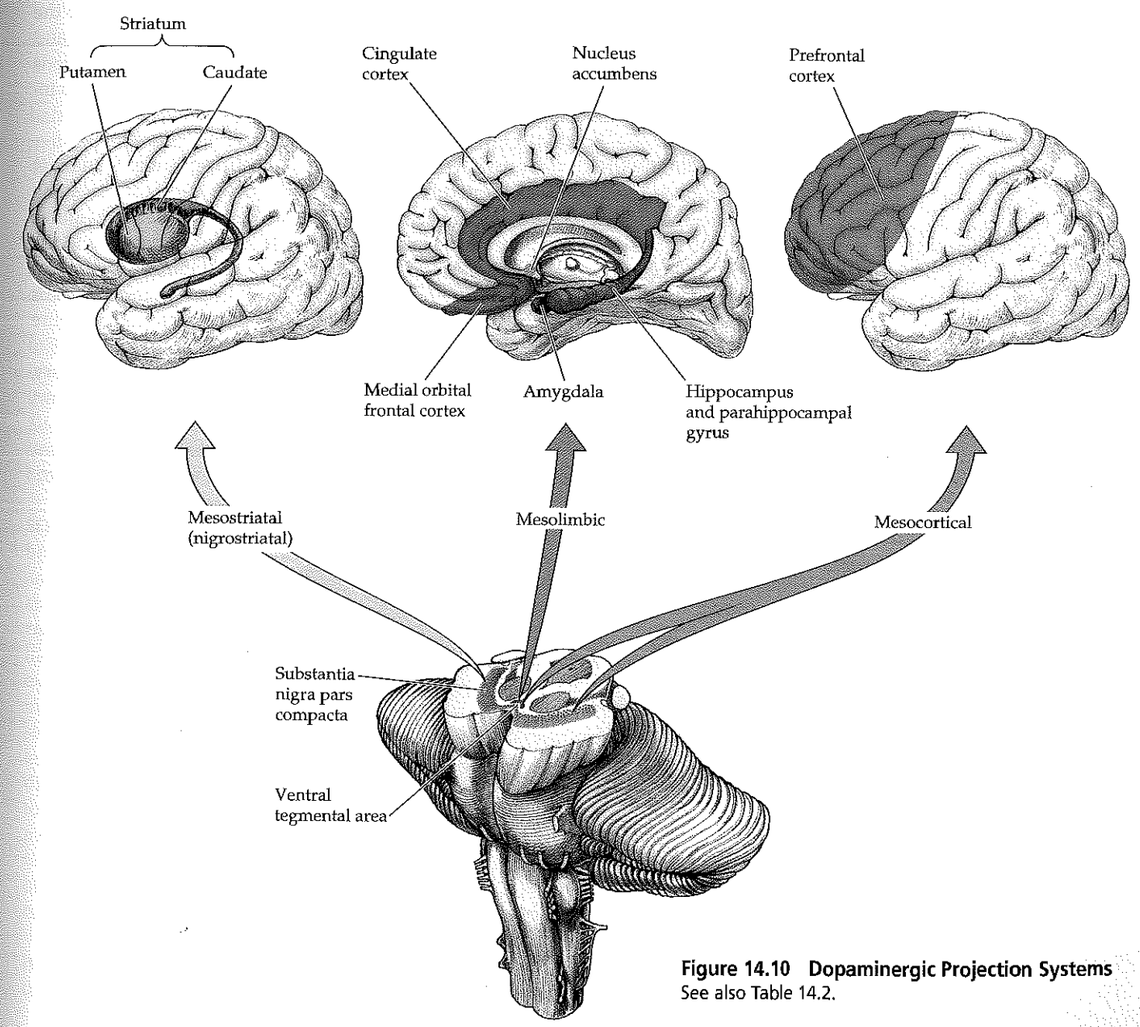

Figure 14.10 Dopaminergic Projection Systems See also Table 14.2.

pacta and projects to the caudate and putamen. Dysfunction of this pathway produces movement disorders such as Parkinson's disease, which is often treated with dopaminergic agonists (see KCC 16.2).

The **mesolimbic** pathway (see Figure 14.10) arises mainly from the ventral tegmental area and projects to limbic structures (see Chapter 18) such as the medial temporal cortex, amygdala, cingulate gyrus, and nucleus accumbens. Overactivity of the mesolimbic pathway is thought to be important in the "positive" symptoms of schizophrenia (see KCC 18.3), such as hallucinations, which often respond to dopaminergic antagonists.

Finally, the **mesocortical** pathway (see Figure 14.10) arises mainly from the ventral tegmental area (as well as from scattered dopaminergic neurons in the vicinity of the substantia nigra) and projects to the prefrontal cortex. Roles for this system have been proposed in frontal lobe functions such as working memory and attentional aspects of motor initiation (see Chapter 19). Damage to the mesocortical dopaminergic pathway may be important for some of the cognitive deficits and hypokinesia seen in Parkinson's disease (see KCC 16.2), and in the "negative" symptoms of schizophrenia (see KCC 18.3). In addition to the dopaminergic projection systems of the substantia nigra pars compacta and ventral tegmental area, dopaminergic neurons with more localized functions are found in the retina, olfactory bulbs, hypothalamus (inhibiting prolactin release; see Chapter 17), and medulla.

NOREPINEPHRINE. Neurons containing **norepinephrine** (noradrenaline) were once thought to be located exclusively in the **locus ceruleus,** meaning "blue spot," located near the fourth ventricle in the rostral pons (see Figures 14.4A, 14.11). However, noradrenergic neurons with similar projections to the locus ceruleus are also found scattered in the **lateral tegmental area** of the pons and medulla. Ascending noradrenergic projections from the locus ceruleus and rostral lateral tegmental area reach the entire forebrain (see Figure 14.11).

The effects of norepinephrine on the cortex can be inhibitory or excitatory, but effects on the thalamus are generally excitatory. Some of the better-known receptor types are listed in Table 14.2. Functions of the ascending norepinephrine projection system include modulation of attention, sleep–wake states, and mood. Attention-deficit disorder is often treated with medications that enhance noradrenergic transmission. Firing of locus ceruleus neurons increases in the awake state and decreases dramatically during sleep. However, lesions of the locus ceruleus do not cause somnolence. On the other hand, narcolepsy, a sleep disorder characterized by excessive daytime sleepiness, often responds to treatment with noradrenergic-enhancing medications. Norepinephrine appears to be important, together with serotonin, in mood disorders such as depression and manic-depressive disorder, and in anxiety disorders including obsessive-compulsive disorder (see KCC 18.3).

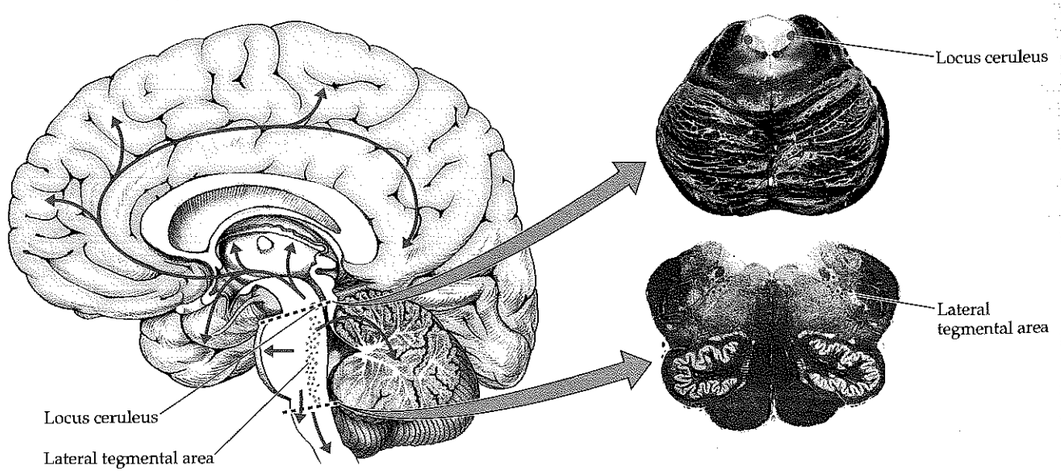

Figure 14.11 Noradrenergic Projection Systems See also Table 14.2. (Brainstem sections modified from [top] the University of Washington Digital Anatomist Project and [bottom] Martin JH. 1996. *Neuroanatomy: Text and Atlas*, 2nd Ed. McGraw-Hill, New York.)

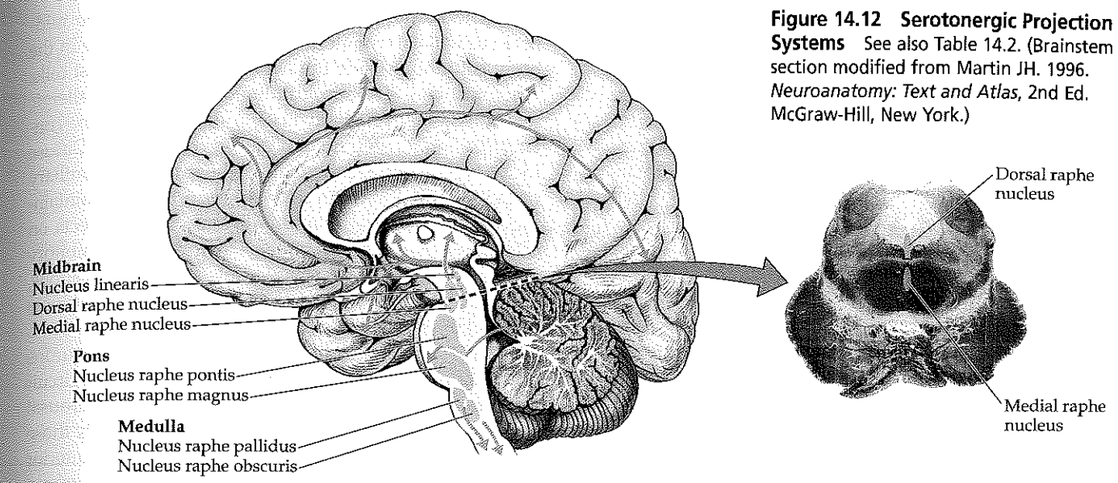

Figure 14.12 Serotonergic Projection Systems See also Table 14.2. (Brainstem section modified from Martin JH. 1996. *Neuroanatomy: Text and Atlas*, 2nd Ed. McGraw-Hill, New York.)

The locus ceruleus and lateral tegmental area also supply norepinephrine to the cerebellum, brainstem, and spinal cord. Noradrenergic neurons in the lateral tegmental area of the caudal pons and medulla are involved in sympathetic functions such as blood pressure control. In addition to norepinephrine, the related catecholamine epinephrine (adrenaline) is found in a small number of brainstem neurons. The role of these neurons has not been established, but it may also be related to blood pressure control.

SEROTONIN. **Serotonin** is found in neurons of the **raphe nuclei** of the midbrain, pons, and medulla (Figure 14.12). "Raphe" means "seam" in Greek, and it refers to the midline seamlike appearance of the brainstem in some areas where these nuclei are located (see Figures 14.3B, 14.4). The **rostral raphe nuclei** of the midbrain and rostral pons project to the entire forebrain, including the cortex, thalamus, and basal ganglia (see Figure 14.12). Both excitatory and inhibitory effects of serotonin have been described, even within the same structure. Serotonergic pathways are believed to play a role in several psychiatric syndromes (see also KCC 18.3), including depression, anxiety, obsessive-compulsive disorder, aggressive behavior, and certain eating disorders. The **caudal raphe nuclei** of the caudal pons and medulla project to the cerebellum, medulla, and spinal cord. Projections to the spinal cord and medulla are involved in pain modulation (see Figure 7.5). In addition to the raphe nuclei, a small number of serotonergic neurons have been identified in other brainstem regions, including in the area postrema and caudal locus ceruleus, and around the interpeduncular nucleus.

HISTAMINE. **Histamine** is found mainly in neurons of the posterior hypothalamus in the **tuberomammillary nucleus** (Figure 14.13), although there

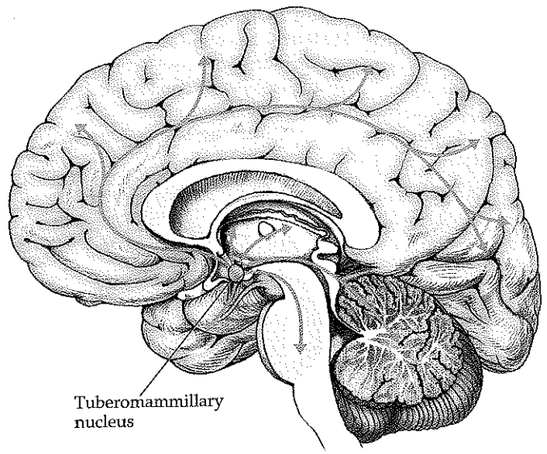

Figure 14.13 Histaminergic Projection Systems See also Table 14.2.

are some scattered histaminergic neurons in the midbrain reticular formation as well. Most histamine in the body is found outside the nervous system in mast cells, where it plays a role in immune responses and allergic reactions. Only relatively recently were histamine-containing neurons identified in the nervous system. Diffuse histaminergic projections from the tuberomammillary nucleus to the forebrain may be important to maintaining the alert state. Histamine has excitatory effects on thalamic neurons, and both excitatory and inhibitory effects on cortical neurons. Antihistamine medications, used to treat allergies, are thought to cause drowsiness by blocking CNS histamine receptors.

As we will discuss shortly, the histaminergic neurons of the tuberomammillary nucleus participate in a circuit with the hypothalamus that regulates sleep and arousal (see Figure 14.15A). Inhibitory neurons, especially those located in the ventrolateral preoptic area of the anterior hypothalamus, project to the tuberomammillary nucleus, inhibiting histamine release and promoting deep sleep.

OTHER PROJECTING SYSTEMS. In addition to the systems already listed, a variety of other neuromodulatory or projecting pathways that may play a role in alertness, mood regulation, memory, and other functions have been described or are still under investigation. These include peptides and small-molecule neurotransmitters. For example, **adenosine** is another putative neurotransmitter that may be important in mechanisms of alertness. Adenosine receptors are found in both the thalamus and the cortex, and adenosine generally has an inhibitory effect on these structures. The sources of adenosine in the nervous system have not been well characterized. Interestingly, concentrations of adenosine vary in a circadian manner, reaching a maximum just before sleep begins. One important mechanism for the increase in alertness produced by caffeine may be the blockade of adenosine receptors.

The inhibitory neurotransmitter **GABA** is found throughout the nervous system. Although well known for its role in inhibitory local interneurons, GABA also participates in long-range inhibitory projections. For example, GABAergic projection systems have been described in the basal forebrain projecting to widespread cortical areas, and in the reticular nucleus of the thalamus projecting to other thalamic nuclei, as well as to the rostral brainstem reticular formation. The functional roles of these GABAergic projection systems are still under investigation, but they may be crucial for gating information flow in the nervous system and for regulating oscillatory electrophysiological activity underlying sleep and arousal.

REVIEW EXERCISE

Cover Table 14.2 except for the leftmost column. For each widespread projection system, list the locations of the cell bodies and the main targets of their projections.

Anatomy of the Sleep–Wake Cycle

The sleep–wake cycle involves a complex interplay of neural circuits, many located in the brainstem. In adult humans, there are five stages of sleep (Figure 14.14). Normally, sleep begins with **stages 1 through 4** of progressively deeper **nonREM** (non-rapid eye movement) sleep. NonREM sleep is followed by **REM** (rapid eye movement) sleep, during which most dreaming typically occurs. The cycle then repeats several times through the night (see Figure 14.14). REM sleep is sometimes called "paradoxical sleep." This name is used because in some ways REM is a deeper stage of sleep than stage 4, while in other ways it more closely resembles the awake state. For example, general

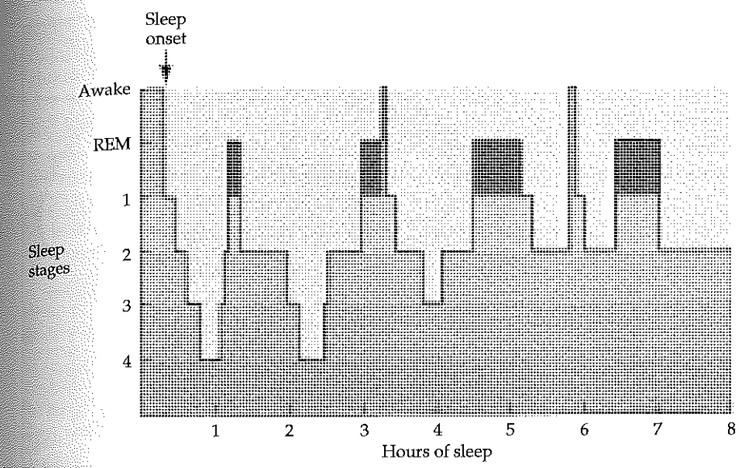

Figure 14.14 Sleep Stages Different stages of sleep can be recorded and scored based on polysomnographic monitoring of multiple physiological parameters, including EEG, extraocular movements, body movements, muscle tone, and respirations.

muscle tone and brainstem monoaminergic neurotransmission are lower during REM sleep than during any other stage. On the other hand, the electroencephalogram (EEG; see Chapter 4) during REM sleep in some ways resembles that of awake activity (a low-voltage mixture of relatively fast activity), while the EEG of stage 3 or 4 nonREM sleep more closely resembles coma (high-voltage slow activity). It is also easier to awaken an individual from REM sleep than from stage 3 or 4 of nonREM sleep.

Sleep is not, as was once thought, simply a passive process arising from decreased stimulation of the nervous system. Several neural circuits interact to generate sleep, including many of the circuits described earlier in this chapter. Interestingly, whereas classic transection experiments in cats at the midbrain level produced coma, demonstrating the importance of the reticular formation in maintaining the awake state, transection at the level of the lower pons markedly *reduced* sleep in cats. This result suggested the presence of **sleep-promoting regions in the medulla,** which have subsequently been postulated to be located in the medullary reticular formation and nucleus solitarius (Figure 14.15A).* In fact, lesions in certain regions of the medulla, as well as in the anterior hypothalamus and basal forebrain can markedly reduce sleep. These regions are especially important for promoting nonREM sleep. For example, GABAergic neurons in the **ventrolateral preoptic area** of the anterior hypothalamus and in nearby regions send inhibitory projections to histaminergic neurons in the posterior hypothalamus (see Figure 14.15A). Some of these anterior hypothalamic neurons are called **nonREM-on cells.** One mechanism by which these cells promote nonREM sleep is inhibition of histaminergic activating systems that project to the forebrain (see Figure 14.13). In addition, inhibition of histaminergic excitatory input to brainstem activating systems, such as those mediated by acetylcholine (ACh), leads to a further reduction in arousal (see Figure 14.15A).

A different set of brainstem circuits is thought to control REM sleep (see Figure 14.15B). Several classes of **REM-on cells** are located in the pontine reticular formation. Activity in **GABAergic REM-on cells** during REM sleep inhibits norepinephrine (NE) release from the locus ceruleus and lateral tegmental area, and inhibits serotonin (5-HT) release from the raphe nuclei (see Figure 14.15B). **Noradrenergic and serotonergic REM-off cells** show progressively reduced

*The precise locations of these sleep-promoting regions in the brainstem have not been confirmed electrophysiologically.

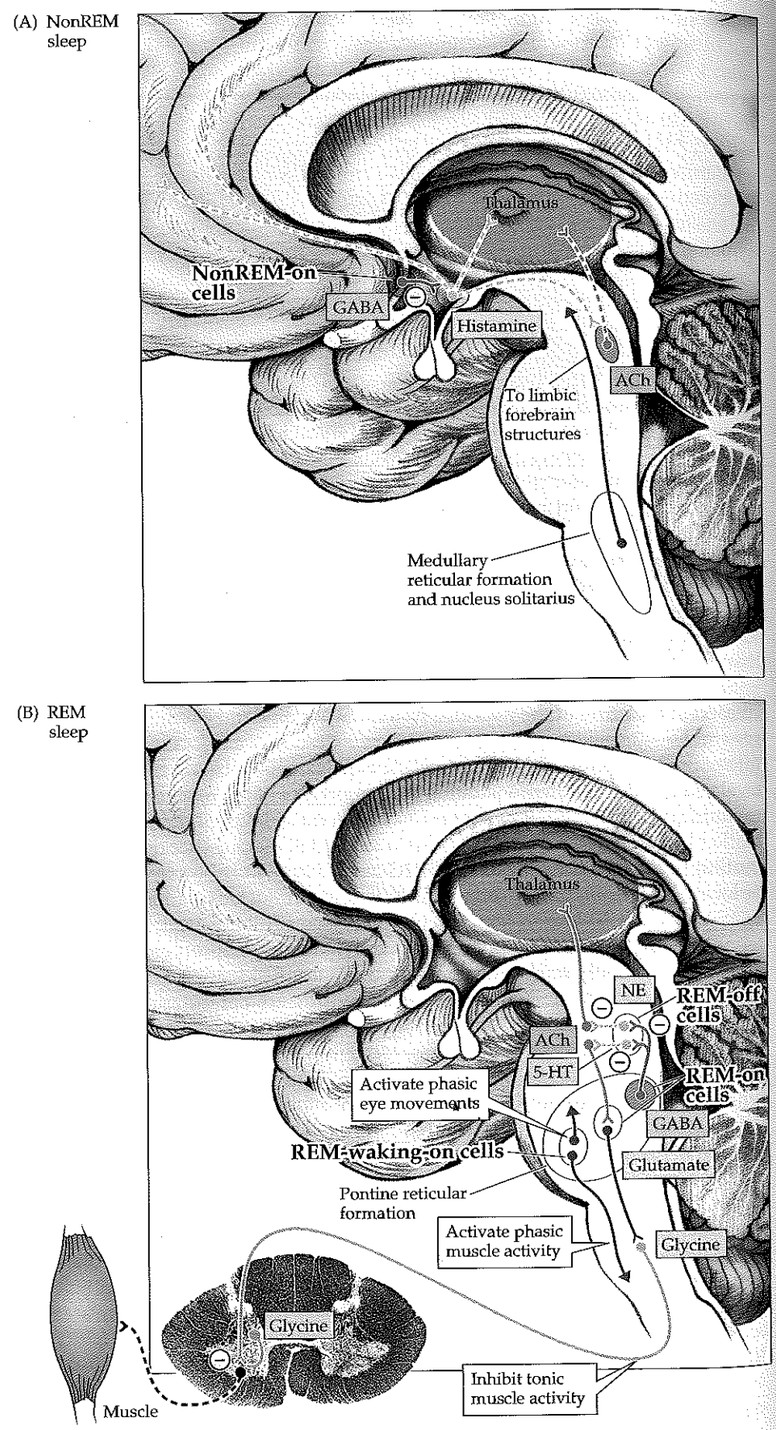

Figure 14.15 Brainstem Circuits Important for Sleep Regulation (A) During nonREM sleep, GABAergic neurons (in the ventral lateral preoptic area of the anterior hypothalamus) inhibit histaminergic neurons (in the tuberomammillary nucleus). This removes histaminergic activation from the forebrain and from brainstem cholinergic neurons (in the pedunculopontine nucleus and in the laterodorsal tegmental nucleus). Certain regions of the medulla may also play a role in nonREM sleep. (B) During REM sleep, REM-on cells and REM-waking-on cells in the pontine reticular formation interact with other brainstem circuits to activate cholinergic inputs to the thalamus, inhibit tonic muscle activity, activate phasic eye movements, and activate other phasic motor activity. (Spinal cord section modified from DeArmond SJ, Fusco MM, Maynard MD. 1989. *Structure of the Human Brain: A Photographic Atlas*, 3rd Ed. Oxford, New York.)

firing during stages 1 through 4 of nonREM sleep, and these neurons are virtually silent during REM sleep. This silence leads to removal of inhibition from cholinergic neurons in the pedunculopontine and laterodorsal tegmental nuclei, resulting in increased cholinergic transmission to the thalamus during REM sleep. These activating changes are thought to underlie the appearance in REM sleep of EEG activity closely resembling the waking state, as well as intermittent waves of activation passing from pons to thalamus to cortex called PGO (ponto-geniculo-occipital) waves.

Brainstem cholinergic neurons also activate another class of REM-on cells in the pons that markedly reduce muscle tone during REM sleep (see Figure 14.15B). These presumably **glutamatergic REM-on cells,** located in the pontine reticular formation, activate circuits involving the inhibitory transmitter glycine in the medulla and spinal cord. As a result, lower motor neurons are inhibited, causing markedly decreased muscle tone (see Figure 14.15B). Lesions or dysfunction of this system abolishes the normal inhibition of motor activity during REM sleep, resulting in complex activities during dreaming, a condition called **REM sleep behavioral disorder**. Although tonic muscle activity is inhibited during REM sleep, there are brief phasic movements during REM sleep, such as rapid eye movements (giving this sleep stage its name) and brief movements of the limbs. These phasic movements occur during the waking state as well and are activated by neurons called **REM-waking-on cells,** also located in the pontine reticular formation.

Numerous other transmitters, peptides, and humoral and endocrine factors regulate and are regulated by sleep. The suprachiasmatic nucleus of the hypothalamus (see Figure 17.3) receives retinal inputs and is crucial for setting circadian rhythms and synchronizing them with the light–dark cycle. Levels of numerous hormones fluctuate in a circadian pattern. Many naturally occurring chemicals have been investigated as potential sleep-promoting substances (e.g., adenosine, mentioned earlier in this chapter), although there is currently no agreement on which ones are the most important.

In a recent exciting series of investigations, peptides called hypocretins (or orexins) arising from cells in the lateral hypothalamus have been found to be deficient in both animals and humans that suffer from a sleep disorder called narcolepsy. **Narcolepsy** is characterized by an abnormal tendency to easily enter REM sleep directly from the waking state (compare to the normal situation in Figure 14.14), which is associated with four classic clinical findings:

1. Excessive daytime sleepiness
2. Cataplexy (sudden loss of muscle tone from the awake state, often in response to an emotional stimulus)
3. Hypnagogic (while falling asleep) or hypnopompic (while awaking) dream-like hallucinations
4. Sleep paralysis (awaking, but remaining unable to move for several minutes)

Discovery of the hypocretin/orexin peptides raises the hope that ongoing investigations will explain these phenomena in cellular and molecular terms, which may lead to improved treatments for this disorder.

REVIEW EXERCISE

Which of the following brainstem neurotransmitter systems is most strongly *in*activated during nonREM sleep? During REM sleep?

Histamine
ACh
NE
5-HT
(see Figure 14.15)

KEY CLINICAL CONCEPT

COMA AND RELATED DISORDERS

14.2 The most commonly accepted definition of **coma,** as proposed by Plum and Posner, is unarousable unresponsiveness in which the patient lies with eyes closed. Coma can perhaps be best understood if it is contrasted with various similar-appearing states, as in Table 14.3.

Brain death might be considered an extreme form of coma. As discussed in Chapter 3, brain death is defined on the basis of clinical examination demonstrating no evidence of forebrain or brainstem function, including no brainstem reflexes. When an EEG is done as a confirmatory test in brain death, it shows

TABLE 14.3 Definitions of Coma and Related States

STATE	PURPOSEFUL RESPONSES TO STIMULI?	BRAINSTEM REFLEXES	SLEEP–WAKE CYCLES OCCUR	EEG
Brain death	No	No	No	Flat (<2 microvolts)
Coma	No	Yes	No	Various fixed patterns (not flat, often slow); usually does not vary over time, including no sleep–wake cycles
Stupor, obtundation, lethargy	Yes, at times	Yes	Variable	Various patterns (not flat, often slow)
Persistent vegetative state	No	Yes	Yes	Various patterns (not flat, often slow); sleep–wake cycles occur
Akinetic mutism, abulia, catatonia	Yes, at times	Yes	Yes	Various patterns (not flat, often slow); sleep–wake cycles occur
Sleep	Yes, at times	Yes	Yes	Normal sleep patterns
Status epilepticus	Variable	Variable	Variable	Seizure activity
Locked-in syndrome	No[a]	Yes[a]	Yes	Normal EEG[b]
Dissociation, somatiform disorders	Yes, at times	Yes	Yes	Normal EEG[b]

[a] Some patients may have preserved vertical eye movements, or other slight movements under volitional control.
[b] Mild abnormalities, such as slight background slowing, may be present.

"electrocerebral inactivity," or a flat pattern, less than 2 microvolts in amplitude. Cerebral perfusion and metabolism are likewise reduced to zero in brain death. In contrast, during coma, many simple or even complex reflex activities may occur. "Unresponsiveness" in coma refers to psychologically meaningful or purposeful responses mediated by the cortex, which are absent (see Table 14.3). For example, in coma a patient may show reflex eye movements (such as the vestibulo-ocular reflex; see Chapter 3, "Coma Exam"), or may exhibit posturing (see Figure 3.5), or even intermittent stereotyped spontaneous movements. However, purposeful (as opposed to reflex) withdrawal from noxious stimuli and other responses demonstrating volition do not occur in coma.

In coma, cerebral metabolism is typically reduced by at least 50%, in agreement with the lack of significant cortical functions. The EEG (see Chapter 4) is usually abnormal in coma, but it can show many different patterns, including large-amplitude slow waves, burst-suppression, triphasic waves, spindle waves, or even alpha activity (a pattern seen in normal wakefulness). The most consistent abnormality of the EEG in coma is that it is typically monotonous, with little variability over time, unlike the normally varying EEG seen in different sleep stages (see Figure 14.14). **Sleep** differs from coma (see Table 14.3) in that patients in coma are unarousable regardless of the stimulus, and as already noted, patients in coma do not undergo cyclical variations of state as seen during sleep.

There is a wide continuum of levels of consciousness between coma and the fully awake state. A variety of more poorly defined terms—**lethargy, obtundation, stupor, semicoma,** and so on—are sometimes used to describe different states along this continuum. Although definitions for these terms exist, use of these terms alone, without further details, can be confusing to other physicians when they read the chart and try to assess the patient's progress. Therefore, as described in Chapter 3 in the section on the coma exam, it is essential to document the patient's level of alertness with a *specific statement* of what the patient did in response to particular stimuli. For example, if pressure applied to a nail bed or to the supraorbital ridge causes a patient to briefly open their eyes, moan, and push away the examiner with one hand before lapsing back into unresponsiveness, the patient is not in a coma. Documenting impaired consciousness and the specific response elicited is the most practical way to follow changes in patients of this kind. Other states along the continuum of impaired alertness, attention, and cognition, such as **delirium** (global confusional states)and **dementia,** are discussed further in Chapter 19 (see KCC 19.14–19.16).

Several weeks after an initial catastrophic brain insult causing coma, many patients emerge into a perplexing state in which they regain sleep–wake cycles and other primitive orienting responses and reflexes mediated by the brainstem and hypothalamus, but remain unconscious. This **vegetative state** can also occur in certain degenerative or congenital disorders, and if it lasts for more than one month it is called a **persistent vegetative state (PVS)** (see Table 14.3). As in coma, patients in PVS have no meaningful responses to stimuli, and they have diffuse cortical dysfunction evidenced by over 50% reduction in cerebral metabolism. However, patients in PVS do open their eyes and arouse in response to stimulation, and they may turn their eyes and heads toward auditory or tactile stimuli, presumably through brainstem-mediated pathways. Patients in PVS do not track visual stimuli, although visual tracking is often the earliest sign of recovery from PVS to a slightly milder form of brain dysfunction. Specific clinical criteria have been established for PVS by a multisociety task force (see the references at the end of this chapter for more information). Terms such as "coma vigil" or "apallic syndrome" were used in the past for PVS and similar states, but they are imprecise and are not generally used today.

Several states of profound apathy, in the extreme, can resemble coma or PVS. These include akinetic mutism, abulia, and catatonia (see Table 14.3). These disorders have in common the dysfunction of circuits involving the frontal lobes, diencephalon, and ascending dopaminergic projections (see Figure 14.10) important to the initiation of motor and cognitive activity. In **akinetic mutism,** the patient appears fully awake, and unlike patients in PVS, such patients visually track the examiner. However, they usually do not respond to any commands. Akinetic mutism can be viewed as an extreme form of **abulia,** often resulting from frontal lesions, in which patients usually sit passively but may occasionally respond to questions or commands after a long delay. In some patients, abulia or akinetic mutism can be reversed with dopaminergic agonists. Abulia is discussed further in Chapter 19 (see KCC 19.11). **Catatonia** is a similar akinetic state that can occasionally be seen in advanced cases of schizophrenia. Again, frontal-lobe and dopaminergic dysfunction have been implicated. Other, related akinetic–apathetic states include advanced parkinsonism (see KCC 16.2), severe depression, and neuroleptic malignant syndrome.

An important consideration in the differential diagnosis of coma is **status epilepticus,** meaning continuous seizure activity (see KCC 18.2). Often seizure activity is clinically obvious. However, sometimes only subtle twitching or no motor activity at all is present. Studies in which EEGs were performed indiscriminately in a series of patients in coma revealed that unrecognized status epilepticus was present in up to 20% of cases. Therefore,whenever the cause of coma cannot be found, or when there is a history of seizures, an EEG should be performed promptly so that anticonvulsant therapy can be initiated when needed.

The **locked-in syndrome** discussed in KCC 14.1 can sometimes be mistaken for coma (see Table 14.3). Unlike coma, however, these patients are conscious and may be able to communicate through vertical eye movements or eye blinks. Several **psychiatric disorders** can cause patients to appear as if in

TABLE 14.4 Some Important Causes of Coma[a]

Head trauma
Brainstem ischemia
Diffuse anoxia
Cardiopulmonary arrest
Intracranial hemorrhage
Status epilepticus (or post-ictal state)
Hydrocephalus
Diffuse cerebral edema
Drug or ethanol toxicity
Electrolyte abnormality (e.g., elevated Na^+, Ca^{2+}, Mg^{2+})
Hypoglycemia
Hypothyroidism
Hypoadrenalism
Thiamine deficiency
Hepatic failure
Renal failure
Meningitis
Encephalitis
Brain abscess
Intracranial neoplasm
End-stage neurodegenerative condition
Inborn errors of metabolism
Hereditary endogenous benzodiazepine production
Psychogenic unresponsiveness

[a]Following the format of Figure 1.1.

a coma. In addition to catatonia and severe depression, patients may be unresponsive when in a **dissociative state,** often resulting from severe emotional trauma. **Somatiform disorders** such as conversion disorder, somatization disorder, or factitious disorder can also sometimes produce states resembling coma, sometimes called "pseudocoma." Often these can be distinguished from coma by a carefully performed neurologic exam (see Chapter 3), although in some cases the diagnosis may not be obvious.

Transient loss of consciousness, as we discussed in KCC 10.3, is usually caused by cardiac or other medical conditions, and is much less commonly caused by neurological disorders such as seizures or brainstem ischemia.

Clinical Approach to the Patient in Coma

Coma is a neurologic emergency because many causes of coma are reversible if treated promptly but can cause permanent damage that becomes progressively more severe as time goes on. Some important causes of coma are listed in Table 14.4. As in any other emergency situation, the initial priorities are to ensure that there is an unobstructed **airway,** that the patient is **breathing,** and that there is normal **circulatory function.** When it is clinically appropriate, the patient should be intubated, and cardiopulmonary resuscitation initiated. Establishing prompt intravenous access is also essential. **Intravenous thiamine, dextrose,** and **naloxone** should be given immediately, even before laboratory results are obtained, because thiamine deficiency, hypoglycemia, and opiate overdose are readily treatable causes of coma. Additional doses are needed when these conditions are confirmed. Flumazenil can also be given, if benzodiazepine overdose is suspected. Next, a more detailed assessment should be performed, including history, exam, blood tests, and other diagnostic tests, to find specific treatable causes of coma.



Pupil light reflex

Much useful information can be obtained from the **neurologic exam** in the comatose patient, and this exam can usually be completed within a matter of minutes. For example, the size and responsiveness of the pupils (see neuroexam.com Video 29) can be a helpful guide to the cause of coma (Table 14.5). Although many exceptions exist, toxic and metabolic causes of coma often produce normal-sized, reactive pupils. Asymmetrically or bilaterally dilated, unresponsive ("blown") pupils can indicate midbrain compression and transtentorial herniation (see KCC 5.4). Bilateral small but responsive pupils are often seen in pontine lesions. Bilateral pinpoint pupils are seen in opiate overdose. At this point, please review the section titled "Coma Exam" in Chapter 3, as this information will be useful for the cases in this chapter (as well as in clinical practice).

Blood tests can reveal many toxic and metabolic causes of coma (see Table 14.4). Next, an **emergency head CT** should be obtained so that appropriate neurosurgical or cerebrovascular treatments can be initiated, especially when focal neurologic findings or other evidence of an intracranial lesion is present. Once the danger of herniation has been excluded by head CT, patients with coma of unknown cause should undergo a **lumbar puncture** for CSF analysis (see KCC 5.10). In addition, if the cause of coma remains unknown after this evaluation, an **EEG** should be obtained immediately so that subtle status epilepticus can be detected and treated if present.

Prognosis in coma depends on the specific cause. In diffuse anoxic brain injury, guidelines have been published by Levy and collaborators that may help predict the outcome on the basis of clinical features at various times after onset (see the References at the end of this chapter for more details). In drug overdose, patients usually recover completely, as long as vital functions are supported adequately during the period of coma. ■

TABLE 14.5 Typical Pupil Abnormalities in Coma

CAUSE OF COMA	APPEARANCE OF PUPILS
Toxic and metabolic disorders	Normal (usually)
Midbrain lesion or transtentorial herniation	Unilateral or bilateral "blown" pupil[a]
Pontine lesion	Small, responsive to light bilaterally
Opiate overdose	Pinpoint pupils bilaterally

[a]Dilated pupil, unresponsive to light.

Reticular Formation Motor, Reflex, and Autonomic Systems

In this chapter we have so far emphasized the role of the reticular formation in modulating alertness, attention, and consciousness. However, many circuits, particularly of the caudal reticular formation, serve crucial functions in motor, reflex, and autonomic function, including basic "life support" systems such as respiration and circulatory control.

Respiration involves a network of control systems acting at multiple levels. Usually, respiratory rhythms occur automatically under the control of circuits in the **medulla.** The importance of the medulla was demonstrated when animals transected at or above the pontomedullary junction continued to breathe. However, other regions of the nervous system have strong modulatory influences on the respiratory pattern. Respiratory rhythms can also be superseded temporarily by voluntary control mediated by the forebrain. Some important brainstem regions involved in respiration are shown in Figure 14.16. There are numerous inputs to respiratory circuits, including chemoreceptors for blood oxygen level and pH, many of which project to the cardiorespiratory portion of the **nucleus solitarius.** In addition, there are inputs from stretch receptors located in the lungs. The pacemaker for respiration is thought to lie in the **pre-Bötzinger complex** located in the medulla. Other nuclei in the medulla participate in respiratory rhythms, and as shown in Figure 14.16, some are active during inspiration, while others are active during expiration. Ultimately, these nuclei project to spinal cord lower motor neurons in cervical spinal segments **C3 to C5** to excite **phrenic nerve** efferents that contract the diaphragm during inspiration, or to lower motor neurons at thoracic levels controlling thoracic inspiratory and expiratory muscles.

Lesions of the medulla disrupt respiratory circuits and can cause **respiratory arrest** and death. Other abnormal respiratory patterns are sometimes seen with lesions of the central nervous system. Proceeding from caudal to rostral, lesions of the medulla that do not cause respiratory arrest can lead to an ominous pattern of very irregular breathing, called **ataxic respiration,** that may ultimately progress to respiratory arrest. Lesions of the rostral pons (in the medial parabrachial Kölliker–Fuse area located dorsal to the motor nucleus of CN V; see Figure 14.16) can cause a peculiar breathing pattern called **apneustic respiration,** in which the patient has brief 2- to 3-second pauses at full inspiration. Midbrain lesions, as well as lesions in other regions, often lead to **hyperventilation.** Finally, in **Cheyne–Stokes respiration,** breathing becomes progressively deeper with each breath, then progressively shallower with each breath to the point of apnea. The cycle then repeats, and breathing gradually becomes deeper again, in a continual crescendo–decrescendo pattern. This breathing pattern is not typically harmful in and of itself. Cheyne–Stokes respiration is usually seen in bilateral lesions at or above the level of the upper pons (including lesions of the

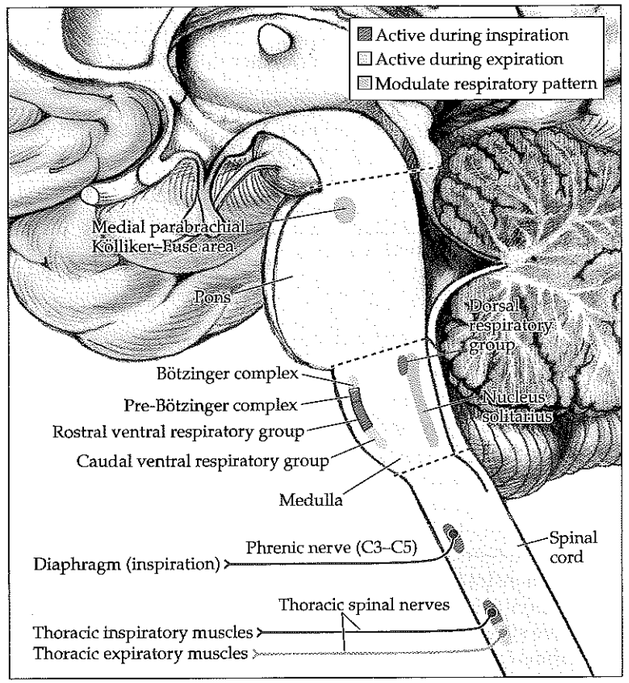

Figure 14.16 Brainstem Regions Involved in Respiratory Control

cerebral cortex), but it can also be seen in mountain climbers and in medical conditions such as cardiac failure.

Control of **heart rate and blood pressure** are likewise mediated by circuits at multiple levels in the nervous system. Inputs to the caudal **nucleus solitarius,** also known as the cardiorespiratory nucleus, are again crucial, as are circuits in the nearby medullary reticular formation. The nucleus solitarius receives inputs from baroreceptors in the carotid body and aortic arch via cranial nerves IX and X, respectively (see Figures 12.19, 12.20). Control of heart rate and blood pressure is then mediated by circuits, many of which project directly from the nucleus solitarius to parasympathetic and sympathetic preganglionic neurons in the brainstem and spinal cord (see Figure 6.13). Presympathetic neurons in the **rostral ventrolateral medulla** project to sympathetic neurons in the spinal cord intermediolateral cell column and are crucial for maintaining normal blood pressure. Interruption of this pathway causes the reduced blood pressure seen in spinal shock (see KCC 7.2). Interestingly, the cardiorespiratory portion of the nucleus solitarius also projects rostrally to the forebrain, largely via relays in the parabrachial nucleus of the rostral pons (see Figure 14.4A). Inputs from the nucleus solitarius to the **limbic system** (see Chapter 18) may, for example, be important in mediating emotional responses to altered cardiorespiratory function, and they have been postulated to play a role in triggering panic attacks. Information travels in the other direction as well, so an emotional state manifested as limbic system activity has a strong effect on autonomic function through projections to the brainstem reticular formation. This may explain, for example, why an emotional experience can cause your heart to race and your palms to sweat.

The reticular formation is involved in many complex motor tasks. Experimental animals in which the brainstem has been disconnected from higher structures can still perform numerous motor tasks, including orienting toward stimuli, maintaining posture, and even locomotion. **Motor systems arising from the brainstem,** discussed in Chapter 6, include the reticulospinal, vestibulospinal, tectospinal, and rubrospinal tracts (see Figure 6.11). In addition, the substantia nigra and pedunculopontine tegmental nucleus play important roles in basal ganglia circuits, and parts of the reticular formation are integral to cerebellar function.

Abnormal **flexor (decorticate) posturing** or **extensor (decerebrate) posturing** (see Figure 3.5) are mediated largely by brainstem circuits. Regions of the reticular formation adjacent to cranial nerve nuclei are crucial for coordinating activity and mediating reflexes involving the cranial nerves, such as the corneal reflex, eye movements, and many other activities (see Chapters 12 and 13). Behaviors such as **coughing, hiccuping, sneezing, yawning, shivering, gagging, vomiting, swallowing, laughing,** and **crying** are all heavily dependent on circuits in the pontomedullary reticular formation. Lesions of the brainstem can interfere with these behaviors or cause them to emerge abnormally. For example, patients with pontine infarcts can exhibit abnormal spontaneous shivering, lesions of the medulla can produce hiccups, and lesions of descending white matter pathways can produce abnormal spontaneous **pseudobulbar laughter and crying** (see KCC 12.8)

In the region of the **area postrema,** located along the caudal wall of the fourth ventricle in the medulla, is a region called the **chemotactic trigger zone** (see Figure 5.15). In this region, the blood–brain barrier is incomplete, allowing endogenous substances or exogenous toxins in the bloodstream to trigger **nausea and vomiting**. Nausea and vomiting can also be triggered by a circuit beginning with the release of serotonin (5-HT) from cells in the stomach and small intestine walls in response to emetic agents. 5-HT stimulates the endings of afferent fibers traveling with the vagus to reach the nucleus solitarius in the brainstem. Vagal afferents also project to the nearby area postrema. Activation of the area postrema or nucleus solitarius may also play a role in the nausea and vomiting seen in disorders of the vestibular system or cerebellum, and in elevated intracranial pressure, although the mechanisms are still under investigation.

The **pontine micturition center** and other regions of the reticular formation are involved in maintaining sphincter control (see Figure 7.11). As we discussed in Chapter 7, the **periaqueductal gray** functions together with other regions in the brainstem and spinal cord to modulate pain transmission (see Figure 7.5).

Brainstem Vascular Supply

The blood supply to the posterior fossa structures arises from the vertebrobasilar system (Figure 14.17; see also Figure 10.2). The paired **vertebral arteries** arise from the subclavian arteries at the base of the neck, and then ascend through the foramina transversaria of cervical vertebrae C6 through C2. They then take a winding course around the lateral aspect of the first cervical vertebra, before piercing the dura and entering the cranial cavity via the **foramen magnum.** The vertebral arteries run along the ventral aspect of the medulla and join at the pontomedullary junction to form a single **basilar artery** (see Figure 14.17A). The basilar artery continues rostrally, running along the ventral surface of the pons, before splitting at the pontomesencephalic junction into the two **posterior cerebral arteries,** which connect via the **posterior communicating arteries** (**Pcomm**'s) to the internal carotid arteries of the anterior circulation.

The vertebrobasilar system gives rise to multiple branches to provide the blood supply to the brainstem and cerebellum. In addition, most parts of the thalamus, as well as the inferior-medial occipital and temporal lobes, are supplied by the posterior cerebral arteries arising from the top of the basilar artery. The largest branches of the vertebrobasilar system are the **posterior inferior cerebellar artery** (**PICA**), **anterior inferior cerebellar artery** (**AICA**), **superior cerebellar artery** (**SCA**), and **posterior cerebral artery** (**PCA**) (see Figure 14.17). Note that just as there are three cerebral arteries (ACA, MCA, PCA) there are also three cerebellar arteries (PICA, AICA, SCA).

MNEMONIC

The **PICA** arises from the vertebral artery at the level of the medulla and wraps around to supply the lateral medulla and inferior cerebellum (see Figure 14.17B). The **AICA** arises from the proximal basilar artery at the level of the caudal pons, usually just after the vertebral arteries fuse, and supplies the lateral caudal pons and a small region of the cerebellum. The **SCA** arises from the top of the basilar artery at the level of the rostral pons and supplies the superior cerebellum, as well as a small region of the rostral laterodorsal pons. The **PCA** arises from the top of the basilar artery as well, just beyond the SCA. Recall that the oculomotor nerves (CN III) usually pass between the SCA and the PCA (see Figure 14.17A). The PCA wraps around the midbrain, supplying it, as well as most of the thalamus, medial occipital lobes, and inferior-medial temporal lobes. The blood supply to the cerebellum is discussed further in Chapter 15.

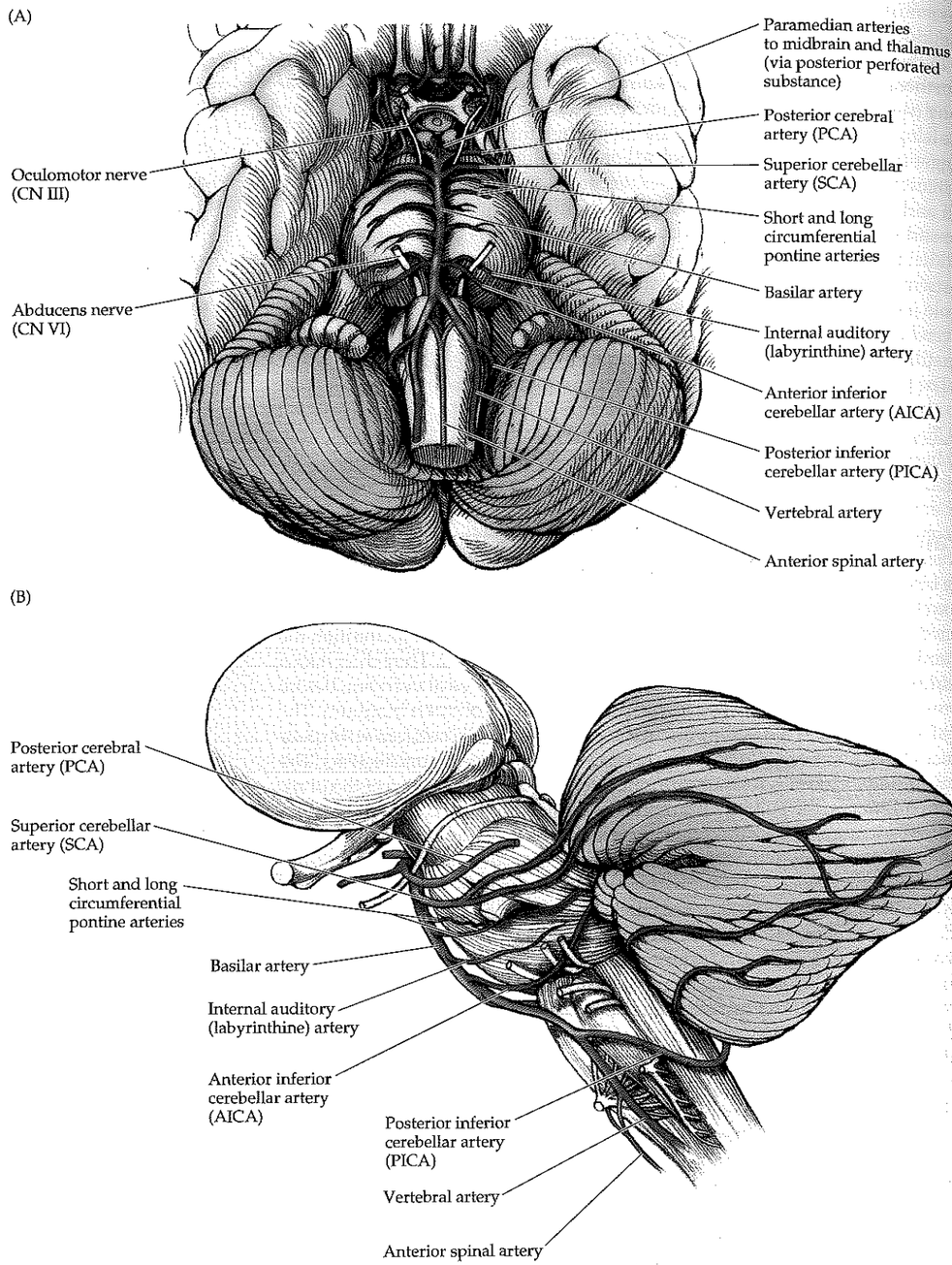

Figure 14.17 Brainstem Blood Supply
(A) Ventral view. (B) Lateral view.

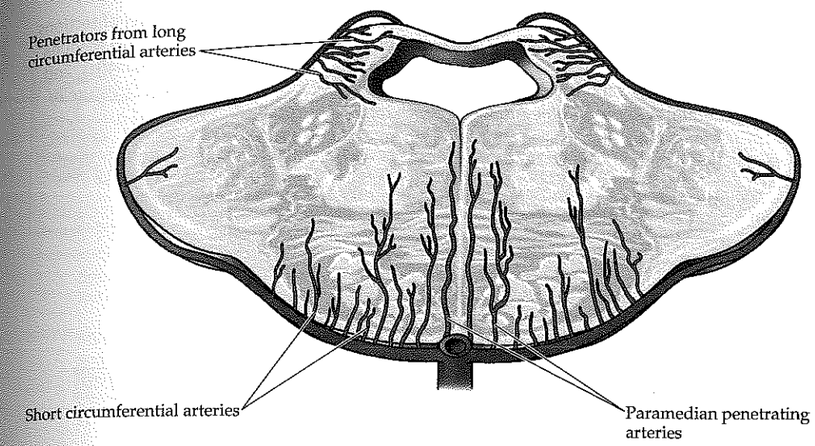

Figure 14.18 Penetrating Vessels Supplying the Internal Brainstem Structures
Penetrating vessels of the brainstem include the paramedian arteries and penetrators from short and long circumferential arteries.

Several types of smaller branches arise from these main arteries and provide the blood supply to the brainstem (Figure 14.18). **Paramedian branches** tend to respect the midline, with individual branches supplying either the right or left paramedian regions. They extend a variable distance from the ventral surface of the brainstem, with the longest branches reaching all the way to the ventricle. **Short circumferential arteries** and **long circumferential arteries** (including PICA, AICA, and so on, as well as smaller branches) give rise to penetrating branches that supply the more lateral portions of the brainstem (see Figure 14.18).

The **main vascular territories of the brainstem** are shown in Figures 14.19 and 14.20. The **medial medulla** is supplied by paramedian branches of the anterior spinal artery in more caudal regions, and by paramedian branches of the vertebral arteries in more rostral regions (see Figure 14.20D). Recall that the anterior spinal artery arises from both vertebral arteries, runs along the ventral surface of the medulla (see Figure 14.17A), and continues out of the cranial vault to supply the ventral spinal cord (see Figure 6.5). The **lateral medulla** is supplied by penetrating branches from the vertebral artery and the PICA (see Figures 14.19, 14.20D). The **medial pons** is supplied by paramedian branches of the basilar artery (see Figures 14.19, 14.20B,C). The **lateral pons** is supplied by circumferential branches of the basilar artery. In the more caudal regions, the lateral pons is supplied by the AICA (see Figures 14.19, 14.20C). The inner ear is supplied by the **internal auditory (labyrinthine) artery** (see Figure 14.17A), which usually arises as a branch of the AICA, but occasionally comes directly off the basilar artery. The more rostral lateral pons is sup-

Figure 14.19 Brainstem Vascular Territories, Surface View

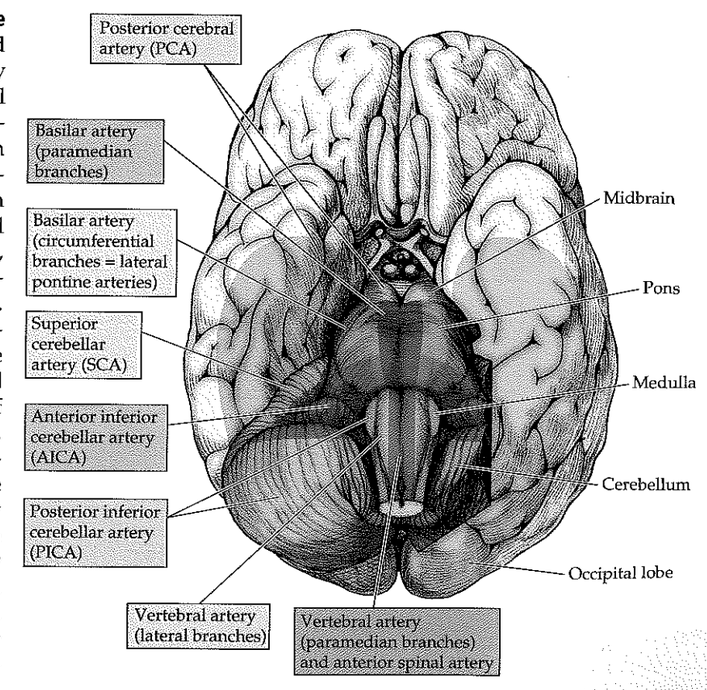

Figure 14.20 Brainstem Vascular Territories Shown in Axial Sections Level of sections shown in insets. (A) Midbrain (×3.1). (B) Rostral pons (×3.4). (C) Caudal pons (×3.5). (D) Medulla (×5.1). (Brainstem sections in A, C, D from Martin JH. 1996. *Neuroanatomy: Text and Atlas*, 2nd Ed. McGraw-Hill, New York. B from DeArmond SJ, Fusco MM, Maynard MD. 1989. *Structure of the Human Brain: A Photographic Atlas*, 3rd Ed. Oxford, New York.)

(A)

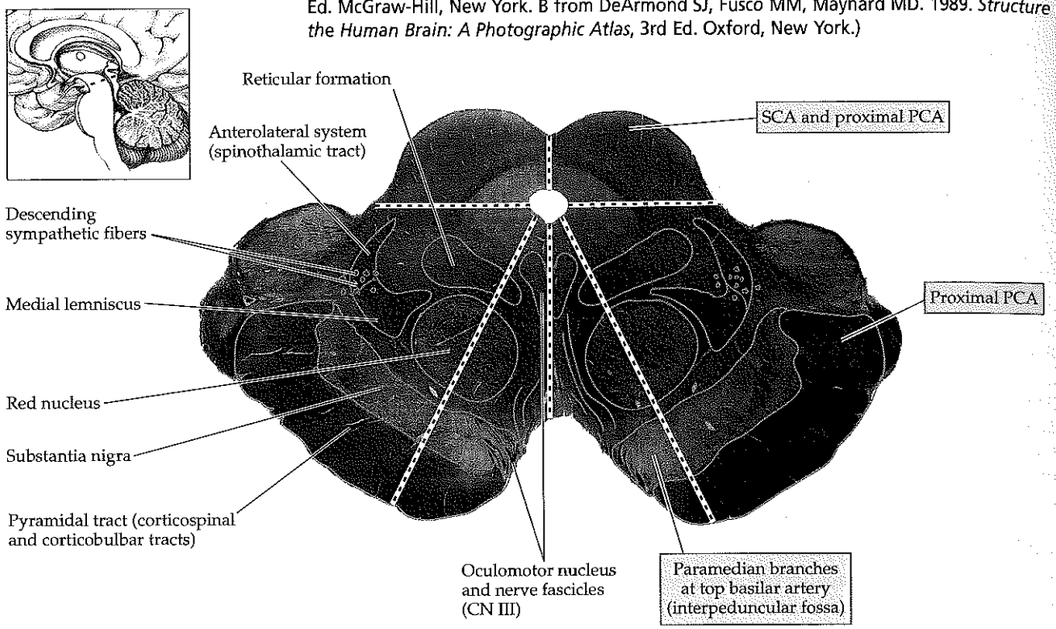

(B)

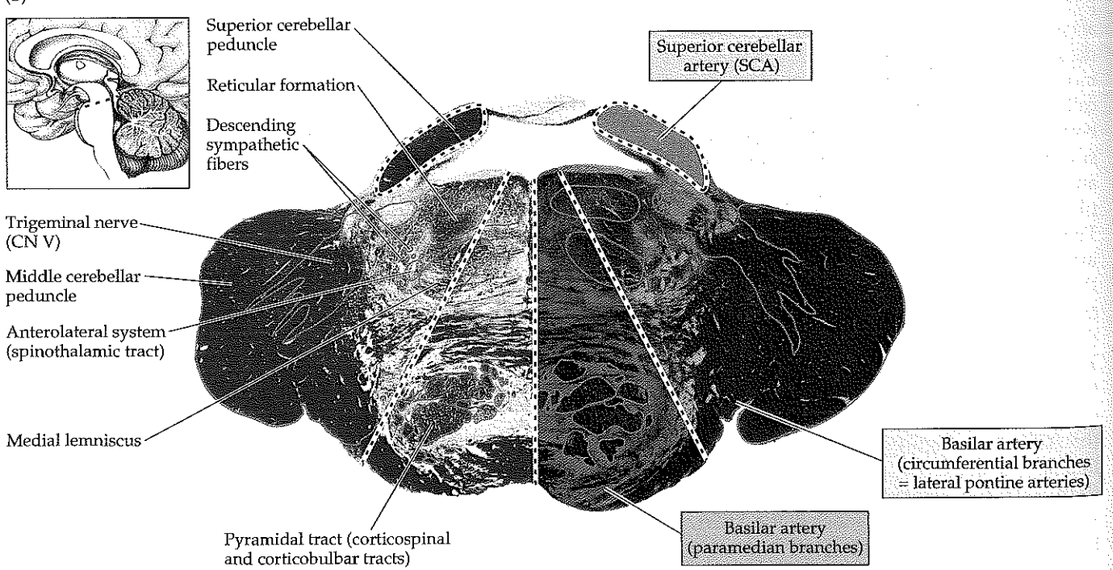

(C)

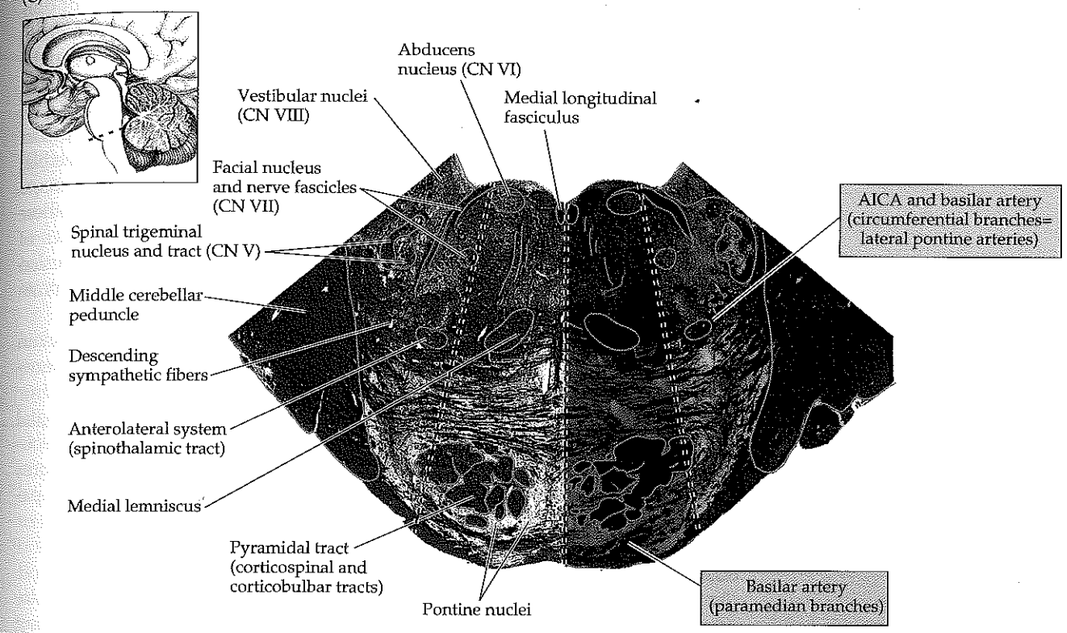

(D)

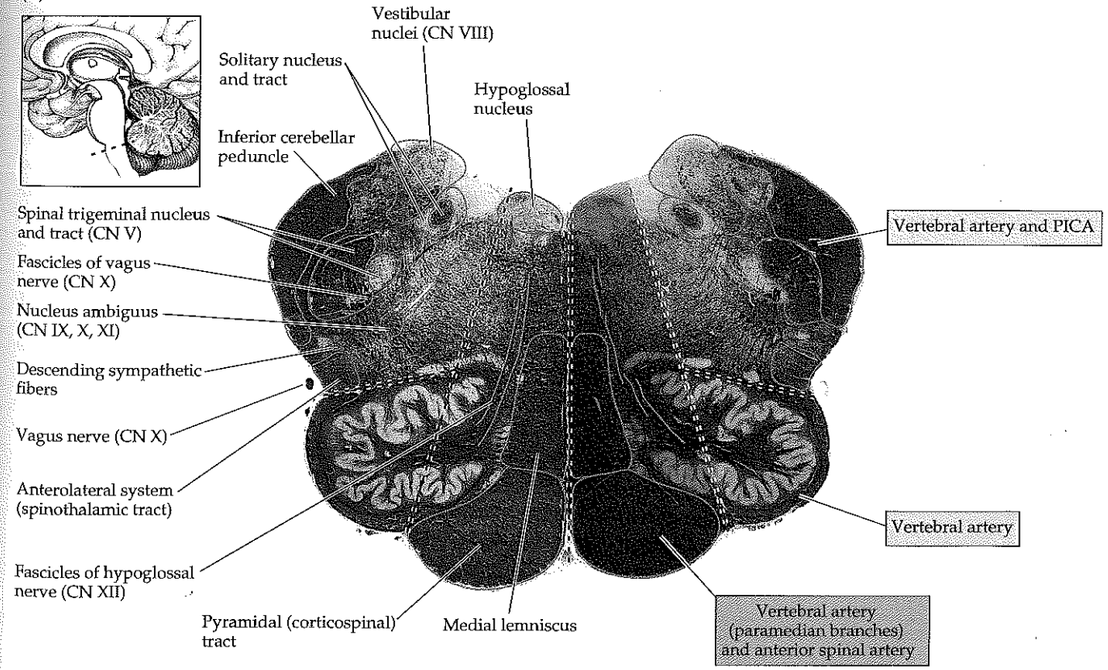

plied mainly by small circumferential branches of the basilar artery called lateral **pontine arteries.** (see Figure 14.17). A small variable region of the **superior dorsolateral pons** receives some blood supply from the SCA (see Figures 14.19, 14.20B), but this artery supplies mainly the superior cerebellum rather than the brainstem. The **midbrain** is supplied by penetrating branches arising from the top of the basilar artery and from the proximal PCAs (see Figures 14.17, 14.19, and 14.20A). Recall that arteries supplying the **thalamus** also arise mainly from the top of the basilar artery and proximal PCAs (see Figure 10.8A). Paramedian branches arising from the top of the basilar enter the interpeduncular fossa to supply the medial midbrain and thalamus (see Figure 14.17A). Sometimes these arteries bifurcate after their origin, giving rise to the so-called arteries of Percheron, which supply the bilateral medial midbrain and thalamus. Occlusion of an artery of Percheron before it bifurcates can lead to bilateral medial midbrain or thalamic infarcts.

Tables 14.7, 14.8, and 14.9 list important structures lying in each of the main brainstem vascular territories. Clinical syndromes associated with these territories will be discussed in the next section.

Because the brainstem is so essential for maintaining consciousness and vital life functions, it is crucial for the clinician to be familiar with the major vascular syndromes of the posterior circulation. We will first discuss general features of vertebrobasilar vascular disease and then review syndromes involving specific vascular territories.

KEY CLINICAL CONCEPT
VERTEBROBASILAR VASCULAR DISEASE

14.3 *General Features of Posterior Circulation Disease*

As discussed in Chapter 10, infarcts can occur by a variety of mechanisms, including **embolism**, often of cardiac origin; in situ **thrombosis,** often occurring on a nidus of preexisting atherosclerotic stenosis; and **lacunar disease,** often resulting from small-vessel occlusion in the setting of chronic hypertension. These mechanisms and the others discussed in Chapter 10 (see KCC 10.4) can all occur in the posterior circulation as well, affecting the vertebral and basilar arteries and their branches. Because the vertebrobasilar system supplies posterior fossa structures, including the brainstem, warning sigus of vertebrobasilar ischemia can be very ominous. Therefore, when patients report these symptoms, they should always be brought to immediate medical attention in an effort to avoid life-threatening brainstem infarction, coma, and death. Some common **warning signs of vertebrobasilar ischemia** are listed in Table 14.6. These warning signs can be attributed to ischemia of specific anatomical components of the brainstem (see Figure 14.1)—such as the cranial nerve nuclei and their interconnections, long sensory and motor tracts, cerebellar circuits, and the reticular activating systems—or to ischemia of the occipital lobes (PCA territory).

TABLE 14.6 Common Warning Signs of Vertebrobasilar Ischemia

SYMPTOM	ISCHEMIC STRUCTURES
Dizziness (vertigo), nausea	Vestibular nuclei, cerebellum, or inner ear
Diplopia, dysconjugate gaze	Supranuclear or infranuclear eye movement pathways (see Chapter 13)
Blurred vision, or other visual disturbances	Eye movement pathways, or visual cortex
Incoordination (ataxia)	Cerebellum or cerebellar pathways
Unsteady gait	Cerebellar pathways; long sensory or motor tracts
Dysarthria, dysphagia	Corticobulbar pathways or brainstem cranial nerve nuclei
Numbness and tingling, particularly bilateral or perioral	Long somatosensory pathways or trigeminal system
Hemiparesis, quadriparesis	Corticospinal tract
Somnolence	Pontomesencephalic reticular formation or bilateral thalami
Headache	
Occipital	Posterior fossa meninges and vessels (CN X and cervical roots)
Frontal	Supratentorial meninges and vessels (CN V; PCA is often CN V_1)
Nonlocalized	Supra- and/or infratentorial meninges and vessels

In addition to these clues from the patient's history, certain findings on neurologic examination can often help distinguish brainstem ischemia from ischemia of the cerebral hemispheres. Features strongly suggestive of **brainstem involvement** rather than hemispheric involvement include **crossed signs,** such as decreased sensation on one side of the face and contralateral body, or weakness on one side of the face and contralateral body, and **cranial nerve abnormalities,** especially those causing eye movement abnormalities, such as **dysconjugate gaze, wrong-way eyes** (see Figure 13.15), **pupillary abnormalities,** or **nystagmus** (see Chapter 13). Features strongly suggestive of **hemispheric involvement** rather than brainstem involvement include aphasia, hemineglect, hemianopia, and seizures. Note that in some situations both brainstem and hemispheric involvement can occur simultaneously, particularly when the PCAs are involved at the top of the basilar artery (see Figures 14.17, 14.19).

Once brainstem disease is suspected, certain rules of thumb can be helpful in further localizing brainstem vascular disease or other lesions to the midbrain, pons, or medulla. Signs of **midbrain dysfunction** include third-nerve palsy, unilateral or bilateral pupil dilation ataxia, flexor (decorticate) posturing, and impaired consciousness. Signs of **pontine dysfunction** include bilateral Babinski's signs, generalized weakness, perioral numbness (see Figure 12.9), "salt and pepper" (pins and needles) facial tingling, bilateral upper or lower visual loss or blurring (usually caused by impaired blood flow from the basilar artery to both PCAs), irregular or apneustic respirations (described earlier), ocular bobbing (eyes dip downward quickly and then return gradually to mid position before dipping again), shivering, palatal myoclonus (central tegmental tract; described earlier), abducens palsy or horizontal gaze palsy, bilateral small but reactive pupils (disruption of descending sympathetic fibers), extensor (decerebrate) posturing, and impaired consciousness. Signs of **medullary dysfunction** include vertigo, ataxia, nystagmus, nausea, vomiting, respiratory arrest, autonomic instability, and hiccups. Specific vascular syndromes of different brainstem regions are discussed in greater detail in the next section.

Treatment of vertebrobasilar disease is similar to treatment of ischemic stroke in the anterior circulation and depends on the mechanism of ischemia (see KCC 10.4). As with anterior circulation disease, transient ischemic attacks (TIAs) sometimes provide a warning prior to ischemic infarction (see KCC 10.3). Patients with an initial ischemic event should undergo an evaluation as described in KCC 10.4 to search for a mechanism for the ischemia. Anticoagulation therapy is used to treat thromboembolic disease caused by atrial fibrillation or mechanical cardiac valves. As discussed in KCC 10.6, **vertebral dissection,** often following minor head or neck trauma, is another important source of embolic disease, usually treated with anticoagulation. Occasionally an ectatic or fusiform basilar artery aneurysm (see Figure 5.20) can form thrombi that embolize intermittently to distal branches. Much more commonly, artherosclerotic disease causes **vertebral stenosis** or **basilar stenosis** (basilar insufficiency) resulting in tenuous waxing and waning brainstem signs that may be sensitive to changes in blood pressure. It is crucial to distinguish vertebral or basilar stenosis from evolving small vessel lacunes, which can also cause waxing and waning symptoms but do not involve stenosis of major blood vessels. To prevent life-threatening **vertebral** or **basilar thrombosis,** vertebral and basilar stenosis are often treated with anticoagulation therapy, although such therapy has not been proven effective by randomized trial. In addition, blood pressure–lowering medications should be used cautiously or avoided to prevent worsening of hypoperfusion. Systemic administration of the thrombolytic agent t-PA can improve outcome if given within 3 hours of onset of an acute stroke, although there is an increased risk of hemorrhage. Intra-arterial administration of thrombolytic agents locally at the site of the clot using interventional neuroradiological techniques has also been beneficial in the investi-

REVIEW EXERCISE

Cover the right column in Table 14.6. For each of the common symptoms of vertebrobasilar disease, list the possible structures suffering from ischemia.

gational setting. Unlike carotid stenosis (see KCC 10.5), vertebral and basilar stenosis have not been successfully treated with endarterectomy, although angioplasty has been tried experimentally with some success. Finally, as with anterior circulation stroke (see KCC 10.4), it is essential to treat the patient with a multidisciplinary approach, with careful attention to other coexisting medical conditions and potential complications, both during the acute stage and during recovery.

Specific Clinical Syndromes of the Vertebrobasilar Territory. The discussion in this section focuses on infarcts in several **specific territories of the posterior circulation** (Tables 14.7–14.9). In addition to being clinically useful, review of these vascular territories and the anatomical structures affected in each territory serves as a useful review of the regional anatomy of the brainstem, and can help consolidate knowledge acquired in this and the preceding two chapters. After discussing these focal syndromes, we will review several multifocal or bilateral brainstem syndromes, such as basilar thrombosis, top-of-the-basilar syndrome, and pontine hemorrhage.

Of all the focal brainstem vascular syndromes that we will discuss here (see Tables 14.7–14.9), only two are common: the *lateral medullary syndrome*, usually caused by vertebral thrombosis; and *medial basis pontis infarcts*, usually caused by lacunar disease. Medial medullary syndrome and SCA syndrome are less common. The other syndromes listed are relatively rare when occurring in isolation.

Proceeding from caudal to rostral, **vascular syndromes of the medulla** are listed in Table 14.7 (see Figure 14.20D). The **medial medullary syndrome** is caused by occlusion of paramedian branches of the anterior spinal or vertebral

TABLE 14.7 Focal Vascular Syndromes of the Medulla

REGION	SYNDROME NAME[a]	VASCULAR SUPPLY	ANATOMICAL STRUCTURE(S)	CLINICAL FEATURE(S)
Medial medulla (see Figure 14.20D)	Medial medullary syndrome	Paramedian branches of vertebral and anterior spinal arteries	Pyramidal tract	Contralateral arm or leg weakness
			Medial lemniscus	Contralateral decreased position and vibration sense
			Hypoglossal nucleus and exiting CN XII fascicles	Ipsilateral tongue weakness
Lateral medulla (see Figure 14.20D)	Wallenberg's syndrome (lateral medullary syndrome)	Vertebral artery (more commonly than PICA)	Inferior cerebellar peduncle, vestibular nuclei	Ipsilateral ataxia, vertigo, nystagmus, nausea
			Trigeminal nucleus and tract	Ipsilateral facial decreased pain and temperature sense
			Spinothalamic tract	Contralateral body decreased pain and temperature sense
			Descending sympathetic fibers	Ipsilateral Horner's syndrome
			Nucleus ambiguus	Hoarseness, dysphagia
			Nucleus solitarius	Ipsilateral decreased taste

[a]Eponymous names for vascular syndromes listed in Tables 14.7–14.9 (Weber's syndrome, Claude's syndrome, etc.) need not be memorized, since their exact meanings have varied historically.

arteries. Infarction of the pyramidal tract results in contralateral arm and leg upper motor neuron weakness (see Figure 6.14C). Sometimes the contralateral face is involved as well, although usually less than the arm and leg. Often, there is ipsilateral tongue weakness from infarction of the exiting CN XII fascicles or, depending on how far the infarct extends from the ventral surface of the medulla, from infarction of the hypoglossal nucleus. Also depending on how far dorsally the infarct extends, there may be contralateral decreased vibration and joint position sense caused by infarction of the medial lemniscus.

Lateral medullary syndrome, or **Wallenberg's syndrome,** is a relatively common brainstem infarct. In addition to being clinically important, this is the one syndrome that students should memorize because understanding the classic clinical features and anatomical structures involved serves as a helpful reference point for understanding all other brainstem syndromes as well. Because the syndrome affects the lateral tegmentum, motor involvement is usually not prominent and prognosis is generally good. Lateral medullary syndrome is usually caused by thrombosis rather than embolus. Vertebral thrombosis is the most common cause. Isolated involvement of the PICA is a less common cause.

The most disabling features of lateral medullary syndrome are ipsilateral ataxia caused by infarction of the inferior cerebellar peduncle, and vertigo caused by infarction of the vestibular nuclei (see Figure 14.20D). Unsteady gait, horizontal or rotatory nystagmus, nausea, and vomiting are common associated features. There is often decreased pain and temperature sensation of the ipsilateral face (spinal trigeminal nucleus and tract) and of the contralateral body (spinothalamic tract; see Figure 7.9B). In some cases, facial sensory loss is contrateral, possibly because of the involvement of crossing fibers, or sometimes ipsilateral facial paresthesias or heightened sensitivity may occur, particularly shortly after onset. Other variants include sensory loss in just the upper or lower contralateral body, probably due to only partial involvement of the spinothalamic tract. Involvement of the descending sympathetic fibers, which run in the lateral tegmentum of the brainstem near the spinothalamic tracts, causes an ipsilateral Horner's syndrome (see KCC 13.5; Figure 13.10), with ptosis, miosis, and, less commonly, anhidrosis. Infarction of the nucleus ambiguus and exiting fascicles of CN X causes breathy hoarseness and dysphagia (see KCC 12.8). The gag reflex is often decreased on the side of the lesion, and laryngoscopy shows ipsilateral vocal cord paralysis. Finally, involvement of the nucleus solitarius can occasionally be demonstrated by tests for decreased taste sensation on the ipsilateral tongue. As already noted, motor involvement is not commonly present. In some cases, however, there may be ipsilateral facial weakness, possibly due to fibers of the facial nerve that loop caudally into the medulla before exiting at the pontomedullary junction. In addition, when infarcts extend somewhat more medially and reach the pyramidal tract, contralateral hemiparesis may be present, and combined lateral and medial medullary infarcts can sometimes occur. An uncommon but interesting manifestation of lateral medullary infarcts is the loss, in some patients, of vertical orientation, making them suddenly feel as if the whole world has turned upside down or sideways.

Many clinical features of lateral medullary syndrome also occur in other lesions of the lateral brainstem tegmentum, such as AICA syndrome, and sometimes in SCA syndrome as well (see Table 14.8; Figure 14.20B,C). The presence of hoarseness or loss of taste sensation helps localize the syndrome to the medulla rather than the pons. In addition, the presence of ipsilateral hearing loss suggests AICA involvement rather than lateral medullary syndrome.

Vascular syndromes of the pons are listed in Table 14.8 (see Figure 14.20B,C). Like lateral medullary syndrome, **medial pontine syndromes** are also relatively common and clinically important. Because the paramedian pon-

TABLE 14.9 Focal Vascular Syndromes of the Midbrain[a]

REGION	SYNDROME NAME(S)[a]	VASCULAR SUPPLY	ANATOMICAL STRUCTURE(S)	CLINICAL FEATURE(S)
Midbrain basis (see Figure 14.20A)	Weber's syndrome	Branches of PCA and top of basilar artery	Oculomotor nerve fascicles	Ipsilateral third-nerve palsy
			Cerebral peduncle	Contralateral hemiparesis
Midbrain tegmentum[b] (see Figure 14.20A)	Claude's syndrome	Branches of PCA and top of basilar artery	Oculomotor nerve fascicles	Ipsilateral third-nerve palsy
			Red nucleus, superior cerebellar peduncle fibers	Contralateral ataxia
Midbrain basis and tegmentum[b] (see Figure 14.20A)	Benedikt's syndrome	Branches of PCA and top of basilar artery	Oculomotor nerve fascicles	Ipsilateral third-nerve palsy
			Cerebral peduncle	Contralateral hemiparesis
			Red nucleus, substantia nigra, superior cerebellar peduncle fibers	Contralateral ataxia, tremor, and involuntary movements

[a]Eponymous names for vascular syndromes listed in Tables 14.7–14.9 (Weber's syndrome, Claude's syndrome, etc.) need not be memorized, since their exact meanings have varied historically.
[b]More dorsal infarcts involving the midbrain reticular formation cause impaired consciousness.

REVIEW EXERCISE

Cover the labels on the left side of Figure 14.20. For each of the following brainstem regions and vascular territories, name the structures affected and the expected deficits:

14.20A: Midbrain basis and tegmentum (PCA and top-of-basilar branches) (See Table 14.9.)

14.20B,C: Medial pontine basis (paramedian branches of basilar, ventral territory) (See Table 14.8.)

14.20C: Lateral inferior pons (AICA) (See Table 14.8.)

14.20D: Medial medulla (paramedian branches of vertebral and spinal arteries) (See Table 14.7.)

14.20D: Lateral medulla (vertebral artery and PICA) (See Table 14.7.)

rostrolateral pons may also be involved, occasionally causing some features of lateral tegmental syndrome.

Vascular syndromes of the midbrain are listed in Table 14.9 (see Figure 14.20A). **Midbrain infarcts** result from the occlusion of penetrating vessels arising from the top of the basilar artery and proximal PCAs. Infarcts in this territory often occur in the setting of an embolus lodged at the top of the basilar artery (top-of-the-basilar syndrome) causing infarcts in multiple other locations as well, but midbrain infarcts can occasionally be seen in isolation. Midbrain syndromes have been described involving different regions of the basis, tegmentum, or both. Infarction of the cerebral peduncles in the midbrain basis causes contralateral hemiparesis; infarction of the third-nerve nucleus or fascicles causes an ipsilateral third-nerve palsy; and infarction of the red nucleus and fibers of the superior cerebellar peduncle (above the decussation) causes a contralateral tremor and ataxia. Larger infarcts of the midbrain that affect the midbrain reticular formation cause impaired consciousness, although when this occurs, other territories are often involved as well.

In addition to these specific territories (see Tables 14.7–14.9), posterior circulation infarcts can sometimes occur that involve multiple territories. In **basilar thrombosis,** there are often catastrophic bilateral infarctions of multiple regions of the pons and other regions supplied by the basilar artery, including the cerebellum, midbrain, thalamus, and occipital lobes. Basilar thrombosis usually results from thrombosis of a previously narrowed basilar artery in the setting of atherosclerotic disease. Patients often develop multiple cranial nerve abnormalities, long-tract signs, and coma, typically with a poor prognosis.

Top-of-the-basilar syndrome is usually caused by an embolus that lodges in the distal basilar artery, also causing infarcts of multiple vascular territories.

Clinical features include visual disturbances resulting from infarcts of the visual cortex; memory disturbances from infarcts of the bilateral medial thalami; eye movement abnormalities from infarction of the oculomotor nuclei and third-nerve fascicles in the midbrain; somnolence, delirium, or vivid visual hallucinations ("peduncular hallucinosis") caused by infarction of the midbrain reticular formation; and ataxia resulting from cerebellar infarcts. Of note, corticospinal involvement is often relatively mild in top-of-the-basilar syndrome. Sometimes, as an embolus migrates up the basilar artery toward the top, it occludes various penetrator arteries in the pons, producing a series of transient deficits referred to as the **basilar scrape syndrome.**

Another important vascular syndrome of the brainstem is **pontine hemorrhage.** This is most commonly seen in the setting of chronic hypertension causing fragility of small penetrating blood vessels (see KCC 5.6). Pontine hemorrhage usually involves the paramedian branches of the basilar artery, at the junction between the tegmentum and basis pontis. Although small hemorrhages can cause relatively mild deficits, pontine hemorrhages are often large and bilateral, resulting in catastrophic bilateral cranial nerve deficits, long-tract signs, coma, and a poor prognosis. Hemorrhage in other regions of the brainstem is relatively uncommon and is usually caused by vascular malformations rather than hypertension. ■

CLINICAL CASES

CASE 14.1 FACE AND CONTRALATERAL BODY NUMBNESS, HOARSENESS, HORNER'S SYNDROME, AND ATAXIA

CHIEF COMPLAINT

A 22-year-old woman suddenly developed left posterior neck pain, vertigo, ataxia, left facial numbness, and hoarseness after chiropractic neck manipulation.

HISTORY

The patient had been well until 4 months previously, when she injured her neck in a car accident. She saw a chiropractor daily for neck pain. On the day of admission, after her neck was "snapped," she suddenly felt increased **pain in the left posterior neck region.** As she left the chiropractor's office, she felt **dizzy and nauseated** and **staggered** out to her car, **falling toward the left.** She noticed her **vision bouncing or swaying (oscillopsia)** but had no diplopia. She vomited twice, and when she reached home her husband noticed that her **voice sounded hoarse.** She also felt a **numbness and tingling on the left side of her face.** The symptoms did not improve after a brief nap, so she came to the emergency room.

PHYSICAL EXAMINATION

Vital signs: T = 96°F, P = 60, BP = 126/84.
Neck: No bruits.
Lungs: Clear.
Heart: Regular rate with no murmurs or gallops.
Abdomen: Soft, nontender.
Extremities: Normal.
Neurologic exam:

MENTAL STATUS: Alert and oriented × 3. Normal language. Named months forward and backward with no errors. Recalled 3/3 words after 4 minutes.

CRANIAL NERVES: **Left pupil 2.5 mm, constricting to 2 mm.** Right pupil 3.5 mm, constricting to 2 mm. Visual fields full. **Right-beating horizontal and counterclockwise rotatory nystagmus,** which increased with rightward gaze. Patient reported an associated perception of the **visual field moving back and forth (oscillopsia).** Extraocular movements full. **Left ptosis. Decreased pinprick and temperature sensation in left ophthalmic, maxillary, and mandibular divisions of CN V** (Figure 14.21). **Decreased left corneal reflex.** Face symmetrical. Taste not tested. Hearing intact. **Voice hoarse. Decreased palate elevation on the left, and decreased left gag reflex.** Normal sternomastoid and trapezius strength. Tongue midline.

MOTOR: No drift. Normal tone. 5/5 power throughout.

REFLEXES:

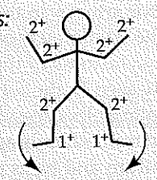

COORDINATION: **Mild ataxia on finger-to-nose testing on the left. Toe tapping on the left was irregular in rhythm (dysrhythmic).**

GAIT: Unable to stand because of severe dizziness.

SENSORY: **Decreased pinprick and temperature sensation in the right limbs and trunk below the neck** (see Figure 14.21). Intact light touch, vibration, and joint position sense.

LOCALIZATION AND DIFFERENTIAL DIAGNOSIS

1. On the basis of the symptoms and signs shown in **bold** above, where is the lesion?
2. Given the sudden onset of deficits and neck pain following neck manipulation, what is the most likely diagnosis? What are some other possibilities?

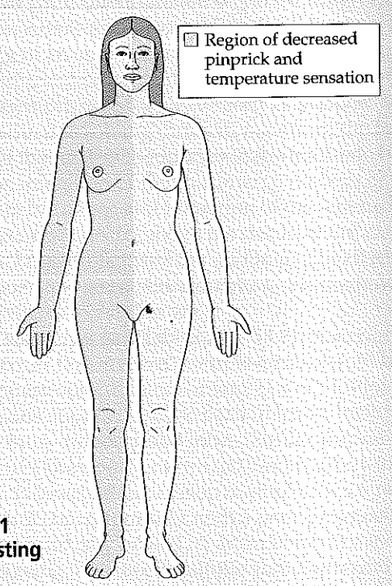

Figure 14.21 Sensory Testing

Discussion

1. The key symptoms and signs in this case are:
   - **Pain in the left posterior neck region**
   - **Unsteady gait, falling toward the left**
   - **Left ataxia and dysrhythmia**
   - **Dizziness and nausea with right-beating nystagmus**
   - **Decreased pinprick and temperature sensation in the left face**
   - **Decreased left corneal reflex**
   - **Decreased pinprick and temperature sensation in the right limbs and trunk below the neck**
   - **Left ptosis, with small, reactive left pupil**
   - **Hoarseness, with decreased palate elevation on the left and decreased left gag reflex**

   This patient had virtually all the clinical features of lateral medullary syndrome, or Wallenberg's syndrome. Review the structures in the lateral medulla involved, as well as the corresponding deficits that produce this characteristic constellation of findings (see Figure 14.20D; Table 14.7; see also Figure 7.9B).
2. Lateral medullary syndrome is usually caused by thrombosis, most often involving the vertebral artery, and less often the PICA in isolation (see KCC 14.3), resulting in a lateral medullary infarct. Given the patient's recent neck manipulation, neck pain, young age, and lack of other stroke risk factors, vertebral dissection should be strongly considered (see KCC 10.6). Other, much less likely causes of lateral medullary dysfunction in this patient include hemorrhage into a vascular malformation, abscess, or demyelinating disease.

   The most likely *clinical localization and diagnosis* is, therefore, left lateral medullary syndrome, with left lateral medullary infarct caused by left vertebral dissection.

Clinical Course and Neuroimaging 623

Initial brain CT and conventional **MRI scans** did not show an infarct (Figure 14.22A). However, diffusion-weighted MRI on the day of admission suggested left lateral medullary infarct (not shown), and this was confirmed by follow-up conventional MRI 5 days later (Figure 14.22B). An MRA performed on the day of admission showed loss of flow in the left vertebral artery. Axial T1-weighted MRI sections through the vertebral arteries demonstrated a bright region of thickening in the wall of the left vertebral artery consistent with intramural clot from a left vertebral dissection (Figure 14.22C). The patient was treated with intravenous heparin anticoagulation for a week, and then switched to Coumadin (Warfarin). On follow-up 11 days after presentation, she no longer had nausea, vertigo, or nystagmus, and she was able to walk well, with only slight leftward veering on tandem gait. She still had a left Horner's syndrome, mildly decreased pinprick sensation in the left face and right body, and trace appendicular ataxia on the left side.

CASE 14.2 HEMIPARESIS SPARING THE FACE

MINICASE

A 53-year-old man with a history of cigarette smoking and hypercholesterolemia was driving home from the airport at 7:00 A.M. one morning and had a 1-hour episode of **pins and needles in his right perioral area, arm, and leg.** He reached home, and at 10:00 A.M., while he was walking the dog, these symptoms recurred, together with **difficulty walking and clumsiness and weakness of the right arm and leg.** On exam in the emergency room, he had **decreased tone and 3/5 to 4/5 strength in the right arm and leg, an upgoing toe on the right, and decreased vibration and joint position sense in the right arm and leg.** There was only a **trace decrease in the right nasolabial fold** at rest, and his smile was symmetrical. Tongue was midline.

LOCALIZATION AND DIFFERENTIAL DIAGNOSIS

1. On the basis of the symptoms and signs shown in **bold** above, what is the most likely location for the lesion?
2. What is the most likely diagnosis?

Discussion

1. The key symptoms and signs in this case are:
   - **3/5 to 4/5 weakness of the right arm and leg with a right Babinski's sign**
   - **Trace decreased right nasolabial fold**
   - **Right body paresthesias, and decreased vibration and joint position sense**

   Right arm and leg upper motor neuron weakness sparing the face could be caused by a lesion in the left medulla or in the right cervical spinal cord (see KCC 6.3; Figure 6.14C). Similarly, paresthesias and decreased vibration and joint position sense in the right body could be caused by a lesion in the left brainstem involving the medial lemniscus (see Figure 7.9C), or in the right cervical spinal cord involving the posterior columns (see Figure 7.10E). The fact that some subtle right facial weakness was present makes the spinal cord location less likely. Since the face was nearly spared, however, the lesion is unlikely to lie above the facial nerve exit point (pontomedullary junction) because if it did, more prominent facial involvement would be expected. This leaves the medial medulla as a likely location (see Table 14.7; Figure 14.20D), involving the left corticospinal fibers in the medullary pyramid, and the left medial lemniscus. The lack of tongue motor involvement (hypoglossal nerve) is interesting, but according to the published literature on medial medullary syndrome, the tongue is involved only 50% of the time or less.

   The most likely *clinical localization* is left medial medulla, involving the pyramid and medial lemniscus, but sparing the hypoglossal nucleus and CN XII fascicles.
2. Given the patient's age, and vascular risk factors of cigarette smoking and hypercholesterolemia, the most likely diagnosis is left medial medullary infarction. This is usually caused by occlusion of paramedian branches of the vertebral or anterior spinal arteries (see KCC 14.3; Table 14.7; Figure 14.20D). The right perioral pins and needles experienced by this patient suggests some possible ischemia affecting the spinal trigeminal nucleus or trigeminothalamic fibers (see Figures 12.8, 12.9). Although this symptom is more common in pontine ischemia, it can occasionally be seen in medial medullary syndrome.

Clinical Course and Neuroimaging 625

Conventional MRI was initially negative, but diffusion-weighted MRI revealed a left medial medullary infarct (Figure 14.23). Several days later this

was visible on conventional MRI as well. The patient was admitted and treated with intravenous heparin. Workup, including MRA, echocardiogram, and a Holter monitor, did not reveal an obvious embolic source (see KCC 10.4). However, an MRA revealed an irregular region of signal loss in the distal left vertebral artery, just prior to the vertebrobasilar junction. Because of the possibility of vertebral dissection (see KCC 10.6) or vertebral stenosis (see KCC 14.3), a conventional vertebral angiogram was done. The angiogram confirmed occlusion of the distal left vertebral artery just beyond the left PICA takeoff point but did not reveal a dissection. This suggests that the patient's medial medullary infarct was caused by occlusion of paramedian vessels arising from the distal left vertebral artery (see Figure 14.20D). The vertebral occlusion may have been embolic from an unknown source, or could have been caused by thrombosis superimposed on a stenosed atherosclerotic vertebral artery. The patient was switched from intravenous heparin anticoagulation to oral anticoagulation with Coumadin. His weakness gradually improved, and he was discharged to an inpatient rehabilitation facility to continue his recovery.

CASE 14.1 FACE AND CONTRALATERAL BODY NUMBNESS, HOARSENESS, HORNER'S SYNDROME, AND ATAXIA

Figure 14.22 Left Laterally Medullary Infarct Caused by Vertebral Dissection Axial MRI images of the brain and cervical spine. (A) T2-weighted MRI done on admission does not show infarct, but does show absence of the flow void in the left vertebral artery. (B) Follow-up T2-weighted MRI done 5 days after admission shows increased signal in the left lateral medulla compatible with infarction (compare to Figure 14.20D). (C) T1-weighted images of the neck done on the day of admission show the left vertebral artery to have a thickened wall with a bright appearance compatible with dissection and coagulation of blood in the wall of the left vertebral artery (see Table 4.4).

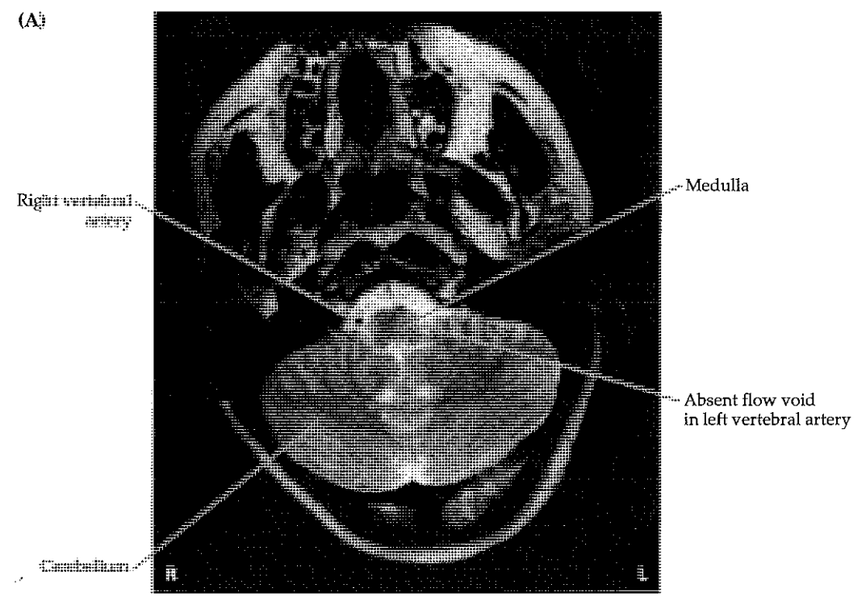

CASE 14.1 *(CONTINUED)*

(B)

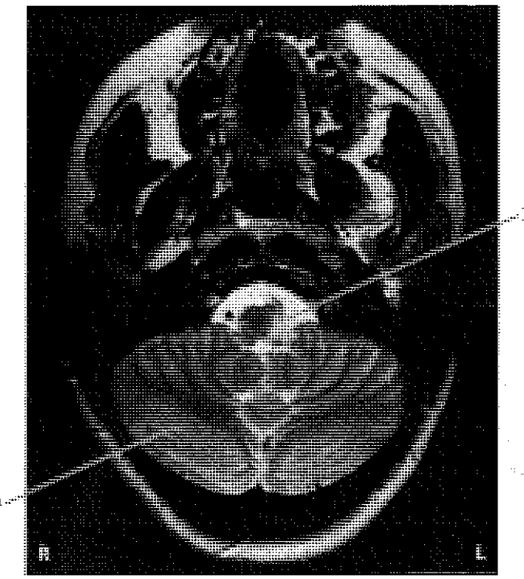

(C)



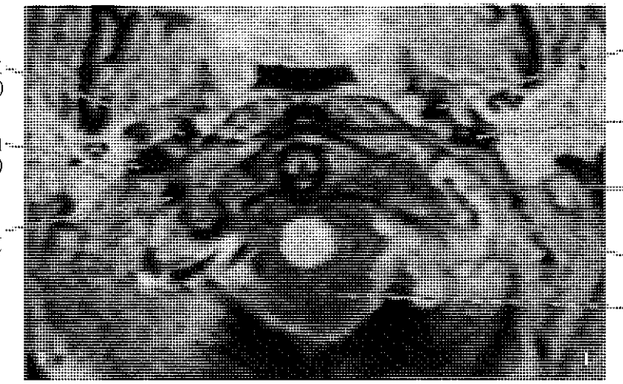

CASE 14.2 HEMIPARESIS SPARING THE FACE

Figure 14.23 Left Medial Medullary Infarct Diffusion-weighted MRI images of the brain. (A) Axial section through the medulla. (B) Coronal section.

(A)

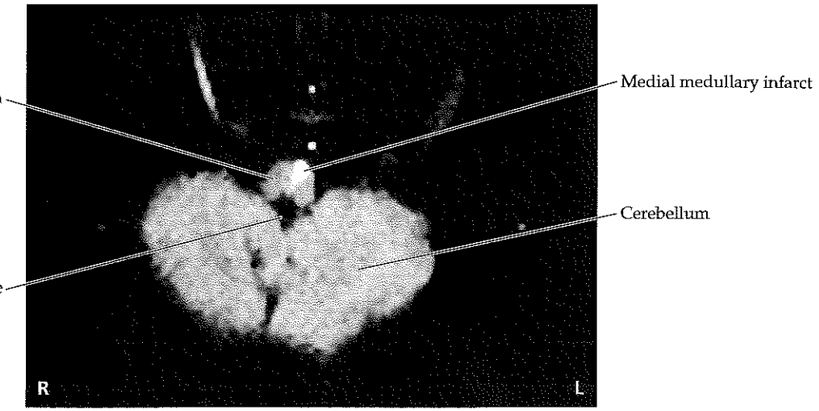

(B)

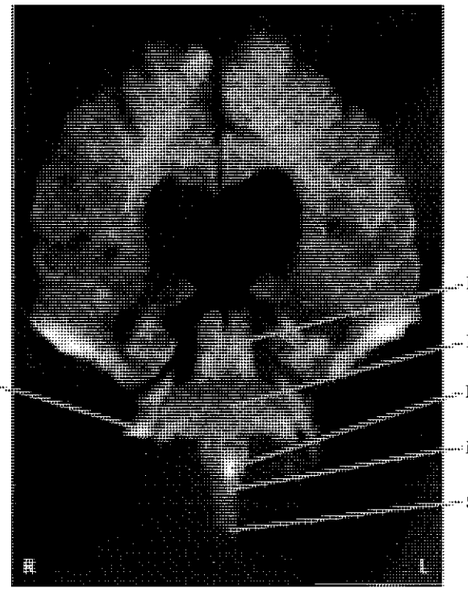

CASE 14.3 DYSARTHRIA AND HEMIPARESIS*

MINICASE

A 74-year-old woman with a history of hypertension and atrial fibrillation had acute onset one morning of **slurred speech and right-sided weakness.** On exam she had **right facial weakness sparing the forehead, dysarthric speech, decreased palate elevation on the right, and tongue deviation to the right.** In addition, **her right arm and leg had decreased tone and 0/5 to 2/5 weakness, and she had increased reflexes on the right and a right Babinski's sign.**

LOCALIZATION AND DIFFERENTIAL DIAGNOSIS

1. On the basis of the symptoms and signs shown in **bold** above, what is the most likely location for the lesion?
2. What is the most likely diagnosis?

*This case appears earlier in the book as Case 6.5.

Discussion

1. The key symptoms and signs in this case are:
   - **Right face, arm, and leg weakness; hyperreflexia; and Babinski's sign**
   - **Dysarthria, decreased right palate elevation, and rightward tongue deviation**

   This patient has dysarthria hemiparesis, or pure motor hemiparesis (see KCC 6.3; Figure 6.14A). The most common localizations for this are the posterior limb of the internal capsule on the left side (see Table 10.3; Case 10.7), or the left basis pontis, involving the corticospinal and corticobulbar tracts (see Table 14.8; Figure 14.20B,C).
2. Given the patient's age and vascular risk factors of hypertension and atrial fibrillation, the most likely diagnosis is infarct in the left internal capsule or left basis pontis.

Clinical Course and Neuroimaging 631

An **MRI of the brain** revealed an infarct in the left basis pontis (Figure 14.24). MRA of the head and neck showed normal flow in the basilar artery and other vessels. The patient was admitted to the hospital, and because of her history of atrial fibrillation, she was anticoagulated with heparin and then switched to Coumadin. She was evaluated and treated by speech therapy for problems with speech and swallowing, and by physical and occupational therapy for her hemiparesis. At 2 weeks after onset she had continued dysarthria and hemiparesis, but she was able to lift her right arm and leg off the bed (3/5 strength). Compare this case to Case 13.7.

CASE 14.4 UNILATERAL FACE NUMBNESS, HEARING LOSS, AND ATAXIA

CHIEF COMPLAINT

A 56-year-old male auto mechanic had 1 month of episodic diplopia and unsteadiness, and then suddenly developed persistent right face numbness, hearing loss, and right-sided clumsiness.

HISTORY

Past history was notable for severely elevated cholesterol and cigarette smoking. About 1 month prior to admission, the patient developed **transient episodes** consisting of **light-headedness, nausea, unsteadiness "staggering like I was drunk," diagonal diplopia with the right image higher than the left, perioral numbness, and a generalized headache.** The episodes were precipitated by his standing up and walking around, lasted 5 or 6 minutes, and occurred up to four or five times per day. The episodes gradually improved over time and nearly stopped.

INITIAL LOCALIZATION, DIFFERENTIAL DIAGNOSIS, AND MANAGEMENT

1. On the basis of the symptoms shown in **bold** above, what general brain region is most likely involved?
2. Given this patient's history, what diagnosis should be seriously considered, and what should be done?

Discussion

1. The symptoms are strongly suggestive of brainstem dysfunction, possibly localized to the pons (see KCC 14.3; Table 14.6). Review each of this patient's symptoms and their localization in Table 14.6.
2. Given the patient's vascular risk factors and the fact that the episodes occur in situations that may lower the patient's systemic blood pressure (standing up), the most likely diagnosis is TIAs in the vertebrobasilar system, possibly caused by basilar stenosis. This is a potentially life-threatening situation, and the patient should be brought to immediate medical attention. An MRA should be performed and anticoagulation considered if a significant stenosis is found.

CASE 14.4 *(CONTINUED)*

HISTORY, CONTINUED

The patient did not seek medical attention for his symptoms. On a Friday night 3 days prior to admission, the patient abruptly developed **right facial numbness, decreased hearing in the right ear, slurred speech, right hand clumsiness (occasionally dropping things), and unsteady gait.** When he returned to work at the garage on Monday, he had trouble working on the cars, so he finally came to the emergency room.

PHYSICAL EXAMINATION

Vital signs: T = 96.7°F, R = 14.
Orthostatic testing:
SUPINE: P = 80, BP = 130/80.
STANDING: P = 88, BP = 122/76.
Neck: Supple with no bruits.
Lungs: Clear.
Heart: Regular rate with no murmurs.
Abdomen: Soft, nontender; normal bowel sounds.
Extremities: Normal.
Neurologic exam:
MENTAL STATUS: Alert and oriented ×3. Naming and repetition intact. Mildly decreased attention; for example, skipped November when naming months backward. Recalled 1/3 words after 5 minutes, but got 3/3 with prompting.
CRANIAL NERVES: Pupils 4 mm, constricting to 2.5 mm bilaterally. Fundi normal. Extraocular movements full, with fine **horizontal nystagmus** (direction of fast phase was not specified). **Light touch and pinprick sensation slightly decreased in right V_2 and V_3 distribution. Right corneal reflex decreased.** Face symmetrical. **Hearing decreased on the right. On the Weber test** (see KCC 12.5) **sounds were louder on the left. Speech slightly slurred.** Normal palate elevation. Shoulder shrug and sternomastoids normal. Tongue midline.
MOTOR: No drift. Normal tone. 5/5 power throughout.
REFLEXES:

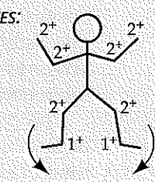

COORDINATION: **Mild dysmetria on finger-to-nose testing on the right. Right finger tapping and foot tapping were slightly slow and dysrhythmic.**
GAIT: **Slightly wide based. Able to do only two or three steps of tandem gait because of unsteadiness.** When the patient stood or walked during the exam, he did not have symptoms of the transient episodes described above.
SENSORY: Intact light touch, pinprick, vibration, and joint position sense.

LOCALIZATION AND DIFFERENTIAL DIAGNOSIS

1. On the basis of the symptoms and signs shown in **bold** above, what is the most likely location for the lesion? Which blood vessel(s) may be involved?
2. What is the most likely diagnosis?

Discussion

1. The key symptoms and signs in this case are:
   - **Decreased hearing in the right ear, with Weber test also eliciting decreased right hearing**
   - **Light touch and pinprick sensation slightly decreased in right V_2 and V_3 distribution, with decreased right corneal reflex**

- **Right dysmetria and dysrhythmia, with slurred speech, horizontal nystagmus, and unsteady, wide-based gait**

The patient has findings compatible with a right lateral caudal pontine syndrome, most likely caused by a right AICA infarct (see Table 14.8; Figure 14.20C). Decreased hearing of sensorineural origin based on the Weber test (see KCC 12.5; neuroexam.com Video 42) may be due to involvement of the labyrinthine artery (see Figure 14.17A); impaired right facial sensation may be due to infarction of the right trigeminal nucleus and tract; and right-sided appendicular ataxia, gait ataxia, slurred speech, and nystagmus may be caused by involvement of the right middle cerebellar peduncle and vestibular nuclei (see Figure 14.20C). The patient also had mildly decreased attention, which is a nonspecific finding that could have many causes, including brainstem ischemia (see KCC 19.14).

The most likely *clinical localization* is right caudal lateral pons, AICA territory.

2. The patient's vascular risk factors and antecedent episodes of transient symptoms make infarction in the right AICA territory the most likely diagnosis.

Clinical Course and Neuroimaging 631

An **MRI** revealed an infarct in the right lateral caudal pons in the territory of the AICA (Figure 14.25A; see also Figure 14.20C). An MRA showed a striking lack of flow in the entire vertebrobasilar system (see Figure 14.25B). This finding suggests that the patient most likely had long-standing disease of the posterior circulation, and that he developed collateral flow through vessels not visible on the MRA to supply his brainstem. In this tenuous situation, artery-to-artery embolus or thrombosus of the AICA could have caused infarction in the right AICA territory.

The patient was admitted to the hospital and treated with intravenous heparin anticoagulation, and then switched to Coumadin. After 5 days, at the time of discharge, he had no nystagmus, his right hearing was improved, facial sensation was normal except for a small area around the right side of his mouth, (see Figure 12.9) he was able to perform tandem gait, and the right arm and leg ataxia was improved but not completely gone. In addition, his inattention (possibly reflecting poor flow in the vertebrobasilar system) had returned to normal.

Five days later he returned to the emergency room with nausea causing decreased eating and drinking, and he had recurrent symptoms of lightheadedness when standing, without other symptoms. Exam was unchanged, except that on orthostatic testing his pulse and blood pressure, respectively, went from 76 and 147/98 supine, to 110 and 124/98 standing (an increase in heart rate of greater than 10 beats per minute, or a decrease in systolic blood pressure of greater than 10 mm Hg is considered abnormal). Blood tests confirmed that his Coumadin anticoagulation was adequate, and there was no evidence of bleeding as the cause of orthostasis, so he was admitted for intravenous hydration and observation. Again he did well, gradually tolerated the upright position better, and was discharged. He quit smoking, started taking daily walks, began a low-cholesterol diet, and later began taking a cholesterol-lowering drug. At follow-up 1 month and again 4 months later, he was without symptoms, and exam was normal except for decreased pinprick sensation in a small area around the right lip and trace dysrhythmia of right finger and toe tapping.

CASE 14.5 LOCKED IN

MINICASE

A 52-year-old woman with a history of Crohn's disease was walking in a mall and suddenly had to sit down because she felt sweaty and the left side of her face felt "funny." Her husband noticed a **"lazy eye" on the left.** She was taken to an outside hospital, where on initial exam she had **slurred speech** with good comprehension. She also had **weakness and decreased sensation of the left face, arm, and leg,** and she was **ataxic** (side not specified). She was admitted to the hospital, but because of concerns about increased bleeding risk with Crohn's disease, she was not anticoagulated.

INITIAL LOCALIZATION AND DIFFERENTIAL DIAGNOSIS

On the basis of the symptoms and signs shown in **bold** above, what is the most likely general location for the lesion? Given this patient's history, what diagnosis should be seriously considered?

Discussion

The symptoms are strongly suggestive of brainstem dysfunction, possibly from vertebrobasilar disease (see KCC 14.3; Table 14.6). Review the localization of each of these symptoms in Table 14.6. Of note, inflammatory bowel disease can sometimes cause hypercoagulability, so incipient thrombosis in the vetebrobasilar system should be strongly considered.

CASE 14.5 *(CONTINUED)*

HISTORY, CONTINUED

That evening at 9:00 P.M., the patient suddenly had a **respiratory arrest** requiring intubation, and she was found to have decerebrate posturing (see Figure 3.4B). The next morning she was transferred to a tertiary care center. On exam, she was intubated and unable to move her extremities, but she was awake and **able to answer yes/no questions appropriately by using eye blinks or vertical eye movements.** She had **no horizontal eye movements, even with oculocephalic maneuvers,** but she did have voluntary vertical eye movements. She also had **ocular bobbing** (fast phase down, slow phase up), **and a skew deviation, with the left eye higher than the right.** There was **no movement of the limbs** in response to commands. In response to pain, **the left arm did not move, the right arm had extensor (decerebrate) posturing, and both legs had triple flexion** (see Figure 3.4C). **Reflexes were absent, and both toes were upgoing.**

LOCALIZATION AND DIFFERENTIAL DIAGNOSIS

1. On the basis of the symptoms and signs shown in **bold** above, what is the most likely localization?
2. What is the most likely cause, and what are some other possibilities? What is the name of this clinical syndrome?

Discussion

1. The key symptoms and signs in this case are:
   - **Respiratory arrest**
   - **No horizontal eye movements**
   - **Ocular bobbing and a skew deviation**
   - **Ability to answer yes/no questions appropriately using eye blinks or vertical eye movements**
   - **No voluntary movements, with only decerebrate posturing, triple flexion, and bilateral Babinski's signs**

Onset with respiratory arrest suggests possible medullary involvement (see Figure 14.16). The other findings—including lack of horizontal eye movements, ocular bobbing, skew deviation, and bilateral upper motor neuron–type paralysis with extensor posturing—all suggest extensive bilateral involvement of the pons (see KCC 14.3; Figure 14.20B,C). The fact that consciousness and vertical eye movement were preserved suggests that the midbrain was spared.

2. This clinical picture is compatible with locked-in syndrome (see KCC 14.1) caused by extensive bilateral pontine and possibly medullary infarcts, sparing the midbrain.

Clinical Course and Neuroimaging 634

An **MRI** revealed massive bilateral infarcts of the pons, extending down to the medulla (Figure 14.26A, B). The midbrain (including the midbrain reticular formation) was not involved (see Figure 14.26C). An MRA showed absent flow in the vertebrobasilar system similar to that exhibited by the patient in Case 14.4 (see Figure 14.25B). The lack of vertebrobasilar flow suggests that this patient had developed a basilar artery thrombosis, but that unlike the patient in Case 14.4, she did not have sufficient collateral flow to supply much of her brainstem. She was treated with intravenous heparin but made no significant improvements during her hospitalization. Eventually, her left arm also developed decerebrate posturing. The patient and family decided to continue the mechanical ventilator; however, they requested no resuscitation in the event of cardiac arrest. A speech therapist worked with the patient to facilitate communications using picture and letter cards and other devices, and she remained able to communicate, but unable to move except for looking up and down or blinking (levator palpebrae superior). She developed several infections that were treated with antibiotics, and when last seen, two and a half months after onset, her exam remained unchanged.

Related Cases. Locked-in syndrome (see KCC 14.1) is usually caused by bilateral ventral pontine lesions, but rarely it can be caused by lesions in other locations. For example, Figure 14.27 shows an MRI scan from a 56-year-old mathematics professor who suddenly became unable to move. Unlike the patient described above, he had preserved horizontal as well as vertical eye movements. MRA showed absent flow in the upper basilar artery, and MRI demonstrated bilateral infarction of the cerebral peduncles (see Figure 14.27C). The midbrain tegmentum and the pons were largely spared, explaining his preserved consciousness and ability to make both vertical and horizontal eye movements. He remained in a locked-in state, communicating with eye movements only, for the next year and a half and eventually succumbed to an overwhelming pulmonary infection.

Atherosclerotic basilar stenosis with superimposed basilar thrombosis is a life-threatening neurologic emergency requiring prompt treatment. The two cases of locked-in patients described here, as well as other cases in this chapter, demonstrating the potentially dire consequences of basilar insufficiency. Figure 14.28 shows a pathology specimen from a patient who died of basilar thrombosis. This patient was a 67-year-old man who, over 2 days, gradually became sedated, weak, and quadriplegic, eventually lapsing into coma with no eye movements. An MRI showed massive infarction of the pons, midbrain (including the reticular formation), thalamus, and cerebellum (all supplied by the basilar artery; see Figures 14.17, 14.19). Postmortem examination revealed severe atherosclerotic narrowing of the basilar artery (see Figure 14.28), with superimposed thrombus.

CASE 14.3 DYSARTHRIA AND HEMIPARESIS

Figure 14.24 Left Basis Pontis Infarct Axial T2-weighted MRI image through the pons.

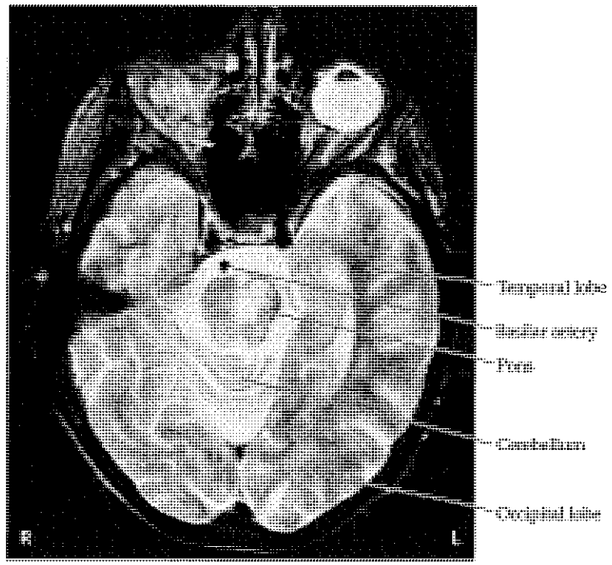

CASE 14.4 UNILATERAL FACE NUMBNESS, HEARING LOSS, AND ATAXIA

Figure 14.25 Right AICA Infarct and Basilar Insufficiency (A) Axial T2-weighted MRI image through the pons demonstrating increased signal in the right dorsolateral pons and middle cerebellar peduncle, compatible with right anterior inferior cerebellar artery (AICA) infarct (compare to Figure 14.20C). (B) MRA demonstrating absence of visible flow in the vertebral or basilar arteries. This suggests severe narrowing of the basilar artery.

(A)

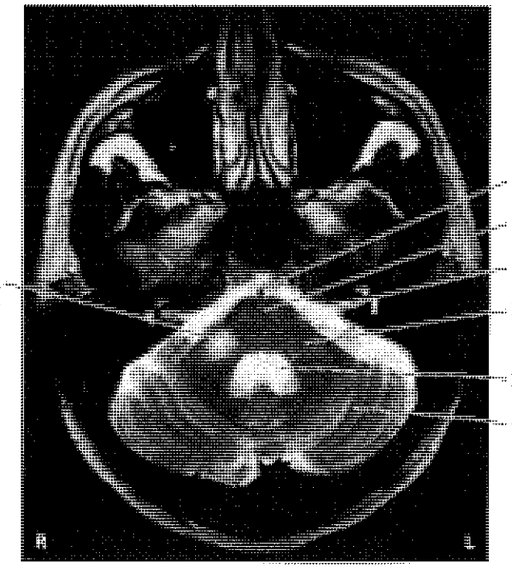

CASE 14.4 *(CONTINUED)*

(B)

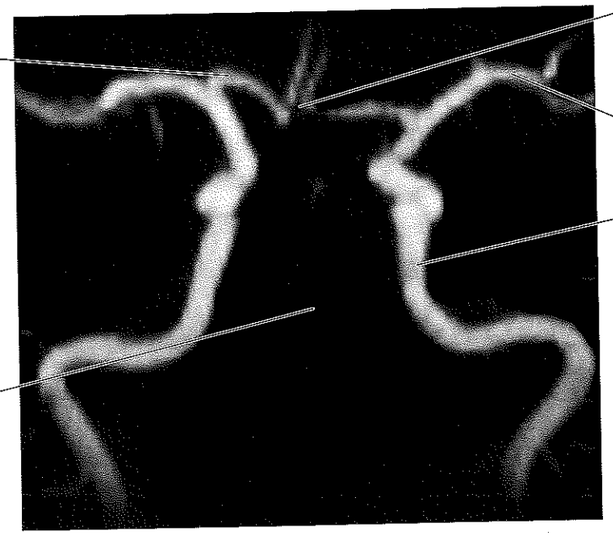

CASE 14.6 WRONG-WAY EYES, LIMITED UPGAZE, DECREASED RESPONSIVENESS, AND HEMIPARESIS WITH AN AMAZING RECOVERY

CHIEF COMPLAINT

A 53-year-old man was brought to the emergency room with acute onset of **decreased responsiveness and left-sided weakness.**

HISTORY

Past history was notable for cigarette smoking, hypertension, and hypertriglyceridemia. He worked as the chef on a Japanese navy ship. Four days prior to admission, he developed **bilateral frontal and retro-orbital headaches.** At 10:00 A.M. on the day of admission, his headache worsened and he developed **generalized weakness and nausea.** At 10:30 A.M. he had a **transient episode of right-sided weakness** and went to see the ship's doctor. Lunchtime was approaching, however, and he had to return to work. At 2:00 P.M. he had sudden onset of **blurred vision, dysarthria, and gait difficulty,** which rapidly evolved into **decreased responsiveness with left-sided weakness.** Fortunately, the ship was docked at a major city, and the patient was urgently transferred to the emergency room, arriving within a half hour of symptom onset.

PHYSICAL EXAMINATION

Vital signs: T = 98°F, P = 84, BP = 170/90.
Neck: Supple with no bruits.
Lungs: Clear.
Heart: Regular rate; 2/6 systolic murmur heard loudest over the apex.
Abdomen: Soft, nontender.
Extremities: Normal.
Neurologic exam:

MENTAL STATUS: **Lethargic, arousable to voice, but needed repeated stimulation to get a response.** Japanese speaking. Correctly followed simple commands and imitated gestures.

CRANIAL NERVES: Pupils 3 mm, constricting to 2 mm. Intact blink to visual threat bilaterally. Extraocular movements full except for **left gaze preference, and inability to move either eye fully to the right, even with oculocephalic maneuvers. Upgaze was also somewhat limited.** Corneal reflexes intact. **Left facial weakness, sparing the forehead. Unable to protrude tongue** on command.

MOTOR: Strong, purposeful movements of the right arm and leg. **Left arm had weak purposeful movements, and left leg had triple flexion only in response to pain.**

PLANTAR RESPONSES: **Upgoing bilaterally.**

OTHER REFLEXES, COORDINATION, GAIT, AND SENSORY EXAM: Not tested.

CASE 14.6 *(CONTINUED)*

Toward the end of the exam, the patient became **less responsive** and began having **shivering movements and bilateral right greater than left extensor posturing** (see Figure 3.5B). He was urgently intubated and taken for a head CT and emergency angiogram at 3:00 P.M. (1 hour after symptom onset).

LOCALIZATION AND DIFFERENTIAL DIAGNOSIS
On the basis of the symptoms and signs shown in **bold** above, what is the most likely localization? What is the most likely diagnosis?

Discussion

The key symptoms and signs in this case are:

- **Bilateral frontal and retro-orbital headaches**
- **Nausea**
- **Blurred vision**
- **Generalized weakness; gait difficulty; transient episode of right-sided weakness; weakness of left face sparing the forehead, left arm, and left leg, with left leg triple flexion, and bilateral Babinski's signs; progression to bilateral right greater than left extensor posturing**
- **Decreased responsiveness, progressively worsening**
- **Dysarthria; inability to protrude tongue**
- **Right horizontal gaze palsy; limited upgaze**
- **Shivering movements**

This patient had symptoms and signs suggestive of waxing, waning, and then sudden worsening dysfunction of several bilateral regions supplied by the vertebrobasilar system (see KCC 14.3; Table 14.6). Blurred vision could be the result of occipital lobe involvement or diplopia The alternating right, then left, and then right hemiparesis with bilateral Babinski's signs is strongly suggestive of basilar artery stenosis affecting the bilateral basis pontis. The presence of wrong-way eyes (see Table 14.8; see also KCC 13.10; Figure 13.15; Case 13.7) at the time of initial examination (left weakness with left gaze preference) suggests extension to the right pontine tegmentum (see Figure 14.20C). Limited upgaze and impaired consciousness suggest impaired function of the midbrain tegmentum. Shivering is characteristic of pontine dysfunction, and the headaches, nausea, and dysarthria are also suggestive of brainstem dysfunction resulting from ischemia (see KCC 14.3; Table 14.6). Given the patient's vascular risk factors, the overall picture is most compatible with evolving basilar thrombosis, possibly in the setting of preexisting basilar stenosis.

Clinical Course and Neuroimaging 638

The patient's initial **head CT** revealed no infarcts or hemorrhages (Figure 14.29A). Interestingly, there was a region of increased density in the basilar artery with Hounsfield units (HU) of 60 to 70 compatible with clotted blood (see Table 4.1). Intravenous heparin was started, and in an experimental treatment for basilar thrombosis, the patient was then taken for an immediate **angiogram** (see Figure 14.29B). When the left vertebral artery was injected with dye, flow stopped after the proximal basilar artery just after the AICAs, and the dye refluxed down into the contralateral right vertebral artery during the injection (see Figure 14.29B). Urokinase, a thrombolytic agent, was then infused through a catheter directly into the basilar artery at the region of the occlusion. The result was successful lysis of a clot that had blocked a very narrow region of the basilar artery (see Figure 14.29C). After the lysis, the injected dye no longer refluxed significantly into the contralateral (right) vertebral artery, but instead continued distally, demonstrating

restored flow in the distal basilar artery, PCA, and SCAs (see Figure 14.29C). Follow-up head CT no longer showed a bright clot in the basilar artery with HU (see Table 4.1) measured at 40 (compare to Case 13.7).

On exam that evening, the patient was alert, following commands, with slightly limited right gaze and upgaze. He had extensor posturing on the left side, purposeful movements on the right and bilaterally upgoing toes. The next day he had full eye movements except for slightly limited right eye abduction, 4+/5 strength on the left side, and bilateral equivocal plantar responses. He was changed over from heparin to Coumadin, and an MRA just before discharge (2 weeks after onset) showed persistent focal stenosis of the midbasilar artery. MRI showed no evidence of infarction. By the time of discharge, the patient had a completely normal neurologic exam, and he walked out of the hospital with no deficits.

CASE 14.5 LOCKED IN

Figure 14.26 Bilateral Pontine Basis Infarcts Causing Locked-in Syndrome Axial T2-weighted MRI images. (A) Rostral medulla with small bilateral regions of increased signal, compatible with infarcts. (B) Pons with extensive bilateral infarcts destroying the corticospinal and corticobulbar pathways. (C) Midbrain is spared, including the midbrain reticular formation, allowing preserved consciousness

(A)

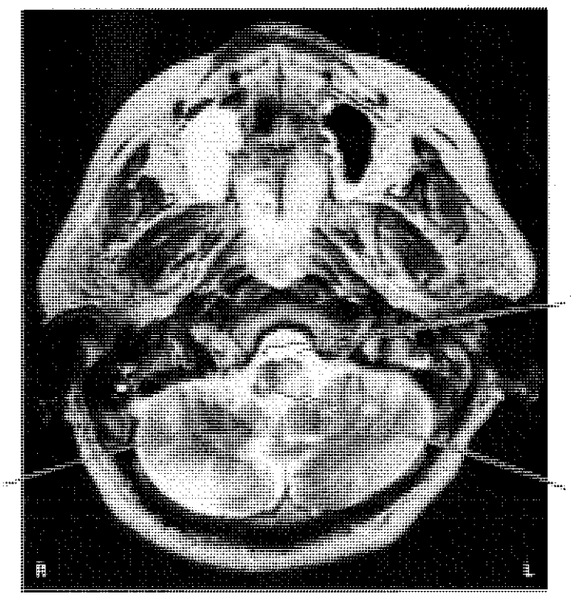

CASE 14.5 *(CONTINUED)*

(B)

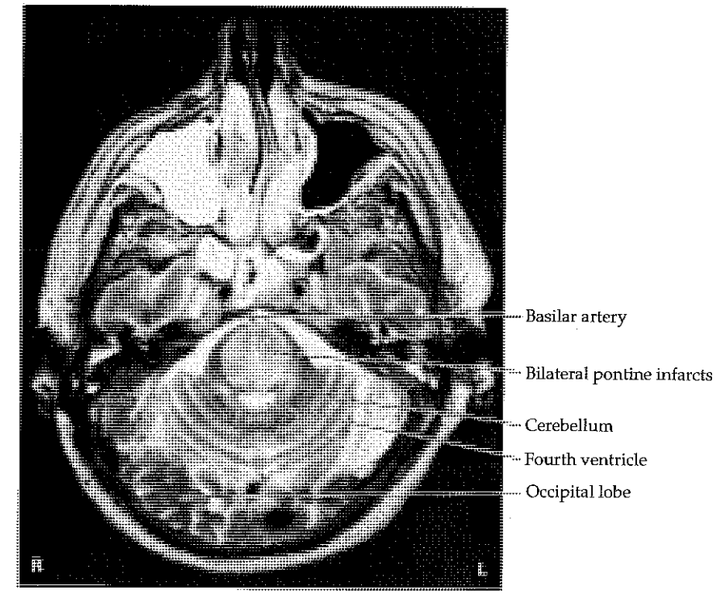

(C)

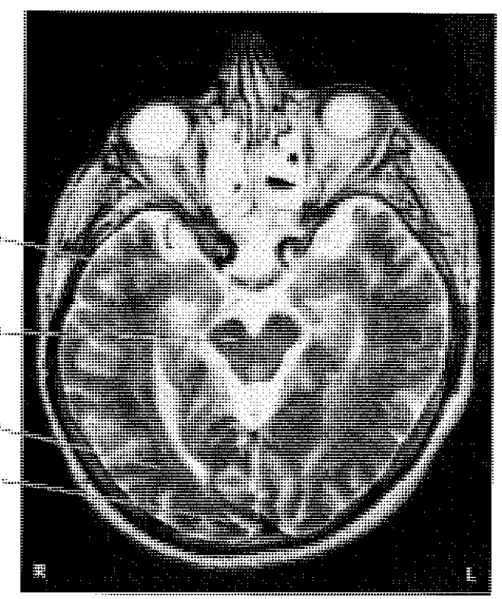

CASE 14.5 RELATED CASES

Figure 14.27 Bilateral Midbrain Basis Infarcts Causing Locked-in Syndrome Axial T2-weighted MRI images. (A) Medulla. (B) Pons. (C) Midbrain, with bilateral T2-bright regions in the cerebral peduncles, compatible with infarcts.

(A)

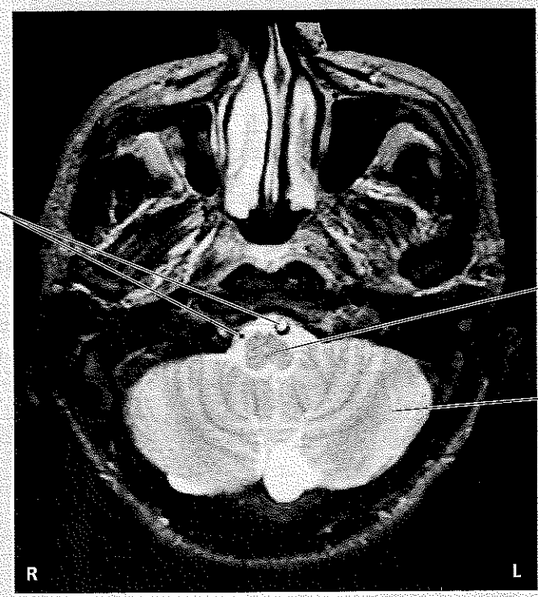

(B)

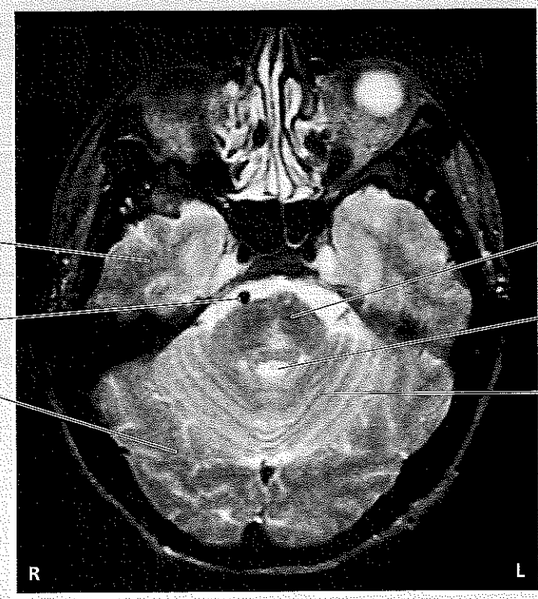

CASE 14.5 RELATED CASES *(CONTINUED)*

(C)

Figure 14.28 Basilar Artery Stenosis Pathology specimen from a patient who died of basilar thrombosis. A severe narrowing of the midbasilar artery can be seen (arrow), caused by atherosclerotic disease. This resulted in the superimposed basilar thrombosis.

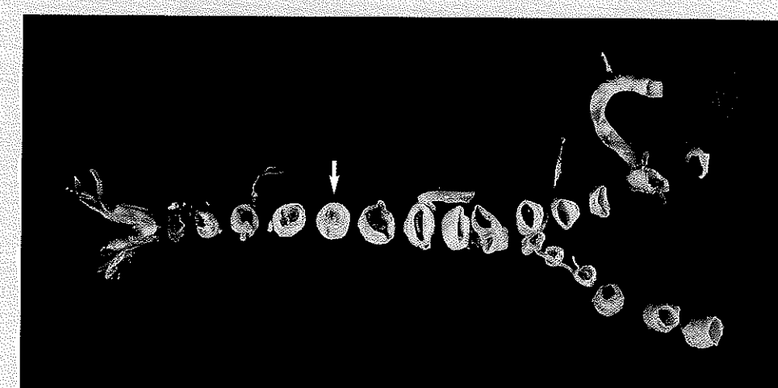

CASE 14.6 WRONG-WAY EYES, LIMITED UPGAZE, DECREASED RESPONSIVENESS, AND HEMIPARESIS WITH AN AMAZING RECOVERY

Figure 14.29 Basilar Artery Thrombosis Treated with Intra-arterial Thrombolysis (A) Head CT on admission showing bright signal in the basilar artery, suggesting thrombosis. No infarct or hemorrhage was seen. (B) Angiogram done following left verterbral artery injection, demonstrating lack of flow in the basilar artery past the anterior inferior cerebellar arteries (AICA). Left anterior oblique view. (C) Repeat angiogram after intra-arterial thrombolysis, demonstrating restored flow in the distal basilar artery territory. A mid-basilar artery narrowing can be seen just distal to the AICAs. Left anterior oblique view following injection of the left vertebral artery, as in B.

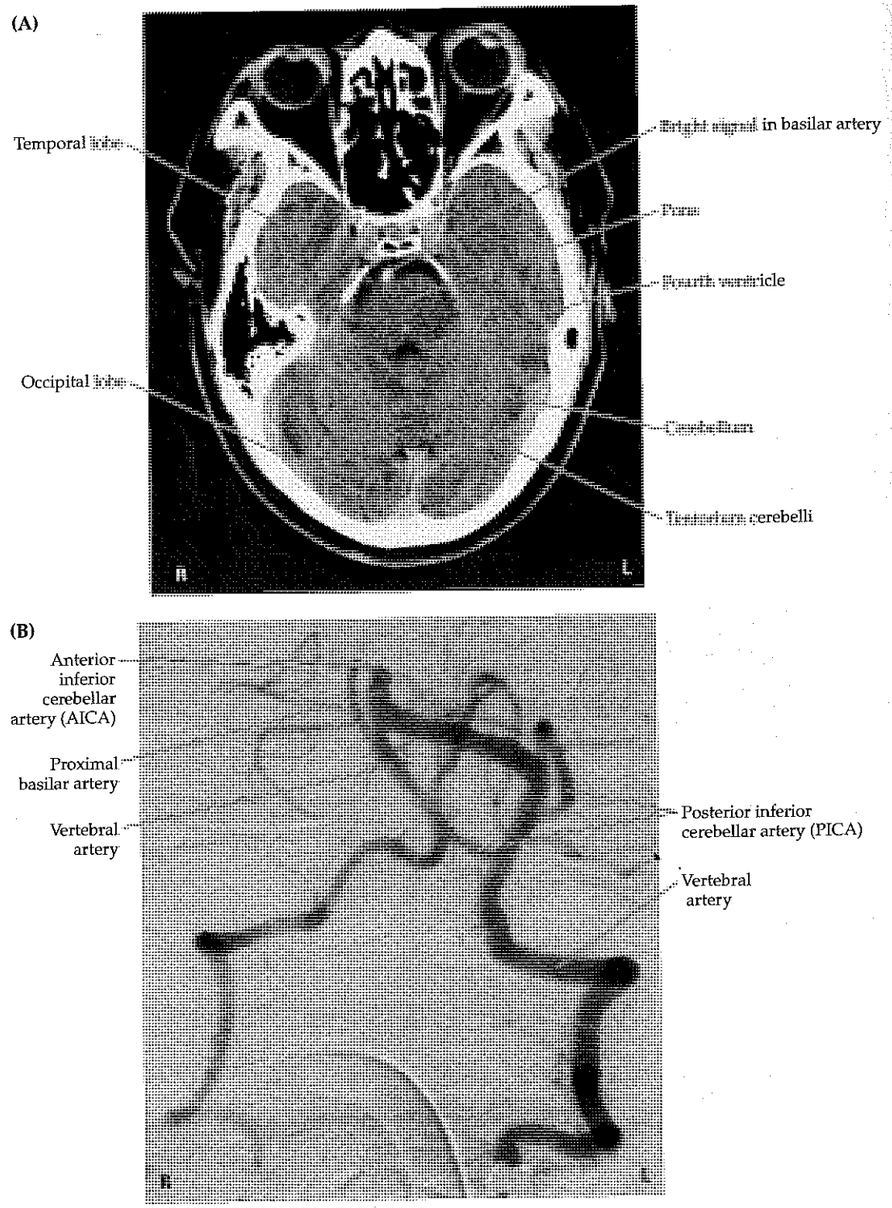

CASE 14.6 *(CONTINUED)*

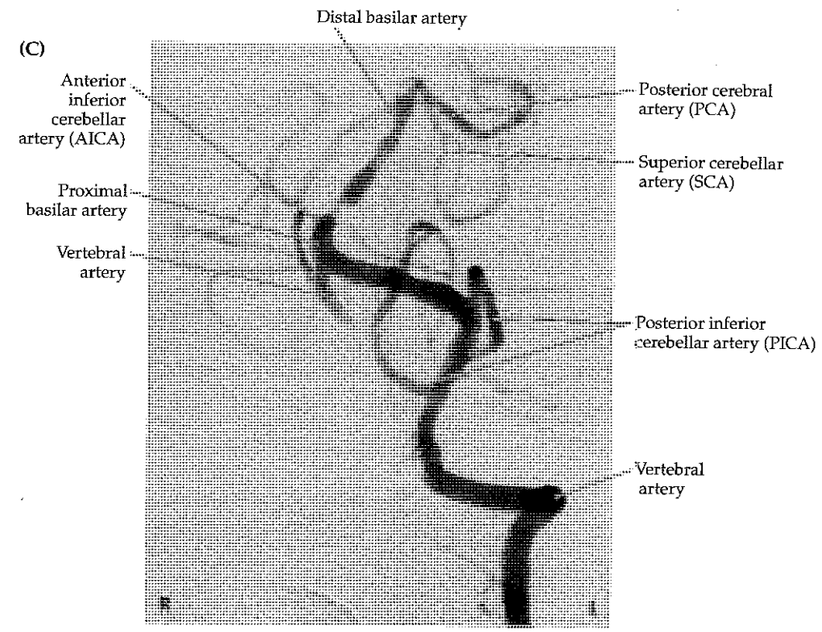

CASE 14.7 DIPLOPIA AND UNILATERAL ATAXIA

MINICASE

A 72-year-old man with a history of hypertension and hypercholesterolemia was watching TV one night and suddenly saw **two faces on the screen diagonally displaced. This diplopia went away when he covered one eye.** In order not to alarm his wife, he quietly made his way to bed, but the next morning the diplopia was unchanged, and he also noticed **gait unsteadiness with staggering to the right.** He tried using a friend's walker, but then also noticed that his **right hand was clumsy.** For example, he had difficulty picking up a credit card from the table with his right hand. On exam, his **left eye would elevate by only 1 mm, adduct by only 2 mm, and depress by only 3 mm** (Figure 14.30B). Left eye abduction was normal. He had diagonal **diplopia,** which was tested with a red glass over the right eye, as shown in Figure 14.30D. There was a **left ptosis,** with the palpebral fissure measuring 4 mm on the left and 9 mm on the right (see Figure 14.30C). The left pupil had a slightly irregular shape (see Figure

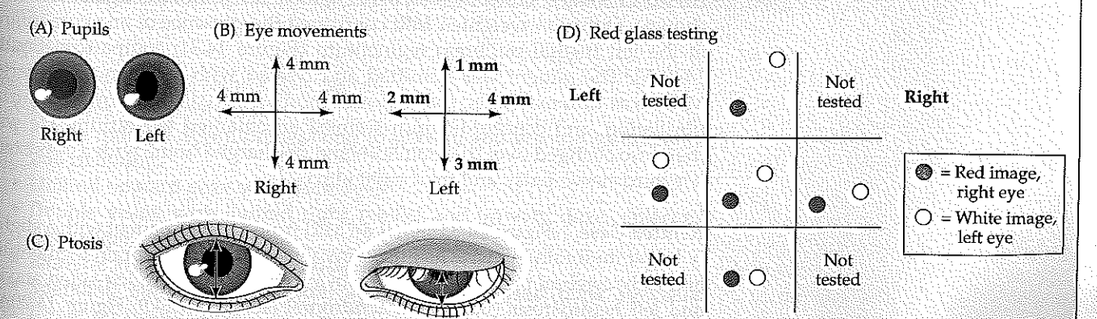

Figure 14.30 Eye Movement Findings (A) Pupils. (B) Eye movements. (C) Ptosis. (D) Red glass testing.

CASE 14.7 *(CONTINUED)*

14.30A) but reacted normally to light. The patient also had **mild right ataxia on finger-to-nose and heel-to-shin testing, and an unsteady gait, tending to list to the right.** The remainder of the exam was normal, except for the **right plantar** response, which was **equivocal.**

LOCALIZATION AND DIFFERENTIAL DIAGNOSIS

1. What is the cause of the eye movement abnormalities summarized in Figure 14.29 (review KCC 13.1, 13.2)?
2. A lesion in what region of the brain could cause these abnormalities along with right ataxia?
3. What is the most likely diagnosis?

Discussion

The key symptoms and signs in this case are:

- **Diagonal diplopia, and left eye movements with only 1 mm elevation, 2 mm adduction, 3 mm depression and normal abduction with left ptosis**
- **Right arm and leg ataxia**
- **Equivocal right plantar response**
- **Unsteady gait, tending to list to the right**
- **Right hand clumsiness**

1. The eye movement abnormalities in Figure 14.30 represent a left third-nerve palsy (compare to Figure 13.5). Note that the pupil is not dilated but has an irregular shape. This may represent midbrain corectopia, which can occasionally be seen with midbrain lesions (see KCC 13.5). The fact that elevation of the contralateral eye was normal suggests that the lesion involves the third-nerve fascicles in the midbrain rather than the entire oculomotor nucleus (fibers from the superior rectus subnucleus project contralaterally; see Table 13.2; Figure 13.3).
2. The right-sided ataxia may be caused by involvement of the fibers of the superior cerebellar peduncle in the left midbrain (see Figure 14.20A; Table 14.9). The subtle right plantar abnormality could result from mild involvement of the left cerebral peduncle in the midbrain.

   The most likely *clinical localization* is left midbrain tegmentum, including the oculomotor nerve fascicles and superior cerebellar peduncle fibers (Claude's syndrome; see Table 14.9).
3. Given the sudden onset of symptoms in a man in his 70s with a history of hypertension and elevated cholesterol, the most likely diagnosis is left midbrain infarct, caused by occlusion of the penetrating vessels at the top of the basilar artery and proximal left PCA (see Figure 14.17A, 14.20A). A far less likely possibility is a small hemorrhage in this region.

Clinical Course and Neuroimaging 643

An MRI revealed subtle increased T2 signal in the midbrain tegmentum (not shown). Diffusion-weighted **MRI** confirmed the presence of an acute infarct in the left medial midbrain tegmentum (Figure 14.31; compare to Figure 14.20A). The patient was admitted and treated with intravenous heparin. MRA was unremarkable, but a Holter monitor revealed intermittent atrial fibrillation, and echocardiogram showed an enlarged left atrium. He was therefore changed over to Coumadin and discharged home with a persistent left third-nerve palsy and mild right ataxia.

Related Case. Figure 14.32 shows an MRI from another patient with a slightly larger midbrain infarct. The infarct involved the right midbrain tegmentum and right cerebral peduncle, resulting in a right CN III palsy, left-sided ataxia, and left hemiparesis (Benedikt's syndrome) (see Table 14.9; Figure 14.20A). Compare Case 14.7 and this related case with Case 13.1.

CASE 14.8 INTERMITTENT MEMORY LOSS, DIPLOPIA, SPARKLING LIGHTS, AND SOMNOLENCE

MINICASE

A 60-year-old retired businesswoman was sent to the emergency room by her physician because of 2 months of worsening episodes of **memory loss, sparkling lights,** and **blurry or double vision.** Her past medical history was notable for anticardiolipin (antiphospholipin) antibody syndrome (a condition causing hypercoagulability; see Table 10.5), including elevated anticardiolipin antibodies (IgG 2407, IgM 38, IgA < 10), a first-trimester miscarriage, left subclavian stenosis, and Raynaud's phenomenon. She had been treated in the past with Coumadin, but she elected to take aspirin instead. She also had a long history of brief, 1- to 2-minute, episodes of migrainelike visual scintillations (see KCC 5.1) that she described as "like firecrackers going off in front of my eyes," associated with multiple other vague complaints, including epigastric, pleuritic, and back pain, which were attributed to fibromyalgia or stress. There was a strong family history of migraine. The patient's sister had died 2 months prior to admission, and shortly afterward the patient began having recurrent **episodes of memory loss** lasting several minutes each, along with worsening of all her other complaints. She was somewhat evasive and vague in describing the episodes, and her physicians initially believed them to be psychiatrically based. Memory lapses included forgetting whether her sister had been buried or cremated, and forgetting a real estate deal she had recently completed.

On the day of admission, she saw her physician because of a new complaint she had developed a few days earlier of **blurred and then double vision** to the point where it was difficult for her to stand up and walk. On initial examination she was alert and fluent but had **mildly reduced attention,** able to repeat only 5/7 digits forward, and recalling 2/3 objects after 3 minutes. Her **right pupil was slightly enlarged at 4 mm, constricting sluggishly to 2.5 mm,** and her left pupil was 3 mm, constricting briskly to 2 mm. She had **limited upward gaze with both eyes.** In addition, **medial gaze was reduced with the right eye,** and she had a **right ptosis.** Exam was otherwise unremarkable.

Her physician sent her to the emergency room, where she was examined by a neurologist, but by the time she arrived she had normal eye movements, with the only abnormality on exam being a mild residual anisocoria. She was admitted for further evaluation, and the next morning she was found again to have limited upgaze bilaterally, right ptosis, and right limited medial gaze, with a somewhat dilated right pupil. Anticoagulation with intravenous heparin was initiated; however, during the subsequent days she had **waxing and waning somnolence and delirium** to the point of being unarousable at times. At other times, despite being transferred to the intensive care unit, she would wake up, pull out all her intravenous lines, and walk down the hallway to use the bathroom. Her eye movement abnormalities persisted, and in addition she developed **bilateral ataxia on finger-to-nose testing** (when she was awake enough to cooperate), and **decreased blink to visual threat on the left side.**

LOCALIZATION AND DIFFERENTIAL DIAGNOSIS

1. How can the eye movement abnormalities in this patient be summarized?
2. Dysfunction in what location can cause these eye movement abnormalities along with an impaired level of consciousness and ataxia?
3. Given the history of hypercoagulability and the addition of a left visual field deficit, as well as episodes of memory loss, what vascular syndrome (specify blood vessels involved) can cause this combination of deficits (see KCC 14.3)?

Discussion

The key symptoms and signs in this case are:

- **Episodes of memory loss**
- **Mildly reduced attention evolving to waxing and waning somnolence and delirium**
- **Limited upward gaze with both eyes**
- **Double vision with limited right medial and upward gaze, enlarged right pupil, and right ptosis**
- **Bilateral ataxia on finger-to-nose testing**
- **Sparkling lights, blurry vision, and later decreased blink to visual threat on the left side**

1. *Summary of eye movement abnormalities*: The patient had limited upgaze bilaterally. In addition, she had findings compatible with right third-nerve dys-

function, including right ptosis, a large right pupil with decreased reactivity to light, and reduced right eye adduction in addition to the limited upgaze.

2. *Localization of eye movement abnormalities, somnolence, and ataxia*: Dysfunction in the midbrain tegmentum (see Figure 14.20A) could cause (1) vertical gaze abnormalities through involvement of the rostral interstitial nucleus of the MLF in the rostral midbrain (see the Chapter 13 section on vertical eye movements); (2) right third-nerve dysfunction through involvement of the right third-nerve fascicles or nucleus (a right third-nerve nucleus lesion involving the ipsilateral superior rectus subnucleus, and contralateral crossing fibers, could also cause bilateral impairment of upgaze; see Table 13.2; Figure 13.3); (3) somnolence and delirium through involvement of the reticular formation (see KCC 14.2); and (4) bilateral ataxia through involvement of the superior cerebellar peduncle fibers.
3. *Vascular localization and diagnosis*: Given this patient's history of hypercoagulability, a thromboembolic disorder is likely. The above deficits can be localized to the midbrain tegmentum, which is supplied by small penetrating vessels arising from the top of the basilar artery and proximal PCAs (see Figures 14.17A, 14.19, 14.20A). The left visual field deficit could be explained by an infarct of the right occipital lobe, which is supplied by the right PCA. In addition, the episodes of memory loss could have been caused by TIAs involving the bilateral medial thalami or medial temporal lobes (see KCC 18.1) and these structures are also supplied by the PCAs (see Figures 10.5, 10.8). Therefore, the above deficits could all be caused by vascular insufficiency at the top of the basilar artery and proximal PCAs, known as top-of-the-basilar sydrome (see KCC 14.3; Figure 14.17). Top-of-the-basilar syndrome is usually caused by an embolus or thrombus lodged at the top of the basilar artery. Another, less likely possibility is thrombosis of the more proximal basilar artery, although in that case pontine dysfunction usually occurs, including corticospinal, horizontal gaze, proprioceptive, and other dysfunctions not seen in this patient.

Clinical Course and Neuroimaging 646

As already noted, despite anticoagulation the patient's condition continued to wax and wane. MRI and **head CT** scans demonstrated multiple bilateral infarcts in the territory of vessels arising from the top of the basilar artery (Figure 14.33), including the midbrain tegmentum, bilateral medial thalami, and right occipital lobe. An **angiogram** was performed because of concerns that, given her rheumatological history, she might have CNS vasculitis (see Table 10.5) which would require a different treatment (immunosuppressive therapy). The angiogram was negative for changes suggestive of vasculitis. However, a filling defect was seen at the top of the basilar artery, most likely due to a thrombus that had embolized to that location from a remote source such as the heart, or less likely, due to a thrombus that had formed locally (Figure 14.34). Of note, the PCAs did not fill from the basilar artery (compare to Figure 4.17B). However, when the internal carotid arteries were injected (not shown), the PCAs did fill, via the posterior communicating arteries, except for the distal right PCA. This result suggests that the midbrain and thalamic infarcts were caused by the occlusion of small penetrating vessels arising from the top of the basilar artery and proximal PCAs (see Figure 14.17A), while the right occipital infarct was probably caused by an embolus that broke off from the top of the basilar region and migrated up into the distal right PCA (see Figure 14.19).

During the course of her hospital stay, the patient's condition initially waxed and waned as already noted, but she later developed right hemiplegia and lapsed into a coma (see KCC 14.2). A week later, she began to regain some responsiveness to stimulation and to commands, and an MRA revealed that some flow had been restored through the distal basilar artery. She was eventually discharged on Coumadin to a rehabilitation facility.

CASE 14.7 DIPLOPIA AND UNILATERAL ATAXIA

Figure 14.31 Left Midbrain Infarct in Region of Third Nerve Fascicles and Superior Cerebellar Peduncle Diffusion-weighted MRI images. (A) Axial image through the midbrain. (B) Coronal image.

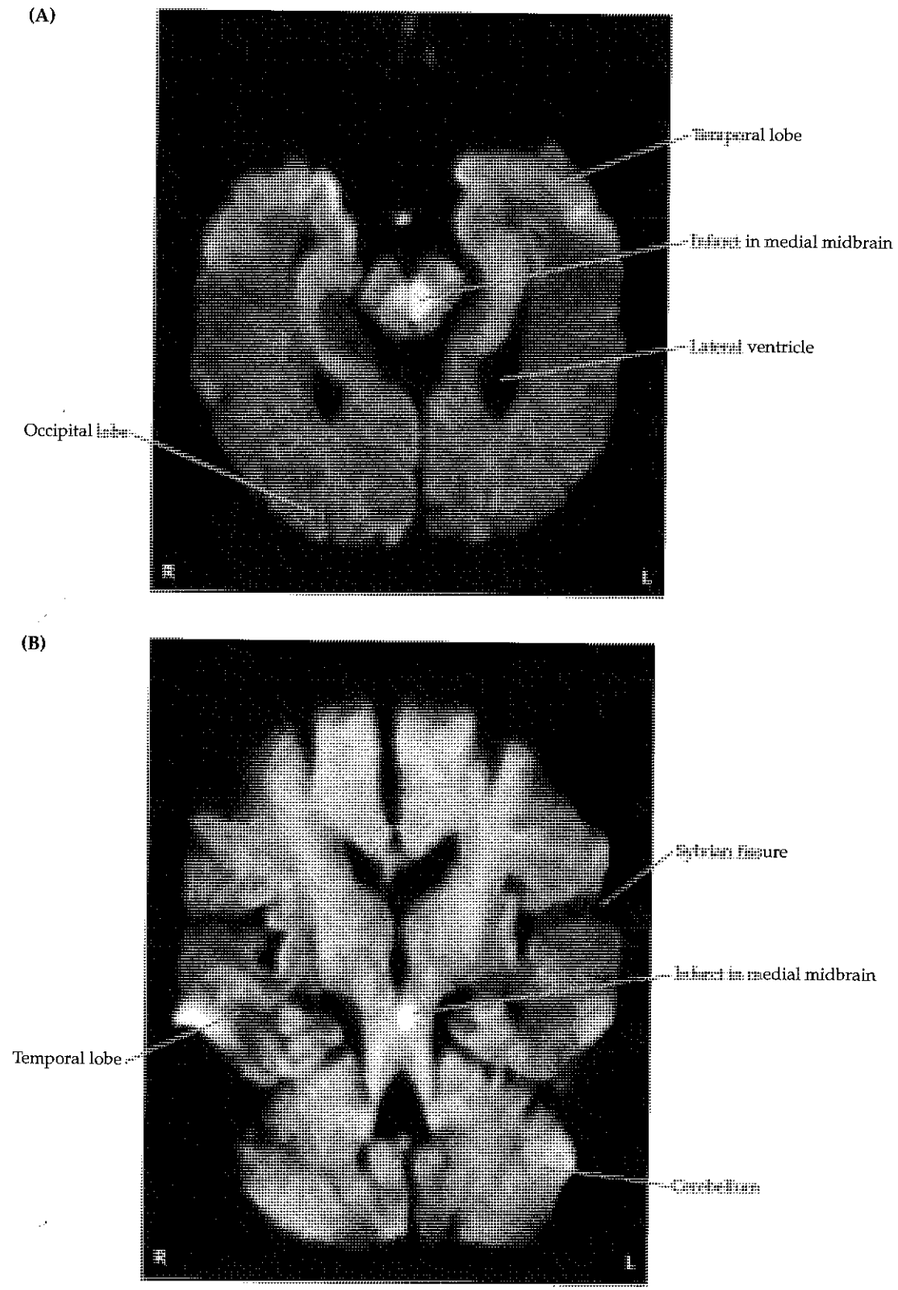

CASE 14.7 RELATED CASE

Figure 14.32 Right Midbrain Infarct in Region of Cerebral Peduncle, Superior Cerebellar Peduncle, Red Nucleus, and Third-Nerve Fascicles Axial T2-weighted MRI image through the midbrain.

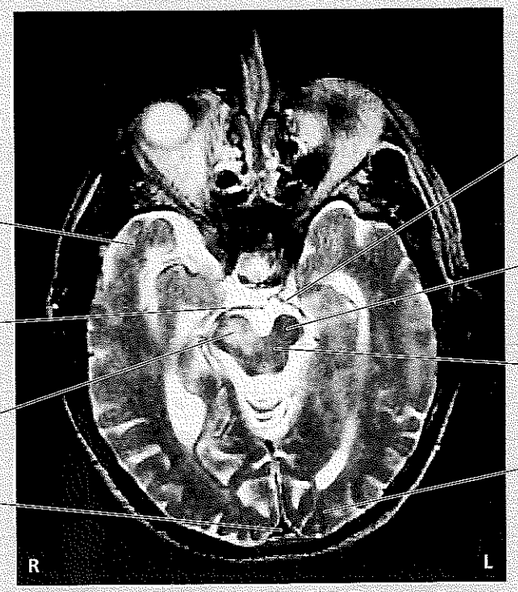

CASE 14.9 INTRACTABLE HICCUPS

MINICASE

A 50-year-old woman developed a **bilateral retro-orbital headache** associated with nasal discharge 2 weeks prior to presentation. She was treated with oral antibiotics for presumed sinusitis, and her symptoms resolved. On review of her past history, she described an episode 14 years previously of vertigo, nystagmus, and dysarthria with a negative workup done in 1977, before MRI was available. Because of these previous symptoms, an MRI scan was scheduled; however, she then suddenly developed **intractable hiccups** lasting 5 days, causing her to come back to her physician's office. General exam and neurologic exam were entirely normal.

LOCALIZATION AND DIFFERENTIAL DIAGNOSIS

Although hiccups (singultus) are usually benign, persistent hiccups can be caused by a variety of systemic or gastrointestinal disorders, as well as by CNS lesions. Lesions in what general region of the CNS are associated with hiccups? Assuming that this patient's previous neurologic symptoms are related to her present complaints, what are some possibilities for the diagnosis?

Discussion

The key symptoms and signs in this case are:

- **Bilateral retro-orbital headache**
- **Intractable hiccups**

Headache can have many causes, but it may be associated with intracranial pathology (see KCC 5.1) Hiccups can be caused by lesions of the posterior fossa, particularly in the medulla (see KCC 14.3). Given the occurrence of symptoms possibly related to brainstem dysfunction many years earlier, a chronic or recurrent lesion of the brainstem, especially the medulla, is the most likely diagnosis. Some possibilities would include demyelination, a low-grade tumor, a small recurrent hemorrhage in an arteriovenous malformation or cavernous angioma, vertebrobasilar migraine, and vasculitis or immune-mediated disorders of the CNS (CNS lupus, Behçet's syndrome, sarcoidosis, etc).

Clinical Course and Neuroimaging 648

A **brain MRI** was performed (Figure 14.35). The MRI revealed a small bright region on unenhanced T1-weighted images, consistent with subacute hemorrhage (see Table 4.4), located in the dorsal portion of the rostral pons in the region of the obex. The patient was admitted briefly for observation and then was discharged home with an appointment for an angiogram approximately 1 month later, once the blood had resolved, to look for an arteriovenous malformation. The angiogram was negative, and it was felt that the patient most likely had a cavernous angioma (see KCC 5.6). A follow-up MRI scan 3 to 4 months later revealed resorption of the hemorrhage (see Figure 14.35B). Treatment of cavernous angiomas is controversial; however, because of concerns about the potential high risk if another bleed should occur in this location, the decision was made to treat the angioma by surgical resection. The lesion was resected during a long, delicate operation in the posterior fossa. Pathologic examination of the resected tissue confirmed cavernous angioma (see KCC 5.6). She made a complete recovery without any deficits.

Additional Cases

Related cases can be found in other chapters for the following topics: **brainstem internal structures and vascular supply** (Cases 5.2–5.6, 10.3, 10.11, 12.8, 13.7–13.9, 15.4, 18.3). Other relevant cases can be found using the **Case Index**.

CASE 14.8 INTERMITTENT MEMORY LOSS, DIPLOPIA, SPARKLING LIGHTS, AND SOMNOLENCE

Figure 14.33 Infarcts Caused by Top-of-the-Basilar Syndrome Axial CT scan images. (A) Hypodensity in midbrain tegmentem and right occipital lobe compatible with infarcts. (B) Section slightly higher than in (A), showing bilateral medial thalamic and right occipital infarcts.

(A)

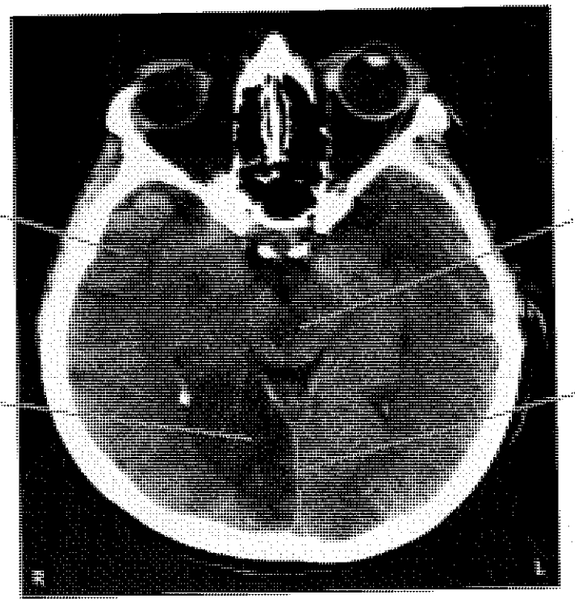

(B)

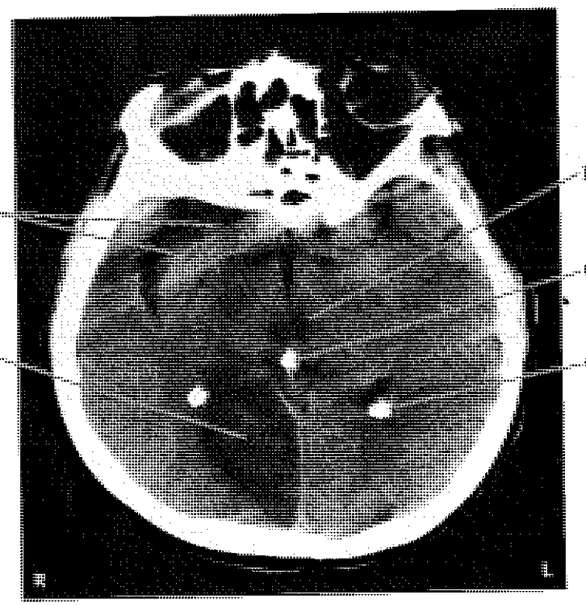

CASE 14.8 *(CONTINUED)*

Figure 14.34 Top-of-the-Basilar Syndrome Angiogram following injection of the left vertebral artery. (A) Left lateral view. Note filling defect in the distal basilar artery, and lack of filling of the bilateral posterior cerebral arteries (PCAs). (B) Anteroposterior view (compare to Figure 4.17).

(A)

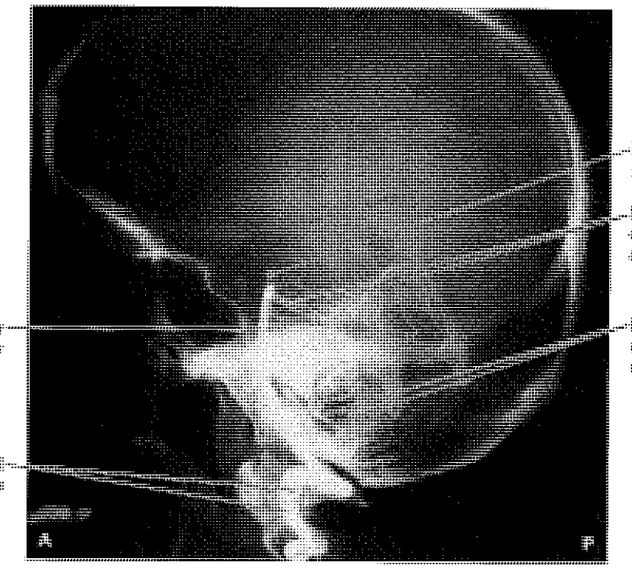

(B)

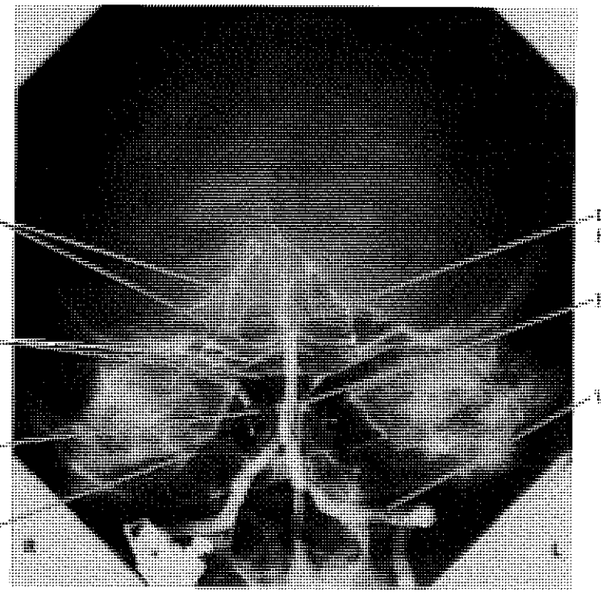

CASE 14.9 INTRACTABLE HICCUPS

Figure 14.35 Cavernous Angioma in the Rostral Medulla, in Region of the Obex T1-weighted MRI images. (A) Axial image at the time of presentation with bright region in rostral medulla, demonstrating subacute hemorrhage. (B) Sagittal image 3 to 4 months later showing dark cavitated region in rostral medulla compatible with prior hemorrhage.

(A)

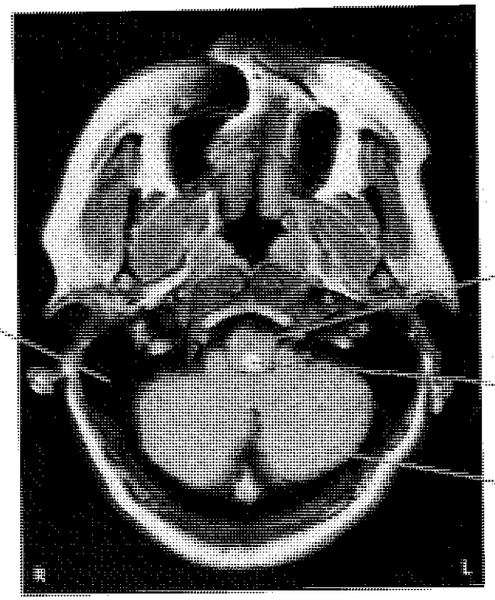

(B)

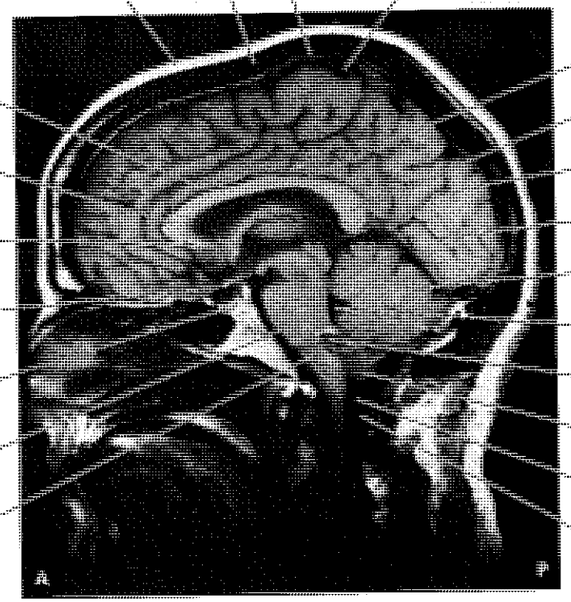

Brief Anatomical Study Guide

In this chapter we focused on the **four main components of internal brainstem structures** shown in Figure 14.1, namely: cranial nerve nuclei and related structures; long tracts; cerebellar circuitry; and reticular formation and related structures. We will describe two strategies for reviewing this material here. First, we will take a **functional approach** and use the myelin-stained brainstem sections shown in Figures 14.3–14.5 to identify functional pathways and functional groupings of nuclei that are distributed throughout these sections and beyond. Second, we will take a **regional approach** and use the vascular territories shown in Figure 14.20 to identify clinically relevant constellations of deficits that occur with focal brainstem infarcts.

1. To begin the functional review, use Table 14.1 to recall each of the **six functional columns of cranial nerve nuclei,** and follow these columns through the brainstem sections in Figures 14.3–14.5, identifying each of the component nuclei (all nuclei can be identified on these sections except for the salivatory nuclei and the cochlear nuclei) (see also Figure 12.5). As you trace structures through adjacent brainstem sections, be sure to note their spatial relationships to nearby structures as well.

2. Next, review the **auditory pathway** by following the lateral lemniscus through the sections from the caudal pons to the inferior colliculus (see Figures 14.3, 14.4), using Figures 12.16 and 12.17 as a guide. Identify the **MLF** in each brainstem section (see Figures 14.3–14.5), and recall its functions (see Figures 12.18, 13.12). Follow the **taste pathway** from the nucleus solitarius rostrally toward the thalamus by following the central tegmental tract from the medulla up through the midbrain (see also Figure 12.12).

3. Next, follow each of the long tracts (see Figures 6.18, 7.1, 7.2) through the brainstem sections, proceeding from rostral to caudal to trace the route of the **corticospinal tract,** and from caudal to rostral to trace the **posterior column–medial lemniscal system** and the **anterolateral (spinothalamic) system** (see Figures 14.3–14.5). **Cerebellar circuitry** is discussed in detail in Chapter 15, but as an initial orientation, use the stained brainstem sections in Figures 14.3–14.5 to identify each of the structures listed under cerebellar circuitry in Table 14.1.

4. The **reticular formation** was simplified in this chapter as containing rostral and caudal regions with different primary functions (see Figure 14.6). The **rostral reticular formation,** located in the midbrain and upper pons, includes several widespread projection systems involved mainly in behavioral and cognitive arousal (see Table 14.2; Figures 14.6–14.13). Lesions in the pontomesencephalic reticular formation often cause coma. Other circuits of the reticular formation located mainly in the **more caudal pons and medulla** are important for control of respiration, heart rate, blood pressure, and other autonomic functions, as well as for motor control, posture, muscle tone, locomotion, and a variety of other relatively stereotyped motor activities.

5. By reviewing **brainstem vascular syndromes,** we will complete a regional overview of internal brainstem structures and also enhance our clinical knowledge. The major blood vessels of the posterior circulation are shown in Figures 14.17–14.20. **Paramedian penetrating bran-**

Brief Anatomical Study Guide *(continued)*

ches supply medial regions of the brainstem, while lateral regions are supplied by penetrators arising from both small-caliber **circumferential branches** (see Figure 14.18) and the larger vessels shown in Figure 14.17.

6. Proceeding from caudal to rostral, identify each vascular territory on the right half of Figure 14.20. Cover the labels and name the vessels that supply each territory (these are also listed in Tables 14.7–14.9). Next, name the structures within each territory that would be affected by occlusion of the blood supply to that territory, and name the associated **clinical symptoms and signs**. By proceeding in this way through the vascular territories of the medulla, pons, and midbrain, you should gain a full appreciation of the elegance of brainstem anatomy and its clinical importance.

References

Anatomical and Clinical Review

Cooper JR, Bloom FE, Roth RH. 1996. *The Biochemical Basis of Neuropharmacology*, 7th Ed. Oxford University Press, New York.

McCormick DA. 1992. Neurotransmitter actions in the thalamus and cerebral cortex and their role in neuromodulation of thalamocortical activity. *Progr Neurobiol* 39(4): 337–388.

Steriade M, Jones EG, McCormick DA (eds.). 1997. *Thalamus*. Elsevier, Amsterdam.

Coma

Fisher CM. 1969. The neurological examination of the comatose patient. *Acta Neurol Scand Suppl* 45(Suppl 36): 1–56.

Plum F, Posner JB. 1980. *The Diagnosis of Stupor and Coma*, 3rd Ed. FA Davis, Philadelphia.

Young GB, Ropper AH, Bolton CF. 1998. *Coma and Impaired Consciousness: A Clinical Perspective*. McGraw-Hill, New York.

Stenade H, McCarley RW. 1990. *Brainstem Control of Wakefulness and Sleep*. Plenum, New York.

Brainstem Vascular Supply and Vertebrobasilar Disease

Archer CR, Horenstein S. 1977. Basilar artery occlusion. *Stroke* 8(3): 383–390.

Barnett HJM, Mohr JR, Stein B (eds.). 1998. *Stroke: Pathophysiology, Diagnosis and Management*. 3rd Ed. Churchill Livingstone, New York, Chapter 18.

Bassetti C, Bogousslavsky J, Barth A, Regli F. 1996. Isolated infarcts of the pons. *Neurology* 46(1): 165–175.

Bassetti C, Bogousslavsky J, Mattle H, Bernasconi A. 1997. Medial medullary stroke: Report of seven patients and review of the literature. *Neurology* 48(4): 882–890.

Bauby, JD. 1997. *Le Scaphandre et le Papillon*. Robert Laffont, Paris, France.

Biller J, Hingtgen WL, Adams HP, Smoker WRK, Godersky JC, Toffol GJ. 1986. Cervicocephalic arterial dissections: A ten-year experience. *Arch Neurol* 43(12): 1234–1238.

Bogousslavsky J, Maeder P, Regli F, Meuli R. 1994. Pure midbrain infarction: Clinical syndromes, MRI, and etiologic patterns. *Neurology* 44(11): 2032–2040.

Brandt T, vonKummer R, Muller-Kuppers M, Hacke W. 1996. Thrombolytic therapy of acute basilar artery occlusion: Variables affecting recanalization and outcome. *Stroke* 27(5): 875–881.

Bruckmann H, Ferbert A, del Zoppo GJ, Hacke W, Zeumer H. 1986. Acute vertebral-basilar thrombosis. Angiologic-clinical comparison and therapeutic implications. *Acta Radiol Suppl* 369: 38–42.

Caplan LR. 1980. "Top of the basilar" syndrome. *Neurology* 30(1): 72–79.

Chia LG. 1991. Locked-in syndrome with bilateral ventral midbrain infarcts. *Neurology* 41(3): 445–446.

Currier RD, Giles CL, DeJong RN. 1961. Some comments on Wallenberg's lateral medullary syndrome. *Neurology* 11: 778–791.

Dollfus P, Milos PL, Chapuis A, Real P, Orenstein M, Soutter JW. 1990. The locked-in syndrome: A review and presentation of two chronic cases. *Paraplegia* 28(1): 5–16.

Hankey GJ, Khangure MS, Stewart-Wynne EG. 1988. Detection of basilar artery thrombosis by computed tomography. *Clin Radiol* 39(2): 140–143.

Kim JS, Lee JH, Suh DC, Lee MC. 1994. Spectrum of lateral medullary syndrome: Correlation between clinical findings and magnetic resonance imaging in 33 subjects. *Stroke* 25(7): 1405–1410.

Kim JS, Kim HG, Chung CS. 1995. Medial medullary syndrome: Report of 18 patients and a review of the literature. *Stroke* 26(9): 1548–1552.

Kubik CS, Adams RD. 1946. Occlusion of the basilar artery: A clinical and pathological study. *Brain* 69: 73–121.

Mas JL, Bousser MG, Hasboun D, Laplane D. 1987. Extracranial vertebral artery dissections: A review of 13 cases. *Stroke* 18(6): 1037–1047.

Matsumoto S, Okuda B, Imai T, Kameyama M. 1988. A sensory level on the trunk in lower lateral brainstem lesions. *Neurology* 38(10): 1515–1519.

Patterson JR, Gabois M. 1986. Locked-in syndrome: A review of 139 cases. *Stroke* 17(4): 758–764.

Provenzale JM, Morgenlander JC, Gress D. 1996. Spontaneous vertebral dissection: Clinical, conventional angiographic, CT and MR findings. *J Comput Assist Tomogr* 20(2): 185–193.

Reznik M. 1983. Neuropathology in seven cases of locked-in syndrome. *J Neurol Sci* 60(1): 67–78.

Schwarz S, Egelhof T, Schwab S, Hacke W. 1997. Basilar artery embolism: Clinical syndrome and neuroradiologic patterns in patients without permanent occlusion of the basilar artery. *Neurology* 49(5): 1346–1352.

Segarra JM. 1970. Cerebral vascular disease and behavior. I. The syndrome of the mesencephalic artery (basilar artery bifurcation). *Arch Neurol* 22(5): 408–418.

Silverman IE, Liu GT, Volpe NJ, Galetta SL. 1995. The crossed paralysis: The original brain-stem syndromes of Millard-Gubler, Foville, Weber, and Raymond-Cestan. *Arch Neurol* 52(6): 635–638.

Tatu L, Moulin T, Bogousslavsky J, Duvernoy H. 1996. Arterial territories of the human brain. *Neurology* 47(5): 1125–1135.

Tijssen CC. 1994. Contralateral conjugate eye deviation in acute supratentorial lesions. *Stroke* 25(7): 1516–1519.

Toyoda K, Imamura T, Saku Y, Oita J, Ibayashi S, Minematsu K, Yamaguchi T, Fujishima M. 1996. Medial medullary infarction: Analyses of eleven patients. Neurology 47(5): 1141–1147.

Vuilleumier P, Bogousslavsky J, Regli F. 1995. Infarction of the lower brainstem: Clinical, aetiological and MRI-topographical correlations. *Brain* 118(pt.4): 1013–1025.

Williams D, Wilson TG. 1975. The diagnosis of the major and minor syndromes of basilar insufficiency. *J Neurol Neurosurg Psychiatry* 39: 741–774.

CHAPTER 15 Cerebellum

ANATOMICAL AND CLINICAL REVIEW
Cerebellar Lobes, Peduncles, and Deep Nuclei
Microscopic Circuitry of the Cerebellum
Cerebellar Output Pathways
Cerebellar Input Pathways
Vascular Supply to the Cerebellum
KCC 15.1 Cerebellar Artery Infarcts and Cerebellar Hemorrhage
KCC 15.2 Clinical Findings and Localization of Cerebellar Ataxia
KCC 15.3 Differential Diagnosis of Ataxia

CLINICAL CASES
15.1 Sudden Onset of Unilateral Ataxia
15.2 Walking Like a Drunkard
15.3 A Boy with Headaches, Nausea, Slurred Speech, and Ataxia
15.4 Nausea, Progressive Unilateral Ataxia, and Right Face Numbness
Additional Cases

BRIEF ANATOMICAL STUDY GUIDE

Cerebellar lesions can cause abnormalities in movement of the body and eyes and can affect balance by disrupting vestibular function. A 13-year-old boy with a lesion in the cerebellum developed gradually worsening headaches, nausea, vomiting, and unsteadiness over the course of 2 months. His headaches were worse at night and were mainly in the left occipital area. A neurologic examination revealed bilateral papilledema, nystagmus, mildly slurred speech, and irregular, ataxic movements that were worse on the left side than the right. In this chapter we will learn about the anatomy and functions of the cerebellum, including network interactions with other parts of the nervous system, and we will see examples of cases in which these functions have been impaired.

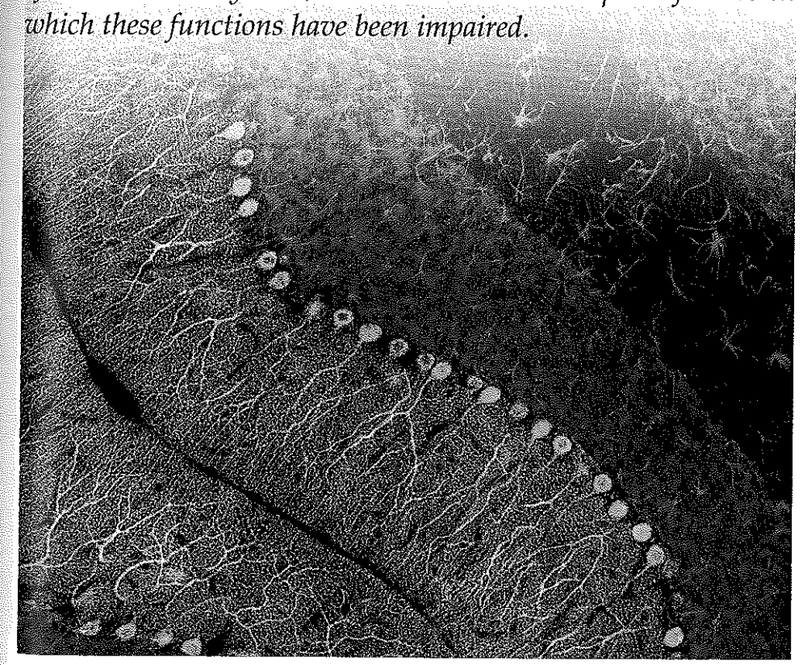

ANATOMICAL AND CLINICAL REVIEW

The cerebellum integrates massive sensory and other inputs from many regions of the brain and spinal cord. This information is used by the cerebellum to smoothly coordinate ongoing movements and to participate in motor planning. Like the basal ganglia, discussed in Chapter 16, the cerebellum has no direct connections to lower motor neurons, but instead exerts its influence through connections to motor systems of the cortex and brainstem (see Figures 2.17, 6.6).

The cerebellum is organized into different regions with specialized functions (see Table 15.1). The inferior vermis and flocculonodular lobes regulate balance and eye movements through interactions with the vestibular circuitry. These regions, together with other parts of the vermis, are involved in control of the medial motor systems discussed in Chapter 6 (proximal trunk muscles). More lateral cerebellar regions control the lateral motor systems (distal appendicular muscles). Finally, large regions of the most lateral cerebellar hemispheres are important in motor planning.

Although cerebellar circuitry is complex, the effects of lesions on the cerebellum are relatively easy to understand based on these different cerebellar regions, as we will see. Cerebellar lesions typically result in a characteristic type of irregular uncoordinated movement, called **ataxia.** Cerebellar lesions can often be localized on the basis of just a few simple principles (see also KCC 15.2):

1. Ataxia is ipsilateral to the side of a cerebellar lesion.
2. Midline lesions of the cerebellar vermis or flocculonodular lobes mainly cause unsteady gait (truncal ataxia) and eye movement abnormalities, which are often accompanied by intense vertigo, nausea, and vomiting.
3. Lesions lateral to the cerebellar vermis mainly cause ataxia of the limbs (appendicular ataxia).

It is also important to recognize that because of the multiple reciprocal connections between the cerebellum, brainstem, and other regions, ataxia may be seen with lesions in these other locations as well. In addition, cerebellar pathways participate in several other functions, including articulation of speech, respiratory movements, motor learning, and possibly certain higher-order coguitive processes.

In this chapter, we will begin our tour of the cerebellum by discussing its overall structure. Next we will discuss the microscopic circuitry and input and output connections of the cerebellum. Finally, we will review the vascular supply to the cerebellum and the clinical effects of lesions on cerebellar networks.

Cerebellar Lobes, Peduncles, and Deep Nuclei

The cerebellum is the largest structure in the posterior fossa (Figure 15.1). It is attached to the dorsal aspect of the pons and rostral medulla by three white matter peduncles (feet) and forms the roof of the fourth ventricle (Figures 15.1, 15.3). The cerebellum consists of a midline **vermis,** named for its worm-like appearance, and two large **cerebellar hemispheres** (see Figure 15.3A). There are numerous fissures, the deepest of which is called the **primary fissure** (see Figures 15.1, 15.3A), separating the cerebellum into an **anterior lobe** and a **posterior lobe.** If the cerebellum is removed from the brainstem by cutting the cerebellar peduncles (Figure 15.2), the ventral surface of the cerebellum becomes visible (see Figure 15.3C). On the ventral inferior surface, the **posterolateral fissure** separates the posterior lobe from the **flocculonodular lobe,** a region with important connections to the vestibular nuclei.

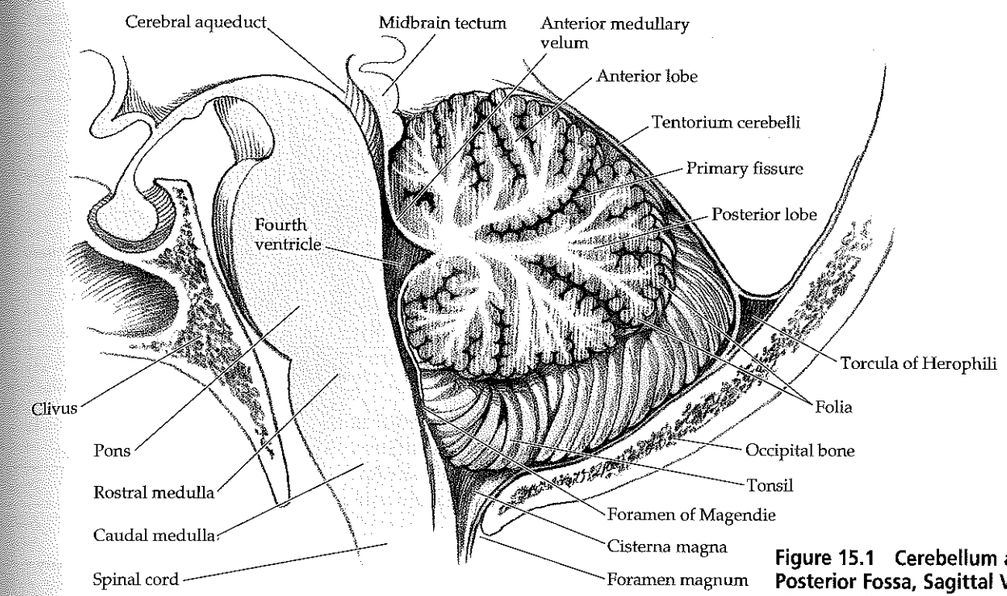

Figure 15.1 Cerebellum and Posterior Fossa, Sagittal View in Situ The cerebellum and brainstem lie within the posterior fossa, formed by the occipital bones and clivus inferiorly, and by the dura of the tentorium cerebelli superiorly.

The two **flocculi** are connected to the midline structure called the nodulus by thin pedicles (see Figure 15.3C). The **nodulus** is the most inferior portion of the cerebellar vermis. Another important landmark on the inferior surface consists of the **cerebellar tonsils** (see Figures 15.1, 15.3C). Mass lesions of the cerebrum or cerebellum, or brain swelling with severely elevated intracranial pressure, can cause the tonsils to herniate (see KCC 5.4) through the foramen magnum (see Figure 15.1; see also Figure 5.18), compressing the medulla and causing death because of impingement on medullary respiratory centers.

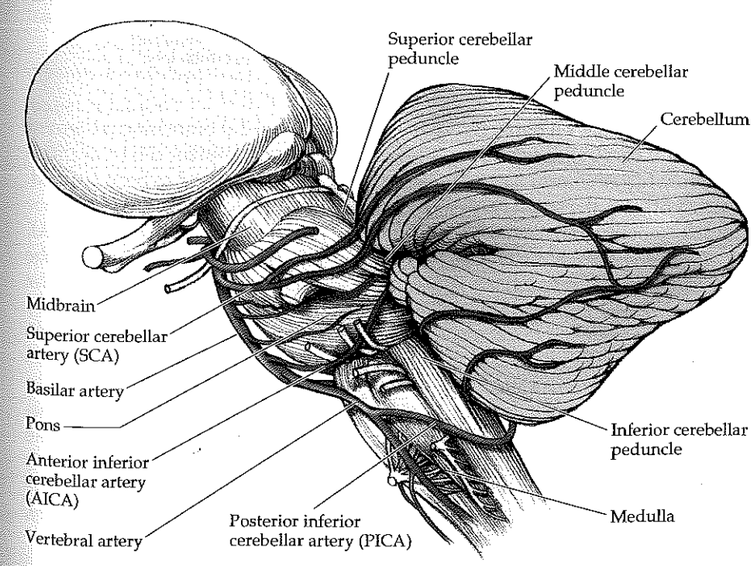

Figure 15.2 Lateral View of the Cerebellum Attached to the Brainstem The cerebellar peduncles and the vascular supply to the cerebellum and brainstem are shown.

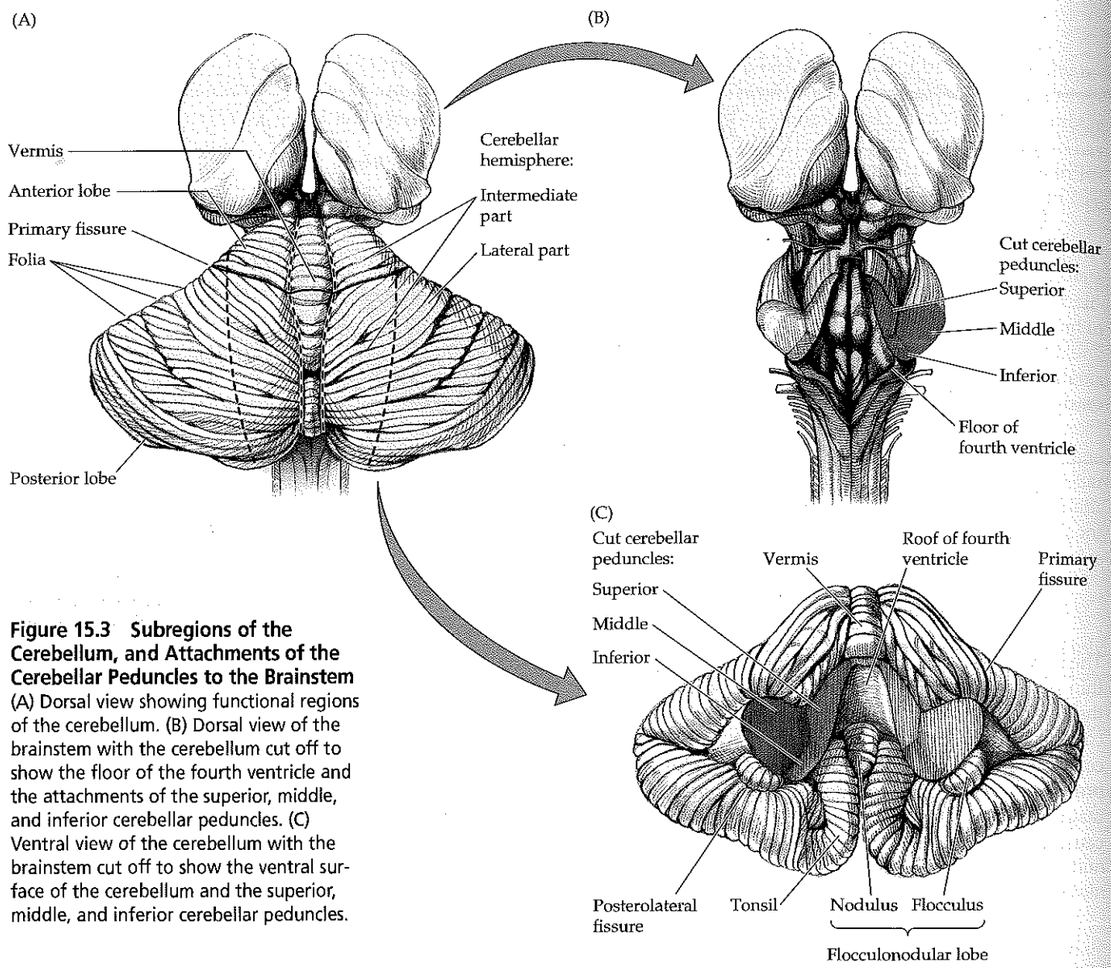

Figure 15.3 Subregions of the Cerebellum, and Attachments of the Cerebellar Peduncles to the Brainstem (A) Dorsal view showing functional regions of the cerebellum. (B) Dorsal view of the brainstem with the cerebellum cut off to show the floor of the fourth ventricle and the attachments of the superior, middle, and inferior cerebellar peduncles. (C) Ventral view of the cerebellum with the brainstem cut off to show the ventral surface of the cerebellum and the superior, middle, and inferior cerebellar peduncles.

On midsagittal section (see Figure 15.1), the beautiful branching pattern of the central **cerebellar white matter** and cortical **gray matter** can be appreciated, to which the term "arbor vitae," meaning "tree of life" has been applied. Instead of gyri, the small ridges that run from medial to lateral on the surface of the cerebellum are called **folia,** meaning "leaves" (see Figures 15.1, 15.3A).

Removing the cerebellum from the brainstem (Figure 15.3B,C) reveals the three **cerebellar peduncles** (superior, middle, and inferior), which form the walls of the fourth ventricle. The **superior cerebellar peduncle** carries mainly outputs from the cerebellum, while the **middle cerebellar peduncle** and **inferior cerebellar peduncle** carry mainly inputs. The **superior cerebellar peduncle decussates** in the midbrain at the level of the inferior colliculi (see Figure 14.3B). Because of the striking conjunction of fibers in this decussation, another name for the superior cerebellar peduncle is the **brachium conjunctivum.** Because of its massive connections to the pons, an alternative name for the middle cerebellar peduncle is **brachium pontis.** The alternative name for the inferior cerebellar peduncle is **restiform body,** meaning "ropelike body."

TABLE 15.1 Functional Regions of the Cerebellum

REGION	FUNCTIONS	MOTOR PATHWAYS INFLUENCED
Lateral hemispheres	Motor planning for extremities	Lateral corticospinal tract
Intermediate hemispheres	Distal limb coordination	Lateral corticospinal tract, rubrospinal tract
Vermis and flocculonodular lobe	Proximal limb and trunk coordination	Anterior corticospinal tract, reticulospinal tract, vestibulospinal tract, tectospinal tract
	Balance and vestibulo-ocular reflexes	Medial longitudinal fasciculus

The cerebellum can be divided into three functional regions, from medial to lateral, based on their input and output connections (see Figure 15.3A,C; Table 15.1):

1. The **vermis** and **flocculonodular lobes** are important in control of proximal and trunk muscles, and in vestibulo-ocular control, respectively.
2. The **intermediate part** of the cerebellar hemisphere is mainly involved in control of more distal appendicular muscles in the arms and legs.
3. The largest part of the cerebellum is the **lateral part** of the cerebellar hemisphere, which is involved in planning the motor program for the extremities. Interestingly, a large portion of the lateral cerebellar hemisphere can be removed *unilaterally* without severe deficits.

The deep cerebellar nuclei and vestibular nuclei also fit with this medial to lateral functional organization (Figure 15.4). *All outputs from the cerebellum* are relayed by these nuclei (Figure 15.5). In addition, these nuclei receive collateral fibers of cerebellar inputs on their way to the cerebellar cortex. The

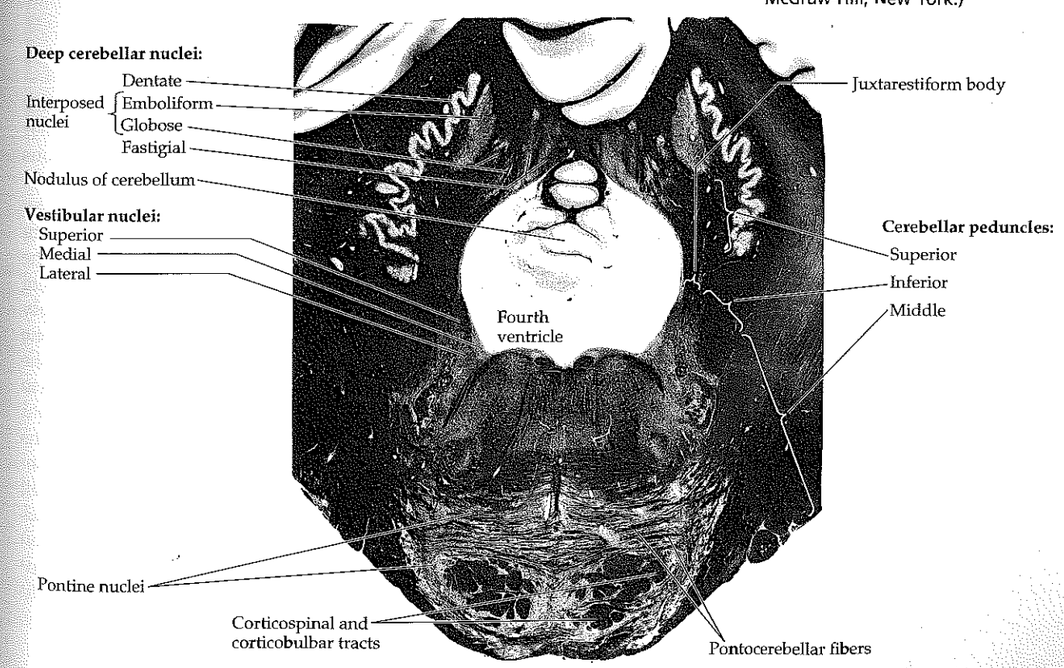

Figure 15.4 Deep Cerebellar Nuclei and Related Structures Cross section through pons and cerebellum showing deep cerebellar (roof) nuclei (dentate, emboliform, globose, and fastigial), vestibular nuclei, juxtarestiform body, corticospinal and corticobulbar fibers, pontine nuclei, pontocerebellar fibers, and cerebellar peduncles (see Figure 14.4C for additional details). (From Martin JH. 1990. *Neuroanatomy: Text and Atlas*, 2nd Ed. McGraw-Hill, New York.)

MNEMONIC

deep cerebellar nuclei, or **roof nuclei,** are, from lateral to medial, the dentate nucleus, emboliform nucleus, globose nucleus, and fastigial nucleus (see Figure 15.4). A mnemonic is "**Don't Eat Greasy Foods**" (Dentate, Emboliform, Globose, Fastigial). The **dentate nuclei** are the largest of the deep cerebellar nuclei, and they receive projections from the lateral cerebellar hemispheres. The **emboliform** and **globose nuclei** are together called the **interposed nuclei,** and they receive input from the intermediate part of the cerebellar hemispheres. Interestingly, experimental recordings have shown the dentate nucleus to be active just before voluntary movements, while the interposed nuclei are active during and in relation to the movement. The **fastigial nuclei** receive input from the vermis, and a small input from the flocculonodular lobe. Most fibers leaving the inferior vermis and flocculi project to the **vestibular nuclei,** (see Figures 12.18, 15.4) which function in some ways like additional deep cerebellar nuclei.

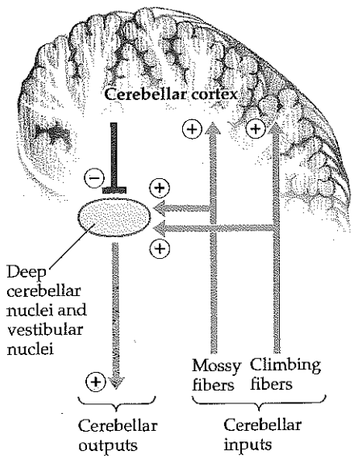

Figure 15.5 Schematic Diagram of Cerebellar Input and Output Pathways

REVIEW EXERCISES

1. Cover the right two columns of Table 15.1. For each region of the cerebellum shown in Figure 15.3 that appears in the left column of Table 15.1, list its major functions and the motor pathways influenced.

2. List the deep cerebellar nuclei from lateral to medial. For each cerebellar region in the left column of Table 15.1, state which deep nuclei convey the outputs.

Microscopic Circuitry of the Cerebellum

The cerebellar cortex has three layers (Figure 15.6). The **granule cell layer** is tightly packed with small **granule cells** so numerous that they rival the total number of cells in the remainder of the nervous system. The **Purkinje cell layer** contains the cell bodies of large, flask-shaped **Purkinje cells.** The **molecular layer** consists of the unmyelinated granule cell axons, Purkinje cell dendrites, and several types of interneurons.

There are primarily **two kinds of synaptic inputs** to the cerebellum (see Figures 15.5, 15.7). One kind is provided by **mossy fibers,** which arise from numerous regions, as will be discussed shortly in the section on cerebellar input pathways. Mossy fibers ascend through the cerebellar white matter to form excitatory synapses onto dendrites of the granule cells. Granule cells, in turn, send axons into the molecular layer, which bifurcate, forming **parallel fibers** that run parallel to the folia (see Figure 15.7). The parallel fibers run perpendicular to the elegant fanlike dendritic trees of the Purkinje cells. During its course, each parallel fiber forms excitatory synaptic contacts with numerous Purkinje cells. **All output from the cerebellar cortex** is carried by the axons of Purkinje cells into the cerebellar white matter. The Purkinje cells form inhibitory synapses onto the deep cerebellar nuclei and vestibular nuclei, which then convey outputs from the cerebellum to other regions through excitatory synapses (see Figure 15.5).

The other kind of synaptic input to the cerebellar cortex is carried by **climbing fibers.** Climbing fibers arise exclusively from neurons in the contralateral inferior olivary nucleus (see Figure 14.5A). They wrap around the cell body and proximal dendritic tree of Purkinje cells (Figure 15.7), forming powerful excitatory synapses. A single climbing fiber will branch to supply about 10 Purkinje cells; however, each Purkinje cell is excited by just one climbing fiber. Climbing-fiber inputs have a strong modulatory effect on the response of Purkinje cells, causing a sustained decrease in their response to synaptic inputs from parallel fibers.

The cerebellar cortex contains several classes of inhibitory interneurons (see Figures 15.7, 15.8). Basket cells and stellate cells are located in the molecular layer. These cells are excited by synaptic inputs from the granule cell parallel fibers. They then give rise to processes that travel in a rostral–caudal direction, perpendicular to the parallel fibers, to cause lateral inhibition of adjacent Purkinje cells. The stellate cells terminate on Purkinje cell dendrites, while basket cells are named for the strong inhibitory basketlike connections they form on Purkinje cell bodies. **Golgi cells** are found in the granule cell layer.

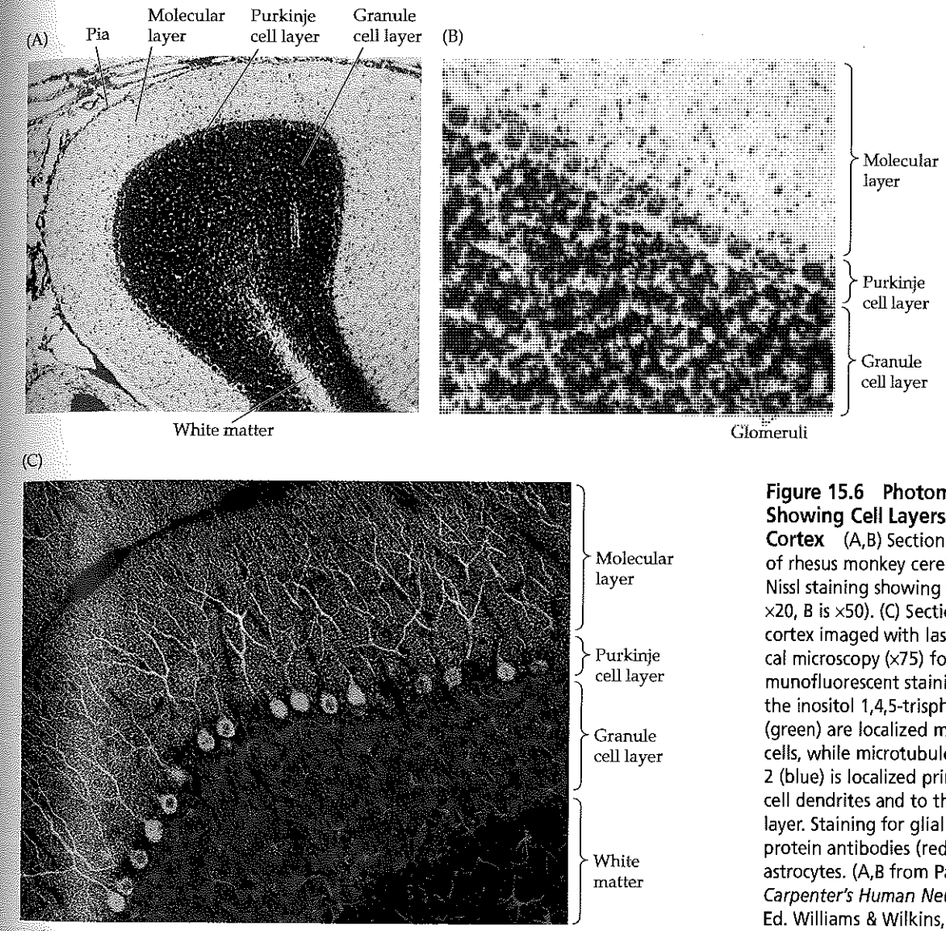

Figure 15.6 Photomicrographs Showing Cell Layers of Cerebellar Cortex (A,B) Sections through a folium of rhesus monkey cerebellar cortex with Nissl staining showing cell bodies. (A is ×20, B is ×50). (C) Section of rat cerebellar cortex imaged with laser scanning confocal microscopy (×75) following triple immunofluorescent staining. Antibodies to the inositol 1,4,5-trisphosphate receptor (green) are localized mainly to Purkinje cells, while microtubule-associated protein 2 (blue) is localized primarily to Purkinje cell dendrites and to the granule cell layer. Staining for glial fibrillary acidic protein antibodies (red) is seen in the glial astrocytes. (A,B from Parent A. 1996. *Carpenter's Human Neuroanatomy,* 9th Ed. Williams & Wilkins, Baltimore. C courtesy of Tom Deerinck and Mark Ellisman, NCMIR.)

The Golgi cells receive excitatory inputs from granule cell parallel fibers in the molecular layer; they then provide **feedback inhibition** onto the granule cell dendrites. This inhibitory feedback tends to shorten the duration of excitatory inputs to the granule cells (enhanced signal resolution in the time domain). Meanwhile, inhibitory lateral connections from stellate and basket cells to adjacent Purkinje cells tend to narrow the spatial extent of excitatory inputs to Purkinje cells (enhanced signal resolution in the spatial domain).

Complex synaptic interactions occur in the granule cell layer in a specialized region called the **cerebellar glomerulus** (Figure 15.8). Cerebellar glomeruli are visible as small clearings among the granule cells (see Figure 15.6); they contain axons and dendrites encapsulated in a glial sheath. Glomeruli contain two types of inputs (large mossy fiber axon terminals and Golgi cell axon terminals), which form synapses onto one type of postsynaptic cell (granule cell dendrites).

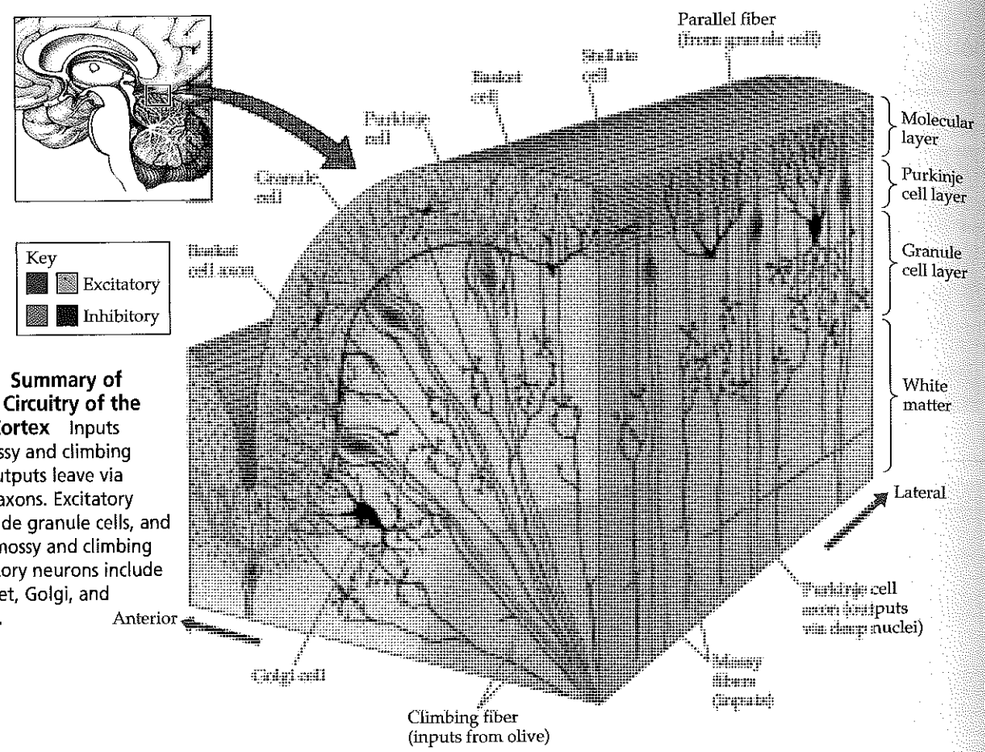

Figure 15.7 Summary of Microscopic Circuitry of the Cerebellar Cortex Inputs arrive via mossy and climbing fibers, and outputs leave via Purkinje cell axons. Excitatory neurons include granule cells, and inputs from mossy and climbing fibers. Inhibitory neurons include stellate, basket, Golgi, and Purkinje cells.

To summarize (see Figure 15.7), mossy fibers excite granule cells, which excite the inhibitory Purkinje cells. Climbing fibers excite Purkinje cells directly. Purkinje cells have fanlike dendritic trees, the orientation of which you can imagine by holding up your open hand in a sagittal plane behind your head. Parallel fibers would then pass through your fingers, perpendicular to your palm. The third dimension is provided by basket cells, whose axons would pass from one finger to the next, perpendicular to the parallel fibers.

MNEMONIC

A simple way to remember the excitatory and inhibitory connections of the cerebellar cortex is to recall that all axons projecting upward are excitatory (mossy fibers, climbing fibers, granule cell parallel fibers), while all axons projecting downward are inhibitory (Purkinje cells, stellate cells, basket cells, Golgi cells). The outputs of the deep cerebellar nuclei, which are not part of the cerebellar cortex, are excitatory.

MNEMONIC

Cerebellar Output Pathways

As we have discussed already, cerebellar pathways are organized around the three functional regions of the cerebellum: the lateral hemispheres, intermediate hemispheres, and vermis plus flocculonodular lobe (see Table 15.1; Figure 15.3A,C). Lesions of the **lateral** cerebellum therefore affect mainly distal limb coordination, while **medial** lesions affect mainly trunk control, posture, balance, and gait. Another important principle with cerebellar lesions is that

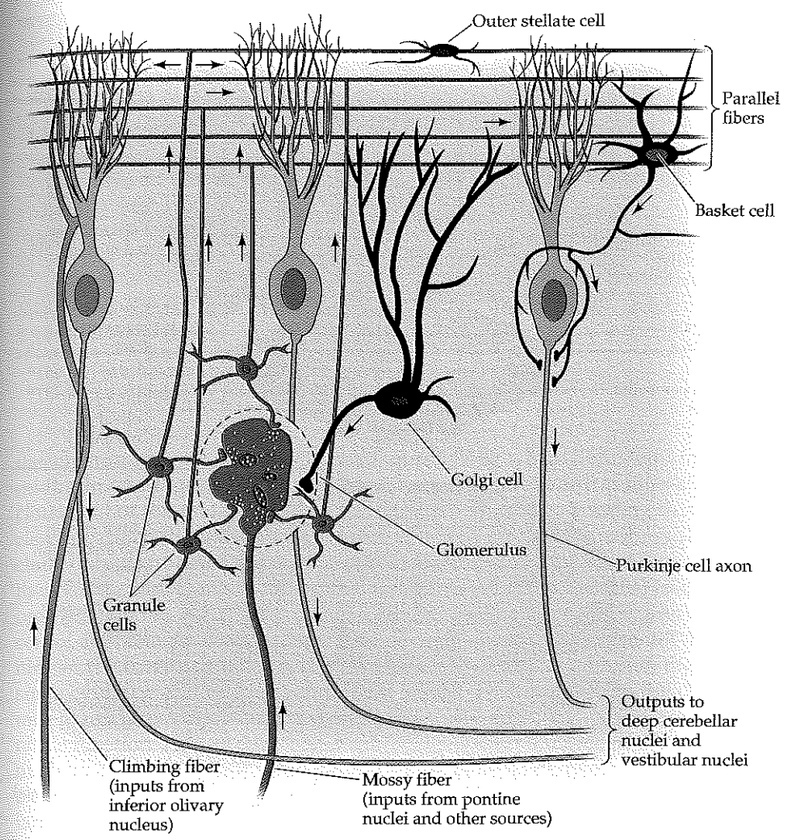

Figure 15.8 Enlarged View of Cerebellar Circuit Showing Cerebellar Glomerulus Synaptic elements of the cerebellar glomerulus include granule cell dendrites that receive excitatory inputs from mossy fiber axonal terminals, and inhibitory inputs from Golgi cell axonal terminals.

deficits in coordination occur ipsilateral to the lesion. The reason is that the pathways from cerebellum to the lateral motor systems (see Table 15.1) and then to the periphery are "**double crossed**" (Figure 15.9B). The first crossing occurs as cerebellar outputs exit in the decussation of the superior cerebellar peduncle, and the second crossing occurs as the corticospinal and rubrospinal tracts descend to the spinal cord. Inputs to the cerebellum also follow this organization, so each cerebellar hemisphere receives information about the ipsilateral limbs. In contrast, midline lesions in the cerebellar vermis have effects on the medial motor systems (see Table 15.1; see also Table 6.3). Lesions of the cerebellar vermis do not typically cause unilateral deficits because the medial motor systems influence the proximal trunk muscles bilaterally.

Outputs from the cerebellum are summarized in Figure 15.9 and Table 15.2. Recall that all outputs from the cerebellum are carried by Purkinje cells to the deep cerebellar nuclei or vestibular nuclei (see Figure 15.5). The **lateral cerebellar hemisphere,** involved in motor planning, projects to the dentate nucleus (see Figures 15.4, 15.9A). The dentate nucleus projects via

REVIEW EXERCISES

Choose the correct term in parentheses.

Mossy fibers form (excitatory or inhibitory) inputs on granule cells, which form (excitatory or inhibitory) synapses on Purkinje cells via parallel fibers. Purkinje cells form (excitatory or inhibitory) outputs on the deep cerebellar nuclei. (See Figures 15.5, 15.7.)

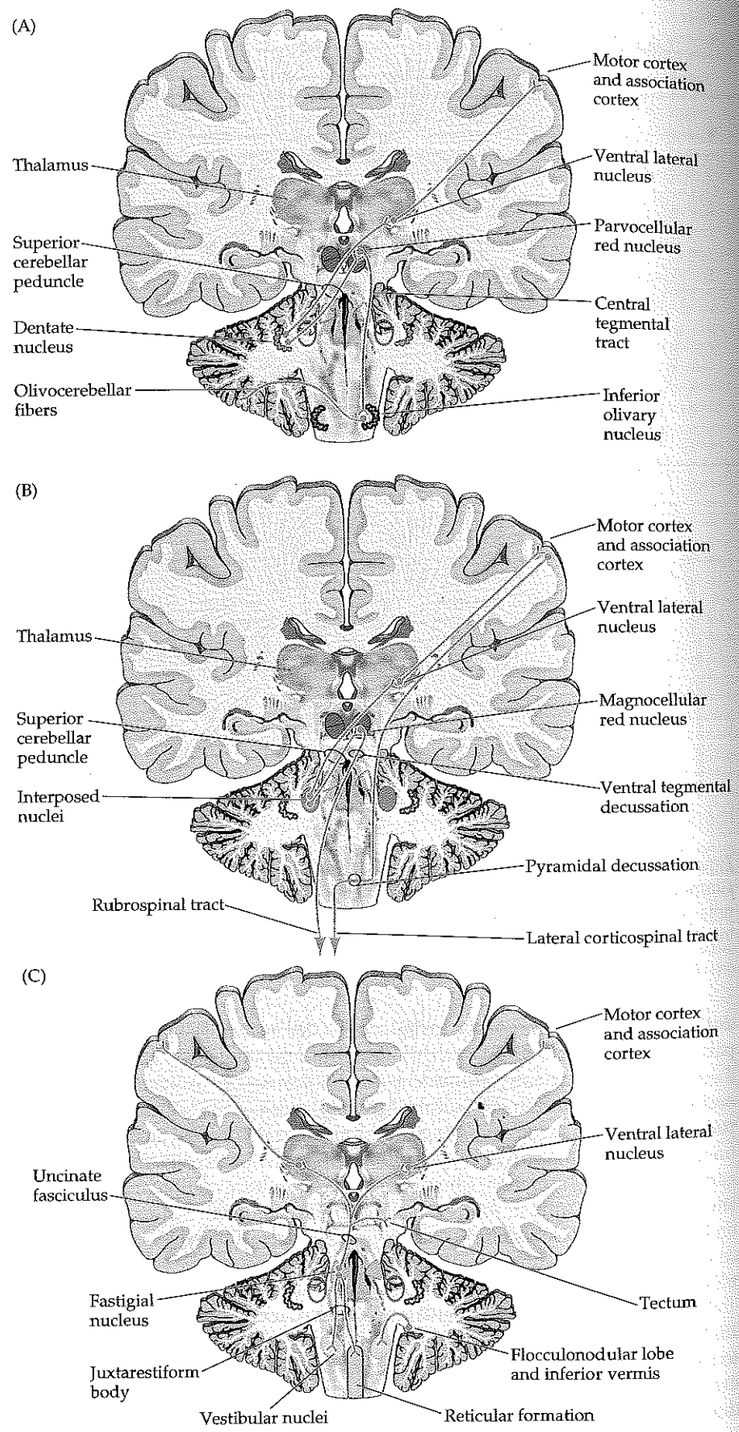

Figure 15.9 Cerebellar Output Pathways (A) Outputs from the lateral cerebellar hemisphere via the dentate nucleus. (B) Output from the intermediate cerebellar hemisphere via interposed nuclei influencing lateral motor systems. Note the "double crossing" of pathways between cerebellum and spinal cord. (C) Outputs from the cerebellar vermis and flocculonodular lobe via the fastigial nucleus influencing medial motor systems. The flocculonodular lobe and inferior vermis also have direct projections to the vestibular nuclei influencing balance and vestibulo-ocular control.

TABLE 15.2 Main Cerebellar Output Pathways

REGION	DEEP NUCLEI	CEREBELLAR PEDUNCLE	MAIN OUTPUT TARGETS OR EQUIVALENT
Lateral hemispheres	Dentate nucleus	Superior cerebellar peduncle	Ventrolateral nucleus of thalamus (VL), parvocellular red nucleus
Intermediate hemispheres	Interposed nuclei	Superior cerebellar peduncle	VL, magnocellular red nucleus
Vermis	Fastigial nuclei	Uncinate fasciculus[a]	VL, tectum
		Juxtarestiform body[b]	Reticular formation, vestibular nuclei
Inferior vermis and flocculonodular lobe	Vestibular nuclei and fastigial nuclei	Juxtarestiform body[b]	Medial longitudinal fasciculus (eye movement pathways)

[a]The uncinate fasiculus travels with the superior cerebellar peduncle.
[b]The juxtarestiform body travels with the inferior cerebellar peduncle.

the superior cerebellar peduncle (see Figure 14.4B), which decussates in the midbrain (see Figure 14.3B) to reach the contralateral **ventral lateral nucleus (VL)** of the thalamus (see Figure 15.9A). The fibers entering this nucleus are called the **thalamic fasciculus,** of which the more anterior parts include outputs from the basal ganglia, which terminate in different regions of the VL (VL, pars oralis) from cerebellar outputs (VL, pars caudalis) (see Figures 7.7, 16.6, 16.9).* The VL, in turn, projects to the motor cortex, premotor cortex, supplementary motor area, and parietal lobe to influence motor planning in the **corticospinal** systems (see Figures 6.1, 6.9). In addition, there is some evidence that outputs from the lateral cerebellum relay in the thalamus to reach the prefrontal association cortex, possibly playing a role in cognitive function. As the output fibers of the dentate nucleus penetrate the red nucleus in the midbrain (see Figure 14.3A), some terminate in the rostral **parvocellular division of the red nucleus.** Recall that the red nucleus has a large rostral parvocellular division that is involved in cerebellar circuitry and a smaller caudal **magnocellular division** that gives rise to the rubrospinal tract. As we will discuss in the next section, the parvocellular division of the red nucleus projects to the inferior olive (see Figure 15.9A).

The **intermediate hemisphere,** involved in the control of ongoing movements of the distal extremities, projects to the emboliform and globose (interposed) nuclei (see Figures 15.4, 15.9B). Like the dentate nucleus, the interposed nuclei project via the superior cerebellar peduncle to the contralateral thalamic VL, which in turn projects to the motor, supplementary motor, and premotor cortex to influence the **lateral corticospinal tract.** Inputs to the VL from the dentate and interposed nuclei (and from the basal ganglia) do not overlap. The interposed nuclei also project via the superior cerebellar peduncle to the contralateral **magnocellular division of the red nucleus** to influence the rubrospinal tract. The intermediate hemisphere thus influences the lateral motor systems (see Figure 15.9B).

The **cerebellar vermis** and **flocculonodular lobes** influence mainly proximal trunk movements and vestibulo-ocular control, respectively. The vermis influences proximal and trunk muscles through connections to the medial motor pathways (anterior corticospinal, reticulospinal, vestibulospinal, and tectospinal tracts; see Tables 15.1 and 6.3). The flocculonodular lobes and inferior vermis influence extraocular movements mainly through con-

*Like the basal ganglia, some cerebellar outputs also project to the thalamic ventral anterior (VA) and intralaminar nuclei (see Table 7.3).

nections to the medial longitudinal fasciculus, which links the vestibular nuclei to nuclei involved in eye movements (see Figures 12.18, 14.3, 14.4). The vermis projects to the fastigial nucleus (see Figures 15.4, 15.9C). The inferior vermis and flocculonodular lobes project mainly to the vestibular nuclei, but also have a small projection to the fastigial nucleus.

Outputs from the fastigial nuclei are carried by fiber pathways running along with the superior cerebellar peduncle and the inferior cerebellar peduncle, respectively, called the **uncinate fasciculus** (see Figure 15.9C) and **juxtarestiform body** (see Figures 15.4, 15.9C). The juxtarestiform body, lying on the lateral wall of the fourth ventricle, just medial to the restiform body, also carries fibers in both directions between the vestibular nuclei and the cerebellum. Let's briefly review the outputs of the vermis to medial motor systems that influence proximal trunk control and the outputs of the flocculonodular lobes to eye movement pathways (see Table 15.2; Figure 15.9C). Outputs from the vermis reach the fastigial nuclei and are then carried out of the cerebellum via the uncinate fasciculus, which hooks over the superior cerebellar peduncle in a crossed pathway. This pathway reaches the thalamic VL and is relayed to the cortex to influence the **anterior corticospinal tract.** Outputs in the same pathway also reach the **tectal area.** Vermis–fastigial outputs also leave the cerebellum via the juxtarestiform body. This pathway reaches the ipsilateral reticular formation and vestibular nuclei to influence the reticulospinal and vestibulospinal tracts, respectively. The flocculonodular lobes and inferior vermis are sometimes referred to as the **vestibulocerebellum** because they project mainly to the vestibular nuclei (via the juxtarestiform body). Reciprocal connections between the cerebellum and vestibular nuclei are important for **equilibrium and balance.** In addition, signals from the vestibular nuclei are relayed via the medial longitudinal fasciculus and other **eye movement pathways** to influence vestibulo-ocular reflexes, smooth pursuit, and other eye movements.

Some fastigial neurons project directly to the upper cervical spinal cord. This small projection appears to be an exception to the principle that the cerebellum and basal ganglia do not project directly to lower motor neurons.

REVIEW EXERCISE

1. Cover the column listing the deep nuclei in Table 15.2. For each region of the cerebellum appearing in the left column of Table 15.2, list the deep nuclei that convey cerebellar outputs from that region.

2. Review the circuits in Figure 15.9B and verify that a lesion of the left cerebellar hemisphere (intermediate portion or interposed nuclei) should cause ataxia of the left (ipsilateral) extremities.

Cerebellar Input Pathways

Inputs to the cerebellum (Table 15.3) arise from widespread areas in the nervous system. These inputs reach the cerebellum from (1) virtually all areas of the cerebral cortex; (2) multiple sensory modalities, including the vestibular, visual, auditory, and somatosensory systems; (3) brainstem nuclei; and (4) the spinal cord. Inputs to the cerebellum have a rough somatotopic organization, with the ipsilateral body represented in both the anterior and posterior lobes, as shown in Figure 15.10. Recall that cerebellar inputs are carried by mossy fibers, except for those from the inferior olivary nucleus, which are carried by climbing fibers. In addition, most inputs to the cerebellar cortex give rise to collaterals that synapse in the deep cerebellar nuclei (see Figure 15.5).

TABLE 15.3 Main Cerebellar Input Pathways

INPUT PATHWAY	MAIN ORIGIN(S) OF INPUT	CELLS PROJECTING TO CEREBELLUM	CEREBELLAR PEDUNCLE OR EQUIVALENT
Pontocerebellar fibers	Cortex	Pontine nuclei	Middle cerebellar peduncle
Spinocerebellar pathways			
Dorsal spinocerebellar tract	Leg proprioceptors	Nucleus dorsalis of Clark	Inferior cerebellar peduncle
Cuneocerebellar tract	Arm proprioceptors	External cuneate nucleus	Inferior cerebellar peduncle
Ventral spinocerebellar tract	Leg interneurons	Spinal cord neurons	Superior cerebellar peduncle
Rostral spinocerebellar tract	Arm interneurons	Spinal cord neurons	Superior and inferior cerebellar peduncles
Climbing fibers	Red nucleus, cortex, brainstem, spinal cord	Inferior olivary nucleus	Inferior cerebellar peduncle
Vestibular inputs	Vestibular system	Vestibular ganglia, vestibular nuclei	Juxtarestiform body

A major source of input consists of **corticopontine fibers** from the frontal, temporal, parietal, and occipital lobes that travel in the internal capsule and cerebral peduncles (see Figure 14.3A). The primary sensory and motor cortices and part of the visual cortex make the largest contributions to the corticopontine fibers. The corticopontine fibers travel to the ipsilateral pons and synapse in the **pontine nuclei.** These are scattered areas of gray matter in the ventral pons interspersed among the descending corticospinal and corticobulbar fibers (see Figure 15.4; see also Figure 14.4). **Pontocerebellar fibers** then cross the midline to enter the contralateral middle cerebellar peduncle and give rise to mossy fibers that reach almost the entire cerebellar cortex (except for the nodulus).

Another major source of input to the cerebellum consists of **spinocerebellar fibers** (Figure 15.11; see also Table 15.3), which travel in four tracts: the **dorsal and ventral spinocerebellar tracts** for the lower extremities, and the **cuneocerebellar and rostral spinocerebellar tracts** for the upper extremities and neck. These spinocerebellar pathways provide feedback information to the cerebellum of two different kinds:

1. Afferent information about limb movements is conveyed to the cerebellum by the **dorsal spinocerebellar tract** for the lower extremity, and by the **cuneocerebellar tract** for the upper extremity and neck.
2. Information about activity of spinal cord interneurons, thought to reflect the amount of activity in descending pathways, is carried by the **ventral spinocerebellar tract** for the lower extremity, and by the **rostral spinocerebellar tract** for the upper extremity.

The **dorsal spinocerebellar tract** ascends in the dorsolateral funiculus, near the surface of the spinal cord, just lateral to the lateral corticospinal tract (see Figure 15.11; see also Figure 7.4). Large, myelinated axons of primary sensory neurons carrying proprioceptive, touch, and pressure sensation from the lower extremities and trunk enter via the dorsal roots and ascend in the gracile fasciculus. Rather than continuing in the posterior columns, some of these fibers form synapses in the **nucleus dorsalis of Clark** (see Figure 15.11; see also Figure 6.4D). This is a long column of cells that runs in the dorsomedial spinal cord gray matter intermediate zone, from C8 to L2 or L3. Fibers arising from the nucleus dorsalis of Clark ascend ipsilaterally in the dorsal spinocerebellar tract (see Figure 15.11). These fibers give rise to mossy fibers that travel to the ipsilateral cerebellar cortex via the inferior cerebellar peduncle. Unlike sensory inputs in the posterior column fibers, the spinocerebellar afferents do not reach conscious perception.

Figure 15.10 Somatotopic Organization of Multimodal Inputs to the Cerebellum

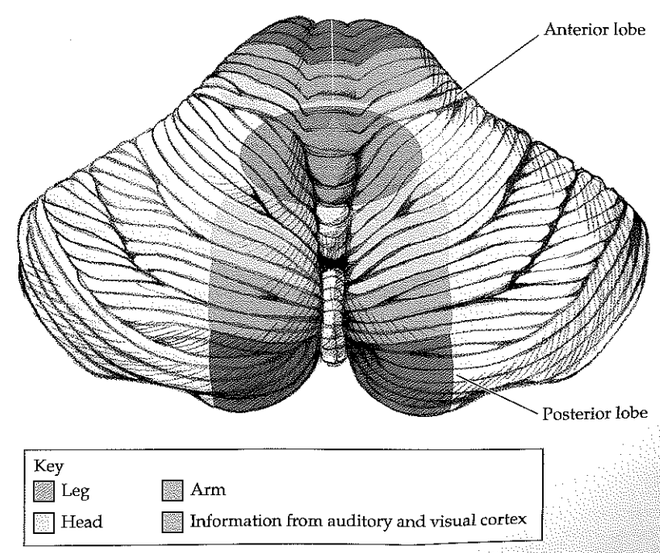

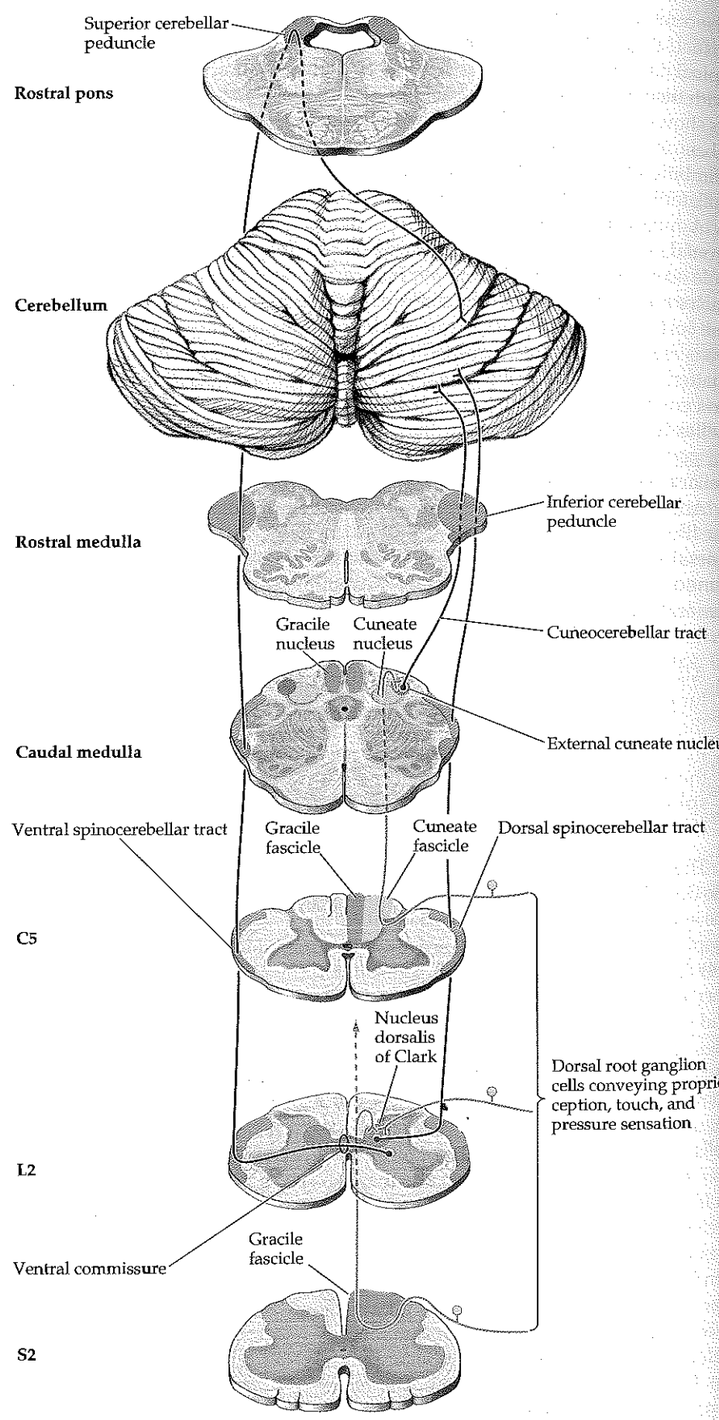

Figure 15.11 Spinocerebellar Pathways The dorsal spinocerebellar, cuneocerebellar, and ventral spinocerebellar tracts. The rostral spinocerebellar tract is not shown.

The upper-extremity equivalent of this pathway is the **cuneocerebellar tract.** Large-diameter fibers from the upper extremities enter the cuneate fasciculus, and ascend ipsilaterally to synapse in the **external** (or **accessory,** or **lateral**) **cuneate nucleus,** located in the medulla, just lateral to the cuneate nucleus (see Figure 15.11; see also Figure 14.5B). The external cuneate nucleus is the upper-extremity analog of the nucleus dorsalis of Clark. From the external cuneate nucleus, cuneocerebellar fibers ascend in the inferior cerebellar peduncle to the ipsilateral cerebellum. Note that for both the dorsal spinocerebellar tract and the cuneocerebellar tract, unconscious information from the extremities reaches the ipsilateral cerebellum. These pathways provide rapid feedback to the cerebellum about ongoing movements, allowing fine adjustments to be made.

The **ventral spinocerebellar tract** arises from neurons along the outer edge of the central gray matter called spinal border cells, and from scattered neurons in the spinal cord intermediate zone (see Figure 15.11). Axons from these cells cross over in the ventral commissure of the spinal cord to ascend in the ventral spinocerebellar tract, just ventral to the dorsal spinocerebellar tract and peripheral to the anterolateral systems (see Figure 7.4). The majority of these fibers then join the superior cerebellar peduncle and cross over a second time, to reach the cerebellum ipsilateral to the side where the pathway began (see Figure 15.11). The **rostral spinocerebellar tract** is the least well characterized of these pathways, but it appears to be the upper-extremity equivalent of the ventral spinocerebellar tract, and it enters the cerebellum through both the inferior and superior cerebellar peduncles. Note that like the output circuits described in the preceding section, the spinocerebellar inputs are either ipsilateral or "double crossed," explaining why cerebellar lesions cause ipsilateral limb ataxia.

The **inferior olivary nuclear complex** gives rise to **olivocerebellar fibers** that cross the medulla to enter the contralateral cerebellum (see Figure 14.5A). These fibers form the major portion of the inferior cerebellar peduncle and terminate as climbing fibers throughout the cerebellum (see Figure 15.7). The parvocellular red nucleus projects to the inferior olive via the central tegmental tract (see Figure 15.9A; see also Figures 14.3–14.5). Note that the parvocellular red nucleus receives inputs from the contralateral dentate nucleus. Thus, a complete loop is formed from lateral cerebellum to dentate nucleus to contralateral parvocellular red nucleus to inferior olive via the central tegmental tract and then crossing back via the inferior cerebellar peduncle to the original cerebellar hemisphere. The inferior olivary nuclear complex also receives inputs from the cerebral cortex, from other brainstem nuclei, and from the spinal cord. The lateral reticular nucleus is located just dorsal to the inferior olive (see Figure 14.5A,B) and receives similar input connections. The lateral reticular nucleus also projects to the cerebellum via the inferior cerebellar peduncle, but it gives rise to mossy fibers instead of climbing-fiber terminals.

Primary vestibular sensory neurons in Scarpa's **vestibular ganglia** (see Figure 12.15) and secondary vestibular neurons in the **vestibular nuclei** project to the ipsilateral inferior cerebellar vermis and flocculonodular lobe via the juxtarestiform body (see Figure 15.4). Connections between the vestibular system and cerebellum are important in the control of balance and equilibrium, as well as in vestibulo-ocular reflexes. The **flocculus** also receives visual inputs related to retinal slip (disparity of intended and perceived target image) that are important for the control of smooth pursuit eye movements.

Noradrenergic inputs from the locus ceruleus and serotonergic inputs from the raphe nuclei project diffusely throughout the cerebellar cortex (see Figures 14.11, 14.12). These inputs are not conveyed by mossy-fiber or climbing-fiber terminals, and they are thought to play a neuromodulatory role.

REVIEW EXERCISES

For each of the four spinocerebellar pathways in Table 15.3, list the origin of input, the location of neurons projecting to the cerebellum, and peduncle.

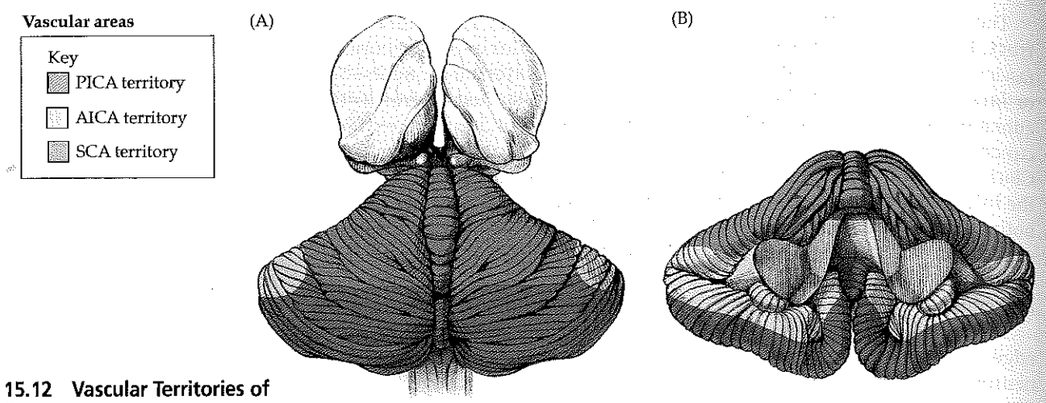

Figure 15.12 Vascular Territories of Cerebellum Surface view, showing territories supplied by the superior cerebellar artery (SCA), anterior inferior cerebellar artery (AICA), and posterior inferior cerebellar artery (PICA). (A) Dorsal view. (B) View of the cerebellum removed from the brainstem to reveal the ventral surface.

Vascular Supply to the Cerebellum

Blood supply to the cerebellum is provided by three branches of the vertebral and basilar arteries (see Figure 15.2):

1. The **posterior inferior cerebellar artery (PICA)**
2. The **anterior inferior cerebellar artery (AICA)**
3. The **superior cerebellar artery (SCA)**

The PICA usually arises from the vertebral artery, the AICA from the lower basilar, and the SCA from the top of the basilar, just below the posterior cerebral artery (see Figure 15.2; see also Figure 14.17).

As these arteries wrap around the brainstem, they supply portions of the lateral medulla and pons in addition to the cerebellum. The **posterior inferior cerebellar artery** supplies the lateral medulla, most of the inferior half of the cerebellum, and the inferior vermis (see Figures 15.2, 15.12, 15.13A,B). Recall from Chapter 14 that a variable portion of the lateral medulla is also supplied by branches of the vertebral artery (see Figure 14.20D). The **anterior inferior cerebellar artery** supplies the inferior lateral pons, the middle cerebellar peduncle, and a strip of the ventral (anterior) cerebellum between the territories of the PICA and the SCA, including the flocculus (see Figures 15.12, 15.13B,C; see also Figure 14.20C). The **superior cerebellar artery** supplies the upper lateral pons, the superior cerebellar peduncle, most of the superior half of the cerebellar hemisphere, including the deep cerebellar nuclei, and the superior vermis (see Figures 15.12, 15.13C,D; see also Figure 14.20B).

Figure 15.13 Vascular Territories of the Cerebellar Arteries Reviewed in Axial Sections (A) Caudal cerebellum and mid-medulla. (B) Caudal cerebellum and rostral medulla. (C) Mid-cerebellum and mid-pons. (D) Rostral pons and rostral cerebellum. PICA, posterior inferior cerebellar artery; AICA, anterior inferior cerebellar artery; SCA, superior cerebellar artery.

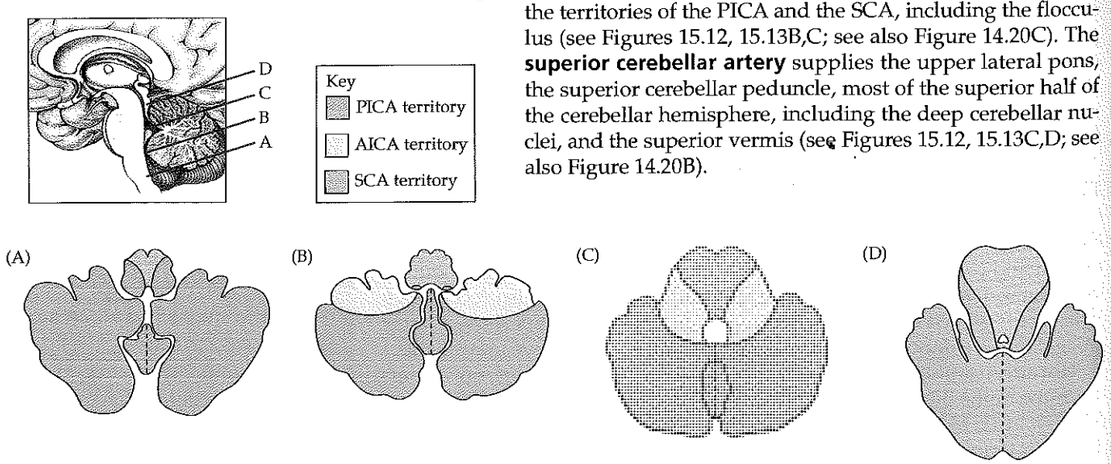

15.1 Infarcts are more common in the PICA and SCA territories than in the AICA territory. Patients with cerebellar infarcts typically present with vertigo, nausea and vomiting, horizontal nystagmus, limb ataxia (see KCC 15.2), unsteady gait, and headache, which can be occipital, frontal, or in the upper cervical regions. In addition, as we saw in Chapter 14 (see KCC 14.3), many of the important clinical symptoms and signs of cerebellar artery infarcts often result from infarction of the lateral medulla or pons, rather than the cerebellum itself. These include trigeminal and spinothalamic sensory loss, Horner's syndrome, and other findings. Note that infarction of the lateral medulla or pons can cause ataxia because of involvement of the cerebellar peduncles, even if the cerebellum itself is spared.

Infarcts that spare the lateral brainstem and involve mainly the cerebellum itself are more common with SCA infarcts than with PICA or AICA infarcts. Therefore, infarcts causing unilateral (ipsilateral) ataxia with little or no brainstem signs are most commonly in the SCA territory. Infarcts in the PICA and AICA more often involve the lateral brainstem in addition to the cerebellum. In addition, infarcts of the lateral pons or medulla that spare the cerebellum can also sometimes occur, more commonly with the PICA and AICA than with the SCA. Possible mechanisms for infarcts that spare the cerebellum include anastomotic connections sparing the cerebellum, or selective occlusion of branches to the lateral brainstem with sparing of cerebellar branches.

Large cerebellar infarcts in the PICA or SCA territories can cause swelling of the cerebellum. The resulting compression of the fourth ventricle can cause hydrocephalus (see KCC 5.7). In addition, compression in the tight space of the posterior fossa (see Figure 15.1) is a life-threatening emergency because the respiratory centers and other vital brainstem structures may be compromised. Large cerebellar infarcts, therefore, often require surgical decompression of the posterior fossa, including resection of portions of the infarcted cerebellum. Hemorrhage into cerebellar white matter can also occur following an infarct and can cause brainstem compression. Once again, this highlights the importance of carefully evaluating patients who present with vertigo (see KCC 12.6). If vertigo is caused by a large PICA infarct sparing the brainstem, the seriousness of the condition may be overlooked until a few days after onset, when cerebellar swelling and posterior fossa compression develop.

Cerebellar hemorrhage, like spontaneous intraparenchymal hemorrhage in other brain regions, can occur in the setting of chronic hypertension, arteriovenous malformation, hemorrhagic conversion of an ischemic infarct, metastases, or other causes (see KCC 5.6). Patients usually present with headache, nausea, vomiting, ataxia, and nystagmus. If the hemorrhage is large, it can cause hydrocephalus (see KCC 5.7), accompanied by sixth-nerve palsies and impaired consciousness, and may eventually cause brainstem compression and death. Sometimes, cerebellar hemorrhage initially presents only with gastrointestinal symptoms of nausea and vomiting, a condition that has been termed "fatal gastroenteritis." Prompt identification and treatment of cerebellar hemorrhage is, therefore, crucial. Hydrocephalus can be treated with ventriculostomy (see KCC 5.7); however, this carries some risk of upward transtentorial herniation as the posterior fossa hemorrhage and edema expand. For large cerebellar hemorrhages, surgical evacuation of the hemorrhage, and decompression of the posterior fossa are often necessary. Patients with cerebellar hemorrhage who are treated promptly usually have a good functional outcome. ■

KEY CLINICAL CONCEPT
CEREBELLAR ARTERY INFARCTS AND CEREBELLAR HEMORRHAGE

REVIEW EXERCISES

Color the regions corresponding to the SCA, AICA, and PICA territories below:

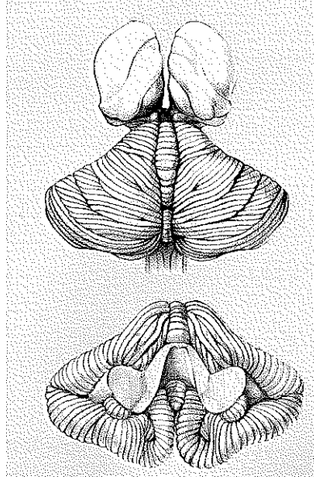

KEY CLINICAL CONCEPT
CLINICAL FINDINGS AND LOCALIZATION OF CEREBELLAR LESIONS

15.2 In this section we will discuss the clinical manifestations and localization of cerebellar lesions. First we will review basic definitions of ataxia and some simple localizing principles. Next we will discuss common symptoms and signs of cerebellar disorders and the expected findings on neurologic examination. Causes of cerebellar disorders are discussed in KCC 15.1 and 15.3. **Ataxia** means literally "lack of order." This term refers to the disordered contractions of agonist and antagonist muscles, and the lack of normal coordination between movements at different joints that is seen in patients with cerebellar dysfunction. As shown in Figure 15.14A, even simple movements require coordination of agonists and antagonists around multiple joints in order to follow a normal smooth path. In ataxia, the movements have an irregular, wavering course that seems to consist of continuous overshooting, overcorrecting, and then overshooting again around the intended trajectory (Figure 15.14B). Ataxic movements have abnormal timing (dysrhythmia) and abnormal trajectories through space (dysmetria). Let's review a few principles of localization with cerebellar lesions.

Truncal Ataxia versus Appendicular Ataxia

Lesions confined to the cerebellar vermis affect primarily the medial motor systems (see Table 15.1). Patients with such lesions therefore often have a

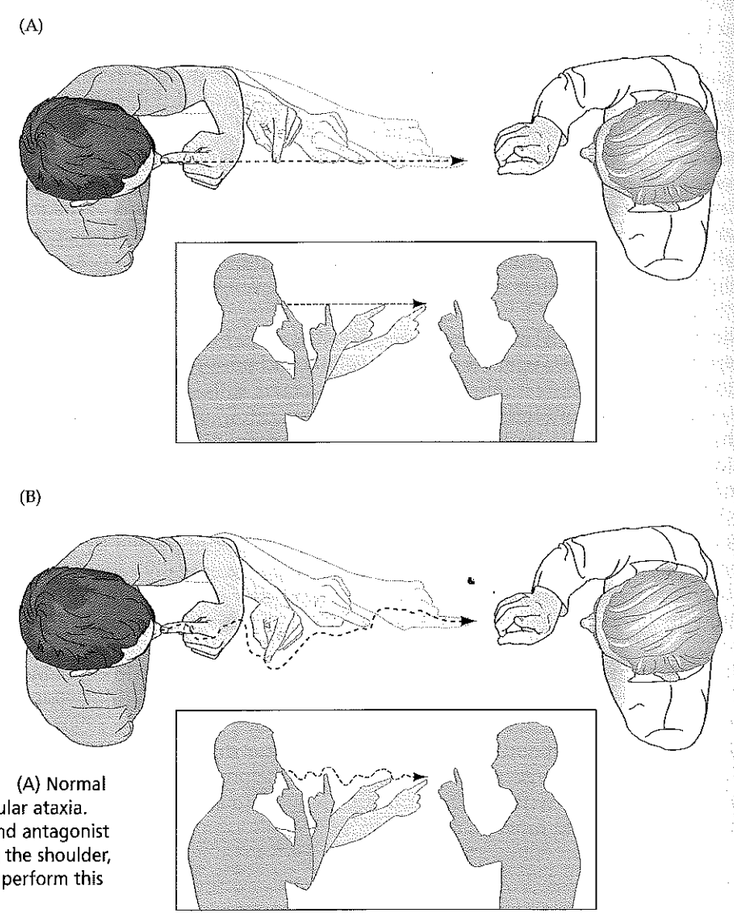

Figure 15.14 Finger–Nose–Finger Test (A) Normal individual. (B) An individual with appendicular ataxia. Note that coordinated actions of agonist and antagonist muscles acting on multiple joints, including the shoulder, elbow, and wrist, are required to smoothly perform this movement in a normal fashion.

wide-based, unsteady "drunklike" gait with no other significant abnormalities on exam. This condition is referred to as **truncal ataxia.** In severe truncal ataxia, patients may even have difficulty sitting up without support.

In contrast, lesions of the intermediate and lateral portions of the cerebellar hemisphere affect the lateral motor systems. Therefore, these patients have ataxia on movement of the extremities like that shown in Figure 15.14B, referred to as **appendicular ataxia.** Often lesions extend to involve both the vermis and the cerebellar hemispheres, and truncal and appendicular ataxia frequently coexist in the same patient. Interestingly, a unilateral lesion in the lateral portion of the cerebellar hemisphere (see Figure 15.3) may produce no appreciable deficit. More severe and lasting deficits are seen with lesions of the intermediate hemisphere, vermis, deep nuclei, or cerebellar peduncles.

Ipsilateral Localization of Ataxia

As we saw in the anatomical review earlier in this chapter, afferent and efferent cerebellar connections involved in the lateral motor systems either are ipsilateral or cross twice between the cerebellum and spinal cord (see Figures 15.9B, 15.11). Therefore, lesions of the cerebellar hemispheres cause ataxia in the extremities **ipsilateral** to the side of the lesion. Similarly, in lesions of the cerebellar peduncles, the ataxia is ipsilateral to the lesion. In contrast, cerebellar lesions affecting the medial motor system cause truncal ataxia, which is a bilateral disorder. Nevertheless, patients with truncal ataxia often tend to fall or sway toward the side of the lesion.

False Localization of Ataxia

Ataxia is often caused by lesions outside the cerebellum that involve the cerebellar input or output pathways. **Lesions of the cerebellar peduncles or pons** can produce severe ataxia, even without involvement of the cerebellar hemispheres. **Hydrocephalus,** which may damage frontopontine pathways, and **lesions of the prefrontal cortex** can both result in gait abnormalities that resemble cerebellar truncal ataxia, as can **disorders of the spinal cord.**

Ataxia-hemiparesis is a syndrome often caused by lacunar infarcts (see KCC 10.4; Table 10.3), in which patients have a combination of unilateral upper motor neuron signs and ataxia, usually affecting the same side. In ataxia-hemiparesis, the ataxia and hemiparesis are both usually contralateral to the side of the lesion. Ataxia-hemiparesis is most often caused by lesions in the corona radiata, internal capsule, or pons that involve both corticospinal and corticopontine fibers. However, it can also be seen in lesions of the frontal lobes, parietal lobes, or sensorimotor cortex, or in midbrain lesions that involve fibers of the superior cerebellar peduncle or red nucleus (see KCC 14.3).

Sensory ataxia occurs when the posterior column–medial lemniscal pathway is disrupted, resulting in loss of joint position sense. Patients with sensory ataxia may have ataxic-appearing overshooting movements of the limbs, and a wide-based, unsteady gait resembling that of patients with cerebellar lesions. Unlike cerebellar patients, however, these patients have impaired joint position sense on exam. In addition, sensory ataxia can be improved significantly with visual feedback, and is worse with the eyes closed or in the dark. Sensory ataxia is usually caused by lesions of the peripheral nerves or posterior columns, which if one-sided, result in ipsilateral ataxia. However, it is also occasionally seen in lesions of the thalamus, thalamic radiations, or somatosensory cortex, which cause contralateral ataxia.

Symptoms and Signs of Cerebellar Disorders

Cerebellar disorders affect medial motor systems, lateral motor systems, eye movements, vestibular pathways, and other circuits, resulting in characteristic symptoms as well as specific findings on neurologic examination.

Symptoms of Cerebellar Disorders. Patients with cerebellar lesions often complain of nausea, vomiting, vertigo, slurred speech, unsteadiness, or uncoordinated limb movements. Headache may occur in the occipital, frontal, or upper cervical areas and is usually on the side of the lesion. Lesions causing incipient tonsillar herniation (see KCC 5.4) can cause depressed consciousness, brainstem findings, hydrocephalus, or head tilt. Head tilt is also seen in cerebellar lesions extending to the anterior medullary velum (see Figures 12.2B, 15.1), which may affect the trochlear nerves.

Other Abnormalities Can Confound the Cerebellar Exam. When examining a patient with a suspected cerebellar disorder, it is essential to first look carefully for upper or lower motor neuron signs, sensory loss, or basal ganglia dysfunction. Abnormalities in these other systems will significantly affect cerebellar testing. **Upper motor neuron** findings make the exam more difficult, since both corticospinal and cerebellar lesions can cause slow, clumsy movements of the extremities. In addition, if there is severe upper or **lower motor neuron** weakness, cerebellar testing may not be possible. Some tests that require little strength may be helpful, such as repeatedly tapping the tip of the index finger to the crease of the thumb and looking at accuracy (see neuroexam.com Video 63). In cerebellar disorders, the tip of the index finger tends to hit a different spot on the thumb each time. **Loss of joint position sense** can cause sensory ataxia. However, the loss of position sense must be severe for significant ataxia to be present, and as mentioned already, sensory ataxia usually improves with visual feedback. **Movement disorders** (see KCC 16.1) such as parkinsonism associated with basal ganglia dysfunction can cause slow, clumsy movements, or gait unsteadiness, which can confound the cerebellar exam. Other movement disorders such as tremor or dyskinesias also make interpretation of cerebellar testing more difficult. We will discuss the typical exam findings in patients with basal ganglia disorders, and how they differ from cerebellar disorders, in Chapter 16.


Precision finger tap

Testing for Appendicular Ataxia. Numerous tests can be used to detect appendicular ataxia. These were discussed in Chapter 3 and are demonstrated through video segments on neuroexam.com. Most abnormalities can be described as a combination of dysmetria and dysrhythmia. **Dysmetria** is abnormal undershoot or overshoot (also known as past pointing) during movements toward a target. **Dysrhythmia** is abnormal rhythm and timing of movements. The best-known tests for ataxia are the finger–nose–finger test and the heel–shin test.

Finger–nose–finger

In the finger–nose–finger test (see neuroexam.com Video 64), the patient touches their nose and then the examiner's finger alternately (see Figure 15.14). The examiner can increase the sensitivity of this test by holding the target finger at the limit of the patient's reach, and by moving the target finger to a different position each time the patient touches their nose.

In the heel–shin test (see neuroexam.com Video 65) the patient rubs his heel up and down the length of his shin in as straight a line as possible. This test should be done supine so that gravity does not contribute to the downward movement. Variations include tapping the heel repeatedly on the same spot just below the knee, or doing a test similar to the finger–nose–finger test, with the patient's foot alternately touching their knee and the examiner's finger.

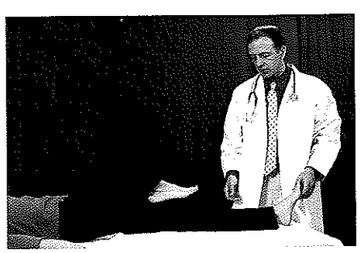
Heel–shin test

Rapid tapping of the fingers together, of the hand on the thigh (see neuroexam.com Video 52), or of the foot on the floor (see neuroexam.com Video 53) are good tests for dysrhythmia. In addition, testing the accuracy of tapping the tip of the index finger on the thumb crease (see neuroexam.com Video 63) can be useful for identifying both dysmetria and dysrhythmia. Abnormalities of other rapid alternating movements, such as alternately tapping one hand with the palm and dorsum of the other hand (see neuroexam.com Video 62) have been called **dysdiadochokinesia** or adiadochokinesia.

The examiner can test for **overshoot,** or **loss of check,** by having the patient raise both arms suddenly from their lap or lower them suddenly to the level of the examiner's hand (see neuroexam.com Video 66). Alternatively, the examiner can apply pressure to the patient's outstretched arms and then suddenly release it. Cerebellar lesions can be associated with an irregular large-amplitude **postural tremor** that occurs when the limb muscles are activated to hold a particular position—for example, both arms held outstretched. This characteristic postural tremor seen in disorders of the cerebellar pathways has been called a **rubral tremor** in the past, although more recently the involvement of the red nucleus has been questioned. In addition, the appendicular ataxia during movements toward a target that was described earlier (see Figure 15.14B) is sometimes referred to as an **action** or **intention tremor.** Tremors are discussed further in Chapter 16. Cerebellar disorders are also often associated with **myoclonus,** a sudden rapid-movement disorder that is discussed in Chapter 16 as well (see KCC 16.1).

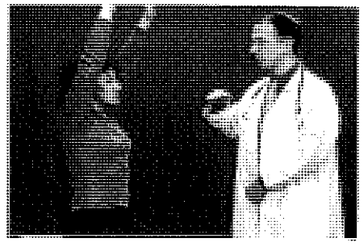
Overshoot

Testing for Truncal Ataxia. Patients with truncal ataxia have a **wide-based, unsteady gait** that resembles the gait of a drunk or of a toddler learning to walk (see also KCC 6.5; Table 6.6). This resemblance is not just coincidental: Alcohol impairs cerebellar function, and cerebellar pathways are not yet fully myelinated in infancy. Truncal ataxia can be demonstrated by having the patient perform a **tandem gait,** in which the heel touches the toe with each step, forcing the patient to assume a narrow stance (see neuroexam.com Video 68). Patients tend to fall or to deviate during their walking toward the side of the lesion. The **Romberg test** (see neuroexam.com Video 67) can also be helpful in identifying truncal ataxia and may help differentiate cerebellar lesions from lesions of the vestibular or proprioceptive systems (see Chapter 3). A peculiar tremor of the trunk or head, called **titubation,** can occur with midline cerebellar lesions.

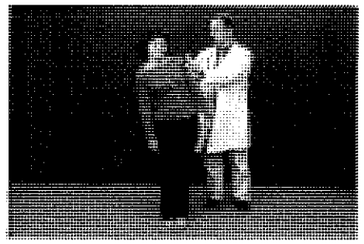
Romberg test

Eye Movement Abnormalities. Patients with cerebellar lesions may exhibit **ocular dysmetria,** in which saccades overshoot or undershoot their target. **Slow saccades** are present in some degenerative conditions of the cerebellum. In addition, during attempted smooth pursuit eye movements there may be jerky saccadic intrusions, particularly when the flocculonodular lobe is involved. **Nystagmus** is often present, usually of the gaze paretic type, meaning that when the patient looks toward a target in the periphery, slow phases occur toward the primary position and fast phases occur back toward the target. Unlike the nystagmus in peripheral vertigo, the nystagmus in cerebellar lesions may change directions depending on the direction of gaze (see Table 12.7). Vertical nystagmus may also be present in cerebellar disorders.

In normal individuals the vestibulo-ocular reflex (see Chapter 13) is often suppressed by visual inputs. For example, when normal individuals read a newspaper while riding a train as it pulls into the station, their eyes do not jump off the page even though their inner ears detect a large deceleration. This normal **suppression of the vestibulo-ocular reflex (VOR) can be impaired** in cerebellar lesions, particularly if the flocculonodular lobe is involved. A good way to test for such impairment is to have the patient fixate on their thumbs, held together at arm's length, and then to ask the patient to rotate their upper body while attempting to maintain fixation on their thumbs. Normal patients exhibit no nystagmus during this test, but nystagmus occurs in patients with impaired suppression of the VOR. The

same test can be done with adults in a swivel chair, or with pediatric patients by picking them up and turning them from side to side while they fixate on the examiner's face.

Paraneoplastic cerebellar disorders, encephalitis, and some other conditions can be associated with unusual eye movements called opsoclonus or ocular flutter, in which the eyes show brief bursts of oscillating movements during fixation.

Speech Abnormalities. Speech can have an ataxic quality in cerebellar disorders, with irregular fluctuations in both rate and volume. This is sometimes called **scanning** or **explosive speech**. Instead of ataxic speech, cerebellar dysfunction can also cause speech to be slurred and difficult to understand. Alcohol intoxication once again provides a good example of this phenomenon.

Other Findings. Muscle tone may be somewhat decreased in cerebellar disease, and reflexes can have a "pendular" quality. These findings are often not emphasized in the setting of other, more dramatic abnormalities caused by cerebellar lesions. Recent evidence suggests the possibility of cognitive disturbances in patients with cerebellar lesions. This is currently under investigation. ■

KEY CLINICAL CONCEPT
DIFFERENTIAL DIAGNOSIS OF ATAXIA

15.3 Ataxia can be caused by a wide variety of disorders. The differential diagnosis depends on the age of the patient and on the time course of evolution of the ataxia. In adults (Table 15.4A) the most common causes of acute ataxia are toxin ingestion and ischemic or hemorrhagic stroke. Chronic ataxia in adults is often caused by brain metastases, chronic toxin exposure (especially to alcohol), multiple sclerosis, or degenerative disorders of the cerebellum and cerebellar pathways. In the pediatric population (Table 15.4B), acute ataxia is most often caused by accidental drug ingestion, varicella-associated cerebellitis, or migraine. Chronic or progressive ataxia in children can be caused by cerebellar astrocytoma, medulloblastoma, Friedreich's ataxia, ataxia-telangiectasia, or a variety of other conditions (see Table 15.4). ■

TABLE 15.4A Differential Diagnosis of Ataxia in Adults

ACUTE OR RECURRENT ATAXIA	CHRONIC OR PROGRESSIVE ATAXIA
Toxin ingestion Ethanol; anticonvulsants; other medications	Cerebellar or other metastasis Lung carcinoma; breast carcinoma; melanoma; other tumors
Ischemic stroke	Multiple sclerosis
Hemorrhagic stroke	Chronic toxin exposure Alcohol/nutritional deprivation; phenytoin; mercury; thallium; toluene (glue, spray paint)
Basilar migraine	Degenerative disorders Olivopontocerebellar atrophy; Machado–Joseph disease (SCA-3);[a] dentatorubropallidoluysian atrophy (DRPLA); other spinocerebellar ataxias
Benign paroxysmal vertigo	Progressive multifocal leukoencephalopathy (PML)
Conversion disorder	Toxoplasmosis
Postconcussion syndrome	Creutzfeldt–Jakob disease
Traumatic hematoma	Arteriovenous malformation
Multiple sclerosis	Paraneoplastic syndrome (especially in breast or ovarian cancer)
Infectious or postinfectious cerebellitis	Wilson's disease
Brainstem encephalitis	Vitamin E deficiency
Miller Fisher Guillain–Barré variant	Adult forms of disorders listed in Table 15.4B
Wernicke's encephalopathy	
Toxoplasmosis	
Brain abscess	
Brain tumor (usually chronic)	
Hereditary episodic ataxias	
Metabolic disorders Hartnup disease; maple syrup urine disease; pyruvate dehydrogenase deficiency	
Paraneoplastic syndrome (especially in breast or ovarian cancer)	

TABLE 15.4B Differential Diagnosis of Ataxia in Infants and Children

ACUTE OR RECURRENT ATAXIA	CHRONIC OR PROGRESSIVE ATAXIA
Toxin ingestion Anticonvulsants; other medications; ethanol	Posterior fossa tumors Medulloblastoma; cerebellar astrocytoma; ependymoma; hemangioblastoma; pontine glioma
Infectious or postinfectious cerebellitis	Congenital malformations Dandy–Walker malformation; cerebellar aplasias; chiari malformation
Brainstem encephalitis	Degenerative disorders Friedreich's ataxia; ataxia-telangiectasia; olivopontocerebellar atrophy; Machado–Joseph disease (SCA-3);[a] dentatorubropallidoluysian atrophy (DRPLA)
Basilar migraine	Multiple sclerosis
Benign paroxysmal vertigo	Metabolic disorders Abetalipoproteinemia; adrenoleukodystrophy; juvenile GM_2 gangliosidosis; juvenile sulfatide lipidosis; Hartnup disease; maple syrup urine disease; pyruvate dehydrogenase deficiency; Marinesco–Sjögren syndrome; Ramsay Hunt syndrome; respiratory chain disorders; sea-blue histiocytosis
Conversion disorder	
Postconcussion syndrome	
Traumatic hematoma	
Epileptic pseudoataxia	
Brain tumor (usually presents as chronic progressive ataxia)	
Hereditary episodic ataxias	
Metabolic disorders Hartnup disease; maple syrup urine disease; pyruvate dehydrogenase deficiency	
Neuroblastoma syndrome	
Miller Fisher Guillain–Barré variant	
Multiple sclerosis	
Hemorrhagic stroke	
Ischemic stroke	
Kawasaki disease	

[a]SCA-3, spinal cerebellar ataxia, type 3.

Source: After Fenichel, GM. 1997. *Clinical Pediatric Neurology: A Signs and Symptoms Approach*, 3rd Ed. Saunders, Philadelphia.

CLINICAL CASES

CASE 15.1 SUDDEN ONSET OF UNILATERAL ATAXIA

MINICASE

A 70-year-old semiretired janitor with a history of hypertension went to work one morning and at 7:00 AM had sudden onset of **nausea, vomiting, and unsteadiness.** He was taken to the emergency room, where his exam was notable for **mildly slurred speech with slowed tongue movements, dysmetria on finger-to-nose testing on the left, dysmetria on heel-to-shin testing on the left, and left dysdiadochokinesia.** Upon **attempting to stand, he fell to the left,** even when he kept his eyes open. The remainder of the exam was unremarkable.

LOCALIZATION AND DIFFERENTIAL DIAGNOSIS

1. On the basis of the symptoms and signs shown in **bold** above, where is the lesion?
2. What is the most likely diagnosis, and what are some other possibilities?

Discussion

The key symptoms and signs in this case are:

- **Left arm and leg ataxia**
- **Unsteadiness, falling to the left**
- **Slurred speech**
- **Nausea and vomiting**

1. This patient had marked appendicular ataxia of the left arm and leg, as well as probable truncal ataxia, causing him to fall to the left side. One possible explanation is an ipsilateral cerebellar lesion involving the left cerebellar hemisphere, extending to the vermis. Another possibility is a lesion of one of the left cerebellar peduncles, which would cause left appendicular ataxia and truncal ataxia. Nausea and vomiting (caused by involvement of cerebellar-vestibular circuits) and slurred speech are also common in cerebellar lesions (see KCC 15.2). Lesions in other locations that cause ataxia are also possible (see KCC 15.2) but would most likely have other associated signs, such as hemiparesis or brainstem findings.

   The most likely *clinical localization* is left cerebellar hemisphere and vermis, or left superior, middle, or inferior cerebellar peduncle.
2. Given the patient's age, history of hypertension, and the sudden onset of symptoms, the most likely diagnosis is an infarct of the left cerebellum. Of the cerebellar arteries, a left superior cerebellar infarct would be most likely to cause pronounced ipsilateral ataxia without other brainstem findings (see KCC 15.1). Another possibility is a cerebellar hemorrhage involving mainly the left cerebellar hemisphere. Less likely possibilities include a left cerebellar abscess or one of the other diagnoses listed in Table 15.4. An acute lesion confined to a cerebellar peduncle is unlikely, although a lesion extending from the left cerebellar hemisphere to one of the left cerebellar peduncles is possible.

Clinical Course and Neuroimaging 678

The patient was admitted, and a **brain MRI** (Figure 15.15) revealed an infarct in the left superior cerebellar artery territory, involving the left superior cerebellar peduncle and the left superior cerebellar hemisphere (compare to Figures 15.12 and 15.13C,D). He was treated with intravenous heparin while an embolic workup (see KCC 10.4) was pursued. This workup included a transesophageal echocardiogram, 24-hour Holter monitor, transcranial Doppler studies, and MRA, none of which revealed an obvious embolic source. His ataxia gradually improved, and 1 week later he had normal speech, with minimal left ataxia, and was ambulating with assistance from a physical therapist. He was entered into a randomized trial of aspirin versus Coumadin therapy to prevent recurrent stroke in patients with stroke of unknown cause.

Related Cases. Figure 15.16A shows an MRI from a different patient, who had bilateral superior cerebellar artery infarcts. This coronal image nicely outlines the SCA territories, with sparing of the PICA territories, inferiorly. The precise SCA and PICA boundaries are variable, but it is possible that the right PICA was involved as well (compare to Figure 15.12). This patient had severe vertebrobasilar disease and ultimately died. Note that infarcts in the PCA territory were present as well (see Figure 15.16A), suggesting that these strokes were caused by disease of the basilar artery (see KCC 14.3).

Figure 15.16B shows an axial MRI image from a patient with bilateral posterior inferior cerebellar artery (PICA) infarcts. Note the sparing of the AICA territories (compare to Figure 15.13B). Recall that the posterior fossa is a small, tight compartment and that large infarcts of the cerebellum present a high risk for brainstem compression and herniation. Therefore, surgical decompression is sometimes required.

CASE 15.2 WALKING LIKE A DRUNKARD

MINICASE

A 76-year-old man with a history of cigarette smoking developed progressive **difficulty walking** over the course of 1 month. He noticed that when he stood up he felt "woozy," and he described his gait as feeling like he was drunk, saying "my legs go one way, and I go the other." His family said he frequently lost his balance, with **staggering and unsteadiness.** He also had frequent mild **headaches** that occurred at any time of the day and night and seemed to be getting worse. Exam was unremarkable except for a **wide-based, unsteady gait, tending to fall to the left, especially with tandem walking.** Of note, there was no ataxia on finger-to-nose or heel-to-shin testing, and rapid alternating movements were normal. There was no history of alcohol intake.

LOCALIZATION AND DIFFERENTIAL DIAGNOSIS

1. On the basis of the symptoms and signs shown in **bold** above, where is the lesion?
2. What is the most likely diagnosis, and what are some other possibilities?

Discussion

The key symptoms and signs in this case are:

- **Unsteady gait, wide-based, falling to the left, especially with tandem walking**
- **Headache**

1. The patient had truncal ataxia, with no significant appendicular ataxia. This symptom may be caused by a lesion of the cerebellar vermis. Other possibilities of this gait disorder include hydrocephalus or a lesion of the frontal lobes or spinal cord (see KCC 15.2; see also KCC 6.5), although additional abnormalities on exam are often (but not always) present with these disorders. The presence of headache suggests that the lesion is intracranial (see KCC 5.1).

   The most likely *clinical localization* is cerebellar vermis.
2. Given the history of cigarette smoking and the gradual onset of symptoms, metastatic lung cancer to the cerebellar vermis should be seriously considered. Other important causes of chronic ataxia in adults are listed in Table 15.4A. In addition, as already mentioned, the patient's gait abnormalities could possibly be caused by hydrocephalus or by lesions of the frontal lobe or spinal cord.

CASE 15.1 SUDDEN ONSET OF UNILATERAL ATAXIA

Figure 15.15 Left Superior Cerebellar Artery (SCA) Infarct (A) Axial, diffusion-weighted MRI at the level of the superior cerebellum and rostral pons. A bright region of decreased diffusion coefficient, consistent with infarction is visible in the left superior cerebellar peduncle and left superior cerebellum. (B) Axial, T2-weighted MRI at the level of the mid to upper pons and cerebellum. A T2-bright region, consistent with infarction, is seen in the left superior cerebellar hemisphere.

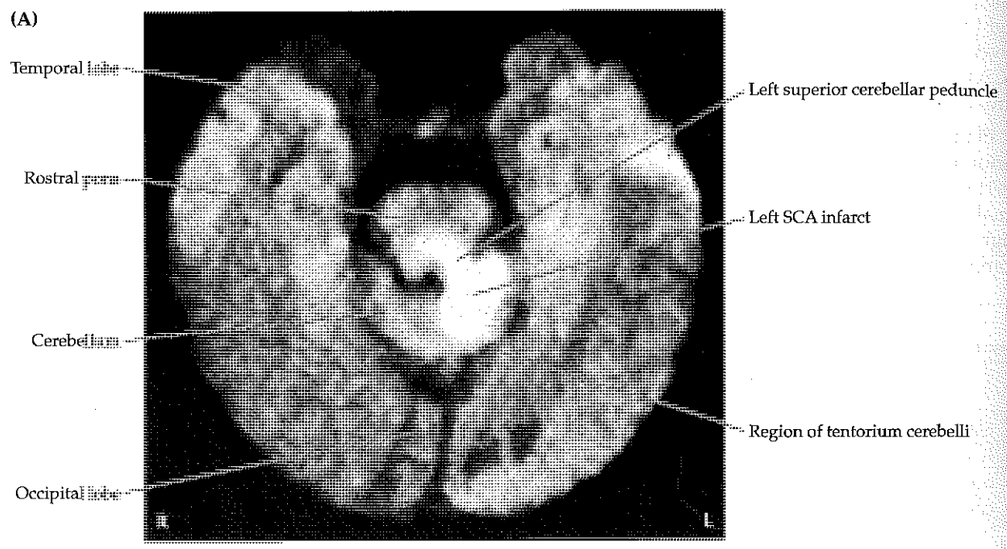

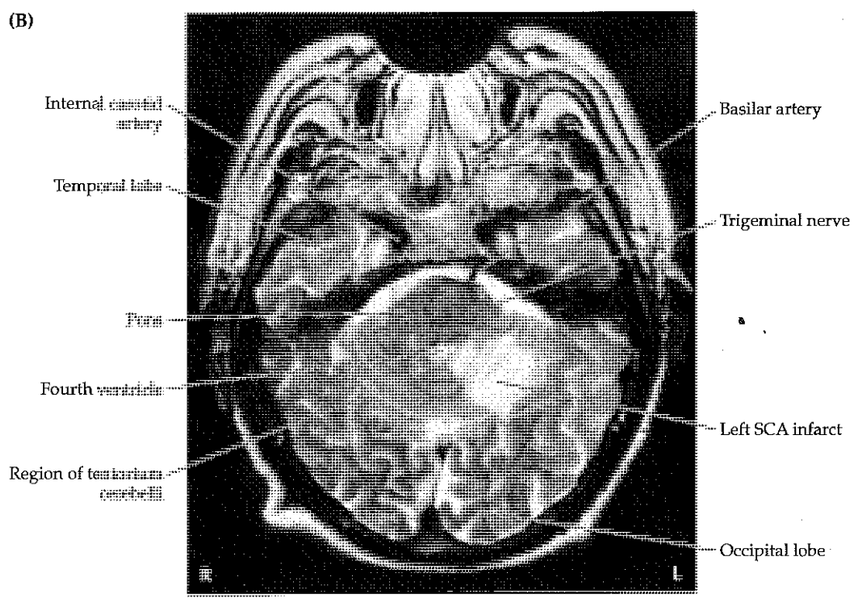

CASE 15.1 RELATED CASES

Figure 15.16 Superior Cerebellar Artery (SCA) and Posterior Inferior Cerebellar Artery (PICA) Infarcts (A) Coronal, T2-weighted MRI in a patient with bilateral SCA infarcts. (B) Axial, T2-weighted MRI in a patient with bilateral PICA infarcts.

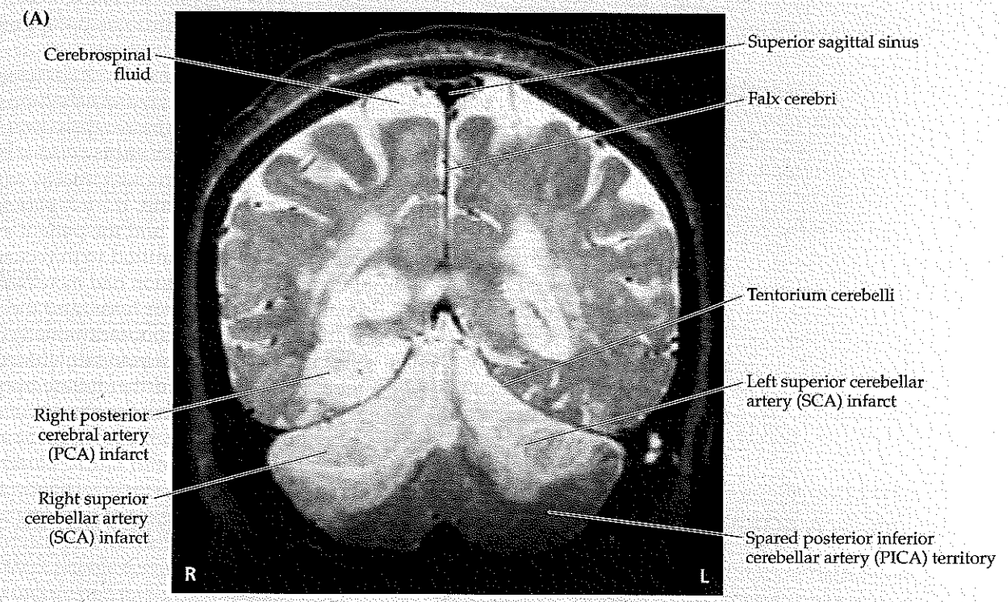

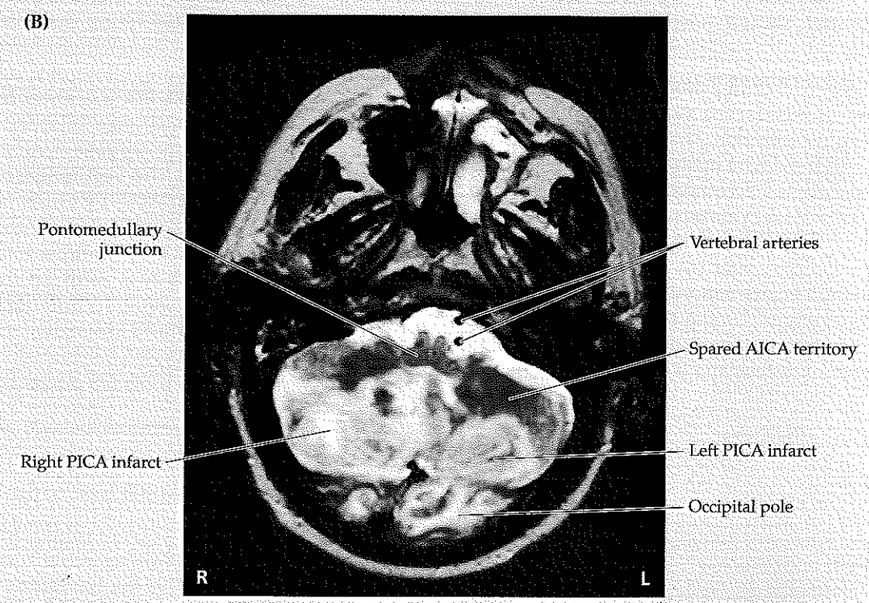

Clinical Course and Neuroimaging 683

A **head CT** with intravenous contrast (Figure 15.17) revealed an enhancing, cystic lesion in the cerebellar vermis. Although the patient often fell to the left on exam, the lesion did not have any obvious asymmetries. This case demonstrates that lesions of the cerebellar vermis can cause truncal ataxia manifesting mainly as a gait abnormality with little or no appendicular ataxia (see KCC 15.2).

On admission, a chest X-ray revealed a left apical 2 to 3 cm opacity, and prominence of the left pulmonary hilum. A CT-guided needle biopsy of the lung lesion showed adenocarcinoma. An MRI of the brain again demonstrated the vermian lesion, but it also showed a small area of enhancement in the left parietal lobe. The patient initially refused surgery and was treated with radiation therapy and steroids as an outpatient. As a result, the left parietal lesion disappeared, the vermian lesion decreased in size, and the patient's gait improved. Four months later, however, he was readmitted with recurrent gait difficulty, and imaging showed that the vermian lesion had increased in size. He consented to surgery to decompress the posterior fossa, and the vermian lesion was resected, with pathology showing adenocarcinoma. Postoperatively he had some dysmetria, which gradually improved. Unfortunately, metastatic carcinoma is not curable, and although further follow-up information is not available, he presumably eventually died of his illness.

CASE 15.3 A BOY WITH HEADACHES, NAUSEA, SLURRED SPEECH, AND ATAXIA

CHIEF COMPLAINT

A 13-year-old boy was brought to the pediatrician's office because of 2 months of progressive left occipital headaches, nausea, slurred speech, and unsteadiness.

HISTORY

The patient was well until 2 months previously, when he began having headaches, which were initially attributed to a sinus infection. The headaches gradually worsened, with **headache mainly in the left occipital area,** and sometimes accompanied by **nausea and vomiting,** but no visual changes. The headaches were worse at night and in the early morning hours. His teachers noticed that over the past few months he had had some **difficulty concentrating** and learning new material at school. During the week prior to presentation his mother noted **increasing gait instability and mildly slurred speech** and decided to bring him to the pediatrician.

PHYSICAL EXAMINATION

Vital signs: T = 98°F, P = 90, BP = 130/88, R = 16.
Neck: Supple.
Lungs: Clear.
Heart: Regular rate with no murmurs.
Abdomen: Soft, nontender.
Extremities: Normal.

Neurologic exam:

MENTAL STATUS: Alert and oriented ×3. Speech fluent, with normal repetition and comprehension.

CRANIAL NERVES: Pupils equal round and reactive to light. Visual fields full. **Fundi had blurred disc margins (mild papilledema) bilaterally.** Extraocular movements were full, but there was **horizontal nystagmus on lateral gaze bilaterally, and vertical nystagmus on upgaze worse than downgaze.** In addition, the **vestibulo-ocular reflex was not fully suppressed by visual fixation.** Facial sensation and corneal reflexes intact. Face symmetrical. Hearing intact to whisper bilaterally. **Speech slightly slurred and with an irregular rate.** Normal palate movements and gag reflex. Normal sternomastoid and trapezius strength. Tongue midline.

MOTOR: No drift. Normal tone. 5/5 power throughout.

REFLEXES:

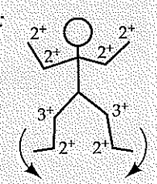

CASE 15.3 *(CONTINUED)*

COORDINATION: **Marked dysmetria on finger-to-nose testing, worse on the left, with approximately 2 inches of error.** There was also **dysdiadochokinesia, with inaccurate rapid alternating movements, worse on the left side. Heel-to-shin movements were ataxic on the left** but normal on the right.

GAIT: **Wide-based, with feet approximately 2 feet apart, and unsteady, staggering to the left. Unable to perform tandem gait.** On the Romberg test with feet 4 inches apart there was no worsening of unsteadiness (unable to stand with feet together even with eyes open).

SENSORY: Intact light touch, pinprick, vibration, and joint position sense. Intact graphesthesia and stereognosis.

LOCALIZATION AND DIFFERENTIAL DIAGNOSIS

1. On the basis of the symptoms and signs shown in **bold** above, where is the lesion?
2. What is the most likely diagnosis, and what are some other possibilities?

Discussion

1. The key symptoms and signs in this case are:
   - **Left greater than right arm and leg ataxia**
   - **Unsteady gait, wide-based, staggering to the left**
   - **Slurred speech, with an irregular rate**
   - **Bilateral horizontal nystagmus on lateral gaze, and vertical nystagmus on upgaze worse than downgaze**
   - **Vestibulo-ocular reflex not fully suppressed by visual fixation**
   - **Left occipital headache**
   - **Nausea and vomiting**
   - **Difficulty concentrating**
   - **Bilateral papilledema**

   This patient had multiple symptoms and signs suggesting diffuse cerebellar dysfunction. The left-sided appendicular ataxia is consistent with a lesion in the left cerebellar hemisphere, while the truncal ataxia suggests involvement of the vermis. The patient also had ataxic speech and typical eye movement abnormalities seen in cerebellar lesions, including impaired suppression of the vestibulo-ocular reflex (see KCC 15.2). The left occipital headache, nausea, and vomiting also fit with a left cerebellar lesion. However, when seen together with papilledema and difficulty concentrating, these symptoms strongly suggest elevated intracranial pressure (see KCC 5.3). Elevated intracranial pressure in cerebellar lesions is commonly due to compression of the fourth ventricle causing hydrocephalus (see KCC 5.7).

   The most likely *clinical localization* is a large left cerebellar lesion with associated noncommunicating hydrocephalus.
2. The slowly progressive course in this child suggests a tumor of the posterior fossa, such as cerebellar astrocytoma or medulloblastoma (see KCC 5.8). Given this patient's age, an astrocytoma would be somewhat more likely since medulloblastoma occurs in the first decade about 90% of the time, while it is not uncommon for cerebellar astrocytoma to occur after age 10. Other, less likely possibilities are listed in Table 15.4B.

Clinical Course and Neuroimaging 684

A **brain MRI** (Figure 15.18) showed an enhancing mass in the cerebellum with a large, fluid-filled cyst occupying almost the entire left cerebellum. A cyst with a mural nodule of this kind is typical of cerebellar astrocytoma (see KCC 5.8). The fourth ventricle was compressed (see Figure 15.18A), and hydrocephalus was present, with dilation of the lateral and third ventricles (see

Figure 15.18B). The patient was admitted to the hospital and started on steroids to reduce swelling. Surgery was performed 2 days after admission. A midline incision was made over the occipital bone. A bone flap was temporarily removed to gain access to the posterior fossa, and the dura over the cerebellum opened, revealing tumor and cyst in the vermis extending into the left cerebellum more than the right. All visible tumor was carefully removed, and the cyst was drained. Pathology was consistent with juvenile pilocytic astrocytoma. This is a histologically benign lesion that, unlike medulloblastoma (see Case 5.7), can often be cured by resection alone (see KCC 5.8). The patient did very well postoperatively, but he did have some residual left greater than right ataxia.

CASE 15.4 NAUSEA, PROGRESSIVE UNILATERAL ATAXIA, AND RIGHT FACE NUMBNESS

MINICASE

A 72-year-old right-handed woman with a history of heavy cigarette smoking came to see an internist because of several months of worsening **nausea and vomiting.** Gastroenterology evaluation had revealed a hiatal hernia, and she was being treated with antiemetics with little benefit. On discussion of her overall symptoms, it became clear that about 2 months previously she noticed her **handwriting was deteriorating,** becoming less precise. Later, she noted some difficulty opening bottles with her right hand, as if she "didn't have good control," and difficulty putting on her earrings. She also was **slightly unsteady,** slipping more frequently than usual on the ice. Most recently she had noticed that the **right side of her face felt cool.** She had lost 3 pounds over the past 2 months and had one episode of hemoptysis (blood-tinged sputum). She did not complain of headaches. On examination, she had **nystagmus on horizontal and vertical end gaze,** as well as **decreased temperature sensation in the right face.** She also had mild to moderate **ataxia on finger-to-nose and heel-to-shin testing on the right. On attempted tandem gait she fell to the right.** The remainder of the exam was normal.

LOCALIZATION AND DIFFERENTIAL DIAGNOSIS

1. On the basis of the symptoms and signs shown in **bold** above, where is the lesion?
2. Given the history of smoking and recent hemoptysis, what is the most likely diagnosis?

Discussion

The key symptoms and signs in this case are:

- **Nausea and vomiting**
- **Right arm and leg ataxia**
- **Mild unsteadiness, and inability to perform tandem gait, falling to the right**
- **Nystagmus on horizontal and vertical end gaze**
- **Right face cool paresthesias and decreased temperature sensation**

1. This patient has appendicular ataxia affecting the right arm and leg, as well as truncal ataxia with an unsteady tandem gait, falling to the right. These findings strongly suggest a right cerebellar lesion (see KCC 15.2). Nystagmus is also common in cerebellar disorders. Loss of temperature sensation in the right face suggests a lesion affecting the right spinal trigeminal nucleus or tract (see Figure 12.8; Table 12.6). The right middle and inferior cerebellar peduncles also pass by this region (see Figure 14.4C, 14.5A), which could explain the right-sided ataxia. Nausea and vomiting can have many causes, both neurologic and systemic. Lesions involving the cerebellum and its connections to the vestibular system, the vestibular system itself, or the chemotactic trigger zone (see Chapter 14) are particularly likely to cause nausea. Elevated intracranial pressure can also cause nausea and vomiting (see KCC 5.3), although there is no evidence of elevated intracranial pressure on the basis of history or physical examination in this patient.

CASE 15.2 WALKING LIKE A DRUNKARD

Figure 15.17 Lung Metastasis in the Cerebellar Vermis Axial head CT scan with intravenous contrast. An enhancing, cystic, lung carcinoma metastasis is visible in the midline cerebellar vermis.

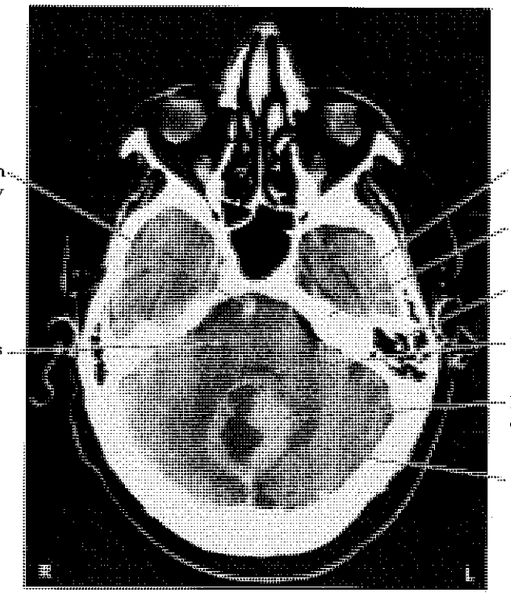

The most likely *clinical localization* is right middle cerebellar or inferior peduncle and right spinal trigeminal nucleus.

2. The history of weight loss and hemoptysis in a longtime smoker strongly suggests lung cancer. Lung cancer commonly metastasizes to the brain, so a metastasis to the right cerebellar peduncles is the most likely diagnosis in this patient. Other, less likely possibilities in this patient include primary neoplasm, infection, or vascular malformation.

Clinical Course and Neuroimaging 685

The internist ordered a **brain MRI** scan with gadolinium (Figure 15.19). An enhancing lesion was found in the right middle cerebellar peduncle. This case illustrates that ataxia is often caused by lesions outside the cerebellum proper, in the cerebellar peduncles, brainstem, or other locations in the cerebellar circuitry (see also the next section). This patient's clinical findings resemble, in some ways, that of the patient we discussed in Chapter 14 with a lateral pontine infarct in the AICA territory (see Case 14.4).

A second very small (5 mm) lesion was found on the lateral surface of the right cerebellum (not shown). On chest X-ray, a right peribronchial lesion was seen. A CT-guided needle biopsy of the peribronchial lesion revealed adenocarcinoma of the lung. Abdominal CT demonstrated another lesion in the adnexal area extending into the cervix. Cervical biopsy confirmed metastatic lung adenocarcinoma in this location as well. Because of the presence of multiple brain metastases, and the location of a major lesion extending into the brainstem (see Figure 15.19), resective neurosurgery was not per-

CASE 15.3 A BOY WITH HEADACHES, NAUSEA, SLURRED SPEECH, AND ATAXIA

Figure 15.18 Cerebellar Astrocytoma in the Vermis and Left Cerebellar Hemisphere Axial T1-weighted MRI images with intravenous gadolinium contrast enhancement, with images A, B progressing from inferior to superior. (A) Cystic lesion in the vermis and left cerebellar hemisphere, with enhancing mural nodule, compatible with cerebellar astrocytoma. Fourth ventricle is compressed. (B) Dilation of lateral and third ventricles with effacement of cortical sulci due to noncommunicating hydrocephalus.

(A)

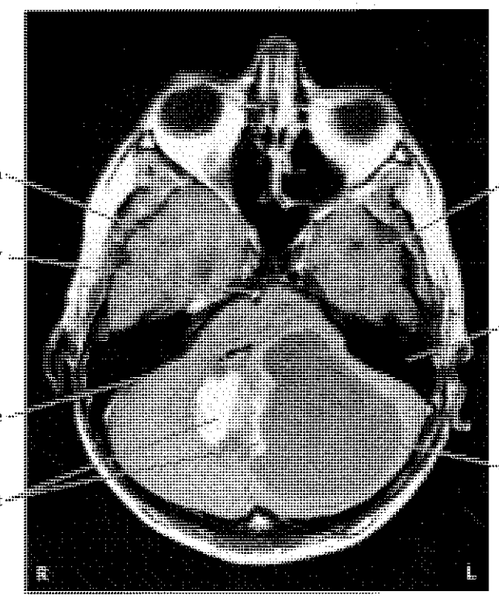

(B)

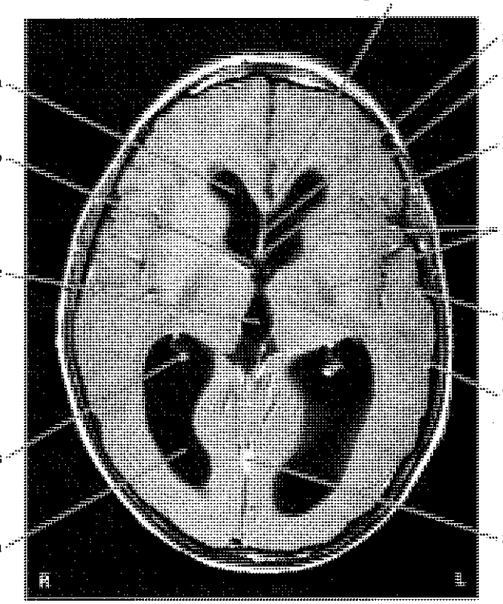

CASE 15.4 NAUSEA, PROGRESSIVE UNILATERAL ATAXIA, AND RIGHT FACE NUMBNESS

Figure 15.19 Metastasis of Lung Adenocarcinoma to the Right Middle Cerebellar Peduncle T1-weighted MRI images with intravenous gadolinium contrast. (A) Axial image demonstrating an enhancing lung adenocarcinoma metastasis in the right middle cerebellar peduncle. (B) Coronal view of the same region.

(A)

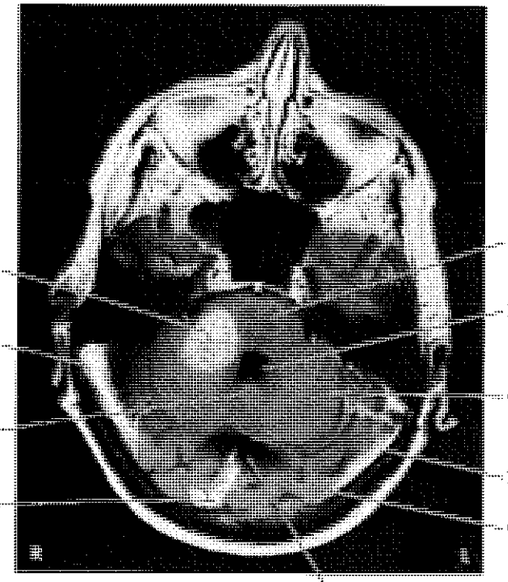

(B)

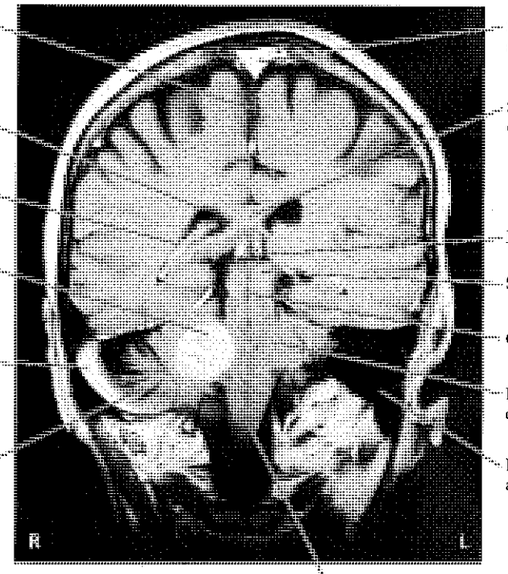

formed. The patient was treated with radiation therapy to the brain and chest and with steroids. She initially worsened with the radiation therapy, but then improved for a while before ultimately requiring admission to a specialized hospice facility for patients with terminal cancer.

Additional Cases

Related cases can be found in other chapters for the following topics: **brainstem lesions associated with ataxia** (Cases 14.1, 14.4, 14.7); **ataxia in childhood** (Case 5.7); and **ataxic-appearing gait** (Cases 5.9, 7.6). Other relevant cases can be found using the **Case Index**.

Brief Anatomical Study Guide

1. The cerebellum is located in the posterior fossa (see Figure 15.1). It consists of the midline **vermis**, the **intermediate part of the cerebellar hemisphere** and the **lateral part of the cerebellar hemisphere** (see Figure 15.3A). The cerebellum is attached to the brainstem by the **superior, middle, and inferior cerebellar peduncles**, which contain the input and output fibers of the cerebellum (see Figure 15.3B,C).
2. All outputs of the cerebellum are carried by the deep cerebellar nuclei and the vestibular nuclei (see Figures 15.4, 15.5). The cerebellar cortex and deep nuclei can be divided into three functional zones (see Table 15.1):
   A. The **vermis** (via **fastigial nuclei**) and **flocculonodular lobes** (via **vestibular nuclei**) are important in the control of proximal and trunk muscles and in vestibulo-ocular control, respectively.
   B. The **intermediate part** of the cerebellar hemisphere (via **interposed nuclei**) is involved in the control of more distal appendicular muscles mainly in the arms and legs.
   C. The largest part of the cerebellum is the **lateral part** of the cerebellar hemisphere (via **dentate nuclei**), which is involved in planning the motor program for the extremities.
3. The microscopic circuitry of the cerebellum involves excitatory inputs carried by **mossy fibers** and **climbing fibers**. These inputs synapse directly or indirectly onto **Purkinje cells**, which carry the outputs to the deep cerebellar and vestibular nuclei (see Figures 15.5, 15.7). Important local cerebellar neurons include **granule cells** and the inhibitory **Golgi, basket, and stellate cells.**
4. Cerebellar **input and output pathways** are fairly complex; they are summarized in Figures 15.9, 15.10, and 15.11, and in Tables 15.2 and 15.3. The most clinically important points are that these pathways again follow a medial–lateral organization and that all pathways to the lateral motor systems are either ipsilateral or **double crossed** so that cerebellar lesions cause ipsilateral deficits.
5. **Ataxia** is a characteristic irregular movement abnormality seen in cerebellar disorders (see Figure 15.14B). On the basis of the anatomical organization of cerebellar pathways, the following principles of localizing cerebellar lesions emerge:
   A. **Ataxia is ipsilateral** to the side of a cerebellar lesion.
   B. Midline lesions of the cerebellar vermis or flocculonodular lobes cause mainly unsteady gait (**truncal ataxia**) and eye movement abnormalities.

Brief Anatomical Study Guide *(continued)*

   C. Lesions of the intermediate part of the cerebellar hemisphere cause mainly ataxia of the limbs (**appendicular ataxia**).
   D. Ataxia is often caused by **lesions of cerebellar circuitry** in the brainstem or other locations rather than in the cerebellum itself, which can lead to false localization.
   E. Because of the strong reciprocal connection between the cerebellum and vestibular system, cerebellar lesions are often associated with **vertigo, nausea, vomiting, and nystagmus.**

References

General

Blanks RHI. 1988. Cerebellum. *Rev Oculomot Res* 2: 225–272.

deZeeuw CI, Strata P, Voogd J (eds.). 1997. *The Cerebellum: From Structure to Control* (Progress in Brain Research, Vol. 114). Elsevier Science, New York.

Schmahmann JD, Jenner P, Harris RA (eds.). 1997. *The Cerebellum and Cognition* (International Review of Neurobiology, Vol. 41). Academic Press, New York.

Cerebellar Vascular Disorders

Adams RD. 1943. Occlusion of the anterior inferior cerebellar artery. *Arch Neurol Psychiatry* 49: 765–770.

Caplan LR, Pessin MS, Amarenco P. 1998. Vertebrobasilar occlusive disease. In Barnett JM, Mohr JP, Bennett MS(eds.), *Stroke: Pathophysiology, Diagnosis, and Management*, Chapter 22. Churchill Livingstone, New York.

Kase CS, Norrving B, Levine SR, Babikian VL, Chodosh EH, Wolf PA, Welch KMA. 1993. Cerebellar infarction: Clinical and anatomic observations in 66 cases. *Stroke* 24(1): 76–83.

Marinkovic S, Kovacevic M, Gibo H, Milisavljevic M, Bumbasirevic L. 1995. The anatomical basis for the cerebellar infarcts. *Surg Neurol* 44(5): 450–460.

Moulin T, Bogousslavsky J, Chopard JL, Ghika J, Crepin-Leblond T, Martin V, Maeder P. 1995. Vascular ataxic hemiparesis: A re-evaluation. *J Neurol Neurosurg Psychiatry* 58(4): 422–427.

Tatu L, Moulin T, Bogousslavsky J, Duvernoy H. 1996. Arterial territories of the human brain. *Neurology* 47(5): 1125–1135.

Tohgi H, Takahashi S, Chiba K, Hirata Y. 1993. Cerebellar infarction: Clinical and neuroimaging analysis in 293 patients. *Stroke* 24(11): 1697–1701.

Other Cerebellar Disorders

Dyste GN, Menezes AH, Van Gilder JC. 1989. Symptomatic Chiari malformations: An analysis of presentation, management, and long term outcome. *J Neurosurg* 71 (20): 159–168.

Harding AE. 1996. Ataxic disorders. In Bradley WG, Daroff RB, Fenichel GM, Marsden CD (eds.). *Neurology in Clinical Practice: The Neurological Disorders*, Vol. 2, 2nd Ed., Chapter 24. Butterworth-Heinemann, Boston.

Ilgren EB, Stiller CA. 1987. Cerebellar astrocytomas: Clinical characteristics and prognostic indices. *J Neurooncol* 4(3): 293–308.

Malm J, Kristenson B, Karlsson T, Carlberg B, Fagerlund M, Olsson T. 1998. Cognitive impairment in young adults with infratentorial infarcts. *Neurology* 51(2): 433–440.

Plaitakis A (ed.). 1992. *Cerebellar Degenerations: Clinical Neurobiology (Foundations of Neurology)*. Kluwer Academic Publishers, Boston.

Solomon DH, Barohn RJ, Bazan C, Grissom J. 1994. The thalamic ataxia syndrome. *Neurology* 44(5): 810–814.

Thach WT Jr., Montgomery EG Jr. 1992. Motor system. In Pearlman AL, Collins RC (eds.), *Neurobiology of Disease*, Chapter 9. Oxford, New York.

CHAPTER 16

ANATOMICAL AND CLINICAL REVIEW
Basic Three-Dimensional Anatomy of the Basal Ganglia
Input, Output, and Intrinsic Connections of the Basal Ganglia
Parallel Basal Ganglia Pathways for Movement, Eye Movement, Cognition, and Emotion
Ansa Lenticularis, Lenticular Fasciculus, and the Fields of Forel
KCC 16.1 Movement Disorders
KCC 16.2 Parkinson's Disease and Related Disorders
KCC 16.3 Huntington's Disease
KCC 16.4 Stereotactic Surgery for Movement Disorders and Other Conditions

CLINICAL CASES
16.1 Unilateral Flapping and Flinging
16.2 Irregular Jerking Movements and Marital Problems
16.3 Asymmetrical Resting Tremor, Rigidity, Bradykinesia, and Gait Difficulties
16.4 Bilateral Bradykinesia, Rigidity, and Gait Instability with No Tremor
Additional Cases

BRIEF ANATOMICAL STUDY GUIDE

Basal Ganglia

A 35-year-old man and his wife came to see a psychiatrist because of marital problems. The wife reported that during recent months her husband had become increasingly argumentative and had also developed occasional irregular jerking movements of the head, trunk, and limbs. The husband denied having any involuntary movements. His father and several other paternal relatives had developed a similar syndrome, caused by a devastating neurodegenerative disease that destroys the basal ganglia. In this chapter, we will learn about the anatomy, circuitry, and functional neurochemistry of the basal ganglia and will see cases in which damage to the basal ganglia produces movement disorders and other deficits, including behavioral and cognitive abnormalities.

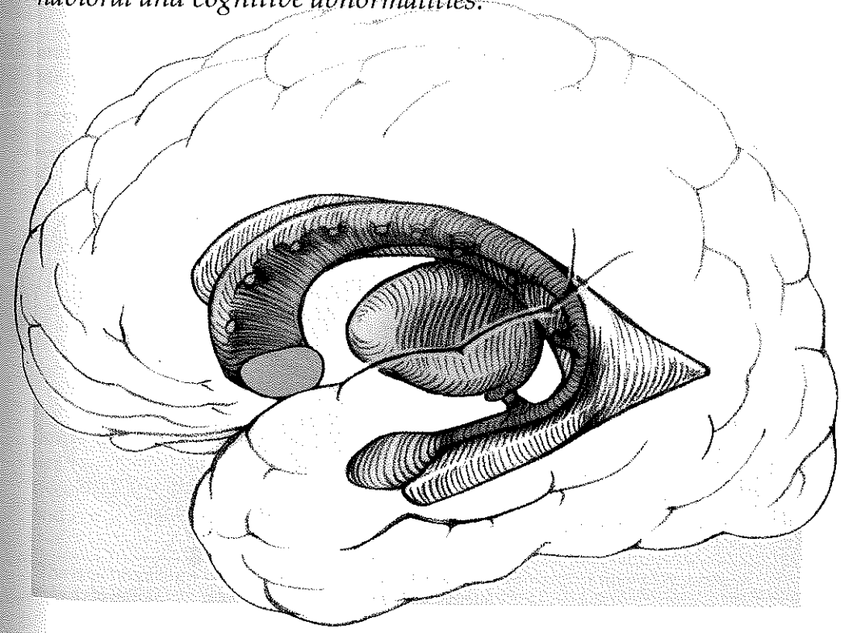

ANATOMICAL AND CLINICAL REVIEW

Like the cerebellum, the basal ganglia participate in complex networks that influence the descending motor systems (see Figures 2.17, 6.6). Also like the cerebellum, the basal ganglia do not themselves project directly to the periphery. However, the movement abnormalities seen with basal ganglia disorders differ markedly from those seen with cerebellar lesions. Patients with basal ganglia lesions can have either hyperkinetic or hypokinetic movement disorders. **Hyperkinetic movement disorders** are typified by Huntington's disease, in which uncontrolled involuntary movements produce a random pattern of jerks and twists. **Hypokinetic movement disorders** are typified by Parkinson's disease, which is characterized by rigidity, slowness, and marked difficulty initiating movements. Often there will be a mixture of these two kinds of movement disorders in any given patient.

In the sections that follow we will review the basic three-dimensional anatomy of the basal ganglia and then discuss their network connections in an attempt to understand the mechanisms underlying hyperkinetic and hypokinetic movement disorders. We will also discuss some of the other functions of the basal ganglia including emotional control, cognition, and eye movements.

Basic Three-Dimensional Anatomy of the Basal Ganglia

The basal ganglia are a collection of gray matter nuclei located deep within the white matter of the cerebral hemispheres. The main components of the **basal ganglia** are the caudate nucleus, putamen, globus pallidus, subthalamic nucleus, and substantia nigra (Table 16.1, Figure 16.1; see also Figure 16.4). Other nuclei, such as the nucleus accumbens and ventral pallidum, which participate in limbic and basal ganglia circuits, are usually included as well. Some authors also include the amygdala; however, this nucleus functions primarily as part of the limbic system (see Chapter 18).

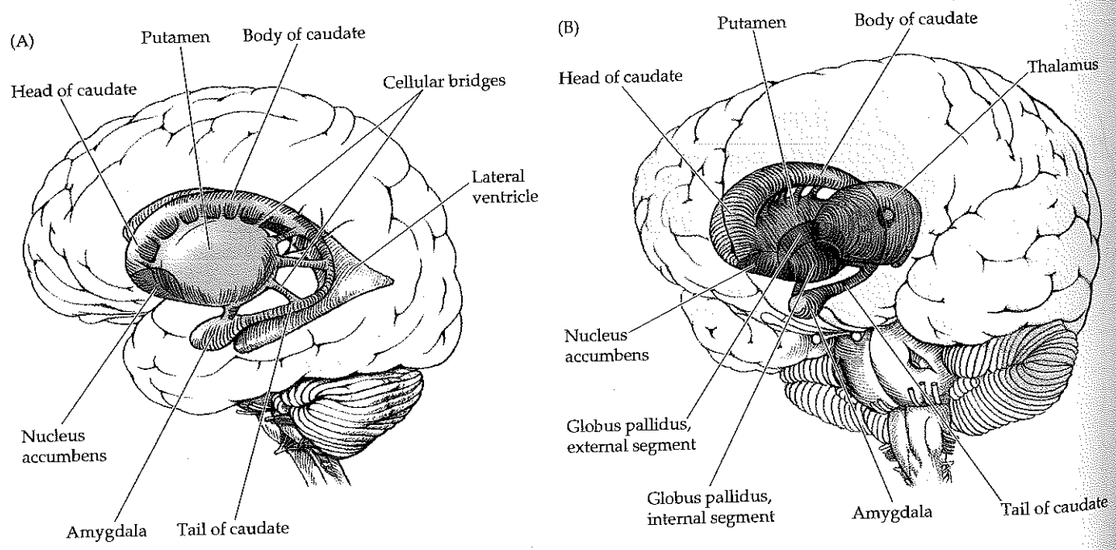

Figure 16.1 Spatial Relationships of Basal Ganglia, Thalamus, and Amygdala The subthalamic nucleus and substantia nigra are not shown (see Figure 16.4D). (A) Lateral view showing basal ganglia, amygdala, and lateral ventricle of the left hemisphere. (B) Anterolateral view showing basal ganglia, amygdala, and thalamus of the right hemisphere.

The caudate and putamen are histologically and embryologically closely related and can be thought of as a single large nucleus called the **neostriatum** or simply **striatum.** The striatum receives all inputs to the basal ganglia. The caudate and putamen are separated by penetrating fibers of the internal capsule but remain joined in some places by **cellular bridges** (see Figure 16.1A). The cellular bridges appear as stripes, or striations, connecting the caudate and putamen in histological sections, giving rise to the name "striatum." The **caudate nucleus** is one of the C-shaped structures that we discussed in Chapter 5: like the corpus callosum and the fornix, it has a constant relationship with the lateral ventricle, as we will discuss shortly. The caudate (meaning "possessing a tail"), is divided into three parts, the **head, body,** and **tail,** which do not have distinct boundaries from each other (see Figure 16.1A). The amygdala lies just anterior to the tip of the caudate tail, in the temporal lobe.

TABLE 16.1 Basal Ganglia[a]

Striatum	Caudate	
	Putamen	Lenticular nucleus
	Globus pallidus	Lenticular nucleus
	Subthalamic nucleus	
	Substantia nigra	

[a]The nucleus accumbens and ventral pallidum can also be considered part of the basal ganglia.

The **putamen** is a large nucleus forming the lateral portion of the basal ganglia (see Figure 16.1). Anteriorly and ventrally the putamen fuses with the head of the caudate. This region, called the **ventral striatum,** is important in limbic circuitry and is often considered part of the striatum because of its similar embryological development and input and output connections. Most of the ventral striatum consists of the **nucleus accumbens.**

Just medial to the putamen lies the **globus pallidus** (or pallidum), meaning "pale globe," so named because of the many myelinated fibers traversing this region. The globus pallidus has an **internal segment** and an **external segment** (see Figure 16.1B). The putamen and globus pallidus together are called the **lenticular,** or **lentiform, nucleus,** meaning "lentil or lens shaped." In fact, as we will see in the sections that follow, these nuclei more closely resemble an ice cream cone lying on its side, with the putamen representing the ice cream and the globus pallidus the cone.

To better appreciate the three-dimensional nature of the basal ganglia and related structures, let's review these structures through artistic renderings (Figure 16.2) and stained brain sections (Figures 16.3, 16.4). Moving from lateral to medial in the horizontal brain sections shown in Figure 16.3, we can identify the following structures in sequence:

- Insula
- Extreme capsule
- Claustrum*
- External capsule
- Putamen
- External medullary lamina
- External segment of the globus pallidus
- Internal medullary lamina
- Internal segment of the globus pallidus
- Internal capsule

As we discussed in Chapter 6, the **internal capsule** is a V-shaped collection of fibers going to and from the cortex (see Figure 16.3). The **anterior limb of the internal capsule** passes between the lentiform nucleus and the head of the caudate. The **posterior limb of the internal capsule** passes between the lentiform nucleus and the thalamus. Recall that the corticobulbar and corticospinal tracts lie in the posterior limb of the internal capsule (see

*The exact functions of the claustrum remain unknown, although it may play a role in visual attention.

Figure 16.2 Basal Ganglia and Thalamus in Relation to the Internal Capsule and Lateral Ventricle
(A) View from the lateral aspect, showing relation of internal capsule to basal ganglia and thalamus (see also Figure 16.3). The anterior limb of the internal capsule passes between the lentiform nucleus (putamen and globus pallidus) and the caudate, while the posterior limb of the internal capsule passes between the lentiform nucleus and the thalamus. (B) View after removal of the putamen, revealing the globus pallidus more medially. (C) View after removal of the globus pallidus, showing the entire internal capsule. (D) View after removal of the internal capsule, showing relations of the caudate to the lateral ventricle and of the thalamus to both the lateral ventricle and the third ventricle.

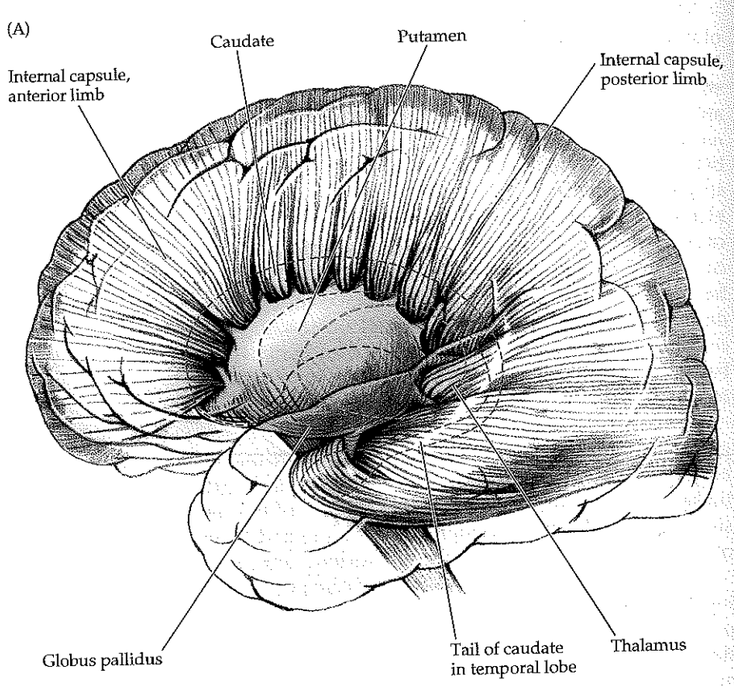

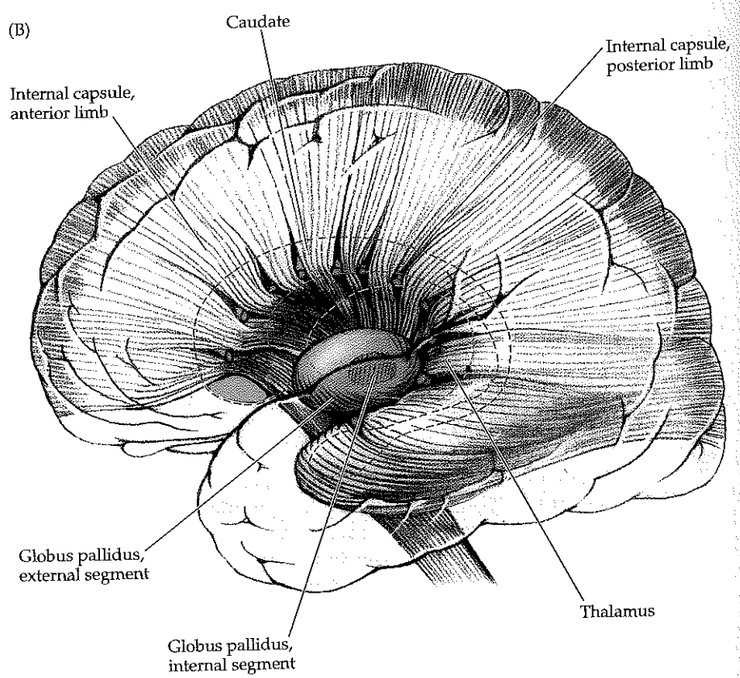

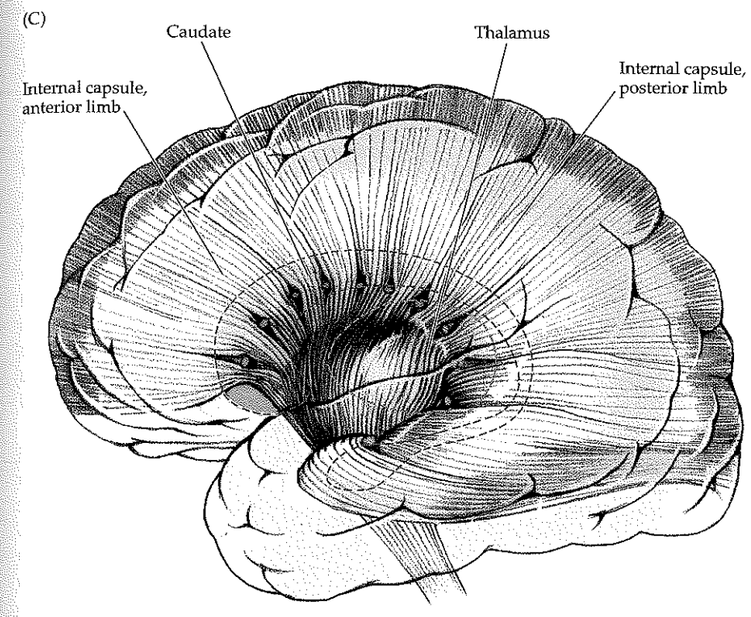

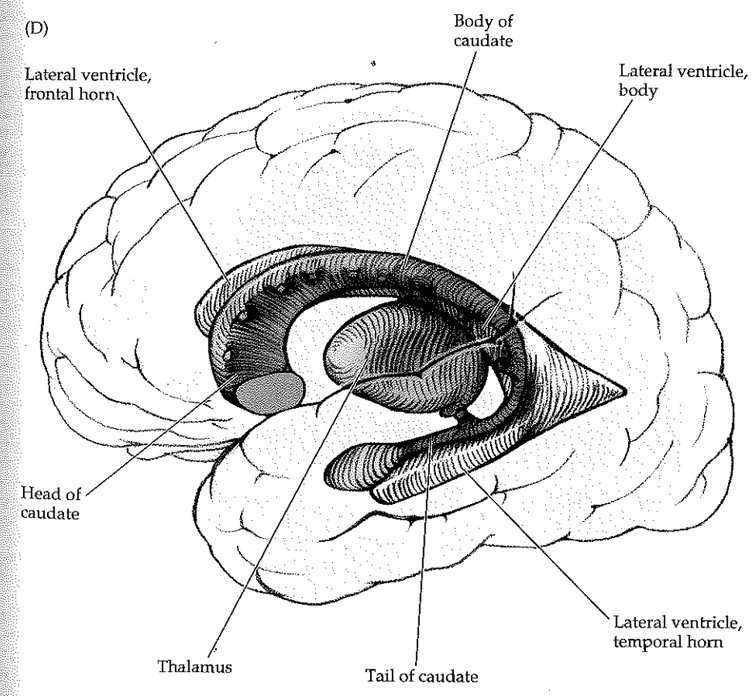

(A)

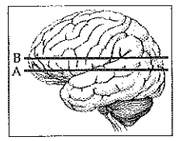

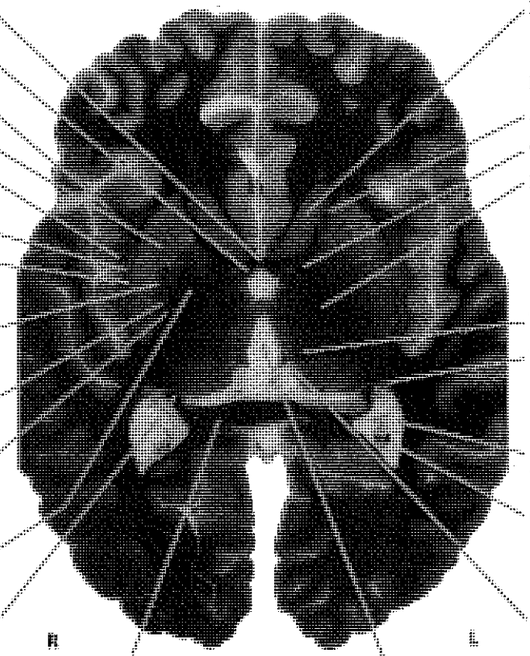

(B)

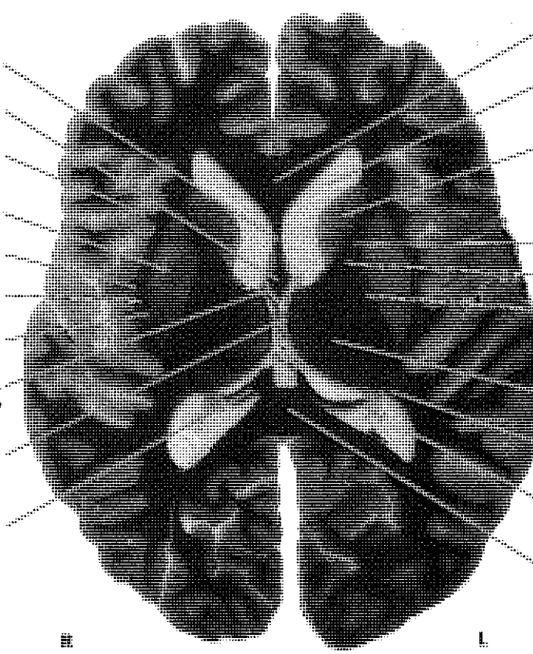

Figure 16.3 Horizontal Brain Sections through Basal Ganglia and Thalamus
Myelin is stained dark (Weigert). The spatial relationships between the basal ganglia, thalamus, internal capsule, ventricles, and other structures can be seen.
A, B progress from inferior to superior. (From the Walter Reed Yakovlev collection.)

Figure 6.9). Note that the **caudate and thalamus are always medial** to the internal capsule, while the **lentiform nucleus** (putamen and globus pallidus) **is always lateral** to the internal capsule.

MNEMONIC

These relationships are again reviewed in Figure 16.2, which shows a left lateral view of these structures. In Figure 16.2A the putamen is visible most laterally, concealing the globus pallidus. The caudate and thalamus lie behind the internal capsule. In Figure 16.2B, the putamen has been removed to reveal the globus pallidus. The external and internal segments of the globus pallidus have been removed in Figure 16.2C to fully expose the internal capsule. Finally, in Figure 16.2D, the internal capsule has been removed to reveal the caudate and thalamus. Note the relationship between these structures and the ventricular system. The head and body of the caudate form a bulge on the lateral wall of the lateral ventricle, while the tail of the caudate runs along the roof of the temporal horn (see Figures 16.2D, 16.3, 16.4). The thalamus forms the lateral walls of the third ventricle (see Figures 16.2D, 16.3, 16.4D) and lies along the floor of the body of the lateral ventricle.

MNEMONIC

Coronal sections (see Figure 16.4) provide additional perspective. In Figure 16.4A (the most anterior section), the head of the caudate, the putamen, and the nucleus accumbens can be seen. The internal capsule seen at this level is part of the anterior limb, since it is separating caudate from lentiform nucleus, with no thalamus visible. Note that this section includes the putamen but not the globus pallidus. We can understand this if we imagine that the lentiform nucleus is an ice cream cone lying on its side with the cone pointing medially. The most anterior coronal sections would thus cut through ice cream (putamen) without cone (globus pallidus).

The globus pallidus first appears in the next coronal section (see Figure 16.4B) moving toward the back. The external segment of the globus pallidus can be seen at this level. The head of the caudate nucleus is visible as a bulge along the lateral wall of the lateral ventricle. Moving posteriorly, in the next section (see Figure 16.4C) the internal segment of the globus pallidus (tip of the ice cream cone) can be seen, along with all of the structures listed above that were identified in Figure 16.3. The head of the caudate can still be seen bulging into the lateral ventricle. Since the thalamus is not yet visible, we are still in the anterior limb of the internal capsule.

In the most posterior section (see Figure 16.4D) we have begun to lose the globus pallidus again, and in more posterior sections (not shown), only the putamen (ice cream) is visible.

In Figure 16.4D the thalamus can be seen, meaning that we are at the level of the posterior limb of the internal capsule, separating thalamus from lentiform nucleus. Both the body and the tail of the caudate can be seen in this section, adjacent to the body and temporal horn of the lateral ventricle, respectively. In addition, by following the internal capsule downward, we see the beginnings of the cerebral peduncles of the midbrain. The **substantia nigra** is visible, just dorsal to the cerebral peduncles (see also Figure 14.3A,B). The substantia nigra has a ventral portion called the **substantia nigra pars reticulata,** which contains cells very similar to those of the internal segment of the globus pallidus. The internal segment of the globus pallidus and the substantia nigra pars reticulata are separated from each other by the internal capsule, much in the same way as it separates the caudate and putamen. The more dorsal **substantia nigra pars compacta** contains the darkly pigmented dopaminergic neurons that give this nucleus its name. Degeneration of these dopaminergic neurons is an important pathogenetic mechanism in Parkinson's disease. Under the thalamus lies the spindle- or cigar-shaped **subthalamic nucleus** (see Figure 16.4D). Unlike the thalamus, the subthalamic nucleus is derived embryologically from the midbrain rather than the forebrain. As discussed

REVIEW EXERCISES

1. Beginning with the insula, and moving medially, name each gray and white matter structure encountered on the way to the third ventricle. Repeat this while covering the labels in Figure 16.3.

2. Using Figures 16.2–16.4, confirm that the thalamus and caudate head lie medial to the internal capsule in all planes of section, while the lentiform nucleus (putamen and globus pallidus) lies lateral to the internal capsule in all planes of section.

3. Using Figures 16.3 and 16.4, confirm that:

   The anterior limb of the internal capsule is bordered by the head of the caudate medially and the lentiform nucleus laterally.

   The posterior limb of the internal capsule is bordered by the thalamus medially and by the lentiform nucleus laterally.

   The genu of the internal capsule occurs at the level of the foramen of Monro.

4. Cover the labels in Figure 16.4A–D and name as many structures as possible.

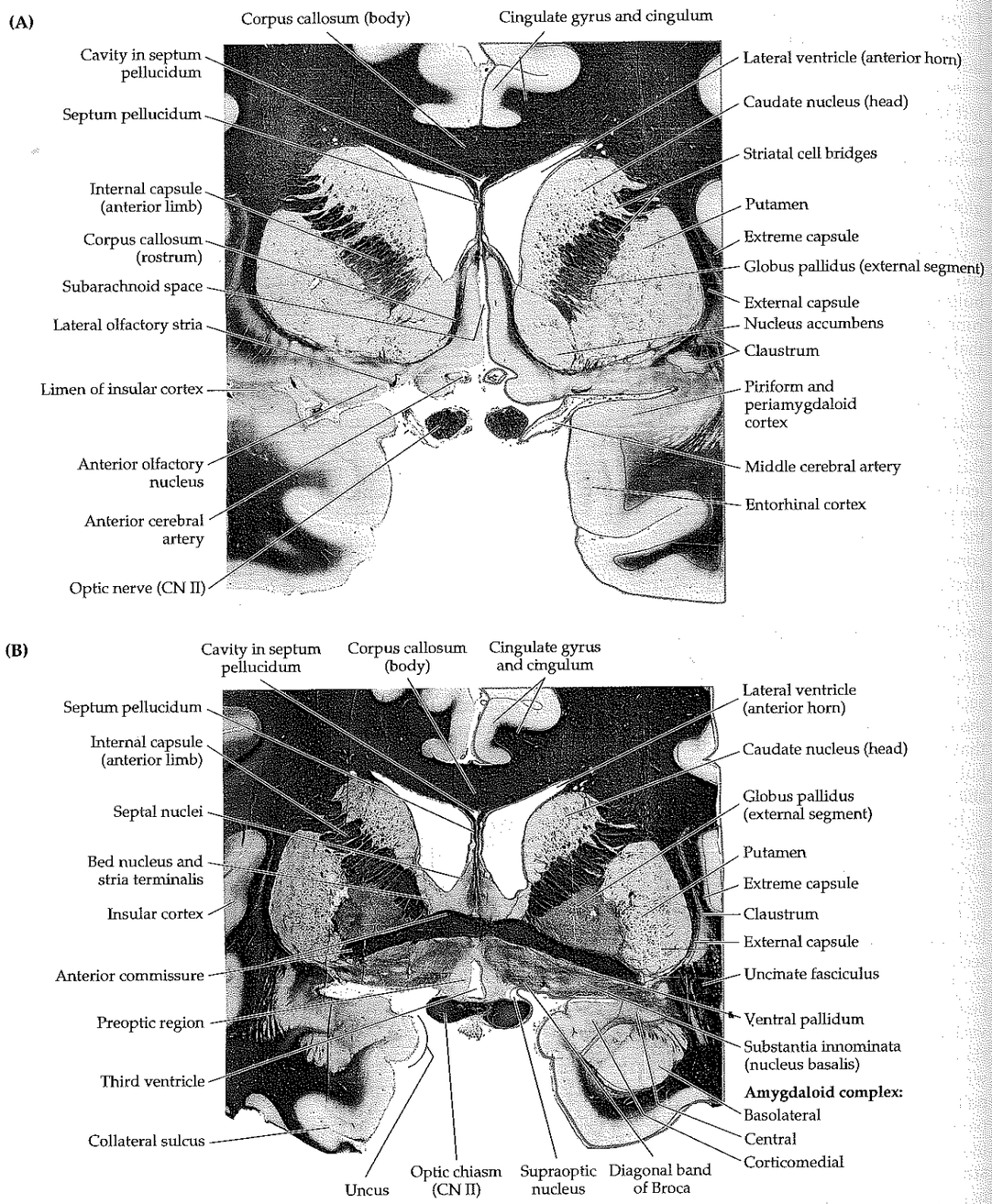

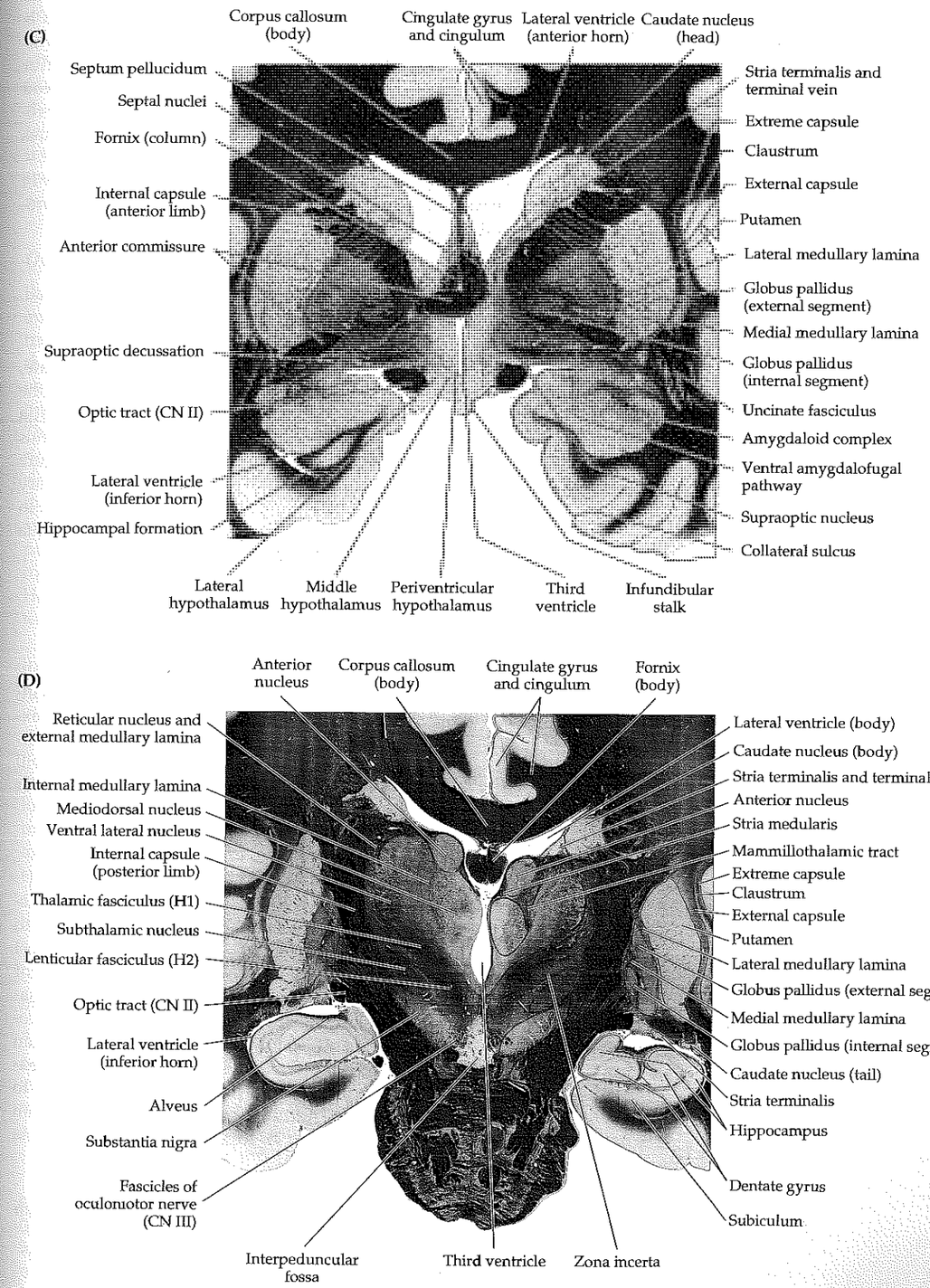

Figure 16.4 Coronal Brain Sections through Basal Ganglia and Thalamus Myelin is stained dark. The spatial relationships between the basal ganglia, thalamus, internal capsule, ventricles, and other structures can be seen. (A–D) progressing from anterior to posterior. (From Martin JH. 1996. *Neuroanatomy: Text and Atlas,* 2nd Ed. McGraw-Hill, New York.)

in Chapter 10, the blood supply to the striatum and globus pallidus is mainly from the lenticulostriate branches of the middle cerebral artery, although the medial globus pallidus is often supplied by the anterior choroidal artery (branch of internal carotid artery), and the caudate head and anterior portions of the lentiform nucleus are often supplied by the recurrent artery of Heubner (branch of anterior cerebral artery) (see Figures 10.7–10.9).

At this point you may find it worthwhile to review the basic anatomy of the basal ganglia one more time, as depicted in Figures 16.1–16.4, before proceeding to the network connections of these structures.

Input, Output, and Intrinsic Connections of the Basal Ganglia

Virtually all inputs to the basal ganglia arrive via the **striatum** (caudate, putamen, and nucleus accumbens). Outputs leave the basal ganglia via the **internal segment of the globus pallidus** and the closely related **substantia nigra pars reticulata.** Inputs and outputs through the basal ganglia are thus easily visualized as a funnel, with the spout pointing medially (see Figure 16.4D). Within the basal ganglia there are a variety of complex excitatory and inhibitory connections utilizing several different neurotransmitters. In addition, there appear to be several parallel pathways in the basal ganglia for different functions, including:

- General motor control
- Eye movements
- Cognitive functions
- Emotional functions

In this section we will review the main pathways involved in motor control and discuss a model to explain hyperkinetic and hypokinetic movement disorders. In the next section (see also Table 16.2) we will briefly discuss some of the circuitry involved in other basal ganglia functions.

Inputs to the Basal Ganglia

The main input to the basal ganglia comes from massive projections from the entire **cerebral cortex** to the striatum (Figure 16.5). The putamen is the most important input nucleus of the striatum for motor control pathways. Most cortical inputs to the striatum are excitatory and use **glutamate** as the neurotransmitter. Another important input to the striatum is the substantia nigra pars compacta. This **dopaminergic nigrostriatal pathway** is excitatory to some cells and inhibitory to others in the striatum (see Figures 16.5, 16.7). Inputs to the pars compacta

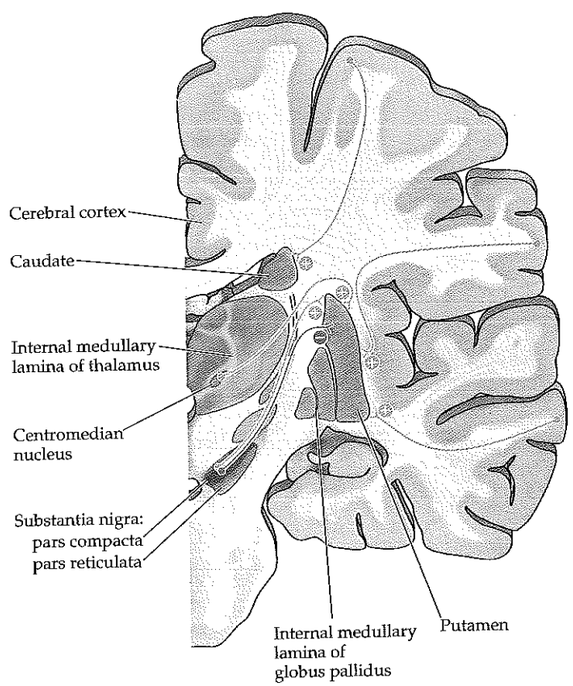

Figure 16.5 Basal Ganglia Inputs Arrive at the Striatum Schematic coronal section. Note that for clarity, inputs other than those from the cortex are shown only projecting to the putamen. In reality, inputs project to the caudate as well.

are still under investigation. However, one important source of input may arise from a subpopulation of striatal neurons located in patches called **striosomes.** The striatum also receives excitatory (glutamatergic) inputs from **intralaminar nuclei** lying within the internal medullary lamina of the thalamus, especially the **centromedian** and **parafascicular nuclei.** The internal medullary lamina of the thalamus should be distinguished from the internal medullary lamina of the globus pallidus (see Figure 16.5). Finally, there are **serotonergic inputs** to the basal ganglia that arise from the raphe nuclei of the brainstem.

REVIEW EXERCISE

List the four major sources of input to the basal ganglia. To which part of the basal ganglia do all inputs project? For each input, list the major neurotransmitter.

Outputs from the Basal Ganglia

Basal ganglia outputs arise from the internal segment of the globus pallidus and from the substantia nigra pars reticulata (Figure 16.6). For motor control, the substantia nigra pars reticulata appears to convey information for the head and neck, while the internal segment of the globus pallidus conveys information for the rest of the body. These output pathways are inhibitory and use the neurotransmitter **gamma-aminobutyric acid (GABA).** The main output pathways are to the **ventral lateral (VL)** and **ventral anterior (VA)** nuclei of the thalamus via the **thalamic fasciculus.** The more anterior parts of the thalamic fasciculus carry outputs from the basal ganglia to the anterior portion of VL, while the more posterior parts of the thalamic fasciculus carry cerebellar outputs to the posterior VL (mnemonic: Caudal part of VL receives inputs from Cerebellum) (see Chapter 15). Thalamic neurons convey information from the basal ganglia to the entire frontal lobe. However, information for motor control travels mainly to the premotor cortex, supplementary motor area, and primary motor cortex (see Figure 16.8).

MNEMONIC

Basal ganglia outputs also travel to other thalamic nuclei. These include **intralaminar nuclei** (centromedian and parafascicular), which project back to the striatum, and the **mediodorsal nucleus,** which is involved primarily in limbic pathways. In addition, the internal segment of the globus pallidus and the substantia nigra pars reticulata project to the pontomedullary **reticular formation,** thereby influencing the descending reticulospinal tract. The substantia nigra pars reticulata also projects to the **superior colliculus,** to influence tectospinal pathways. In this way the basal ganglia influence both the lateral motor systems (e.g., the lateral corticospinal tract) and the medial motor systems (e.g., the reticulospinal and tectospinal tracts) (see Table 6.3).

Intrinsic Basal Ganglia Connections

An understanding of the excitatory and inhibitory connections in these pathways provides some insight into the mechanisms of hyperkinetic and hypokinetic movement disorders. There are two predominant pathways from input to output nuclei through the

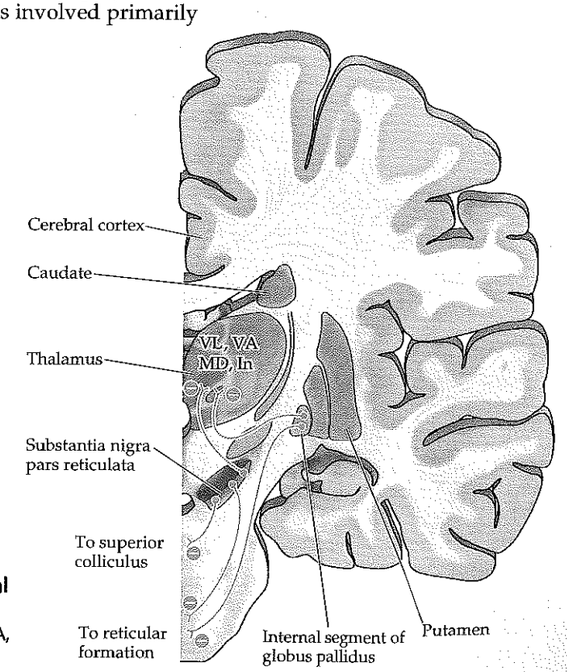

Figure 16.6 Basal Ganglia Outputs Arise from the Internal Globus Pallidus, and the Substantia Nigra Pars Reticulata Schematic coronal section. Thalamic nuclei: VL, ventral lateral; VA, ventral anterior; MD, mediodorsal; In, intralaminar.

REVIEW EXERCISE

List the four major thalamic nuclei to which the basal ganglia project. List two additional basal ganglia outputs. From what structures do the basal ganglia outputs arise? What is the major neurotransmitter for all outputs from the basal ganglia?

MNEMONIC

basal ganglia (Figure 16.7). The **direct pathway** travels from the striatum directly to the internal segment of the globus pallidus or the substantia nigra pars reticulata. The **indirect pathway** takes a detour from the striatum, first to the external segment of the globus pallidus and then to the subthalamic nucleus, before finally reaching the internal segment of the globus pallidus or the substantia nigra pars reticulata. For simplicity, only the pathways through the putamen and internal segment of the globus pallidus are shown in Figure 16.7, although similar pathways also involve the caudate and the substantia nigra pars reticulata.

Figure 16.7B shows that the net effect of excitatory input from the cortex through the direct pathway will be excitation of the thalamus, which in turn will facilitate movements through its connections with the motor and premotor cortex. On the other hand, the net effect of excitation of the indirect pathway will be inhibition of the thalamus, resulting in inhibition of movements through connections back to the cortex (mnemonic: Indirect Inhibits).

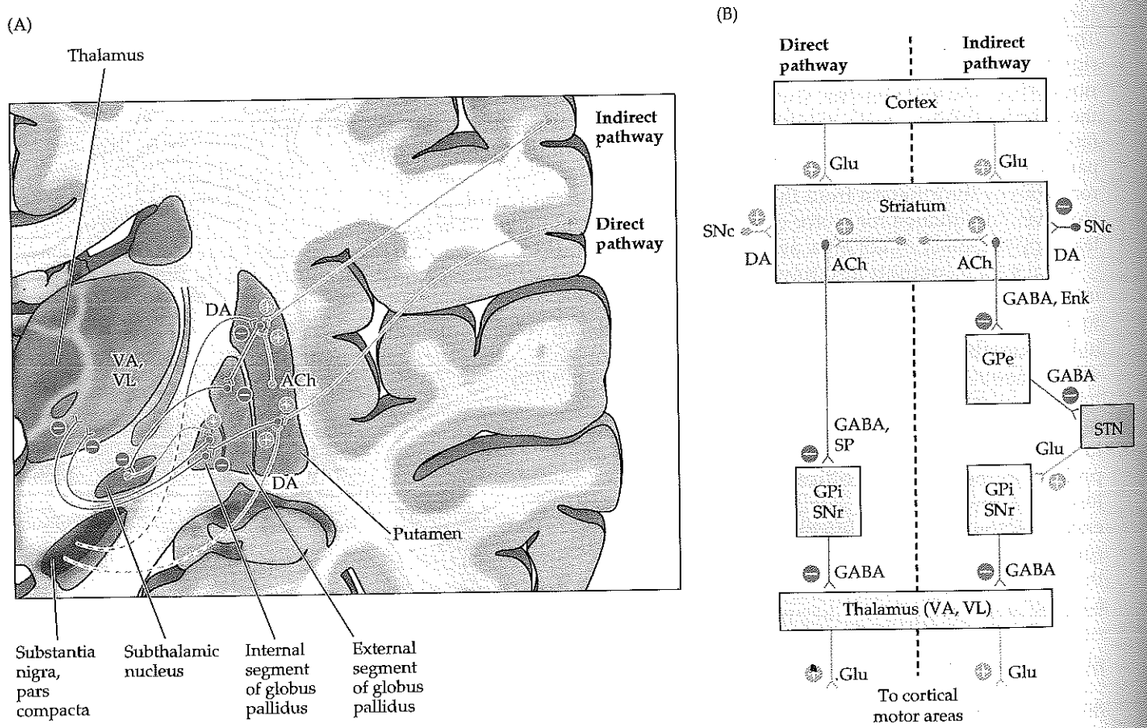

Figure 16.7 Basal Ganglia Internal Connections, Showing the Direct and Indirect Pathways (A) Schematic coronal section. For simplicity, the striatum is represented by the putamen only, although the caudate has the same connections as well. Similarly, the connections shown for the internal segment of the globus pallidus are the same for the substantia nigra pars compacta (not shown). The excitatory connections from the thalamus to the cortex are also not shown. (B) Circuit diagram for direct and indirect pathways. *Neurotransmitters:* Ach, acetylcholine; DA, dopamine; Glu, glutamate; Enk, enkaphalin; SP, substance P. *Nuclei:* SNc, substantia nigra pars compacta; SNr, substantia nigra pars reticulata; GPe, globus pallidus pars externa; GPi, globus pallidus pars interna; STN, subthalamic nucleus; VL, ventral lateral nucleus; VA, ventral anterior nucleus.

Let's look at each of the major synapses in the direct and indirect pathways in series. Striatal projection neurons for both pathways are primarily **inhibitory spiny neurons,** which contain the neurotransmitter **GABA.** In the direct pathway, spiny striatal neurons project to the internal segment of the globus pallidus (and to the substantia nigra pars reticulata) and contain the peptide **substance P** in addition to GABA. Output neurons from the internal globus pallidus and substantia nigra pars reticulata to the thalamus are also inhibitory and contain GABA. In the indirect pathway, striatal neurons project to the external segment of the globus pallidus and contain the inhibitory neurotransmitter GABA, plus the peptide **enkephalin** (mnemonic: Enkephalin to External pallidum). Neurons of the external globus pallidus, in turn, send inhibitory GABAergic projections to the subthalamic nucleus. Excitatory neurons in the subthalamic nucleus containing **glutamate** then project to the internal segment of the globus pallidus and to the substantia nigra pars reticulata. As in the direct pathway, outputs from these nuclei to the thalamus are inhibitory and are mediated by GABAergic neurotransmission.

MNEMONIC

Hyperkinetic and Hypokinetic Movement Disorders

Several aspects of hyperkinetic and hypokinetic movement disorders can be understood from the scheme in Figure 16.7. In **Parkinson's disease** (see KCC 16.2), dopamine-containing neurons in the substantia nigra pars compacta degenerate. Dopamine appears to have excitatory effects on striatal neurons of the direct pathway, but inhibitory effects on striatal neurons of the indirect pathway (see Figure 16.7), which normally has a net excitatory effect on the thalamus. Therefore, loss of dopamine will result in net inhibition of the thalamus, through both the direct and the indirect pathways, which may account for the paucity of movement seen in Parkinson's disease. Drugs that bolster dopaminergic transmission can improve the symptoms of Parkinson's disease.

REVIEW EXERCISE

Follow the inhibitory and excitatory pathways in Figure 16.7 to confirm that: (1) Excitatory inputs to the direct pathway produce net excitation of thalamocortical outputs; (2) Excitatory inputs to the indirect pathway produce net inhibition of thalamocortical outputs.

In addition, anticholinergic drugs can be beneficial. There are large interneurons in the striatum called **aspiny neurons,** some of which contain the neurotransmitter **acetylcholine.** Some evidence suggests that these cholinergic interneurons preferentially form excitatory synapses onto striatal neurons of the indirect pathway. Removal of cholinergic excitation of the indirect pathway produces a net decrease in inhibition of the thalamus, which may account for the beneficial effects of anticholinergic agents in parkinsonism (see Figure 16.7). Note that this model does not account for the tremor commonly seen in Parkinson's disease, and the model therefore continues to evolve.

In **hemiballismus** (KCC 16.1) there are unilateral wild flinging movements of the extremities contralateral to a lesion in the basal ganglia, typically involving the subthalamic nucleus. Figure 16.7 shows how damage to the subthalamic nucleus could decrease excitation of the internal segment of the globus pallidus, resulting in less inhibition of the thalamus, causing a hyperkinetic movement disorder. In **Huntington's disease,** striatal neurons in the caudate and putamen degenerate. There is some evidence that, at least initially, the enkephalin-containing striatal neurons of the indirect pathway are more severely affected. This would cause removal of inhibition from the external segment of the globus pallidus, allowing it to inhibit the subthalamic nucleus (see Figure 16.7). Inhibition of the subthalamic nucleus produces a situation similar to a lesion of the subthalamic nucleus, and may account for the hyperkinetic movement disorder seen in Huntington's disease. In more advanced stages of Huntington's disease, both the direct and the indirect pathways degenerate, and a rigid hypokinetic parkinsonian state results.

Parallel Basal Ganglia Pathways for Movement, Eye Movement, Cognition, and Emotion

The basal ganglia contain multiple parallel channels of information processing for different functions. **Four channels** have been well described (Table 16.2), although others probably exist as well. Each channel passes through slightly different pathways and projects to different regions of the frontal lobes (Figure 16.8). In another classification scheme, the first three channels are lumped together as **dorsal striatal pathways,** while the limbic channel is distinguished because it involves **ventral striatal pathways.** We will see in KCC 16.1–16.3, that basal ganglia disorders can affect all four of these parallel channels, not just the motor system.

The **motor channel** is the best known and forms the basis for most of the discussion in the previous section. Cortical inputs travel mainly to the putamen, and outputs arise from the internal segment of the globus pallidus and the substantia nigra pars reticulata to reach the VL and VA of the thalamus (see Table 16.2). From the thalamus the motor channel continues to the supplementary motor area, premotor cortex, and primary motor cortex (see Figure 16.8).

A separate **oculomotor channel** subserves basal ganglia regulation of eye movements. The input for this pathway is predominantly from the body of the caudate nucleus. Output is to the frontal eye fields and supplementary eye fields of the frontal lobes, areas important for the higher control of eye movements, as discussed in Chapter 13. The **prefrontal channel** is probably important in cognitive processes involving the frontal lobes (see Chapter 19). Input is primarily from the head of the caudate, and output reaches the prefrontal cortex (see Table 16.2; Figure 16.8).

Finally, the **limbic channel** is an important ventral pathway through the basal ganglia that is involved in limbic regulation of emotions and motivational drives. Inputs arise from major areas for the limbic system (see Chapter 18), such as the limbic cortex, hippocampus, and amygdala, and project to the **nucleus accumbens** and other regions of the ventral striatum. Outputs arise from the **ventral pallidum,** a region just ventral to the globus pallidus, to reach the thalamic mediodorsal and ventral anterior nuclei. The **mediodorsal nucleus** is particularly important to limbic circuitry. Projections from these thalamic nuclei reach the limbic cortex of the **anterior cingulate gyrus** and **medial orbital frontal gyri** (see Figure 16.8). The limbic channel through the basal ganglia is likely to play a central role in many neurobehavioral and psychiatric disorders (see KCC 18.3). Another component of this pathway is the dopaminergic projection from the **ventral tegmental area,** which lies just medial and dorsal to the substantia nigra of the midbrain, at the base of the interpeduncular fossa (see Figure 14.3A). The ventral tegmental area provides dopaminergic inputs to the nucleus accumbens, as well as to other limbic structures and to the frontal lobes(see Figure 14.10). The dopaminergic projections of the ventral tegmental area

TABLE 16.2 Four Parallel Channels through the Basal Ganglia

SOURCES OF CORTICAL INPUT	BASAL GANGLIA INPUT NUCLEI	BASAL GANGLIA OUTPUT NUCLEI[a]	THALAMIC RELAY NUCLEI[b]	CORTICAL TARGETS OF OUTPUT
MOTOR CHANNEL				
Somatosensory cortex; primary motor cortex; premotor cortex	Putamen	GPi, SNr	VL, VA	Supplementary motor area; premotor cortex; primary motor cortex
OCULOMOTOR CHANNEL				
Posterior parietal cortex; prefrontal cortex	Caudate, body	GPi, SNr	VA, MD	Frontal eye fields; supplementary eye fields
PREFRONTAL CHANNEL				
Posterior parietal cortex; premotor cortex	Caudate, head	GPi, SNr	VA, MD	Prefrontal cortex
LIMBIC CHANNEL				
Temporal cortex; hippocampus; amygdala	Nucleus accumbens; ventral caudate; ventral putamen	Ventral pallidum; GPi; SNr	MD, VA	Anterior cingulate; orbital frontal cortex

Source: Based on Martin, JH. 1996. *Neuroanatomy: Text and Atlas.* McGraw-Hill, New York.
[a]GPi, globus pallidus, internal segment; SNr, substantia nigra pars reticulata.
[b]MD, mediodorsal nucleus; VA, ventral anterior nucleus; VL, ventral lateral nucleus.

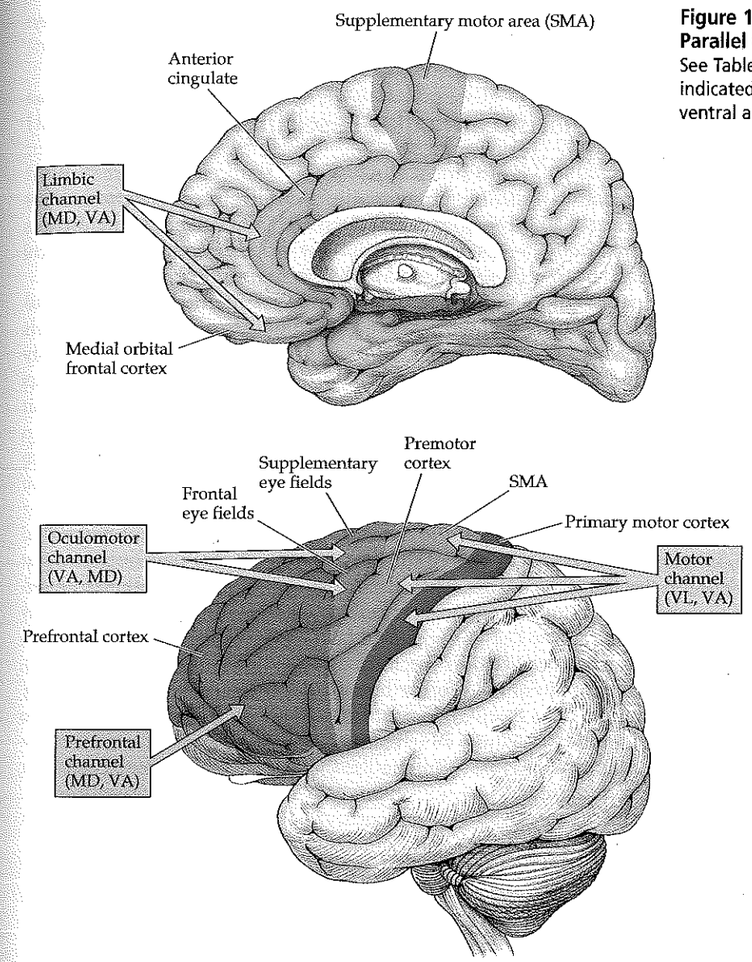

Figure 16.8 Frontal Lobe Outputs of the Four Parallel Channels through the Basal Ganglia See Table 16.2. Thalamic origins of the outputs are indicated. Thalamic nuclei: VL, ventral lateral; VA, ventral anterior; MD, mediodorsal.

REVIEW EXERCISE

Name the four main channels through the basal ganglia. For each channel give the input nuclei in the striatum and the output targets in the cortex.

may be affected in the pathophysiology of schizophrenia and other psychotic disorders.

Ansa Lenticularis, Lenticular Fasciculus, and the Fields of Forel

The output pathways of the globus pallidus and related structures have been dubbed with some very esoteric-sounding names. We will review this nomenclature briefly here, since it occasionally crops up in neuroanatomical discussions. The structures in question are summarized in Figure 16.9.

The internal segment of the globus pallidus sends outputs to the thalamus through two different pathways. One pathway is the **ansa lenticularis** (meaning "lenticular loop"), named for the looping course it takes ventrally under the internal capsule before passing dorsally to reach the thalamus (Figure 16.9). The ansa lenticularis actually passes slightly rostrally as it loops around the inferior medial edge of the internal capsule, and it then turns back toward the thalamus. Recall that the globus pallidus is lateral to the internal capsule, while the thalamus is medial to the posterior limb of the internal capsule (see Figures 16.3, 16.4D).

The other pathway is the **lenticular fasciculus** (see Figure 16.9). Instead of taking a looping course, fibers of the lenticular fasciculus penetrate straight through the internal capsule. They then pass dorsal to the subthalamic nucleus and ventral to the zona incerta before turning superiorly and laterally to enter the thalamus. The **zona incerta** (see Figures 16.4D, 16.9) is the inferior extension of the **reticular nucleus of the thalamus** (see Figure 7.6), which should not be confused with the reticular formation of the brainstem. The fibers of the ansa lenticularis and lenticular fasciculus join together to form the **thalamic fasciculus,** which enters the thalamus. The thalamic fasciculus also contains fibers ascending to the thalamus from the deep cerebellar

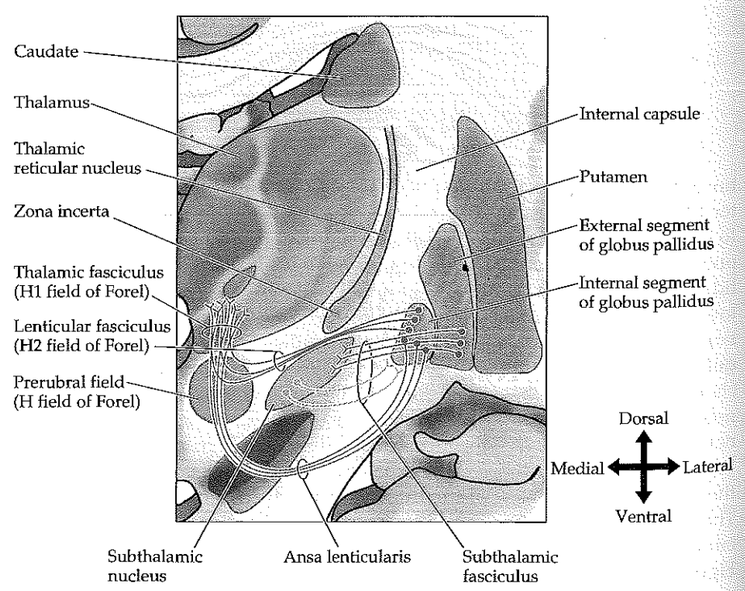

Figure 16.9 Terminology of Basal Ganglia Output Pathways, and Fields of Forel Coronal section through the basal ganglia and thalamus.

nuclei. At this point it is helpful to review the course of the ansa lenticularis, lenticular fasciculus, and thalamic fasciculus as summarized in Figure 16.9.

Another nomenclature for these regions was contributed by the Swiss neurologist and psychiatrist Auguste H. Forel. His terminology describes the Haubenfelder (meaning "hood" or "cap") fields of the subthalamic tegmentum, currently abbreviated as the **H fields of Forel** (see Figure 16.9). The **H1 field of Forel** is the thalamic fasciculus, and the **H2 field of Forel** is the lenticular fasciculus, where it lies dorsal to the subthalamic nucleus. The **prerubral field,** or **H field of Forel,** is the region where the ansa lenticularis and lenticular fasciculus join together.

We will add one more name to the list of tracts discussed so far. In addition to the ansa lenticularis, lenticular fasciculus, and thalamic fasciculus, there is the subthalamic fasciculus (see Figure 16.9). The **subthalamic fasciculus** carries fibers of the indirect pathway from the external segment of the globus pallidus to the subthalamic nucleus, and from the subthalamic nucleus to the internal segment of the globus pallidus.

KEY CLINICAL CONCEPT
MOVEMENT DISORDERS

16.1 Abnormal movements can be caused by dysfunction anywhere in the complex hierarchical motor network, including upper motor neurons, lower motor neurons, cerebellar circuitry, basal ganglia circuitry, motor association cortex, and even sensory systems. However, when clinicians discuss **movement disorders,** they are often referring to abnormal movements resulting from basal ganglia pathology. Basal ganglia disorders tend to look different from disorders in other parts of the motor system, and there are several well-recognized syndromes caused by lesions of the basal ganglia.

Lesions in other systems are often referred to by other names, rather than being called movement disorders. For example, slow, clumsy, stiff movements and hyperreflexia resulting from corticospinal, upper motor neuron lesions are called spasticity (see KCC 6.1). Irregular, uncoordinated movements caused by lesions of cerebellar circuitry are called ataxia or a variety of other names (see KCC 15.2). On the other hand, abnormal movements caused by basal ganglia dysfunction may be referred to as **dyskinesia,** meaning simply "abnormal movement."

As in the cerebellar exam (see KCC 15.2), when examining a patient with abnormal movements thought to be of basal ganglia origin, it is essential to first look carefully for abnormalities in other systems that can also cause abnormal movements, including upper or lower motor neuron signs, sensory loss, or ataxia (see neuroexam.com Videos 48–78). In addition, abnormal movements are occasionally caused by psychological conditions such as conversion disorder (see Chapter 3).

There is also a historical basis for focusing on the basal ganglia when discussing movement disorders. In the beginning of the twentieth century it was believed that two independent "pyramidal" and "extrapyramidal" motor systems converged on lower motor neurons. The pyramidal system was similar to current corticospinal or upper motor neuron pathways. However, the extrapyramidal system was mistakenly thought to constitute an independent pathway from the striatum descending through polysynaptic connections to the spinal cord. As we have discussed in this chapter, the basal ganglia are in fact part of a network of complex loops that exert their major influence on descending motor systems through projections to the motor and premotor cortex. Nevertheless, movement disorders resulting from basal ganglia dysfunction are still often referred to as extrapyramidal syndromes.

Some of the abnormal movements seen in movement disorders are slow, and some are fast. Some occur at rest, and others are accentuated by

TABLE 16.3 Ranking of Common Movement Disorders by Movement Speed

Bradykinesia, hypokinesia	SLOW
Rigidity	↓
Dystonia	↓
Athetosis	↓
Chorea	↓
Ballismus	↓
Tics	↓
Myoclonus	FAST
Tremor	Slow or fast depending on type

movement or occur only during movement. One common, even if simplified, way of discussing abnormal movements is on a spectrum from slow to fast (Table 16.3). Some movement disorders, such as tremor, can be either slow or fast. Movement disorders can be focal or generalized, unilateral or bilateral. In unilateral movement disorders caused by focal basal ganglia lesions such as infarct, hemorrhage, abscess, tumor, or degeneration, the **movement disorder is contralateral** to the basal ganglia lesion.

During sleep, most obvious movement abnormalities cease, with rare exceptions, such as palatal myoclonus and some tic disorders. Nevertheless, certain aspects of movement disorders often persist in sleep, causing a marked disruption in the normal stages of sleep, and insomnia in some patients. Gait is frequently abnormal in movement disorders, as discussed in KCC 6.5. We will now define several different types of abnormal movements and briefly discuss their differential diagnosis. Localization will also be discussed when possible; however, note that for many movement abnormalities the precise localization is still under investigation. In the sections that follow (see KCC 16.2, 16.3), we will then review a few specific syndromes in greater detail. In addition, we will see how basal ganglia dysfunction affects not only general body movements, but also eye movements, cognition, and emotional regulation (see Table 16.2).

Bradykinesia, Hypokinesia, Akinesia

Bradykinesia means "slowed movements"; **hypokinesia** "decreased amount of movements"; and **akinesia** "absence of movement." These terms are traditionally reserved for localizations at levels higher than the upper motor neurons. In other words, these terms are not used for corticospinal, corticobulbar, lower motor neuron, or muscular disorders. Bradykinetic movement disorders can be caused by increased inhibitory basal ganglia outflow to the thalamus. Reviewing the connections in Figure 16.7 should make it clear that lesions in several regions of the basal ganglia can indirectly cause an increase in inhibitory output from the internal globus pallidus and substantia nigra pars reticulata to the thalamus. Examples include loss of function of the dopaminergic nigrostriatal system, loss of inhibitory pathways from the striatum to the substantia nigra and internal pallidum, or loss of inhibitory neurons projecting from the external pallidum to the subthalamic nucleus. Bradykinesia and hypokinesia resulting from basal ganglia dysfunction are an important feature of Parkinson's disease and related disorders (see KCC 16.2). In addition, decreased spontaneous movements without coma can be seen in diffuse lesions of the frontal lobes (see KCC 19.11), subcortical white matter, thalami, or brainstem reticular formation (see KCC 14.2). These disorders have been given a variety of names, including abulia and akinetic mutism. Depression and advanced schizophrenia can also cause marked psychomotor retardation, which in the extreme is called catatonia.

Rigidity

Increased resistance to passive movement of a limb is called **rigidity.** Rigidity is often present in disorders that cause bradykinesia or dystonia. There are numerous different types of rigidity, seen in different conditions. In spasticity, which results from upper motor neuron lesions, rigidity is velocity dependent. Resistive tone initially increases as the muscles of the limb are stretched, but it may then decrease, giving rise to the term **clasp-knife rigidity** in corticospinal disorders. In contrast, rigidity caused by basal ganglia disorders tends to be more continuous throughout attempts to bend the limb, and it has therefore been called **plastic, waxy,** or **lead pipe rigidity.** A particular kind of plastic rigidity is often seen in parkinsonian disorders (see KCC 16.2), called **cogwheel rigidity** because of the ratchetlike interruptions in tone that can be felt as the limb is bent. Cogwheel rigidity is often thought of as rigidity with a superimposed tremor. Patients with frontal lobe dysfunction often actively resist movement of their limbs. This condition is called **paratonia** or **gegenhalten** and can sometimes be distinguished from other causes of rigidity because it has a more active, inconsistent, or almost voluntary quality.

Dystonia

In **dystonia** the patient assumes abnormal, often distorted positions of the limbs, trunk, or face that are more sustained or slower than in athetosis (see Table 16.3). Dystonia can be generalized, unilateral, or focal. **Focal dystonias** include **torticollis,** which involves the neck muscles; **blepharospasm,** which involves the facial muscles around the eyes; **spasmodic dysphonia,** which involves the laryngeal muscles; and **writer's cramp.** These disorders are presumed to be caused by basal ganglia dysfunction, although usually no focal lesion is found.

Treatment with numerous medications has been tried, with modest success. Many cases of dystonia respond well to injection of small amounts of **botulinum toxin** into the affected muscles, which needs to be repeated every few months. Botulinum toxin acts by interfering with presynaptic acetylcholine release at the neuromuscular junction.

Primary idiopathic torsion dystonia, previously called dystonia musculorum deformans, is an uncommon hereditary disorder causing generalized dystonia. Dystonia can also be seen in other disorders known to involve the basal ganglia, such as tumor, abscess, infarct, carbon monoxide poisoning, Wilson's disease, Huntington's disease, and Parkinson's disease. Episodes of dystonic posturing also occur during certain kinds of focal seizures, possibly because of the spread of seizure activity into the basal ganglia circuits.

Dystonias, or faster dyskinesias such as athetosis or chorea, are commonly seen both acutely and after long-term use of dopaminergic antagonists, including many **antipsychotic** and **anti-emetic medications.** Long-term use can produce delayed, or **tardive, dyskinesia,** in which oral and lingual choreic dyskinesias are often prominent. In about one-third of cases, tardive dyskinesia remains severe despite discontinuation of the offending medication. Other dyskinesias induced more acutely by these medications, including dystonia and parkinsonism, are usually reversible, although sometimes up to several weeks are required for recovery. Parkinsonism (see KCC 16.2) is fairly common with antipsychotic and anti-emetic dopaminergic antagonists, and prophylactic anticholinergic medications are therefore often used with neuroleptic agents, especially in young patients.

An important disorder to recognize early is **Wilson's disease,** an autosomal recessive disorder of biliary copper excretion that causes progressive degeneration of the liver and basal ganglia. Typical neurologic manifestations include the gradual onset of dysarthria, dystonia, rigidity, tremor, choreoathetosis, and prominent psychiatric disturbances. Some patients have a characteristic "wing beating" tremor, in which the arms are abducted with the elbows flexed, and facial dystonia causing a wry smile called risus sardonicus. Liver failure can be the presenting feature, especially in children under the age of 10 years. Almost all patients with neurologic manifestations have brownish outer corneal deposits of copper called Kayser–Fleischer rings that

are visible on ophthalmological slit-lamp examination, and serum ceruloplasmin concentrations of less than 20 milligrams per deciliter. In equivocal cases, liver biopsy may be necessary for diagnosis. Treatment with copper-chelating agents such as penicillamine can arrest progress of this disorder, making early diagnosis critical for improving outcome. Siblings of affected individuals should also be tested for presymptomatic Wilson's disease.

Athetosis

Athetosis is characterized by twisting movements of the limbs, face, and trunk that sometimes merge with faster choreic movements, giving rise to the term **choreoathetosis.** Important causes include perinatal hypoxia involving the basal ganglia, kernicterus caused by severe neonatal jaundice, Wilson's disease, ataxia telangiectasia, Huntington's disease, and antipsychotic or antiemetic medications, among others. In addition, patients with Parkinson's disease (see KCC 16.2) who are being treated with levodopa can experience disabling hyperkinetic dyskinesias, ranging from athetosis to ballismus, at certain times after taking their medications.

Chorea

The word **chorea** means literally "dance" and is applied to movement disorders characterized nearly continuous involuntary movements that have a fluid or jerky, constantly varying quality. In mild cases, low-amplitude chorea may be mistaken for fidgeting or restless movements of the extremities, face, or trunk. Choreic movements are often incorporated into voluntary movements in an attempt to conceal their occurrence. In severe cases, larger-amplitude movements resemble frantic "break dancing," occurring constantly, interrupting voluntary movements, and increasing during distraction or during ambulation. Chorea can involve proximal and distal extremities, the trunk, neck, face, and respiratory muscles.

A major cause of chorea is **Huntington's disease,** an autosomal dominant neurodegenerative disorder that is discussed in KCC 16.3. In addition to chorea, patients with Huntington's disease have severe neuropsychiatric disturbances and ultimately become unable to walk; they die about 15 years after onset, usually from respiratory infections. Most other causes of chorea have a more favorable long-term prognosis. **Benign familial chorea** also usually has an autosomal dominant inheritance pattern, but the chorea is nonprogressive and is not accompanied by cognitive or emotional decline.

Sydenham's chorea, or **rheumatic chorea,** is now rare, except in populations in which group A streptococcal infections are not treated with antibiotics. Onset is usually in adolescence and is more common in females. About 4 months after streptococcal infection, patients insidiously develop increased fidgetiness and emotional lability that may initially be mistaken for normal adolescent behavior. Chorea becomes more apparent over weeks and then gradually subsides, but it recurs later in about one-fifth of patients. Impulsive or obsessive-compulsive behaviors can occasionally persist. The cause of Sydenham's chorea is thought to be antistreptococcal antibodies that cross-react with striatal neurons. However, anti-streptolysin O titers may no longer be elevated by the time chorea occurs. Patients should be treated with antibiotics because rheumatic fever occurs in up to one-third of patients with Sydenham's chorea.

Another important cause of chorea, with increased incidence in young females, is **systemic lupus erythematosus (SLE)**. Chorea can be the first manifestation of SLE. The antinuclear antibody, or other rheumatological blood tests, are often positive, which can be helpful in distinguishing this condition from Sydenham's chorea. Chorea occurring during pregnancy (**chorea gravidarum**) or while oral contraceptives are being taken can represent an initial episode or recurrence of Sydenham's chorea or SLE.

Chorea is commonly seen as a dyskinetic side effect of **levodopa** in Parkinson's disease, or as an early or delayed (tardive) side effect in patients taking **antipsychotic or anti-emetic medications.** There are numerous other causes of chorea, including perinatal anoxia, hyperthyroidism, hypoparathyroidism, electrolyte and glucose abnormalities, phenytoin and other drugs or toxins, neuroacanthocytosis, Wilson's disease, Lesch–Nyhan syndrome, amino acid disorders, and lysosomal storage disorders. **Hemichorea** can occur contralateral to infarct, hemorrhage, tumor, abscess, or other focal lesions of the basal ganglia.

Ballismus

Movements of the proximal limb muscles with a larger-amplitude, more rotatory or flinging quality than chorea are referred to as **ballism** or **ballismus.** The most common type is **hemiballismus,** in which there are unilateral flinging movements of the extremities contralateral to a lesion in the basal ganglia. The classic cause is a lacunar infarct of the subthalamic nucleus, which leads to decreased pallidal inhibition of the thalamus (see Figure 16.7). However, lacunes in other regions of the basal ganglia, especially the striatum, can also cause contralateral hemiballismus. Hemiballismus usually gives way over days or weeks to subtler choreoathetotic movements. However, the movements are often initially quite disabling, and they can be improved with dopaminergic antagonists such as haloperidol. Additional causes of hemiballismus include other unilateral lesions of the basal ganglia, such as hemorrhage, tumor, infection, or inflammation.

Tics

A sudden brief action that is preceded by an urge to perform it and is followed by a sense of relief is called a tic. **Motor tics** usually involve the face or neck, and less often, the extremities. **Vocal tics** can be brief grunts, coughing sounds, howling or barkinglike noises, or even more elaborate vocalizations that sometimes include obscene words (coprolalia). Tic disorders make up a spectrum ranging from transient single motor or vocal tics of childhood to **Tourette's syndrome** (also known as Gilles de la Tourette's syndrome), which is characterized by persistent motor and vocal tics.

Tourette's syndrome is four times more common in boys than girls, and it appears to have an autosomal dominant inheritance pattern with incomplete penetrance. Onset is usually in late childhood, and there is often some spontaneous improvement during adolescence. There is an increased incidence of attention-deficit hyperactivity disorder and obsessive-compulsive disorder in patients with Tourette's syndrome, as well as in family members. Diagnosis is based on clinical presentation, since MRI and other tests are generally unrevealing. The most important aspect of treatment is counseling and education of the patient, family, and other contacts about the nature of the disorder, to reduce stigmatization. Symptoms tend to wax and wane, and during severe periods treatment with dopaminergic antagonists such as haloperidol or pimozide may be beneficial. Alternative pharmacological agents, such as clonidine (a central α_2-receptor antagonist) are increasingly being tried first, despite modest efficacy, because of the long-term side effects of antidopaminergic agents.

Aside from Tourette's syndrome, there are other idiopathic tic disorders, which involve either motor or vocal tics, but not both. Finally, tics can sometimes occur as a consequence of lesions such as encephalitis, infarcts, hemor-

rhage, or tumors; however, these patients usually have other abnormalities in addition to tics.

Myoclonus

Generally considered the fastest of all movement disorders (see Table 16.3), **myoclonus** is a sudden rapid muscular jerk that can be focal, unilateral, or bilateral. Myoclonus can have numerous causes with many possible localizations, including the cerebral cortex, cerebellum, basal ganglia, brainstem, and even the spinal cord. Anoxic brain injury, encephalitis, and toxic or metabolic encephalopathies are common causes of myoclonus seen in severely ill patients. Myoclonus can result from epileptic cortical activity in disorders such as juvenile myoclonic epilepsy and the progressive myoclonic epilepsies. Myoclonus can occur as a paraneoplastic disorder, especially with small cell lung carcinoma, ovarian or breast carcinoma, and neuroblastoma. It is also often prominent in the neurodegenerative condition cortical basal ganglionic degeneration, in prion-related illnesses such as Creutzfeldt–Jakob disease (see KCC 5.9), in lysosomal storage disorders, and late in the course of diffuse Lewy body disease or Alzheimer's disease.

Palatal myoclonus is famous for its notable persistence during sleep, as well as its rhythmicity, which distinguishes it from most other forms of myoclonus. Movements of the palate occur at 1 to 2 hertz and can sometimes extend to the face and even proximal upper extremities. Some patients complain of hearing "clinking sounds" arising from their palate. Palatal myoclonus is typically caused by lesions of the central tegmental tract (see Figure 15.9A), most commonly with brainstem infarcts.

Asterixis (meaning "lack of fixed position"), or **flapping tremor,** is another form of brief rapid movement that is often seen in toxic or metabolic encephalopathies, particularly in hepatic failure, in which case it is called a "**liver flap.**" An examiner can bring out the movements by asking the patient to hold both arms straight in front of their chest with their palms facing forward and wrists extended, as if they are "stopping traffic." In asterixis, intermittent brief flexion movements are seen at the wrists bilaterally, as the patient attempts to hold this pose. Unlike myoclonus, the movements in asterixis are not caused by muscle contractions, but are actually caused by brief interruptions in contraction of the wrist extensors, which have been recorded on EMG as brief silent periods, prompting the term "negative myoclonus."

Tremor

Rhythmic or semirhythmic oscillating movements are called **tremor.** Tremor differs from myoclonus and asterixis in that both agonist and antagonist muscles are activated, resulting in bidirectional movements. Tremor can have many causes, and it can be slow or fast. The specific characteristics of a tremor can help define its localization and etiology (Table 16.4).

Tremors are most simply classified as **resting tremor, postural tremor,** and **intention (ataxic) tremor. Resting tremor** is most prominent when the limbs are relaxed. It is usually easiest to observe while the patient's hands are resting on their lap and they are distracted—for example, while discussing unrelated aspects of their past medical history. The tremor decreases or stops when the patient moves their limbs. Resting tremor is an important feature of Parkinson's disease and is sometimes called **parkinsonian tremor.** The tremor is often asymmetrical and involves mainly the hands and upper extremities, but it can also involve the lower extremities and mouth. Since patients may appear to be rolling something between their thumb and other fingers, the term **pill-rolling tremor** is sometimes used. Resting tremor typically has a frequency of 3 to 5 hertz.

In contrast, **postural tremor** is most prominent when the patient's limbs are actively held in a position—for example, with both arms parallel to the floor—and disappears at rest. **Essential tremor** is the most typical example, and it is arguably the most common of all movement disorders. It is sometimes also called familial, benign, or senile tremor, although none of these names are strictly correct. Essential tremor has a frequency of 5 to 8 hertz. It most commonly involves the hands or arms, but it can also affect the jaw, tongue, lips, head, vocal cords, and less often, the legs or trunk. It is usually bilateral, but it may be asymmetrical. The tremor can be mild, or it can cause significant functional impairment. Patients often complain about difficulty holding a glass of water without spilling, and they may have problems with handwriting. The tremor increases with stress and can often be improved by beta-adrenergic antagonists such as propranolol. A drink of alcohol frequently decreases the tremor temporarily. Essential tremor often occurs in families, with autosomal dominant inheritance; however, sporadic cases occur as well. Onset can occur anytime from early adulthood to advanced age, and the tremor tends to progress only very slightly over time. No treatment is needed for mild cases, and more severe cases often show symptomatic improvement with beta-blockers or primidone. In very severe cases, ventrolateral thalamotomy or thalamic stimulation (see KCC 16.4) may be beneficial.

Intention tremor is also called **ataxic tremor** because it is usually a feature of appendicular ataxia associated with cerebellar disorders, as discussed in Chapter 15 (see KCC 15.2). Intention tremor occurs as the patient attempts to move their limb toward a target and has irregular, oscillating movements in multiple planes throughout the trajectory. Intention, or ataxic, tremor has a frequency of 2 to 4 hertz.

A variety of other terms for tremor are sometimes used, and they can cause confusion. **Action tremor** can mean either a postural or an intention tremor. **Static tremor** can mean either a resting or a postural tremor. Intention tremor is sometimes also called **kinetic tremor.** When tremor increases toward the end of a movement, as is common in intention tremor, it is called **terminal tremor.** In addition, terminal tremor can result from the emergence of a postural tremor as the limb approaches its final position.

Before leaving the topic of tremors, let's briefly discuss the other examples listed in Table 16.4. In addition to ataxic (intention) tremor, cerebellar lesions can cause other kinds of tremors that occur at rest or while holding a posture. Despite its name, so-called **rubral tremor** is most likely caused by a lesion not of the red nucleus, but rather of the nearby superior cerebellar peduncle or other cerebellar circuitry. Rubral tremor has a frequency of 2 to 4 hertz and is usually of low amplitude at rest, but it becomes more violent as soon as the limbs are abducted slightly or attempts are made to hold a posture or perform a movement. This tremor is usually caused by multiple sclerosis or brainstem infarcts, and it can resemble the tremor seen in Wilson's disease. Other tremors seen in cerebellar disorders include trunk and head titubation associated with lesions of the vermis, and palatal myoclonus, which some authorities classify as a tremor rather than true myoclonus.

Postural tremor can be caused by a variety of drugs, medications, metabolic derangements, alcohol withdrawal, intense fear, anxiety, and other conditions. In some cases the tremor is thought to be caused by an enhancement of the normal **physiological tremor,** present in all individuals but not usually visible without special equipment. Physiological tremor has a frequency of 8 to 13 hertz, slightly higher than essential tremor, and is enhanced with

TABLE 16.4 Classification of Tremors

Resting tremor
Parkinsonian tremor
Cerebellar disorders ("rubral" tremor)
Postural tremor
Essential tremor
Toxic/metabolic causes
Exaggerated physiological tremor
Neuromuscular disorders
Cerebellar disorders ("rubral" tremor; trunk and head titubation)
Parkinsonism
Intention tremor
Cerebellar appendicular ataxia
All causes of postural tremor, especially near end of movement
Other disorders resembling tremor
Clonus
Myoclonus
Flapping tremor (asterixis)
Dystonic tremor
Fasciculations
Motor seizures

caffeine. In addition, peripheral neuromuscular disorders can produce a postural and intention tremor. Some patients with Parkinson's disease actually have a postural tremor, in addition to the more typical parkinsonian resting tremor.

Disorders that cause postural tremor often cause some intention tremor as well. As already noted, the tremor may be especially apparent as the limb approaches its final position, causing the postural tremor to emerge. Some other disorders that cause rhythmic or semirhythmic movements may be confused with tremor, including clonus, myoclonus, flapping tremor (asterixis), fasciculations, and focal clonic seizures. These disorders are not considered true tremors. ■

KEY CLINICAL CONCEPT
PARKINSON'S DISEASE AND RELATED DISORDERS

16.2 **Parkinson's disease** is a common idiopathic neurodegenerative condition caused by loss of dopaminergic neurons in the substantia nigra pars compacta. It is characterized by asymmetrical resting tremor, bradykinesia, rigidity, and postural instability, which usually respond to therapy with levodopa. **Parkinsonism** and **parkinsonian signs** are more general terms used to describe several other conditions that have some features of Parkinson's disease, especially the bradykinesia and rigidity. In this section we will first discuss idiopathic Parkinson's disease and then briefly review several other conditions associated with parkinsonism (Table 16.5).

TABLE 16.5 Differential Diagnosis of Parkinsonism

Parkinson's disease
Drug-induced parkinsonism (dopamine antagonists)
Multisystem atrophy
Striatonigral degeneration
Shy–Drager syndrome
Olivopontocerebellar atrophy
Progressive supranuclear palsy (Steele–Richardson–Olszewski syndrome)
Dementia with Lewy bodies
Cortical basal ganglionic degeneration
Machado–Joseph disease (SCA-3)[a]
Dentatorubropallidoluysian atrophy
Juvenile-onset Huntington's disease
Wilson's disease
MPTP toxicity
Von Economo's encephalitis lethargica
Dementia pugilistica
Other metabolic and neurodegenerative disorders
Disorders resembling parkinsonism:
Hydrocephalus
Frontal lobe lesions
Diffuse subcortical lesions
Depression

[a]SCA-3, spinocerebellar ataxia, type 3.

Idiopathic Parkinson's Disease

Parkinson's disease is a sporadic disorder of unknown etiology that occurs worldwide. The usual age of onset is between 40 and 70 years. About 1% of individuals over age 65 are affected. There is generally no familial tendency, except in rare cases of familial Parkinson's. Pathologically, there is loss of pigmented dopaminergic neurons in the substantia nigra pars compacta, causing the substantia nigra to appear pale to the eye on cross section (Figure 16.10A). Remaining dopaminergic neurons often contain characteristic cytoplasmic inclusions called **Lewy bodies,** which are eosinophilic, contain ubiquitin and α-synuclein, and have a faint halo (see Figure 16.10B). There is also loss of pigmented neurons in other regions of the nervous system.

Diagnosis is based on clinical features. Initially patients may have only some subtle difficulty using one limb, slowing of movements, or an asymmetrical resting tremor. Eventually patients with idiopathic Parkinson's disease usually have the classic triad of **resting tremor, bradykinesia,** and cogwheel **rigidity,** accompanied by postural instability that causes an **unsteady gait.** The disorder is initially unilateral but later becomes bilateral although the severity often remains **asymmetrical.** It nearly always **improves when treated with levodopa.**

A diagnosis other than idiopathic Parkinson's should be suspected in cases of symmetrical symptoms, absence of resting tremor, or lack of response to dopaminergic agents. Other reasons to suspect alternative diagnoses are the presence of features of atypical parkinsonian disorders (which we will discuss shortly) or rapid progression of symptoms. In Parkinson's disease, **progression is usually insidious,** over the course of 5 to 15 years, and can eventually cause severe disability and death. Since onset is late in life, many patients die of other causes rather than as a direct result of Parkinson's disease.

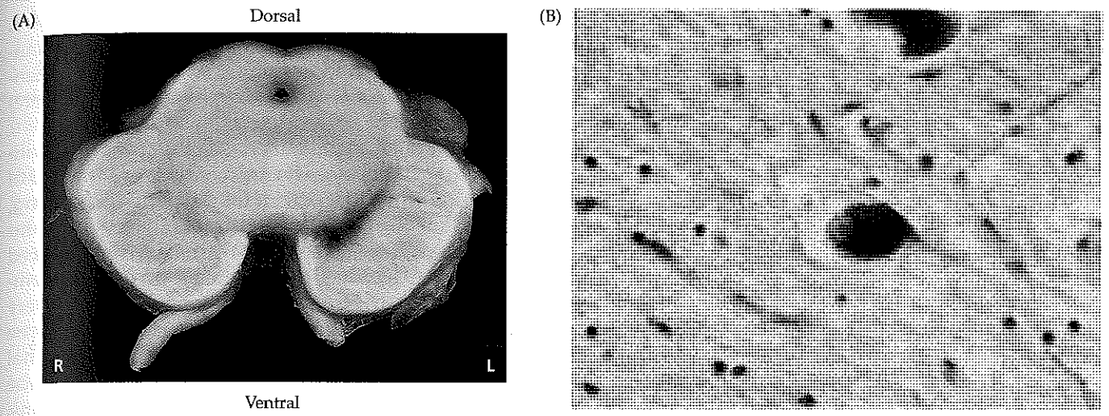

Figure 16.10 Pathologic Changes of Parkinson's Disease (A) Section through the midbrain from a patient who died with Parkinson's disease. Asymmetrical pallor affecting the right substantia nigra greater than the left can be seen, caused by degeneration of pigmented dopaminergic neurons in the substantia nigra pars compacta. (B) Microscopic section through the substantia nigra from a different patient with Parkinson's disease showing a typical Lewy body. The Lewy body has a characteristic dense (pink) center with a lighter halo and is located in the cytoplasm of a darkly pigmented dopaminergic neuron. (A from Nolte J. 1999. *The Human Brain,* 4th Ed. Mosby, St. Louis; courtesy of Naomi Rance, The University of Arizona College of Medicine. B courtesy of Jean Paul G. Vonsattel, Massachusetts General Hospital, Harvard School of Medicine.)

Some of the clinical features of Parkinson's disease are worth discussing in greater detail. The resting "pill rolling" tremor has already been discussed in KCC 16.1, as has the rigidity, which is often of the cogwheel type. There are numerous manifestations of bradykinesia and hypokinesia in Parkinson's disease. There is a characteristic decrease in spontaneous blink rate and in facial expression called **masked facies** or **hypomimia.** The voice becomes **hypophonic,** and speech has a hurried, muttering quality. Saccades are slow, and smooth pursuit eye movements are often broken up into a series of catch-up saccades. Writing becomes small, a symptom termed **micrographia.** The posture is stooped, and some patients may have some dystonia. **Postural instability,** the diminished ability to make reflex postural adjustments that maintain balance, can be disabling and results in a characteristic **parkinsonian gait** (see Table 6.6). If pulled backward slightly, patients may exhibit **retropulsion,** in which they take several backward steps to regain balance, or they may fall. They often cannot rise from a chair without using their hands, and they have difficulty initiating gait. Once they have started, they tend to walk with small shuffling steps, termed a **festinating gait.** They sometimes appear to be continually falling and shuffling forward, referred to as **anteropulsion.** Arm swing is diminished, and they often exhibit **en bloc turning,** in which turns are executed without the normal twist of the torso. Inability to suppress blinking when the center of the brow ridge (glabella) is tapped repeatedly (**Myerson's sign**), is a nonspecific finding that can be seen in other neurodegenerative conditions as well.

Dementia is not an early feature of Parkinson's disease, but estimates of dementia later in the course vary from 15 to 40% or higher. Some of these cases are likely due to the coincidence of Alzheimer's disease and Parkinson's disease, and others may represent diffuse Lewy body disease (discussed shortly), but additional cases may not be explained by either of these causes. Patients with advanced Parkinson's disease often have **bradyphrenia,** in which responses to questions are slowed but may be accurate if enough time is allowed. Depression and anxiety are common, especially in advanced Parkinson's disease. Other associated features in Parkinson's disease of uncertain etiology include seborrhea and hypersalivation.

The most effective drug for treatment of Parkinson's disease is **levodopa.** Most formulations also contain **carbidopa,** a decarboxylase inhibitor that cannot cross the blood–brain barrier. Carbidopa inhibits the breakdown of levodopa to dopamine in peripheral tissues, making more levodopa avail-

able for conversion to dopamine in the central nervous system where it is needed. The most common peripheral side effects of dopamine are gastrointestinal disturbances and orthostatic hypotension, and these are substantially reduced by carbidopa. Higher doses of levodopa can sometimes precipitate psychiatric symptoms such as psychosis.

As Parkinson's disease progresses, patients have other problems with levodopa therapy. Troublesome **wearing off** can occur toward the end of the time between doses during which the patient may experience **freezing,** becoming almost unable to move. The opposite problem—levodopa-induced **dyskinesias**—also becomes increasingly troublesome. With advanced Parkinson's disease, patients may increasingly experience **on–off phenomena,** in which they fluctuate between dyskinesias and immobility, with very little time during which they are functional. On–off phenomena may be helped somewhat by sustained-release formulations. In addition, catechol *O*-methyltransferase (COMT) inhibitors have recently shown some promise in increasing plasma levodopa levels and decreasing wearing-off symptoms.

There is currently some controversy about whether to start therapy with levodopa early in the course of Parkinson's disease or to reserve it for later, when other agents are no longer effective. Other treatments used for Parkinson's disease include anticholinergic agents such as benztropine mesylate (Cogentin) and trihexyphenidyl (Artane). The antiviral agent amantadine has an anticholinergic and antiglutamatergic effect and probably also increases the release of dopamine in the striatum. Dopaminergic agonists such as pergolide, bromocriptine, ropinirole, and pramipexole are also sometimes used. Selegiline works by inhibiting the breakdown of dopamine. Early claims that selegiline may slow progression of Parkinson's disease have not been substantiated, and there remains no known agent that alters the progression of this disease. Surgical treatments for Parkinson's disease are discussed in KCC 16.4.

It should be apparent from reviewing Figure 16.7 how decreased dopaminergic input to the striatum in Parkinson's disease results in increased inhibition of the thalamus by basal ganglia outputs (through both the direct and indirect pathways), causing a hypokinetic movement disorder. In addition, Figure 16.7 should make clear the beneficial effects of agents that enhance dopaminergic actions or inhibit cholinergic actions. However, it is important to recall that this simplified schematic is still incomplete; for example, it fails to account for the tremor seen in Parkinson's disease.

Other Causes of Parkinsonism

Antipsychotic and anti-emetic **dopaminergic antagonists** such as haloperidol (Haldol), and prochlorperazine (Compazine) commonly cause parkinsonian signs such as rigidity, hypokinesia, and even resting tremor. Unlike Parkinson's disease, onset is usually abrupt and symptoms are symmetrical. Occasionally symptoms can persist for several weeks after the offending agent has been discontinued, making a careful review of prior medication history essential when evaluating patients with subacute onset of parkinsonism.

Several neurodegenerative conditions other than Parkinson's disease are associated with parkinsonism (see Table 16.5). These are sometimes referred to as **parkinsonism plus** syndromes. They often produce atypical parkinsonism, which differs from idiopathic Parkinson's disease by having relatively symmetrical symptoms, absence of resting tremor, and little response to dopaminergic agents. One group of neurodegenerative conditions associated with **atypical parkinsonism** falls under the heading of **multisystem atrophy.** These disorders include striatonigral degeneration, Shy–Drager syndrome, and olivopontocerebellar atrophy. In multisystem atrophy there is loss of dopaminergic neurons of the substantia nigra pars compacta (see Figure 16.7). However, there is also loss of striatal neurons projecting to the globus pallidus and substantia nigra pars reticulata. Therefore, even if dopaminergic transmission is enhanced pharmacologically, there will still be decreased inhibition of the basal ganglia output nuclei, resulting in increased inhibition of the thalamus, and parkinsonism (see Figure 16.7). This may explain the relative insensitivity of multisystem atrophy to levodopa compared to Parkinson's disease.In **striatonigral degeneration,** atypical parkinsonism is often present. In **Shy–Drager syndrome** there is marked atrophy of the intermediolateral cell column of the spinal cord (see Figures 6.4D, 6.12B). Therefore, patients with Shy–Drager syndrome have parkinsonism together with autonomic disturbances such as marked orthostatic hypotension, impotence, and urinary incontinence (see KCC 7.5). **Olivopontocerebellar atrophy** is characterized by parkinsonism together with ataxia. Often these different syndromes of multisystem atrophy overlap significantly.

Another important neurodegenerative condition in which parkinsonism is prominent is **progressive supranuclear palsy** (**PSP**), also known as **Steele–Richardson–Olszewski syndrome.** In this disorder there is degeneration of multiple structures around the midbrain–diencephalic junction, including the superior colliculus, red nucleus, dentate nucleus, subthalamic nucleus, and globus pallidus. The range of **vertical eye movement** is usually markedly limited, including both upward and downward saccades, relatively early in the illness (see Chapter 13). This finding should be distinguished from mildly decreased upward eye movements seen in numerous neurodegenerative conditions, and even in normal aging. Patients with PSP also have waxy rigidity, bradykinesia, and a tendency to experience falls early in the course of the illness. There is often a characteristic wide-eyed stare. In contrast to Parkinson's disease, rigidity early in the course of PSP tends to be more prominent proximally—for example, in the neck rather than in the limbs.

Dementia with Lewy bodies (also called diffuse Lewy body disease) is increasingly being recognized as an important cause of parkinsonism and dementia. Lewy bodies in this disorder are found in the substantia nigra and throughout the cerebral cortex. Patients often have prominent psychiatric symptoms, including visual hallucinations, relatively early in the course of the disorder, which tend to have episodic exacerbations. In **cortical basal ganglionic degeneration,** there is parkinsonism that resembles Parkinson's disease by being asymmetrical, together with marked cortical features such as apraxia (see KCC 19.7) and corticospinal abnormalities.

Machado–Joseph disease (also called spinocerebellar ataxia type 3) and **dentatorubropallidoluysian atrophy** are rare neurodegenerative disorders that often include parkinsonian features. Both are transmitted by autosomal dominant inheritance and are caused by expanded trinucleotide repeats (see KCC 16.3). **Huntington's disease,** another trinucleotide repeat disorder, can present with predominantly parkinsonian features in the unusual patients in which onset is in childhood or early adulthood. **Wilson's disease** (see KCC 16.1) can also cause tremor, rigidity, and bradykinesia. Illicit drug users who were exposed to the toxin **MPTP** while taking a synthetic heroine-like meperidine analog developed parkinsonism caused by destruction of pars compacta dopaminergic neurons.

In 1914–1930 there was an epidemic of **von Economo's encephalitis lethargica,** a condition that has since disappeared. Many patients were left with severe parkinsonism following this illness. Boxers may develop **dementia pugilistica,** in which there is parkinsonism and cognitive decline.

There are numerous other causes of parkinsonism that are beyond the scope of this text (see the references at the end of this chapter for more details). We should mention, however, that bradykinesia, rigidity or paratonia, hypophonia, and unstable gait can be seen in **hydrocephalus, frontal lobe lesions,** and **diffuse subcortical disorders,** and these disorders can sometimes be hard to distinguish from parkinsonism. In addition, severe **depression** can cause paucity of movement that may be mistaken for parkinsonism. ■

KEY CLINICAL CONCEPT
HUNTINGTON'S DISEASE

16.3 Huntington's disease is an autosomal dominant neurodegenerative condition characterized by a progressive, usually choreiform movement disorder, dementia, and psychiatric disturbances, ultimately leading to death. The pathologic hallmark of Huntington's disease is progressive atrophy of the striatum, especially involving the caudate nucleus. Clinical manifestations include abnormalities in all four domains of basal ganglia function discussed earlier (see Table 16.2; Figure 16.8). Specifically, Huntington's disease results in abnormalities of body movements, eye movements, emotions, and cognition.

The overall prevalence of Huntington's disease is about 4 to 5 cases per million people, although it is higher in those of northern European ancestry. Usual age of onset is between 30 and 50 years, although early-onset and late-onset cases are occasionally seen. Initial symptoms are usually subtle chorea (see KCC 16.1) and behavioral disturbances. These symptoms may be denied by the patient and brought to medical attention by family members or other contacts. While taking the history, the examiner often can elicit abnormalities extending back several years in retrospect. Interestingly, those experienced with Huntington's disease can often detect subtle eye movement abnormalities before other manifestations become apparent. These include slow saccades, impaired smooth pursuit, sluggish optokinetic nystagmus (see Chapter 13), and a characteristic difficulty initiating saccades without moving the head or blinking.

Early movement abnormalities include clumsiness and subtle chorea as described in KCC 16.1, such as mild jerking, fidgety movements. Mild chorea may be voluntarily suppressed and examiners can make it more obvious by having patients walk or by asking them to hold their arms outstretched with eyes closed. In addition to chorea, other abnormal movements include tics, athetosis, and dystonic posturing. In the rare cases of juvenile onset, a more parkinsonian phenotype is often present.

Common psychiatric manifestations include affective disorders such as depression and anxiety, obsessive-compulsive disorder, impulsive or destructive maniclike behavior, and occasionally psychosis. Cognitive impairments are multiple and include decreased attention (see KCC 19.14), a memory disorder that affects both recent and remote memories, anomic aphasia (see KCC 19.6), and impaired executive functions (see KCC 19.11). In advanced Huntington's disease, patients are profoundly demented and lose the ability to make nearly all purposeful movements. They are bedbound, cannot speak, and usually die of respiratory infections. Median survival from the onset of first symptoms is about 15 years.

Pathologically, the most dramatic change in Huntington's disease is progressive atrophy of the caudate nucleus. The putamen is also involved, and to a lesser extent the nucleus accumbens atrophies as well. As already noted, the degeneration initially affects striatal neurons of the indirect pathway (see Figure 16.7), possibly explaining why a hyperkinetic movement disorder usually results. Atrophy of the caudate and putamen can lead the lateral ventricles to appear enlarged on CT and MRI scans. This condition is easily distinguished from hydrocephalus because in Huntington's disease the caudate head no longer forms the bulge normally seen on the walls of the lateral ventricles in coronal sections (see Figure 4.14C). As the disease progresses, milder atrophy of the cerebral cortex also occurs.

In a landmark achievement for human genetics, the abnormal gene causing Huntington's disease was mapped in 1983 and cloned in 1993. The gene is located on chromosome 4, and it includes a region containing multiple repeats of the trinucleotide sequence CAG in tandem. Normal individuals have fewer than 30 CAG repeats in this gene. Individuals with over 40 CAG repeats either have Huntington's disease or will ultimately develop this disorder. The higher the number of CAG repeats, the earlier the onset of symptoms. The gene causing Huntington's disease encodes a protein called huntingtin. Active investigation is under way to clarify how an increase in CAG repeats, encoding multiple copies of the amino acid glutamine in the huntingtin protein, can lead to Huntington's disease. It is hoped that this information will suggest a cure for this devastating condition. In addition to the gene for Huntington's disease, several other genetic disorders, many of which have prominent neurologic manifestations, have also been found to be caused by expanded trinucleotide repeats.

A suspected diagnosis of Huntington's disease can be made on the basis of the appearance of typical clinical features, especially if there is a positive family history. Inheritance is autosomal dominant with complete penetrance. However, in many cases the family history is sketchy, or there may be only suggestive leads, such as a parent who died young or was institutionalized. Other causes of chorea should be considered in the differential diagnosis (see KCC 16.1). With the cloning of the Huntington's disease gene, it is now possible to perform a genetic test for Huntington's disease even before symptoms appear. Because the disorder remains incurable, however, such testing raises many ethical and philosophical issues. The test should therefore be performed only on consenting adults in a setting where specialized counseling is available.

Treatment for Huntington's disease is currently directed at alleviating symptoms and does not alter the course of the disease. Chorea can be reduced somewhat with antidopaminergic agents. Psychiatric manifestations can be treated with counseling and psychotropic medications. The coming years may bring advances in molecular medicine will enable more definitive treatments for Huntington's disease and other degenerative disorders. ■

KEY CLINICAL CONCEPT
STEREOTACTIC SURGERY FOR MOVEMENT DISORDERS AND OTHER CONDITIONS

16.4 Stereotactic surgery is a relatively old technique that has had increasing applications in neurosurgery in recent years. This method allows relatively precise localization in three-dimensional space of structures in the brain, based on surface landmarks. There are several variations on this technique, and only the basic concept will be discussed here.

To establish a stereotactic coordinate system, reference points are first applied to the patient's head. Examples of reference systems used in stereotactic surgery include a series of small radiopaque markers placed on the patient's scalp, or a rigid frame affixed to the skull under local anesthesia. The patient, with the reference system in place, is then taken to the CT or MRI scanner, and images are obtained of the brain and reference system. A computer program can then calculate the location of any point in the brain relative to the external reference system.

The patient is then taken to the operating room with the reference system still in place. Using the information provided by the scanned images, the surgeon can guide the tip of a needle or probe to a precise location in the brain through a small hole in the skull. This procedure can be performed under local anesthesia. Applications of this stereotactic technique in

neurosurgery have been numerous. For example, an instrument can be inserted through a narrow tube to obtain a **biopsy** of a lesion located deep within the brain. Prior to the development of stereotactic methods, a similar biopsy may have required highly invasive surgery or may have been impossible to perform. Fluid collections such as abscesses can be drained stereotactically, providing therapeutic benefit. In addition to surgery, stereotactic methods are used in radiation therapy. Known as **stereotactic radiosurgery,** this technique can be used to target highly focused beams of radiation such as the "gamma knife," applied externally, to a specific location within the brain.

In the treatment of movement disorders, stereotactic methods are used to carefully place lesions or stimulators at specific points in basal ganglia pathways. Lesions are made by placing the tip of an electrode in a particular location, and then using electrical current to heat the tip sufficiently to cause a lesion. These lesions are placed in two main locations. For **Parkinson's disease** that has progressed to severe on–off swings (see KCC 16.2) despite medical therapy, **pallidotomy** can provide substantial improvement in bradykinesia, rigidity, and medication-related dyskinesias. In this procedure a lesion is placed stereotactically in the ventral posterior portion of the globus pallidus. The lesion interrupts the inhibitory output pathway carried by the ansa lenticularis from the medial globus pallidus to the ventral lateral nucleus of the thalamus (see Figures 16.7, 16.9). Removal of this inhibition may explain why bradykinesia and rigidity are improved. However, it is somewhat perplexing that this lesion does not cause deficits. It is also unclear why medication-related dyskinesias are improved with this treatment. The benefit of pallidotomy in patients with Parkinson's disease is most dramatic contralateral to the lesion, although there is usually some temporary ipsilateral benefit as well.

For debilitating **tremor** (see KCC 16.1), especially in cases of severe essential tremor not responding to medications, **thalamotomy** can be beneficial. In this procedure a lesion is placed stereotactically in the posterior portion of the ventral lateral nucleus of the thalamus (see Figure 16.7). The mechanism for improvement in tremor produced by this lesion is not known. Also, like pallidotomy, it is not clear why this lesion does not cause a significant motor deficit.

Other recent surgical approaches to the treatment of movement disorders have involved the implantation of electrical stimulating electrodes in the thalamus, subthalamus, or globus pallidus, instead of the creation of lesions. These devices can be turned on or off by the patients at will. When on, electrical current at the tip of the electrode apparently causes transient dysfunction of nearby neurons, resulting in improvement in the movement disorder. For example, subthalamic stimulators have been shown to alleviate the bradykinesia and other symptoms of Parkinson's disease, as might be predicted from the relative hyperkinesia usually produced by inhibited function in this nucleus (see Figure 16.7). Another surgical approach has been transplantation of fetal midbrain neurons or adrenal chromaffin cells into the striatum of patients with Parkinson's disease. The long-term benefits of transplantation remain uncertain, and enthusiasm for these procedures has waned in recent years with the increasing popularity of stereotactically placed lesions or stimulators. ■

CLINICAL CASES

CASE 16.1 UNILATERAL FLAPPING AND FLINGING*

MINICASE

A 65-year-old HIV-positive man began having **involuntary flinging movements of the right arm and leg,** which became progressively worse over the course of 1 month, making gait and use of the right hand difficult. On exam, he had **continuous wild, uncontrollable flapping and circular movements of the right arm, and occasional jerky movements of the right leg,** with an unsteady gait, falling to the right. The remainder of the exam was unremarkable.

LOCALIZATION AND DIFFERENTIAL DIAGNOSIS

1. On the basis of the symptoms and signs shown in **bold** above, where is the lesion?
2. What is the most likely diagnosis, and what are some other possibilities?

Discussion

The key symptoms and signs in this case are:

- **Involuntary, wild flinging movements of the right arm and leg**

1. This patient had a unilateral hyperkinetic movement disorder that could be described as hemiballismus or hemichorea (see KCC 16.1). As discussed in the section on hyperkinetic and hypokinetic movement disorders earlier in the chapter, and in KCC 16.1, hyperkinetic movement disorders are often caused by dysfunction of the contralateral subthalamic nucleus, or of indirect-pathway neurons in the striatum (see Figure 16.7). A review of Figure 16.7 should make it clear that a lesion in either location would result in less inhibitory output from the internal segment of the globus pallidus (and the substantia nigra pars reticulata) to the thalamus, resulting in increased excitatory activity traveling from the thalamus to the motor cortex.

   The most likely *clinical localization* is left subthalamic nucleus or left striatum.

2. Given the patient's age, a lacunar infarction in the left subthalamic nucleus or left striatum is the most likely diagnosis. A small hemorrhage in these locations is also possible. Nevertheless, the history of gradual onset over the course of a month would be somewhat unusual for either an infarct or a hemorrhage. Especially because the patient has a history of HIV, other brain lesions should also be considered. The most common intracranial mass lesions in patients with HIV (see KCC 5.9) are toxoplasmosis and primary central nervous system lymphoma, either of which could occur in the subthalamic nucleus or striatum.

Clinical Course and Neuroimaging ➡

A **brain MRI** with gadolinium (Figure 16.11) showed a ring-enhancing lesion in the region of the left subthalamic nucleus (compare to Figures 16.4D and 16.9). Given the clinical setting, the patient was treated empirically with the antitoxoplasmosis medications pyrimethamine and sulfadiazine (see KCC 5.9). Serum and cerebrospinal fluid *Toxoplasma* titers were positive. Four weeks later the patient's right-sided hemiballismus had subsided, but he still had some mild wavering movements on finger-to-nose and heel-to-shin testing on the right side. Repeat MRI showed that the lesion had shrunk markedly in response to therapy. MRI after 4 months showed the lesion to be nearly gone, with only a small homogeneous region of enhancement remaining.

*A description of this patient was published previously by Provenzale and Schwarzschild in 1994; see the references at the end of this chapter.

CASE 16.2 IRREGULAR JERKING MOVEMENTS AND MARITAL PROBLEMS

CHIEF COMPLAINT

A 35-year-old man with a recent history of jerking movements went with his wife to see a psychiatrist for marital problems.

HISTORY

The wife reported that during recent months her husband had been having **occasional irregular jerking movements of the head, trunk, and limbs.** At night he sometimes would grind his teeth in his sleep, grip his wife's hand tightly without knowing it, or swallow noisily. The husband **denied having any involuntary movements** but said "they could be there." He did admit to **occasional stumbling,** having recently fallen down a flight of stairs. However, he denied that this represented any significant change in his gait over recent years. He worked as a salesman in a small business and denied any depression or problems due to intellectual function or psychiatric problems. In the army he was a high-70s golfer. At the time of consultation he was shooting 120, but he attributed this decrease in performance to practicing golf less often than previously. His wife felt something was wrong and urged him to seek medical attention, and his refusal led to **bitter arguments.**

FAMILY HISTORY

The wife's family history was unremarkable. The husband had no siblings. His father had died at age 50 years from Huntington's disease (diagnosed at 44 years). His mother's family was unaffected. The following pedigree gives further details:

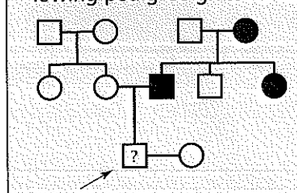

○ = Unaffected female
□ = Unaffected male
● = Female with Huntington's disease
■ = Male with Huntington's disease
? = The man in this case

PHYSICAL EXAMINATION

At the end of the counseling session, the psychiatrist set aside some time to examine the husband.

Vital signs: T = 98.6°F, P = 76, BP = 140/80, R = 16.
Neck: Supple.
Lungs: Clear.
Heart: Regular rate with no murmurs.
Abdomen: Benign.
Extremities: Normal.
Neurologic exam:

MENTAL STATUS: Alert and fully oriented. Speech fluent. Good attention and calculation skills. Recalled 3/3 objects after 5 minutes. **Affect slightly to moderately blunted,** with some apathy regarding emotional impact of the consultation, stating, for example, "If I've got it, I've got it."

CRANIAL NERVES: Normal, except that **saccadic eye movements were moderately slowed.**

MOTOR: **Rare, brief, irregular, restless-appearing movements in the face, neck, trunk, and upper extremities. Tone was normal to slightly decreased** in all extremities. 5/5 power throughout.

REFLEXES:

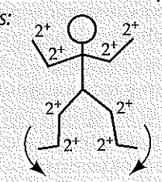

COORDINATION: Normal on finger-to-nose and heel-to-shin testing.

GAIT: Normal. Involuntary movements were not noticeably increased during walking. **Tandem gait was slightly unsteady.**

SENSORY: Intact.

LOCALIZATION AND DIFFERENTIAL DIAGNOSIS

1. On the basis of the symptoms and signs shown in **bold** above, which of the four parallel channels through the basal ganglia (see Table 16.2) are abnormal in this patient?
2. Does this patient have a predominantly hyperkinetic or hypokinetic movement disorder? Referring to Figure 16.7, identify the parts of the basal ganglia in which dysfunction could explain these movements.
3. Which mode of inheritance is suggested by the patient's pedigree, assuming he is affected by the same disorder as other family members? What is the most likely diagnosis? What genetic abnormality causes this disorder? What parts of the brain are predominantly affected?

Discussion

The key symptoms and signs in this case are:

- **Irregular jerking movements, slightly decreased tone, and unsteady gait**
- **Moderately slowed saccadic eye movements**
- **Flat affect, argumentative, and denied having any involuntary movements**

1. The abnormal movements suggest involvement of the motor channel; impaired saccades suggest involvement of the oculomotor channel (see Table 16.1). The patient's emotional changes and disinhibited behavior suggest involvement of the limbic channel and possibly the prefrontal channel as well (see KCC 19.11).
2. This patient has a bilateral hyperkinetic movement disorder, best described as a mild tic or chorea (see KCC 16.1). Hyperkinetic movements of this kind may be caused by bilateral dysfunction in the subthalamic nuclei, or in the striatal neurons of the indirect pathway (see Figure 16.7).
3. The pedigree suggests an autosomal dominant inheritance pattern. The most likely diagnosis is Huntington's disease (see KCC 16.3). This disorder is caused by an expanded CAG trinucleotide repeat in the gene encoding the huntingtin protein, located on chromosome 4. In early Huntington's disease, the indirect-pathway neurons of the striatum are preferentially involved (see Figure 16.7). Later in the course of this disorder, there is gross degeneration of the bilateral caudate and putamen, with lesser involvement of the cerebral cortex as well.

Clinical Course and Neuroimaging 722

The psychiatrist was concerned that the husband in this couple could have early Huntington's disease, and he referred the patient to a neurologist. This occurred in the 1970s, before genetic testing for Huntington's disease was available. Treatment with baclofen had a modest effect in decreasing the patient's involuntary movements.

Three years later his symptoms had progressed substantially, and he was briefly admitted to the hospital for further evaluation. In the interim he had lost his job as a salesman because "business was slow." He was then fired from work as a newspaper distributor because he "was robbed." In addition, he had recently divorced. On exam, mental status was notable for mild irritability, and slightly garbled speech when speaking at high speeds. In addition, he made some errors when asked to repeat nonsense syllables. He had developed frequent paroxysmal involuntary twitches of all four limbs, worse distally than proximally. Gait had a slight waddling character, with some dystonic arm carriage. Head CT was normal except for a very slight enlargement of the lateral ventricles. EEG was normal except for low voltage.

Eleven years after initial presentation the patient was readmitted after expressing suicidal thoughts when his driver's license was revoked. He said he was stopped by the police, but he was unable to say why, stating only that he was "trying to make a left turn." He had last worked about 1 year previously doing part-time paper deliveries. He was still able to live independently at home. On exam, he was alert and oriented ×3. Speech was fluent but had an abnormal rhythm. He was able to follow complex commands. Memory and calculating skills were intact. He had a labile affect, behaving in a frustrated, angry, and impulsive manner. For example, he threatened suicide if he could not drive. He had poor insight into his illness, denying any abnormalities in speech or movements. Motor exam was notable for hypotonia, motor

impersistence (see KCC 19.14), and continuous choreiform writhing movements of the tongue, arms, neck, and torso. The involuntary movements were worsened by walking, and he was unable to perform tandem gait.

A **brain MRI** performed at this time showed marked flattening of the lateral walls of the lateral ventricles (Figure 16.12A) when compared to an MRI from a normal individual (see Figure 16.12B). This shape suggests bilateral atrophy of the head of the caudate nucleus, which normally bulges into the lateral ventricle in this location (see Figure 16.12B). Note that some degree of cortical atrophy was present as well.

The patient was treated with additional medications, including dopamine antagonists such as haloperidol with little benefit. He was discharged home once it was ascertained that he was no longer suicidal, and he was followed by both a psychiatrist and a neurologist as an outpatient. Within 2 years he could no longer be managed at home and required admission to a chronic inpatient psychiatric facility, where he died soon afterward.

Related Case. Figure 16.13 shows coronal sections of two half brains. The right half is from the brain of a patient who died with Huntington's disease (this is a different patient from the one presented in Case 16.1). The left half is from the brain of a normal individual who died in an automobile accident. Note that the patient with Huntington's disease had severe atrophy of the caudate nucleus and putamen, as well as some atrophy of the nucleus accumbens and cerebral cortex.

CASE 16.1 UNILATERAL FLAPPING AND FLINGING

Figure 16.11 Ring-enhancing Toxoplasmosis Lesion in Left Subthalamic Nucleus Coronal T1-weighted MRI with intravenous gadolinium.

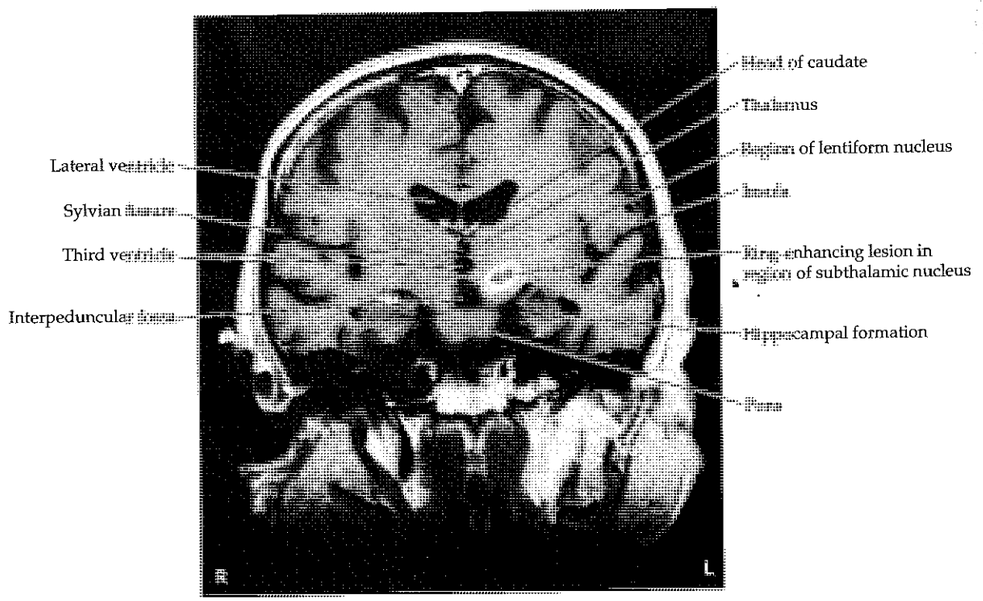

CASE 16.3 ASYMMETRICAL RESTING TREMOR, RIGIDITY, BRADYKINESIA, AND GAIT DIFFICULTIES

CHIEF COMPLAINT

A 53-year-old right-handed man was referred for a second opinion regarding progressive bradykinesia, tremor, rigidity, and unsteady gait.

HISTORY

The patient was well until 10 years previous, when, while working as a fireman, he had noticed some **slowness and difficulty using his right arm.** This symptom gradually progressed, and 2 years later he had to change jobs and began working for the phone company. In the interim he developed occasional **shaking of the right arm and right leg.** He saw a neurologist, who diagnosed him with Parkinson's disease. Treatment with **levodopa plus carbidopa (Sinemet) provided significant benefit.** Bromocriptine (a dopaminergic agonist) was also helpful. He was later enrolled in an experimental trial of deprenyl (selegiline) plus vitamin E, but his symptoms **gradually continued to worsen.** The tremor spread to involve his whole body, and he became progressively slower and stiffer, complaining that he often had **difficulty initiating movements.**

He had no family history of Parkinson's disease, and no history of use of dopaminergic antagonist medications, toxin exposure, strokes, or encephalitis. CT and MRI scans were normal, and blood tests for Wilson's disease were negative.

PHYSICAL EXAMINATION

Vital signs: T = 97.1°F, P = 80, BP = 130/80, R = 14.
Skin: Slightly oily and flaky, with ceruminous buildup in ear canals.
Neck: Supple with no bruits.
Lungs: Clear.
Heart: Regular rate with no murmurs, gallops, or rubs.
Abdomen: Normal bowel sounds; nontender.
Extremities: No edema.
Neurologic exam:

MENTAL STATUS: Alert and oriented ×3. Normal language. Recalled 3/3 words after 5 minutes. Spelled "world" forward and backward correctly. Copied shapes correctly. In writing a sentence, exhibited **micrographia.**

CRANIAL NERVES: Normal, except for **masklike decreased facial expression and slightly hypophonic voice.**

MOTOR: **4 Hz tremor of the head and all extremities, worse on the right side and worse at rest. Cogwheel rigidity, especially of the right arm. Finger tapping and rapid alternating movements slow bilaterally.** No pronator drift. 5/5 power throughout.

REFLEXES: **No extinction of the glabellar reflex (positive Myerson's sign).**

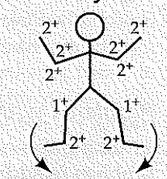

COORDINATION: Slow but not ataxic on finger-to-nose and heel-to-shin testing.

GAIT: **Unable to rise from a chair without assistance. Slow, stiff gait, with stooped posture, short steps, decreased arm swing,** and narrow (normal) base. **Turned slowly without twisting body (en bloc turning). Exhibited retropulsion of two steps when pulled gently backward.**

SENSORY: Intact light touch, pinprick, vibration, and joint position sense.

LOCALIZATION AND DIFFERENTIAL DIAGNOSIS

1. On the basis of the symptoms and signs shown in **bold** above, is this patient more likely to have typical idiopathic Parkinson's disease or atypical parkinsonism (KCC 16.1, 16.2)?
2. Degeneration of neurons in which structure is primarily responsible for idiopathic Parkinson's disease, and what is their main neurotransmitter? How does loss of these neurons result in a hypokinetic movement disorder?

Discussion

The key symptoms and signs in this case are:

- **Asymmetrical bradykinesia, cogwheel rigidity, and resting tremor**
- **Stooped gait with short steps, decreased arm swing, en bloc turning, and retropulsion**
- **Significant benefit from levodopa**
- **Gradual progression over a period of years**

1. This patient had all of the typical core features of idiopathic Parkinson's disease listed earlier (see KCC 16.1, 16.2), so this is the most likely diagnosis. No atypical features, such as symmetrical findings, absence of resting tremor, impaired vertical eye movements, orthostatic hypotension, early psychiatric features, or lack of response to levodopa were present. The gradual progression makes acute causes, such as drug exposure, unlikely. Other associated features seen in this patient, such as the masked facies, hypophonia, micrographia, and Myerson's sign are consistent with parkinsonism, but are not specific to idiopathic Parkinson's disease.
2. Parkinson's disease is caused by loss of dopaminergic neurons in the substantia nigra pars compacta. Pathologic changes typical of Parkinson's disease are shown in Figure 16.10. Dopaminergic neurons in the substantia nigra normally project to the striatum. A review of Figure 16.7 shows that loss of dopaminergic excitation of the direct pathway and loss of dopaminergic inhibition of the indirect pathway *both* ultimately result in more inhibitory output from the internal segment of the globus pallidus (and the substantia nigra pars reticulata) to the thalamus. This, in turn, leads to less excitatory activity from the thalamus to the motor and premotor cortices, resulting in a hypokinetic movement disorder.

Problems with On–Off Fluctuations

In taking the history from this patient, the examiner uncovered another problem in addition to the hypokinesia. Escalating doses of Sinemet, amantadine, and dopaminergic agonists had helped his symptoms somewhat. However, he was having more and more problems with fluctuations, from being "on" after taking a dose of Sinemet to "off" just before a dose. When "off," he could not rise from a chair unassisted, had some trouble walking, occasionally "freezing" in place, had difficulty rolling over in bed, was slow in using utensils and carrying out hygienic activities, and could not button his shirt without assistance. When "on," he still had some difficulties walking and carrying out his daily activities, as well as excessive jerky involuntary movements (dyskinesias) of all limbs. Despite the use of a sustained-release formulation, or frequent small doses, the therapeutic window had gradually narrowed, and his on–off symptoms were becoming more severe.

When examined at a different time in relation to his Sinemet dose from the exam described above, the patient had bilateral hyperkinetic dyskinesias and no tremor. Rigidity and bradykinesia were improved but still present, worse on the right than the left.

1. How might excess dopamine cause the hyperkinetic dyskinesias seen in this patient (see Figure 16.7)?
2. Given the unacceptable response to medications in this patient, what neurosurgical procedure might be tried to improve his hypokinetic parkinsonian movements? Why is this procedure expected to benefit hypokinesia?

Discussion

1. We have just seen how too little dopamine in the nigrostriatal projections could cause the hypokinetic features of Parkinson's disease (see Figure 16.7). Conversely, too much dopamine acting on striatal neurons of both the direct and the indirect pathways could inhibit the internal segment of the globus pallidus, thereby reducing the inhibitory output to the thalamus. With less inhibition of the thalamus, thalamocortical projections to motor and premotor cortex would be more active, resulting in hyperkinesia.

2. Pallidotomy has been used in recent years to treat medically refractory parkinsonism (see KCC 16.4). In this procedure a lesion is placed stereotactically in the ventral posterior globus pallidus (see Figures 16.7, 16.9). This interrupts the inhibitory output from the globus pallidus to the thalamus, leading to increased thalamocortical excitatory activity to motor and premotor cortex, and less hypokinesia. It is not known why this procedure does not produce a hyperkinetic movement disorder. In fact, for unclear reasons, pallidotomy actually causes a marked improvement in medication-related hyperkinetic dyskinesias. Another procedure that is beneficial and has been used more frequently in recent years for treating refractory parkinsonism is implantation of a subthalamic stimulator (see KCC 16.4).

Clinical Course and Neuroimaging 725

After reviewing this patient's history and his increasingly narrow therapeutic window in response to medications, a stereotactic pallidotomy was recommended. This was performed on the left side because his parkinsonism was worse on the right. The surgery was done with mild sedation and local anesthesia so that the patient could remain awake and be tested neurologically during the procedure. An MRI was done with the stereotactic frame in place, and he was then taken to the operating room without the frame being removed. The MRI was used to calculate the coordinates of the left globus pallidus with respect to the frame. A small burr hole was then placed in the left frontal bone, the dura was opened, and an electrode was advanced by 2 mm increments until it reached the internal segment of the left globus pallidus. Before a permanent lesion was created in this area, the location of the electrode tip was tested by passage of a high-frequency electrical stimulus. This caused reversible dysfunction of the cells near the electrode tip, resulting in a dramatic improvement in the patient's right-sided bradykinesia and rigidity. In addition, no visual changes or hemiparesis occurred, indicating that the electrode tip was not too close to the optic tract or internal capsule, respectively (see Figure 16.4D). A permanent lesion was next created by the passage of sufficient current to heat the electrode tip to 70°C.

A postoperative **brain MRI** is shown in Figure 16.14. The stereotactically placed lesion is visible in Figure 16.14A, just ventral to the left globus pallidus (see Figure 16.14B). One day after surgery, the patient no longer had any tremor on the right side, the tremor on the left was decreased, and he had only a single episode of mild dyskinesia lasting about 10 minutes. He also showed marked improvement in his rigidity, and his gait was faster, with larger steps and increased arm swing. Three months after surgery he was seen in follow-up while taking the same medications. He continued to enjoy a marked improvement in his symptoms, saying, "I'm doing a lot, lot better. I can walk. I can walk straight, and people don't look at me like I'm a weirdo anymore." He was on for about 14.5 hours per day, and off for only 2 hours per day. He had dyskinesias for about 3 of his on hours, but these were much milder than preoperatively and did not interfere with his activities. On exam, his speech was normal, he had no tremor, he had mild facial bradykinesia, mild dyskinesias of the left leg, minimal rigidity on the right side, moderate rigidity on the left side, and mild slowing of finger tapping. He was able to rise from a chair without difficulty and had a normal gait.

CASE 16.4 BILATERAL BRADYKINESIA, RIGIDITY, AND GAIT INSTABILITY WITH NO TREMOR

MINICASE

A 48-year-old woman gradually developed difficulty with handwriting and typing, saying that her fingers were stiff and slow. In addition, her gait became unsteady, and she had several falls. She was **treated with levodopa plus carbidopa with no significant benefit.** When examined 5 years after symptom onset, she had a normal mental status, **slow saccades, masked facies, slow dysarthric speech, prominent bilateral bradykinesia and rigidity, especially of the axial and neck muscles, no tremor, and a slow shuffling gait with retropulsion.** There was no evidence of autonomic dysfunction, ataxia, or dementia. Although saccades were slow in the vertical direction, there was no significant limitation of up- or downgaze.

LOCALIZATION AND DIFFERENTIAL DIAGNOSIS

1. On the basis of the symptoms and signs shown in bold above, is this patient more likely to have typical idiopathic Parkinson's disease or atypical parkinsonism (see KCC 16.1, 16.2)?
2. What is the most likely diagnosis?
3. Which neurons degenerate in this condition? How does this result in a hypokinetic movement disorder? Referring to Figure 16.7, explain why patients with this disorder usually do not respond very well to levodopa therapy.

Discussion

The key symptoms and signs in this case are:

- **Bilateral bradykinesia and waxy rigidity**
- **No tremor**
- **Gait slow, shuffling with retropulsion (parkinsonian gait)**
- **No significant benefit from levodopa**
- **Gradual progression over a period of years**
- **Masked facies, slow saccades, slow dysarthric speech**

1. Bilaterally symmetrical symptoms, absence of tremor, and lack of response to levodopa make this a case of atypical parkinsonism (see KCC 16.2; Table 16.5).
2. In most of the disorders listed in Table 16.5, there are other significant abnormalities in addition to atypical parkinsonism. Atypical parkinsonism alone, without other significant abnormalities, can be seen in striatonigral degeneration (a form of multisystem atrophy). Drug-induced parkinsonism is another possibility; however, the patient's gradual progression does not fit this etiology. The masked facies, slow saccades, and dysarthria are nonspecific findings present in most parkinsonian disorders. In conclusion, the most likely diagnosis is striatonigral degeneration.
3. In striatonigral degeneration, as in idiopathic Parkinson's disease, there is loss of dopaminergic neurons from the substantia nigra pars compacta. The result is more inhibitory activity to the thalamus from the internal globus pallidus and substantia nigra pars reticulata, causing a hypokinetic movement disorder (see Figure 16.7). In idiopathic Parkinson's disease, this dopamine deficiency can be corrected by the administration of levodopa. The medication levodopa is converted to dopamine in the brain, which can then act on striatal neurons (see Figure 16.7). In striatonigral degeneration, however, the striatal neurons degenerate as well. Therefore, administration of levodopa is usually not as beneficial to these patients as in Parkinson's disease.

Clinical Course and Postmortem Examination 730

The patient's dysarthria, dysphagia, bilateral bradykinesia, and rigidity without tremor continued to progress. Six years after symptom onset, she underwent pallidotomy (see KCC 16.4), which provided only some transient

CASE 16.2 IRREGULAR JERKING MOVEMENTS AND MARITAL PROBLEMS

Figure 16.12 Atrophy of Caudate Head Associated with Huntington's Disease Coronal T1-weighted MRI scans. (A) The lateral ventricular walls have an abnormal concave shape due to severe atrophy of heads of the caudate nuclei as well as the putamen. The cortex is slightly atrophied as well. These findings are typical for Huntington's disease. (B) Normal MRI scan from a different patient at the same plane of section for comparison. Note the normal convex shape of the lateral ventricular walls, formed by the bulges of the heads of the caudate nuclei.

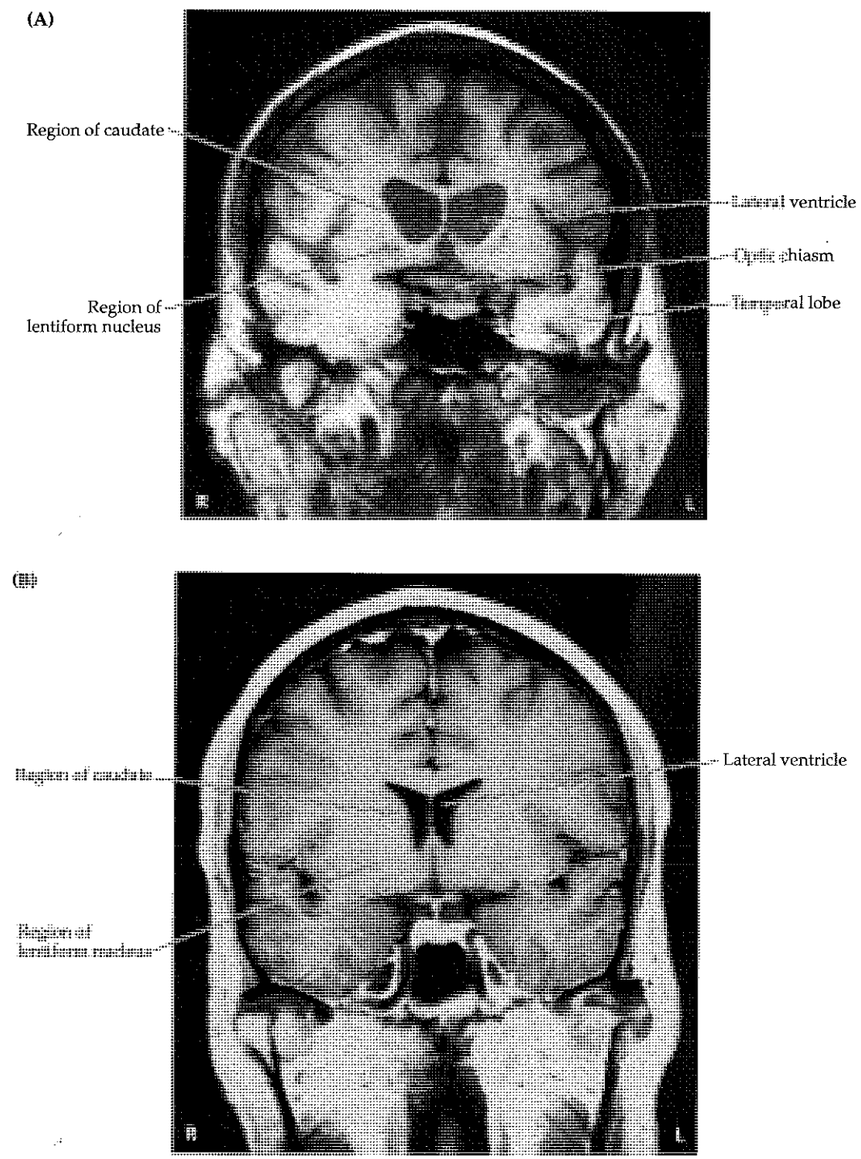

CASE 16.2 RELATED CASE

Figure 16.13 Gross Pathologic Changes of Huntington's Disease Coronal brain sections. The right half-section is from a patient who died of Huntington's disease. The caudate and putamen are markedly atrophied. Some cortical atrophy is present as well. For comparison, the left half-section is from a normal brain. (Courtesy of Jean Paul G. Vonsattel, Massachusetts General Hospital, Harvard School of Medicine.)

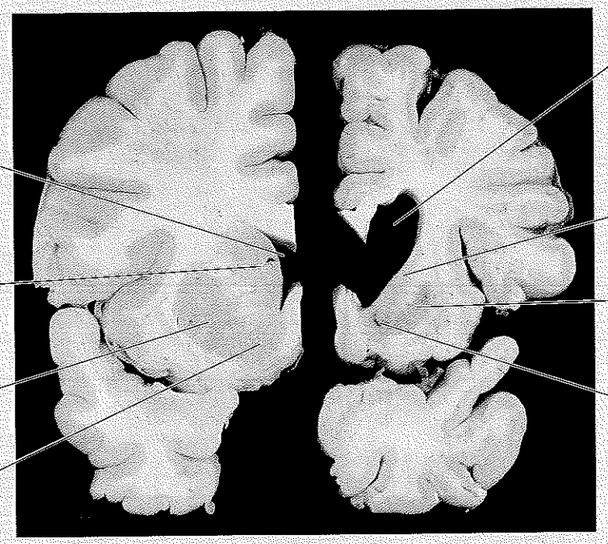

benefit. She eventually became bedbound and died of aspiration pneumonia, 7 years after initial symptoms.

In accordance with the patient's previously stated wishes, her family consented to an autopsy. On examination of brain sections by eye, the substantia nigra appeared somewhat pale (similar to left side of Figure 16.10A). In addition, the caudate, putamen, and external segment of the globus pallidus were markedly atrophied (Figure 16.15). Microscopic examination of the substantia nigra revealed marked loss of pigmented neurons, and an increase in glial cells (Figure 16.16A) when compared to a normal control (see Figure 16.16B). However, unlike the typical findings in Parkinson's disease, Lewy bodies were not present. Microscopic examination of the striatum also showed marked neuronal loss and gliosis (see Figure 16.16C) compared to a normal control (see Figure 16.16D). Some atrophy was also found in the external segment of the globus pallidus, subthalamic nucleus, pons, locus ceruleus, and cerebellum. These findings were compatible with a diagnosis of multisystem atrophy of the striatonigral degeneration type.

CASE 16.3 ASYMMETRICAL RESTING TREMOR, RIGIDITY, BRADYKINESIA, AND GAIT DIFFICULTIES

Figure 16.14 Left Pallidotomy Performed for Advanced Parkinson's Disease Horizontal T1-weighted MRI scans. A and B are adjacent horizontal sections progressing from inferior to superior. (A) Stereotactically placed lesion is visible. (B) By comparison with A, it can be seen that the lesion was placed along the ventral edge of the globus pallidus.

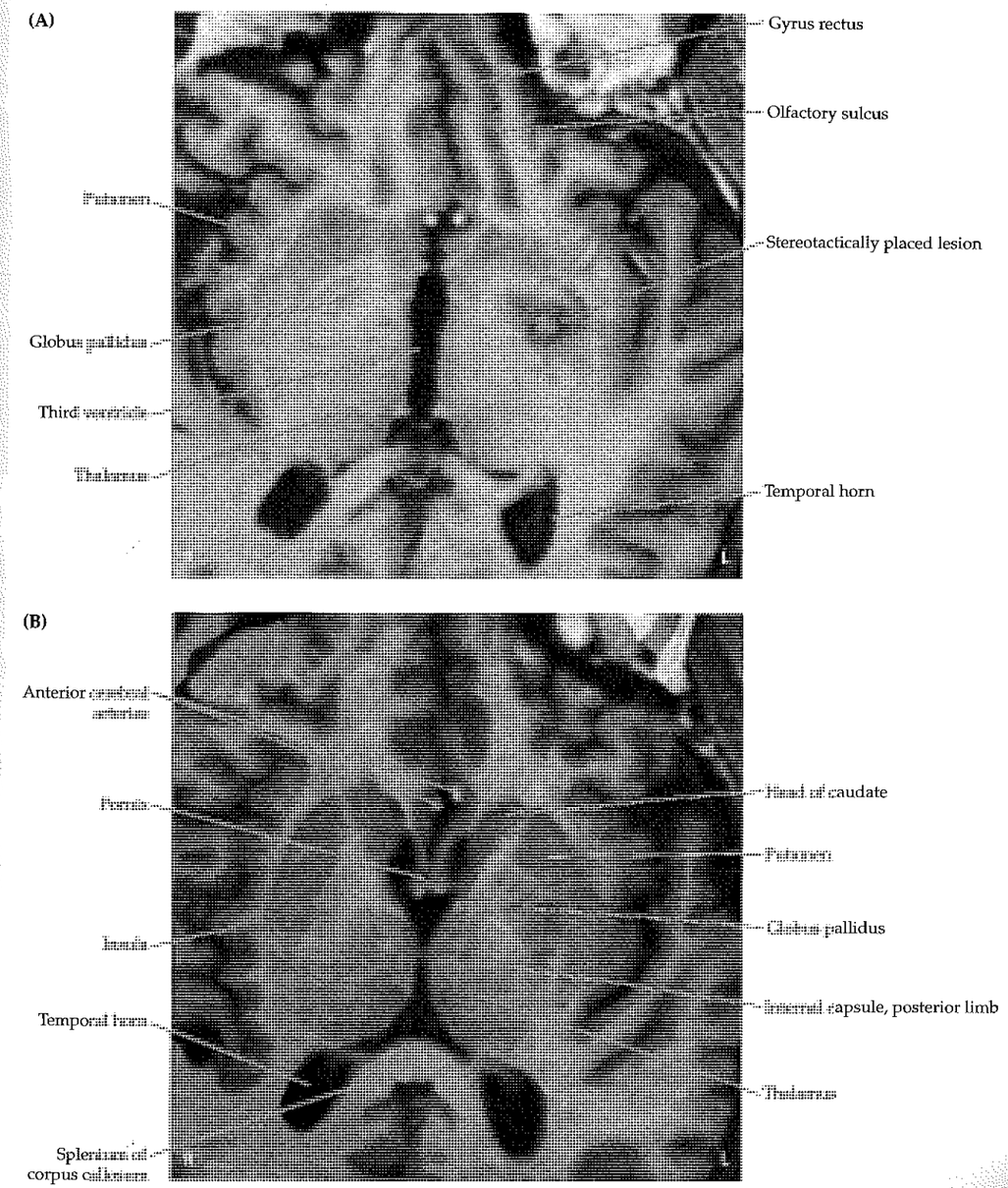

CASE 16.4 BILATERAL BRADYKINESIA, RIGIDITY, AND GAIT INSTABILITY WITH NO TREMOR

Figure 16.15 Gross Pathologic Changes in a Patient with Striatonigral Degeneration Coronal brain sections; A, B progress from anterior to posterior. Note the severe atrophy of the striatum, including the caudate and putamen. The external segment of the globus pallidus appears atrophied as well.

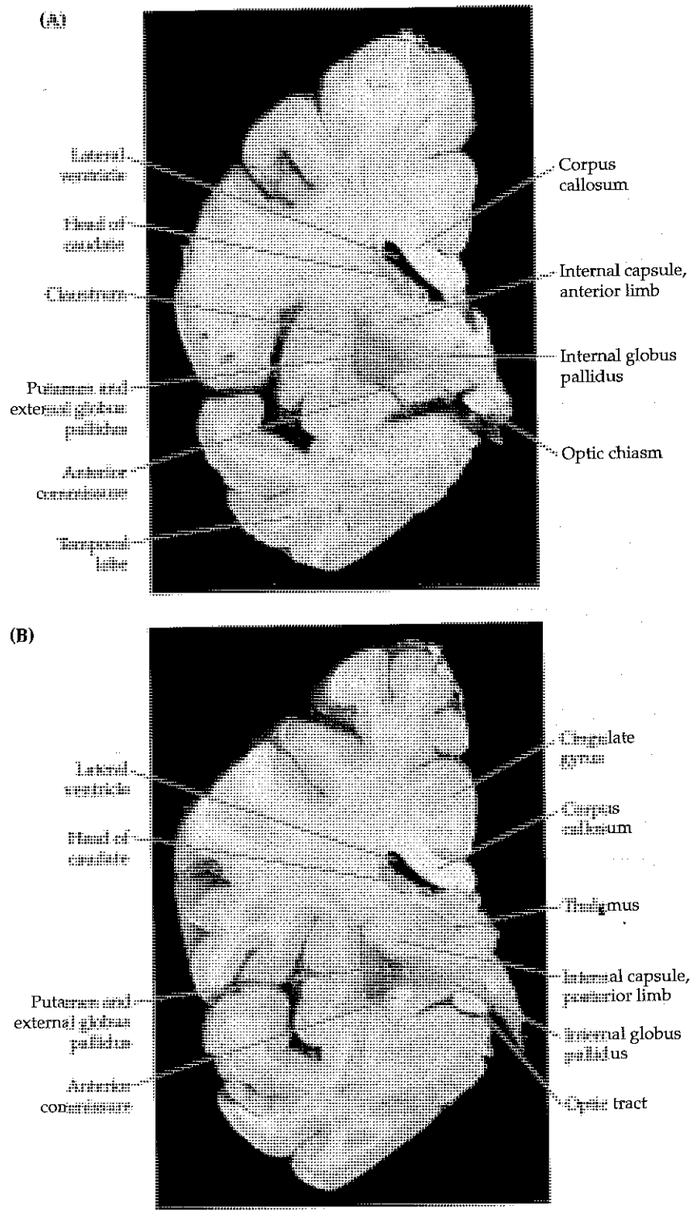

CASE 16.4 *(CONTINUED)*

Figure 16.16 Microscopic Pathologic Changes in a Patient with Striatonigral Degeneration (A) Substantia nigra specimen from a normal control showing darkly pigmented dopaminergic neurons (arrow). (B) In a substantia nigra specimen from the patient in Case 16.4, no dopaminergic neurons are visible, and there is an increase in the number of glial cells: the small, darkly staining nuclei are in oligodendrocytes (black arrows); the paler ovoid nuclei are in astrocytes (white arrows). (C) Striatal specimen from a normal control showing many stained neurons (arrows). (D) Striatal specimen from the patient in Case 16.4 shows neuronal loss and gliosis, including oligodendrocytes (black arrows) and astrocytes (white arrows).

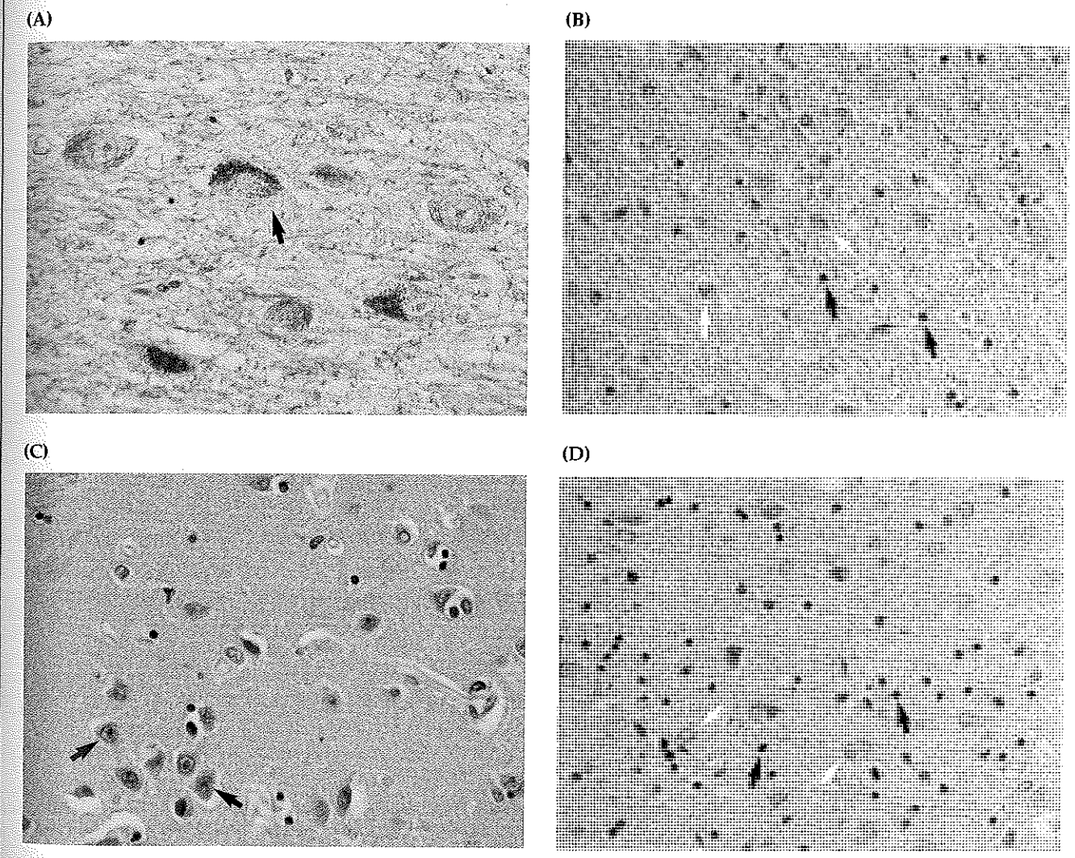

Brief Anatomical Study Guide

1. Like the cerebellum, the basal ganglia provide complex feedback loops that influence descending motor pathways, as well as other functions. The main components of the basal ganglia are the **caudate nucleus, putamen, globus pallidus, subthalamic nucleus,** and **substantia nigra** (see Table 16.1; Figures 16.1, 16.2). The **striatum** includes the caudate and putamen, while the **lentiform nucleus** includes the putamen and globus pallidus. The three-dimensional relationships of these structures are best appreciated through examination of horizontal (see Figure 16.3) and coronal (see Figure 16.4) brain sections. Note that in horizontal sections (see Figure 16.3), the **internal capsule** forms a sideways V-shaped demarcation with the thalamus and caudate nucleus lying medial to the internal capsule, and with the lentiform nucleus lying lateral.

2. The main input and output connections of the basal ganglia are summarized in Figures 16.5 through 16.7. Briefly, **all inputs,** including inputs from motor and premotor **cortex,** dopaminergic inputs from the **substantia nigra pars compacta,** and inputs from the **thalamic** intralaminar nuclei enter the basal ganglia circuitry **via the striatum** (see Figure 16.5). **All outputs,** including those to the thalamic ventral anterior **(VA)** and ventral lateral **(VL)** nuclei, other thalamic nuclei, brainstem **reticular formation,** and **tectum** leave **via the internal segment of the globus pallidus and the substantia nigra pars reticulata** (see Figure 16.6).

3. The intrinsic connections of the basal ganglia circuitry can be divided into a **direct pathway** from the striatum to the output nuclei, and an **indirect pathway** that reaches the output nuclei via a detour through the subthalamic nucleus (see Figure 16.7).

4. Understanding the neurotransmitters and intrinsic connections of the basal ganglia as depicted in Figure 16.7 provides a theoretical framework for understanding **hyperkinetic movement disorders** such as Huntington's disease, and **hypokinetic movement disorders** such as Parkinson's disease. In hyperkinetic movement disorders the inhibitory output from the basal ganglia to the thalamus (and hence to the cortex) is decreased, leading to a relative disinhibition of descending motor systems. Examples include lesions of the subthalamic nucleus such as stroke causing hemiballismus, or loss of inhibitory GABAergic neurons from the striatal neurons of the indirect pathway in early Huntington's disease. In hypokinetic movement disorders the inhibitory output from the basal ganglia to the thalamus is increased, resulting in a relative paucity of movements. Examples include degeneration in Parkinson's disease of dopaminergic neurons projecting from the substantia nigra pars compacta to the striatum.

5. In addition to **general motor functions,** the basal ganglia are also involved in **eye movements, frontal executive function,** and **limbic pathways;** these four parallel channels through the basal ganglia circuitry are summarized in Table 16.2 and Figure 16.8. The inputs to the general motor channel enter mainly via the putamen, while those for the oculomotor and prefrontal channels enter via the body of the caudate and the head of the caudate, respectively. The

Brief Anatomical Study Guide *(continued)*

limbic channel involves ventral structures such as the nucleus accumbens (part of the ventral striatum) and ventral pallidum. Because of these multiple basal ganglia pathways, the clinical manifestations of basal ganglia disorders often include prominent oculomotor, cognitive, and psychiatric manifestations in addition to disorders of movement.

Additional Cases

Related cases can be found in other chapters for the following topics: **movement disorders, ataxia, or related syndromes** (Cases 5.7, 5.9, 10.2, 14.1, 14.4, 14.7, 15.1–15.4, 18.5, 19.7). Other relevant cases can be found using the **Case Index.**

References

Anatomy and Circuit Connections of the Basal Ganglia

Afifi AK. 1994. Basal ganglia: Functional anatomy and physiology. Part I. *J Child Neurol* 9(3): 249–260.

Albin RL, Young AB, Penny JB. 1989. The functional anatomy of basal ganglia disorders. *Trends Neurosci* 12(10): 366–375.

Alexander GE, Crutcher MD. 1990. Functional architecture of basal ganglia circuits: Neural substrates of parallel processing. *Trends Neurosci* 13(7): 266–271.

Carpenter MB. 1991. *Core Text of Neuroanatomy,* 4th Ed. Williams & Wilkins, Baltimore, MD, Chapter 11.

Delong MR. 1990. Primate models of movement disorders of basal ganglia origin. *Trends Neurosci* 13(7): 281–285.

Hoover JE, Strick PL. 1993. Multiple output channels in the basal ganglia. *Science* 259(5096): 819–821.

Martin JH. 1996. *Neuroanatomy: Text and Atlas,* 2nd Ed. Appleton & Lange, Stamford, CT, Chapter 11.

Parent A, Cicchetti F. 1998. The current model of basal ganglia organization under scrutiny. *Mov Disorders* 13(2): 199–202.

Parent A, Harzati LN. 1993. Anatomical aspects of information processing in primate basal ganglia. *Trends Neurosci* 16(3): 111–116.

Steriade M, Jones EG, McCormick DA (eds.). 1997. Thalamic organization and chemical anatomy. In *Thalamus,* Vol. 1: *Organisation and Function,* Chapter 2. Elsevier, Amsterdam.

General Movement Disorders

Bressman SB, Greene PE. 1990. Treatment of hyperkinetic movement disorders. *Neurol Clin* 8(1): 51–75.

Riley DE, Lang AE. 1996. Movement disorders. In Bradley WG, Daroff RB, Fenichel GM, Marsden CD. (eds.), *Neurology in Clinical Practice: The Neurological Disorders,* Vol.2 , 2nd Ed., Chapter 76–77. Butterworth-Heinemann, Boston.

Wayne Martin WR, Snow B, Ashforth R. 1995. Abnormalities of movement and posture due to disease of the extrapyramidal motor systems. In Greenberg JO (ed.), *Neuroimaging. A Companion to Adams and Victor's Principles of Neurology,* Chapter 1 McGraw-Hill, Health Professions Division, New York.

Hemichorea or Hemiballismus

Camac A, Greene P, Khandji A. 1990. Paroxysmal kinesigenic dystonic choreoathetosis associated with a thalamic infarct. *Mov Disorders* 5(3): 235–238.

Lee MS, Marsden CD. 1994. Movement disorders following lesions of the thalamus or subthalamic region. *Mov Disorders* 9(5): 493–507.

Lownie SP, Gilbert JJ. 1990. Hemichorea and hemiballismus: Recent concepts. *Clin Neuropathol* 9(1): 46–50.

Provenzale JM, Schwarzschild MA. 1994. Hemiballismus. *Am J Neuroradiol* 15(7): 1377–1382

Vidakovic A, Dragasevic N, Kostic VS. 1994. Hemiballism: Report of 25 cases. *J Neurol Neurosurg Psychiatry* 57(8): 945–949.

Tourette's Syndrome

Comings DE. 1995. Tourette's syndrome: A behavioral spectrum disorder. *Adv Neurol* 65: 293–303.

Price BH. 1989. Gilles de la Tourette syndrome. In Scheinberg P. (ed.), *Neurology and Neurosurgery*, update series, pp. 1–8. CPEC, Princeton, NJ. Tourette Syndrome Classification Study Group. 1993. Definitions and classification of tic disorders. *Arch Neurol* 50: 1013–1016.

Wilson's Disease

Demirkiran M, Jankovic J, Lewis RA, Cox DW. 1996. Neurologic presentation of Wilson disease without Kayser-Fleischer rings. *Neurology* 46(4): 1040–1043.

LeWitt PA, Pfeiffer RF. 1998. Wilson's disease. In Jankovic J, Tolosa E (eds.), *Parkinson's Disease and Movement Disorders*, 3rd Ed., Chapter 19. Williams & Wilkins, Baltimore, MD.

Young AB, Brewer GJ. 1990. Wilson's disease. In RT Johnson, *Current Therapy in Neurologic Disease*, 3rd Ed., pp. 339–343. BC Decker, Philadelphia.

Tremor

Findley LJ, Cleeves L. 1989. Classification of tremor. In Quinn NP, Jenner PG (eds.), *Disorders of Movement: Clinical, Pharmacological and Physiological Aspects*, Chapter 36. Academic Press, London.

Findley LJ, Koller WC. 1987. Essential tremor: A review. *Neurology* 37(7): 1194–1197.

Koller WC, Huber SJ. 1989. Tremor disorders of aging: Diagnosis and management. *Geriatrics* 44(5): 33–37.

Parkinson's Disease and Related Disorders

Berger Y, Salinas JN, Blaivas JG. 1990. Urodynamic differentiation of Parkinson disease and the Shy Drager syndrome. *Neurourol Urodynamics* 9: 117–121.

Consensus Committee of the American Autonomic Society and the American Academy of Neurology. 1996. Consensus statement of the definition of orthostatic hypotension, pure autonomic failure, and multiple system atrophy. *Neurology* 46(5): 1470.

Gouider-Khouja N, Vidailhet M, Bonnet A, Pichon J, Agid Y. 1995. "Pure" striatonigral degeneration and Parkinson's disease: A comparative clinical study. *Mov Disorders* 10(3): 288–294.

Hughes AJ, Ben-Shlomo Y, Daniel SE, Lees AJ. 1992. What features improve the accuracy of clinical diagnosis in Parkinson's disease: A clinicopathologic study. *Neurology* 42(6): 1142–1146.

Koller WC, Tolosa E (eds.). 1998. Current and emerging drug therapies in the management of Parkinson's disease. *Neurology* 50(Suppl 6): S1–S48.

Krusz JC, Koller WC, Ziegler DK. 1987. Historical review: Abnormal movements associated with epidemic encephalitis lethargica. *Mov Disorders* 2(3): 137–141.

Lang AE, Lozano AM. 1998. Parkinson's disease. *N Engl J Med* 339(15): 1044–1053 and 339(16): 1130–1143.

Lantos PL, Papp MI. 1994. Cellular pathology of multiple system atrophy: A review. *J Neurol Neurosurg Psychiatry* 57(2): 129–133.

Marsden CD. 1990. Parkinson's disease. *Lancet* 335(8695): 948–952.

Poewe WH, Wenning GK. 1996. The natural history of Parkinson's disease. *Neurology* 47(Suppl 3): S146–S160.

Santacruz P, Uttl B, Litvan I, Grafman J. 1998. Progressive supranuclear palsy: A survey of the disease course. *Neurology* 50(6): 1637–1647.

Stephen PJ, Williamson J. 1984. Drug-induced parkinsonism in the elderly. *Lancet* 2(8411): 1082–1083.

Wenning GK, Shlomo YB, Magalhaes M, Daniel SE, Quin NP.1994. Clinical features and natural history of multiple system atrophy. An analysis of 100 cases. *Brain* 117(Pt. 4): 835–845.

Huntington's Disease

Albin RL, Tagle DA. 1995. Genetics and molecular biology of Huntington's disease. *Trends Neurosci* 18(1): 11–14.

Cattaneo E, Rigamonti D, Goffredo D, Zuccato C, Squitieri F, Sipione S. 2001. Loss of normal Huntington function: new developments in Huntington's disease research. *Trends Neurosci* 24(3): 182–188.

Gusella JF, Wexler NS, Conneally PM, Naylor SL, Anderson MA, Tanzi RE, Watkins PC, Ottina K, Wallace MR, Sakaguchi AY, Young AB, Shoulson I, Bonilla E, Martin JB. 1983. A polymorphic DNA marker genetically linked to Huntington's disease. *Nature* 306(17): 234–238.

Gutekunst CA, Norflus F, Hersch SM. 2000. Recent advances in Huntington's disease. *Curr Opin Neurol* 13(4): 445–450.

The Huntington's Disease Collaborative Research Group. 1993. A novel gene containing a trinucleotide repeat that is expanded and unstable on Huntington's disease chromosomes. *Cell* 72(16): 971–983.

Lanska DL. 1995. George Huntington and hereditary chorea. *J Child Neurol* 10(1): 46–48.

Mendez MF. 1994. Huntington's disease: Update and review of neuropsychiatric aspects. *Int J Psychiatry Med* 24(3): 189–208.

Stereotactic Surgery and Movement Disorders

Dogali M, Sterio D, Fazzini E, Kolodny E, Eidelberg D, Berie A. 1996. Effects of posteroventral pallidotomy on Parkinson's disease. *Adv Neurol* 69: 585–590.

Germano IM (ed.). 1998. *Neurosurgical Treatment of Movement Disorders*. American Association of Neurological Surgeons, Park Ridge, IL.

Gildenberg PL. 1996. Surgical therapy for movement disorders. In Wilkens RH, Rengachary SS (eds.), *Neurosurgery*, 2nd Ed., Chapter 431. McGraw-Hill, New York.

Goetz CG, Delong MR, Penn RD, Bakay RAE. 1993. Neurosurgical horizons in Parkinson's disease. *Neurology* 43(1): 1–7.

Hauser RA, Freeman TB, Olanow CW. 1995. Surgical therapies for Parkinson's disease. In Kurlan R (ed.), *Treatment of Movement Disorders*, Chapter 2. Lippincott, Philadelphia.

Iacono RP, Lonser RR, Mandybur G, Morenski JD, Yamoda S, Shima F. 1994. Stereotactic pallidotomy results for Parkinson's exceed those for fetal graft. *Am Surg* 60(10): 777–782.

Lang AE, Lozano AM, Montgomery E, Duff J, Tasker R, Hutchinson W. 1997. Posteroventral medial pallidotomy in advanced Parkinson's disease. *N Engl J Med* 337(15): 1036–1042.

Marsden CD, Obeso JA. 1994. The functions of the basal ganglia and the paradox of stereotaxic surgery in Parkinson's disease. *Brain* 117(Pt. 4): 877–897.

CHAPTER 17

ANATOMICAL AND CLINICAL REVIEW
Overall Anatomy of the Pituitary and Hypothalamus
Important Hypothalamic Nuclei and Pathways
Endocrine Functions of the Pituitary and Hypothalamus
KCC 17.1 Pituitary Adenoma and Related Disorders
KCC 17.2 Diabetes Insipidus and SIADH
KCC 17.3 Panhypopituitarism

CLINICAL CASES
17.1 Moon Facies, Acne, Amenorrhea, and Hypertension
17.2 Impotence, Anorexia, Polyuria, Blurred Vision, Headaches, and Hearing Loss
Additional Cases

BRIEF ANATOMICAL STUDY GUIDE

Pituitary and Hypothalamus

The hypothalamus and pitutitary exert complex and fine control over the endocrine system, but because of their anatomical relations to adjacent structures, pituitary or hypothalamic lesions can cause visual deficits as well. A 50-year-old woman developed gradually worsening vision problems over the course of several months that eventually interfered with her driving. She also had a long-standing history of menstrual irregularity and infertility. Her examination was normal except for decreased vision bilaterally, primarily in the temporal portions of her visual fields. Eventually, it was discovered that this patient had a lesion in the pituitary region compressing her optic chiasm. In this chapter we will learn about the anatomy and neuroendocrine functions of the hypothalamus and pituitary and clinical ramifications of lesions in these structures.

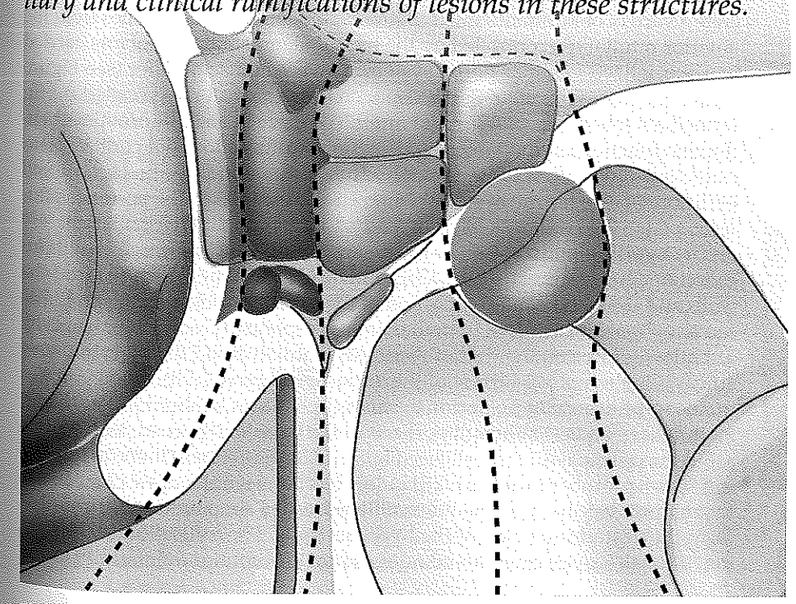

ANATOMICAL AND CLINICAL REVIEW

The pituitary and hypothalamus constitute a unique region of the nervous system. In addition to communicating through conventional synaptic transmission, both of these structures utilize soluble humoral factors as a major source of afferent and efferent information. The pituitary and hypothalamus form the link between the **neural and endocrine systems.** In addition, the hypothalamus is the central regulator of **homeostasis** (mnemonic: Hypothalamus Homeostasis), and has been informally nicknamed the "homeostatic head ganglion." The hypothalamus maintains homeostasis in the body by interacting with and exerting important regulatory influences over four other systems, thereby participating in:

MNEMONIC

1. **Homeostatic** mechanisms controlling hunger, thirst, sexual desire, sleep–wake cycles, etc.
2. **Endocrine** control, via the pituitary
3. **Autonomic** control
4. **Limbic** mechanisms (see Chapter 18).

(Mnemonic: **HEAL**)

In the sections that follow, we will first review the overall anatomy of the pituitary and hypothalamus. Then we will discuss the major hypothalamic nuclei and their roles in each of the above functions, focusing in most detail on neuroendocrine control of pituitary hormones. Finally, we will review the clinical effects of pituitary and hypothalamic dysfunction.

Figure 17.1 Embryological Development of the Anterior and Posterior Pituitary

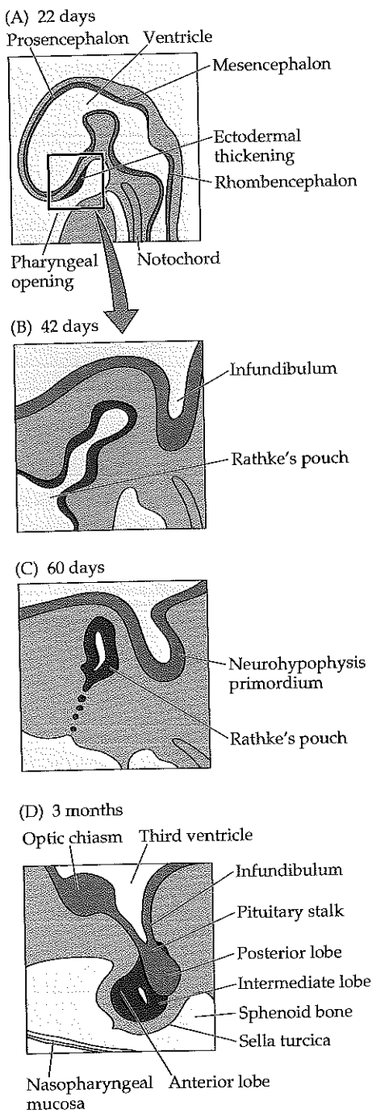

Overall Anatomy of the Pituitary and Hypothalamus

The pituitary, or hypophysis, is derived from two different embryological pouches (Figure 17.1). The **anterior pituitary,** or **adenohypophysis,** is formed by a thickened area of ectodermal cells on the roof of the developing pharynx that invaginate, forming **Rathke's pouch.** The **posterior pituitary,** or **neurohypophysis,** forms from an evagination of the floor of the developing ventricular system. The anterior pituitary contains glandular cells that secrete a variety of hormones into the circulation. Release of hormones from the anterior pituitary is controlled by the hypothalamus through factors carried in a specialized vascular portal system, as we will discuss later (see Figure 17.5). The posterior wall of Rathke's pouch forms a small region called the intermediate lobe of the pituitary (Figure 17.1D), which has less prominent endocrine functions in humans. The posterior pituitary does not contain glandular cells. Instead, it contains axons and terminals of neurons whose cell bodies are located in the hypothalamus. These terminals in the posterior pituitary secrete the hormones oxytocin and vasopressin into the circulation.

The **hypothalamus** is part of the diencephalon, and it is named for its location underneath the thalamus (Figure 17.2A). The hypothalamus forms the walls and floor of the inferior portion of the third ventricle (see Figure 17.2A; see also Figure 16.4C). The hypothalamus is separated from the thalamus by a shallow groove on the wall of the third ventricle called the **hypothalamic sulcus.** On the ventral surface of the brain (see Figure 17.2B), the hypothalamus can be seen just posterior to the optic chiasm, (tuber cinereum and mammillary bodies) although portions of the hypothalamus are located dorsal to the optic chiasm as well (see Figure 17.3). The **tuber cinereum,** meaning "gray protuberance," is a bulge located between the optic chiasm and the mammillary bodies. The **mammillary bodies** are paired structures that form the posterior portion of the hypothalamus. The **infundibulum,** meaning "funnel," arises from the tuber cinereum and continues inferiorly as the

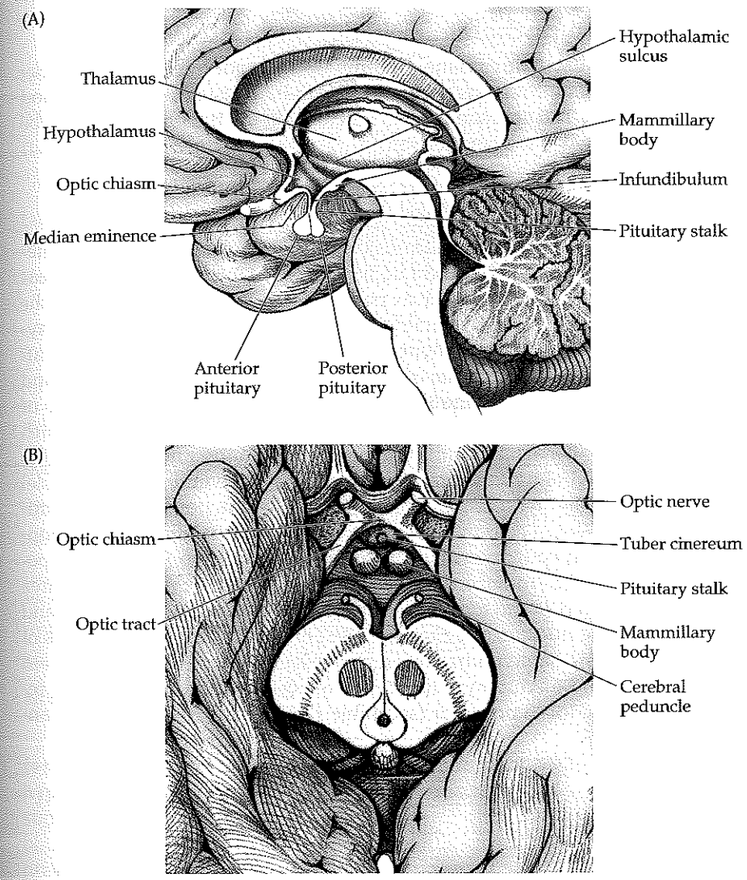

Figure 17.2 Anatomical Relations of Hypothalamus and Pituitary (A) Medial view. (B) Inferior view with the brainstem and pituitary removed.

pituitary stalk (see Figure 17.2A). The anterior portion of the infundibulum is slightly elevated and is called the **median eminence.** The median eminence is the region where hypothalamic neurons release regulating factors that are carried by portal vessels to the anterior pituitary (see Figure 17.5).

The pituitary gland lies within the **pituitary fossa** (see Figures 12.1, 12.3A). The pituitary fossa is bounded by the **anterior clinoid process** and the **posterior clinoid process,** which, together with the intervening portions of the sphenoid bone, form the fancifully named **sella turcica,** meaning "Turkish saddle." Just beneath the floor of the sella turcica lies the **sphenoid sinus,** allowing the pituitary fossa to be accessed by a transsphenoidal surgical approach (see KCC 17.1). Within the pituitary fossa the pituitary is surrounded by dura. The dura covering the superior portion of the pituitary fossa is called the **diaphragma sella,** and the pituitary stalk communicates with the main cranial cavity through a round hole in the middle of the diaphragma sella (see Figure 10.11B). The pituitary fossa is bounded laterally on both sides by the **cavernous sinus** (see Figure 13.11). Note that the pituitary and other sellar and suprasellar structures lie just behind and inferior to the optic chiasm (see Figure 17.2). Tumors in this region therefore can compress the optic chiasm, causing visual problems, including **bitemporal hemianopia** (see KCC 11.2).

REVIEW EXERCISES

1. Which of the following is derived embryologically from Rathke's pouch and which from the prosencephalon?

A. Anterior pituitary

B. Posterior pituitary

2. Enlargement of the pituitary by a tumor may compress which structure of the visual pathway?

TABLE 17.1 Some Important Hypothalamic Nuclei

- **Periventricular area**
  - Periventricular nucleus
- **Medial hypothalamic area**
  - Preoptic area
    - Medial preoptic nucleus
  - Anterior (supraoptic) region
    - Anterior hypothalamic nucleus
    - Supraoptic nucleus
    - Paraventricular nucleus
    - Suprachiasmatic nucleus
  - Middle (tuberal) region
    - Arcuate nucleus
    - Ventromedial nucleus
    - Dorsomedial nucleus
  - Posterior (mammillary) region
    - Medial mammillary nucleus
    - Intermediate mammillary nucleus
    - Lateral mammillary nucleus
    - Posterior hypothalamic nucleus
- **Lateral hypothalamic area**
  - Lateral preoptic nucleus
  - Lateral hypothalamic nucleus

Important Hypothalamic Nuclei and Pathways

In this section we will discuss the anatomy of the major hypothalamic nuclei and the hypothalamic regions that specialize in homeostatic, autonomic, and limbic functions. The neuroendocrine functions of the hypothalamus will be discussed in detail in the next section.

Major Hypothalamic Nuclei

The hypothalamic nuclei can be divided into four major regions, from anterior to posterior (Figure 17.3) and into two different medial and lateral areas (Figure 17.4). The fibers of the fornix pass through the hypothalamus on the way to the mammillary body, dividing the hypothalamus into a **medial hypothalamic area** and a **lateral hypothalamic area** (see Figure 17.4). The lateral hypothalamic area consists of the **lateral hypothalamic nucleus** and several smaller nuclei. The **medial forebrain bundle** is a diffuse group of fibers running rostrocaudally through the lateral hypothalamic area, which carries many connections to and from the hypothalamus, and between other regions. The medial hypothalamic area consists of several different nuclei (Table 17.1; see Figures 17.3, 17.4). Most medially, the **periventricular nucleus** is a thin layer of cells that lies closest to the third ventricle. The **preoptic area** is derived embryologically from the telencephalon, while the hypothalamus is derived from the diencephalon. Nevertheless, the preoptic area is functionally part of the hypothalamus. The **lateral preoptic nucleus** and **medial preoptic nucleus** (see Figure 17.4A) are the rostral continuations of the lateral and medial hypothalamic areas, respectively.

The remaining medial hypothalamic area can be divided into three regions, from anterior to posterior (see Table 17.1; Figures 17.3, 17.4). The **anterior hypothalamic region,** or **supraoptic region,** includes the **anterior hypothalamic nucleus, supraoptic nucleus, paraventricular nucleus,** and **suprachiasmatic nucleus** (see Figures 17.3, 17.4B). Some neurons located in both the supraoptic and the paraventricular nuclei contain oxytocin or vasopressin and project to the posterior pituitary (see Figure 17.5). The suprachiasmatic nucleus is the "master clock" for circadian rhythms. It receives inputs from retinal ganglion cells conveying information about day–night cycles. The **middle hypothalamic region,** or **tuberal region** (see Table 17.1; Figures 17.3, 17.4C), includes the **arcuate nucleus, ventromedial nucleus,** and **dorsomedial nucleus.** The arcuate nucleus is one of the hypothalamic nuclei projecting to the median eminence to control the anterior pituitary. The **posterior hypothalamic region,** or **mammillary region** (see Table 17.1; Figures 17.3, 17.4D), includes the **medial mammillary nucleus, intermediate mammillary nucleus, lateral mammillary nucleus,** and **posterior hypothalamic nucleus.**

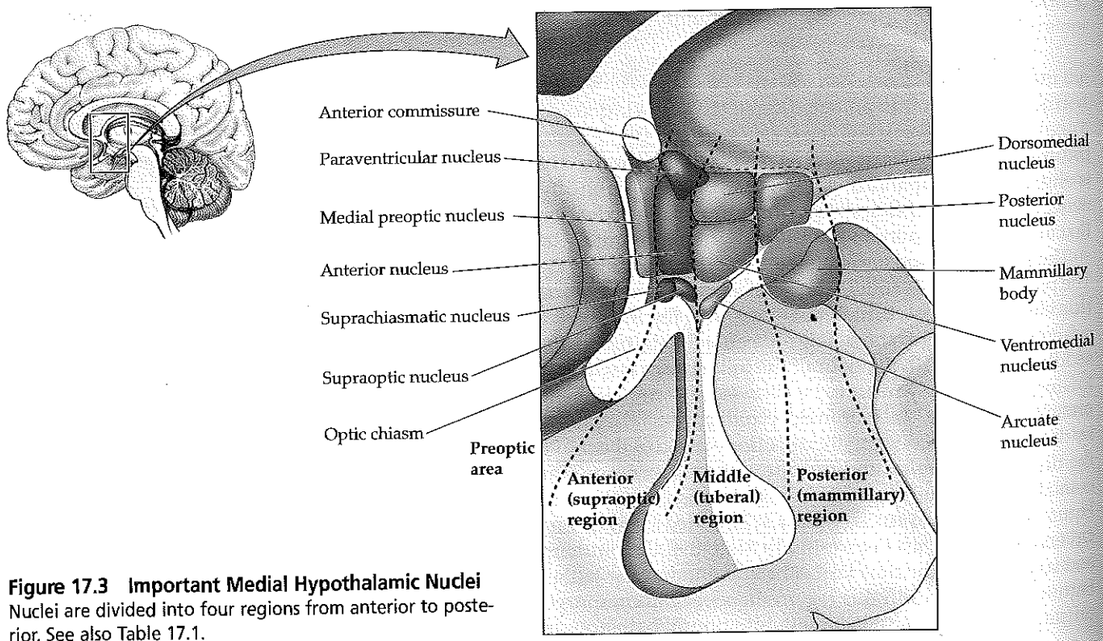

Figure 17.3 Important Medial Hypothalamic Nuclei Nuclei are divided into four regions from anterior to posterior. See also Table 17.1.

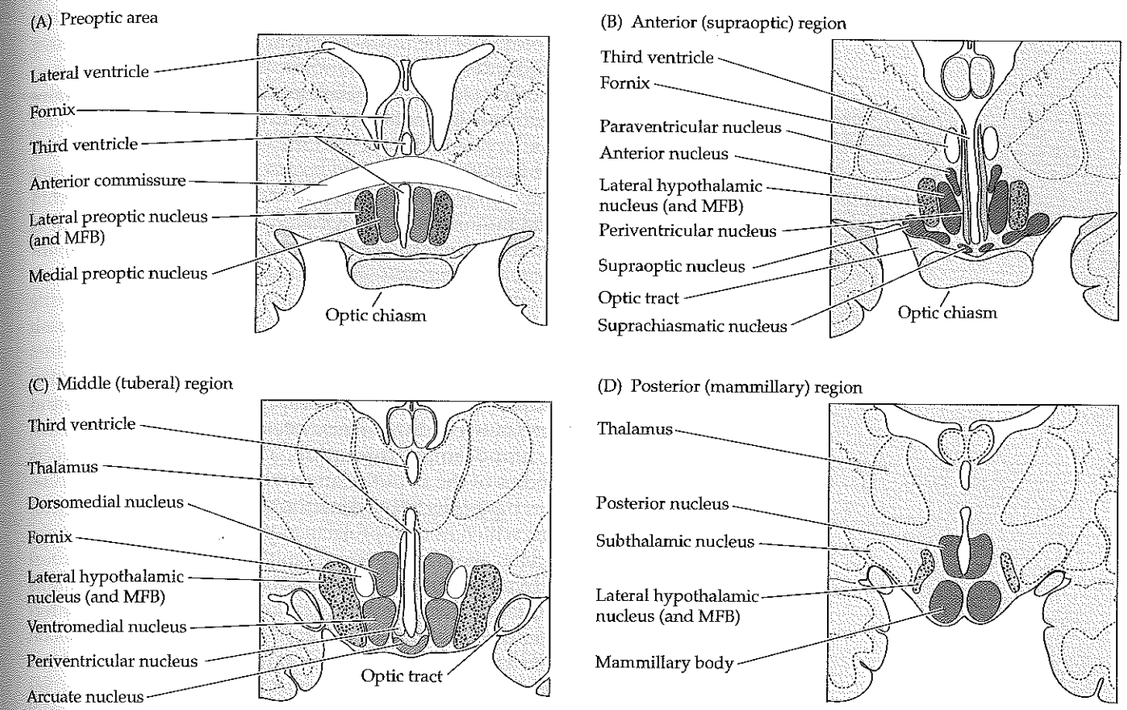

Figure 17.4 Coronal Sections through the Hypothalamus Periventricular, medial, and lateral nuclei are shown in four coronal sections See also Table 17.1. (After Purves D, Augustine GJ, Fitzpatrick D, Katz LC, LaMantia A-S, McNamara JO, Williams SM (eds.). 2001. *Neuroscience*, 2nd Ed. Sinauer, Sunderland, MA.)

Hypothalamic Control of the Autonomic Nervous System

The hypothalamus has important descending projections that influence both the sympathetic and the parasympathetic divisions of the autonomic nervous system. Descending autonomic fibers originate mainly from the **paraventricular nucleus,** but also from the dorsomedial hypothalamic nucleus and from the lateral and posterior hypothalamus. The descending autonomic fibers initially travel in the medial forebrain bundle, and then in the dorsolateral brainstem and periaqueductal gray matter. Ultimately they synapse onto preganglionic parasympathetic nuclei in the brainstem and intermediate zone of

REVIEW EXERCISE

What are the four major types of functions carried out by the thalamus (mnemonic: **HEAL**)?

the sacral spinal cord, and onto preganglionic sympathetic neurons in the intermediolateral cell column of the thoracolumbar spinal cord (see Figures 6.12, 6.13). Aside from the descending autonomic pathways from the hypothalamus, there are also descending autonomic pathways from several brainstem nuclei, including the nucleus solitarius, noradrenergic nuclei, raphe nucleus, and pontomedullary reticular formation. Many of these nuclei also receive inputs from the hypothalamus.

Inputs to the hypothalamus that regulate autonomic function come from numerous synaptic and humoral sources. One important source of input is the amygdala and certain regions of the limbic cortex (see Chapter 18), including the orbital frontal, insular, anterior cingulate, and temporal cortices.

Hypothalamic–Limbic Pathways

The limbic system and its connections with the hypothalamus will be discussed in detail in Chapter 18. Here we will simply mention the main input and output connections between the limbic system and the hypothalamus. The subiculum of the **hippocampal formation,** a limbic structure, projects to the mammillary bodies of the hypothalamus via the **fornix.** Meanwhile, the mammillary bodies project via the **mammillothalamic tract** to the **anterior thalamic nucleus,** which in turn projects to limbic cortex in the cingulate gyrus. The **amygdala,** another important limbic structure, has reciprocal connections with the hypothalamus via two pathways: the **stria terminalis** and the **ventral amygdalofugal pathway.** The limbic–hypothalamic interconnections may be an important mechanism for emotional influences on autonomic pathways (explaining why your palms get sweaty and your stomach churns when you are anxious) and on homeostatic pathways, including the immune system (explaining why depressed individuals may be more susceptible to infection). In addition, connections from the hypothalamus to limbic pathways may enable complex motivational and emotional programs to be activated in the service of homeostatic and reproductive functions.

Other Regionalized Functions of the Hypothalamus

In addition to its roles in endocrine, autonomic, and limbic function, the hypothalamus is important in regulating a variety of appetitive, homeostatic, and other behaviors that are often essential to survival of the organism. The regional aspects of these functions have been studied predominantly through lesion and stimulation studies in animals. However, evidence is accumulating for similar localization for many of these functions in humans as well. As we have already mentioned, the **suprachiasmatic nucleus** in the anterior hypothalamus (see Figures 17.3, 17.4B) is an important regulator of circadian rhythms. Recall also that GABAergic neurons in the ventral lateral preoptic area (VLPO) contribute to nonREM sleep by inhibiting the histaminergic neurons in the tuberomammillary nucleus (TMN) (see Figures 14.13, 14.15A). The **lateral hypothalamus** is important in **appetite,** and lateral hypothalamic lesions cause a decrease in body weight. Conversely, the **medial hypothalamus,** especially the ventromedial nucleus, appears to be important in **inhibiting appetite,** and medial hypothalamic lesions can cause obesity. Recently, **leptin,** a hormone that is produced by adipose tissue, was discovered. Leptin binds to receptors in the hypothalamus named **Ob receptors,** and plays an important role in feedback regulation of food intake and obesity. **Thirst** appears to result from the activation of osmoreceptors in the anterior regions of the hypothalamus. Hypovolemia or elevated

body temperature can also activate thirst. Lesions of the lateral hypothalamus decrease water intake.

Thermoregulation involves the control of multiple systems, including sweat production, smooth muscles that affect core and surface blood flow, skeletal muscles involved in shivering, panting, and other motor activity; and endocrine systems that control the metabolic rate. The **anterior hypothalamus** appears to detect increased body temperature and activates mechanisms of **heat dissipation.** Anterior hypothalamic lesions can cause hyperthermia. In contrast, the **posterior hypothalamus** functions to **conserve heat.** Bilateral lesions of the posterior hypothalamus usually cause poikilothermia, in which the body temperature varies with the environment because these lesions destroy both heat conservation mechanisms of the posterior hypothalamus and descending pathways for heat dissipation arising from the anterior hypothalamus. The hypothalamus probably also participates in circuitry involved in sexual desire and other complex motivational states. In addition, sexual development and differentiation involves an interplay of neural and endocrine signals, many of which appear to be regulated by the hypothalamus.

REVIEW EXERCISE

What are the effects of lateral hypothalamic lesions vs. medial hypothalamic lesions on body weight? What are the effects of anterior hypothalamic lesions vs. posterior hypothalamic lesions on temperature control?

Endocrine Functions of the Pituitary and Hypothalamus

The anterior pituitary produces six important hormones, many of which regulate endocrine systems in other parts of the body, such as the adrenal cortex, thyroid, and gonads. These anterior pituitary hormones are **adrenocorticotropic hormone (ACTH), growth hormone (GH), prolactin, thyroid-stimulating hormone (TSH), luteinizing hormone (LH),** and **follicle-stimulating hormone (FSH)** (Table 17.2). The intermediate lobe is rudimentary in

TABLE 17.2 Anterior Pituitary Hormones and Hypothalamic Releasing and Inhibitory Factors

PITUITARY HORMONE	HYPOTHALAMIC RELEASING FACTORS	HYPOTHALAMIC INHIBITORY FACTORS
Adrenocorticotropic hormone (ACTH)	Corticotropin-releasing hormone (CRH), vasopressin, and other peptides	—
Thyroid-stimulating hormone (TSH)	Thyrotropin-releasing hormone (TRH)	Growth hormone–inhibiting hormone (GIH, somatostatin)
Growth hormone (GH)	Growth hormone–releasing hormone (GHRH)	Growth hormone–inhibiting hormone (GIH, somatostatin)
Prolactin	Prolactin-releasing factor (PRF) and thyrotropin-releasing hormone (TRH)	Prolactin release–inhibiting factor (PIF, dopamine)
Luteinizing hormone (LH)	Luteinizing hormone–releasing hormone (LHRH)	—
Follicle-stimulating hormone (FSH)	Luteinizing hormone–releasing hormone (LHRH)	—

humans, produces pro-opiomelanocortin (POMC) and melanocyte-stimulating hormone (MSH), and has little known clinical significance. Two hormones are released in the posterior pituitary: (1) **oxytocin** and (2) **vasopressin,** which is also called **arginine vasopressin** (**AVP**) or **antidiuretic hormone** (**ADH**).

REVIEW EXERCISE

Name 6 hormones released in the anterior pituitary and 2 hormones released in the posterior pituitary. What kind of cells (glandular cells or neurons) release the anterior pituitary hormones? Where in the hypothalamus are the inhibitory and releasing factors released and how do they reach the anterior pituitary? What kind of cells release the posterior pituitary hormones, and what are the names of the nuclei where their cell bodies are located?

Release of the anterior pituitary hormones by glandular cells is controlled by neurons in the hypothalamus through the **hypophysial portal system** (Figure 17.5). The pituitary receives arterial blood from the **inferior and superior hypophysial arteries,** which are both branches of the internal carotid artery. The first capillary plexus of the portal system occurs in the **median eminence.** Neurons lying adjacent to the third ventricle in several hypothalamic nuclei project to the median eminence, where they secrete inhibitory and releasing factors (see Table 17.2). Nuclei projecting to the median eminence include the **arcuate nucleus, periventricular nucleus, medial preoptic nucleus,** and medial parvocellular portions of the **paraventricular nucleus.**

Inhibitory and releasing factors enter the capillary plexus of the median eminence (see Figure 17.5; see also Figure 5.15) and are carried by the **hypophysial portal veins** to the anterior pituitary. Most of these factors are peptides, except for prolactin release–inhibiting factor (PIF), which is dopamine (see Table 17.2). Hormones released in the anterior pituitary are

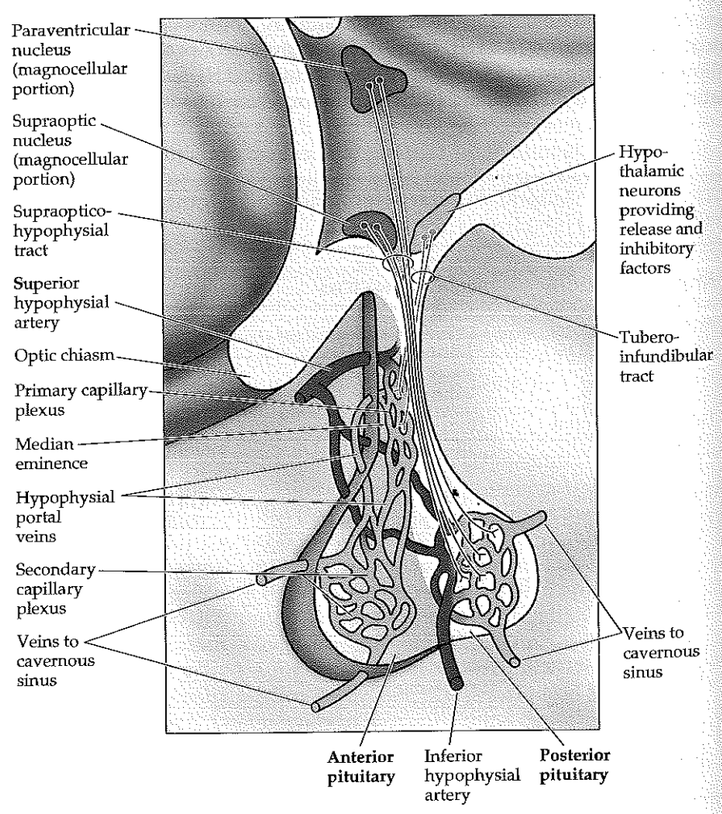

Figure 17.5 Regulation of Anterior and Posterior Pituitary Hormones by the Hypothalamus Hypothalamic neurons producing inhibitory and releasing factors project to the median eminence where these factors are carried by the hypophysial portal veins to modulate anterior pituitary hormone release. Hypothalamic neurons in the supraoptic and paraventricular nuclei secrete oxytocin and vasopressin in the posterior pituitary.

picked up by the secondary capillary plexus of the portal system and carried by draining veins to the cavernous sinus. Recall that the cavernous sinus drains primarily via the superior and inferior petrosal sinuses to reach the internal jugular vein (see Figure 10.11A,B).

The posterior pituitary also has a capillary plexus (see Figure 17.5), which picks up oxytocin and vasopressin and carries these hormones into the systemic circulation. Oxytocin and vasopressin are secreted in the posterior pituitary by terminals of neurons whose cell bodies lie in the supraoptic and paraventricular nuclei. Both nuclei contain both hormones, but different neurons appear to contain either oxytocin or vasopressin.

We will now briefly review the most important functions of each of the pituitary hormones (Figure 17.6). **ACTH** stimulates the **adrenal cortex** to produce **corticosteroid hormones,** especially the glucocorticoid hormone **cortisol,** and to a lesser extent the mineralocorticoid hormone **aldosterone.** These steroid hormones are important for maintaining blood pressure, controlling electrolyte balance, promoting glucose mobilization into the blood-

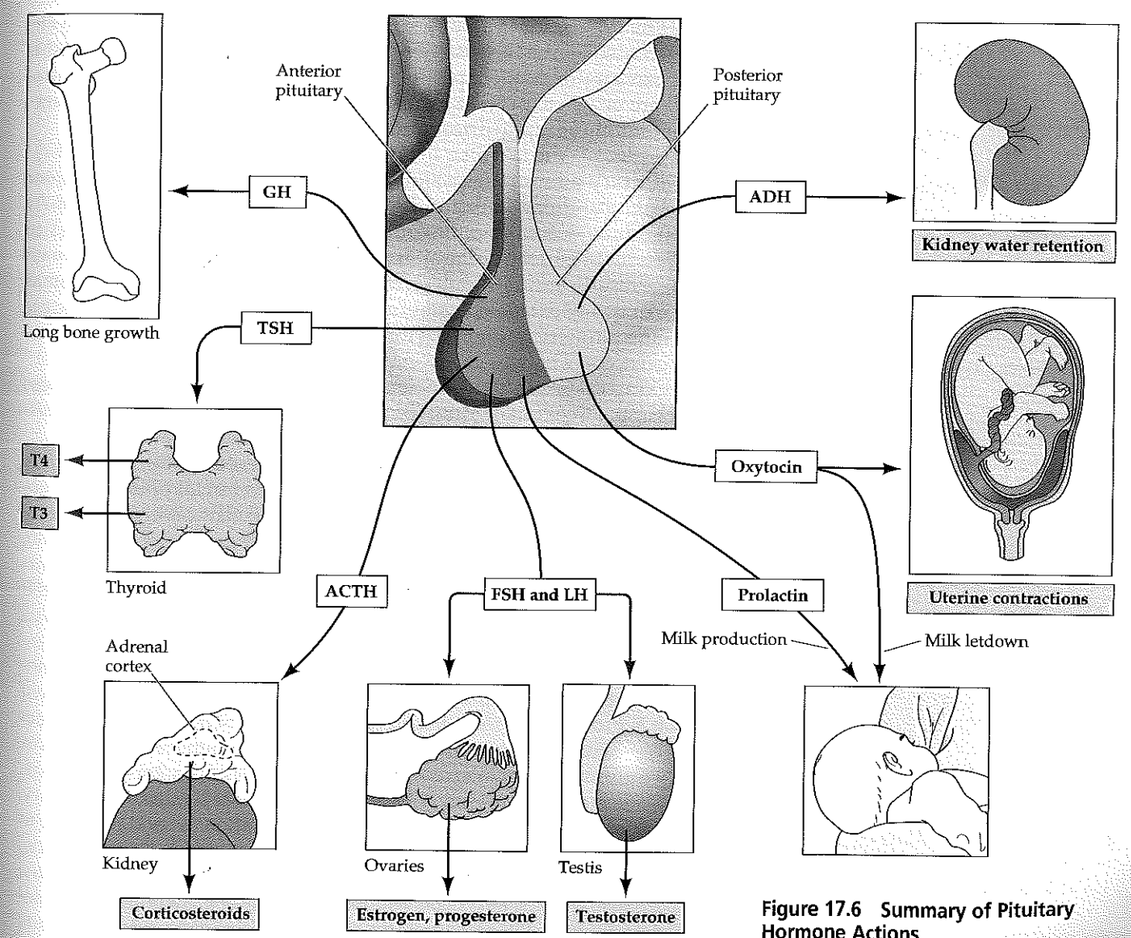

Figure 17.6 Summary of Pituitary Hormone Actions

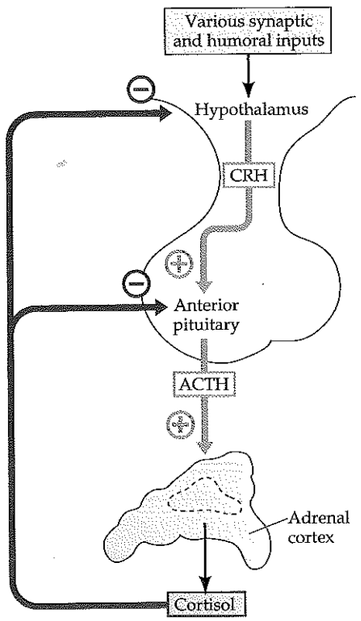

Figure 17.7 Feedback Control of CRH and ACTH Production in the Hypothalamic–Pituitary Axis

stream, and a variety of other functions. **TSH** stimulates the **thyroid gland** to produce **thyroxine (T4)**, and **triiodothyronine (T3)**. These hormones promote cellular metabolism. **Growth hormone** causes the liver, kidneys, and other organs to produce **somatomedins** or **insulin-like growth factors,** which promote increased growth of the long bones and other tissues. **Prolactin** causes the mammillary glands to produce milk. **LH** and **FSH** regulate ovarian hormones responsible for the menstrual cycle and oogenesis in females, and they regulate testicular hormones and spermatogenesis in males. **Oxytocin** causes contractions of smooth muscle in the breast for milk letdown, and contractions of the uterus during labor. **Vasopressin,** or ADH, participates in osmotic regulation by promoting water retention by the kidneys, allowing concentration of the urine.

Release of hormones in the **hypothalamic–pituitary axis** is regulated by multiple neuroendocrine feedback loops. For example (Figure 17.7), release of corticotropin-releasing hormone (CRH) by the hypothalamus and release of ACTH by the anterior pituitary both receive feedback inhibition from circulating cortisol in the bloodstream. Chronic administration of exogenous steroids can suppress ACTH production to the point that the adrenals atrophy and are unable to provide sufficient cortisol to support life if the exogenous steroids are abruptly discontinued.

KEY CLINICAL CONCEPT

PITUITARY ADENOMA AND RELATED DISORDERS

17.1 Pituitary adenoma is a slow-growing histologically benign tumor arising from glandular epithelial cells in the anterior pituitary. It is a fairly common tumor, accounting for about 5% of all intracranial neoplasms in adults (see Table 5.6). Mean age at the time of diagnosis is 40 years, although cases occasionally occur in adolescents or in the elderly. Pituitary adenomas can arise from any of the cell types in the anterior pituitary, and 85% secrete one or more pituitary hormones. Hormone secretion by pituitary adenomas is often in excess of normal levels and is not under normal hypothalamic control, resulting in several endocrinological syndromes, which we will discuss in this chapter. Even small pituitary **microadenomas** less than 1 mm in diameter can cause significant endocrinological abnormalities.

In contrast, nonfunctioning ("silent") adenomas often grow larger before causing symptoms. Headache may be present even in small pituitary adenomas because of irritation of pain fibers in the adjacent cavernous region; however, headache is more common in large pituitary tumors. In addition, compression of the optic chiasm by large tumors can cause visual disturbances, including a characteristic **bitemporal hemianopia** (see KCC 11.2). If left untreated, large pituitary adenomas can eventually cause hydrocephalus and brainstem compression.

Prolactin is the most commonly secreted hormone in pituitary adenomas, accounting for about 50% of all pituitary adenomas. The next most common is growth hormone, followed by ACTH. TSH-, LH-, and FSH-secreting tumors are more rare, as are tumors secreting more than one hormone. Nonfunctioning tumors account for about 15% of pituitary adenomas.

Treatment options for pituitary adenomas include medication, surgery, and radiotherapy. Prolactin-secreting tumors often show a good response to treatment with dopaminergic agonists such as bromocriptine or cabergoline, which inhibit prolactin release (see Table 17.2) and shrink tumors. Recently, promising results have also been obtained in treating growth hormone–secreting tumors with the somatostatin analogue octreotide, which inhibits

growth hormone release (see Table 17.2) and shrinks tumors. Treatment of nonprolactin-secreting or growth hormone–secreting tumors with medications has generally been disappointing. Surgical resection offers the advantages of potential immediate cure and relatively low risk. Surgery is also used for prolactin-secreting or growth hormone–secreting tumors that do not respond adequately to medical therapy. Usually, a **transsphenoidal approach** is taken, in which, under general anesthesia, the floor of the pituitary fossa is entered through the roof of the sphenoid sinus (see Figure 12.1), with instruments inserted through the nose. With suprasellar pituitary tumors (extending above the sella turcica), an intracranial approach is often necessary to attain adequate tumor removal. Radiotherapy is used mainly for cases that fail to respond to surgery, although use of highly focused treatments such as proton beam therapy and the gamma knife are being investigated as alternatives to surgery.

Let's discuss the **clinical presentation and diagnosis** of each type of hormone-secreting pituitary adenoma. Prolactin-secreting adenomas typically cause amenorrhea in women, hypogonadism in men, and galactorrhea, infertility, hair loss, decreased libido, and weight gain in both sexes. Some of these effects of elevated prolactin are mediated by inhibition of hypothalamic LHRH, which in turn leads to decreased LH and FSH levels (see Table 17.2). In normal women this effect of prolactin on LH and FSH delays the resumption of menses during lactation. As with all other pituitary tumors, headache and visual symptoms can also occur.

Elevated prolactin levels can have many causes, but very high levels (>150 micrograms per liter in nonpregnant patients) are virtually diagnostic of pituitary adenoma. MRI is useful for diagnosis and can now be used to detect microadenomas as small as 0.5 to 1 mm in diameter through indirect effects on pituitary shape, although smaller tumors may not be visualized despite significant endocrine abnormalities. Hypothalamic lesions can also sometimes cause elevated prolactin levels due to decreased PIF (dopamine) production, but the increase is not as high as is typically seen in pituitary adenomas.

Growth hormone–secreting adenomas cause acromegaly, a slowly progressive overgrowth of bones and soft tissues. Acromegaly is characterized by enlarged hands and feet, coarsened facial features, and a protuberant jaw. Gigantism occurs if growth hormone excess begins before epiphyseal closure in adolescence. Other common problems in patients with growth hormone excess include carpal tunnel syndrome, arthritis, infertility, hypertension, and diabetes. Diagnosis is by typical clinical features, elevated GH levels of greater than 2 micrograms per liter even after glucose administration, and MRI.

ACTH-secreting adenomas cause Cushing's disease. **Cushing's syndrome** is a general term for the clinical features of glucocorticoid excess of any cause, inlcuding endogenous cortisol excess or exogenous administration of glucocorticoid medications (such as prednisone, methylprednisolone, dexamethasone, or hydrocortisone). **Cushing's disease** is an important cause of Cushing's syndrome, and means specifically that the syndrome is caused by an ACTH-secreting pituitary adenoma. In Cushing's syndrome there is a characteristic **cushingoid** appearance, with a round "moon-shaped" facies and deposition of fat on the trunk more than the extremities, resulting in truncal obesity. The body habitus of the cushingoid patient has, therefore, been described as "spiderlike." Glucocorticoid excess can also cause acne, hirsutism, purplish skin striae, thin-appearing skin, easy bruising, poor wound healing, hypertension, diabetes, edema, immunosuppression, osteoporosis, avascular necrosis of the femoral head, amenorrhea, decreased libido, myopathy, fatigue, and psychiatric disturbances including

mania, psychosis, and depression. Cushing's syndrome is caused by primary adrenal adenomas or adenocarcinomas in only about 15% of cases. The remaining 85% are caused by ACTH oversecretion by pituitary adenomas (70%), or by nonpituitary tumors that secrete ACTH, such as bronchial carcinoma (15%), referred to as "ectopic" ACTH production.

A series of endocrinological tests is done to localize the cause of endogenous cortisol excess. The **dexamethasone suppression test** works on the principle that administration of a dose of dexamethasone at midnight normally acts through negative feedback like cortisol (see Figure 17.7) to suppress cortisol levels or urine cortisol metabolites measured the next morning. A low-dose (1 to 3 milligram) overnight dexamethasone suppression test is often used as an initial screening test for excess cortisol production. If cortisol production is not suppressed with the low-dose test, the high-dose (8-milligram) dexamethasone suppression test is then helpful because ACTH-secreting pituitary tumors are usually suppressible with this dose, while ectopic ACTH-secreting tumors and adrenal tumors are not. Another strategy is to administer CRH (see Figure 17.7; Table 17.2), which causes an excessive rise in plasma ACTH and cortisol in pituitary adenomas but not in ectopic ACTH or adrenal tumors. MRI is useful in diagnosis as well. Finally, when results of these tests are equivocal, **petrosal sinus sampling** can be helpful to distinguish pituitary from nonpituitary ACTH overproduction. In addition, petrosal sinus sampling can often correctly localize the side of a microadenoma not visible on MRI. In this way, selective surgery on the side of the microadenoma may be possible while function of the remaining pituitary gland is spared.

In petrosal sinus sampling, catheters are inserted through a femoral vein and passed upward under radiological guidance through the internal jugular veins to reach the inferior petrosal sinuses on both sides (see Figure 10.11A,B). Aliquots are first removed to determine baseline ACTH levels. In ACTH-secreting pituitary adenomas, ACTH levels in at least one petrosal sinus should be more than two times the ACTH levels in a peripheral vein. An intravenous dose of CRH (see Figure 17.7) is then given, and ACTH measurements from each inferior petrosal sinus are taken approximately every 5 minutes. A threefold increase in ACTH is diagnostic of a pituitary adenoma. In addition, the ACTH rise is usually 2 to 20 times higher on the side of the tumor than on the contralateral side.

TSH-secreting adenomas are a rare cause of hyperthyroidism. **Hyperthyroidism** is much more commonly caused by primary thyroid disorders such as Graves' disease, thyroiditis, toxic multinodular goiter, and thyroid adenomas. Clinical manifestations of hyperthyroidism include nervousness, insomnia, weight loss, tremor, excessive sweating, heat sensitivity, increased sympathetic output, and frequent bowel movements. Thyroid ophthalmopathy can occur, in which there is inflammatory involvement of orbital tissues leading to proptosis, and ultimately extraocular muscle fibrosis, which can mimic brainstem or cranial nerve disorders. Other important neurologic manifestations of hyperthyroidism include proximal muscle weakness, tremor, dyskinesias, and dementia. Particularly in the elderly, many of the other manifestations may be absent, and hyperthyroidism can mimic dementia (see KCC 19.16) or depression. In hyperthyroidism caused by primary thyroid disorders, TSH levels are completely suppressed, while in TSH-secreting pituitary adenomas, TSH levels are elevated.

Hypothyroidism is also usually caused by primary thyroid disorders such as autoimmune thyroid disease, iodine deficiency, or previous ablative treatment for hyperthyroidism, and rarely is caused by pituitary or hypothalamic insufficiency. However, when lesions of the hypothalamus or pituitary are present, including medium-to-large pituitary adenomas of any type, it is relatively common for TSH production to be impaired, resulting in hypothyroidism. Manifestations of hypothyroidism of any cause include lethargy, weight gain, cold intolerance, smooth dry skin, hair loss, depression, and constipation. Eventually, **myxedema coma** and cardiac involvement can occur. Other important neurologic manifestations include neuropathy, carpal tunnel syndrome, myalgias, ataxia, and dementia. Like hyperthyroidism, hypothyroidism can present in the elderly with a dementia or depression-like picture. Untreated hypothyroidism in utero or in infancy can cause cretinism, which is characterized by mental retardation, short stature, microcephaly, and other abnormalities.

LH or FSH-secreting adenomas often cause **hypogonadism and infertility,** although tumors can reach a relatively large size before being detected clinically. Interestingly, these tumors may produce either high or low testosterone and estradiol levels; however, in either situation, patients have clinical hypogonadism. Because these tumors are often large, patients may present with headache and visual changes as the major manifestations.

Other lesions can also occur in the sellar and suprasellar region, causing endocrine disturbances or compressing the optic chiasm. Although pituitary adenoma is the most common, other lesions seen in this region include craniopharyngioma, aneurysms, meningioma, optic glioma, hypothalamic glioma, chordoma, teratoma, epidermoid, dermoid, Rathke's pouch cysts, empty sella syndrome, sarcoidosis, lymphoma, and metastases. ■

KEY CLINICAL CONCEPT
DIABETES INSIPIDUS AND SIADH

17.2 **Diabetes insipidus** (**DI**) is the production of large amounts of dilute urine. This condition can be caused by deficiency of ADH (**central or neurogenic DI**) or by insensitivity of the kidneys to ADH (**nephrogenic DI**). Symptoms of DI include severe thirst, polyuria, and polydipsia. Patients who are able to drink consume large amounts of water to maintain fluid balance. Patients who cannot drink adequately become dehydrated rapidly and die if not treated. The diagnosis is made in a patient with polyuria by documentation of relatively low urine osmolality, despite increased plasma osmolality. To detect this condition, sometimes the patient must be asked to temporarily stop drinking while in a supervised setting. A dose of subcutaneous vasopressin will cause urine osmolality to rise in neurogenic but not in nephrogenic DI. Common causes of neurogenic DI include neurosurgery, head trauma, and infiltrative or neoplastic lesions in the pituitary–hypothalamic region (see KCC 17.1) or in the third ventricle. Interestingly, lesions of the posterior pituitary do not cause DI unless the lesion is high enough in the pituitary stalk to result in retrograde degeneration of hypothalamic neurons in the supraoptic and paraventricular nuclei (see Figure 17.5). This suggests that neurons in these nuclei are capable of releasing vasopressin in locations other than the posterior pituitary. Treatment of DI is with subcutaneous or intranasal administration of synthetic vasopressin analogs.

In the **syndrome of inappropriate antidiuretic hormone** (**SIADH**), excess ADH production causes a low serum sodium (**hyponatremia**), together with inappropriately elevated urine osmolality. Note that hyponatremia with elevated urine osmolality is not always caused by SIADH, and it can also be seen in hypovolemia or in edematous states such as heart failure or cirrhosis. SIADH can be caused by many neurologic and non-neurologic conditions, including head trauma, meningitis, and numerous other neurologic disorders, pulmonary disorders, medication side effects, and ADH-secreting neoplasms. Severe hyponatremia can cause lethargy, coma, or seizures. When SIADH is

the cause of hyponatremia, it should be treated by restriction of daily fluid intake. In severe cases, infusions of hypertonic saline are sometimes used, but care must be taken not to correct hyponatremia too rapidly because **central pontine myelinolysis** can result from this approach.

Some conditions can cause the consecutive appearance of SIADH and DI in a single patient. For example, following surgery in the pituitary region there is occasionally a triphasic response, with DI shortly after surgery, followed by SIADH, and finally DI again, which may then gradually improve. Patients with other intracranial disorders, such as catastrophic hemorrhage or infarct, may initially have SIADH. If brain death then ensues, all ADH production ceases, resulting in DI. ■

KEY CLINICAL CONCEPT
PANHYPOPITUITARISM

17.3 Deficiency of multiple pituitary hormones can occur in several conditions of the pituitary and hypothalamic regions. When all pituitary hormones are involved, the condition is called **panhypopituitarism. ACTH deficiency** causes hypocortisolism, with fatigue, weakness, decreased appetite, and impaired response to stress resulting in hypotension, fever, hypoglycemia, and a high mortality rate. **TSH deficiency** causes hypothyroidism (see KCC 17.1), and **ADH deficiency** causes diabetes insipidus (see KCC 17.2). **LH and FSH deficiencies** cause hypogonadism, including decreased libido, amenorrhea, and infertility. **GH deficiency** in children causes dwarfism. **Prolactin deficiency** in women causes inability to lactate.

There are multiple possible causes of panhypopituitarism. Lesions in this region include (see KCC 17.1) large nonfunctioning pituitary adenomas, hypothalamic tumors, metastases, and other infiltrative processes, including sarcoidosis, infections, and autoimmune disorders. On rare occasions, pituitary tumors can undergo spontaneous hemorrhage resulting in **pituitary apoplexy.** Patients with pituitary apoplexy often present with sudden headache, meningeal signs, unilateral or bilateral cavernous sinus syndrome (see KCC 13.7), visual loss, hypotension, and depressed level of consciousness. Panhypopituitarism is a common sequela of pituitary apoplexy. Other causes of panhypopituitarism include head trauma, surgery, radiation therapy, pituitary infarct, and congenital abnormalities.

Panhypopituitarism is treated by exogenous replacement of pituitary hormones. ACTH insufficiency is treated by daily administration of steroids such as prednisone or hydrocortisone, with increased doses given in situations of stress such as infection or surgery. Diabetes insipidus is treated with synthetic ADH analogs, and hypothyroidism is treated with synthetic thyroid hormones. Hypogonadism is treated with testosterone or estrogen–progesterone combinations, and fertility can sometimes be achieved with LH and FSH substitution therapy. GH replacement is used in children; possible beneficial effects of GH replacement in adults are still under investigation. ■

CLINICAL CASES

CASE 17.1 MOON FACIES, ACNE, AMENORRHEA, AND HYPERTENSION

CHIEF COMPLAINT
A 33-year-old woman presented to an endocrinology clinic with multiple complaints, including truncal obesity, acne, amenorrhea, and hypertension.

HISTORY
Symptoms had begun 3 years previously with **increased facial hair, new-onset acne, 45-pound weight gain especially in the abdomen, easy bruisability, excessive sweating, and striae on her skin.** Two years prior to presentation her **menstrual periods stopped,** and she developed **hypertension** requiring medication. During recent months she had become **irritable and depressed,** and had **decreased energy, with difficulty walking up stairs.**

PHYSICAL EXAMINATION
General appearance: **Round face ("moon facies"), truncal obesity with a "buffalo hump" of fat in the posterior neck, and thin legs.**
Vital signs: T = 98°F, BP = 125/85.
Neck: Supple, obese. Thyroid not enlarged.
Lungs: Clear.
Breasts: No masses.
Heart: Regular rate with no murmurs.
Abdomen: Obese; normal bowel sounds; no masses.
Extremities: No clubbing or edema.
Skin: **Ruddy faced, with facial hair, abdominal striae, ecchymoses, and thin-appearing skin in some areas.**
Genitalia: Normal female.
Neurologic exam: Normal mental status, cranial nerves, motor exam, reflexes, coordination, gait, and sensation.

DIAGNOSIS AND INITIAL LOCALIZATION
1. On the basis of the symptoms and signs shown in **bold** above, what endocrinological syndrome is present in this patient? This syndrome is caused by excess of which hormone?
2. What are the possible localizations for this disorder?

Discussion

The key symptoms and signs in this case are:
- **Truncal obesity, increased facial hair, new-onset acne, easy bruisability, excessive sweating, ruddiness and skin striae, amenorrhea, hypertension, irritability and depression, decreased energy, and difficulty walking up stairs**

1. These clinical features are all typical of Cushing's syndrome (see KCC 17.1). In the absence of exogenous glucocorticoid administration, Cushing's syndrome is caused by excess cortisol production by the adrenal cortex.
2. Cushing's syndrome can be caused by pituitary or extrapituitary hypersecretion of ACTH or by adrenal tumors. The most common cause is ACTH-secreting pituitary adenoma.

CASE 17.1 *(CONTINUED)*

INITIAL TEST RESULTS
The patient's free cortisol level in the urine was 410 μg/dl (normal is <70). A low-dose overnight dexamethasone suppression test did not fully suppress the patient's free cortisol in the urine, but a high-dose dexamethasone suppression test did. Serum ACTH level was 35 pg/ml (normal is 6–86), which was not low despite high cortisol levels. The patient had an MRI scan with special attention to the pituitary region, which was entirely normal.

1. How do these results help with localization?
2. What does the MRI scan suggest about the diagnosis?
3. What test could be done to narrow the localization further?

Discussion

1. Elevated urinary cortisol, with suppression only with the high-dose dexamethasone test, suggests the presence of an ACTH-secreting pituitary adenoma (see KCC 17.1). Recall that nonpituitary sources of excess ACTH are usually not suppressed by the high-dose test, while pituitary sources are suppressed. In further support of an ACTH-secreting pituitary tumor, she had a normal ACTH level despite having elevated cortisol, suggesting that ACTH secretion was not under normal feedback inhibition (see Figure 17.7).
2. The normal MRI scan suggests that if a pituitary tumor were present, it would have to be a small microadenoma, probably less than 0.5 to 1 mm in diameter.
3. Petrosal sinus sampling (see KCC 17.1) can be used to confirm that excess ACTH is from a pituitary source and can often determine which side of the pituitary contains the adenoma.

CASE 17.1 *(CONTINUED)*

PETROSAL SINUS SAMPLING

Petrosal sinus sampling was performed in which catheters were passed up from the femoral vein through the vena cava to the internal jugular veins, to finally reach the right and left inferior petrosal sinuses. Catheter tip positions were then confirmed by the injection of a small amount of radiopaque dye through each catheter (Figure 17.8). Baseline ACTH in the inferior petrosal sinuses (in picograms per milliliter) was 573 on the right and 31 on the left, with ACTH peripherally measuring 26. Fifteen minutes after systemic administration of CRH, ACTH was 20,100 on the right, 560 on the left, and 255 peripherally.

1. Where is CRH normally produced, and how does it reach the anterior pituitary?
2. How do these results help further with localization?

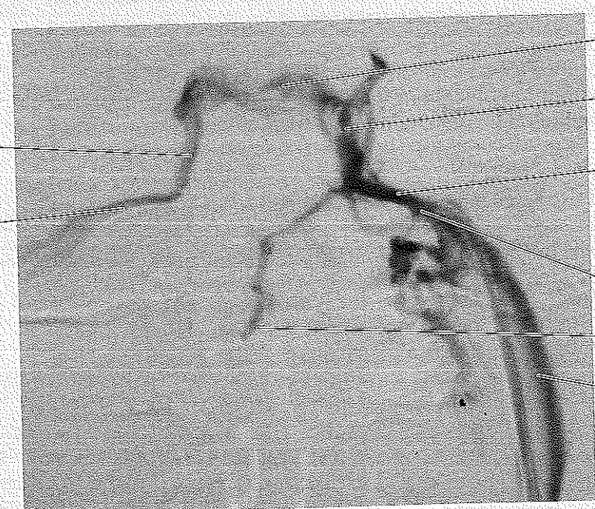

Figure 17.8 Venous Angiogram for Petrosal Sinus Sampling Contrast injection demonstrates the cavernous sinus and inferior petrosal sinuses draining into the internal jugular veins. Sampling catheters can be seen in the right and left inferior petrosal sinus

Discussion

1. CRH is produced in the hypothalamus and carried to the anterior pituitary by the hypophysial portal circulation (see Figures 17.5, 17.7).
2. Greatly elevated baseline ACTH in the petrosal sinus compared to the periphery confirms a pituitary source for ACTH hypersecretion. The dramatically asymmetrical response to CRH further localizes excess ACTH secretion to the right half of the pituitary gland.

CASE 17.1 *(CONTINUED)*

TRANSSPHENOIDAL SURGERY

The patient was admitted to the hospital for transsphenoidal surgery on the pituitary gland. Under general anesthesia, an incision was made in the mucosa under the upper lip, and the lip was retracted upward so that a speculum could be inserted through the incision into the nasal passages. In this way, access was gained to the sphenoidal sinus. The position in relation to the sella turcica was confirmed by the use of lateral fluoroscopic radiographs. The mucosa of the sphenoidal sinus was then removed to expose the bony roof of the sphenoidal sinus, or the floor of the sella turcica (see Figure 12.1). This was penetrated by a small drill and bone tools to reveal dura. An incision in the dura provided access to the pituitary gland, which was inspected and showed no obvious evidence of tumor. Several small tissue samples were removed from the right anterior pituitary and sent to pathology for immediate examination using frozen sections. One of these contained a small pituitary microadenoma.

Postoperatively the patient did well, with no visual problems or other neurologic deficits. However, on the evening after surgery she began having increased urine output, producing 2000 cc of urine in 8 hours. Serum sodium rose from 134 to 146 m*M* (normal is 135–145), urine specific gravity was low, at 1.001, and she felt very thirsty.

1. What neuroendocrinological syndrome is associated with polyuria, polydipsia, increased thirst, and increased serum osmolality without a commensurate rise in urine osmolality? A decrease in which pituitary hormone can cause these changes?
2. Where are the cell bodies of the neurons that produce this hormone, and where is it released into the circulation?

Discussion

1. The patient has developed diabetes insipidus (DI) following surgery in the pituitary region (see KCC 17.2), which is caused by insufficient release of ADH (vasopressin).
2. Vasopressin is synthesized in neurons in the supraoptic and paraventricular nuclei of the hypothalamus, and transported via axons through the pituitary stalk to the posterior pituitary, where it is released into the circulation (see Figure 17.5).

CASE 17.1 *(CONTINUED)*

HYPONATREMIA

The patient was treated with an injection of the synthetic vasopressin analog DDAVP, which immediately led to decreased urine output. Her diabetes insipidus then resolved spontaneously over the next day, requiring no further injections. Over the following few days, however, the serum sodium fell to 125 m*M* (normal is 135–145), and urine specific gravity was 1.020, which is not low. She did not show signs of edema or hypovolemia.

1. What neuroendocrinological syndrome can cause hyponatremia with a normal or increased urine osmolality?
2. Excess of which pituitary hormone is responsible for this condition?

Discussion

1. The patient's hyponatremia at this point was most likely caused by postoperative SIADH (see KCC 17.2).
2. This condition is caused by excessive ADH release.

Clinical Course

The patient was treated with restriction of free water intake, and her sodium gradually normalized. Soon afterward she again developed diabetes insipidus triphasic response; see KCC 17.2), which required treatment with DDAVP for several months. She subsequently did well, with normal cortisol

levels, and her cushingoid features gradually resolved. One month postoperatively her normal menses resumed. Nine months after surgery she had lost 25 pounds, no longer had moon facies, and had only mild acne, and her abdominal striae had faded. She also no longer had irritability or depression, but instead had a calmer mood and improved energy level.

CASE 17.2 IMPOTENCE, ANOREXIA, POLYURIA, BLURRED VISION, HEADACHES, AND HEARING LOSS*

CHIEF COMPLAINT

Over a 6-month period, a 49-year-old man saw his physician for multiple complaints including impotence, anorexia, polyuria, blurred vision, headaches, and hearing loss.

HISTORY

Six to 12 months prior to presentation the patient had developed **impotence,** including no early-morning erections and decreased sexual drive. He also developed **fatigue,** and his daily sleep requirement increased from 6 hours to 12 hours with naps. His **muscle endurance decreased,** and he became **intolerant of cold temperatures.** Five or six weeks prior to evaluation he began having **increasing headaches** over the vertex of his head, with **light bothering his eyes.** His **hearing decreased, especially on the right side,** making it difficult to understand phone conversations at work, and he noticed some **blurring of his vision.** He also had **increased thirst, drinking approximately 1 gallon each night and urinating up to 16 times.** Finally, he had marked **anorexia, with no interest in food,** and lost 22 pounds over the 3 weeks prior to presentation.

PHYSICAL EXAMINATION

Vital signs: T = 99.4°F, P = 80, BP = 110/70.
Neck: Supple with no bruits.
Lungs: Clear.
Heart: Regular rate with no murmurs, gallops, or rubs.
Abdomen: Normal bowel sounds; nontender.
Extremities: No edema.
Skin: Normal.
Genitalia: **Slightly decreased testicular volume bilaterally.**
Neurologic exam:

MENTAL STATUS: Alert and oriented ×3. Normal language and memory.

CRANIAL NERVES: Normal, except for **visual acuity 20/200 on the right, 20/40 on the left** with intact fields, and **hearing markedly decreased on the right, with air conduction greater than bone conduction.**

MOTOR: Normal tone. Power 5/5 throughout.

REFLEXES:

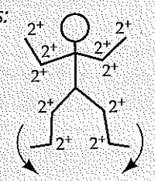

COORDINATION: Normal on finger-to-nose and heel-to-shin testing.

GAIT: Slightly wide based (secondary to old leg fracture).

SENSORY: Intact pinprick, temperature, vibration, and joint position sense.

LOCALIZATION OF PITUITARY–HYPOTHALAMIC ABNORMALITIES

1. Deficiency of which pituitary hormones can cause the following abnormalities seen in this patient?
   a. Polyuria, polydipsia, and excessive thirst
   b. Impotence, with bilateral decreased testicular volume
   c. Cold intolerance
   d. Fatigue and decreased muscle endurance
   e. Decreased appetite and weight loss
2. How does this information help with localization? A lesion in which region of the hypothalamus can also cause decreased appetite?

*This patient was described previously as a case report in *N Engl J Med*, 1994. 331(13): 861–868

Discussion

1. a. ADH (vasopressin) deficiency
   b. LH and FSH deficiency
   c. TSH deficiency
   d. TSH or ACTH deficiency
   e. ACTH deficiency
2. This patient has clinical evidence of panhypopituitarism (see KCC 17.3). The presence of ADH deficiency suggests that the lesion includes the high pituitary stalk or the hypothalamus (see KCC 17.2). In addition to ACTH deficiency, decreased appetite could also be caused by a lesion involving the lateral hypothalamus (see KCC 17.1). Note, however, that decreased appetite alone is a very nonspecific finding and can be caused by many medical disorders.

CASE 17.2 *(CONTINUED)*

RESULTS OF LABORATORY TESTS

The laboratory tests shown in the table below were performed, confirming that the patient had low levels of LH, FSH, testosterone, thyroxine, and cortisol. Elevated serum sodium and serum osmolality, with a low urine osmolality, was consistent with DI. Interestingly, prolactin levels were modestly elevated rather than decreased. Although elevated prolactin can have many causes, (including hypothyroidism, which this patient had) one additional possibility, given the fact that a hypothalamic lesion is suspected based on the presence of DI, is that the presence of a hypothalamic lesion could lead to decreased PIF (dopamine) production (see Table 17.2; KCC 17.1). Growth hormone and oxytocin levels were not measured, and somatomedin C levels were normal.

Laboratory Test Results

TEST NAME	RESULT	NORMAL RANGE	UNITS[a]
Sodium	**152**	135–145	mEq/liter
Potassium	4.5	3.5–5	mEq/liter
Glucose	92	70–110	mg/100 ml
Urine osmolality	**122**	50–1200	mosm/kg
Serum osmolality	**308**	280–296	mosm/kg
Cortisol (8:00 AM)	**1.7**	5–25	μg/100 ml
Testosterone	**10**	300–1100	ng/100ml
LH	**<1**	3–18	mU/ml
FSH	**0.3**	1–10.5	mU/ml
Prolactin	**24**	2–15	ng/ml
Thyroxine (T4)	**3.0**	4–12	μg/100 ml
Thyroid hormone binding	**0.83**	0.83–1.17	—
Triiodothyronine (T3)	96	75–195	ng/100 ml
Somatomedin C	75.6	54–328	ng/ml

[a]mEq, milliequivalents; mU, milliunits.

LOCALIZATION OF OTHER ABNORMALITIES IN THIS PATIENT, AND DIFFERENTIAL DIAGNOSIS

In addition to the above neuroendocrine findings, this patient had decreased hearing with a sensorineural pattern (see KCC 12.5) especially on the right side, decreased visual acuity, headache, and photophobia.

1. What space is shared by the hypothalamic–pituitary region, acoustic nerves, and optic nerves?
2. What are some possibilities for the diagnosis?

Discussion

The key symptoms and signs in this case are:

- **Decreased hearing, especially on the right side (air conduction greater than bone conduction)**
- **Visual acuity 20/200 on the right, 20/40 on the left**
- **Headaches, with light bothering the eyes**

1. The subarachnoid space is shared by the hypothalamic–pituitary region and by the cranial nerves. Pathology in the subarachnoid space could also explain the presence of headache and photophobia, which are signs of meningeal irritation (see Table 5.5). The panhypopituitarism in this patient suggests a lesion in the hypothalamic or pituitary region. There are some clues but no definite

evidence that the lesion involves primarily the hypothalamus rather than the pituitary, including the presence of diabetes insipidus and the fact that prolactin levels were elevated rather than decreased. Involvement of CN II could be caused by direct extension of a hypothalamic or pituitary lesion, rather than by spread through the cerebrospinal fluid; however, involvement of CN VIII cannot be explained in this manner. Therefore, a lesion of the hypothalamus or pituitary, extending into the subarachnoid space to involve CN II and VIII, should be considered.

2. Possibilities for a lesion involving these areas include metastatic disease and chronic inflammatory or infectious disorders such as sarcoidosis or tuberculosis.

Clinical Course and Neuroimaging 758

A brain **MRI scan** showed a large enhancing lesion of the hypothalamus, with some involvement of the optic tracts bilaterally (Figure 17.9). Abnormal enhancement was seen in the septum pellucidum as well, suggesting that the lesion had possibly spread by CSF pathways. The patient was admitted to the hospital and underwent a lumbar puncture (see KCC 5.10), with CSF showing an elevated protein of 82 (normal is 15–45), normal glucose, no red blood cells, and an increased CSF white blood cell count of 18 (normal is <5), with 93% lymphocytes (see Tables 5.7, 5.9). CSF cytology was suspicious for lymphoma but not definitive. Repeat CSF cytology was also not definitive. Therefore, the patient underwent a needle biopsy of the enhancing lesion in the septum pellucidum (Figure 17.9) using a right frontal stereotactic approach (see KCC 16.4). Pathologic analysis showed B cell lymphoma (see KCC 5.8). An HIV test was done and was negative.

The patient was treated for his panhypopituitarism (see KCC 17.3) with (1) synthetic vasopressin (DDAVP) nose spray for his diabetes insipidus, (2) the steroid prednisone for his hypoadrenalism, (3) thyroid hormone replacement therapy for his hypothyroidism, and (4) testosterone for his impotence and hypogonadism.

His lymphoma was treated with repeated cycles of intravenous chemotherapy with methotrexate about once per month, with an excellent response and no major toxicity. After 1 month his hearing in the right ear had improved, and he no longer had headaches. After 2 months his vision had improved, and he returned to work. Follow-up MRI scans showed complete disappearance of the enhancing lesions. Two years later an MRI scan showed recurrent enhancement in the original locations, as well as pial enhancement along the pons and midbrain. CSF showed lymphoma cells. He was switched to a different chemotherapy regimen, and the lesions on MRI again disappeared. At last follow-up, 3 years after diagnosis, he continued to do well.

Additional Cases

Related cases can be found in other chapters for the following topics: **lesions of the sellar region** (Cases 11.3, 13.5); and **disorders of hypothalamic connections to autonomic or limbic circuits** (Cases 14.1, 18.1–18.5). Other relevant cases can be found using the **Case Index**.

Brief Anatomical Study Guide

1. The pituitary and hypothalamus link the nervous system through both synaptic and humoral forms of communication with numerous other systems in the body. The **pituitary gland** is connected to the bottom of the hypothalamus via the pituitary stalk (see Figure 17.2). This location of the pituitary gland just underneath the optic chiasm can result in compression of crossing optic nerve fibers by pituitary region tumors, classically causing **bitemporal hemianopia** or other visual deficits (see Figure 11.15).

2. The **hypothalamus** is located beneath the thalamus and can be divided from anterior to posterior into the **preoptic region, anterior (supraoptic) region, middle (tuberal) region,** and **posterior (mammillary) region.** The hypothalamus can also be divided from medial to lateral into a **periventricular area, medial hypothalamic area,** and **lateral hypothalamic area** (see Figures 17.3, 17.4). The **main nuclei** of the hypothalamus are listed in Table 17.1.

3. The hypothalamus participates in a variety of neural and non-neural systems that mainly regulate **homeostasis** through multiple complex feedback loops. The hypothalamus participates in these functions:
   A. **Homeostatic** control of appetite, thirst, thermoregulation, sleep-wake cycles, and sexual desire
   B. **Endocrine** control
   C. **Autonomic** nervous system
   D. **Limbic** system (Chapter 18)

4. Important nuclei and connections of the hypothalamus include:
   A. The **paraventricular nucleus** and other associated nuclei that control autonomic function (see Figures 13.10, 17.3, 17.4)
   B. Limbic inputs to the **mammillary bodies** from the hippocampal formation via the **fornix** (see Figures 18.9, 18.13)
   C. Limbic outputs from the mammillary bodies via the **mammillothalamic tract** to the anterior thalamic nucleus (see Figure 18.9)
   D. Reciprocal limbic connections with the amygdala via the **stria terminalis** and **ventral amygdalofugal pathway** (see Figure 18.17)
   E. Control of circadian rhythms by the **suprachiasmatic nucleus** (see Figures 17.3, 17.4)
   F. Release of oxytocin and vasopressin by the **supraoptic and paraventricular nuclei** into the posterior pituitary (see Figures 17.5, 17.6)
   G. Release of stimulatory and inhibitory factors by the **arcuate nucleus, periventricular nucleus, medial preoptic nucleus,** and medial parvocellular portions of the **paraventricular nucleus** for control of the anterior pituitary (see Table 17.2; Figure 17.5)

5. The **pituitary gland** is composed of an **anterior lobe,** or **adenohypophysis,** derived embryologically from the roof of the pharynx (see Figure 17.1), and a **posterior lobe,** or **neurohypophysis,** derived embryologically from the diencephalon. The anterior pituitary is composed of endocrine tissue and secretes the following six hormones: **adrenocorticotropic hormone (ACTH), growth hormone (GH), prolactin, thyroid-stimulating hormone (TSH), luteinizing hor-**

CASE 17.2 IMPOTENCE, ANOREXIA, POLYURIA, BLURRED VISION, HEADACHES, AND HEARING LOSS

Figure 17.9 Enhancing Mass in the Hypothalamus Extending into the Optic Tracts Coronal T1 weighted MRI scans with gadolinium. A, B progress from posterior to anterior.

(A)

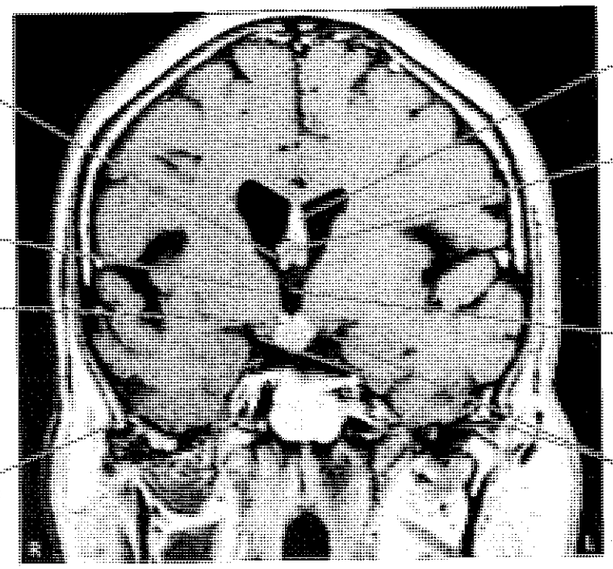

(B)

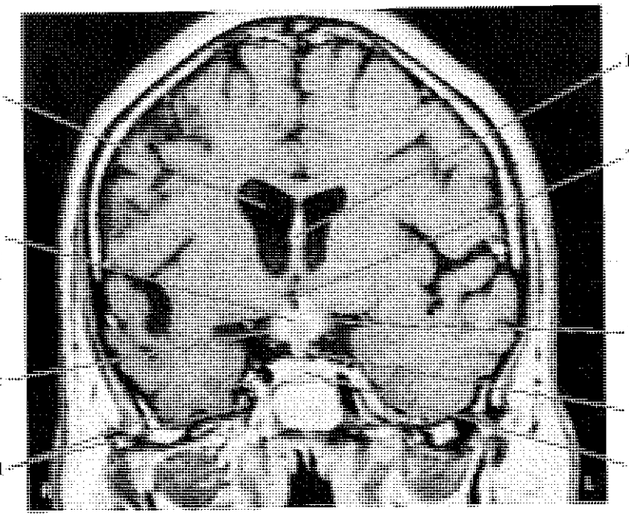

Brief Anatomical Study Guide *(continued)*

mone (LH), and **follicle-stimulating hormone (FSH)**. The posterior pituitary is composed of neural tissue extending from the hypothalamus and releases the two hormones **oxytocin** and **vasopressin**, also called **arginine vasopressin (AVP)** or **antidiuretic hormone (ADH)**. Functions of these anterior and posterior pituitary hormones are summarized in Figure 17.6.

6. Secretion of anterior pituitary hormones is controlled by hypothalamic **releasing and inhibitory factors** (see Table 17.2) that travel from the **median eminence** to the anterior pituitary via a **hypophysial portal circulatory system** (see Figure 17.5). Posterior pituitary hormones are released at axon terminals of magnocellular neurons located in the **supraoptic** and **paraventricular** nuclei of the hypothalamus (see Figure 17.5). The hypothalamic–pituitary axis is controlled by multiple feedback loops, as shown, for example, with the adrenocortical system in Figure 17.7.

References

Blevins LS, Wand GS. 1992. Diabetes insipidus. *Crit Care Med* 20(1): 69–79.

Cooper P. 2000. Neuroendocrinology. In Bradley WG, Daroff RB, Fenichel GM, Marsden CD (eds.), *Neurology in Clinical Practice: Principles of Diagnosis and Management*, 3rd Ed. Chapter 48. Butterworth-Heinemann, Boston.

Cardoso ER, Peterson EW. 1984. Pituitary apoplexy: A review. *Neurosurgery* 14(3): 363–373.

Celesia GG, Archer CR, Chung HD. 1981. Hyperphagia and obesity. Relationship to medial hypothalamic lesions. *JAMA* 246(2): 151–153.

Davis PC, Hoffman JC, Tindall GT, Braun IF. 1985. CT-surgical correlation in pituitary adenomas: Evaluation in 113 patients. *Am J Neuroradiol.* 6(5): 711–716.

Friedman JM, Halaas JL. 1998. Leptin and the regulation of body weight in mammals. *Nature* 395(6704): 763–770.

Greger NG, Kirkland RT, Clayton GW, Kirkland JL. 1986. Central diabetes insipidus. *Am J Dis Child* 140(6): 551–554.

Kamijo K, Yachi A, Tanabe K, Daibo M. 1988. Clinical diagnosis of pituitary adenoma. *Pathol Res Pract* 183(5): 538–539.

Kovacs K, Horvath E, Ezrin C. 1977. Pituitary adenomas. *Pathol Annu* 12(Pt 2): 341–382.

Kovacs L, Robertson GL. 1992. Syndrome of inappropriate antidiuresis. *Endocrinol Metab Clin North Am* 21(4): 859–875.

Ludecke DK. 1991. Transnasal microsurgery of Cushing's disease 1990. *Pathol Res Pract* 187(5): 608–612.

Rolih CA, Ober KP. 1993. Pituitary apoplexy. *Endocrinol Metab Clin North Am* 22(2): 291–302.

Scanarini M, Mingrino S. 1980. Functional classification of pituitary adenomas. *Acta Neurochir* 52(3–4): 195–202.

Schild HH, Strack TR. 1992. Selective simultaneous bilateral sampling from the inferior petrosal sinuses. In Ulfacker R, Sorensen R (eds.), *Percutaneous Venous Blood Sampling in Endocrine Diseases*, Chapter 3. Springer, New York.

Tien R, Kucharczyk J, Kucharczyk W. 1991. MR imaging of the brain in patients with diabetes insipidus. *Am J Neuroradiol* 12(3): 533–542.

CHAPTER 18

Limbic System: Homeostasis, Olfaction, Memory, and Emotion

ANATOMICAL AND CLINICAL REVIEW

Overview of Limbic Structures

Olfactory System

Hippocampal Formation and Other Memory-Related Structures

KCC 18.1 Memory Disorders

The Amygdala: Emotions, Drives, and Other Functions

Other Limbic Pathways

KCC 18.2 Seizures and Epilepsy

KCC 18.3 Anatomical and Neuropharmacological Basis of Psychiatric Disorders

CLINICAL CASES

18.1 Sudden Memory Loss after a Mild Head Injury

18.2 Progressive Severe Memory Loss, with Mild Confabulation

18.3 Transient Diplopia, Lethargy, and Hemiparesis, Followed by a Sustained Memory Deficit

18.4 Episodes of Panic, Olfactory Hallucinations, and Loss of Awareness

18.5 Episodes of Staring, Lip Smacking, and Unilateral Semipurposeful Movements

Additional Cases

BRIEF ANATOMICAL STUDY GUIDE

The structures of the limbic system regulate emotions, olfaction, memory, drives, and homeostasis. A 40-year-old woman awoke from sleep and complained to her husband of an indescribable unpleasant odor, nausea, and a panicky, fearful sensation. During the following week, she had repeated stereotyped episodes of this kind followed by decreased responsiveness and slow, inappropriate speech lasting 2 to 3 minutes. As we shall see, limbic system abnormalities can cause paroxysmal disorders of the kind seen in this patient. In this chapter we will learn about this important and diverse neural system and the consequences of limbic system damage or dysfunction.

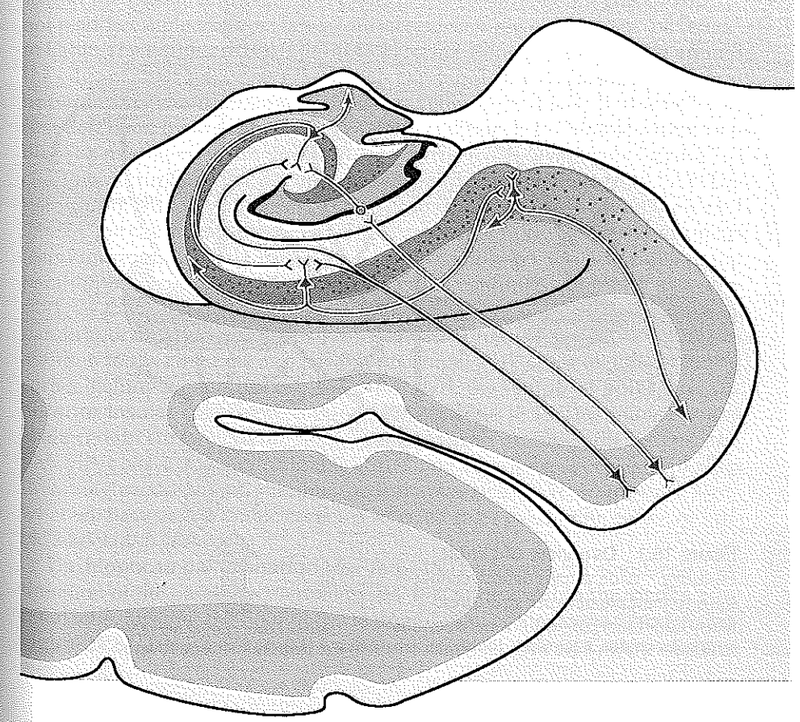

ANATOMICAL AND CLINICAL REVIEW

The limbic system includes diverse cortical and subcortical structures located mainly in the medial and ventral regions of the cerebral hemispheres. These structures are unified by their evolutionarily ancient origins, and they constitute the major portion of the forebrain in many species. Only in higher mammals has the larger neocortical mantle surpassed the limbic system in size.

The functions of the limbic system are also ancient, and they play an important role for survival in the animal kingdom. Limbic functions can be divided into the following four basic categories:

1. **Olfaction**
2. **Memory**
3. **Emotions and drives**
4. **Homeostatic functions including autonomic and neuroendocrine control**

MNEMONIC

An aid to remembering these functions is **HOME** (for Homeostasis, Olfaction, Memory, and Emotion).* Numerous limbic structures participate in each of these functions, as we will see. The various components of the limbic system (Table 18.1) form a complex network, with multiple reciprocal connections (Figure 18.1). However, simplifying somewhat, one limbic structure can be thought of as central to each of these four functions (Table 18.2): The **olfactory cortex** is essential to olfaction, the **hippocampal formation** to memory, the **amygdala** to emotions and drives, and the **hypothalamus** to homeostasis (see Chapter 17). It cannot be emphasized enough that in reality, each of these structures participates in a complex network involving numerous limbic components to carry out these functions.

*Recall that a similar mnemonic (HEAL) was used to remember hypothalamic functions in Chapter 17. Limbic system and hypothalamic functions are strongly interconnected.

TABLE 18.1 Main Components of the Limbic System

- Limbic cortex
  - Parahippocampal gyrus
  - Cingulate gyrus
  - Medial orbitofrontal cortex
  - Temporal pole
  - Anterior insula
- Hippocampal formation
  - Dentate gyrus
  - Hippocampus
  - Subiculum
- Amygdala
- Olfactory cortex
- Diencephalon
  - Hypothalamus
  - Thalamus
    - Anterior nucleus
    - Mediodorsal nucleus
    - Internal medullary lamina
  - Habenula
- Basal ganglia
  - Ventral striatum
    - Nucleus accumbens
    - Ventral caudate and putamen
  - Ventral pallidum
- Basal forebrain
- Septal nuclei
- Brainstem

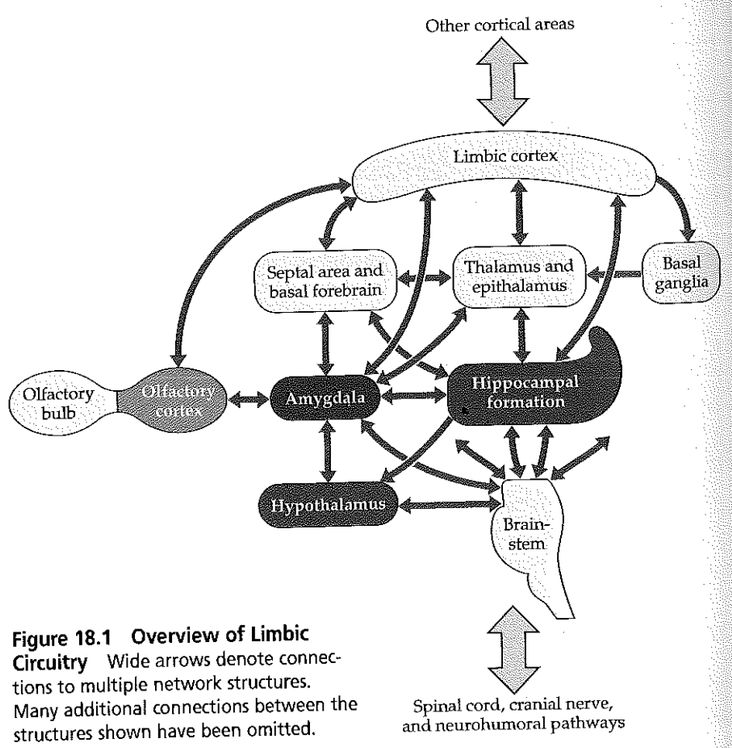

Figure 18.1 Overview of Limbic Circuitry Wide arrows denote connections to multiple network structures. Many additional connections between the structures shown have been omitted.

TABLE 18.2 Simplification of Limbic Functions and Corresponding Key Structures

LIMBIC FUNCTION	KEY STRUCTURE
Olfaction	Olfactory cortex
Memory	Hippocampal formation
Emotions and drives	Amygdala
Homeostasis; autonomic and neuroendocrine control	Hypothalamus

In this chapter we will first review the overall structure of the limbic system and briefly discuss each of its main components. Then we will discuss specific subsystems responsible for the four major categories of limbic function (see Table 18.2). Finally, we will review important clinical disorders of the limbic system, including memory loss and epileptic seizures.

Overview of Limbic Structures

The **limbic system** includes a variety of structures extending from the forebrain to the brainstem (see Table 18.1). Most of these structures lie hidden within the medial and ventral regions of the cerebral hemispheres and are not readily visible from the lateral surface. *Limbus* means "border" or "edge" in Latin. The **limbic cortex** (Figure 18.2) forms a ringlike **limbic lobe** around the edge of the cortical mantle, which surrounds the corpus callosum and upper brainstem–diencephalic junction. This "grand lobe limbique" was first described by Broca in 1878. The main components of limbic cortex visible on a medial view are the **cingulate gyrus** (*cingulum* means "girdle" or "belt" in Latin) and the **parahippocampal gyrus** (see Figure 18.2A). The parahippocampal gyrus is separated from the remainder of the temporal lobe by the **collateral sulcus,** which continues anteriorly as the **rhinal sulcus** (see Figure 18.2B). The **uncus** is a bump visible on the anterior medial parahippocampal gyrus. The cingulate gyrus continues anteriorly and inferiorly as the subcallosal and paraterminal gyri. The cingulate gyrus joins the parahippocampapal gyrus posteriorly at the isthmus (see Figure 18.2A). In addition to the cingulate and parahippocampal gyri, other regions of limbic cortex include the **medial orbitofrontal gyri,** the **temporal poles,** and the **anterior insular cortex** (see Figure 18.2A,C; Table 18.1). The limbic cortices share certain surface immunological markers. For example, the herpes simplex virus has a tropism for limbic cortex and can cause severe encephalitis involving predominantly limbic cortical areas (Figure 18.3). In some texts, what we have called limbic cortex is referred to as paralimbic cortex or limbic association cortex.

The **hippocampal formation** (see Table 18.1) is the medial and dorsal continuation of the parahippocampal gyrus. It is buried within the medial temporal lobe, forming the floor of the temporal horn of the lateral ventricle (see Figure 18.8). The hippocampal formation is one of several C-shaped struc-

REVIEW EXERCISE

What are the five regions where limbic cortex is found?

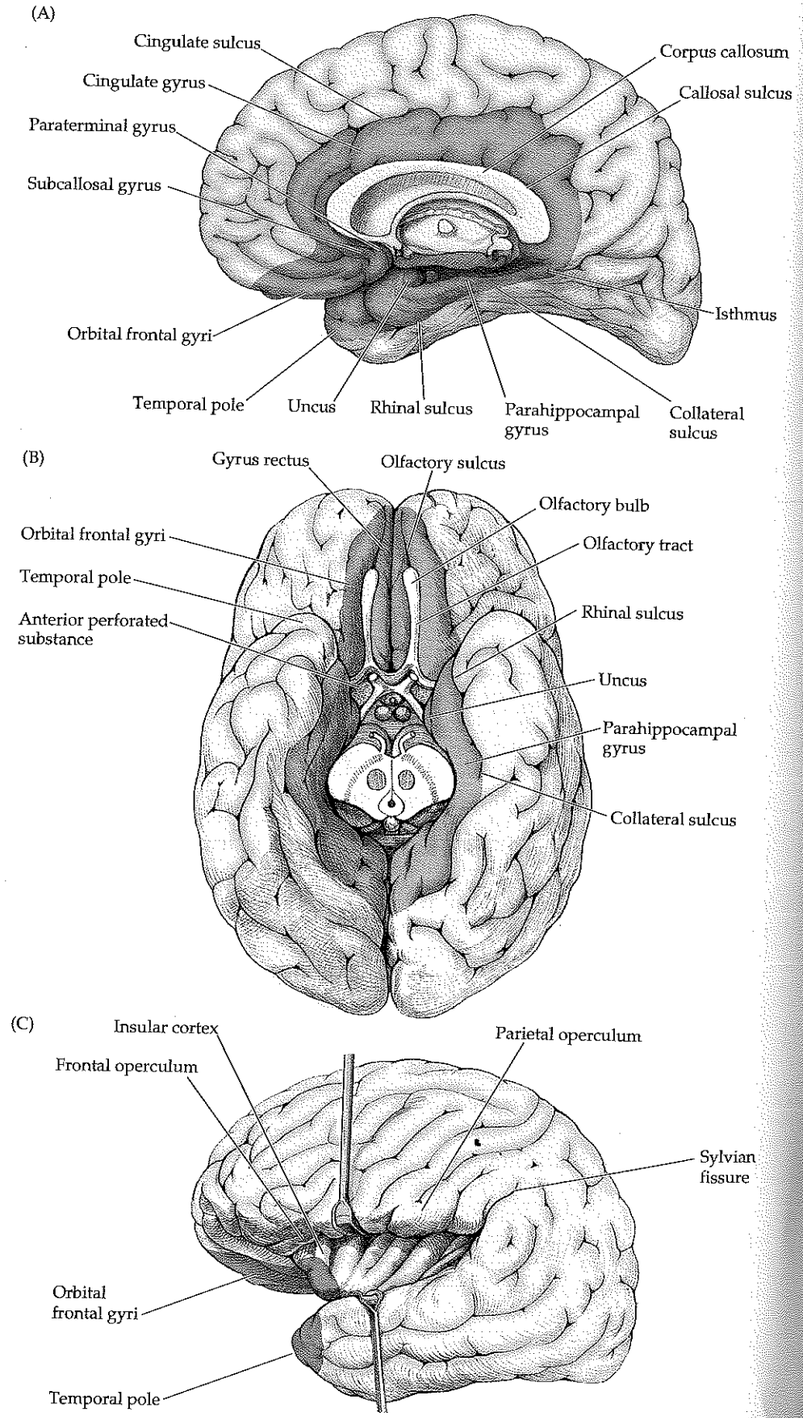

Figure 18.2 Limbic Cortex Blue regions represent limbic cortex, also known as paralimbic cortex, or limbic association cortex.

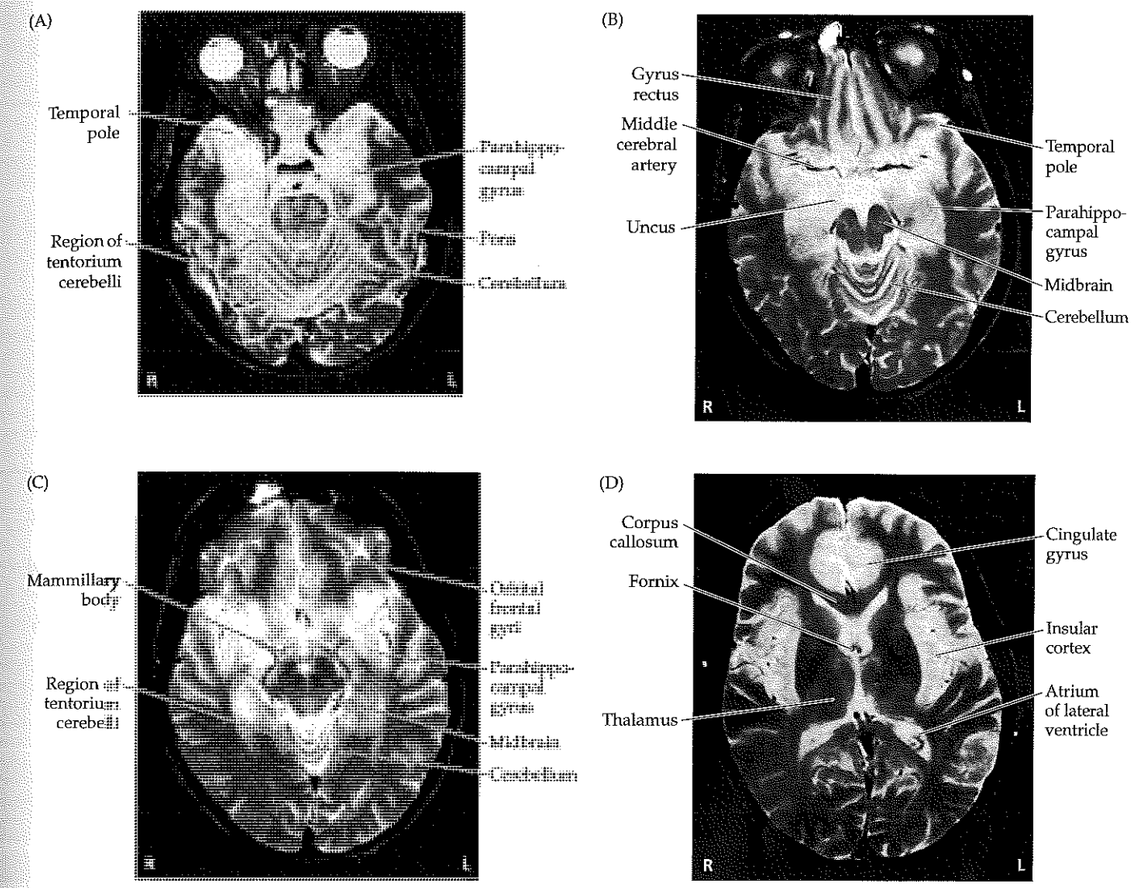

Figure 18.3 Herpes Encephalitis Affecting the Limbic Cortex Bilaterally Axial T2-weighted MRI images from a patient with herpes encephalitis. Slices A–D progress from inferior to superior.

tures in the limbic system. As we will discuss shortly, the hippocampal formation plays an important role in the memory functions of the limbic system.

Unlike the six-layered neocortex, the hippocampal formation has only three layers and is called archicortex. About 95% of the cortex in humans is six-layered **neocortex** (meaning "new cortex," also called isocortex, meaning "same cortex") (Table 18.3). The different types of neocortex will be discussed in Chapter 19 (see Table 19.1). More phylogenetically ancient forms of cortex, which do not have six distinct layers, are referred to as **allocortex** (meaning "other cortex"). Allocortex includes the three-layered **archicortex** (meaning "first" or "original cortex") of the hippocampal formation, as well as **paleocortex** (meaning "old cortex"), which is found predominantly in the piriform cortex of the **olfactory area** (see Figure 18.6). Olfactory pathways will be discussed in the next section. The regions between three- and six-layered cortex form **transitional cortex,** or **mesocortex** (meaning "middle cortex"), which is found, for example, in the limbic cortex of the parahippocampal gyrus and anterior inferior insula (see Figure 18.2). Some authors classify portions of the transitional cortex as paleocortex rather than as mesocortex. The term **corticoid areas** (see Table 18.3) is used for regions of the simple cortex that overlie or merge with subcortical nulcei such as the amygdala, substantia innominata,

REVIEW EXERCISE

Cover the right two columns in Table 18.3. Describe and provide an example of each type of cortex.

TABLE 18.3 Terminology for Classifying Cerebral Cortex

NAME	EQUIVALENT NAME(S)	DESCRIPTION	EXAMPLE(S)
Neocortex[a]	Isocortex, neopallium	Six-layered cortex	Majority of the cerebral cortex
Mesocortex	Limbic cortex, paralimbic cortex, transitional cortex	Forms gradual transition between three- and six-layered cortex	Parahippocampal gyrus, cingulate gyrus, anterior insula, orbitofrontal cortex, temporal pole
Allocortex	—	Cortex with fewer than six layers	Archicortex, paleocortex
Archicortex	Archipallium	Three-layered hippocampal cortex	Hippocampal formation
Paleocortex	Paleopallium	Three-layered olfactory cortex	Piriform cortex
Corticoid areas	—	Simple cortex that merges with subcortical nuclei	Amygdala, substantia innominata, septal region

[a]See Table 19.1 for additional details.

and septal region. In fish and amphibians, the archicortex, paleocortex, and corticoid areas form the major portion of the cerebral hemispheres; only in mammals does the neocortex predominate.

The **amygdala** is a nuclear complex that lies in the anteromedial temporal lobe. It overlaps the anterior end of the hippocampus and lies dorsal to the tip of the temporal horn of the lateral ventricle (Figure 18.4B,C; see also Fig-

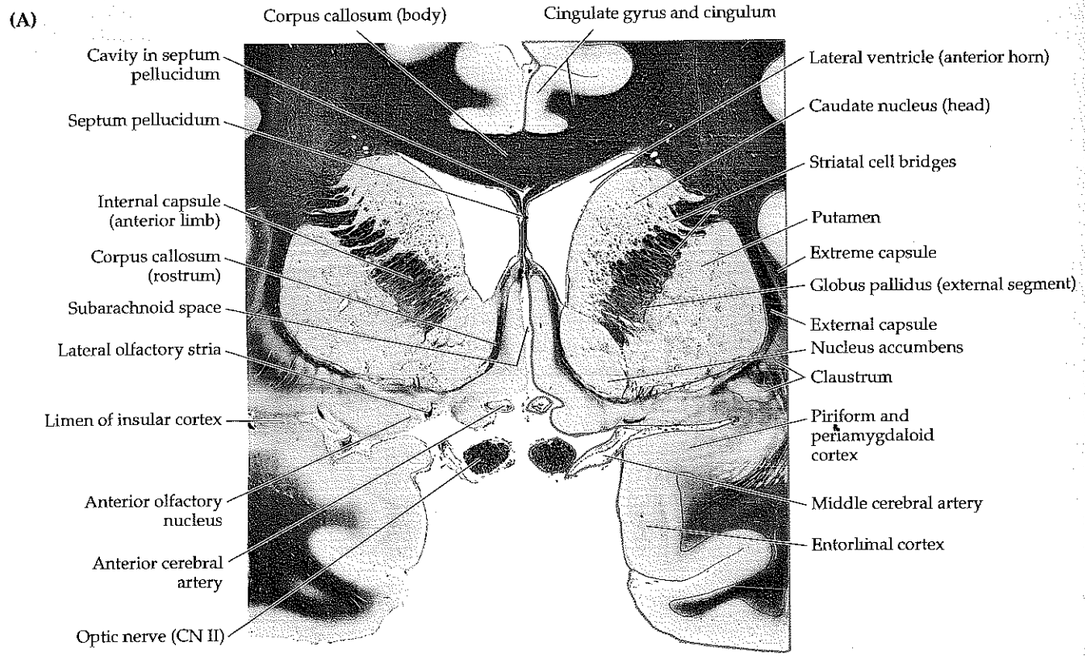

Figure 18.4 Coronal Brain Sections through Basal Forebrain and Septal Region
Myelin is stained dark. (A–C) progress from anterior to posterior. (From Martin JH. 1996. *Neuroanatomy: Text and Atlas,* 2nd Ed. McGraw-Hill, New York.)

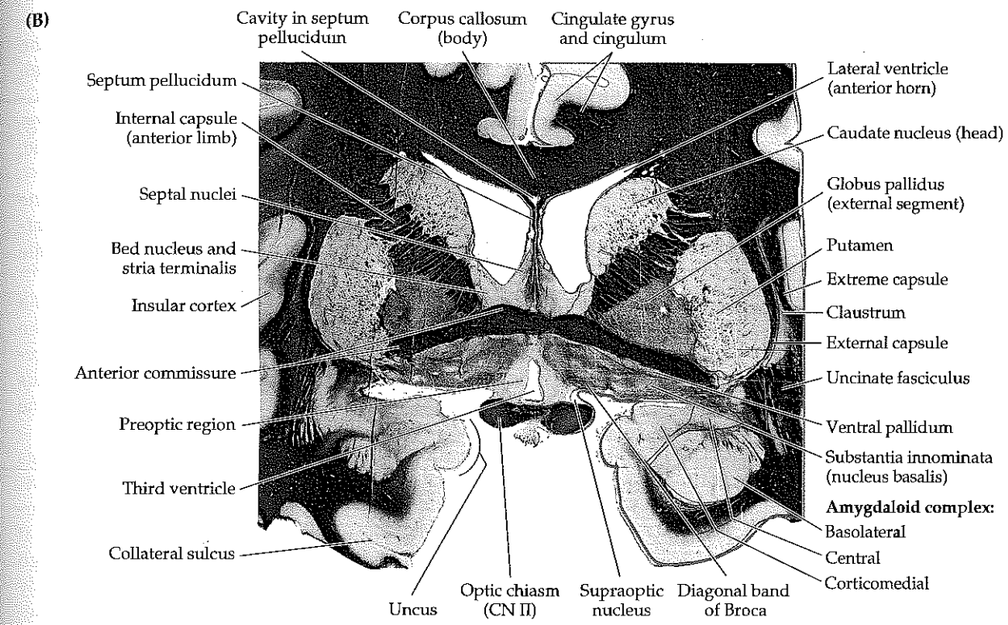

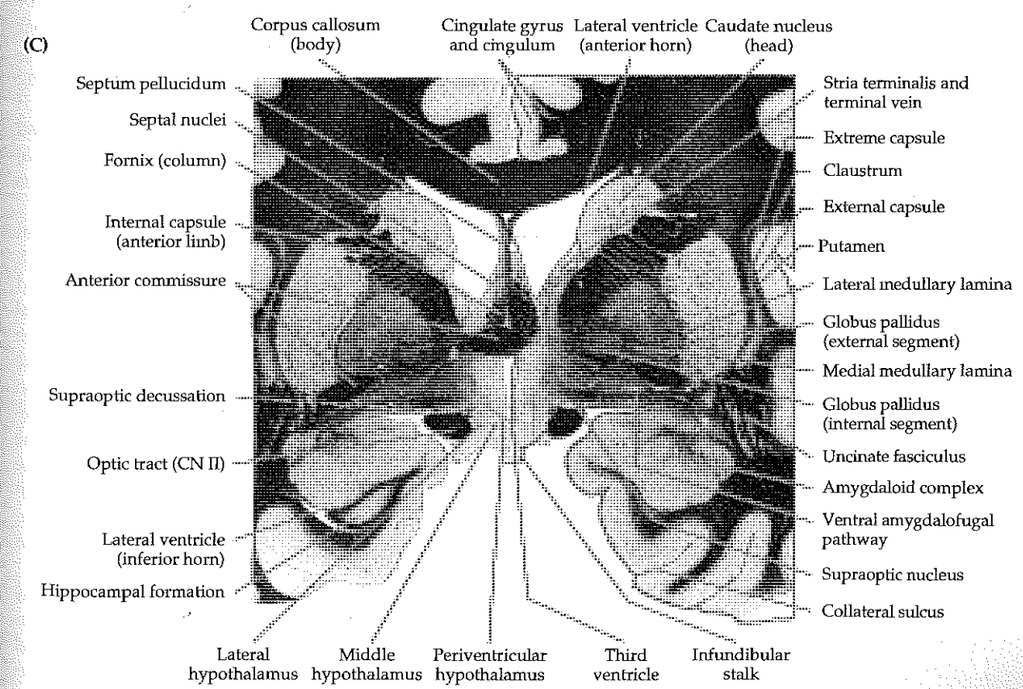

ure 18.10). The posterior amygdala and anterior hippocampus lie just underneath the **uncus,** a bump visible on the medial surface of the temporal lobe (see Figures 18.2, 18.4B). The amygdala is composed of three main nuclei: the **corticomedial, basolateral,** and **central nuclei.** In addition, the C-shaped **bed nucleus of the stria terminalis** is considered part of the amygdala. The amygdala serves important functions in emotional, autonomic, and neuroendocrine circuits of the limbic system.

Diencephalic structures (see Table 18.1) participate in all functions of the limbic system. These structures include the **hypothalamus,** the **mediodorsal nucleus** of the thalamus, the **anterior nucleus** of the thalamus, and the **habenula.**

As we discussed in Chapter 16, the ventral portions of the **basal ganglia** process limbic information. Limbic inputs to the basal ganglia arrive at the **ventral striatum** and **nucleus accumbens** (see Figure 18.4) and are then relayed via the **ventral pallidum** to the **mediodorsal nucleus** of the thalamus (see Figure 16.4D). The mediodorsal nucleus of the thalamus projects to the orbitofrontal and anterior cingulate limbic cortices (see Figure 16.8).

The basal forebrain and septal region are contiguous and are sometimes lumped together in one category, but we will discuss them separately here. The **basal forebrain** includes several structures that participate in limbic circuits. These structures lie just anterior and lateral to the hypothalamus, at the base of the frontal lobes near the midline (see Figure 18.4A,B). Although these structures are on surface of the forebrain, they are more histologically like gray matter nuclei than like cortex. Therefore, like the amygdala, the nuclei of the basal forebrain and septal region are **corticoid** structures. The term **substantia innominata** is applied variably to the entire basal forebrain or to a nucleus within it called the **nucleus basalis of Meynert,** which lies just ventral to the anterior commissure (see Figure 18.4B).

The nucleus basalis contains cholinergic neurons that provide the major cholinergic innervation for the entire cerebral cortex (see Figure 14.9B). Other nuclei of the basal forebrain include the **olfactory tubercle,** which lies just underneath the anterior perforated substance (see Figure 18.6), and the following nuclei, which can be identified in Figure 18.4B: the **ventral pallidum,** which participates in limbic basal ganglia circuits; the **nucleus of the diagonal band of Broca,** which also contains cholinergic neurons; and the **preoptic area,** which is the rostral extension of the hypothalamus (see Figure 17.3). Portions of the amygdala also lie close to or within the region of the basal forebrain.

The **septal region** lies just dorsal to the basal forebrain, near the septum pellucidum, and it also participates in limbic pathways (see Figure 18.4B,C). The main septal nuclei lie within and just caudal to the subcallosal and paraterminal gyri and are named the **medial septal nucleus** and the **lateral septal nucleus.** The medial septal nucleus contains cholinergic neurons (see Figure 14.9B) that project to the hippocampal formation and may play a role in modulation of memory function. Inputs from the hippocampal formation are mainly to the lateral septal nucleus, and outputs are mainly from the medial septal nucleus. The lateral septal nucleus has a large projection to the medial septal nucleus, completing this circuit. The **nucleus accumbens** (see Figure 18.4A) is sometimes included in the septal region or basal forebrain and is involved in basal ganglia–limbic circuitry, as we have already discussed. Another nearby nucleus with limbic connections is the **bed nucleus of the stria terminalis** (see Figure 18.4B).

Numerous **brainstem nuclei** have reciprocal connections with limbic pathways and are sometimes considered part of the limbic system. Examples include the interpeduncular nucleus, superior central nucleus, dorsal tegmental nucleus, ventral tegmental nucleus, parabrachial nucleus, periaqueductal gray, reticular formation, nucleus solitarius, and dorsal motor nucleus of the vagus. These nuclei may help link limbic pathways to mechanisms for autonomic and behavioral arousal.

The gray matter structures of the limbic system are interconnected by white matter pathways, some of which form prominent tracts. These pathways are summarized in Table 18.4 and will be discussed further in the sections that follow.

REVIEW EXERCISE

Cover the labels in Figures 18.2 and 18.4 and name as many structures as possible.

TABLE 18.4 Summary of Major Limbic Pathways

PATHWAY	FIBERS CARRIED[a] FROM	TO
Fornix	Subiculum	Medial and lateral mammillary nuclei; lateral septal nuclei
	Hippocampus	Lateral septal nuclei
	Hippocampal formation	Anterior thalamic nucleus
	Medial septal nucleus	Hippocampal formation
	Nucleus of the diagonal band	Hippocampal formation
Mammillothalamic tract	Medial mammillary nucleus	Anterior thalamic nucleus
Cingulum	Cingulate gyrus	Parahippocampal gyrus
Anterior commissure, anterior part	Anterior olfactory nucleus	Contralateral anterior olfactory nucleus
Anterior commissure, posterior part	Amygdala	Contralateral amygdala
	Anterior temporal cortex	Contralateral anterior temporal cortex
Medial olfactory stria	Anterior olfactory nucleus	Anterior commissure
	Anterior commissure	Anterior olfactory nucleus
Lateral olfactory stria	Olfactory bulb	Piriform cortex; periamygdaloid cortex; corticomedial amygdala
Stria terminalis	Corticomedial amygdala	Hypothalamus
	Amygdala	Septal nuclei
Uncinate fasciculus (temporal stem)	Piriform and entorhinal cortex	Orbitofrontal olfactory cortex
	Amygdala	Orbitofrontal and cingulate cortex
Inferior thalamic peduncle	Amygdala, anteromedial temporal cortex, insula	Medial diencephalon
Ventral amygdalofugal pathway	Amygdala	Hypothalamus; nucleus basalis; ventral striatum; brainstem nuclei
	Brainstem nuclei	Amygdala
Medial forebrain bundle	Amygdala, other forebrain structures	Brainstem nuclei
	Brainstem nuclei	Amygdala, other forebrain structures
Stria medullaris	Medial septal nuclei	Habenula
Habenulointerpeduncular tract (fasciculus retroflexus)	Habenula	Interpeduncular nucleus
Mammillotegmental tract	Mammillary bodies	Brainstem
Perforant pathway	Entorhinal cortex	Dentate gyrus granule cells
Alvear pathway	Entorhinal cortex	Hippocampal pyramidal cell

[a]For conciseness, many additional reciprocal connections have not been listed here.

mation and adjacent cortex of the parahippocampal gyrus; and the **medial diencephalic memory areas,** including the thalamic mediodorsal nucleus, anterior nucleus of the thalamus, internal medullary lamina, mammillary bodies, and other diencephalic nuclei lining the third ventricle. The medial temporal and medial diencephalic memory areas are interconnected both with each other and with widespread regions of cortex by a variety of pathways that we will discuss shortly. Therefore, these **white matter network connections** constitute a third component that is necessary for normal memory function. The **basal forebrain** may also play a role in memory, primarily through its widespread cholinergic projections to the cerebral cortex, including the medial temporal lobes. However, some effects of lesions in the basal forebrain may be explained by damage to nearby fibers of passage from medial temporal or diencephalic memory pathways. In the subsections that follow we will discuss the anatomy of medial temporal and medial diencephalic memory systems in more detail. We will also briefly review the cholinergic pathways of the basal forebrain and septal region.

Hippocampal Formation and Parahippocampal Gyrus

The key structures of the medial temporal lobe memory system are the **hippocampal formation** and the **parahippocampal gyrus.** The hippocampal formation has an elaborate curving S or inverted S shape on coronal sections (Figures 18.7, 18.8). This appearance inspired the names **hippocampus** (meaning "sea horse" in Greek) and **cornu Ammonis** (Latin for "horn of the ancient Egyptian ram-headed god Ammon"). The three components of the hippocampal formation are the **dentate gyrus** (named for the toothlike bumps on its medial surface; Figure 18.9), the **hippocampus,** and the **subiculum** (Latin for "support"). Sometimes the term "hippocampus" is used to

REVIEW EXERCISE

Refer to Figures 18.7 and 18.8 and name the three components of the hippocampal formation.

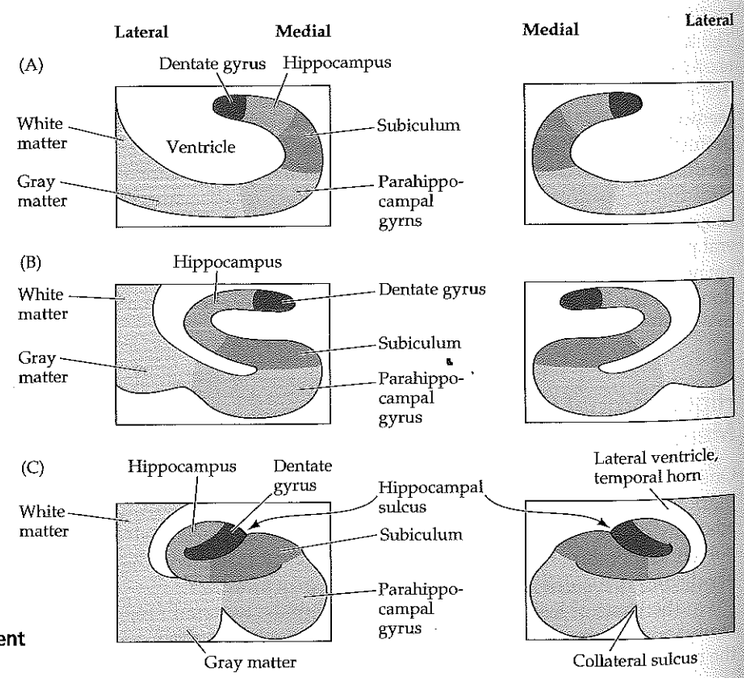

Figure 18.7 Embryological Development of the Hippocampal Formation

refer to all three components. During embryological development, the three-layered archicortex of the medial temporal lobe folds over on itself twice (see Figure 18.7). As a result of this double folding, the pial or gray matter surfaces of the dentate gyrus and subiculum fuse, and the ventricular or white matter surfaces of the subiculum and parahippocampal gyrus fuse.

The principal neurons of the dentate gyrus are called **granule cells.** The three layers of the dentate gyrus, moving inward from the pia, are the **molecular layer, granule cell layer,** and **polymorphic layer** (see Figure18.8A). Note the similarities of these names to the names for the six layers of neocortex (see Table 2.3). The principal

Figure 18.8 Hippocampal Formation
(A) Coronal section through the hippocampus and parahippocampal gyrus. Nissl stain, in which cell bodies appear dark. (B) Schematic circuit diagram showing the perforant and alvear pathway inputs to the hippocampal formation arising from the entrorhinal cortex. Intrinsic hippocampal circuitry sending major outputs back to the entorhinal cortex is also shown, as well as outputs leaving via the fornix. (A after Martin JH. 1996. *Neuroanatomy: Text and Atlas,* 2nd Ed. McGraw-Hill, New York. Histology courtesy of David Amaral, University of California, Davis.)

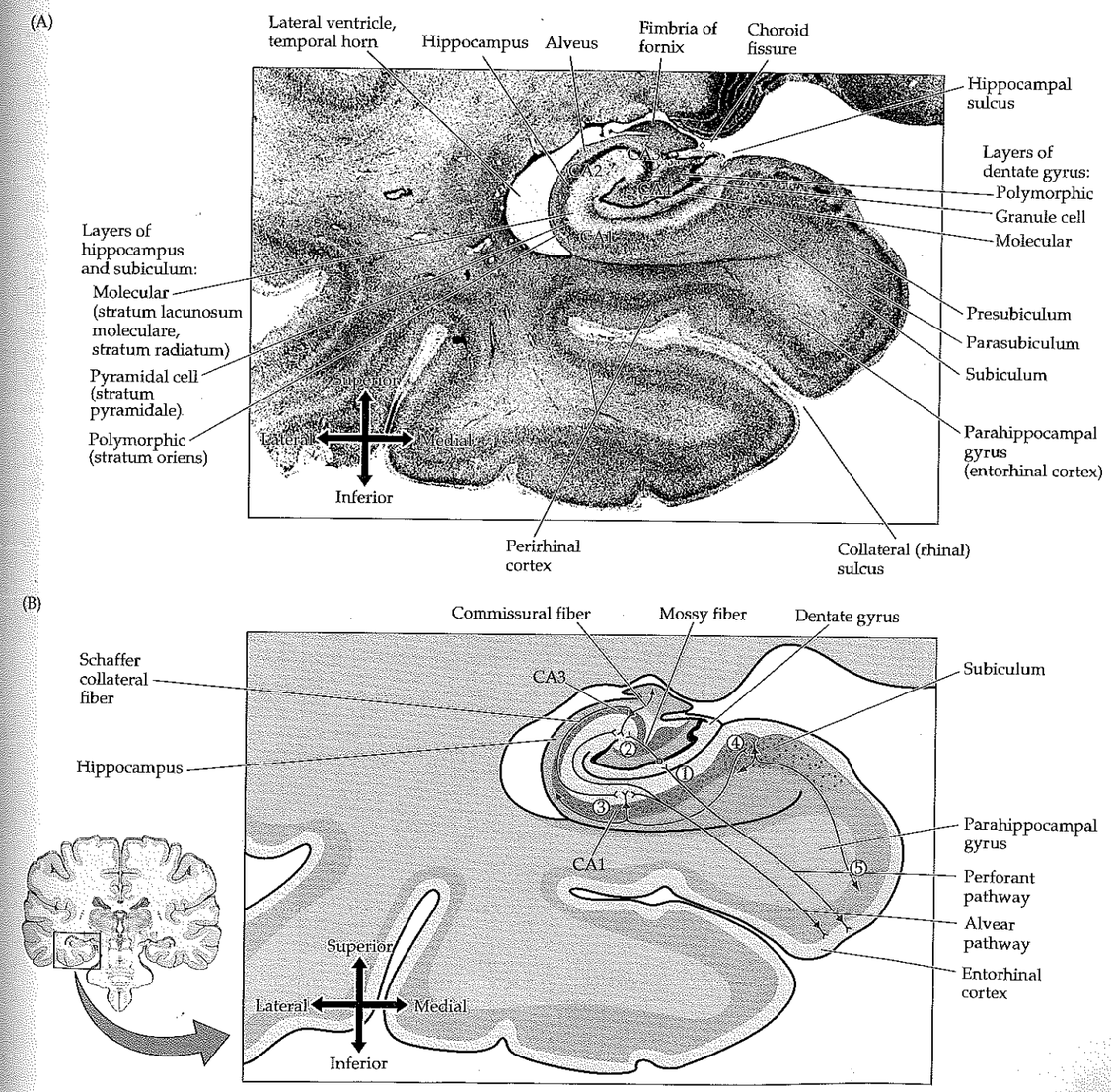

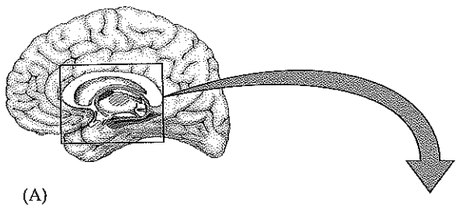

Figure 18.9 Circuit of Papez and Related Structures (A) Medial view showing the major structures participating in hippocampal circuits. (B) Although it is just one of many limbic circuits, the circuit of Papez provides a useful review of several limbic pathways.

(A)

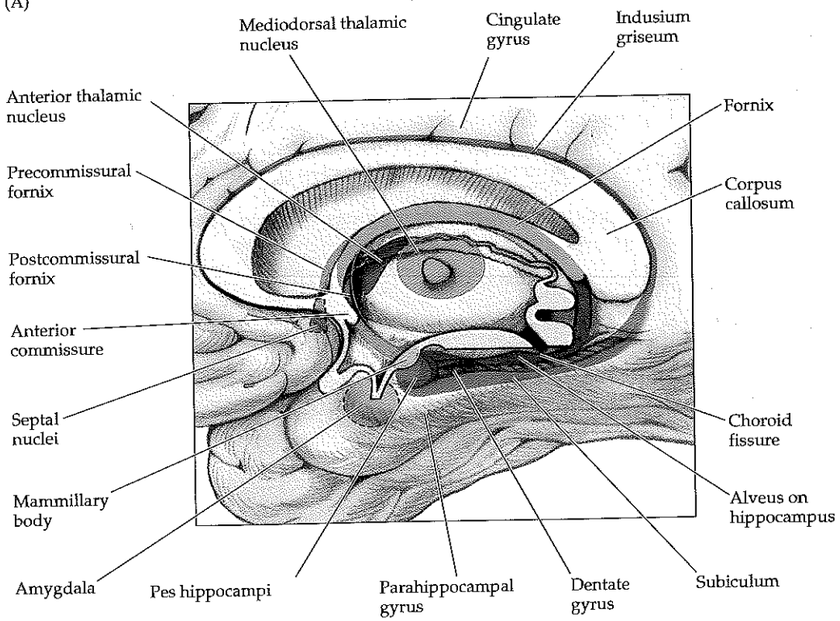

(B)

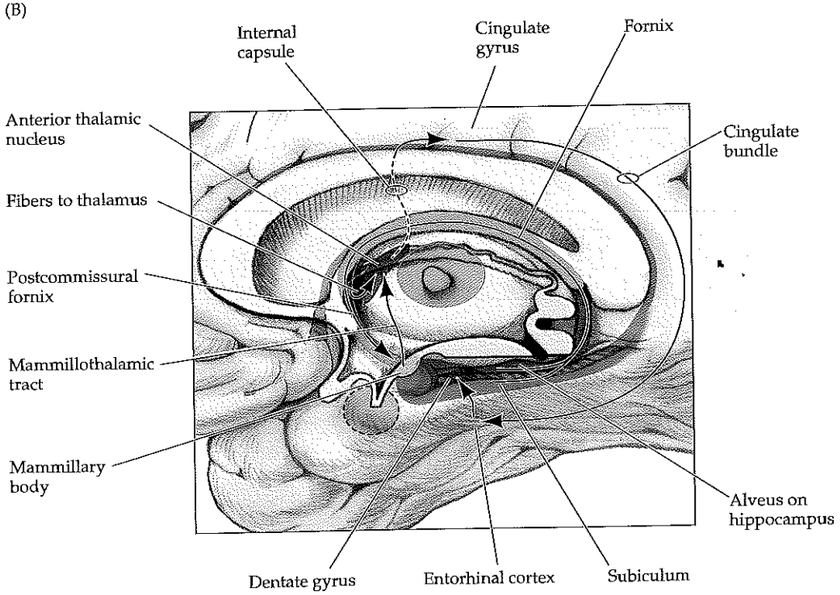

neurons of the hippocampus and subiculum are **pyramidal cells,** and the layers of these structures are the **molecular layer, pyramidal cell layer,** and **polymorphic layer** (see Figure18.8A). The molecular layers of the dentate gyrus and subiculum are apposed, forming the **hippocampal sulcus.** The groove in the medial temporal lobe just dorsal to the hippocampal formation is called the **choroid fissure** (see Figures 18.8A, 18.9). The hippocampal formation is largest anteriorly, where it forms the **pes hippocampi,** also called the **hippocampal head.** The hippocampal formation curves back along the floor of the temporal horn, tapers to a smaller **hippocampal tail,** and finally disappears as it curves under the ventral posterior edge of the splenium of the corpus callosum. A minor vestigial remnant of the hippocampal formation, called the indusium griseum, continues along the dorsal surface of the corpus callosum (see Figure 18.9). The layers of the hippocampus can also be appreciated in sagittal sections (Figure 18.10).

The **parahippocampal gyrus** includes several cortical areas with connections to the hippocampal formation, the most important of which is the **entorhinal cortex** (see Figures 18.6, 18.8, 18.9, 18.11). The entorhinal cortex (Brodmann's area 28; see Figure 2.15) lies in the anterior portions of the parahippocampal gyrus, adjacent to the subiculum, and serves as the major input and output relay between association cortex and the hippocampal formation. The posterior portion of the parahippocampal gyrus is simply called the **parahippocampal cortex** (see Figure 18.6). Laterally, the parahippocampal gyrus is delimited by the **collateral sulcus,** which continues anteriorly as the **rhinal sulcus** (see Figure 18.6). Along both medial and lateral walls of the rhinal sulcus, and continuing laterally onto the adjacent occipitotemporal gyrus, lies the **perirhinal cortex** (Brodmann's areas 35 and 36). About two-thirds of the input from association cortex reaches the entorhinal cortex via relays in the adjacent perirhinal cortex and parahippocampal cortex (Figure 18.11; see also Figure 18.6).

For the sake of completeness, we will now briefly mention the names of the other parts of the parahippocampal gyrus aside from the entorhinal and perirhinal cortex (Table 18.5). (Knowledge of these other terms has no direct

REVIEW EXERCISE

Refer to Figure 18.6 and name the region of the parahippocampal gyrus that is the most important input and output relay between the hippocampal formation and the association cortex.

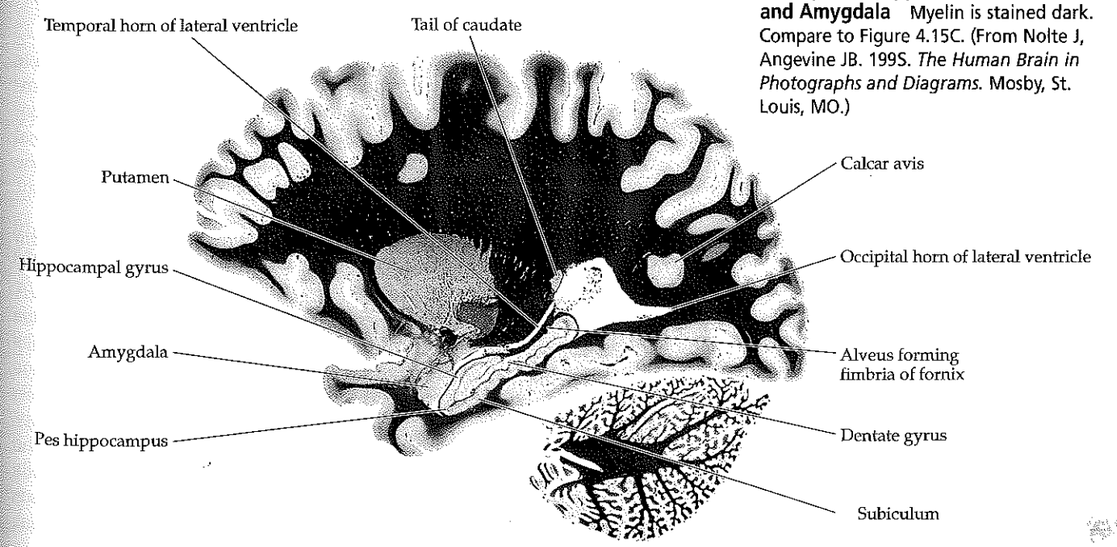

Figure 18.10 Sagittal Section through the Hippocampal Formation and Amygdala Myelin is stained dark. Compare to Figure 4.15C. (From Nolte J, Angevine JB. 1995. *The Human Brain in Photographs and Diagrams.* Mosby, St. Louis, MO.)

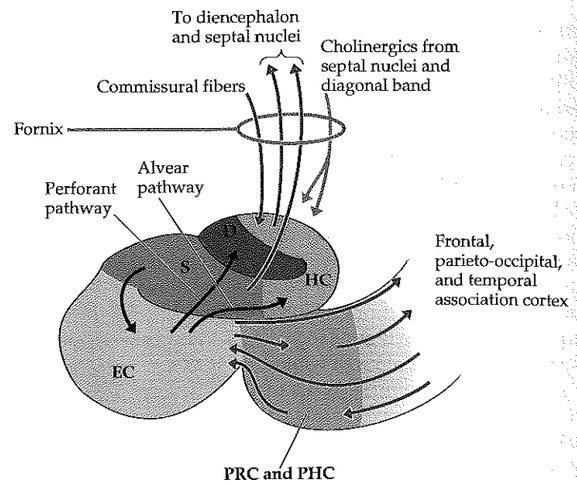

Figure 18.11 Summary of Hippocampal Input and Output Connections S = subiculum; D = dentate gyrus; HC = hippocampus; EC = entorhinal cortex.

clinical relevance.) As we discussed in the earlier section on olfaction, the small regions of olfactory cortex adjacent to the lateral olfactory stria are called piriform and periamygdaloid cortex (see Figure 18.6). Laterally, some authors distinguish a region of cortex called prorhinal cortex lying between the entorhinal and perirhinal cortex. Medially, there are transition zones between the entorhinal mesocortex (parahippocampal gyrus) and the three-layered archicortex of the subiculum (hippocampal formation). Moving from entorhinal cortex toward subiculum, one first encounters the parasubiculum, then the presubiculum, and then the subiculum (see Figure 18.8A). Finally, although this structure is not part of the parahippocampal gyrus, we will mention here that some authors also refer to an additional transition zone, called prosubiculum, lying between the subiculum and the CA1 field of the hippocampus (see the next subsection).

Intrinsic Circuitry of the Hippocampal Formation

The circuitry of the hippocampal formation has been the subject of intensive scientific investigation because of its possible important role in human memory. Figure 18.8B illustrates the major circuits for information flow from the entorhinal cortex, through the hippocampal formation, and back to the entorhinal cortex. Pyramidal cells in layers 2 and 3 of the entorhinal cortex project to the hippocampal formation via the perforant pathway and the alvear pathway. (See Figure 18.8B, Synapse 1.)

The **perforant pathway** is named for its course through the subiculum and across the hippocampal sulcus to reach the granule cell layer of the dentate gyrus. The hippocampus has different pyramidal cell sectors named CA (for cornu Ammonis) 1 through 4 (see Figure 18.8A). **CA4** lies within the hilus of the dentate gyrus. **CA3** is adjacent to CA4, **CA2** comes next, and **CA1** lies closest to the subiculum. Granule cells of the dentate gyrus give rise to axons called **mossy fibers,** which synapse on the dendrites of CA3 pyramidal cells (see Figure 18.8B, Synapse 2). The axons of CA3 pyramidal cells leave the hippocampal formation via the fornix. However, these axons also give rise to the **Schaffer collaterals,** which synapse on the dendrites of CA1 pyramidal cells (Synapse 3). Axons of CA1 pyramidal cells also leave the hippocampal formation via the fornix. In addition, CA1 pyramidal cells project to the next cellular

TABLE 18.5 Components of the Parahippocampal Gyrus

Piriform cortex
Periamygdaloid cortex
Presubicular cortex
Parasubicular cortex
Entorhinal cortex
Prorhinal cortex
Perirhinal cortex
Parahippocampal cortex

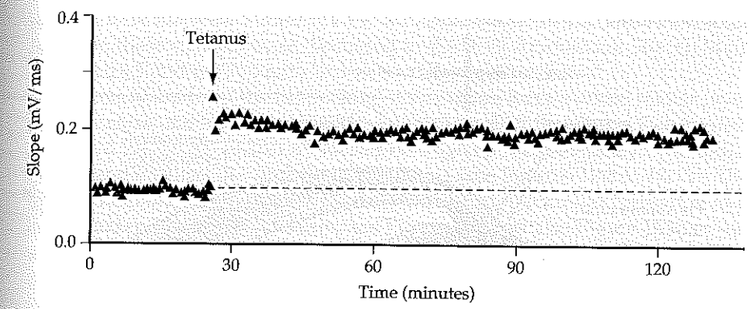

Figure 18.12 Long-Term Potentiation (LTP) in the CA1 Sector of the Hippocampus Input fibers to the CA1 pyramidal cells (see Figure 18.8) were stimulated with a test stimulus every 10 seconds, and the CA1 EPSPs were recorded extracellularly. Slope of the EPSPs (an indication of synaptic strength) is indicated on the vertical axis. At the time marked "tetanus," 2 100 Hz stimulus trains lasting 1 second each were delivered at twice the usual stimulus intensity. Following this strong stimulus, a sustained increase in the EPSP slope is evident, lasting several hours. (From Nicoll RA, Kauer JA, and Malenka RC. 1988. The current excitement in long-term potentiation. *Neuron* 1: 97–103.)

relay, which lies in the subiculum (Synapse 4). Finally, pyramidal cells of the subiculum project both into the fornix and back to neurons in the deeper layers of the entorhinal cortex, completing the loop (Synapse 5).

In addition to the perforant pathway, neurons of the entorhinal cortex project via the **alvear pathway** directly to CA1 and CA3 (see Figures 18.8B, 18.11). As in the perforant pathway, outputs in the alvear pathway are primarily from CA1 and CA3 to the subiculum.

An interesting form of synaptic plasticity called **long-term potentiation (LTP)** has been found in the perforant pathway–granule cell, mossy fiber–CA3, and Schaffer collateral–CA1 connections (Figure 18.12). High-frequency activity at any of these synapses causes a long-lasting increase in synaptic strength between the involved neurons. In particular, the perforant pathway–granule cell and Schaffer collateral–CA1 (but not mossy fiber–CA3) synapses require simultaneous pre- and postsynaptic activity for LTP to be elicited. This interesting property may allow these synapses to perform an **associative function,** similar to the learning rule proposed by the psychologist Donald Hebb in the 1940s. The **Hebb rule** states, "When an axon of cell A . . . excite(s) cell B and repeatedly or persistently takes part in firing it, some growth process or metabolic change takes place in one or both cells so that A's efficiency as one of the cells firing B is increased."

Since its initial discovery, LTP has also been demonstrated at synapses in several other areas of the nervous system. In addition, numerous other forms of excitatory and inhibitory, short-term and long-term synaptic modulation have been described. The cellular mechanisms underlying LTP and other types of synaptic plasticity are currently an important and very active area for further investigation and are thought to play an important role in memory formation.

REVIEW EXERCISE

List each of the five synapses forming the circuit from entorhinal cortex via the perforant pathway to the hippocampal formation and back to the entorhinal cortex (see Figure 18.8B).

Input and Output Connections of the Medial Temporal Lobe Memory System

The **main input** to the hippocampal formation arrives at the **entorhinal cortex** from association cortex in the frontal, parieto-occipital, and temporal lobes (see Figure 18.11). Much of this information is relayed in the adjacent perirhinal cortex and parahippocampal cortex before reaching the entorhinal cortex. These inputs are thought to contain higher-order information from multiple sensorimotor modalities that is processed further by the medial temporal structures for memory storage. The storage process itself is believed to occur not in the medial temporal structures, but back in the association and primary cortices that allow a particular memory to be reactivated. An **important output** pathway of the hippocampal formation is therefore

Figure 18.13 Three-Dimensional Structure of the Fornix and Anterior Commissure

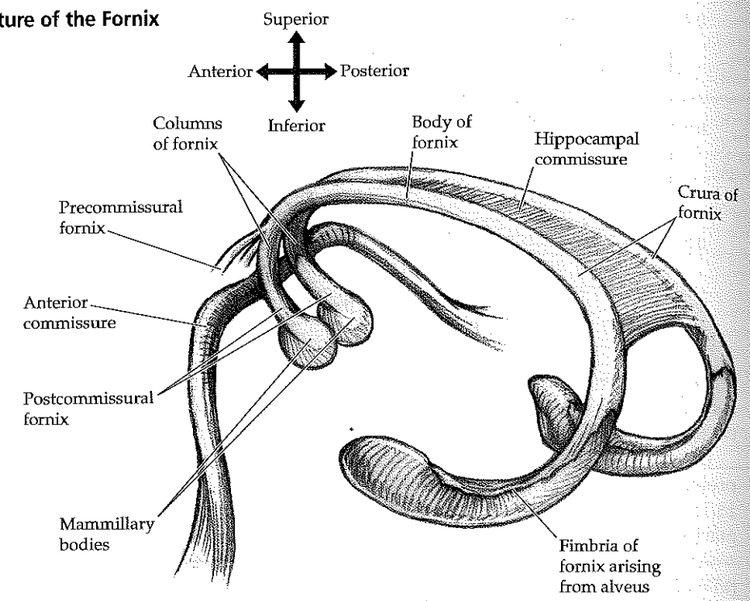

the projection from the **subiculum to the entorhinal cortex,** and from there back to multimodal association cortex (see Figure 18.11). The mechanisms by which medial temporal structures induce storage, consolidation, and retrieval of memories in the association cortex are not currently known.

An additional major output pathway of the hippocampal formation is the **fornix,** which carries outputs to the diencephalon and septal nuclei (Figure 18.13; see also Figure 18.11). These pathways will be discussed in greater detail in the next subsection. Note that the **subiculum** is the main source of output fibers from the hippocampal formation to the fornix, as well as to the entorhinal cortex. The subiculum is thus an important structure in hippocampal outputs.

Some inputs reach the hippocampus from the contralateral hippocampus through the **hippocampal commissure** (see Figures 18.11, 18.13). Finally, the hippocampal formation receives important modulatory inputs via the fornix arising from **cholinergic neurons** in the medial septal nucleus and the nucleus of the diagonal band. The entorhinal cortex and the remainder of the cerebral cortex also receive cholinergic inputs, which arise primarily from the nucleus basalis of Meynert (see Figure 18.4B). These cholinergic pathways activate muscarinic receptors and may be important in modulating neuronal excitability and synaptic plasticity. Additional modulatory influences also reach the medial temporal lobes from noradrenergic, dopaminergic, and serotonergic nuclei in the brainstem (see Chapter 14).

The Fornix and Medial Diencephalic Memory Pathways

Fornix means "arch" in Latin, which is an appropriate name for this white matter structure that curves through the ventricular system from the hippocampal formation to the diencephalon and septal area (see Figure 18.13). As we discussed in Chapter 5, there are several C-shaped structures that follow the curve of the lateral ventricles, including the fornix, corpus callosum, and caudate nucleus. Please review the three-dimensional relations of the fornix to these structures, as discussed in the Brief Anatomical Study Guide in Chapter 5 and in "A Scuba Expedition through the Brain."

Output fibers from the hippocampal formation form a white matter layer on the ventricular surface of the hippocampus called the **alveus** (see Figures 18.8A, 18.9A, 18.10, 18.13). As these fibers sweep medially, they form a discrete bundle called the **fimbria** of the fornix (see Figures 18.8A, 18.13). The **crura** (meaning "legs") of the fornix leave the hippocampal formation and curve under the corpus callosum (see Figure 18.9; see also Figure 16.3) to run adjacent to each other in the midline, at which point their name changes to the **body** of the fornix (see Figure18.13; see also Figure 16.4D). Between the crura of the fornix, on the undersurface of the corpus callosum, the **hippocampal commissure** provides a route for fibers arising from one hippocampus to reach the contralateral side. The body of the fornix curves anteriorly and downward to form the **columns** of the fornix (see Figures 18.4C, 18.9, 18.13; see also Figure 16.3).

Axons traveling forward in the fornix have three main targets. The majority of the fibers arise from the **subiculum** and descend behind the anterior commissure in the **postcommissural fornix** to reach the **medial and lateral mammillary nuclei** of the hypothalamus (see Figures 18.9, 18.13). A smaller contingent of fibers, arising from both the **subiculum and hippocampus,** pass anterior to the anterior commissure in the **precommissural fornix** to reach the **lateral septal nucleus.** Finally, some fibers leave the fornix to terminate in the **anterior thalamic nucleus** (see Figure 18.9).

As has already been mentioned, some fibers travel back in the fornix, predominantly from cholinergic neurons in the **medial septal nuclei** and diagonal bard of Broca, to reach the hippocampal formation (see Figure 18.11). This pathway can be influenced by projections from the hippocampal formation forward to the lateral septal nuclei because the lateral septal nuclei project strongly to the medial septal nuclei. These cholinergic projections, along with inhibitory GABAergic projections that also travel in the fornix from the septal nuclei to the hippocampal formation, may play an important modulatory role in memory function.

In 1937 the anatomist James Papez described a circuit involving several limbic structures, thereby stimulating the development of the concept of the limbic system in the 1950s. Although the structures in this circuit have subsequently been shown to have many other important connections as well, the **Papez circuit** remains a useful heuristic device for reviewing some of the major limbic pathways (see Figure 18.9B). The Papez circuit begins with fibers arising from the subiculum of the **hippocampal formation,** which enter the fornix and travel forward to both the medial and the lateral mammillary nuclei. The **medial mammillary nucleus** then projects through the **mammillothalamic tract** to the **anterior thalamic nucleus** (see Figure 16.4D). Recall that the anterior thalamic nucleus also receives a direct projection from the fornix (see Figure 18.9B). The anterior thalamic nucleus next projects through the **internal capsule** to the **cingulate gyrus.** Finally, a prominent white matter pathway underlying the cingulate gyrus called the **cingulate bundle** or **cingulum** passes from the cingulate cortex to the **parahippocampal gyrus,** from which projections continue to the **entorhinal cortex** and hippocampal formation, completing the loop.

In summary, the **medial temporal lobe memory systems** communicate with the association cortex mainly through bidirectional connections via the entorhinal cortex (see Figure 18.11). The **medial diencephalic memory systems** communicate with the medial temporal memory systems through several pathways. The fornix connects the hippocampal formation with the

REVIEW EXERCISE

Using Figure 18.13 as a guide, study the axial, coronal, and sagittal MRI scan images in Figures 4.13F–H, 4.14A–C, and 4.15A, and review the three-dimensional course of the fornix. Identify the crura (see Figures 4.13G, 4.14A), body (see Figures 4.13H, 4.14B, 4.15A), and columns (see Figures 4.13G, 4.14C), and review the relationships of the fornix to the hippocampus, lateral ventricle, third ventricle, corpus callosum, septum pellucidum, foramen of Monro, anterior commissure, and mammillary bodies.

REVIEW EXERCISE

Review the major hippocampal input and output connections using Figure 18.11 and referring to Figures 18.6, 18.8, and 18.9.

mammillary bodies and septal nuclei, as well as with the anterior thalamic nuclei, both directly and indirectly, through the mammillothalamic tract. Other medial diencephalic structures implicated in memory function include the **mediodorsal nucleus** of the thalamus, the internal medullary lamina, and the midline thalamic nuclei (see Figure 7.6). These medial diencephalic nuclei are connected to the limbic structures of the medial temporal lobe and insula via fibers of the inferior thalamic peduncle (see Table 18.4) traveling near the auditory radiation (see Figure 6.9B). The functional roles of individual medial diencephalic nuclei and their relative importance in memory are still under investigation.

KEY CLINICAL CONCEPT
MEMORY DISORDERS

184 In this section we will discuss memory disorders, beginning with a specific, well known case of amnesia. This case will be used to illustrate the different kinds of memory loss that can occur, before we discuss the differential diagnosis of memory loss.

Patient H.M.: A Landmark Case of Amnesia

In 1953 a 27-year-old man with the initials H.M. underwent an operation in which the *bilateral* medial temporal lobes, including the hippocampal formations and parahippocampal gyri, were resected in an attempt to control his medically refractory epileptic seizures (Figure 18.14). Following the surgery, his seizures improved, but he had severe memory problems, with no other significant deficits. He was unable to learn new facts or recall new experiences. For example, when given a list of three or four words to remember, he was able to correctly recite them back immediately. Within 5 minutes, however, he had no recall of any of the words, even with hints, and he did not even remember being given the list to remember in the first place. In contrast, his memory of remote events from his childhood and up to several years before the surgery was intact; however, he had no recall of events from that point on. Despite his profound memory deficit, H.M.'s personality and general intelligence assessed by IQ testing were normal. In addition, he retained the ability to learn certain tasks that did not require conscious recall. For example, his performance on a mirror drawing task improved on successive days similarly to normal controls, despite his having no recollection of doing the task the previous day. Similarly, when primed by exposure to a word such as "DEFINE" and then asked to complete the stem "DEF-," he chose the word he had seen previously at higher than chance levels, despite having no conscious recall of having seen the word before.

The selective yet devastating and permanent effects of this operation on H.M.'s memory led to intensive investigations of the medial temporal lobes' role in human memory. H.M. continues to participate in these tests today. Patients today with medically refractory temporal lobe epilepsy can often be cured with *unilateral* medial temporal lobe resection (see KCC 18.2); after the unfortunate experience with patient H.M., bilateral medial temporal lobe resection is no longer performed.

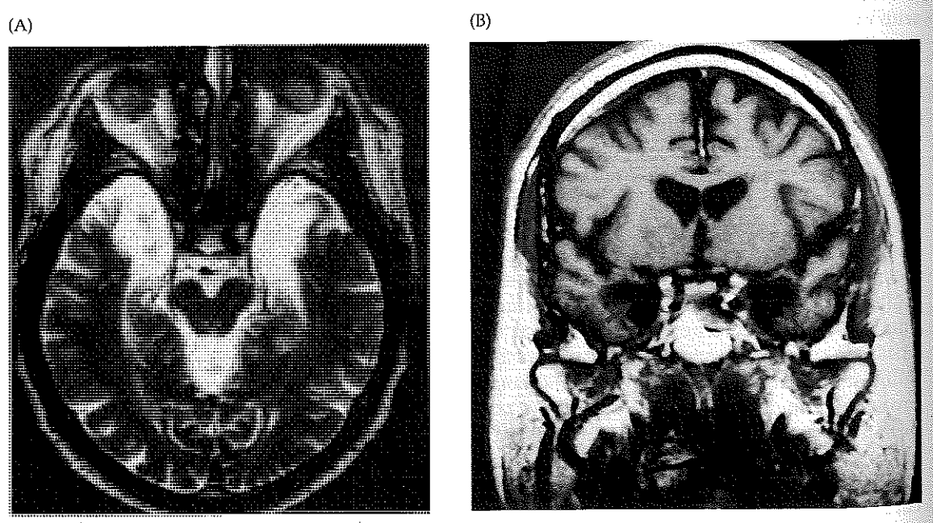

Figure 18.14 MRI from Patient H.M. This patient underwent bilateral resection of the medial temporal lobe structures. (A) Axial T2-weighted MRI image. (B) Coronal T1-weighted image. Regions of resection are indicated by arrows. (From Corkin S, Amaral DG, Gonzalez RG, Johnson KA, Hyman BT. 1997. H.M.'s medial temporal lesion: findings from magnetic resonance imaging. *J Neurosci* 17 (10): 3964–3979.)

Lessons Learned from H.M.: Classification of Memory and Memory Disorders

On the basis of studies of patient H.M. and numerous other studies of patients and experimental animals in subsequent years, several types of memory and memory disorders have been defined. Although many of these distinctions did not emerge until years after the original studies on H.M., we will review the case of patient H.M. to help illustrate and understand some of these distinctions.

Declarative versus Nondeclarative Memory. One major distinction is between **declarative** (or **explicit**) **memory,** which involves conscious recollection of facts or experiences, and **nondeclarative** (or **implicit**) **memory,** which involves nonconscious learning of skills, habits, and other acquired behaviors (Figure 18.15). H.M. was severely impaired in his ability to recollect new facts or experiences; however, his behavior could be modified by previous experiences in a nonconscious manner. Thus, H.M. suffered a loss of declarative memory, while his nondeclarative memory remained intact. The term **amnesia** is typically used for declarative memory loss. This form of selective loss of **declarative memory** is typical of **bilateral medial temporal lobe** or **bilateral medial diencephalic** lesions. Unilateral lesions do not usually produce severe memory loss. However, unilateral lesions of the dominant (usually

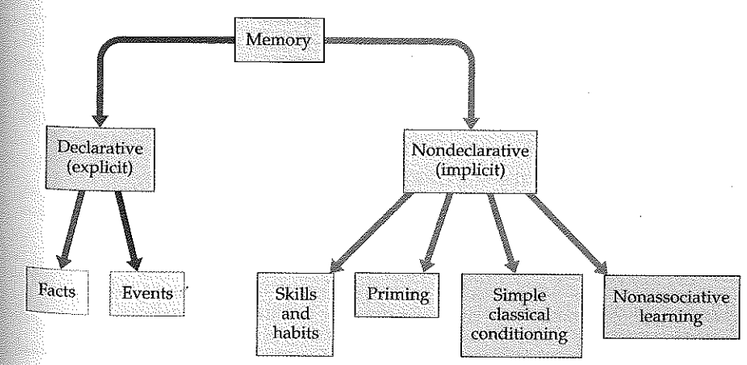

Figure 18.15 Classification of Memory (After Squire LR, and Zola-Morgan S, The medial temporal lobe memory system. *Science* 253: 1380–1385, 1991.)

left) medial temporal or diencephalic structures can cause some deficits in **verbal memory,** while unilateral lesions of the nondominant (usually right) hemisphere can cause deficits in **visual-spatial memory.**

Unlike declarative memory, specific lesions do not usually result in clinically significant selective loss of nondeclarative memory (see Figure 18.15). Learning of **skills,** such as mirror drawing by H.M., and of **habits** most likely involves plasticity in several areas, including the basal ganglia, cerebellum, and motor cortex. The caudate nucleus appears to be particularly important in habit learning, and interestingly, pathology in this region may be linked to obsessive-compulsive disorder (KCC 18.3). **Priming,** as exhibited by H.M. in the word stem completion task, depends on several cortical areas. Simple associative learning such as **classical conditioning,** and nonassociative learning such as **habituation** and **sensitization,** have been studied extensively in animals and appear to involve a variety of structures, including the cerebellum (in classical conditioning), amygdala (in conditioned fear), cerebral cortex, brainstem nuclei, and even spinal cord.

Temporal Aspects of Memory and Memory Loss. Although H.M. was able to repeat a short list of words immediately after hearing them, within 5 minutes he could not recall any of the words. How are memories converted from short-term to long-term storage? At least two classes of mechanisms appear to be involved (Table 18.6). First of all, a variety of different cellular mechanisms store information in the nervous system on different time scales (see Table 18.6A). Secondly, different anatomical regions of the brain are important for storing memories at different times. The brain regions thought to be involved in declarative memory at different times are listed in Table 18.6B.

When examining patients at the bedside, practitioners perform tests of **immediate recall, attention,** and **working memory** often by asking the patient to repeat back lists of digits or words forward and backward (see neuroexam.com Video 4). These functions, which operate on the time scale of less than 1 or 2 minutes, must be intact in order for information to be encoded successfully in declarative memory. However, these functions do not depend on the medial temporal or medial diencephalic memory systems (see Table 18.6B). As we will discuss in Chapter 19, alertness and attention are mediated by an interaction of brainstem–diencephalic and frontoparietal networks, acting on the specific regions of cortex involved in portraying a particular concept in conscious awareness. In addition, **working memory** involves holding a particular concept briefly in awareness while a mental operation, such as the carrying function in arithmetic, is performed. Working memory requires the participation of dorsolateral prefrontal association cortex (see Chapter 19). After testing attention and confirming the patient's ability to register new information, **recent memory** should be tested by giving the patient several words to remember and then testing for recall of these words 4 to 5 minutes later (see neuroexam.com Video 6). **Remote memory** should then also be tested by asking the patient about either verifiable personal information such as previous addresses or schools, and about well known current events (see neuroexam.com Video 7). In addition to these simple bedside tests, more precise and quantitative neuropsychology testing can often be useful in evaluating memory dysfunction (see also KCC 19.16).

TABLE 18.6 Memory Mechanisms in the Time Domain and in the Spatial Domain

A. CELLULAR MECHANISMS INVOLVED AT DIFFERENT TIMES IN MEMORY STORAGE

SECONDS TO MINUTES	MINUTES TO HOURS	HOURS TO YEARS
Ongoing electrical activity of neurons; changes in intracellular Ca^{2+} and other ions; changes in second messenger systems	Protein phosphorylation and other covalent modifications; expression of immediate early genes	Additional changes in gene transcription and translation resulting in structural changes of proteins and neurons

B. ANATOMICAL STRUCTURES INVOLVED AT DIFFERENT TIMES IN STORAGE OF EXPLICIT MEMORIES

LESS THAN 1 SECOND ("ATTENTION" OR "REGISTRATION")	SECONDS TO MINUTES ("WORKING MEMORY")	MINUTES TO YEARS ("CONSOLIDATION")	YEARS
Brainstem–diencephalic activating systems; frontoparietal association networks; specific unimodal and heteromodal cortices	Frontal association cortex; specific unimodal and heteromodal cortices	Medial temporal structures; medial diencephalic structures; specific unimodal and heteromodal cortices	Specific unimodal and heteromodal cortices

H.M. and other patients with bilateral medial temporal or medial diencephalic lesions are unable to recall facts and events for more than a few minutes. **Medial temporal and diencephalic structures** appear to mediate a process by which declarative memories are gradually **consolidated** in the neocortex (see Table 18.6B). Ultimately, through this process, declarative memories can be recalled through activity of specific regions of **neocortex** without requiring medial temporal and diencephalic involvement.

Anterograde amnesia is the deficit in forming new memories that H.M. and other similar patients have from the time of their brain injury onward (Figure 18.16). For example, ever since his surgery, H.M. has not been able to learn his address, and when asked, he still cites the address of his childhood; he cannot learn the date, and despite watching the news every day, he does not remember most events from after the 1950s. **Retrograde amnesia** is the loss of memories from a period of time before the brain injury. For example, H.M.'s memories of his childhood and adolescence are relatively normal, but they stop several years before the surgery (see Figure 18.16). This combination of retrograde and anterograde amnesia for declarative memories is typical of lesions of the medial temporal lobe or medial diencephalic memory systems (although it can also be seen in concussion or other diffuse disorders).

The phenomenon of retrograde amnesia suggests that recent memories, for a period of up to several years, are dependent on the normal functioning of medial temporal and diencephalic structures, while more remote memories are not. Retrograde amnesia is often graded, with the memories from the time just before the injury being the most severely impaired (although like most biological phenomena, the time gradient is typically not perfectly uniform). In patients with reversible causes of amnesia (described in the next subsection), the period of retrograde amnesia often gradually shrinks forward; older memories are recovered before more recent ones. Ultimately, these patients will have a short time period (several hours) of permanently lost memories from before the injury, and a period of lost memories from the injury until the time they recover from the anterograde amnesia.

REVIEW EXERCISE

Amnesia for explicit (declarative) memories with retrograde amnesia for the period preceding onset and anterograde amnesia following onset is typically caused by bilateral lesions in which of two possible locations?

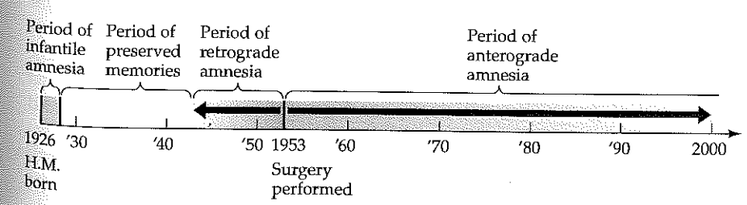

Figure 18.16 Diagram of Anterograde and Retrograde Amnesia in Patient H.M.

The expressions "short-term" and "long-term" memory are sometimes used for memories enduring less than or more than a few minutes, respectively. This terminology is not ideal because so-called long-term memory includes even recent memories that are disrupted by bilateral medial temporal or diencephalic disorders. Numerous cognitive models of memory function have been developed that are beyond the scope of this book. One common way that memory has been described is as a three-step process involving encoding, storage, and retrieval. However, it has proven very difficult to demonstrate a selective deficit in human or animal studies in just one of these processes.

Differential Diagnosis of Memory Loss

Impaired memory can have many causes, as summarized in Table 18.7. These can be conveniently divided into those in which there are usually anatomical abnormalities visible on conventional imaging studies, those in which there are not, and finally, "normal" forms of memory loss. We will comment on only a few of these conditions in detail.

Cerebral contusions caused by head trauma often involve the anteromedial temporal lobes, as well as the basal orbitofrontal cortex (see Figure 5.21), resulting in permanent deficits in memory. In contrast, **concussion** (see KCC 5.5) can be associated with memory loss that is usually reversible, except for the hours around the time of the injury.

Infarcts or **ischemia** (see KCC 10.3, 10.4) can cause memory deficits, especially when bilateral medial temporal or medial diencephalic structures are affected. Recall that the medial temporal lobes are supplied by distal branches of the posterior cerebral arteries (see Figure 10.5). The medial thalami are supplied by paramedian thalamoperforator arteries, which arise from the initial segments of the posterior cerebral arteries (see Figures 10.8, 10.9). Thus, arterial lesions at the top of the basilar artery (see Figure 14.17A; KCC 14.3) are well positioned to cause either bilateral medial temporal or medial diencephalic infarcts. In addition, the bilateral medial thalami are often supplied by a single paramedian thalamoperforator artery (or "artery of Percheron"), which bifurcates shortly after its origin from the top of the basilar. This provides another mechanism for bilateral infarctions in this area.

In **global cerebral anoxia,** such as that caused by cardiac arrest, memory loss is often prominent. This may be related to the particular vulnerability of the hippocampus to anoxic injury, especially CA1, in which marked loss of pyramidal cells can be seen. As has already been mentioned, rupture of an **anterior communicating artery aneurysm** can damage the basal forebrain, causing memory loss together with other deficits seen in frontal lobe lesions (see KCC 19.11). It is unclear whether the memory loss in these patients is due to damage to the basal forebrain, medial diencephalon, frontal lobes, or a combination of these locations.

Wernicke–Korsakoff syndrome is caused by thiamine deficiency, seen most often in alcoholics, but also occasionally in patients on chronic parenteral nutrition. Pathologically, these patients have bilateral necrosis of the mammillary bodies and of a variety of medial diencephalic and other periventricular nuclei. Acutely, patients with thiamine deficiency have a triad of ataxia; eye movement abnormalities ranging from horizontal gaze paresis, or nystagmus, to ophthalmoplegia; and a confusional state. Severe cases can result in coma or death. Patients who survive the acute stages are left with anterograde and retrograde amnesia, thought to be caused by the bilateral diencephalic lesions. In addition to amnesia, however, patients with Wernicke–Korsakoff syndrome usually have other neuropsychological deficits, that suggest frontal lobe dysfunction (see KCC 19.11). These include impairments in judgment, initiative, impulse control, and sequencing tasks. In contrast to patients with "pure" medial diencephalic or medial temporal lesions, patients with Wernicke–Korsakoff syndrome often lack an awareness of their memory deficit, and in fact they tend to **confabulate,** providing spurious answers to questions rather than saying that they do not remember. Confabulation is also probably related to frontal lobe dysfunction, which causes disinhibition and a loss of self-monitoring capabilities.

Patients with complex partial and generalized tonic-clonic **seizures** (see KCC 18.2) usually have memory loss of events during the seizure and post-ictal period (the period immediately following the seizure). Memory between seizures may be normal, unless the seizures are severe or caused by lesions of the medial temporal lobe, such as **hippocampal sclerosis** (see KCC 18.2). **Electroconvulsive therapy** (**ECT**) is an effective mode of therapy for selected patients with refractory depression. In ECT, seizures are induced while the patient is under anesthesia during multiple sessions, usually over the course of several weeks. During the treatment period, patients develop retrograde and anterograde amnesia similar to that seen in patients with bilateral temporal or diencephalic lesions. The amnesia gradually resolves after the course of treatment is complete, but it typically leaves a gap, including retrograde and anterograde memory loss from around the treatment period.

Transient global amnesia is a somewhat mysterious disorder in which patients abruptly develop retrograde and anterograde amnesia with no obvious cause and no other deficits. Episodes often occur in the setting of physical exertion or emotional stress. During the amnesia, patients characteristically ask the same questions over and over, with no recollection of having asked them a few minutes earlier. The amnesia typically lasts for approximately 4 to 12 hours, after which the patient recovers fully, except for a permanent loss of memories for a period of a few hours before and after onset. In about 85% of patients, a similar episode never happens again.

TABLE 18.7 Causes of Memory Loss

ANATOMICAL LESIONS USUALLY VISIBLE ON IMAGING STUDIES
Bilateral medial temporal lesions
Surgery
Cerebral contusions
Infarct (posterior cerebral arteries)
Hippocampal sclerosis (usually with chronic epilepsy)
Herpes encephalitis
Paraneoplastic limbic encephalitis
Neoplasm
Inflammatory process, such as sarcoidosis
Bilateral medial diencephalic lesions
Wernicke–Korsakoff syndrome
Infarct (thalamoperforator arteries)
Whipple's disease
Neoplasm
Basal forebrain lesions
Anterior communicating artery aneurysmal rupture
Neoplasm
Diffuse disorders
Multiple sclerosis
Numerous other diffuse cerebral disorders (additional deficits common)
NO ANATOMICAL LESIONS VISIBLE ON CONVENTIONAL IMAGING[a]
Seizures, including electroconvulsive therapy
Concussion
Ischemia (bilateral medial temporal or medial diencephalic structures)
Diffuse cerebral anoxia
Transient global amnesia
Early Alzheimer's disease and other degenerative disorders
Diffuse infectious or toxic/metabolic encephalopathies (additional deficits common), including those caused by medications such as benzodiazepines
Psychogenic amnesia
Dissociative disorders
Repression
Conversion disorder
Malingering
"NORMAL" MEMORY LOSS
Infantile amnesia
During or shortly after awakening from sleep
Passage of time (forgetting)

[a]In some of these disorders, abnormalities may be visible on functional imaging studies such as PET or fMRI (see Chapter 4).

The cause of this intriguing syndrome is not known. It differs from other common causes of transient neurologic episodes (see KCC 10.3), such as seizures and transient ischemic attacks (TIAs), in several ways. Seizures can cause periods of memory loss; however, other manifestations of seizures, such as abnormal movements or decreased responsiveness, are usually present as well. Complex partial seizures can occasionally cause brief episodes of amnesia with no other obvious behavioral changes. Unlike transient global amnesia, however, the duration of amnesia is only a few minutes, the episodes recur multiple times in a stereotyped fashion, and the EEG is often abnormal. EEG recordings during transient global amnesia do not show epileptic activity. TIAs can cause transient memory loss; however, the typical duration of TIAs is minutes, not hours. In addition, patients who have had an episode of transient global amnesia are not at increased risk for subsequent stroke compared to the general population. A migrainelike (see KCC 5.1) phenomenon has also been proposed as the mechanism for transient global amnesia, and indeed a history of migraine is common in patients with transient global amnesia. Functional imaging studies during transient global amnesia have demonstrated decreased blood flow or decreased glucose metabolism in the medial temporal lobes, as well as in other brain regions. In conclusion, the cause of transient global amnesia remains unknown. It is possible that this syndrome is produced by different etiologies in different patients, but the relative uniformity of this disorder argues for a common mechanism in at least the majority of cases.

In the early stages of several neurodegenerative disorders, especially early **Alzheimer's disease** (see KCC 19.16), memory loss for recent events is often prominent, with no other obvious abnormalities. This phenomenon may occur because early Alzheimer's disease tends to preferentially affect the bilateral hippocampal, temporal, and basal forebrain structures (see Figure 19.14). As Alzheimer's disease progresses, other neurobehavioral abnormalities occur as well, as we will discuss in Chapter 19. Memory loss can also be seen as a part of numerous other diffuse or multifocal disorders of the nervous system stemming from many etiologies. In these disorders—which include multiple sclerosis, brain tumors, intracerebral hemorrhage, infarcts, CNS infections , various toxic or metabolic encephalopathies, CNS vasculitis, hydrocephalus, and many other conditions—a variety of other abnormalities are usually present in addition to memory loss. It is sometimes difficult to distinguish true memory disorders in these conditions from deficits in attention or language processing.

Psychogenic amnesia can occur in several settings, including dissociation, repression, conversion, and malingering. In contrast to medial temporal lobe or diencephalic amnesia, patients with psychogenic amnesia usually do not have a pattern of retrograde and anterograde amnesia affecting mainly recent memories. Instead, patients with psychogenic amnesia often have memory loss for events of particular emotional significance. In psychogenic amnesia there may also be loss of autobiographical memories such as one's name and birthplace—memories that are ordinarily preserved in medial temporal lobe or diencephalic amnesia unless other severe cognitive deficits are present as well.

"Normal" memory loss occurs in several situations. **Infantile amnesia** is the inability for adults to recall events from the first 1 to 3 years of life. A variety of mechanisms have been proposed, but infantile amnesia is most likely the result of ongoing central nervous system maturational processes, such as myelination, that are quite active during infancy and early childhood. At the other extreme of life, **benign senescent forgetfulness** is the presumably normal mild decline in memory function that occurs gradually over the decades. This should be contrasted with Alzheimer's disease and other forms of dementia in which memory loss is more severe and occurs over the course of a few years.

In another normal form of memory loss, dreams can be recalled immediately after awakening from **sleep,** but they can no longer be remembered a few minutes later. Similarly, a common experience is being awakened from a deep sleep and having a conversation on the telephone that, the next day, one cannot recall. Finally, with the passage of time, **forgetting** normally occurs, in which memories gradually become less distinct and eventually may not be recalled. ■

The Amygdala: Emotions, Drives, and Other Functions

The **amygdala** (meaning "almond" in Greek), or **amygdaloid nuclear complex,** is a group of nuclei located in the anteromedial temporal lobe, just dorsal to the anterior tip of the hippocampus and temporal horn. It has three main nuclei: the **corticomedial, basolateral,** and **central nuclei** (see Figures 18.4B, 18.6, 18.10). The **bed nucleus of the stria terminalis** (see Figure 18.4B) is also considered part of the amygdala. In humans, the **basolateral nucleus** is largest and is predominantly involved in direct and indirect connections of the amygdala to diverse cortical areas as well as to the basal forebrain and medial thalamus. The smaller **corticomedial nucleus** derives its name from its corticoid structure, located on the medial surface of the temporal lobe, near the basal forebrain and olfactory areas (see Figure 18.4A,B). The main connections of the corticomedial nucleus are involved in olfaction, and in interactions with the hypothalamus related to appetitive states. The **central nucleus** is smallest and has connections with the hypothalamus and brainstem that are important in autonomic control.

REVIEW EXERCISE

What are the main connections of the corticomedial, central, and basolateral nuclei of the amygdala? Note that, despite its name, the corticomedial nucleus is not the one with major cortical connections.

As discussed in the beginning of the chaper, the amygdala plays a pivotal role in emotions and drives (see Table 18.2). However, through its extensive connections to other structures in the limbic network (see Figure 18.1), the amygdala is an active participant in all four major limbic functions (see Table 18.2). We will first discuss functional roles of the amygdala and then review its main input and output connections.

Emotions and drives appear to be mediated by complex interactions among numerous brain regions, including the heteromodal association cortex, limbic cortex, amygdala, septal area, ventral striatum, hypothalamus, and brainstem autonomic and arousal pathways (Figure 18.17A,B). The amygdala plays a central role, but the other components of the network are essential as well. On the basis of the effects of lesions in humans and experimental animals, the amygdala is important for attaching emotional significance to various stimuli perceived by the association cortex. When both amygdalas have been ablated, behavior tends to be placid. Tame, nonaggressive behavior, together with other behavioral changes, constitutes the **Klüver–Bucy syndrome** studied in monkeys with bilateral lesions of the amygdala and adjacent temporal structures. (Klüver–Bucy syndrome has been observed only rarely in humans.) Seizures (see KCC 18.2) involving the amygdala and adjacent cortex cause powerful emotions of fear and panic.

Interestingly, while activity in the amygdala has been found to be important in states of fear, anxiety, and aggression, activity in the septal area appears to be important in pleasurable states. For example, experimental animals will press a lever repeatedly to obtain electrical stimulation of the septal area, even to the point of neglecting to eat in order to continue the stimulation. Increased activity has been recorded in the septal area during orgasm,

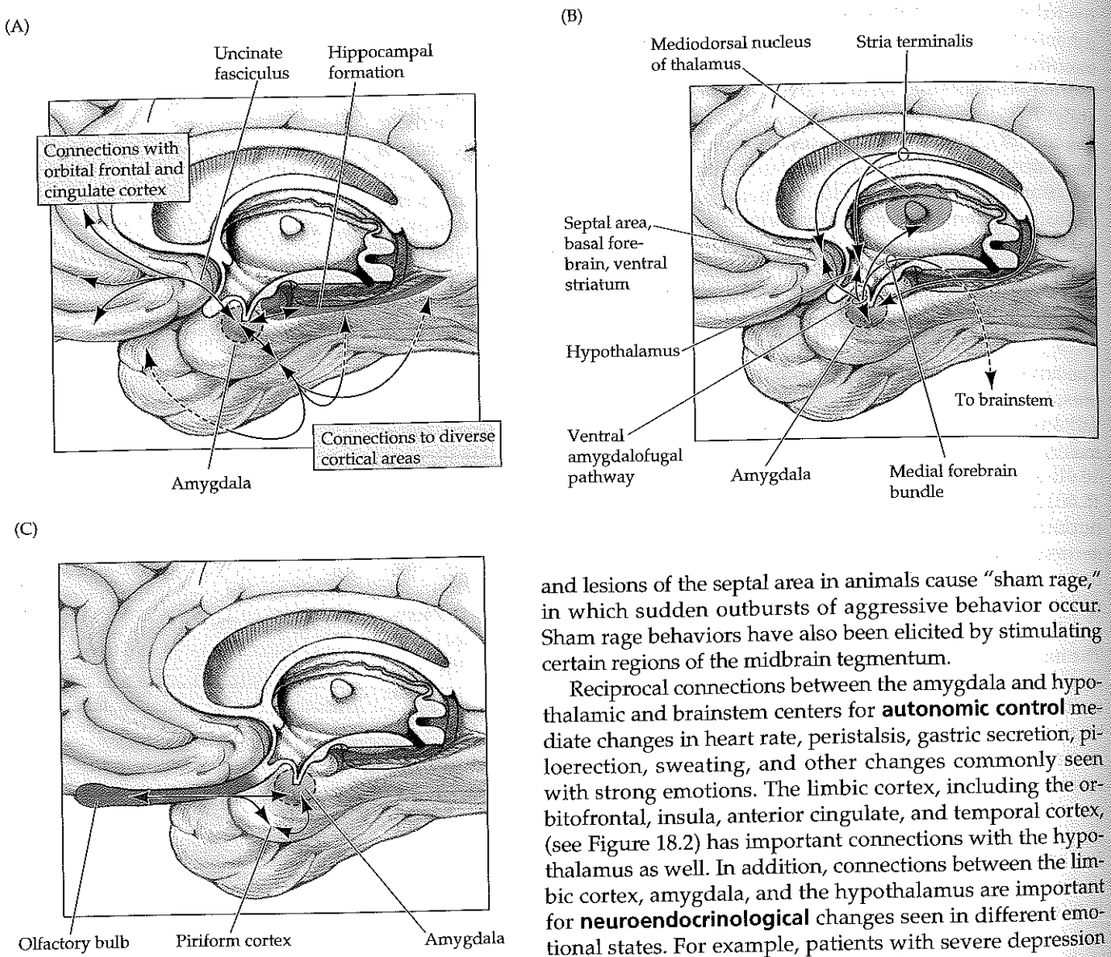

Figure 18.17 Input and Output Connections of the Amygdala
(A) Cortical connections. (B) Subcortical connections. (C) Olfactory connections.

and lesions of the septal area in animals cause "sham rage," in which sudden outbursts of aggressive behavior occur. Sham rage behaviors have also been elicited by stimulating certain regions of the midbrain tegmentum.

Reciprocal connections between the amygdala and hypothalamic and brainstem centers for **autonomic control** mediate changes in heart rate, peristalsis, gastric secretion, piloerection, sweating, and other changes commonly seen with strong emotions. The limbic cortex, including the orbitofrontal, insula, anterior cingulate, and temporal cortex, (see Figure 18.2) has important connections with the hypothalamus as well. In addition, connections between the limbic cortex, amygdala, and the hypothalamus are important for **neuroendocrinological** changes seen in different emotional states. For example, patients with severe depression appear to have an increased susceptibility to infection, possibly resulting from endocrinological effects on the immune system. Although the amygdala was previously thought to be crucial for **memory functions,** more recent studies have instead emphasized the importance of the hippocampal formation. However, the amygdala does appear to play an important role in attaching emotional significance to memories. The role of the amygdala in **olfaction,** particularly in emotional and motivational aspects of olfaction, was mentioned earlier in this chapter.

Let's review the main input and output connections of the amygdala with these functional considerations in mind (see Figure 18.17). Most connections of the amygdala are bidirectional. In analogy to the hippocampal formation, the amygdala both receives and transmits information from **diverse cortical areas,** including heteromodal association cortex and limbic cortex (see Figure 18.17A). These connections occur through two pathways. Fibers pass posteriorly and laterally from the amygdala to reach most cortical areas, often via relays in the anterior temporal and insular cortices. In addition, the **uncinate fasciculus** passes anteriorly to connect the amygdala with the medial orbitofrontal and cingulate cortices (see Figures 18.4B,C, 18.17A; Table 18.4) . The **hippocampal formation** and amygdala have reciprocal connections that may be important for emotional aspects of memory. For example, the amygdala has been demonstrated to be involved in fear memory and in modulating the effects of arousal on memory strength.

Subcortical connections of the amygdala (see Figure 18.17B) are important in the motivational, autonomic, and neuroendocrine aspects of limbic function. Connections that are mainly efferent from the amygdala, but have a smaller afferent component as well, pass through two major pathways: the stria terminalis and the ventral amygdalofugal pathway (see Table 18.4). In simple terms, the stria terminalis can be thought of as "the long way around," while the ventral amygdalofugal pathway can be thought of as "the shortcut" (see Figure 18.17B). The **stria terminalis** is a C-shaped structure that runs from the amygdala along the wall of the lateral ventricle to reach ultimately the hypothalamus and septal area. The stria terminalis can thus be thought of as the "fornix of the amygdala" (compare Figures 18.9A and 18.17B). The stria terminalis can be seen in coronal brain sections to lie just medial to the caudate nucleus (see Figure 18.4B,C) or in the groove between the caudate and thalamus (see Figure 16.4D) and, like the tail of the caudate, can also be seen running along the roof of the temporal horn of the lateral ventricle (see Figure 16.4D). One connection carried by the stria terminalis from the corticomedial amygdala to the ventromedial hypothalamus may carry olfactory information that either increases or decreases appetite, depending on the odor. The **ventral amygdalofugal pathway** (see Figures 18.4C, 18.17B) passes anteriorly from the amygdala to reach several forebrain and brainstem structures. Projections to the forebrain involved in emotion, motivation, and cognitive functions include connections to the nucleus basalis, septal nuclei,* ventral striatum, and mediodorsal nucleus of the thalamus. Recall that the mediodorsal nucleus serves as a limbic relay, projecting to the frontal lobes (see Figure 7.8). The ventral amygdalofugal pathway also carries bidirectional signals involved in homeostatic (autonomic and neuroendocrine) function and behavioral arousal between the amygdala and hypothalamus (see Chapter 17), and between the amygdala and brainstem nuclei such as the nucleus solitarius, parabrachial nucleus, dorsal motor nucleus of the vagus, periaqueductal gray, and reticular formation. These connections between the amygdala, hypothalamus, and brainstem travel in the medial forebrain bundle (see Figure 18.17B; see also Figure 17.4).

MNEMONIC

As we discussed earlier, **olfactory inputs** are carried from the olfactory bulb through the lateral olfactory stria to the corticomedial nucleus of the amygdala (see Figure 18.17B). In addition, indirect olfactory projections are relayed in the piriform cortex to reach the basolateral amygdala.

REVIEW EXERCISE

Consult Table 18.4 and Figure 18.17 to answer the following questions:

1. What is the name of the pathway connecting the amygdala and other medial temporal structures with the orbitofrontal cortex?

2. What are the names of two pathways connecting the amygdala with the hypothalamus and the septal region?

3. What is the name of a major pathway connecting the amygdala and the hypothalamus with the brainstem?

Other Limbic Pathways

As should be clear by now, limbic circuits are fairly complex, and there are many other pathways in addition to those already mentioned. We will summarize only a few additional limbic pathways here (see Table 18.4), selected because they form prominent anatomical landmarks. The **stria medullaris** is a band of fibers that runs rostrocaudally along the walls of the third ventricle, on the medial surface of the thalamus (see Figures 16.3A, 16.4D). It carries

*Ventral amygdalofugal fibers travel to the septal nuclei in the **diagonal band of Broca.** The diagonal band of Broca also contains fibers connecting the septum with the hypothalamus and the cortex with the striatum, as well as cholinergic neurons with projections to the medial temporal lobes (see Figure 14.9).

fibers from the medial septal nuclei to the **habenula,** a small epithalamic structure located just lateral to the pineal gland. The habenula, in turn, projects via the **habenulointerpeduncular tract** (fasciculus retroflexus) to the **interpeduncular nuclei** in the midbrain. The interpeduncular nuclei project to the serotonergic **raphe nuclei,** as well as to dopaminergic nuclei, which have diffuse projections throughout the brain (see Figures 14.10, 14.12).

The anterior portion of the **anterior commissure** (see Figures 18.4B,C, 18.13) connects the anterior olfactory nucleus of the olfactory bulb to the same structure on the contralateral side. The posterior portion of the anterior commissure interconnects the bilateral amygdalas and anterior temporal lobes.

KEY CLINICAL CONCEPT
SEIZURES AND EPILEPSY

18.2 *Definitions and Incidence*

A **seizure** is an episode of abnormally synchronized and high-frequency firing of neurons in the brain that results in abnormal behavior or experience of the individual. As we will discuss in this section, different types of seizures can occur depending on the location in the brain and the duration and type of abnormal electrical activity. **Epilepsy** is a disorder in which there is a tendency to have recurrent unprovoked seizures. Thus, a seizure is a *symptom* of abnormal brain function, which can occur in patients with or without epilepsy. For example, seizures can occur in patients with epilepsy but can also be provoked in normal individuals by conditions such as electrolyte abnormalities, alcohol withdrawal, electroshock therapy, toxins, etc.

Epilepsy in a given individual can be caused by genetic, structural, metabolic or other abnormalities, or the cause may be unknown. Epilepsy is a fairly common disorder, affecting close to 1% of the population. The lifetime risk of having a single seizure is even higher, with estimates ranging from 10 to 15% of the population.

A few more definitions will be helpful at this point, to understand the material that follows. **Ictal** means during a seizure, **post-ictal** means immediately after a seizure, and **interictal** means between seizures.

TABLE 18.8 International Classification of Epileptic Seizures

I. Partial (focal, local) seizures
- A. **Simple partial**[a] seizures
  1. With motor signs
  2. With somatosensory or special sensory symptoms
  3. With autonomic symptoms or signs
  4. With psychic symptoms
- B. **Complex partial** seizures
  1. Simple partial onset followed by impairment of consciousness
  2. With impairment of consciousness at onset
- C. Partial seizures evolving to secondarily generalized seizures
  1. Simple partial seizures evolving to generalized seizures
  2. Complex partial seizures evolving to generalized seizures
  3. Simple partial seizures evolving to complex partial seizures evolving to generalized seizures

II. Generalized seizures
- A. Absence seizures
  1. Typical **absence (petit mal)**
  2. Atypical absence
- B. Myoclonic seizures
- C. Clonic seizures
- D. Tonic seizures
- E. **Tonic-clonic (grand mal)** seizures
- F. Atonic seizures

III. Unclassified epileptic seizures

Source: Epilepsia 1981, 22: 489–501.

[a]The most common and clinically important seizure types are shown in **boldface**.

Classification

No classification is perfect, and new classification schemes of seizures and epilepsy are currently being developed. The classification discussed in this section is still the most widely used and is based on that developed by the International League Against Epilepsy in the 1980s. Seizures are classified as either partial or generalized (Table 18.8). In **partial (focal, local) seizures,** abnormal paroxysmal electrical activity occurs in a localized region of the brain; in **generalized seizures,** the abnormal electrical discharge involves the entire brain. Note that a seizure can begin as a partial seizure and then spread to become **secondarily generalized.**

A similar classification scheme is used for epilepsy syndromes. Specific epilepsy syndromes are defined on the basis of the types of seizures that occur, together with other clinical features, such as age of onset, family history, and associated medical abnormalities other than seizures. In broad terms, however, epilepsy syndromes are divided into **localization-related (partial, focal,** or **local) epilepsy** and **generalized,** or **primary generalized, epilepsy.** Some seizures or epilepsy syndromes cannot easily be assigned to the local or generalized categories and remain unclassified. Ultimately, as our genetic and pathophysiological understanding of epilepsy improves, epilepsy syndromes will be defined on the basis of specific gene defects or cellular abnormalities.

Partial seizures can be further subdivided into simple partial and complex partial seizures (see Table 18.8). In **simple partial seizures,** consciousness is spared. For example, if a patient has rhythmic twitching movements of the left hand caused by a simple partial seizure in the right motor cortex hand area, they will remain alert, talk normally during the seizure, and clearly recall the entire episode afterward. Partial seizures can have positive symptoms, such as hand twitching, or negative symptoms, such as impaired language abilities. The manifestations of partial seizures depend on the anatomical regions of the brain in which the seizure activity occurs (Table 18.9). For example, as we discussed in Chapter 11 (see KCC 11.1), seizures in the primary visual cortex can cause simple geometric shapes and flashes of light to appear in the contralateral visual field, while seizures in visual association cortex can produce more elaborately formed visual hallucinations such as people's faces or complex scenes. Patients with seizures in auditory cortex report simple sounds like a roaring engine or horn, most often coming from the direction opposite the involved cortex, or they may report having difficulty hearing, as if they were submerged underwater. Seizures in auditory association cortex can cause the patient to hear voices or music. Musical hallucinations are more common in nondominant hemisphere seizures (see KCC 19.13). Contralateral somatosensory phenomena occur during seizures in the somatosensory cortex.

The term **aura** means "breeze" and was originally used in ancient Greece by Galen's teacher Pelops to describe the sensation felt by one of his patients in his leg prior to having a large seizure. Auras are brief simple partial seizures of any type that are experienced by a patient with no outward behavioral manifestations. They can occur in isolation, or they may serve as a warning for a larger seizure, when a patient has seizures that typically begin in one region of the brain before spreading. Patients with seizures arising from medial temporal limbic structures (see Table 18.9) often report a visceral sensation of rising in the epigastric area, a feeling of déjà vu, strange unpleasant odors, or feelings of extreme fear and anxiety. **Odors** and **panic** are thought to arise from the amygdala and nearby cortex, rather than from the hippocampus. Some reports suggest that olfactory phenomena during seizures can also arise from the orbitofrontal olfactory cortex (see Figure 18.6).

As mentioned earlier, patients with seizures in primary motor cortex usually have simple rhythmic jerking **clonic** movements or sustained **tonic** contractions in the contralateral extremities. However, seizures in frontal motor association cortex, such as the supplementary motor area, can produce more elaborate movements, including a characteristic "fencing posture"; bilateral leg cycling movements; turning of the eyes, head, or entire body; and the production of unusual sounds. Typical duration for simple partial seizures is 5 to 10 seconds, although longer seizures are not uncommon. Recall that the time during a seizure is called the ictal period, and the time immediately after a seizure is called the post-ictal period. With brief simple partial seizures there are often no new post-ictal deficits. If the

TABLE 18.9 Clinical Manifestations of Partial Seizures in Different Brain Regions

TEMPORAL LOBE

Medial: An indescribable sensation, rising epigastrium ("butterflies" in the stomach), nausea, déjà vu, fear, panic, unpleasant odor, autonomic phenomena (tachycardia, pupillary dilation, piloerection, borborygmi, belching, pallor, flushing), bland staring with unresponsiveness, oroalimentary automatisms (lipsmacking, chewing, swallowing), bilateral or unilateral gestural automatisms, contralateral dystonia with ipsilateral automatisms.

Lateral: Vertigo (temporoparietal operculum), inability to hear, simple auditory hallucinations (buzzing, roaring engine, tones), elaborate auditory hallucinations (voices, music). Aphasia, including inability to understand what people are saying, is more common with dominant temporal seizures. Saying words or phrases repeatedly and having musical hallucinations are more common with nondominant temporal seizures.

Comments: Usual duration 1 to 2 minutes, often with post-ictal amnesia, tiredness, headache, emotional changes, or other focal deficits. Most common cause of complex partial seizures. Head or eye deviation probably results from spread to frontal or parietal lobes (see below). Medial temporal lobe seizures associated with hippocampal sclerosis usually do not generalize once treated with anticonvulsant medications; however, the complex partial seizures in this condition are often medically refractory and frequently can be cured by surgery.

FRONTAL LOBE

Dorsolateral convexity: Contralateral tonic or clonic activity (primary motor cortex); strong version (turning) of eyes, head, and body away from side of the seizure (prefrontal cortex and frontal eye fields). Aphasia (dominant hemisphere).

Supplementary motor area: Fencing posture with extension of contralateral upper extremity, other tonic postures, speech arrest, unusual sounds.

Orbitofrontal and cingulate: Elaborate motor automatisms, making unusual sounds, autonomic changes, olfactory hallucinations (orbitofrontal), incontinence (cingulate).

Comments: Seizures are often brief, occur multiple times per day, and may have no post-ictal deficits. Nocturnal exacerbation is common. Elaborate motor automatisms without loss of consciousness or postictal deficits often lead to misdiagnosis as psychogenic episodes.

PARIETAL LOBE

Vertigo, contralateral numbness, tingling, burning, sensation of movement or need to move, aphasia (dominant hemisphere), contralateral hemineglect (nondominant hemisphere). Eyes and head may deviate toward or away from the side of the seizure.

OCCIPITAL LOBE

Sparkles, flashes, pulsating colored lights, scotoma, or hemianopia in contralateral visual field (primary visual cortex), formed visual hallucinations (inferior temporo-occipital association cortex), nystagmoid or oculogyric jerks, palpebral jerks, eye blinking, sensations of eye oscillation.

Comments: May be precipitated by changes in lighting conditions. Often associated with migrainelike symptoms. Variable spread to other lobes is common and can lead to mislocalization.

Note: Features of both simple partial and complex partial seizures are included here. Seizures may begin in one region and spread to another, producing signs and symptoms corresponding to multiple neuroanatomical areas.

seizures are prolonged or recurrent, there may be post-ictal depressed function of the local region of cortex involved, producing focal weakness (**Todd's paresis**), or other deficits.

Unlike simple partial seizures, in **complex partial seizures** (see Table 18.8) there is **impairment of consciousness**. The impaired consciousness with complex partial seizures is presumably due to seizure activity affecting wider regions of cortex, or deep brainstem and diencephalic regions. Impairment of consciousness in complex partial seizures may be complete or mild, sometimes making the distinction from simple partial seizures difficult. The most common localization for complex partial seizures is the temporal lobes; however, such seizures can arise from the frontal, parietal, or occipital lobes as well. Patients with complex partial seizures arising from the temporal lobes are sometimes said to have temporal lobe epilepsy, or psychomotor epilepsy. **Medial temporal lobe–onset complex partial seizures** (see Table 18.9) often begin with an aura, as described earlier, of an unusual, often indescribable sensation, or with epigastric, emotional, or olfactory phenomena, or déjà vu. Sometimes no aura can be recalled. The initial symptoms are followed by unresponsiveness and loss of awareness, during which the patient may have **automatisms,** which are usually repetitive behaviors such as lip smacking, swallowing, or stereotyped hand or leg movements such as stroking, wringing, or patting.

Interestingly, in temporal lobe seizures the ipsilateral basal ganglia are often involved, causing contralateral dystonia or immobility (see KCC 16.1), while the ipsilateral extremities remain free to exhibit automatisms. These behaviors can be falsely localizing to the unpracticed eye, since the side ipsilateral to the temporal lobe seizure shows movements (automatisms), while the contralateral side is relatively still (dystonia). Sometimes instead there is simply bland staring, immobility, and unresponsiveness. Autonomic phenomena such as tachycardia, pupillary dilation, and piloerection can occur. Typical duration is 30 seconds to 1 to 2 minutes. Post-ictal deficits may last from minutes to hours and can include unresponsiveness, confusion, amnesia, tiredness, agitation, aggression, and depression. Headache is common. Patients with left temporal-onset seizures may have post-ictal language deficits, although care must be taken to distinguish such deficits from overall decreased responsiveness, which is nonlocalizing. There may also be some mild post-ictal weakness or hyperreflexia contralateral to the side of onset. This is usually subtle, unless the seizure has spread to the motor cortex, in which case there would be unilateral tonic or clonic activity during the seizure.

The most common type of **generalized seizure** is a **generalized tonic-clonic,** or **grand mal, seizure** (see Table 18.8). A generalized tonic-clonic seizure can be generalized from the onset, or it may begin focally and then secondarily generalize. It typically begins with a **tonic phase** characterized by loss of consciousness and generalized contraction of all muscles lasting for 10 to 15 seconds. This often results in stiff extension of the extremities, during which the patient may fall "like a tree" and injure themselves, and a characteristic expiratory gasp or moan may occur as air is forced past the closed glottis. Next is a **clonic phase,** characterized by rhythmic bilateral jerking contractions of the extremities, usually in flexion, at a frequency of about 1 hertz, which gradually slow down and then stop. Incontinence or tongue biting is common. There is usually a massive ictal autonomic outpouring with tachycardia, hypertension, hypersalivation, and pupillary dilation. Typical duration is 30 seconds to 2 minutes. Immediately post-ictally, patients lie immobile, flaccid, and unresponsive, with eyes closed, breathing deeply to compensate for the mixed metabolic and respiratory acidosis produced by the seizure. Within a few minutes they usually begin to move and respond. Post-ictal deficits last from minutes to hours and include profound tiredness, confusion, amnesia, headache, and other deficits related to the location of seizure onset.

In addition to generalized tonic-clonic, or grand mal, seizures, there are a variety of other generalized seizure types (see Table 18.8). Most of these are relatively uncommon and will not be discussed further here, with the exception of absence seizures. Typical **absence (petit mal) seizures** are brief episodes of staring and unresponsiveness lasting for about 10 seconds or less. There are no post-ictal deficits, except for a lack of awareness of what occurred during the brief time of the seizure. These seizures are accompanied by a characteristic **generalized 3–4 hertz spike and wave** discharge on electroencephalogram (EEG) recordings (see Chapter 4).

Although absence seizures are generalized, they differ from grand mal seizures, which begin with a prolonged high-frequency electrical discharge that causes a more severe disruption of brain function. Absence seizures are most common in childhood and can occur multiple times per day, causing impaired school performance. They often can be provoked by hyperventilation, strobe lights, or sleep deprivation. About 40% of children with typical absence seizures remit spontaneously. It should be noted that both absence seizures and complex partial seizures can cause episodes of staring and unresponsiveness. Typical cases of medial temporal lobe complex partial seizures can usually easily be distinguished from typical absence seizures on clinical grounds (Table 18.10). However, in atypical absence seizures or brief complex partial seizures, the distinction may be more difficult.

When seizures of any type occur continuously, or repeatedly in rapid succession, the condition is referred to as **status epilepticus.** Generalized tonic-clonic status epilepticus is a medical emergency that requires immediate and aggressive treatment. When first-line agents such as benzodiazepines and phenytoin are ineffective, intubation and general anesthesia may be necessary. EEG recording should always be performed urgently in this situation to ensure that electrographic seizure activity has stopped. Blood tests (see the next subsection), head CT, and lumbar puncture (when appropriate) should be performed without delay so that other specific treatments can be initiated. Prognosis depends mainly on the promptness of treatment and on the underlying etiology. Other forms of status epilepticus aside from tonic–clonic seizures should also be treated promptly, although a balance must be struck between the risks of aggressive treatment and the risks of ongoing seizures. The behavioral features of status epilepticus can sometimes be subtle, so the prompt performance of an EEG is often needed for the diagnosis to be made, and for treatment to be initiated.

Diagnosis and Etiology

The diagnostic evaluation of patients with epilepsy is essential because the correct diagnosis has a major impact on treatment. The first step is to ascertain whether the episodes are epileptic seizures or another type of transient event (see Tables 10.2, 16.3). Epileptic seizures are usually brief events that are **stereotyped** from one episode to the next in a given patient and often fit one of the typical seizure patterns already described. If the events are epileptic seizures, the next step is to determine the type of seizure (see Tables 18.8, 18.10), as well as the localization if the seizures are focal in onset (see Table 18.9). Finally, a cause for the seizures should be sought (Table 18.11).

TABLE 18.10 Staring Spells: Complex Partial Seizures versus Absence Seizures

TYPE OF SEIZURE	AURA	DURATION	AUTOMATISMS	POST-ICTAL DEFICITS	FREQUENCY	INTERICTAL BRAIN FUNCTION	ICTAL EEG
Typical medial temporal complex partial seizures	May be present	30–120 s	May be present	May be present	3–4/month	Focal abnormalities	Unilateral or asymmetrical 5–8 Hz rhythmic activity over the temporal lobe
Typical absence seizures	None	<10 s	None[a]	None	Multiple daily	Normal	Generalized 3–4 Hz spike–wave

[a]Minor clonic movements of the eyelids or corners of the mouth at 3–4 Hz sometimes occur.

The fundamental tools used for diagnosis in epilepsy include a detailed clinical history; physical exam; basic blood tests; MRI scan with special thin coronal cuts and pulse sequences used to view the medial temporal, cortical, and subcortical structures in detail; and an interictal EEG (see Chapter 4). When the diagnosis remains uncertain, additional tests can be helpful in diagnosis and localization. These include admission for continuous video and EEG monitoring in an attempt to obtain an ictal recording; ictal and interictal nuclear medicine tests, such as SPECT (single photon emission computed tomography) and PET (positron emission tomography) scans; and neuropsychology testing. In patients who are being considered for epilepsy surgery, additional tests, including a Wada test (see the next subsection), are often performed.

Let's briefly discuss some of the individual causes of seizures listed in Table 18.11. The most common causes vary with age, resulting in a bimodal age distribution for the risk of developing new-onset seizures. The risk of new-onset seizures is high in infancy and childhood, declines in adulthood, and then rises again in the elderly population. The most common causes of seizures in infancy and childhood are **febrile seizures, congenital disorders,** and **perinatal injury.** In contrast, the most common cause in patients over age 60 years is **cerebrovascular disease,** followed by **brain tumors** and **neurodegenerative conditions.**

The risk of seizures after **head trauma** increases with the severity of the injury. Minor head injuries with no clear structural damage and only brief confusion or loss of consciousness (for less than 30 minutes) do not pose a significant risk for subsequent seizures. **Hypoglycemia, electrolyte abnormalities** such as hyponatremia, hypernatremia, hypocalcemia, or hypomagnesemia; **metabolic abnormalities** or exposure to a variety of endogenous or exogenous **toxic substances** can provoke seizures. It is therefore essential to check blood chemistries, including glucose, sodium, calcium, magnesium, liver function tests, creatinine, and a toxicology screen when assessing a patient with new-onset seizures, especially in the acute setting, so that these abnormalities can be corrected.

Febrile seizures are fairly common, occurring in 3 to 4% of all children, usually between the ages of 6 months and 5 years. These are usually brief, generalized tonic-clonic seizures called **simple febrile seizures**, which are not associated with increased risk of epilepsy. However, there is an increased risk of subsequent epilepsy in children with **complex febrile seizures**, defined as seizures lasting more than 15 minutes, or occurring more than once in 24 hours, or having focal features. Some of these children may have an underlying cause for epilepsy that is first unmasked in the setting of fever. It has also been hypothesized that prolonged febrile seizures cause subsequent temporal lobe epilepsy in some patients, through a pathologic process called **mesial temporal sclerosis** or **hippocampal sclerosis**, in which there is marked neuronal loss and gliosis, particularly in the CA1 sector of the hippocampus, as well as in other medial temporal structures. In addition to febrile seizures, mesial temporal sclerosis may also be triggered by other initial precipitating injuries in infancy and childhood, such as head trauma or

TABLE 18.11 Causes of Seizures[a]

Head trauma
Cerebral infarct
Intracerebral hemorrhage
Vascular malformation
Cerebral venous thrombosis
Anoxia
Mesial temporal (hippocampal) sclerosis
Electrolyte abnormalities
Hypoglycemia
High fever
Toxin exposure
Alcohol, benzodiazepine, or barbiturate withdrawal
Meningitis
Encephalitis
Brain abscess
Vasculitis
Neoplasm
Inborn error of metabolism
Neuronal migrational abnormality
Hereditary epilepsy syndrome
Neurodegenerative disorder
Nonepileptic seizures[b]

[a]Following format of Figure 1.1.

[b]Formerly called "pseudoseizures," these include psychogenic episodes, syncopse, arrhythmias, and other causes of nonepileptic transient episodes listed in Table 10.2.

CNS infections. Once established, there is often a latent period of up to several years between the precipitant and the onset of complex partial seizures. The seizures usually consist of a hard-to-describe aura of fear or epigastric sensation and other features typical of medial temporal lobe seizures (see Table 18.9). Once treated with anticonvulsant medications, seizures in patients with mesial temporal sclerosis rarely generalize. However, the complex partial seizures in these patients can be quite incapacitating, and are often associated with memory decline. In addition, unlike the tonic-clonic seizures, the complex partial seizures in these patients are often medically refractory. Based on the diagnostic methods discussed earlier, unilateral surgical resection of the medial temporal lobe structures has a cure rate of over 90% in patients with seizures localized to one temporal lobe.

Numerous other causes of **focal brain lesions,** some of which are listed in Table 18.11, can result in seizures, and many can be detected by a good-quality MRI scan. **Family history** is also essential in assessing patients with seizures. Many epilepsy syndromes, especially primary generalized epilepsies, but also some focal disorders, have a genetic component. **Rolandic epilepsy** is a common cause of focal, mostly nocturnal seizures in children that probably has autosomal dominant inheritance with incomplete penetrance. The EEG shows characteristic **centrotemporal spikes.** Onset is usually between ages 3 and 13 years, and seizures are often mild, not always requiring medications. Remission is nearly always complete by age 15 years.

There are several familial **primary generalized epilepsy** syndromes, including **childhood absence epilepsy** (pyknolepsy), characterized by typical absence seizures (discussed earlier), **juvenile myoclonic epilepsy,** and other disorders. For a more detailed discussion of the many other causes of epilepsy, see the references at the end of this chapter.

Treatment

The basic goals of epilepsy treatment are to reduce the risk of seizures while minimizing side effects, to achieve the best possible overall quality of life. Major considerations include impact on driving (regulations vary from state to state), ability to work, the unfortunate public stigma associated with seizures, and effects on pregnancy and lactation. **Medications** can be used to achieve satisfactory control of seizures in over 70% of cases. The first-line agents for treatment of localization-related epilepsy, with or without secondary generalization, are carbamazepine (Tegretol) or phenytoin (Dilantin). For childhood absence epilepsy, the first-line agent is ethosuximide (Zarontin). If treatment with ethosuximide is unsuccessful, or if grand mal seizures are present as part of a primary generalized epilepsy syndrome, valproate (Depakote) is preferred. After a period of over 15 years in which no major new anticonvulsant medications were introduced in the United States, the pharmaceutical industry began in 1993 to reinvest in anticonvulsant medications. An average of 1 to 2 new anticonvulsants per year have appeared on the market since that time. Many of these new anticonvulsants have advantages over the medications already discussed, although the newer medications are still not typically used for first-line therapy (see References for additional details on epilepsy medications).

About 20 to 30% of patients with epilepsy have seizures that cannot be adequately controlled with medications and are considered **medically refractory.** Some children with refractory epilepsy may improve on a high-fat, low-carbohydrate **ketogenic diet,** but the effect is often temporary and the diet is hard to maintain in the long term. For unknown reasons, chronically implanted **vagal nerve stimulators** seem to reduce seizure frequency in some patients; however, only rarely do the seizures stop completely with this device. As we have discussed in this chapter and in Chapter 14, vagal afferents reach the nucleus solitarius (see Figures 12.12, 14.5A,B) and are relayed to the limbic system and other forebrain structures via the parabrachial nucleus of the pons (see Figure 14.4A). The mechanisms by which vagal stimulation appears to raise seizure threshold are still under active investigation. Other methods of neurostimulation, such as chronically implanted thalamic stimulators, are also being investigated for the treatment of epilepsy.

Many patients with medically refractory epilepsy are candidates for **epilepsy surgery.** In the ideal candidate for epilepsy surgery, seizures always start in the same location, and this location can be safely resected without creating deficits. The best surgical outcome statistics are seen for patients with unilateral medial temporal lobe epilepsy, in which surgery controls seizures in 90% or more of cases, depending on the study. Prior to epilepsy surgery, patients undergo a detailed evaluation and education process, and recommendations to the patient for or against surgery are usually based on a multidisciplinary team approach.

In attempting to localize the region of onset, no single test is definitive. Therefore, combined information is used from each of the diagnostic tests listed in the previous section. In addition, an **angiogram Wada test** is often helpful in planning surgery. In this test the sedative agent sodium amytal is injected through an angiographic catheter (see Figure 4.9) directly into each common carotid artery, causing transient inhibition of the injected hemisphere for approximately 10 minutes. After each injection, **language** is tested, and the presence or absence of aphasia is used to localize which hemisphere is dominant for language so that language areas can be avoided during surgery.

In addition, **memory** is tested after each injection. In patients with normal bilateral medial temporal memory function, injection of one hemisphere does not eliminate memory, since the other hemisphere can compensate. However, when a medial temporal lobe is not functioning properly, as is often the case in patients with medial temporal epilepsy, injection of the contralateral hemisphere causes severe memory difficulties. Preserved memory with injection of the hemisphere ipsilateral to seizure onset is reassuring because it suggests that the contralateral hemisphere will be able to support memory function after the ipsilateral medial temporal structures are resected. Note that in the Wada test, amytal is injected into the common carotid artery, which in most individuals perfuses the anterior (ACA) and middle (MCA) cerebral artery territories, but not the posterior cerebral artery (PCA) territory (see Figures 4.16, 4.17). Since the medial temporal structures are perfused by the PCA, it is not immediately obvious why the Wada test should inhibit medial temporal function. The most likely explanation is that the large ACA/MCA injection inhibits most of the hemispheric cortex, white matter, and corpus callosum, thereby indirectly inhibiting the medial temporal lobe by cutting off its major sources of input.

When these tests are all concordant, suggesting seizure onset in a single area, surgical resection can be contemplated. However, when there are discrepancies in localization between different tests, **intracranial EEG monitoring** can be employed to record seizure activity directly from the brain. Multicontact subdural electrodes are used to record from the cortical surface, and depth electrodes are used to record from deep structures, such as the hippocampus.

In appropriately selected candidates, several different surgical approaches can be used to treat medically refractory epilepsy. As we have already mentioned, the best candidates for **focal surgical resection** have epilepsy localized to a single temporal lobe; these patients have a surgical success rate of over 90%. Patients with confirmed localization to a single location other than the temporal lobe can also often be treated successfully

with surgical resection. For these patients with extratemporal epilepsy, the best outcomes are usually seen when all diagnostic studies point to a single location; however, certain other features may also predict a favorable prognosis, including a focal lesion visible on MRI scan or seizure onset in the supplementary motor area. Surgery is considered successful if patients no longer have seizures and have no adverse effects from the surgery. Although many patients must continue anticonvulsant medications following surgery to maintain freedom from seizures, this is still a major lifestyle improvement for patients who, prior to surgery, had frequent seizures even with medications. Following successful surgery, for example, many previously disabled patients are able to drive and to pursue productive employment.

In some patients, the region of seizure onset lies in a functionally critical area such as the motor or language cortex, and surgical resection cannot safely be performed. In these patients, **multiple subpial transection** may be helpful. In this procedure, a special sharpened probe is inserted under the pia and is used to sever the cortical–cortical connections, thereby making multiple parallel tracts that functionally disconnect the epileptogenic cortex. Patients with severe epilepsy arising from multiple locations in the brain may benefit from **callosotomy.** In this procedure, the corpus callosum is cut, preventing seizures from propagating from one hemisphere to the other. Callosotomy does not cure seizures. The procedure is reserved mainly for patients who have frequent falls and injuries when their seizures generalize. These patients may be helped if generalization is prevented, by allowing them to avoid such falls during seizures. Deficits associated with callosotomy are discussed in KCC 19.8.

In some patients, the seizure onset is not localized to a specific region but rather to multiple regions within a single hemisphere. In patients younger than 2 to 3 years, hemispheric specialization is still under development. Therefore, in some of these patients, **hemispherectomy** (surgical removal of an entire hemisphere) can be considered. Remarkably, many patients do quite well following hemispherectomy and are able to lead functional lives. Seizures are often cured, allowing language and motor development (often arrested by severe epilepsy) to proceed, with language and motor representations for both sides of the body forming in the single remaining hemisphere.

In summary, the majority of patients with epilepsy can be successfully treated with either medications or other therapies discussed here and are able to resume their normal lives. ■

KEY CLINICAL CONCEPT
ANATOMICAL AND NEUROPHARMACOLOGICAL BASIS OF PSYCHIATRIC DISORDERS

18.3 The neurobiological basis of many psychiatric disorders is beginning to be better understood through a convergence of information derived from pathologic and anatomical imaging studies, functional imaging studies, neuropharmacological analysis, and other methods of investigation, such as molecular genetics. In this section we will briefly discuss some of the major pathophysiological findings for a few common psychiatric disorders on a basic level.

Schizophrenia

Patients with schizophrenia exhibit a variety of abnormalities of thought, including delusions, hallucinations, disorganized tangential speech, flat affect, and occasionally a profound decrease in spontaneous activity called catatonia. Studies of the pathophysiology of schizophrenia have suggested abnormalities in the limbic system, frontal lobes, and basal ganglia. Both pathologic studies and high-resolution MRI have demonstrated bilateral subtle decreases in the volume of the amygdala, hippocampal formation, and parahippocampal gyrus in patients with schizophrenia. More variable anatomical changes have also been reported in the basal ganglia and other regions. Functional imaging studies such as PET scanning have shown decreased activation of the dorsolateral prefrontal cortex in patients with schizophrenia during tasks such as the Wisconsin Card Sorting Test. Much evidence suggests that an abnormality in dopamine is important in schizophrenia; for example, psychotic symptoms improve with antidopaminergic agents.

Recall from Chapter 16 that dopaminergic neurons in the ventral tegmental area project to the nucleus accumbens and ventral striatum, as well as to the prefrontal cortex and limbic cortex (see also Figure 14.10). Some other neurotransmitters may be important as well in the pathogenesis of schizophrenia, including glutamate, gamma-aminobutyric acid (GABA), serotonin, and norepinephrine. A complete pathophysiological understanding of schizophrenia is complicated by the fact that this disorder can include both positive symptoms such as psychotic delusions and hallucination, and negative symptoms such as flat affect and impaired executive function. The most likely cause of schizophrenia is a combination of abnormalities in several anatomical areas and neurotransmitter systems.

Obsessive-Compulsive Disorder

In obsessive-compulsive disorder, recurrent intrusive obsessive thoughts cause the patient much anxiety, while the performance of repetitive compulsive behaviors such as hand washing or checking the door lock provide temporary relief. The improvement of obsessive-compulsive symptoms with serotonin-enhancing medications suggests a role for serotonin in this disorder; however, other neurotransmitters may be important as well. Functional imaging studies have shown abnormally increased activity in the basal ganglia, especially the head of the caudate, as well as in the anterior cingulate gyrus and orbitofrontal cortex. These changes improve with pharmacological or behavioral treatment.

MRI studies have shown a subtle bilateral decreased volume in the head of the caudate, but these findings are not conclusive. Thus, obsessive-compulsive disorder appears to result from dysfunction in a network consisting of the caudate, cingulate gyrus, and orbitofrontal cortex. This may be analogous to hyperkinetic movement disorders (see Chapter 16), but with unwanted thoughts or compulsions instead of movements. Indeed, there may be some overlap, since obsessive-compulsive disorder is present in about half of patients with Tourette's syndrome and can also occur in Huntington's disease, Sydenham's chorea, and other basal ganglia disorders.

Anxiety

Anxiety disorders encompass a variety of conditions, including panic disorder, phobias, posttraumatic stress disorder, and generalized anxiety disorder. Obsessive-compulsive disorder is also classified as an anxiety disorder. Anxiety is thought to be associated with an increase in noradrenergic and serotonergic transmitter systems in the central nervous system. In addition, anxiety symptoms can be controlled with benzodiazepines, which act on $GABA_A$ receptors. Symptoms of anxiety, panic, and fear are also accompanied by increased peripheral sympathetic tone and increased release of epinephrine by the adrenal glands. Functional imaging studies during episodes of panic have shown inconsistent results, but they may demonstrate increased activation in the anterior cingulate and temporal cortices. Evidence from patients with panic as an epileptic phenomenon suggests involvement of the amygdalar region of the medial temporal lobes.

Depression and Mania

Patients with depression have a sad mood and lack of enjoyment, together with other findings, such as impaired concentration, increased or decreased

sleep, appetite, or level of activity, and feelings of worthlessness, guilt, and suicidal thoughts or actions. In contrast, patients with mania have an abnormally elevated, irritable mood, with other features including grandiosity, decreased sleep, pressured speech, racing thoughts, distractibility, increased activity, and impulsive behavior. A variety of evidence suggests that depression is marked by deficits in both the noradrenergic and serotonergic neurotransmitter systems. Other transmitters may be important as well, including dopamine, amino acid neurotransmitters, and neuropeptides.

Structural and functional neuroimaging studies in depression have produced contradictory results, but there is some evidence of a global decrease in activity of the cerebral cortex, with a more prominent decrease in the frontal lobes. Neuroendocrine changes occur in depression as well, including an increased release of cortisol in about 40% of patients with depression, resulting from excessive release of corticotropin-releasing hormone by the hypothalamus. The effects of brain lesions on mood have also shed some light on possible mechanisms for mood disorders. Some studies suggest that left frontal lesions are more likely to produce a depressed mood, while right frontal lesions tend to produce an abnormally elevated mood, although these associations are not absolutely consistent. Similarily, bilateral lesions of the dorsolateral prefrontal cortex tend to produce a flat affect resembling depression (see KCC 19.11), while bilateral lesions of the medial orbitofrontal cortex may produce an abnormally elevated affect. ■

CLINICAL CASES

CASE 18.1 SUDDEN MEMORY LOSS AFTER A MILD HEAD INJURY

MINICASE

A 33-year-old neurology resident with a history of migraine fell backward while attempting a ski jump, struck his occiput on the snow, and suddenly developed amnesia. His wife witnessed the incident and reported that he had not lost consciousness from the fall. He stood himself up, skied part way down the slope, and then stopped skiing to tell his wife that he must have amnesia because he did not know the date, where he was, or how he had gotten there. He also reported seeing a scintillating scotoma in the left upper part of his visual field, like that accompanying his typical migraines.

At first his wife thought he was joking around, but when he began **asking the same questions repeatedly**, it soon became clear that he had a serious problem. He was **unable to retain any new information for more than 1 to 2 minutes.** In addition, **he did not recall any events that had occurred during the previous approximately 1 year**, including the fact that his wife was pregnant. Aside from the memory loss, he had no other significant deficits. He was taken to a local hospital, where a head CT was normal, and he was discharged in the care of his wife and friends. Being a neurologist, he constantly urged those around him to test his memory during the long car ride home. Meanwhile, he was able to enjoy the exciting "news" that his wife was pregnant, over and over again. Approximately 5 hours after onset, he was finally able to recall three words after a 3- to 4-minute delay, but this ability was still inconsistent. At about the same time, memories from the previous year began to return gradually, with the **most remote memories generally returning first**. By the next morning he was able to consistently recall new facts about as well as at baseline. In addition, he remembered everything from the previous year, except for a period extending from 2 to 3 hours before the injury to about 5 hours after the injury. An MRI scan performed a few days later was normal.

LOCALIZATION AND DIFFERENTIAL DIAGNOSIS

1. On the basis of the symptoms and signs shown in **bold** above, what type of memory was impaired in this patient? How would you describe the chronological features of his amnesia? Dysfunction in which locations in the brain could produce these findings (see KCC 18.1)?
2. What is the most likely diagnosis, and what are some other possibilities?

Discussion

The key symptoms and signs in this case are:

- **Inability to retain any new information for more than 1 to 2 minutes, and asking the same questions repeatedly**
- **Inability to recall any events that had occurred during the previous approximately 1 year**
- **During recovery, return of the most remote memories generally first**

1. The patient was unable to remember facts and events; therefore, he had a deficit in declarative (explicit) memory (see Figure 18.15). He had anterograde amnesia, since he was unable to learn new information, and retrograde amnesia for a period of about 1 year prior to the injury (see Figure 18.16). This pattern of selective declarative memory loss with anterograde and retrograde amnesia is characteristic of bilateral medial temporal or bilateral medial diencephalic dysfunction (see KCC 18.1). Asking the same questions repeatedly is also typical of acute dysfunction in these areas, and recovery of remote memories prior to more recent ones is often seen when the memory loss is reversible.

   The most likely *clinical localization* is bilateral medial temporal or bilateral medial diencephalic structures.
2. Given the onset after a head injury, concussion must be considered as the cause of amnesia in this patient (see KCC 18.1; see also KCC 5.5). No loss of consciousness was observed; however, it may have been too brief to be noticed. Interestingly, it is unclear whether concussion causes amnesia due to direct impact to the medial temporal structures, or whether the mechanism is diffuse dysfunction of the white matter pathways necessary for normal function of the medial temporal and medial diencephalic memory systems.
3. Alternatively, the clinical features of the memory loss and recovery in this patient could represent transient global amnesia (see KCC 18.1) that occurred coincidentally following a minor head injury. The onset in the setting of stress and history of migraine are also suggestive of this diagnosis, as are the typical migraine symptoms of a scintillating scotoma (see KCC 5.1) reported by the patient during the episode. Other causes of transient amnesia, which are less likely, given the history in this patient, include transient ischemic attack, seizure, Wernicke's encephalopathy, psychogenic amnesia, or administration of a benzodiazepine or other medication (see Table 18.7).

Clinical Course

The patient resumed work a few days later and had no further episodes of amnesia. On follow-up over 5 years, he had no deficits except for continued lack of memories for the period of a few hours before and after onset of his amnesia.

CASE 18.2 PROGRESSIVE SEVERE MEMORY LOSS, WITH MILD CONFABULATION

MINICASE

A 75-year-old semiretired businessman was brought to the emergency room by his friends because of several weeks of **severe progressive memory problems.** At baseline, the patient had normal cognition, exercised avidly, and maintained an active schedule, driving himself to appointments with friends and business associates. Ten days prior to admission he met a friend for lunch and had a normal, clear, precise conversation, except that he did not remember the name of the hostess, whom he had known for several years. Four days later, the same friend spoke with the patient on the phone and discovered that the patient had no recollection of having lunch or of any of their conversation. He seemed normal otherwise. The next day the patient missed an important business meeting. When the patient's son contacted him over subsequent days, his conversation seemed appropriate except that he was totally unaware of current events, including a recent highly publicized plane crash. There was no known history of alcoholism.

Exam was normal except for **profound problems with recent memories and milder problems with remote memories.** He said the year was 1964 (it was 1994) and realized he was in a hospital but did not know which one. Attention and immediate recall were normal, with a digit span forward of 7 and backward of 5. He was able to repeat three words immediately when asked to memorize them. After 3 minutes, however, he did not even recall the task, and he got 0/3 words correct even with multiple choice. When the examiner left the room and came back a few minutes later, the patient had no recollection of having met him before.

The patient had no knowledge of recent current events and was completely unaware of the highly publicized O. J. Simpson trial going on at the time. More remote memory was better but still not perfect. For example, he was able to describe his hometown, childhood, family members, marriage, and the fact that he had fought in World War II. However, he could not recall any battles he fought in, and he was surprised to hear that John F. Kennedy had been shot. He did not know that Johnson and Nixon were presidents during the Vietnam War, or that his wife had died a few years back. With some prompting, however, he was able to generate the name of the current president: "Clinton." There was also a mild **tendency to confabulate.** For example, when asked why he was in the hospital, he said he "came here to pick up some things and leave," and when asked if anyone had visited him, he mentioned several names despite having had no visitors. The remainder of the mental status exam was normal, including normal attention span (see above), pleasant affect and behavior, normal language, good calculations, normal reading and writing, normal drawing of a clock face and cube, and good interpretation of similarities and proverbs. The rest of the neurologic exam was likewise normal.

LOCALIZATION AND DIFFERENTIAL DIAGNOSIS

1. On the basis of the symptoms and signs shown in **bold** above, where is the lesion?
2. What is the most likely diagnosis, and what are some other possibilities?

Discussion

The key symptoms and signs in this case are:

- **Severe progressive problems with recent memory and milder problems with remote memory**
- **Tendency to confabulate**

1. As in Case 18.1, this patient had anterograde and retrograde amnesia affecting declarative memory, which could be caused by dysfunction of the bilateral medial temporal or bilateral medial diencephalic structures (see KCC 18.1). Unlike the patient in Case 18.1, however, this patient also had a mild tendency to confabulate. This symptom suggests additional dysfunction affecting the frontal lobes (see KCC 19.11).

2. The time course of the memory decline in this patient was too rapid to be a neurodegenerative disorder such as Alzheimer's disease, which progresses over months to years, rather than over weeks as in this case (see KCC 19.16). Wernicke–Korsakoff syndrome resulting from thiamine deficiency should be considered, since this disorder causes declarative memory loss, often with confabulation (see KCC 18.1). However, there was no known alcoholism or nutritional deficiency in this case, and onset in Wernicke–Korsakoff syndrome is often more abrupt. Given the insidious onset, other important possibilities to consider, among those listed in Table 18.7, include tumor, paraneoplastic limbic encephalitis, or other inflammatory or infiltrative disorders affecting the bilateral medial temporal or medial diencephalic structures and extending to the frontal lobes. Other, less likely possibilities include an anterior communicating artery aneurysm that had a small hemorrhage followed by a larger hemorrhage, or several transient ischemic attacks or small infarcts followed by a larger infarct.

Clinical Course and Neuroimaging 808

The patient was given thiamine with no benefit and was admitted to the hospital, where a **brain MRI** with gadolinium (Figure 18.18) revealed markedly abnormal enhancement in the bilateral medial temporal lobes, including the anterior hippocampal formations and amygdalae. In addition, there was less dramatic enhancement in the fornix, bilateral periventricular region of the third ventricle, and foramina of Monro (see Figure 18.18B) and extending to the bilateral basal forebrain and medial orbitofrontal cortex (see Figure 18.18C). Several lumbar punctures (see KCC 5.10) and blood tests were done but did not yield a diagnosis. A follow-up examination revealed that the patient had **lost his sense of smell,** suggesting that the lesion had spread to involve adjacent olfactory structures such as the bilateral piriform cortex or olfactory bulbs (see Figures 18.5, 18.6). Over the course of several days he became more disoriented, stating that his location was "Israel," and he responded more slowly to questions. This change raised concerns about more diffuse spread, and a stereotactic biopsy (see KCC 16.4) of the right orbitofrontal cortex was therefore done. Pathologic examination revealed an atypical-appearing B cell lymphoma (see KCC 5.8).

The patient was treated with steroids and multiple cycles of intravenous chemotherapy with methotrexate and had a dramatic improvement in his memory. One month after diagnosis he was able to recall 3/4 words at 5 minutes, and 4/4 with hints. Formal neuropsychology testing revealed that he still had some subtle residual memory deficits in both verbal and visual-spatial domains. Repeat MRI scan 3 months after diagnosis showed complete disappearance of the enhancing lesions, and the patient had resumed most of his previous activities. He continued chemotherapy, and at last follow-up, 15 months after diagnosis, he was doing well, recalling 3/3 words after 10 minutes.

CASE 18.3 TRANSIENT DIPLOPIA, LETHARGY, AND HEMIPARESIS, FOLLOWED BY A SUSTAINED MEMORY DEFICIT

MINICASE

A 45-year-old right-handed research technician woke up late for work one morning and noticed that he had **horizontal diplopia,** which disappeared if he covered either eye. His wife found him in the bathroom with his head resting on the sink. She helped him back to bed and thought he seemed **unusually somnolent, with slurred speech,** so she called 911. In the emergency room the patient was initially back to baseline, but then he had a **transient episode of right-sided weakness** lasting approximately 30 minutes. Neurologic exam, after he recovered from this episode, was entirely normal except for a **deficit in recent memory.** He was alert and oriented × 3, with good attention, spelling "world" forward and backward correctly, and he knew the names of the past three presidents. However, he **recalled 0/3 words after 3 minutes.**

LOCALIZATION AND DIFFERENTIAL DIAGNOSIS

1. Dysfunction in which part of the brain could account for all of the transient symptoms listed in **bold** above (excluding the memory loss)?
2. In what locations could a lesion produce memory loss as described in this case?
3. What is the most likely diagnosis, and what are some other possibilities?

Discussion

The key symptoms and signs in this case are:

- **Horizontal diplopia**
- **Somnolence**
- **Dysarthria**
- **Transient right-sided weakness**
- **Deficit in recent memory**

1. Horizontal diplopia, together with somnolence and dysarthria, strongly suggest brainstem dysfunction involving, respectively, horizontal eye movement pathways (see KCC 13.8), the pontomesencephalic reticular activating systems (see KCC 14.2), and corticobulbar or cerebellar pathways (see KCC 14.3). The episode of transient right-sided weakness could also be explained by involvement of brainstem corticospinal fibers (see KCC 6.3, 14.3). These abnormalities together suggest dysfunction of the medial pons (abducens fascicles or nucleus, paramedian pontine reticular formation, or medial longitudinal fasciculus; reticular activating systems; corticobulbar or pontocerebellar fibers; and corticospinal tract), or of the midbrain (oculomotor fascicles or nucleus, convergence center, or medial longitudinal fasciculus; reticular activating systems; corticobulbar, corticopontine, or rubropontine fibers; and corticospinal tract). Note that horizontal diplopia with no vertical component, and hemiparesis, are more common with pontine than with mesencephalic lesions (see KCC 14.3).
2. After recovering from the initial transient episode, this patient had anterograde amnesia for declarative memories. He was more mildly affected than the patients in Cases 18.1 and 18.2, since he was able to remember some recent information, such as his location and the correct date. Some retrograde amnesia may have been present as well, although this was not specifically described. This patient's deficit in declarative (explicit) memory, with preserved attention and other cognitive skills, suggests bilateral medial temporal or bilateral medial diencephalic dysfunction (see KCC 18.1).
3. The transient neurologic symptoms in this patient (see KCC 10.3) affecting the pons or midbrain were most likely caused by transient ischemic attack, or possibly migraine. Given this, the sudden onset of a permanent memory deficit suggests that the transient episodes heralded a subsequent infarct in the medial temporal lobes or diencephalon. Together these findings could indicate a "basilar scrape" syndrome (see KCC 14.3), with an embolus migrating up the basilar artery causing transient symptoms as various penetrators were temporarily occluded, followed by an infarct when the embolus lodged at the top of the basilar, obstructing bilateral thalamoperforator arteries or branches of the bilateral PCAs supplying both medial temporal lobes.

Clinical Course and Neuroimaging BH

A head CT revealed no hemorrhage or infarct, and the patient was admitted and treated with intravenous heparin while an embolic workup was pursued. A **brain MRI** done the day after admission (Figure 18.19) showed bilateral T2-bright areas consistent with infarcts in both medial thalami, larger on the left than on the right side. An magnetic resonance angiogram, echocardiogram, and 24-hour cardiac Holter monitor were negative. However, a hypercoagulation profile showed activated protein C resistance, a disorder that can predispose affected individuals to blood clot formation. Heparin was therefore changed over to oral anticoagulation with Coumadin by the time of discharge. By hospital day 2 the patient was able to recall 3/5 words after 5 minutes.

Neuropsychology testing was done on hospital day 3 and repeated on hospital day 5. Subtests of the Wechsler Memory Scale—Revised were used to test verbal and visual memory. To test verbal memory, two paragraphs were read to the patient, and he was scored on his ability to recall items from the paragraphs immediately after they were read and after a 20-minute delay. To test visual memory, the patient was shown three cards with printed geometric designs, and he was scored on his ability to draw the designs from memory immediately and after a 20-minute delay. The results are shown in the table below.

Results of the Wechsler Memory Scale Test[a]

	Hospital day 2	Hospital day 5
Verbal memory		
Immediate	**1%**	21%
Delayed	**2%**	**8%**
Visual memory		
Immediate	50%	72%
Delayed	**16%**	45%

[a]Scores are expressed as the percentile of the normal population. Scores that were significantly lower than the normal range are shown in bold.

On hospital day 2 the patient had severe deficits in verbal memory and a barely significant deficit in delayed visual memory. On hospital day 5, he continued to have a significant deficit in delayed verbal memory. The discrepancy between verbal and visual memory in this patient was likely due to the larger lesion on the left side (see Figure 18.19). Similar discrepancies are seen in patients with asymmetrical lesions in medial temporal memory structures.

Repeat neuropsychology testing 2 months later showed further improvements in his verbal memory. At a follow-up appointment 6 months after the stroke, he was still able to recall only 3/5 words after 5 minutes, but he was back to his previous level of activity at work, and he was not aware of any language or memory difficulties.

CASE 18.4 EPISODES OF PANIC, OLFACTORY HALLUCINATIONS, AND LOSS OF AWARENESS

MINICASE

A 40-year-old right-handed woman came to the emergency room because of unusual episodes. She had been healthy until 2 weeks previously, when she awoke one night from sleep and complained to her husband of an **indescribable unpleasant odor, nausea, and a panicky, fearful sensation.** This lasted for 2 to 3 minutes, after which she felt very tired and went back to sleep. During the following week, while traveling with a Girl Scout troup, she began having stereotyped episodes about three times per day. These always began with panic, nausea, and a strong unpleasant odor "like smelling salts," followed by **decreased responsiveness and slow, inappropriate speech** lasting 2 to 3 minutes. After each episode she had a bifrontal headache and felt very tired. On the day of presentation, she had six episodes of this kind, so her husband brought her to the emergency room. General exam and a detailed neurologic exam were normal.

LOCALIZATION AND DIFFERENTIAL DIAGNOSIS

1. On the basis of the symptoms shown in **bold** above, where in the brain is dysfunction occurring during the episodes?
2. What type of transient neurological episodes was this patient most likely experiencing (see KCC 10.3).
3. What is the most likely diagnosis, and what are some other possibilities?

Discussion

The key symptoms and signs in this case are:

- **Episodes of an indescribable unpleasant odor, nausea, and a panicky, fearful sensation**
- **Decreased responsiveness and slow, inappropriate speech**

1. Episodes of olfactory phenomena, nausea, and panic could arise from dysfunction in the amygdala and adjacent cortex in the medial temporal lobe. Decreased responsiveness can be caused by dysfunction of the brainstem–diencephalic activating systems or of bilateral diffuse regions of the cerebral hemispheres (see KCC 14.2). The slow, inappropriate speech could either signify involvement of language areas in the left hemisphere (see KCC 19.6), or it could be secondary to the impaired responsiveness, as already mentioned.

   The overall *clinical localization* in this patient is focal dysfunction of the amygdala and adjacent cortex (most likely of the left hemisphere), as well as milder, more diffuse dysfunction of both hemispheres or of the activating systems.
2. The transient episodes in this patient (see KCC 10.3) could be caused by seizures arising from the medial temporal lobe. Since there was decreased responsiveness, these events would be classified as complex partial seizures (see KCC 18.2). Additional support for this diagnosis comes from the fact that the episodes were stereotyped, had the appropriate duration for complex partial seizures, and were followed by post-ictal lethargy and headache. The slow, inappropriate speech may have been caused by language dysfunction resulting from spread of left mesial temporal–onset seizures to the left lateral temporal neocortex. However, since the patient was not examined during an actual seizure, one cannot exclude speech difficulties simply caused by decreased responsiveness.

   Psychogenic episodes, such as panic attacks, could also be considered in this case (see Table 18.11). However, panic attacks are not accompanied by olfactory phenomena, usually last longer, and do not have post-ictal deficits. Other causes of transient neurologic episodes listed in Table 10.2, such as migraine or transient ischemic attack, are also unlikely to have this time course or to be accompanied by positive olfactory phenomena.
3. Numerous focal lesions in the medial temporal lobe could produce seizures of the type seen in this patient (see Table 18.11). The most likely possibilities in a 40-year-old woman are a tumor such as glioblastoma, metastatic breast or lung cancer, other neoplasms (see KCC 5.8), a bacterial brain abscess, toxoplasmosis, cysticercosis (see KCC 5.9), vascular malformation, previous head trauma, sarcoidosis, or other infectious or inflammatory disorders. For unknown reasons, neuronal developmental disorders can sometimes present with seizure onset in adulthood. Onset at age 40 years would be older than usual, but not impossible. In mesial temporal (hippocampal) sclerosis, seizure onset is typically at a younger age than in this patient, there is often an initial precipitating injury such as prolonged febrile seizures in childhood, and olfactory auras are not commonly present.

Clinical Course and Neuroimaging B13

A head CT with contrast was performed in the emergency room, and a subsequent **brain MRI** with gadolinium confirmed the presence of a large enhancing mass in the left anterior temporal lobe, involving the amygdala (Figure 18.20A) and extending to the left orbitofrontal region (Figure 18.20B). Note that the mass had a heterogeneous, hypointense center, suggesting central necrosis. There was also surrounding hypointensity on T1-weighted images, with effacement of the Sylvian fissure and temporal horn, consistent with edema and mass effect (see Chapter 4). This appearance was felt to be most compatible with a glioblastoma multiforme, or less likely a metastasis or other tumor. The patient was started on the anticonvulsant medication phenytoin, which stopped her seizures, and she underwent a surgical resection of the left anterior temporal lobe. Pathology revealed a glioblastoma multiforme (see KCC 5.8). She was treated with radiation therapy and multiple cycles of chemotherapy. On this regimen she remained stable for a while, but then she developed progressive deficits as the tumor grew. At last follow-up, 9 months after presentation, she was lethargic and disoriented, with a right visual field cut and right-sided hemiparesis (2/5 to 3/5 strength). Glioblastoma multiforme, unfortunately, remains a relatively common, yet incurable brain tumor.

CASE 18.2 PROGRESSIVE SEVERE MEMORY LOSS, WITH MILD CONFABULATION

Figure 18.18 Bilateral Medial Temporal Lymphoma
T1-weighted MRI scan with intravenous gadolinium.

(A) Axial image. (B,C) Coronal images progressing from posterior to anterior.

(A)

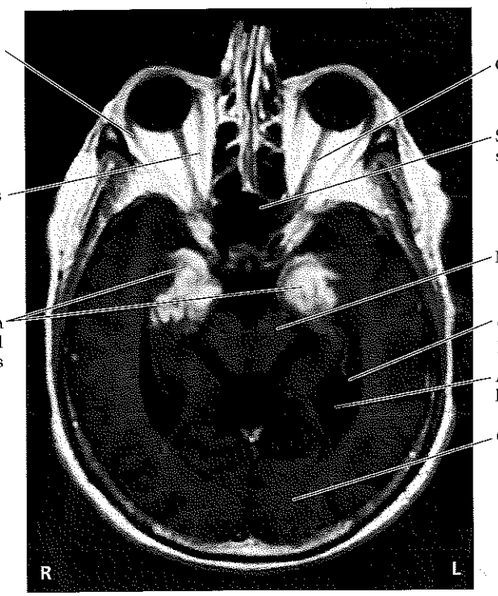

(B)

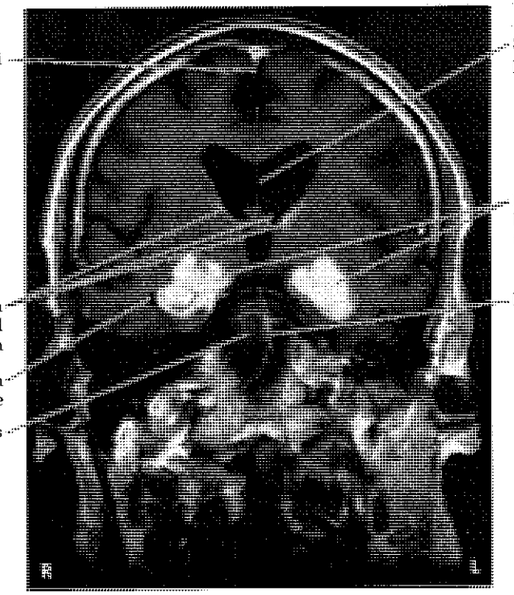

CASE 18.2 *(CONTINUED)*

(C)

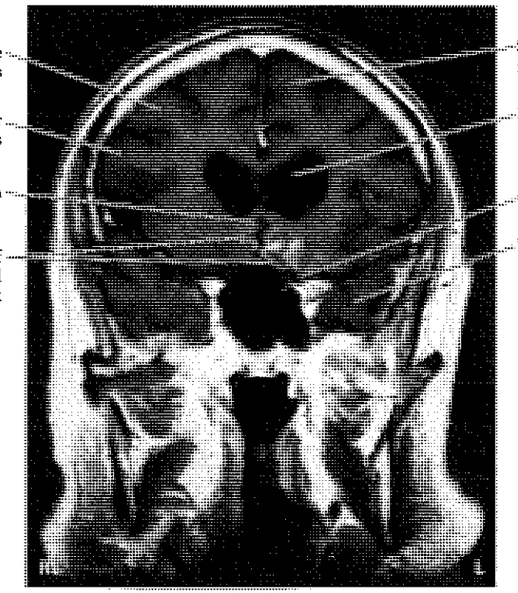

CASE 18.5 EPISODES OF STARING, LIP SMACKING, AND UNILATERAL SEMIPURPOSEFUL MOVEMENTS

MINICASE

A 26-year-old right-handed woman was evaluated at an epilepsy referral center for medically refractory seizures. She was the product of a normal birth and delivery, but at age 9 months she had two prolonged febrile seizures in one day. These consisted of generalized tonic-clonic activity, with the first seizure lasting nearly 2.5 hours and the second seizure, after arrival in the hospital, lasting about 1 hour. She was treated with anticonvulsant medications, which initially stopped the seizures. Within a few years, however, she began having stereotyped episodes that continued into adulthood and were refractory to multiple medications. Her episodes typically began with an **aura of a "vague" and "scary feeling,"** followed by **loss of awareness.** Her mother has witnessed many of her seizures and described her as next having **staring, unresponsiveness, lip smacking, rigid posturing of the left arm, and groping, purposeless movements of the right arm lasting for about 1 minute.** Sometimes she **spoke during the episodes without grammatical errors,** but what she said was inappropriate for the questions being asked. Post-ictally she was **fatigued and somewhat confused but had no other deficits.** These episodes occurred two to three times per week, occasionally up to three times per day. She also had occasional isolated auras, without progression to full-blown episodes.

Her longest seizure-free interval in adulthood was about 3 months. Rarely (at intervals of greater than about 3 to 5 years), mostly in the setting of missing her medications, she had an episode that progressed to a **generalized convulsion.** Numerous medications, including phenobarbital, phenytoin, carbamazepine, mephobarbital, valproate, gabapentin, and felbamate were tried in various combinations, without effective seizure control. Aside from the febrile seizures, she had no other seizure risk factors, such as head injury, CNS infections, or family history of seizures. She graduated from high school, worked briefly as a cashier,

CASE 18.5 *(CONTINUED)*

was married, and had three children. She was unable to drive because of her seizure risk. General physical exam and neurologic exam were normal.

LOCALIZATION AND DIFFERENTIAL DIAGNOSIS

1. On the basis of the features shown in **bold** above, this patient had simple partial, complex partial, and generalized seizures at different times. How would you classify the different seizures in this patient according to this scheme (see Table 18.8)?
2. How can these different seizure types all be explained by onset in one region of the brain and spread to different areas?
3. In what part of the brain and on which side is the most likely region of onset?
4. What is the most likely cause of the seizures, and what are some other possibilities?

Discussion

The key symptoms and signs in this case are:

- **Aura of a "vague" and "scary feeling"**
- **Loss of awareness, staring, and unresponsiveness**
- **Lip smacking, rigid posturing of the left arm, and groping, purposeless movements of the right arm**
- **Ability to produce speech during the episodes that was inappropriate, but without grammatical errors**
- **Post-ictal fatigue and confusion without other deficits**
- **Rare generalized convulsions**

1. According to the classification in Table 18.8, the auras in this patient were simple partial seizures, since consciousness was spared. The episodes with loss of consciousness but no generalized convulsion were complex partial seizures. Finally, the febrile convulsions in infancy and the rare generalized convulsions in adulthood were generalized tonic-clonic seizures.
2. A simple partial seizure beginning in one part of the brain can spread to become a complex partial seizure, and then spread further to become a generalized tonic-clonic seizure.
3. A vague feeling and fear are features typically seen in seizures arising from the medial temporal lobe (see Table 18.9). In addition, complex partial seizures with staring, unresponsiveness, oral automatisms, unilateral gestural automatisms, and contralateral dystonia are commonly seen in temporal lobe seizures. The fact that dystonic posturing occurred on the left and automatisms on the right suggests that the seizures arose from the right side (see KCC 18.2). The fact that the patient had nonaphasic speech during the seizures and no post-ictal aphasia also suggests that the seizures arose from the nondominant (usually right) hemisphere. The most likely *clinical localization* is right medial temporal lobe.
4. The history of prolonged febrile seizures in infancy, followed by the development of medial temporal–onset complex partial seizures is the classic presentation of hippocampal (mesial temporal) sclerosis (see KCC 18.2). Although only a small number of children with febrile seizures go on to develop epilepsy, children in the subgroup with complex febrile seizures are at increased risk for epilepsy. In addition, about 30 to 40% of patients with epilepsy and hippocampal sclerosis have a known history of febrile convulsions. Other features in this patient that are typical of hippocampal sclerosis are complex partial seizures that are notoriously refractory to medication therapy, and only rare secondary generalization while on medications. Other possible lesions in the medial temporal lobe that could be the cause of epilepsy in this patient are listed in Table 18.11.

CASE 18.3 TRANSIENT DIPLOPIA, LETHARGY, AND HEMIPARESIS, FOLLOWED BY A SUSTAINED MEMORY DEFICIT

Figure 18.19 Bilateral Medial Thalamic Infarcts Axial T2-weighted MRI images. A, B progress from inferior to superior.

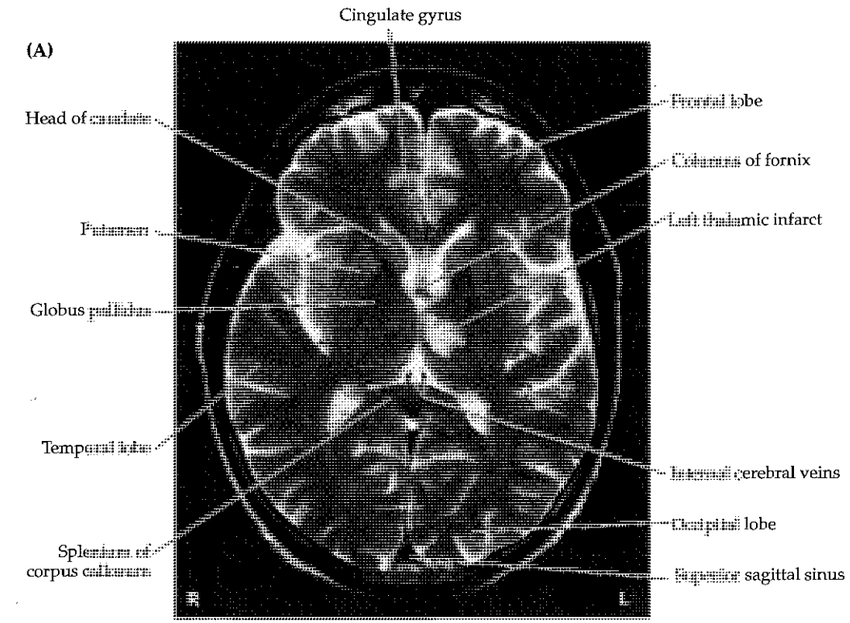

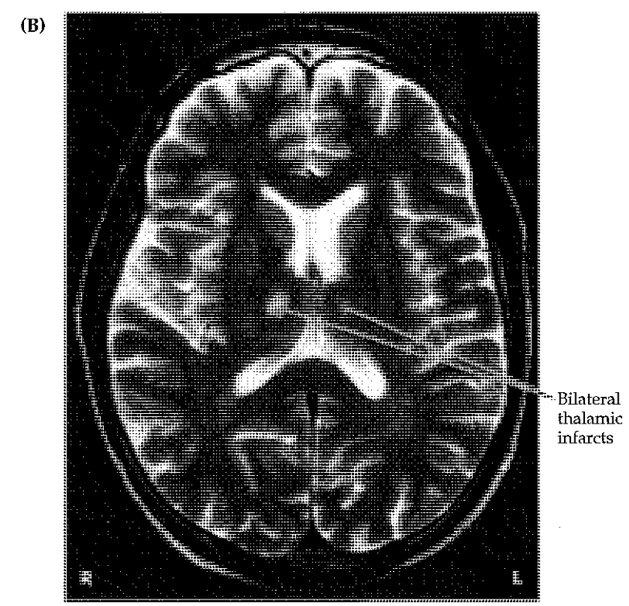

Clinical Course and Neuroimaging 814

Given this patient's frequent, medically refractory seizures, a comprehensive evaluation was pursued in an effort to localize the region of onset and to determine if she was a suitable candidate for epilepsy surgery. She was admitted to the hospital for continuous video and simultaneous EEG monitoring. Ten stereotyped seizures were recorded, with loss of consciousness, lip smacking, left-sided dystonia, and right-sided automatisms. EEG during the seizures showed rhythmic 8 Hz activity over the right temporal lobe. Interictal EEG showed occasional right temporal spikes and right temporal slow waves. A **brain MRI** was performed, with special thin coronal sections used to evaluate epilepsy patients. This technique is capable of demonstrating detailed hippocampal anatomy (Figure 18.21A). The MRI revealed marked atrophy of the right hippocampal formation compared to the left (see Figure 18.21C–F). In addition, signal intensity in the right hippocampal formation was increased, suggesting gliosis (Figure 18.21B). The volumes of the right and left hippocampal formations were 562 and 983 (arbitrary units), respectively, based on measurements performed on the entire sequence of coronal MRI images. This discrepancy between the two sides was over five standard deviations greater than normal. A **fluorodeoxyglucose PET scan** (see Chapter 4) performed interictally showed markedly reduced glucose metabolism in the right temporal lobe, especially medially and anteriorly (Figure 18.22), a finding commonly seen in medial temporal lobe epilepsy.

Neuropsychology testing revealed decreased visual-spatial memory on the Wechsler Memory Scale, with preserved verbal memory. In addition, on selective reminding tests (another measure of recent memory), the patient had visual-spatial memory that was two standard deviations below normal, and verbal memory that was normal. A Wada test (see KCC 18.2) was performed as well. Following injection of the right carotid with amytal, the patient developed left hemiplegia and was shown 10 test items. Her speech was not aphasic. Ten minutes later the hemiplegia had worn off, and the patient was able to remember 5/10 items spontaneously, and 10/10 with multiple choice. These results demonstrated good memory in the left hemisphere. Injection of the left carotid produced right hemiplegia and global aphasia. The patient was shown 10 test items. During recovery she had paraphasic errors and comprehension difficulties that resolved, as did the hemiplegia, within 10 minutes. She was then able to recall 0/10 test items, and got only 2/10 correct with multiple choice. These results demonstrated poor memory in the right hemisphere. In addition, the Wada test results demonstrated that language dominance was in the left hemisphere.

These findings were discussed by the multidisciplinary team at the epilepsy referral center, and all results were felt to be concordant, indicating onset of her seizures in the right medial temporal lobe. Given this location and the results of the patient's Wada test and neuropsychology testing suggesting that the left temporal lobe could support adequate memory functions, it was felt that surgical treatment of her right mesial temporal sclerosis could be offered with a low risk of producing deficits and a good chance of curing her seizures. She decided to pursue this option and underwent a right anteromedial temporal resection.

She had no deficits as a result of the surgery, and her seizures stopped completely. Pathology revealed right hippocampal cell loss and gliosis, consistent with hippocampal sclerosis. About 1 month after surgery and again 6 months after surgery, she tried briefly to discontinue her antiepileptic medications, but on both occasions she had recurrent seizures. As long as she took her medications, she remained without seizures or auras at last follow-up, a year and a half after surgery.

CASE 18.4 EPISODES OF PANIC, OLFACTORY HALLUCINATIONS, AND LOSS OF AWARENESS

Figure 18.20 Left Anterior Temporal Glioblastoma Multiforme Coronal T1-weighted MRI images, with intravenous gadolinium. (A, B) progress from posterior to anterior.

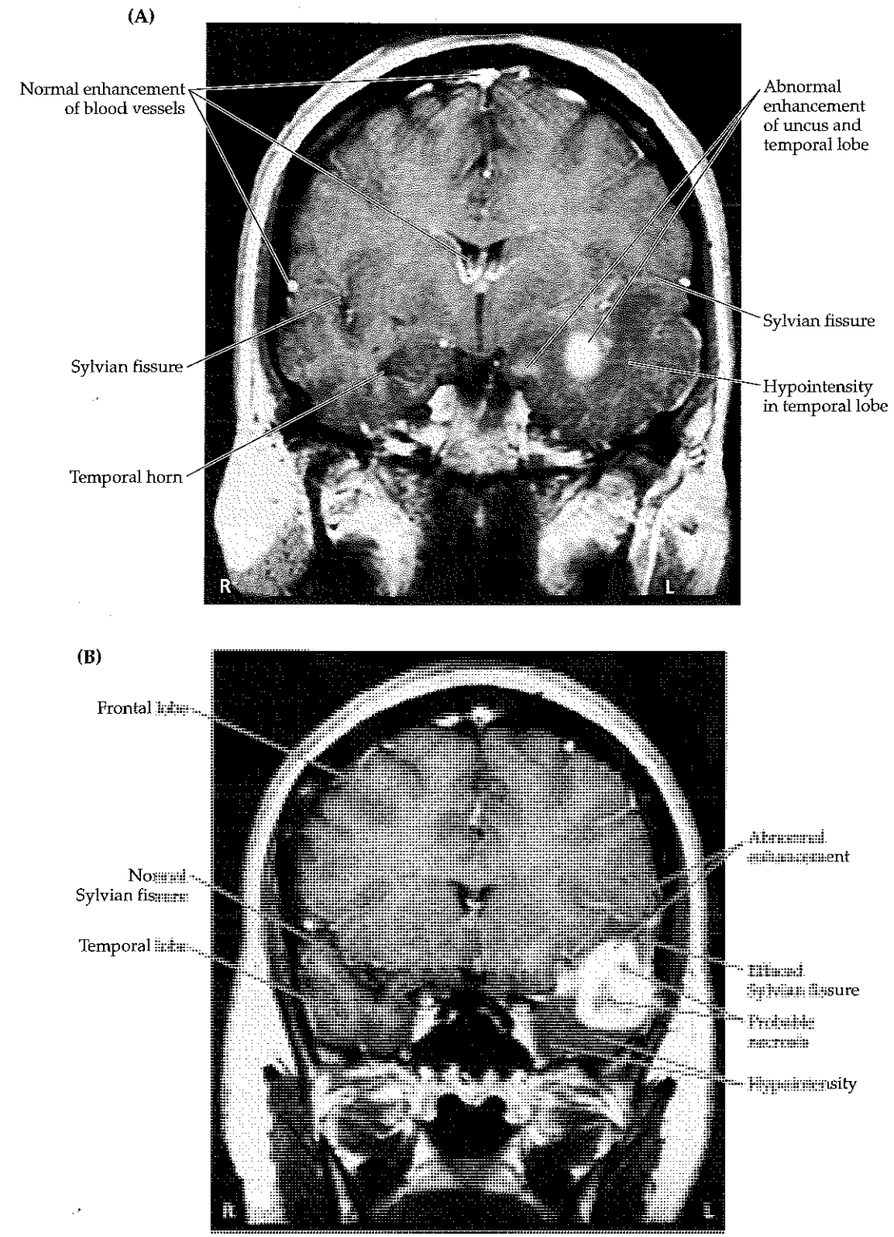

CASE 18.5 EPISODES OF STARING, LIP SMACKING, AND UNILATERAL SEMIPURPOSEFUL MOVEMENTS

Figure 18.21 Right Hippocampal Sclerosis
(A) Enlarged view of coronal thin-slice, T1-weighted MRI done with a special epilepsy protocol revealing normal structures of the left medial temporal lobe (compare to Figure 18.8A). (B) Coronal T2-weighted image. Increased signal intensity is evident in the right hippocampal formation, compatible with gliosis. (C–F) Coronal thin-slice, T1-weighted images. Atrophy is seen in the right hippocampal formation compared to the left. Images C–F progress from posterior to anterior.

(A)

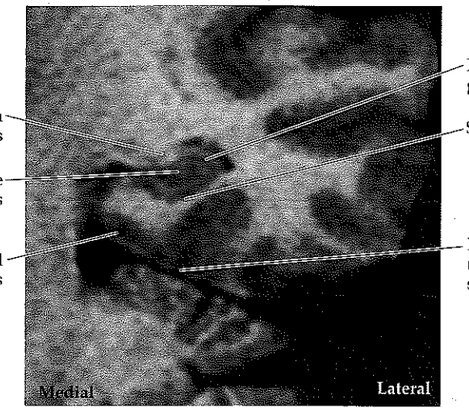

(B)

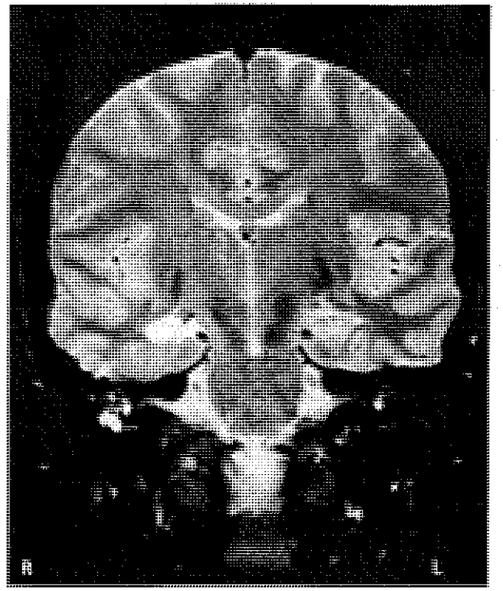

CASE 18.5 *(CONTINUED)*

(C)

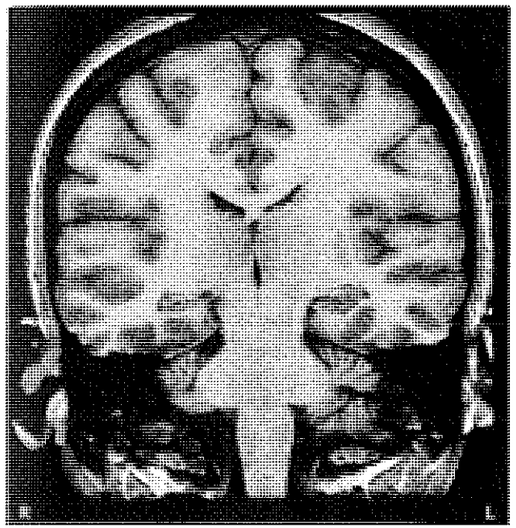

(D)

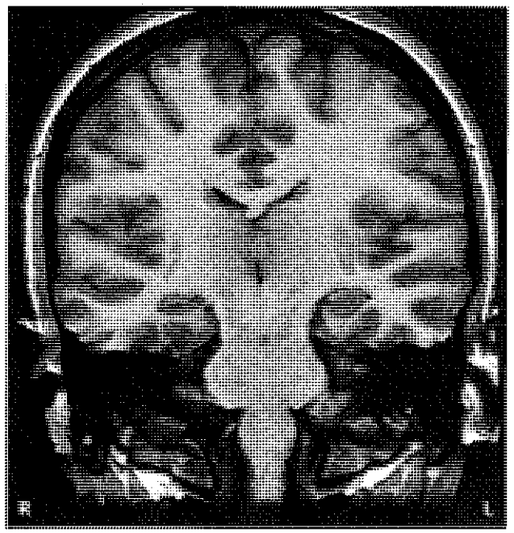

(E)

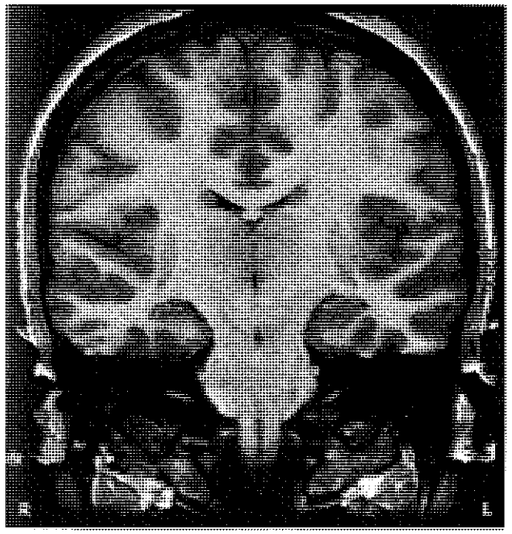

(F)

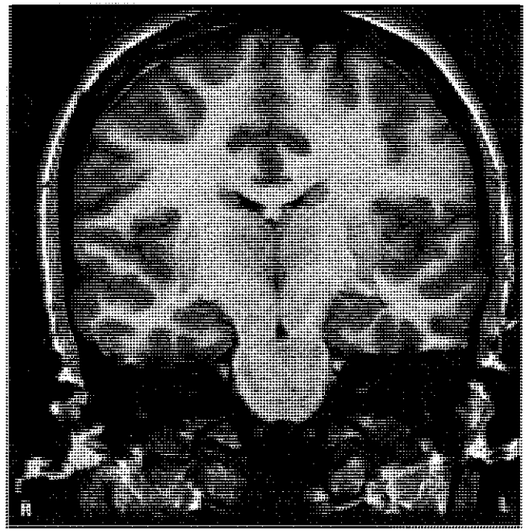

CASE 18.5 *(CONTINUED)*

Figure 18.22 Right Temporal Hypometabolism Fluorodeoxyglucose (FDG) PET scan for patient in Case 18.5, showing right medial temporal hypometabolism. Darker colors indicate regions of decreased metabolism. (A, B) Axial sections progressing from inferior to superior. (C, D) Coronal sections progressing from posterior to anterior.

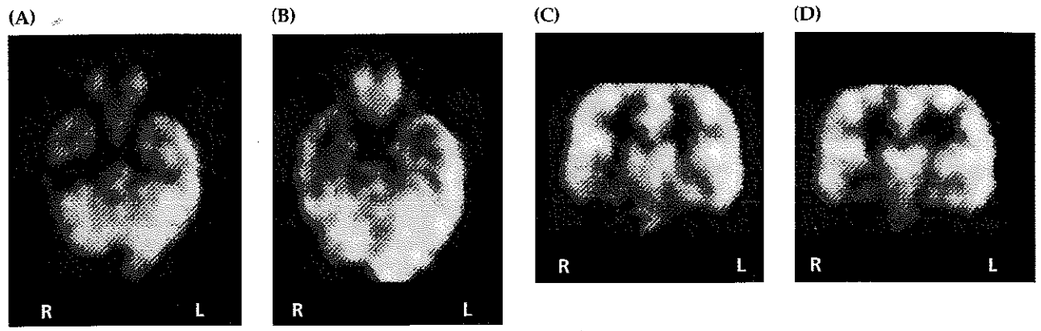

Brief Anatomical Study Guide

1. In this chapter we have reviewed the main neuroanatomical structures and functions of the limbic system. The **limbic system** can be defined as a network of brain structures lying on the medial and inferior aspects of the brain (see Figures 18.1, 18.2), involved in four general functions: **homeostasis, olfaction, memory,** and **emotions and drives** (mnemonic HOME). Simplifying somewhat, the most important structure for each of these functions is listed in Table 18.2, although in reality these functions are mediated by a widely distributed network (see Figure 18.1).

2. **Limbic cortex,** also called paralimbic cortex or limbic association cortex, forms a ring on the medial aspect of the brain consisting mainly of the **cingulate gyrus** and the **parahippocampal gyrus** (see Figure 18.2). Within this ring and in the temporal lobe lies the simple three-layered **archicortex** of the **hippocampal formation** (see Table 18.3; Figure 18.9). The hippocampal formation consists of three gyri, named, from medial to lateral, the **dentate gyrus, hippocampal gyrus,** and **subiculum** (see Figures18.7, 18.8). Unlike the six-layered neocortex making up most of the brain surface, these gyri of the hippocampal formation each consist of three layers (see Figure 18.8).

3. The hippocampal formation is crucial to memory function and has many input and output network connections (see Figure 18.11). The connections with the **association cortex** may be particularly impor tant for memory, and they occur mainly via the **perirhinal** and **parahippocampal cortex,** connected to the adjacent **entorhinal cortex** (see Figure 18.6), which in turn is connected to the hippocampal formation. Inputs from the entorhinal cortex to the hippocampal formation reach the dentate gyrus via the **perforant pathway,** and the CA1 and CA3 fields of the hippocampal gyrus via the **alvear pathway** (see Figure 18.8B). Outputs from the hippocampal formation travel from the subiculum back to the entorhinal cortex. The hippocampal formation also has connections with subcortical structures, especially the **mammillary bodies, mediodorsal nuclei, other medial diencephalic nuclei** and **the septal nuclei** via the **fornix** (see Figures18.9, 18.11, 18.13) and other connections.

Brief Anatomical Study Guide *(continued)*

4. Lesions of the **medial temporal lobe memory system** (hippocampal formation and parahippocampal gyrus) or of the **medial diencephalic memory system** (thalamic mediodorsal nucleus, anterior nucleus, internal medullary lamina, and other periventricular diencephalic nuclei) cause a characteristic **anterograde amnesia,** in which new information cannot be learned, together with **retrograde amnesia,** in which material from a period of time prior to the lesion cannot be recalled (see Figure 18.16).

5. The **amygdala** is a nuclear complex located just anterior to the hippocampal formation in the anterior temporal lobe (see Figure 18.10). It has three main nuclei: the **corticomedial, basolateral,** and **central nuclei** (see Figure 18.4B). Like the hippocampal formation, the amygdala has connections with association cortex and subcortical structures (see Figure 18.17A,B), but unlike the hippocampal formation, it also has direct connections with olfactory structures (see Figure 18.17C). The amygdala participates in networks mediating all of the major limbic functions, including autonomic and neuroendocrine control, olfaction, emotional aspects of memory (e.g., fear memory), and emotions.

6. Olfaction is relatively poorly developed in humans, but it is a major function of limbic structures in other species. Olfactory inputs travel via the **olfactory nerves** to reach the **olfactory bulbs,** where **mitral cells** and **tufted cells** relay information to olfactory areas, including the piriform cortex, periamygdaloid cortex, olfactory tubercle, and amygdala (see Figures 18.5, 18.6). Unlike other sensory modalities, olfactory inputs reach the **primary olfactory cortex** (**piriform cortex** and **periamygdaloid cortex**) directly, with no obligatory relay in the thalamus.

Additional Cases

Related cases can be found in other chapters for the following topics: **impaired olfaction** (Case 12.1); **abnormal emotions** (Cases 12.8, 16.2, 19.7); **memory decline** (Cases 5.9, 14.8, 19.7, 19.11); and **seizures** (Cases 10.13, 12.3, 19.10). Other relevant cases can be found using the **Case Index.**

References

General References

Adolphs R. 1999. The human amygdala and emotion. *Neuroscientist* 5: 125–137.

Aggleton JP (ed.). 1992. *The Amygdala: Neurobiological Aspects of Emotion, Memory, and Mental Dysfunction.* Wiley-Liss, New York.

Carpenter MB. 1991. *Core Text of Neuroanatomy,* 4th Ed., Chapter 12. Williams & Wilkins, Baltimore, MD.

Eldridge LL, Knowlton BJ, Furmanski CS, Bookheimer SY, Engel SA. 2000. Remembering episodes: A selective role for the hippocampus during retrieval. *Nat Neurosci* 3: 1149–1152.

Martin JH. 1996. *Neuroanatomy: Text and Atlas*, 2nd Ed., Chapters 8 and 15. Appleton & Lange, Stamford, CT.

McGaugh JL. 2000. Memory—A century of consolidation. *Science* 287: 248–251.

Memory and Memory Disorders

Arasaki K, Kwee IL, Nakada T. 1987. Limbic lymphoma. *Neuroradiology* 29: 389–392.

Bauer RM, Tobias B, Valenstein E. 1993. Amnesic disorders. In Heilman KM, Valenstein E (eds.), *Clinical Neuropsychology*, 3rd Ed., Chapter 15. Oxford University Press, New York.

Bliss TVP, Collingridge GL. 1993. A synaptic model of memory: Long-term potentiation in the hippocampus. *Nature* 361: 31–39.

Capruso DX, Levin HS. 1992. Cognitive impairment following closed head injury. *Neurol Clin* 10: 879–893.

Corkin S. 1984. Lasting consequences of bilateral medial temporal lobectomy: Clinical course and experimental findings in H.M. *Sem Neurol* 4: 249–259.

Gentilini M, Renzi E, Crisi G. 1987. Bilateral paramedian thalamic artery infarcts: Report of eight cases. *J Neurol Neurosurg Psychiatry* 50: 900–999.

Jacobson RR, Acker CF, Lishman WA. 1990. Patterns of neuropsychological deficit in alcoholic Korsakoff's syndrome. *Psychol Med* 20: 321–334.

Jernigan TL, Schafer K, Butters N, Cermak LS. 1991. Magnetic resonance imaging of alcoholic Korsakoff patients. *Neuropsychopharmacology* 4: 175–186.

Levin HS, High Wm, Meyers CA, Von Laufen A, Hayden ME, Eisenberg HM. 1985. Impairment of remote memory after closed head injury. *J Neurol Neurosurg Psychiatry* 49: 556–563.

Melo TP, Ferro JM, Ferro H. 1992. Transient global amnesia: A case control study. *Brain* 115: 261–270.

Rempel-Clower NL, Zola SM, Squire LR, Amaral DG. 1996. Three cases of enduring memory impairment after bilateral damage limited to the hippocampal formation. *J Neurosci* 16: 5233–5255.

Sandson TA, Price BH. 1995. Transient global amnesia. *Sem Neurol* 15: 183–187.

Scoville WB, Milner B. 1996. Loss of recent memory after bilateral hippocampal lesions. *J NIH Res* 8: 42–51.

Squire LR, Kandel ER. 1999. *Memory: From Mind to Molecules*. Freeman, New York.

Squire LR, Zola-Morgan S. 1991. The medial temporal lobe memory system. *Science* 253: 1380–1386.

Tulving E, Schacter DL. 1990. Priming and human memory systems. *Science* 247: 301–306.

Vlope BT, Holtzman JD, Hirst W. 1986. Further characterization of patients with amnesia after cardiac arrest: Preserved recognition memory. *Neurology* 36: 408–411.

Zola-Morgan S, Squire LR. 1993. Neuroanatomy of memory. *Annu Rev Neurosci* 16: 547–563.

Seizures and Epilepsy

Acharya V, Acharya J, Luders H. 1998. Olfactory epileptic auras. *Neurology* 51: 56–61.

Engel J. 1989. *Seizures and Epilepsy*. FA Davis, Philadelphia.

Engel J, Pedley TA (eds.). 1998. *Epilepsy: A Comprehensive Textbook*, 3 vols. Lippincott-Raven, Philadelphia.

Wyllie E (ed.). 1997. *The Treatment of Epilepsy*, 2nd Ed. Williams & Wilkins, Baltimore, MD.

Psychiatric Disorders

Dougherty, DD, Rauch SL. 2001. *Psychiatric Neuroimaging Research: Contemporary Strategies*. American Psychiatric Press.

Arnold SE. 1999. Cognition and neuropathology in schizophrenia. *Acta Psychiatr Scand Suppl* 395: 41–50.

Insel TR. 1992. Toward a neuroanatomy of obsessive-compulsive disorder. *Arch Gen Psychiatry* 49: 739–744.

Kaplan HI, Sadock BJ. 1996. *Concise Textbook of Clinical Psychiatry*. Williams & Wilkins, Baltimore, MD.

Lilly R, Cummings JL, Benson DF, Frankel M.1983. The human Klüver–Bucy syndrome. *Neurology* 33: 1141–1145.

CHAPTER 19 Higher-Order Cerebral Function

ANATOMICAL AND CLINICAL REVIEW
KCC 19.1 The Mental Status Exam
Unimodal and Heteromodal Association Cortex
Principles of Cerebral Localization and Lateralization
The Dominant Hemisphere: Language Processing and Related Functions
KCC 19.2 Differential Diagnosis of Language Disorders
KCC 19.3 Bedside Language Exam
KCC 19.4 Broca's Aphasia
KCC 19.5 Wernicke's Aphasia
KCC 19.6 Simplified Aphasia Classification Scheme
KCC 19.7 Other Syndromes Related to Aphasia
KCC 19.8 Disconnection Syndromes
The Nondominant Hemisphere: Mechanisms of Attention and Spatial Processing
KCC 19.9 Hemineglect Syndrome
KCC 19.10 Other Clinical Features of Nondominant Hemisphere Lesions
The Frontal Lobes: Anatomy and Functions of an Enigmatic Brain Region
KCC 19.11 Frontal Lobe Disorders
Visual Association Cortex: Higher-Order Visual Processing
KCC 19.12 Disorders of Higher-Order Visual Processing
KCC 19.13 Auditory Hallucinations
Attention, Awareness, and Other General Network Functions of The Brain
KCC 19.14 Attentional Disorders
KCC 19.15 Delirium and Other Acute Mental Status Disorders
KCC 19.16 Dementia and Other Chronic Mental Status Disorders

CLINICAL CASES
19.1 Acute Severe Aphasia, with Improvement
19.2 Nonsensical Speech
19.3 Aphasia with Preserved Repetition
19.4 Impaired Repetition
19.5 Inability to Read, with Preserved Writing Skills
19.6 Left Hemineglect
19.7 Abulia
19.8 Blindness without Awareness of Deficit
19.9 Sudden Inability to Recognize Faces
19.10 Musical Hallucinations
19.11 Progressive Dementia, Beginning with Memory Problems

Additional Cases

BRIEF ANATOMICAL STUDY GUIDE

A 64-year-old woman progressively developed difficulties with reading, along with a right visual field defect. When she presented at the clinic, she was completely unable to read, but was able to write normally. For example, she wrote "Today is a nice day" and "It is a sunny day in Boston," but was unable to read her own writing a few minutes later. As we shall see, higher-order cerebral functions (such as reading) depend on both local cortical functions (vision), together with more distributed cortical network functions (language). In this chapter, we will learn about the local higher-order functions of the cerebrum, and about the network connections that are essential for distributed functions such as language and cognition.

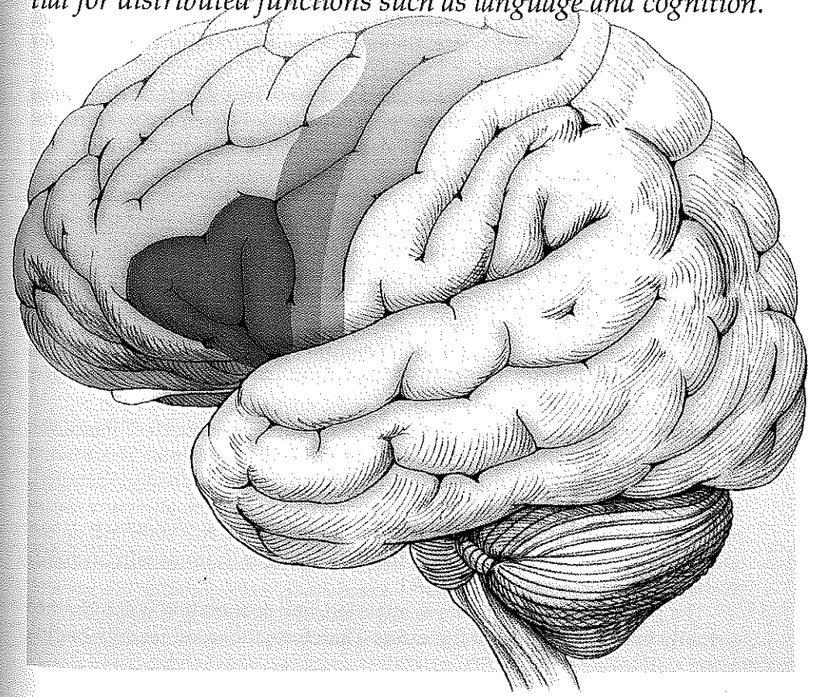

ANATOMICAL AND CLINICAL REVIEW

In humans, the majority of the brain surface is composed of association cortex. The functions of this vast cortical mantle are perhaps more difficult to understand than those of any other brain area, yet they are also what make us uniquely human. Functions of the association cortex include sophisticated operations such as higher-order sensory processing, motor planning, language processing and production, visual-spatial orientation, determining socially appropriate human behavior, and perhaps even what we would call "abstract thought."

Although the emphasis of this chapter is association cortex, it should be noted that numerous subcortical structures participate in these functions as well. We saw in Chapter 18 that lesions of the medial diencephalon can mimic the memory deficits seen in medial temporal lesions. Similarly, lesions of the basal ganglia, thalamus, subcortical white matter, and other structures can produce deficits such as aphasia or unilateral neglect that resemble lesions of the association cortex. Although cerebral cortical localization will be emphasized in this chapter, in reality networks of both cortical and subcortical structures mediate virtually all brain functions. For example, we have learned that the thalamus and basal ganglia participate in association cortex networks (see Figures 7.8, 16.8), that brainstem activating systems are crucial for behavioral arousal (see Figure 14.7), and that the amygdala has widespread connections participating in emotions and drives (see Figure 18.17). Thus, in addition to deficits arising from focal cortical lesions, specific neurobehavioral deficits can be caused by lesions that involve only subcortical structures, or by lesions that disrupt cortical–cortical or cortical–subcortical network connections.

Historically there has been a dichotomy in theories of brain function. Some investigators have attributed brain functions to distributed networks, while others have assigned functions to specific localizations. In reality, both network and localized mechanisms participate in brain function, and therefore, these will both be discussed in this chapter. We will begin by reviewing the overall structure of the mental status examination introduced in Chapter 3. Next, we will discuss localized aspects of cerebral function and focal clinical disorders in four general regions of the association cortex: dominant (usually left) hemisphere, nondominant (usually right) hemisphere, frontal lobes, and visual association cortex. Finally, we will discuss more widely distributed functions such as attention and awareness and clinical disorders resulting from more global brain dysfunction.

The epilogue that follows this chapter will briefly present an overview of the integrated functions of the nervous system, including the various systems discussed throughout this book. An attempt will be made to unify these into a simple working model of the mind.

KEY CLINICAL CONCEPT
THE MENTAL STATUS EXAM

19.1 In Chapter 3, we introduced the **mental status exam.** This part of the neurological exam, like all other parts, should be performed and interpreted in the context of a more general clinical assessment that includes the patient history, general physical examination, and appropriately selected diagnostic tests. The mental status exam provides a useful bedside evaluation of mental performance. Formal **neuropsychology testing** can provide more detailed, accurate, and quantitative information when needed. There are many variations in the mental status exam, depending on the clinician's style and on the specific clinical situation. However, the mental status exam usually includes the basic elements listed in Table 19.1.

The patient's level of alertness, attention, and cooperation will influence virtually every other part of the exam. Therefore, the exam usually begins with an evaluation of these functions, which tend to depend on more widely distributed networks. Any abnormalities should be carefully documented, since they will affect the interpretation of all other parts of the exam and could lead to false diagnosis of a focal condition. For example, patients who are in a global confusional state because of a toxic or metabolic disorder (see KCC 19.15) are often inattentive and may perform poorly on writing tests. Unless the level of alertness and attention is carefully tested, this poor performance could be misinterpreted as a focal deficit in written language.

Next, the patient's orientation and memory should be tested. Memory is a crucial element of mental status that was covered in detail in Chapter 18. The remaining parts of the mental status exam (see Table 19.1) mainly test more localized brain regions such as the dominant (usually left) hemisphere (language and related functions), right hemisphere (neglect and constructions), and frontal lobes (sequencing tasks and frontal release signs). In the sections that follow, we will discuss the anatomy and testing of each of these brain regions in greater detail. In addition, we will discuss testing and disorders of visual processing, not listed explicitly in Table 19.1. Finally, the examiner should evaluate the patient for several additional, more global functions (logic and abstractions) and for psychiatric disorders (see KCC 18.3).

To avoid confusion, note that the general organization of this chapter does not follow the order of Table 19.1, but instead begins with localized functions and then later continues with more global functions such as attention. The mental status exam is described in greater detail in Chapter 3 (and in neuroexam.com Videos 3–23) and should be reviewed carefully at this point before reading the rest of this chapter, since it will make the material presented here much easier to understand. ■

TABLE 19.1 Overview of the Mental Status Exam

1. Level of alertness, attention, and cooperation
2. Orientation
3. Memory
   - Recent memory
   - Remote memory
4. Language
   - Spontaneous speech
   - Comprehension
   - Naming
   - Repetition
   - Reading
   - Writing
5. Calculations, right–left confusion, finger agnosia, agraphia
6. Apraxia
7. Neglect and constructions
8. Sequencing tasks and frontal release signs
9. Logic and abstraction
10. Delusions and hallucinations
11. Mood

Unimodal and Heteromodal Association Cortex

Association cortex can be divided into **unimodal (modality-specific) association cortex** and **heteromodal (higher-order) association cortex** (Figure 19.1; Table 19.2). Examples of unimodal association cortex include somatosensory association cortex, visual association cortex, auditory association cortex, and motor association cortex (premotor cortex and supplementary motor area).

TABLE 19.2 Terminology Used for Classifying Neocortex[a]

NAME	EQUIVALENT NAME(S)	EXAMPLES
Primary sensory and motor cortex	Idiotypic cortex, heterotypic cortex[b]	
Primary sensory cortex	Koniocortex, hypergranular cortex, granular cortex	Primary somatosensory cortex, primary visual cortex, primary auditory cortex
Primary motor cortex	Macropyramidal cortex, agranular cortex	Primary motor cortex
Association cortex	Homotypic cortex[c]	
Unimodal association cortex	Modality-specific association cortex	Somatosensory, visual, or auditory association cortex, premotor cortex, supplementary motor area
Heteromodal association cortex	Higher-order association cortex	Prefrontal cortex, parietal and temporal heteromodal association cortex

[a] Six-layered cortex, sometimes called isocortex or neopallium. See Table 18.3 for classification of other types of cerebral cortex.
[b] "Meaning cortex in which the layers are unequal."
[c] "Meaning cortex in which the layers are relatively equal."

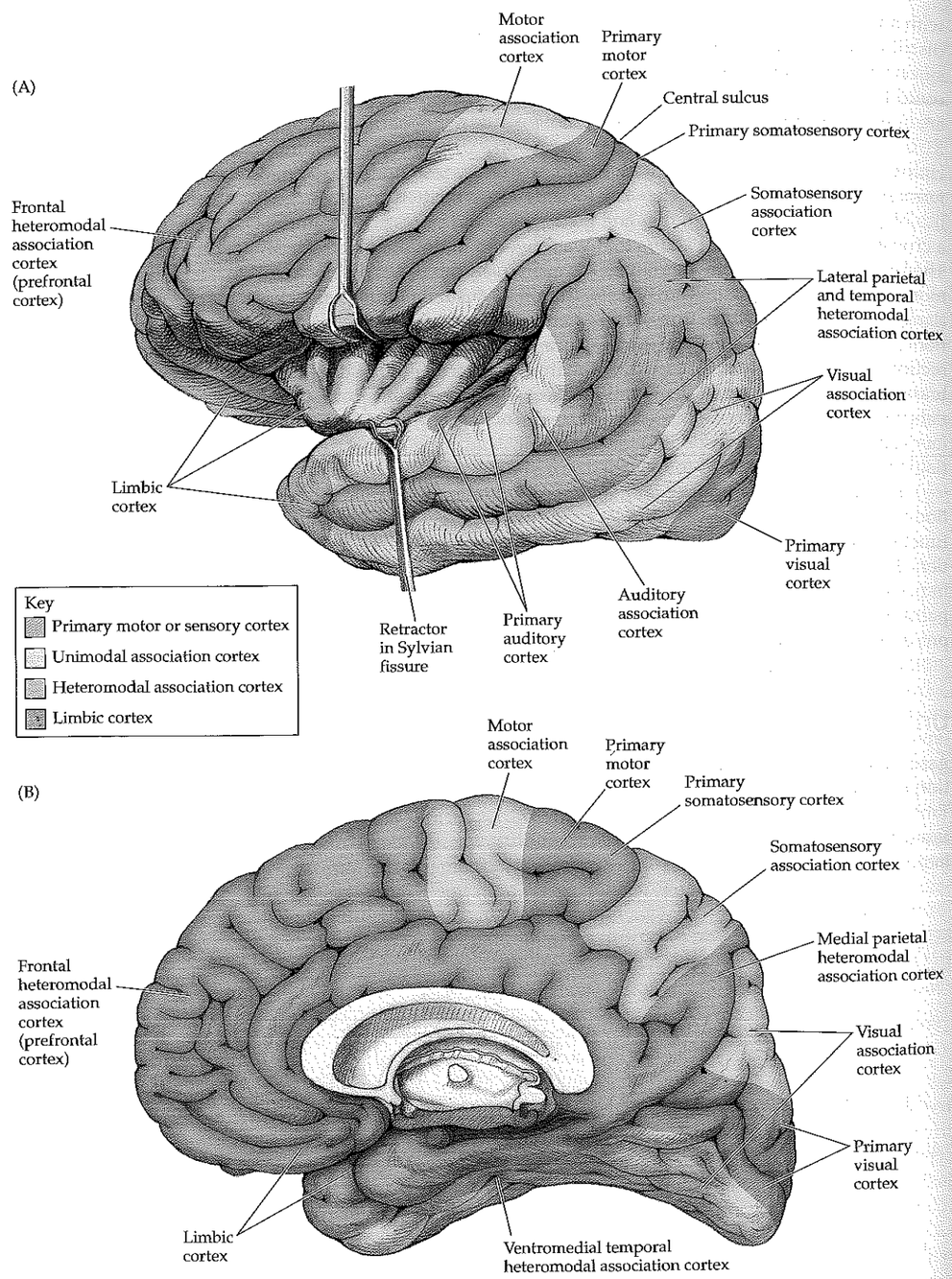

Figure 19.1 Classification of Different Types of Cortex
See also Tables 18.3 and 19.2.

Unimodal sensory association cortex receives its predominant input from primary sensory cortex of a specific sensory modality and performs higher-order sensory processing for that modality. Unimodal motor association cortex projects predominantly to primary motor cortex, and it is important in formulating the motor program for complex actions involving multiple joints.

In contrast, heteromodal association cortex has bidirectional connections with both motor and sensory association cortex of all modalities. In addition, heteromodal association cortex has bidirectional connections with limbic cortex. This anatomical arrangement enables heteromodal association cortex to perform the highest-order mental functions. These functions apparently require integration of abstract sensory and motor information from unimodal association cortex, together with emotional and motivational influences provided by limbic cortex. Heteromodal association cortex is found in the frontal lobes and at the parieto-occipitotemporal junctions (see Figure 19.1).

In the sections that follow, we will survey some of the main functions of unimodal and heteromodal association cortex in different brain regions and study disorders that result from lesions in these areas.

REVIEW EXERCISE

Cover the labels in Figure 19.1. Name each region and state whether it is primary motor or sensory cortex, unimodal association cortex, heteromodal association cortex, or limbic cortex.

Principles of Cerebral Localization and Lateralization

As we have already mentioned, in the 1800s and early 1900s there was a controversy between those who described the brain as a network and those who described it as a collection of specialized areas. In reality, the brain is both. Localized regions of the brain do carry out specific functions, but they do so through network interactions with many other regions of the nervous system. **Focal brain lesions can cause specific deficits,** as we will see in the sections that follow. By understanding the main functions of the different cortical regions, deficits such as aphasia, unilateral neglect, impaired executive function, or inability to process visual information normally, can often be localized based on the neurological exam. However, because brain functions are mediated by networks involving not single, but multiple areas, **false localization** can sometimes occur. For example, so-called frontal lobe functions involve networks that encompass diverse regions including the frontal, parietal, and limbic cortices, the thalamus, basal ganglia, cerebellum, and brainstem. Therefore, lesions in these other structures, or in their white matter connections, can sometimes produce deficits that mimic frontal-lobe lesions. **Disconnection syndromes** (see KCC 19.8) are another result of the network properties of brain function. For example, when a lesion in the white matter disconnects the network connections between visual cortex and the language processing areas, a patient may lose the ability to read.

Another important principle that can help localize deficits on clinical grounds is the tendency of some functions to be lateralized to the left or right hemisphere, resulting in **hemispheric specialization**. The human brain appears fairly symmetrical anatomically between the left and right hemispheres, and many basic sensory and motor functions in the brain are distributed symmetrically. Homologous regions of cerebral cortex on either side of the brain are connected to each other via long association fibers carried by the corpus callosum. For unknown reasons, however, there are marked asymmetries in several brain functions. It has been postulated that these asymmetries allow certain functions to be processed mainly within one hemisphere, eliminating delays caused by long callosal transmission times.

The most obvious asymmetry in cerebral function is **handedness.** Approximately 90% of the population is right-handed. The degree of asymmetry in manual dexterity varies, but most individuals are remarkably clumsy

in performing tasks such as writing or closing buttons with the nondominant (usually left) hand. Functional neuroimaging and the results of lesions have suggested that although each hemisphere controls simple movements of the contralateral limbs, skilled complex motor tasks for both right and left limbs are programmed mainly by the dominant usually left hemisphere. Lesions of the dominant hemisphere therefore are more commonly associated with apraxia, a disorder of formulating skilled movements (KCC 19.7).

Language is another well-known example of hemispheric specialization. In most individuals, language function depends predominantly on the left hemisphere. **The left hemisphere is dominant for language in over 95% of right-handers, and in over 60 to 70% of left-handers.** Thus, lesions of the left hemisphere language areas usually cause language dysfunction even in left-handed individuals. However, many left-handed individuals have significant bilateral representation of language, especially if there is a family history of left-handedness or ambidexterity. Thus, after a left hemisphere lesion, left-handed individuals tend to recover language more quickly than right-handers.

The **nondominant hemisphere is specialized for certain nonverbal functions** and appears to be generally more important for complex visual-spatial skills, for imparting emotional significance to events and language, and for music perception. Although the right and left hemispheres are each involved in attention to the contralateral environment, only the right hemisphere is significantly involved in attending to both sides. Lesions of the right hemisphere usually cause marked inattention to the contralateral (left) side even in individuals who are right hemisphere dominant for language. Right hemisphere specialization for spatial attention may therefore be even more highly conserved than left hemisphere dominance for language.

To summarize the "flavor" of lesions of each hemisphere, dominant (usually left) hemisphere lesions cause impairments of language, detailed analytical abilities, and complex motor planning (praxis), while nondominant (usually right) hemisphere lesions cause impairments of spatial attention and complex visual-spatial abilities, especially those involving spatial orientation and perception of the overall gestalt, or big picture. As Table 19.3 shows, many important activities are carried out by combinations of different specialized skills of the left and right hemispheres. These functions of the dominant and nondominant hemispheres are mediated by distributed networks involving frontoparietal connections, connections with limbic memory structures, and reciprocal connections with subcortical nuclei. Lesions that disconnect these networks, either within one hemisphere or between hemispheres at the corpus callosum, can cause specific disconnection syndromes (see KCC 19.8).

TABLE 19.3 Functions of the Dominant and Nondominant Hemispheres

DOMINANT (USUALLY LEFT) HEMISPHERE FUNCTIONS	NONDOMINANT (USUALLY RIGHT) HEMISPHERE FUNCTIONS
Language	Prosody (emotion conveyed by tone of voice)
Skilled motor formulation (praxis)	Visual-spatial analysis and spatial attention
Arithmetic: sequential and analytical calculating skills	Arithmetic: ability to correctly line up columns of numbers on the page
Musical ability: sequential and analytical skills in trained musicians	Musical ability: in untrained musicians, and for complex musical pieces in trained musicians
Sense of direction: following a set of written directions in sequence	Sense of direction: finding one's way by overall sense of spatial orientation

The anatomical basis for hemispheric specialization is only just beginning to be investigated. Although it has been known since the 1960s that the left superior temporal plane (planum temporale) is larger in the left hemisphere in most individuals, the functional significance of this finding is still debated. Some preliminary evidence suggests that portions of the parietal lobe are larger in the right hemisphere. Functional and structural asymmetries in the brain are not unique to humans and have been demonstrated in other primates, and even in amphibians. Handedness and other lateralized aspects of cerebral function are not apparent in humans until 3 or 4 years of age, suggesting that developmental processes play a crucial role in hemispheric specialization. When lesions of the dominant hemisphere occur early in life, language and other functions often move to the nondominant hemisphere resulting in a remarkable preservation of function.

In the sections that follow, we will move through the brain from left to right, and then from front to back. Thus, we will first discuss functions generally associated with the dominant hemisphere, followed by functions associated with the nondominant hemisphere. Then we will turn to the frontal lobes, and finally to visual association cortex.

The Dominant Hemisphere: Language Processing and Related Functions

In this section, we will describe the components of the language network and then discuss disorders of the dominant hemisphere affecting language and other typical functions of the dominant hemisphere (see Table 19.3).

Anatomy of Language Processing

A Historical Note:
The anatomical study of language disorders has had considerable historical importance over the past two centuries in the development of theories of cerebral localization in general. In the 1860s and 1870s, when Pierre Paul Broca and Karl Wernicke described language disorders caused by focal lesions in the brain, these descriptions were taken as important support for the notion that localized regions of the brain are specialized to perform specific cognitive functions. This concept fell into disfavor around the turn of the twentieth century, in the face of more holistic schemes of brain function proposed by Sigmund Freud and Pierre Marie, only to be revitalized eventually by Norman Geschwind and others in the 1960s and subsequent decades. Currently, the most widely accepted model is based on localized regions of cortex that have specialized functions but also participate in networks employing multiple brain regions to perform cognitive tasks.

As mentioned in the previous section, the left hemisphere is **dominant** for language in over 95% of right-handers and in over 60 to 70% of left-handers. Important areas for language processing and production are shown in Figure 19.2. Figure 19.2A shows the core structures associated with basic linguistic processes, such as hearing a word and then repeating it aloud. Auditory information reaches primary auditory cortex on the superior bank of the Sylvian fissure in the temporal lobe (see Figure 19.1A). The initial steps of language processing that enable particular sequences of sounds to be identified and comprehended as meaningful words are performed in the adjacent association cortex, which has been named **Wernicke's area** (see Figure 19.2A). Wernicke's area corresponds to Brodmann's area 22 (see Chapter 2), which encompasses the posterior two-thirds of the superior temporal gyrus in the dominant hemisphere. Many authors also include in Wernicke's area a rim of adjacent association cortex from Brodmann's areas 37, 39, and 40 because lesions extending to these areas produce Wernicke's aphasia (see KCC 19.5).

Articulation of the sounds that constitute speech depends on the face area of the primary motor cortex, located in the inferior portion of the precentral gyrus (see Figure 6.2). The motor program that activates particular se-

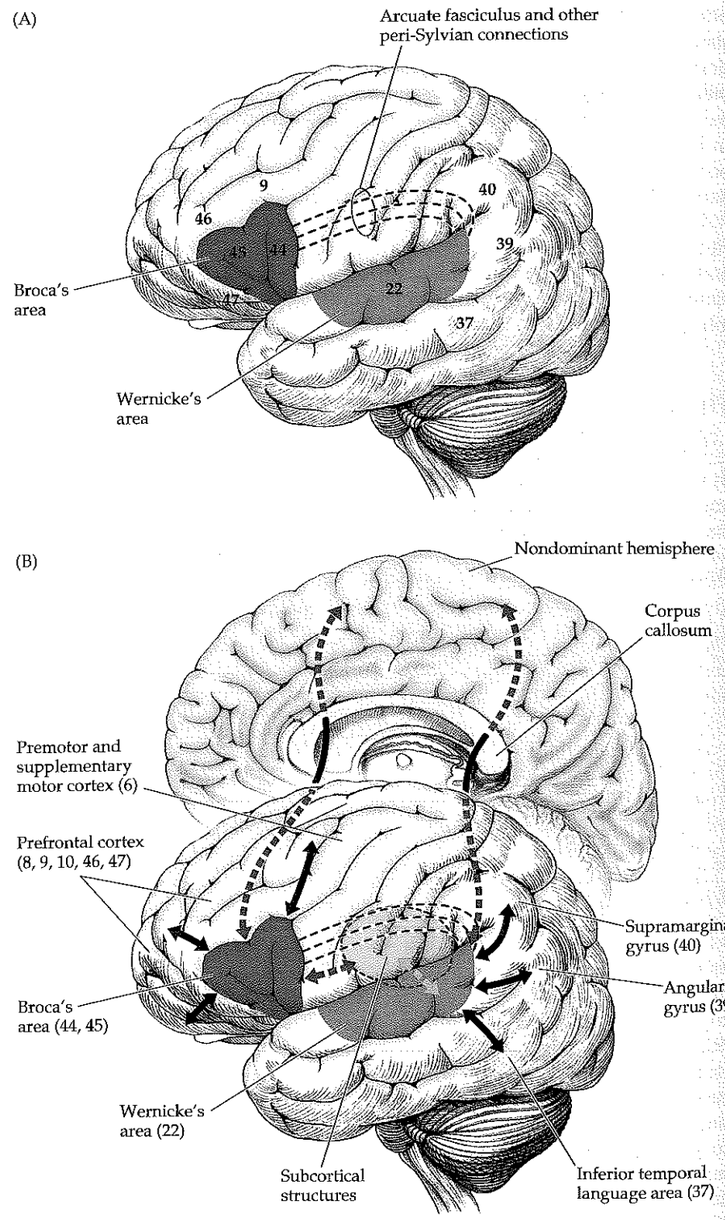

Figure 19.2 Anatomy of Language Areas (A) Core language circuit composed of Broca's area, Wernicke's area, and the arcuate fasciculus. (B) Network of areas involved in language, including interactions with adjacent anterior and posterior association cortex, subcortical structures, and callosal connections to the contralateral hemisphere.

MNEMONIC

quences of sounds to produce words is formulated in the adjacent association cortex, which is called **Broca's area** (see Figure 19.2B). Broca's area corresponds to Brodmann's areas 44 and 45 (easy to remember because Broca's—44, is twice Wernicke's—22). Broca's area lies in the opercular and triangular portions of the inferior frontal gyrus (see Figure 2.11A) in the dominant hemisphere (see Figure 19.2A). Many authors include a rim of the

adjacent areas 9, 46, and 47 in Broca's area, or more widely including 6, 8 and 10 (see Figure 2.15), because lesions extending to these areas produce Broca's aphasia (see KCC 19.4).

Continuing with our example, the ability to hear a word and then repeat it aloud requires transfer of information across the Sylvian fissure from Wernicke's area to Broca's area (see Figure 19.2A). Simplifying somewhat, neural representations for sounds are converted into words in Wernicke's area, and neural representations for words are converted back into sounds in Broca's area. Wernicke's and Broca's areas communicate with each other through several different connections, the best known of which is a subcortical white matter pathway called the **arcuate fasciculus** (see Figure 19.2A). In addition, numerous polysynaptic connections convey information from Wernicke's area along the intervening peri-Sylvian cortex to reach Broca's area.

Although Broca's area and Wernicke's area are critical way stations, they do not perform the operations involved in the production and comprehension of language alone. In fact, Broca's and Wernicke's areas have reciprocal connection with a large network of cortical areas engaged in language processing (see Figure 19.2B). Broca's area connects with other regions of the frontal lobes, including the prefrontal cortex, premotor cortex, and supplementary motor area. These areas function together with Broca's area, primarily in higher-order motor aspects of speech formulation and planning. In addition, the correct **syntax,** or grammatical structure, of both language production and comprehension appears to depend critically on these anterior structures. Wernicke's area has reciprocal connections with the supramarginal gyrus and angular gyrus of the parietal lobe, as well as with regions of the temporal lobe such as Brodmann's area 37 (see Figure 19.2B). These posterior language areas function together with Wernicke's area primarily in language comprehension. In addition, the posterior areas appear to contain the **lexicon,** which is important in mapping sounds to meaning for both the comprehension and the production of meaningful language. The language areas of the dominant parietal lobe, especially the angular gyrus, are also important for written language. When one is **reading,** visual information first reaches primary visual cortex in the occipital lobes, is processed in visual association cortex, and then travels anteriorly via the angular gyrus to reach the language areas.

Connections through the corpus callosum (see Figure 19.2B) allow the **nondominant hemisphere** to participate in the language-processing network. The nondominant hemisphere appears to be important in both the recognition and the production of the affective elements of speech. Thus, patients with lesions of the nondominant hemisphere usually have no obvious language disturbance. However, they may have difficulty judging the intended expression imparted by a particular tone of voice, or they may have difficulty producing emotionally appropriate expression in their own voice. Perhaps more importantly, in lesions of the dominant hemisphere, callosal connections may allow the nondominant hemisphere to take over some functions of the damaged areas, and to participate in at least partial recovery.

The language network also has important reciprocal connections with **subcortical structures** such as the thalamus and basal ganglia. Lesions of the thalamus, basal ganglia, or subcortical white matter in the dominant hemisphere can produce aphasia that can sometimes be mistaken for a cortical lesion.

REVIEW EXERCISE

For each of the following, state whether it is more closely associated with Broca's or Wernicke's area:

1. Superior temporal gyrus
2. Areas 44, 45
3. Language formulation and planning
4. Inferior frontal gyrus
5. Area 22
6. Lexicon
7. Syntax
8. Language comprehension

Answers: (B = Broca's area, W = Wernicke's area) 1. W; 2. B; 3. B; 4. B; 5. W; 6. W; 7. B; 8. W.

19.2 **Aphasia,** or dysphasia, is a defect in language processing caused by dysfunction of the dominant cerebral hemisphere. Because aphasia is a disorder of language, and not a simple sensory or motor deficit, both spoken language and written language are affected. Aphasia is not caused by impaired audition or articulation, although deficits in these modalities may coexist

KEY CLINICAL CONCEPT
DIFFERENTIAL DIAGNOSIS OF LANGUAGE DISORDERS

TABLE 19.4 Disorders Commonly Mistaken for Aphasia

Disorders of speech production
Dysarthria
Aphemia (verbal apraxia)
Mutism
Auditory disorders
Peripheral hearing loss
Pure word deafness
Cortical deafness
Defects in arousal and attention
Global confusional state
Narcolepsy
Psychiatric disorders
Schizophrenia
Conversion disorder and other somatoform disorders
Uncooperative patient

with aphasia. The definition of aphasia will become more intuitively clear as we discuss specific examples in the sections that follow.

It is important to distinguish aphasia from several other disorders that affect language but are not specific disorders of language itself (Table 19.4). In motor disorders such as dysarthria (see KCC 12.8) and aphemia (verbal apraxia) (see KCC 19.7), speech may be difficult to comprehend; however, it has normal content and grammar, and written language is often normal. Mutism may result from severe aphasia or from motor disorders, which can sometimes be distinguished by other clues, such as writing. Similarly, in peripheral (see KCC 12.5) or central (see KCC 19.7) auditory disorders, perception of spoken language is impaired, but reading and other aspects of language are normal.

Disorders of arousal and attention from a variety of causes (see Chapter 14), including toxic or metabolic disorders, post-ictal state, brainstem ischemia, and sleep disorders, are occasionally mistaken for aphasia because of the impaired comprehension and incoherent speech seen in these conditions. Finally, psychiatric disorders are sometimes confused with aphasia. In particular, schizophrenic patients may have very disordered, nonsensical, clanging speech, full of neologisms, which may resemble aphasia. It is important to recognize that the opposite situation can also be hazardous, in which a patient with aphasia is incorrectly given one of the diagnoses in Table 19.4. Through careful examination of the patient, as discussed in the following sections, it is usually possible to make these critical distinctions.

The most common cause of acute onset of aphasia is cerebral infarct, as we will discuss through multiple examples in this chapter. However, aphasia can also be caused by a wide variety of other disorders of the dominant hemisphere, (Table 19.5). ■

KEY CLINICAL CONCEPT
BEDSIDE LANGUAGE EXAM

Comprehension

19.3 Examination of language is an integral part of the mental status exam (see KCC 19.1). The language exam is often very helpful in alerting the examiner to the presence of a focal brain lesion and in identifying its localization. In some patients, the presence of subtle language dysfunction goes undetected until formally tested.

Benson and Geschwind popularized a six-step bedside examination for language that is still widely used today (Table 19.6). This language exam is demonstrated on neuroexam.com Videos 8–12. We will elaborate on some of the test items as we discuss specific language disorders in the sections that follow. In some situations, referral for more extensive formal neuropsychology testing is appropriate. Note that language testing should be done in the patient's primary language whenever possible. ■

TABLE 19.5 Causes of Aphasia[a]

Cerebral contusion; subdural or epidural hematoma
Ischemic or hemorrhagic vascular events
Ictal or post-ictal deficit with focal seizures in dominant hemisphere
Mass lesions such as brain tumor, abscess, or toxoplasmosis
Inflammatory or autoimmune disorders such as multiple sclerosis or vasculitis
Developmental disorders such as language delay or autism
Degenerative disorders such as primary progressive aphasia, moderately advanced Alzheimer's disease, or Huntington's disease

[a]Following the format of Figure 1.1.

KEY CLINICAL CONCEPT
BROCA'S APHASIA

MNEMONIC

19.4 Broca's aphasia is usually caused by lesions affecting Broca's area and adjacent structures in the dominant frontal lobe (see Figure 19.2). The most common etiology is infarct in the territory of the left middle cerebral artery (MCA) superior division (Figure 19.3A; see also KCC 10.1), although other lesions in this location can produce Broca's aphasia as well. Clinically, the most salient feature of Broca's aphasia is **decreased fluency** of spontaneous speech (see Table 19.6). The impaired fluency in Broca's (in contrast to Wernicke's) aphasia can be remembered by the mnemonic *Broca's broken boca* ("boca" means "mouth" in Spanish). **Fluency** can be surprisingly difficult to define and assess in an objective manner. Some helpful guidelines are that patients with decreased fluency tend to have a **phrase length** of fewer than five words, and the number of **content words** (e.g., nouns) exceeds the number of **function words** (e.g., prepositions, articles, and other syntactic modifiers). Word generation tasks, such as FAS (see KCC 19.11) can be useful for detecting subtle decreases in verbal fluency. In addition, **prosody** (the normal melodious intonation of speech that conveys the meaning of sentence structure) is lacking in patients with Broca's aphasia. The resulting speech in Broca's aphasia has an effortful, telegraphic quality, with a lack of grammatical structure and a monotonous sound.* Speech output is often better for certain overlearned, semiautomatic tasks, such as naming the days of the week or singing familiar songs like "Happy Birthday," and performance is often improved by cuing—that is, providing the first sound of a word during naming tests. Paraphasic errors (see KCC 19.5) occasionally occur, although these are less common than in Wernicke's aphasia.

The decreased fluency in Broca's aphasia is associated with marked **naming difficulties.** In addition, lesions in Broca's area cause a disconnection of this structure from Wernicke's area (see Figure 19.3A). Therefore, in Broca's aphasia **repetition is impaired** as well. Patients tend to have the most difficulty repeating phrases with a high content of function words, such as "No ifs, ands, or buts" or "If I were here, she would be there." In contrast, because the posterior language structures are spared, **comprehension is relatively intact** in Broca's aphasia. The one notable exception is impaired comprehension of **syntactically dependent structures.** For example, when given a passive sentence such as "The lion was killed by the tiger," a patient with Broca's aphasia often incorrectly chooses the tiger as the animal that is dead. **Writing** and **reading** aloud in Broca's aphasia have a slow, effortful, agrammatical quality that is similar to the deficits in spoken language. Reading comprehension is often relatively spared, except for syntactically dependent structures.

Commonly **associated features** in Broca's aphasia include **dysarthria,** and **right hemiparesis** affecting the face and arm more than the leg, especially when left MCA superior division infarct is the cause. Visual fields are usually normal. Other common features are **frustration** and **depression. Apraxia** (see KCC 19.7) may also be present, often affecting the nonparetic left side of the body and oral–buccal–lingual structures.

A distinction is often made between so-called **little Broca's** aphasia and **big Broca's** aphasia. Big Broca's aphasia is caused by large lesions, such as MCA superior division infarcts (see Figure

*In the extreme, patients in the early stages of severe Broca's aphasia may be virtually mute, and then gradually develop the more typical pattern of decreased fluency.

TABLE 19.6 Bedside Language Exam

1. Spontaneous speech
Fluency
Prosody
Grammar and meaning
Paraphasias
Articulation
2. Naming
Visual confrontation naming
Responsive naming
Objects and parts
Nouns, verbs, proper nouns, colors, etc.
3. Comprehension
Commands, simple to complex
Yes/no questions and multiple choice
Point to objects
Syntax-dependent meaning
4. Repetition
Single words
Simple sentences
Complex sentences
5. Reading
Aloud
Comprehension
6. Writing
Patient's name
Copy sentence
Spontaneous sentence

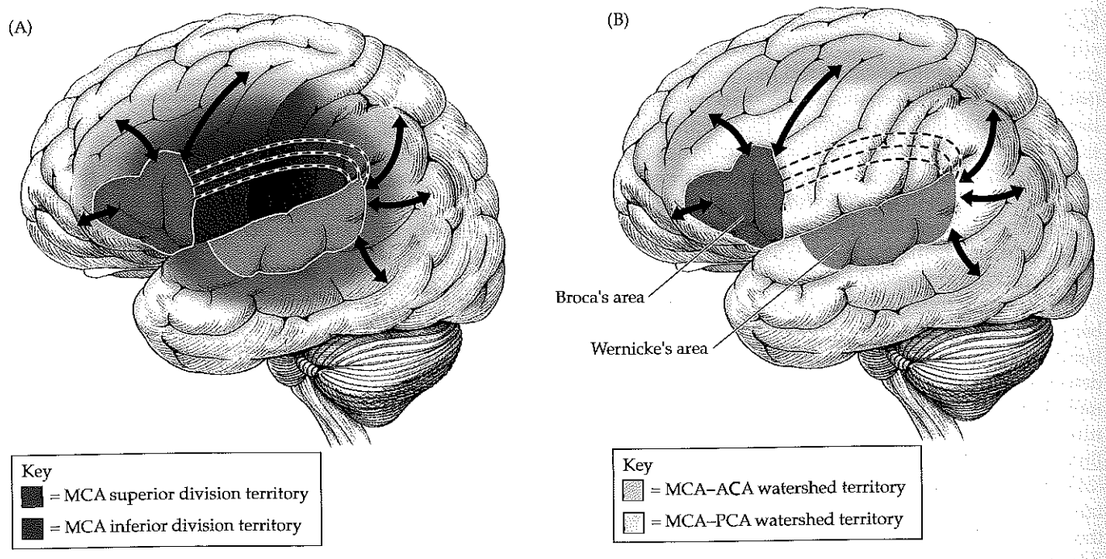

Figure 19.3 Vascular Territories of Language Areas (A) Middle cerebral artery (MCA) superior and inferior division territories. (B) MCA–ACA and MCA–PCA watershed territories. (ACA, anterior cerebral artery; PCA, posterior cerebral artery.)

19.3A), which often involve much of the dominant frontal lobe, as well as subcortical structures. In big Broca's there is initially a **global aphasia** (see KCC 19.6), which improves during recovery to settle into a Broca's aphasia. Little Broca's is caused by smaller lesions, confined to the region of the frontal operculum, including Broca's area. In little Broca's there is initially a Broca's aphasia, which improves during recovery to only mildly decreased fluency and some naming difficulties. ■

KEY CLINICAL CONCEPT
WERNICKE'S APHASIA

19.5 Wernicke's aphasia is usually caused by a lesion of Wernicke's area and adjacent structures in the dominant temporoparietal lobes (see Figure 19.2). The most common etiology is infarct in the left MCA inferior division territory (see Figure 19.3A; see also KCC 10.1), although other lesions can also produce Wernicke's aphasia. Clinically, patients with Wernicke's aphasia have markedly **impaired comprehension** (see Table 19.6). Patient's with severe Wernicke's aphasia do not respond appropriately to questions, and follow virtually no commands. Interestingly, a few commands relating to axial muscles, especially "close your eyes," and sometimes "stick out your tongue" may elicit a correct response despite severe Wernicke's aphasia (and even in global aphasia, discussed in KCC 19.6). Spontaneous speech in Wenicke's aphasia has normal fluency, prosody, and grammatical structure. However, impaired lexical function results in speech that is **empty, meaningless, and full of nonsensical paraphasic errors. Paraphasic errors** can be either inappropriate substitutions of a word for one of similar meaning (verbal or semantic paraphasias), or of a part of a word for one with a similar sound (literal or phonemic paraphasias). For example, a semantic paraphasia is when a patient says "ink" instead of "pen" or "bus" instead of "taxi." A phonemic paraphasia is when a patient says "pish" instead of "fish" or "rot" instead of "rock." Occasional **neologisms,** or nonwords, are used. **Naming** is similarly impaired in Wernicke's aphasia, with frequent paraphasic errors or other irrelevant responses. Lesions of Wernicke's area also result in disconnection from Broca's area (see Figure 19.3A), causing **impaired repetition. Reading and writing** show similar impairments to the

speech deficits in Wernicke's aphasia, and consist of fluent, but meaningless, paraphasic renditions.

Commonly **associated features** in Wernicke's aphasia include a **contralateral visual field cut,** especially of the right upper quadrant (see Figure 11.15E). **Apraxia** may be present (see KCC 19.7), but it can be difficult to demonstrate because of impaired comprehension. Dysarthria and right hemiparesis are usually absent or very mild. In addition, in marked contrast to Broca's aphasia, patients often appear **unaware of their deficit** (anosognosia), behaving as if carrying on a normal conversation despite their markedly abnormal speech. **Angry or paranoid behavior** may occur, causing Wernicke's aphasia occasionally to be misdiagnosed as a psychotic disorder (recall that patients with schizophrenia may also have abnormal speech). Examining a patient with severe Wernicke's aphasia can be difficult because the patient may respond to all questions or commands with nothing but incomprehensible paraphasic jargon. When examining the patient with Broca's aphasia the patient often feels frustrated, while when examining the patient with Wernicke's aphasia, the examiner may feel frustrated.

MNEMONIC

Other names are sometimes used to refer to Broca's aphasia and Wernicke's aphasia, respectively, including expressive and receptive aphasias, motor and sensory aphasias, anterior and posterior aphasias, and nonfluent and fluent aphasias. However, these terms each have drawbacks. For example, Broca's aphasia is not simply an expressive deficit, since comprehension of syntactically dependent structures is impaired. Conversely, Wernicke's aphasia is not simply a receptive deficit, since speech expression is highly paraphasic and largely uninterpretable. Similarly, although Broca's and Wernicke's aphasias are usually caused by anterior and posterior lesions, respectively, this is not always the case. The simple syndromic names Broca's aphasia and Wernicke's aphasia are preferable. ■

KEY CLINICAL CONCEPT
SIMPLIFIED APHASIA CLASSIFICATION SCHEME

19.6 Broca's aphasia and Wernicke's aphasia are prototypical aphasia syndromes that, once understood, allow for easier classification of other aphasia syndromes. In this section we will present a simplified scheme for classifying aphasias that is useful because it is easy to apply and makes anatomical sense (Figure 19.4). Note, however, that aphasias do not always fit neatly into these categories. Left-handed patients, in particular, have more variable distribution of their language areas between the two hemispheres, and they may have aphasia syndromes that do not fit the classification presented here. In addition, many aphasia researchers consider this classification to be oversimplified. Nevertheless, this scheme is useful for most basic clinical purposes.

When examining patients with aphasia, recall that neurologic deficits are not all-or-none phenomena. In addition to deciding on the absence or presence of a deficit such as decreased fluency or impaired comprehension, it is important to assess its severity. This assessment can help both to clarify the diagnosis and to track the clinical progression of the disorder. For example, consider a patient with normal fluency who can comprehend and repeat simple phrases, but who has difficulty comprehending and repeating more complex phrases and has occasional paraphasic errors. Despite the fact that some comprehension is present, this patient would be considered to have Wernicke's aphasia (see KCC 19.5), but in a relatively mild form.

The classification scheme is based on three parts of the language exam: fluency, comprehension, and repetition (see Figure 19.4). The other portions of the exam are important as well, to complete the clinical picture and to distinguish aphasias from other disorders. For example, naming difficulty and paraphasias do not appear explicitly in Figure 19.4 because these two disorders of language can occur in virtually any aphasia syndrome and have little

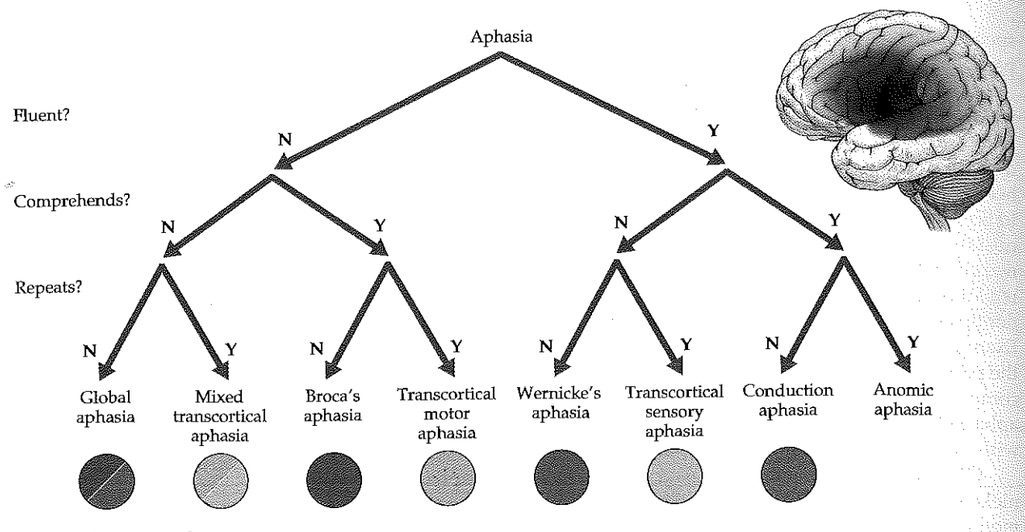

Figure 19.4 Classification of Language Disorders Aphasias can be classified based on fluency, comprehension, and repetition. All patients are assumed to have impaired naming and some paraphasic errors. The usual lesion locations for different forms of aphasia are indicated on the brain inset. Anomic aphasia can occur with lesions in many locations in the language network.

localizing value. Nevertheless, the presence of naming difficulty or paraphasic errors may help suggest the presence of a language disturbance, as opposed to another disorder.

Let's begin tracing the different alternative pathways in the decision tree of Figure 19.4. A patient with impaired fluency, normal comprehension, and impaired repetition has Broca's aphasia (see KCC 19.4). This is often caused by a left MCA superior division infarct (see Figure 19.3A).

Normal fluency with impaired comprehension and impaired repetition is Wernicke's aphasia (see KCC 19.5). Wernicke's aphasia is often caused by a left MCA inferior division infarct (see Figure 19.3A).

A patient with impaired fluency, impaired comprehension, and impaired repetition has **global aphasia.** Global aphasia can be seen in large left MCA infarcts that include both the superior and the inferior divisions (see Figure 19.3A). It can also be seen in the initial stages of large left MCA superior division infarcts that eventually improve to become Broca's aphasia (big Broca's), and in large subcortical infarcts, hemorrhages, or other lesions.

A patient with normal fluency and normal comprehension, but impaired repetition, has **conduction aphasia.** This condition is caused by infarct or other lesions in the peri-Sylvian area that interrupt the arcuate fasciculus or other pathways in the vicinity of the supramarginal gyrus that connect Wernicke's area to Broca's area (see Figure 19.2A). Speech is fluent, paraphasic errors are common, and naming is often impaired, which can lead to a misdiagnosis of Wernicke's aphasia. Unlike the case with Wernicke's aphasia, however, comprehension is spared.

Transcortical aphasias resemble Broca's, Wernicke's, and global aphasias, except that **repetition is spared** (see Figure 19.4). The classic cause of transcortical aphasia is watershed infarcts (see Figure 19.3B; see also KCC 10.2), which spare Broca's area, Wernicke's area, and their interconnections but damage other language areas in the frontal or temporoparietal cortices (see Figure 19.2B). Transcortical aphasias are also common in subcortical lesions, such as those involving the basal ganglia or thalamus in the dominant hemisphere. In addition, transcortical aphasia is a common pattern seen during recovery from other aphasia syndromes.

A patient with impaired fluency and normal comprehension, as in Broca's aphasia, but with spared repetition, has **transcortical motor aphasia.** One possible cause is ACA–MCA watershed infarct (see Figure 19.3B). This lesion destroys connections to other regions of the frontal lobe that are needed for Broca's area to function in language formulation (see Figure 19.2B). However, peri-Sylvian connections from posterior to anterior language areas are left intact, enabling repetition.

A patient with normal fluency but impaired comprehension, as in Wernicke's aphasia, but with intact repetition, has **transcortical sensory aphasia.** MCA–PCA watershed infarcts (see Figure 19.3B) are one possible cause of this disorder. Connections to structures in the parietal lobe and temporal lobe that are needed for Wernicke's area to function are destroyed (see Figure 19.2B), while the peri-Sylvian area is left intact. The result is a condition that resembles Wernicke's aphasia, except that repetition is spared.

A patient with impaired fluency and impaired comprehension, as in global aphasia, but with intact repetition, has **mixed transcortical aphasia,** also called isolation of the language areas. One possible cause is combined MCA–ACA and MCA–PCA watershed infarcts (see Figure 19.3B), although this form of aphasia is often seen in subcortical lesions as well.

Finally, let's consider patients who show normal fluency, normal comprehension, and normal repetition but, like the other patients discussed here, have some naming difficulties and occasional paraphasias. This disorder is called **anomia** or **dysnomia** (see Figure 19.4). Naming difficulties can be severe or relatively mild. Careful testing for subtle dysnomia can be a sensitive indicator of language dysfunction because naming is often the first function to be impaired and the last to recover in language disorders. A careful test of naming is thus an excellent **screening test** for aphasia. Patients with subtle dysnomia often have particular difficulty naming lower-frequency words or parts of objects (see neuroexam.com Video 10). For example, the parts of a watch (face, band, clasp) or a shirt (collar, pocket, sleeve, cuff) are a useful bedside test. Sometimes a similar but incorrect word will be used, such as "clock" for watch or "pencil" for pen (semantic paraphasias). Causes of anomic aphasia are numerous and include subcortical or cortical lesions in the dominant hemisphere, and recovery from more severe forms of aphasia.

Recovery from Aphasia

Although the extent of recovery from aphasia can vary, the nature of recovery tends to follow certain common patterns. Global aphasia seen in big Broca's usually recovers to a Broca's aphasia. Broca's aphasia may recover to a transcortical motor aphasia, and eventually to a subtle dysnomia. Similarly, Wernicke's aphasia may recover to a transcortical sensory aphasia, and then to a dysnomia. Other patients have primarily naming and repetition difficulties following recovery, resembling a conduction aphasia. Dysnomia is the most common long-term deficit, although some patients have other more severe residual deficits as well. Subtle decreases in fluency can be tested for with word generation tasks, as discussed in KCC 19.11. ■

REVIEW EXERCISE

1. On a blank sheet of paper, draw the three-tiered classification tree shown in Figure 19.4 until you are able to reproduce it without referring to the figure.

2. Referring to Figure 19.4, draw a rough sketch showing a lateral view of the left hemisphere. For each of the disorders listed in Figure 19.4 (except anomia), shade in the usual area of infarction and explain how involvement of Broca's area, Wernicke's area, other related association cortex, or white matter connections are responsible for the observed deficits. For each disorder, list the vascular territory or watershed territory most commonly involved.

Naming

19.7 Several important syndromes are related to the aphasic disorders of the dominant hemisphere. These disorders can occur either together with aphasia or in isolation.

KEY CLINICAL CONCEPT
OTHER SYNDROMES RELATED TO APHASIA

Alexia and Agraphia

Alexia and **agraphia** are impairments in reading or writing ability, respectively, that are caused by deficits in central language processing and not by simple sensory or motor deficits. Alexia and agraphia can each occur in isolation, or they can occur together. In patients with aphasia, agraphia is invari-

ably present. This co-occurrence may be due to the fact that normal writing requires intact functioning of the entire language apparatus. When alexia or agraphia occurs as part of an aphasic disorder, the reading and writing abnormalities tend to parallel those of the aphasic syndrome for spoken language. For example, reading aloud is nonfluent and agrammatical in patients with Broca's aphasia, but comprehension is relatively spared, except for syntactically dependent structures. Reading comprehension is impaired in Wernicke's aphasia, and reading aloud is fluent but full of paraphasic errors. Writing in Broca's aphasia is usually performed with the ipsilateral (usually left) nonparetic hand and is labored, agrammatical, and sparse. Writing in Wernicke's aphasia is paraphasic and largely incomprehensible. Lesions that cause aphasia are the most common cause of alexia and agraphia.

Alexia or agraphia can occasionally occur without significant aphasia. **Agraphia without aphasia** can be seen in lesions of the inferior parietal lobule of the language-dominant hemisphere. This may or may not be accompanied by the other features of Gerstmann's syndrome (see the next subsection). Writing requires focused attention and is therefore usually severely abnormal in patients with global confusional disorders (see KCC 19.15). In addition, agraphia in the hand ipsilateral to the language-dominant hemisphere can occasionally be seen in lesions of the corpus callosum because of disconnection of language from motor function (see KCC 19.8).

The classic syndrome of **alexia without agraphia** was first described by Dejerine in 1892, and is caused by a lesion in the dominant occipital cortex extending to the posterior corpus callosum, often a PCA infarct (Figure 19.5). The lesion in the dominant (usually left) occipital cortex prevents the processing of visual information from the right hemifield, including written material. A right hemianopia is therefore usually present (see Figure 11.15). Meanwhile, information about the left hemifield that has reached the right occipital cortex is prevented from crossing to the language areas by the lesion in the posterior corpus callosum (see Figure 19.5), another example of a disconnection syndrome (see KCC 19.8).

Patients who have alexia without agraphia are characteristically able to write normally, but they cannot read even their own writing. Other mild associated deficits are sometimes present, including some degree of anomia, especially **color anomia** (see KCC 19.12). It is not known why the lesion of alexia without agraphia impairs reading so much more than other visual naming tasks, but it is possible that the information for these other tasks crosses the callosum at a different point.

Figure 19.5 Schematic Circuit Diagram of Alexia without Agraphia

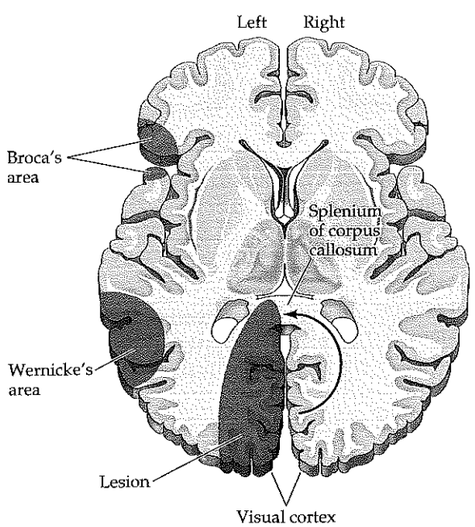

Alexia *with* agraphia can occur with lesions of the dominant inferior parietal lobule, in the region of the angular gyrus (see the next section). In these patients, aphasia is sometimes absent or may consist of only mild dysnomia and paraphasias. Alexia, which is an acquired deficit in reading, should be distinguished from **dyslexia,** a developmental reading disorder.

Before reading and writing abilities are tested, it is important to obtain a history of the patient's educational level and previous literacy skills because these factors can greatly influence the results of assessment.

Gerstmann's Syndrome

Gerstmann's syndrome consists of the following somewhat odd tetrad of clinical findings: (1) **agraphia;** (2) **acalculia** (impaired arithmetic calculating abilities); (3) **right–left disorientation** (difficulty identifying the right versus left side of the body); and (4) **finger agnosia** (inability to name or identify individual fingers). **Agnosia** has been defined by Teuber as "a normal percept stripped of its meanings." Specific agnosias have been described for a variety of visual, auditory, and other percepts, as we will see in this chapter. Each of the single components of Gerstmann's syndrome, when found in isolation, has little specific localizing value and can be seen in a variety of brain disorders. However, when all four components are present in the absence of a global confusional state or other diffuse disorder, this syndrome is strongly localizing to the **dominant inferior parietal lobule,** in the region of the angular gyrus. Gerstmann's syndrome can occur as a relatively pure syndrome, but it is more often accompanied by other deficits localizing to the dominant inferior parietal lobule, such as a contralateral visual field cut (see Figure 11.15), alexia, anomia, or more severe aphasia.

Apraxia

Apraxia, or more specifically, **ideomotor apraxia,** is the inability to carry out an action in response to verbal command, in the absence of any comprehension deficit, motor weakness, or incoordination. It is caused by an inability to formulate the correct movement sequence. In testing for apraxia, the patient is usually asked to carry out imaginary actions, such as saluting the flag, brushing their hair, lighting a match and blowing it out, and so on (see neuroexam.com Video 15). Patients with apraxia make awkward-looking attempts and perform tasks ineffectually. In mild apraxia, patients may exhibit **body part substitution**—for example, using their index finger like a toothbrush instead of holding an imaginary toothbrush between their fingers in the normal fashion. Intact comprehension of the command should be confirmed by multiple choice, with different actions demonstrated by the examiner. In addition, the patient should have intact motor skills that would allow performance of the task, which can be demonstrated if the patient spontaneously performs the same task or a similar task involving the same muscles at another time. These strict criteria are hard to meet, and sometimes a patient's inability to perform a task is best described as "probably" resulting from apraxia.

Praxis

Apraxia is not a very well localized disorder, and it can be caused by lesions in many locations. However, there is an association between apraxia and aphasia: At least one-third of patients with aphasia have some apraxia. Apraxia can affect orofacial, proximal, or distal limb movements differentially. Thus, some patients may have particular difficulty puckering their lips or sticking out their tongues on command, while others may have more difficulty with other body movements.

In addition to ideomotor apraxia (usually known simply as apraxia), the term "apraxia" has been applied to a variety of other, seemingly unrelated disorders. For discussion of conditions such as dressing apraxia, ocular apraxia, constructional apraxia, gait apraxia, ideational apraxia, and so on, consult the references at the end of this chapter.

REVIEW EXERCISE

Using Figure 19.5 as a guide, draw a rough sketch of the circuit involved in reading, and explain how a lesion of the left occipital cortex and posterior corpus callosum can cause alexia without agraphia.

Aphemia (Verbal Apraxia)

In **aphemia,** patients have severe apraxia of the speech articulatory apparatus, without a language disturbance. Aphemia is usually caused by a small lesion of the dominant frontal operculum restricted to Broca's area. In contrast to patients with Broca's aphasia, these patients have normal written language. Patients with aphemia have effortful, poorly articulated speech sometimes referred to as **foreign accent syndrome.** Severe aphemia can cause muteness, with preserved writing ability. Aphemia also occurs as a developmental disorder in children, often without a visible lesion on imaging studies. It is referred to as **verbal apraxia** in this context.

REVIEW EXERCISE

Fill in the blank:

Pure word deafness is to Wernicke's aphasia as aphemia is to _____.

(Answer: The syndrome described in KCC 19.4.)

Cortical Deafness, Pure Word Deafness, and Nonverbal Auditory Agnosia

Patients with **cortical deafness** have bilateral lesions of the primary auditory cortex in Heschl's gyrus (see Figure 19.1). These patients are often aware that a sound has occurred but are unable to interpret verbal stimuli and cannot identify nonverbal stimuli such as a telephone ringing or a dog barking. In contrast, patients with **pure word deafness,** or verbal auditory agnosia, can identify nonverbal sounds but cannot understand any spoken words. Unlike Wernicke's aphasia patients, these patients can read and write normally. Although a few paraphasic errors may occur early on, speech is usually normal within a few days of onset.

The lesion in pure word deafness is usually an infarct in the auditory area of the dominant hemisphere that extends to the subcortical white matter, cutting off auditory input from the contralateral hemisphere as well (another disconnection syndrome; see KCC 19.8). Some patients with pure word deafness have also been reported with bilateral lesions of the superior temporal gyrus. In **nonverbal auditory agnosia,** patients understand speech but cannot identify nonverbal sounds. The lesion in nonverbal auditory agnosia is usually located in the nondominant hemisphere. ■

KEY CLINICAL CONCEPT
DISCONNECTION SYNDROMES

19.8 In **disconnection syndromes**, cognitive dysfunction is caused by damage to pathways that connect one cortical area to another. We have already discussed several disconnection syndromes in this chapter, including conduction aphasia, impaired repetition in Broca's and Wernicke's aphasia (see Figures 19.3, 19.4), alexia without agraphia (see Figure 19.5), and pure word deafness (see KCC 19.7). We also mentioned, when discussing Broca'a aphasia (see KCC 19.4) that left MCA superior division infarcts can cause apraxia of the left (nonweak) hand. Figure 19.6 demonstrates how a lesion in this location can disconnect the language areas and premotor cortex of the dominant left hemisphere from the right hemisphere premotor cortex, resulting in left hand apraxia.

Lesions of the corpus callosum can produce several additional classic disconnection syndromes. Naturally occurring **lesions involving primarily the corpus callosum** are relatively uncommon, but they can be seen in multiple sclerosis, gliomas, metastases, lymphoma, lipoma, and infarcts (ACA or PCA territory). **Corpus callosotomy** is occasionally performed in cases of medically refractory, poorly localized epilepsy, in which falls are a major problem (see KCC 18.2). The goal in these cases is to prevent secondary generalization—not to cure the seizures. After corpus callosotomy, the right hemisphere is unable to access language functions in the left hemisphere. Therefore, there may be agraphia of the left hand, inability to name objects placed in the left hand with the eyes closed, and inability to read in the left hemifield (usually detectable only with special testing apparatus). Other information also cannot be transferred between the hemispheres. Therefore, for example, if the patients are blindfolded and given an object to feel with one hand, they may then be unable to select that object from others using the contralateral hand. Some patients may have difficulty with tasks that require bimanual coordination, and in extreme cases the two hands may even work against each other. In most cases of callosotomy, however, what is surprising is not the deficits, but rather how functional these patients are in daily life despite the separation of the two hemispheres.

A Wada test (seeKCC 18.2) can be helpful to predict some of the more severe deficits that occasionally occur following callosotomy. For example, the Wada test could show that a patient is left hemisphere dominant for language but has significant memory function only in the right hemisphere. In this case, callosotomy would disconnect language (left hemisphere) from memory functions (right hemisphere) and could produce a severe verbal memory deficit. Similarly, a patient who writes with the left hand could be found on Wada testing to be left hemisphere dominant for language. In this case, callosotomy would disconnect left hand motor control (right hemisphere) from language (left hemisphere) and could produce agraphia. ■

Figure 19.6 Disconnection Syndrome in which a Left Middle-Cerebral Artery (MCA) Superior Division Infarct Causes Left-Hand Apraxia

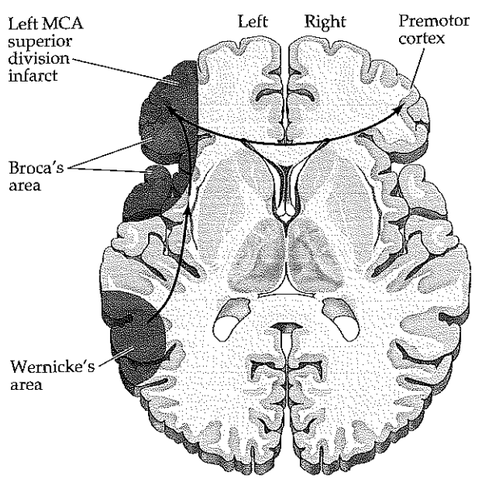

The Nondominant Hemisphere: Mechanisms of Attention and Spatial Processing

Exploring the functions of the **nondominant (usually right) hemisphere** brings us tantalizingly close to the fundamental mechanisms of consciousness. While the dominant hemisphere is specialized for language and step-by-step formulation and execution of motor tasks, the nondominant hemisphere is more important for **attention** and for generating an **integrated visual-spatial gestalt.** In this section we will emphasize the more localized functions of the nondominant hemisphere in directed attention to the contralateral hemispace and in visual-spatial processing. The role of the nondominant hemisphere, and of other more distributed networks in global attentional mechanisms (such as generalized vigilance, concentration, and behavioral arousal), will be discussed later in this chapter.

Lateralized Aspects of Attention

Attention includes two major components:

1. **Global attention** (discussed later in this chapter) includes functions such as vigilance, concentration, and generalized behavioral arousal.
2. **Selective, or directed attention** involves focusing attention on a particular domain above others.

The circuits involved in these two aspects of attention share many common components and mechanisms. We began learning about these networks through our discussions of brainstem and diencephalic activating systems in Chapter 14. Thus, attention (like alertness) depends on activating systems such as the pontomesencephalic reticular formation (see Figures 14.7, 14.8), thalamic intralaminar nuclei and other diencephalic structures, widespread projecting neuromodulatory systems (see Figures 14.9–14.13), as well as the cingulate gyrus and other limbic, frontal, and parietal higher-order association cortices (see Figure 19.1).

Although both hemispheres are involved, there is a marked asymmetry in the relative importance of the two hemispheres, and **the right hemisphere is more important for attentional mechanisms in most individuals.** As we will discuss in KCC 19.9, lesions of the right hemisphere often lead to prominent and long-lasting deficits in attention to the contralateral side, while in left hemisphere lesions, contralateral neglect is relatively mild or undetectable. In studies of normal individuals using functional neuroimaging or electrophysiological investigations, the left hemisphere responds to stimuli on the right side, while the right hemisphere responds to both left- and right-sided stimuli but more strongly to stimuli on the left. (This is analogous to the involvement of the right premotor cortex in movement of the left hand and of the left premotor cortex in movement of both the right and left hands, discussed earlier.)

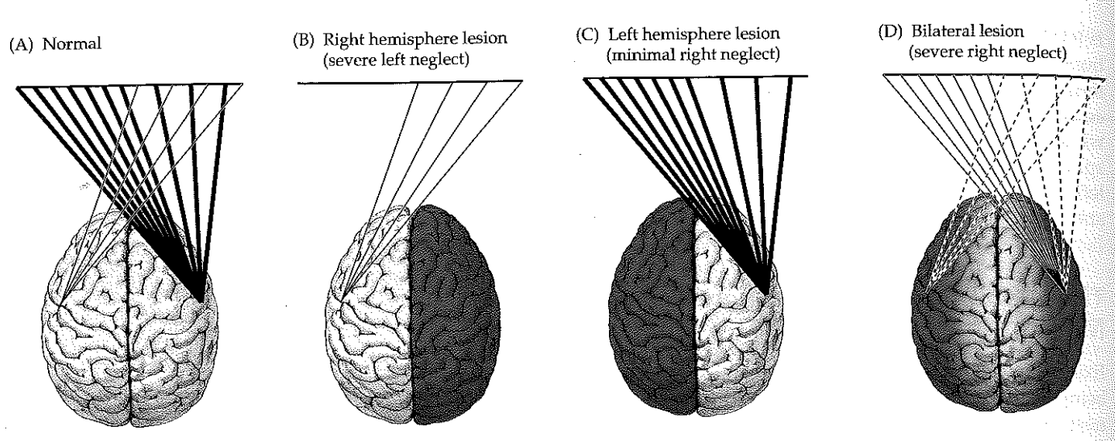

Figure 19.7 Hemispheric Asymmetry in Attention Demonstrated through Attentional Rays

The hemispheric asymmetry of attentional mechanisms, and the effects of lesions, are shown schematically with "attention rays" in Figure 19.7. Under normal conditions (Figure 19.7A), the right hemisphere attends strongly to the left side and less strongly to the right side, while the left hemisphere attends mainly to the right side. The result is a very slight net attentional bias toward the left in most individuals, which may explain why many languages are written from left to right. With right hemisphere lesions (see Figure 19.7B), the left hemisphere is still able to attend to the right side, but there is a profound deficit in attention to the left. In addition, there is a milder deficit in attention on the right side (ipsilateral to the lesion) as well. With left hemisphere lesions (see Figure 19.7C), the right hemisphere is still able to attend to the right side, so only mild right-sided deficits or no deficits in attention are seen. Finally, with bilateral partial lesions (see Figure 19.7D), there is some residual ability of the right hemisphere to attend to the left side only, resulting in a marked deficit in attention to the right. As we discussed in the section on cerebral lateralization earlier in this chapter, the reasons for left hemisphere specialization for language and right hemisphere specialization for attention and spatial analysis are not known.

REVIEW EXERCISE

What deficits in attention are expected with:

Right hemisphere lesions?

Left hemisphere lesions?

Bilateral partial lesions?

Spatial Analysis and Integration

Spatial analysis depends on integration of information from multiple sensory modalities; however, since vision plays such an important role in human perception, the term "visual-spatial analysis" is often used. Like other mental functions, visual-spatial analysis is performed by a distributed network and depends on bilateral regions of the frontal and parietal association cortex. However, the **parietal association cortex** at the junction of the parietal, temporal, and occipital lobes is especially important for spatial analysis, and the **nondominant (usually right) hemisphere** is more important than the left.

As we discussed in Chapter 11, and will further discuss later in this chapter, visual information is analyzed by two streams of higher-order information processing: a *"What?"* stream in the *ventral* occipital, temporal, and prefrontal cortex, and a *"Where?"* stream in the *dorsal* occipital, parietal, and prefrontal cortex (see Figure 19.12). The parietal association cortex at the junction of the parietal, temporal, and occipital lobes (see Figure 19.1) lies directly in the dorsal stream, analyzing **location and movement of visual objects in space.** The posterior parietal cortex is also ideally situated to integrate other sources of spatial information from adjacent cortical areas. Spatial analysis thus encompasses both the surrounding environment and the relative position of the individual's body in space, using **visual, proprioceptive, vestibular, auditory,** and other information from adjacent cortical areas (see Figure 19.1). As we will discuss in KCC 19.10, disorders of spatial analysis such as impaired visual-spatial judgment or spatial constructional abilities are most commonly seen in lesions of the right parietal cortex, but can be seen with lesions on other areas as well.

KEY CLINICAL CONCEPT
HEMINEGLECT SYNDROME

19.9 One of the most dramatic syndromes in clinical neurology is hemineglect syndrome, seen most often with infarcts or other acute lesions of the right parietal or right frontal lobes. Patients with this syndrome often exhibit profound neglect for the contralateral half of the external world, as well as for the contralateral half of their own bodies. Most strikingly, despite their profound deficits, these patients are often unaware that anything is wrong, and they sometimes even fail to recognize that the left sides of their bodies belong to them.

Contralateral hemineglect occurs most often with lesions of the **right parietal or frontal cortex** (Figure 19.8). Cases of contralateral neglect also occasionally occur with lesions of the cingulate gyrus, thalamus, basal ganglia, or midbrain reticular formation. As we have already discussed, neglect is usually much more pronounced and lasts longer with right hemisphere lesions, but milder forms of neglect can occur with left hemisphere lesions as well (see Figure 19.7).

Neglect is most severe in lesions of sudden onset such as infarct, hemorrhage, seizures, or head trauma, but it can also be seen in more slowly developing lesions, such as brain tumors or other space-occupying lesions. In large strokes, recovery from hemineglect can take weeks to months, and

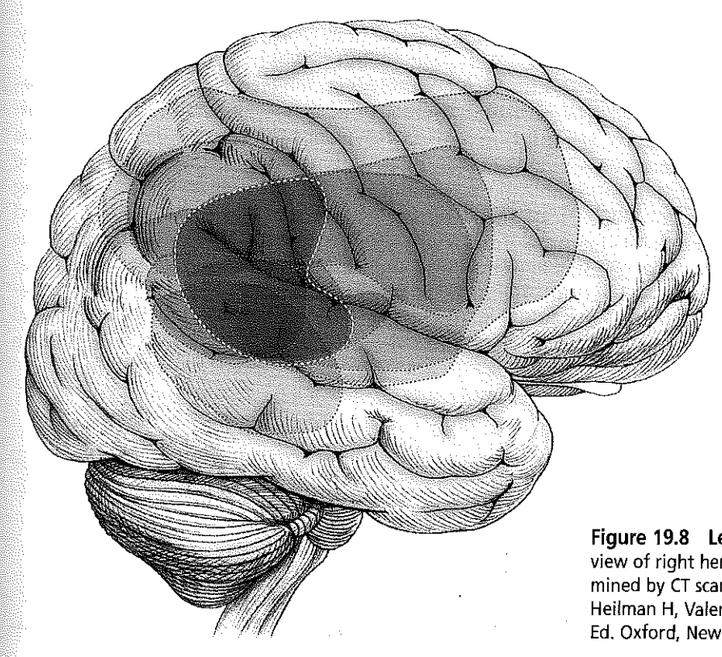

Figure 19.8 Lesions Causing Left Hemineglect Lateral view of right hemisphere with superimposed lesions, as determined by CT scan, for 8 patients with left hemineglect. (After Heilman H, Valenstein E. 1985. *Clinical Neuropsychology.* 2nd Ed. Oxford, New York.)

some patients remain with a permanent deficit in contralateral attention. During the recovery period, patients with hemineglect are more prone to injury and falls, and they may inadvertently bump or injure their contralateral side. Driving should be avoided until patients are able to demonstrate normal attention to both sides.

Testing for Hemineglect on Patient Examination

Clues to the presence of hemineglect include a history of the patient's bumping into objects on one side, ignoring food on one side of the plate, or being unaware of deficits. In addition, careful observation of the patient's behavior, movements, and grooming (some patients may comb or shave only their right side!) can be helpful. Other associated features of nondominant hemisphere lesions are discussed in KCC 19.10.

Four main types of testing can be performed on patient examination to evaluate different aspects of the hemineglect syndrome (Table 19.7). Tests usually evaluate **sensory neglect,** in which patients ignore visual, tactile, or auditory stimuli in the contralateral hemispace; **motor-intentional neglect,** in which patients perform fewer movements in the contralateral hemispace; **combined sensory and motor neglect;** and **conceptual neglect,** in which the patients' internal representations of their own bodies or of the external world exhibit contralateral hemineglect. Many tasks used to test for hemineglect depend on more than one component of the neglect syndrome. For example, drawing the face of a clock from memory depends on all of the above components. Although it has been postulated that more posterior or anterior lesions may cause more sensory or motor neglect, respectively, this has not been consistently demonstrated, and the sublocalization of different aspects of the hemineglect syndrome is still under active investigation.

In the subsections that follow, we will describe several useful tests for evaluating different aspects of the hemineglect syndrome.

Testing for Sensory Neglect

Visual extinction

Tactile extinction

Hemineglect can be present in just one or in more than one sensory modality. **Tactile hemineglect** is most common, but **visual hemineglect** is fairly common as well, with **auditory hemineglect** detected less frequently. As described in Chapter 3, **visual, tactile, or auditory extinction on double simultaneous stimulation** are useful tests of sensory hemineglect (see neuroexam.com Videos 27, 42, 77). For the results of extinction testing to be valid, it is important first to establish normal primary sensation by testing each side alone. Next, unilateral and bilateral presentations of stimuli should be randomly intermixed and the patient asked to report whether the stimulus was on the right, left, or both sides (eyes should be closed for tactile and auditory testing). With subtle neglect, extinction may be inconsistent. In addition, to bring out subtle tactile neglect, a proximal stimulus on the normal side (touching the left cheek) may produce extinction of a distal stimulus on the neglected side (touching the right hand), whereas when the sides are reversed, both stimuli may be reported (see neuroexam.com Video 77).

TABLE 19.7 Types of Neglect Tested on Patient Examination

1. Sensory neglect (visual, tactile, or auditory)
2. Motor-intentional neglect
3. Combination of sensory and motor neglect
4. Conceptual neglect

Patients with hemineglect commonly exhibit **allesthesia,** in which they erroneously report the location of a stimulus given to the right side of the body as being on the left. The extent of sensory neglect may vary depending on the relative position of the stimulus to the patient's eyes, head, or body. The frame of reference that is most important varies from patient to patient. For example, some patients may completely ignore both sides of a visual stimulus when it is placed to the left of their bodies, while ignoring only the left half of the stimulus when it is placed directly in front of them. Therefore, it is usually best to examine patients with the eyes, head, and body aligned straight ahead, and to present the stimuli symmetrically. This may be difficult with patients who have a marked unilateral gaze preference (see the next subsection).

Testing for Motor-Intentional Neglect

Patients should be observed for akinesia or decreased spontaneous movements of unilateral limbs or trunk, or eye movements. A marked ipsilateral gaze preference (toward the lesion) is common, especially in acute frontal or parietal lesions (see Figure 13.15A). Patients may exhibit motor impersistence (see KCC 19.4), especially of the contralateral limbs. They may have apparently decreased motor power on the neglected side, yet normal power may be demonstrated with increased effort, increased motivation, and active redirection of the patient's attention to the neglected side. The examiner can demonstrate **motor extinction** with the patient's eyes closed by randomly intermixing commands to raise the right arm, left arm, or both. **Allokinesia** may also be present, in which the patient inappropriately moves the normal limb when asked to move the neglected limb.

A useful test of hemineglect in patients who are encephalopathic (see KCC 19.14, 19.15) or have difficulty following commands is the **tactile response test.** Patients are instructed to raise whichever limb is touched, obviating the need for them to attend to and interpret the commands "right," "left," or "both." Once they understand the task, more subtle deficits can be detected during this test if they are asked to close their eyes. Note that the tactile response test is sensitive to both sensory and motor neglect (see the next subsection).

To test motor neglect in isolation, a variant of the tactile response test, called the **crossed response test,** can be used. In this test the patient is asked to move the limb *opposite* the one touched. Some patients may have difficulty understanding this task. Other tests of motor neglect, or of **directional motor bias,** include asking the patient to close their eyes and then point to a spot directly opposite their sternum, or asking them to collect coins from a table while blindfolded. Some patients exhibit **spatial akinesia,** in which movements of the limbs are worse when they are located in the neglected hemispace. The examiner can demonstrate this deficit by asking patients to cross their arms during testing.

Combined Testing for Sensory and Motor Neglect

Many tests of neglect combine sensory and motor modalities, as well as conceptual or representational functions described in the next section. One simple example of combined sensory and motor neglect testing is the tactile response test that was described in the previous section. Other useful tests that combine sensory and motor function often involve the use of pen and paper. Several of these tests are demonstrated on neuroexam.com Video 16. In administering **pen-and-paper tests,** it is essential to ensure that the patient is

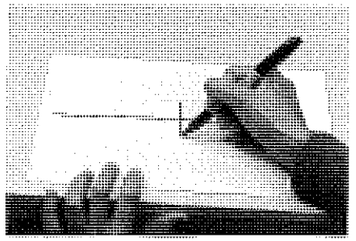

Neglect drawing tests



Figure 19.9 Cancellation Tasks in a Patient with Left Hemineglect
Cancellation tasks from a 50-year-old right-handed man, 2 days after he sustained a right MCA inferior division infarct involving the right temporoparietal cortex. (A) Line bisection task, showing left neglect. (B) A more difficult line cancellation task, making deficit more obvious. (C) A still more difficult task involving letter cancellation among distractors, showing even worse performance.

centered and that the test objects are centered in front of the patient and immobile if possible, to prevent patients from moving the entire stimulus into their non-neglected field. In addition, the stimuli should be large enough that they extend into both fields, again to prevent patients from easily capturing the entire stimulus within their normal hemifield.

In the **line bisection** task, the patient is instructed to cross a horizontally oriented line right in the middle. The line should appear on a blank piece of paper without other cues and should be about 10 inches long. Normal individuals bisect the line right in the middle, or up to about 1 cm to the left of center, whereas patients with hemineglect often bisect the line far to the right of midline (Figures 19.9A, 19.10A). Other, more difficult **cancellation tasks** are useful in detecting and quantifying more subtle neglect. Such tasks include presenting patients with a page filled with numerous small lines for them to cross out, or harder still, a page full of mixed letters or other objects among which they must cancel only certain targets (e.g., the letter A, or all star shapes) while ignoring the distractors (see Figure 19.9B,C). Patients with neglect tend to miss the targets on the left side of the page.

Drawing is a useful test, and famous examples exist of artists who drew only half of objects or faces after developing hemineglect. A standard test is to ask the patient to draw a clock face, taking up as much of the page as possible, and to then fill in the numbers (see Figure 19.10B). Patients can also be asked to draw other objects, such as a flower or a house, and to copy simple or complex figures (see neuroexam.com Video 17). In addition to testing for neglect, drawing tests **constructional abilities** (see KCC 19.10). These visual-spatial functions are often impaired in patients with lesions of the nondominant hemisphere, even when significant hemineglect is not present.

Reading a newspaper or magazine can be helpful in testing for hemineglect. Patients often read only the right few letters or the right few words of headlines. They may also ignore the left half of a picture when asked to **describe a visual scene.** In addition, while **writing,** patients with hemineglect tend to crowd their words onto one side of the page.

Conceptual Neglect

One of the more striking features of hemineglect syndrome is the common occurrence of **anosognosia,** meaning lack of awareness of the illness. Patients with hemiplegia, hemianopia, and hemisensory loss caused by right hemisphere lesions are often perplexed as to why they are in the hospital and may ask to be discharged. Anosognosia is not unique to right hemisphere lesions; it can be seen in other disorders as well. For example, anosognosia is also seen in patients with Wernicke's aphasia (see KCC 19.5), frontal lobe disorders (see



Copy drawing

Figure 19.10 Pen-and-Paper Tasks from Another Patient with Left Hemineglect Test results from an 88-year-old right-handed woman, 1 day after sustaining a right MCA inferior division infarct, again involving the right temporoparietal cortex. (A) Line bisection task. On her first attempt, the patient missed the line entirely and made a mark on the far right margin of the page. When the examiner actively directed her attention to the line, she bisected it, but to the right of midline. Of note, a heavy line was used for this patient because on initial testing with a normal thickness line (as in Figure 19.9A) the patient ignored the line no matter how much her attention was directed to it. (B) Clock-drawing task, demonstrating left hemineglect. Note that this patient demonstrated some perseveration as well (see KCC 19.11) in the tests shown in both (A) and (B).



KCC 19.11), amnesia with confabulation such as that seen in Wernicke–Korsakoff syndrome (see KCC 18.1), and cortical blindness (see KCC 19.12).

Aside from anosognosia, some patients with right hemisphere lesions may exhibit **anosodiaphoria,** in which they are aware that they have severe deficits, yet show no emotional concern or distress about it. An even more bizarre manifestation of hemineglect is **hemiasomatognosia,** in which patients deny that the left half of their body belongs to them. A patient may become distressed because "someone left an arm in my bed." When shown their left extremities, the patient may claim that they belong to someone else, or that they are not even limbs at all.

Other aspects of what we have called conceptual neglect include abnormal internal representations or memories of imagined scenes or experiences. For example, Bisiach and Luzzatti described patients who were asked to recall various landmarks from a square in Milan while facing the cathedral. Patients with left hemineglect could recall details on only the right side of the square. When they were then asked to imagine themselves facing away from the cathedral, the patients were able to describe details on the opposite side of the square. ■

KEY CLINICAL CONCEPT
OTHER CLINICAL FEATURES OF NONDOMINANT HEMISPHERE LESIONS

19.10 Not all patients with nondominant (right) hemisphere lesions have significant hemineglect, and in some patients other deficits may be more troublesome. The most common difficulty encountered by patients with nondominant-hemisphere lesions is in tasks requiring **visual-spatial analysis,** or **constructional abilities,** such as drawing pictures or arranging blocks in specific geometric patterns. Patients may also have marked difficulty judging or matching the orientation of lines displayed at different angles. Deficits in these tasks are usually most severe with right parietal lesions, but they can also be seen with lesions in other locations in the right hemisphere, as well as with lesions of the left parietal lobe. Patients with nondominant-hemisphere lesions often have difficulty appreciating the **gestalt,** or overall spatial arrangement, in such tasks. These patients tend to make errors in the overall organization of the picture or block design, often rotating elements inappropriately in space. In contrast, patients with dominant-hemisphere lesions tend to understand the overall concept, yet omit certain important details.

Patients with nondominant-hemisphere lesions often have relatively severe personality and emotional changes. They may appear bland or apathetic, and in addition to hemineglect, they often display an overall decrease in the level of alertness and attention, especially with acute lesions. On the other hand, irritability is common. Patients with acute right parietal infarcts sometimes exhibit bilateral ptosis, lying in bed with both eyes forcibly closed and becoming very nasty when one attempts to examine them. Some patients are overtly psychotic and have delusions and hallucinations. Patients with nondominant hemisphere lesions also often have difficulty comprehending the emotional content of others' speech (receptive aprosody) and conveying appropriate emotional expression in their own speech (expressive aprosody).

Patients with lesions of the right hippocampal formation, such as mesial temporal sclerosis (see KCC 18.2), may have deficits in visual-spatial memory. For example, these patients may be able to copy a picture, but cannot draw it from memory a few minutes later. Impaired **geographic orientation,** or sense of direction, was thought to be associated with right temporal lesions, although recent studies have emphasized the importance of the right parietal or right occipitotemporal cortex. Many patients with right temporal seizures or lesions have an increased tendency to experience **déjà vu,** and other mystical or religious phenomena. Right hemisphere lesions may also be associated with rare but intriguing disorders such as **Capgras syndrome,** in which patients insist that their friends or family members have all been replaced by identical-looking imposters and **reduplicative paramnesia,** in which patients believe that a person, place, or object exists as two identical copies. ■

TABLE 19.8 Some Functions of the Frontal Lobes

RESTRAINT	INITIATIVE	ORDER
Judgment	Curiosity	Abstract reasoning
Foresight	Spontaneity	Working memory
Perseverance	Motivation	Perspective taking
Delaying gratification	Drive	Planning
Inhibiting socially inappropriate responses	Creativity	Insight
	Shifting cognitive set	Organization
Self-governance	Mental flexibility	Sequencing
Concentration	Personality	Temporal order

The Frontal Lobes: Anatomy and Functions of an Enigmatic Brain Region

More than any other part of the brain, the frontal lobes enable us to function as effective and socially appropriate human beings. It should perhaps be no surprise, therefore, that the frontal lobes are also among the most enigmatic, contradictory, and difficult to study brain regions. The importance of the frontal lobes has been debated over the years, with some earlier researchers believing that the frontal lobes are generally superfluous, and others feeling that they are the most important part of the brain. These different opinions arose because patients with frontal lobe lesions often have no deficits that can be detected on routine testing, yet they are completely unable to function normally in the "laboratory" of the real world. Additional complexity is evident in the wide variety of functions ascribed to the frontal lobes, some of which are listed in Table 19.8. Similarly, lesions of the frontal lobes produce highly variable behavioral syndromes, many of which seem contradictory even within a single patient (Table 19.9).

It should be clear from this discussion that there is no single frontal lobe syndrome. Frontal lobe function is probably best viewed as comprising several different realms, which we will present in this section, in somewhat simplified fashion, as clustering around the following three domains: restraint, initiative, and order (see Table 19.8). First, however, we will review the regional anatomy of the frontal lobes and some of the more important connections of frontal lobe circuitry.

TABLE 19.9 Apparently Contradictory Behavior Seen in Frontal Lobe Syndromes

Apathetic indifference	vs.	Explosive emotional lability
Abulia	vs.	Environmental dependency
Akinesia	vs.	Distractibility
Perseveration	vs.	Impersistence
Mutism	vs.	Confabulation
Depression	vs.	Mania
Hyposexuality	vs.	Hypersexuality

Regional Anatomy of the Frontal Lobes

The frontal lobes are the largest region of the brain, comprising nearly one-third of the cerebral cortex. Recall that the frontal lobes are separated from the parietal lobes by the central sulcus, and from the temporal lobes by the Sylvian fissure (Figure 19.11A). The frontal

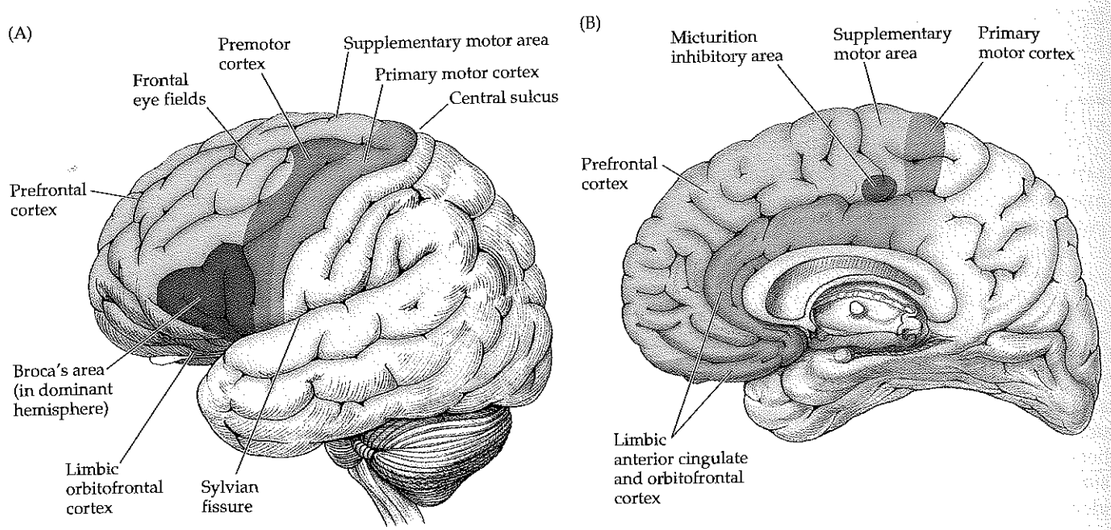

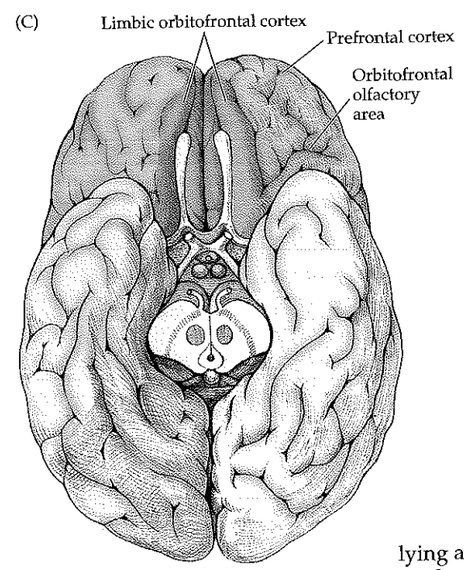

Figure 19.11 Main Functional Areas of Frontal Cortex Prefrontal cortex, motor cortex, and limbic cortex are indicated. (A) Lateral surface. (B) Medial surface. (C) Orbitofrontal surface.

lobes have three surfaces: lateral, medial, and orbitofrontal (see Figure 19.11 A, B, and C, respectively). Let's study these three surfaces and briefly review the regions of frontal cortex discussed in previous chapters. On the lateral surface, the primary motor cortex lies in the precentral gyrus (see Figure 19.11A). The primary motor cortex continues medially in the anterior portion of the paracentral lobule. Just in front of the primary motor cortex, on the lateral surface, lie the premotor cortex and, in the dominant hemisphere, Broca's area. In front of the primary motor cortex on the medial surface is the supplementary motor area (see Figure 19.11B). The motor, premotor, and supplementary motor cortex were discussed in Chapters 6, 15, and 16. The frontal eye fields are located in the premotor cortex on the lateral convexity and extend anteriorly, as discussed in Chapter 13 (see Figure 13.14). The medial frontal lobes contain a micturition inhibitory area (see Figure 19.11B; KCC 7.5). In addition, as we discussed in Chapter 18, the anterior cingulate gyrus and posteromedial orbitofrontal cortex are important limbic areas that lie in the frontal lobes (see Figure 19.11B), and the ventral frontal lobes contain the orbitofrontal olfactory area (see Figure 19.11C).

The discussion in this section will focus on the frontal cortex lying anterior to the motor, premotor, and limbic areas, which is called the **prefrontal cortex** (see Figure 19.11). The prefrontal cortex is the largest part of the frontal lobes and consists of higher-order heteromodal association cortex. It is the prefrontal cortex that is usually being referred to when disorders of the frontal lobe are discussed.

Connections of the Prefrontal Cortex

The prefrontal cortex has numerous cortical and subcortical connections, which have been studied most extensively in nonhuman primates. Most of these connections are bidirectional. The anatomical configuration of frontal lobe connections is compatible with the role of this lobe in higher-order processes that require integration of multimodal sensory, motor, and limbic

information. **Cortical connections** are mainly with the **association cortex** of the parietal, occipital, and temporal lobes, including unimodal sensory association cortex and heteromodal association cortex. In addition, there are connections with motor association cortex in the frontal lobes. Important connections of the prefrontal cortex with **limbic cortex** exist as well, especially with the anterior cingulate gyrus and posteromedial orbitofrontal cortex. **Subcortical connections** are numerous as well. The **amygdala** is connected with the orbital and medial portions of the frontal lobes by the uncinate fasciculus (see Figure 18.4B,C). The frontal lobes are connected to anteromedial temporal cortex by the uncinate fasciculus and to the **hippocampal formation** via the cingulate gyrus and parahippocampal gyrus (see Figure 18.9).

The most important **thalamic nucleus** that relays information to and receives projections back from the prefrontal cortex is the **mediodorsal nucleus**, although connections with the medial pulvinar and intralaminar nuclei are present as well (see Figure 7.8). The prefrontal cortex projects to the **basal ganglia** mainly via the head of the caudate nucleus (see Figure 16.8; Table 16.2). Other important subcortical connections also exist with the hypothalamus, septal region, subthalamic region, cerebellum, and midbrain. Finally, like all other cortical areas, the frontal lobes receive projections from multiple subcortical and brainstem modulatory neurotransmitter systems, including dopamine, acetylcholine, serotonin, norepinephrine, and histamine.

REVIEW EXERCISE

Cover the labels in Figure 19.11 and name each cortical region of the frontal lobe.

Functions of the Frontal Lobes

As mentioned already, frontal lobe functions are quite diverse and apparently contradictory at times (see Tables 19.8, 19.9). The frontal lobes are crucial for the sophisticated decisions we make, and for the subtle social interactions we continually engage in as normal humans. The vast range of human proclivities have been classified into three categories by philosophers and scientists from Plato to Freud, and we will follow this traditional simplification in describing the functions of the frontal lobes. These can be classified as functions important for (1) **restraint** (inhibition of inappropriate behaviors), (2) **initiative** (motivation to pursue positive or productive activities), and (3) **order** (the capacity to correctly perform sequencing tasks and a variety of other cognitive operations) (mnemonic RIO). The functions listed in Table 19.8 are arranged according to this scheme. Note, however, that this is only a simplification, and that some frontal lobe functions do not fit easily into any one of these categories.

MNEMONIC

You will get a better sense for frontal lobe functions when we review frontal lobe disorders in KCC 19.11. Here we will discuss only briefly a few frontal lobe functions that have been studied extensively in the research setting. **Working memory** (see Table 18.6) is the ability to hold a limited amount of information in an immediately available store while a variety of cognitive operations are performed. An example is the carrying function in arithmetic. Both studies in animals and functional imaging in humans have shown the importance of the dorsolateral prefrontal cortex in working memory.

Recent functional imaging studies have also shown that the dorsolateral prefrontal cortex may function together with the medial temporal lobes in **learning new material.** In these studies, the left frontal lobe and medial temporal lobes showed activation during learning of new verbal information that was later successfully recalled. Similarly, the right frontal lobe and medial temporal lobes showed activation during learning of new nonverbal information that was later successfully recalled.

Activation of the dorsolateral frontal cortices has also been shown during tasks that require **shifting cognitive set.** An example is the Wisconsin Card

Sorting Test, in which subjects must have the mental flexibility to infer that the rules for the sorting task they are performing change repeatedly. Interestingly, the frontal lobes are also activated during tasks that require **selective attention**—for example, listening to words while visual or tactile stimuli are presented simultaneously. Another important area of research has been the role of the frontal lobes in **integrating information from limbic and heteromodal association cortex** in decision making. This emotional weighting of abstract decision making is thought to enable subtle emotional and motivational factors to participate in human judgment so that more efficient, or "intuitive," decisions can be made when limited information and time are available.

KEY CLINICAL CONCEPT
FRONTAL LOBE DISORDERS

19.11 As shown in Table 19.9, the effects of frontal lobe lesions are often perplexing, with apparently contradictory features seen in different patients, or even within a single patient. Several explanations have been offered for this observation. First, the frontal lobes are large, encompassing many different functional areas. Frontal lobe deficits are often subtle at first, and lesions may reach a large size and involve several different functional areas before becoming clinically apparent. Similarly, bilateral lesions usually produce more clinically obvious deficits than unilateral lesions, and behaviorally complex disorders result from bilateral lesions. Finally, the functions of the frontal lobes are themselves complex and therefore difficult to study, especially in the formal examination setting.

On the basis of studies of animals and humans with frontal lobe lesions, a distinction is sometimes made between lesions of the dorsolateral convexity and lesions of the orbitofrontal cortex. According to this scheme, **dorsolateral convexity lesions** tend to produce an apathetic, lifeless, **abulic** (opposite of ebullient) state, while **orbitofrontal lesions** lead to impulsive, disinhibited behavior and poor judgment. In clinical practice, numerous exceptions to this dichotomy exist. In addition, many frontal lesions affect both dorsolateral and orbitofrontal regions, making the usefulness of this classification somewhat limited. Another distinction has been made, between **left frontal lesions,** which on the whole are more commonly associated with depression-like symptoms, and **right frontal lesions,** which are more commonly associated with behavioral disturbances resembling mania. Again, numerous exceptions exist.

Despite these contradictions and uncertainties, certain characteristic features revealed during evaluation of a patient can suggest frontal lobe dysfunction. Familiarity with these features is important for recognizing patients with probable frontal lobe dysfunction, so we will now discuss them in detail.

Evaluating Patients with Suspected Frontal Lobe Dysfunction

The basic steps of clinical assessment for patients with suspected frontal lobe dysfunction are summarized in Table 19.10. The most important information in evaluating patients with suspected frontal dysfunction is often not obtained during the formal neurologic exam. Critical evidence of frontal lobe dysfunction may be obtained from the patient's **history** and through discussions with family and other contacts who have witnessed the patient's abnormal functioning in the real world. In addition, careful observations should be made for certain **behavioral abnormalities** that may be seen in patients with frontal lobe dysfunction (see Table 19.10).

Abulic patients are passive, exhibiting little spontaneous activity, markedly delayed responses, and a tendency to speak briefly or softly. In the extreme, they may be totally immobile, akinetic, and mute but will continue to appear awake, sitting with their eyes open. In contrast, **disinhibition** may also be seen, including silly behavior, crass jokes, and aggressive outbursts. Some patients exhibit **inappropriate jocularity,** or **witzelsucht,** seeming unconcerned about potentially serious matters. Patients may have **limited insight** into their condition and may **confabulate.** Patients who display **utilization behavior** or **environmental dependency** tend to respond to whatever stimuli are at hand, even when not appropriate. For example, they may put on glasses that are not theirs. **Perseveration, impersistence,** and **frontal release signs** are tested for during the neurologic exam, but they may also be observed spontaneously, especially in more severely affected patients. Patients with severe perseveration may repeatedly answer the same question even when the examiner is trying to move on. **Incontinence** is sometimes seen in frontal lobe disorders, especially those affecting the medial frontal regions. Patients are characteristically unconcerned about their incontinence.

During the **mental status** portion of the neurologic exam, important clues can be obtained about possible frontal lobe dysfunction. Note that many of these tests do not test frontal lobe function alone, but depend on intact functioning of numerous other systems, which should be assessed during the remainder of the exam. The tests listed here were selected for their clinical usefulness in detecting subtle frontal lobe abnormalities.

In patients with frontal lobe dysfunction, **attention** may be impaired; such impairment can be evaluated with digit span and other simple tests (see KCC 19.14; Table 19.10). Subtle **perseveration** may be detected by use of one of the **Luria sequencing tasks** (see neuroexam.com Videos 19, 20). For example, when a patient was asked to copy the sequence in Figure 3.1 and continue it to the end of the page, the patient clearly perseverated. Figure 3.1 also demonstrates the **closing-in** phenomenon with this test, in which some patients' drawing gradu-

TABLE 19.10 Evaluating Frontal Lobe Function

I. History and behavioral observations
- A. Best test is real world; history from family or other contacts may be more revealing than patient exam
- B. Behavioral observations, looking especially for:
  1. Abulia
  2. Inappropriate jocularity (witzelsucht)
  3. Other abnormalities of comportment or insight
  4. Confabulation
  5. Utilization behavior and environmental dependency
  6. Perseveration, impersistence, and spontaneous frontal release signs
  7. Incontinence

II. Mental status exam
- A. Attention
  1. Digit span forward and backward
  2. Months forward and backward
- B. Perseveration and set-shifting ability
  1. Bedside: Luria alternating sequencing tasks (written, manual)
  2. Formal testing: Trails B, Wisconsin Card Sorting Test
- C. Ability to suppress inappropriate response
  1. Bedside: auditory or visual go-no-go tasks
  2. Formal testing: Stroop test
- D. Word generation, figure generation
  1. FAS test or other word generation tasks
  2. Figure generation
- E. Abstract reasoning
  1. Similarities
  2. Proverb interpretation
  3. Logic problems
- F. Judgment; influence of future consequences on current behavior
  1. Difficult to test; questions about situations (e.g., fire in theater) are artificial and test mainly general knowledge and reasoning ability
  2. Gambling task[a]
- G. Language testing
- H. Testing for hemineglect

III. Other exam findings
- A. Skull shape (hyperostosis may signify a frontal meningioma)
- B. Olfaction (anosmia may signify an orbitofrontal tumor)
- C. Optokinetic nystagmus testing (impaired saccades occur away from side of lesion)
- D. Hemiparesis or upper motor neuron signs
- E. Motor impersistence (stick out tongue or hold up arms for 20 seconds)
- F. Gegenhalten (paratonia)
- G. Primitive reflexes, or "frontal release signs" (grasp, suck, snout, root)
- H. Frontal "magnetic" gait disturbance

[a] See Bechara A, Damasio AR, Damasio H, and Anderson SW. 1994. Insensitivity to future consequences following damage to human prefrontal cortex. *Cognition* 50: 7–15.

Manual alternating sequencing test

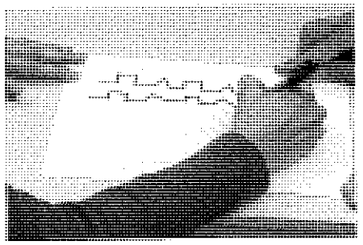

Written alternating sequencing test



Auditory go-no-go

ally approaches that of the examiner, possibly exhibiting a form of environmental dependency. Another useful test of perseveration is the Luria manual sequencing task, in which the patient is asked to tap their thigh with a closed fist, then with the palm of their hand, and then with the side of their open hand, repeatedly. Some formal neuropsychological tests of perseveration and set-shifting ability are also listed in Table 19.10.

A useful bedside test of a patient's inability to suppress inappropriate responses is the **go-no-go** task (see neuroexam.com Video 21). This task is similar to (but easier than) the children's game "Simon Says." In the auditory go-no-go task, the patient is instructed to raise a finger in response to one tap and to keep the finger still in response to two taps. The examiner then produces a random sequence of one or two tapping sounds. In the visual form of the task, the examiner randomly shows one or two fingers. More formal testing can be accomplished with the Stroop test. In the **Stroop test,** patients are given a list of color names such as "red, yellow, green" and so on, which are printed in colored ink, but the colors do not match the meanings of the words (e.g., the word "yellow" might be printed in green ink). Patients are then instructed to list the ink colors of the words without reading the words.

The ability to spontaneously **generate lists** of related words or drawings is often impaired in patients with frontal lobe lesions. **Word generation tasks** can be used to detect subtle decreases in verbal fluency and are a sensitive measure of dominant frontal dysfunction. A useful standardized task of this kind is the FAS test, in which the patient is given 60 seconds to produce as many words as possible starting with the letter F, then 60 seconds to produce words starting with the letter A, and so on. Proper nouns, such as names of persons or places, are not allowed. Normal individuals produce 12 or more words for each letter. Similarly, normal individuals can name at least 15 animals in 60 seconds. For detecting nondominant frontal lobe dysfunction, similar tasks based on the generation of simple drawings can be used (referred to as tests of figural fluency).

Frontal dysfunction often interferes with **abstract reasoning** ability. Two common tools for testing this are **proverbs** and **similarities.** (see neuroexam.com Video 22). Responses are rated as either normal or concrete. It is important to use proverbs and similarities ranging from easy to difficult (Table 19.11) to gauge the patient's level of functioning. A variety of logic problems can also be used to test abstract reasoning. **Judgment** is very difficult to test in the artificial setting of the neurologic exam and is best evaluated on the basis of reports of the patient's performance in the real world. Questions can be asked such as, "What would you do if you saw a fire in a crowded theatre?" or "What would you do if you found a stamped and addressed letter on the street?" However, patients usually respond to this kind of question on the basis of their general knowledge and reasoning ability, and they may behave quite differently in real-life situations. Bechara, Damasio, and colleagues recently devised a task resembling gambling that may be useful for detecting impaired judgment or overemphasis on short-term versus long-term consequences in frontal lobe patients (see Table 19.10).

TABLE 19.11 Examples of Proverbs and Similarities Used for Testing Abstraction

Proverbs: "What does it mean if I say . . ."		
Don't cry over spilled milk.		*Easiest*
People who live in glass houses should not throw stones.		↑
The tongue is the enemy of the neck.		
One swallow does not a summer make.		↓
You never cross the same stream twice.		*Most difficult*
Similarities: "How are a _____ and a _____ alike?"		
Hammer	Screwdriver	*Easiest*
Orange	Apple	↑
Table	Couch	
Train	Airplane	
Poem	Sculpture	↓
Moth	Tree	*Most difficult*

Two other parts of the mental status exam may provide clues about frontal dysfunction. In language testing, a nonfluent aphasia suggests possible left frontal lobe dysfunction (see KCC 19.4). In addition, althought left-sided neglect is more common with right parietal lesions, it can occasionally be seen with right frontal lesions as well (see KCC 19.9). Left-sided neglect, together with other signs of frontal lobe dysfunction, suggests a lesion in the right frontal lobe.

Finally, certain findings on other parts of the general and neurologic exam can be helpful for identifying frontal lobe lesions (see Table 19.10). On general exam, **skull shape** should be noted. For example, meningiomas can occasionally cause hyperostosis of the overlying skull, resulting in a large palpable bump on the head. **Olfaction** should be checked (see neuroexam.com Video 24) because tumors in the orbitofrontal area often cause anosmia (see Case 12.1). **Saccades** should be carefully checked because involvement of the frontal eye field can cause impaired saccades away from the lesion (see Figure 13.14). **Optokinetic nystagmus (OKN) testing** is a sensitive way of evaluating saccades (see Chapters 13 and neuroexam.com Videos 33, 34). Subtle asymmetries in OKN, with a decreased fast phase in one direction, may indicate a lesion in the contralateral frontal lobe.

Motor findings, such as hemiparesis or upper motor neuron signs, may be present, with lesions affecting the primary motor cortex of the precentral gyrus or underlying white matter pathways in the frontal lobe. In contrast, lesions of the prefrontal cortex are often associated with other, more elaborate motor findings, reflex abnormalities, or gait abnormalities. The examiner can test for **motor impersistence** by having the patient sustain an action such as holding out both arms or sticking out the tongue for 20 seconds. Impersistence can also be seen in right parietal lesions, Huntington's disease, and other conditions that cause inattention (see KCC 19.14). Patients with frontal lobe lesions may have **paratonia,** or **gegenhalten,** in which tone is increased, but in a manner in which the patient appears to resist the movements of the examiner in an almost willful fashion (see also KCC 16.1).

In addition, so-called **frontal release signs,** or **primitive reflexes,** normally seen in infants may return in adults with frontal lesions. The most useful of these is the **grasp reflex,** which the examiner can elicit by stroking the patient's palm (see neuroexam.com Video 18). When the grasp reflex is severe, the patient cannot release their grasp even when explicitly told not to grab the examiner's hand. A more subtle grasp reflex may be elicitable only if the examiner distracts the patient—for example, by engaging the patient in conversation. If asked why they are grabbing the examiner's hand, patients usually respond that they do not know.

Other, less specific reflexes are the **suck,** elicited by touching the patient's lips with a cotton swab; **snout,** elicited by tapping the patient's lips; and **root,** elicited by stroking the patient's cheek or holding an object near the patient's mouth. The palmomental reflex, in which stroking the thenar eminence causes the ipsilateral chin muscles to contract, is not generally useful because it is seen in many normal individuals. Myerson's glabellar sign is associated with movement disorders such as Parkinson's disease (see KCC 16.2). Frontal lobe lesions can cause characteristic **frontal gait abnormalities** (see KCC 6.5; Table 6.6), with a shuffling, unsteady, **magnetic gait,** in which the patient's feet barely leave the floor.

Olfaction

OKN

Grasp reflex

TABLE 19.12 Differential Diagnosis of Frontal Lobe Disorders

I. Disorders commonly affecting the frontal lobes
- Head trauma
- ACA or MCA infarcts
- Hemorrhage, from hypertension, tumor, or AComm aneurysm
- Gliomas, metastases, meningiomas, other tumors
- Brain abscess, toxoplasmosis, or herpes simplex encephalitis (limbic cortex)
- Pick's disease
- Developmental abnormalities
- Frontal lobe seizures

II. Diffuse processes causing frontal-like syndromes
- Toxic or metabolic disorders
- Hydrocephalus
- Binswanger's encephalopathy
- Diffuse anoxic injury
- Demyelination and other subcortical degenerative disorders
- Advanced Alzheimer's disease

III. Other disorders causing frontal-like syndromes:
- Schizophrenia (negative symptomatology)
- Depression
- Parkinson's disease
- Huntington's disease
- Cerebellar lesions
- Lesions of brainstem ascending reticular activating system or thalamus

Differential Diagnosis of Frontal Lobe Disorders

Disorders that commonly affect the frontal lobes are listed in part I of Table 19.12. Often patients with clinical syndromes that closely resemble frontal lobe lesions turn out to have disorders that affect the brain diffusely (Table 19.12, part II). One reason for this may be that the frontal lobes make up a large proportion of the brain, and therefore multifocal disorders have a greater chance of affecting the frontal lobes before other brain regions. In the case of hydrocephalus, it has been proposed that the dilated ventricles compress frontal subcortical white matter pathways, or possibly the anterior cerebral arteries.

Other disorders, some of which have lesions located remotely from the frontal lobes, may also mimic frontal lobe pathology (see Table 19.12, part III). This is likely because, as already discussed, the frontal lobes form part of a network of widespread cortical and subcortical connections. In addition, abnormalities of certain neurotransmitter systems, especially dopamine, can lead to frontal lobe dysfunction. These numerous other conditions listed in Table 19.12, which can mimic frontal lobe disorders are discussed in more detail elsewhere (see KCC 5.7, 6.5, 6.6, 14.2, 15.2, 16.2, 18.3, 19.15, 19.16). ■

Visual Association Cortex: Higher-Order Visual Processing

As we discussed in Chapter 11, after arrival at the primary visual cortex, visual information is processed in two streams of association cortex (Figure 19.12). The **dorsal pathways** project to parieto-occipital association cortex. These pathways answer the question **"Where?"** by analyzing motion and spatial relationships between objects, and between the body and visual stimuli. The **ventral pathways** project to occipitotemporal association cortex. These pathways answer the question **"What?"** by analyzing form, with specific regions identifying colors, faces, letters, and other visual stimuli (Figure 19.13). In reality, this processing is very complex and involves the cooperation of multiple specialized cortical modules (see Figure 11.11A). The functions of the dorsal and ventral higher-order visual pathways in humans are well illustrated by the clinical syndromes that will be discussed in KCC 19.12. Here we will briefly mention a few areas of active research in higher-order visual processing.

Figure 19.12 "What?" and "Where?" Streams of Visual Processing

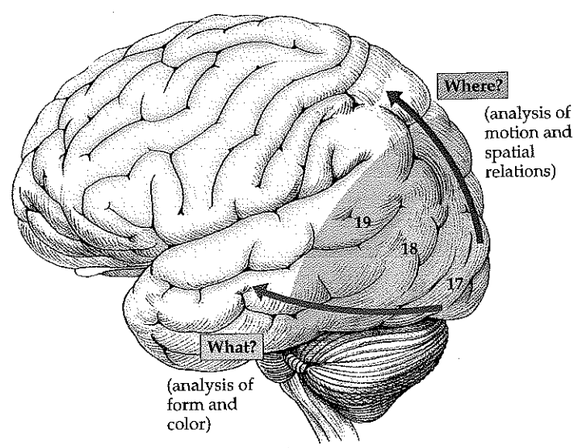

Figure 19.13 Color, Face, Letter, and Number Recognition Areas of the Inferior Occipitotemporal Cortex Regions of the inferior occipitotemporal cortex (fusiform gyrus) activated on human functional imaging and evoked potential studies by colors, faces, letterstrings, and numbers. (After Allison T, McCarthy G, Nobre A, Puce A, and Belger A. 1994. Human extrastriate visual cortex and the perception of faces, words, numbers, and colors. *Cerebral Cortex* 4(5): 544–554.)

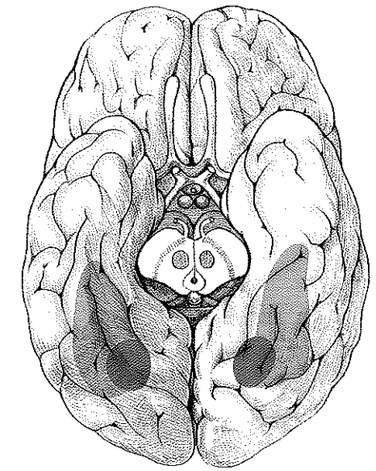

One important area of research is the question of how information from different cortical areas, both visual and nonvisual, is combined to form the unified perceptions that we experience. For example, our experience of someone speaking to us is not fragmented into a perception of sounds, verbal comprehension, facial recognition, facial color, location of the face in space, and emotional impact of the words spoken, even though these functions each occur in a different cortical area. The question of how unified percepts are formed in the brain is called the **binding problem.** Much research and hypothesis development is taking place to investigate the binding problem, especially in the visual system; however, no conclusive mechanism has yet been found.

A second area of research is **visual mental imagery**—that is, our ability to imagine a scene even when it is not present. This process appears to utilize the same visual areas that perceive exogenous visual stimuli; however, there is some controversy over the extent to which primary visual cortex is involved.

A third research area is the phenomenon of **blindsight,** in which some individuals with lesions of the primary visual cortex are able to perform tasks such as inserting an envelope correctly in a slot, despite having no conscious visual perception of the slot. Blindsight apparently depends on information transmitted to association cortex by extrageniculate visual pathways (see Figure 11.6), bypassing the lateral geniculate nucleus and primary visual cortex. Some studies have also demonstrated small islands of preserved vision in the blind hemifield measuring only a few minutes of degree that are not able to support conscious vision but may influence behavior.

KEY CLINICAL CONCEPT
DISORDERS OF HIGHER-ORDER VISUAL PROCESSING

19.12 Visual hallucinations, illusions, and other visual phenomena were introduced in Chapter 11; review this material before reading further (see KCC 11.1). In this section we will build on this background and describe several syndromes of abnormal visual processing associated with specific localization to the primary visual cortex, inferior occipitotemporal cortex ("what" pathways), or dorsolateral parieto-occipital cortex ("where" pathways).

Syndromes of Primary Visual Cortex

Visual hallucinations, seizures, and migraine-related phenomena associated with the primary visual cortex were discussed in KCC 11.1, and alexia without agraphia associated with color anomia was discussed in KCC 19.7. Another well-known syndrome is **cortical blindness,** or **Anton's syndrome,** caused by bilateral lesions of the primary visual cortex. In Anton's syndrome, patients have complete visual loss on confrontation testing, yet they have anosognosia and are completely unaware of the deficit. Other exam findings include loss of blink to threat, loss of eye closure in response to bright lights, and loss of optokinetic nystagmus (OKN). Some patients may have blindsight (see the previous section). Anosognosia for visual loss can also be seen in other situations that are not, strictly speaking, Anton's syndrome, such as combined occipital and frontal lesions (resulting in confabulation) or combined occipital and right parietal lesions (resulting in neglect).

Syndromes of the Inferior Occipitotemporal Cortex

The inferior occipitotemporal cortex lies in the "what" stream of visual analyis and processes color and visual form involved in object identification. Specialized regions that are involved in recognizing colors, faces, and letter strings (see Figure 19.13) have been described. Lesions of the inferior occipitotemporal cortex can therefore cause deficits in the recognition of colors, faces, and other objects, as well as other visual phenomena related to color and form. Complex formed visual hallucinations resulting from seizures of the inferior occipitotemporal visual association cortex were described in KCC 11.1 and KCC 18.2.

In **prosopagnosia,** patients are unable to recognize people by looking at their faces. The usual lesion location in prosopagnosia is the bilateral inferior **occipitotemporal cortex,** also known as the **fusiform gyrus** (see Figure 19.13; see also Figure 2.11C). Some evidence suggests that the right hemisphere is more important in face recognition, but in most reported cases of prosopagnosia with an enduring deficit, the lesions are bilateral. Recall that **agnosia** is defined as normal perception stripped of its meaning. In prosopagnosia, for example, patients can describe or even name the different parts of a face and can identify a face as being a face, and they may even be able to match faces on the basis of similar features, but they cannot recognize a face as belonging to a particular individual, even if it is someone they know very well. This "pure" form of agnosia without perceptual deficits is also known as associative agnosia, which should be distinguished from perceptual (apperceptive) agnosia, in which impairments of the primary sensory modality may contribute to difficulties with recognition. One way to remember the definition of agnosia is to think of it as a higher-order deficit, in contrast to simple impairments of perception.

Patients with prosopagnosia cannot recognize people by their faces, but they can identify people by their clothes, voices, or other cues. Interestingly, the recognition deficit in prosopagnosia is not restricted to human faces. Farmers with prosopagnosia have been reported to have difficulty recognizing their cows, and bird-watchers have been reported to have difficulty recognizing specific birds. One formulation is that prosopagnosia results in intact "generic recognition"—for example, the ability to recognize felines as felines—but impaired "specific recognition"—for example, the ability to recognize leopards, tigers, lions, and so on. Prosopagnosia is often associated with achromatopsia (see the next paragraph). In addition, it is sometimes associated with alexia and with upper-quadrant or bilateral upper visual field defects (see Figures 11.15J, 11.17B).

Achromatopsia is a central disorder of color *perception.* It can be thought of as cortical color blindness and should be contrasted with color agnosia, in which color perception is intact (see the next paragraph). Patients with achromatopsia cannot name, point to, or match colors presented visually. They can, however, name the appropriate color for an object described verbally. Usually patients with achromatopsia are aware of the deficit and describe the affected vision as appearing in shades of gray. Achromatopsia may occur in a quadrant, a hemifield, or the entire visual field. When the whole field is involved, the deficit is usually associated with prosopagnosia and is caused by lesions in bilateral inferior occipitotemporal cortex (see Figure 19.13). Hemiachromatopsia is caused by lesions in the contralateral inferior occipitotemporal cortex. Other deficits that are sometimes associated with achromatopsia include alexia and upper-quadrant or bilateral upper visual field defects.

Although **color anomia,** more correctly referred to as **color agnosia,** is not caused by lesions of the inferior occipitotemporal cortex, we discuss it briefly here to contrast it with achromatopsia. Color agnosia is caused by lesions of the primary visual cortex of the dominant hemisphere extending into the corpus callosum, and it is associated with alexia without agraphia and right hemianopia (see KCC 19.7; Figure 19.5). Patients cannot name or point to colors presented visually. However, perception of colors is preserved, as demonstrated by patients' ability to match colors presented visually. This is not a true anomia or language disorder because patients can name the appropriate color for an object described verbally, so it should be distinguished from anomic aphasia.

Other visual agnosias are more controversial. For example, investigators have described several category-specific visual agnosias for living things, human-made tools, or other specific categories. Large bilateral lesions of the inferior occipitotemporal region may cause a generalized visual-object agnosia applying to both generic and specific recognition of all visual objects, including those just described. This may be considered a perceptual agnosia because vision is often described as appearing hazy. Interestingly, some patients with lesions of this kind have a so-called visual static agnosia, in which they are able to recognize an object only when it moves.

Other illusory phenomena can occur with lesions of the inferior occipitotemporal cortex that are less specifically localized to this region. In **micropsia,** objects appear unusually small; in **macropsia,** objects appear unusually big; and either disorder can sometimes occur in only part of the visual field. **Metamorphopsia** is a more general term describing a condition in which objects have distorted shape and size. These disorders are sometimes referred to as "Alice in Wonderland" syndrome and can occur in migraine, infarct, hemorrhage, tumors, or other disorders of the inferior or lateral visual association cortex. They can also occasionally be seen in retinal pathology or toxic or metabolic disturbances.

In **visual reorientation,** the environment appears tilted or inverted to the patient.This condition has been associated with vestibular or lateral medullary dysfunction. In **palinopsia,** lesions of the visual association cortex cause a previously seen object to reappear periodically. For example, one patient looked at a plant, and then a few minutes later the plant reappeared and seemed to be growing out of her omelet. Another patient saw an aide entering her hospital room, and then later that evening she saw the image of the aide entering her room over and over again. Palinopsia can occasionally be caused by medications such as trazodone.

In **cerebral diplopia** or **polyopia,** patients see two or more images, respectively, of an object. Diplopia caused by dysconjugate gaze was discussed in KCC 13.1. The appearance of more than two images, as well as monocular diplopia, is sometimes psychiatric in origin. However, monocular or binocular double vision, triple vision, and so on can also occasionally be seen with occipital lesions, corneal lesions, or cataracts. Another visual illusion occasionally seen with cortical lesions is **erythropsia,** which is characterized by gold, red, purple, or other unnatural coloring of the visual field. Disturbances of color vision can also be seen with certain drugs, such as in digitalis toxicity, in which objects may appear to have a yellowish halo.

Syndromes of the Dorsolateral Parieto-Occipital Cortex

The dorsolateral parieto-occipital cortex lies in the "where" stream of visual analyis and processes motion and spatial localization and integration (see Figure 19.12). Lesions of the dorsolateral parieto-occipital cortex can therefore cause deficits in these aspects of visual processing. Constructional impairments and other deficits of visual-spatial analysis occurring especially in lesions of the parietal lobes and more commonly in the nondominant hemisphere were mentioned earlier in this chapter (see KCC 19.10).

In **Balint's syndrome,** caused by bilateral lesions of the dorsolateral parieto-occipital association cortex, there is a clinical triad consisting of (1) simultanagnosia, (2) optic ataxia, and (3) ocular apraxia. **Simultanagnosia** is the core abnormality of Balint's syndrome and consists of impaired ability to perceive parts of a visual scene as a whole. Patients with simultanagnosia can perceive only one small region of the visual field at a time. This region shifts around unpredictably, often causing patients to lose track of what they were looking at. Patients have particular difficulty scanning a complex visual scene or identifying moving objects (this is the opposite of visual static agnosia, described earlier). When confronted with a large complex visual stimulus, patients tend to describe small, isolated parts seemingly at random and have no awareness of the overall unified object or scene. Simultanagnosia can be thought of as a deficit in visual-spatial binding.

Optic ataxia is the impaired ability to reach for or point to objects in space under visual guidance. This condition can be distinguished from cerebellar ataxia because in optic ataxia the ability to point using proprioceptive or auditory cues is intact, and once an object has been touched, a patient with optic ataxia can perform smooth movements back and forth to it even with the eyes closed. **Ocular apraxia** is difficulty voluntarily directing one's gaze toward objects in the peripheral vision through saccades. Some patients need to move their heads to initiate a voluntary redirection of gaze. This condition again may be related to the defect in visual perception of stimuli other than in a small region of the visual field.

Patients with Balint's syndrome may be diagnosed incorrectly with visual agnosias or alexia, which can be shown not to be present when care is taken to ensure that the visual stimulus is in a region the patient can see. Because Balint's syndrome is caused by lesions of the dorsolateral parieto-occipital association cortex, associated deficits may include inferior-quadrant visual field cuts (see Figure 11.15), aphasia, or hemineglect. Most often these bilateral lesions of dorsolateral parieto-occipital cortex are caused by MCA–PCA watershed infarcts (see Figure 19.3B; see also Figure 10.10B), although bilateral hemorrhage, tumors, or other lesions can also produce this syndrome.

Isolated features of Balint's syndrome may occur in some patients with bilateral parieto-occipital lesions who do not exhibit the full syndrome. For example, some patients may exhibit optic allesthesia (a false localization of objects in visual space) or cerebral akinetopsia (an inability to perceive moving objects). ■

REVIEW EXERCISE

For each of the following, state whether it is usually associated with lesions of the dorsal parieto-occipital ("where?") stream, the ventral occipital temporal ("what?") stream (see Figure 19.12), or the primary visual cortex:

1. Prosopagnosia
2. Simultagnosia
3. Achromatopsia
4. Blindness with anosognosia

KEY CLINICAL CONCEPT
AUDITORY HALLUCINATIONS

19.18 Disturbances of higher-order auditory processing involving the auditory cortex and adjacent association cortex (see Figure 19.1) are just one cause of auditory hallucinations and other positive auditory phenomena. **Tinnitus** is a common disorder consisting of a persistent ringing tone or buzzing in one or both ears, usually caused by peripheral auditory disorders affecting the tympanic membrane, middle ear ossicles, cochlea, or eighth cranial nerve (see KCC 12.5). **Self-audible bruits** are pulsatile "whooshing" sounds that can be associated with turbulent flow in arteriovenous malformations, carotid dissection, or the extracranial-to-intracranial pressure gradient that is produced by elevated intracranial pressure. Some positive auditory phenomena are analogous to similar disturbances of the visual system (see KCC 11.1, 19.12). For example, elderly patients with sensorineural deafness can develop elaborate auditory hallucinations (music, voices, etc.), which may be a **release phenomenon** analogous to Bonnet syndrome (visual hallucinations caused by visual loss). Lesions or ischemia of the **pontine tegmentum** involving the trapezoid body, superior olivary nucleus, and other auditory circuits (see Figure 12.17) can rarely cause auditory hallucinations, such as rain on a roof, buzzing or musical tones like an orchestra tuning up, which are analogous to the visual phenomena of peduncular hallucinosis. In **paracusis,** another rare disorder, a sound that is heard once is then heard repeatedly, analogous to palinopsia. **Psychotic disorders** are a relatively common cause of either simple or elaborate auditory hallucinations. Functional neuroimaging studies during auditory hallucinations in schizophrenic patients have recently demonstrated activation of diverse brain regions. As we discussed in KCC 18.2, **seizures** in primary auditory cortex can cause simple auditory phenomena, such as the sound of a train approaching or of an airplane taking off, often perceived as coming from the side opposite to the involved cortex. Seizures in auditory cortex can also cause transiently decreased hearing. Involvement of the auditory association cortex gives rise to more elaborate auditory phenomena such as voices or music. Musical hallucinations are more often caused by seizures in the nondominant hemisphere than in the dominant hemisphere, although musical hallucinations can also occur with peripheral or pontine lesions, as we have just discussed. Other disturbances of higher-order auditory perception, such as cortical deafness and nonverbal auditory agnosia, were discussed in KCC 19.7. ■

Attention, Awareness, and Other General Network Functions of the Brain

Consciousness is one of the most fascinating topics in neuroscience. The quest to explain conscious thought in terms of brain activity has become somewhat of a Holy Grail for neuroscience, and has attracted many individuals into this field, especially in recent years. No brain system comes as close to explaining consciousness as do the networks underlying attentional mechanisms.

So far in this chapter we have focused on specialized brain networks subserving functions such as language, spatial analysis, executive control, and visual processing, and the effects of localized lesions on these networks. We have even discussed attention from a localized perspective, by learning about effects of nondominant-hemisphere lesions on contralateral-directed attention (see KCC 19.9). In this section we will change our emphasis to more globally distributed networks subserving generalized attention and other functions. We will also discuss disorders that tend to affect these networks in a diffuse manner, including delirium and dementia. Finally, we will briefly talk about the more elusive topic of awareness and some recent theories on the neural basis of consciousness.

General Mechanisms of Attention

Consciousness is often described as involving two components:

1. Content of consciousness
2. Level of consciousness

The **content of consciousness** is the substrate upon which consciousness acts and includes sensory, motor, emotional, and mnemonic systems acting at multiple levels. It comprises many of the systems described throughout this book, including memory, emotion and drives, language, executive function, visual processing, and so on. Without normal operation of these systems, completely normal consciousness is not possible. The **level of consciousness** is regulated by several systems that act on this substrate. Recall that the level of consciousness can be described in terms of three distinct but

MNEMONIC

related processes that maintain (1) **alertness**; (2) **attention;** and (3) **awareness** of self and environment (mnemonic **AAA**). We introduced these concepts in Chapter 14, along with the networks that regulate the level of consciousness. Recall that these networks include the brainstem-diencephalic activating systems, basal forebrain, and cortex. We will now continue our exploration of consciousness by moving from functions that prevent coma (and promote alertness), first to a discussion of attention, and later to the more controversial topic of awareness.

Attention can be described in many different ways and has a variety of different functional components. A coherent, physiologically or anatomically based taxonomy of attention has not yet emerged, so we will simply list several different attentional functions that have been described. **Selective attention,** or **directed attention,** implies attention to certain objects, stimuli, or concepts to the exclusion of others. Selectivity is an essential component of attention and has been studied extensively. In selective attention, attention is directed at specific components of the "substrate," or content of consciousness, described in the previous paragraph. Examples of selective attention are quite diverse; they include

- Attention to a visual, tactile, or auditory stimulus in a particular location in space (discussed earlier in this chapter)
- Attention to inputs of a specific sensory modality
- Attention to a specific higher-order aspect of a stimulus (e.g., color versus shape)
- Attention to a particular object, including inputs from various modalities
- Attention to an object, emotion, plan, or concept that is not physically present but is either remembered or imagined

Functional MRI and evoked-potential studies in humans, and recordings from animal models, suggest that these examples of directed attention are reflected in the activation of specific brain regions, following known anatomical principles. For example, attention to a somatosensory stimulus on the body activates the corresponding somatotopic region of somatosensory cortex, attention to a visual stimulus in a particular location activates the corresponding retinotopic region of visual cortex, and so on. In addition, specific areas of limbic and association cortex are involved in aspects of higher-order processing.

Sustained attention (concentration, vigilance, nondistractibility) is a second major set of attentional functions. Sustained attention can be directed at a specific task, object, or modality, or it can involve a more generalized increased level of vigilance—for example, while one is awaiting an anticipated stimulus.

As illustration of different types of attentional mechanisms, imagine a student trying to study for a final exam while sitting in the middle of a rowdy fraternity party. The student demonstrates directed (selective) attention by looking at her book and reading, attending to the visual, linguistic, and conceptual aspects of its content while ignoring the loud noises, flashing lights, and scents of the room around her. She demonstrates sustained attention and concentration by continuing to read even if she finds the subject slightly boring, and she exhibits nondistractibility by ignoring other students' pleas for her to join in the dancing. Finally, she demonstrates vigilance by being prepared to duck quickly out of harm's way when flying objects occasionally enter her peripheral vision.

It should be evident from this discussion that both selective and sustained attention may involve enhanced activity in stimulus-relevant regions of the brain ("signal") and/or decreased activity in stimulus-irrelevant brain regions ("noise"). The relative importance of **signal enhancement versus noise suppression** in attention is still under active investigation. Similarly, attention must be able to shift from one target to the next, which may involve mechanisms that both **engage** the relevant stimulus and **disengage** the irrelevant (or no longer relevant) stimulus. Other, harder questions still under active investigation include the mechanisms through which directed attention has a **limited capacity** in the spatial, temporal, modality-specific, and other domains, and the mechanisms through which attended targets from disparate brain regions are unified into a single coherent concept (the **binding problem**).

Anatomy of Attention

Networks involved in attention are distributed through many cortical and subcortical structures. Systems involved in attention include (1) widespread projection systems (discussed in Chapter 14); (2) frontal and parietal association cortex; (3) anterior cingulate cortex and limbic pathways; (4) tectum, pretectal area, and pulvinar; and (5) other structures, such as the cerebellum and basal ganglia. Interestingly, networks involved in generalized alertness and attention also participate in mechanisms of directed attention. Recall that attentional networks are asymmetrical and that the nondominant (usually right) hemisphere plays a more important role (see KCC 19.9). Let's review each of the anatomical systems involved in generalized and directed attention in more detail.

WIDESPREAD PROJECTION SYSTEMS. A prerequisite for attention is an awake, alert state. Mechanisms of arousal were discussed in Chapter 14; they include widespread projection systems of the upper brainstem, thalamus, hypothalamus, and basal forebrain. In addition to aiding in generalized arousal, many of the same systems may contribute to directed and sustained attention. We will therefore briefly review these systems (see Table 14.2 and Figures 14.7–14.13) again here. **Upper brainstem projection systems** include cholinergic (pedunculopontine and laterodorsal tegmental nuclei) and noncholinergic (pontomesencephalic reticular formation, possibly glutamatergic) projections to thalamus, hypothalamus, and basal forebrain systems, which in turn have widespread cortical projections. In addition, noradrenergic (locus ceruleus and lateral tegmental area) and serotonergic (dorsal and medial raphe) systems project widely to the cortex and other structures, while dopaminergic (substantia nigra pars reticulata, ventral tegmental area) systems project to striatum, limbic cortex, and prefrontal cortex.

Thalamic systems involved in arousal include the intralaminar, midline, ventral medial, and possibly other thalamic nuclei that transfer inputs from the upper brainstem reticular formation and cholinergic nuclei to widespread areas of cerebral cortex. In addition, the thalamic reticular nucleus has been postulated to play a role in gating information transfer through the thalamus because it receives inputs from cortex, thalamus, and brainstem systems and sends inhibitory (GABAergic) projections to the thalamus (and possibly back to the brainstem as well).

Hypothalamic systems important to arousal include the posterior lateral hypothalamic histaminergic neurons (tuberomamillary nucleus), which receive inputs from basal forebrain, anterior hypothalamus, and brainstem and project widely to cortex and thalamus.

Finally, **basal forebrain systems** involved in arousal include the nucleus basalis, diagonal band, and medial septal cholinergic and GABAergic neurons, which receive inputs from the brainstem and project to the entire cortex and thalamus.

FRONTAL AND PARIETAL ASSOCIATION CORTEX. The frontal and parietal association cortices (see Figure 19.1) communicate with each other via strong reciprocal connections and play an important role in attentional mechanisms. The lateral **parietal cortex** and adjacent temporal and occipital association cortex lie at the nexus of auditory, visual, and somatosensory unimodal association cortex (see Figure 19.1). This region is thus ideally situated for heteromodal integration in attention. As we discussed earlier in this chapter, the parietal association cortex plays an important role in heteromodal spatial representations, encoding the location of attended objects in space. Lesions of the parietal cortex, especially in the nondominant hemisphere, are the best-known cause of deficits in contralateral directed attention, or hemineglect (see KCC 19.9).

The **frontal heteromodal association cortex** (prefrontal cortex; see Figure 19.1), also discussed earlier, plays important roles in both directed and sustained attentional mechanisms. In particular, the region of the frontal eye fields is important in directed attention to the contralateral side, and in the initiation of eye movements toward attended targets. In addition, the prefrontal cortex may play an important role in motor-intentional aspects of attention toward the contralateral side. The ability to initiate spontaneous movements of the contralateral limbs or toward the contralateral hemispace may depend on prefrontal cortex and on ascending dopaminergic modulation of the prefrontal cortex and striatum. Finally, on the basis of both functional neuroimaging studies and the effects of lesions, the prefrontal cortex is crucial to sustaining attention and reducing distractibility.

ANTERIOR CINGULATE CORTEX AND LIMBIC PATHWAYS. The **anterior cingulate cortex** (see Figure 19.1B) is important in motivational aspects of attention. It forms a network together with the amygdala, medial orbitofrontal cortex, thalamic mediodorsal nucleus, and other **limbic structures** (see Chapter 18) that may play an important role in motivating directed and sustained attention toward a relevant or interesting stimulus. The importance of motivational factors in attention is illustrated by the example in which a patient performs poorly when asked to remove objects such as pieces of paper from a table but then shows a dramatic improvement when the objects are replaced with dollar bills.

REVIEW EXERCISE

Name 3 cortical and 3 subcortical structures that participate in mechanisms of attention (note that there are many possible correct answers).

TECTUM, PRETECTAL AREA, AND PULVINAR. The **superior colliculi, pretectal area, and pulvinar** participate together with the parietotemporo-occipital cortex and frontal eye fields in directing visual attention toward relevant visual stimuli for saccadic eye movements (see Figures 11.6, 13.14). Directed attention for other modalities, such as audition, may also be processed by these pathways.

OTHER STRUCTURES. There is accumulating evidence that certain parts of the **basal ganglia** and **cerebellum** also participate in mechanisms of directed attention.

Awareness of Self and Environment

One of the great remaining mysteries of modern science is the mechanism for our subjective and personal experience of awareness. As we have discussed in this chapter, consciousness certainly includes a "substrate," or content, represented by sensorimotor systems, memory systems, and limbic systems, as well as mechanisms for controlling the level of consciousness, including the level of alertness, attention, and awareness. So far, we have discussed alertness and attention, but what are the mechanisms of awareness? Philosophers may debate whether a biological explanation for the awareness aspects of consciousness, sometimes referred to as **qualia,** is even possible. As this debate continues, and although the final answers are not in yet, exciting new developments in neuroscience have begun to shed light on at least some systems that may participate in generating our subjective personal experience of awareness.

Like other functions of the nervous system, awareness most likely is mediated by a network involving both specialized regions of local processing and widespread regions of distributed processing. We saw in Chapter 18 that memory functions are segregated anatomically into **declarative memory,** which involves conscious awareness and is processed by medial temporal and diencephalic regions, and **nondeclarative memory,** which does not involve consciousness and is processed by other brain regions (see KCC 18.1). Further investigation of the neural circuits underlying declarative memory may ultimately help us understand what is "special" about conscious versus nonconscious memories.

We have discussed the **hemineglect syndrome,** in which inattention causes circumscribed loss of awareness of both the self and the environment (see KCC 19.9). This syndrome suggests that the same mechanisms that are involved in attention play an important role in awareness as well, and some investigators even debate whether a distinction between attention and awareness is valid. One aspect of awareness that is difficult to explain in terms of current theories of attention is the **binding** of sensory, motor, emotional, and mnemonic information from disparate brain regions into what we perceive as a single unified experience. Where or how is this synthesis of multiple forms of information perceived? Some investigators have contended that binding is a distributed process occurring over widespread networks. Theories for binding on a cellular level have included widespread horizontal connections between certain cortical layers, and synchronized or coherent gamma-frequency (about 40 hertz) oscillations in neuronal activity occurring between regions involved in binding. Others have proposed that specific regions of higher-order association cortex, such as the frontal or parietal lobes, may be critical for binding. From a clinical perspective, **Balint's syndrome** (see KCC 19.12) provides an interesting example of how focal lesions of the parieto-occipital cortex can cause a profound deficit in the ability to bind various individual parts of a visual scene into a single integrated whole.

The role of the prefrontal cortex in **working memory,** or the ability to hold a certain amount of information in an active short-term store, is also likely to play an important role in any process that mediates awareness, as are the senses of **chronological sequence** and **self-monitoring** that are mediated by the frontal lobes. Similarly, studies of **mental imagery** have begun to demonstrate the involvement of certain regions of primary and association cortex in generating internal representations of both sensory and motor phenomena—important ingredients for any internal representation or engram of awareness.

Finally, although significant advances are being made in understanding **limbic networks,** the question of how neural activity gives rise to emotions remains as difficult for us to answer as the question of how neural activity gives rise to conscious thought. In summary, conscious awareness may yet be explained on the basis of an understanding of both distributed and specialized local network processing in the brain. However, this important and interesting quest for understanding is still very much under way and will undoubtedly continue to provide a rich vein for researchers.

KEY CLINICAL CONCEPT
ATTENTIONAL DISORDERS

19.14 Because attention depends on so many different systems, as described in the preceding sections, it is not surprising that deficits in attention can be produced by focal lesions in many locations, as well as by diffuse disorders affecting large regions of the nervous system. In this section we will discuss the assessment and diagnosis of patients with general disorders of **sustained attention** (see KCC 19.9 for the special case of unilateral deficits in directed attention). In the next two sections we will discuss other disorders that tend to affect the nervous system in a widespread manner and which may also cause prominent deficits in global attention (see KCC 19.15, 19.16).

Like most other disorders of the nervous system, attentional disorders can range in severity from mild to severe. Mild inattention may cause patients to have difficulty registering new information, and they may occasionally fail to complete tasks. Severe inattention, on the other hand, may cause patients to be completely unresponsive to outside stimuli. Of note, patients may be fully awake and yet profoundly inattentive.

Testing Sustained Attention

Because attention is so important for performance on the mental status examination and can affect nearly all other tests, it is essential to evaluate and document the patient's level of attention toward the beginning of the examination. Clues that an attentional disorder is present can often be obtained from the history, and by observation of the patient's behavior during all parts of the examination. A very useful test and well-standardized measure of attention (and working memory) is **digit span.** In this test, a random series of numbers is recited to the patient, and the patient is asked to repeat them back immediately to the examiner. Normal digit span is five to seven or more digits. Next, patients can again be given a series of numbers but then asked to repeat them backward. This task is slightly more difficult, and **backward digit span** is normally four or more digits, or two less than the patient's forward digit span.

A similar test that is easier to administer is to ask the patient to recite the **months of the year forward and then backward** (see neuroexam.com Video 4). Although this test is not standardized, with some experience the examiner gets a sense of what is normal and what is abnormal. Normally, reciting the months backward should take less than twice as long as reciting them forward, and this task should be performed without errors. Other similar but perhaps less useful tests include asking the patient to spell "world" backward, or to count backward by threes from 30, or by sevens from 100.

Motor impersistence is another useful bedside indication of impaired attention, which we discussed earlier in the evaluation of frontal lobe disorders (see KCC 19.11; Table 19.10). The patient is asked to stick out their tongue, or hold up their arms for 20 seconds, without subsequent prompting. If they fail to do so, they have motor impersistence, a form of inattention. **Vigilance** can also be tested at the bedside with the **"A" random letter test,** in which the examiner recites a random sequence of letters at a rate of about one per second, and the patient is instructed to tap the desk each time they hear the letter A.

Formal neuropsychological tests of attention exist as well, and can be useful for obtaining a more quantitative assessment. As already noted, patients with impaired attention may perform poorly on many other parts of the mental status examination as well. This poor overall performance can lead to false localization unless the attentional deficit is recognized. Finally, note that there is some overlap between the definitions of sustained attention and working memory. Attention, however, is involved in instantaneous stimulus selection, while working memory serves as a temporary storage depot without necessarily being directly involved in stimulus selection. The frontal lobes play an important role in both working memory and in attention mechanisms, and tests of frontal lobe function (discussed in KCC 19.11) are often quite sensitive to deficits in attention.

Differential Diagnosis of Disorders of Sustained Attention

Some common causes of impaired general attention are listed in Table 19.13. As already noted, impaired attention can be mild or quite severe. **Encephalopathy** is a nonspecific term that means simply diffuse brain dysfunction, which we will discuss further in KCC 19.15 and 19.16. Various forms of diffuse encephalopathy are the most common causes of impaired attention. Encephalopathy, especially when acute in onset, can also be associated with an impaired level of alertness ranging from mild lethargy to coma. **Focal lesions** can also cause impaired attention. This is particularly true of lesions in the frontal lobes, parietal lobes, or brainstem activating systems, although focal lesions in numerous other brain regions can also result in impaired attention.

Attention-deficit hyperactivity disorder (ADHD) is a fairly common condition affecting 1 to 5% of elementary school children. Onset is typically by age 3 years, although problems do not usually become severe until school is started. In some children the disorder of attention is predominant, while in others problems with impulsive and hyperkinetic behaviors are predominant. Most children with ADHD have normal neuroimaging studies and essentially normal neurologic evaluations, except for markedly impaired attention, impulsivity, and perhaps some "soft" findings on exam. The impaired attention in ADHD is somewhat different from the other disorders listed in Table 19.13. ADHD is more likely, for example, to cause problems with high-level executive functions, organizational skills, and time management abilities rather than simpler impairments of digit span. ADHD is occasionally seen in patients with other neurologic conditions, but in most cases the cause of ADHD is unknown. ADHD is three to five times more common in boys than girls, and siblings are at increased risk for having the disorder. The condition is treated with CNS stimulants such as methylphenidate (Ritalin), combined with individual and family psychotherapy. It is interesting that stimulants that enhance dopaminergic noradrenergic neurotransmission are beneficial in this disorder. Long-term outcome is variable: Many individuals show remission upon reaching adolescence, but 15 to 20% of patients continue to have ADHD into adulthood.

Psychiatric disorders (see KCC 18.3) are a very important cause of impaired attention. Patients with depression, anxiety, mania, schizophrenia, or other milder conditions are often severely inattentive on examination. The remainder of the mental status examination in these patients should therefore be carefully interpreted in this context to avoid misdiagnosis of the patient as having a memory disorder or other focal dysfunction. Formal neuropsychological testing can often be helpful in distinguishing "pseudodementia" seen in psychiatric conditions from true dementia (see KCC 19.16). ■

TABLE 19.13 Common Causes of Impaired General Attention

Diffuse encephalopathy (see Tables 19.14, 19.15)
Focal lesions, especially of the frontal or parietal lobes, or of the reticular activating systems, but also of many other brain regions
Attention deficit hyperactivity disorder (ADHD)
Psychiatric disorders—e.g., depression, mania, schizophrenia

KEY CLINICAL CONCEPT
DELIRIUM AND OTHER ACUTE MENTAL STATUS DISORDERS

19.15 One of the most common reasons for neurologic consultation is the nonspecific condition referred to as "mental status changes." Although focal lesions can cause altered mental status, usually the consultation is for a patient with no significant focal findings on examination, other than impaired cognitive abilities. The impairments of mental status are often relatively nonlocalizing as well, consisting of prominent inattention, confusion, and mem-

ory deficits, together with variable degrees of impaired alertness and attention. These patients may be referred to as **encephalopathic,** meaning simply that they exhibit diffuse brain dysfunction.

In evaluating patients of this kind, the first important piece of information is whether the change in mental status is **acute** (or subacute), meaning that it is of recent onset (days to months), or **chronic,** meaning that it is part of a long-standing or more gradual deterioration (months to years). Acute encephalopathy is most often toxic or metabolic in origin and is often reversible (Table 19.14); chronic encephalopathy has a poorer prognosis, and in elderly patients it most often represents dementia of the Alzheimer's type (see KCC 19.16). It is often surprisingly difficult to determine whether mental status changes are acute or chronic, even after consultation with family members, because they may not provide the most objective information about the mental status of loved ones and may minimize changes and attribute them to "aging." When it is available, the most useful information is a prior mental status examination, or at least historical information about the patient's level of functioning, including specific things they previously could or could not do on their own ranging from complex activities (managing finances, driving) to more simple activities (dressing, grooming). Of note, impaired attention is usually prominent in acute mental status changes, while it may be minimal in chronic encephalopathies, especially early on (see KCC 19.16).

TABLE 19.14 Causes of Acute or Subacute Mental Status Changes

Toxic or metabolic encephalopathies
Drug or alcohol toxicity
Withdrawal from alcohol or other sedatives
Electrolyte abnormality (especially elevated sodium, calcium, or magnesium)
Hypoglycemia
Diffuse anoxia
Hypothyroidism, hyperthyroidism
Hypoadrenalism
Thiamine deficiency (Wernicke–Korsakoff encephalopathy)
Hepatic failure
Renal failure
Pulmonary failure
Sepsis
Inborn errors of metabolism
Paraneoplastic syndrome
Hereditary endogenous benzodiazepine production
Head trauma
Diffuse or focal cerebral ischemia or infarct
Intracranial hemorrhage
Migraine
Seizures or post-ictal state
Hydrocephalus
Elevated intracranial pressure
Diffuse cerebral edema
Meningitis, encephalitis, brain abscess
Vasculitis, diffuse subcortical demyelination (e.g., multiple sclerosis)
Intracranial neoplasm
Paraneoplastic syndrome
Mild insult (e.g., urinary infection or change in environment) in setting of underlying impaired mental status
Psychiatric disorders (e.g., depression, mania, schizophrenia, etc.)
Sleep deprivation
Visual deprivation or more generalized sensory deprivation
Hypotension
Hypertensive crisis

Acute mental status changes are also referred to as **acute confusional states,** acute global confusional states, organic psychosis, or acute organic brain syndrome. All of these terms have a similar meaning and apply to patients who have recent onset of encephalopathy, with prominent inattention, confusion, waxing and waning level of alertness, and difficulty registering new memories due to both inattention and diffuse dysfunction of the memory network (see KCC 18.1). Patients often have marked difficulty with writing, calculations, and constructional abilities, which could be misconstrued as focal deficits if the underlying deficit in attention is not recognized. Acute confusional states tend to wax and wane in severity over the course of hours, and they are often exacerbated in the evening (a phenomenon referred to as "sundowning"). Although all patients with acute confusional states are inattentive, the level of alertness may be normal in mild cases and can range from agitation to near coma in more severe cases. **Delirium** is a common form of acute confusional state in which agitation and hallucinations (auditory, visual, and tactile) are often prominent.

The most common causes of acute confusional states are **toxic or metabolic disorders,** followed by infection, head trauma, and seizures (see Table 19.14). Patients should therefore be evaluated promptly by assessment of vital signs, respiratory status (including arterial blood gas), and other appropriate blood tests, including blood glucose, electrolytes, blood urea nitrogen, creatinine, liver function tests, ammonia level, complete blood count, thyroid function tests, and toxicology screen. The patient's medications should be reviewed for those with known central nervous system side effects (e.g., anticholinergic, sedative–hypnotic, narcotic). When the diagnosis remains uncertain, the patient should immediately undergo neuroimaging and a lumbar puncture. If these are negative, an EEG should be performed promptly to rule out subtle ongoing seizure activity. An EEG is also helpful because in most forms of encephalopathy listed in Table 19.14, diffuse slowing of the EEG should be present, with the exception of psychiatric disorders, sleep deprivation, and sensory deprivation. In elderly patients or patients with previous neurologic disorders, acute confusional states can be provoked by seemingly minor causes, such as a urinary tract infection, or even by a change from home to the hospital setting. Patients in intensive care units are prone to acute confusional states from the combination of sedative use, immobilization, and sleep and sensory deprivation, although they should be evaluated for treatable causes as described above.

Chronic mental status changes, as we will discuss in the next section, can also have numerous causes and are more typically gradually progressive, as in Alzheimer's disease, or are static, as in anoxic brain damage (see KCC 19.16). **Dementia** is a broad term, meaning literally "decline in mental function"; however, it is usually applied more specifically to gradually progressive disorders such as Alzheimer's disease. Although both acute and chronic mental status changes can be treatable, acute mental status changes usually carry a better prognosis. Therefore, an important goal is often to distinguish **delirium versus dementia**.

To summarize, **acute confusional states** such as delirium typically develop over the course of days to months, have prominent attentional disturbances, tend to wax and wane over the course of hours, often have marked slowing on the EEG, and are most often caused by toxic or metabolic disorders, head trauma, infection, and seizures. **Chronic mental status changes,** typified by Alzheimer's disease and other gradually progressive dementias (see KCC 19.16), usually develop over months to years, do not tend to fluctuate as rapidly (although exacerbations of function can occur in certain settings), and early in their course tend to have less prominent disturbances in attention and a relatively normal EEG. Note that there are many exceptions to these general principles. For example, patients with acute mental status changes do not always show waxing and waning function, and many patients with chronic mental status changes (Huntington's disease, for example) show prominent deficits in attention early in the course of the disorder.

The vast majority of cases of encephalopathy and global confusional states are caused by conditions that affect the brain in a diffuse manner *bilaterally*. However, unilateral lesions, particularly in the right parietal, right frontal, or right medial temporo-occipital regions, can occasionally produce global states of impaired alertness and attention that mimic diffuse encephalopathy. ■

KEY CLINICAL CONCEPT

DEMENTIA AND OTHER CHRONIC MENTAL STATUS DISORDERS

19.16 As we approach the end of this book, it is appropriate to discuss a group of disorders that may await many of us in the future, so that we may be motivated to pursue greater understanding of these disorders and ultimately to discover more effective treatments for them. **Dementia** is defined as a decline in memory and other cognitive abilities from a previously higher level of function to impaired functional status. Although this definition includes patients in which the decline is sudden or nonprogressive (e.g., the result of a single head injury or other insult), the term "dementia" is more typically used when there is gradually progressive deterioration over the course of months to years.

Patients with dementia typically show a decline in memory and other more generalized cognitive abilities, although patients with focal decline, such as in primary progressive aphasia, are often included in the definition of dementia as well. Dementia is not restricted to the elderly; however, disorders causing dementia are much more common in the later years of life. Dementia should be distinguished from the apparently "normal" mild deterioration of memory function that occurs with age and that is referred to as benign forgetfulness of senescence. Patients with dementia exhibit deterioration well beyond statistical norms for age-matched controls.

Aside from dementia, several other terms for **chronic mental status changes** are sometimes used. **Static encephalopathy** is a term that refers to permanent nonprogressive brain damage, as a result of head injury, anoxia, or congenital abnormalities of brain development, for example. **Mental retardation** is defined as impaired general intellectual and social adaptive function originating during development that is approximately two or more standard deviations below average.

Cortical dementias, with prominent disturbances in language, praxis, visual-spatial functions, and other typically cortical functions, are sometimes distinguished from **subcortical dementias** (such as Huntington's disease or progressive supranuclear palsy), in which these features are not present, although the usefulness of this distinction has been questioned. Dementia can also be subdivided into **primary dementia,** typically associated with neurodegenerative conditions for which definitive treatments are usually unavailable, and **secondary dementia,** caused by other conditions that may, in some cases, be reversible. In the sections that follow we will discuss the different causes of dementia and other chronic mental status changes, and the general approach to evaluating patients with these disorders, before focusing on Alzheimer's disease in greater detail.

Causes and Evaluation of Dementia

Fifty years ago, senile dementia was thought to be caused mainly by cerebrovascular disease, known colloquially as "hardening of the arteries," and Alzheimer's disease was considered relatively rare. With increased knowledge and understanding of Alzheimer's disease, it is now recognized that over 50% of the cases of senile dementia are caused by Alzheimer's disease, making it the most common cause by far . We will discuss Alzheimer's disease in more detail in the sections that follow; here we focus on the other causes of chronic mental status changes (Table 19.15). Many of the causes of chronic mental status changes listed in Table 19.15 are the same as for acute mental status changes (see Table 19.14), but are the result of long-standing treatable disorders such as chronic hypothyroidism or chronic hydrocephalus, or are the outcome of permanent brain injury, such as previous head trauma or encephalitis. Note that because Alzheimer's disease is relatively common, many elderly patients will have Alzheimer's disease coexisting with one of the other disorders listed in Table 19.15.

Because there are so many possible causes of dementia, **evaluation of patients with dementia** should focus on and target treatable disorders, with the recognition that a treatable cause is found in only about 10% of cases. Patients should be evaluated with a **thorough history,** including including an assessment of activities of daily living, family history, and description of any possible precipitants. As in the evaluation of patients with acute mental status changes (see KCC 19.15), it is crucial to review the patient's medications for any that may cause central nervous system side effects. A careful **general and neurologic exam** should then be performed.

Formal neuropsychological testing can be useful in distinguishing dementia from "pseudodementia" caused by depression or other treatable psychiatric disorders. Testing batteries that can be administered easily at the bedside and that are especially useful in following patients during serial evaluations over time include the Blessed Dementia Scale (Table 19.16), the Folstein Mini-Mental State Examination, and the Activities of Daily Living Rating Scale. **Blood tests** should include routine chemistries, as well as thyroid function tests, B_{12} and folate levels, serum syphilis test, and other blood tests (see Table 19.15), depending on the patient's age and the clinical situation. **Neuroimaging** should ideally include an MRI scan of the brain. If the patient is unusually young (e.g., dementia before age 50), has headaches, or any other atypical features suggesting chronic meningitis, a lumbar puncture should be performed. In selected cases, an EEG can be helpful (for example, to detect periodic sharp waves in Creutzfeldt–Jakob disease, or triphasic waves in hepatic encephalopathy), and occasionally a brain biopsy is indicated, when the results may guide treatment (e.g., in suspected CNS vasculitis).

Often the distinction between acute and chronic mental status changes is not obvious, as discussed in KCC 19.15. In addition, patients may have a combination of acute mental status changes superimposed on an underlying chronic mental status disorder, such as the "sundowning" seen in demented patients, especially when in unfamilar surroundings, or the delirium caused by a minor infection in a patient with underlying mild dementia (resulting in a "beclouded dementia"). These cases can be challenging at times, especially in attempts to find treatable causes of impaired mental status, and they require careful evaluation.

TABLE 19.15 Causes of Chronic Mental Status Changes

- Primary neurodegenerative disorders
  - Alzheimer's disease
  - Frontotemporal dementias (including Pick's disease)
  - Dementia with Lewy bodies
  - Parkinson's disease with dementia
  - Huntington's disease
  - Progressive supranuclear palsy
  - Cerebellar atrophies
  - Cortical–basal ganglionic degeneration
  - Primary progressive aphasia
  - Dentatorubropallidoluysian atrophy
  - Other disorders
- Vascular dementia
  - Multi-infarct dementia
  - Binswanger's disease
  - Intracranial hemorrhage
  - Cerebral amyloid angiopathy
- Psychiatric pseudodementia (especially depression, schizophrenia, and conversion disorder)
- Thiamine deficiency (Wernicke–Korsakoff encephalopathy) and other alcohol-related causes
- Intracranial neoplasms, and paraneoplastic syndromes
- Normal-pressure hydrocephalus and noncommunicating hydrocephalus
- Head trauma, including chronic subdural hematoma and dementia pugilistica
- AIDS dementia complex and other infections including meningitis, encephalitis, neurosyphilis, Lyme disease, Creutzfeldt–Jakob disease, other prion diseases, and CNS Whipple's disease
- Diffuse anoxic injury
- Prolonged status epilepticus
- Chronically elevated intracranial pressure
- Multiple sclerosis and other demyelinating disorders
- Vasculitis
- Chronic electrolyte abnormalities or hepatic, renal, or pulmonary failure
- Heavy-metal toxicity (lead, arsenic, gold, bismuth, manganese, mercury)
- Hypothyroidism, hyperthyroidism
- Vitamin B12 deficiency, pellagra
- Inborn errors of metabolism
- Wilson's disease
- Congenital or developmental disorders

TABLE 19.16 Blessed Dementia Scale[a]

A. CHANGES IN PERFORMANCE OF EVERYDAY ACTIVITIES

Inability to perform household tasks	0 .5 1
Inability to cope with small sums of money	0 .5 1
Inability to remember short lists of items (e.g., in shopping)	0 .5 1
Inability to find way about indoors	0 .5 1
Inability to find way about familiar streets	0 .5 1
Inability to interpret surroundings (e.g., to recognize whether in hospital or at home, to discriminate between patients, doctors, nurses, relatives, hospital staff, etc.)	0 .5 1
Inability to recall recent events (e.g., recent outings, relatives' or friends' visits, etc.)	0 .5 1
Tendency to dwell in the past	0 .5 1

B. CHANGES IN HABIT

Eating:	Cleanly with proper utensils	0
	Messily with spoon	1
	Simple solids (no utensils)	2
	Has to be fed	3
Dressing:	Unaided	0
	Occasionally misplaced buttons, etc.	1
	Wrong sequence, often forgets items	2
	Unable to dress	3
Sphincter control:	Complete	0
	Occasionally wets bed	1
	Frequently wets bed	2
	Doubly incontinent	3

C. CHANGES IN PERSONALITY

Increased rigidity	0 1
Increased egocentricity	0 1
Impairment of regard for feelings of others	0 1
Coarsening affect	0 1
Impairment of emotional control (e.g., increased petulance and irritabilty)	0 1
Hilarity in inappropriate situations	0 1
Diminshed emotional responsiveness (e.g., depression)	0 1
Sexual misdemeanor (de novo in old age)	0 1

D. CHANGES IN INTERESTS AND DRIVES

Hobbies relinquished	0 1
Diminshed initiative or growing apathy	0 1
Purposeless hyperactivity	0 1

LEFT SCORE _____

E. INFORMATION

Name		0 1
Age		0 1
Time (hour)		0 1
Time of day		0 1
Day of week		0 1
Date		0 1
Month		0 1
Season		0 1
Year		0 1
Place:	Name	0 1
	Street	0 1
	Town	0 1
Type of place (home, hospital, etc.)		0 1
Recognition of persons (any 2 available)		0 1 2

F. PERSONAL MEMORY

Date of birth	0 1
Place of birth	0 1
School attended	0 1
Occupation	0 1
Name of sibling or spouse	0 1
Name of any town where patient worked	0 1
Name of employer	0 1

G. NONPERSONAL MEMORY

Date of WWI (1914–1918)	0 1
Date of WWII (1939–1945)	0 1
President	0 1
Vice-President	0 1

H. 5-MINUTE RECALL

(Mr.) John Brown	0 1 2
42 West (Street)	0 1 2
Cambridge, (MA)	0 1

I. CONCENTRATION

Months backwards	0 1 2
Counting 1–20	0 1 2
Counting 20–1	0 1 2

RIGHT SCORE _____

TOTAL SCORE _____

[a]From Blessed G, Tomlinson BE, Roth M. 1968. *Br J Psychiatry* 114: 797–811.

Aside from Alzheimer's disease, numerous other primary neurodegenerative disorders can lead to dementia, some of which are listed in Table 19.15. Many (such as dementia with Lewy bodies, Parkinson's disease, and others) are associated with movement disorders and are described in Chapters 15 and 16 (see KCC 15.3, 16.1–16.3). Briefly, recall that **dementia with Lewy bodies** typically begins with fluctuating dementia, parkinsonism, and visual hallucinations. Pathologically, there are intraneuronal inclusions called Lewy bodies in the substantia nigra (as in Parkinson's disease) as well as in more widespread cortical and subcortical structures, often coexisting with the pathologic changes of Alzheimer's disease. After Alzheimer's disease and dementia with Lewy bodies the next most common group of primary degenerative dementias consists of the **frontotemporal dementias.** These patients develop **lobar atrophy,** usually involving the anterior frontal and temporal lobes out of proportion to other structures. The atrophy may be asymmetrical in some patients. Onset is often accompanied by behavioral changes suggestive of frontal lobe dysfunction, such as personality changes, abulia, and disinhibition (see KCC 19.11).

One relatively common type of frontotemporal dementia is **Pick's disease,** in which pathologic changes include neuronal loss, especially in cortical layers 1 to 3, and argyrophilic inclusion bodies in the cytoplasm of neurons called Pick bodies, that stain with anti-ubiquitin and anti-tau antibodies. Other frontotemporal dementias involve frontotemporal atrophy without these characteristic pathologic changes, referred to as dementia lacking specific histopathology (DLSH). In some forms, motor neuron disease resembling ALS (amyotrophic lateral sclerosis; see KCC 6.7) occurs as well. One interesting form of frontotemporal dementia having autosomal dominant inheritance has been localized to chromosome 17.

In **cortical-basal ganglionic degeneration** (corticobasal degeneration), there is asymmetrical onset of a movement disorder such as dystonia, accompanied by cortical features most often consisting of a marked apraxia. **Primary progressive aphasia** is likely a family of degenerative conditions in which aphasia may be prominent at the outset. Pathology in these patients shows changes similar to Alzheimer's disease, Pick's disease, DLSH, or Creutzfeldt–Jakob disease, often more severe in the language areas of the dominant hemisphere.

Although Alzheimer's disease is now recognized as being the most common cause, **vascular dementia** remains the second most common single cause, representing 10 to 15% of all cases of dementia. In **multi-infarct dementia,** several cortical or subcortical infarcts cause a stepwise decline in cognitive function. Diffuse subcortical infarcts, often associated with chronic hypertension, cause a form of subcortical dementia termed **Binswanger's disease.** With the advent of CT and MRI scans, however, nonspecific diffuse white matter changes termed leukoaraiosis are often seen in older patients but are not always associated with dementia. When diffuse and severe white matter degeneration of any cause are present, a clinical picture emerges consisting of dementia, pseudobulbar affect, and frontal lobe–like features such as shuffling, magnetic gait, and gegenhalten (see KCC 19.11). **Cerebral amyloid angiopathy,** often familial, can cause dementia through multifocal recurrent hemorrhages, as well as through white matter ischemic disease. Patients who recover from severe intracranial hemorrhage of any cause may remain with astatic encephalopathy.

Psychiatric pseudodementia resulting from depression or conversion disorder can sometimes be mistaken for dementia. The diagnosis of depression, especially in the elderly, is often overlooked. It is critical to recognize the presence of so-called masked depression in these cases because

depression is usually much more treatable than dementia, can have at least as significant an impact on function, and may be life-threatening because of suicide risk. In cases of uncertainty, neuropsychology testing can be helpful in making the distinction. A clinical rule of thumb with many exceptions is that depressed patients often complain about having memory problems, while demented patients usually do not. Schizophrenia can also occasionally mimic dementia, but in addition to its typically younger age of onset, in schizophrenia delusions and hallucinations are more prominent than in most forms of dementia. In schizophrenia, attention is often profoundly impaired, making examination of cognition difficult. When patients are able to attend, however, they usually are oriented and have intact recent memory, unlike patients with dementia.

Alcoholism is another major cause of dementia. Dementia in such patients is likely multifactorial, with possible causes including thiamine deficiency, other nutritional deficiencies, multiple head injuries, and seizures. Whether alcohol itself causes permanent cortical neuronal injury remains controversial, although it is likely to cause cerebellar degeneration.

Intracranial neoplasms, which were discussed in KCC 5.8 can cause cognitive decline through local cerebral injury or through elevated intracranial pressure. It is important to perform a neuroimaging study as part of the evaluation of dementia because sometimes treatable tumors such as meningiomas can present with no significant neurologic findings other than slowly progressive cognitive decline over months to years. Similarly, imaging studies can elucidate other treatable causes, such as **normal-pressure hydrocephalus** or **chronic subdural hematoma** (see KCC 5.6, 5.7). In the elderly, chronic subdural hematomas can occur with little or no significant history of head injury.

The relationship of **head injury** to dementia is complicated because some epidemiological studies suggest an increased risk of Alzheimer's disease in patients who have had head injuries with loss of consciousness. **Dementia pugilistica** is another form of head trauma–related dementia, seen mainly in boxers who suffer recurrent head injuries. The **AIDS dementia complex** is common in advanced AIDS, but it can also occur early in the course of the illness, and it responds to treatment with antiretroviral therapy. Dementia can also occur as a result of other HIV-associated illnesses, such as PML (progressive multifocal leukoencephalopathy), and other CNS infections (see KCC 5.9). **Prion diseases,** such as Creutzfeldt–Jakob disease, are unfortunately untreatable at present, and they lead to a relatively rapid cognitive decline (see KCC 5.9).

We will now briefly touch on a few of the other secondary causes of chronic mental status changes listed in Table 19.15, particularly those that are treatable. **Electrolyte abnormalities,** especially of calcium, magnesium, or sodium, or **hepatic, renal, or pulmonary failure** can cause reversible cognitive impairment. Either **hypothyroidism or hyperthyroidism** can impair cognition. Particularly in the elderly, cognitive impairments may occur without other obvious manifestations of thyroid dysfunction. **Vitamin B_{12}** deficiency causes megaloblastic anemia, along with **subacute combined degeneration** of the spinal cord (posterior columns more than corticospinal tracts). Subacute combined degeneration can also involve the cerebral white matter, resulting in dementia. The degree of reversibility depends on how quickly vitamin B_{12} deficiency is treated. In **pellagra,** niacin deficiency can cause dementia, dermatitis, and diarrhea (mnemonic three **D**s).

MNEMONIC

Treatable infectious disorders (see KCC 5.9) such as **chronic meningitis,** particularly caused by *Cryptococcus,* can occasionally present as dementia (most often seen in elderly patients or patients with HIV). **Neurosyphilis** was formerly common and has returned somewhat in recent decades, possibly in association with the rise of HIV. **Lyme disease** is a spirochetal illness that sometimes causes impaired cognition (see KCC 5.9).

Wilson's disease is an important treatable cause of dementia, often presenting in adolescence with hepatic dysfunction, dysarthria, movement disorders, or psychotic manifestations (see KCC 16.1). **Heavy-metal toxicity** can result in cognitive impairment, often with other neurologic signs, such as peripheral neuropathy. **Dialysis dementia** has become uncommon since aluminum was removed from dialysate solutions.

Pathophysiology of Alzheimer's Disease

In Alzheimer's disease, the distribution of pathologic changes parallels the typical clinical features of this disorder (Figure 19.14). The major pathologic changes are **cerebral atrophy, neuronal loss, amyloid plaques,** and **neurofibrillary tangles.** These changes typically occur initially and are most severe in the following locations (see Figure 19.14), in decreasing order: (1) medial temporal lobes, including the amygdala, hippocampal formation (especially CA1), and entorhinal cortex; (2) basal temporal cortex extending over the lateral posterior temporal cortex, parieto-occipital cortex, and posterior cingulate gyrus; (3) frontal lobes. Of note, the primary motor, somatosensory, visual, and auditory cortices are relatively spared (see Figure 19.14). Cell loss and neurofibrillary tangles are also prominent in the nucleus basalis, septal nuclei, and nucleus of the diagonal band, where cholinergic projections arise (see Figure 14.9B), and to a lesser extent in the locus ceruleus (norepinephrine), and raphe nuclei (serotonin).

The cause of neuronal loss and the other pathologic changes of Alzheimer's disease is still under investigation, although much progress has been made in recent years. **Senile plaques** are composed of an insoluble protein core containing β-amyloid, along with apolipoprotein E, surrounded by a rim of abnormal axons and dendrites called dystrophic neurites. **Neurofibrillary tangles** are intracellular accumulations of hyperphosphorylated microtubule-associated proteins or paired helical filaments known as tau proteins. Amyloid is a general term for insoluble protein deposits that can occur in various organ systems in different forms of amyloidosis. **β-Amyloid** is a specific insoluble protein associated with Alzheimer's disease, derived from proteolytic cleavage of a transmembrane protein of unknown function called **amyloid precursor protein (APP)**. Cleavage of APP can occur at sev-

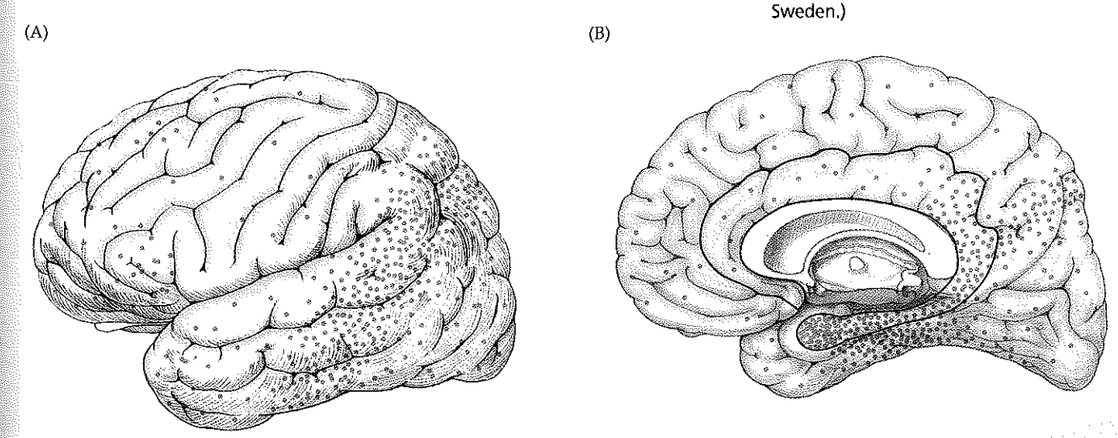

Figure 19.14 Typical Distribution of Pathologic Changes in Alzheimer's Disease Severity of composite gray matter changes (including plaques, tangles, gliosis, microvacuolation, neuronal loss, laminar blurring, and shrinkage of gray matter) is indicated by the density of colored dots. (After figure provided by Arne Brun, Lund University Hospital, Lund, Sweden.)

eral different sites, but cleavage at an intramembranous location by a protein called γ-secretase is thought to promote the formation of insoluble forms of β-amyloid, increasing plaque formation.

Investigations of the genetic basis of Alzheimer's disease have also begun to shed some light on pathogenesis. **Most cases of Alzheimer's disease are sporadic** and occur after the age of 60 years. However, two genetic loci have been found so far that affect the risk of developing Alzheimer's disease late in life. The first, located on chromosome 19, encodes **apolipoprotein E (apo E)** and has several different alleles. The ε2 allele reduces the risk of developing Alzheimer's disease, while the ***ε4* allele increases the risk of developing Alzheimer's disease.** Because apo E is a component of the amyloid plaques, these different forms of apo E have been postulated to play a role in modulating plaque formation and clearance. The second locus that may affect susceptibility to late-onset Alzheimer's is located on chromosome 12 and encodes **α_2-macroglobulin.** Two alleles have been found that increase susceptibility, and this protein has also been postulated to play a role in amyloid deposition.

In addition, Alzheimer's disease can rarely be inherited as an **autosomal dominant disorder in some families with early onset,** as early as the third or fourth decade of life. In these families, mutations have been found in three different locations that can cause early-onset disease: (1) the ***APP*** gene located on chromosome 21, (2) the ***presenilin 1* gene** on chromosome 14, and (3) the ***presenilin 2* gene** on chromosome 1. These findings are very interesting because APP is the precursor for β-amyloid, while the presenilins appear to be involved in APP cleavage. Additional genetic evidence suggesting the importance of abnormal APP processing in the pathogenesis of Alzheimer's disease comes from **Down's syndrome.** In Down's syndrome there is an extra copy of chromosome 21, which contains the *APP* gene. Patients with Down's syndrome develop early pathologic and clinical features of Alzheimer's disease after the age of 30 years.

Clinical Features of Alzheimer's Disease

Alzheimer's disease is a common disorder affecting a large proportion of the elderly population. The prevalence of Alzheimer's disease increases rapidly with age, from 1% below the age of 65 to 40% over the age of 85 years. Aside from age, the strongest risk factor is positive family history. Another possible risk factor is a history of head trauma causing loss of consciousness. Estrogen and nonsteroidal anti-inflammatory drug use may be protective.

The clinical course of Alzheimer's disease is variable; however, a description of the typical evolution is instructive and parallels the anatomical distribution of pathologic changes (see Figure 19.14). Obtaining the history from patients with Alzheimer's disease may be difficult because patients often, but not always, have anosognosia and are unaware of their deficits. Family members may be helpful, although some will also deny deficits in loved ones, so the best data comes from either previous mental status assessments (when available) or objective descriptions of functional status at specific times, such as ability to balance a checkbook, pay the bills, shop unaccompanied, and so on.

The earliest clinical feature, often appreciated only in retrospect, is typically a subtle loss of interest or withdrawal from some previous activities. However, **the dominant early feature of Alzheimer's disease is usually memory loss,** particularly for recent memories, with a relative sparing of remote memories. Patients may have difficulty remembering recent events, where they left their keys, or what they were planning on buying in a store. Although remote memories are less severely impaired, there is often some memory loss for less recent events as well. These early changes in memory function parallel the prominent pathologic involvement of the medial temporal lobe structures in Alzheimer's disease (see Figure 19.14; see also KCC 18.1).

Next, patients often develop word-finding difficulty, or an **anomic aphasia** (see KCC 19.6), along with other features of posterior temporoparieto-occipital dysfunction, including **apraxia** and **visual-spatial deficits** (see KCC 19.7, 19.10). At some point in the course of the illness, patients develop various behavioral abnormalities that become very difficult for caregivers. Typically, behavioral abnormalities occur later in this illness than in the frontotemporal dementias, but eventually they occur in Alzheimer's disease as well. Patients may wander and become lost in the neighborhood; leave the house unclothed; become paranoid or accusatory, sexually inappropriate, agitated, or aggressive; fail to recognize family members; or perform unusual activities, such as placing food in the oven without turning it on or, even worse, turning on all the stove's burners and then leaving the house. One woman cut holes in her pillows, poured orange juice into them, and then explained that she was "feeding the babies." Later in the course of the disease, patients develop more severe **frontal lobe dysfunction,** with gait impairment, abulia, and incontinence.

Of note, motor disturbances are not usually present early in the course, and if abnormal gait is present early on, other diagnoses should be considered. Similarly, while hallucinations may occur in Alzheimer's disease, they are not usually an early feature, and they are more common in dementia with Lewy bodies. In late Alzheimer's disease, patients eventually become akinetic, mute, unresponsive, and bedridden, ultimately succumbing to infection or other illnesses. The median time of survival from onset is approximately 8 years.

The evaluation of patients with suspected Alzheimer's disease is similar to that of other patients with dementia, as described earlier.

Treatment of Alzheimer's Disease

Although a definitive treatment for Alzheimer's disease has not yet been developed, a combination of symptomatic treatment and counseling of the patient and family members can substantially improve quality of life. Several cholinesterase inhibitors, including tacrine, donepezil, rivastigmine, and galantamine have been shown to produce a modest delay in cognitive decline in patients with Alzheimer's disease. The occurrence of depression, psychosis, or agitation should be treated carefully with medications, with care being taken to avoid worsening functional status with medication side effects.

Investigations are ongoing for a number of agents that may slow the progression of Alzheimer's disease. α-Tocopherol (vitamin E) and seligiline cause a slight delay, of about 20 to 30 weeks, in the development of the later stages of Alzheimer's disease. Several other anti-inflammatory and antioxidant agents are being investigated, and most recently the possibility of β-amyloid protein immunization therapy is being explored. It is hoped that with further research, a cure for this common and debilitating disorder will be developed in the near future. ■

CLINICAL CASES

CASE 19.1 ACUTE SEVERE APHASIA, WITH IMPROVEMENT

CHIEF COMPLAINT

A 74-year-old right-handed woman was brought to the emergency room because **of sudden inability to speak and right-sided weakness.**

HISTORY

One month prior to admission, the patient was diagnosed with atrial fibrillation associated with hyperthyroidism. Her medications included Coumadin anticoagulation, but she may have been noncompliant. During dinner on the evening of admission, she suddenly stopped speaking and was noted by her family to have right-sided weakness. By the time they brought her to the emergency room, the right-sided weakness had mostly resolved, but her speech remained very abnormal.

PHYSICAL EXAMINATION (HOSPITAL DAY 1)

Vital signs: T = 99.1°F, P = 100, BP = 138/84, R = 20.
Neck: Supple with no bruits; thyroid slightly enlarged.
Lungs: A few crackles at the bases bilaterally.
Heart: Irregular rate; tachycardic; 2/6 systolic murmur heard at apex.
Abdomen: Normal bowel sounds; soft, nontender.
Extremities: No edema.
Neurologic exam:

MENTAL STATUS: Alert.

1. *SPONTANEOUS SPEECH:* **Marked paucity of spontaneous speech;** said only single words and rare rote phrases, such as "No" (inappropriately), "I can't," or "I don't know." Cleared throat as if about to speak, but then didn't say anything or said very little. Uttered occasional meaningless **paraphasic** phonemes. Voice **dysarthric** and hypophonic. Did better with rote tasks and singing. For example, once the examiner got her started, the patient was able to continue counting up to 7 and to sing a few phrases of "Happy Birthday." She appeared frustrated by her difficulties.
2. *COMPREHENSION:* **Followed no commands** correctly except "close your eyes." Did not answer yes/no questions or point appropriately at named objects. Did imitate or obey gestures occasionally and caught on to tasks on the basis of context.
3. *REPETITION:* **Could repeat "no," but not "cat,"** "Alice," or other words.
4. *NAMING:* **Named no objects.**
5. *READING:* **Unable to read.**
6. *WRITING:* **Scribbled** with pen, producing no letters.

CRANIAL NERVES: **Pupils 3 mm bilaterally. Preserved blink to threat bilaterally.** Extraocular movements intact. Corneal reflex intact bilaterally. **Marked weakness of right face, sparing forehead.** Normal gag.

MOTOR: Normal tone. **Finger taps slightly slowed on the right.** Normal strength bilaterally, but testing limited by motor impersistence. Able to use both hands well when putting on socks.

REFLEXES:

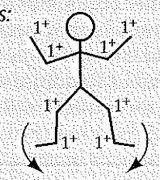

COORDINATION: No ataxia of arm movements when reaching for objects bilaterally.

GAIT: Somewhat tentative, but narrow based.

SENSORY: Flinched equally in response to pinprick in all extremities.

FOLLOW-UP EXAM (HOSPITAL DAY 3)

On motor exam, the patient had **mild clumsiness and pronator drift of the right arm.** Spontaneous speech consisted of **only a few single words.** Comprehension was much improved, and she could answer most yes/no questions appropriately and followed one-step commands. **Repetition, naming, reading, and writing were still very poor or nonexistent.**

FOLLOW-UP EXAM (HOSPITAL DAY 5)

Spontaneous speech was **markedly nonfluent, with brief agrammatical phrases and occasional paraphasias.** For example, when asked to describe what she saw in a complex scene that included water overflowing a sink, she said, **"Walur over here."** She continued to seem **frustrated and discouraged** by her limitations. Comprehension continued to improve, and she was able to answer simple questions related to herself with 70% accuracy, and to point to objects with 75% accuracy, with occasional perseveration. **When asked to name a pen, she said "pencil," and she could not name a watch. She wrote "Thank you" instead of her name, and she could not read it back.**

LOCALIZATION AND DIFFERENTIAL DIAGNOSIS

1. Summarize the findings on day 1. What kind of aphasia did the patient have that day, and what is the localization? What is the most likely cause?
2. Summarize the findings on days 3 and 5. What kind of aphasia did the patient have, and what is the localization?

Discussion

1. The key symptoms and signs in this case on day 1 are:
   - **Poor fluency**
   - **Poor comprehension**
   - **Poor repetition**
   - **Paraphasias, anomia, alexia, agraphia, frustration**
   - **Dysarthria, with right face and hand weakness**

   Severely impaired fluency, comprehension, and repetition together are classified as global aphasia (see Figure 19.4; KCC 19.6), a diagnosis that is compatible with the other language abnormalities seen in this patient. Persistent global aphasia is usually caused by large lesions involving the anterior and posterior language areas, or by large subcortical lesions (KCC 19.6). However, global aphasia can also occur acutely in new-onset lesions confined to the anterior or posterior language areas. Combined anterior–posterior language area lesions or large subcortical lesions usually result in contralateral hemiplegia, whereas this patient had relatively mild arm weakness and no leg weakness. The pattern of weakness in this patient is compatible with a lesion encroaching on the left lateral precentral gyrus face and hand areas (see Figures 6.2, 6.14D), suggesting that she has acute global aphasia resulting from a lesion in the left lateral frontal cortex, including the anterior language areas. Given her vascular risk factors of atrial fibrillation and possible noncompliance with anticoagulation therapy, as well as the sudden onset of her deficits, the most likely diagnosis is embolic infarction in the territory of the left middle cerebral artery superior division (see Figure 19.3A). Another possibility is a hemorrhage in the left frontal lobe, especially because she is taking Coumadin. Focal seizures or migraine are also possible, but much less likely (see also Table 19.5).
2. The key symptoms and signs in this case on days 3 and 5 are:
   - **Poor fluency**
   - **Poor repetition**
   - **Comprehension relatively spared**
   - **Poor naming, reading, and writing, with paraphasias and frustration**
   - **Mild right arm weakness**

   By days 3–5 the patient's global aphasia had improved to a typical Broca's aphasia (see KCC 19.4). This pattern of evolution is often seen in acute lesions of the left lateral frontal lobe. The next most common cause would be left MCA superior division infarct.

Clinical Course and Neuroimaging 878

Initial head CT was normal. The patient's admission INR (International Normalized Ratio), a measure of the amount of anticoagulation, was subtherapeutic at 1.1 (target 2.0–3.0), and levels of her heart medication were also low, supporting medication noncompliance as the cause of a presumed embolic infarction in the territory of the left MCA superior division. She was admitted and placed on intravenous heparin anticoagulation while her Coumadin was readjusted. Two days after admission, a **brain MRI** (Figure 19.15) revealed a medium-sized infarct in the left frontal operculum involving Broca's area, just in front of the precentral gyrus face and arm areas.

As already noted, the patient's global aphasia rapidly evolved into a Broca's aphasia, and this condition continued to improve, as did her trace right-sided weakness. She was seen in follow-up 2 months later, at which time she was able to speak in sentences with occasional pauses to find words, and occasional paraphasias. Comprehension, repetition, reading, and writing were relatively good (although not perfect), and her main difficulties were with naming and finding words. Thus, as is commonly seen in cases with good recovery, her residual deficit was predominantly a dysnomic aphasia.

CASE 19.1 ACUTE SEVERE APHASIA, WITH IMPROVEMENT

Figure 19.15 Left MCA Superior Division Infarct MRI scans. (A) Axial T2-weighted image showing bright region compatible with infarct in the left frontal operculum including Broca's area. (B) Sagittal T1-weighted image showing hypointense region compatible with infarct.

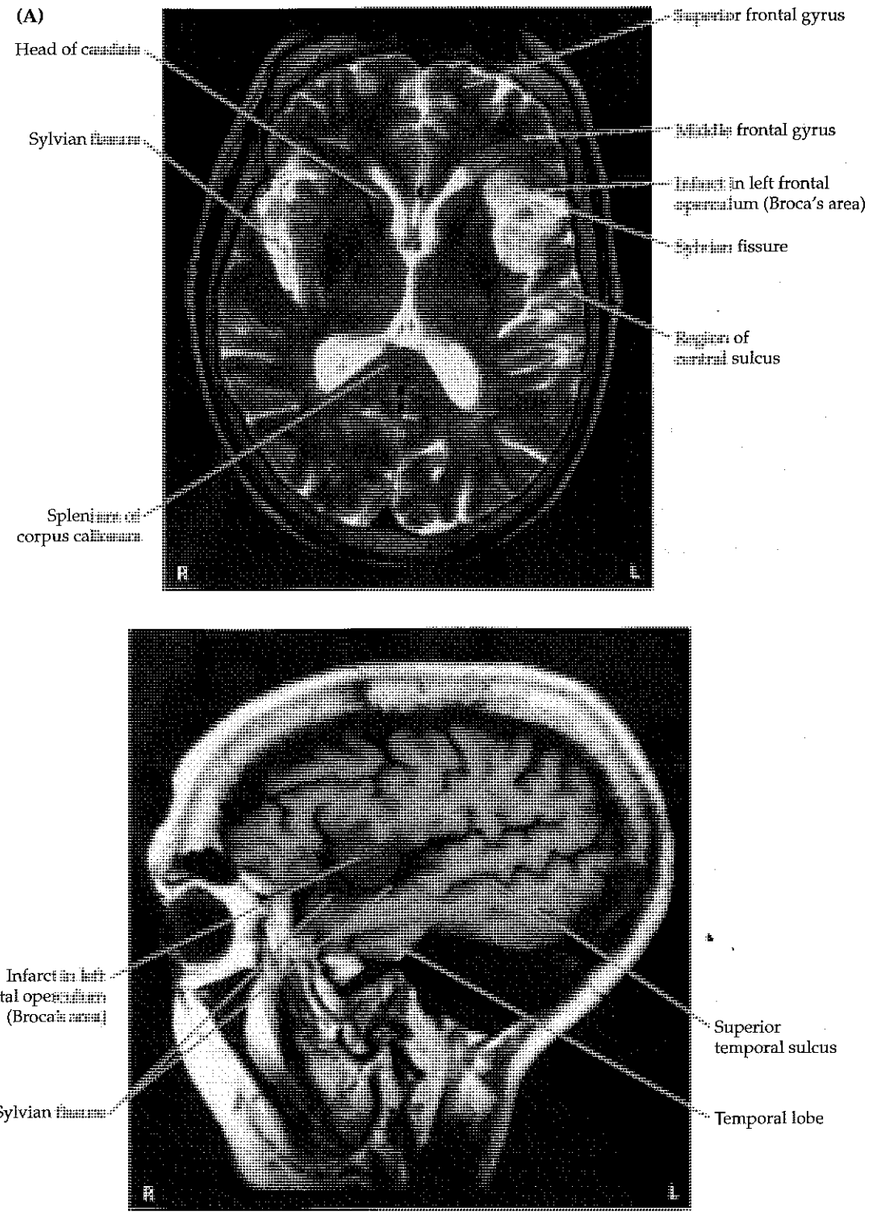

CASE 19.2 NONSENSICAL SPEECH

MINICASE

An 81-year-old right-handed woman with a history of hypertension was brought to the emergency room by her family one morning when she was suddenly **"unable to communicate properly," speaking with words and sentences that did not make any sense.** On exam, she had an irregular pulse, and spontaneous speech was fluent with normal prosody and grammatical constructs; however, most of what she said was **meaningless and did not fit the context, showing frequent paraphasic errors and repetition. She followed no commands, except to close her eyes. When asked to raise her arms, she said, "What do you want?" She could not repeat even single words. On testing of naming, she called a pen "red rains," a watch "round thing," a tie "po, do, bi, fisdo," and a pen (second presentation) "like when you want to write down something." Writing sample: "the wond youg wweng whaweta." She could not read what she wrote. When asked to read, "The dog ran down the road," she read, "The roth ran ra a goth." She had a pleasant, unconcerned affect and seemed oblivious to any deficits. Blink to threat was decreased on the right side.** The remainder of her exam was normal.

LOCALIZATION AND DIFFERENTIAL DIAGNOSIS

1. What kind of aphasia does this patient have? Where is her lesion?
2. What is the most likely cause, and what are some other possibilities?

Discussion

The key symptoms and signs in this case are:

- **Fluent, meaningless speech**
- **Poor comprehension**
- **Poor repetition**
- **Poor naming, reading, and writing; frequent paraphasias**
- **Lack of concern about and obliviousness to deficits**
- **Right visual field defect**

1. This patient has typical findings of Wernicke's aphasia (see KCC 19.5). The localization therefore is most likely in the left posterior superior temporal and left inferior parietal region. A lesion in this location would also explain the patient's right visual field cut because it could interrupt the left optic radiations (see Figure 11.8).
2. The left temporoparietal region lies in the territory of the left MCA inferior division. The most likely diagnosis, especially given the patient's age, history of hypertension, and acute onset, is an infarct in this territory (see Figure 19.3A). Hemorrhage in this location is also possible, with focal seizure or migraine again possible but unlikely (see also Table 19.5).

Clinical Course and Neuroimaging BBO

A head CT on the day of admission showed an infarct in the left temporoparietal region, in the territory of the left MCA inferior division. This was confirmed 4 days later by an **MRI scan** (Figure 19.16). Note that the infarct included Wernicke's area along with the adjacent temporoparietal cortex, as well as the left optic radiation where it passes just lateral to the atrium of the lateral ventricle. The MRI also demonstrated moderate cortical atrophy as an incidental finding in this patient. Admission electrocardiogram showed new onset of atrial fibrillation. Other embolic workup (see KCC 10.4) was negative. The patient was treated with intravenous heparin, changed over to oral anticoagulation with Coumadin, and discharged home in the care of her family after 1 week. Further follow-up was not available.

Additional Basic Aphasia Cases

For additional cases illustrating **basic types of aphasia,** see Chapter 10 (Cases 10.5, 10.6, and 10.8).

CASE 19.2 NONSENSICAL SPEECH

Figure 19.16 Left MCA Inferior Division Infarct Axial T2-weighted images. A, B progress from inferior to superior. The infarct includes Wernicke's area.

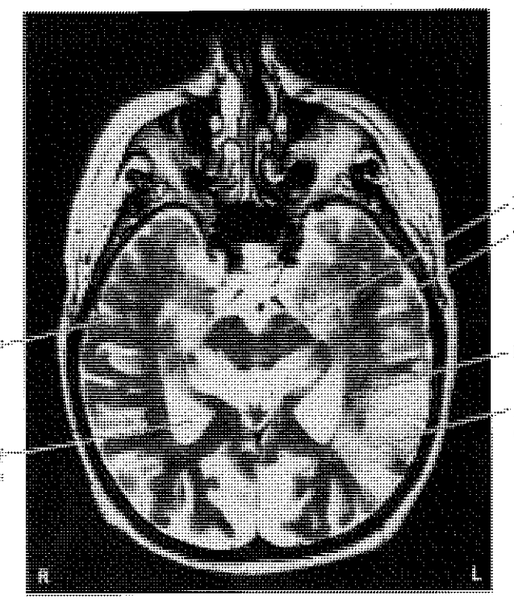

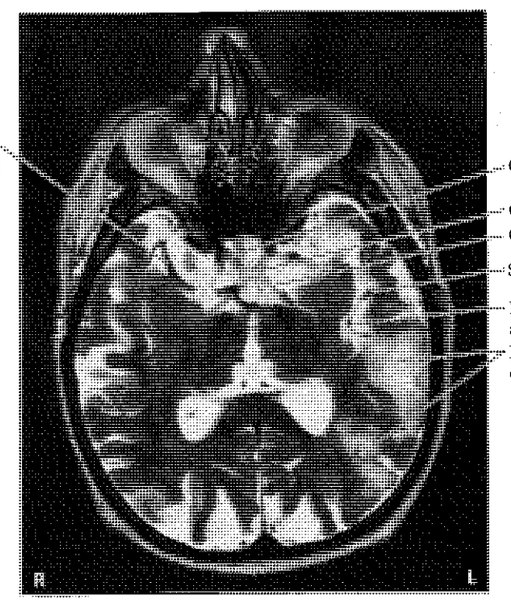

CASE 19.3 APHASIA WITH PRESERVED REPETITION

MINICASE

A 63-year-old right-handed woman with a history of breast cancer in remission was talking on the phone with her sister one evening and suddenly began to have **difficulty getting the words out, and she could not answer simple questions.** She was taken to the hospital, and on exam she was alert and able to state her name, the month, and the year, but not the date, and she correctly chose her location by multiple choice. Her language exam was as follows:

1. *SPONTANEOUS SPEECH:* **Halting, labored, telegraphic, with decreased use of function words (verbs and prepositions). She frequently used fillers such as "um," "aaah," and "you know" and had many paraphasic errors and neologisms. She did better once started by the examiner on automatic tasks such as naming the days of the week. On word generation tasks, she could name only six animals in 1 minute, and she came up with no words starting with the letter "s" in 1 minute.**
2. *COMPREHENSION:* Followed three-step verbal commands. Was able to rapidly identify body parts, objects, shapes, and letters by pointing. Correctly answered 6/8 questions on verbally presented paragraphs. Had difficulty following only lengthy, complex commands.
3. *REPETITION:* Repeated words and sentences with 100% accuracy (much better than spontaneous speech). With low-probability sentences, she made occasional paraphasic errors.
4. *NAMING:* **Could name only 1/6 objects and no shapes.** Naming was improved when she was given the first sound of the word as a hint.
5. *READING:* Reading aloud was not tested.
6. *WRITING:* **Wrote the following sentence spontaneously: "I this a mighty foyin am y."**

The remainder of her exam was normal.

LOCALIZATION AND DIFFERENTIAL DIAGNOSIS

1. What kind of aphasia was present in this patient? Where was her lesion?
2. What are some possible causes in this patient?

Discussion

The key symptoms and signs in this case are:

- **Poor fluency**
- **Repetition and comprehension relatively spared**
- **Poor naming and writing; paraphasias**

1. This patient had a transcortical motor aphasia (see Figure 19.4). This can be produced by lesions located in the lateral frontal cortex in the dominant hemisphere that spare the arcuate fasciculus, the other peri-Sylvian conducting pathways, and Broca's area (see Figure 19.3B), or occasionally by subcortical lesions of the dominant hemisphere sparing the same regions.
2. Possible causes of a lesion in these locations resulting in sudden onset of deficits include watershed infarct in the ACA–MCA territory (see Figure 19.3B) or hemorrhage (see KCC 5.6). Given the patient's history of breast cancer, a metastasis should also be considered, possibly resulting in hemorrhage. Of note, sudden onset of deficits in brain tumors can sometimes occur even without hemorrhage, although this is relatively uncommon.

Clinical Course and Neuroimaging 884

Head CT (Figure 19.17A) showed a hemorrhage in the left frontal lobe, sparing the peri-Sylvian cortex and sparing Broca's area, but lying just dorsal to it. This hemorrhage would be expected to disconnect Broca's area from other structures in the left frontal lobe needed for language formulation, producing the transcortical motor aphasia (impaired fluency, preserved repetition) seen in this patient. An **MRI scan** (see Figure 19.17B) done with gadolinium was negative for brain metastases, but again showed a hemorrhage in this location. The exam and neuroimaging findings in this patient should be contrasted against those for the patient with Broca's aphasia in Case 19.1.

Follow-up MRI scans at 1, 4, and 9 months after the hemorrhage showed no evidence of metastases or vascular malformation. The patient did not undergo an angiogram, but MRAs were unremarkable. Her language gradually improved, and 1 year later her fluency was nearly normal. She remained in active speech therapy, and her main residual problems were some word-finding difficulties and circumlocution.

CASE 19.4 IMPAIRED REPETITION

MINICASE

A 67-year-old right-handed woman was in a motor vehicle accident with **brief loss of consciousness and mild confusion at the scene.** Past history was significant for a mechanical mitral valve and coronary artery disease, treated with aspirin and Coumadin anticoagulation. After the accident she complained of **left frontal headache, neck pain, nausea, and vomiting.** She was brought to the emergency room, where cervical spine X-rays were normal and initial neurologic exam was described as normal except for **amnesia for the accident and uncertainty about the exact date,** although she knew the correct month and the year. Two days later her headache worsened, and she was noted to have some new speech difficulties. A neurology consult was called. Exam showed some **nuchal rigidity,** a systolic murmur, fluent speech, intact comprehension following three-step commands, but **difficulties with repetition (unable to repeat "no ifs, ands, or buts" or other similar short phrases), a slight right pronator drift, and an upgoing toe on the right side.**

LOCALIZATION AND DIFFERENTIAL DIAGNOSIS

1. What kind of aphasia did this patient have on exam, and what is the localization of her aphasia and associated mild motor abnormalities?
2. What diagnosis is suggested by the patient's history and her initial symptoms?

Discussion

The key symptoms and signs in this case are:

- **Poor repetition**
- **Relatively preserved fluency and comprehension**
- **Mild right pronator drift and right Babinski's sign**
- **Brief loss of consciousness, amnesia, left frontal headache, nausea, vomiting, and nuchal rigidity**

1. This patient had conduction aphasia (see Figure 19.4), which can be caused by subcortical lesions involving the arcuate fasciculus or by cortical lesions of the peri-Sylvian region in the dominant hemisphere (see Figure 19.2A). The mild right corticospinal findings also suggest a lesion in the left hemisphere causing mild impingement on the nearby corticospinal tract (see Figure 6.10A).
2. The brief loss of consciousness and confusion suggest a possible head injury during the motor vehicle accident. The headache, nausea, vomiting, and nuchal rigidity are signs of meningeal irritation (see Table 5.5) which, together with the patient's use of oral anticoagulation and aspirin, suggest intracranial hemorrhage (see KCC 5.6) located in the peri-Sylvian region of the dominant (left) hemisphere. Other, less likely possibilities include infarct, neoplasm, or infection in this location.

Clinical Course and Neuroimaging 885

Head CT (Figure 19.18) demonstrated a traumatic hemorrhage (see KCC 5.5, 5.6) in the left Sylvian fissure. This included layering of subarachnoid blood in the sulci, as well as a more confluent parenchymal hematoma. The hemorrhage involved the peri-Sylvian region, including the region of the arcuate fasciculus, and could thus disconnect the anterior and posterior language areas (see Figure 19.2A). A small subdural hematoma was present as well, adjacent to the right falx cerebri (not shown on Figure 19.18), likely unrelated to this patient's findings.

The patient's aspirin was discontinued and her Coumadin temporarily stopped. She was also given a few units of fresh frozen plasma to partly reverse her anticoagulation. She remained stable over the next few days and was carefully treated with low-dose heparin before resuming her Coumadin. Nine days after admission, her repetition had improved, but she also practiced the commonly used phrases, and would greet the neurology team on morning rounds with "Good morning. No ifs, ands, or buts. If I were here, she would be there . . . How was that?" She continued to have some mild difficulties, especially when repeating new sentences that she had not heard before.

CASE 19.5 INABILITY TO READ, WITH PRESERVED WRITING SKILLS

MINICASE

A 64-year-old right-handed woman had 1 week of progressive **troubles with her vision and reading.** Of note, she had a 3-year history of colon cancer with metastases to the liver. Exam was normal, except for **inability to read written words, some difficulties with short-term verbal memory, and a right homonymous hemianopia.** She was able to write normally, writing "Today is a nice day" and "It is a sunny day in Boston," but when shown her own writing a few minutes later, she was unable to read it. She also had a **subtle dysnomia,** naming a watch, ring, finger, elbow, and lips, but unable to name knuckle, nail, veins, or hand. Color naming was not tested.

LOCALIZATION AND DIFFERENTIAL DIAGNOSIS

1. What is the name for the syndrome that includes the inability to read and preserved writing seen in this patient, and where is it localized?
2. Given the gradual onset of deficits and the patient's history, what are some possible causes of a lesion in this location?

Discussion

The key symptoms and signs in this case are:

- **Ability to write normally, but inability to read**
- **Right homonymous hemianopia**
- **Some difficulties with short-term verbal memory**
- **Mild dysnomia**

1. This patient has the classic findings of alexia without agraphia, which is caused by lesions of the left medial occipital visual cortex extending to the posterior corpus callosum (see KCC 19.7; Figure 19.5).
2. Given the gradual onset over the course of a week, and the history of colon cancer, brain metastases should be considered in this patient. Other possibilities include a slowly evolving infarct in the left PCA territory, evolving intracranial hemorrhage, other intracranial neoplasm, or abscess.

Clinical Course and Neuroimaging 887

A **head CT** with intravenous contrast (Figure 19.19) revealed a large, cystic enhancing lesion in the left medial occipital lobe with edema and mass effect extending into the posterior corpus callosum. The patient was admitted and treated with steroids to reduce edema. By means of a stereotactic approach (see KCC 16.4) , fluid was drained from the cyst with a needle, leading to a partial improvement in her hemianopia and reading difficulties. In addition, a stereotactic biopsy revealed metastatic adenocarcinoma. She was then treated with stereotactic proton beam radiosurgery (see KCC 16.4) directed at the lesion, and she remained stable at last available follow-up, 3 months after presentation.

CASE 19.3 APHASIA WITH PRESERVED REPETITION

Figure 19.17 Left Frontal Hemorrhage The hemorrhage lies just dorsal to Broca's area, and spares the peri-Sylvian region. (A) Axial CT scan image. (B) Coronal T1-weighted MRI with intravenous gadolinium.

(A)

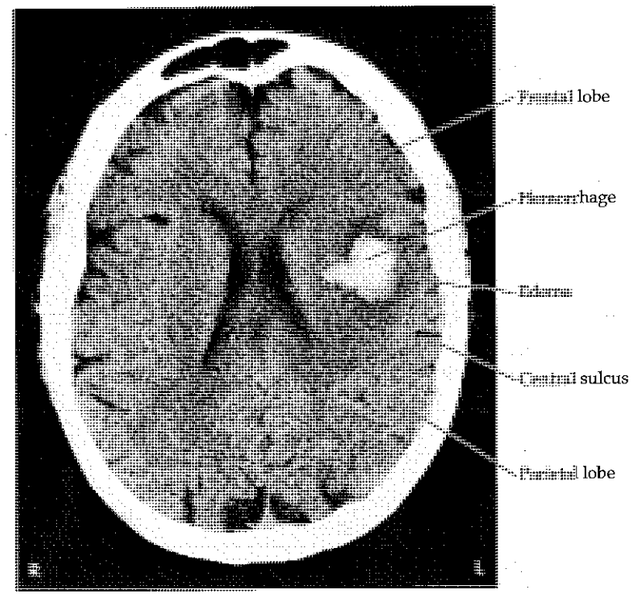

(B)

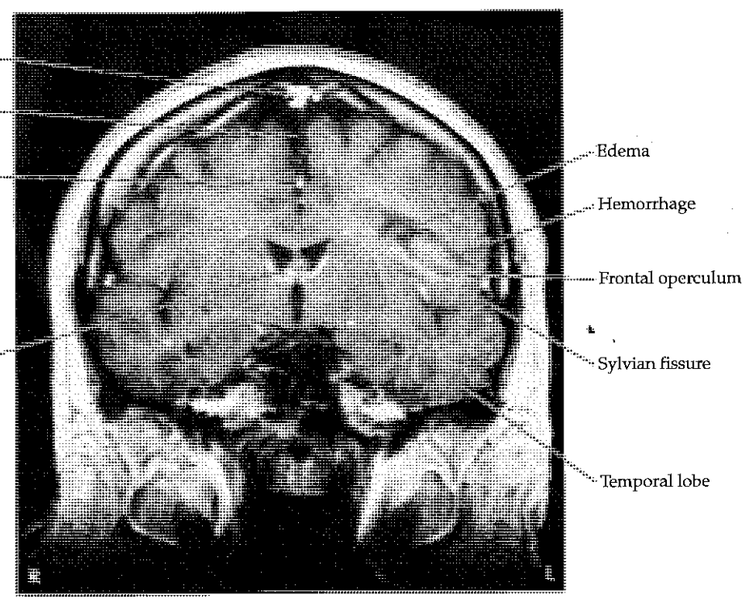

CASE 19.4 IMPAIRED REPETITION

Figure 19.18 Left Peri-Sylvian Intraparenchymal Hemorrhage in Region of Arcuate Fasciculus Axial CT images. A–D progress from inferior to superior.

(A)

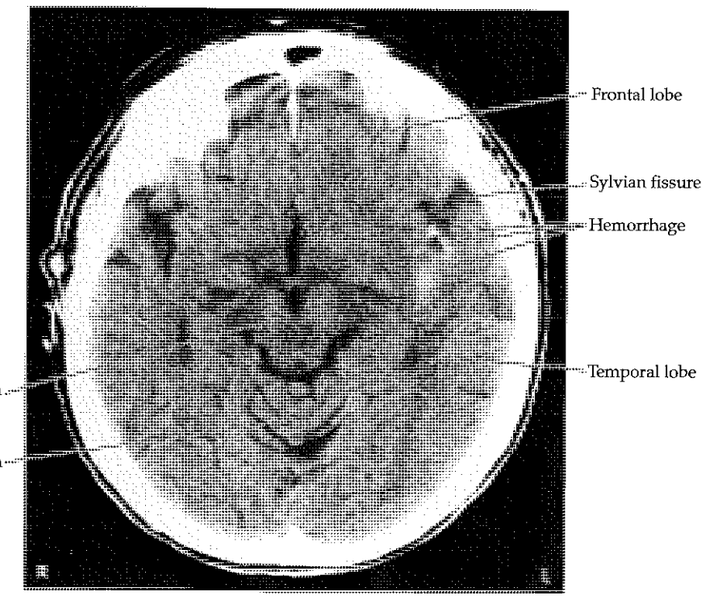

(B)

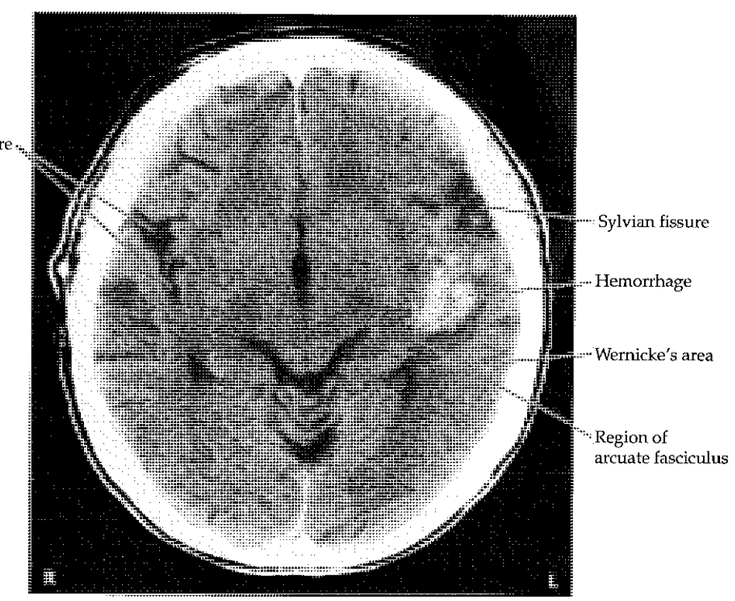

CASE 19.4 *(CONTINUED)*

(C)

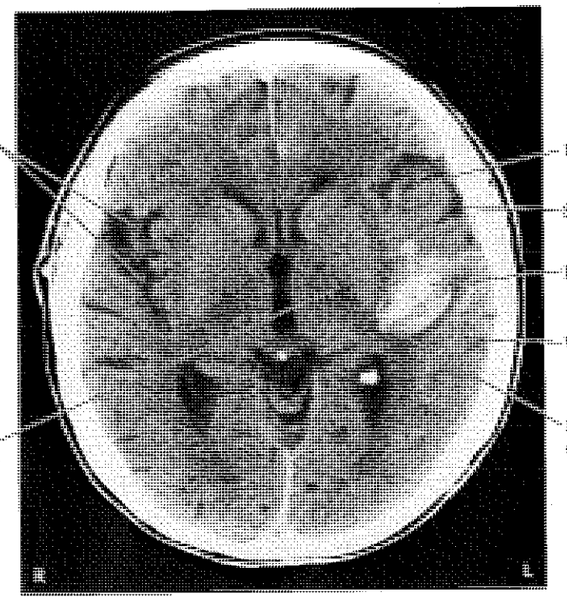

(D)

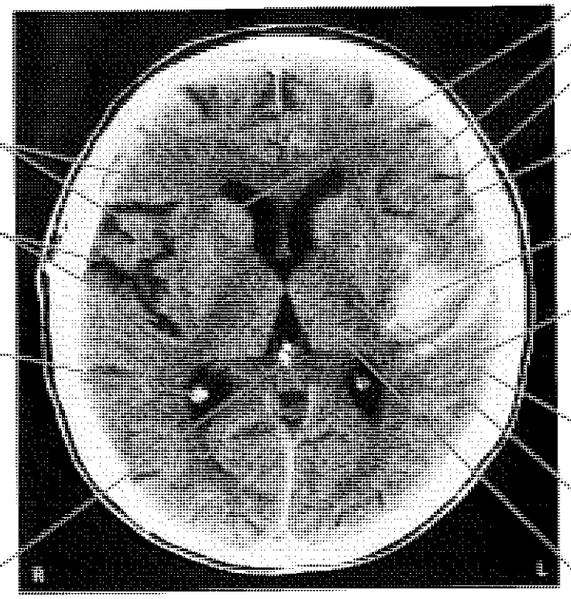

CASE 19.5 INABILITY TO READ, WITH PRESERVED WRITING SKILLS

Figure 19.19 Metastasis of Colon Adenocarcinoma to the Left Medial Occipital and Posterior Callosal Region Axial CT images with intravenous contrast enhancement. A, B progress from inferior to superior.

(A)

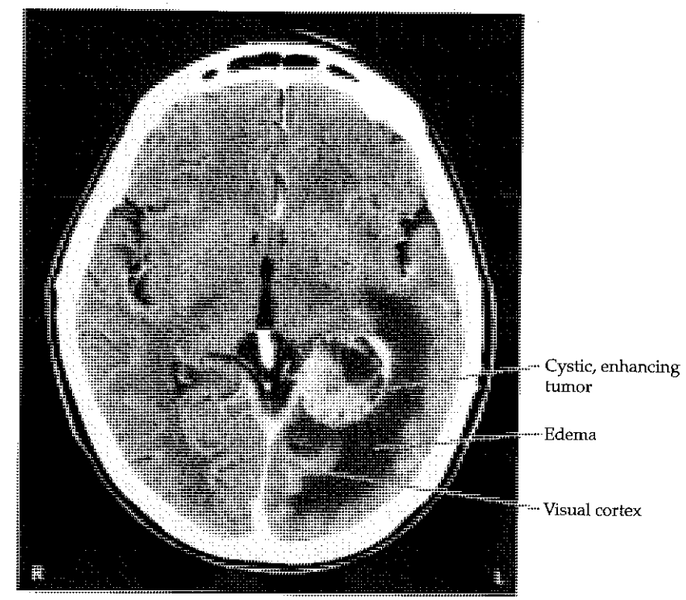

(B)

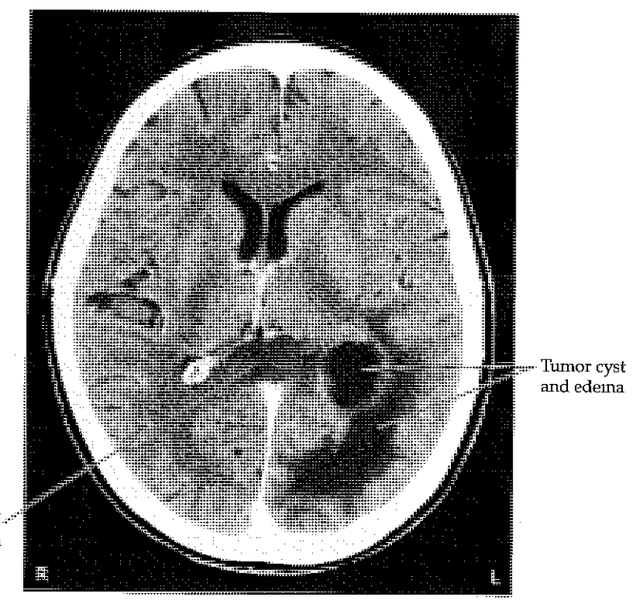

CASE 19.6 LEFT HEMINEGLECT*

MINICASE

A 61-year-old left-handed security guard with a history of cigarette smoking had an **episode of left hand tingling lasting less than an hour** that was reported to medical staff by a friend. The next day he was at the grocery store buying a lottery ticket and reportedly slumped briefly to the floor. He **denied that anything was wrong** but said, "They called an ambulance because they said I had a stroke."

On examination, he was **unaware of having any deficits** and was quite **impatient and grouchy,** wanting to go home. He had **profound left visual neglect,** describing only the curtains to the far right in a picture of a complex visual scene (Figure 19.20) and reading only the right two words on each line of a magazine article. When asked to write or draw a clock, he **moved the pen in the air off to the right of the page.** He then handed the pen back, saying, "I'm finished," apparently thinking he had completed the task. He had **no blink to threat on the left, a marked right gaze preference, and mildly decreased left nasolabial fold.** Spontaneous **movements were decreased on the left side,** but with provocation he was able to achieve **4/5 strength in the left arm and leg.** He was able to feel touch on the left side but had **extinction on the left to double simultaneous tactile stimulation. Reflexes were slightly brisker on the left.**

LOCALIZATION AND DIFFERENTIAL DIAGNOSIS

1. Summarize the different types of neglect demonstrated by this patient (see Table 19.7).
2. On the basis of the symptoms and signs shown in **bold** above, what is the most likely location of the lesion in this patient?
3. What is the most likely diagnosis?

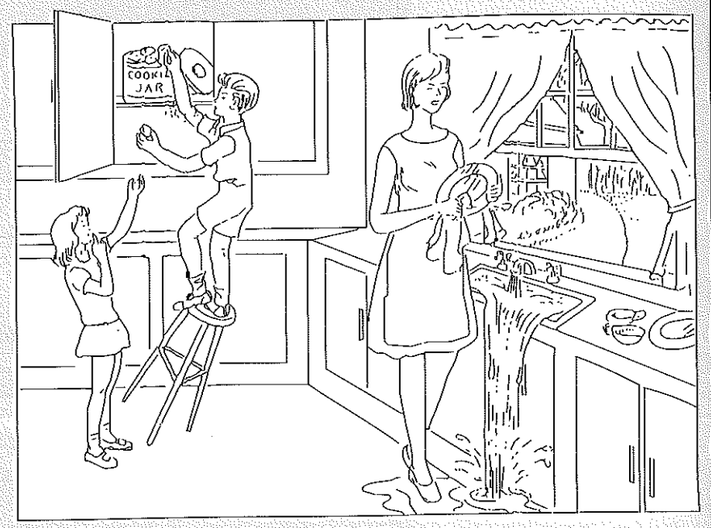

Copyright © 1972 by Lea and Febiger

Figure 19.20 Complex Picture Used for Visual Neglect Testing Asked to describe what he saw, the patient mentioned only the curtains on the far right edge of the page. (Reproduced with permission of Lea and Febiger.)

Discussion

The key symptoms and signs in this case are:

- **Anosognosia**
- **Left visual neglect**
- **Extinction on the left to double simultaneous tactile stimulation**
- **Movement of the hand off to the right of the page when asked to draw, and decreased spontaneous movements on the left side, but ability to achieve 4/5 strength when pressed**
- **Impatience and irritability**
- **Right gaze preference**
- **No blink to threat on the left**
- **Mildly decreased left nasolabial fold, 4/5 strength in the left arm and leg, and slightly brisker reflexes on the left side**
- **Transient episode of left hand tingling**

1. This patient demonstrated several typical features of hemineglect syndrome (see KCC 19.9), including *sensory neglect* for the visual and somatosensory modalities; *motor neglect* manifested as directional motor bias while attempting to draw and decreased voluntary movements of the left side unless strongly encouraged; and *conceptual neglect* in the form of complete anosognosia for his deficits. He also had a change in personality, becoming irritable, as is often seen with right hemisphere lesions (see KCC 19.10).
2. Left hemineglect is most common in lesions of the right parietal or frontal cortex (see Figure 19.8), but it can also occasionally occur with lesions of the cingulate gyrus, thalamus, basal ganglia, or midbrain reticular formation. The right gaze preference further supports a right hemisphere frontal or parietal localization (see Figure 13.14). However, decreased blink to threat is ordinarily caused by damage to primary visual pathways, and not by neglect. Therefore, the decreased blink to threat on the left suggests that the lesion is more posteriorly located, possibly involving the optic radiations as they travel beneath the right temporal and parietal lobes (see Figure 11.8). Mild corticobulbar and corticospinal findings can also be seen in parietal lesions, especially acutely (see KCC 10.1). Left hand tingling is consistent with involvement of the hand somatosensory cortex in the right parietal lobe.

   The most likely *clinical localization* is: Right temporoparietal lobe, including the optic radiations.
3. Given the sudden onset of deficits, the patient's age, and his history of smoking, the most likely diagnosis is TIA causing left hand tingling, followed by ischemic infarct (see KCC 10.3, 10.4). The right temporoparietal lobe is supplied by the right MCA inferior division. Another possibility is that the initial episode was a focal seizure, and that the patient has a tumor, hemorrhage, or infection with deficits that had previously been neglected by the patient and that became more severe on the day of admission.

Clinical Course and Neuroimaging 390

Head CT on the day of admission showed a mild hypodensity in the right temporoparietal area. Follow-up **head CT** 2 months later (Figure 19.21) confirmed right MCA inferior division infarct involving the right temporoparietal cortex and optic radiation.

Carotid Dopplers and an MRA suggested occlusion versus critical stenosis of the right carotid artery (see KCC 10.5), so a conventional cerebral angiogram was done showing occlusion of the right common carotid artery (see Figure 10.22). This result suggests that he had an embolus to the right MCA inferior division that broke off the thrombotic occlusion of the internal carotid. The patient was treated with intravenous and, later, oral anticoagulation in an attempt to reduce the risk of further emboli. By 3 days after admission, he was able to look voluntarily to the left, strength was normal on the left side when he was motivated, and reflexes were symmetrical. He still had decreased blink to threat on the left and occasional (one-third of trials) left extinction on double simultaneous tactile stimulation. Coumadin was eventually stopped, and in follow-up 1 year later, he had a normal exam except for a left visual field cut (not precisely mapped out by the examiner).

Interestingly, as is often the case, this patient had profound left hemineglect from a right hemisphere lesion, even though he was left-handed. Other examples of left hemineglect were shown earlier, in Figures 19.9 and 19.10, as well as in Cases 10.9 and 10.11.

* Note: This patient was also presented as Case 10.10.

Related Case. Figure 19.22 shows a head CT from an interesting patient who developed severe *right* hemineglect. She was a 52-year-old woman who had a left hemispherectomy (see KCC 18.2) in childhood because of early-onset severe refractory seizures arising from the left hemisphere. Despite this drastic surgery, she was highly functional as an adult, working as a librarian. Over the course of 6 months, however, she developed communicating hydrocephalus (see KCC 5.7), a known delayed complication of hemispherectomy (Figure 19.22A,C). In addition to signs of hydrocephalus such as impaired gait and lethargy, her exam was notable for right hemineglect (Figure 19.23A). This may be explained by "bilateral" lesions (see Figure 19.7D), consisting of left hemispherectomy together with depression of the right hemisphere by hydrocephalus. After ventriculoperitoneal shunting (see KCC 5.7), the patient's hydrocephalus improved (see Figure 19.22B,D) and she no longer had right hemineglect (see Figure 19.23B).

CASE 19.6 LEFT HEMINEGLECT

Figure 19.21 Right MCA Inferior Division Infarct
Axial head CT image 2 months after onset of symptoms, demonstrating a right temporoparietal hypodensity compatible with infarct.

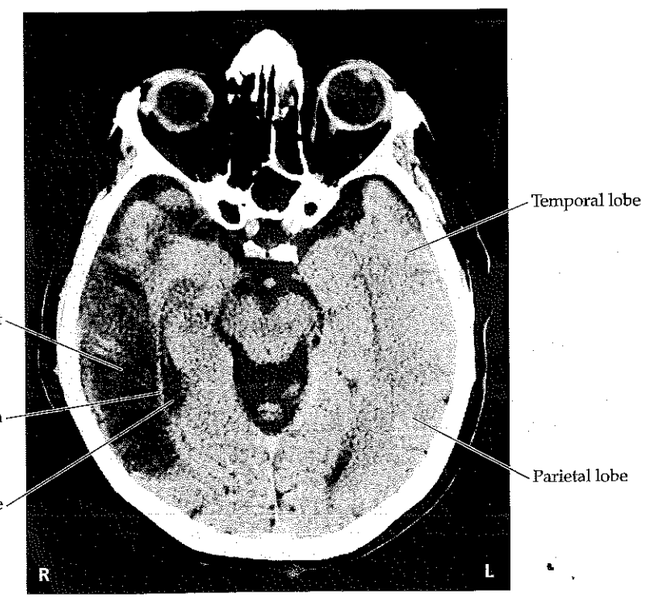

CASE 19.7 ABULIA

CHIEF COMPLAINT
A 27-year-old woman was brought to the hospital with increasing lethargy, slowness, and incontinence.

HISTORY
Five years previously the patient had developed speech difficulties and was diagnosed with a left frontal oligoastrocytoma. She was treated with resection, radiation therapy, and chemotherapy and did well, returning to work as a receptionist. Six months prior to admission, she underwent a **personality change, becoming progressively slower and more withdrawn.** As her slowness worsened, her **voice became very muted, and she rarely initiated movements.** This condition had become particularly severe over the most recent 2 to 3 weeks, and she had developed **urinary incontinence, inability to walk without assistance, and falling to the left, and she had to be fed by her mother.**

PHYSICAL EXAMINATION
Vital signs: T = 98°F, P = 80, BP = 120/70.
Neck: Supple.
Lungs: Clear.
Heart: Regular rate with no murmurs, gallops, or rubs.
Abdomen: Normal bowel sounds; soft.
Extremities: Normal.
Neurologic exam:

MENTAL STATUS: **Awake but lethargic, responding to questions or commands very slowly, often after a long delay. Sometimes she did not respond at all.** Her voice was very soft, but she could speak louder when asked. She stated the correct month, date, year, and location. She named the past two presidents after a **long delay, and then stopped.** She was able to repeat correctly, and she named 5/5 **objects. She recalled 0/3 objects after 4 minutes, even with prompting and with a second trial. She did not respond at all when asked a simple arithmetic question or when asked to spell "world."**

CRANIAL NERVES: Normal, except for **slight left facial droop and decreased shoulder shrug on the left.**

MOTOR: No drift. Normal bulk and tone. Power difficult to test because of **motor impersistence; exerted only a brief nonsustained submaximal effort during tests of each muscle group.** However, she appeared to have **4–/5 grip on the left,** 4+/5 grip on the right, and otherwise 4/5 approximately symmetrical strength throughout.

REFLEXES: **Prominent grasp reflexes were present bilaterally.** There was no snout or suck reflex.

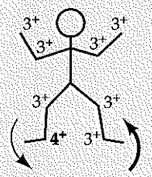

COORDINATION: Slow but not ataxic on finger-to-nose and heel-to-shin testing.

GAIT: **Very slow, shuffling, not picking feet up off floor, requiring support to avoid falling to left.**

SENSORY: Intact light touch, pinprick, and vibration sensation. No extinction.

LOCALIZATION AND DIFFERENTIAL DIAGNOSIS
1. Summarize the clinical features seen in this patient. Dysfunction of what region of the brain usually produces this syndrome? Is the lesion unilateral or bilateral?
2. Why does this patient have impaired memory testing?
3. What is the most likely diagnosis causing this patient's decline?

Discussion

1. The key symptoms and signs in this case are:
   - **Abulia (awake but slow, withdrawn, responding after long delay)**
   - **Hypokinesia (rarely initiating movements)**
   - **Hypophonia**
   - **Impaired short-term memory**
   - **Motor impersistence**
   - **Bilateral grasp reflexes**
   - **Urinary incontinence**
   - **Unsteady, slow, shuffling "magnetic" gate, falling to the left**
   - **Slight left face and arm weakness, left Babinski's sign, right ankle clonus, brisk reflexes throughout**

The clinical features summarized here can be seen in large lesions involving the frontal lobes of both hemispheres (see KCC 19.11; Table 19.10). The patient's mild corticospinal findings are bilateral as well, suggesting a bilateral lesion.

2. Memory testing commonly reveals impairment in frontal lobe lesions, probably because of impaired attention and working memory.
3. Given her prior history of a left frontal oligoastrocytoma, and bilateral findings on present exam, the most likely diagnosis is recurrent tumor extending to involve both frontal lobes.

Clinical Course and Neuroimaging 895

A **head CT** (Figure 19.24) demonstrated abnormal hypodensity involving virtually all of the prefrontal cortex bilaterally, probably representing edema and recurrent tumor. Glial tumors of this kind, extending across the anterior corpus callosum to involve both frontal lobes, are sometimes referred to as butterfly gliomas. Note also that the sulci are fully effaced, suggesting that elevated intracranial pressure could also be contributing to the patient's decreased alertness (see KCC 5.3).

The patient was admitted to the hospital and treated with increased steroids and a brief course of mannitol with no significant improvement. A repeat biopsy confirmed recurrent tumor. She was given additional chemotherapy, including intra-arterial chemotherapy delivered by superselective catheterization of the supraclinoid right internal carotid artery; however, she continued to deteriorate gradually.

Related Cases. Figure 19.25 shows an MRI from a different patient, a 73-year-old woman who was brought to a memory disorders clinic because of 6 months of forgetfulness. Neurologic exam was entirely normal except that she exhibited some perseveration, tending to answer the same thing for several questions in a row regardless of the question, and mild difficulties with both recent and remote memory. This case illustrates how enormous lesions in the frontal lobes sometimes cause relatively subtle deficits, especially if the lesion is slow growing. The lesion was removed surgically, and pathology showed it to be a meningioma. The patient's mental status improved after surgery, and she subsequently did very well. Another important lesson of this case is the importance of performing a neuroimaging study in the evaluation of patients with suspected dementia (see KCC 19.16) in an attempt to find reversible causes.

An abnormality commonly seen in patients with frontal lobe lesions is perseveration. This finding may be obvious, as it was in the patient just described and in Case 19.7. In other cases, more subtle perseveration can be detected by tests such as manual or written alternating sequencing tasks (see neuroexam.com Videos 19, 20). Figure 19.26 shows an example of a different patient who exhibited perseveration on a written alternating sequencing task. Interestingly, this patient had benzodiazepine toxicity but did not have a frontal lobe lesion, demonstrating that diffuse disorders can sometimes mimic lesions of the frontal lobes (see KCC 19.11).

CASE 19.6 RELATED CASE

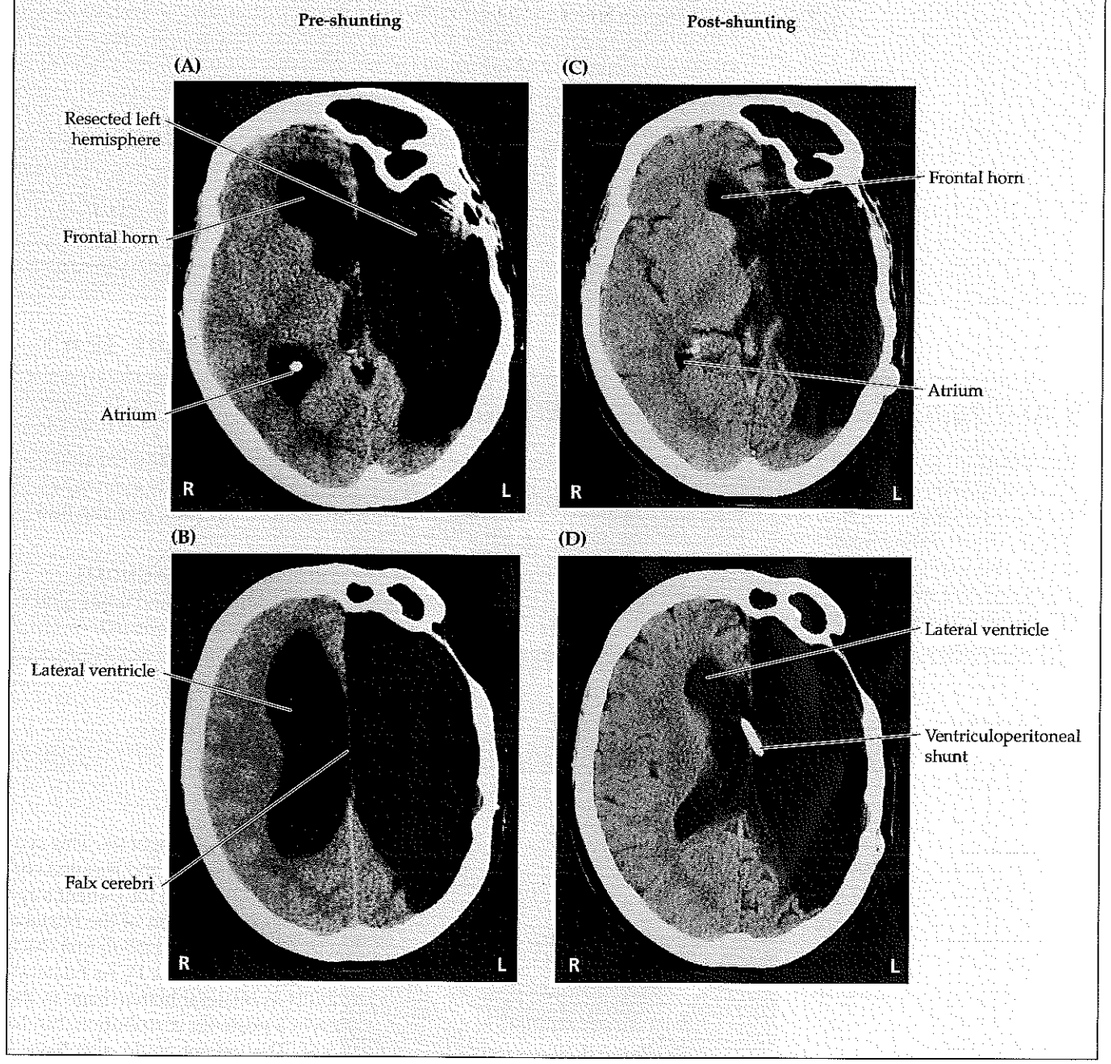

Figure 19.22 Head CT Scans from a Patient with Left Hemispherectomy and Hydrocephalus Axial CT scan images. (A, C) Before shunting. (B, D) After ventriculoperitoneal shunt placement. (From Kalkanis SN, Blumenfeld H, Sherman JC, Krebs DE, Irizarry MC, Parker SW, Cosgrove GR 1996. Delayed complications 36 years after hemispherectomy: a case report. *Epilepsia* 37(8): 758–762.)

CASE 19.7 RELATED CASES

Figure 19.25 Large Falcine Meningioma Compressing the Frontal Lobes
Axial T2-weighted MRI.

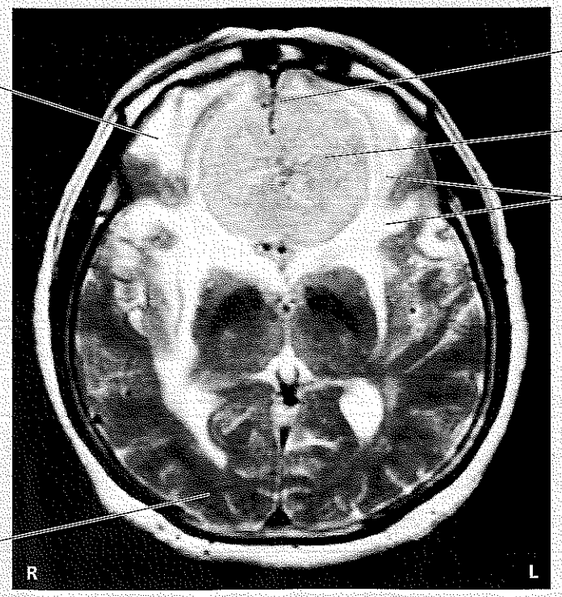

Figure 19.26 Written Alternating Sequencing Task
Patient was instructed to copy a pattern drawn by the examiner and continue it to the end of the page. Perseveration and "closing in" are evident in this patient with benzodiazepine toxicity. This is an example of apparently focal deficits that can be seen in patients with diffuse encephalopathy (see KCC 19.15).

CASE 19.8 BLINDNESS WITHOUT AWARENESS OF DEFICIT

Figure 19.27 Bilateral Infarcts of the Visual Cortex Axial CT scan images.
A, B progress from inferior to superior.

(A)

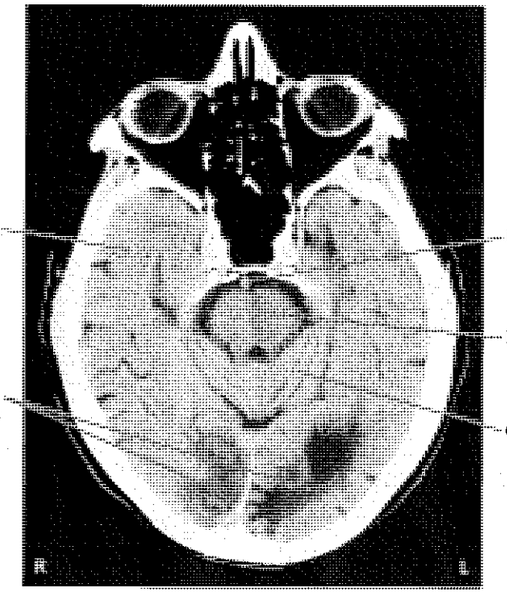

(B)

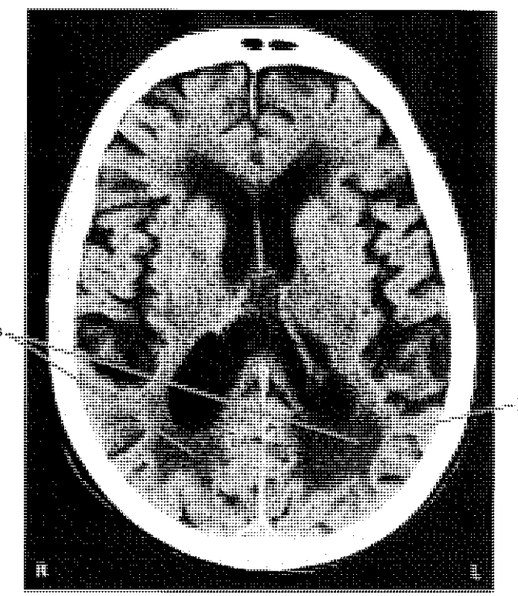

CASE 19.9 SUDDEN INABILITY TO RECOGNIZE FACES

MINICASE

A 78-year-old right-handed man with a history of atrial fibrillation treated with Coumadin anticoagulation came to the emergency room because of unusual visual disturbances. He had a history of a cerebral infarct 6 years previously, resulting in a left homonymous hemianopia, which subsequently improved. On the day prior to admission, while driving his car, he suddenly saw **"a translucent white curtain" obscuring the upper part of his vision** and making it hard to see traffic. He felt that his **motion perception was off** because he nearly hit a truck that was stopped in front of him. By the morning of admission, he no longer saw a curtain, but instead had the perception of **"shimmering glass balls or water drops" dotting the upper areas of his vision with both eyes.** He then encountered a close friend on the street, who began walking next to him, but his friend looked unfamiliar. "His facial features were moving all around his face. I couldn't put it together. I know this guy like I know my brother." The patient said to the friend, "Who are you?" and his friend answered, "What are you talking about? You've known me for years!" The patient then recognized him, but by his voice only.

On exam in the emergency room, the patient had normal mental status, including naming presidents back to Wilson and 3/3 memory at 5 minutes. He had normal visual fields, except for a **homonymous scotoma in the left inferior quadrant,** and he was able to see through the teardroplike distortion in his upper fields. In addition, he had **difficulty recognizing faces** in a magazine. For example, when shown a picture of George Bush, he said, "I think I should know him." When shown a picture of Bill Clinton, he said, "Get that thing away from me!" (the patient was a staunch Republican). He was able to name objects other than faces well. Reading and writing abilities were normal, and he did not have achromatopsia. The remainder of his exam was normal.

LOCALIZATION AND DIFFERENTIAL DIAGNOSIS

1. What is the name for disorders in which perception and language are normal but recognition is impaired? Given the findings shown in **boldface** above, what is the most likely localization for this patient's lesion(s)?
2. What is the most likely diagnosis?

Discussion

The key symptoms and signs are

- **Difficulty recognizing faces**
- **Visual obscuration of upper fields bilaterally**
- **Left inferior-quadrant scotoma**

1. Impaired recognition in the absence of defects in primary perception or in naming ability is called agnosia (see KCC 19.12). This patient demonstrates impaired ability to recognize faces, with preserved ability to see, recognize, and name other objects. This syndrome is known as prosopagnosia and is usually caused by bilateral lesions of the face recognition areas in the visual association cortex of the inferior occipitotemporal (fusiform) gyri (see Figure 19.13). Associated features can include upper visual field obscuration of the kind seen in this patient because of the proximity to the inferior calcarine regions (see Figure 11.15). This patient's left inferior-quadrant scotoma is most likely related to his prior history of a cerebral infarct 6 years earlier that had caused a left homonymous hemianopia at the time, which subsequently improved.
2. Given his history of atrial fibrillation and treatment with Coumadin, the most likely diagnoses are bilateral inferior occipitotemporal infarcts or hemorrhages.

Clinical Course and Neuroimaging 900

A **head CT** (Figure 19.28) demonstrated an old right occipital infarct, along with a recent infarct of the left inferior occipitotemporal (fusiform) gyrus. The patient was admitted and briefly treated with intravenous heparin, in addition to the Coumadin that he was already taking for atrial fibrillation. On admission, his anticoagulation INR (International Normalized Ratio) was in the therapeutic range. An MRA showed no significant stenoses. His ability to recognize faces improved markedly within 2 days of admission, and the visual distortion in his upper fields resolved more gradually. He was discharged home on Coumadin.

CASE 19.10 MUSICAL HALLUCINATIONS

MINICASE

A 21-year-old right-handed man from El Salvador was brought to the emergency room after having a seizure. Beginning 3 years previously, he had developed frequent brief episodes in which he heard music playing and voices. These episodes were often followed by a generalized convulsion. He was living in a rural area at the time, and the episodes stopped on their own after about 3 months without medical treatment. On the day of admission, while at work, the patient again suddenly **heard music playing and voices.** He then **felt dizzy, saw spots, and lost consciousness.** Witnesses reported that he had had a **generalized tonic-clonic seizure** lasting 2 to 3 minutes, followed by **post-ictal** lethargy and generalized headache, but **no clear language deficit.** He had a second identical episode upon arrival at the emergency room. Exam performed a few hours after the last seizure was entirely normal.

LOCALIZATION AND DIFFERENTIAL DIAGNOSIS

1. What anatomical structures could be involved sequentially during this patient's seizures to produce the sequence of reported ictal phenomena? Which side of the brain and what location were likely involved in seizure onset (see KCC 18.2)?
2. What are some possible causes of seizures in this patient?

Discussion

The key symptoms and signs in this case are:

- **Hearing music playing and voices**
- **Dizziness**
- **Seeing spots**
- **Loss of consciousness, and generalized convulsion**
- **No clear language deficit post-ictally**

1. Although auditory hallucinations can be caused by lesions in many possible locations along the auditory pathways (see KCC 19.13), only lesions in the cortex would be expected to produce seizures.* Therefore, this patient's seizures probably began in the auditory cortex or auditory association cortex; spread to the vestibular cortex of the parietal operculum, producing dizziness; then to parieto-occipital cortex, producing visual spots; and finally to the entire brain, producing generalized tonic-clonic activity (see KCC 18.2). Musical abilities depend more on the right hemisphere than on the left in most individuals who are not trained musicians (see Table 19.3), and musical hallucinations are more often seen with right rather than left temporal seizures (see KCC 19.13). In addition, left hemisphere seizures are often associated with post-ictal aphasia, which was not present in this patient. Therefore, the most likely site of seizure onset is the right superior temporal gyrus, in the vicinity of Heschl's gyri (primary auditory cortex) or auditory association cortex (see Figure 19.1).
2. The most common cause of nontraumatic early-adult-onset seizures in patients from Central America is CNS cysticercosis (see KCC 5.9; see also Figure 5.30). Other possibilities include other CNS infections, a low-grade brain tumor, or a cortical developmental abnormality.

*Certain rat strains exhibit seizures triggered by brainstem auditory pathways, but a similar condition has not been reported in humans.

Clinical Course and Neuroimaging 903

A **brain MRI** revealed an enhancing cyst near the right superior gyrus and Heschl's gyri (Figure 19.29). The patient underwent lumbar puncture and had blood serology sent to confirm the diagnosis of cysticercosis. He was treated with anticonvulsant medications and given a course of the antiparasitic agent praziquantel, together with a brief course of steroids to prevent swelling that can sometimes occur in response to treatment. He did well and was discharged home without further problems.

CASE 19.9 SUDDEN INABILITY TO RECOGNIZE FACES

Figure 19.28 Bilateral Inferior Occipitotemporal Infarcts Axial CT image.

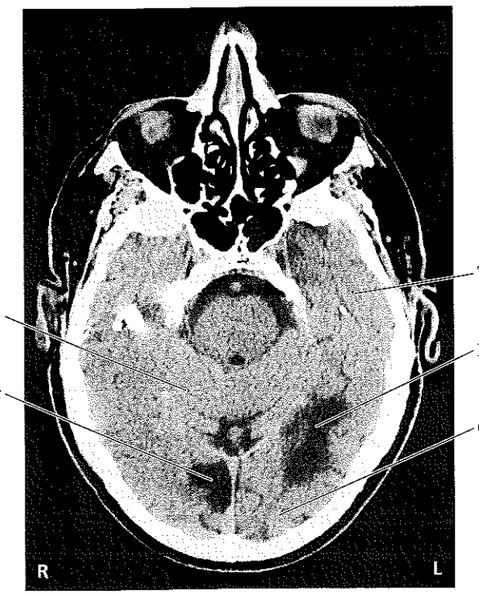

CASE 19.11 PROGRESSIVE DEMENTIA, BEGINNING WITH MEMORY PROBLEMS

CHIEF COMPLAINT

A 76-year-old right-handed woman was referred to a memory disorders clinic because of 4 years of worsening memory problems.

HISTORY

The patient had previously been in good health. Her **memory problems began when she retired as a secretary at age 72, and had progressed slowly ever since.** Her husband reported that she initially had difficulty making certain recipes at home, as well as trouble recalling things she had been told in recent days or weeks. She seemed to recall events from the distant past somewhat better. Her memory gradually grew worse, and she began losing her keys and her pocketbook. She often repeated questions that she had asked a few minutes before. She occasionally had **difficulty distinguishing the letter "O" from the number zero on the touch-tone phone.** Most recently, her husband had been concerned that if she were left four or five blocks from home, she **would get lost.** She also became **somewhat irritable and became angry over little things that would not have bothered her in the past.** For example, one morning she was very insistent on making her bed before going to church. She saw her physician, who ordered a head CT and routine blood tests, including thyroid function tests, VDRL (test for syphilis), B_{12} level, and erythrocyte sedimentation rate, all of which were normal.

PHYSICAL EXAMINATION

Vital signs: T = 98°F, BP = 140/82.
Neck: No bruits.
Lungs: Clear.
Heart: No murmurs.
Abdomen: Soft, nontender.
Extremities: No edema.
Neurologic exam:

MENTAL STATUS: Alert. Named five objects easily, and had no apraxia. No delusions or hallucinations. The **Blessed Dementia Scale (BDS) showed significant memory impairment** (see Table 19.16). She scored 3 on the left column and **11 on the right column, losing points mostly for questions on 5-minute recall, nonpersonal memory, and orientation. Her Activities of Daily Living (ADL) score was 22%.** (Higher scores on the BDS and ADL indicate more severe impairment.)

CRANIAL NERVES: Normal.

MOTOR: Normal tone. No pronator drift. Normal power.

REFLEXES: No grasp, root, suck, or snout reflexes.

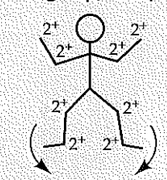

COORDINATION: Normal on finger-to-nose testing.

GAIT: Normal. Normal tandem gait and hopping on either foot. No Romberg sign.

SENSORY: Normal.

LOCALIZATION AND DIFFERENTIAL DIAGNOSIS

Dysfunction in what anatomical structures could explain the abnormalities shown in **boldface** above? What is the most likely diagnosis, and what are some other possibilities?

Discussion

The key symptoms and signs in this case are:

- **Slowly progressive memory impairment, worse for recent memories**
- **Difficulty distinguishing the letter "O" from zero on a touch-tone phone**
- **Tendency to get lost**
- **Irritability**

Impairment of recent memory can be caused by bilateral dysfunction of the medial temporal lobe or medial diencephalic memory systems (see KCC 18.1). This patient's geographic disorientation and her spatial disorientation with regard to O and zero on the telephone (or possibly reading difficulties) suggest possible parietotemporal dysfunction (see KCC 19.7, 19.10). Irritability and personality changes are nonspecific, but they can also be caused by dysfunction of limbic or association cortex. Overall, these findings and the slowly progressive time course fit both anatomically and clinically with early Alzheimer's disease

(see Figure 19.14; KCC 19.16). In a patient over the age of 65 with progressive deficits in recent memory, mild temporoparietal dysfunction, no motor abnormalities on neurologic exam, and normal basic blood tests and neuroimaging, as in this patient, Alzheimer's disease is by far the most likely diagnosis. Other possible causes of chronic mental status changes are listed in Tables 19.15.

Clinical Course

The patient had an MRI scan of the brain that was unremarkable except for mild atrophy. Follow-up in the months after her first visit was as follows:

- **7 months:** BDS left = 2.5, right = 11; ADL = 23%. The patient was still carrying out activities around the house, such as making the beds and doing the cooking, and she was doing volunteer work with her husband at a hospital.
- **11 months:** BDS right = 10; ADL = 36%. Still doing some volunteer work.
- **17 months:** BDS right = 16; ADL = 32%.
- **25 months:** BDS right = 15; ADL = 47%.
- **31 months:** BDS right = 21; ADL = 37%. No longer cooking. Could not be left home alone, and was enrolled in a day care program. No longer wanted to take regular baths, and instead took sponge baths. Neurologic exam and general health still normal, other than her dementia.
- **37 months:** BDS right = 25; ADL = 52%. Increased agitation, with daily episodes of inconsolable screaming and swearing at her husband.
- **43 months:** BDS right = 26; ADL = 59%. Needed assistance in getting dressed. Continued occasional agitation. Husband attending support groups.
- **47 months:** BDS right = 23; ADL = 60%. Having occasional hallucinations. For the first time, her tandem gait and hopping were mildly unsteady on exam. General health remained good, and she was on no medications.
- **52 months:** She became angry and aggressive with increasing frequency and was placed in a nursing home.
- **70 months:** The patient died at age 82, about 10 years after her first symptoms.

Pathology 904

The patient's family consented to a postmortem examination, which revealed typical changes of Alzheimer's disease, including cortical atrophy, neuronal loss, and plaques and tangles in a widespread distribution but most prominent in the medial temporal lobes. A typical amyloid plaque and intracytoplasmic neurofibrillary tangle seen on silver staining from the frontal polar cortex of this patient are shown in Figure 19.30.

Additional Cases

Related cases can be found in other chapters for the following topics: **acute mental status changes** (Cases 5.3, 5.10, 7.1, 14.8); **chronic mental status changes** (Cases 5.1, 5.9, 15.3, 16.2); **aphasia** (Cases 7.1, 10.5, 10.6, 10.8); **hemineglect** (Cases 5.1, 10.2, 10.11); and **limbic system disorders** (18.1–18.5). Other relevant cases can be found using the **Case Index**.

CASE 19.10 MUSICAL HALLUCINATIONS

Figure 19.29 Cysticercosis Lesion in the Right Superior Temporal Gyrus T1-weighted MRI. (A) Sagittal image. (B) Coronal image with intravenous gadolinium enhancement.

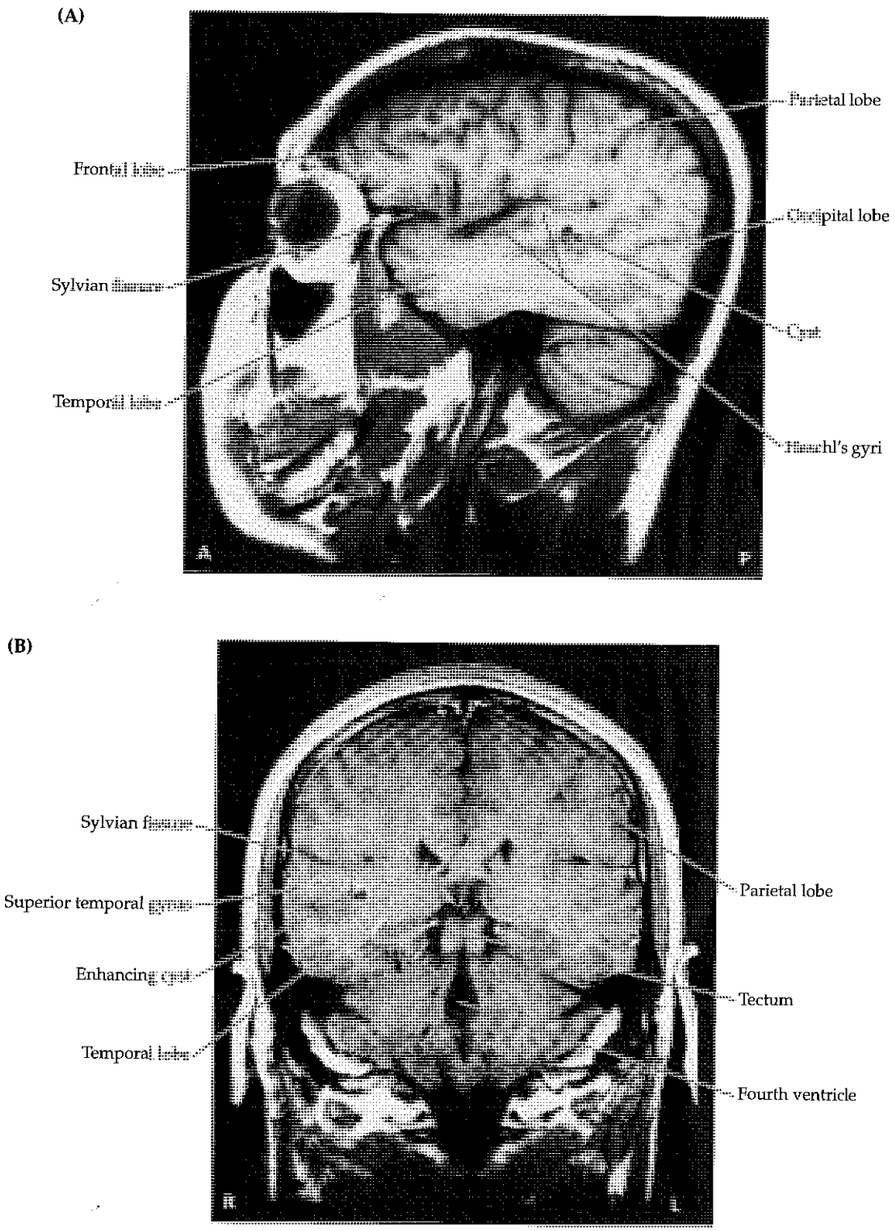

CASE 19.11 PROGRESSIVE DEMENTIA, BEGINNING WITH MEMORY PROBLEMS

Figure 19.30 Plaque and Tangles Pathology slide from the frontal cortex prepared with a silver stain demonstrating an amyloid plaque and neurofibrillary tangles typical of Alzheimer's disease.

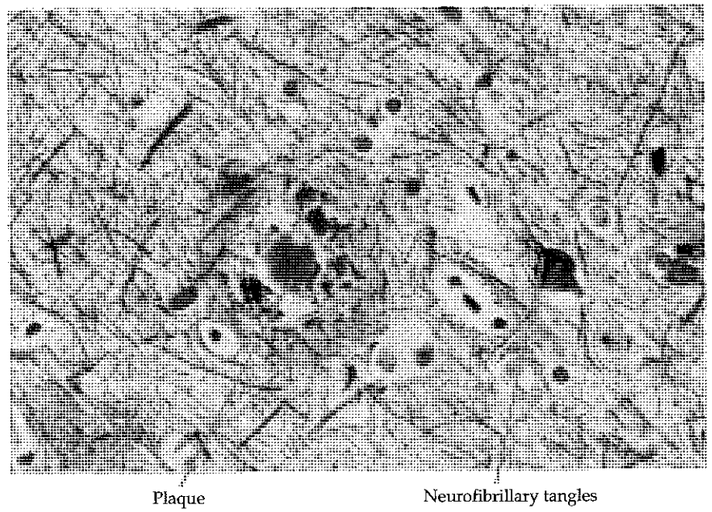

Brief Anatomical Study Guide

1. In this chapter we discussed networks involved in higher-order cognitive functions, emphasizing the cerebral cortex. A majority of the cerebral cortical surface is composed of association cortex. Association cortex can be divided into **unimodal (modality-specific) association cortex** and **heteromodal (higher-order) association cortex** (see Figure 19.1; Table 19.2).

2. Although most structures and sensorimotor functions are distributed symmetrically in the brain, there are also marked asymmetries in brain function. The **left hemisphere** is typically dominant for skilled motor functions (handedness) and language, and the **right hemisphere** plays a greater role in attentional mechanisms and spatial analysis (see Table 19.3). The **left hemisphere** is dominant for language in over 95% of right-handers, and in over 60 to 70% of left-handers. Language is mediated by a network centered on structures in the dominant (usually left) hemisphere, but extending to the right hemisphere as well (see Figure 19.2).

3. **Broca's area,** located in the frontal lobe adjacent to the speech articulatory motor cortex, is important in language formulation. **Wernicke's area,** located in the temporal lobe adjacent to the primary auditory cortex, is important in associating meaning with words. Both Broca's and Wernicke's areas function through interactions between the posterior and anterior language areas via the **arcuate fasciculus**

Brief Anatomical Study Guide *(continued)*

and other connections in the peri-Sylvian region (see Figure 19.2). A simplified classification scheme for language disorders, or **aphasias,** resulting from different lesions is summarized in Figure 19.4.

4. In Chapter 14 we described the activating systems of the brainstem pontomesencephalic region—the basal forebrain, thalamus, and cortex—essential for maintaining the normal awake state (see Figures 14.7, 14.8; Table 14.2). In this chapter we discussed mechanisms of attention, touching briefly on the more controversial topic of awareness. In discussing **networks mediating attention,** we reviewed the roles of widespread projection systems, frontal and parietal association cortex, anterior cingulate cortex and limbic pathways, tectal circuits, and other structures, such as the basal ganglia and cerebellum.

5. Although both hemispheres are involved, **the right hemisphere is more important for attentional mechanisms in most individuals** (see Figure 19.7). Lesions of the right hemisphere often cause prominent neglect of the contralateral side. In addition, the right hemishere, particularly the **right parietal region** is most important in **visual-spatial analysis.**

6. The **frontal lobes** are large in humans, constituting nearly one-third of the cerebral hemispheres. They have three surfaces: lateral, medial, and orbitofrontal (see Figure 19.11). In this chapter we focused on the frontal cortex lying anterior to the motor, premotor, and limbic areas, which is called the **prefrontal cortex** (see Figure 19.1) and consists of higher-order heteromodal association cortex. The prefrontal cortex has **cortical connections** with **heteromodal association cortex** (parietal, occipital, and temporal lobes), **motor association cortex** (frontal lobes), and **limbic cortex** (anterior cingulate and posteromedial orbitofrontal cortex). **Subcortical connections** include the **amygdala** (connected with the orbital and medial portions of the frontal lobes by the uncinate fasciculus; see Figure 18.4B,C), the **hippocampal formation** (via the cingulate gyrus and parahippocampal gyrus; see Figure 18.9), **thalamus** (mediodorsal nucleus, medial pulvinar, and intralaminar nuclei; see Figure 7.8), and the **basal ganglia** (mainly via the head of the caudate nucleus; see Table 16.2; Figure 16.8).

7. Frontal lobe functions are quite diverse and apparently contradictory at times (see Tables 19.8, 19.9). The frontal lobes are crucial for the sophisticated decisions we make, and for the subtle social interactions we continually engage in as normal humans. The functions of the frontal lobes can be classified as important for (1) **restraint,** or inhibition of inappropriate behaviors; (2) **initiative,** or motivation to pursue positive or productive activities; and (3) **order,** or the capacity to correctly perform sequencing tasks and a variety of other cognitive operations. As we discussed in Chapter 11, after arrival at the primary **visual cortex,** visual information is processed in two streams of association cortex (see Figure 19.12). The **dorsal pathways** project to parieto-occipital association cortex. These pathways answer the question **"Where?"** by analyzing motion, as well as spatial relationships between objects and between the body and visual

Brief Anatomical Study Guide *(continued)*

stimuli. The **ventral pathways** project to occipitotemporal association cortex. These pathways answer the question **"What?"** by analyzing form, with specific regions identifying colors, faces, letters, and other visual stimuli (see Figure 19.13). The functions of these two streams of higher-order visual information processing are well illustrated by clinical syndromes of the dorsal and ventral visual association pathways (see KCC 19.12).

6. We concluded this chapter with a discussion of dementia because it demonstrates the functional importance of multiple neuroanatomical systems (see Figure 19.14; KCC 19.16), and because discovering new treatments for dementia and other presently incurable neurologic disorders may lie just over the horizon if we continue through study and investigation to increase our understanding of the brain.

References

General Reviews of Aphasia

Benson DF, Geschwind N. 1985. Aphasia and related disorders: A clinical approach. In Mesulam MM (ed.), *Principles of Behavioral Neurology*. FA Davis, Philadelphia.

Critchley M. 1964. The Broca-Dax controversy. *Rev Neurol (Paris)* 110: 73.

Damasio AR. 1992. Aphasia. *N Engl J Med* 326(8): 531–539.

Kirshner HS. 1996. Aphasia. In Bradley WG, Bharucha NE, Cohen ME, Evans OB (eds.), *Neurology in Clinical Practice*, 2nd Ed., Butterworth-Heinemann, Boston.

Rhawn J. 1990. *Neuropsychology, Neuropsychiatry, and Behavioral Neurology*. Plenum, New York.

Broca's Aphasia

Alexander MP, Naesser MA, Palumbo C. 1990. Broca's area aphasia: Aphasia after lesions including the frontal operculum. *Neurology* 40(2): 353–362.

Transcortical Aphasia

Freedman M, Alexander MP, Naeser MA. 1984. Anatomic basis of transcortical motor aphasia. *Neurology* 34(4): 409–417.

Grossi D, Trojano L, Chiacchio L, Soricelli A, Mansi L, Postiglione A, Salvatore M. 1991. Mixed transcortical aphasia: Clinical features and neuroanatomical correlates. *Eur Neurol* 31(4): 204–211.

Global Aphasia

Tranel D, Biller J, Damasio H, Adams HP, Cornell SH. 1987. Global aphasia without hemiparesis. *Arch Neurol* 44(3): 304–308.

Conduction Aphasia

Damasio H, Damasio AR. 1980. The anatomical basis of conduction aphasia. *Brain* 103(2): 337–350.

Kempler D, Metter EJ, Jackson CA, Hanson WR, Riege WH, Mazziotta JC, Phelps ME. 1998. Disconnection and cerebral metabolism. *Arch Neurol* 45(3): 275–279.

Tanabe H, Sawada T, Inoue N, Ogawa M, Kuriyama Y, Shiraishi J. 1987. Conduction aphasia and arcuate fasciculus. *Acta Neurol Scand* 76(6): 422–427.

Subcortical Aphasia

Crosson B, Parker JC, Kim AK, Warren RL, Kepes JJ, Tully R. 1986. A case of thalamic aphasia with postmortem verification. *Brain Lang* 29(2): 301–314.

Mega MS, Alexander MP. 1994. Subcortical aphasia: The core profile of capsulostriatal infarction. *Neurology* 44(10): 1824–1829.

Okuda B, Tanaka H, Tachibana H, Kawabata K, Sugita M. 1994. Cerebral blood flow in subcortical aphasia: Perisylvian cortical hypoperfusion as a crucial role. *Stroke* 25(7): 1495–1499.

Gerstmann's Syndrome

Benton AL. 1992. Gerstmann's syndrome. *Arch Neurol* 49(5): 445–447.

Pearce JMS. 1996. Gerstmann's syndrome. *J Neurol Neurosurg Psychiatry* 61(1): 56.

Alexia without Agraphia

Quint DJ, Gilmore JL. 1992. Alexia without agraphia. *Neuroradiology* 34(3): 210–214.

Aphasia and Apraxia

Benson DF, Geschwind N. 1985. Aphasia and related disorders: A clinical approach. In Mesulam MM (ed.), *Principles of Behavioral Neurology*. FA Davis, Philadelphia.

Damasio AR. 1992. Aphasia. *N Engl J Med* 326(8): 531–539.

Damasio AR, Damasio H. 1992. Brain and language. *Sci Am* 267(3): 89–95.

Gibbons A. 1991. Deja vu all over again: Chimp-language wars. *Science* 251(5001): 1561–1562.

Callosal Disconnection Syndromes

Bogen, JE. 1993. The callosal syndromes. In Heilman KM, Valenstein E (eds.), *Clinical Neuropsychology*, 3rd Ed., Chapter 11. Oxford University Press, New York.

Brain Arousal Systems

Heilman KM, Watson RT, Valenstein E. 1993. Mechanisms underlying attention. In Heilman KM, Valenstein E (eds.), *Clinical Neuropsychology*, 3rd Ed., Chapter 10. Oxford University Press.

Mesulam MM. 1985. Biology of the attentional matrix. In Mesulam MM (ed.), *Principles of Behavioral Neurology*. FA Davis, Philadelphia.

Right Parietal Lobe and Attention Mechanisms

Heilman KH, Watson RT, Valenstein E. 1993. Neglect and related disorders. In Heilman KH, Valenstein E (eds.), *Clinical Neuropsychology*, 3rd Ed., Chapter 10. Oxford University Press, New York.

Hier DB, Mondlock J, Caplan LR. 1983. Behavorial abnormalities after right hemisphere stroke. *Neurology* 33(3): 337–344.

Mesulam MM. 1985. Attention, confusional states, and neglect. In Mesulam MM (ed.), *Principles of Behavioral Neurology*. FA Davis, Philadelphia.

Binding: Oscillations versus Connections

Kinomura S, Larsson J, Gulyas B, Roland PE. 1996. Activation by attention of the human reticular formation and thalamic intralaminar nuclei. *Science* 271(5248): 512–515.

Neuenschwander S, Singer W. 1996. Long-range synchronization of oscillatory light responses in the cat retina and lateral geniculate nucleus. *Nature* 379(6567): 728–733.

Steriade M, Curro Dossi R, Contreras D. 1993. Electrophysiological properties of intralaminar thalamocortical cells discharging rhythmic (~40 Hz) spike-bursts at ~1000 Hz during waking and rapid eye movement sleep. *Neuroscience* 56(1): 1–9.

Stewart I. 1991. All together now. *Nature* 350: 557.

Musical Hallucinations

Berrios GE. 1991. Muscial hallucinations: A statistical analysis of 46 cases. *Psychopathology* 24(6): 356–360.

Gordon AG. 1994. Musical hallucinations. *Neurology* 44(5): 986–987.

Murata S, Naritomi H, Sawada T. 1994. Musical auditory hallucinations caused by brainstem lesion. *Neurology* 44(1): 156–158.

Frontal Lobes

Bechara A, Damasio AR, Damasio H, Anderson SW. 1994. Insensitivity to future consequences following damage to human prefrontal cortex. *Cognition* 50(1–3): 7–15.

Bogousslavsky J. 1994. Frontal stroke syndromes. *Eur Neurol* 34(6): 206–215.

Damasio AR. 1994. Unpleasantness in Vermont—Phineas P. Gage. In *Descartes' Error: Emotion, Reason, and the Human Brain*, Part 1. GP Putnam, New York.

Damasio AR, Anderson SW. 1993. The frontal lobes. In Heilman KM, Valenstein E (eds.), *Clinical Neuropsychology*, 3rd Ed., Chapter 12. Oxford University Press, New York.

Desimone R. 1995. News and views: Is dopamine a missing link? *Nature* 376(6541): 549–550.

Goldman-Rakic PS. 1992. Working memory and the mind. *Sci Am* 267(3): 110–7.

Jonides J, Smith EE, Koeppe RA, Awh E, Minoshima S, Mintun MA. 1993. Spatial working memory in humans as revealed by PET. *Nature* 363(6430): 623–625.

Lhermitte F. 1983. Utilization behavior and its relation to lesions of the frontal lobes. *Brain* 106(Pt 2): 237–255.

Mattson AJ, Levin HS. 1990. Frontal lobe dysfunction following closed head injury. A review of the literature. *J Nerv Ment Dis* 178(5): 282–291.

Mesulam MM. 2001. *Principles of Behavioral Neurology*, 2nd Ed. FA Davis, Philadelphia.

Raichle ME. 1993. News and views: The scratchpad of the mind. *Nature* 363(6430): 583–584.

Rhawn, J. 1990. *Neuropsychology, Neuropsychiatry, and Behavioral Neurology*. Plenum, New York.

Trimble MR. 1990. Psychopathology of frontal lobe syndromes. *Sem Neurol* 10(3): 287–294.

Williams GV, Goldman-Rakic PS. 1995. Modulation of memory fields by dopamine D1 receptors in prefrontal cortex. *Nature* 376(6541): 572–575.

Working Memory

Desimone R. 1995. News and views: Is dopamine a missing link? *Nature* 376(6541): 549–50.

Goldman-Rakic PS. 1992. Working memory and the mind. *Sci Am* 267(3): 110–117.

Jonides J, Smith EE, Koeppe RA, Awh E, Minoshima S, Mintun MA. 1993. Spatial working memory in humans as revealed by PET. *Nature* 363(6430): 623–625.

Raichle ME. 1993. News and views: The scratchpad of the mind. *Nature* 363(6430): 583–584.

Williams GV, Goldman-Rakic PS. 1995. Modulation of memory fields by dopamine D1 receptors in prefrontal cortex. *Nature* 376(6541): 572–575.

Mental Imagery and Blindsight

Cowey A. 1991. News & views: Grasping the essentials. *Nature* 349(6305): 102–103.

Georgopoulos AP, Lurito JT, Petrides M, Schwartz AB, Massey JT. 1989. Mental rotation of the neuronal population vector. *Science* 243(4888): 234–236.

Goodale MA, Milner AD, Jakobson LS, Carey DP. 1991. A neurological dissociation between perceiving objects and grasping them. *Nature* 349(6305): 154–156.

Kosslyn SM, Thompson WL, Kim IJ, Alpert NM. 1995. Topographical representations of mental images in primary visual cortex. *Nature* 378(6556): 496–498.

Marshall JC, Halligan PW. 1988. Blindsight and insight in visuo-spatial neglect. *Nature* 336(6201): 766–767.

Parsons LM, Fox PT, Hunter Downs J, Glass T, Hirsch TB, Martin CC, Jerabek PA, Lancaster JL. 1995. Use of implicit motor imagery for visual shape discrimination as revealed by PET. *Nature* 375(6526): 54–58.

Visual Hallucinations and Related Phenomena

Newman NM. 1992. *Neuro-ophthalmology: A practical text*. Appleton & Lange, Norwalk, CT.

Occipital Seizures

Engel J. 1989. *Seizures and Epilepsy*. FA Davis, Philadelphia.

Syndromes of Visual Association Cortex

Adams RD, Victor M, Ropper AH. 1997. *Principles of Neurology*, 6th Ed. McGraw-Hill, New York.

Ashworth B, Isherwood I. 1981. Cortical disturbances of vision. In *Clinical Neuro-ophthalmology*, 2nd Ed., Oxford, Boston.

Bauer RM. 1993. Agnosia. In Heilman KM, Valenstein E (eds.), *Clinical Neuropsychology*, Chapter 9. Oxford University Press, New York.

Bornstein B, Kidron DP. 1959. Prosopagnosia. *J Neuro Neurosurg Psychiatry* 22: 124.

Damasio AR. 1985. Disorders of complex visual processing: Agnosias, achromatopsia, Balint's syndrome, and related difficulties of orientation and construction. In Mesulam MM (ed.), *Principles of Behavioral Neurology*, FA Davis, Philadelphia.

Damasio AR, Damasio H, Van Hoesen GW. 1982. Prosopagnosia: Anatomic basis and behavorial mechanisms. *Neurology* 32(4): 331–341. Hecaen H, Angelergues R. 1962. Agnosia for faces (prosopagnosia). *Arch Neurol* 7: 24. Miller NR. 1985. *Clinical Neuro-Ophthalmology*, Vol. 2, Williams & Wilkins, Baltimore, MD.

Zeki S. 1990. A century of cerebral achromatopsia. *Brain* 113(Pt 6): 1721–1777.

Functions of Human Inferior Occipitotemporal Cortex

Allison T, McCarthy G, Nobre A, Puce A, Belger A. 1994. Human extrastriate visual cortex and the perception of faces, words, numbers, and colors. *Cerebral Cortex* 4(5): 544–554.

Lueck CJ, Zeki S, Friston KJ, Cope P, Cunningham VJ, Lamertsma AA, Kennard C, Frackowiak RSJ. 1989. The colour centre in cerebral cortex of man. *Nature* 340(6232): 386–389.

Puce A, Allison T, Asgari M, Gore JC, McCarthy G. 1996. Differential sensitivity of human visual cortex to faces, letterstrings, and textures: A functional magnetic resonance imaging study. *J Neurosci* 16(16): 5205–5215.

Basal Forebrain and Dementia

Barinaga M. 1995. Research news: New Alzheimer's gene found. *Science* 268(5219): 1845–1846.

Fibiger HC. 1991. Cholinergic mechanisms in learning, memory and dementia: A review of recent evidence. *Trends Neurosci* 14(6): 220–223.

Huerta PT, Lisman JE. 1993. Heightened synaptic plasticity of hippocampal CA1 neurons during a cholinergically induced rhythmic state. *Nature* 364(6439): 723–725.

Marx J. 1990. Research news: Alzheimer's pathology explored. *Science* 249(4972): 984–986.

Rossor M. 1991. Primary degenerative dementia. In Bradley WG, Daroff RB, Fenichel GM, Marsden CD (eds.), *Neurology in Clinical Practice*, 1st Ed., Butterworth-Heinemann, Boston.

Epilogue

A Simple Working Model of the Mind

Where is the mind, and what is the mind? These questions have taunted scientists and philosophers throughout human history. Although we cannot yet answer these questions with certainty, investigation of the nervous system allows at least tentative conjectures in this realm.

Basic Assumptions

Although some would argue otherwise, the burden of evidence currently available suggests that the mind is manifested through ordinary physical processes located within the body. Note that these first two fundamental conjectures about where the mind is (in the body) and what the mind is (normal physical processes) remain hypotheses, perhaps with growing evidence in their favor, yet remaining unproven nonetheless. Within the body, one can conjecture further, the mind appears to be manifested in the nervous system. Interactions with the rest of the body and with the external environment are clearly important, yet most evidence suggests that the main functions of the mind are carried out within the nervous system. Finally, there appears to be a gradation in the importance of different parts of the nervous system in what we consider to be the mind. For example, although the peripheral nervous system and spinal cord play a significant role in channeling (and even in modulating) inputs and outputs to the remainder of the nervous system, the brain is likely more important to the mind. It should be emphasized, however, that there is no sharp division between "mind" and "nonmind" parts of the nervous system. A gradient of relative importance to mind may exist within the nervous system, yet reciprocal interactions ensure that the tapering of the gradient extends to all parts and possibly even to structures outside the nervous system.

We will now briefly summarize some of the abundant evidence supporting these conjectures before moving on to a more specific model of the mind. As for the location and nature of the mind, we know that physical injuries to the brain cause changes in mind function. Furthermore, changes in mind function vary from mild disturbances in cognition, to profound abnormalities in thought, to brain death, and they are related to both the anatomical sites involved and the mechanisms of the injury. We have seen numerous examples of this kind in the patients discussed throughout this book, and an overwhelming number of other examples exist in the literature.

In addition to negative effects of lesions, positive evidence for the participation of specific regions of the nervous system in mind functions comes from a multitude of studies employing electrophysiological recordings, functional neuroimaging, brain stimulation, and other methods. Lesion studies and recordings of neural function come not just from humans, but from other animals as well. In this regard, another line of evidence supporting the dependence of mind on brain comes from the parallel evolutionary trends in the complexity of brain and mind. However, despite these and a mountain of other studies, some lingering doubts remain as to

whether the mind is truly an ordinary physical process manifested within the nervous system.

Summary and Model of Mind Functions

Perhaps the reason for these lingering doubts is that many processes of the mind, particularly certain aspects of consciousness and emotions, remain difficult to explain fully in neurophysiological terms. Plausible and testable hypotheses for the relationship between brain activity and conscious thought are still under development. However, as understanding of the brain increases, functions of the mind once thought beyond the ken of scientific investigation come more and more firmly into the arena of neuroscience. Examples include memory, language, planning, and attention, to name a few. With continued investigation, my opinion is that consciousness will eventually migrate as well into the domain of accepted neurophysiological phenomena. In the interim, and as a conclusion to this neuroanatomy text, it may be useful to consider an overall framework for summarizing the functions of the nervous system and the mind, encompassing both those mechanisms that are relatively well understood and those still under intense investigation.

The first task in this summary is to discuss inputs and outputs (see figure). In the earlier chapters of this book, we discussed numerous sensory and motor systems. Different sensory inputs include vision, somatic sensation, hearing, smell, taste, and vestibular sense, as well as various chemical, mechanical, and other signals arising from the body's internal milieu. Similarly, numerous different effector pathways leave the nervous system, including motor outputs to skeletal muscle, autonomic outputs to smooth muscle and glands, and neuroendocrine outputs. These sensory and motor pathways are organized in multiple parallel channels entering and leaving the nervous system and subserving different sensory and motor functions.

Information processing in sensory and motor systems is hierarchically organized (see figure). For example, primary somatosensory information is processed at the most rudimentary level by the receptor cell and primary somatosensory neuron entering the spinal cord. This information is refined further and integrated with inputs and influences from other neurons at successively higher-order levels of processing in the nervous system, including the brainstem, thalamus, primary somatosensory cortex, unimodal association cortex, and heteromodal association cortex. In motor systems, similar hierarchical processing occurs, but in reverse. For example, higher-order signals for motor planning that arise from heteromodal association cortex are conveyed to successively lower levels of processing in premotor cortex, primary motor cortex, and lower motor neurons in the spinal cord before traveling to the periphery.

Information flow in the hierarchically organized sensory and motor pathways is not strictly linear, however. Direct connections exist between sensory and motor systems beginning at the spinal cord and continuing throughout successively higher levels of processing. In addition, from the spinal cord and upward, chains of interneurons of varying complexity further process sensory and motor information at various levels and carry information between these systems. Numerous feed-forward and feedback loops occur between higher-level and lower-level sensory and motor systems, involving both local and long-range network interactions. The integrated action of these hierarchically organized sensory and motor systems is capable of fantastic feats of information processing, including visual recognition of abstract shapes, programming of complex motor tasks in response to the environment, understanding and formulation of written and spoken language, and even generation of sensory–motor mental images.

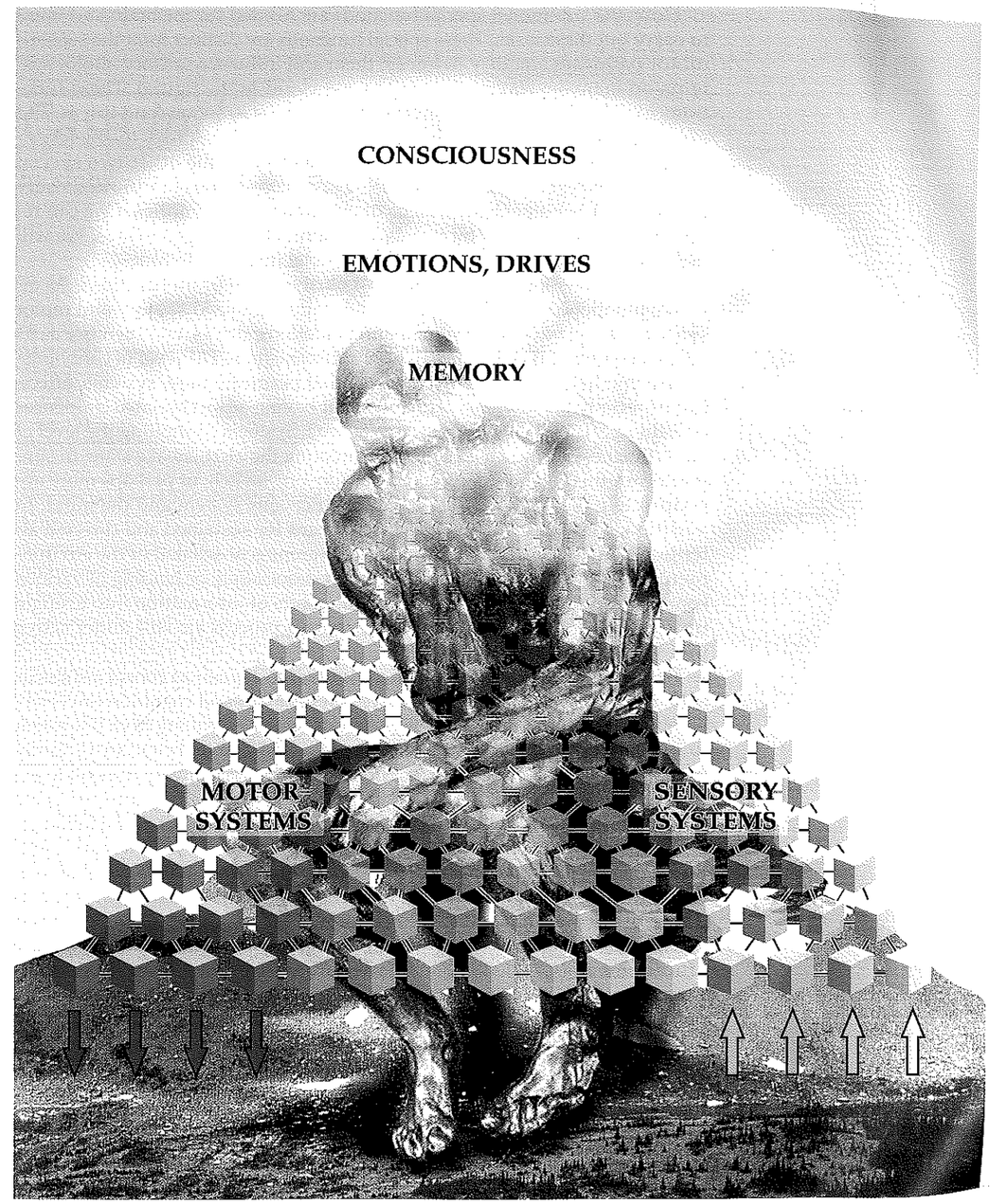

A Working Model of the Mind
Parallel interconnected and hierarchically organized sensory and motor systems receive inputs, generate outputs, and perform internal processing on multiple levels, from relatively simple to highly abstract. Three additional special functions—consciousness, emotions and drives, and memory—act on these systems in a widely distributed manner, especially at the highest levels of processing.

However, additional special functions are needed for the brain and mind to carry out these tasks. These special functions are distinct from the sensorimotor pathways, yet they permeate them and influence sensory–motor systems on many levels (represented by the cloud in the figure). These functions include neural mechanisms of consciousness, emotions and drives, and memory (see the figure). Each of these three functions utilizes the hierarchically organized sensory–motor systems, as well as the other two special functions, as substrate. For example, one can be conscious of various sensory and motor phenomena, as well as of emotions and memories. One can remember sensory and motor events, emotions, and being conscious. We will now briefly discuss each of these three special functions in turn.

Consciousness is perhaps the most elusive of all brain functions. As already mentioned, it utilizes the hierarchically organized sensory and motor systems, along with systems mediating emotions, drives, and memory as its substrate, giving rise to the content of consciousness. The level of consciousness is mediated by brain mechanisms that permeate these systems, affecting especially the forebrain structures, but having arousal-related influences on other parts of the nervous system as well. Systems controlling the level of consciousness include mechanisms promoting the alert, awake state. In simple terms, this could be considered the "on–off" switch, or perhaps more appropriately the "dimmer" switch, of the nervous system and the mind. In addition, consciousness involves mechanisms for sustained and directed attention. Finally, consciousness involves awareness of self and of the environment. This awareness requires integration, association, or binding of various sensory, motor, mnemonic, and emotional bits of information into a single unified percept, and the mechanisms for this process are still under active investigation.

Emotions and drives are almost as difficult to explain as consciousness itself. The effects of emotions and drives on behavior and cognition can easily be observed, and so-called limbic system structures extending from brainstem to diencephalon, to basal ganglia, amygdala, and limbic cortex, are certainly involved. Yet the experience of emotions and drives is still very difficult to explain in neuroscientific terms, and it may need to await a more complete mechanistic understanding of conscious awareness for its full illumination.

Memory, defined most broadly as a change in behavior of a system resulting from its past experience, affects the function of the entire nervous system—indeed, of the whole body. Within the nervous system, abundant evidence has demonstrated that memory occurs as a result of physiological and anatomical changes influencing communication between neurons. A specific kind of memory, called explicit or declarative memory, involves the conscious recollection of experiences. Persistence of explicit memories for more than a few minutes depends on normal functioning of the medial temporal lobes and medial diencephalon. This dependence suggests a critical role for these structures in conscious memory and may provide further clues to understanding the mechanisms of consciousness.

It seems plausible that the mind arises from the integrated actions of all the components we have just discussed. Thus, the mind involves many parallel pathways of sensory–motor information processing occurring on both a conscious and an unconscious level, invoking memories, motivated by drives, and modulated by emotions. The figure provides a framework and summary of the integrated actions of these systems. By continuing to investigate the nervous system, perhaps someday soon we can fill in some of the gaps in our understanding and reach a more complete picture of the relationship between brain activity and conscious and unconscious thought.

Case Index

by signs, symptoms, and diagnoses

A

Abducens nerve palsy, 13.2, 13.5
Abrasions
  arm, 9.3, 10.2
  leg, 10.2
Abulia, 19.7
ACA–MCA watershed infarction, 10.12
Achilles tendon reflex, absent, 8.8, 9.8
Acne, 17.1
Acoustic neuroma, 12.5
Adduction, eye
  limited, 13.1, 13.4
  unilaterally absent, 13.8
Afferent pupillary defect, 11.2
Agitation, 5.2, 5.3, 5.7
Agnosia, 19.9
Agraphesthesia, unilateral, 7.1
Agraphia, 19.1. *see also* Writing, impaired
Alexia, 19.1
  without agraphia, 19.5
Alien hand syndrome, 10.2
Altered mental status, 5.2, 5.3, 5.4, 5.5, 6.1, 10.13, 14.6, 19.11. *see also* Awareness; Confusion; Consciousness, loss of
Alzheimer's disease, 19.11
Amenorrhea, 17.1
Amnesia, 5.2, 19.4. *see also* Memory loss
  anterograde, 18.1, 18.2, 18.3
  retrograde, 18.2
  transient, 18.1
Amyotrophic lateral sclerosis (ALS), 6.6
Anal sphincter, 7.4
Anal wink, absent, 8.11
Aneurysm
  AComm, 10.1
  PComm, 13.1
Anger, 19.6, 19.11
Anhidrosis, 13.6
Anomia, 19.1
Anorexia, 17.2
Anosognosia, 10.2, 10.10, 10.11, 19.6
Anosmia, bilateral, 12.1, 18.2
Anterior cerebral artery (ACA) infarct, 10.2
Anterior communicating artery (AComm) aneurysm, 10.1
Anterior inferior cerebellar artery (AICA) infarct, 14.4
Anton's syndrome, 19.8. *see also* Writing, impaired; Alexia
Aphasia, 10.4, 19.2
  Broca's, 10.5, 19.1
  conduction, 19.4
  fluent, 10.6
  global, 10.8
  mild, 7.1
  nonfluent, 10.5, 19.1
  severe, 19.1
  transcortical motor, 19.3
  Wernicke's, 10.6, 19.2
Arrythmia, cardiac, 6.1. *see also* Atrial fibrillation
Arteriovenous malformations (AVM), 11.5
Astereognosis, unilateral, 7.1
Ataxia, 14.1, 14.4
  appendicular, 15.3
  arm, 15.4
  bilateral, 14.8
  finger-to-nose test, 15.4
  heel-to-shin test, 15.4
  leg, 15.4
  mild, 14.7
  sudden onset, 15.1
  truncal, 15.2, 15.3
  unilateral, 14.7
Atherosclerotic disease, 10.3, 10.12
Atrial fibrillation, 6.1, 10.9, 13.7, 14.7
Atrophy
  caudate head, 16.2
  foot muscles, 6.6
  hand muscles, 6.6
  putamen, 16.2
  tongue, 12.7
Attention, decreased, 14.4, 14.8
Auras, 11.4, 18.5
Awareness
  impaired, 14.5, 19.2, 19.6, 19.8
  loss of, 18.4, 18.5

B

Babinski's sign, 5.1, 5.3, 5.6, 6.4, 6.5, 6.6, 7.4, 10.2, 10.6, 10.7, 10.8, 10.11, 10.12, 10.13, 13.7, 14.2, 14.3, 14.5, 14.6, 19.4, 19.7
Back injury, 7.3
Back pain, thoracic, 7.4
Balance, impaired, 6.6, 15.1
Basal cistern effacement, 5.2
Basilar artery, 14.6
  calcification, 13.7
  insufficiency, 14.4
  stenosis, 14.5
  thrombosis, 14.6
Basilar scrape syndrome, 14.1
Basis pontis infarct, 14.3
Bell's palsy, 12.4
Benedikt's syndrome, 14.7
Biceps reflexes, absent, 8.1, 8.4, 9.2
Bielschowsky three step test, 538
Bilateral leg flaccid paralysis, 7.3
Bitemporal hemianopia, 11.3
Blindness, 19.8
Blink to threat
  absent, 19.8
  impaired, 14.8, 19.6
  unilateral, 10.6, 10.8, 10.10, 10.11
Blisters, arm, 8.4
Bone conduction decreased, 12.5
Bowel function
  depressed, 7.4
  impaired, 7.7, 8.11
Brachial plexus
  neoplasm, 9.1
  upper trunk injury, 9.2
Brachioradialis reflexes absent, 8.1, 8.4
Bradykinesia, 16.3, 16.4
Broca's aphasia, 10.5
Bulbocavernosus reflex, absent, 7.3, 8.11

C

Carotid artery
  bruit, 10.4, 10.12, 11.1
  dissection, 13.6, 13.16
  occlusion, 10.10
Carpal tunnel syndrome, 9.4
Cauda equina syndrome, 8.11
Caudate head atrophy, 16.2
Cavernous angioma, 14.9
Cerebellar hemisphere astrocytoma, 15.3
Cerebellar peduncle metastasis, 15.4
Cerebral vessel stenoses, 10.3
Ciliospinal reflex decreased, 13.6
Cingulate gyrus displacement, 5.3, 5.4
Clonus, right ankle, 19.7
Cognitive impairment, 5.9
Coma, 5.1, 5.2, 5.4, 5.5, 5.6. *see also* Awareness; Consciousness; Unresponsiveness
Combativeness, 5.2
Common peroneal nerve injury, 9.9
Comprehension, impaired, 19.1, 19.2
Concentration, difficulty, 15.3
Concussion, 18.1
Confabulation, 18.2
Confusion, 5.2, 5.10, 7.1, 12.3, 19.4
Consciousness. *see also* Altered mental status; Awareness, loss of; Coma; Unresponsiveness
  impaired, 5.2
  loss of, 5.3, 5.4, 5.5, 6.1, 10.10, 12.3, 13.7, 14.5, 19.4, 19.10
Constipation, 8.11
Contusions
  frontal lobe, 5.2
  temporal lobe, 5.2
Convergence–retraction nystagmus, 13.9
Coordination, deteriorating, 15.4. *see also* Ataxia
Corneal reflexes
  absent, 5.6
  decreased, 10.8, 12.5
  decreased unilaterally, 14.1, 14.4
  unilateral, 5.2
Cortical sensory loss, 7.1
Cortisol
  high, 17.1
  low, 17.2
Coup contrecoup injury, 5.2
Cramping, 6.6
Cushing's syndrome, 17.1
Cysticercosis, 5.7, 19.10
Cysts, 5.8, 15.3
  colloid, 5.8

D

Delirium, 14.8
Dementia, progressive, 19.11
Demyelination, 6.4
Depression, 17.1
Dexterity, decreased, 7.6
Diabetic neuropathy, 9.7, 13.3
Diplopia, 13.1, 14.7, 14.8. *see also* Eye movements
  diagonal, 14.4
  episodic, 14.4
  horizontal, 5.7, 13.2, 13.4, 13.5, 13.8, 18.3
  vertical, 13.3
Disc herniation. *see also* Radiculopathy
  C5–C6, 8.1
  C6–C7, 8.5
  C7–T1, 8.6
  L4–L5, 8.9, 8.10
  L5–S1, 8.8, 8.11
Discriminative sensation, decreased, 8.1
Dissection
  carotid arteries, 13.6, 13.16
  vertebral arteries, 14.1
Dizziness, 12.5, 14.1, 19.10
Downgaze, impaired, 13.1, 13.3, 15.3
Dysarthria, 6.3, 6.4, 6.5, 9.11, 10.2, 10.7, 10.9, 12.8, 14.3, 14.6, 16.4, 18.3, 19.1. *see also* Speech
Dysdiadochokinesia, 15.1
Dyskinesia, 16.3
Dysmetria
  finger-to-nose tests, 14.4, 15.1
  hands, 7.6
  heel-to-shin test, 15.1
Dysnomia, 19.1, 19.2, 19.3, 19.5
Dysphagia, 12.7, 12.8
Dysrhythmia, 14.1

E

Ecchymoses, 17.1
Edema, cerebral, 5.2
Emesis, 5.3
Emotional incontinence, 12.8
Empty delta sign, 10.13
End gaze
  on abduction, 13.8
  nystagmus on abduction, 13.8
Erb–Duchenne palsy, 9.2
Erythema
  orbital conjunctiva, 13.4
Exercise tolerance decreased, 9.11
Extinction
  tactile, 5.1, 10.2, 10.9, 10.10, 10.13, 19.6
  unilateral, 7.1
  visual, 5.1, 10.9, 10.13
Extraocular movements
  incomplete abduction, 5.7
  unilaterally absent, 13.5
Eye movements. *see also* Gaze; Nystagmus; Diplopia
  abduction incomplete, 13.2, 13.4
  absent, 5.5
  absent horizontally, 14.5
  lazy eye, 14.5
  ocular bobbing, 14.5
  oculomotor nerve palsy, 13.1
  one-and-a half syndrome, 13.8
  ophthalmoplegia, 13.5
  oscillopsia, 14.1
  ptosis, 14.7
  trochlear nerve palsy, 13.5
  unilaterally absent, 13.5
  wrong-way eyes, 13.7, 14.6
Eyelid, drooping, 13.1

F

Fasciculations, 6.6, 12.7
Fatigue, 17.2
  generalized, 5.1
  post-ictal, 18.5
Femoral nerve deficits, 9.7
Finger taps, slowed, 19.1
Finger-to-nose test, 14.4, 15.1
Flexion, triple, 14.5, 14.6
Fluency, impaired, 19.1. *see also* Aphasia
Foot drop, 9.9
Foramen ovale, schwannoma, 12.3
Foramen rotundum, meningioma, 12.2
Fourth ventricle compression, 15.3
Frontal lobes
  astrocytoma, 19.7
  compression, 19.7
  hemorrhage, 19.3
Frustration, 19.1

G

Gag reflex
  absent, 12.8
  decreased, 14.1
Gait
  abnormal, shuffling and slow, 7.5
  decreased arm swing, 16.3
  difficulty, 14.6
  difficulty with stairs, 17.1
  "drunkard-like," 15.2
  en bloc turning, 16.3
  falling to left, 14.1, 19.7
  falling to right, 16.1
  leg, 7.4
  magnetic, 5.9, 19.7
  occasional stumbling, 16.2

  painful, 8.8
  paraparetic, 6.6
  retropulsion, 16.3, 16.4
  short steps, 16.3
  shuffling, 16.4
  slow, 8.8, 16.4
  spastic, 6.6, 7.4
  stiff lower extremities, 12.8
  stooped, 16.3
  uncoordinated, 11.2
  unsteady, 5.1, 5.4, 5.9, 6.2, 6.4, 7.4, 7.6, 10.12, 12.8, 14.1, 14.2, 14.4, 14.7, 15.1, 15.2, 15.3, 15.4, 16.1
  wide-based, 14.4
Gaze. *see also* Eye movements
  downward, 13.3
  left, 13.3
  right, 13.4
Gaze preference, 10.11
  left, 10.8, 14.6
  right, 10.10, 10.13, 13.7, 19.6
Glioblastoma multiforine, 18.4
Glomus jugulare tumor, 12.7
Graphesthesia, unilateral decrease, 10.13
Grasp reflex, 10.2, 19.7

H

Hair, facial, 17.1
Hallucinations
  auditory, 19.10
  olfactory, 18.4
Head injury, 5.2, 5.3, 18.1
Head tilt, 13.3
Headaches, 5.4, 5.8, 5.10, 13.9, 17.2
  bifrontal, 19.8
  bilateral frontal, 14.6
  bilateral retro-orbital, 14.9
  frontal, 13.1
  generalized, 14.4, 15.2
  left frontal, 13.4, 19.4
  left occipital, 15.3
  migraine, 11.5
  nocturnal, 5.1
  retro-orbital, 10.3, 13.1, 14.6
  right occipital, 11.5
  unilateral, 5.1, 6.2, 10.13, 12.2, 12.7, 13.5
  worsening, 5.7
  "worst in life," 10.1
Hearing loss, 17.2
  progressive, 12.5
  unilateral, 12.7, 14.4
Heart rhythm, irregular, 6.1
Hematoma
  epidural, 5.3
  subdural, 5.1, 5.2, 5.6
Hemianopia
  bitemporal, 11.3
  homonymous, 10.3
  left, 10.11
  left homonymous, 11.4
  right, 10.8
Hemianosognosia, 10.11
Hemiballismus, 16.1
Hemichorea, 16.1
Hemineglect. *see also* Neglect
  left, 5.1, 10.10, 10.11, 19.6
  mild, 10.9
Hemiparesis, 5.1, 5.4, 10.7, 14.6, 18.3. *see also* Weakness
  left, 5.1, 5.4
  pure motor, 6.4, 6.5
  right, 6.3, 14.3
  sparing the face, 14.2
Hemiplegia, 5.2. *see also* Weakness
  left, 5.4, 10.11
  right, 5.2, 5.3, 10.8
Hemorrhage, 13.5
  cavernous angioma, 14.9
  Duret–Bernard, 5.4
  epidural, 5.3
  frontal lobe, 19.3
  intraventricular, 5.2, 5.5
  left frontal, 19.3
  peri-Sylvian intraparenchymal, 19.4
  petechial, 5.4, 10.3
  right hemisphere, 5.5
  right parietal, 10.13
  subarachnoid, 5.2, 5.6, 10.1
  subdural hematoma, 5.1, 5.2, 5.6
  subgaleal, 5.2
  Sylvian fissure, 19.4
Herniation. *see also* Disc herniation
  brainstem, 5.5
  subfalcine, 5.1, 5.3, 5.4, 5.6
  tentorial, 5.2, 5.3, 5.6
  tonsillar, 5.5
  transtentorial, 5.4, 5.5
  uncal, 5.2, 5.3, 5.4, 5.5
Herpes zoster, 8.4
Hiccups, intractable, 14.9
Hippocampal sclerosis, 18.5
HIV, 16.1
Hoarseness, 12.6, 12.7, 14.1
Hoffmann's sign, bilateral, 6.6
Homonymous hemianopia, 19.5
Horizontal gaze
  abnormality, 13.8
  palsy, 14.6
Horner's syndrome, 13.6, 14.1
Huntington's disease, 16.2
Hydrocephalus, 5.7, 5.8, 5.9, 10.1, 15.3, 19.6
  ex vacuo, 5.2
  mild, 5.2
  noncommunicating, 5.7
  obstructive, 5.5
Hyperkinetic movement disorder, 16.1
Hyperpathia, abdominal, 7.6
Hyperreflexia, 6.4, 6.5, 6.6, 7.4, 10.9, 14.3, 19.6, 19.7
  extremities, 7.5
  left, 10.10, 10.12
  leg, 10.2
  right, 5.3, 10.8
Hypertension, 14.3, 17.1
Hypertropia, unilateral, 13.3
Hypokinesia, 19.7
Hyponatremia, 17.1
Hyporeflexia, leg, 9.8
Hypotonia, 7.7

I

Impotence, 17.2
Incontinence, 5.3
  emotional, 12.8
  fecal, 7.7
  urinary, 5.9, 7.4, 19.7
Infarct
  ACA, 5.6, 10.2
  ACA–MCA watershed, 10.12
  AICA, 14.4
  basilar thrombosis, 14.6
  basis pontis, 14.3
  bilateral medial thalamus, 18.3
  calcarine cortex, 19.8
  lacunar, 7.2, 10.7
  left MCA superior divison, 19.1
  left medial midbrain tegmentum, 14.7
  left medial pontine basis, 13.7
  "man-in-the-barrel" syndrome, 10.12
  MCA, 10.5, 10.6, 10.7, 10.8, 10.9, 10.10, 10.11
  MCA, inferior division, 19.2, 19.6
  medullary, 14.1, 14.2
  occipitotemporal, 19.9
  parietal lobe, 7.1
  PCA, 5.4
  pons, 14.4, 14.5
  pontine basis, 6.5, 13.7, 14.5
  postcentral gyrus, 7.1
  precentral gyrus, 6.1, 6.3
  primary motor cortex, 6.2
  SCA, 15.1
  top-of-the-basilar syndrome, 14.8
  watershed, 10.12

Infectious disorders of the nervous system, 5.10
Infertility, 11.3
Internal capsule lesion, 6.4
Internal carotid artery (ICA)
  occlusion, 10.5
  stenosis, 10.4
Intracranial pressure
  elevation of, 5.2, 5.7
  increased, 5.8
Intranuclear ophthalmoplegia (INO), 13.8
Irregular heart rate, 15.3. *see also* Atrial fibrillation
Irritability, 17.1
Iter, obstruction of, 5.7

J

Jaw jerk reflex, 6.6
Joint position sense
  decreased, 7.4
  loss in extremities, 7.6

L

Lacrimation, decrease, 12.4
Lacunar infarct, 7.2, 10.7
Lateral rectus muscle dysfunction, 13.2, 13.4. *see also* Eye movements
Lazy eye, 14.5
Lenticulostriate artery occlusion, 10.7
Lethargy, 5.2, 5.10, 13.7, 14.6, 18.3
Levodopa beneficial, 16.3
Levodopa not beneficial, 16.4
Lhermitte's sign, 7.6
Light–near dissociaton, 13.9
Locked-in syndrome, 14.5
Lucid intervals, 5.3
Luteinizing hormone (LH) low, 17.2
Lymphoma, 17.2

M

"Man-in-the-barrel" syndrome, 10.12
Masked facies, 16.4
Mass effect, 5.2, 5.7, 5.8, 10.8, 11.4
Medial gaze, reduced, 14.8
Medial longitudinal fasciculus (MLF) plaque, 13.8
Medial midbrain tegmentum infarct, 14.7
Median nerve lesion, 9.4
Medullary infarct, 14.1, 14.2
Memory, impaired, 19.7
Memory loss, 14.8, 19.11. *see also* Amnesia
  progressive severe, 18.2
  sudden, 18.1
  sustained, 18.3
  verbal, 18.3, 19.5
Meningioma, spinal, 7.4
Meningitis, bacterial, 5.10
Menstrual irregularity, 11.3
Middle cerebral artery infarct, 10.5, 10.6, 10.7, 10.8, 10.9, 10.10, 10.11, 19.6
Midline shift, 5.1, 5.2, 5.3
Miosis, 13.6
Moon facies, 17.1
Motor impersistence, 10.2, 19.7
Movement disorders. *see also* Specific conditions
  dyskinesias, 16.3
  facial, 10.5
  left, 10.10
  on–off fluctuations, 16.3
  purposeless movements, 18.5
  tics, 16.2
Multiple sclerosis, 11.2, 13.8
Muscle endurance, decreased, 17.2
Muscle tone. *see also* Weakness
  decreased in arm, 9.2
  decreased in foot, 9.8
  diminished in foot, 9.8
  increased, 6.4, 7.4
  increased in arm, 10.6
Myasthenia gravis, 9.11
Myelitis, 7.6

N

Naming. *see* Dysnomia
Nasolabial fold, decreased, 6.4, 10.2, 10.5, 10.10, 12.7, 14.2. *see also* Weakness, facial
Nausea, 5.7, 14.4, 14.6, 15.1, 15.3, 15.4, 18.4, 19.4
Neck
  muscle wasting, 12.7
  pain, 8.1, 8.6
  stiffness of, 5.10
Neglect. *see also* Hemineglect
  conceptual, 19.6
  contralateral, 10.2
  motor, 10.10, 19.6
  sensory, 10.10, 19.6
  tactile, 10.10
  unilateral, 5.1
  visual, 10.10, 19.6
Neoplasms
  acoustic neuroma, 12.5
  adenocarcinoma, 15.2
  astrocytoma, 11.4, 19.7
  C2 nerve root, 8.2
  cerebellar astrocytoma, 15.3
  glioblastoma multiforme, 5.4, 18.4
  glomus jugulare, 12.7
  lung, 9.1
  lymphoma, 17.2, 18.2
  meningioma, 7.4, 11.3, 12.1, 12.2, 12.8, 19.7
  metastatic, 8.2, 15.2, 15.4, 19.5
  pineoblastoma, 5.7
  pineocytoma, 13.9
  pituitary microadenoma, 17.1
  right hemisphere, 5.4
  schwannoma, 12.3, 12.5
  trigeminal neuroma, 12.3
Nuchal rigidity, 5.10, 10.1, 19.4
Numbness. *see also* Sensory deficits
  arm, 7.2, 7.5, 7.6, 10.13
  buttock, 8.9
  cheek, 12.2
  contralateral body, 14.1
  face, 7.2, 14.1, 14.4
  fingers, 8.5
  forearm, 9.6
  forehead, 13.5
  gluteal, 8.11
  hand, 9.3
  hand, medial surface, 9.6
  index finger, 8.1, 8.5
  jaw, 12.3
  legs, 7.2, 7.4, 7.6, 8.9
  little finger, 8.6, 9.6
  medial arm, 8.7
  middle finger, 8.5
  perioral, 14.4
  right arm, 7.1
  ring finger, 8.6, 9.6
  saddle anesthesia, 8.11
  shoulder, 7.5, 8.3, 8.7
  thigh, 9.10
  thumb, 8.1
  trunk, 7.6
Nystagmus, 15.4
  convergence–retraction, 13.9
  end gaze, on abduction, 13.8
  horizontal, 14.4, 15.3
  right-beating, 14.1
  vertical, 15.3

O

Oculocephalic maneuvers, no response, 14.5
Oculomotor nerve palsy, 13.1
Olfactory aura, 11.4
Olfactory loss, 12.1, 18.2
Oligoclonal bands, 7.6
One-and-a-half syndrome, 13.8
Ophthalmoplegia, 13.5
Optic chiasm compression, 11.3
Optic disc pallor, 11.2
Optokinetic nystagmus (OKN), 10.12

Orbital myositis, 13.4
Orbital pseudotumor, 13.4
Oscillopsia, 14.1
Osteophytes, 8.3

P

Pain
  arm, 8.3, 8.4, 9.1
  big toe, 8.10
  buttock, 8.9
  cheek, 13.5
  eye, 12.4, 13.1, 13.4
  facial, 12.5, 12.8
  foot, 8.8
  forehead, 13.5
  gluteal, 8.11
  hand, 8.1, 8.3
  hyperacusis, 12.4
  leg, 8.9, 8.10, 9.7
  low back, 8.8, 8.10
  medial arm, 8.7
  middle finger, 9.4
  mouth, 12.8
  neck, 8.1, 8.2, 8.6, 14.1, 19.4
  nocturnal, 9.4
  occipital scalp, 8.2
  orbital conjunctiva, 13.4
  pointer finger, 9.4
  retroauricular, 12.4
  shoulder, 8.1, 8.3, 8.5, 8.7
  small toe, 8.8
  thigh, 9.7, 9.10
  thumb, 9.4
  unilateral, 8.6, 12.4
  unresponsiveness to, 5.4
Palate
  elevation, decreased, 14.1, 14.3
  movement, decreased, 12.7
Pallidotomy, 16.3
Pancoast's syndrome, 9.1
Panhypopituitarism, 17.2
Panic, 18.4
Papilledema, 5.7, 5.8, 15.3
Paralysis. *see also* Weakness
  arm, 9.1, 10.7, 10.8
  bilateral leg, 7.3
  face, 10.7, 10.8
  foot, 9.8
  leg, 10.7, 10.8
  vocal cord, 12.6
Paraphasias, 19.1, 19.2, 19.3. *see also* Aphasia
Paraplegia, 7.3
Paresthesia. *see also* Pain; Numbness
  arm, 7.5, 14.2
  calf, 8.8, 8.9
  diffuse, 7.6
  face, 13.5, 14.1, 15.4
  face, perioral, 14.2
  finger, index, 8.5
  finger, little, 8.6, 9.6
  finger, middle, 8.5, 9.4
  finger, ring, 8.6, 9.6
  fingers, 11.2
  foot, 8.8, 9.8
  foot, sole, 8.8
  hand, 10.10
  left hand, 19.6
  leg, 9.7, 14.2
  leg, lower, 9.8
  pointer finger, 9.4
  shin, 8.9
  shoulders, 7.5
  thigh, 8.9, 9.7
  thumb, 9.4
  toe, small, 8.8
  unilateral, 7.4
Parietal lobe infarct, 7.1
Parinaud's syndrome, 13.9
Parkinsonism, atypical, 16.4
Parkinson's disease, idiopathic, 16.3
Patellar reflex absent, 8.9, 9.7
Personality change, 19.7
Petechiae, 5.10
Peticheal hemorrhage, PCA, 10.3
Petrosal sinus sampling, 17.1
Photophobia, 5.10, 17.2
Pineoblastoma, 5.7
Pineocytoma, 13.9
Plantar reflexes. *see also* Babinski's sign
  absent, 5.2
  equivocal, 14.7
  upgoing, 10.7, 13.7, 14.6
  upgoing bilateral, 5.6
Polyurea, 17.2
Pons, infarct, 14.4, 14.5
Pontine basis infarct, 6.5, 13.7, 14.5
Postcentral gyrus infarct, 7.1
Posterior cerebral artery (PCA) peticheal hemorrhage, 10.3
Posterior communicating artery (PComm) aneurysm, 13.1
Posturing
  absent, 5.6
  decerebrate, 5.5, 14.5
  decorticate, 5.6
  extensor, 5.5
  flexor, 5.6, 10.11
  left arm, 18.5
  left extensor, 14.6
Precentral gyrus infarction, 6.1, 6.3
Primitive neuroectodermal tumor (PNET), 5.7
Progression, gradual, 16.3, 16.4
Pronator drift
  arm, 10.9
  left, 10.13, 12.8
  right, 7.1, 19.1
  slight, 19.4
Proptosis, unilateral, 12.2
Prosopagnosia, 19.9
Psychomotor agitation, 5.2, 5.3
Ptosis, 9.11, 13.1, 13.6
  left, 13.5, 14.7
  right, 14.8
Pupillary response
  accommodation absent, 13.1
  unilaterally impaired, 13.6
Pupils
  afferent pupillary defect, 11.2
  enlarged, 13.9
  fixed dilated, 13.1
  Horner's syndrome, 13.6, 14.1
  unilateral dilation, 10.11
  unilaterally enlarged, 14.8
  unilaterally fixed, dilated, 13.5
  unilaterally sluggish, 14.8
  unresponsive, 5.3, 5.4, 5.5, 5.6
Pure motor hemiplegia, 10.7
Putamen atrophy, 16.2
Pyrexia, 5.10

Q

Quadrantanopia, left inferior, 11.5

R

Radial nerve lesion, 9.5
Radiculopathy. *see also* Disc herniation
  C5, 8.3
  C8, 8.6
  L4, 8.9
  L5 nerve root, 8.10
  S1 nerve root, 8.8
  thoracic, 8.7
Reading, impaired, 19.1, 19.2, 19.5
Recall, impaired, 18.1. *see also* Memory loss
Recognition
  faces, 19.9
  impaired, 19.8
Rectal tone
  decreased, 7.3
  loss of, 8.11
Red glass test, diplopia, 13.3
Reflexes. *see* Hyperreflexia; Specific reflex
Repetition

impaired, 19.1, 19.2, 19.4
preserved, 19.3
Respiration
arrest, 5.4, 14.5
depression, 5.5
Retinal artery occlusion, 11.1
Rigidity
cogwheel, 16.3
waxy, 16.4
Romberg sign, 7.6

S

Saccadic eye movements, slowed, 16.2, 16.4
Scalp abrasion, 5.6
Scalp wound, 5.2
Sciatic nerve lesion, 9.8
Scotomas
central, 11.2
fortification, 11.5
left inferior quadrant, 19.9
right eye, 11.1
Seizures, 10.13, 11.4, 18.5, 19.10
generalized, 18.5
generalized tonic-clonic, 19.10
simple partial, 18.5
Self-awareness, diminished, 10.11
Sensory (somatosensory) deficits, 9.1. *see also* Numbness; Paresthesia; Pain
arm, 7.5, 8.7, 9.1, 14.1, 14.5
bilateral, 7.6
buttocks, 8.11
calf, 8.9, 8.10, 9.7
facial, 12.2, 12.3, 13.5, 14.4, 14.5
finger, index, 8.1, 8.5
finger, little, 8.6, 9.6
finger, middle, 8.5
finger, ring, 8.6, 9.6
fingers, 8.1, 9.4
foot, 8.8, 8.10, 9.9
forearm, 8.7
genitals, 8.11
impaired response to pain, 10.8
joint position sense, 7.3, 7.4, 7.6, 10.13, 14.2
legs, 7.3, 8.8, 14.1, 14.5
occipital scalp, 8.2
pinprick, 7.2, 7.3, 7.4, 7.7, 8.1, 8.3, 8.4, 8.9, 8.11, 9.1, 9.3, 9.4, 9.6, 9.9, 9.10, 10.2, 10.6, 10.11, 10.13, 12.2, 12.3, 13.5, 14.1, 14.4
response to light, 14.8
shin, 8.9
shoulder area, 7.5
temperature, 7.2, 7.7, 9.10, 10.13, 12.3, 14.1, 15.4
thigh, 8.9, 9.7, 9.10
toes, 9.9
touch, 7.2, 7.3, 8.5, 8.11, 9.1, 9.3, 9.10, 10.13, 12.2, 12.3, 14.4
trunk, 14.1
unilateral, 7.2
vibration sense, 7.2, 7.3, 7.4, 7.6, 9.1, 10.13, 14.2
Sensory level
C7, 7.7
pinprick, 7.7
Sensory nerve injury, 9.10
Sequencing tasks, impaired, 10.7
Sexual function, impaired, 8.11, 17.2
Shivering, 14.6
Skin
bruising, 17.1
striae, 17.1
thin-appearing, 17.1
Skull fractures
frontotemporal, 5.6
parietal, 5.3
temporal, 5.3
temporal bone, 12.4
Sodium, high, 17.2
Somnolence, 5.2, 14.8, 18.3
Sparkling lights, 14.8
Spasticity, leg, 7.4. *see also* Rigidity
Speech. *see also* Aphasia; Dysarthria
aphasia, 10.4
difficulty enunciating, 9.11
impaired, 19.1
inappropriate, 18.4
irregular rate, 15.3
nonsensical, 19.2
slurred, 6.3, 6.5, 12.8, 14.3, 14.4, 14.5, 15.1, 15.3
stuttering, 6.4
Spinal cord
acute lesion, 7.7
compression, 7.4, 7.5
demyelination, 7.7
injury, 7.3, 7.5
Spinal shock, 7.3
Staring, 18.5
Stereognosis, 10.13
Striatonigral degeneration, 16.4
Stroke, embolic, 7.1. *see also* Infarct
Subarachnoid hemorrhage, 5.2, 5.6, 10.1
Subdural hematomas, chronic, 5.1, 5.6
Superior cerebellar artery (SCA) infarcts, 15.1
Superior sagittal sinus thrombosis, 10.13
Swallowing, difficulty, 12.7, 12.8
Sweat production
excessive, 17.1
unilaterally impaired, 13.6
Swelling, arm, 9.1
Swinging flashlight test, afferent pupillary defect, 11.2
Sympathetic trunk injury, 13.16
Syncope, 10.10
Syringomyelia, posttraumatic, 7.5

T

Tandem gait, impaired, 15.4
Taste, altered, 12.5, 12.7
Temperature, elevated, 5.10
Temporal lobe
bilateral medial lymphoma, 18.2
glioblastoma multiforme, 18.4
Tenderness, arm, 9.3
Tensilon test, 9.11
Tentorium cerebelli hematoma, 5.2
Testicular volume, decreased, 17.2
Testosterone, low, 17.2
Thalamic infarct, 7.2, 18.3
Thirst, 17.2
Thrombosis, basilar arteries, 14.6
Thyroxine, low, 17.2
Tongue
atrophy, 12.7
deviation, 6.5, 12.7
fasciculations, 12.7
muscle wasting, 12.7
rightward deviation, 14.3
slowed movements, 15.1
unable to protrude, 14.6
Top-of-the-basilar syndrome, 14.8
Toxoplasmosis, 16.1
Transient ischemic attack (TIA), 14.3. *see also* Infarct
Transient, right-sided weakness, 18.3
Transsphenoidal surgery, 17.1
Trauma, head injury, 5.1, 5.2, 5.3
Tremor, resting, 16.3
Triceps reflexes, absent, 7.7, 8.5
Trochlear nerve palsy, 13.5
Truncal obesity, 17.1

U

Ulnar nerve, CMAP decrease, 9.6
Unresponsiveness, 5.2, 5.3, 5.4, 5.5. *see also* Altered mental status; Awareness; Coma; Consciousness
Upgaze, limited, 13.1, 13.9, 14.6, 14.8, 15.3
Upper motor neuron lesion, 5.1, 10.13, 14.2
Upper trunk injury, 9.2
Urinary bladder function
difficulty initiating, 12.8
frequency, 7.4
hyperactive sphincter reflexes, 7.7

impaired, 12.8
incontinence, 7.4
retention, 7.7, 8.11
urgency, 12.8

V

Ventricles, dilation, 5.2, 5.7, 5.8, 5.9, 10.1, 15.3
Verbal memory, impaired, 19.5
Vermis
astrocytoma, 15.3
lung metastasis in, 15.2
Vertebral fracture, 7.3
Vertigo, 14.1. *see also* Dizziness
Vestibulo-ocular reflex, not suppressed, 15.3
Vibration sense deficits, 7.2, 7.3, 7.4, 7.6, 9.1, 10.13, 14.2
Vision
blurred, 7.1, 10.4, 14.6, 14.8, 17.2
field extinction, 5.1
impaired, 12.1, 19.8, 19.9. *see also* Blink to threat; Diplopia
loss, monocular, 11.2
loss of, 5.8
unilateral decrease, 10.3
Visual acuity, impaired, 12.1
Visual cortex infarcts, 10.7
Visual field defects, 19.2
bilateral temporal, 11.3
concentric loss, 5.8
homonymous hemianopia, 10.3
left eye, 11.2
left homonymous hemianopia, 11.4
left inferior quadrantanopia, 11.5
obscuration, 19.9
oscillopsia, 14.1
right eye, 11.1
unilateral deficit, 10.6
Vocal cord paralysis, 12.6, 12.7
Voice, muted, 19.7
Vomiting, 5.7, 14.1, 15.1, 15.3, 15.4, 19.4

W

Wallenberg's syndrome, 14.1
Weakness. *see also* Hemiparesis; Hemiplegia; Muscle tone; Paralysis; Pronator drift
ankle, 6.2
arm, 5.5, 6.4, 6.5, 8.4, 8.5, 9.1, 9.2, 10.2, 10.5, 10.9, 10.12, 10.13, 13.7, 14.2, 14.3, 14.5, 14.6, 19.6, 19.7
biceps, 6.5, 8.1, 8.4, 10.12
biceps femoris, 8.8
brachioradialis, 8.1, 8.4
deltoid, 6.5, 8.3, 10.12, 12.8
elbow flexion, 9.2
extensor hallucis longus, 8.10, 9.8, 9.9, 10.13, 12.8
facial, 5.5, 6.3, 6.4, 6.5, 9.11, 10.2, 10.5, 10.9, 10.13, 12.4, 13.7, 14.3, 14.5, 14.6, 19.1, 19.7. *see also* Nasolabial fold decreased
feet, 7.5
finger extensors, 8.5, 9.5, 12.8
finger flexors, 9.3
fingers, 6.1
foot, 6.2, 6.5
foot evertors, 8.10, 9.8, 9.9
foot inverters, 8.10, 9.8
forearm, 9.5
gastrocnemius, 8.8, 9.8
generalized, 14.6
hamstring, 6.2, 8.8, 9.8, 12.8
hand, 6.1, 6.3, 6.5, 6.6, 7.5, 7.7, 8.6, 9.3, 9.5, 10.4, 19.1
hip flexors, 10.12
illiopsoas, 6.2, 6.5, 7.4, 8.9, 9.7, 12.8
interossei, 8.6
left side, 14.6
leg, 5.1, 5.4, 6.4, 6.5, 6.6, 7.4, 9.11, 10.2, 10.4, 10.5, 10.12, 10.13, 13.7, 14.2, 14.3, 14.5, 19.6
lower motor neuron, 6.6, 7.7
lumbricals, 8.6
neck, 9.11, 12.8
opponens pollicis, 9.4
progressive, 6.6
quadriceps, 6.5, 8.9, 9.7
respiratory muscles, 9.11
right-sided, 19.1
semimembranous, 8.8
semitendinosus, 8.8
shoulder, 8.3
shrug, 10.12
sternomastoid, 12.7
thumb, 6.1, 9.3, 9.5
tibialis anterior, 8.10, 9.8, 9.9, 12.8
transient right-sided, 18.3
trapezius, 12.7
triceps, 5.4, 6.5, 7.7, 8.5, 10.12, 12.8
upper motor neuron, 5.1, 5.3, 6.6
wrist, 6.1, 9.5
wrist extensors, 8.1, 9.5, 12.8
wrist flexion, 9.3
Weber test, abnormal, 14.4
Wernicke's aphasia, 10.6, 19.2
Wide-based, unsteady gait, 15.2
Writing, impaired, 15.4, 19.1, 19.2, 19.3. *see also* Agraphia

Subject Index

Page numbers in **boldface** *refer to the main discussion of an entry;* f *after a page number indicates that the entry is included in a figure;* t *after a page number indicates that the entry is included in a table.*

A

"A" random letter test, 864
Abdomen, assessment in neurologic exam, 10
Abdominal cutaneous reflexes, 67
Abducens nerve (CN VI)
  cavernous sinus and, 546
  extraocular movements and, 59–60
  extraocular muscles and, 532
  function, 40t, 461t, **472–473**
  location, 38f, 39f, 464, 535f
Abducens nuclei, 534, 581, 584
Abducens palsy, **539–540**, 539f
Abduction, eye, 531
Abscesses, **155**, 156
Absence seizures, 794f
Abstraction, **57**, 852t
Abulia
  assessment in neurologic exam, 75
  definition, 602t, 603
  description, 44
  frontal lobe lesions and, 57, 850, 891–892, 895f, 896f
ACA–MCA watershed territory, 114f, 415–416, 418f
Accessory spinal nucleus, 581. *see also* Spinal accessory nerve and nucleus
Accommodation response, 59, 540
Acetylcholine, **593–595**
  anti-acetylcholine receptor antibodies, 313
  aspiny neurons and, 701
  autonomic efferents, 229f
  function, 20, 20t
  parasympathetic nervous system and, 24
  release, 229
  somatic efferents, 229f
Achromatopsia, 44, 856
Acoustic neuroma, 492, 494, 512–513, 515f
Action potentials, 19
Action tremor, 711
Acute, definition, 866
Acute confusional states, 866, 867
Acute inflammatory demyelinating polyneuropathy (AIDP), 312
Acute mental status changes, 866
Acute subdural hematoma, **143**, 144f, **146**
Adduction, eye, 531
Adenocarcinoma, 682–683, 685f
Adenohypophysis, 738
Adenosine, 598
Adiadochokinesia, 673. *see also* Dysdiadochokinesia
Adie's myotonic pupil, **546**
Adrenal cortex, 745
Adrenocorticotropic hormone (ACTH), 743f, 745, 746f, 747
Adrenocorticotropic hormone deficiency, 750
Afferent pathways, 22
Afferent pupillary defect, 59, **445**, 447–448, **545**
Agnosia, 837, 838, 856
Agraphia, **55**, 835–836
AIDS dementia complex, 159, 872
Air emboli, 381
Airway in coma, 604
Akinesia, 75, **706**
Akinetic mutism, 602t, 603
Alcohol, 494
Alcoholism, 872
Aldosterone, 745
Alertness, 53–54, 72, 860
Alexia, **835–836**, 836f
Allergies, **6**
Allesthesia, 843
Allocortex, 765
Allodynia, 276
Allokinesia, 843
Altered mental status, 138, 166–173, 866f. *see also* Awareness; Consciousness, loss of; Specific conditions
Altitudinal scotomas, 444f
Alvear pathway, 777
Alveus, 113f, 779
Alzheimer's disease
  case report, 901–902, 904f
  clinical features, 874–875
  memory loss and, 786
  pathologic changes, 873f
  pathophysiology, 873–874
  treatment, 875
Amacrine cells, 430
Amaurosis fugax, 444
Ambient cistern, 133, 133f
Amblyopia, 536
Amnesia
  anterograde, **54**, 783f
  definition, 781
  infantile, 786
  patient H.M., 780–782
  psychogenic, 786
  retrograde, 54, 783f
  transient, 800–801
  transient global, 785
Amniotic fluid emboli, 381
Ampullae, 486f, 490
Amygdala
  anatomy, 766
  basolateral, 771
  circuits, 788f
  cortical connections, 849
  emotions and, 763
  functions, **787–789**
  hypothalamic connections, 742
  limbic system and, 42f
  location, 41
  memory and, 788
  MRI, axial T1-weighted images, 106f
  MRI, coronal T1-weighted images, 111f

MRI, sagittal T1-weighted images, 113f
sagittal section, 775f
spatial relationships, 690f
Amygdaloid complex, 697f
Amygdaloid nuclear complex, 787
β-Amyloid, 873
Amyloid angiopathy, 149, 871
Amyloid plaques, 873–874
Amyloid precursor protein (APP), 873–874
Amyotrophic lateral sclerosis (ALS), 243, 256–258
Anal sphincter, 282
Anal wink, 67
Aneurysm
AComm, 388–389, 393f–394f
common sites, 147f
oculomotor palsy and, 536–537
PComm, 554–555, 556f
subarachnoid hemorrhage and, 146
Anger, 833
Angiograms, **114–115**, 148, 797
Angular gyrus, 26f
Anhidrosis, 543, 544, 560–561
Anisocoria, 543, **545**
Annulus fibrosus, 305, 306f
Anomia, 835, 856–857
Anomic aphasia, 875
Anosmia, 472, 504, 506f–507f
Anosodiaphoria, 846
Anosognosia, 44, 56, 845, 894–895
Ansa lenticularis, 704
Anterior cerebral arteries (ACA)
angiographic images, 114f
blood supply to, 44, 45f
cerebral cortex supply, 372f
circle of Willis and, 369
course of branches, 371f
infarct, 188, 190f, 389–390, 395f
MRA images, 116f
MRI, axial T1-weighted images, 106f, 107f
MRI, coronal T1-weighted images, 111f
syndromes of the territory of, 377t, 378
vascular territories, 371–372
watershed zones, 379f
Anterior choroidal artery, 373
Anterior cingulate cortex, 862
Anterior cingulate gyrus, 703, 848
Anterior clinoid process, 123f, 465f, 739
Anterior columns, 217, 217f. *see also* Ventral columns
Anterior commissure
limbic system and, 42f, 790
MRI, coronal T1-weighted images, 111f
MRI, sagittal T1-weighted images, 112f, 113f
olfactory system and, 770
spinal cord, 268
structure, 778f
Anterior communicating artery (AComm)
aneurysm, 388–389, 393f–394f
angiographic images, 114f
circle of Willis and, 369
location, 45f
memory loss and, 784
MRA images, 116f
subarachnoid hemorrhage and, 146
Anterior cord syndrome, 296, 297
Anterior corticospinal tract, 221t, 222, 227f, 664
Anterior cranial fossa, 123f
Anterior entorhinal cortex, 771
Anterior fossa, 124, 125f, 465f
Anterior horn
cells, 282, 283t
central gray matter, 33, 33f
lateral ventricle, 131
spinal cord, 216, 217f
Anterior hypothalamic area, 743
Anterior hypothalamic nuclei, 741
Anterior hypothalamic region, 740–741
Anterior inferior cerebellar artery (AICA)
angiographic images, 115f
brainstem and, 607
cerebellar blood supply, 668
infarcts, 617, 626–628, 631f, 669
location, 45f
MRA images, 116f
Anterior insular cortex, 763
Anterior medullary velum. *see* Superior medullary velum
Anterior nuclear group of thalamus, 271, 273t, 274, 768
Anterior olfactory nucleus, 770
Anterior orientation, 17
Anterior perforated substance (basal forebrain), 27f, 770
Anterior pituitary, 738, 739f, 743f
Anterior spinal arteries, 46, 219, 219f
Anterior thalamic nucleus, 742, 779
Anterior thalamic radiation, 223f
Anterograde amnesia, 54, 783
Anterolateral system
components, 266f
function, 34, 35, 264, 586
organization, **268–270**
Anterolisthesis, 315t
Anteropulsion, 713
Anti-acetylcholine receptor antibodies, 313
Anti-emetic medications, 707, 709
Antibiotics, 154–155, 156
Anticholinergic agents, 545
Antidiuretic hormone (ADH), 744, 749
Antidiuretic hormone deficiency, 750
Antipsychotic medications, 707, 709
Anton's syndrome, 855
Anxiety, 799
Aorta, 219f
Aortic arch, 45f, 118f
"A&O×3," 53–54
Aphasias, **829–830**
causes, 830t
classification, 833–835
conduction, 834
cortical lesions, 382
definition, 62
global, 405, 407–408, 834
MCA infarct and, 876–877, 878f
nonfluent, 399–400, 402f
preserved repetition and, 881–882, 884f
primary progressive, 871
recovery, 835
transcortical, 834–835
Aphemia (verbal apraxia), 837
Apnea test, 78
Apneustic respiration, 605
Apolipoprotein E, 874
Appendicular ataxia, 68, 69, 670–673, 680–683, 684f
Appetite, 742
Apraxia, **837**
Alzheimer's disease, 875
aphasia and, 831
assessment in neurologic exam, **55–56**, 73
ideomotor, **55**
MCA infarct and, 838f
motor system and, 220
ocular, 858
parietal lobe and, 43
Aqueduct of Sylvius, 112f, 131f, 132, 191, 194f–196f. *see also* Cerebral aqueduct
Arachnoid, 16, 125, 126, 306f
Arachnoid granulations, 132
Arachnoid villus cells, 134
Archicortex, 765
Arcuate fasciculus, 829

Arcuate nucleus, 741, 744
Area postrema, 134f
Areflexia, 312
Arginine vasopressin (AVP), 744
Argyll Robertson pupil, 545–546
Arm
nerve roots, 317, 317f, 318t
nerves, 342–344, 342t
Arousal, 861
Arteriovenous malformations (AVMs), 146, 150, 451, 453, 454f–455f
Artery-to-artery emboli, 381
Artherosclerotic disease, 415–416, 418f
Articulatory processes, 306f
Ascending reticular activating systems (ARAS), 275
Aseptic meningitis, 157
Aspergillosis, 160
Aspiny neurons, 701
Aspiration pneumonia, 502
Assessments, H&P, **7–8**
Association cortex, **41–44**
components, 43f
cortical connections, 849
divisions, 823–825
function, 432
lesion-related conditions, 44
terminology, 823t
Associative function, 777
Astrocytomas
"butterfly," 895f
cerebellar, 680–682, 684f
malignant, 449–450, 452f
source, 153
Asymmetry, assessment in neurologic exam, 71
Ataxia
adults, 674t, 675
appendicular, 670–671, 672–673, 680–682, 682–683, 684f
cerebellar lesions and, 34
defmition, 654, 670
description, 68
false localization, 671
lesions and, 587
localization, 671
midbrain infarct, 639–640, 643f–644f
optic, 858
pediatric patients, 675, 675f
sensory, 671
sudden onset, 676–677
truncal, 670–671, 673, 677, 680–682, 682–683
Ataxia-hemiparesis, 233, 381, 382t, 671
Ataxic gait, 240t
Ataxic respiration, 605
Ataxic tremor, 710, 711
Atherosclerotic disease, 390–392, 613
Athetosis, 707, **708**
Atonic bladder, 284
Atraumatic hemorrhage, 143, 146–148
Atrial fibrillation, 381
Atrium, 131f, 132. *see also* Trigone
Atrophy, 231, 714, 715, 716
Attention
anatomy, **861–862**
assessment in neurologic exam, **53–54**
causes of impairment, 865t
consciousness and, 860
hemispheric asymmetry, 840f
impaired, 72, 851
lateralized aspects, 839–840
mechanisms, **859–861**
process, 591
projection systems, 589–598
testing, 864
Attention-deficit hyperactivity disorder (ADHD), 865
Attentional disorders, **864–865**
Atypical parkinsonism, 714
Auditory association cortex, 43f
Auditory canal, 464, 479, 484
Auditory cortex, 487f
Auditory extinction, 842
Auditory go-no-go test, 57, 57f
Auditory hallucinations, **858–859**
Auditory neglect, 842
Auditory pathways, 485–487, 487f, 488f, 827
Auditory radiations, 223f, 488
Auras, 135, 791
Autonomic control, 788
Autonomic efferents, 228, 229f
Autonomic nervous system (ANS)
composition, 23f
divisions, 230f
hypothalamic control, **741–743**
organization, **228–229**, 229f, 230f
Autoregulation, 138
Avulsion, 317
Awareness, 591, 833, 860, **862–863**, 894–895
Axial sections, radiographic, 17
Axillary nerve, 340f, 342–344, 342t
Axillary neuropathy, 346
Axon collaterals, 18
Axons, 17, 312, 350

B

Babinski's sign, 66, 67f, 231
Back, assessment in neurologic exam, 9
Back pain, **314–315**, 314t
Bacterial infections, **154–158**
Bacterial meningitis, **155**
Balance, control, 664
Balint's syndrome, 858, 863
Ballismus, **709**
Bárány positional testing, 493
Basal forebrain, 592, 766f–767f, 768, 772, 861
Basal ganglia
anatomy, **690–698**, 691t
attention and, 862
cerebellum and, **34**
channels through, 702–704, 702t
coronal sections, 696f–697f
cortical connections, 849
deep blood supply, 374f
eye movements and, 552
gray matter in, 21
hemorrhage, 145f
horizontal section, 694f
hypertensive hemorrhage and, 149
intrinsic connections, 699–701, 700f
lacunae, 382t
language and, 829
limbic system and, 768
motor system and, 220
output, 699, 704f
pathways, **698–702**
position, 692f–693f
spatial relationships, 690f
Basal veins of Rosenthal, 387
Basilar arteries
angiographic images, 115f
blood supply, 44, 45f
brainstem and, 607
CT image, 99f
insufficiency, 626–628, 631f
MRA images, 116f
MRI, axial T1-weighted images, 105f
MRI, coronal T1-weighted images, 110f
MRI, sagittal T1-weighted images, 112f
spinal blood supply and, 219f
stenosis, 637f
thrombosis, 632–634, 638f–639f
Basilar membrane, 485
Basilar migraine, 135
Basilar scrape syndrome, 617–619, 804–805
Basilar stenosis, 613
Basilar thrombosis, 613, 618
Basis, brainstem, 577
Basis pedunculi, 224f, 225, 579f, 581
Basis pontis, 577, 581, 616t, 617
Basolateral nuclei, 768, 787

Batson's plexus, 220, 305
Bed nucleus of the stria terminalis, 768, 787
Bedside gait testing, **240**
Bedside hemiparesis detection, **239–241**
Bedside language exam, 830, 831t
Behavioral abnormalities, 850
"Bellman's" pose, 346f
Bell's palsy, 482–483, 509–510. *see also* Weakness, unilateral facial
Benedikt's syndrome, 640
Benign anisocoria, **545**
Benign familial chorea, 708
Benign paroxysmal positional vertigo, 494
Benign senescent forgetfulness, 786–787
Berry aneurysm, 146
Betz cells, 222
Bielschowsky three step test, 538
Binding, 855, 861, 863
Binocular visual disturbances, 439
Binswanger's disease, 871
Biopsy, stereotactic, 718
Bipolar cells, 429–430
Bipolar neurons, 18
Bitemporal hemianopia, 441, 442f, 448–449, 739, 746
Blepharospasm, 707
Blessed dementia scale, 870t
Blind spots, 139, 196–197, 429f
Blindness, 894–895
Blindsight, 855
Blink to threat, 75f, 441
Blood flow. *see also* Blood supply
  assessment in neurologic exam, 384
  cerebral perfusion pressure and, 138
  MRI artifacts, 92
  ophthalmic arteries, 443
  perfusion MRI, 96
  PET, 96
  SPECT, 96
  Xe rCBF, 96
Blood oxygen level–dependent functional MRI (BOLD fMRI), 96
Blood pressure, 493, 606
Blood supply. *see also* Blood flow
  anterior circulation, 114f
  brain, **44–46**, 45f
  brainstem, 46, **607–619**, 608f, 609f
  cerebellum, 655f, 668
  cerebral cortex, 372f
  cerebral hemispheres, 375f
  deep cerebral structures, 374f
  imaging, 94–95
  intracranial circulation, 116f
  neck vessels, 117f
  posterior circulation, 115f
  spinal cord, **44–46**, 45f, **219–220**, 219f
  visual pathways, **443–445**
Blood–brain barrier, **133–135**, 133f, 607
Blood–CSF barrier, 133f
Blown pupils, 141
Body of caudate, **110f**
Body part substitution, 837
Bone conduction, 491
Bone flaps, 163, 170
Bone windows, 87, 124f, 179f
Bonnet syndrome, 440
Bony labyrinth, 485
Borrelia burgdorferi, 157–158, 317
Botulinum toxin, 707
Bowel function, **282–285**, 283f
Brachial diplegia. *see* Weakness, bilateral arm
Brachial monoparesis or monoplegia. *see* Weakness, unilateral arm
Brachial plexus
  anatomy, 23, **340–341**, 340f
  diagram, **341f**
  lower trunk injury, 346
  neoplasms, 351–352, 354f
  spinal cord, 22f
  upper trunk injury and, 346, 353
Brachiocephalic artery, 118f
Brachiocephalic vein, 45f
Brachiocrural paresis. *see* Weakness, unilateral arm and leg
Brachiocrural plegia. *see* Weakness, unilateral arm and leg
Brachium conjunctivum, 581, 656
Brachium of inferior colliculus, 39f, 488
Brachium of superior colliculus, 39f, 432–433, 432f
Brachium pontis, 656
Bradykinesia, **706**, 712
Bradyphrenia, 713
Brain
  abscesses, **155**
  blood supply to, **44–46**, 45f
  location, 14f
  metastases to, 153–154
  protective layers, 122f
  sensory loss and, 278
  ventricles, 131f, 132t
Brain attack, 383
Brain death, **78**, 601–602, 602t
Brain herniation syndromes, **140–142**
Brain tumors, 152–154, 795
Brainstem
  auditory pathways, 488f
  blood supply, 46, 608f–609f
  brain death and, 78
  cerebellar peduncle attachments, 656f
  components, 15, 21f, 461, **576–577**, 576f, 578t
  cranial nerves and, 38f–39f
  horizontal gaze and, 548f, 549–550, 549f
  lesions, 382
  midsagittal view, 460f
  motor nuclei, 33
  motor systems and, 606
  reflexes and, 77
  respiration control, 606f
  reticular formation, 589f
  sagittal view, 655f
  sections, **577–584**, 577f
  signs of dysfunction, 613
  sleep circuits, 600f
  surface anatomy, 462f, 463f
  surface features, **461–464**
  vascular supply, **607–619**
  vascular territories, 609f, 610f–611f
Brainstem nuclei, 768
Branchial arches, 468
Branchial motor nuclei, 468, 478, 584
Breasts, assessment in neurologic exam, 9
Breathiness, 501
Breathing, in coma, 604
Bridging veins, 127–128, 143
Broca's aphasia, 399–400, 402f, 831–832, **831–832**
Broca's area, 43f, 97f, 828
Brodmann's area 4. *see* Primary motor cortex
Brodmann's areas, 31t, 32t
Brodmann's areas 1, 2, 3. *see* Primary somatosensory cortex
Brodmann's areas 44 and 45, 828
Brown–Séquard syndrome, 280, 291–292
Brudzinski's sign, 10, 147t
Bruit, 9, 858
Buccal branches, CN VII, 479
Bulbocavernosus reflex, 67
Bundle, white matter in, 22
Burr holes, 163

C

Calcarine cortex, 454f–455f
Calcarine fissure
  CT image, 101f
  infarct, 397f
  location, 25, 26f, 28
  MRI, axial T1-weighted images, 106f, 107f
  MRI, sagittal T1-weighted images, 112f
  primary visual cortex and, 434
Calculations, assessment in neurologic exam, 55

Callosomarginal arteries, 114f, 116f
Callosotomy, 798
Caloric testing, 60, 61, 76
Cancellation tasks, 844f, 845
Candidiasis, 160
Cape distribution, 281
Capgras syndrome, 847
Capillary telangiectasias, 150
Carbidopa, 713
Carcinomatous meningitis, 163
Cardiac arrest, 784
Carotid artery, 118f
  bifurcation, 117f
  dissection, **385**
  intracranial segment, 370
  occlusion, 411–412, 414f
  origin, 118f
Carotid body, 495
Carotid canal, 98f, 123f
Carotid endarterectomy, 385
Carotid foramen, 465f
Carotid occlusion, 385
Carotid plexus, 543
Carotid siphon, 370, 546
Carotid stenosis, **384–385**
Carpal tunnel syndrome, 347, 355
Catatonia, 75, 602t, 603
Cauda equina
  anatomy, 23, 304
  lumbar puncture and, 162
  nerve root location, 304f
  spinal cord, 22f
Cauda equina syndrome, **318**, 332–333, 334f–335f
Caudal intralaminar nuclei, 273t, 275
Caudate nucleus, 101f, 691, 697, 782
  head of, 100f, 107f, 111f, 112f, 727f–728f
  tail of, 110f
  MRI, coronal T1-weighted images, 110f
Caudal nucleus solitarius, 495, 497
Caudal orientation, 16f
Causalgia, 312
Cavernous malformations, 150
Cavernous segments, 370
Cavernous sinus
  anatomy, 547f
  cerebral hemisphere drainage, 386, 387
  location, 129f, 739
  MRI, coronal T1-weighted images, 111f
  parasympathetic pathways and, 473
  sympathetic fibers and, 546–547
Cavernous sinus syndrome, **547–548**
Cell body, neurons, 17
Cellular bridges, 691
Center–surround cells, 430
Center–surround receptive fields, 430–431, 431f
Central canal, 131f
Central cord syndrome, 280f–281f
Central diplopia, 857
Central disc herniations, 307
Central gray matter, 33
Central gyrus, 27f
Central herniation, **141–142**, 181
Central lateral nucleus, 269
Central nervous system (CNS)
  components, 14, **21–22**
  embryological development, **15–16**, 15f
  primary tumors, 152
  reptilian, 16f
Central nucleus, 768, 787
Central pontine myelinolysis, 750
Central scotomas, 445
Central sulcus
  CT image, 102f, 103f
  location, 24f, 26f, 27f, 28, 43f, 214, 215f
  MRI, axial T1-weighted images, 108f, 109f
  MRI, sagittal T1-weighted images, 112f, 113f
  "omega," 250
Central sulcus of Rolando, 24
Central tegmental tract, 482, 586
Centromedian nucleus, 273t, 275, 699
Cephalic flexure, **15f**
Cephalohematomas, 150
Cerebellar arteries, 668
Cerebellar astrocytomas, 154
Cerebellar cortex, 658, 659f, 660f
Cerebellar glomerulus, 659, 661f
Cerebellar hemispheres, 98f, 104f, 654, 661
Cerebellar nuclei, 657f, 658
Cerebellar peduncles
  adenocarcinoma metastasis, 682–683, 685f
  anatomy, 656, 657f
  attachment to brainstem, 656f
  lesions, 671
  visual system and, 463
Cerebellar tonsils
  anatomy, 655
  CT image, 98f
  inferior view, 739f
  MRI, axial T1-weighted images, 104f
  MRI, sagittal T1-weighted images, 112f
Cerebellopontine angle, 464, **479**, 484
Cerebellum (metencephalon)
  anatomy, 15f, 26f, **654–668**
  attention and, 862
  basal ganglia and, **34**
  circuitry, 587–588
  CT image, 99f, 100f
  functional regions, 657t
  hypertensive hemorrhage and, 149
  input pathways, 664–667, 664t
  lateral view, 655f
  localization of lesions, 670–675
  microscopic circuitry, 658–660
  motor system and, 220
  MRI, axial T1-weighted images, 105f, 106f
  MRI, coronal T1-weighted images, 110f
  MRI, sagittal T1-weighted images, 112f, 113f
  output pathways, 660–664, 662f, 663t
  pathways, 658f
  sagittal view, 655f
  signs and symptoms of disorders, 671
  somatic organization of inputs, 665f
  subregions, 656f
  vascular supply, 668
  vascular territories, 668f
Cerebral amyloid angiopathy, 871
Cerebral aqueduct. *see also* Aqueduct of Sylvius
  CSF flow, 132
  location, 131f
  MRI, axial T1-weighted images, 106f
  MRI, coronal T1-weighted images, 110f
Cerebral artery watersheds, 379f
Cerebral atrophy, 873–874
Cerebral contusions, 142, 784
Cerebral cortex
  arterial supply, 372f
  basal ganglia and, 698
  classification, 766t
  cytoarchitectonic areas, 30
  functional areas, 368, 368f
  gray matter in, 21
  inferior view, 26f
  lateral view, 26f
  medial view, 26f
  motor areas, **28–29**
  motor system and, 220
  organization, **24–31**, 24f
  primary sensory areas, **28–29**
  regional classification, **29–31**
  somatotopic maps, 29f
  superior view, 26f
Cerebral edema, 142

Cerebral hemispheres
blood supply, 375f
composition, 21f
dominant, 43, 826, 827–839
eye movements and, 552
language, 827–839
nondominant, 829, **839–847**
specialization, 825–827, 826t
surface anatomy, **25–27**
venous drainage, **386–387**, 386f
Cerebral peduncles
components, 581
CT image, 100f
inferior view, 739f
internal capsule and, 225
location, 38f, 39f
midbrain and, 463
MRI, axial T1-weighted images, 106f
Cerebral perfusion pressure (CPP), 138
Cerebral vasospasm, 148
Cerebrospinal fluid (CSF)
absorption, 132
circulation, 130f
cisterns and, 132–133
CT image, 98f
elevated protein levels in, 312
hydrocephalus and, 151
infectious meningitis and, 155t
location, 14
meningeal irritation and, 154
MRI, axial T1-weighted images, 104f, 105f
normal-pressure hydrocephalus, 199–200
production, 128, 132
transependymal absorption of, 191
ventricles and, **128–133**
xanthochromic, 162
Cerebrovascular disease, 795
Cervical spinal cord, 304f
Cervical enlargement, 22f, 23, 217, 305, 340
Cervical flexure, 15f
Cervical nerve roots, 22
Cervical plexus, 341
Cervical segments, 370
Cervical stenosis, 317
Cervicomedullary junction, 15f, 122, 130f, 225, 461, 581, 583f
Chemical synapses, 19
Chemotactic trigger zones, 134, 607
Chemotherapy, 153
Cheyne–Stokes respiration, 605
Chiasm, 26f
Chief complaint (CC), **5**
Chief trigeminal sensory nucleus, 476, 478
Cholesterol emboli, 381
Cholinergic neurons, 778
Chorea, 707, **708–709**
Chorea gravidarum, 709
Choreoathetosis, 708
Choroid epithelial cells, 128, 134
Choroid fissure, 775
Choroid plexus
CSF and, 16
CT image, 99f, 100f, 101f, 102f
MRI, axial T1-weighted images, 106f, 107f
Chronic, definition, 866
Chronic meningitis, 872
Chronic mental status changes, 867, **867–875**, 869t. *see also* Altered mental status; Specific condition
Chronic subdural hematomas, **143**, 144f, 872
Chronological sequences, 863
Ciliary ganglia, 473, 540
Ciliary muscles, 473, 532, 541, 542f
Ciliospinal reflex, 543–544
Cingulate bundle, 779
Cingulate gyrus
anatomy, 763, 764f
limbic system and, 42f, 779, 848f
location, 25, 26f
MRI, coronal T1-weighted images, 110f, 111f
MRI, sagittal T1-weighted images, 112f
Cingulate sulcus, 26f, 102f, 108f
Cingulum, 779
Circle of Willis, 44, 45f, **369–370**, 369f, 370f
Circuit of Papez, 774f
Circumferential arteries, 609
Circumventricular organs, 134f
Cisterna magna, 98f, 104f, 112f, 133f
Cisterns, **132–133**
Clasp-knife rigidity, 706
Climbing fibers, 658
Clivus, 112f, 124f
Clonic movements, 791
Clonic phase, 793
Clonus, 66
Closing-in phenomenon, 851
Clubbing, 10
Cluster headaches, 136
CN I. *see* Olfactory nerve
CN II. *see* Optic nerve
CN III. *see* Oculomotor nerve
CN IV. *see* Trochlear nerve
CN IX. *see* Glossopharyngeal nerve
CN V. *see* Trigeminal nerve
CN VI. *see* Abducens nerve
CN VII. *see* Facial nerve
CN VIII. *see* Vestibulocochlear nerve
CN X. *see* Vagus nerve
CN XI. *see* Spinal accessory nerve
CN XII. *see* Hypoglossal nerve
Coccygeal cord, 304
Cochlea, 124f, 485, 486f
Cochlear ducts, 485
Cognition, 702–704
Cognitive impairment, 199–200
Cogwheel rigidity, 707, 712
Cold water calorics, 553
Collateral sulcus, 25, 27f, 110f, 763, 775
Color
anomia, 836, 856–857
perception, 856
recognition areas, 855f
vision, 58, 435–436
Coma
causes, 604t
circulatory function, 604
definition, 73, 602t
hand-dropping test, 79
neurologic exam, **73–78**, 74t
pupil abnormalities, 605t
related disorders and, **601–605**
saccadic eye movements and, 79
transtentorial herniation, 140
vestibulo-ocular reflex and, 61
Commissures, 22
Common carotid arteries, 117f
Common peroneal nerve, 359–360
Communicating hydrocephalus, 151
Complex cells, 438
Complex partial seizures, 793, 794t
Complex regional pain syndrome causalgia, 312
Complicated migraine, 135
Compound motor action potential (CMAP), 349, 350f, 356–357
Compound sensory nerve action potential (SNAP), 349
Comprehension, 54, 831, 832
Compression, 312
Computed tomography (CT), **84–87**
acute blood, 146
comatose patients, 604
with contrast material, 87f
epidural hematomas, 178f–179f
helical scanners, 85
Hounsfield units, 86t
intracranial hemorrhage, 144f–145f, 184f–185f
MRI compared with, 87t

neuroradiological atlas, **98–103**
normal-pressure hydrocephalus, 201f–202f
scanning gantry, 85f
single-slice, 84
subdural hematomas, 171–173
without contrast, 85f, 148
Concentric visual loss, 443
Conceptual neglect, 845
Concussion, 142, 784, 800–801
Conditioning, classical, 782
Conduction aphasia, 834
Conductive hearing loss, 491
Cones, 429
Confabulation, 785, 802–803, 808f–809f, 851
Confluence of sinuses, 129f, 387
Confrontation testing, 440–441
Congenital disorders, 795
Congophilic angiopathy, 149
Consciousness, 380, 589–598, 604, 859–860
loss of, 604
Consensual response, 59, 540
Construction tasks, **56**, 846
Constructional abilities, 845
Content words, 831
Contralateral homonymous hemianopia, 378, 441, 442f
Contralateral homonymous inferior quadrantanopia, 434, 442f
Contralateral homonymous superior quadrantanopia, 433, 442f
Contrast materials, 86
Contrecoup injuries, 148
Contusions, 145f, 148, 149f
Conus medullaris, 22f, 162, 304, 304f
Conus medullaris syndrome, 318
Convergence, impaired, 551
Convergence movements, 60, 550
Convergence–retraction nystagmus, 551
Conversion disorder, **78–79**
Cooperation, assessment in neurologic exam, **53–54**
Coordination, 51t, **68–70**, 80t, 661. *see also* Gait; Specific conditions
Corneal reflexes, 60, 60f, 75, **484**
Cornu Ammonis (CA), 772, 776
Corona radiata, 101f, 102f, 108f, 222
Coronal plane, 17f
Corpus callostomy, 838
Corpus callosum
composition, 25
CT image, 101f
lesions, 838
limbic system and, 42f
location, 24f, 25, 26f
MRI, axial T1-weighted images, 107f, 108f
MRI, coronal T1-weighted images, 110f, 111f
MRI, sagittal T1-weighted images, 112f
Cortex
classification by type, 824f
layers, 29, 30f
Cortical basal ganglionic degeneration, 715, 871
Cortical blindness, 855
Cortical deafness, 838
Cortical dementias, 868
Cortical lesions, 382
Cortical maps, 214
Cortical sensation, 71–72
Cortical sensory loss, 270, 278, 382
Cortical signs, 382
Cortical taste area, 482
Cortical veins, 387
Corticobulbar tracts, 223f, 224f, 225, 586
Corticoid areas, 765, 768
Corticomedial nuclei, 768, 770, 787
Corticopontine fibers, 665
Corticospinal tracts, 32–33, 33f, 224f, 225, 586
Corticosteroid hormones, 745
Corticothalamic projections, 37f
Corticotropin-releasing hormone (CRH), 743f, 746f
Cortifugal fibers, 223f
Cortisol, 745
Coughing, 606
Coup contrecoup injuries, 169–170
Coup injury, 148
Cover–uncover test, 536
Cranial nerve nuclei, 584–586
Cranial nerve parasympathetic nuclei, 229
Cranial nerves. *see also* Individual cranial nerve names (e.g., Trigeminal nerve [CN V]).
assessment in neurologic exam, 51t
brainstem and, 38f–39f, 462f, 463f
classification of nuclei, 468t
combinations, 502–503
courses, **469–471**
exit foramina, **464–466**, 465f, 466t
functions, 461t, **469–471**
location, 14f
minimal screening exam, 80t
motor functions, 470t
neurologic exam, **58–63**
nuclei, 21
organization, **466–469**
overview, 40t
pairs, 22
parasympathetic ganglia, 471t
parasympathetic pathways, 473f
peripheral sensory ganglia, 471t
sensory functions, 470t
signs of dysfunction, 613
Cranial trauma, 75t
Cranial vault, **122–128**
Craniosacral division, 24
Craniosacral nervous system. *see* Parasympathetic nervous system
Craniotomy, **163**
Cremasteric reflex, 67
Crescent-shaped hematomas, 143
Creutzfeldt–Jakob disease, 161
Cribriform plate, 464, 465f, 471, 770
Crista ampullaris, 490
Crossed adduction, 66
Crossed response test, 843
Crossed straight-leg raising test, 316
Crura, 779
Crural monoparesis or monoplegia. *see* Weakness, unilateral leg
Crying, 606
Cryptococcal meningitis, 159
CT-myelography, 86
Cuneate fasciculus, 267
Cuneocerebellar tracts, 665, 667
Cuneus, 25, 26f, 112f
Cupula, 490
Cushingoid appearance, 747
Cushing's disease, 747
Cushing's syndrome, 747
Cushing's triad, 139
Cutaneous nerves, 342, 343f
Cysticercosis, 160, 194f–196f, 899–900, 903f
Cysts, 196–199, 198f–199f
Cytoarchitectonic areas, 30, 31t
Cytomegalovirus (CMV), 159
Cytomegalovirus polyradiculopathy, 317
Cytotoxic edema, 135

D

Dawson's fingers, 242
Deafness, 73, 838
Decerebrate posturing, 606
Decerebrate reflexes, 77
Decision making, 850
Declarative memory, 781–782, 863
Decorticate posturing, 606
Decorticate reflexes, 77
Decrements, 350

Deep middle cerebral veins, 387
Deep tendon reflexes, 37f, 38, 64–66, 66f, 66t, 280f
Déjà vu, 846
Dejerine–Roussy syndrome, 276
Delirium, 603, 865–867
Delusions, **57**
Dementia, **867–875**
  Blessed scale, 870t
  definition, 603
  with Lewy bodies, 715
  progressive, 901–902, 904f
  pugilistica, 715, 872
Demyelination. *see also* Multiple sclerosis; Guillain–Barré syndrome
  immune-related, 312
  nerve conduction studies, 312, 349–350
  spinal cord, 298f
  vertigo and, 494
Dendrites, 17
Density, tissue, 84
Dentate gyrus, 113f, 772–773
Dentate nucleus, 658
Dentatorubropallidoluysian atrophy, 715
Depression, 716, 799–800, 831
Depression, assessment in neurologic exam, **57–58**
Dermatological exam, 10
Dermatomes, 264, **307–308**, 308f
Dermatomyositis, 314
Detrusor reflex, 282
Detrusor–sphincter dyssynergia, 284
Dexamethasone suppression test, 748
Dextrose, in coma, 604
Diabetes insipidus (DI), **749–750**
Diabetic neuropathy, 312, 357–358
Dialysis dementia, 873
Diaphragma sella, 129f, 739
Diencephalon, 15f, 26f, 27f, 271
Differential diagnosis, **7**, **8**, 8t
Diffuse axonal shear injury, 142
Diffuse projection systems, 589
Diffuse subcortical disorders, 716
Digit span, 53, 864
Diplopia, **535–536**
  assessment in neurologic exam, 60
  cerebral, 857
  diagonal, 536
  horizontal, 539, 540, 555–556, 558, 563–564
  increased ICP and, 139
  midbrain infarct, 641, 642, 643f, 644f
  neoplasms and, 189, 192–193
  PComm aneurysm, 554–555, 556f
  vertical, 538, 539, 557
Direct response, pupillary, 59
Directed attention, 860
Directional motor bias, 843
Disc emboli, 381
Disc herniations
  C5–C6, 322f
  C6–C7, 324–325
  C7–T1, 326–327
  cauda equina compression, 332–333, 334f–335f
  central, 307
  far lateral, 306
  L4–L5, 329, 330f
  L5–S1, 327, 330f–332f
  nerve roots and, 305
  posterolateral, 306
  radiculopathies and, 315
Discectomy, 319
Disconnection syndromes, 825, **838–839**, 838f
Disinhibited behaviors, 44, 850–852
Dissection, carotid or vertebral artery, 381, **385**
Dissociative state, 602t, 604
Distal symmetrical polyneuropathy, 279f, 312
Divergence, eye movements, 550
Dix–Hallpike positional testing, 493
Dizziness, 492–494, 512–513, 515f
Doll's eyes, 76
Dome of aneurysm, 146
Dominant hemisphere. *see* Cerebral hemispheres
Dopamine, 20t, **595–596**, 743f
Dopaminergic antagonists, 714
Dopaminergic nigrostriatal pathway, 698
Doppler ultrasound, 95, 384
Dorello's canal, 465f, 535
Dorsal cochlear nuclei, 467f, 487, 585
Dorsal column tubercles, 39f
Dorsal columns, spinal cord, 217f, 218f. *see also* Posterior column–medial lemniscal system
Dorsal horn, spinal cord, 216, 217f, 218f
Dorsal interossei, 345
Dorsal motor nucleus of vagus, 283t, 466f, 467f, 497, 585
Dorsal nerve roots, 22, 216, 218f
Dorsal orientation, 16f
Dorsal root ganglia, 34, 216, 217f, 264
Dorsal scapular nerve, 340f
Dorsal spinocerebellar tracts, 665
Dorsal striatal pathways, 702
Dorsolateral convexity lesions, 850
Dorsolateral parieto-occipital cortex, 857–858
Dorsomedial nuclei, 741
Double crossed pathways, 661, 662f
Double vision. *see* Diplopia
"Down and out" eye position, 536
Downgaze, 550
Down's syndrome, 874
Drawing tests, 56f, 845
Drift, assessment in neurologic exam, 64f
Drives, 787
Drugs, vertigo and, 494
Duchenne muscular dystrophy, 314
Dura mater
  anatomy, 126
  CT image, 98f
  location, 16, 125, 128f
  MRI, axial T1-weighted images, 104f
  spinal, 306f
Dural sac, 305
Dural venous sinuses, 128, 129f
Duret–Bernard hemorrhage, 180, 182f
Dynamic contrast functional MRI (perfusion MRI), 96
Dynorphin, 271
Dysarthria
  articulation and, 62, 501
  basis pontis infarct and, 626, 631f
  Broca's aphasia and, 831
  hemiparesis and, 404–405, 409f
Dysarthria pure motor hemiparesis, 233
Dysconjugate gaze, 60, 536, 613
Dysdiadochokinesia, 68, 673
Dysesthesia, 276
Dyskinesias, 705, 714
Dyskinetic gait, 241t
Dyslexia, 836
Dysmetria, 672
Dysnomia, 835
Dysphagia, 501–502
Dysphasia, **829–830**
Dysrhythmia, 672
Dystonia, **707–708**
Dystonia musculorum deformans, 707

E

Ears, innervation, 503
Echo time (TE), 88
Echocardiograms, 384
Ectodermal thickening, 738f
Edema. *see also* Papilledema
  cerebral, **142**
  cytotoxic, 135
  hypertensive hemorrhage and, 149
  vasogenic, 135
Edinger–Westphal nucleus, 467f, 473, 533, 540, 551, 584

Effacement, 137
Efferent pathways, 22
Ejaculatory function, 284–285
Elderly patients, chronic subdural hematomas in, 143
Electrocardiogram, 384
Electrical synapses, 19
Electroconvulsive therapy (ECT), 785
Electrodes, 718
Electroencephalogram (EEG)
  centrotemporal spikes, 796
  comatose patients, 604
  description, 96
  intracranial monitoring, 797
  seizures, 794
Electrolyte abnormalities, 795, 872
Electromyography (EMG). *see also* Nerve conduction studies
  clinical concept, **349–351**
  demyelination and, 312
  motor neuron disease and, 243
  MUPs and, 351
  myasthenia gravis and, 313
  repetitive stimulation and, 363
Elevated intracranial pressure, **137–140**, 138t
Emboli, 380, 381, 612
Emboliform nucleus, 658
Emotional incontinence, 502, 521–522, 524f–525f
Emotions, 702–704, 787
Empty delta sign, 387, 419–420, 422f–423f
Empyema, 156
En bloc turning, 713
Encephalitis, 158, 494
Encephalopathic, definition, 866
Encephalopathies, 865, 868
Endogenous opiate peptides, 271
Endolymph, 485, 486f
β-endorphin, 271
Enkephalin, 271, 701
Enteric nervous system, 228
Entopic phenomena, 440t
Entorhinal cortex, 42f, 775, 777–779
Entrapment neuropathy, 312
Environmental dependency syndrome, 851
Ependymal cells, 128
Ependymoma, 154
Epidural abscess, 156
Epidural hematoma, **143**, 144f, 178f–179f
Epidural metastases, 317
Epidural space, 127, 128f
Epilepsy
  case report, 809–812, 814f–816f
  classification of seizures, 790f
  extratemporal, 798
  gelastic, 502
  generalized, 791
  localization-related, 791
  patient H.M., 780–782
  seizures and, **790–798**
  surgery for, 797
  treatments, 796–797
Epileptic activity, EEG, 96
Epithalamus, 271
Epstein–Barr virus, 160
Equilibrium, control, 664
Erb–Duchenne palsy, 346, 353
Erectile function, 284–285
Erythrocyte sedimentation rate (ESR), 136–137
Erythropsia, 857
Escherichia coli, 156t
Esophageal phase, 501
Esotropia, 536
Essential tremor, 711
Evoked potentials, 96, 445
Excitatory postsynaptic potentials (ESPSs), 19
Excitory input terminals, 18f
Exercise tolerance, 362–363
Exotropia, 536
Explosive speech, 674
Expressive aphasia, 43
Extensor posturing, 77, 606
External auditory meatus, 123f, **465f**
External capsule, 107f
External carotid artery (ECA), 45f, 117f
External cuneate nucleus, 667
External striated muscle sphincter, 284
External ventricular drains, 152
Extinction
  assessment in neurologic exam, 71–72
  definition, 44
  on double simultaneous stimulation, 56, 59, 842
Extorsional movements, 530
Extracranial hemorrhage, **150**
Extrageniculate pathways, 432–433, 432f
Extraocular movements, **59–60**, 76, 180, 189
Extraocular muscles, **530–531**, 531f, 532t
Extraocular nerves, **532–535**
Extraocular nuclei, **532–535**
Extratemporal epilepsy, 798
Extremities, assessment in neurologic exam, 10
Eye movements. *see also* Extraocular movements
  abnormalities, 673–674
  basal ganglia channels, 702–704
  cortical regions in control, 551f
  forebrain in control, 551–552
  horizontal, 548–549, 548f
  hydrocephalus and, 151
  intorsion, 538
  right- and wrong-way, 552–553, 553f
  supranuclear control, **548–553**
  vergence, 550
  vertical, 550
  wrong-way eyes, 562, 567f, 613, 632–633, 638f–639f
Eyelids, 546, 551
Eyes
  anatomy, **428–431**
  closure, 546
  CT image, 99f
  opening, 546

F

Face, innervation, 502
Face recognition areas, 855f
Facial arteries, 116f, 117f
Facial asymmetry, 76
Facial canal, 479
Facial colliculi, 39f, 463, 479, 481f
Facial diplegia, 61, 237
Facial expression, 61, 479t
Facial nerve (CN VII)
  anatomy, 38f, 39f
  corneal reflexes, 76
  expression and, 61
  facial asymmetry, 76
  function, 40t, 461t, **479–482**
  grimace response, 76
  lesions, 482–484
  location, 464
  muscles of articulation and, 62
  pathways, 480f
  taste and, 61
Facial nucleus, 479, 584
Facial sensation, 60–61, 478
Facial weakness, isolated. *see* Weakness, unilateral facial
Faciobrachial paresis or plegia. *see* Weakness, unilateral face and arm
Factitious disorder, **79**
False localization, 825
Falx cerebri, 126f, 129f
  CT image, 100f–103f
  MRI, axial T1-weighted images, 107f, 108f, 109f
  MRI, coronal T1-weighted images, 110f
Family history (FHx), 796
Far lateral disc herniations, 306

Fascicle, white matter in, 22
Fasciculations, 62–63, 63f, 231
Fasiculus cuneatus, 39f
Fasiculus gracilis, 39f
Fastigial nucleus, 658, 662f
Fat, epidural, 128, 305, 306f
Fat, subcutaneous, 98f, 104f, 105f
Fat emboli, 381
Fatal familial insomnia, 161
Febrile seizures, 795
Feedback inhibition, 659
Femoral nerve, 341f, 345f, 357–358
Femoral neuropathy, 348
Festinating gait, 713
Fiberoptic laryngoscopy, 501
Fields of Forel, 704f, 705
"Fight or flight" response, 23f
Filum terminale, 304
Fimbria of fornix, 113f, 779
Fine movements, 64, **239–240**
Fine touch, 34
Finger–nose–finger test, 68f, 69f, 670f, 672f
Fingers
  agnosia, 43, **55**
  extensors, **239**
  flexors, 66f
  isolated movements, **240**
  nerve functions in, 344t
  rapid tapping, 672
First echo in MRI, 91
Flaccid acontractile bladder, 284
Flaccid areflexic bladder, 284
Flexor posturing, 77, 606
Flocculus, 655, 667
Flocculonodular lobe, 654, 657, 662f, 663
Flow artifacts, 92
Fluency, 831
Fluorodeoxyglucose PET scan, 812
Focal dystonia, 707
Focal neurologic deficits, 143, 382
Focal seizures, 790
Follicle-stimulating hormone (FSH), 743f, 746, 749
Follicle-stimulating hormone deficiency, 750
Foramen lacerum, 465f
Foramen magnum
  brainstem and, 607
  CT image, 98f
  CT scan bone windows, 124f
  location, 122, 123f, 465f
  MRI, axial T1-weighted images, 104f
  MRI, coronal T1-weighted images, 110f
  MRI, sagittal T1-weighted images, 112f
Foramen of Luschka, 130f
Foramen of Magendie, 130f
Foramen of Monro
  CT image, 100f
  location, 131f, 197–199
  MRI, axial T1-weighted images, 107f
  MRI, coronal T1-weighted images, 110f
  MRI, sagittal T1-weighted images, 112f
Foramen ovale
  cranial nerve exits, 464, 475
  CT scan bone windows, 124f
  location, 123f, 465f
  patent (cardiac), 381
  schwannoma, 508–509, 510f–511f
Foramen rotundum, 464, 465f, 475, 505, 507f
Foramen spinosum, 123f, 124f, 127, 128f, 465f
Foraminotomy, 319
Forced gait, 70, **240**
Forebrain (prosencephalon), 15f, 551–552, 592
Foreign accent syndrome, 837
Form analysis visual, 435–436
Formed visual hallucinations, 440
Formulation, in H&P, 7
Fornix, **778–789**
  anatomy, 26f
  columns, 779
  CT image, 101f
  hippocampal formation connections, 742, 778
  limbic system and, 42f
  location, 41
  memory pathways and, 778–780
  MRI, axial T1-weighted images, 107f
  MRI, coronal T1-weighted images, 110f, 111f
  MRI, sagittal T1-weighted images, 112f
  structure, 778f
Fortification scotoma, 135, 440
Fourth-nerve palsy, 538
Fourth ventricle
  anatomy, 581
  CSF and, 16
  CT image, 99f
  location, 131f, 463
  MRI, axial T1-weighted images, 105f
  third ventricle and, 132
Fovea, function, 428
Freezing, parkinsonian, 714
Frontal craniotomy, 163
Frontal eye fields, 552
Frontal horn
  CT image, 101f
  lateral ventricle, 100f, 131
  MRI, axial T1-weighted images, 107f
Frontal lobes
  anatomy, **847–849**
  association cortex (heteromodal), 862
  basal ganglia outputs and, 703f
  "butterfly" astrocytoma, 895f
  cerebral cortex, 24
  CT image, 102f
  diagnosis of disorders, 854t
  disorders, **850–854**
  evaluating function, 851t
  falcine meningioma, 896f
  functions, 847t
  gait abnormality, 240t, 853
  lesion-related conditions, 44
  lesions, **44**, 716
  location, 24f
  MRI, sagittal T1-weighted images, 112f, 113f
  partial seizures, 792t
  syndromes, 847t, 875
Frontal operculum, 25, 42f, 100f, 107f
Frontal pole, 26f, 27f, 107f
Frontal release signs, 44, 57, 67, 851, 853
Frontal sinuses, 99f, 100f, 107f
Frontopontine fibers, 223f
Frontotemporal dementias, 871
Function words, 831
Functional gait disorder, 241t
Functional magnetic resonance imaging (fMRI), 96–97
Functional neuroimaging, **95–97**
Functional testing, 64
Fungal infections, **160–161**
Fusiform aneurysm, 146
Fusiform gyri, 25, 27f, 856
Fusion, vertebral bodies, 319

G

GABA (gamma-aminobutyric acid), 20t, 275, 598, 699
Gadolinium, 92, 93f
Gag reflex, 62, 76, 502, 606
Gait
  assessment in neurologic exam, 51t
  bedside testing, **240**
  disorders, **241–243**
  frontal, 853
  hydrocephalus and, 151–152
  localization of disorders, 240t–241t
  minimal screening exam, 80t
  motor exam and, **68–70**
  progressive difficulty, 199–200
  testing, 70f
  unsteadiness, 199
  unsteady, 712
  wide-based, unsteady, 671, 673
Gait apraxia, 70
Ganglia
  PNS, **21–22**
  white matter and, 22
Ganglion cells, 430, 431f
Gasserian ganglion, 475
Gate control theory of pain modulation, 270
Gaze palsy, 540
Gaze persistence, 378
Gaze preference, 405, 407–408, 552
Gegenhalten, 707, 853
Gelastic epilepsy, 502
General appearance, 9
General exam, 869
General paresis, 157
General somatic efferents (GSEs), 466–469
General somatic nuclei, 469
General somatic sensory (GSA) inputs, 585
General visceral afferents (GVA), 586
General visceral sensation, 503
Generalized seizures, 790, 793
Generalized tonic-clonic seizures, 793
Geniculate ganglion, 479
Genitalia, assessment in neurologic exam, 10
Genitofemoral nerve, 341f
Gentamicin, 494
Genu, 25, 225, 479
Geographic orientation, 846
Gerstmann–Sträussler–Scheinker disease, 161
Gerstmann's syndrome, 43, **55**, 836–837
Gestalt, 839, 846
Giant cell arteritis, 136–137
Glabellar response, 67
Glial cells, 17
Glial tumors, 153
Glioblastoma multiforme, 153, 806–807, 813f
Global aphasia, 832, 834
Global attention, 839
Global cerebral anoxia, 784
Globose nucleus, 658
Globus pallidus
  basal ganglia outputs, 699f
  CT image, 100f
  deep blood supply, 374f
  internal segment, 698
  location, 691
  MRI, axial T1-weighted images, 107f
  MRI, coronal T1-weighted images, 111f
  MRI, sagittal T1-weighted images, 112f
Glomeruli, olfactory bulb, 770
Glomus jugulare, 500, 517–518, 520f
Glossopharyngeal nerve (CN IX)
  anatomy, 38f, 39f
  disorders, 500
  function, 41t, 461t, **495**
  gag reflex and, 62, 76
  location, 464
  palate elevation and, 62
  pathways, 496f
Glossopharyngeal neuralgia, 500
Glove and stocking pattern of sensory loss, 312
Glutamate, 20t, 698, 701
Glycine, 20t
Go-no-go task, 852
Goldmann perimetry, 441
Golgi cells, 659
Gracile fasciculus, 267
Gradient coils in MRI, 88
Grand mal seizure, 793
Granule cells, 658, 770
Graphesthesia, 71–72, 72f, 278f
Grasp reflexes, 44, 67, 853
Gray matter
  central, 33
  cortical, 656
  function, **21–22**
  localization, 21f
  MRI, axial T1-weighted images, 105f
  spinal cord, 216, 217f
Great radicular artery of Adamkiewicz, 219f, 220
Great vein of Galen, 129f, 386
Greater petrosal nerve, 480
Grimace response, 76
Growth hormone (GH), 743f, 746
Growth hormone deficiency, 750
Growth hormone–inhibiting hormone (GIH), 743f
Growth hormone–releasing hormone (GHRH), 743f
Guillain–Barré syndrome, 312, 317
Gustatory nucleus, 495
Gyri, 24
Gyrus rectus, 25, 27f, 99f

H

Habenula, 768, 790
Habenulointerpeduncular tract, 790
Habits, memory and, 782
Habituation, 782
Haemophilus influenzae, 156t
Hair cells, inner ear, 485, 490
Hallucinations
  assessment in neurologic exam, **57**
  auditory, **858–859**, 899–900, 903f
  definition, 440t
  description, 44
  formed visual, 440
  olfactory, 806–807, 813f
Hamstring muscles, 345
Hand-dropping test in coma, 79
Handedness, 825–826
Head tilt, 538, 539
Head trauma, **142–143**, 166–173, 169t, 188, 190, 795, 800–801, 872
Headaches, **135–137**
  cluster, 136
  differential diagnosis, 136t
  hydrocephalus and, 189, 191–193
  increased ICP and, 138
  ischemic stroke and, 382, 612t
  meningeal irritation and, 147
  migraine, 451, 453, 454f
  posttraumatic, 136
  retro-orbital, 390–392
  tension-type, 136
  vascular, 135
  visual loss and, 196–199
Hearing, 61, 61f, 841
Hearing loss, 491–492, 512–513, 515f
Heart, assessment in neurologic exam, 9
Heart rates, 606
Heat conservation, 743
Heat dissipation, 743
Heavy-metal toxicity, 873
Hebb rule, 777
Heel–shin test, 68–69, 69f, 672f
HEENT assessment in neurologic exam, 9
Helical CT scanners, 85
Hematocrit effect, in subdural hematoma, 145f, 146
Hematomas, 143, 146
Hemianopia
  bitemporal, 441, 442f, 448–449
  homonymous, 390–392, 442f
  left, 413–415, 417f
  MCA infarct, 405, 407–408
Hemiansomatognosia, 846
Hemiballismus, 701, 709
Hemichorea, 709
Hemicord lesions, 280f
Hemicraniectomy, 384, 417f
Hemineglect syndrome
  assessment in neurologic exam, 56
  clinical concept, **841–846**
  frontal cortex and, 841

left, 411–415, 414f, 417f, 888–890, 890f
lesions causing, 841f
parietal cortex and, 44, 841
testing for, 842
types, 842
visual, 863
Hemiparesis, **239–241**, 404–405, 409f, 622, 625f, 626, 631f. *see also* Weakness, unilateral
Hemiplegia. *see also* Weakness, unilateral
left, 413–415, 417f
right, 405, 407–408
transtentorial herniation, 140–141
Hemispherectomy, 893f
Hemispheric lesions, 382
Hemispheric specialization, 825
Hemorrhage
cavernous angioma, 644–645, 648f
cerebellar, 669
on CT scans, 86
Duret–Bernard, 180, 182f
head trauma and, 169t
intracranial, 92, **143–152**
intracranial mass lesions and, 137
IV anticoagulation and, 180–181
left frontal, 884f
ophthalmoplegia and, 565f
peri-Sylvian, 885f–886f
right parietal, 419–420, 422f–423f
thalamic, 552
Hemosiderin, 92
Hemotympanum, 510
Heparin, 383
Hepatic failure, 872
Herniations, 137, 140, 190f, 307f
Herpes encephalitis, 765f
Herpes simplex viruses, 158, 159
Herpes zoster, 317, 323
Heschl's transverse gyri, 42f, 113f, 488
Heteromodal association cortex, 42, 43f, 823–827, 824f
Hiccuping, 606, 644–645, 648f
Higher-order association cortex, 823–827
Hindbrain (rhombencephalon), 15f
Hippocampal formation, 763, 765, 767f
amygdala and, 789
anatomy, **771–780**
circuitry, 776–777
coronal section, 773f
cortical connections, 849
embryology, 772f
hippocampal commissure, 778, 779
hippocampal gyrus (hippocampus proper), 106f, 113f, 776f
hippocampal head, 775
hippocampal sclerosis, 785, 795, 809–812, 814f–816f
hippocampal sulcus, 775
hippocampal tail, 775
limbic system and, 42f, 742
location, 41
memory system and, 772–776
MRI, coronal T1-weighted images, 110f
sagittal section, 775f
Hippus, 59, 545
Histamine, 20t, **597–598**
History and physical exam, 5, 50, 850–853, 869
History of present illness (HPI), **5–6**
Hoarseness, 500–501, 516, 519f
Hoffmann's sign, 66, 231
Homeostasis, 738
Homonymous hemianopia, 378, 391–392, 442f, 449–450, 452f
Homonymous inferior quadrantanopia, 434
Homonymous superior quadrantanopia, 433
Homonymous visual field defects, 382, 432, 439, 440t
Homunculi, 28, 29f, 214, 216f
Hoover test, 79
Horizontal cells, 430
Horizontal gaze, 61, 549–550, 549f
Horizontal gaze center, 549
Horizontal plane, 17f
Horizontal sections, radiographic, 17
Hormones, 743–750, 743f, 744f, 745f
Horner's syndrome, 346, **543–544**, 620–621, 623f–624f
Hounsfield units (HU), 86t
Human immunodeficiency virus (HIV), 159–160
Huntington's disease, 34, 701, 708, 715, **716–717**, 720–722, 727f–728f
Hydrocephalus, **151–152**
cerebellar disorders, 671
ex vacuo, 152
hemispherectomy and, 893f
intracranial mass lesions and, 137
noncommunicating, 189, 191–193, 194f–196f
normal-pressure, 199–200, 201f–202f, 872
obstructive, 198f–199f
Hyperactive stretch reflex, 38
Hyperacusis, 509–510
Hypercoagulability, 383t
Hypercolumn, 439f
Hyperdense, in CT imaging, 85, 146
Hyperglycemia, 384
Hyperintense areas, in MRI, 89
Hyperkinetic movement disorders, 34, 690, 701, 718, 722f
Hyperpathia, 276
Hyperreflexia, 63–64, 66, 231
Hyperreflexic bladder, 284
Hypertensive hemorrhage, 149
Hyperthyroidism, 748, 872
Hypertropia, 536, 538
Hyperventilation, 605
Hypesthesia, 276
Hypoactive stretch reflex, 38
Hypodense, in CT imaging, 85, 146
Hypoglossal nerve (CN XII)
canal, 464, 465f
foramen, 465f, 499
function, 40t, 461t, **499–500**
location, 38f, 39f, 464
MRI, axial T1-weighted images, 104f
muscles of articulation and, 62
nuclei, 466f, 467f, 499, 582, 584
tongue muscles and, 62–63
trigone, 463, 500
Hypoglycemia, 795
Hypogonadism, 749
Hypointense areas, in MRI, 89
Hypokinesia, **706**
Hypokinetic movement disorders, 34, 690, 701
Hypomimia, 713
Hyponatremia, 749, 753
Hypophysial portal system, 744
Hypophysial portal veins, 744
Hypophysis. *see* Pituitary gland
Hyporeflexia, 63–64, 231
Hypothalamic lesions, 754–756, 758f
Hypothalamic–limbic pathways, 742
Hypothalamic nuclei, **740–741**, 740f, 741f
Hypothalamic–pituitary axis, 746
Hypothalamic sulcus
formation, 738
median view, 739f
Hypothalamic systems, **738–739**
Hypothalamus
anatomy, 15f, 26f, 861
control of the ANS, **741–743**
endocrine functions, **743–750**
formation, 738
limbic system and, 763, 768
location, 271
median view, 739f
pituitary and, **737–759**
regionalized functions, **742–743**
reticular formation projections, 592

Hypothenar eminence, 344
Hypothyroidism, 748, 872

I

Ictal-interictal SPECT difference imaging, 96f
Ideomotor apraxia, 55, 837
Illusions, definition, 440t
Imaging planes, 84
Immunosuppressive agents, 314
Impersistence, 851
Incontinence, 284f, 502, 851
Incus, 485
Infantile amnesia, 786
Infarcts
ACA, 378, 389–390, 395f
AICA, 617, 626–628, 631f
basis pontis, 617, 626, 631f
bilateral medial thalamic, 804–805, 811f
cerebellar arteries, 669
CT scans and, 86
lacunar, 286–287, 290f
large vessel, 381
MCA, 376t–377t, 402f, 406f, 409–410
MCA, inferior division, 880f, 888–890, 890f
MCA, superior division, 876–877, 878f
mechanisms, 380
medullary, 614–615, 621–622, 623f–625f
memory loss and, 784
midbrain, 636f–637f, 639–640, 643f–644f
occipitotemporal, 898–899, 900f
PCA, 182f–183f, 378
pontine basis, 256f, 617
precentral gyrus, 244–249, 252f–253f
SCA, 617, 678f–679f
visual cortex, 897f
Infectious disorders of the nervous system, **154–161**
Inferior anastomotic vein of Labbe, 387
Inferior articular processes, 305
Inferior cerebellar peduncle, 39f, 104f, 110f, 588, 656
Inferior cervical (stellate) ganglion, 228
Inferior colliculus, 39f, 432f, 463, 488, 577, 585
Inferior frontal gyrus, 25, 26f, 100f, 111f
Inferior frontal sulcus, 25, 26f
Inferior glossopharyngeal ganglion, 495
Inferior horn, lateral ventricle, 132
Inferior hypophysial arteries, 744
Inferior occipitotemporal cortex, 856–857
Inferior olivary nuclear complex, 104f, 463, 667
Inferior orientation, 17
Inferior parietal lobule, 25, 26f, 27f, 102f, 108f
Inferior petrosal ganglion, 495
Inferior petrosal sinus, 129f, 387
Inferior rectus muscles, 530
Inferior sagittal sinus, 129f
Inferior salivatory nucleus, 495, 585
Inferior temporal gyrus, 25, 26f, 27f, 110f
Inferior temporal sulcus, 25, 27f
Inferior vagal ganglion, 497
Inferior vestibular ganglion, 490
Infertility, 749
Infratentorial cavity, 126
Infundibulum, 738f
Inhibitory input terminals, 18f
Inhibitory postsynaptic potentials (ISPSs), 19
Inhibitory spiny neurons, 701
Initiative, 849
Inner ear, 485, 485f, 493
Insight, impaired, 851
Inspection, motor exam, 63
Insula, 100f, 106f, 107f, 110f, 113f
Insular cortex, 25, 42f
Insulin-like growth factors, 746
Intention tremor, 673, 710, 711
Interhemispheric fissure, 25, 27f
Intermediate mammillary nuclei, 741
Intermediate zone, spinal cord, 216, 217f
Intermediolateral cell column, 218f, 228, 282, 283t, 543
Internal arcuate fibers, 268, 586
Internal auditory artery, 609
Internal auditory canal, 105f, 485f
Internal auditory meatus, 124f, 464, 465f, 479, 484, 485f
Internal capsule
anatomy, 223f
caudate and, 695
CT image, 100f
deep blood supply, 374f
horizontal section, 694f
lesion, 255f
limbic system and, 779
limbs of, 691
MRI, axial T1-weighted images, 107f
MRI, coronal T1-weighted images, 110f, 111f
MRI, sagittal T1-weighted images, 112f
organization, 225
position, 692f–693f
posterior limb, 268
thalamus and, 695
Internal carotid artery (ICA)
angiographic images, 114f
circle of Willis circulation and, 369, 369f
location, 44, 45f
MRA images, 116f, 117f
MRI, axial T1-weighted images, 104f, 105f
MRI, coronal T1-weighted images, 111f
segments of, 370
stenosis, 398, 401f, 446
subarachnoid hemorrhage and, 146
Internal cerebral vein, 110f, 112f, 387
Internal jugular vein
blood flow into, 128
cerebral hemisphere drainage, 386
dural venous sinuses and, 129f
location, 45f, 46, 129f
Internal medullary lamina, 271
Internal smooth muscle sphincter, 284
Interneurons, 38
Interossei, 344–345
Interpeduncular cistern, 133, 133f
Interpeduncular fossa, 133, 463
Interpeduncular nuclei, 790
Interposed nuclei, 658
Interspinous ligaments, 306f
Interthalamic adhesion, 131f
Interventional neuroradiology, 95
Interventricular foramen of Monro, 132
Intervertebral discs, 305, 306f. *see also* Disc herniations
Intervertebral foramina, 305
Intorsion, eye, 530, 539
Intracerebral hemorrhage, **148–150**
Intracranial aneurysm, 147f
Intracranial circulation, 116f
Intracranial EEG monitoring, 797
Intracranial hemorrhage, 92, 142, **143–152**, 144f–145f, 184f–185f
Intracranial mass lesions, **137**, 138f, 872
Intracranial pressure (ICP)
CPP and, 138
elevated, **137–140**
intracranial mass lesions and, 137
intracranial mass volume and, 138f
normal adult levels, 139
treatment for elevation of, 140t
Intralaminar neurons, 432
Intralaminar nuclei, 269, 271, 274–275, 699
Intranuclear ophthalmoplegia (INO), 550
Intraparenchymal hemorrhage, 145f, **148–150**

Intraparietal sulcus, 25, 26f, 27f, 102f, 108f
Intravenous contrast material, 86
Intraventricular extension, 149
Intrinsic hand muscles, 344–345
Ipsilateral, definition, 32
Ischemic stroke, 136, **380–384**, 612–613, 784. *see also* Infarcts
Isodense, 85, 144f, 146
Isolated nerve lesions, 279f
Isthmus, 26f, 112f
Iter, 112f. *see also* Aqueduct of Sylvius and Cerebral aqueduct
Ixodes, 157–158

J

Jaw jerk reflex, 60, 61f, 477, **484**
Jocularity, inappropriate, 851–852
Joint position sense, 35f, 71f, 278f, 672
Judgment, 852
Jugular foramen
  cerebral hemisphere drainage, 387
  CN IX and, 495
  CN X and, 497
  cranial nerve exits, 464, 499
  CT scan bone windows, 124f
  location, 123f, 129f, 465f
Jugular glossopharyngeal ganglion, 495
Jugular vagal ganglion, 497
Juvenile myoclonic epilepsy, 796
Juxtarestiform body, 664

K

Kaposi's sarcoma, 160
Kernig's sign, 10, 147t
Kernohan's phenomenon, 141
Ketogenic diet, 796
Kinetic tremor, 711
Klumpke's palsy, 346
Klüver–Bucy syndrome, 787
Kuru, 161

L

Labyrinth, 105f, 485
Labyrinthine arteries, 609
Laceration, 312
Lacunar disease, 612
Lacunar infarcts, 381, 404–405, 409f
Lacunar syndromes, 381, 382t
Lambert–Eaton myasthenic syndrome, 350
Lamina terminalis, 26f
Laminae, spinal, 269, 305
Laminectomy, 319
Language. *see also* Aphasia; Speech
  anatomy, 828f
  assessment in neurologic exam, **54–55**
  classification of disorders, 834f
  diagnosis of disorders, **829–839**
  dominant hemisphere and, 44, 826, 827–839
  neurologic exam and, 72
  processing, **827–839**
  structures involved in, 43
Language cortex, 97f
Language testing, 797
Laryngoscopy, 501
Larynx, 503
Lateral columns, 217f, 218f
Lateral corticospinal tract, 221t, **222–225**, 222f, 226f, 663
Lateral dorsal nucleus, 272t
Lateral foramina of Luschka, 132
Lateral gaze palsy, 549–550
Lateral geniculate nucleus (LGN)
  anatomy, 39f, 223f
  blood supply, 444
  description, 272t
  layers, 433f
  lesions, 441
  MRI, axial T1-weighted images, 106f
  pathways, 432–433
  visual pathways, 274, 432f
Lateral horn, spinal cord, 219
Lateral hypothalamic area, 740, 742
Lateral hypothalamic nuclei, 740
Lateral lemniscus, 488, 585
Lateral mammillary nuclei, 741, 779
Lateral medullary syndrome, 615, 623f–624f
Lateral motor systems, 220
Lateral nuclear group, 271
Lateral olfactory stria, 770
Lateral pectoral nerve, 340f
Lateral pontine lesion, 278f
Lateral posterior nucleus, 272t
Lateral preoptic nuclei, 740
Lateral recess, spinal canal, 306
Lateral rectus muscles, 99f, 106f, 530, 563f
Lateral septal nucleus, 768, 779
Lateral ventricles
  CSF and, 16
  CT image, 100f, 102f
  location, 131f
  MRI, axial T1-weighted images, 106f, 107f, 108f
  MRI, coronal T1-weighted images, 110f, 111f
  MRI, sagittal T1-weighted images, 113f
  nomenclature, 131–132
  position, 692f–693f
Lateral vestibular nucleus, 490
Lateral vestibulospinal tract, 490
Lateralization, 825–827
Laterodorsal tegmental nuclei, 593
Laughing, 606
Layers I–VI, neocortex, 29, 30f
Lead-pipe rigidity, 707
Learning, 782, 849
Left frontal lesions, 850
Legs
  important nerves, 345f
  nerve roots, 317f, 318t
Lemniscus, 22
Lens, 99f, 106f, 428
Lens-shaped biconvex hematoma, 143
Lenticular fasciculus, 704
Lenticular nucleus, 691
Lenticulostriate arteries, 114f, 373f, 409f
Leptin, 742
Lesser petrosal nerve, 495
Lethargy, 147t, 602t
Letter recognition areas, 855f
Levator palpebrae superior, 532
Level of alertness, **53–54**
Level of consciousness, 859
  assessment in neurologic exam, 53
  circuits important for, 41f
  coma and, 73, 602t
  lesions and, 591
  reticular formation in regulation of, 40
Levodopa, 709, 712, 713
Lewy bodies, 712
Lexicon, 829
Lhermitte's sign, 276
Ligamentum flavum, 305, 306f
Light reflex, pupillary, 59f. *see also* Pupils
Light–near dissociation, **545–546**, 551
Limbic cortex
  anatomy, 763, 764f
  cortical connections, 849
  herpes encephalitis in, 765f
  location, 43f
  terminology, 824f
Limbic lobes, 763
Limbic networks, 863
Limbic system, **41**
  anatomy, 37f, 763–769
  basal ganglia and, 703
  circuitry, 762f, 769t
  components, 42f, 762t, 763t
  corticoid structures, 768
  diencephalic structures, 768
  inputs, 606
  structures, 860

Limen, 766
Line bisection task, 845
Lingual nerve, 480
Lingula, 25, 26f, 112f
Lipohyalinosis, 149, 381
Lissauer's tract, 218f, 268
List generation test, 852
Listeria, 156t
Liver flap, 710
LMNs. *see* Lower motor neurons
Lobar atrophy, 871
Lobar hemorrhage, 149–150
Local seizures, 790
Localization
  comatose patients, 76
  of lesions, 97, 232, 277
  neuroanatomical clues, 8
  principles of, 825–827
Localizer images, 84f
Locked-in syndrome, 75, 79, **587**, 602t, 603, 629–630, 634f–636f
Locus ceruleus, 596
Logic, assessment in neurologic exam, **57**
Long-term potentiation (LTP), 777
Longitudinal fissure, 25
Loss of check, 673
Lou Gehrig's disease, 243
Lower motor neurons (LMNs), **231**
  anatomy, 33
  cerebellar exam and, 672
  CN XI lesions, 499
  facial weakness and lesions of, 482, 483f
  lesions of, 61
  motor exam and, 63–64
  motor system and, 220
  signs of lesions, 231t
Lucid interval, 143
Lumbar cistern, 133f
Lumbar spinal cord, 304f
Lumbar nerve roots, 22
Lumbar puncture, **161–163**
  comatose patients, 604
  ICPs and, 139
  location, 133
  meningeal irritation and, 154
  MS diagnosis and, 242
  normal-pressure hydrocephalus and, 199–200
  patient positioning, 162f
  subarachnoid hemorrage and, 148
Lumbar stenosis, 317
Lumbosacral enlargement, 22f, 217, 305, 341
Lumbosacral plexus, 22f, 23, **341f–342f**
Lumbricals, 344
Lungs, assessment in neurologic exam, 9
Luria sequencing tasks, 56, 851
Luteinizing hormone (LH), 743f, 746, 749
Luteinizing hormone deficiency, 750
Luteinizing hormone–releasing hormone (LHRH), 743f
Lyme disease, 157–158, 317, 873
Lymph nodes, assessment in neurologic exam, 9
Lymphocyte-predominant meningitis, 157, 158
Lymphocytic meningitis, 158
Lymphoma, 153, 160, 802–803, 808f–809f

M

M cells, 431
Machado–Joseph disease, 715
α_2-Macroglobulin, 874
Macula, 428, 486f
Macular sparing, 443, 443f
Magnetic gait, 44, 151, 853
Magnetic resonance angiography (MRA), 92, 95, **116–118**, 384
Magnetic resonance imaging (MRI)
  auditory canal, 491
  basic concepts, **87–93**
  commonly scanned tissues, 89t
  CT compared with, 87t
  diffusion-weighted, 250
  gadolinium contrast, 93f
  intracranial hemorrhage, 92t, 150
  MS features, 242
  neuroradiological atlas, **104–113**
  physics of excitation, 88–89, 88f
  proton density–weighted images, 91f
  radiculopathies and, 316
  T1-weighted images, 90f
  T2-weighted images, 90f
  three-dimensional surface reconstruction, 94f
  TIAs and, 379
Magnetic resonance spectroscopy (MRS), 96
Magnetic resonance venography (MRV), 95
Magnetic susceptibility, 92
Magnetoencephalography (MEG), 96
Magnocellular division of red nucleus, 663
Magnocellular layers, of lateral geniculate, 433
Malingering, **78–79**
Malleus, 485
Mammillary bodies, 27f, 100f, 106f, 110f, 112f
  inferior view, 739f
  location, 738
  median view, 739f
Mammillary region, 741
Mammillothalamic tract, 742
Mandible bone, 98f, 104f
Mandibular branches, 479
Mandibular division (CN V_3), 474
Mandibular fossa, 465f
Mania, 799–800
Marantic endocarditis, 381
Marcus Gunn pupil, **545**
Marginal branch, 25
Marginal ramus of cingulate sulcus, 102f, 103f
Marginal zone, 268
Masked facies, 713
Mass effect, 86, 137, 170
Masseter, 60f
Mastication, 60–61, 478
Mastoid air cells, 98f, 99f, 104f, 105f, 110f, 124f
Maxilla, 123f
Maxillary division (V_2), 474, 546
Maxillary sinus, 98f, 104f
Mean arterial pressure (MAP), 138
Meckel's cave, 475
Medial diencephalic memory areas, 772, 778–780, 781
Medial forebrain bundle, 740
Medial frontal micturition centers, 282
Medial geniculate nuclei (MGN), 39f, 106f, 223f, 272t, 274, 432f, 488, 585
Medial hypothalamic area, 740, 742
Medial lemniscus, 268, 586
Medial longitudinal fasciculus (MLF), 490, 549, 569f, 584, 586
Medial mammillary nuclei, 741, 779
Medial medullary syndrome, 614–615
Medial motor systems, 220
Medial nuclear group of thalamus, 271
Medial olfactory stria, 770
Medial orbital frontal gyri, 703, 763
Medial pontine syndromes, 615–617
Medial preoptic nuclei, 740
Medial rectus muscles, 99f, 106f, 530
Medial septal nucleus, 768, 779
Medial temporal lobe memory areas, 771, 777–778
Medial temporal lobe–onset complex partial seizures, 793
Medial vestibulospinal tract, 490
Median eminence, 134f, 739f, 744

Median nerve, 340f, 342–344, 342t, 353–354
Median neuropathy, 347
Medications, in H&P, 6
Mediodorsal nucleus (MD)
basal ganglia outputs, 699
cortical connections, 849
description, 273t
function, 274
limbic system and, 703, 768, 771
memory and, 780
spinothalamic projections, 269
Medulla (myelencephalon)
anatomy, 38f, 39f
brainstem and, 461
caudal, 581
cavernous angioma, 644–645, 648f
CT image, 98f
focal vascular syndromes, 614t
infarcts, 620–623, 623f–625f
lateral, 609
lesions, 278f, 279
location, 15f, 26f
medial, 609
MRI, axial T1-weighted images, 104f
MRI, coronal T1-weighted images, 110f
MRI, sagittal T1-weighted images, 112f
myelin-stained sections, 582f
nuclei, 466f
respiration control, 605
rostral, 581
rostral ventrolateral, 606
sensory loss and, 279
signs of dysfunction, 613
sleep-promoting regions, 599
vascular syndromes of, 614–615
vascular territories, 609f, 611f
visual system and, 463
Medullary pyramids, 225
Medulloblastoma, 154
Membranous labyrinth, 485
Memory
classification, 781–782, 781f
dementia and, 901–902, 904f
disorders, **780–787**
recent, **54**
remote, **54**
spatial domains, 782t
storage, 782t
structures related to, **771–780**
temporal domains, 782t
testing, 797
Memory loss
Alzheimer's disease, 874–875
causes, 785t
differential diagnosis, 784–787
head injury and, 800–801
progressive severe, 802–803, 808f–809f
recent, 804–805, 811f
Meniere's disease, 494
Meningeal layer, 126
Meningeal signs, 154
Meninges
cranial vault and, **122–128**
irritation, 147t, 154
layers, 16, 125
sensation from, 503
spaces formed by, 127
vertebral bones and, 306f
Meningioma
compression of optic chiasm, 450f–451f
foramen rotundum, 505, 507f
frontal lobes, 896f
pathology, 153
pons compressed by, 524f–525f
spinal cord compression, 291–292, 294f
visual effects, 448–449
Meningismus, 154
Meningitis
carcinomatous, 163
chronic, 872
cryptococcal, 159
CSF values in, 155t
infectious, **154–155**
viral, 158–159
Meningoencephalitis, 158
Meningovascular syphilis, 157
Menstrual irregularity, 448–449
Mental decline, 152
Mental imagery, 863
Mental retardation, 868
Mental status
assessment in neurologic exam, **50–58**, 51t, 822–823, 823t, 851
causes of changes, 866t
coma, assessment of, 73–75
disorders, **865–867**
minimal screening exam, 80t
Meralgia paresthetica, 349
Mesencephalic trigeminal nucleus, 467f, 477, 585
Mesencephalic trigeminal tract, 477, 585
Mesencephalon, 15f. *see also* Midbrain
Mesial temporal sclerosis, 795
Mesocortex, 765
Mesocortical dopaminergic pathways, 596
Mesolimbic dopaminergic pathways, 596
Mesostriatal dopaminergic pathways, 595
Mestinon (pyridostigmine), 313
Metabolic abnormalities
mental status changes and, 867
seizures and, 795
Metamorphopsia, 857
Metastases, 152, 317, 320, 324f
Metencephalon (cerebellum), 15f
Methemoglobin, 92
Meyer's loop, 433, 434f
Microadenomas, 746, 751–754
Microaneurysm of Charcot–Bouchard, 149
Micrographia, 713
Micropsia, 857
Midbrain (mesencephalon), 15f, 26f, 27f, 38f, 39f
blood supply, 612
brainstem and, 461
development, 738f
dorsal surface, 463
focal vascular syndromes (infarcts), 618t
MRI, sagittal T1-weighted images, 112f
myelin-stained sections, 577f
signs of dysfunction, 613
structure, 577
tegmentum, 100f, 106f
vascular territories, 610f
Midbrain corectopia, **546**
Midbrain–diencephalic junction, 15f, 461
Middle cerebellar peduncle
inputs, 587–588
location, 38f, 39f
MRI, axial T1-weighted images, 105f
MRI, coronal T1-weighted images, 110f
MRI, sagittal T1-weighted images, 112f
Middle cerebral artery (MCA)
angiographic images, 114f
cerebral cortex supply, 372f
circle of Willis and, 369
divisions, 372f
infarct, 402f, 403–404, 406f, 408–409, 838f
inferior division infarct, 880f, 888–890, 890f
location, 44, 45f
MRA images, 116f
MRI, axial T1-weighted images, 106f
MRI, coronal T1-weighted images, 111f
MRI, sagittal T1-weighted images, 112f
stem infarct, 405, 407–408, 410f–411f, 417f
subarachnoid hemorrhage and, 146
superior division infarct, 878f
syndromes of the territory of, 376t, 376–378
vascular territories, 371
watershed zones, 379f
Middle cervical ganglion, 228
Middle cranial fossa, 123f, 124, 125f, 465f
Middle ear, 124f
Middle frontal gyri
CT image, 100f, 101f, 102f
location, 25, 26f, 27f
MRI, axial T1-weighted images, 108f
MRI, coronal T1-weighted images, 111f
Middle hypothalamic region, 741
Middle meningeal artery, 127, 128f, 143
Middle temporal gyrus, 25, 26f, 110f
Middle temporal sulcus, 26f
Midline shift, 137, 170
Midline thalamic nuclei, 271, 273t, 592
Midsagittal sections, radiographic, 17
Migraine headaches, 9, 135–136, 451, 453, 454f
Miosis, 543, **545**, 560–561
Mitral cells, 770
Mixed spinal nerves, 305
Mixed transcortical aphasia, 835
Modality-specific association cortex, 823–827
Molecular layer, of cerebellar cortex, 658
Monocular scotoma, 441, 442f
Monocular visual disturbances, 439, 441, 442f
Mononeuropathies, 312
Mononeuropathy multiplex, 312
Monosynaptic stretch reflex, 37–38
Mood, assessment in neurologic exam, **57**
Morton's metatarsalgia, 349
Mossy fibers, 658, 776
Motion, visual analysis of, 435–436
Motor aphasia, 43
Motor areas, **28–29**
Motor basal ganglia channel, 702
Motor columns, 467
Motor exam, 51t, **63–64**, **76–77**, 80t
Motor extinction, 843
Motor findings, 853
Motor homunculi, 214, 216f
Motor impersistence, 56, 73, 853, 864
Motor-intentional neglect, 842
Motor neglect, 73
Motor neuron disease, **243**
Motor nuclei
brainstem, 33, 577
development, 466f
functional columns, 467f
spinal cord, 218f
Motor systems
brainstem and, 606
descending pathways, 226f–228f
diagram, 220f
lateral, 221ft
main pathways, **32–33**
medial, 221ft
organization, **220–222**
Motor tics, 709
Motor unit action potentials (MUPs), 351
Movement, 702–704
Movement disorders, 672, **705–712**, 706t, 718, 722f
MPTP, 715
MRI. *see* Magnetic resonance imaging
Mucormycosis, 161
Müller's muscle, 543
Multi-infarct dementia, 871
Multiple sclerosis (MS), 241–243
horizontal diplopia and, 563–564, 569f
oligoclonal bands, 163
signs and symptoms, 242t
visual loss and, 447–448
Multipolar neurons, 18
Multisystem atrophy, 714
Munchausen syndrome. *see* Factitious disorder
Muscarinic cholinergic receptors, 229, 595
Muscle spindles, 37–38, 37f
Muscle tone testing, 63–64
Muscles. *see also* Specific muscles
of articulation, 62
CT image, 98f
MRI, axial T1-weighted images, 104f
peripheral nerves, nerve roots and, 309t–311t
strength testing, 64, 65t
tone testing, 63–64
Muscular dystrophies, 314
Musculocutaneous nerve, 340f, 342–344, 342t
Myasthenia gravis, **313–314**, 350, 363
Myasthenic crisis, 314
Mycobacterium tuberculosis, 157
Mydriasis, pharmacological, **545**
Myelencephalon, 15f. *see* Medulla
Myelin sheaths, 19, 241–243
Myelitis, 277, 295–296, 298f
Myelography, 86, 328, 332f, 334f, 335f, 338
Myerson's glabellar sign, 67, 713, 853
Myocardial infarction, 381
Myoclonus, **710**
Myopathic disorders, **314–315**, 351
Myotomes, **307–308**
Mystical phenomena, 846
Myxedema coma, 749

N

Naloxone, 604
Naming, in language exam, 54, 831, 832, 835
Narcolepsy, 79, 601
Nasolabial folds, **240**
Nausea, 138, 607
Neck
assessment in neurologic exam, 9
of aneurysm, 146
muscles, 98f, 104f
pain, 320
vessels, 117f
Needle biopsy, 193
Neglect, 56, 382, 842t, 844f. *see also* Hemineglect
Neglect drawing test, 843f
Neighborhood effects, 14
Neisseria meningitidis, 156t
Neocortex
classification, 823t
layers, 29, 30f, 30t, 765
memory and, 783
visual processing, **435–438**
Neologisms, 54, 832
Neoplasms, 86, 152. *see also* Specific neoplasms
CT scans and, 86
pineal region, 570f
Neoplastic meningitis, 163
Neostriatum, 691
Nerve conduction studies, **349–351**, 350f. *see also* Electromyography (EMG)
Nerve roots, 304–337, 304f
arm, 317f, 318t
L4 compression, 329
L5 compression, 329, 330
leg, 317f, 318t
origin of, 305
peripheral nerves, muscles and, 309t–311t
radiculopathies and, 315–316
S1 compression, 327, 330f–332f

sensory loss and, 279
spinal anatomy and, **305–307**
spinal cord and, **304–337**
T1 compression, 326
Nerve and plexus syndromes, **346–349**
Nerves. *see also* Neurons; Specific nerves, functions
arm, 342–344, 342t
leg, 345t
Nervous system. *see also* Autonomic nervous system; Central nervous system; Parasympathetic nervous system; Peripheral nervous system; Sympathetic nervous system
cellular organization, **17–19**
fluid compartments of, 134f
long tracts, 264t
macroscopic organization, **14–17**
parts, 14f, 15t
projection systems, 590t
segmental organization, **304–305**
Neural tube, 14
Neuroangiography, **93–95**
Neurodegenerative conditions, 795
Neuroexam.com, 50, 52
Neurofibrillary tangles, 873–874, 904f
Neurofibroma, 317
Neurogenic bladder, 284
Neurogenic claudication, 317
Neurohypophysis, 134f, 738f
Neuroimaging. *see* Neuroradiological techniques
Neurologic differential diagnosis, **8**
Neurologic exam, **49–81**
ataxia and cerebellar disorders, 670
comatose patients, 604
dementia and, 869
flexibility, **72–73**
frontal lobes, 850
gait testing, 241
language testing, 830
neglect testing, 842–846
outline, 51t
overview, 50–52
physical exam and, **9–10**
screening use, 80, 80t
subtle weakness, 239
visual field testing, 440
Neuromodulation, 19, 593
Neuromuscular junction, **313–314**
Neurons. *see also* Specific nerves, functions
anatomy, 17–18, 18f
loss, 873–874
Neuropathic disorders, 311–312, 351
Neuropsychology testing, 822–823
Neuroradiological techniques, **83–119**, 95
angiography, **114–115**
computed tomography (CT), **98–103**
magnetic resonance angiography, **116–118**
MRI, axial T1-weighted images, **104–109**
MRI, coronal T1-weighted, **110–111**
MRI, sagittal T1-weighted, **112–113**
Neurosyphilis, 157, 545, 872–873
Neurotransmitters, 19. *see also* Specific neurotransmitters
receptors, 19
release, 229
storage, 19
systems, 592–598
Nicotinic cholinergic receptors, 595
Nodes of Ranvier, 18f, 19
Nodose vagal ganglia, 497
Nodulus, 655
Noise suppression, 861
Noncommunicating hydrocephalus, 151
Nondeclarative memory, 781–782, 863
Nondominant hemispheres, 44, **839–847**, 846–847
Nontraumatic. *see* Atraumatic
Nonverbal auditory agnosia, 838
Noradrenergic inputs to cerebellar cortex, 667
Norepinephrine, **596–597**
autonomic efferents, 229f
function, 20t
release, 229
somatic efferents, 229f
sympathetic nervous system and, 24
Normal-pressure hydrocephalus, 152, 872
Nuchal rigidity, 147, 154
Nuclei, 21, 217
Nucleus accumbens, 111f, 113f, 691, 703, 768
Nucleus ambiguus, 466f, 467f, 495, 497
Nucleus basalis of Meynert, 594, 768
Nucleus cuneatus, 39f, 267, 586
Nucleus dorsalis of Clark, 665
Nucleus gracilis, 39f, 267, 586
Nucleus of the diagonal band of Broca, 594, 768
Nucleus pulposus, 305, 306f
Nucleus solitarius, 466f, 467f, 586, 605, 606
Number recognition areas, 855f
Nystagmus, 60, 493t, 548, 551, 613, 673–674

O

Obex, 39f, 462
Ob receptors, 742
Observation, motor exam, 63
Obsessive–compulsive disorder, 782, 799
Obtundation, 602t
Obturator nerve, 345f
Occipital bone, 123f, 124f
Occipital horn, 101f, 132
Occipital lobes
adenocarcinoma, 883, 887f
cerebral cortex, 24, 454f–455f
CT image, 100f, 101f
gyri, 26f
location, 24f
MRI, axial T1-weighted images, 105f–107f
MRI, sagittal T1-weighted images, 112f, 113f
partial seizures, 792t
Occipital pole, 26f, 27f
Occipital somites, 468
Occipitotemporal cortex
association cortex (fusiform gyrus), 854, 856
gyrus, 25, 898–899, 900f
Ocular myasthenia, 313
Ocular apraxia, 858
Ocular dominance columns, **437–438**, 437f
Ocular dysmetria, 673
Oculocephalic reflex, 60f, 61, 76, 490f, 553
Oculomotor channel, basal ganglia, 702
Oculomotor nerve (CN III)
assessment in neurologic exam, 59, 536
cavernous sinus and, 546
extraocular movements, 76
extraocular muscles and, 532
function, 40t, 461t, **472–473**
location, 38f, 39f, 464
MRI, sagittal T1-weighted images, 112f
palsy, 537f
pupillary responses and, 59, 75
in situ, 533f
vestibulo-ocular reflex, 76
Oculomotor nucleus, 467f, 532, 533f, 534f, 534t, 577, 584
Oculomotor palsy, **536–538**
Odors, in seizures, 791
Olfaction, 58f, 765, **770–771**, 770f, 788, 789, 853
Olfactory bulbs, 27f, 464, 471, 770

Olfactory cortex, 763, 770, 771f
Olfactory mucosa, 770
Olfactory nerve (CN I)
anosmia and, 472
assessment in neurologic exam, 58
function, 40t, 461t, **471–472**
location, 464
Olfactory receptor neurons, 770
Olfactory sulcus, 25, 27f, 99f, 464, 770
Olfactory tract, 27f, 471, 770
Olfactory tubercle, 768, 770
Oligoclonal bands, 163, 242
Oligodendrocytes, 19
Olive, 38f, 39f. *see also* Inferior olivary nuclear complex
Olivocerebellar fibers, 667
Olivopontocerebellar atrophy, 715
Omega region of hand somatosensory cortex, 250, 252f–253f
On–off cells, 430
One-and-a-half syndrome, 550
On–off phenomena, 714
Onuf's nucleus, 282, 283t
Ophthalmic artery, 114f, 443
Ophthalmic division (V_1), 474, 546
Ophthalmoplegia, 559–560
Ophthalmoplegic migraine, 135
Ophthalmoscopic exam, 58, 75, 438
Opiates, mechanism, 271
Optic ataxia, 858
Optic canal, 464, 465f, 472
Optic chiasm
assessment in neurologic exam, 59
compression, 450f–451f
embryological development, 738f
inferior view, 739f
location, 38f
median view, 739f
MRI, axial T1-weighted images, 106f
MRI, coronal T1-weighted images, 111f
MRI, sagittal T1-weighted images, 112f
optic tract and, 431–432
Optic disc, 428, 445
Optic nerve (CN II)
blink-to-threat test, 75
CT image, 99f
function, 40t, 428, 461t, **472**
inferior view, 739f
lesions, 441
location, 26f, 38f, 39f, 464
MRI, axial T1-weighted images, 106f
ophthalmoscopic exam, 58, 75
optic tract and, 431–432
pupillary responses, 59, 75
vision assessment in neurologic exam, 58–59
visual field exam, 75
Optic neuritis, 242, **445**, 447–448
Optic radiations, 223f, **433–434**, 434f, 441
Optic tract
CT image, 100f
inferior view, 739f
lesions, 441
location, 38f, 39f, 472
MRI, axial T1-weighted images, 106f
MRI, coronal T1-weighted images, 111f
MRI, sagittal T1-weighted images, 112f
neoplasm, 452f
optic nerve and, 431–432
Optokinetic nystagmus (OKN), 60f, 548, 552–553, 853
Oral phase, swallowing, 501
Oral preparatory phase, swallowing, 501
"Orator's hand," 347f
Orbital apex, 546–547
Orbital apex syndrome, 161, **547–548**
Orbital frontal gyri
CT image, 99f
limbic system and, 42f
location, 25, 27f
MRI, axial T1-weighted images, 106f
Orbital gyri, 26f. *see also* Orbital frontal gyri
Orbital myositis, 558
Orbitofrontal lesions, 850
Orbitofrontal olfactory area, 771
Organ of Corti, 485
Organum vasculosum, 134f
Orientation, assessment in neurologic exam, **53–54**
Orientation columns, **437–438**, 437f
Orthopedic gait disorder, 241t
Osteophytes, 315t, 316, 321
Orthostatic hypotension, and dizziness, 493
Otic ganglia, 495
Otoliths, 490
Oval window, 485
Overflow incontinence, 284
Overshoot, 68f, 673, 673f
Oxytocin, 744, 746

P

P cells, 431
Pain
assessment in neurologic exam, 71
central modulation, **270–271**, 271f
migraine, 135
neck, 320
occipital, 320
posterior column pathways, 34
radicular, 276
spinothalamic pathway, 36f
Painful (antalgic) gait, 241t
Palatal myoclonus, 710
Palate elevation, 62, 502
Paleocortex, 765
Palinopsia, 44, 857
Pallidotomy, 718, 729f
Palmar interossei, 345
Palmomental reflex, 67
Palpation, 63
Palsies, 157, 232t. *see also* Specific palsies
Pancoast's syndrome, 346, 352
Panhypopituitarism, **750**, 754–756, 758f
Panic, 791, 806–807, 813f
Papez circuit, 779
Papilledema. *see also* Edema
comatose patients, 75
headache and, 196–197
increased ICP and, 139f
mass lesions and, 189
Papillitis, 445
Paracentral lobule
CT image, 102f, 103f
location, 25, 26f
MRI, axial T1-weighted images, 108f, 109f
MRI, sagittal T1-weighted images, 112f
Paracusis, 859
Parafascicular nuclei, 699
Parahippocampal cortex, 775
Parahippocampal gyrus
anatomy, 775
cingulum and, 779
components, 776t
limbic system and, 42f
location, 25, 27f, 763
memory system and, 772–776
MRI, coronal T1-weighted images, 110f
MRI, sagittal T1-weighted images, 113f
structures, 771f
Parallel fibers, in cerebellar cortex, 658
Paralysis, **232–239**. *see also* Weakness
bilateral arm, 237
bilateral arm and leg, 238–239
bilateral leg, 237–238
description, 232t
generalized, 239
unilateral arm, 234–235
unilateral arm and leg, 233–234

unilateral face and arm, 234
unilateral face, arm and leg, 232–233
unilateral facial, 236–237
unilateral leg, 235–236
Paramagnetic substances, 91–92
Paramedian branches, 609
Paramedian pontine reticular formation (PPRF), 549, 553
Paraneoplastic syndromes, 154, 243
Paranoid behavior, 833
Paraparesis or paraplegia. *see* Weakness, bilateral leg
Paraphasic errors, 54, 832
Paraplegia, 288
Parasagittal sections, radiographic, 17
Parasitic infections, **160**
Parasympathetic nervous system, 23f, 24, 228
Parasympathetic nuclei, 468, 584
Parasympathetic postganglionic neurons, 229
Paraterminal gyrus, 26f, 111f, 112f
Paratonia, 707, 853
Paraventricular nucleus, 741
Paravertebral ganglia, 228
Paravertebral sympathetic chain ganglia, 228, 543
Paresis, 157, 232t, 792. *see also* Weakness
Paresthesias, **276**, 312
Paretic gait, 241t
Parietal lobes, 24
association cortex, 215f, 840, 841, 862
cerebral cortex, 24
CT image, 102f
infarct in, 285–286, 289f
lesion-related conditions, 44
location, 24f
mental status exam and, 43, 53
MRI, axial T1-weighted images, 107f, 108f
MRI, coronal T1-weighted images, 110f
MRI, sagittal T1-weighted images, 112f, 113f
partial seizures, 792t
Parietal lobule, 837
Parietal operculum, 25, 42f, 107f
Parieto-occipital association cortex, 854
Parieto-occipital fissure (sulcus), 24f, 26f, 112f, 397f
Parieto-occipito-temporal cortex, 552
Parinaud's syndrome, 151, 551–552, 567–568
Parkinsonism
basal ganglia lesions and, 34
causes, 714–716
gait, 240t
plus syndromes, **714**
signs, 712–713
tremor, 710
Parkinson's disease, **712–716**
case study, 723–725, 729f
dopamine and, 701
idiopathic, 712–714
pathologic changes, 713f
stereotactic surgery, 718
Parotid gland, 495
Pars opercularis, frontal lobe, 26f
Pars orbitalis, frontal lobe, 26f
Pars triangularis, frontal lobe, 26f
Partial seizures, 790, 791–793, 792t
Parvocellular division, red nucleus, 663
Parvocellular layers, lateral geniculate, 432
Past medical history (PMH), **6**
Past pointing, 68
Patient H.M., 780–782
Pedicles, spinal, 305
Pedunculopontine tegmental nucleus, 593
Pellagra, 872
Pelvic exam, 10
Pelvic floor muscles, 284
Pen-and-paper tests, 843–844, 845f
Penetrating trauma, 142
Peptides, neuromodulatory function, 20t
Percussion of the spine, 316
Perforant pathway, 776
Periamygdaloid cortex, 770
Periaqueductal gray, 269, 270, 607
Pericallosal artery, 114f, 116f
Periglomerular cells, 770
Perilymph, 485
Perimesencephalic cistern, 133f
Perinatal injuries, 795
Periosteal layer, 126
Periosteum, 306f
Peripheral nerves, 22, 278, 279, 309t–311t
Peripheral nervous system (PNS)
components, 14f, **21–22**
disorders, 311–315
spinal cord and, **21–24**
Perirhinal cortex, 775
Periventricular nucleus, 740, 744
Peroneal nerve, 345f
Peroneal nerve palsy, 348–349
Perseveration, 44, 56, 851
Persistent vegetative state (PVS), 602t, 603
Pes hippocampus, 113f, 775
Petechial hemorrhage, 142, 390–392
Petit mal seizures, 794
Petrosal sinus sampling, 748, 752f
Petrotympanic fissure, 465f, 480
Petrous ridge, 99f
Petrous segment, carotid artery, 370
Petrous temporal bone, 99f, 124f, 479
Pharyngeal phase, of swallowing, 501
Pharynx, 502
Phonophobia, 147t
Phoria, 536
Phosphenes, 440t
Photophobia, 147t
Photopsias, 440t
Photoreceptors, 429
Phrase length, in language evolution, 831
Phrenic nerve, 341, 605
Physical exam. *see also* Neurologic exam
in H&P, **7**
neurologic exam and, **9–10**
parts with neurologic significance, 51t
Physiological tremor, 711–712
Pia mater, 16, 125, 126, 306f
Pick's disease, 871
"Pie in the sky" visual defect, 442
"Pie on the floor" visual defect, 442
Pill-rolling tremor, 711
Pineal body
CT image, 100f
function, 135
location, 39f, 134f
MRI, axial T1-weighted images, 106f
MRI, coronal T1-weighted images, 110f
MRI, sagittal T1-weighted images, 112f
neoplasm of, 192f
Pineal region tumors, 153
Pineal shift, 137
Pineoblastoma, 193
Pineocytoma, 570f
Pinprick assessment, 71f
Piriform cortex, 770
Pituitary adenoma, 153, **746–749**
Pituitary apoplexy, 750
Pituitary fossa, 99f, 739
Pituitary gland
anatomy, **738–739**
embryological development, 738f
endocrine functions, **743–750**
hormone actions, 745f
hormone regulation and release, 134
hypothalamus and, **737–759**
location, 129f
median view, 739f
microadenoma, 751–754

MRI, axial T1-weighted images, 105f
MRI, coronal T1-weighted images, 111f
MRI, sagittal T1-weighted images, 112f
Pituitary stalk, 106f, 111f
formation, 738–739
inferior view, 739f
median view, 739f
Plan, in H&P, **7–8**
Planes, imaging, **84**
Planes of section, **16–17**
Plantar response, 64, 66f, 67f, 77f, 240
Plaque, 904f
Plasmapheresis, 314
Plastic rigidity, 707
Plegia, 232t
Plexus syndromes, **346–349**
Polymyositis, 314
Polyneuropathy, 312
Polyopia, 857
Pons
anatomy, 38f, 39f, 581
brainstem and, 461
compression, 524f–525f
CT image, 99f
facial colliculus, 481f
hypertensive hemorrhage and, 149
lesions, 671
location, 15f, 26f, 463
medial, 609
MRI, axial T1-weighted images, 105f
MRI, coronal T1-weighted images, 110f
MRI, sagittal T1-weighted images, 112f
myelin-stained sections, 580f–581f
sensory loss and, 279
superior dorsolateral, 612
vascular syndromes of, 615–616t, 617
vascular territories, 610f, 611f
Pontine artery, 612
Pontine basis, 256f, 552, 617
Pontine hemorrhage, 619
Pontine micturition center, 282, 607
Pontine nuclei, 588, 665
Pontine pupils, 544
Pontine region, 613, 617. *see also* Pons
Pontine tegmentum, 581, 858
Pontocerebellar fibers, 665
Pontomedullary junction, 15f
Pontomesencephalic junction, 15f, 461
Positional vertigo, 61f, 493
Positional vertigo testing, 61f, 493t
Positron emission tomography (PET), 96, 812
Post-ictal deficits, 793
Postcentral gyrus
CT image, 102f, 103f
infarct in, 285–286, 289f
location, 25, 26f, 27f, 214
MRI, axial T1-weighted images, 108f, 109f
MRI, sagittal T1-weighted images, 113f
primary somatosensory cortex and, 28
Postcentral sulcus, 26f
Postcommissural fornix, 779
Postconcussive syndrome, 142
Posterior cerebral artery (PCA)
angiographic images, 114f, 115f
brainstem and, 607, 608f
cerebral cortex supply, 372f
circle of Willis and, 370
course of branches, 371f
infarcts, 182f–183f, 396f–397f
location, 45f
MRA images, 116f
MRI, coronal T1-weighted images, 110f
MRI, sagittal T1-weighted images, 113f
supply for, 46
syndromes of the territory of, 377t, 378
vascular territories, 372
watershed zones, 379f
Posterior choroidal artery, 115f
Posterior clinoid process, 465f, 739
Posterior column–medial leminiscal system, 34, 35f, 264, 265f, **267–268**, 462f, 463f. *see also* Dorsal columns
long tracts, 586
nuclei, 463, 586
somatotopic organization, 267, 268f
spinal cord, 217f
Posterior commissure, 540
Posterior communicating artery (PComm)
angiographic images, 114f, 115f
circle of Willis and, 369
location, 45f, 607
MRA images, 116f
subarachnoid hemorrhage and, 146
Posterior cord syndrome, 281, 281f
Posterior fossa
components, 123f, 124, 125f
CT scan bone windows, 124f
location, 465f
sagittal view, 655f
Posterior horn, spinal cord, 216, 217f
Posterior hypothalamic nucleus, 741
Posterior hypothalamic region, 741
Posterior hypothalamus, 743
Posterior inferior cerebellar artery (PICA)
angiographic images, 115f
cerebellar blood supply, 668
cerebellar infarcts, 669
location, 45f, 46, 607
MRA images, 116f
spinal blood supply and, 219f
Posterior limb, of internal capsule, 33f
Posterior lobes, of cerebellum, 654
Posterior longitudinal ligament, 305–306
Posterior orientation, 17
Posterior parietal lobules, 270
Posterior pituitary, 738, 739f
Posterior spinal artery, 46, 219
Posterolateral disc herniations, 306
Posterolateral fissure, 654
Posteromedial orbitofrontal cortex, 848
Postganglionic neurons, 228
Postinfectious encephalitis, 158–159
Postsynaptic neurons, 18f, 19
Posttraumatic headaches, 136
Posttraumatic syringomyelia, 293
Postural instability, 713
Postural tremor, 673, 710, 711, 712
Posturing
comatose patients, 77f
decerebrate, 77, 180–181, 606
decorticate, 77, 188
extensor, 77, 180–181, 606
flexor, 77, 188, 606
motor pathway damage and, 68
reflexes, 77
subtle dystonic, 240
UMN lesions and, 231
Pott's disease, 156
Pre-Bötzinger complex, 605
"Preacher's hand," 347f
Precentral gyrus
CT image, 102f, 103f
infarct, 244–249, 246f–247f, 248f–249f, 252f–253f
location, 25, 26f, 27f, 33f, 214, 215f
MRI, axial T1-weighted images, 108f, 109f
MRI, sagittal T1-weighted images, 112f, 113f
primary motor cortex and, 28
Precentral sulcus, 27f
Precision finger tap, 68f, 672f
Precommissural fornix, 779
Precuneus, 25, 26f, 112f
Prefrontal association cortex, 43f
Prefrontal channels, 702

Prefrontal cortex, 671, 848–849. *see also* Prefrontal lobes
Preganglionic neurons, 228, 229
Preganglionic sympathetica, 218f
Premotor cortex, 43f, 215f
Preoccipital notch, 26f
Preoptic area, 740, 768
Prepontine cisterns, 133f
Presenilin 1 gene, 874
Pressure cones, 181
Presynaptic cells, 18f
Presynaptic terminals, 18f, 19
Pretectal area, 432, 540, 862
Prevertebral ganglia, 228
Primary auditory cortex, 28f, 43f, 488
Primary central nervous system lymphoma, 160
Primary CNS tumors, 152
Primary dementias, 868
Primary fissure, 112f, 654
Primary generalized epilepsy syndromes, 796
Primary idiopathic torsion dystonia, 707
Primary lateral sclerosis, 243
Primary motor cortex
  feedback loops, 34f
  lateral view, 215f
  location, 28f, 33f, 43f, 214, 215f
  precentral gyrus and, 28
  terminology, 823t, 824f
Primary olfactory cortex, 770
Primary progressive aphasia, 871
Primary sensation, 71
Primary sensory neurons, 34
Primary somatosensory cortex, **28–29**, 823t, 824f
  information to, 270
  lateral view, 215f
  location, 28f, 36f, 43f, 214, 215f
  sensory loss and, 278f
  VPL neurons and, 268
Primary visual cortex. *see also* Visual cortex
  anatomy, 435f
  blood supply, 444
  location, 28f, 43f, 434
  optic radiations and, **433–434**
  syndromes, 855
Primary visual pathways, 442f
Priming, memory and, 782
Primitive neuroectodermal tumor (PNET), 193
Primitive reflexes, 853
Prions, 161, 872
Progressive multifocal leukoencephalopathy (PML), 159
Progressive supranuclear palsy (PSP), 715
Projectile vomiting, 138
Projection systems
  cholinergic, 594f
  dopaminergic, 595f
  histaminergic, 598f
  noradrenergic, 596f
  serotonergic, 597f
Prolactin, 743f
Prolactin deficiency, 750
Prolactin release–inhibiting factor (PIF), 743f
Prolactin-releasing factor (PRF), 743f
Pronator drift, **239**
Proprioception
  definition, 264
  description, 34
  inputs, 553
  posterior column pathways, 35f
  spatial analysis and, 841
Prosencephalon (forebrain), 15f, 738f
Prosody, 831
Prosopagnosia, 44, 856
Proton density, 88, 89, 91
Proton density–weighted MRI imaging, 91f
Proton relaxation times, 88
Proverbs, in mental status testing, 852, 852t
Pseudobulbar affect, 243, 502, 607
Pseudobulbar crying, 606
Pseudobulbar laughter, 606
Pseudobulbar palsy, 502
Pseudotumor cerebri, 136, 563f
Psychiatric disorders, 603–604, **798–800**, 865
Psychiatric pseudodementia, 871–872
Psychogenic amnesia, 786
Psychogenic paralysis, 79
Psychotic disorders, 859
Pterional craniotomy, 163
Pterygoid process, 98f
Pterygopalatine ganglion, 480
Ptosis, 543, **546**, 560–561
Pulmonary failure, 872
Pulses, assessment in neurologic exam, 10
Pulvinar
  attention and, 862
  description, 272t
  function, 274, 432f, 433
  MRI, axial T1-weighted images, 106f
  MRI, coronal T1-weighted images, 110f
Pupillary abnormalities, **543–546**, 613
Pupillary constrictor muscles, 473, 532, 540, 541f
Pupillary dilator muscles, 532, 543
Pupillary light reflex, 432
Pupillary muscles, 542f
Pupils
  Adie's myotonic, 546
  "blown," 141
  coma and, 605t
  common abnormalities, 544f
  dilation, 542f
  dilation lag, 543
  impaired constriction, 543
  large irregular, 551
  oculomotor palsies and, 536
  pontine, 544
  responses, 59, 75, 75f, 540–541
  unilateral dilation, 543
Pure motor hemiparesis, **232–233f**, 251, 253–256, 255f–256f, 381, 382t. *see also* Weakness, unilateral
Pure sensory stroke, 382t
Pure word deafness, 838
Purkinje cells, 658
Purposeful withdrawal, 77
Putamen
  atrophy, 728f
  basal ganglia and, 691
  CT image, 100f, 101f
  MRI, axial T1-weighted images, 107f
  MRI, coronal T1-weighted images, 110f, 111f
  MRI, sagittal T1-weighted images, 113f
Pyknolepsy, 796
Pyramidal cells, 775
Pyramidal decussation
  anatomy, 32
  brainstem and, 581
  location, 33f, 38f, 223f, 463
  spinal cord, 218f
  tract fibers and, 225
Pyramidal tracts, 225
Pyramids, 38f, 39f, 104f, 223f, 463
Pyridostigmine (Mestinon), 313

Q

Quadrantanopia, 433, 434, 442f, 451, 453
Quadrigeminal cistern, 133, 133f
Quadriparesis. *see* Weakness, bilateral arm and leg
Quadriplegia. *see* Weakness, bilateral arm and leg
Qualia, 863

R

Radial nerve
  arm function, 342–344
  injury to, 355–356
  location, 340f
  motor functions, 342t
  thumb and, 344
Radial neuropathy, 346–347
Radiation therapy, 153
Radicular artery, 219f
Radicular pain, 276
Radiculopathy, **315–317**
  C8, 325–326
  C4–C5, 321
  common causes, 316t
  definition, 312
  L4–L5, 329
  thoracic, 326
Radiography, 17
Radiosurgery, stereotactic, 718
Rami communicantes, 229f
Random letter test, 864
Raphe nuclei, 597, 790
Rapid alternating movements, 68
Rapid foot tapping, 64f
Rapid hand movements, 64f
Rathke's pouch, 738f
Reading
  assessment in neurologic exam, 54
  difficulty, 831, 832–833
  hemineglect and, 845
  inability, 883, 887f
  processing, 829
Recall, immediate, 782
Recent memory, 54, 783
Receptive aphasia, 43
Receptive fields, 429, 438f
Recognition, 898–899
Recruitment patterns, on electromyography, 351
Rectum, assessment in neurologic exam, 10
Recurrent artery of Heubner, 114f, 373
Recurrent laryngeal nerve, 500
Red desaturation, on visual testing, 58f, 445
Red glass tests, 536, 537f
Red nucleus, 577, 587, 663
Reduplicative paramnesia, 847
Reflex arcs, 37–38
Reflex stick figure, 67f
Reflex sympathetic dystrophy, 312
Reflexes. *see also* Specific reflexes
  assessment in neurologic exams, 51t
  comatose patients, **77–78**
  eye movement, 548
  minimal screening exam, 80t
  motor exam and, 63–64
  spinal cord lesions and, 67t
  testing, **64–68**
  UMN lesions and, 231
Refractive errors, on visual testing, 440t
Regeneration, axonal, 312
Reinforcement, for eliciting reflexes, 66
Release phenomenon, 440, 858
Religious phenomena, 846
REM-off cells, 599
REM-on cells, 599, 601
REM (rapid eye movement) sleep, 598–599
REM-waking-on cells, 601
Remote memory, 54, 783
Renal failure, 872
Repetition
  assessment in neurologic exam, 54
  impaired, 831, 832, 882–883, 885f–886f
  preserved, 881–882, 884f
Repetitive stimulation, 350
Repetiton time (TR), 88
Reptiles, CNS, 16f
Respiration, 605, 606f
Respiratory arrest, 605
"Rest or digest" response, 23f
Restiform body, 656
Resting tremor, 710, 712
Restraint, in frontal lobe function, 849
Reticular formation
  anatomy, 588–589f
  ascending systems, 591f
  basal ganglia outputs, 699
  eye movements and, 550
  location, 37f
  nuclei in, 40
  pontomesencephalic, 590–591, 592f
Reticular nucleus, of thalamus, 273t, 275–276, 704
Reticulospinal tracts, 222, 228f
Retinal artery occlusion, 444, 446
Retina, **428–431**, 428f, 430f
Retinotopic map, 28, 434f
Retrobulbar neuritis, 445
Retrochiasmal lesions, 441
Retrograde amnesia, 54, 783, 783f
Retrolisthesis, 315t
Retropulsion, 713
Review of systems (ROS), **6**
Rexed's laminae, 217f
Rheumatic chorea, 708
Rhinal sulcus, 25, 27f, 763, 775
Rhinencephalon, 770
Rhombencephalon (hindbrain), 15f, 738f
Romberg test, 69–70, 70f
Right frontal lesions, 850
Right-way eyes, 552–553
Right–left confusion, **55**
Rigidity, **706–707**, 712
Rinne test, 491
Rods, 429
Rolandic epilepsy, 796
Rolandic sulcus. *see* Central sulcus
Romberg test, 673
Roof nuclei, of cerebellum, 658
Root, 304–337, 304f
Root reflexes, 44, 67, 853
Rostral interstitial nucleus of the MLF, 550
Rostral intralaminar nuclei, 273t, 275, 592
Rostral medulla, 463, 581
Rostral nucleus solitarius, 482, 497
Rostral orientation, 16f
Rostral spinocerebellar tracts, 665, 667
Rostral ventral medulla (RVM), 270–271
Rostrum, of corpus callosum, 25
Round window, 485
Rubral tremor, 673, 711
Rubrospinal tract, 221t, 226f

S

Saccadic eye movements
  assessment in neurologic exam, 60f, 853
  description, 548
  frontal eye fields and, 552
  pseudocoma and, 79
  slow, 673
Saccular aneurysm, 146
Saccule, 485
Sacral radicular arteries, 219f
Sacral spinal cord, 304f
Sacral nerve roots, 22
Sacral parasympathetic nucleus, 229, 282, 283t
Sacral sparing, 281
Saddle anesthesia, 318
Sagittal plane, 17f
Sagittal sinus, **387**
Scala tympani, 485
Scala vestibuli, 485
Scalp, layers of, 122f
Scanning speech, 674
Schaffer collaterals, 776
Schizophrenia, 798–799
Schwann cells, 19
Schwannomas, 153, 317, 492, 508–509, 510f–511f, 512–513, 515f
Sciatic nerves, 341f, 345f
Sciatic neuropathy, 348, 358–359, 360f–361f
Sclera, 539
Scotomas
  altitudinal, 444f
  central, 445, 447
  definition, 439, 440t
  monocular, 441
  right eye, 446

Scout images, in neuroimaging, 84f
Screening, brief exam, 80
Screening test, language, 835
Secondary dementias, 868
Secondary somatosensory area, 43f, 215f, 270
Seizures
amygdala and, 787
auditory hallucinations, 859
causes, 795t
classification, 790f
epilepsy and, **790–798**
hippocampal sclerosis, 809–812, 814f–816f
ischemic stroke and, 382
memory loss and, 785
wrong-way eyes and, 552
Selective attention, 839, 850, 860
Self-audible bruits, 858
Self-monitoring, in frontal lobe function, 863
Sella turcica, 739
Semicircular canals, 124f, 485, 486f
anatomy, 489–490
Semicoma, 602
Semilunar ganglion, 475
Senile plaques, 873–874
Sense of direction, 846
Sensitization, in memory function, 782
Sensorimotor cortex, 97f
Sensorimotor stroke, 382t
Sensory aphasia, 43
Sensory columns, 467
Sensory exam
comatose patients, **76–77**
components, 51t, **70–72**
minimal screening exam, 80t
Sensory homunculus, 214
Sensory inputs, 220. *see also* Somatosensory systems
Sensory loss, **277–279**
CN VI function, 479
glove and stocking pattern, 312
nerves in the arm, 342t
sensory level, 71, 280, 288
Sensory neglect, 73, 842–843
Sensory neurons
fiber types, 267t
injury, 361
spinal cord, 216
Sensory nuclei, 466f, **467f**, 577
Septal nuclei, 111f, 594
Septal regions, coronal sections, 766f–767f
Septic emboli, 381
Septum pellucidum
CT image, 101f, 102f
location, 26f
MRI, axial T1-weighted images, 107f
MRI, coronal T1-weighted images, 110f, 111f
Sequencing tasks, **56–57**, 56f, 57f, 851, 896f
Serotonergic pathways, 699
Serotonin, 20t, **597**
Setting-sun sign, 551
Sexual function, **282–285**, 283f
Sexual lubrication, 284–285
Shadow artifacts, on CT scans, 98f
Shifting cognitive sets, in frontal lobe function, 849–850
Shingles, 317
Shivering, 606
Shy–Drager syndrome, 715
Sigmoid sinuses, 128, 129f, 387
Signal enhancement, in attention, 861
Silent plantar, **240**
"Simian hand," 347f
Similarities, on mental status exam, 852t
Simple cells, 437
Simultanagnosia, 858
Simultaneous stimulus, 44
Single photon emission computerized tomography (SPECT), 96
Sinus rectus, 387
Skew deviation, 539
Skill learning, 782
Skin, 98f, 104f, 105f
Skull bone, 105f
Skull foramina, **464–466**, 465f, 466t
Skull fractures, 179f, 510, 514f
Skull shape, 853
Sleep
brainstem circuits and, 600f
definition, 602t
disorders, 601
memory loss and, 787
paralysis, 79
stages, 599f
Sleep-promoting regions, 599
Sleep–wake cycle, 598–601
Slow phase, nystagmus, 60
Slow saccades, 673–674
Small-vessel infarcts, 381
Smooth pursuit, 59f, 60, 548, 553
Sneezing, 606
Snellen notation, 438
Snout reflexes, 44, 67, 853
Social and environmental history (SocHx/EnvHx), **6**
Somatic efferents, 228, 229f
Somatic motor nuclei, 468, 584
Somatic sensation, 34
Somatiform disorders, 602t, 604
Somatization disorder, **78–79**
Somatomedins, 746
Somatosensory systems, **34–37**, 264–269. *see also* Sensory loss
cortex, **270**
definition, 264
homunculi, 216f
Somatostatin, 743f
Somatotopic maps
illustration, 28, 29f
internal capsule and, 225
spinal trigeminal nucleus, 477f
Somatotopic organization, 214, 267, 268f, 269
Spasmodic dystonia, 707
Spastic bladder, 284
Spastic catch, **240**
Spastic gait, 240t
Spatial akinesia, 843
Spatial analysis, in nondominant hemisphere function, 840
Special senses, 469
Special somatic efferents (SSEs), 466–469
Special somatic sensory nuclei, 469
Special somatic sensory (SSA) inputs, 585
Special visceral afferents (SVAs), 466–469, 586
Special visceral sensory fibers, 480
Speech. *see also* Aphasia; Language
abnormalities, 674
decreased fluency, 831
motor areas, 827–828
muscles involved in, 62
nonsensical, 879, 880f
spontaneous, 54
Sphenoid bone, 123f
Sphenoid sinus, 105f, 111f, 112f, 739
Sphenopalatine ganglion, 480
Sphincteromotor nucleus of Onuf. *see* Onuf's nucleus
Spin echo (SE), 88
Spinal accessory nerve (CN XI)
disorders, 500
function, 40t, 461t, **499**
location, 38f, 39f, 464
sternocleidomastoid muscles and, 62
trapezius muscles and, 62
Spinal accessory nucleus, 467f, 499, 581, 584
Spinal arterial plexus, 219, 219f
Spinal canal, 290f–291f, 305
Spinal column, 306f

Spinal cord
anatomy, 22f, 26f, **216–219**, 217f
anterior (ventral) commissure, 268
anterior cord syndrome, 281f
anterior lesion, 298f
arterial supply, 219f
ataxia and lesions of, 671
blood supply, **44–46**, 45f, **219–220**
central canal, 131f
central cord syndrome, 280f, 281f
cervical, myelin-stained sections, 583f
composition, 21f
cross section, 22f
damage, 67
demyelination, 298f
diagnosis of dysfunction, 277t
embryonic, 15f
hemicord lesion, 280f
hyperintensity on MRI, 298f
injury, 288
laminae, 217t
lesions, **276–277**
location, 14f
lumbar, 218f
meningiomas, 292–293, 294f
MRI, sagittal T1-weighted images, 112f
myelin-stained sections, 218f
nerve roots and, **304–337**, 304f
nuclei, 217f, 217t
pathways, 268f
PNS and, **21–24**
posterior cord syndrome, 281f
reflexes and lesions in, 67t
Rexed's laminae, 217f
sacral, 218f
sensory loss and, 279
spinal canal and, 305
subacute combined degeneration, 872
syringomyelia, 295f
thoracic, 218f
transverse cord lesion, 280f
Spinal cord–medulla junction, 98f, 104f
Spinal cord syndromes, **279–282**, 280f–281f
Spinal muscular atrophy, 243
Spinal nerve root, 304–337, 304f
Spinal nerves, 14f, 22, 66t, 306f
Spinal shock, 277, 288
Spinal somatosensory systems, 475t
Spinal stenosis, 315t, 316–317
Spinal trigeminal nucleus, 466f, 467f, 475, 477
Spinal trigeminal tract, 477
Spine
assessment in neurologic exam, 9
degenerative disorders of, 315t
head trauma and, 142
pain on percussion of, 316
surgical approaches, **318–319**
Spinocerebellar pathways, 665, 666f
Spinomesencephalic tract, 269
Spinoreticular tract, 269
Spinothalamic tract, **268–270**, 586
Spinous processes, 305, 306f
Spiral CT angiography (CTA), 95
Spiral ganglion, 485, 487
Spirochetes, 157
Splenium, of corpus callosum, 25
Spondylolisthesis, 315t
Spondylolysis, 315t
Spondylosis, 315t
Spreading, of reflexes, 66
Stage curtain sign, 502
Stance, assessment in neurologic exam, 70
Stapedius, 479
Stapes, 485
Staring spells, 794t, 809–812, 814f–816f
Static encephalopathy, 868
Static tremor, 711
Status epilepticus, 602t, 603, 794
Stellate (inferior cervical) ganglion, 228
Steelle–Richardson–Olszewski syndrome, 715
Stereognosis, 71–72, 72f
Stereotactic surgery, 163, 193, **717–718**
Sternocleidomastoid (sternomastoid) muscles, 62, 499
Strabismus, 536
Straight-leg raising test, 316
Straight sinus
cerebral hemisphere drainage, 387
location, 129f
MRI, axial T1-weighted images, 106f
MRI, sagittal T1-weighted images, 112f
Strength testing, 64f, 79
Streptococcus, 156t
Stretch reflex, **37–38**
Stria medullaris, 789–790
Stria of Gennari, 435f
Stria terminalis, 742, 768, 789
Striate cortex. *see* Primary visual cortex
Striatonigral degeneration, 715, 726, 728, 730f–731f
Striatum, 691, 698, 700f
Striosomes, 699
Stroke, **380–384**, 383t, 612–619, 784. *see also* Infarcts
Stupor, 602t
Styloid process, 98f, 124f
Stylomastoid foramen, 124f, 464, 465f, 479
Stylopharyngeus muscle, 495
Subacute combined degeneration of the spinal cord, 872
Subacute sclerosing panencephalitis, 159
Subarachnoid hemorrhage, 145f, **146–148**, 188, 190f
Subarachnoid space, 127, 128
Subclavian artery, 45f, 118f
Subclavian vein, 45f
Subcommissural organ, 134f
Subcortical dementias, 868
Subcortical lesions, 382
Subcortical structures, 829
Subdural empyema, 156
Subdural hematoma, **143**, 144f, 164–166, 166f, 171f–173f
Subdural space, 127
Subfalcine herniation, **142**
Subfornical organ, 134f
Subgaleal hemorrhage, 150
Subiculum, 113f, 772, 775, 778, 779
Submandibular ganglion, 480
Suboccipital craniotomy, 163
Substance P, 701
Substantia innominata, 111f, 768
Substantia nigra, 579f, 581, 697, 731f
pars compacta, 595, 697
pars reticulata, 697, 698, 699f
Subthalamic fasciculus, 705
Subthalamic nucleus, 695
Suck reflexes, 44, 67, 853
Sulci, 24
Sulcus limitans, 466, 577
Summary, in H&P, 7
Superconducting quantum interference device (SQID), 96
Superficial middle cerebral vein, 387
Superficial peroneal nerve, 345f
Superficial cortical vein, 386
Superior anastomotic vein of Trolard, 387
Superior articular processes, 305
Superior cerebellar artery (SCA)
angiographic images, 115f
brainstem and, 607
cerebellar blood supply, 668
decussation of, 587
infarcts, 617, 669, 676–677, 678f–679f
location, 45f
MRA images, 116f
MRI, coronal T1-weighted images, 110f
Superior cerebellar peduncles, 39f, 110f, 587, 656
Superior cervical ganglion, 228, 543

Superior colliculus
attention and, 862
basal ganglia outputs, 699
brainstem and, 577
CT image, 100f
eye movements and, 551
location, 39f, 463
MRI, axial T1-weighted images, 106f
MRI, coronal T1-weighted images, 110f
visual attention and, 432
Superior frontal gyrus
CT image, 100f, 101f, 102f, 103f
location, 25, 26f, 27f
MRI, axial T1-weighted images, 107f, 108f, 109f
MRI, coronal T1-weighted images, 111f
Superior frontal sulcus
CT image, 102f, 103f
location, 25, 26f, 27f
MRI, axial T1-weighted images, 108f, 109f
Superior glossopharyngeal ganglion, 495
Superior hypophysial arteries, 744
Superior laryngeal nerve, 497
Superior medullary velum, 39f
Superior oblique muscles, 530
Superior olivary nuclear complex, 488, 585
Superior orbital fissure, 464, 465f, 473, 475
Superior orientation, 17
Superior parietal lobule, 25, 26f, 27f, 103f, 108f, 109f
Superior petrosal sinus, 129f, 387
Superior rectus muscle, 99f, 106f, 530
Superior sagittal sinus
cerebral hemisphere drainage, 386f
CT image, 101f, 102f
location, 129f
MRI, axial T1-weighted images, 106f, 107f, 108f
MRI, coronal T1-weighted images, 110f, 111f
Superior salivatory nucleus, 467f, 480, 585
Superior tarsal muscle, 543
Superior temporal gyrus, 25, 26f, 110f
Superior temporal sulcus, 25, 26f
Superior thalamic radiation, 223f
Superior vagal ganglion, 497
Superior vestibular ganglion, 490
Superior vestibular nucleus, 490
Supplementary motor area (SMA), 43f, 215f
Suprachiasmatic nuclei, 741, 742
Supraclinoid segment, of carotid artery, 370
Supramarginal gyrus, 25, 26f
Supraoptic nuclei, 741
Supraoptic recess, 131f
Supraoptic region, 741
Suprapineal recess, 131f, 151
Suprascapular nerve, 340f
Supratentorial cavity, 126
Supratentorial dura mater, 475
Surgical approaches, to the spine, **318–319**
Suspended sensory loss, 280–281
Sustained attention, 860, 864, 865
Swallowing, 501, 606
Swinging flashlight test, 59f, 445, 447, 545
Sylvian fissure
cerebral cortex, 24
CT image, 100f, 101f
limbic system and, 42f
location, 24f, 26f
MRI, coronal T1-weighted images, 110f, 111f
Sylvian point, 114f
Sylvian triangle, **114f**
Sympathetic nervous system, 23–24, 23f, 228
Sympathetic postganglionic neurons, 229
Sympathetic trunk, 228, 566f
Synapses, 18f, 19
Syncope, cardiac, 380
Syndenham's chorea, 708
Syndrome of inappropriate antidiuretic hormone (SIADH), 749
Synkinesis, 483–484
Syntax, 829, 831
Syringomyelia, 293, 295f
Systemic lupus erythematosus (SLE), 708–709

T

T1-weighted images, **104–113**
axial, **104–109**
coronal, **110–111**
description, 89, 90f
sagittal, **112–113**
T2-weighted images, 89, 90f, 91
Tabes dorsalis, 157
Tabetic gait, 241t
Tactile extinction, 60, 71–72, 72f, 842
Tactile neglect, 842
Tactile response test, 843
Taenia solium, 160
Tandem gait, 70, 673
Tardive dyskinesia, 707
Taste
assessment in neurologic exam, 61f
central pathways, 481f
CN VII and, 480f
cranial nerves and, 502
decreased, 510
vagus nerve and, 497
Tectorial membrane, 485
Tectospinal tracts, 221t, 222, 228f
Tectum, 112f, 463, 577, 862
Tegmental area, 595, 596
Tegmental nuclei, 593
Tegmentum, 552, 577, 615, 617
Telencephalon, 15f
Temperature sensation, 36f, 71f
Temporal arteritis, 136–137
Temporal bone, 123f, 143, 510, 514f
Temporal branch, of trigeminal nerve, 479
Temporal craniotomy, 163
Temporal horn, 99f
Temporal lobes
amnesia, 781
bilateral lesions, 781
bilateral medial lymphoma, 802–803, 808f–809f
cerebral cortex, 24
CT image, 98f, 99f, 100f, 101f
lesion-related conditions, 44
location, 24f
MRI, axial T1-weighted images, 105f, 106f
MRI, coronal T1-weighted images, 111f
MRI, sagittal T1-weighted images, 113f
partial seizures, 792t
patient H.M., 780f
Temporal poles, 27f, 42f, 111f, 763
Tensilon test, 313, 363
Tension-type headache, 136
Tentorial incisura, 126
Tentorial notch, 126, 127f
Tentorium cerebelli
anatomy, 126
CT image, 100f
location, 126f, 129f
MRI, axial T1-weighted images, 105f, 106f
MRI, sagittal T1-weighted images, 112f, 113f
tentorial notch and, 127f
Terminal autonomic ganglia, 228
Terminal tremor, 711

Tetraparesis. *see* Weakness, bilateral arm and leg
Tetraplegia. *see* Weakness, bilateral arm and leg
Thalamic fasciculus, 663, 699, 704
Thalamic hemorrhage, 552
Thalamic intralaminar nuclei, 590t, 592
Thalamic lacunes, 382
Thalamic nuclei, 272t–273t, 849
Thalamic reticular nucleus, 271
Thalamic somatosensory radiations, 268, 278
Thalamic system, in attention, 861
Thalamocortical projections, 37f
Thalamoperforator artery, 115f, 373
Thalamotomy, 718
Thalamus, **271–276**
anatomy, 37f, 38f, 39f
basal ganglia outputs and, 703f
bilateral lesions, 591
bilateral medial infarcts, 804–805, 811f
blood supply, 374f, 612
coronal section, 696f–697f
cortex and, 275f
CT image, 100f, 101f
gray matter in, 21
horizontal section, 694f
hypertensive hemorrhage and, 149
internal capsule and, 697f
lacunar infarction, 286–287, 290f
language and, 829
location, 15f, 26f
median view, 739f
mediodorsal nucleus of, 771
motor system and, 220
MRI, axial T1-weighted images, 106f, 107f
MRI, coronal T1-weighted images, 110f
MRI, sagittal T1-weighted images, 112f, 113f
noncortical inputs to, 274f
nuclear divisions, 272f
pathways, **34–37**
patterns of sensory loss, 278f
position, 692f–693f
spatial relationships, 690f
Thecal sac, 305
Thenar eminence, 344
Thermoregulation, 743
Thiamine, 604
Third-nerve palsy, 146
Third ventricle
CSF and, 16
CT image, 100f
embryological development, 738f
hypothalamic sulcus and, 738
lateral ventricles and, 132
location, 131f
MRI, axial T1-weighted images, 106f, 107f
MRI, coronal T1-weighted images, 110f
Third ventriculostomy, 152
Thirst, 742
Thoracic nerve roots, 22
Thoracic spinal cord, 304f
Thoracolumbar division, 24. *see also* Sympathetic nervous system
Thrombosis, 380, 612, 618, 638f–639f
Thumb, nerve supply, 344, 344f
Thymectomy, 313–314
Thymoma, 313
Thyroid gland, 746
Thyroid-stimulating hormone (TSH), 743f, 746, 748
Thyroid-stimulating hormone deficiency, 750
Thyrotropin-releasing hormone (TRH), 743f
Thyroxine (T4), 746
Tibial nerve, 345, 345f
Ticks, 157–158
Tics, **709–710**
Tight junctions, 133
Tinnitus, 492, 858
Tissue plasminogen activator (t-PA), 383
Todd's paresis, 792
Tongue muscles
assessment in neurologic exam, 62–63
functions, 503
protrusion, 62f
protrusion testing, 499f
UMN and movement of, 500
weakness, 500
Tonic contractions, 791
Tonic phase, 793
Tonotopic representations, 28, 485
Tonsillar herniation, 142, 181, 184f–185f
Top-of-the-basilar syndrome, 618, 641–642, 646f–647f
Topographical organization, 28
Torcula of Herophili, 387
Torsional eye movements, 530
Torticollis, 707
Tourette's syndrome, 709
Toxic disorders, 867
Toxins
heavy-metal, 873
seizures and, 795
vertigo and, 494
Toxoplasma gondii, 159–160
Toxoplasmosis, 159–160, 719, 722f
Traction, 312
Tracts, white matter, 22
Transcortical aphasias, 834–835
Transient global amnesia, 785
Transient ischemic attacks (TIAs), **379–384**, 444, 626–627
Transient loss of consciousness, 380
Transient neurologic episodes, **379–380**, 380t
Transitional cortex, 765
Transsphenoidal approach, in pituitary surgery, 163, 747, 753
Transtentorial herniation, **140–141**, 181
Transverse cord lesions, 280f
Transverse gyri of Heschl, 28
Transverse myelitis, 159, 242
Transverse processes, 305, 306f
Transverse sections, radiographic, 17
Transverse sinus, 129f, 387
Trapezius muscles, 62, 499
Trapezoid bodies, 488
Trauma, cranial, 75t. *see also* Head trauma
Traumatic hemorrhage, 143
Traumatic subarachnoid hemorrhage, **148**
Traumatic tap (lumbar puncture), 162, 163
Tremor, **710–711**
classification, 711t
intention, 673
postural, 673
rubral, 673
surgery for, **718**
Treponema pallidum, 157
Trigeminal ganglion, 475
Trigeminal lemniscus, 476
Trigeminal motor nucleus, 478, 584
Trigeminal nerve (CN V)
corneal reflexes, 76
disorders, 478
facial asymmetry, 76
facial sensation, assessment in neurologic exam, 60–61
function, 40t, 461t, **474–478**
grimace response, 76
location, 38f, 39f
mastication assessment in neurologic exam, 60–61
muscles of articulation and, 62
pathways, 476f
Trigeminal neuralgia, 478
Trigeminal neuromas, 492, 508–509, 510f–511f
Trigeminal nuclear complex, 585
Trigeminal nuclei, 469, 475

Trigeminal somatosensory systems, 475t, 476f
Trigeminal tract, 218f
Trigeminothalamic tract, 477
Trigone, 132. *see also* Atrium
Triiodothyronine (T3), 746
Triple flexion, 77f, 78
Trochlea, 530
Trochlear nerve (CN IV)
  cavernous sinus and, 546
  extraocular muscles and, 59–60, 530
  function, 40t, 461t, **472–473**
  location, 38f, 39f, 464, 535f
Trochlear nuclei, 467f, 533, 534f, 581
Trochlear palsy, **538–539**, 538f
Truncal ataxia, 68
Tuberal region, 741
Tuber cinereum, 738, 739f
Tuberculous meningitis, 156
Tuberomammillary nucleus, 597–598
Tufted cells, 770
Two-point discrimination, 71f
Tympanic membrane, 485

U

"Ulnar claw," 347f
Ulnar groove, 348
Ulnar nerve, 340f, 342–344, 342t, 356–357
Ulnar neuropathy, 347–348
UMNs (upper motor neurons), 33
Uncal herniation, 181, 184f–187f
Uncinate fasciculus, 664, 788
Unconscious movements, 79
Uncooperative patients, 72
Uncus, 27f, 42f, 140–141, 763, 768
Unimodal association cortex, 41, 43f, 823–825, 824f
Unipolar neurons, 19
Unsteady gait, 241
Upgaze, 550, 551, 567–568, 570f
Upper brainstem projection systems, 861
Upper extremities, examination of, 63f, 64f, 65t
Upper motor neurons (UMNs), 33, **231**
  cerebellar exam and, 672
  CN VI control, 478
  facial weakness and lesions of, 482, 483f
  head turning and, 499
  lesions, 61
  motor exam and, 63–64
  motor system and, 220
  signs of lesions, 231t
  tongue movement and, 500
Urethral reflex, 282–283
Urethral sphincter, 282
Urge incontinence, 284
Urinary bladder function
  anatomy, **282–285**
  control pathways, 282f
  incontinence, 44, 152, 199–200, 284f
  nuclei and nerve roots for, 283t
  urinary retention, 284
  urinary urgency, 284
Utilization behavior, in frontal lobe function, 851
Utricles, 485

V

Vagal nerve stimulators, 796
Vagal trigone, 39f, 463, 585
Vagus nerve (CN X)
  disorders, 500
  function, 40t, 461t, **496–497**
  gag reflex and, 62, 76
  location, 38f, 39f, 464
  muscles of articulation and, 62
  palate elevation and, 62
  pathways, 498f
Valvular disease, and stroke, 381
Variable resistance, 79
Varicella-zoster virus, 159, 317
Vascular dementia, 871
Vascular headache, 135
Vascular malformations, 150
Vascular territories
  brainstem, 607, 608f–611f
  cerebellum, 668f
  language areas, 832f
  vertebrobasilar, 614–619
Vasogenic edema, 135
Vasopressin, 743f, 744, 746
Vegetative state, 603
Veins of Rosenthal, 387
Venous angioma, 150
Ventral amygdalofugal pathways, 742, 789
Ventral anterior nucleus (VA), 272t
Ventral cochlear nucleus, 467f, 487, 488, 585
Ventral columns, 217, 217f
Ventral commissure, spinal cord, 268
Ventral horn, spinal cord, 216, 217f, 218f
Ventral lateral nucleus (VL), 272t, 274, 663
Ventral medial nucleus, 272t
Ventral nerve roots, 22, 216, 218f
Ventral orientation, 16, 16f
Ventral pallidum, 703, 768
Ventral posterior lateral nucleus (VPL), 268, 269, 272t, 273, 278
Ventral posterior medial nucleus (VPM), 272t, 278, 477, 482
Ventral spinocerebellar tracts, 665, 667
Ventral striatal pathways, 702
Ventral striatum, 691, 768
Ventral tegmental area, 703
Ventricles
  anatomy, 131f
  brain, 14
  CSF and, **128–133**
  locations, 132t
Ventriculoperitoneal shunt, 152, 191, 196
Ventrolateral preoptic area, 599
Ventromedial nucleus, 741
Verbal apraxia, 837
Verbal memory, 782
Vergence, eye movements, 548, 550
Vermis, 654, 657, 662f, 663, 685f
Vertebrae, fracture, 288, 290f–291f
Vertebral arches, 306f
Vertebral artery
  angiographic images, 115f
  brainstem and, 607
  circle of Willis circulation and, 369, 370f
  CT image, 98f
  dissection, **385**
  location, 44, 45f
  MRA images, 116f, 117f
  MRI, axial T1-weighted images, 104f
  origin, 118f
  spinal blood supply and, 219f
Vertebral bodies, 305, 306f, 319
Vertebral bones, 306f
Vertebral dissection, 613, 620–621, 623f–624f
Vertebral foramen, 305, 306f
Vertebral stenosis, 613
Vertebrobasilar infarct, 494
Vertebrobasilar ischemia, 494, 612t
Vertebrobasilar system, 146
Vertebrobasilar vascular disease, 612
Vertical diplopia, 538
Vertical eye movement, 715
Vertical gaze, 61, 551
Vertiginous gait, 240t
Vertigo, 61, 492, 493t
Vestibular ganglia, 667
Vestibular ganglia of Scarpa, 490
Vestibular neuritis, 494
Vestibular nucleus, 466f, 467f, 489–491, 489f, 585, 657f, 658, 667
Vestibular sense, 61, 841
Vestibular tract, 489f

Vestibule, 485, 486f
Vestibulo-ocular reflex (VOR), 61, 76, 490, 553, 673–674
Vestibulocerebellum, 664
Vestibulocochlear nerve (CN VIII)
  dizziness and, 492–494
  function, 40t, 461t, **484–491**
  hearing and, 61, 491–492
  location, 38f, 39f, 464
  MRI, axial T1-weighted images, 105f
  vestibular sense and, 61
Vestibulospinal tract (VSTs), 221t, 222, 227f
Vibration sense, 35f, 71f, 79
Vigilance, 864
Viral encephalitis, 158
Viral infections, **158–161**
Viral meningitis, 158–159
Visceral afferents, 586
Visceral motor nuclei, 468
Visceral sensory columns, 469
Vision
  acuity, 58, 438
  assessment in neurologic exam, 58–59
  "blurred," 439
  comatose patients, 74t
  concentric loss, 443
  impairment, 139, 390–392, **438–440**, 440t, 442f, 447–448, 504–505, 506f–507f
  migraines and, 451, 453, 454f
  monocular loss, 441
  processing disorders, 854t, 855
  processing pathways, 436f, 854t
  progressive loss of, 196–199
  spatial analysis and, 841
Visual association cortex
  blood supply, 443
  extrastriate regions of, 436
  lesion-related conditions, 44
  location, 43f
  seizures in, 44
  visual processing, 854–859
Visual cortex. *see also* Primary visual cortex
  accommodation response and, 540
  CT image, 101f
  infarcts, 897f
  lesions, 441
  MRI, axial T1-weighted images, 106f, 107f
Visual extinction, 59, 842
Visual fields
  assessment in neurologic exam, 58f, 75, 438, 441
  bitemporal defects, 432
  comatose patients, 74t
  concentric deficits, 139
  contralateral cut, 833
  defects in, 441–443
  homonymous defects, 432
  inputs, 29
  localization of defects, **440–443**
  monocular defects, 432
  normal, 429f
  peripheral loss, 196
  retinotopic map, 434f
  testing of, 440–441
Visual mental imagery, 855
Visual neglect, 842
Visual objects in space, 840
Visual reorientation, 857
Visual-spatial analysis, 840, 846
Visual-spatial deficits, 875
Visual-spatial memory, 782
Visual system, **427–457**. *see also* Vision
Vital signs, 9
Vitamin B_{12}, 872
Vitreous humor of eye, 99f, 106f
Vocal cords, 500–501, 516, 517–518, 519f
Vocal tics, 709
Voice, disorders of, 500–501
Voiding reflex, 282
Vomiting, 138, 606
Von Economo's encephalitis lethargica, 715
Vulnerable zone, in spinal cord blood supply, 220

W

Wada test, 95, 797, 812, 838
"Waiter's tip" pose, 346f
Wallenberg's syndrome, 615
Wallerian degeneration, 312
Watershed territories, 832f
Waxy rigidity, 707
Weakness, **232–239**
  bilateral arm, 237
  bilateral arm and leg, 238–239
  bilateral leg, 237–238
  descriptors of, 232t
  generalized, 239
  LMN lesions and, 231
  unilateral arm and leg (brachiocrural plegia or paresis), 233–234
  unilateral arm (brachial monoparesis or monoplegia), 234–235, 244–245
  unilateral face, arm, and leg (hemiparesis or hemiplegia), 232–233
  unilateral face and arm (faciobrachial paresis or plegia), 234, 249–250, 252f–253f
  unilateral facial, 236–237
  unilateral leg, 232–233, 245–246
  unilateral leg (crural monoparesis or monoplegia), 235–236
Weber test, 491
Wechsler memory scale test, 805, 812
Werdnig–Hoffman disease. *see* Spinal muscular atrophy
Wernicke–Korsakoff syndrome, 784
Wernicke's aphasia, 43, 827, 832–833, 845, 879, 880f
Wernicke's area, 43, 43f, 97f, 827
"What?" and "Where?" streams of visual processing, 854
White matter
  cerebellar, 656
  function, **21–22**
  localization, 21f
  MRI, axial T1-weighted images, 105f
  network connections, 772
White rami communicantes, 543
Wilson's disease, 10, 707, 715, 873
Wisconsin Card Sorting Test, 849–850
Withdrawal, from painful stimulus, 76
Witzelsucht, 851
Word generation tasks, 852
Working memory, 782, 783, 849, 863
Wrist drop, 347f
Writer's cramp, 707
Writing, 54, 831, 832–833, 845
Wrong-way eyes. *see* Eye movements

X

X-ray imaging, 84–85
Xanthochromic CSF, 162
Xenon regional cerebral blood flow mapping (Xe rCBF), 96

Y

Yawning, 606

Z

Zona incerta, 705
Zygomatic arch, 123f
Zygomatic branch, of facial nerve, 479